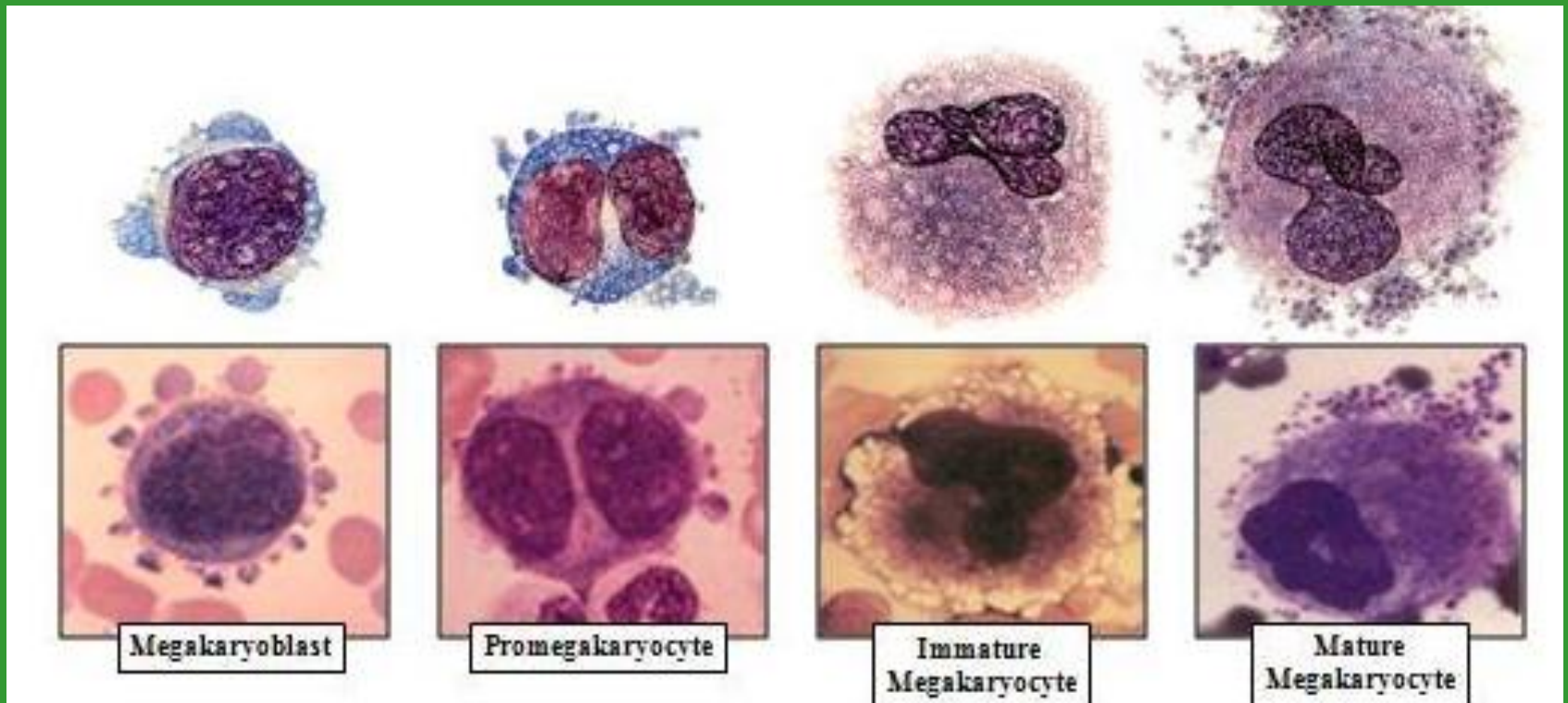


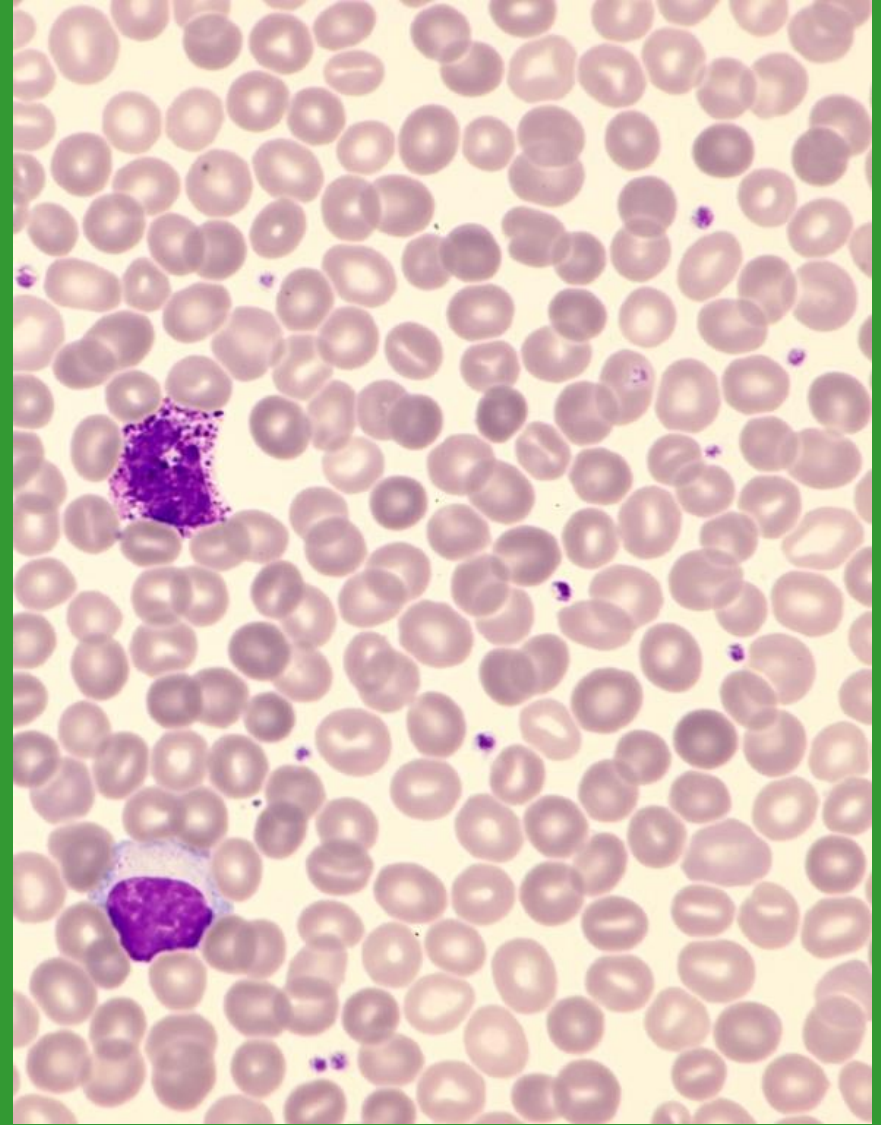
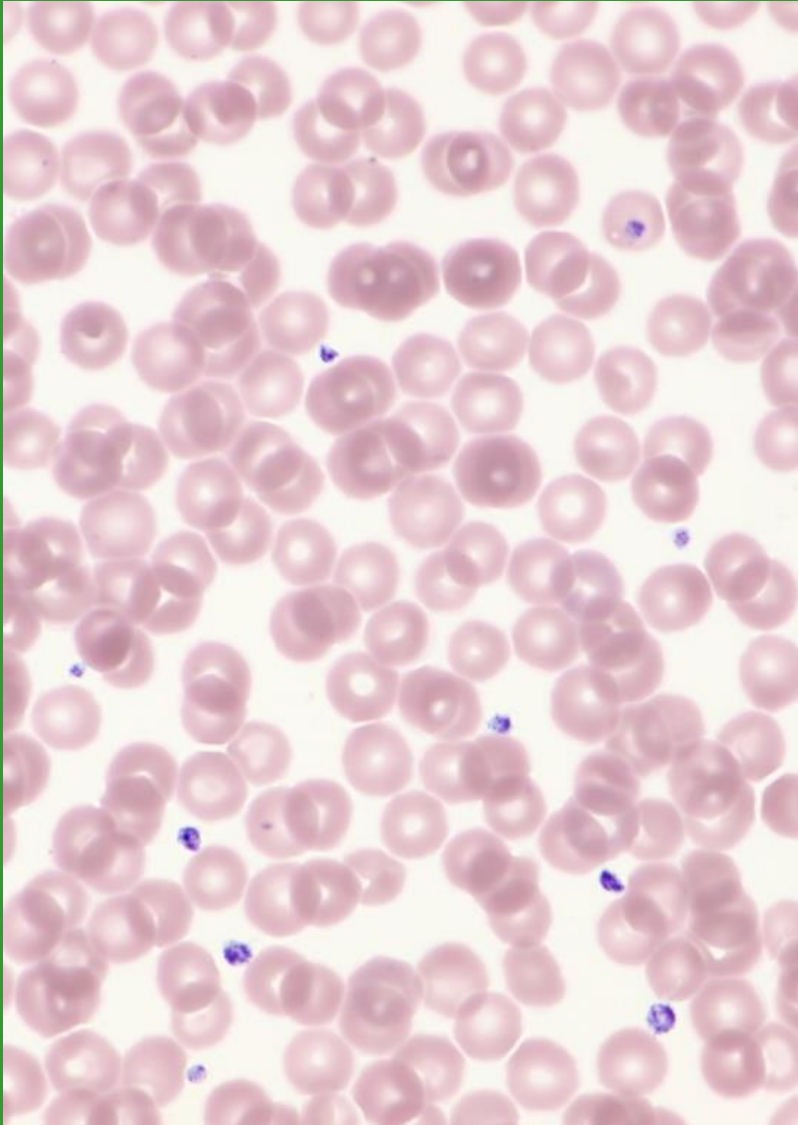
Morfologie trombocytů

Bourková L., OKH FN Brno

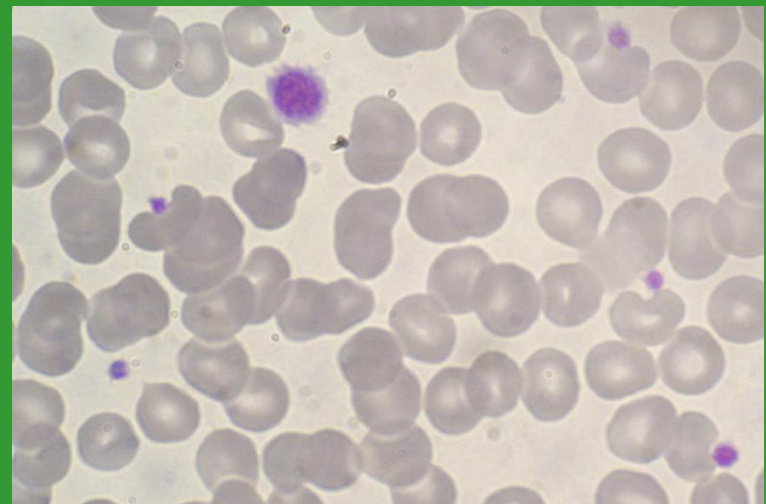
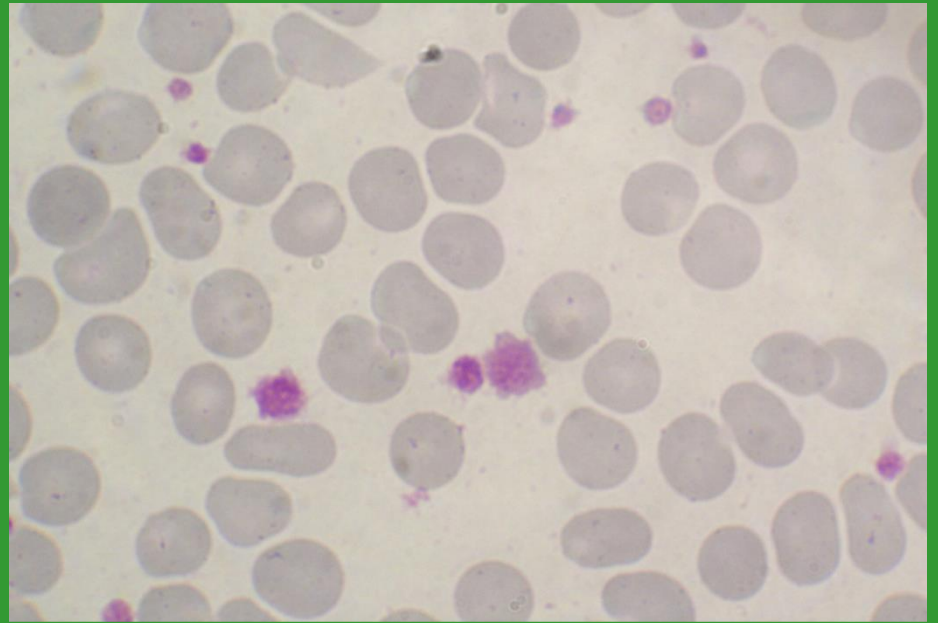
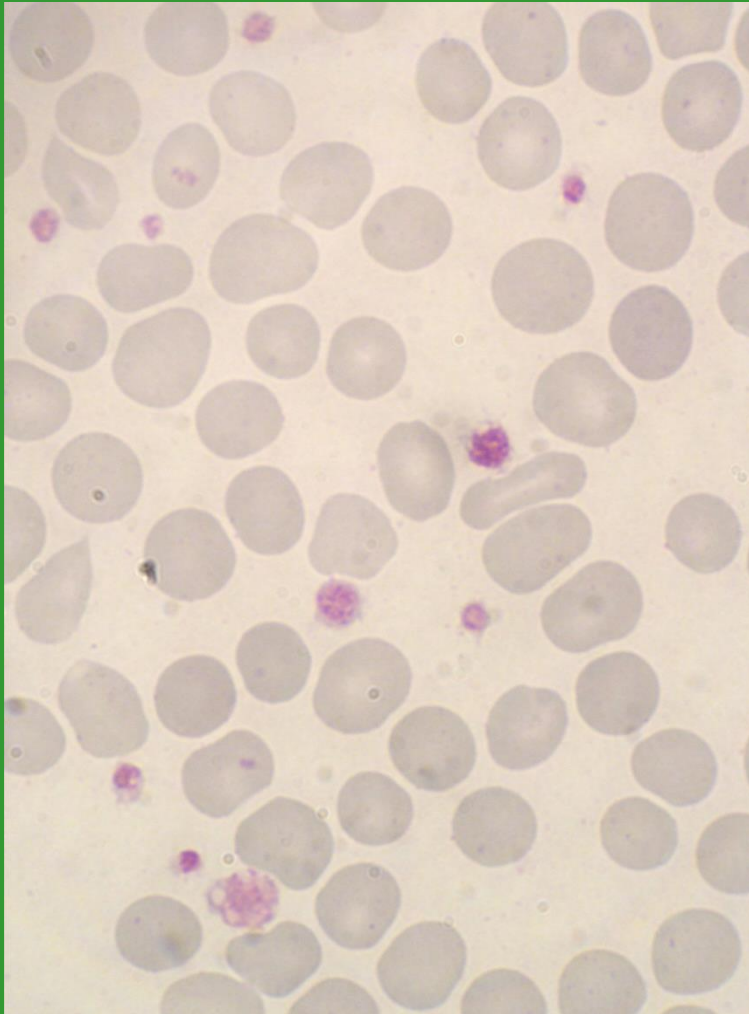
Příklad vývojových stádií megakaryocytů



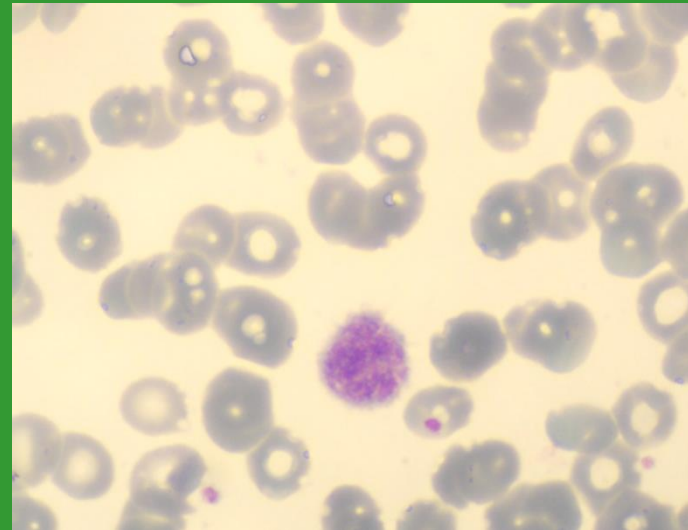
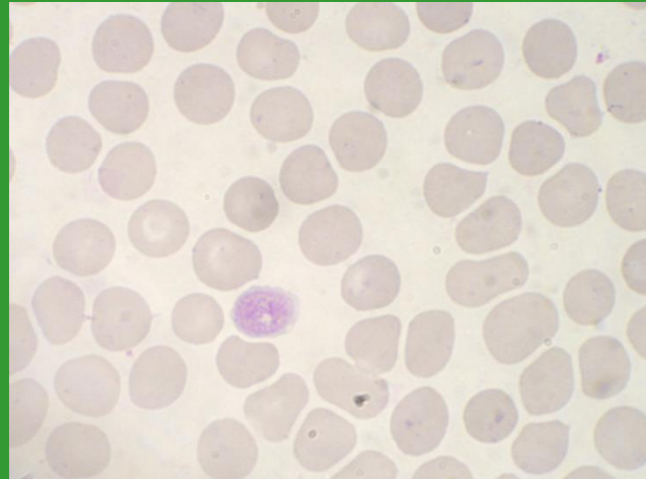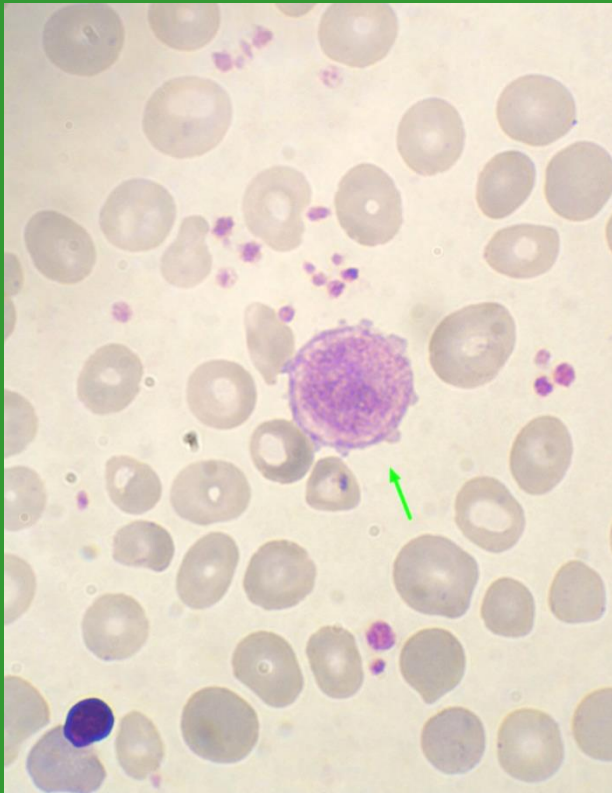
Fyziologické trombocyty



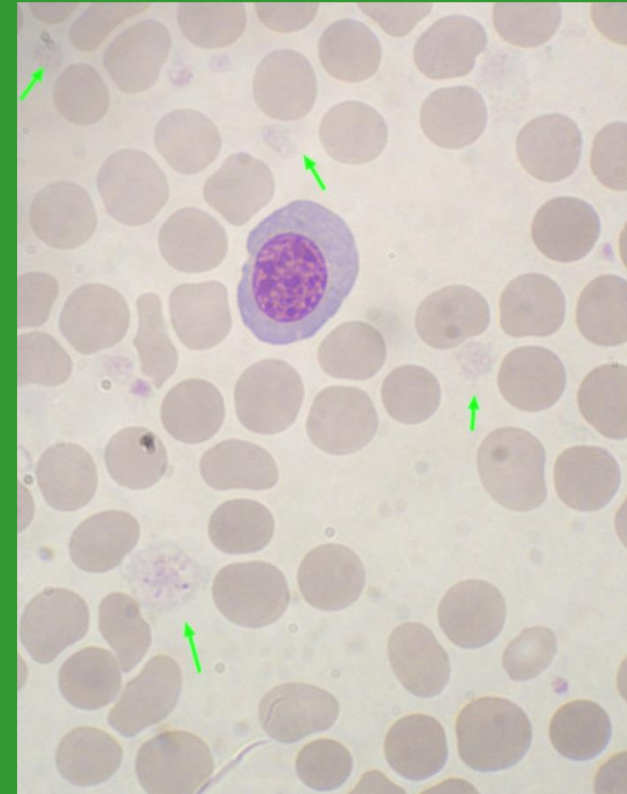
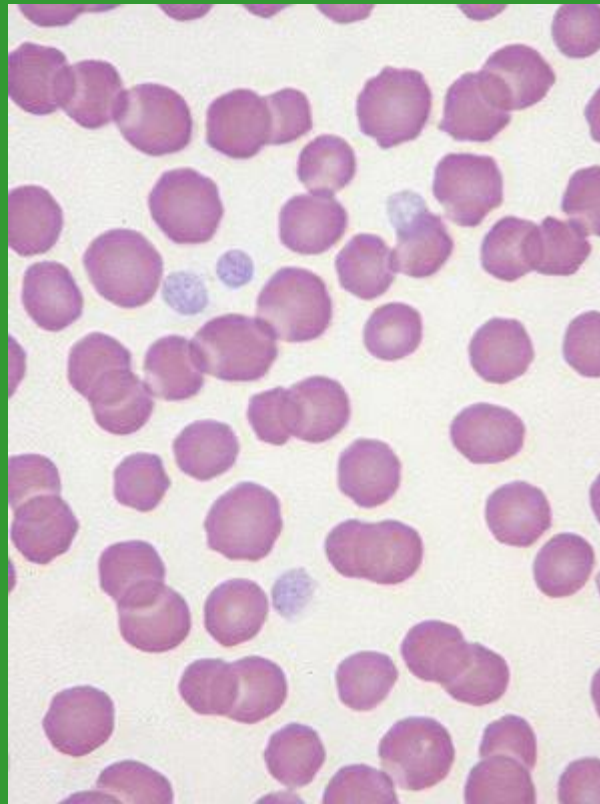
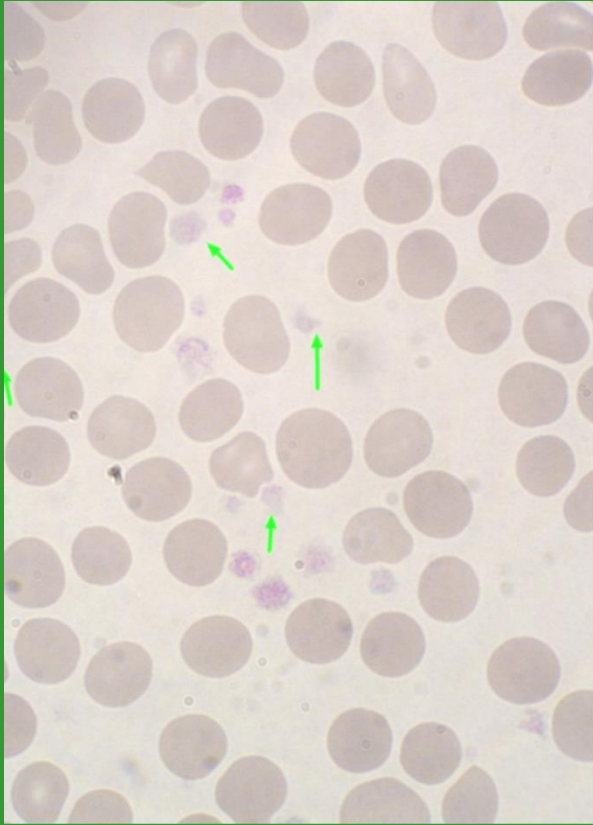
Anizocytóza trombocytů



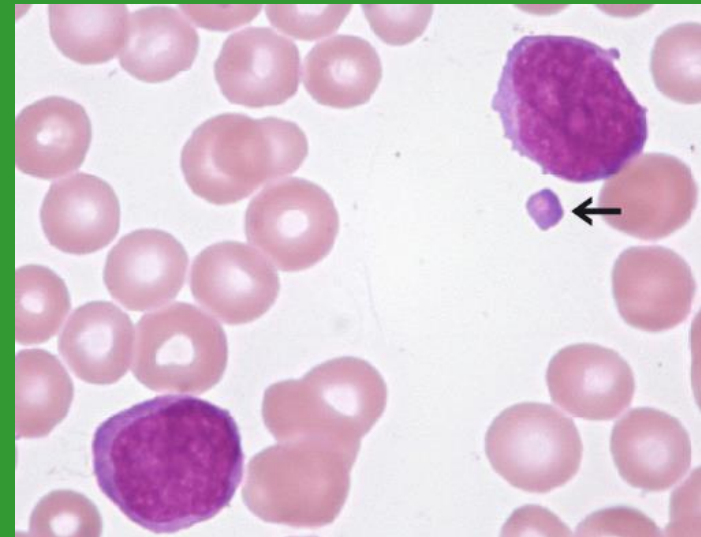
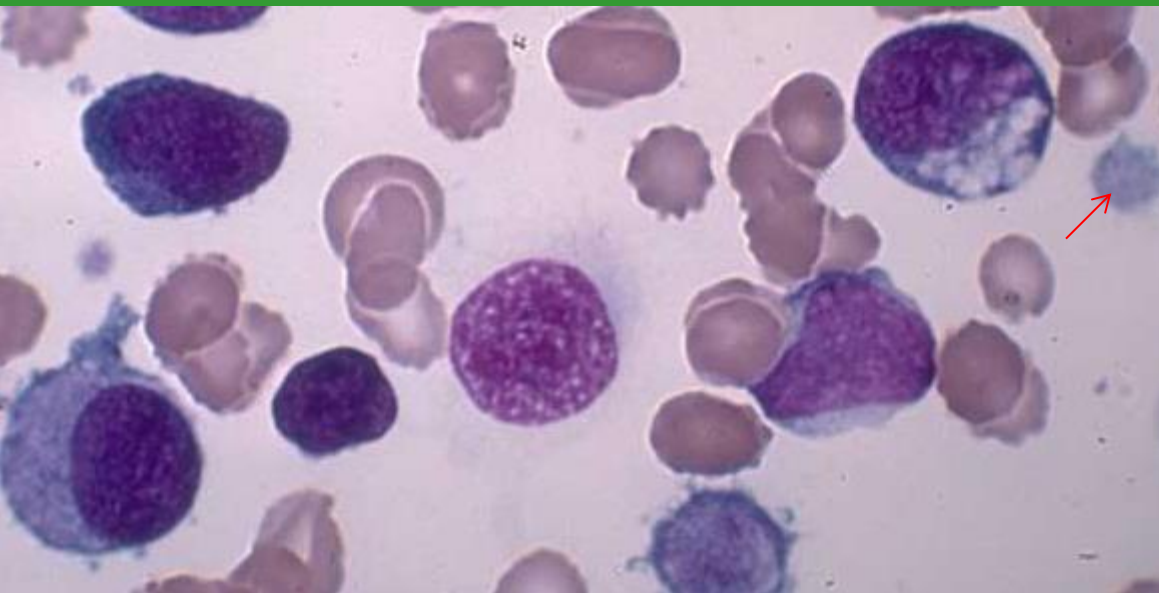
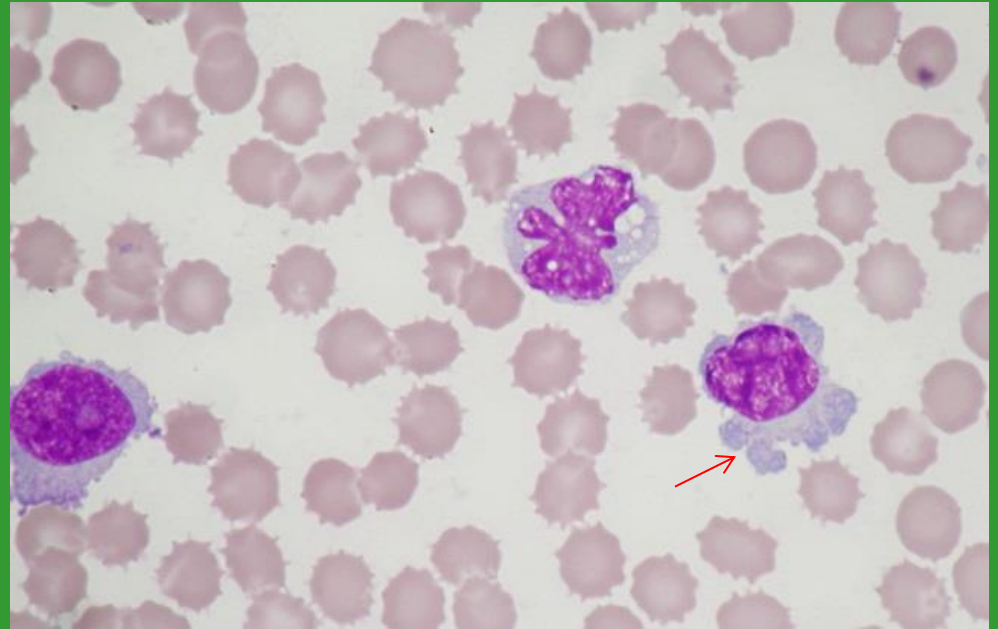
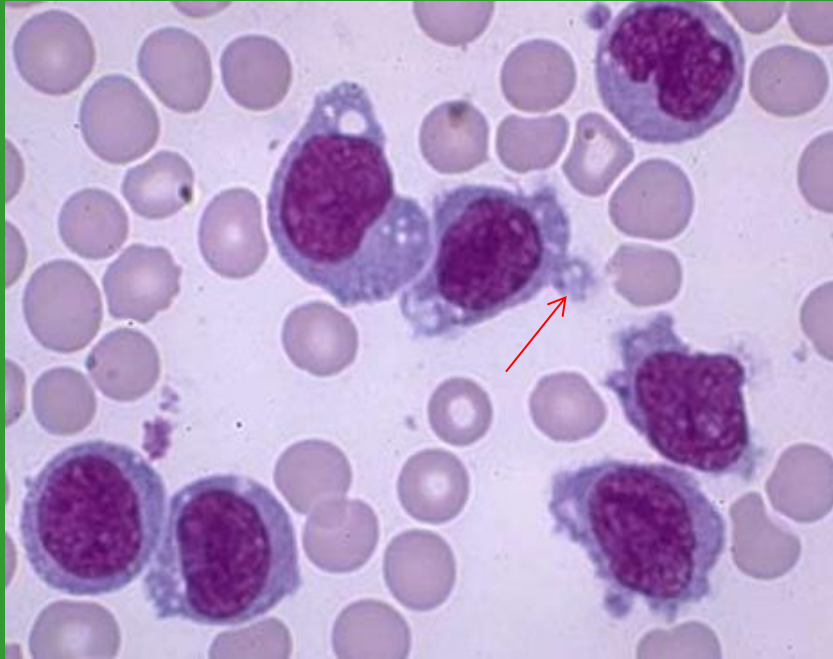
Makrotrombocyty – gigantické trombocyty



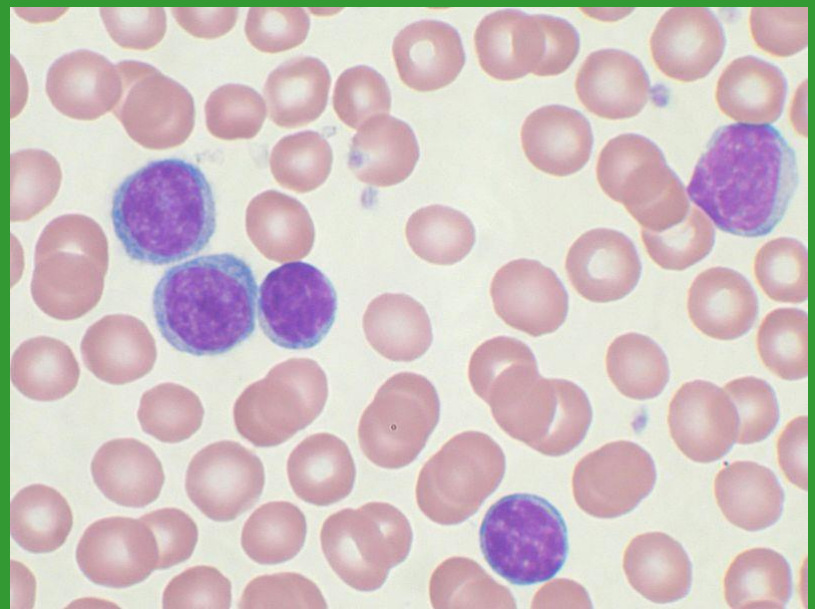
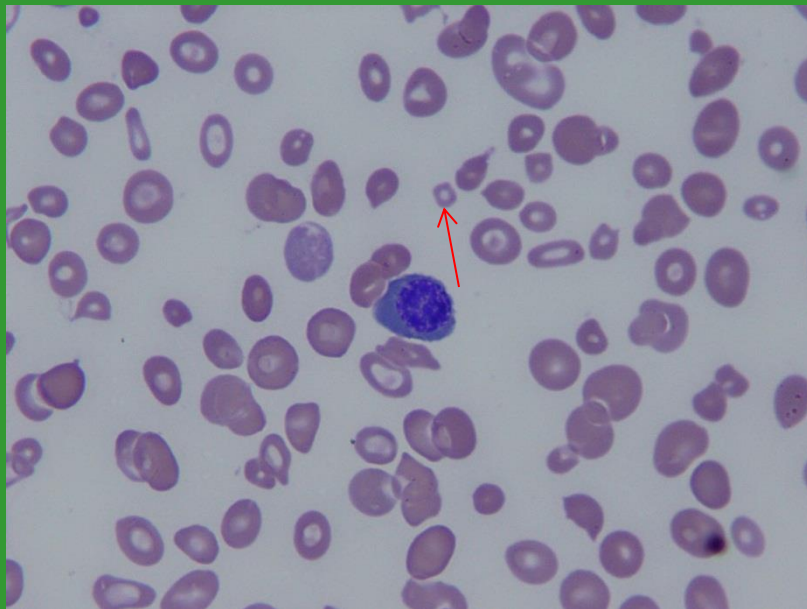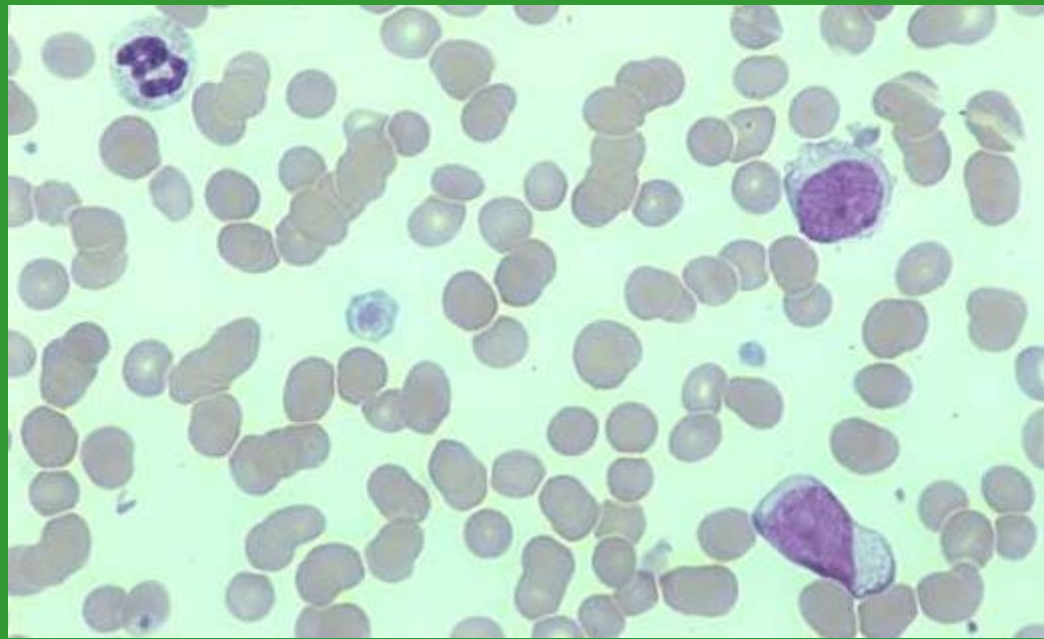
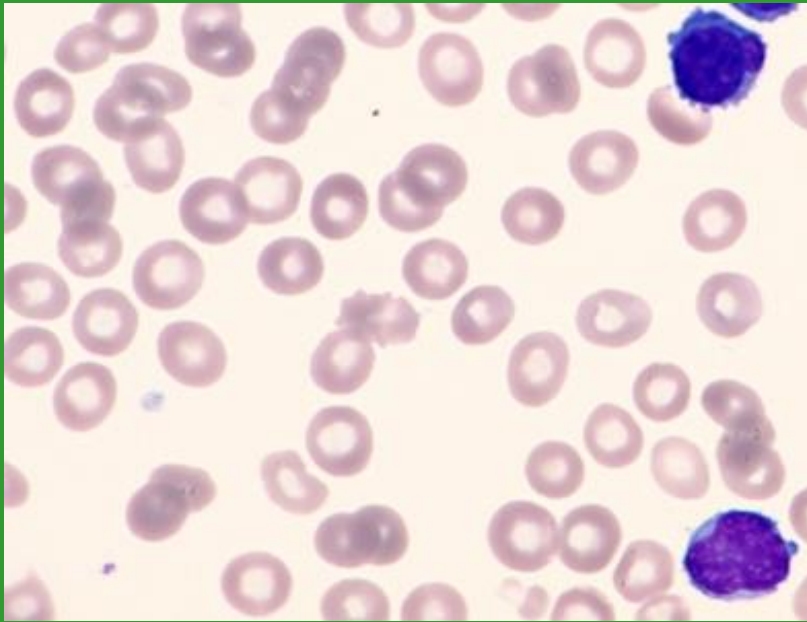
Hypogranulární trombocyty



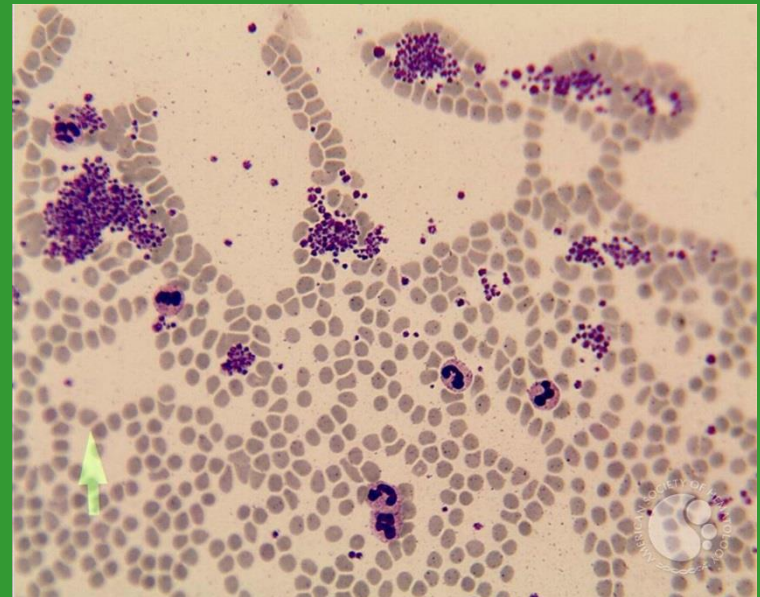
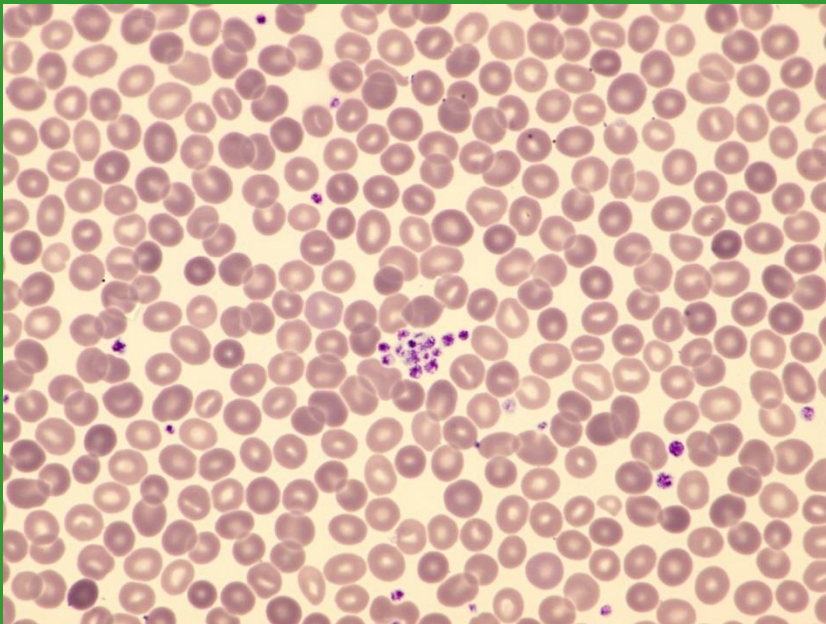
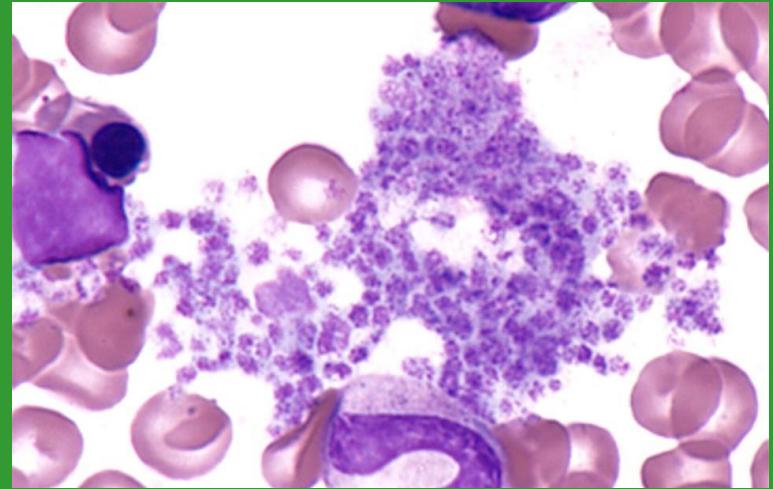
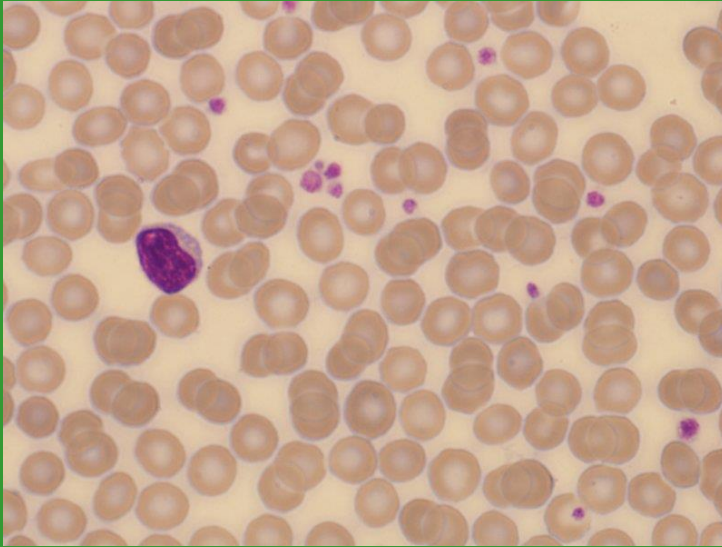
Fragmenty cytoplazmy (MGK x WBC)



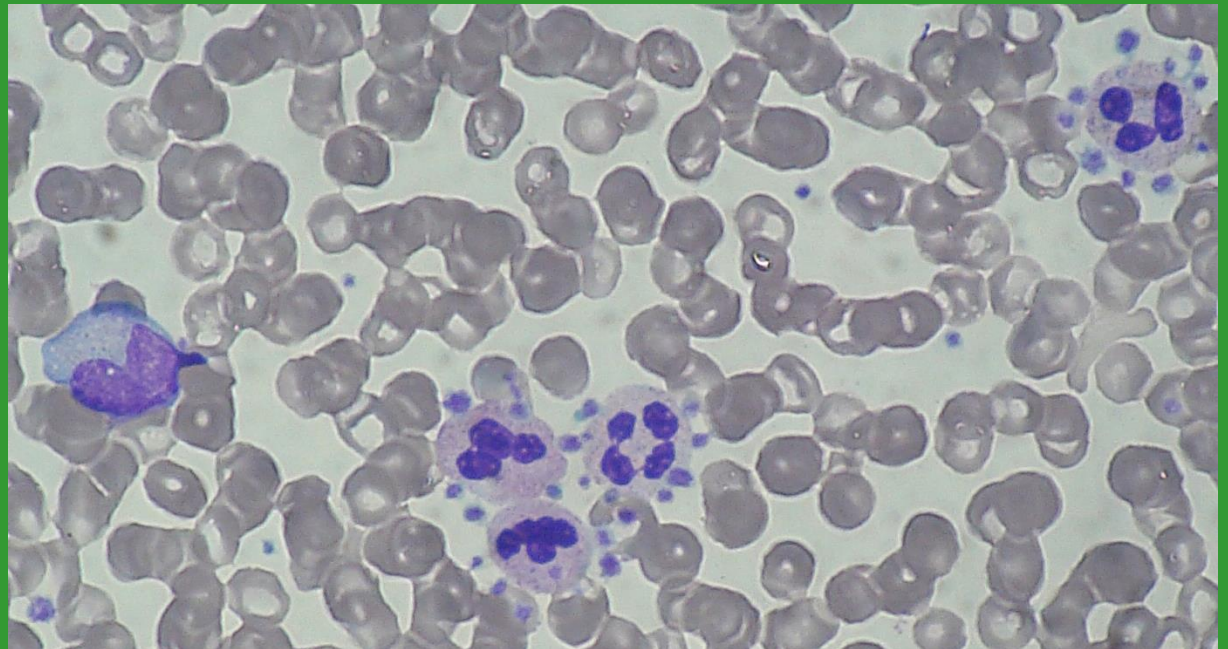
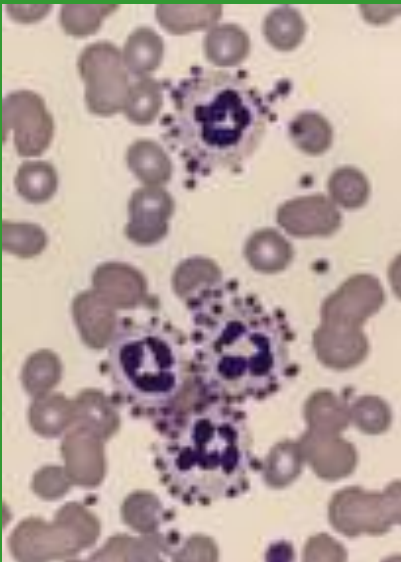
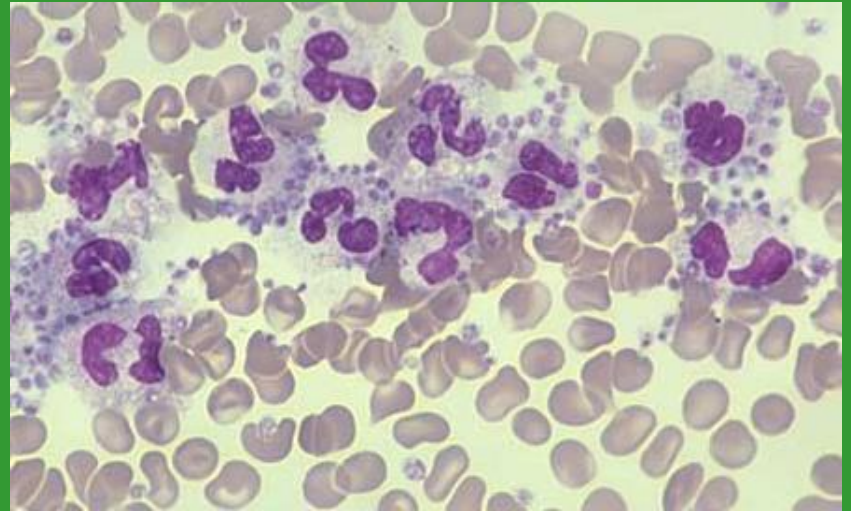
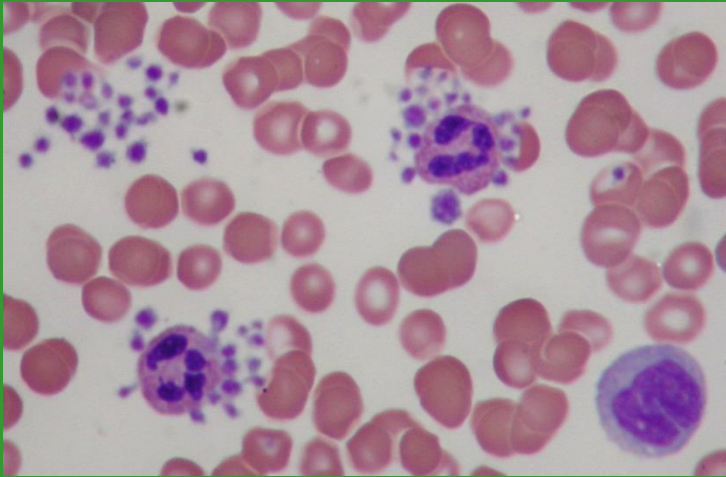
PLT – hypogranulace x buněčné fragmenty x mikrocyty



Shluky/sraženiny trombocytů

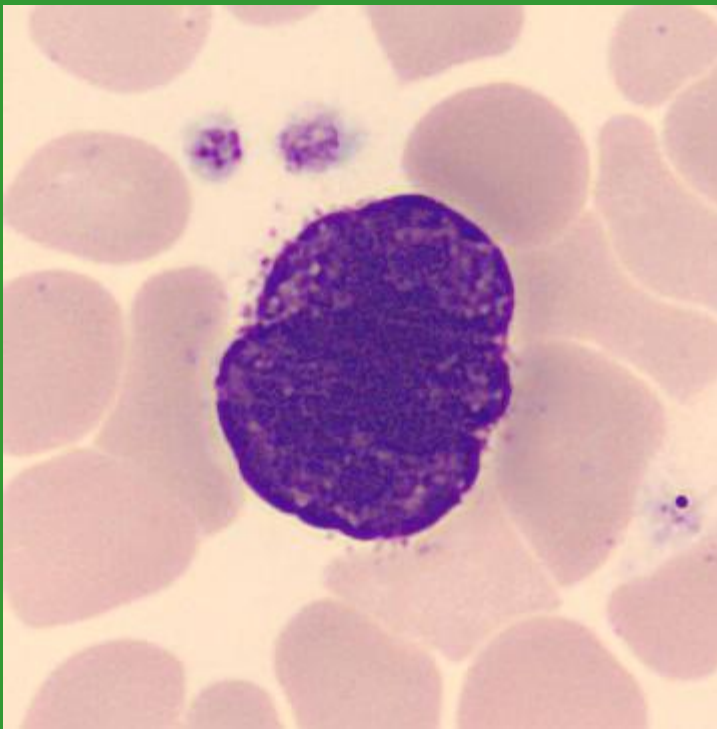


Satelitismus trombocytů



Megakaryocyty

holé jádro MGK v PK



MGK v KD

