

## Úrazy oka

Eye injuries occur more often in combination with other injuries (in cases of polytrauma) than in isolation. Life-threatening injuries should always be treated before ophthalmological treatment is started.

**Definition:** Life takes priority over vision. Eye injuries should be treated in patients who have been fully examined and stabilized.

### 18.1 Examination Methods

The incidence of ocular injuries is still high, despite improved safety regulations in recent years, such as the mandatory use of seat belts and protective eyewear for persons operating high-speed rotary machinery. It is therefore important that every general practitioner and member of healthcare staff should be able to recognize an ocular injury and provide initial treatment. The patient should then be referred to an ophthalmologist, who should be solely responsible for evaluation of the injury and definitive treatment. The following diagnostic options are available to determine the nature of the injury more precisely:

**Patient history.** Obtaining a thorough history will provide important information about the cause of the injury.

Work with a hammer and chisel nearly always suggests an intraocular foreign body.

Cutting and grinding work suggests corneal foreign bodies.

Welding and flame-cutting work suggests ultraviolet keratoconjunctivitis.

The examiner should always ascertain whether the patient has adequate tetanus immunization.

**Inspection** (gross morphologic examination). Ocular injuries frequently cause pain, photophobia, and blepharospasm. A few drops of topical anesthetic are recommended to allow the injured eye to be examined at rest with minimal pain to the patient. The cornea and conjunctiva are then examined for signs of trauma using a focused light, preferably one combined with a magnifying loupe (see Fig. 1.10 for examination technique). The eyelids can be everted to inspect the tarsal surface and conjunctival fornix. A foreign body can then be removed immediately.

**Ophthalmoscopy.** Examination with a focused light or ophthalmoscope will allow gross evaluation of deeper intraocular structures, such as whether a vitreous or retinal hemorrhage is present. Vitreous hemorrhage can be identified by the lack of red reflex

on retroillumination. Care should be taken to avoid unnecessary manipulation of the eye in an obviously severe open-globe injury (characterized by a soft globe, pupil displaced toward the penetration site, prolapsed iris, and intraocular bleeding in the anterior chamber and vitreous body). Such manipulation might otherwise cause further damage, such as extrusion of intraocular contents.

To properly estimate the urgency of treating palpebral and ocular trauma, it is particularly important to differentiate between open-globe injuries and closed-globe injuries. Open-globe injuries have highest priority due to the risk of losing the eye.

## 18.2 Classification of Ocular Injuries by Mechanism of Injury

### Mechanical injuries.

- Eyelid injuries.
- Injuries to the lacrimal system.
- Conjunctival laceration.
- Foreign body in the cornea and conjunctiva.
- Corneal erosion.
- Nonpenetrating injury (blunt trauma to the globe).
- Injury to the floor of the orbit (blow-out fracture).
- Penetrating injury (open-globe injury).
- Impalement injury to the orbit.

### Chemical injuries.

#### Injuries due to physical agents.

- Burns.
- Radiation injuries (ionizing radiation).
- Ultraviolet keratoconjunctivitis.

**Indirect ocular trauma.** Transient traumatic retinal angiopathy (Purtscher retinopathy).

## 18.3 Mechanical Injuries

### Eyelid Injury

**Etiology.** Eyelid injuries can occur in practically every facial injury. The following types warrant special mention:

Eyelid lacerations with involvement of the eyelid margin.

Avulsions of the eyelid in the medial canthus with avulsion of the lacrimal canaliculus.

**Clinical picture.** The highly vascularized and loosely textured tissue of the eyelids causes them to bleed profusely when injured. Hematoma and swelling will be severe (Fig. 18.1). *Abrasions* usually involve only the superficial layers of the skin, whereas

punctures, cuts, and all eyelid avulsions due to blunt trauma (such as a fist) frequently involve all layers. Bite wounds (such as dog bites) are often accompanied by injuries to the lacrimal system.

**Treatment.** Surgical repair of eyelid injuries, especially lacerations with involvement of the eyelid margin, should be performed with care. The wound should be closed in layers and the edges properly approximated to ensure a smooth margin without tension to avoid later complications, such as cicatricial ectropion (Fig. 18.2). Lid swellings are best treated by wool pads or ice compresses.

## Injuries to the Lacrimal System

**Etiology.** Lacerations and tears in the medial canthus (such as dog bites or glass splinters) can divide the **lacrimal duct**. Obliteration of the **punctum** and **lacrimal canaliculus** is usually the result of a burn or chemical injury. Injury to the **lacrimal sac** or **lacrimal gland** usually occurs in conjunction with severe craniofacial trauma (such as a kick from a horse or a traffic accident). Dacryocystitis is a common sequela, which often can only be treated by surgery (dacryocystorhinostomy).

**Clinical picture.** See Chapter 3 for dacryocystitis. Figure 18.3 shows avulsion of the lower lacrimal system (avulsions in the medial canthus).

**Treatment.** Lacrimal system injuries are repaired under an operating microscope. A ring-shaped silicone stent is advanced into the canaliculus using a special probe (Fig. 18.3b–f). The silicone stent remains *in situ* for 3–4 months and is then removed.

Surgical repair of eyelid and lacrimal system injuries must be performed by an ophthalmologist.

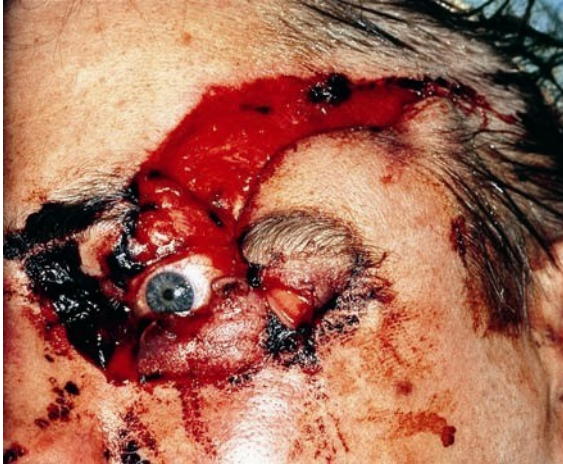## Conjunctival Laceration

**Epidemiology.** Due to its exposed position, thinness, and mobility, the conjunctiva is susceptible to lacerations, which are usually associated with subconjunctival hemorrhage.

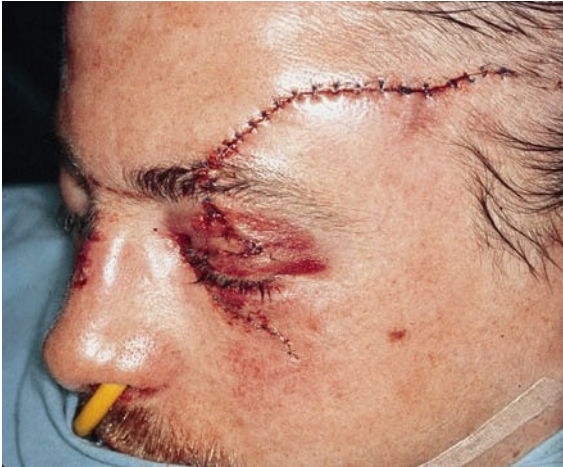**Etiology.** Conjunctival lacerations most commonly occur as a result of penetrating wounds (such as from bending over a spiked-leaf palm tree or from a branch that snaps back onto the eye).

**Symptoms and diagnostic considerations.** The patient experiences a foreignbody sensation. Usually this will be rather mild. Examination will reveal cir-

**Laceration of the upper and lower eyelids with avulsion of the lacrimal system**



**Fig 18.1**  
**a** The injury has exposed the cornea. The patient is unable to close the eye, and the cornea and conjunctiva can no longer be moistened.

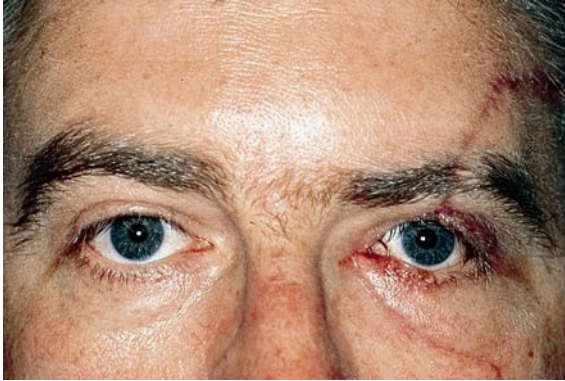

**b** Postoperative findings.

Continued

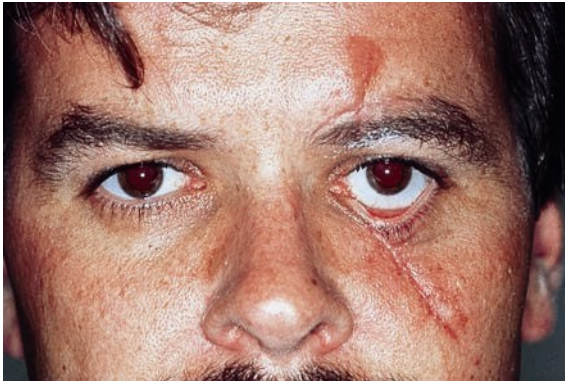cumscribed conjunctival reddening or subconjunctival hemorrhage in the injured area. Occasionally only application of fluorescein dye to the injury will reveal the size of the conjunctival gap.

**Laceration of the upper and lower eyelids with avulsion of the lacrimal system(continued)**



**Fig. 18.1c**  
The findings 2 months post-operatively after the wound had been treated with placement of a plastic stent (see also Fig. 18.3 for surgical technique).

**Cicatricial ectropion in the left lower eyelid after incorrect repair**



**Fig. 18.2** Failure to close the wound in layers without creating tension in the wound results in a scar that pulls the lower eyelid downward.

**Treatment.** Minor conjunctival injuries do not require treatment as the conjunctiva heals quickly. Larger lacerations with mobile edges are approximated with absorbable sutures.

Surgical treatment of avulsion of the eyelid with avulsion of the lacrimal system (bicanalicular ring intubation)

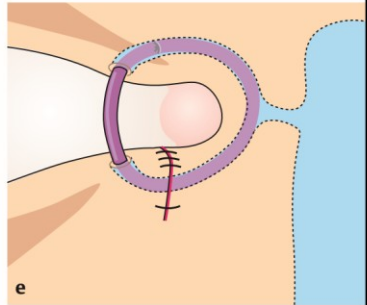
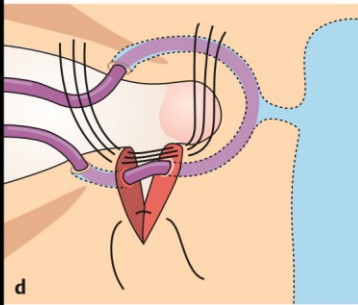
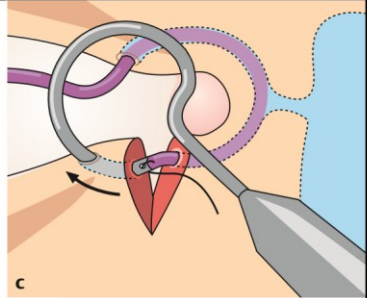
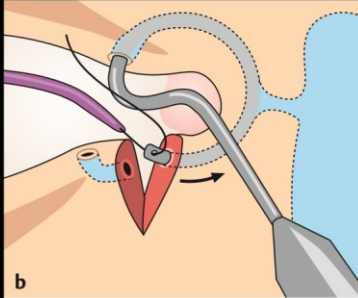
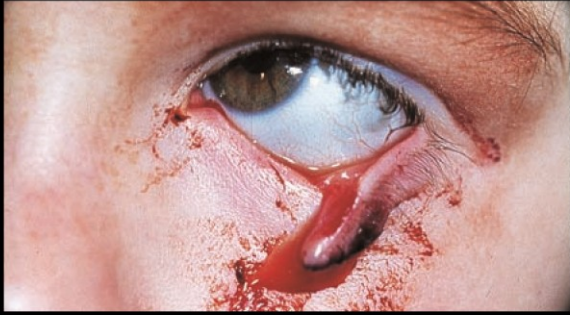

Fig. 18.3 a The findings before treatment of the wound. b A pigtail probe is introduced through the uninjured superior lacrimal canaliculus. The silicone tube can now be introduced at the medial margin of the wound and pulled through. c Next, the probe is advanced into the punctum of the injured canaliculus to grasp the other end of the silicone tube. d Finally, the ends of the tube are joined to form a ring. e, f The surgical site after the repair.

Continued ▶

### Surgical treatment of avulsion of the eyelid with avulsion of the lacrimal system (bicanalicular ring intubation) (continued)

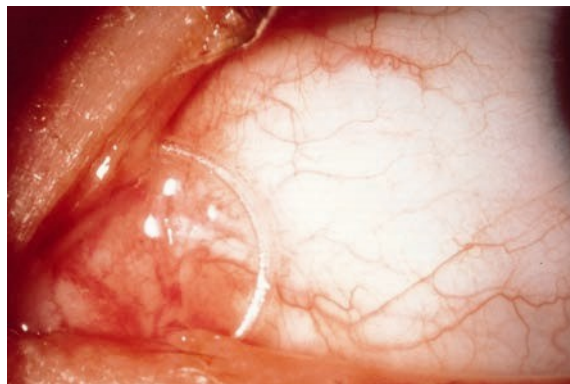

Fig. 18.3f

The possibility of a perforating injury should always be considered in conjunctival injuries. When the wound is treated, the physician should inspect the underlying sclera after application of topical anesthetic.

## Corneal and Conjunctival Foreign Bodies

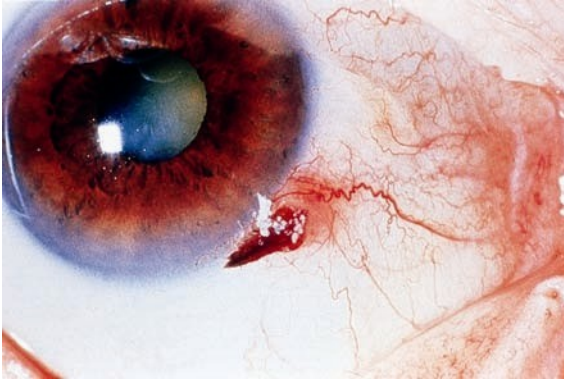
**Epidemiology.** Foreign bodies on the cornea and conjunctiva are the commonest ocular emergency encountered by general practitioners and ophthalmologists.

**Etiology.** Airborne foreign bodies and metal splinters from grinding or cutting discs in particular often become lodged in the conjunctiva or cornea or burn their way into the tissue.

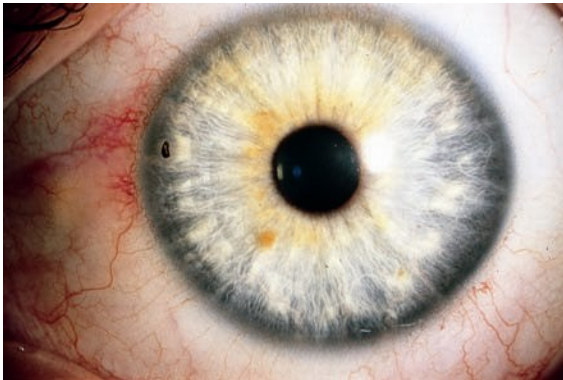**Symptoms and diagnostic considerations.** The patient experiences a foreignbody sensation with every blink of the eye. This is accompanied by epiphora (tearing) and blepharospasm. Depending on the time elapsed since the injury—i.e., after a few hours or several days—conjunctival or ciliary injection will be present (Fig. 18.4). The foreign bodies on the conjunctiva or cornea are themselves often so small that they are visible only under loupe magnification. There may be visible infiltration or a ring of rust. Where there is *no* visible foreign body but fluorescein dye reveals vertical corneal striations, the foreign body will be beneath the tarsus (see Fig. 5.11, p. 137).

A foreign-body sensation with every blink of the eye accompanied by epiphora, blepharospasm, and vertical striations on the surface of the cornea are typical signs of a subtarsal foreign body.

**Corneal and conjunctival foreign bodies and the reamer used to remove them**



**Fig. 18.4**  
**a** A conjunctival foreign body (a grain kernel that has become caught) on the limbus of the cornea, with conjunctival injection.



**b** A foreign body that has burned its way into the cornea. When the patient was using a grinder without protective eyewear the previous day, a splinter flew into the eye (arrow), which now exhibits a slight halo of visible infiltration. The conjunctival and ciliary injection at the site of the foreign body should be noted (see also Fig. 4.6).

Continued

**Treatment. Corneal and conjunctival foreign bodies.** The foreign body is prised out of its bed with a fine needle or cannula. The defect created by the foreign body will often be contaminated with rust or infiltrated with leukocytes. This defect is carefully reamed out with a drill (Fig. 18.4c) and treated with an antibiotic eye ointment and bandaged if necessary.



### Corneal and conjunctival foreign bodies and the reamer used used to remove them(continued)

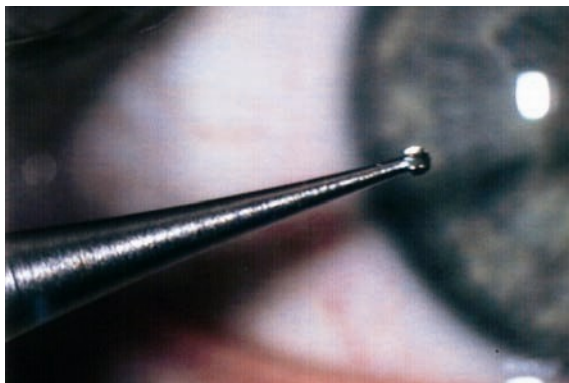


Fig. 18.4  
c The reamer used to ream out the defect created by the foreign body.

**Subtarsal foreign bodies.** Everting the upper and lower eyelids will usually reveal the foreign body, which may then be removed with a moist cotton swab. An antibiotic eye bandage is placed until the patient is completely free of symptoms.

## Corneal Erosion

**Etiology.** This disorder follows initial **trauma** to the surface cornea, such as the fingernail of a child carried in the parent's arms, a spiked-leaf palm tree, or a branch that snaps back onto the eye. Properly treated, this epithelial defect usually heals within a short time—i.e., 24–48 hours depending on the size of the defect. However, *occasionally* the epithelial cells do not properly adhere to Bowman's layer so that the epithelium repeatedly ruptures at the site of the initial injury. This characteristically occurs in the morning when the patient wakes up and suddenly opens his or her eyes. This **recurring erosion** often creates severe emotional stress for the patient.

**Symptoms and diagnostic considerations.** Immediately after the injury, the patient experiences a severe foreign-body sensation associated with tearing. Because there is actually a defect in the *surface* of the cornea, the patient has the subjective sensation of a foreign body *within* the eye. The epithelial defect causes severe pain, which immediately elicits a blepharospasm. Additional symptoms associated with corneal erosion include immediate eyelid swelling and conjunctival injection. Fluorescein sodium dye will readily reveal the corneal defect when the eye is examined through a blue light (Fig. 18.5).

**Treatment.** An antibiotic ointment eye bandage is used.

Treatment of recurrent corneal erosion often requires hospitalization. Bilateral

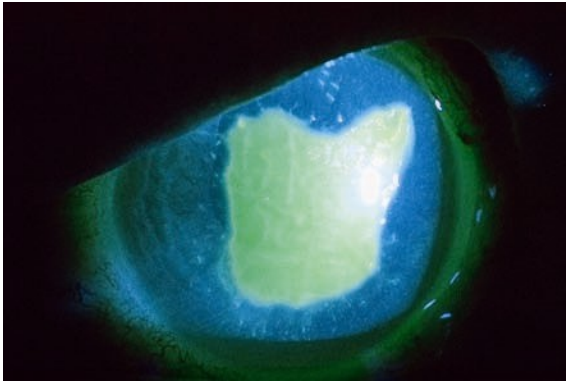
**Corneal erosion**

Fig. 18.5 The epithelial defect in the cornea is readily visible when the eye is examined with blue light after administration of fluorescein sodium dye.

bandages are placed to ensure that the eyes are completely immobilized.

### Blunt Ocular Trauma (Ocular Contusion)

**Epidemiology and etiology.** Ocular contusions resulting from blunt trauma such as a fist, ball, champagne cork, stone, falling on the eye, or a cow's horn are very common. Significant deformation of the globe can result where the diameter of the blunt object is less than that of the bony structures of the orbit.

**Clinical picture and diagnostic considerations.** Deformation exerts significant traction on intraocular structures and can cause them to tear. Often there will be blood in the anterior chamber, which will initially prevent the examiner from evaluating the more posterior intraocular structures.

Do not administer medications that act on the pupil as there is a risk of irreversible mydriasis from a sphincter tear, and pupillary movements increase the risk of subsequent bleeding. The posterior intraocular structures should only be thoroughly examined in mydriasis to determine the extent of injury after a week to 10 days.

Common injuries are listed in Table 18.1 and Fig. 18.6.

Tab. 18.1 Overview of possible injuries resulting from blunt trauma to the globe

Description of injury	Definition	Sequelae	Treatment
Iridodialysis	Avulsion of the root of the iris	Loss of pupillary roundness Increased glare Optical impairment results if there is a large gap at the palpebral fissure leading to a "double pupil"	Suture of the base of the iris is indicated for severe injuries (patient has two pupils due to severe avulsion; see Fig. 18.6). Other cases do not require treatment
Traumatic aniridia	Total avulsion of the iris	Patient suffers from increased glare	Sunglasses Where a simultaneous cataract is present, a black prosthetic lens with an optical aperture the size of the pupil is inserted during cataract surgery
Recession of the angle	Widening of the angle of the anterior chamber	Late sequela: secondary glaucoma	See Chapter 10
Cyclodialysis	Avulsion of the ciliary body from the sclera	Intraocular hypotonia with choroidal folds and optic disc edema Visual impairment	The ciliary body must be reattached with sutures to prevent phthisis bulbi (shrinkage of the eyeball)
Subluxation of the lens	Avulsion of the zonule fibers	Dislocation of the lens and iridodonesis Decreased visual acuity	Removal of the lens and implantation of a prosthetic lens; see Chapter 7

Vitreous detachment	Separation of the base of the vitreous body	Patient sees floaters (see Chapter 11)	See Chapter 11
---------------------	---------------------------------------------	----------------------------------------	----------------

Continued

Tab. 18.1 Continued

Description of injury	Definition	Sequelae	Treatment
Avulsion of the ora serrata	Avulsion of the peripheral retina (ora serrata)	Retinal detachment resulting in flashes of light, shadows, and blindness	Retinal surgery; see Chapter 12
Sphincter tear	Tear in the sphincter pupillae with elongation of the iris	Traumatic mydriasis or impaired pupillary function may be present	Sunglasses are indicated. Otherwise, no treatment is possible
Contusion rosette	Traumatic lens opacity (traumatic cataract)	Rosette-shaped subcapsular opacity on the anterior surface of the lens, which with time migrates into the deeper cortex due to the apposition of lens fibers yet otherwise remains unchanged Patient suffers from gradually increasing loss of visual acuity	Opacity in the optical center is routinely an indication for surgery (see Chapter 7, for details of surgery)

---

Berlin's edema	Retinal and macular edema at the posterior pole of the globe (contrecoup location) possibly associated with bleeding	Loss of visual acuity	Watch-and-wait approach is advised until swelling recedes
Choroidal ruptures	Crescentic concentric choroidal tears around the pupil	Tears that extend through the macula can result in decreased visual acuity	No treatment is possible. Watchand-wait approach is advised until scarring develops

---

Tab. 18.1 Continued

Description of injury	Definition	Sequelae	Treatment
Traumatic retinochoroidopathy	Choroidal and retinal atrophy due to avulsion or impingement of the short posterior ciliary arteries	Loss of visual acuity	No treatment is possible
Avulsion of the globe	Traumatic avulsion of the globe out of the orbit, frequently associated with avulsion of the optic nerve (see next row)	Immediate blindness	Enucleation
Avulsion of the optic nerve	Avulsion of the entire optic nerve at its point of entry into the globe	Immediate blindness	The separation of the nerve fibers is irreversible
Injury to the optic nerve	Possible injuries include: Hematoma of the optic nerve sheath Optic nerve contusion Fracture of the optic nerve canal	Atrophy of the optic nerve with loss of visual acuity and visual field defects	No treatment is possible
Retrobulbar hematoma	Injury to retrobulbar vascular structures	Orbital bleeding Eyelid hematoma Exophthalmos	Wait for blood to be absorbed Surgery is indicated only when the central retinal artery is occluded by pressure

Continued

Late sequelae of blunt ocular trauma include:

Secondary glaucoma.

Retinal detachment.

Cataract.

Tab. 18.1 Continued

Description of injury	Definition	Sequelae	Treatment
Hyphema	Bleeding in the anterior chamber	vision has blurred ion	Patient should assume an upright posture to allow blood to settle. This will restore vision Hyphema will resolve spontaneously
Vitreous hemorrhage	Bleeding into the vitreous chamber	Identified by the lack of red reflex on retroillumination during ophthalmoscopy Loss of visual acuity	wait for spontaneous resolution
Orbital fracture (blow-out fracture)	Fracture of the floor of the orbit with displacement into the maxillary sinus	Diplopia in the affected eye Elevation or depression deficit	Patient should refrain from blowing his or her nose if paranasal sinuses are involved (crepitus upon palpation) Surgical repair of the orbital floor and release of impinged orbital contents



■ Late sequelae of blunt ocular trauma may occur years after the injury.

**Treatment.** This involves immobilizing the eye initially, to allow intraocular blood to settle. See Table 18.1 for details.

■ Subsequent bleeding 3–4 days after the injury is common.

## Blow-Out Fracture

**Etiology** (see also Blunt Ocular Trauma). Blow-out fractures of the orbit result from blunt trauma. Blunt objects of small diameter, such as a fist, tennis ball, or baseball, can compress the contents of the orbit so severely that the orbital wall fractures. This fracture usually occurs where the bone is thinnest, *along the paper-thin floor of the orbit over the maxillary sinus*. The ring-shaped bony orbital rim usually remains intact. The fracture can result in protrusion and impingement of orbital fat and the inferior rectus and its sheaths in the fracture gap. Where the *medial ethmoid wall* fractures instead of the orbital floor, emphysema in the eyelids will result.

**Symptoms and diagnostic considerations.** The more severe the contusion, the more severe the intraocular injuries and resulting visual impairment will be. Impingement of the inferior rectus can result in **diplopia**, especially in upward gaze. Initially, the diplopia may go unnoticed when the eye is still swollen shut. A large bone defect may result in displacement of larger portions of the contents of the orbital cavity. The eye may recede into the orbit (**enophthalmos**) and the **palpebral fissure may narrow**. Injury to the infraorbital nerve, which runs along the floor of the orbit, may result. This can cause **hypesthesia of the facial skin**.

Crepitus upon palpation during examination of the eyelid swelling is a sign of emphysema due to collapse of the ethmoidal air cells. The crepitus is caused by air entering the orbit from the paranasal sinuses. The patient should refrain from blowing his or her nose for the next 4–5 days to avoid forcing air or germs into the orbit. Radiographs should be obtained and an ear, nose, and throat specialist consulted to help determine the **exact location of the fracture**. CT studies are more precise and may be indicated to evaluate difficult cases.

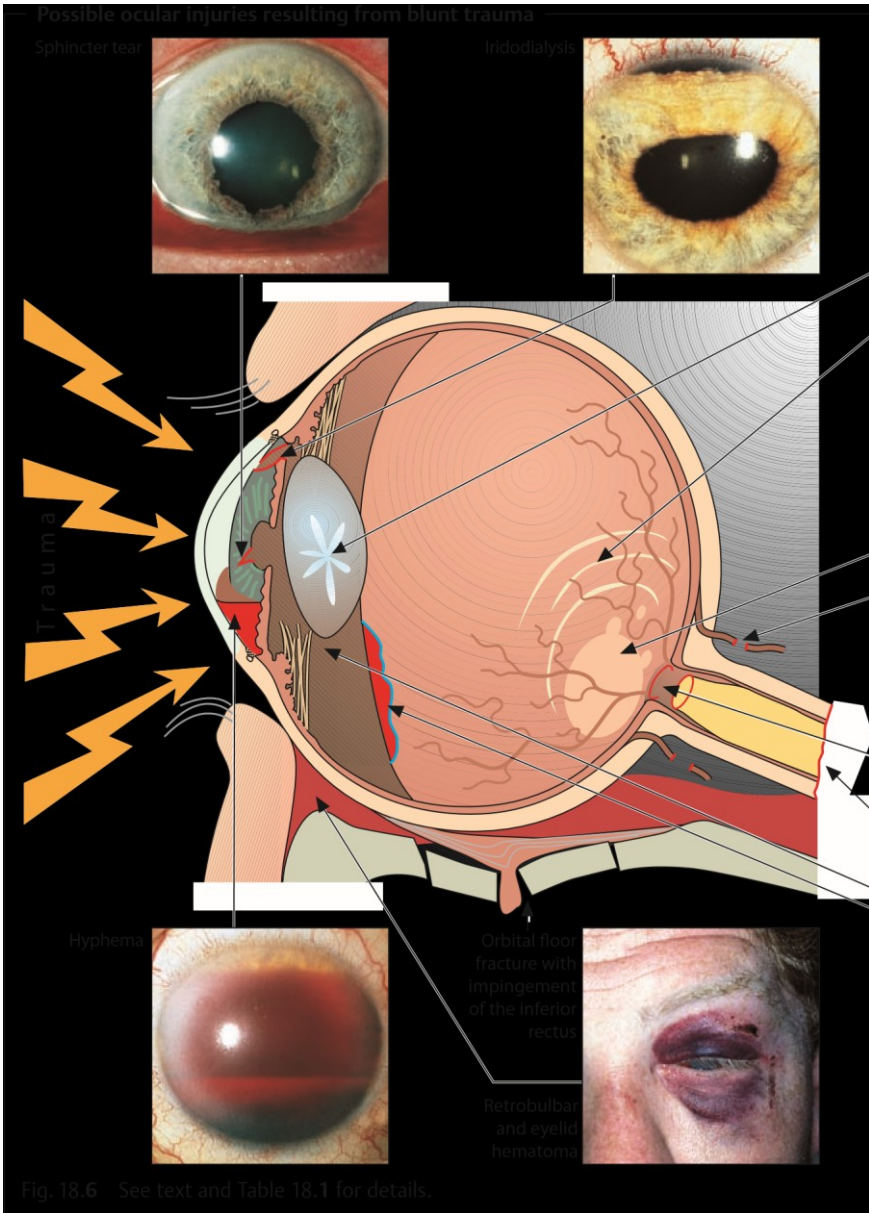
■ Tissue displaced into the maxillary sinus will resemble a hanging drop of water in the CT image.

**Treatment.** Surgery to restore normal anatomy and the integrity of the orbit should be performed within 10 days. This minimizes the risk of irreversible damage from scarring of the impinged inferior rectus. Where treatment is prompt, the prognosis is good (see Section 15.8 for orbital surgery).

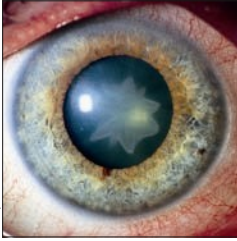
■ Tetanus prophylaxis and treatment with antibiotics are crucial.

## Open-Globe Injuries

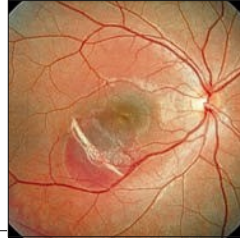
**Etiology.** Together with severe chemical injuries, open-globe injuries are the most devastating forms of ocular trauma. They are caused by sharp objects that penetrate the cornea and sclera. A distinction is made between penetration with and without an intraocular foreign body. However, even blunt



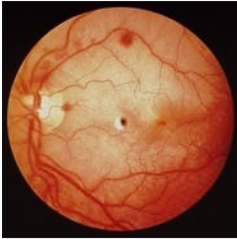Traumatic cataract (contusion rosette)



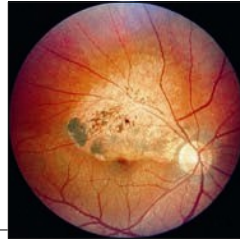
Choroidal rupture



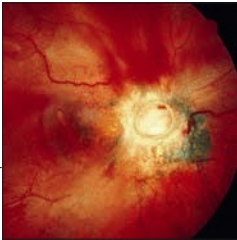Retinal contusion (Berlin edema)



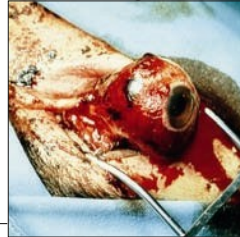
Traumatic retinochoroidopathy



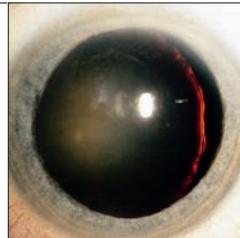
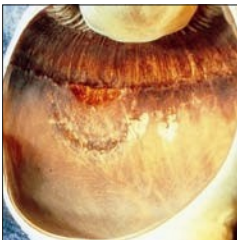
Avulsion of the optic nerve



Avulsion of the globe



Tear in the ora serrata



Subluxation of the lens

trauma can cause an open-globe injury in an eye weakened by previous surgery or injury where extremely high-energy forces are involved (such as falling on a cane or a blow from a cow's horn).

**Clinical picture and diagnostic considerations.** Penetrating injuries cover the entire spectrum of clinical syndromes. Symptoms can range from massive penetration of the cornea and sclera (Fig. 18.7) with loss of the anterior chamber to tiny, nearly invisible injuries that close spontaneously. The latter may include a fine penetrating wound or the entry wound of a foreign body. Depending on the severity of the injury, the patient's visual acuity may be severely compromised or not influenced at all.

One of the most common sequelae is a **traumatic cataract**. The rupture in the lens capsule allows aqueous humor to penetrate, causing the lens to swell. This results in lens opacification of varying severity. Large defects will lead to total opacification of the lens within hours or a few days. Smaller defects that close spontaneously often cause a circumscribed opacity. Typically, penetration results in a rosette-shaped anterior or posterior subcapsular opacity.

Depending on the severity of the injury, the following **diagnosticsigns** will be present in an open-globe injury:

The anterior chamber will be shallow or absent.

The pupil will be displaced toward the penetration site.

Swelling of the lens will be present (traumatic cataract).

There will be bleeding in the anterior chamber and vitreous body.

Hypotonia of the globe will be present.

The rupture of the lens capsule and vitreous hemorrhage often render examination difficult as they prevent direct inspection. These cases, and any patient whose history suggests an intraocular foreign body, require one or both of the following diagnostic imaging studies:

#### Penetrating injury

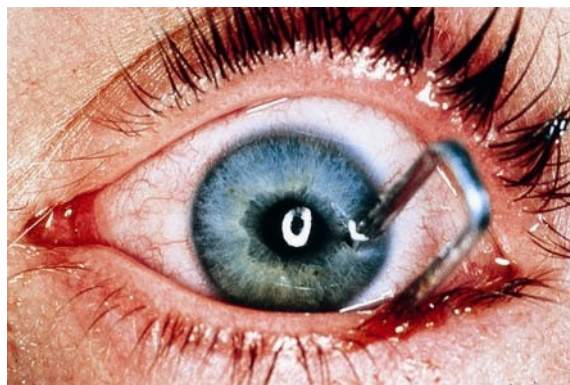


Fig. 18.7 An open-globe injury by a staple, involving the cornea, iris, lens, sclera, and retina.

Radiographs in two planes to determine whether there is a foreign body in the eye.

CT studies, which allow precise localization of the foreign body and can also image radiolucent foreign bodies such as Plexiglas.

An injury sustained while working with a hammer and chisel suggests an intraocular foreign body. The diagnosis can be confirmed by examining the fundus in mydriasis and obtaining radiographic studies.

**Treatment. First aid.** Where penetrating trauma is suspected, a sterile bandage should be applied and the patient referred to an eye clinic for treatment. Tetanus immunization or prophylaxis and prophylactic antibiotic treatment are indicated as a matter of course.

**Surgery.** Surgical treatment of penetrating injuries must include suturing the globe and reconstructing the anterior chamber. Any extruded intraocular tissue (such as the iris) must be removed. Intraocular foreign bodies (Fig. 18.8) should be removed when the wound is repaired (i.e., by vitrectomy and extraction of the foreign body).

#### Late sequelae:

**Improper reconstruction of the anterior chamber** may lead to adhesions between the iris and the angle of the anterior chamber, resulting in secondary angle closure glaucoma.

A **retinal injury** (for example at the site of the impact of the foreign body) can lead to retinal detachment.

Failure to remove **iron foreign bodies** can lead to ocular siderosis, which causes irreparable damage to the receptors and may manifest itself years later.

**Copper foreign bodies** cause severe inflammatory reactions in the eye (ocular chalcosis) within a few hours. Symptoms range from uveitis and hypopyon to phthisis bulbi (shrinkage and hypotonia of the eyeball).

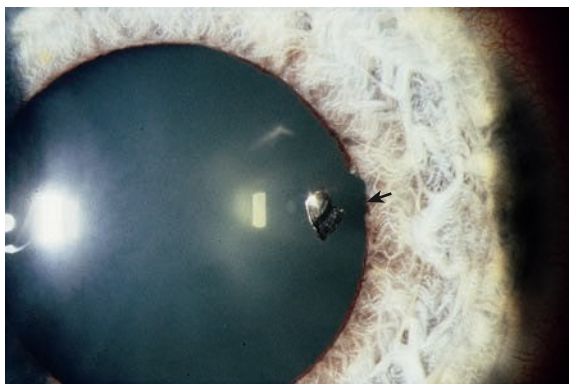
**Organic foreign bodies** (such as wood) in the eye lead to fulminant endophthalmitis.

### Impalement Injuries in the Orbit

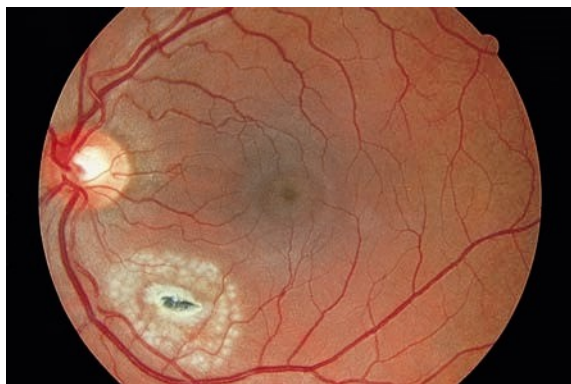
**Etiology.** Impalement injuries occur most frequently in situations such as these: Children may fall on pencils held in their hands (Fig. 18.9).

Injuries may result from the actions of other persons (such as arrows or darts).

A knife may slip while a butcher is removing a bone from a cut of meat. Often the impaling “stake” will glance off the round hard outer layer of the globe (*cornea and sclera*) and lodge in the soft tissue of the orbit.

**Intraocular foreign body sustained while working with a hammer and chisel**

**Fig. 18.8**  
**a** An iron splinter has caught in the lens; the cornea closed spontaneously immediately after the injury (white arrow). A sphincter injury is also present (black arrow).



**b** The iron splinter has entered through the sclera and is now lodged in the retina on the posterior wall of the globe, which it has “coagulated” (white discoloration of the surrounding retinal tissue). Focal burns are placed around the foreign body with an argon laser to fix the retina before a vitrectomy is performed to remove the foreign body.

**Symptoms and diagnostic considerations.** The stake can cause displacement of the globe. Often there will be minimal bleeding in the surrounding tissue. Diagnostic studies used to ascertain possible damage to intraocular structures include ophthalmoscopy, radiographic studies, and ultrasound.

**Treatment.** First aid treatment should leave the stake *in situ*. Removing the stake could cause severe bleeding and orbital hematoma. If necessary, the stake should be

stabilized before the patient is transported to the eye clinic. Once the patient is in the clinic, the foreign body is removed from the orbit



## 18.4 Chemical Injuries

## Impalement injury in the right orbit

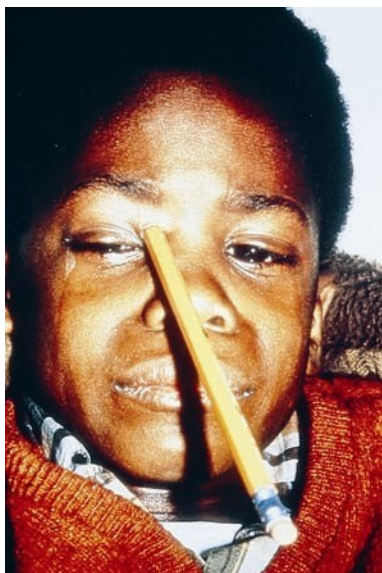

Fig. 18.9 Orbital injury without injury to the globe following a fall on a pencil the patient was holding in his hand. (Photograph courtesy of Prof. W.D. Green, MD, Baltimore, Maryland.)

and the integrity of the globe is verified, depending on specific findings. Any bleeding is controlled. Prophylactic antibiotic treatment is indicated routinely to minimize the risk of orbital cellulitis.

## 18.4 Chemical Injuries

**Etiology.** Chemical injuries can be caused by a variety of substances such as acids, alkalis, detergents, solvents, adhesives, and irritants such as tear gas. The severity can range from slight irritation of the eye to total blindness.

Chemical injuries are among the most dangerous ocular injuries. First aid at the site of the accident is crucial to minimize the risk of severe sequelae such as blindness.

As a general rule, acid burns are less dangerous than alkali burns. This is because most acids do not act deeply. **Acids** differ from alkalis in that they cause immediate *coagulation necrosis* in the superficial tissue. This has the effect of preventing the acid from penetrating deeper so that the burn is effectively a self-limiting process.

However, some acids penetrate deeply like alkalis and cause similarly severe injuries. Concentrated sulfuric acid (such as from an exploding car battery) draws water out of tissue and simultaneously develops intense heat that affects every layer of the eye. Hydrofluoric acid and nitric acid have a similar penetrating effect.

**Alkalis** differ from most acids in that they can penetrate by hydrolyzing structural proteins and dissolving cells. This is referred to as *liquefactive necrosis*. They then cause severe intraocular damage by alkalizing the aqueous humor.

**Symptoms.** Epiphora, blepharospasm, and severe pain are the primary symptoms. Acid burns usually cause immediate loss of visual acuity due to the superficial necrosis. In alkali injuries, loss of visual acuity *often* manifests itself only several days later.

**Clinical picture and diagnostic considerations.** Proper diagnosis of the cause and severity of the burn is crucial to treatment and prognosis.

Alkali burns can appear less severe initially than acid burns, but they may lead to blindness.

Morphologic findings and the resulting prognosis can vary greatly depending on the severity and duration of exposure to the caustic agent. This information is summarized in Table 18.2.

**Treatment.** First aid rendered at the scene of the accident often decides the fate of the eye. The first few seconds and minutes and resolute action by persons at the scene are crucial. Immediate copious irrigation of the eye can be performed with any watery solution of neutral pH, such as tap water, mineral water, soft drinks, coffee, tea, or similar liquids. Milk should be avoided as it increases the penetration of the burn by opening the epithelial barrier. A second person must rigorously restrain the severe blepharospasm to allow effective irrigation. A topical anesthetic to relieve the blepharospasm will rarely be available at the scene of the accident. Coarse particles (such as lime particles in a lime injury) should be flushed and removed from the eye. Only after these actions have been taken should the patient be brought to an ophthalmologist or eye clinic.

### Chronology of treatment of chemical injuries.

#### First aid at the scene of the accident (co-workers or family members):

- Restrain blepharospasm by rigorously holding the eyelids open.
- Irrigate the eye within seconds of the injury using tap water, mineral water, soft drinks, coffee, tea, or similar liquids. Carefully remove coarse particles from the conjunctival sac.
- Notify the rescue squad at the same time.
- Transport the patient to the nearest ophthalmologist or eye clinic.

#### Treatment by the ophthalmologist or at the eye clinic:

- Administer topical anesthesia to relieve pain and neutralize blepharospasm.

- With the upper and lower eyelids fully everted, carefully remove small particles such as residual lime from the superior and inferior conjunctival fornices under a microscope using a moist cotton swab.

Tab. 18.2 Findings in chemical injuries of various degrees of severity

Severity of the injury	Damage to the corneal epithelium	Damage to the conjunctiva	Damage to the corneal stroma	Intraocular involvement	Prognosis
Slight	Superficial punctate keratitis No corneal erosion	Conjunctival epithelium largely intact Slight chemosis (edematous conjunctival swelling)	Clear	None	Good: healing without loss of function
Moderate to severe	Moderate to total corneal erosion	Moderate chemosis Segmental ischemia of the limbal vessels	Slightly opacified	Slight irritation of the anterior chamber (slight amount of cellular and protein exudate in the anterior chamber)	Defect healing with functional impairment and possibly symblepharon

18.4

ChemicalInjuries

---

Severe	Total corneal erosion including erosion of the conjunctival epithelium at the limbus.	Severe chemosis Total ischemia of the limbal vessels	All layers are opacified (“cooked fish eye”; see Fig. 18.11)	Severe irritation of the anterior chamber Damage to the iris, lens, ciliary body, and angle of the anterior chamber)	Poor Defect healing with functional impairment that may include loss of the eye Symblepharon
--------	---------------------------------------------------------------------------------------	---------------------------------------------------------	--------------------------------------------------------------	-------------------------------------------------------------------------------------------------------------------------	----------------------------------------------------------------------------------------------------

- Flush the eye with a buffer solution. Long-term irrigation using an irrigating contact lens may be indicated (the lens is connected to a cannula to irrigate the eye with a constant stream of liquid).
- Initiate systemic pain therapy if indicated.

**Additional treatment on the ward in an eye clinic.** The following therapeutic measures for severe chemical injuries are usually performed on the ward:

- Continue irrigation.
- Initiate topical cortisone therapy (dexamethasone 0.1% eyedrops and prednisolone 1% eyedrops).
- Administer subconjunctival steroids.
- Immobilize the pupil with atropine 1% eyedrops or scopolamine 0.25% eyedrops twice daily.
- Administer anti-inflammatory agents (two oral doses of 100 mg indomethacin or diclofenac) or 50–200 mg systemic prednisolone.
- Administer oral and topical vitamin C to neutralize cytotoxic radicals.
- Administer 500 mg of oral acetazolamide (Diamox) to reduce intraocular pressure as prophylaxis against secondary glaucoma.
- Administer hyaluronic acid for corneal care to promote re-epithelialization and stabilize the physiologic barrier.
- Administer topical antibiotic eyedrops.
- Carry out debridement of necrotic conjunctival and corneal tissue and make radial incisions in the conjunctiva (Passow's method) to drain the subconjunctival edema.

**Additional surgical treatment in the presence of impaired wound healing following extremely severe chemical injuries:**

- *A conjunctival and limbal transplantation* (stem cell transfer) can replace lost stem cells that are important for corneal healing. This will allow re-epithelialization.
- Where the cornea does not heal, cyanoacrylate glue can be used to attach a *hard contact lens* (artificial epithelium) to promote healing.
- A Tenon's capsuloplasty (mobilization and advancement of a flap of subconjunctival tissue of Tenon's capsule to cover defects) can help to eliminate conjunctival and scleral defects.

**Late surgical treatment after the eye has stabilized.**

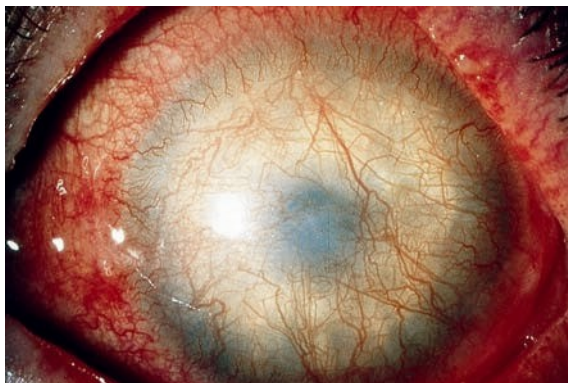- Lysis of symblepharon (symblepharon refers to adhesions between the palpebral and bulbar conjunctiva; see also prognosis and complications) to improve the motility of the globe and eyelids.
- Plastic surgery of the eyelids to release the globe. (This should only be performed 12–18 months after the injury.)
- Where there is total loss of the goblet cells, transplantation of nasal mucosa usually relieves pain (the lack of mucus is substituted by goblet cells from the nasal mucosa).

## 18.4 Chemical Injuries

- Penetrating keratoplasty (see Chapter 5) can be performed to restore vision. Because the traumatized cornea is highly vascularized (Fig. 18.10), these procedures are plagued by a high incidence of graft rejection. A clear cornea can rarely be achieved in a severely burned eye even with an HLA-typed corneal graft and immunosuppressive therapy.

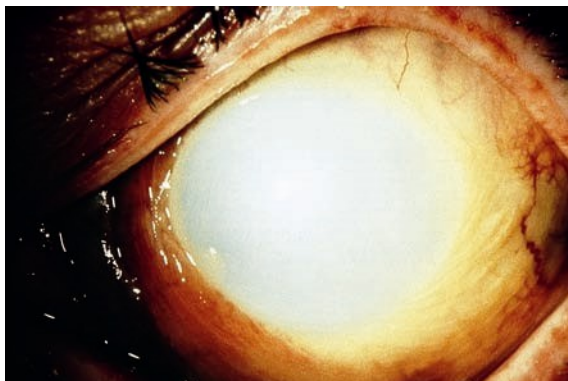
**Prognosis and possible complications.** The degree of ischemia of the conjunctiva and the limbal vessels is an indicator of the severity of the injury and the prognosis for healing (see Table 18.2). The *greater the ischemia of the conjunctiva and limbal vessels, the more severe the burn will be.* The most severe form

#### Lime injury

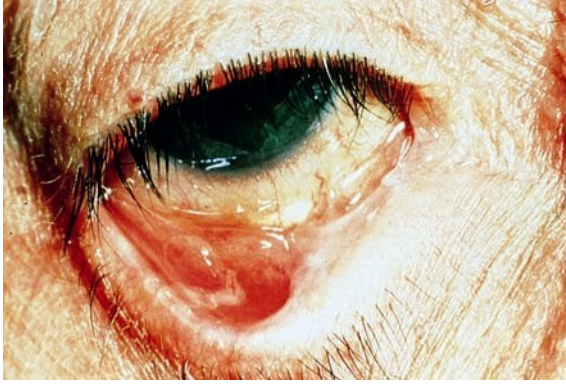

**Fig. 18.10** Superficial and deep corneal vascularization is present, and the eye is dry due to loss of most of the goblet cells.

#### “Cooked fish eye” following alkali injury



**Fig. 18.11** The cornea is as white as chalk and opaque. The vascular supply to the limbus (capillaries on the edge) has been obliterated.

**Symblepharon**

**Fig. 18.12** Moderate and severe chemical injuries can produce adhesions between the palpebral and bulbar conjunctiva.

of chemical injury presents as a “**cooked fish eye**” (Fig. 18.11) for which the prognosis is very poor—i.e., blindness is possible.

Moderate to severe chemical injuries involving the bulbar and palpebral conjunctiva can result in **symblepharon** (adhesions between the palpebral and bulbar conjunctiva; Fig. 18.12). Inflammatory reactions in the anterior chamber secondary to chemical injuries can lead to **secondary glaucoma**.

## 18.5 Injuries Due to Physical Agents

### Ultraviolet Keratoconjunctivitis

**Etiology.** Injury from ultraviolet radiation can occur from welding without proper eye protection, exposure to high-altitude sunlight with the eyes open without proper eye protection, or due to sunlight reflected off snow when skiing at high altitudes on a sunny day. Intense ultraviolet light can lead to ultraviolet keratoconjunctivitis within a short time (for example just a few minutes of welding without proper eye protection). Ultraviolet radiation penetrates only slightly and therefore causes only superficial necrosis in the corneal epithelium. The exposed areas of the cornea and conjunctiva in the palpebral fissure become edematous, disintegrate, and are finally cast off.

■ Ultraviolet keratoconjunctivitis is one of the most common ocular injuries.

**Symptoms and diagnostic considerations.** Symptoms typically manifest themselves after a latency period of 6–8 hours. This causes patients to seek the aid of an ophthalmologist or eye clinic in the middle of the night, complaining of “acute blindness” accompanied by pain, photophobia, epiphora, and an intol-



## 18.5 Injuries Due to Physical Agents

erable foreign-body sensation. Often severe blepharospasm will be present. Slit lamp examination will require administration of a topical anesthetic. This examination will reveal epithelial edema and superficial punctate keratitis or erosion in the palpebral fissure under fluorescein dye (see Fig. 18.5).

The topical anesthetic will completely relieve symptoms within a few seconds and allow the patient to see clearly and open his or her eyes without pain. Under no circumstances may the patient be allowed access to this anesthetic without medical supervision. Uncontrolled habitual use suppresses the pain reflex (eye closing reflex), which could result in incalculable corneal damage.

**Treatment.** The “blinded” patient should be instructed that the symptoms will resolve completely under treatment with antibiotic ointment within 24–48 hours. Ointment is best applied to both eyes every 2–3 hours with the patient at rest in darkened room. The patient should be informed that the eye ointment will not immediately relieve pain and that eye movements should be avoided.

### Burns

**Etiology.** Flaring flames such as from a cigarette lighter, hot vapors, boiling water, and splatters of hot grease or hot metal cause thermal coagulation of the corneal and conjunctival surface. Because of the eye closing reflex, the eyelids often will be affected as well.

Injuries due to explosion or burns from a starter’s gun also include particles of burned powder (powder burns). Injuries from a gas pistol will also involve a chemical injury.

**Symptoms and diagnostic considerations.** Symptoms are similar to those of chemical injuries (epiphora, blepharospasm, and pain).

A topical anesthetic is administered, and the eye is examined as in a chemical injury. *Immediate opacification of the cornea* will be readily apparent. This is due to scaling of the epithelium and tissue necrosis, whose depth will vary with the severity of the burn. In burns from metal splinters, one will often find cooled metal particles embedded in the cornea.

**Treatment.** Initial treatment consists of applying cooling antiseptic bandages to relieve pain, after which necrotic areas of the skin, conjunctiva, and cornea are removed under local anesthesia. Foreign particles such as **embedded ash and smoke particles in the eyelids and face** are removed in cooperation with a dermatologist by brushing them out with a sterile toothbrush under general anesthesia. This is done to prevent them from growing into the skin like a tattoo. **Superficial particles in the cornea and conjunctiva** are removed under local anesthesia together with the necrotic tissue. The affected areas are then treated with an antibiotic ointment.

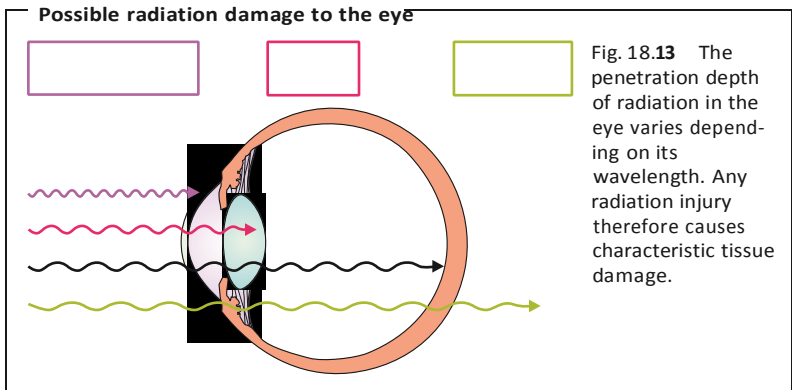
**Prognosis.** The clinical course of a burn is usually less severe than that of a chemical injury. This is because burns, like acid injuries, cause superficial coagulation. Usually they heal well when treated with antibiotic ointment.

### Radiation Injuries (Ionizing Radiation)

**Etiology.** Ionizing radiation (neutron, or gamma/x-ray radiation) has high energy that can cause ionization and formation of radicals in cellular tissue. The penetration depth in the eye varies with the type of radiation—i.e., the wavelength, resulting in characteristic types of tissue damage (Fig. 18.13). This tissue damage always manifests itself after a latency period, often only after a period of years (see also Symptoms and clinical picture). Common sites include the lens (radiation cataract) and retina (radiation retinopathy). This tissue damage is usually the result of tumor irradiation in the eye or nasopharynx. Radiation disorders have been observed in patients from Hiroshima and Nagasaki and, more recently, in Chernobyl.

**Symptoms and clinical picture.** Loss of the eyelashes and eyelid pigmentation accompanied by blepharitis are typical symptoms. A dry eye is a sign of damage to the conjunctival epithelium (loss of the goblet cells). Loss of visual acuity due to a radiation cataract is usually observed within 1–2 years of irradiation. Radiation retinopathy in the form of ischemic retinopathy with bleeding, cotton-wool spots, vascular occlusion, and retinal neovascularization usually occurs within months of irradiation.

**Treatment and prophylaxis.** Care should be taken to cover the eyes prior to planned radiation therapy in the head and neck. Radiation cataract can be treated surgically. Radiation retinopathy can be treated with panretinal photocoagulation with an argon laser.



18.6 Indirect Ocular Trauma

## 18.6 Indirect Ocular Trauma

### Purtscher's Retinopathy

**Etiology.** Arterial and venous circulatory disruption in the retina characterized by a sudden increase in intravascular pressure may occur following severe chest injuries (compression trauma such as in a seat-belt injury) or fractures of long bones (presumably due to fat embolisms or vascular spasms).

**Symptoms and diagnostic considerations.** Acute retinal ischemia with impaired vision and loss of visual acuity will occur either immediately or within 3–4 days of the injury. Examination of the fundus will reveal cottonwool spots and intraretinal bleeding indicative of focal retinal ischemia. Lines of bleeding will also be observed.

**Treatment.** Fundus symptoms will usually disappear spontaneously within 4–6 weeks. Reduced visual acuity and visual field defects may occasionally persist. Occasionally treatment with high doses of systemic steroids and prostaglandin inhibitors is attempted.

### High-Altitude Retinopathy

**Etiology.** Increased concentrations of hematocrit and hemoglobin are frequent findings in high-altitude climbers. They are caused by excessive fluid loss (up to 8 liters of water a day) as a result of the required moistening of the extremely dry, cold air that is breathed and due to sweating (as a result of strenuous climbing).

Raised hematocrit levels and hypoxia are dangerous for climbers, as they lead to:

Altitude sickness (dizziness, disorientation)

Cerebral edema

Pulmonary edema

Thromboembolism

High-altitude retinopathy

**Symptoms.** Bilateral intraretinal hemorrhage with loss of vision and scotomas.

**Treatment and prophylaxis.** Normalization of hematocrit and hemoglobin readings with isovolumetric hemodilution and treatment with pentoxifylline.

Appropriate training for high-altitude exercise includes practicing climbing and descending stages beforehand and ensuring the required fluid intake. As extremely high altitudes can compromise the microcirculation, prophylactic hemodilution after a descent may be able to prevent the high-altitude complications listed above.

Lang, Ophthalmology: A Pocket Textbook Atlas, 2nd Ed. (ISBN 978-1-58890-555-0), copyright © 2007 Thieme Medical Publishers. All rights reserved. Usage subject to terms and conditions of license.