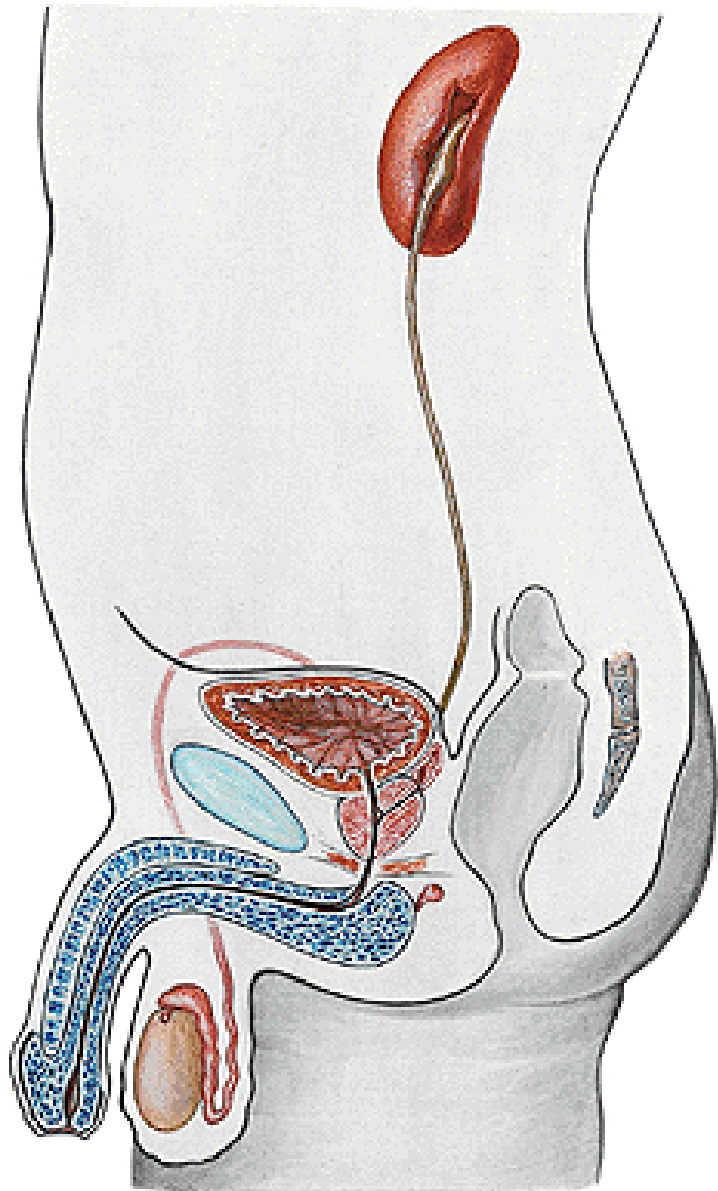


ORGANA URINARIA



Ren

Calices renales

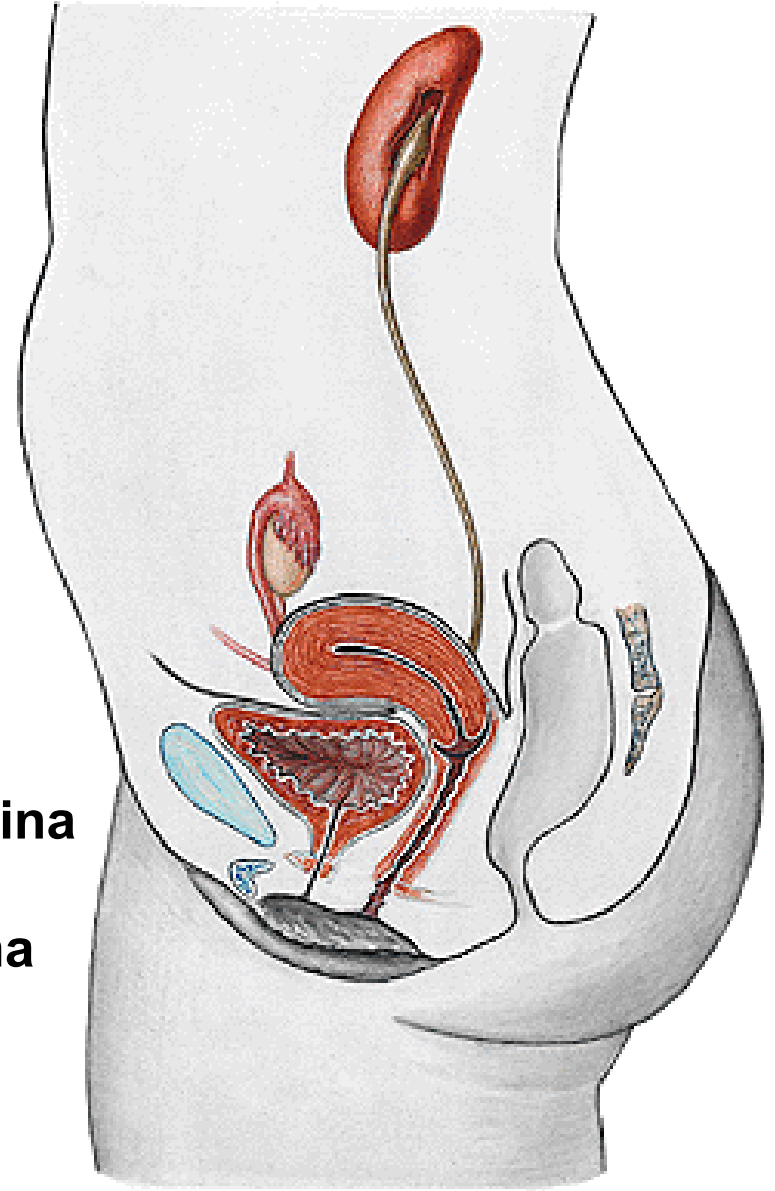
Pelvis renalis

Ureter

Vesica urinaria

Urethra masculina

Urethra feminina



REN (NEPHROS)

Extremitas superior

Extremitas inferior

Facies anterior

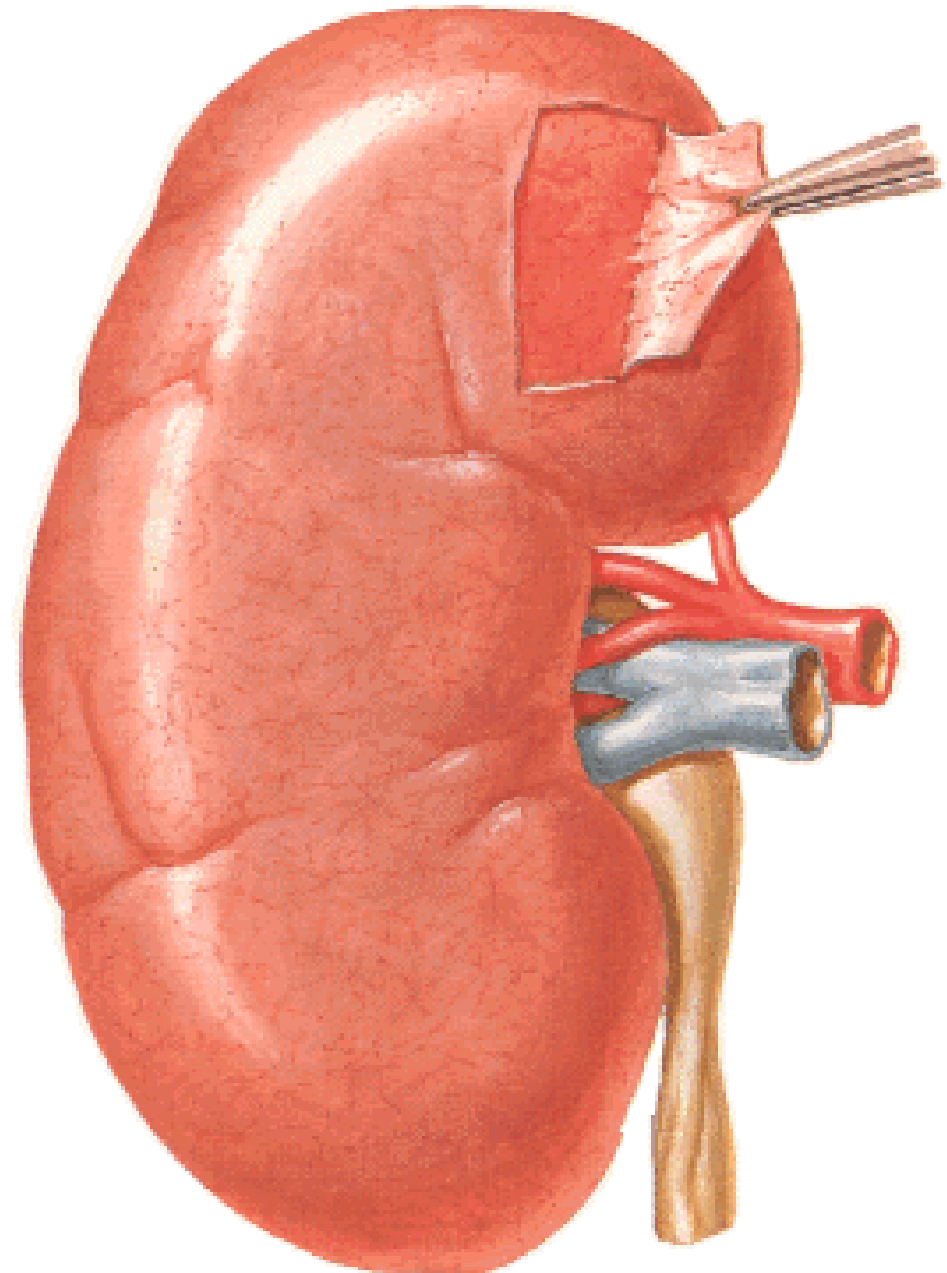
Facies posterior

Margo lateralis

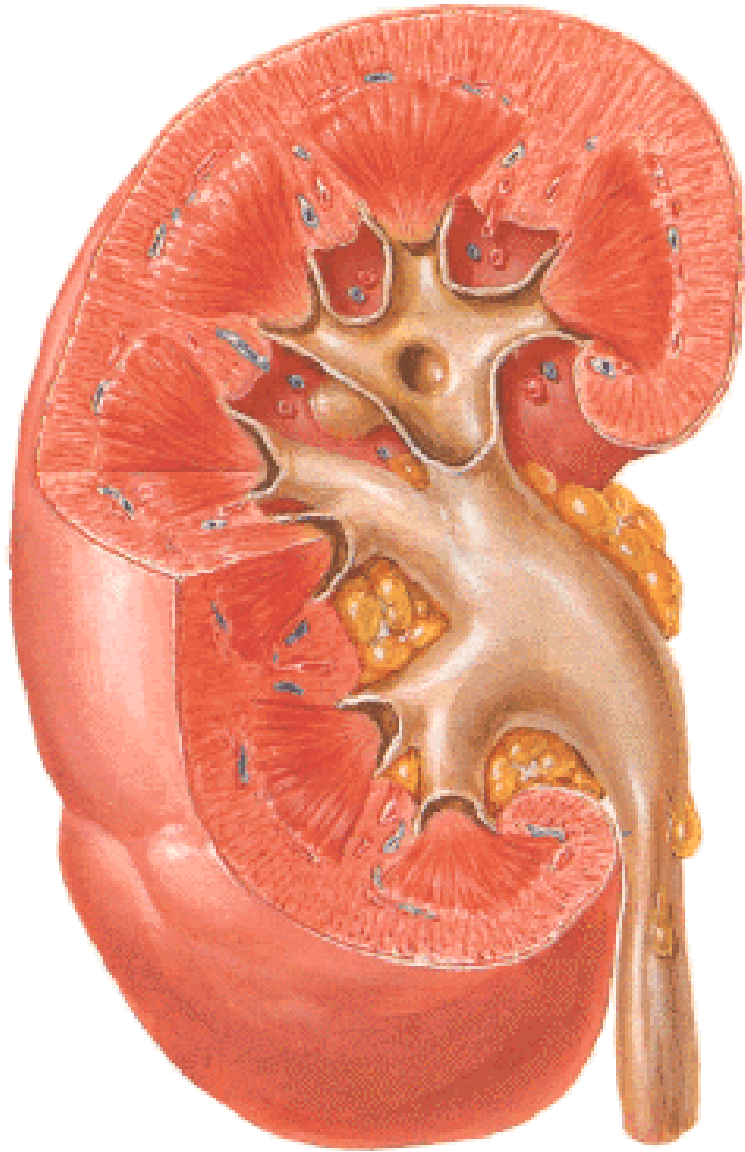
Margo medialis

Capsula fibrosa

Hilus (hilum) renalis



STAVBA LEDVINY



Capsula fibrosa

Cortex renalis

Medulla renalis

Columnae renales

Pars radiata corticis

Pyramides renales (6-20)

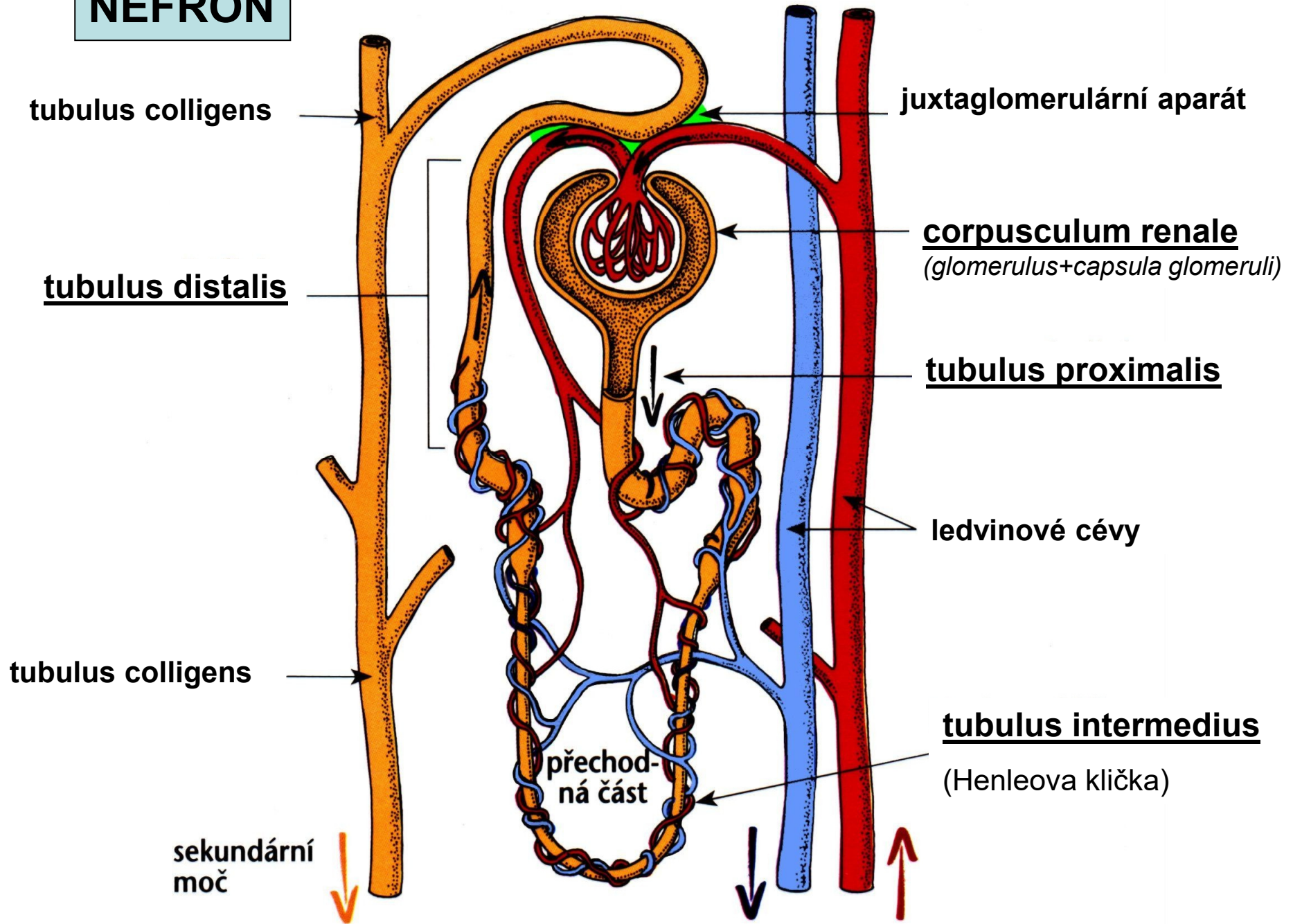
Papilla renalis

Foramina papillaria (ductus papillares)

Area cribrosa

Lobulus renalis (renculus)

NEFRON



SINUS RENALIS:

Calices renales

Pelvis renalis

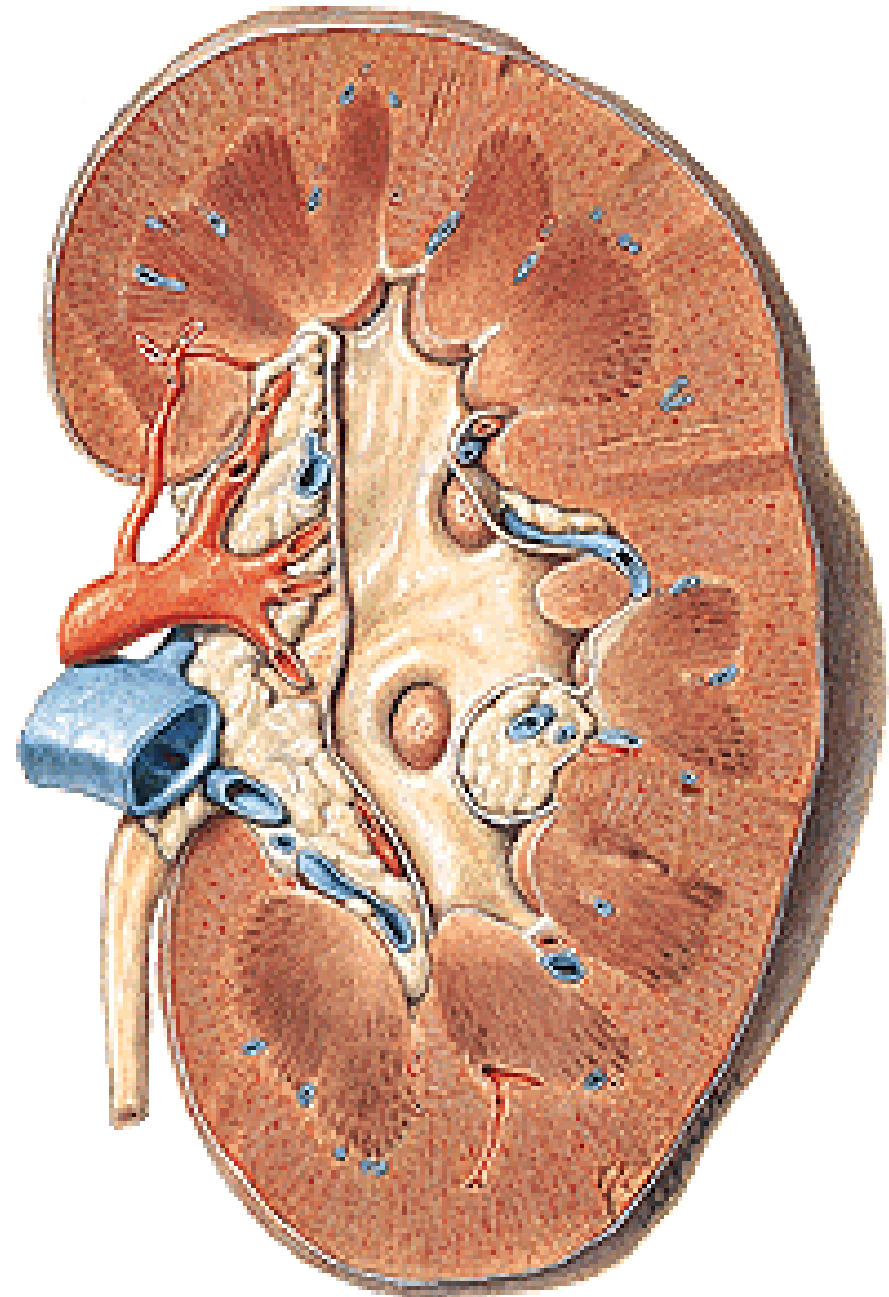
Arteria renalis

Vena renalis

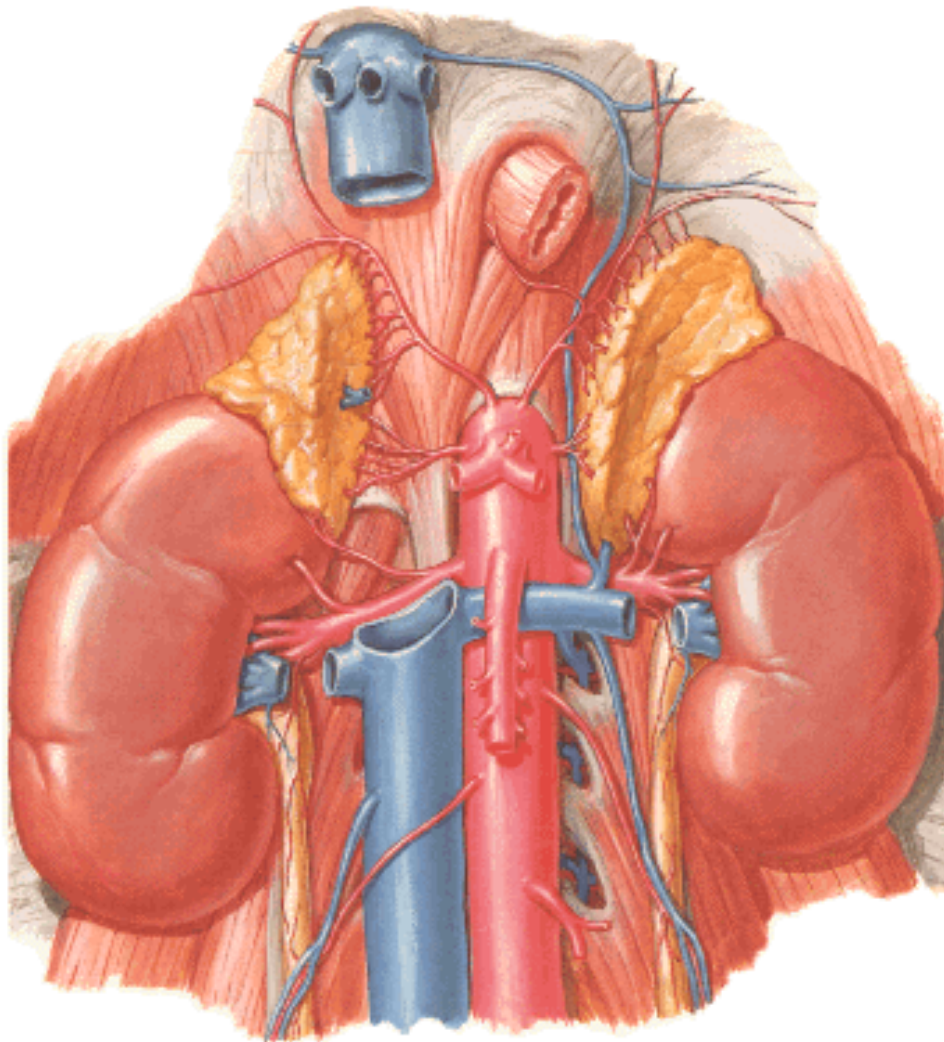
Plexus renalis

Mízní cévy

Tuková tkáň



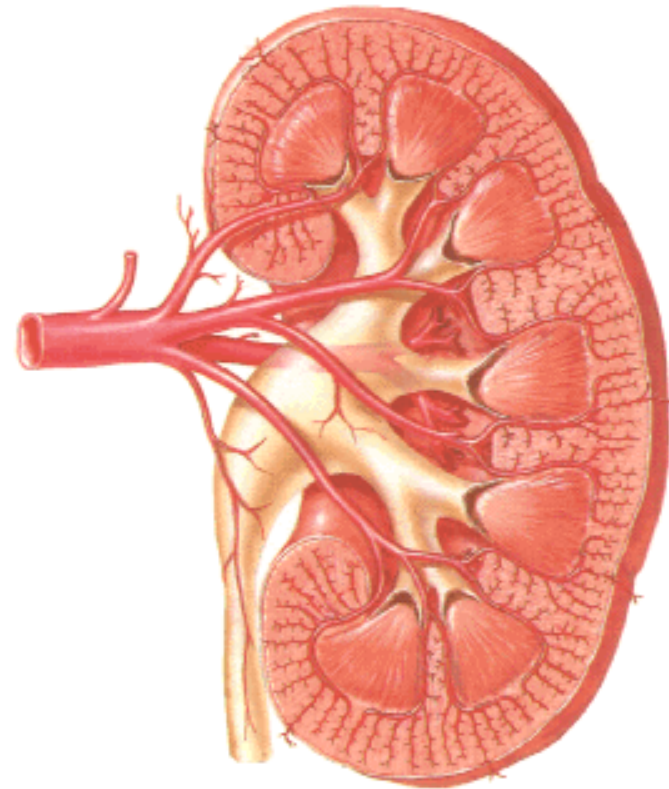
ARTERIA RENALIS



1,2-2 l krve /min., 5l za 4-5min.

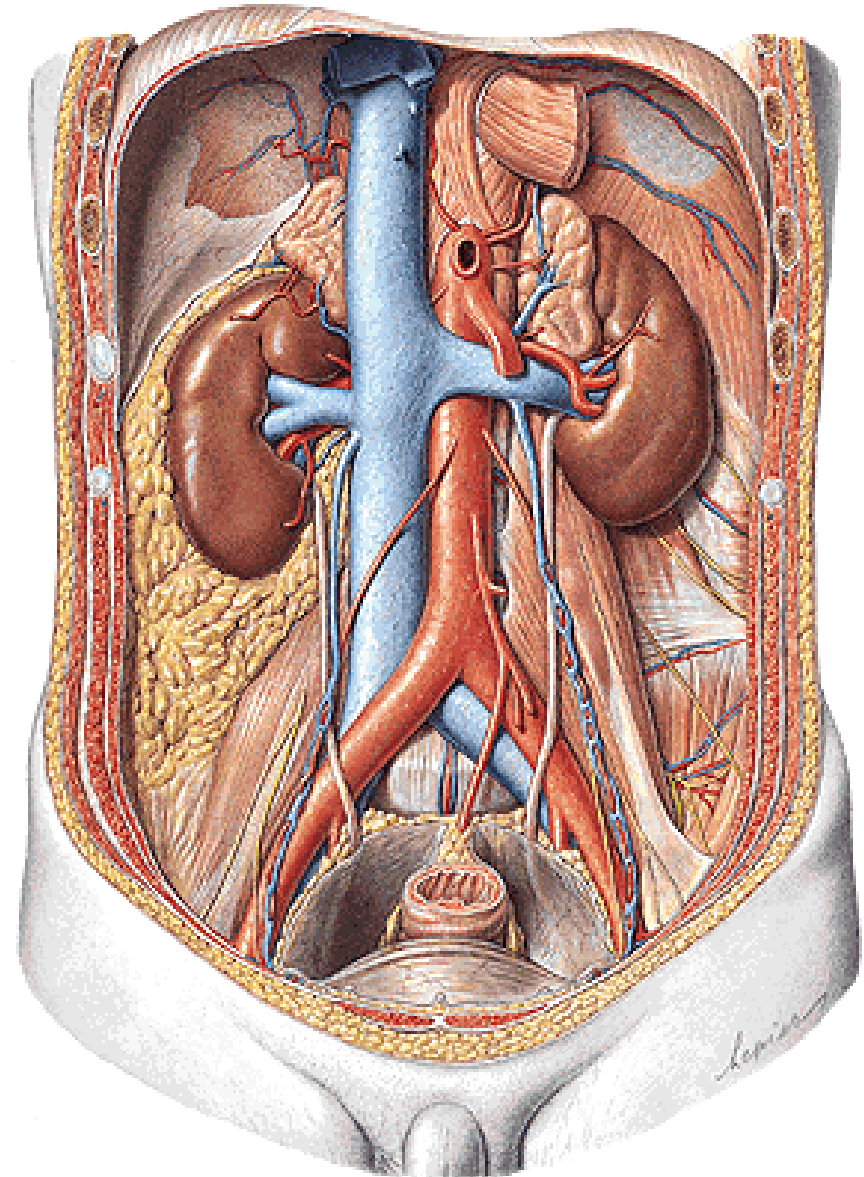
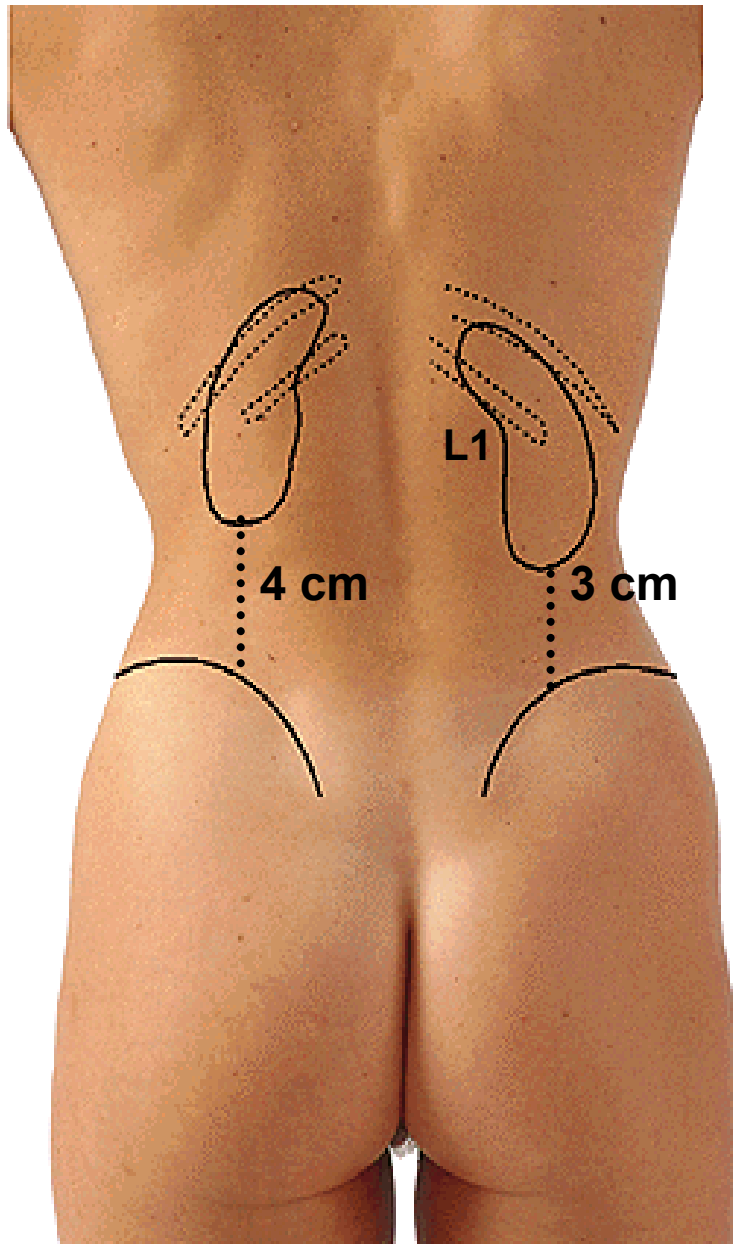
2-4 rami praepelvici } segmentální
ramus retropelvicus } tepny

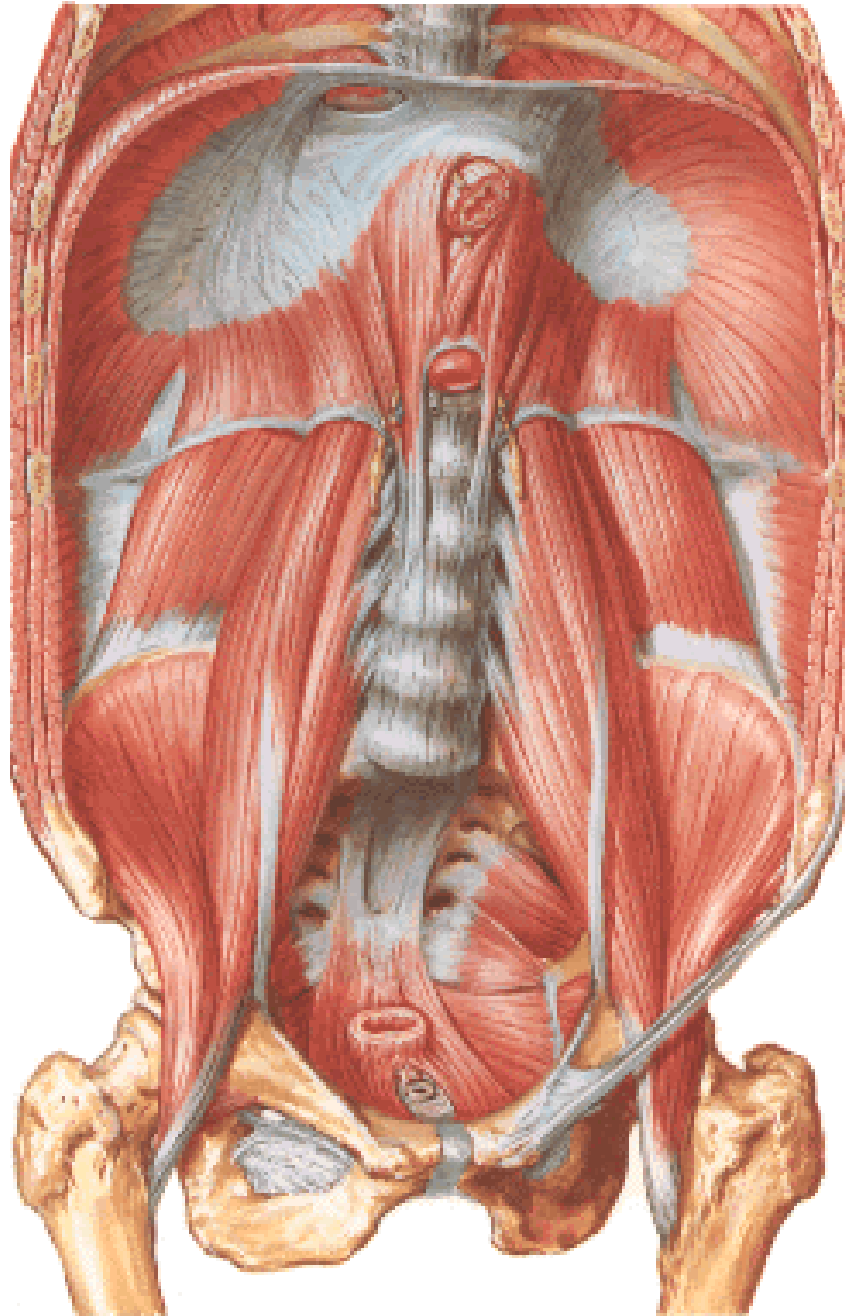
Brödelova čára



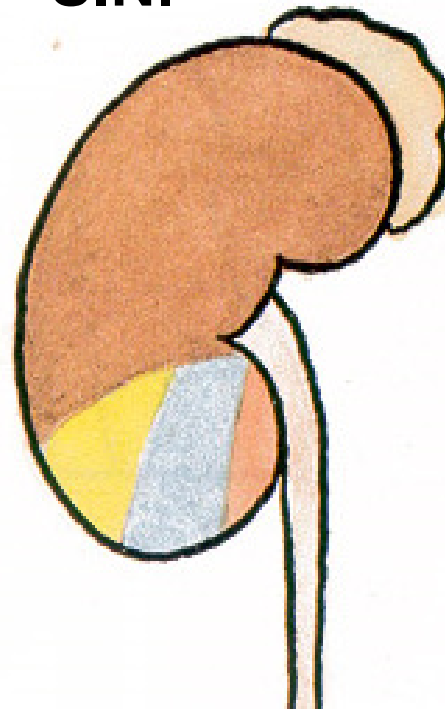
Poloha ledvin

Primárně retroperitoneální orgán

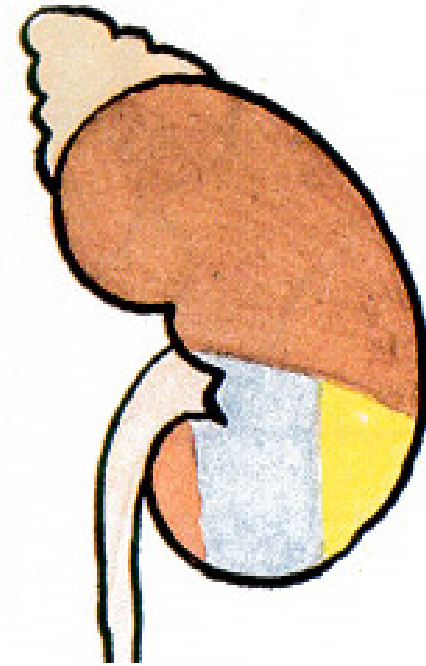




SIN.



DX.

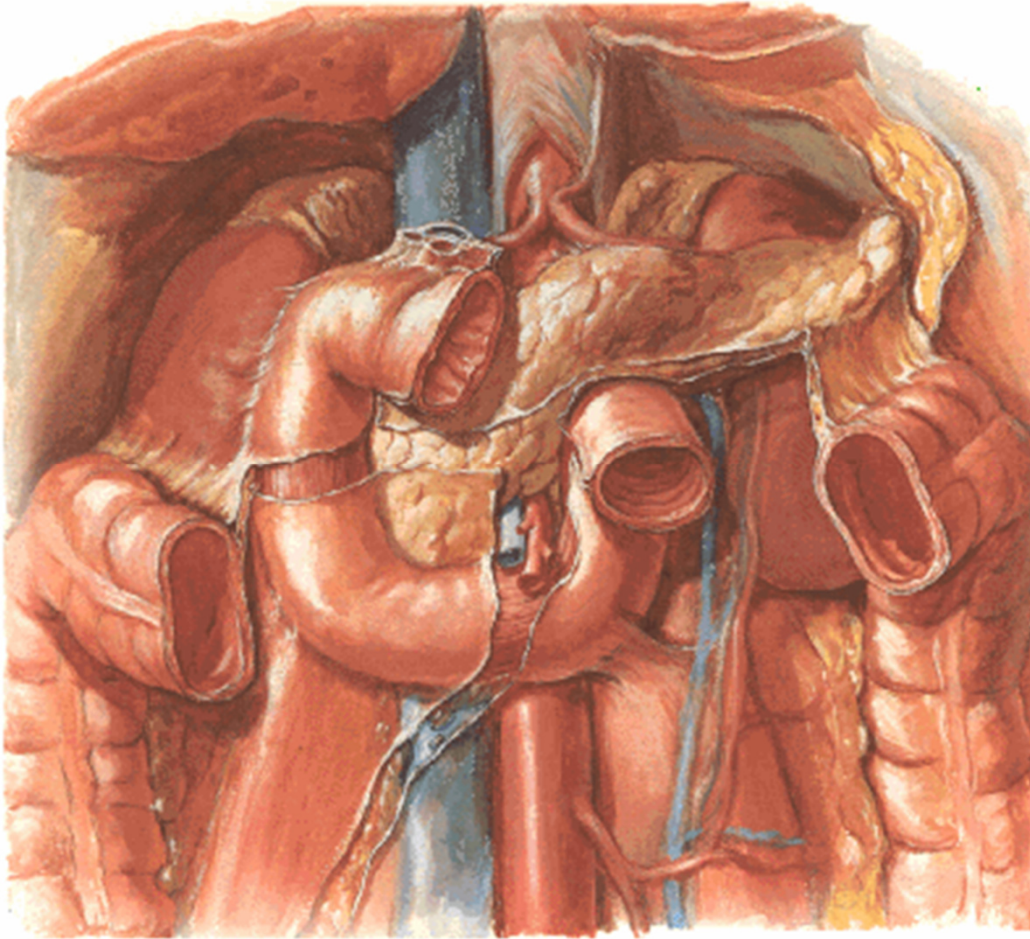


Bránice

Musculus transversus abd.

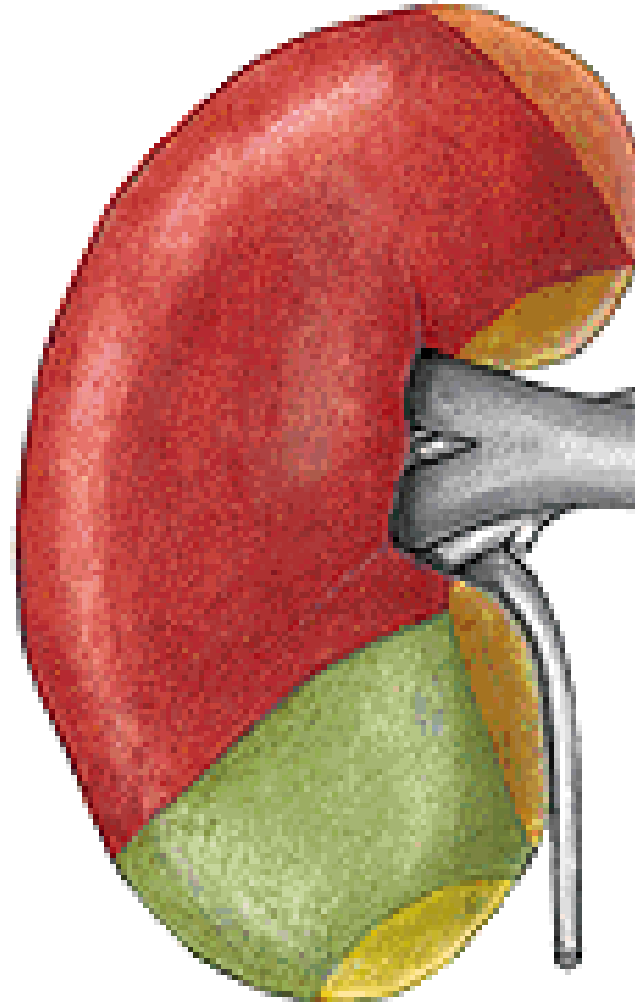
Musculus quadratus lumborum

Musculus psoas major

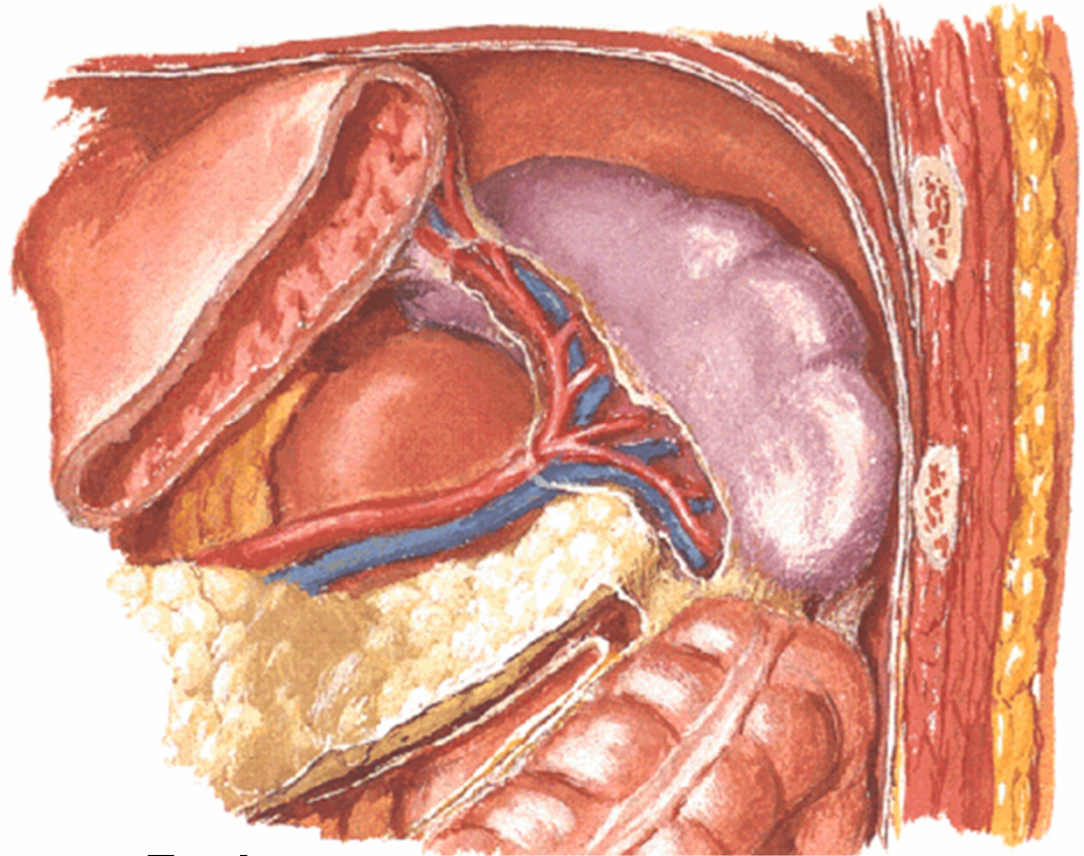
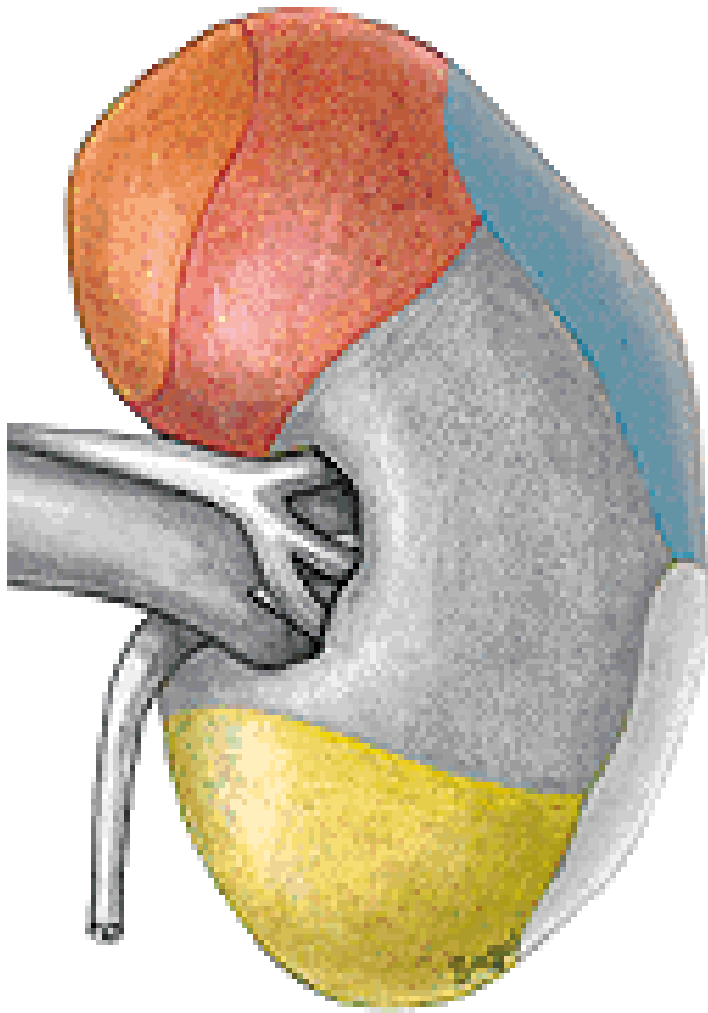


**Facies: suprarenalis, hepatica,
duodenalis, colica, jejunalis**

DX.



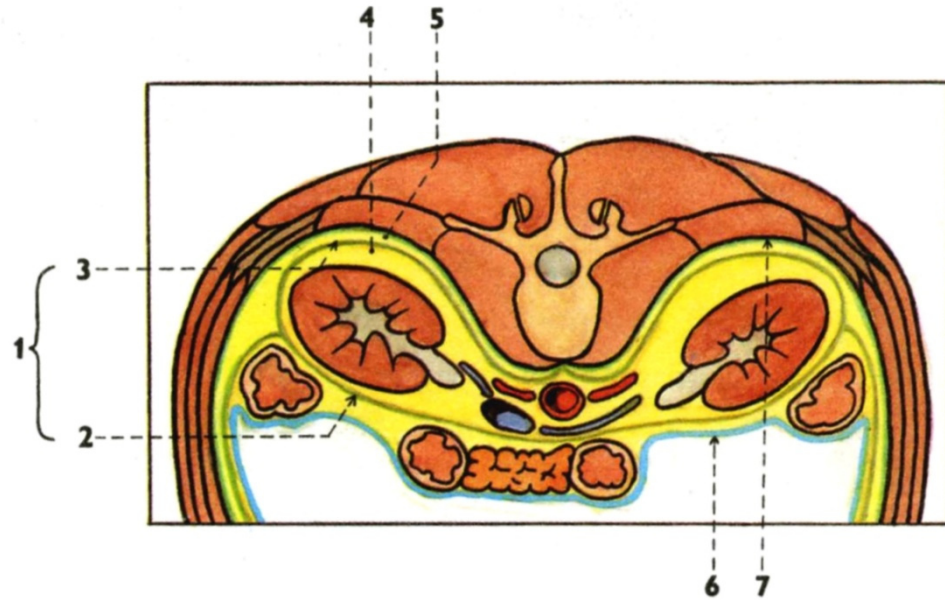
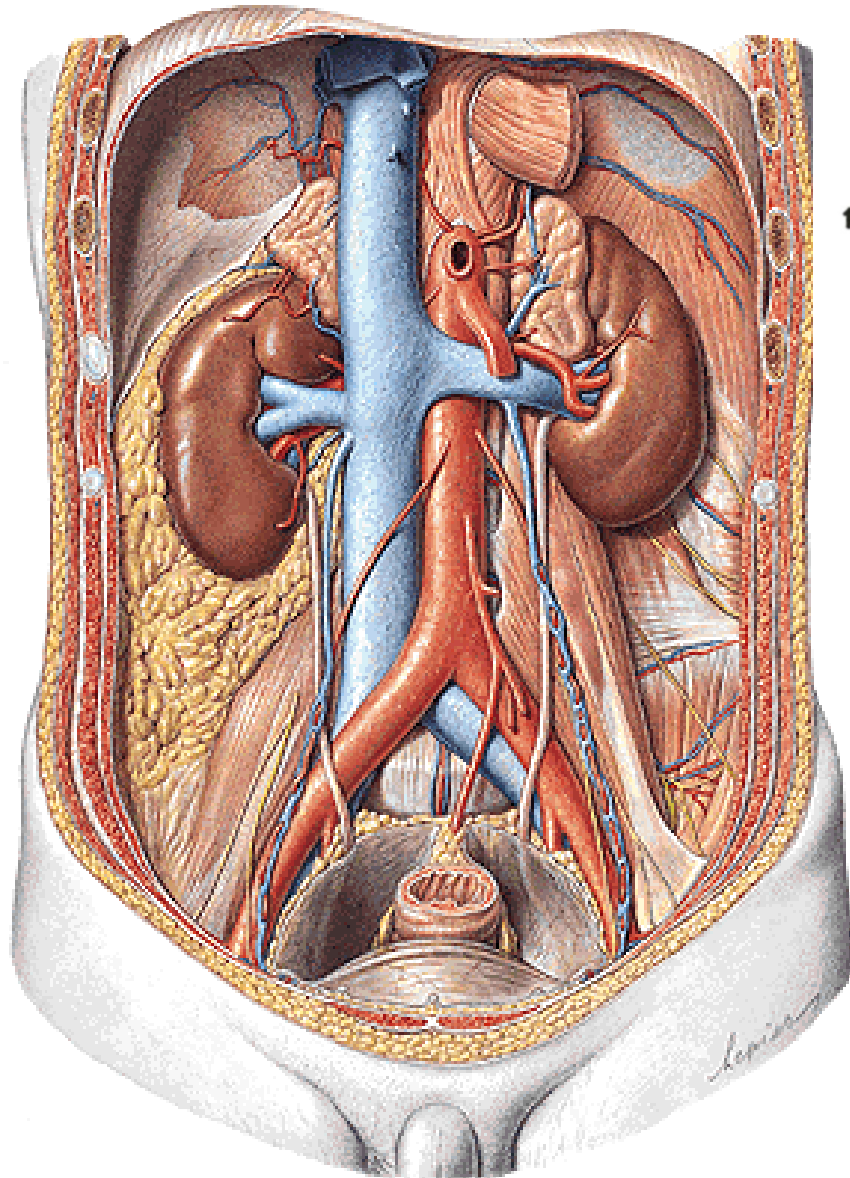
Sin.



Facies:

**suprarenalis, gastrica, lienalis,
pancreatica, colica, jejunalis**

Obaly ledviny



Capsula adiposa

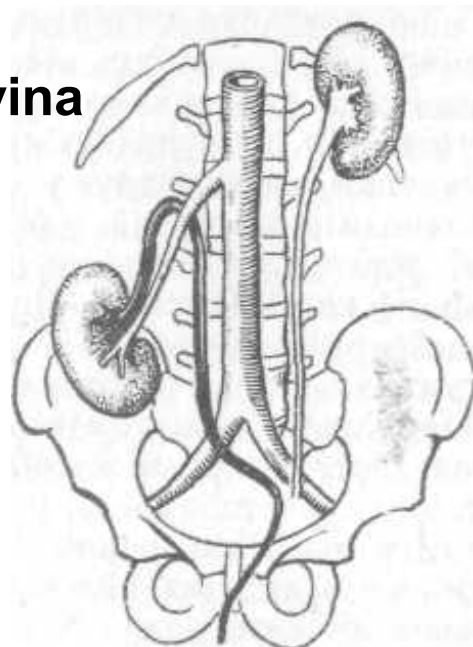
Fascia renalis

Lamina praerenalis

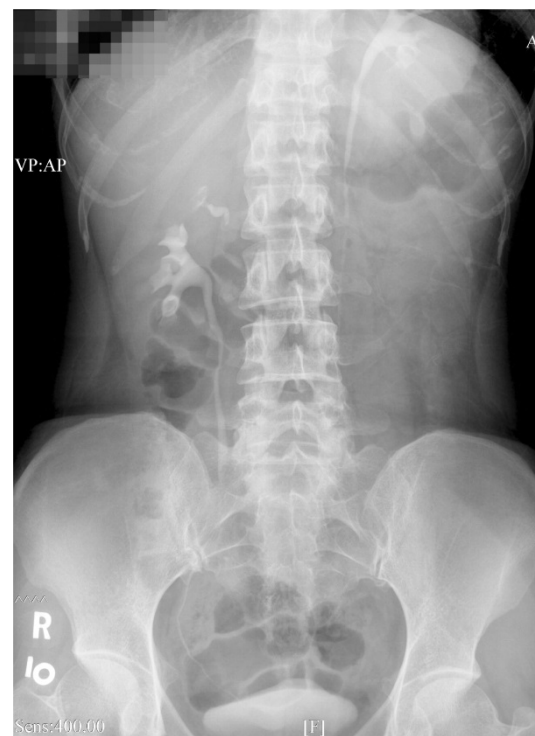
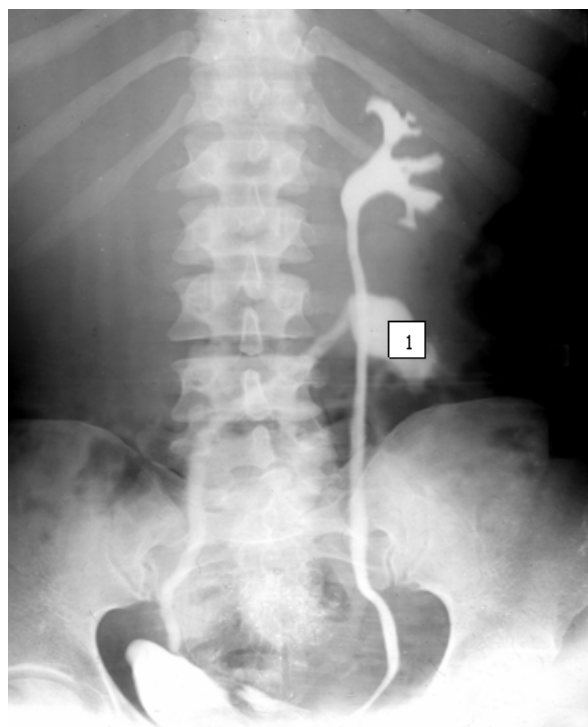
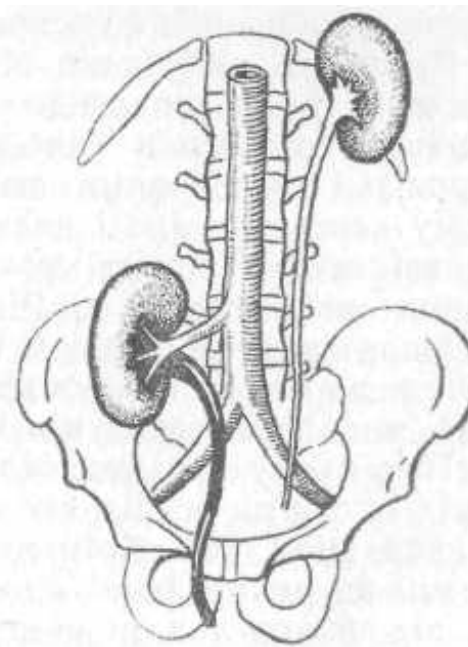
Lamina retrorenalis

Corpus adiposum pararenale

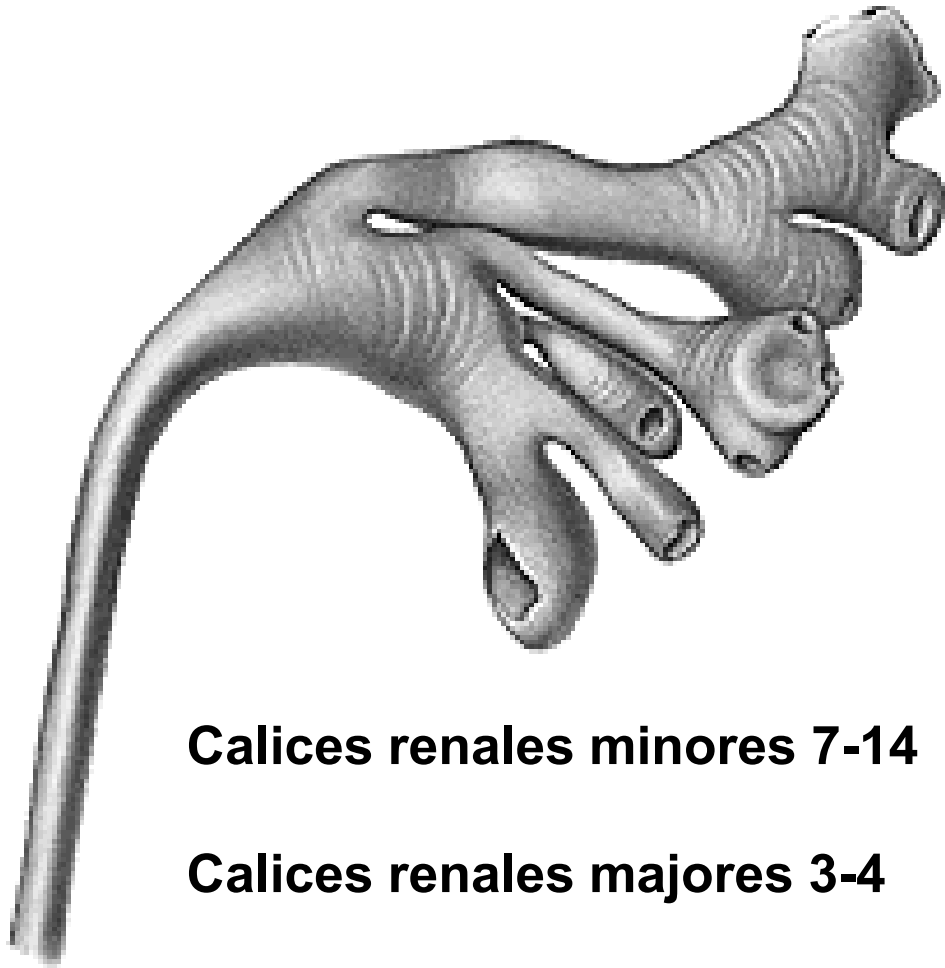
Ren migrans
Bloudivá ledvina



Dystopická
ledvina

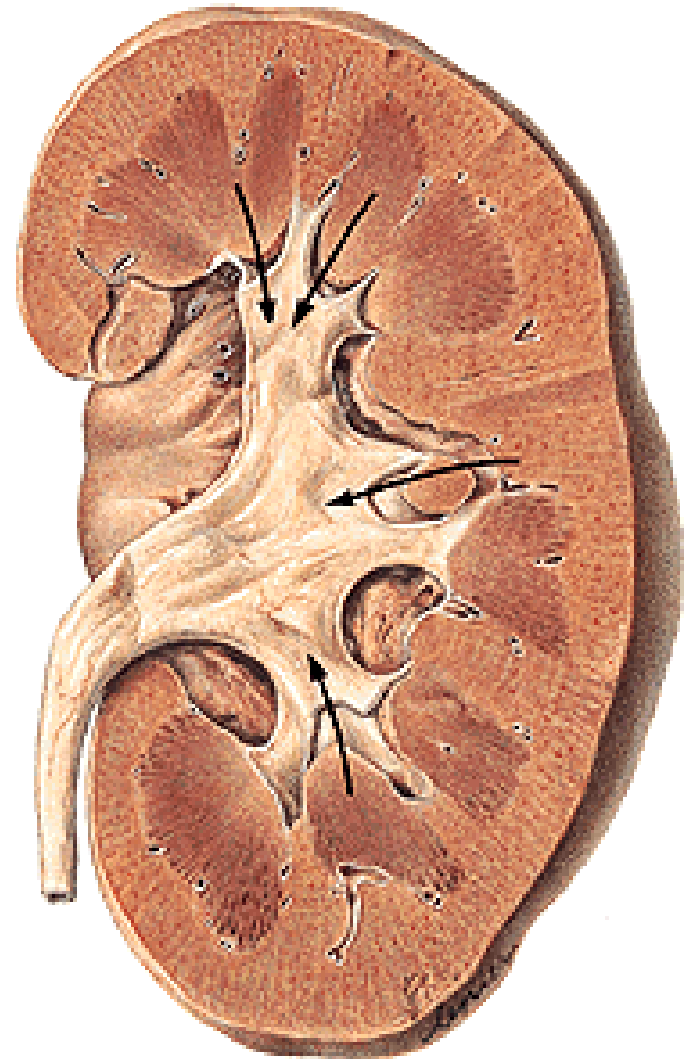


CALICES RENALES

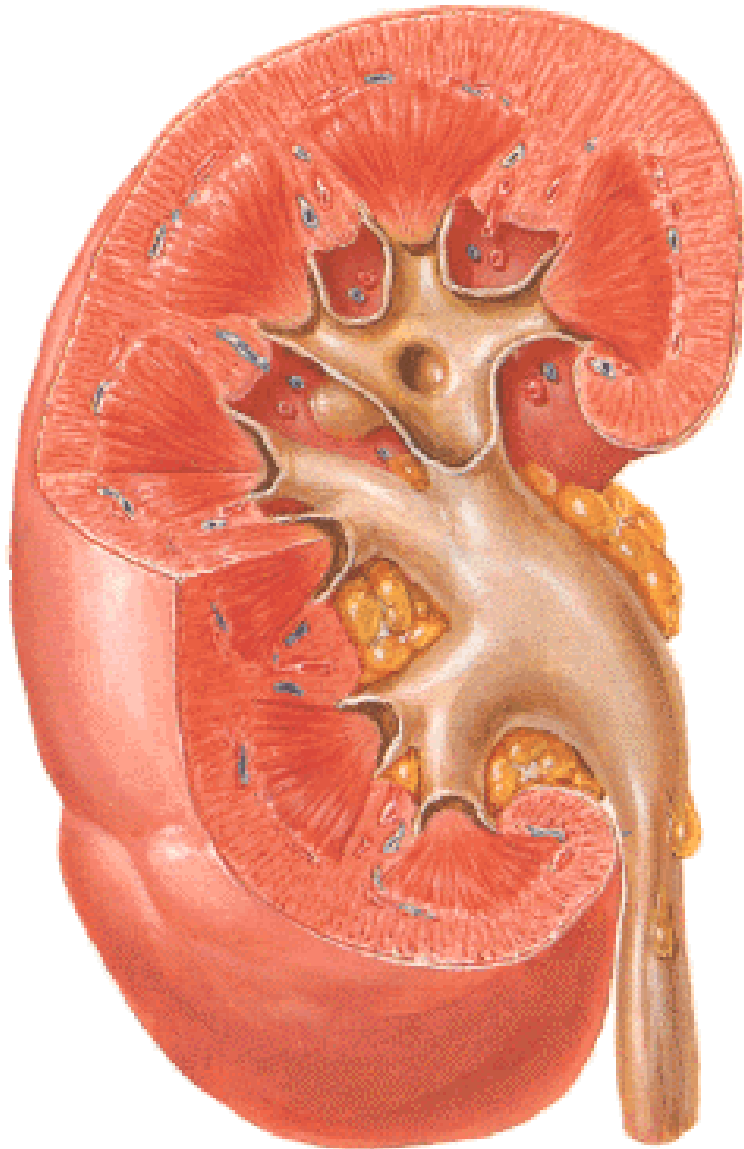


Calices renales menores 7-14

Calices renales mayores 3-4



PELVIS RENALIS



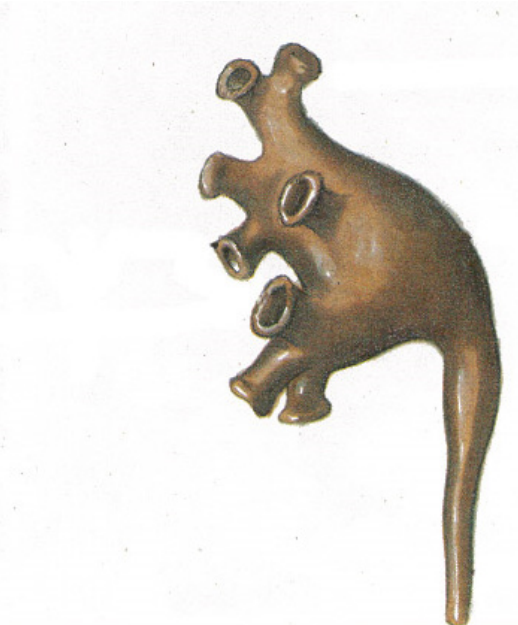
Kapacita: 2-5 ml

Uložení: sinus renalis

hilus renalis

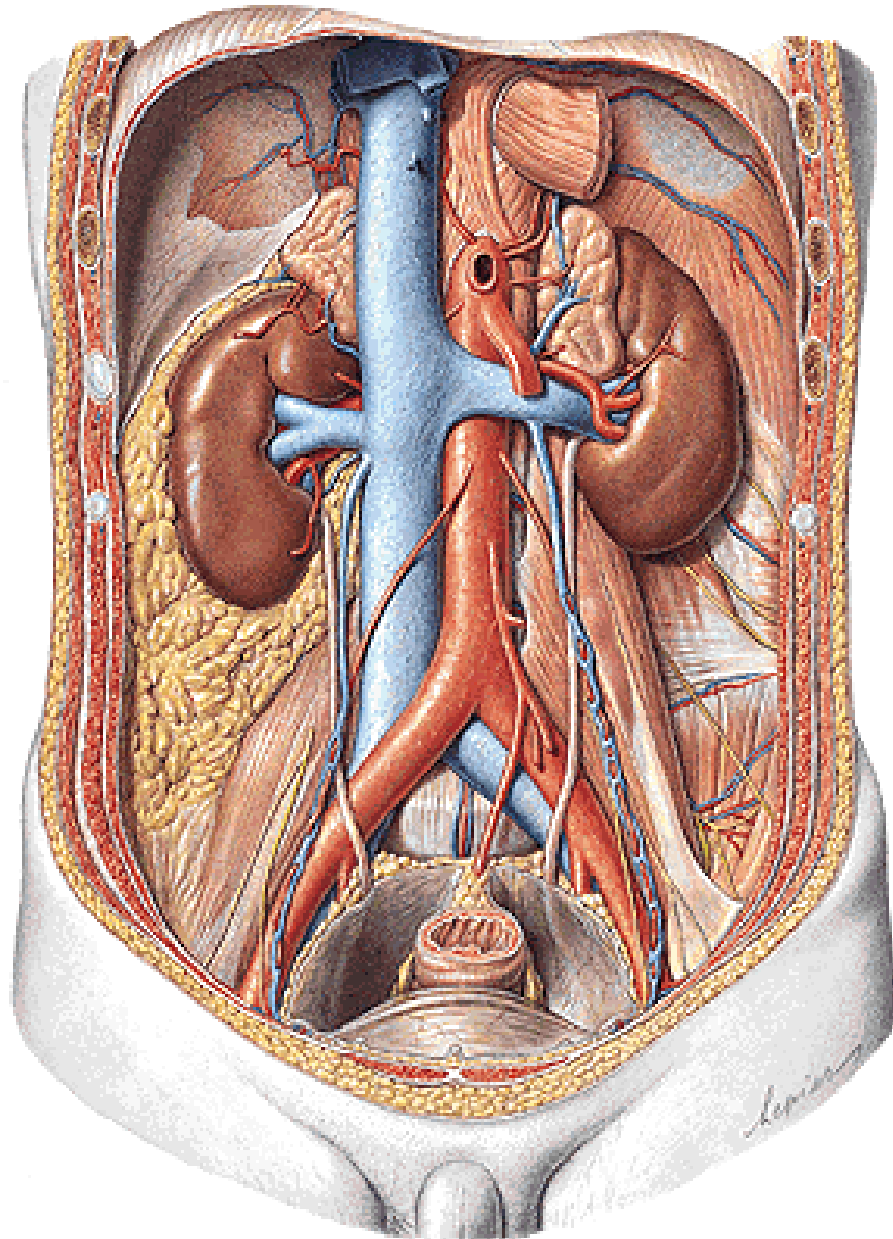


Dendritický typ



Ampulární typ

URETER



25-35 cm

Pars abdominalis

pelvis renalis - linea terminalis

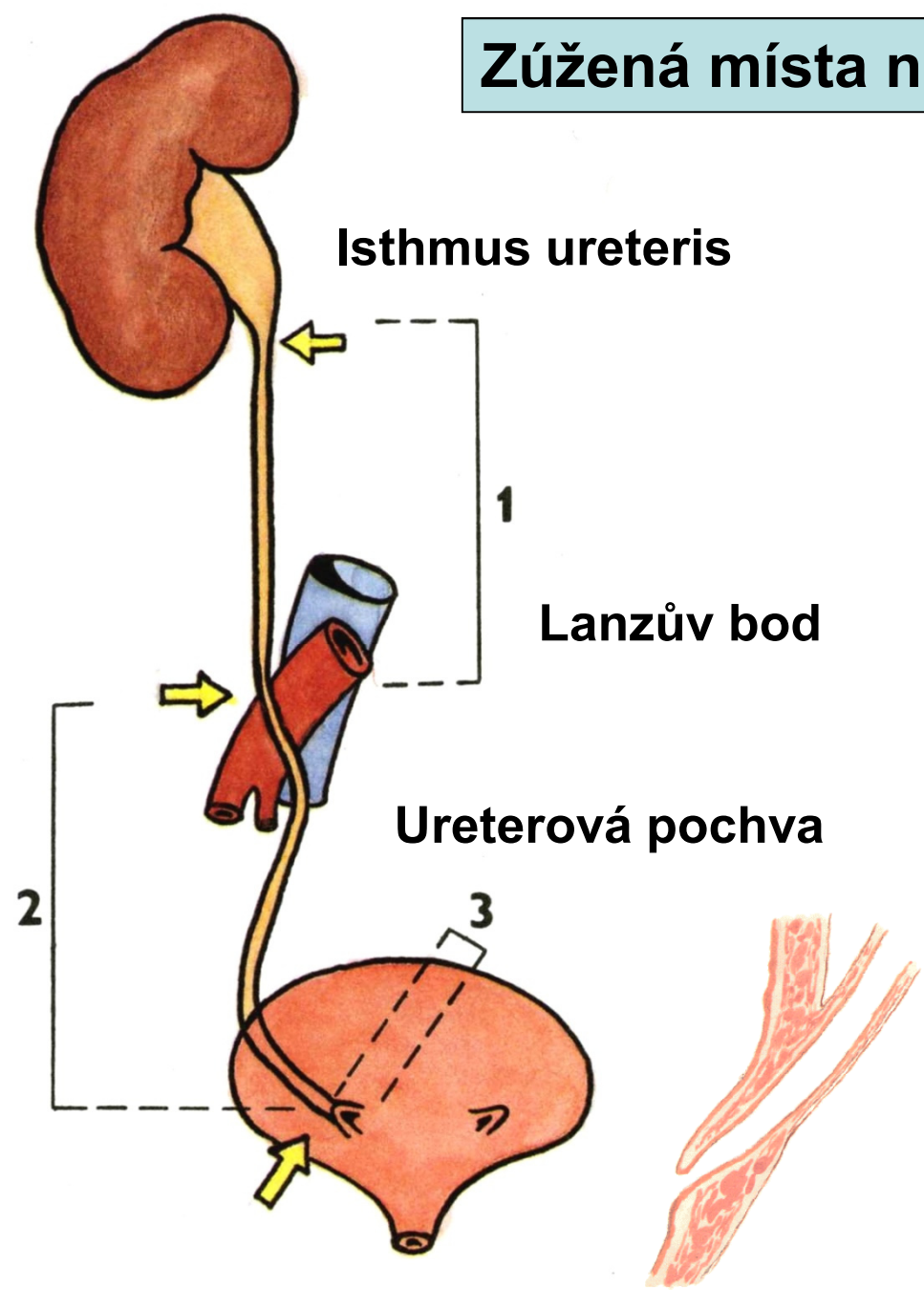
Pars pelvina

linea terminalis - vesica urinaria

Pars intramuralis

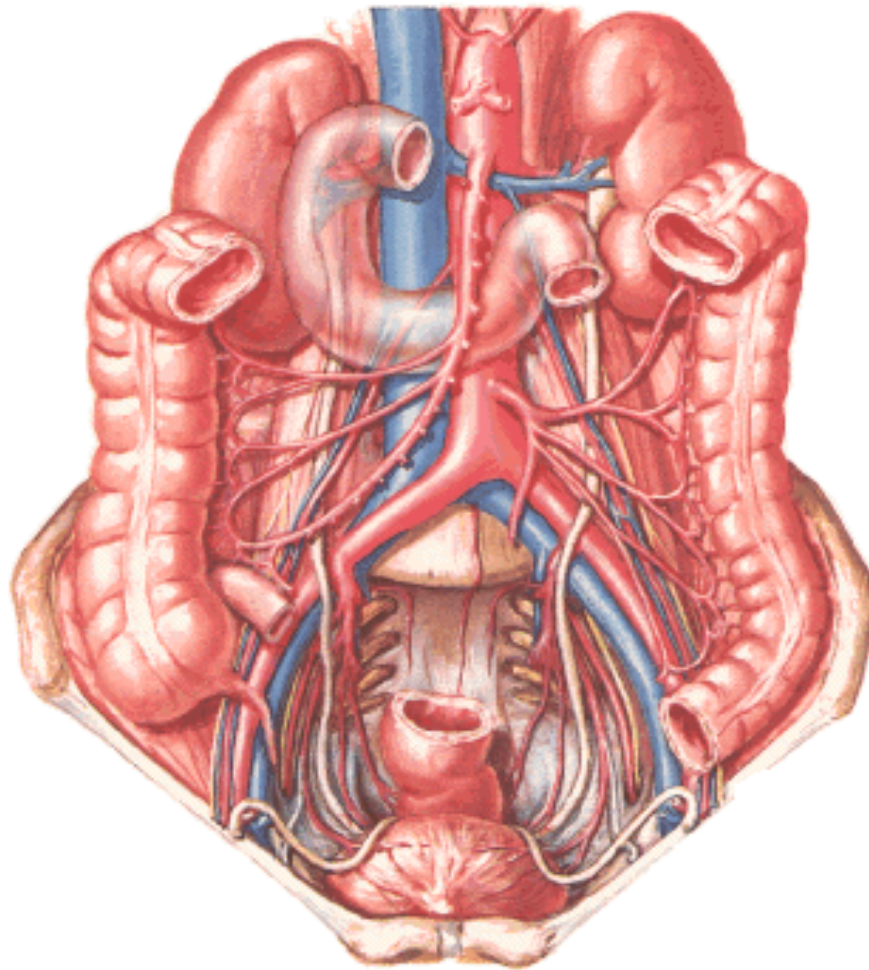
stěna moč. měchýře - ostium ureteris

Zúžená místa na ureteru

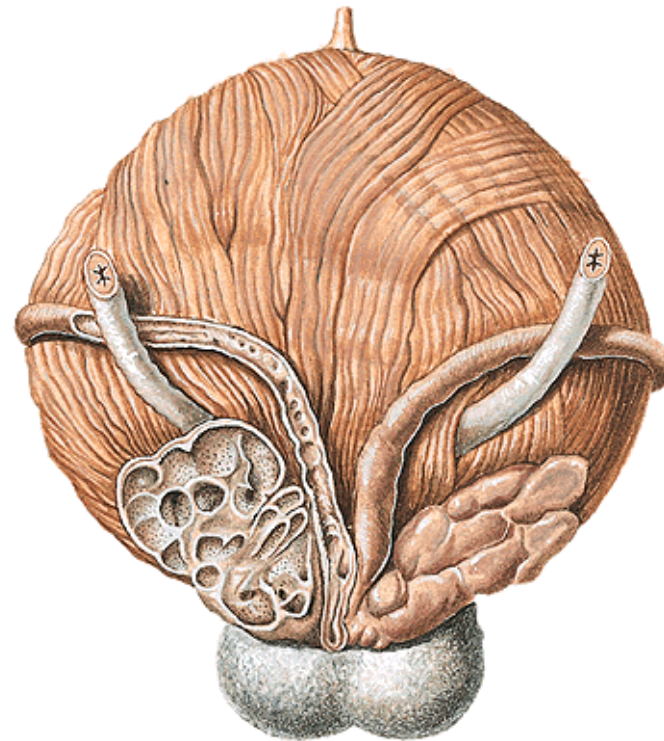


Překřížení ureteru

s vasa iliaca comm.



s ductus deferens



Vesica urinaria

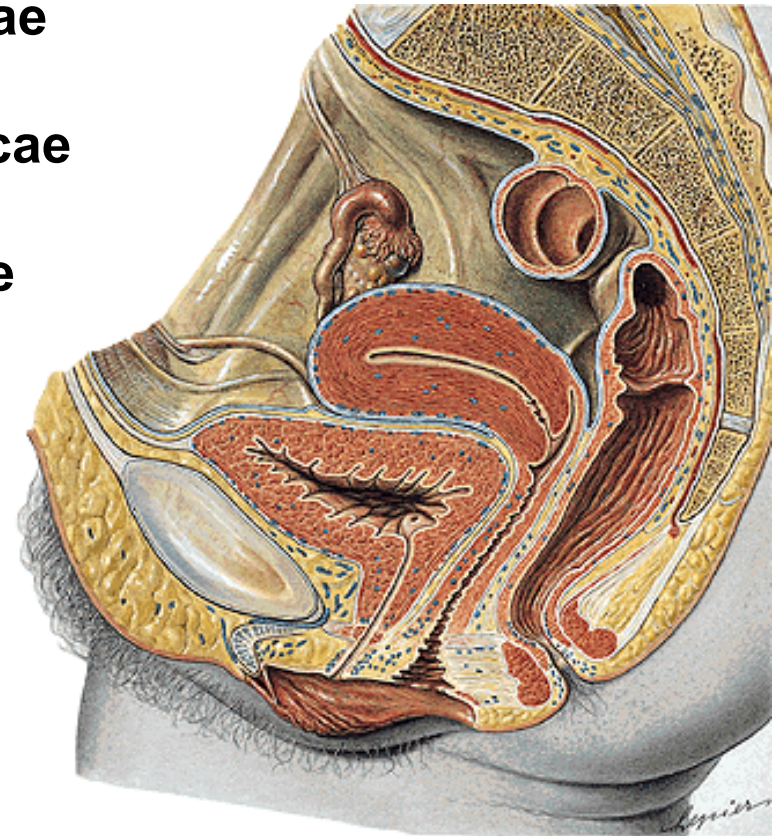
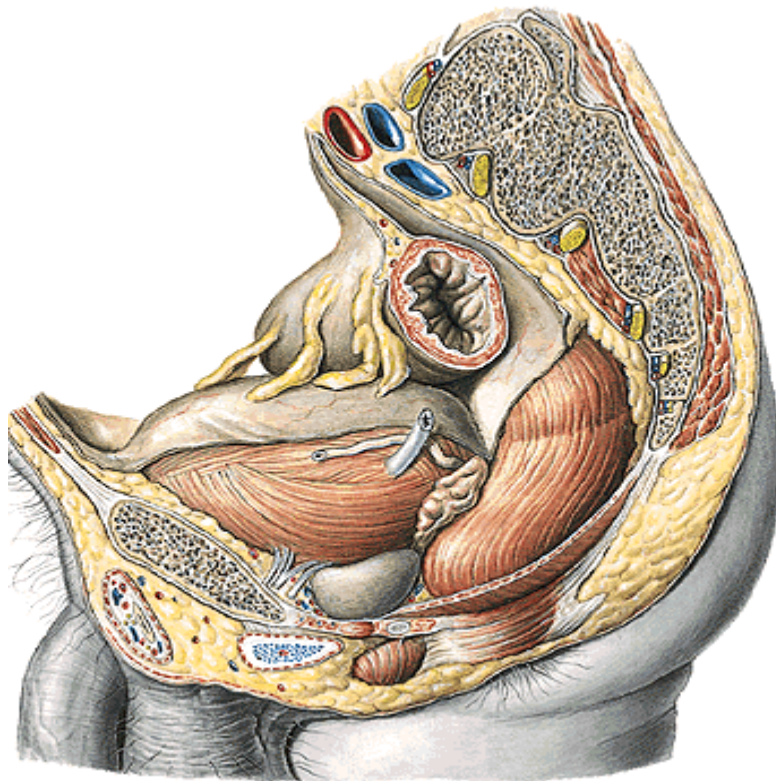
250-300 ml, max. asi 750 ml

Fundus vesicae

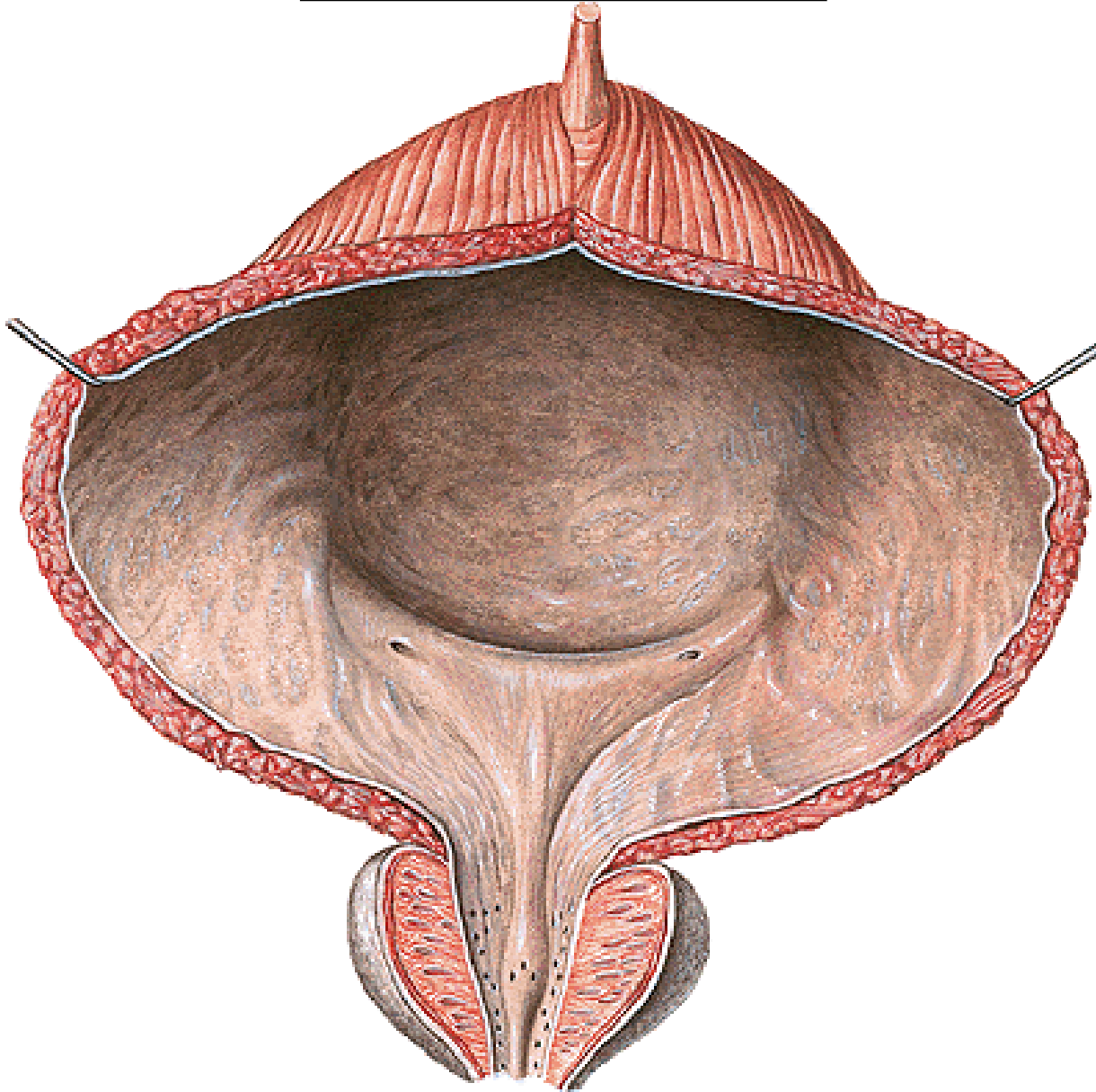
Cervix vesicae

Corpus vesicae

Apex vesicae



Trigonum vesicae



Ostia ureterum

(plicae uretericae)

Ostium urethrae internum

(uvula, anulus urethralis)

Plica interureterica

Bellovy snopce

Fossa retrotrigonalis

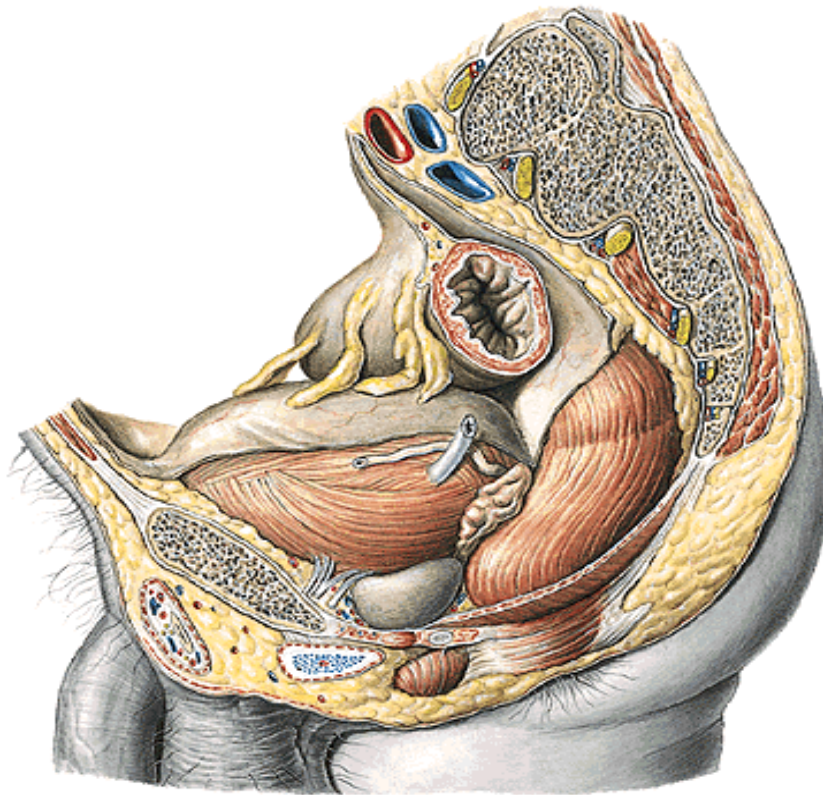
Fossae paratrigonales

Musculus trigonalis

Peritoneum a adventicia

excavatio rectovesicalis

fascia vesicae, paracystium



Fixace moč. měchýře

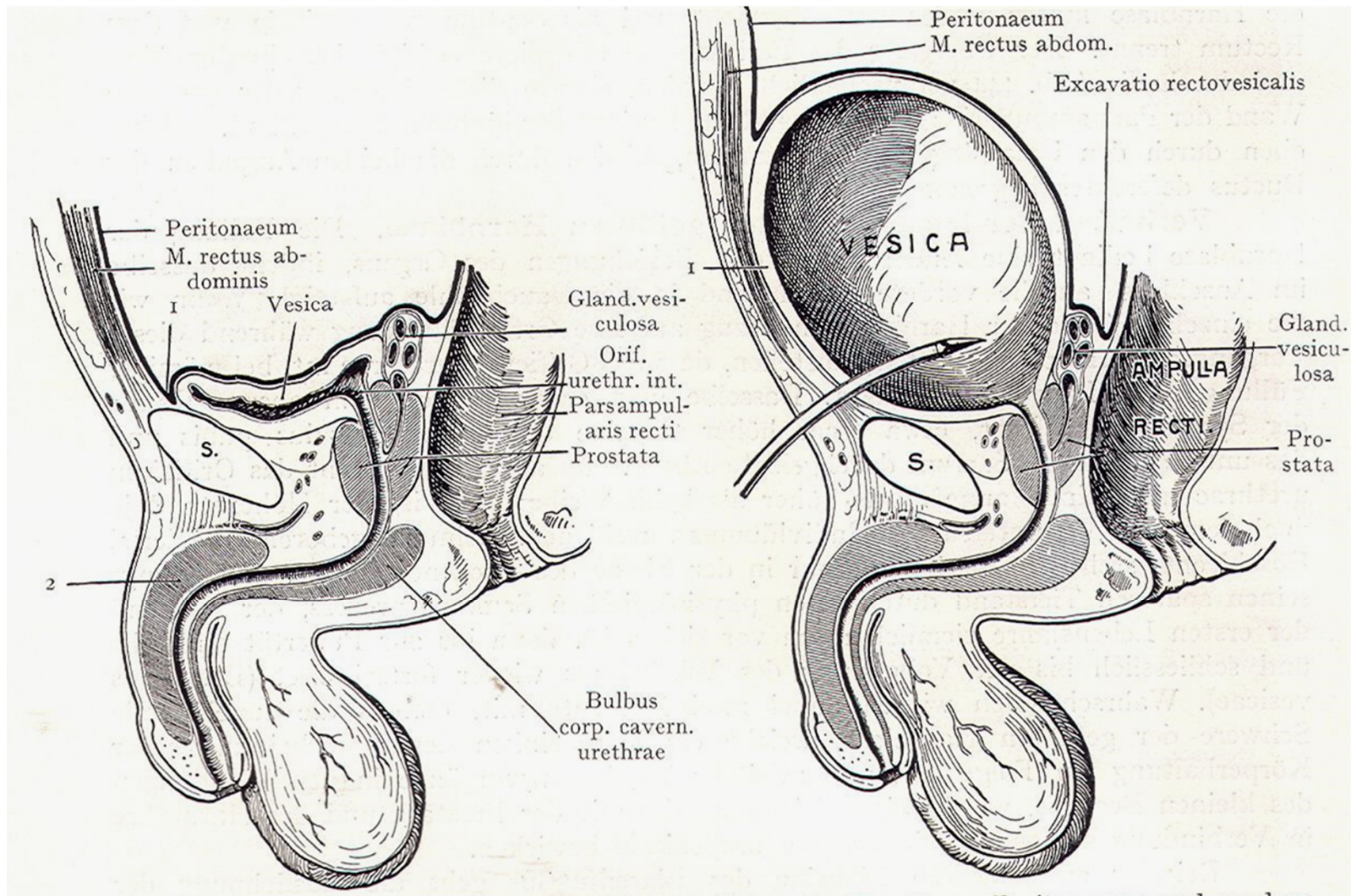
ligg. pubovesicalia

ligg. puboprostatica

ligg. rectovesicalia
(m. rectovesicalis)

septum rectovesicale

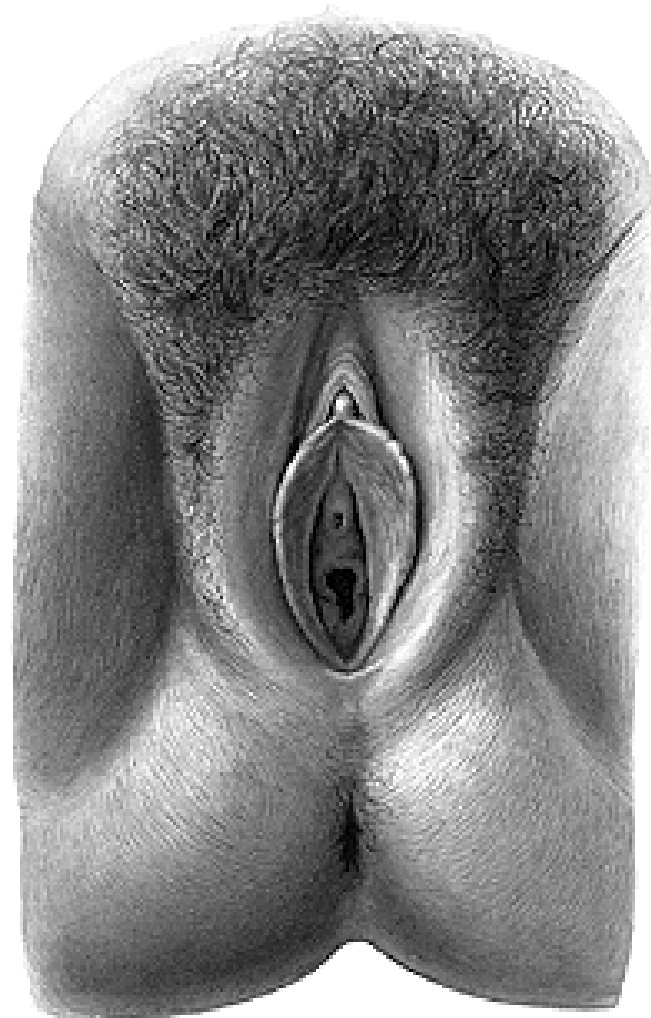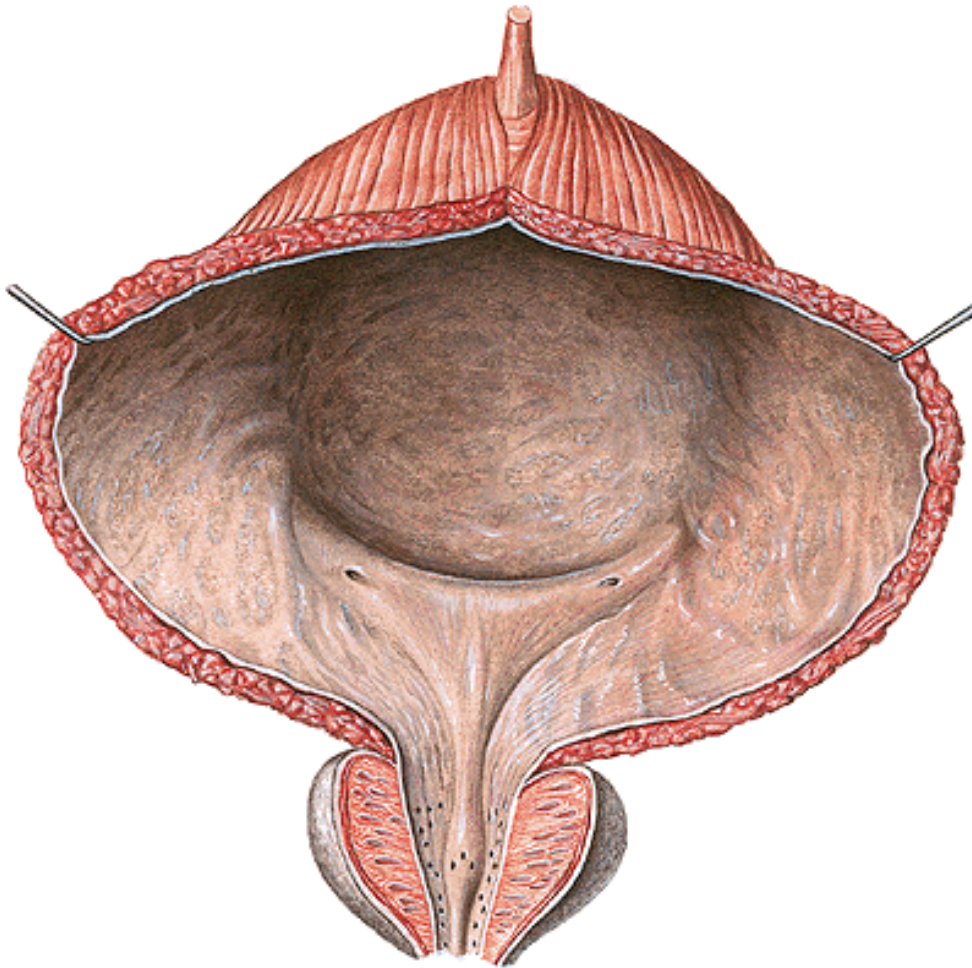
Praeperitoneální a subperitoneální poloha močového měchýře



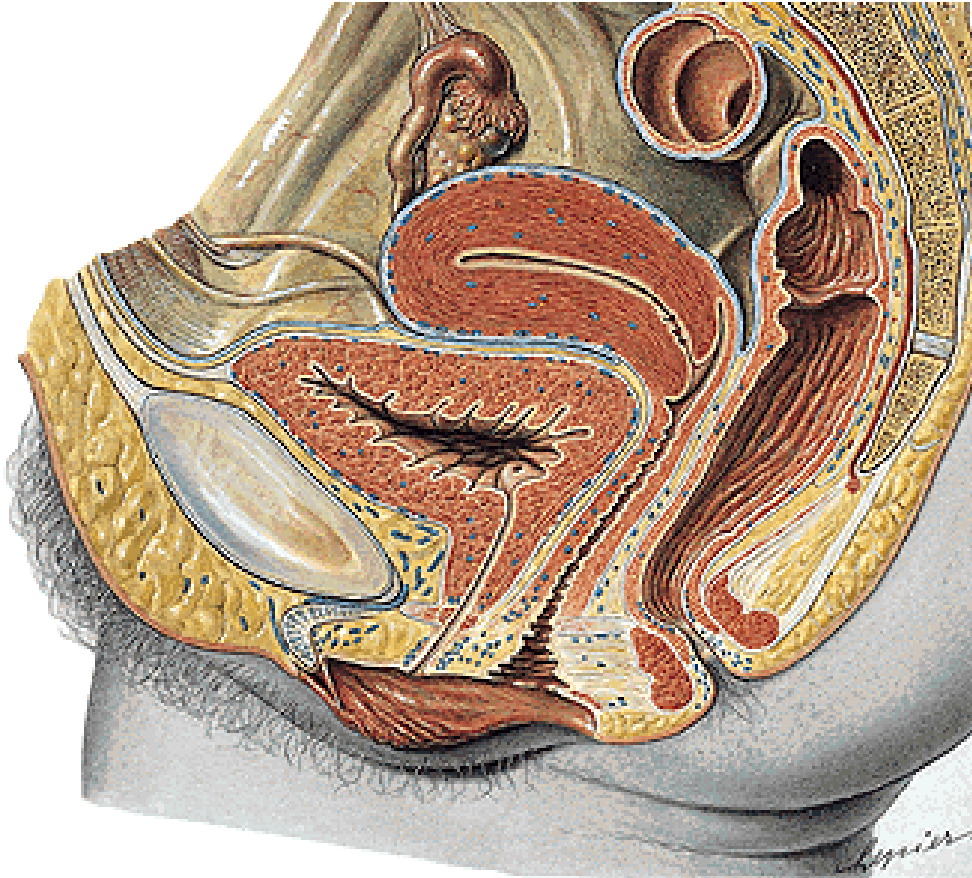
Urethra feminina

Ostium urethrae internum (trigonum vesicae)

Ostium urethrae externum (papilla urethralis ve vestibulum vaginae)



Urethra feminina



pouze vývodná cesta močová

4-6cm

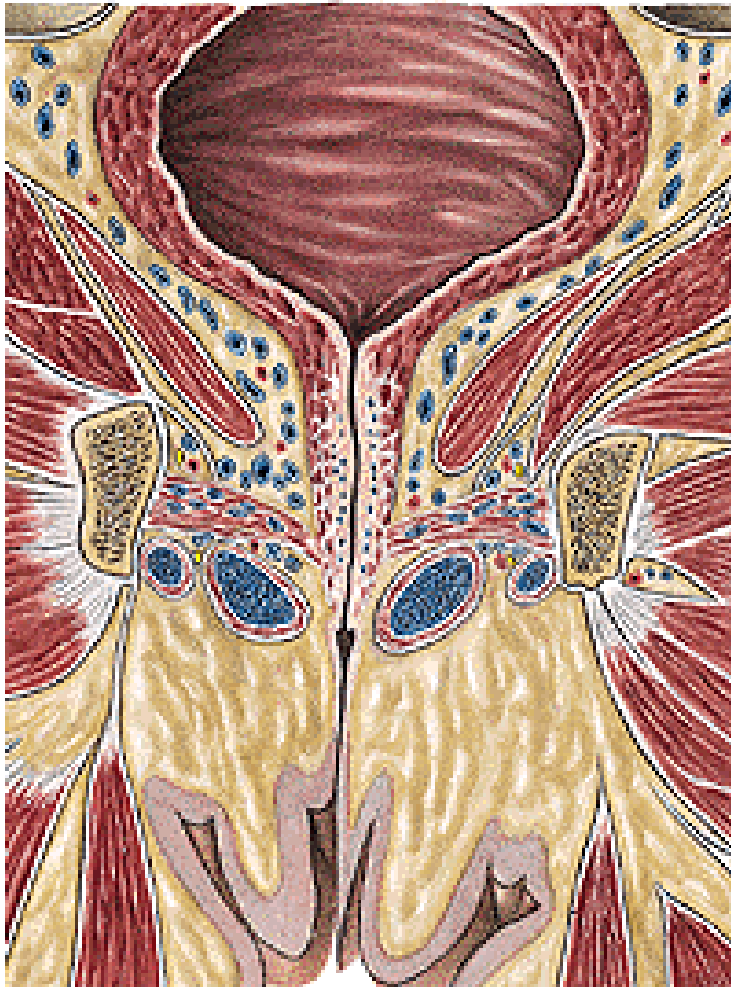ventrálně – retropubický prostor

dorsálně – vagina

crista urethralis vaginae

septum urethrovaginale

Urethra feminina



Pars intramuralis

m. sphincter vesicae

(m. sphincter urethrae int.)

(m. lissosphincter urethrae)

Pars pelvina (k hiatus urogenitalis)

Pars diaphragmatica

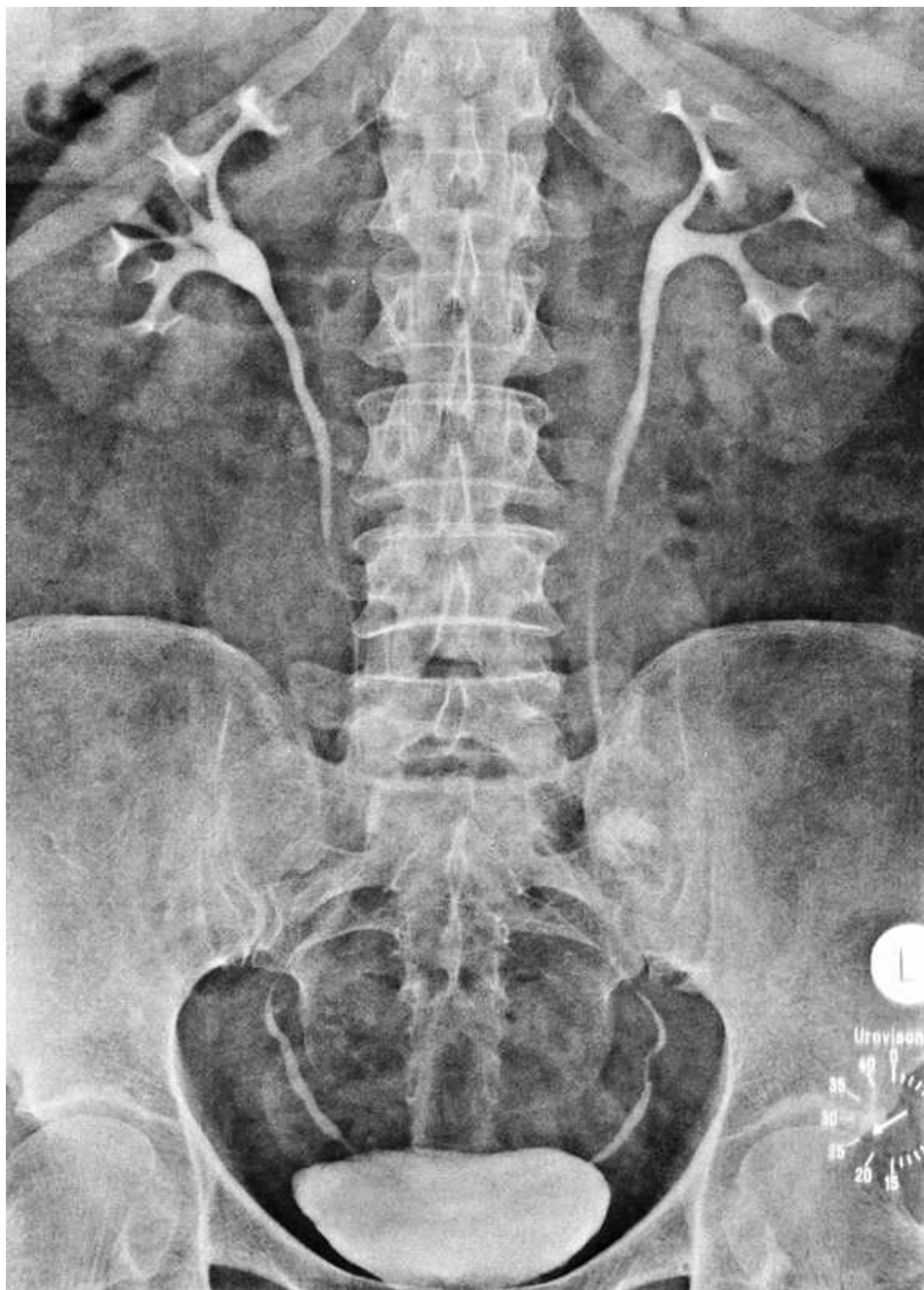
m. sphincter urethrae (ext.)

(m. rhabdosphincter urethrae)

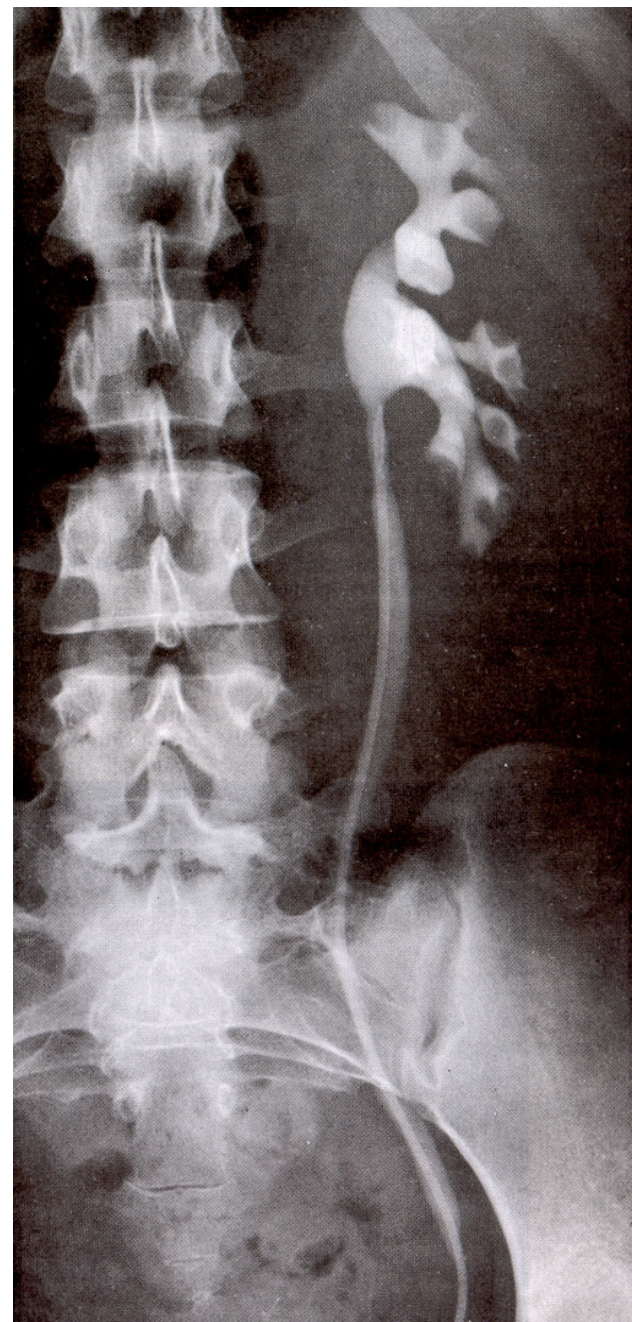
(m. sphincter urethrovaginalis)

Pars perinealis

Vylučovací (descendentní) urografie



Ascendentní pyelografie



Organa genitalia masculina

ORGANA GENITALIA MASCULINA INTERNA

VARLE (TESTIS)

NADVARLE (EPIDIDYMIS)

CHÁMOVOD (DUCTUS DEFERENS)

SEMENNÝ PROVAZEC (FUNICULUS SPERMATICUS)

SEMENNÉ VÁČKY (VESICULAE SEMINALES)

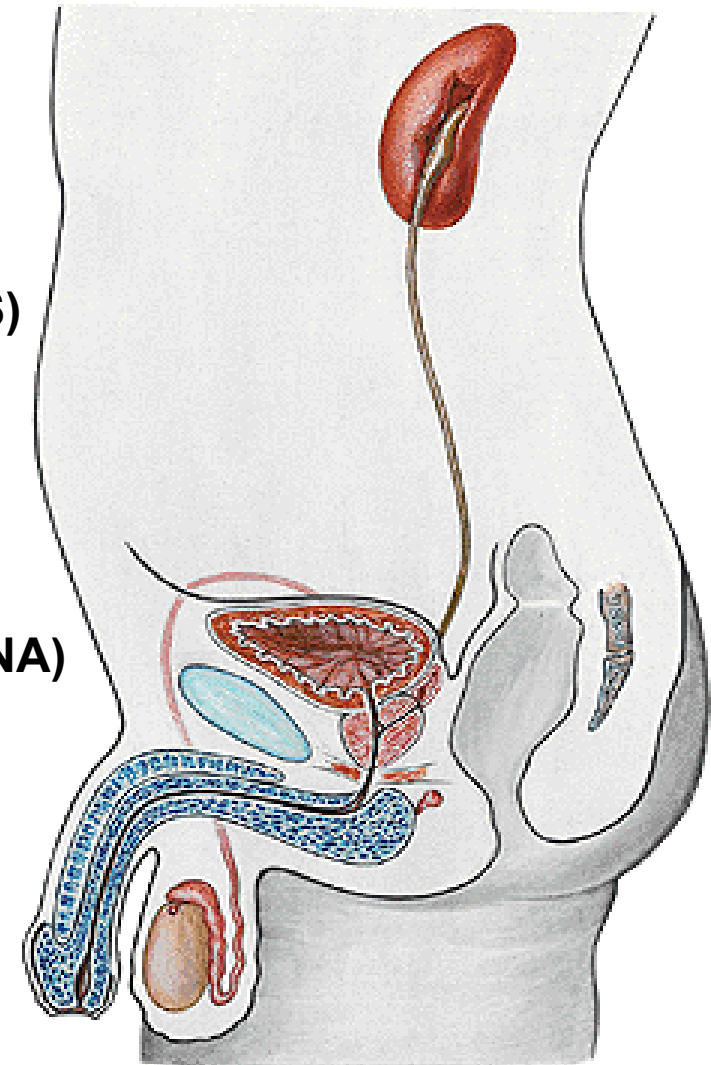
PŘEDSTOJNÁ ŽLÁZA (PROSTATA)

MUŽSKÁ MOČOVÁ TRUBICE (URETHRA MASCULINA)

ORGANA GENITALIA MASCULINA EXTERNA

PYJ (PENIS)

ŠOUREK (SCROTUM)



TESTIS

4-4,5 cm 20-30 g

Extremitas superior

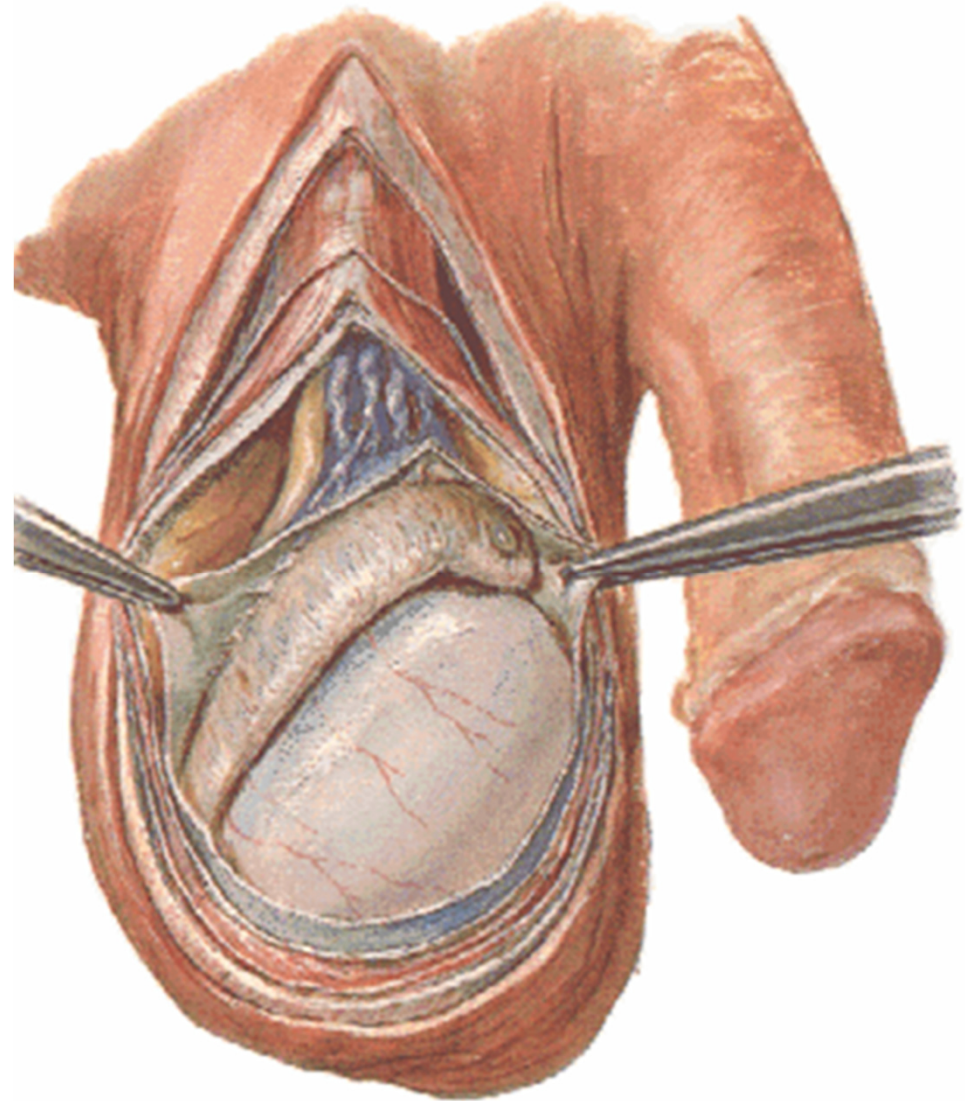
Extremitas inferior

Facies medialis

Facies lateralis

Margo anterior

Margo posterior



STAVBA VARLETE

tunica albuginea

hilum testis

mediastinum testis

septula testis

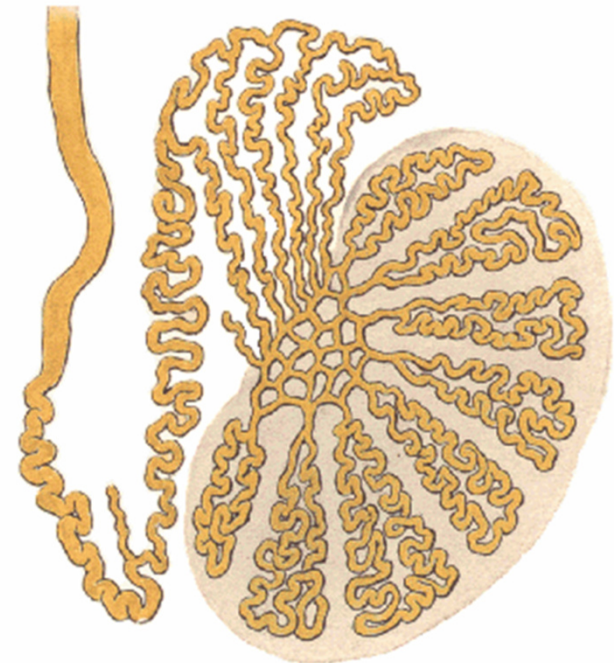
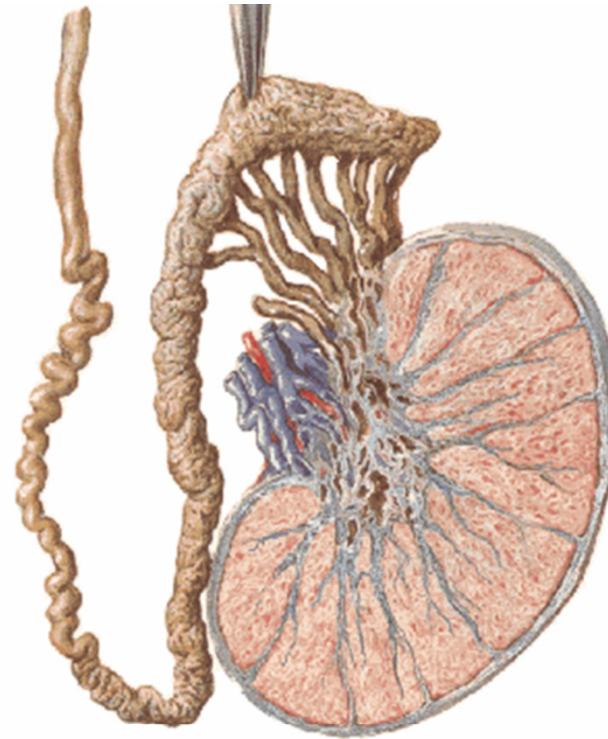
lobuli testis (200-300)

tubuli seminiferi contorti (50-70 cm)

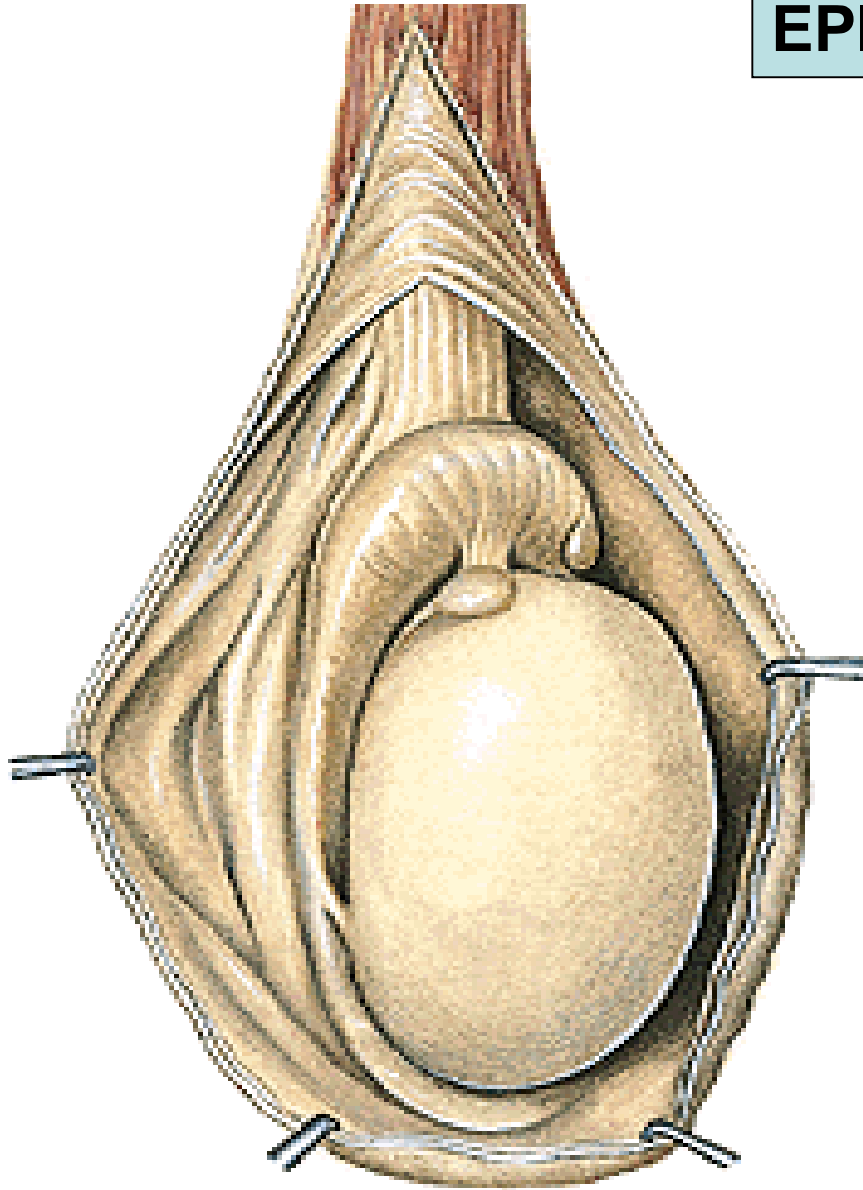
tubuli seminiferi recti, rete testis

ductuli efferentes testis (10-14)

intersticiální Leydigovy buňky (testosteron)



EPIDIDYMIS



Caput epididymidis

Corpus epididymidis

Cauda epididymidis

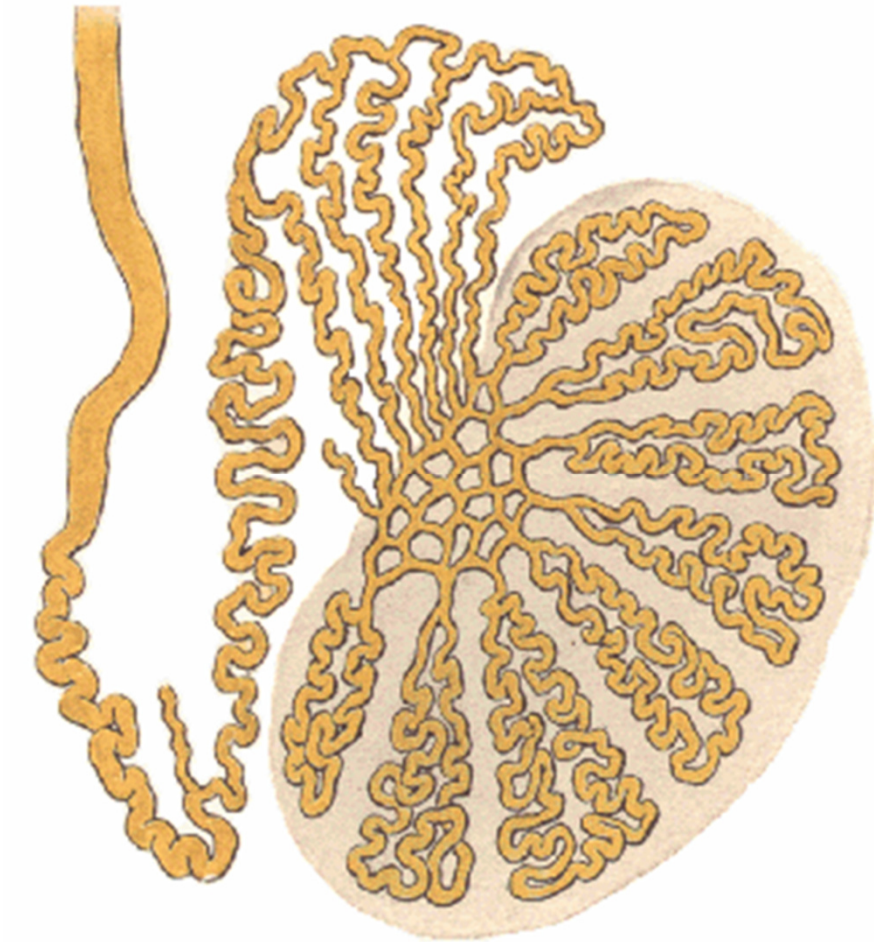
Sinus epididymidis

Lig. epididymidis superius

Lig. epididymidis inferius

**Lig. scrotale
(gubernaculum testis)**

STAVBA NADVARLETE



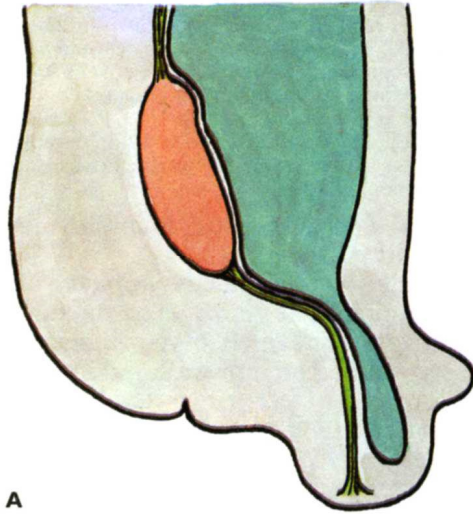
Ductuli efferentes testis (12-15)

Lobuli epididymidis

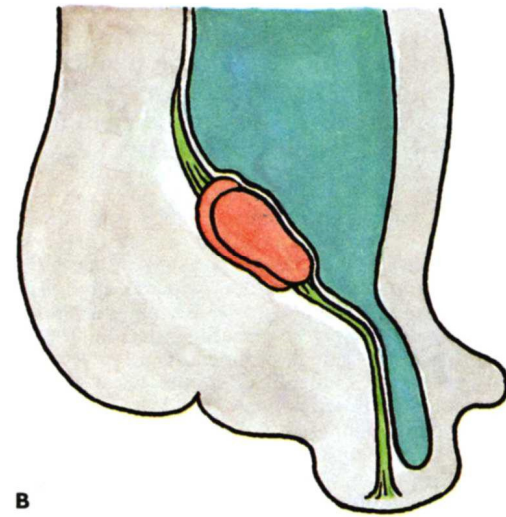
Ductus epididymidis (délka 6 m)

Ductus defferens

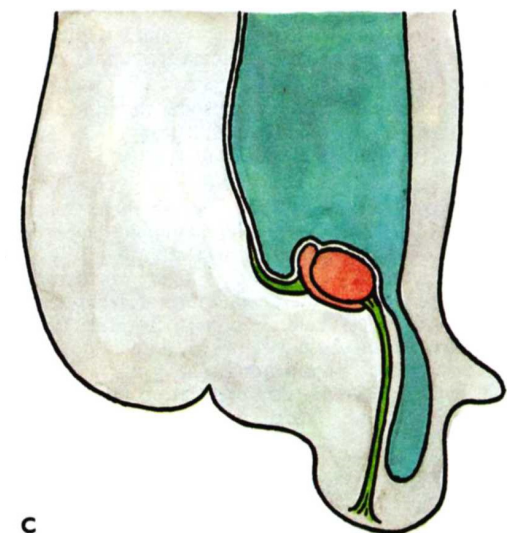
DESCENSUS TESTIS



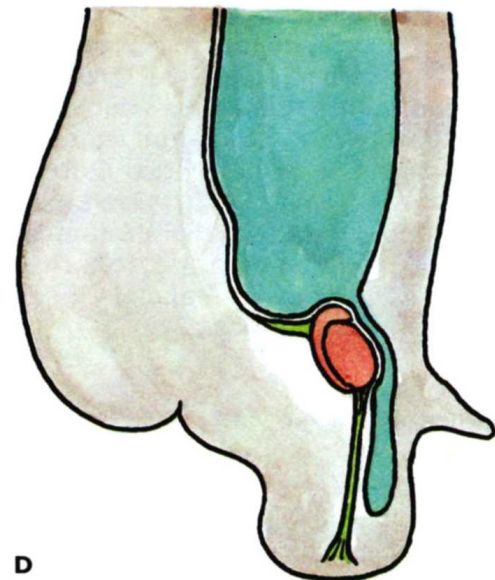
A



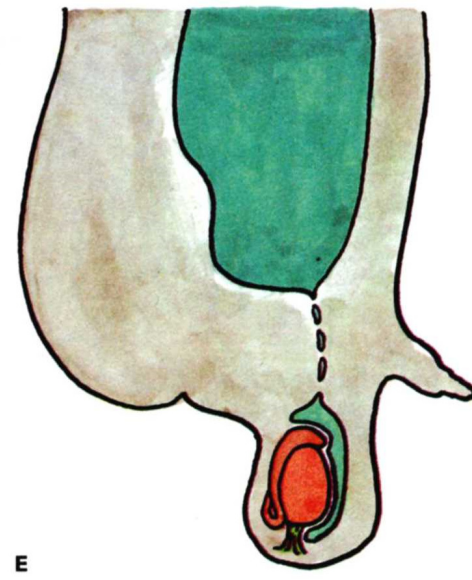
B



C



D

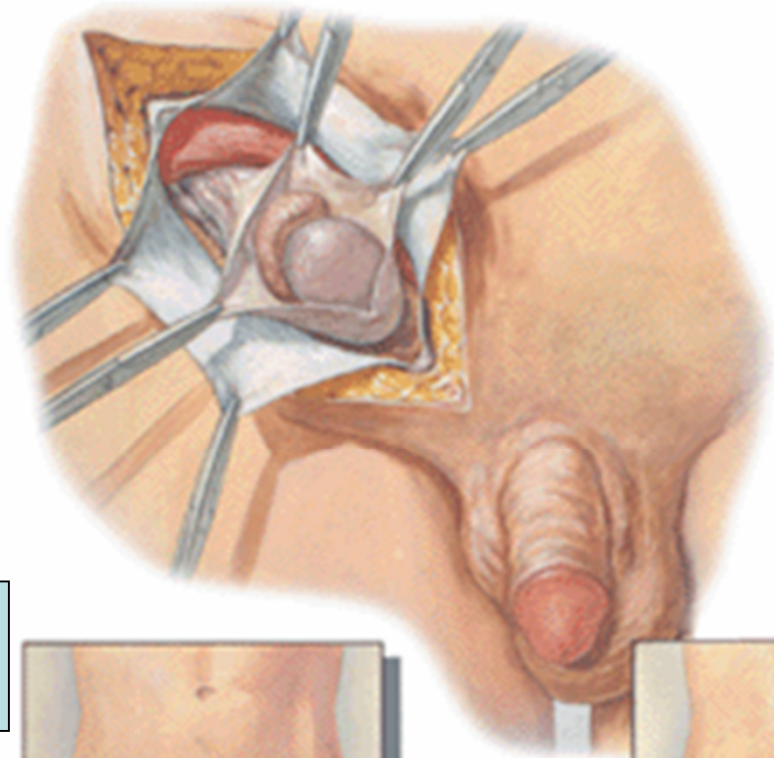


E

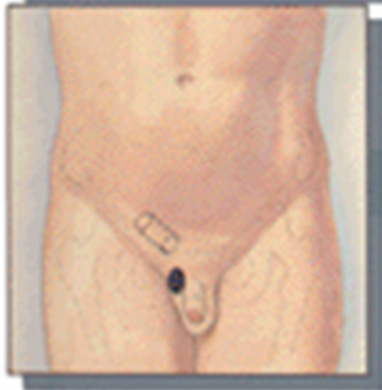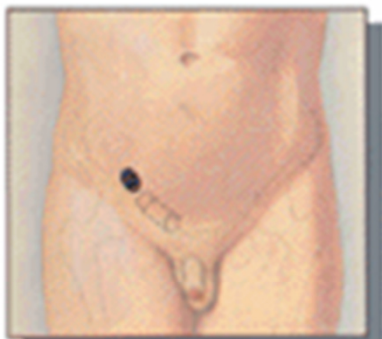Mesorchium

Gubernaculum testis

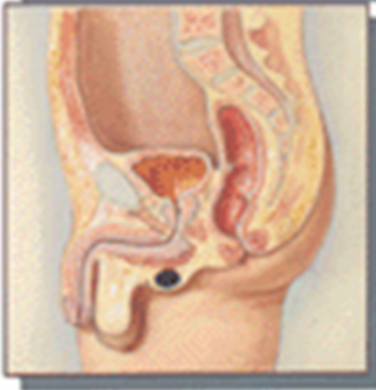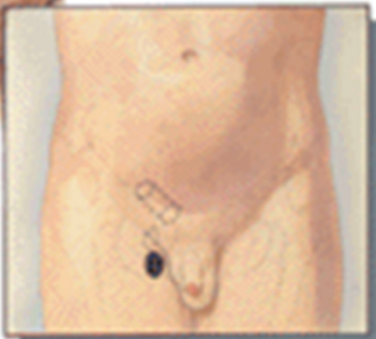Processus vaginalis perit.



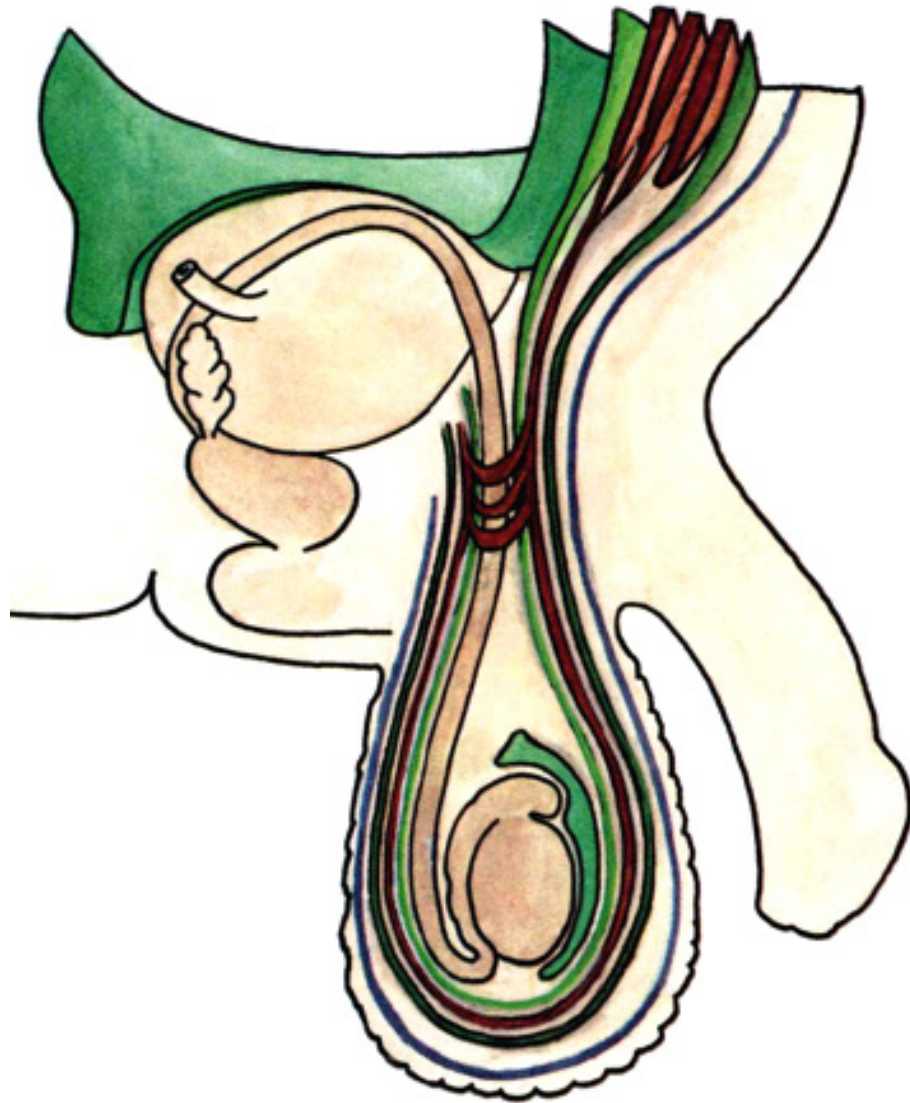
**Retentio testis
(cryptorchismus)**



Ectopia testis



OBALY VARLETE



Kůže

Tunica dartos scroti

Fascia spermatica ext.

Musculus cremaster, fascia

Fascia spermatica int.

Tunica vaginalis testis

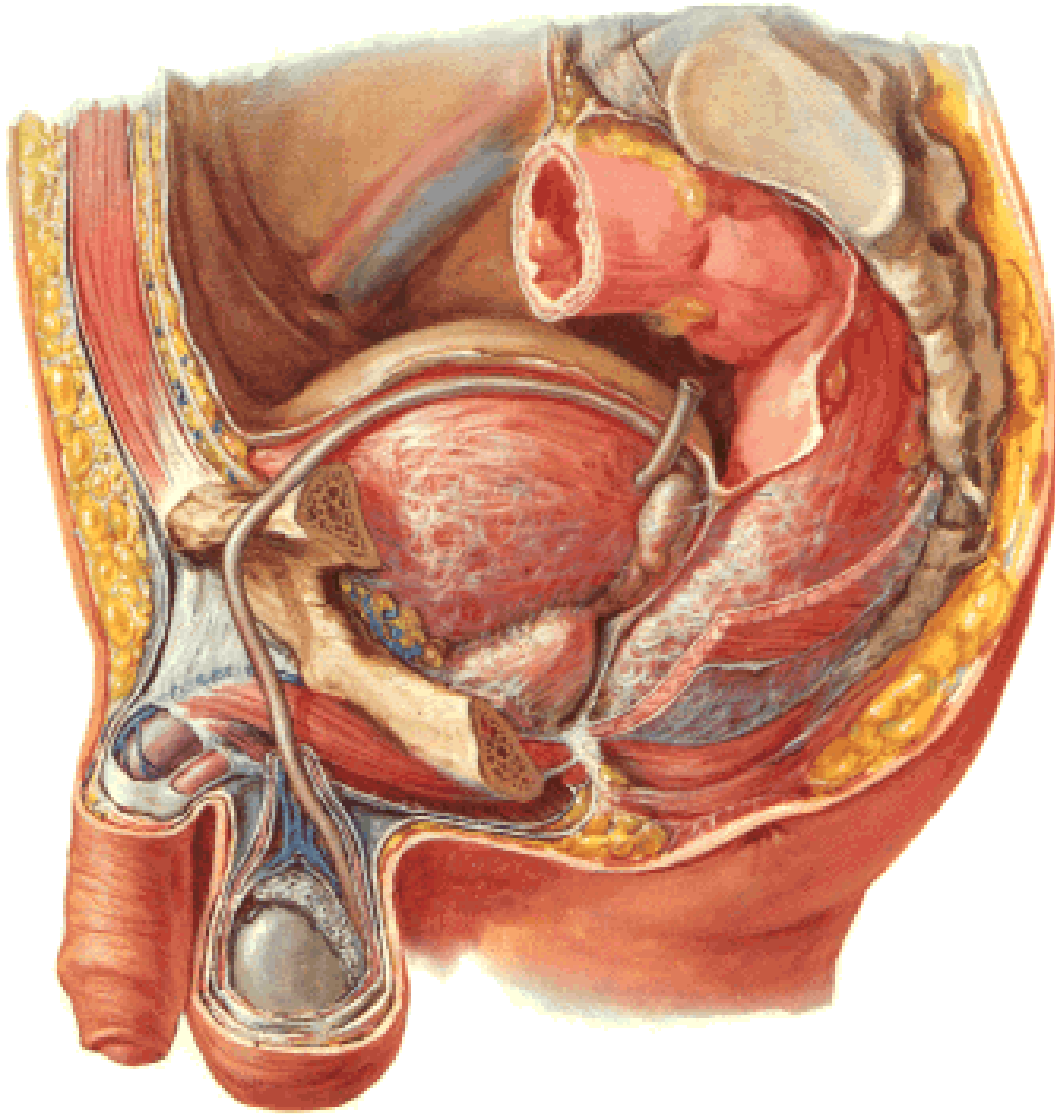
lamina parietalis (*periorchium*)

cavum serosum scroti

lamina visceralis (*epiorchium*)

Tunica albuginea

CHÁMOVOD (DUCTUS DEFERENS)



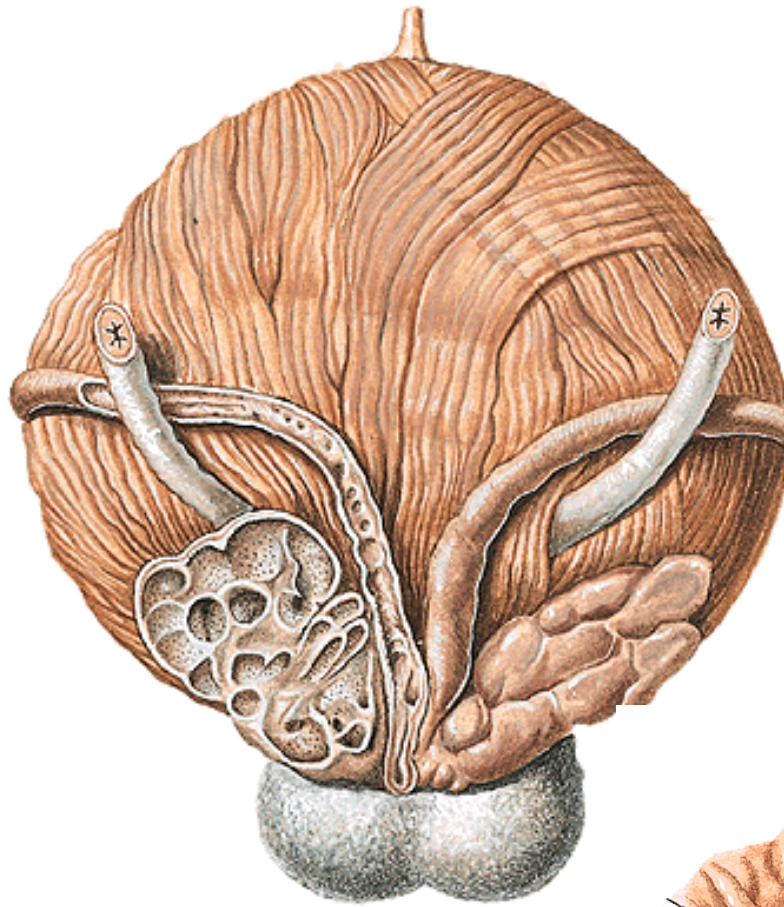
asi 40 cm

pars epididymica

pars funicularis

pars inguinalis

pars pelvina (kříží močovod)



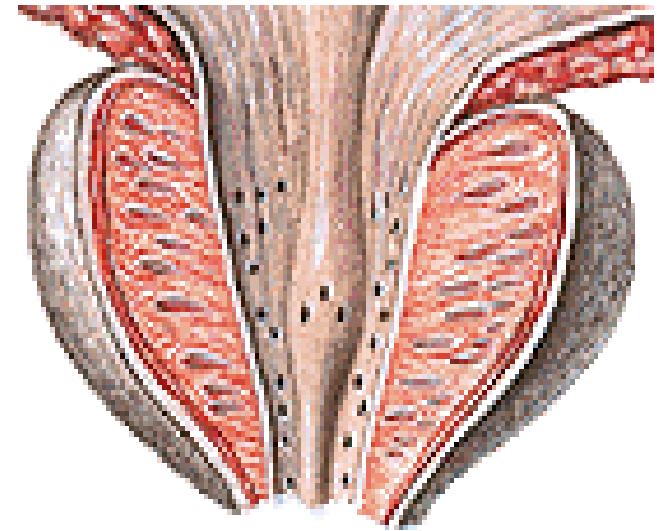
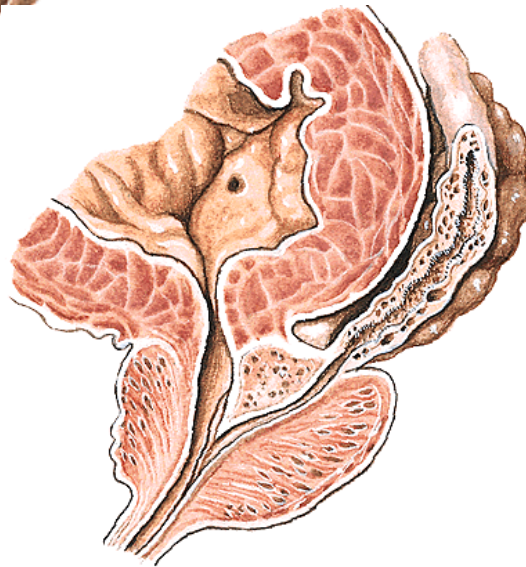
Ampulla ductus deferentis

Diverticula ampullae

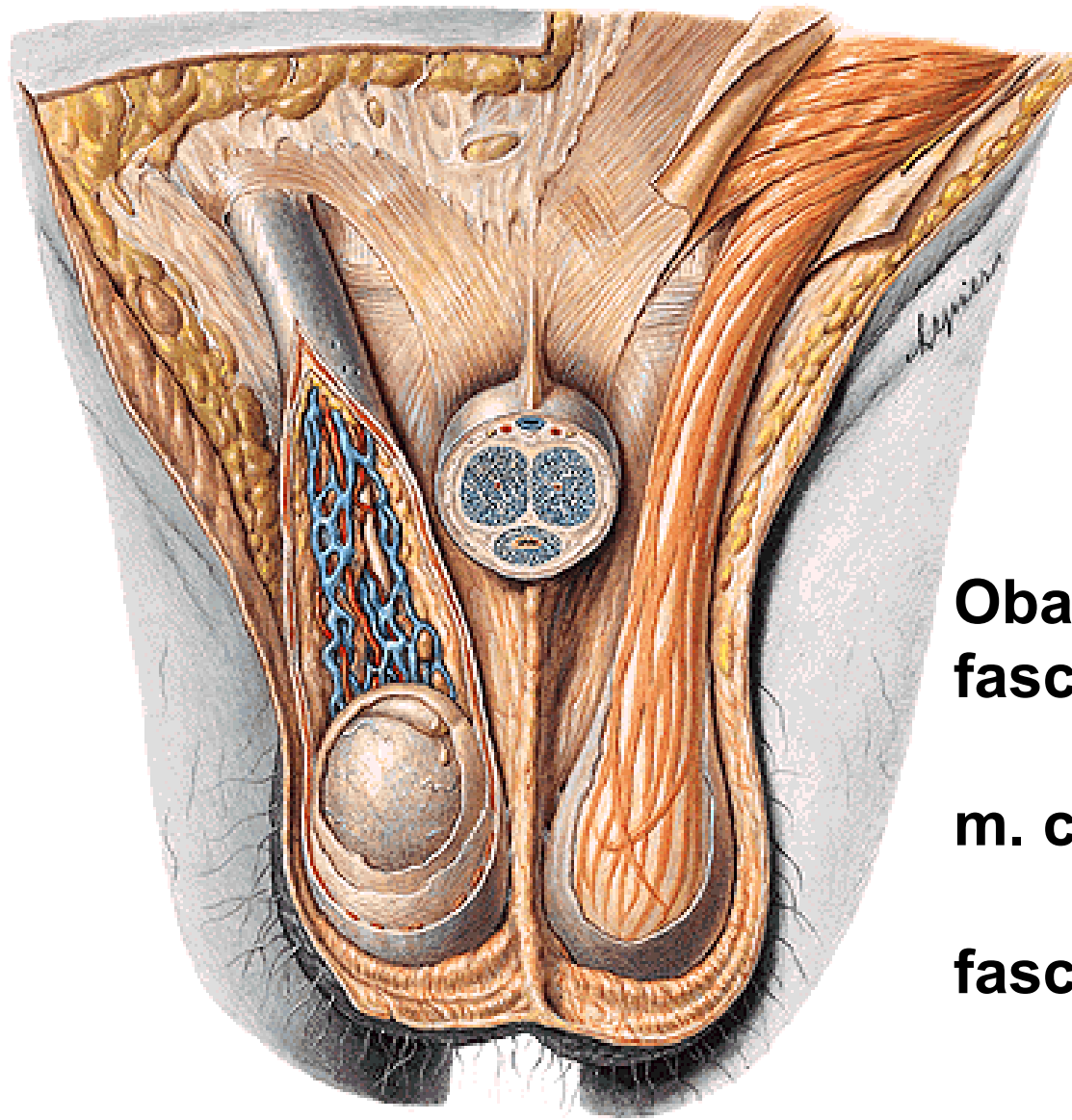
Spojení s vesiculae seminales

Ductus ejaculatorius

Colliculus seminalis



PROVAZEC SEMENNÝ (FUNICULUS SPERMATICUS)



**cauda epididymidis –
anulus inguinalis prof.**

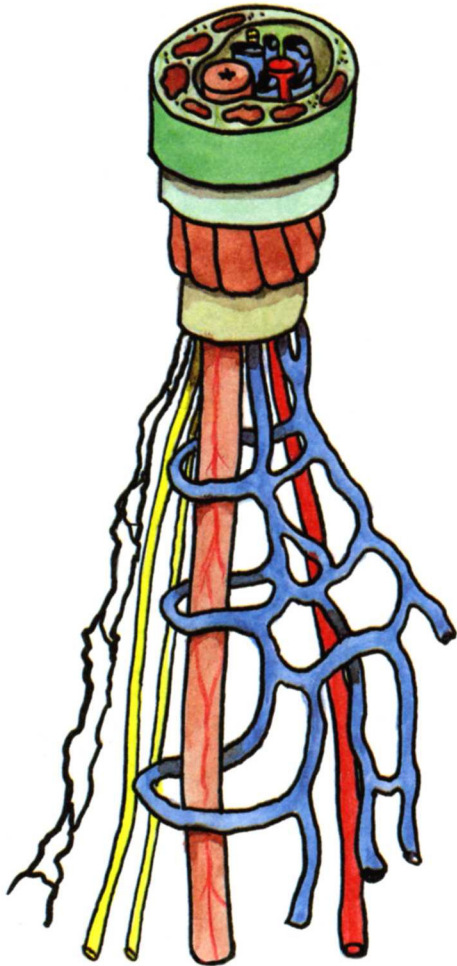
Obaly:

fascia spermatica ext.

m. cremaster a jeho fascie

fascia spermatica int.

PROVAZEC SEMENNÝ (FUNICULUS SPERMATICUS)



Ductus deferens

Arteria ductus deferentis

Plexus deferentialis

Arteria testicularis

Plexus testicularis

Plexus pampiniformis

Mízní cévy

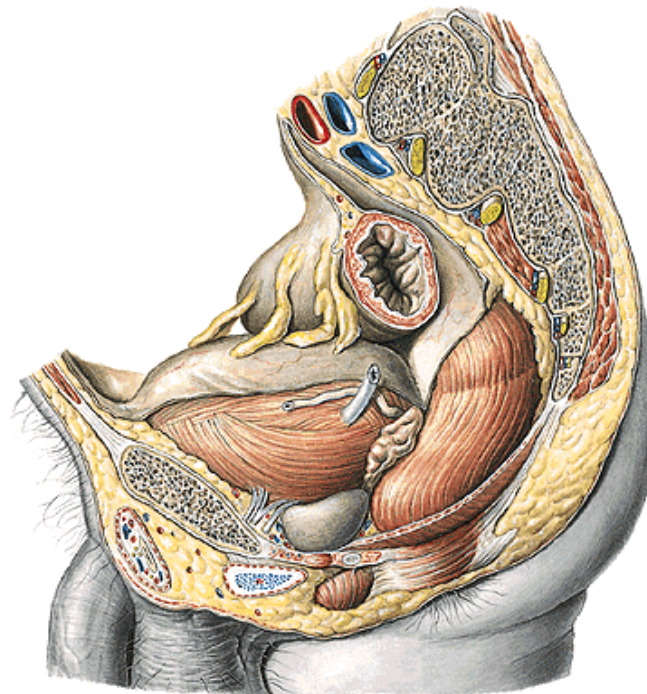
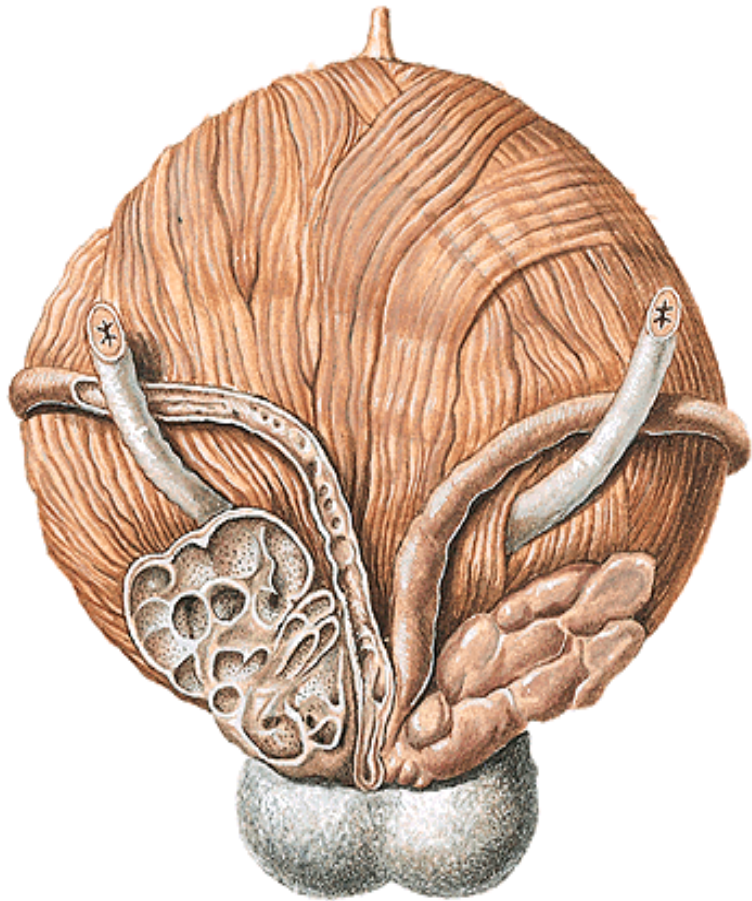
VESICULAE SEMINALES

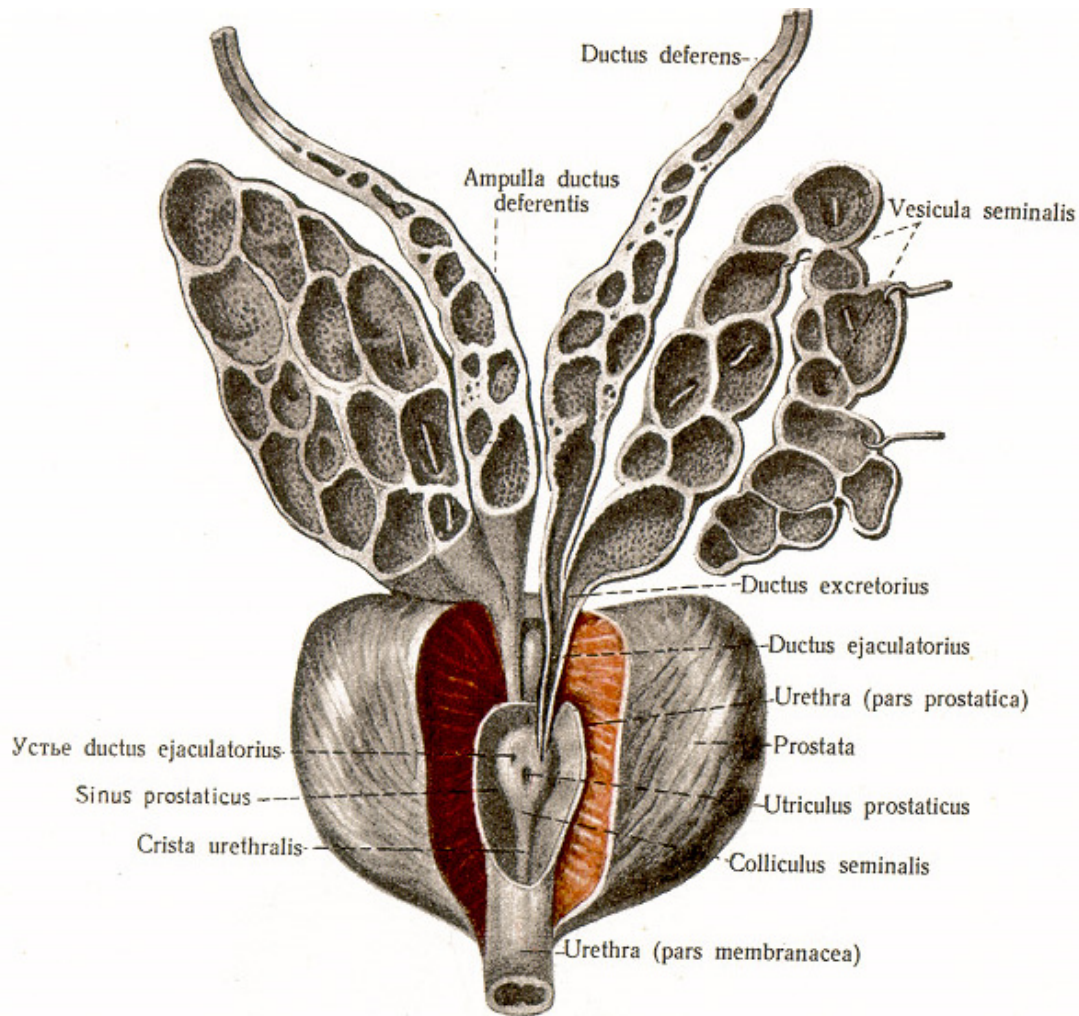
délka 4-5 cm

laterálně od ampulla ductus deferentis

subperitoneálně

(excavatio rectovesicalis,
septum rectovesicale)





Stavba:

sliznice (četné řasy)

svalovina

adventicie

**alkalický sekret
(50-80% ejakulátu)**

corpus vesiculae seminalis

ductus excretorius

ductus excretorius + ductus deferens = ductus ejaculatorius

PROSTATA

V = 3cm, š = 4 cm; 20-30g

Basis prostatae (facies vesicalis)

urethra masculina

ductus ejaculatorii

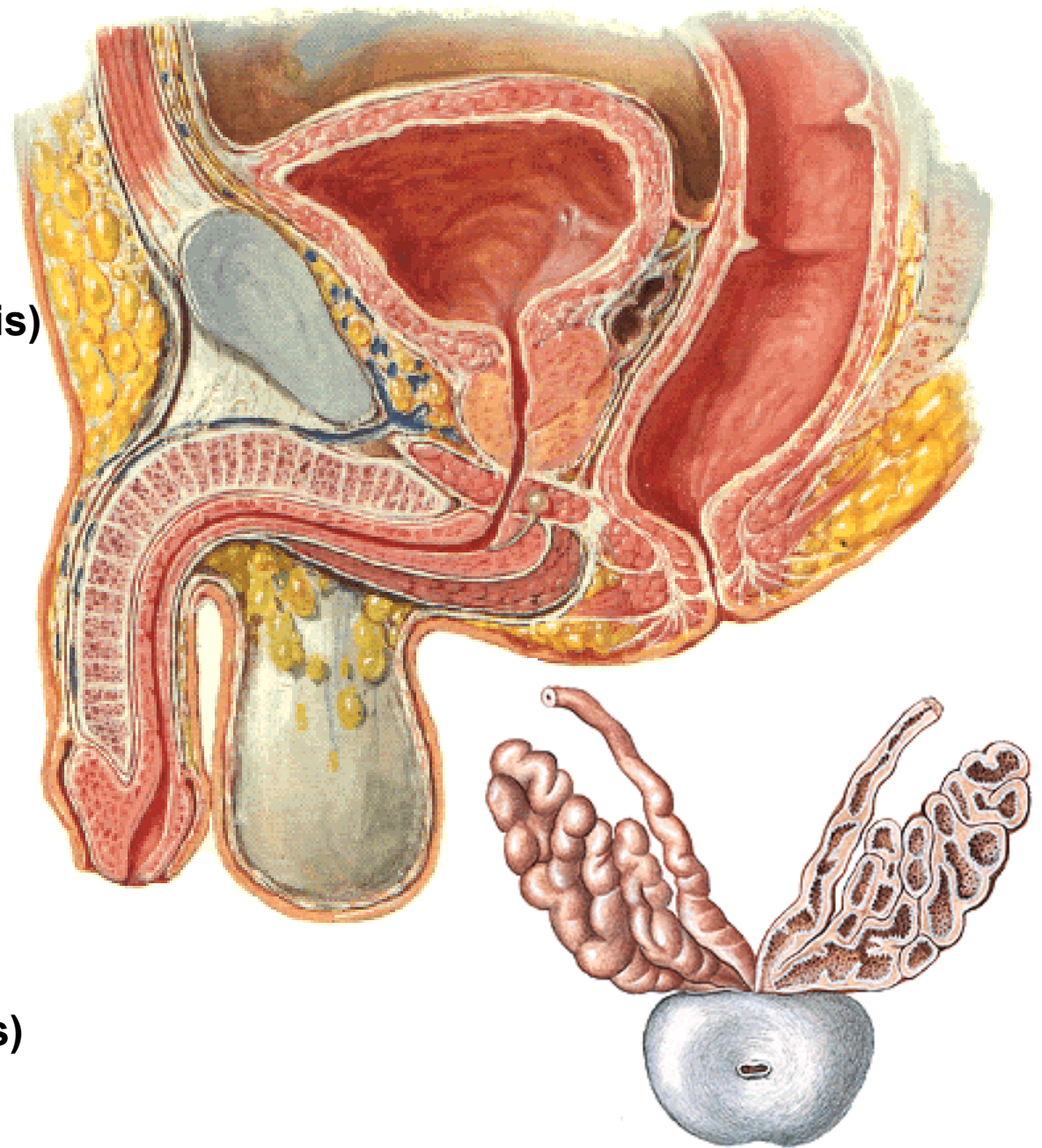
Apex prostatae

Facies anterior

(ligg. puboprostatica)

Facies posterior

Facies laterales (inferolaterales)



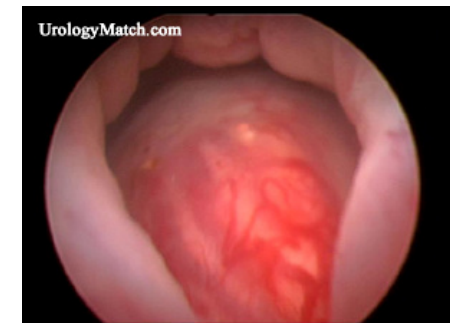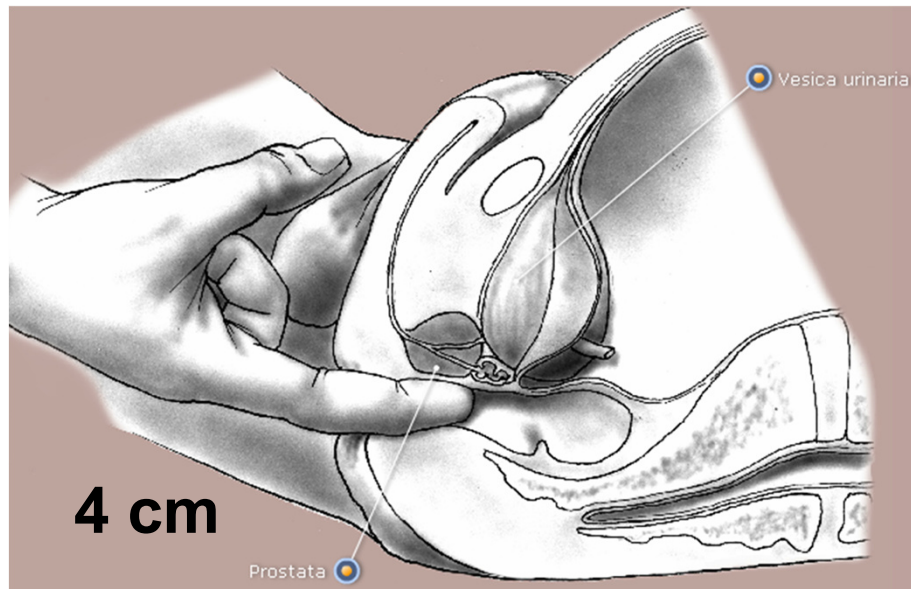
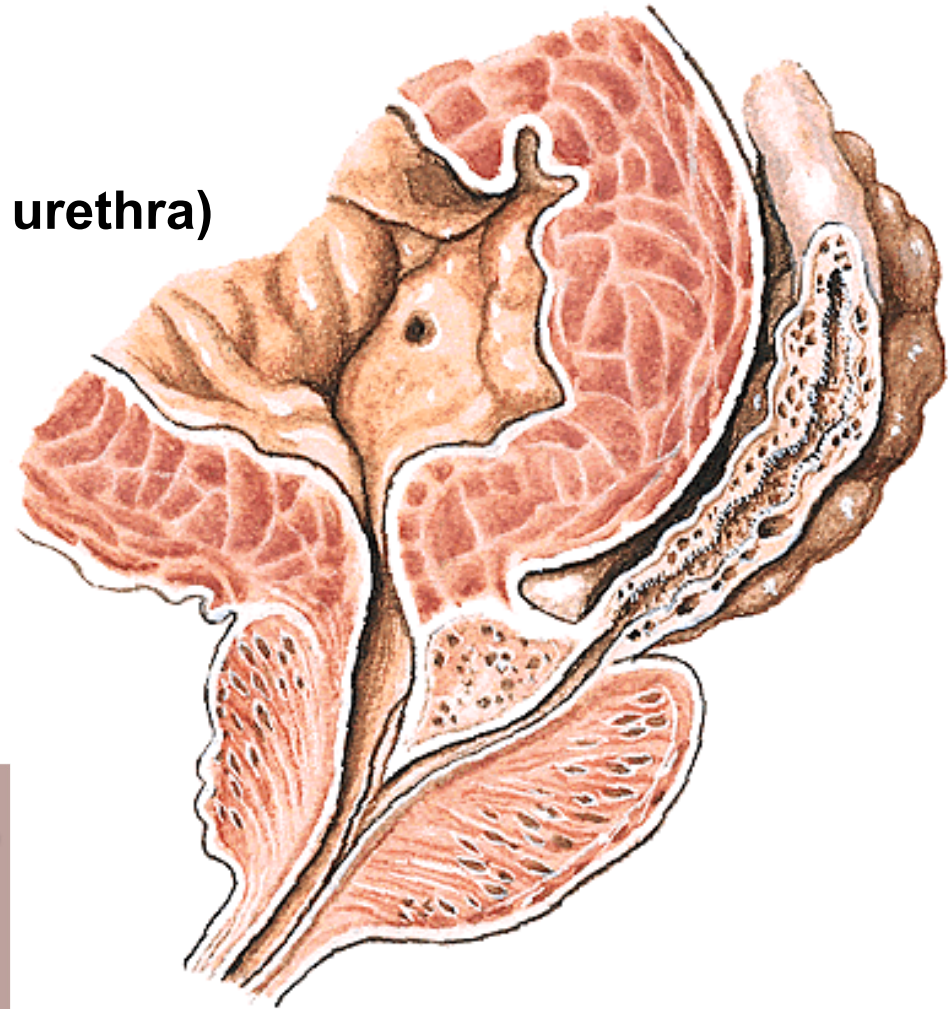
Lobus anterior (isthmus prostatae)

Lobus medius (ductus ejaculatorii, urethra)

Lobus posterior

Lobus dexter

Lobus sinister



STAVBA PROSTATY

**Capsula periprostatica
(viscerální list fascia pelvis)**

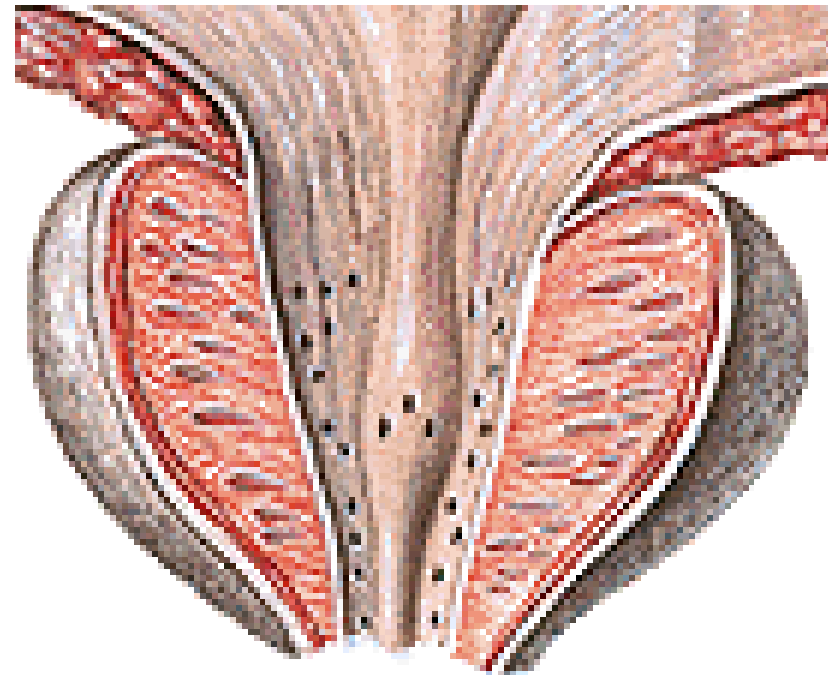
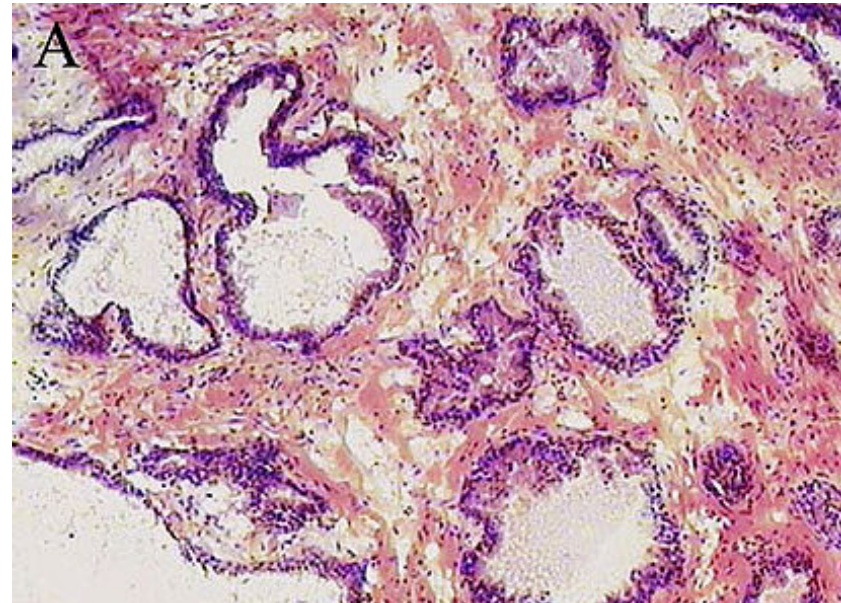
Plexus venosus prostaticus

Capsula propria

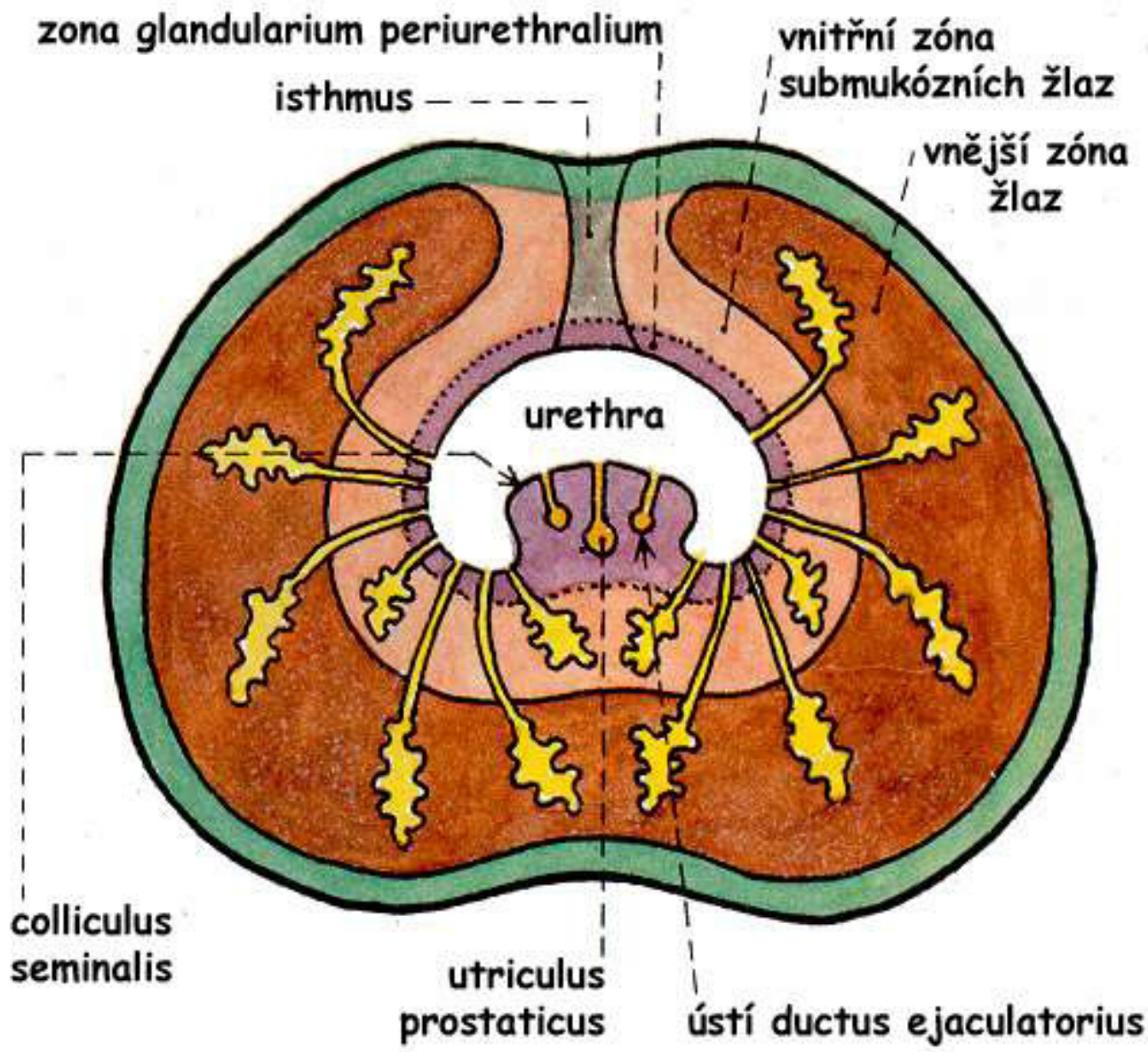
Fibromuskulární stroma

**30 – 50 tuboalveolárních žláz
15-30% ejakulátu**

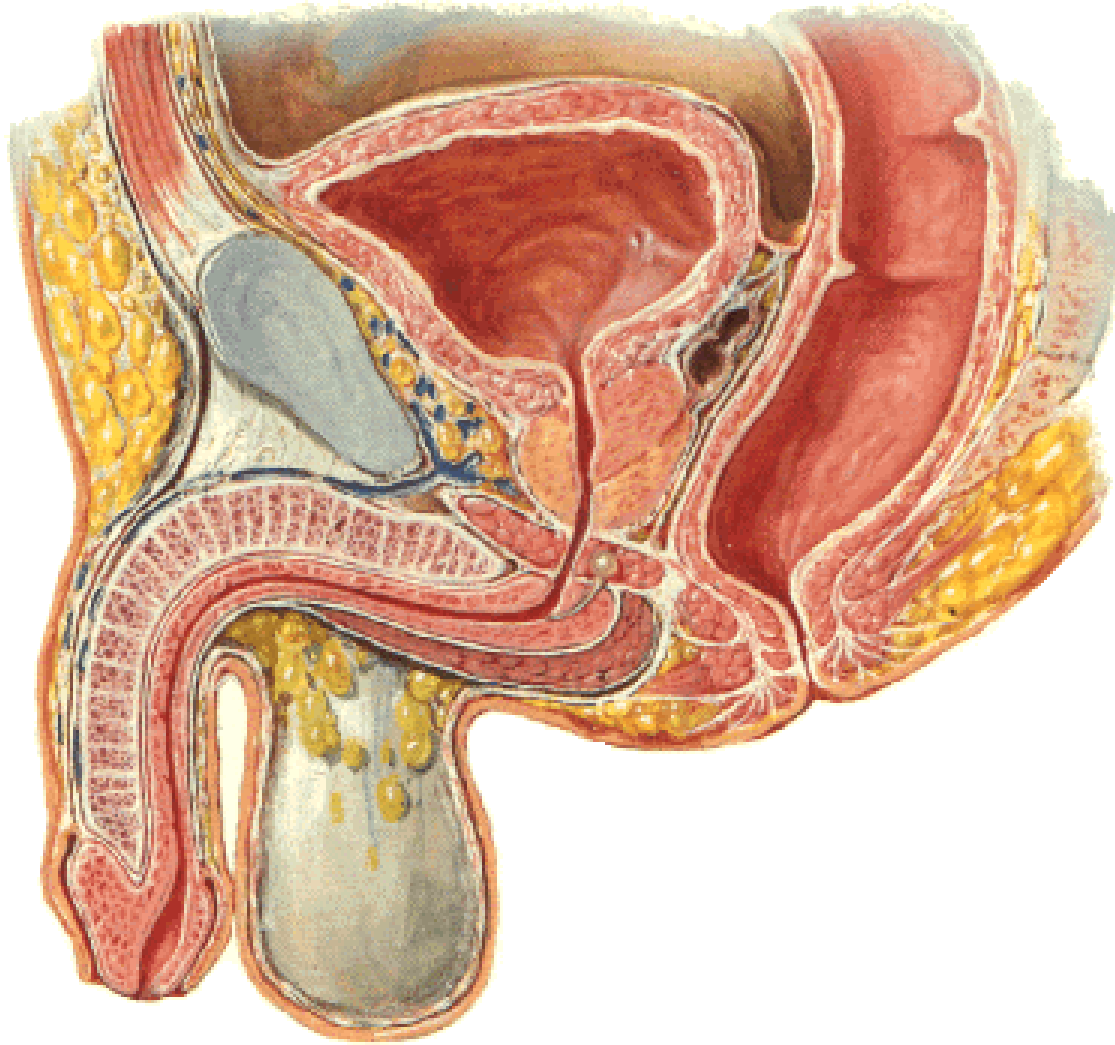
**Ductuli prostatici (15-30)
(pars prostatica urethrae)**



KLINICKÉ DĚLENÍ PROSTATY



URETHRA MASCULINA



20-25 cm (7mm)

Ostium urethrae int.

Ostium urethrae ext.

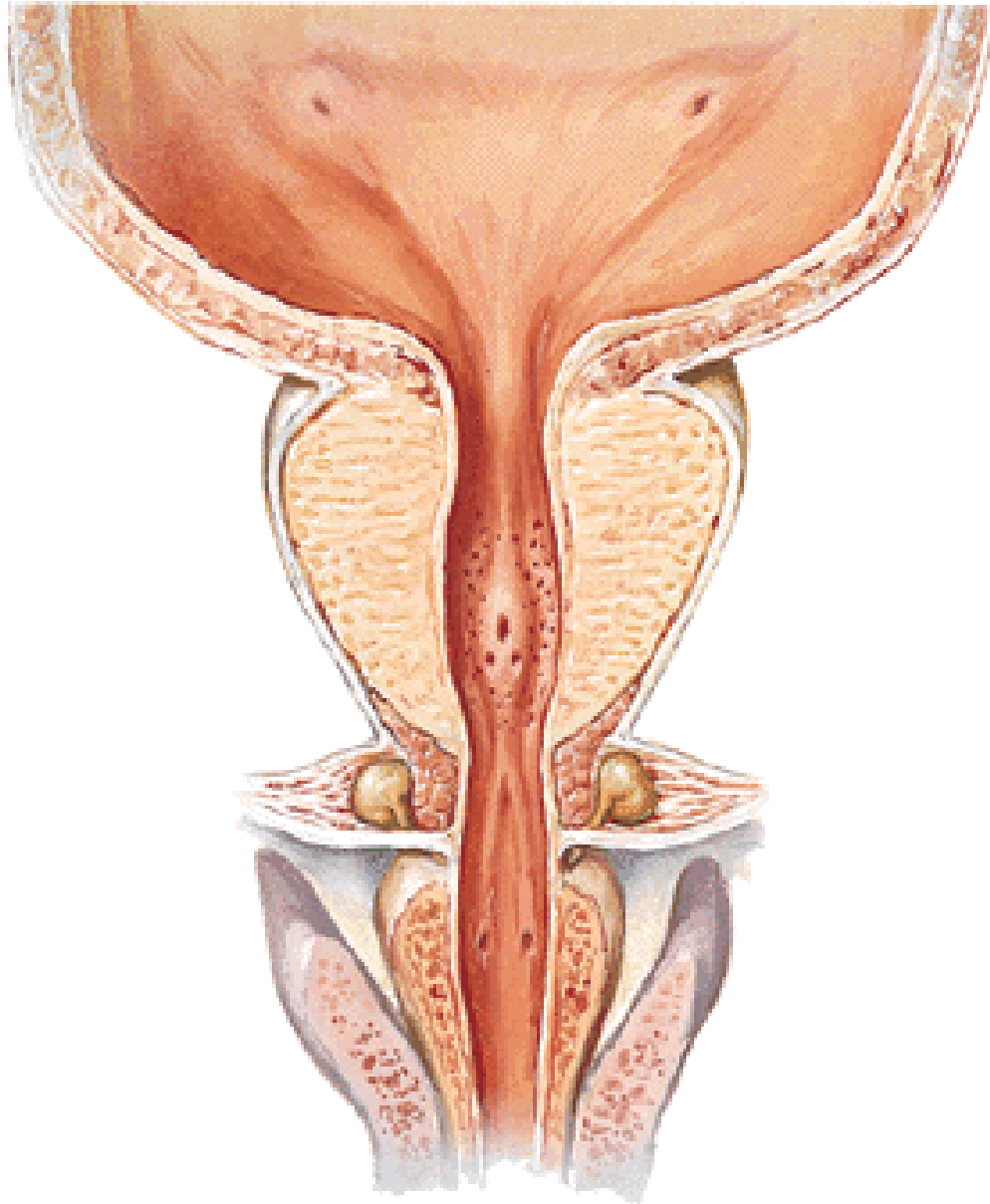
**Pars intramuralis
(m. sphincter vesicae)**

Pars prostatica

**Pars membranacea
(m. sphincter urethrae)**

Pars spongiosa

PARS PROSTATICA URETHRAE



Crista urethralis

Colliculus seminalis

Utriculus prostaticus

Ductus ejaculatorii

Sinus prostaticus

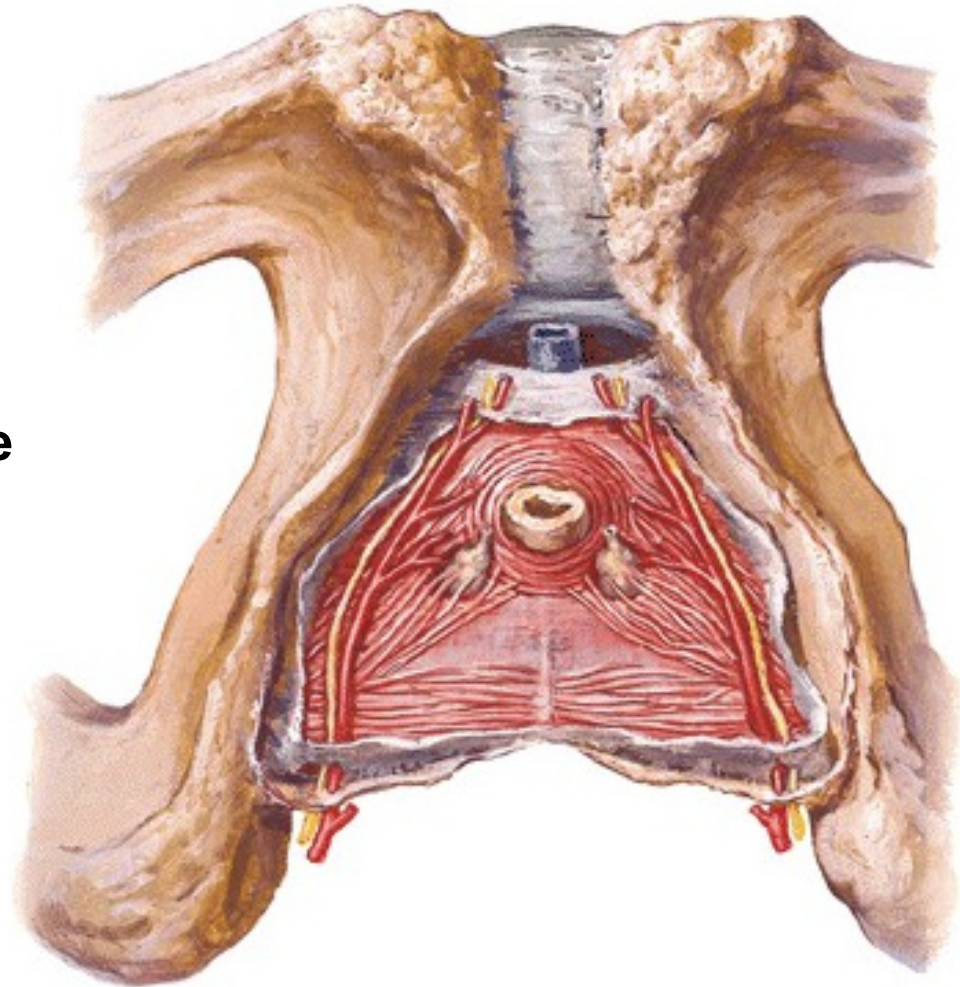
Ductuli prostatici

PARS MEMBRANACEA URETHRAE

Diaphragma urogenitale

Musculus sphincter urethrae

Zúžené miesto močové trubice



PARS SPONGIOSA URETHRAE

Bulbus penis – ostium urethrae externum

Ampulla urethrae

Glandulae bulbourethrales

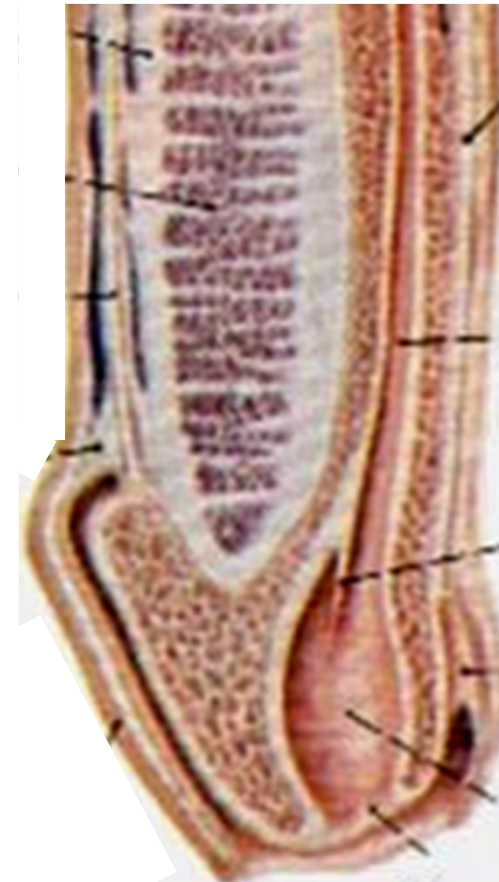
Lacunae urethrales

Glandulae urethrales

Fossa navicularis

Valvula fossae navicularis

Recessus fossae navicularis



PROHNUTÍ MOČ. TRUBICE:

Curvatura subpubica

Curvatura praepubica

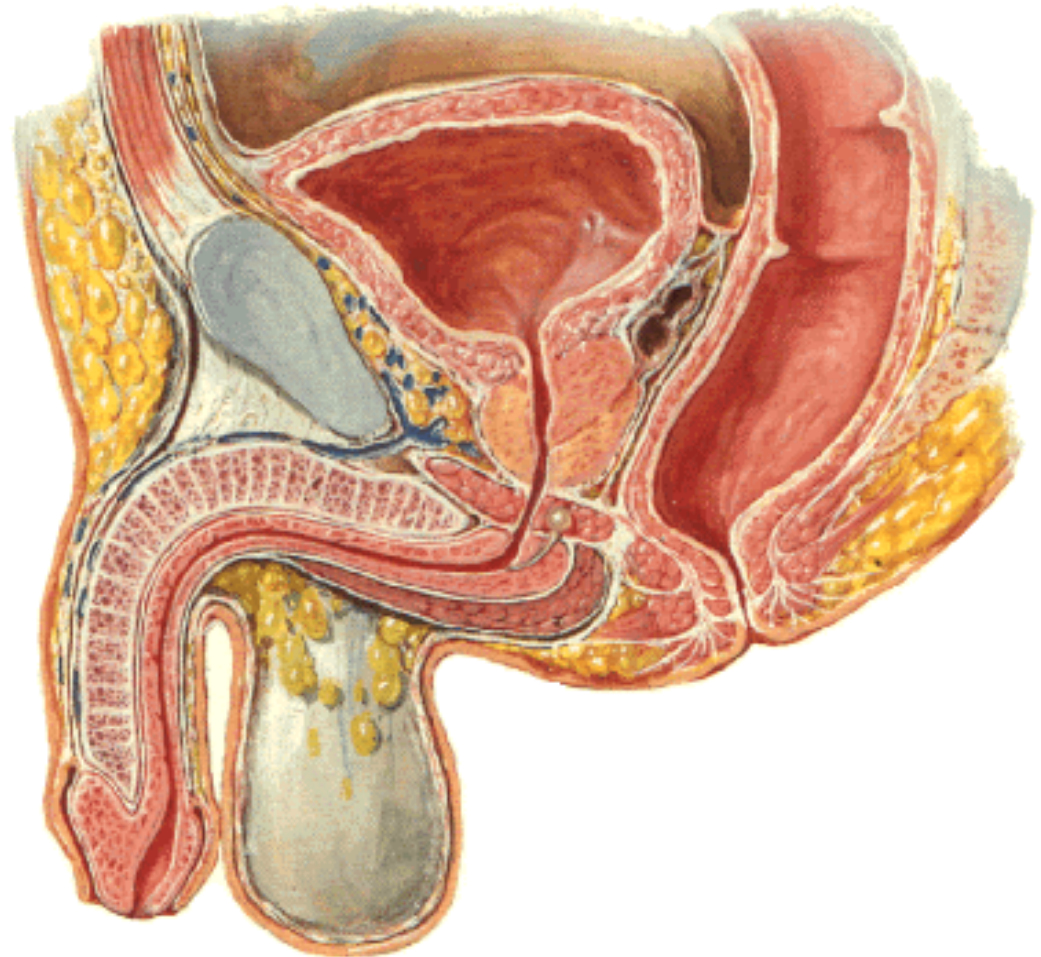
ZÚŽENÍ MOČ. TRUBICE:

Ostium urethrae externum

Mezi fossa navicularis a
ampulla urethrae

Pars membranacea

Pars intramuralis



PYJ (PENIS, PHALLOS)

Radix penis

Corpus penis

Glans penis

Corona glandis

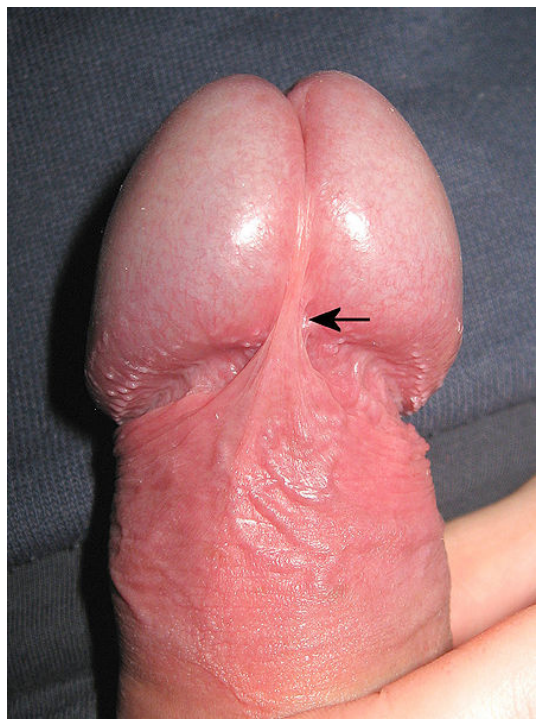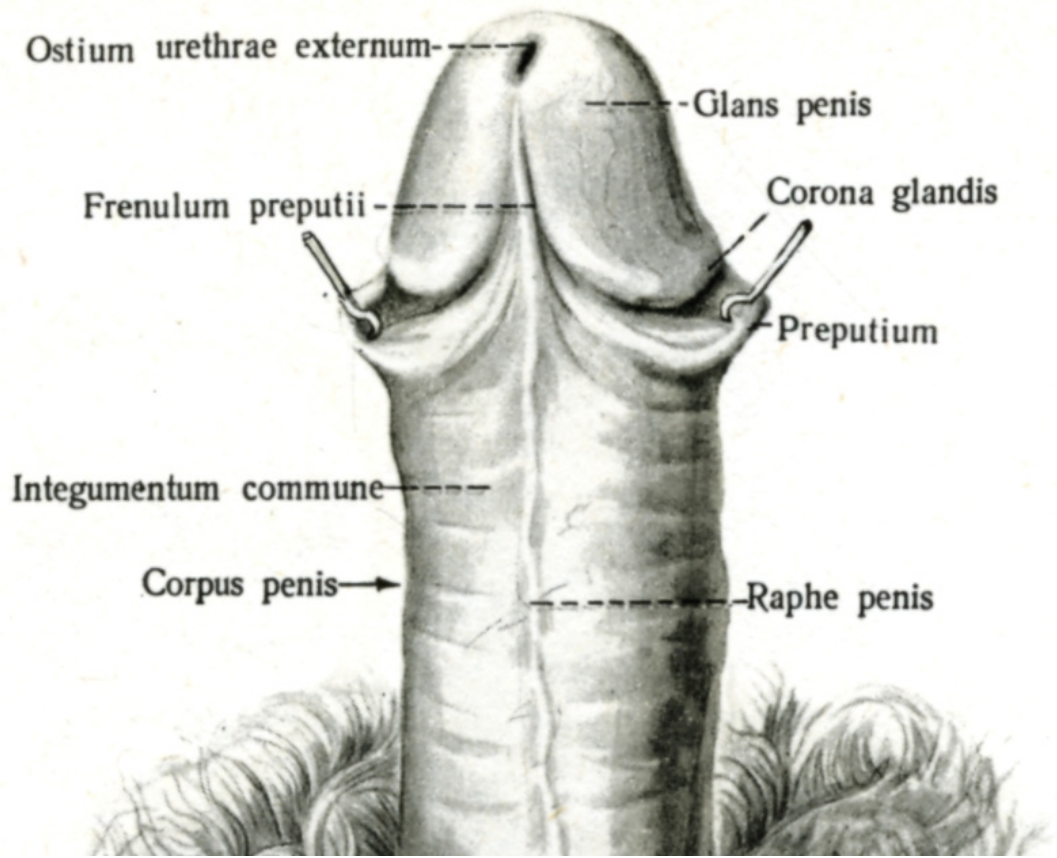
Collum glandis

Dorsum penis

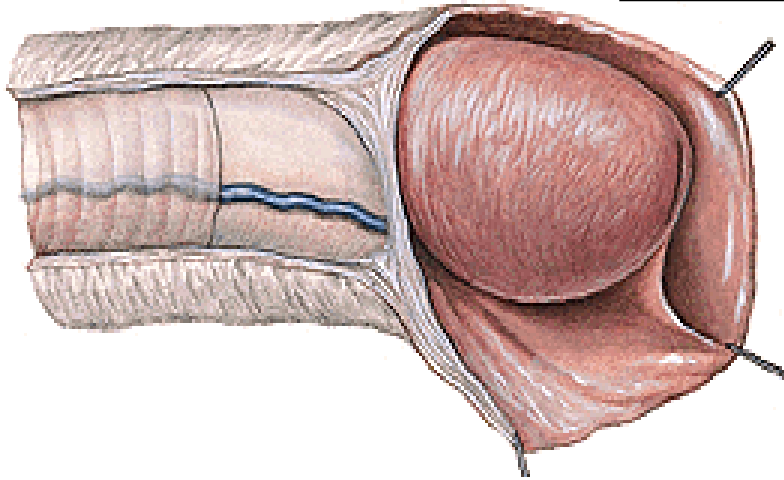
Facies urethralis



Facies urethralis



PRAEPUTIUM



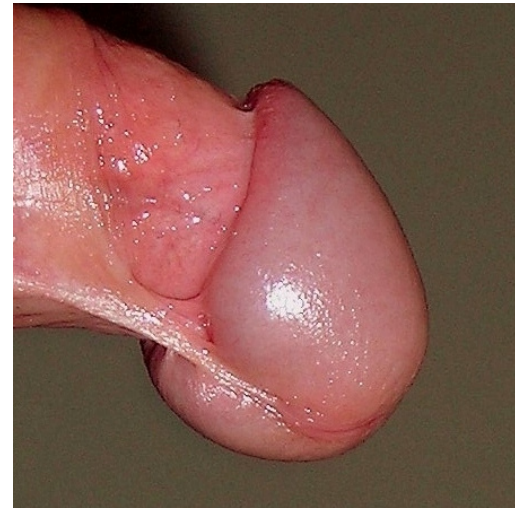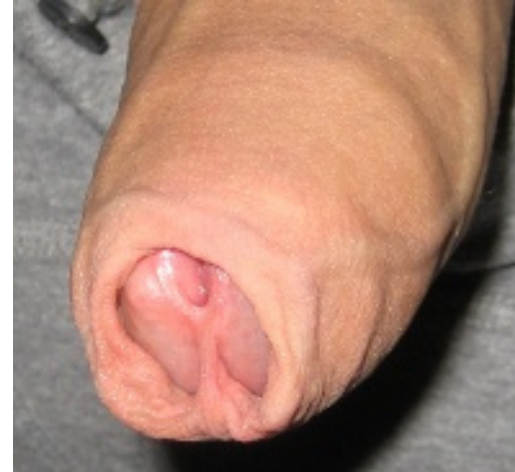Frenulum praeputii

Ostium (orificium) praeputii


Glandulae praeputiales

Smegma preputii

Phimosis



STAVBA PENISU



Corpora cavernosa

crura penis

(crista phallica)

m. ischiocavernosus

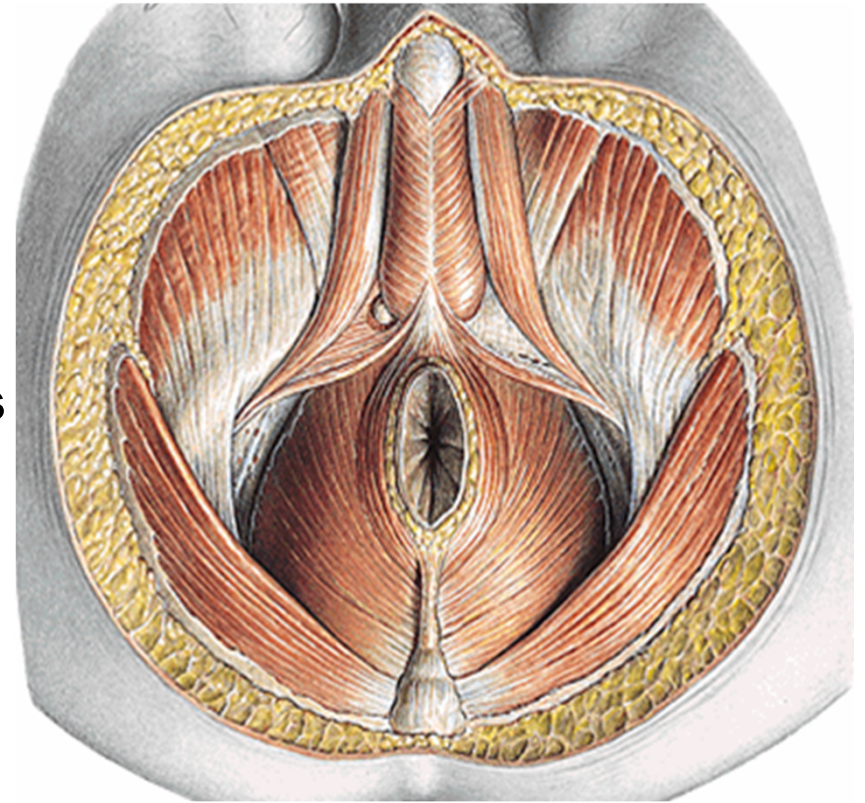
Corpus spongiosum

bulbus penis

m. bulbospongiosus

Glandulae bulbourethrales

Centrum perineale



STAVBA TOPOŘIVÝCH TĚLES

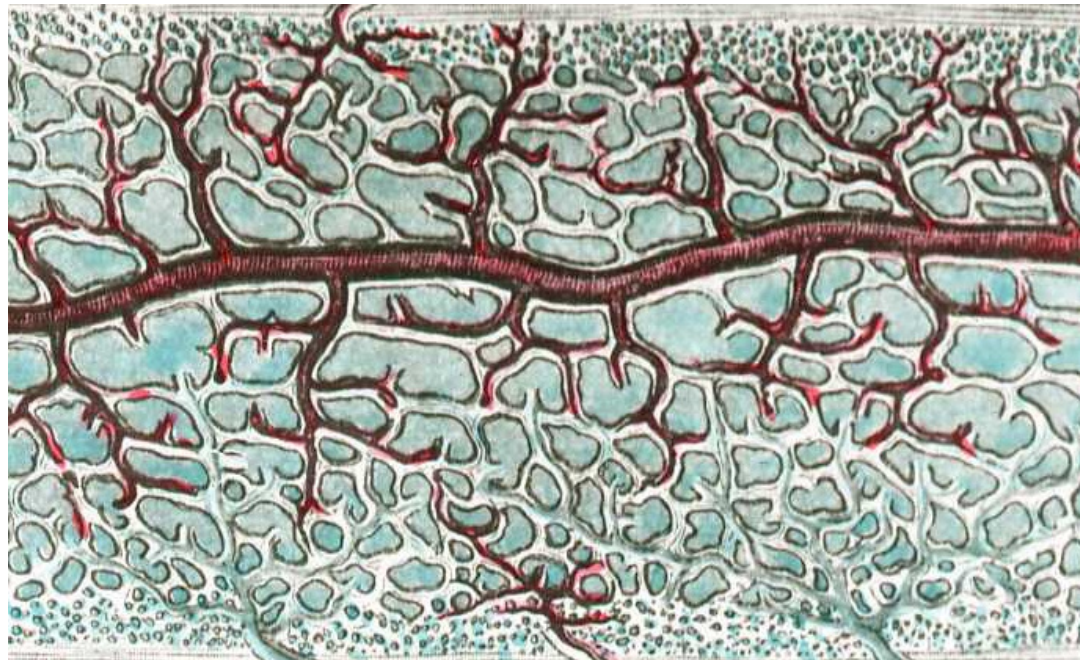
Tunica albuginea

Trabeculae corporis cavernosi (spongiosi)

Cavernae corporis cavernosi (spongiosi)

Aa. helicinae

(Ebnerovy polštářky)

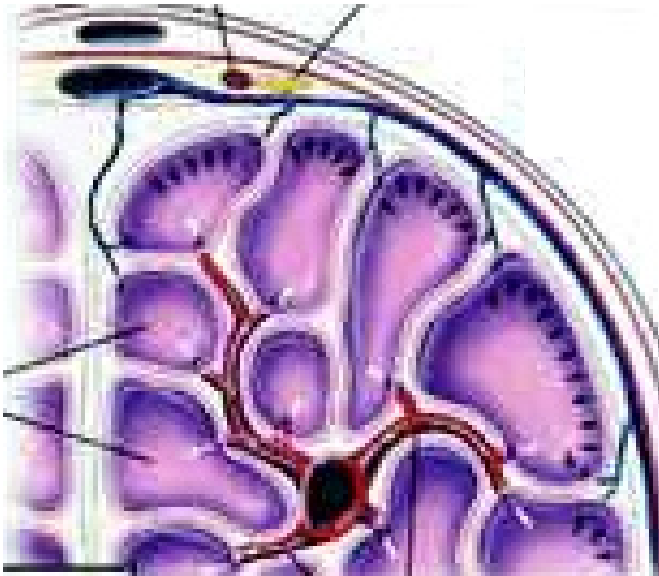


EREKCE PENISU

Parasympatikus (míšní segment S_3)

ochabnutí svaloviny Ebnerových polštářků

rozšíření aa. helicinae, kaverny se plní krví



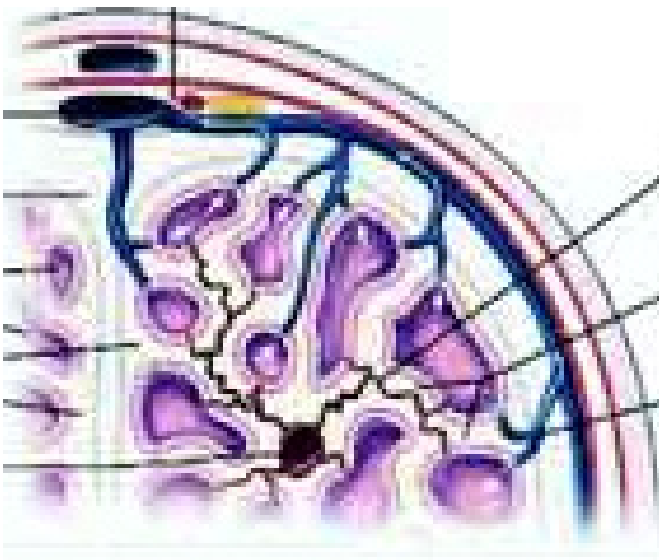
DETUMESCENCE PENISU

Sympatikus (míšní segment L_{2-3})

kontrakce svaloviny Ebnerových polštářků

zúžení průsvitu aa. helicinae

snížený přítok krve do kaveren



Obaly penisu

kůže

fascia penis superficialis

(vv. dorsales penis spf.)

fascia penis profunda

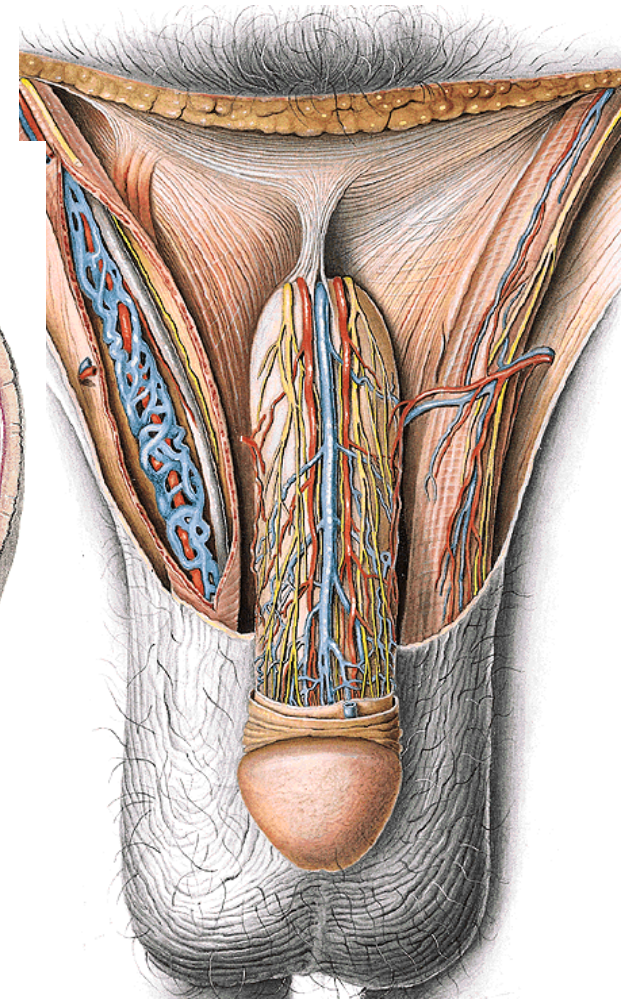
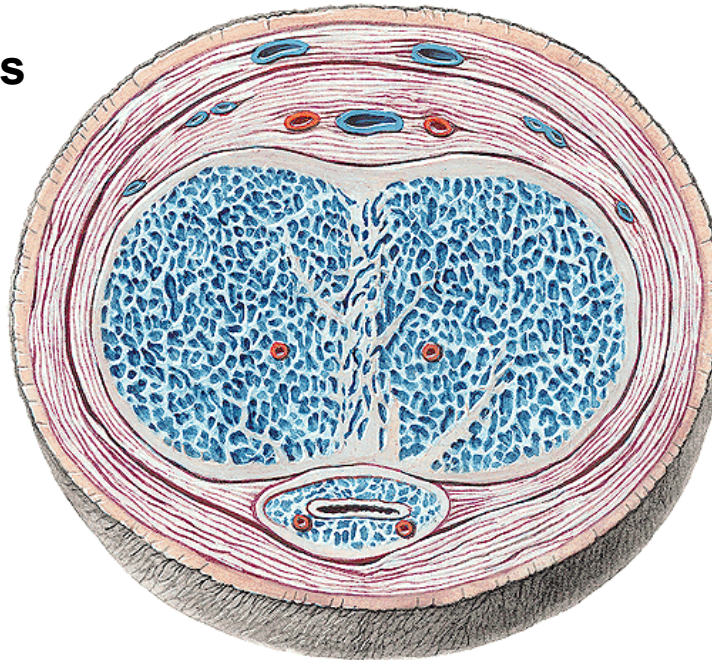
(v. dorsalis penis prof.)

(aa. dorsales penis)

(nn. dorsales penis)

tunica albuginea

septum penis



lig. fundiforme penis

lig. suspensorium penis

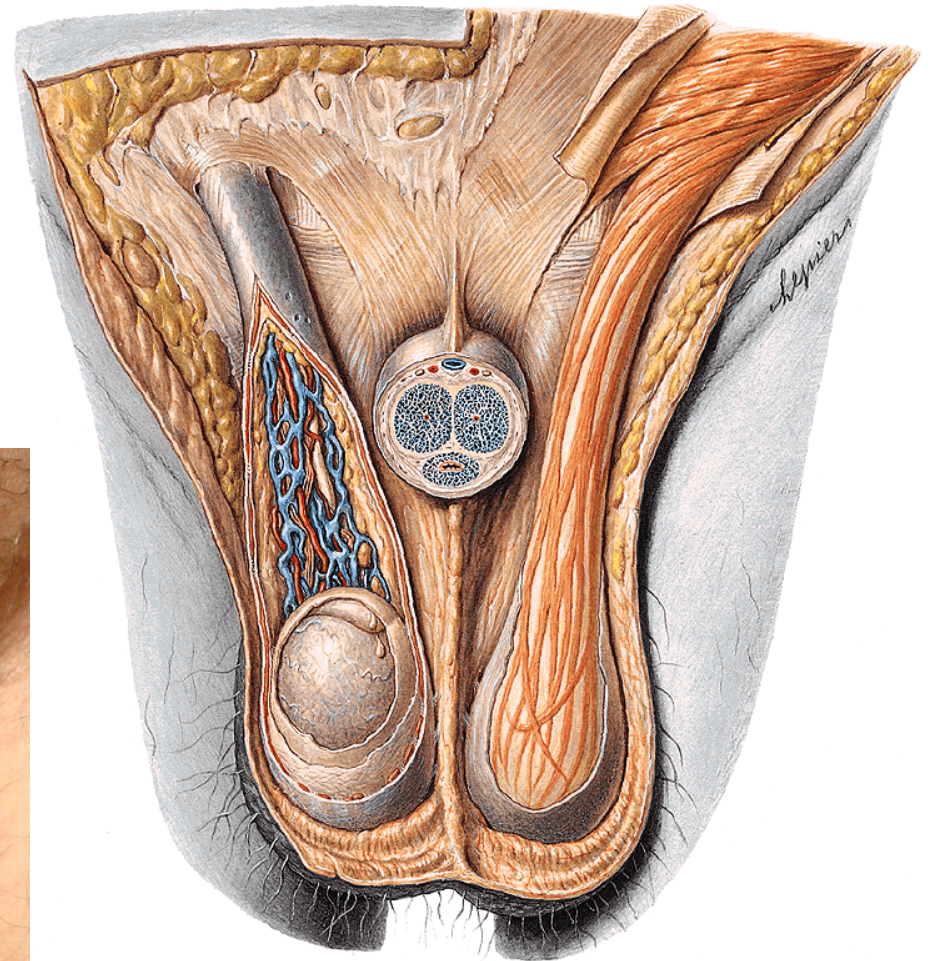
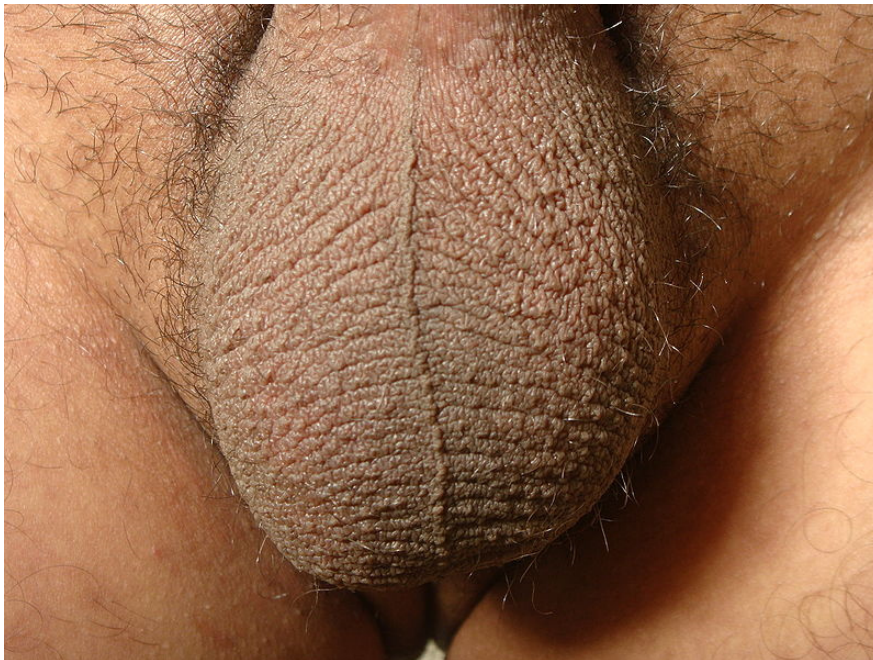SCROTUM

Raphe scroti, pubes

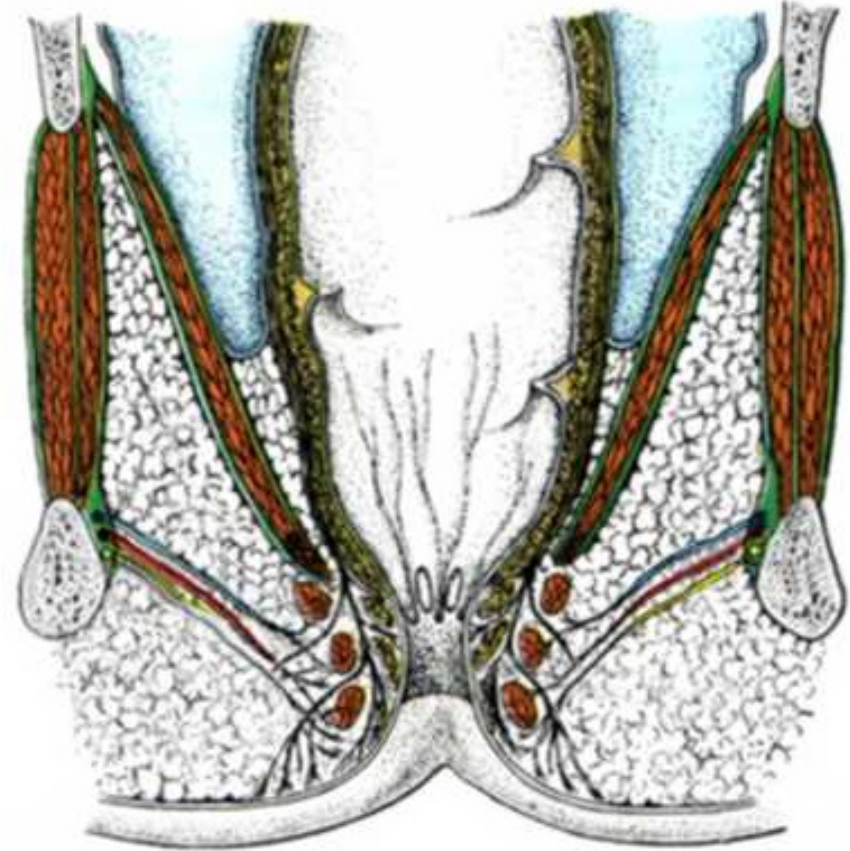
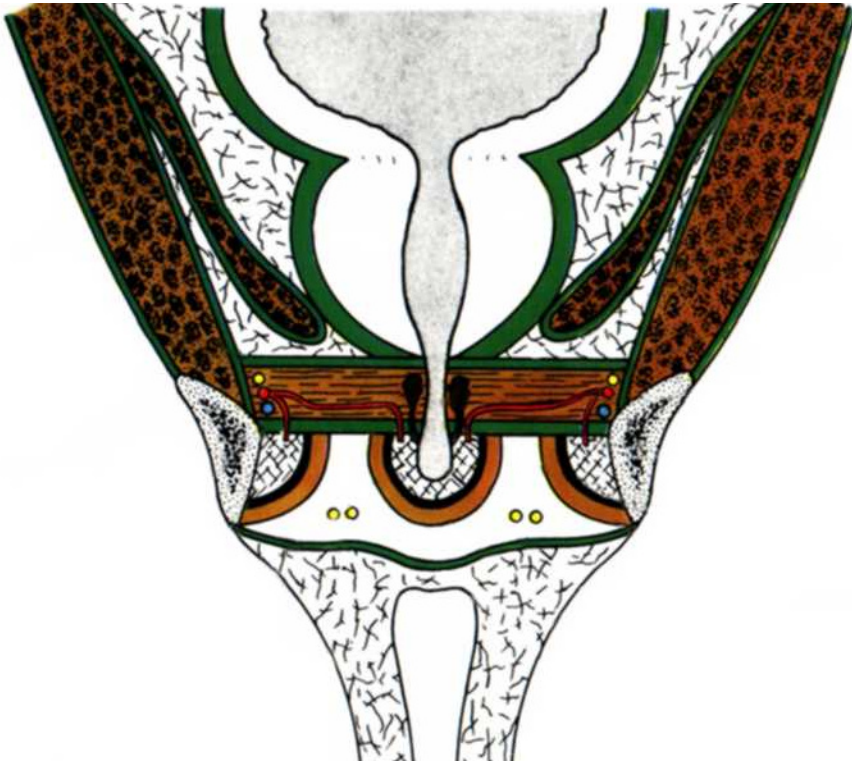
Tunica dartos scroti

Septum scroti

Cavum scroti



Diaphragma pelvis et urogenitale



Diaphragma pelvis

Musculus levator ani (arcus tendineus m. levatoris ani)

musculus pubococcygeus

musculus iliococcygeus

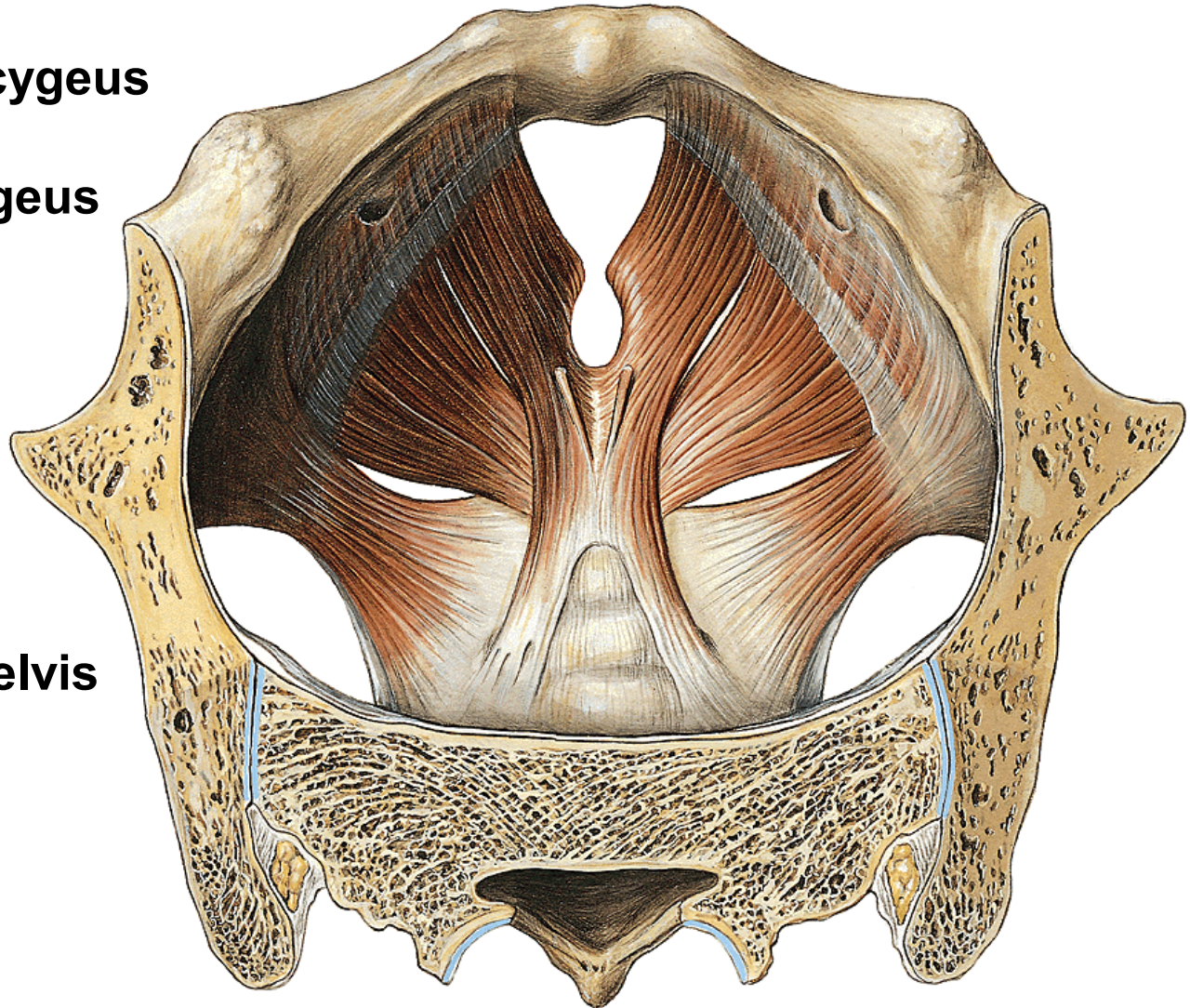
Musculus coccygeus

Hiatus urogenitalis

Lig. anococcygeum

Fascia diaphragmatis pelvis

superior et inferior



Diaphragma urogenitale

Lig. transversum perinei

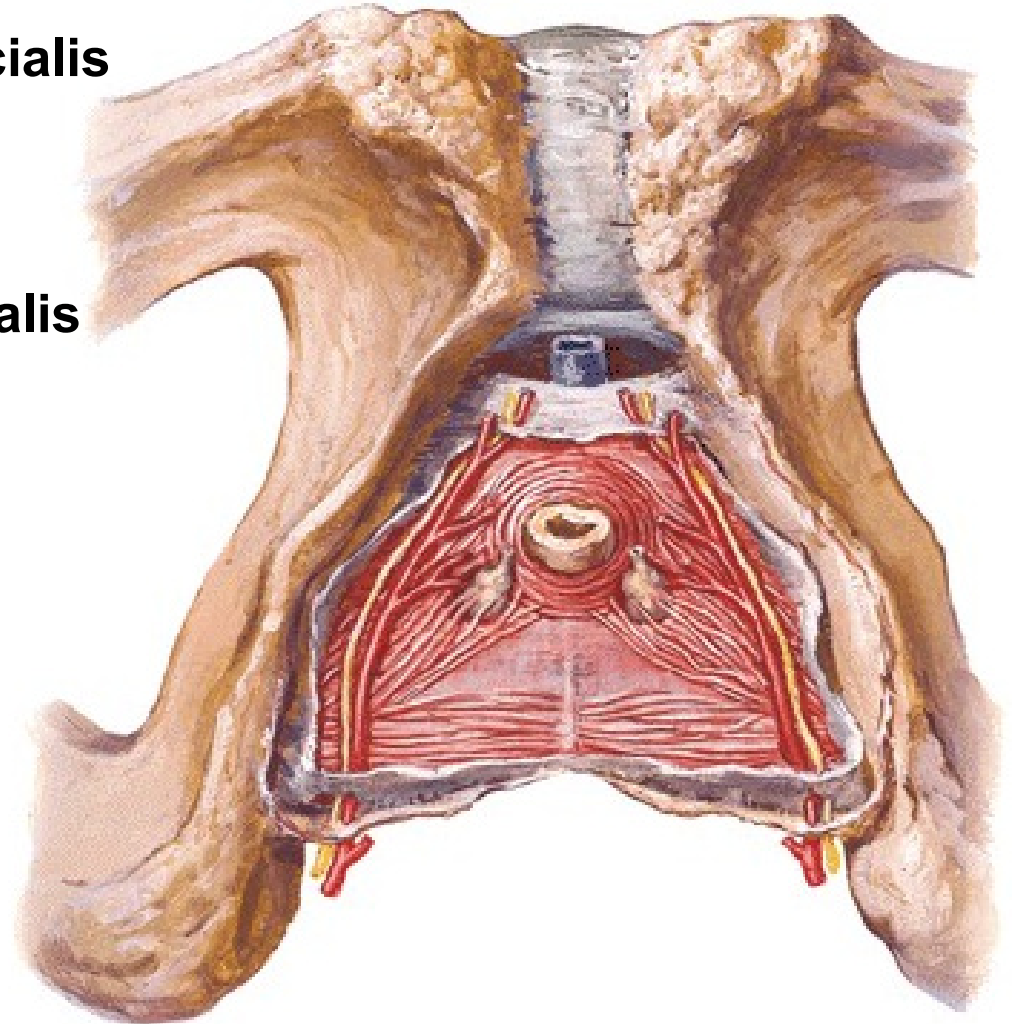
M. transversus perinei profundus (centrum perineale)

M. transversus perinei superficialis

M. sphincter urethrae

Fascia diaphragmatis urogenitalis

superior et inferior



M. ischiocavernosus

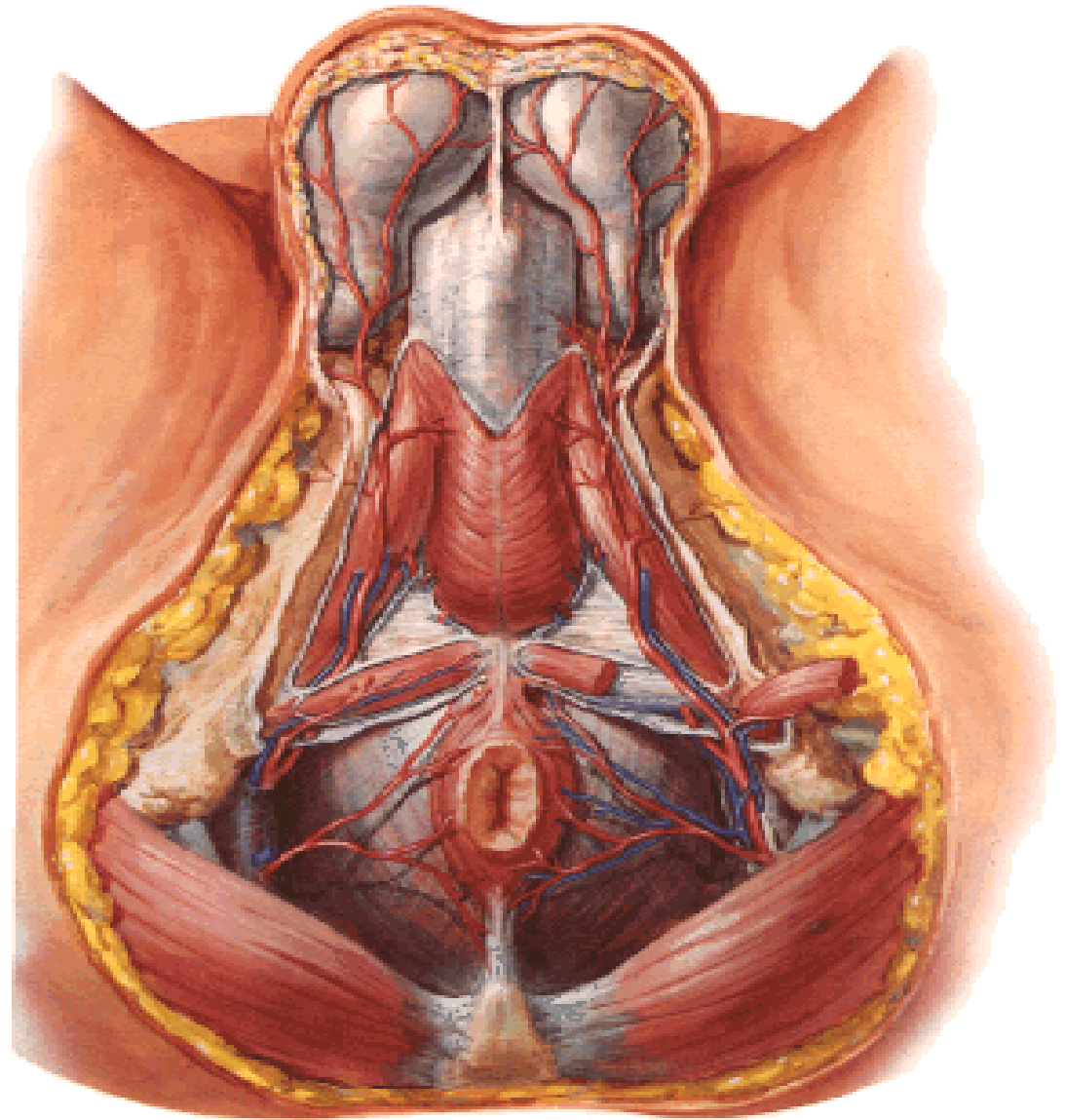
M. bulbospongiosus

M. sphincter ani externus

Fascia perinei superficialis

Spatium perinei profundum

Spatium perinei superficiale



FOSSA ISCHIORECTALIS

Mediokraniálně:
diaphragma pelvis

Laterálně:
m. obturatorius int.
fascia obturatoria
(canalis pudendalis)

Ventrálně:
recessus pubicus

Dorsálně:
m. gluteus maximus

Corpus adiposum fossae ischiorectalis

