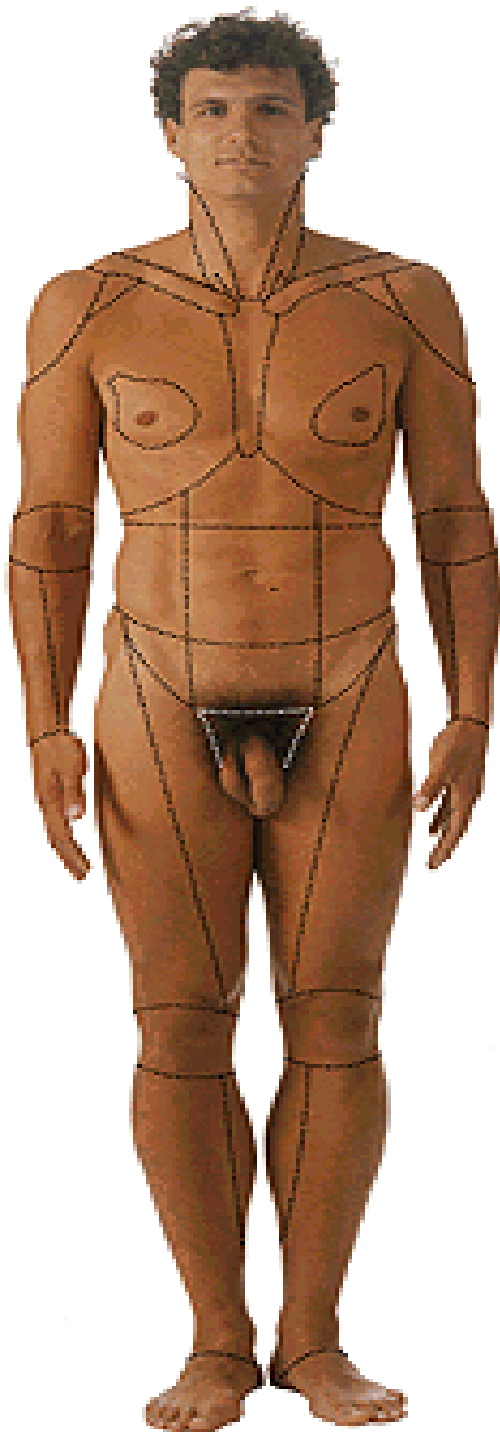


# TOPOGRAFICKÁ ANATOMIE BŘICHA I

a) krajiny – rozdělení      b) regio inguinalis



**Epigastrium**

**čára: xifisternální**

**Mesogastrium**

**subkostální**

**Hypogastrium**

**bispinální**

**břicho:**

**a) v niveau hrudníku**

**b) nad niveau hrudníku**

**Orientační čáry, krajiny**

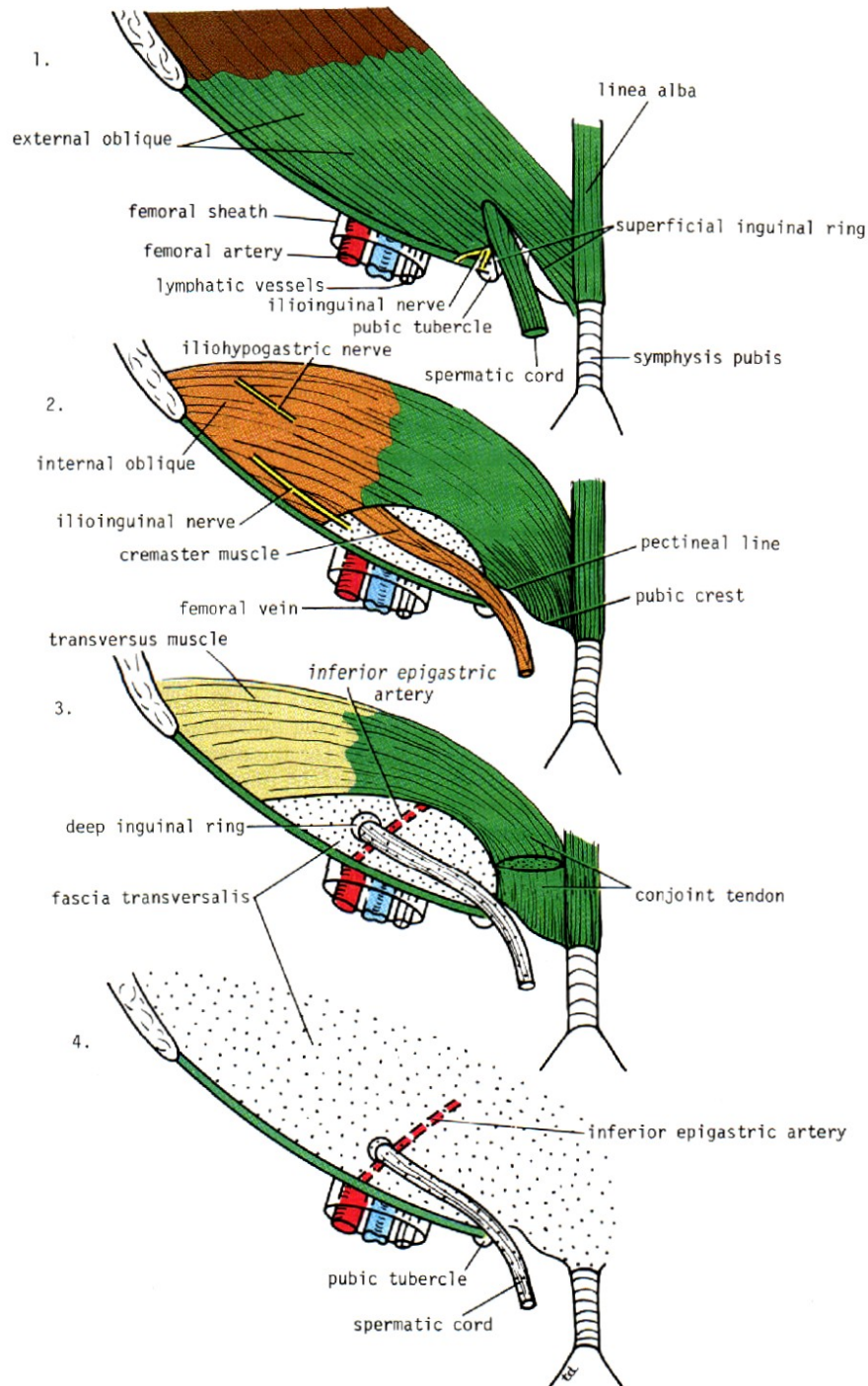
# stěny

a) přední

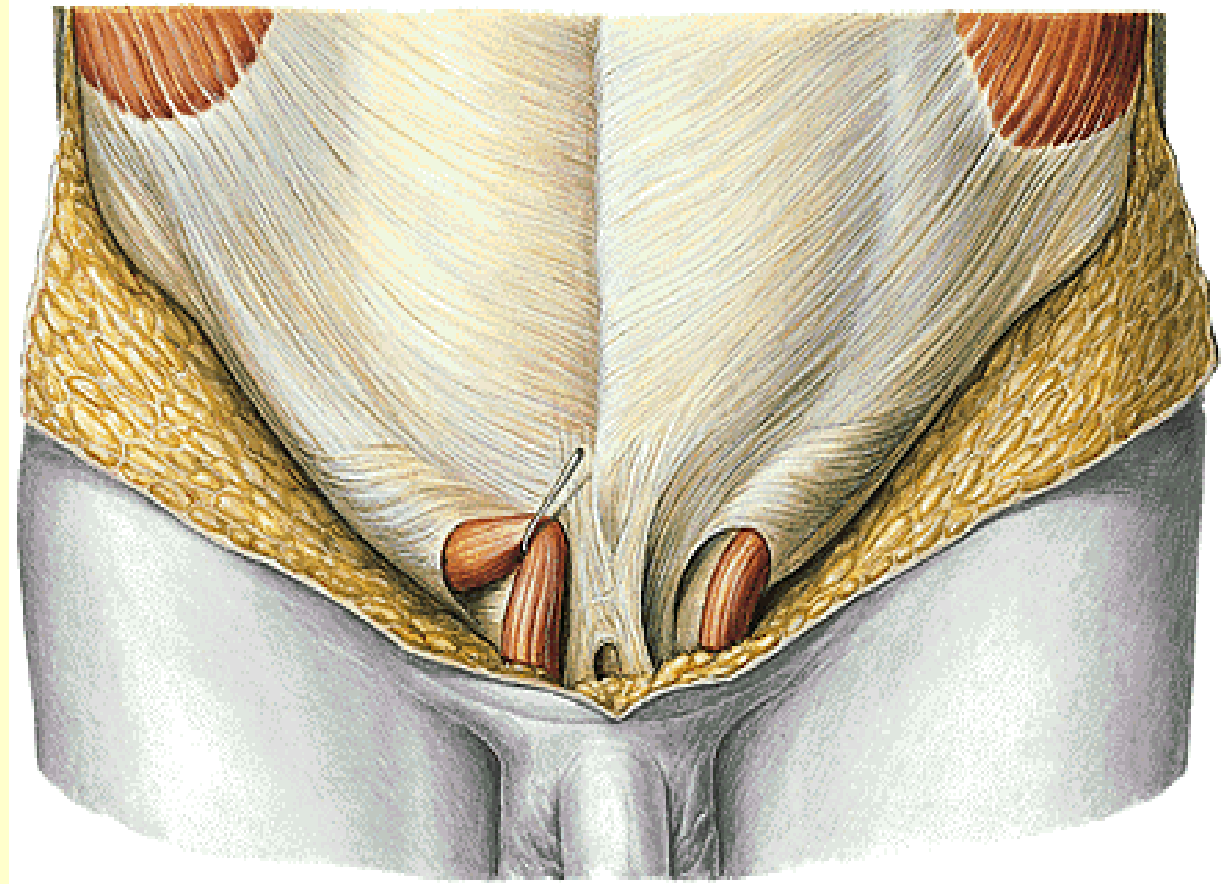
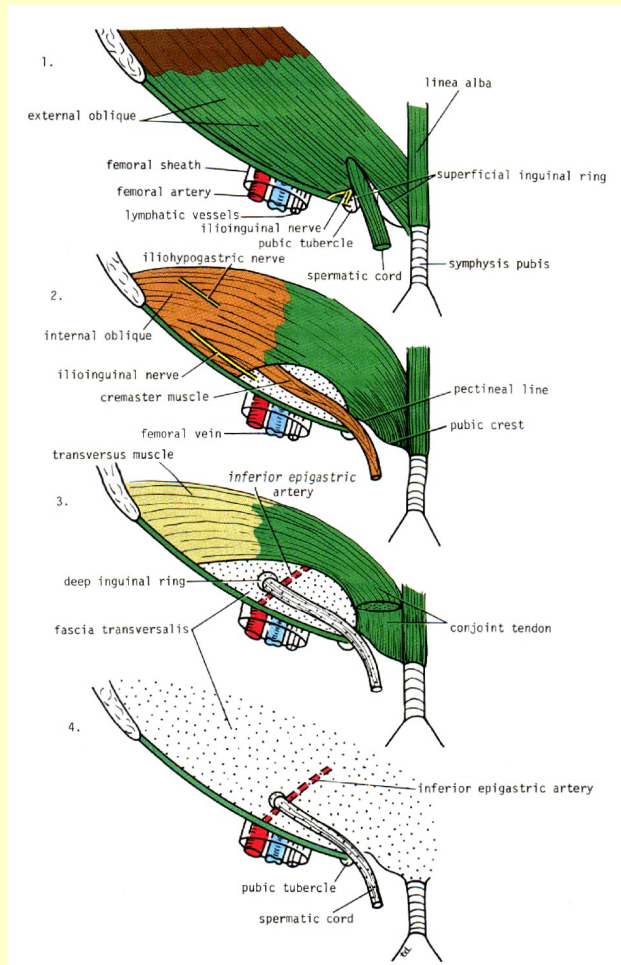
b) horní

c) horní, zadní

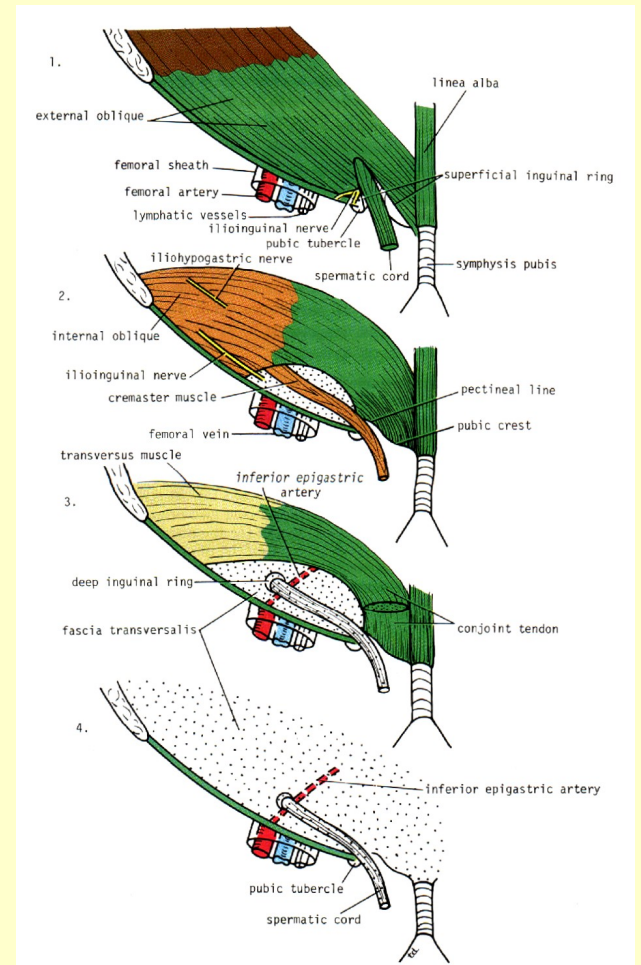
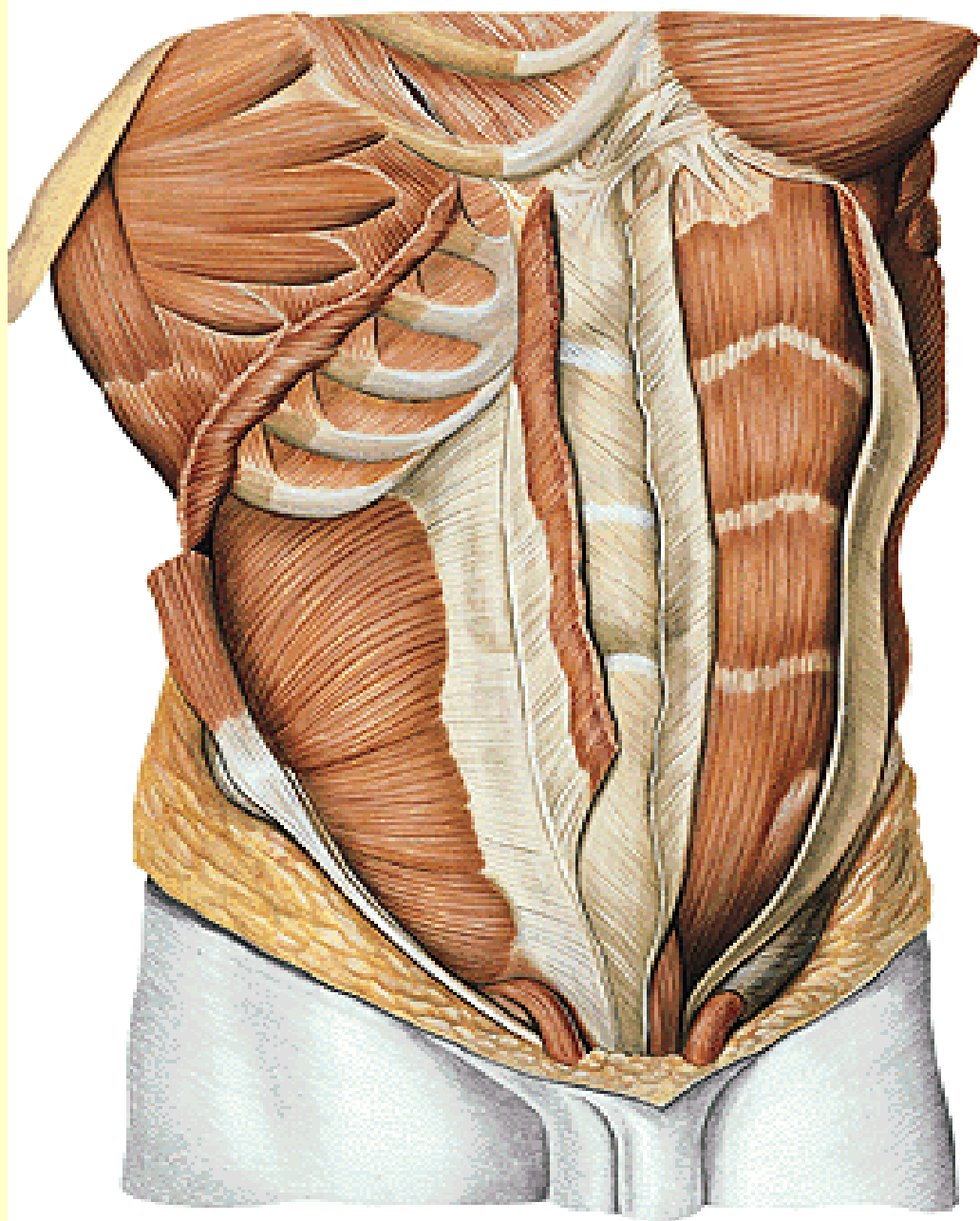
d) zadní, dolní



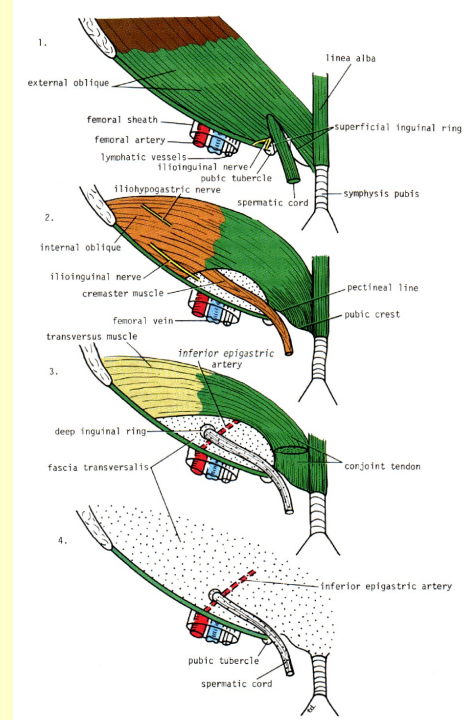
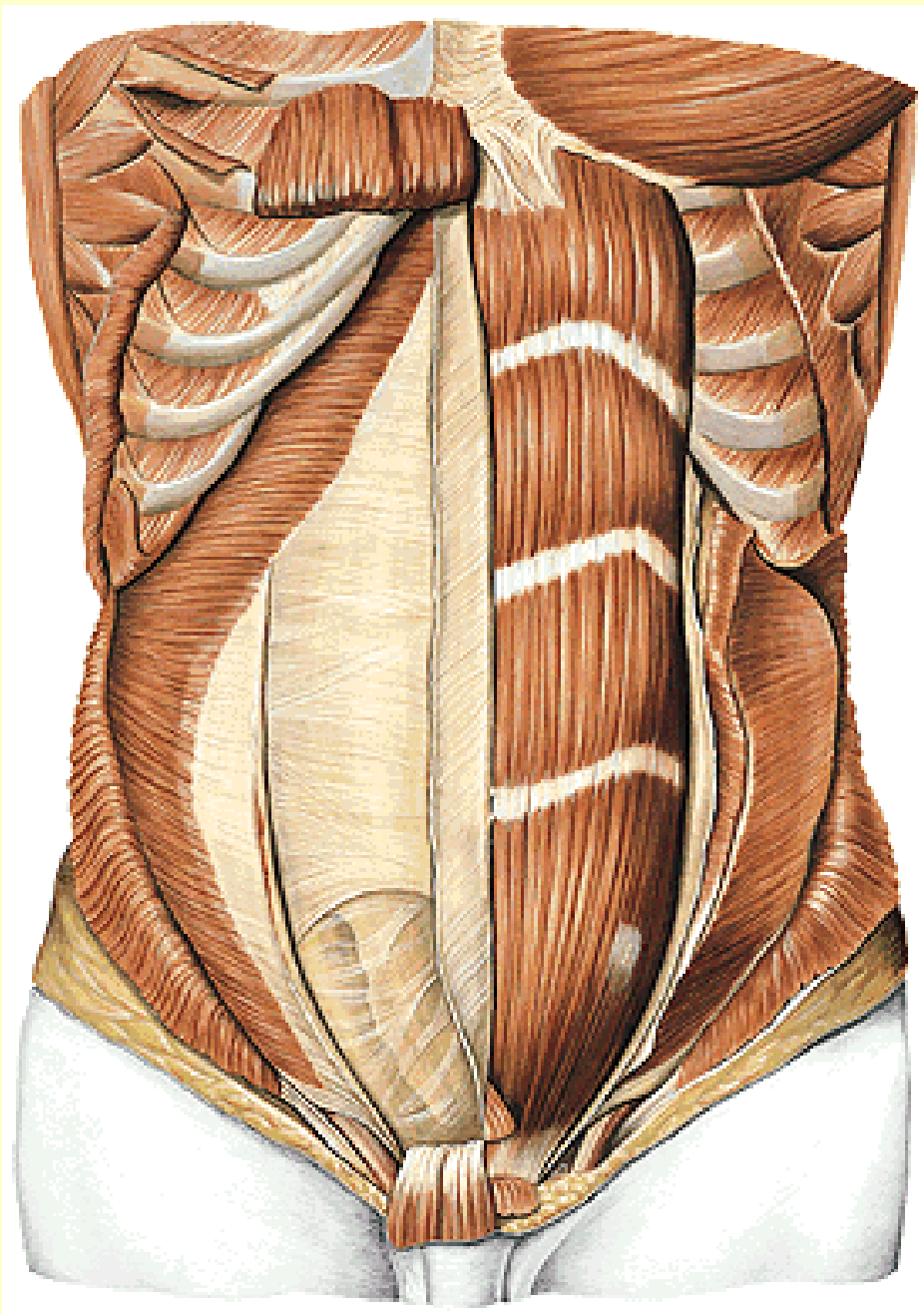
Inguinální  
kanál:



**Přední stěna:** zevní anulus (crus, fibrae, lig. reflexum),  
zevní obliquus, funiculus,



**Horní stěna:**  
**m. obliquus internus**



**Horní stěna:**

**m. transversus abd.**

**+ linea semilunaris Spigelii**

**Zadní stěna:**

**2/3 – apon. obl. int., apon.m.transv.**

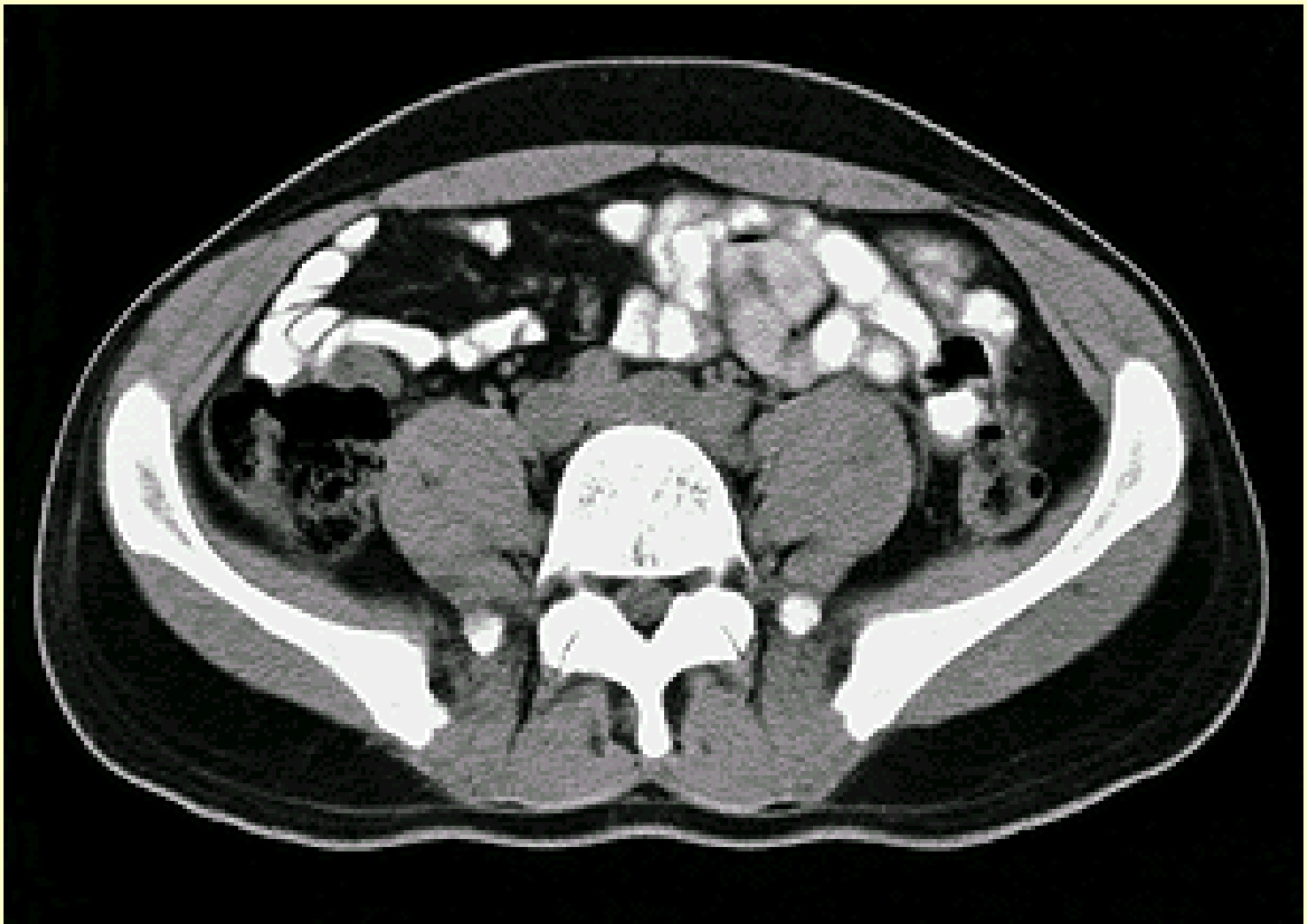**fasc. transv., peritoneum**

**= 4 vrstvy**

**1/3- pod zona (lin.) arcuata (Douglas)**

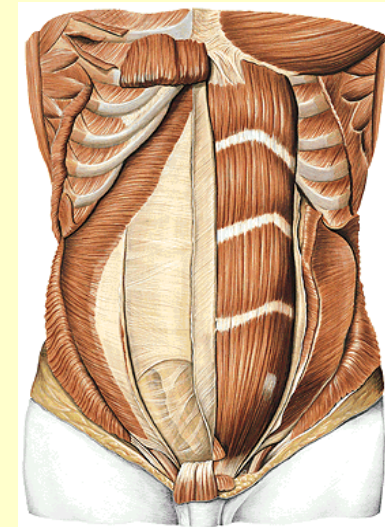
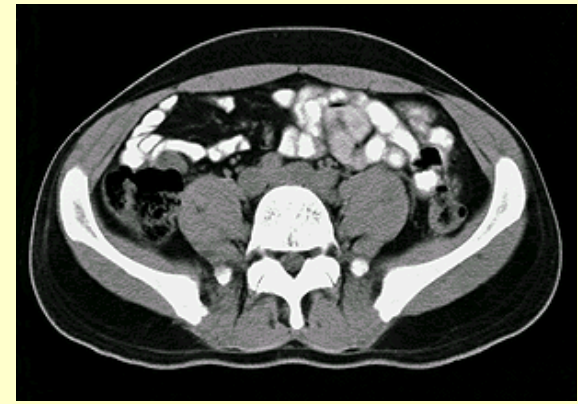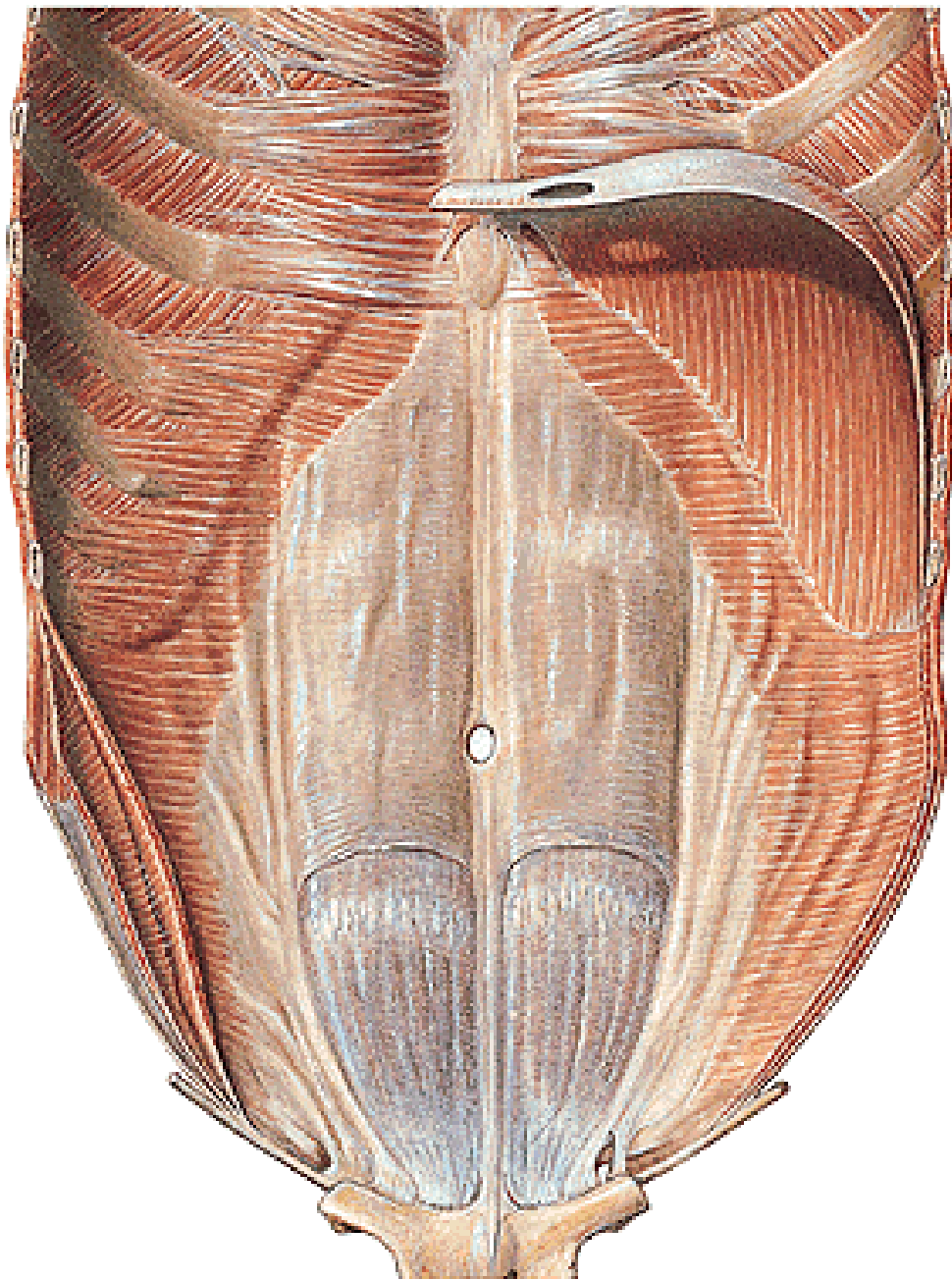
**fascia transv.+ peritoneum**

**= 2 vrstvy**



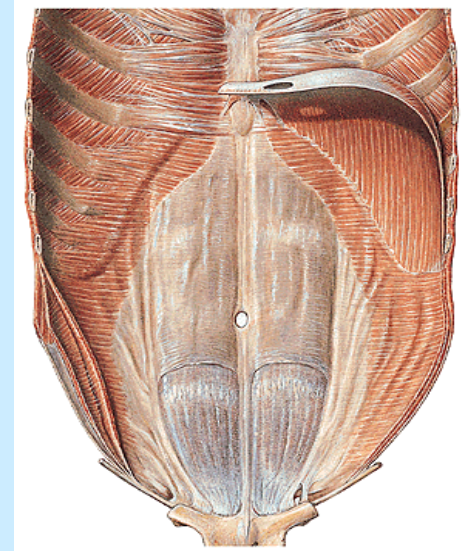
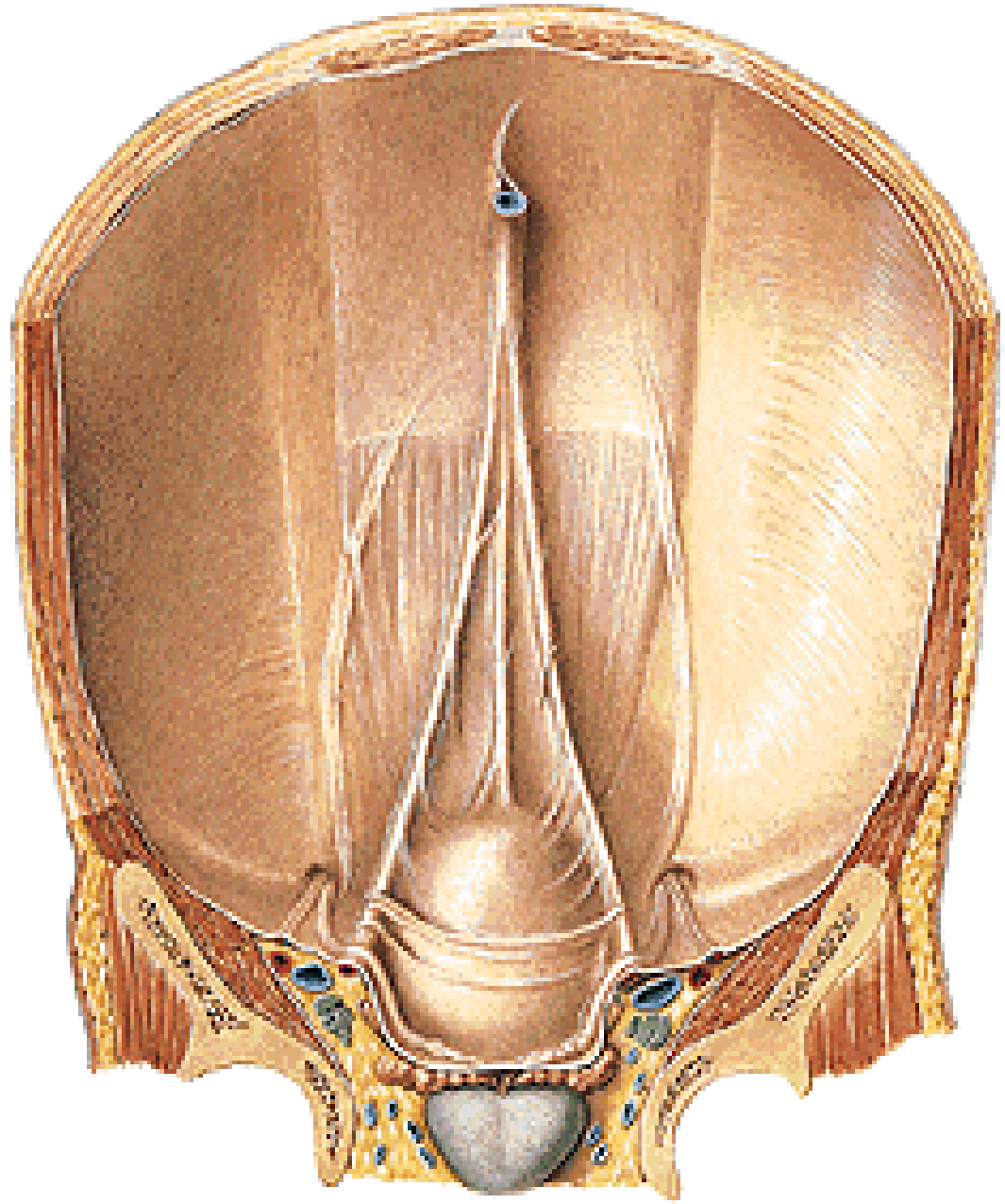
MR břišní stěny – m. rectus, linea alba, m. obliquus ext., int., transv.





**Zadní stěna:** linea arcuata  
m. transversus abd.,  
linea alba  
linea semilunaris Spigelii,  
*falx inguinalis, lig. interfoveol.*





## Zadní stěna:

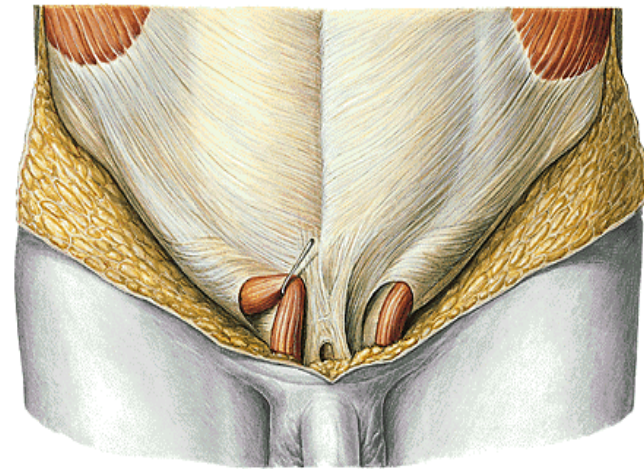
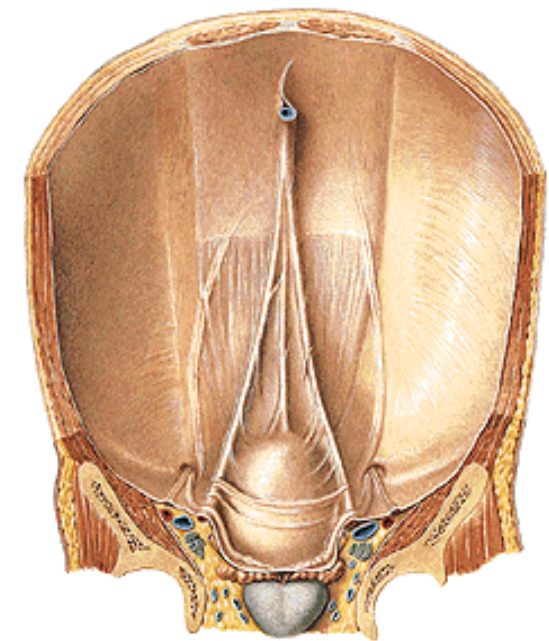
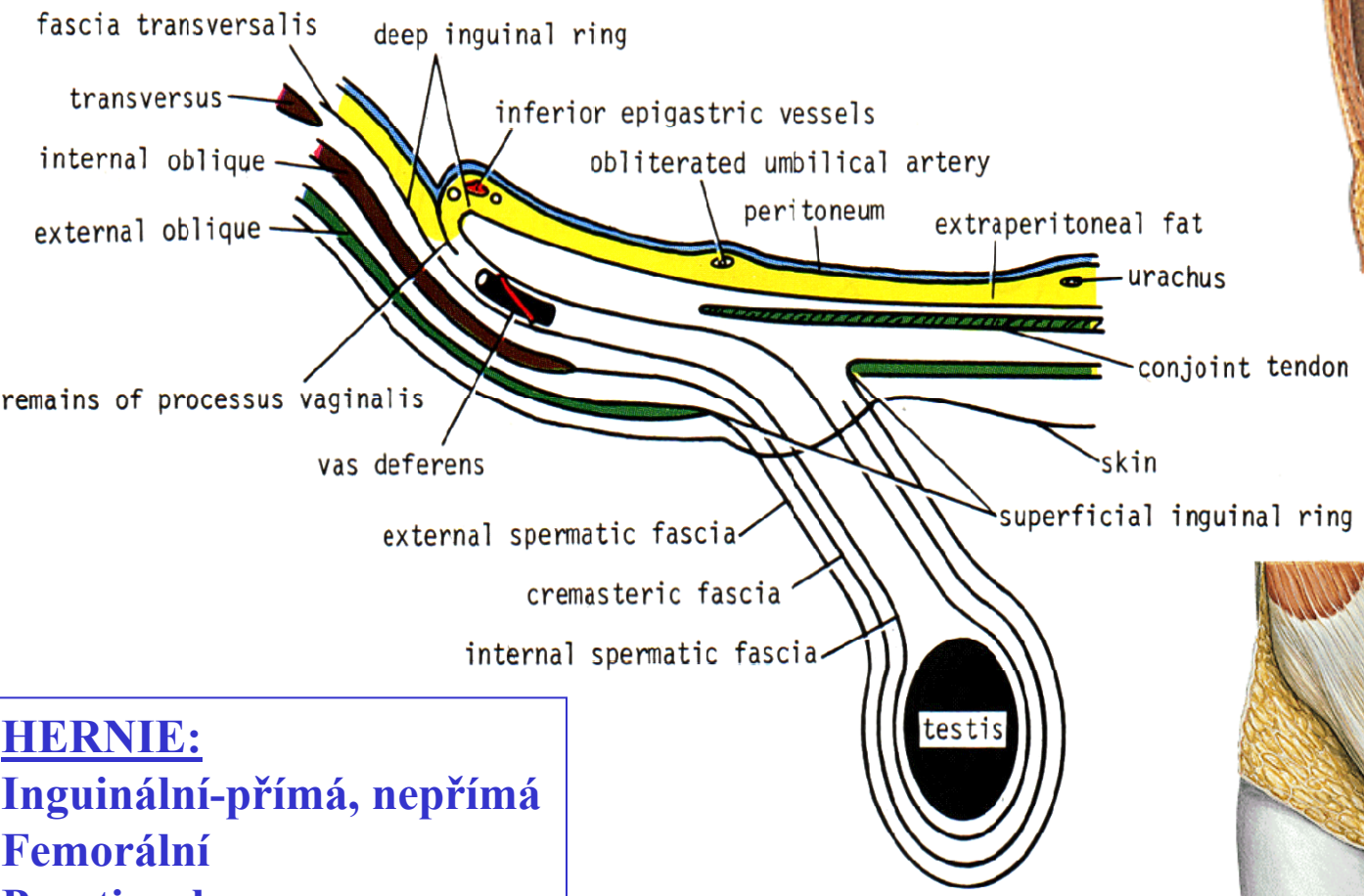
a) **plica umbilic. mediana**  
( lig. umbil. medianum –  
- urachus)

b) **plica umbilic. medialis**  
(lig. umbilic. mediale - a. umbil.)

c) **plica umbil. lateralis** – vasa  
epigastrica + lig.interfoveol.

fossae: supravesicalis,  
inguinalis medialis  
- lateralis



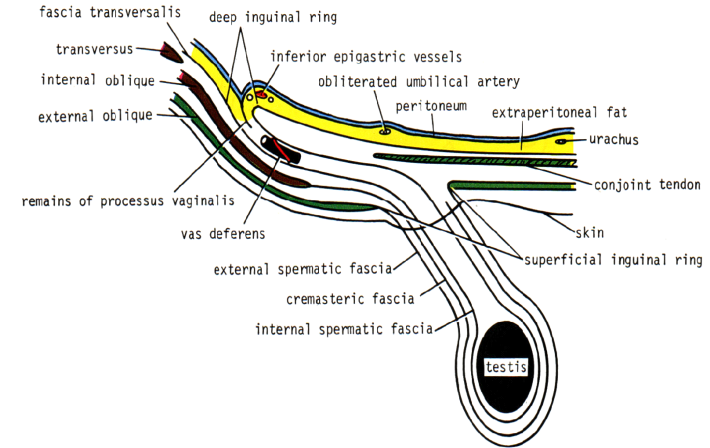
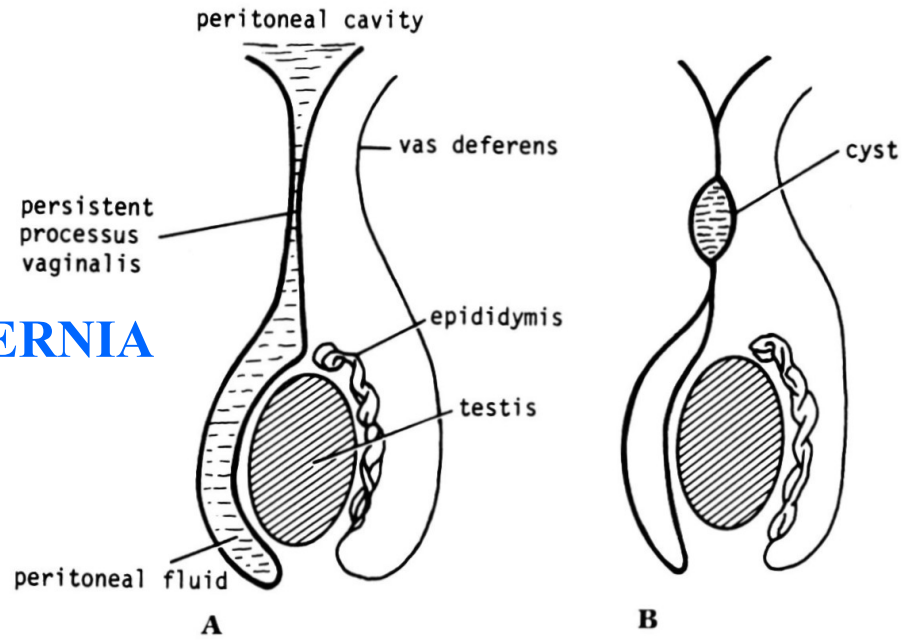


**HERNIE:**  
**Inguinální-přímá, nepřímá**  
**Femorální**  
**Psoatic. absces**

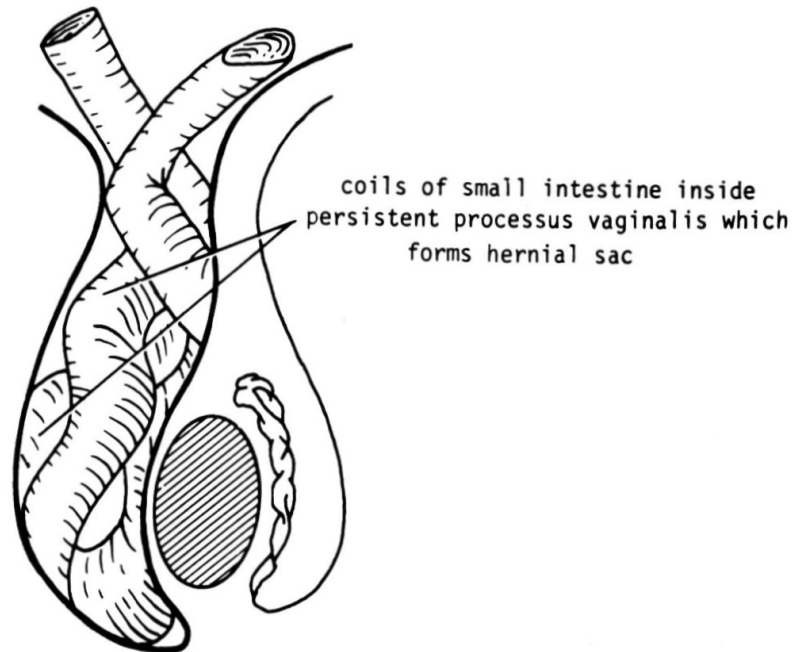
**Příčný řez**

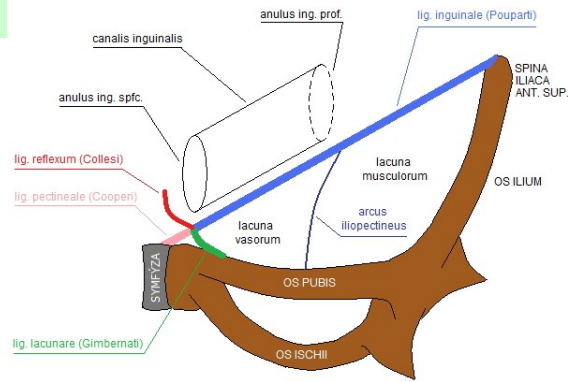
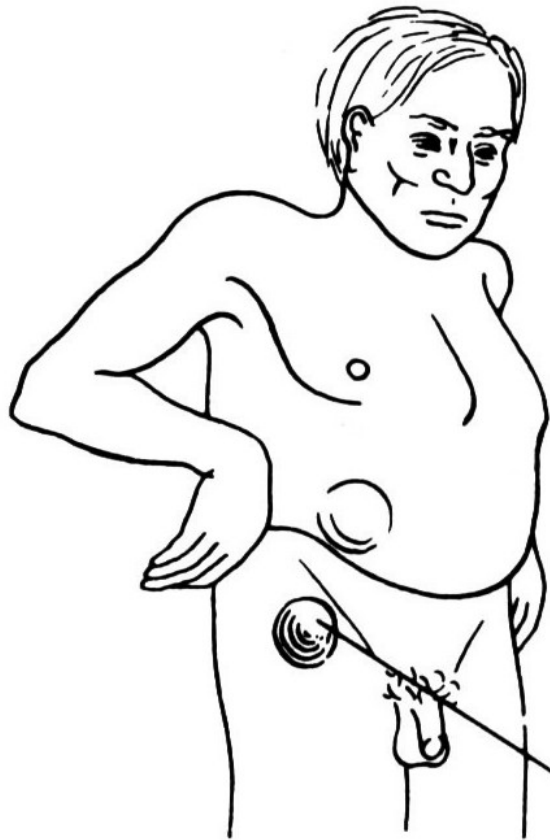

# HERNIA

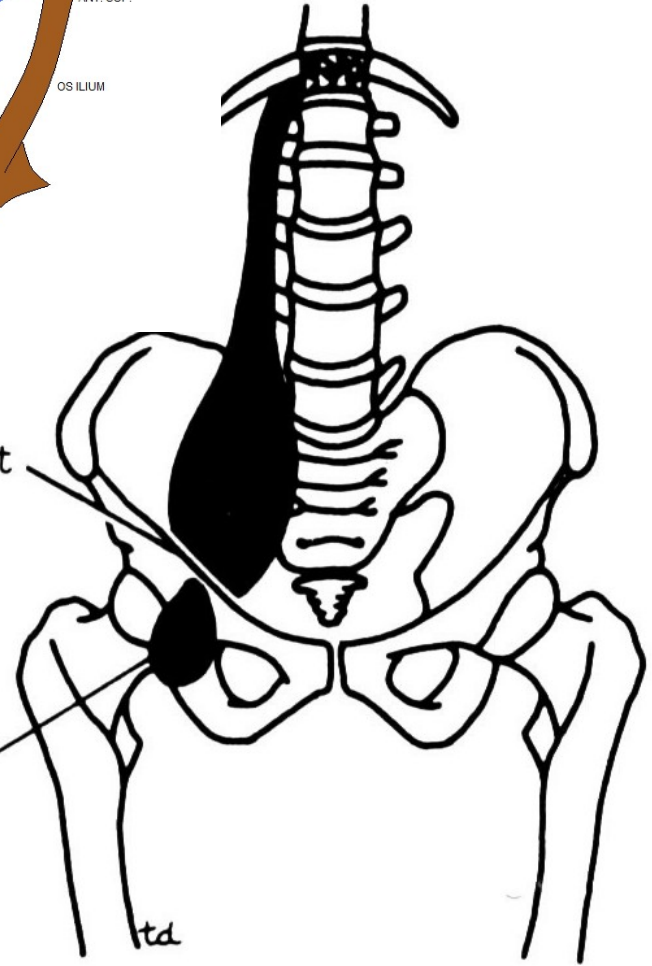


# HERNIA



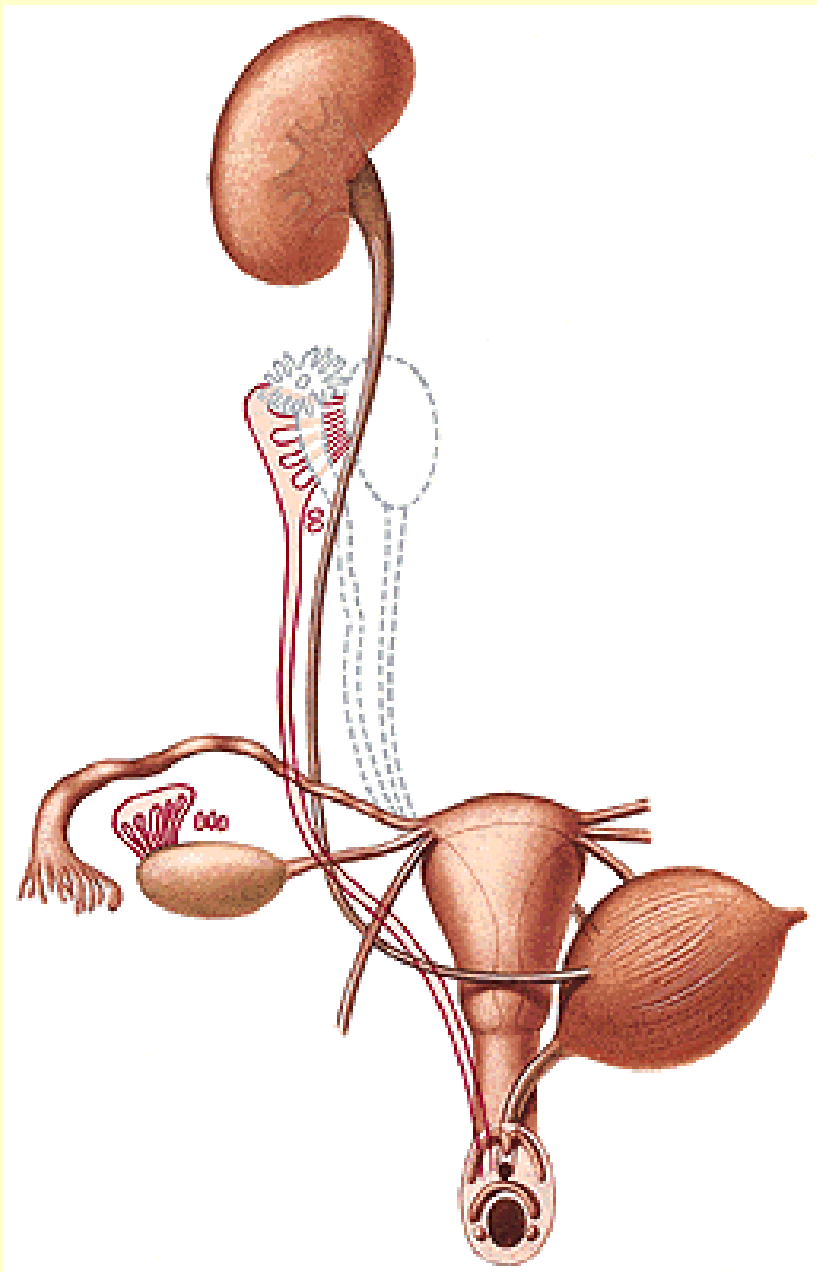


inguinal ligament



psoas abscess

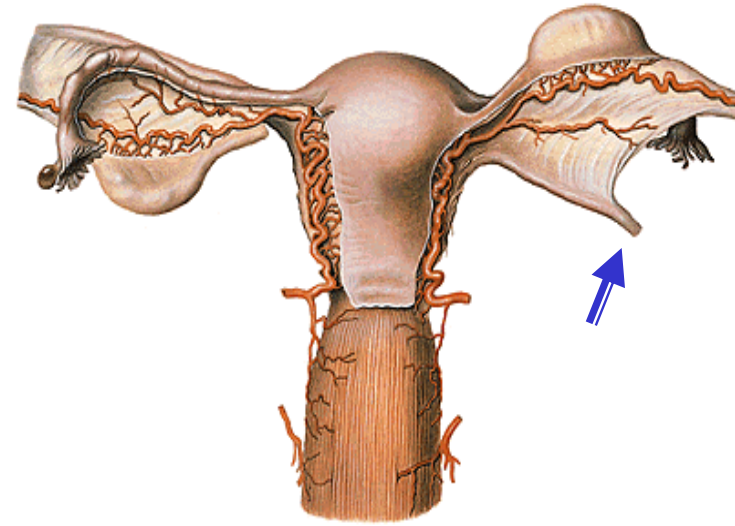
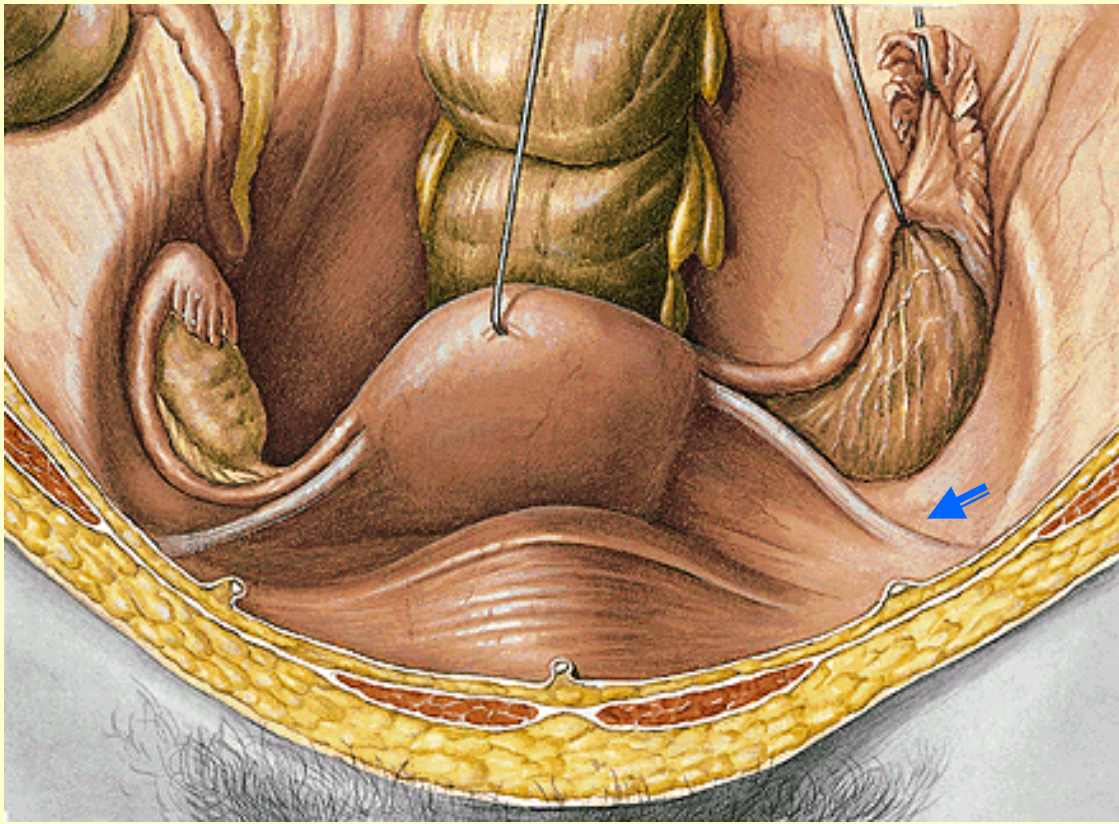
**Diferenciální diagnostika – hernia femoralis vs. psoatický absces**



## Obsah kanálu (žena)

**lig. teres uteri, lig.rotundum  
chorda uteroinguinalis**





**Lig. teres uteri** (rotundum, chorda uteroinguinalis )  
AV + AF ( anteverze, anteflexe)

