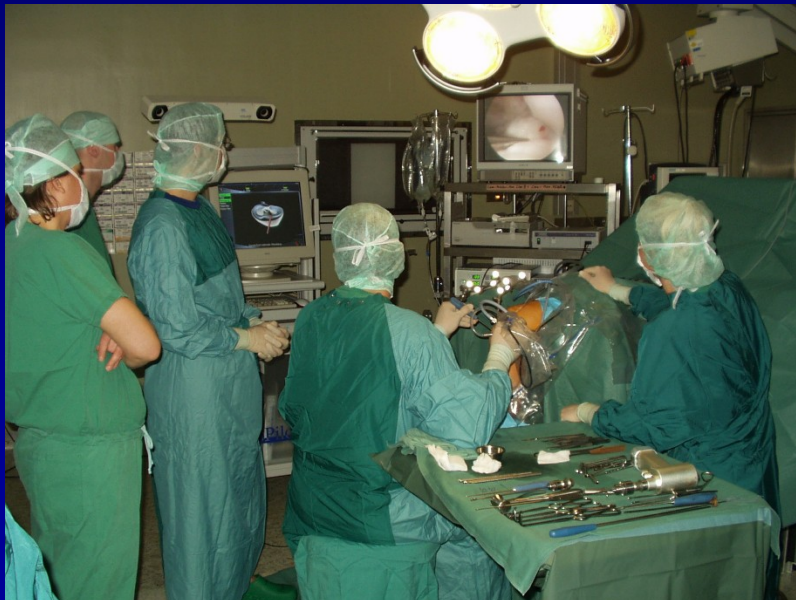

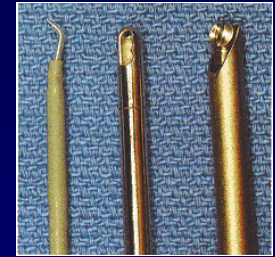
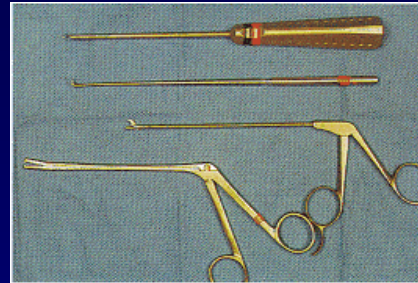

# ARTROSKOPIE

- Endoskopická metoda
- Zobrazení a léčba
- Celková nebo spinální anestezie

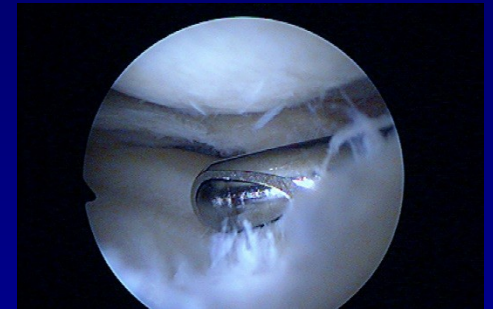

- koleno
- rameno
- hlezno
- loket
- zápěstí
- kyčel
- malé klouby

# Artroskopie



- Kamera
- Artroskop
- Xenonové světlo s optickým kabelem
- ASK pumpa
- Nástroje
- Shaver
- Vaper
- Tisk, VIDEO



# Diagnostická artroskopie

Chrupavka

Vazy

Menisky

Jiné intraartikulární struktury

Synovialní membrána

Biopsie

# Operativní artroskopie

Menisky

Chondropathie

Plastika vazů

Sutura rotátorové manžety

Instabilita ramene

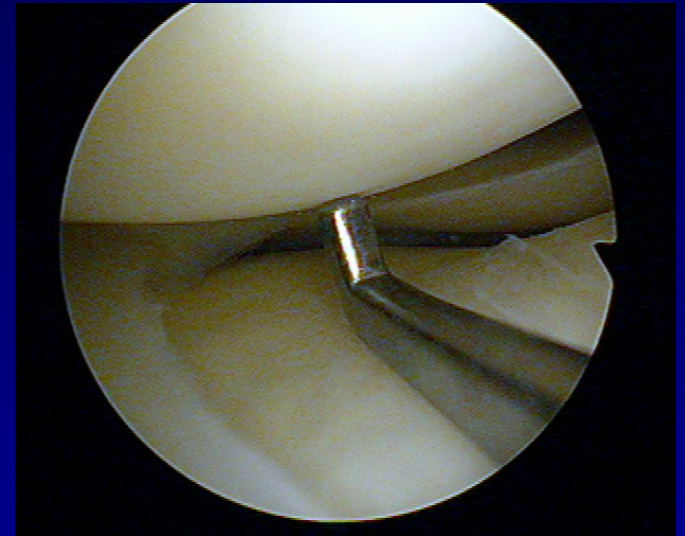
Ošetření transchodrálních lézí

Synovektomie

Podpora při léčení nitrokloubních zlomenin

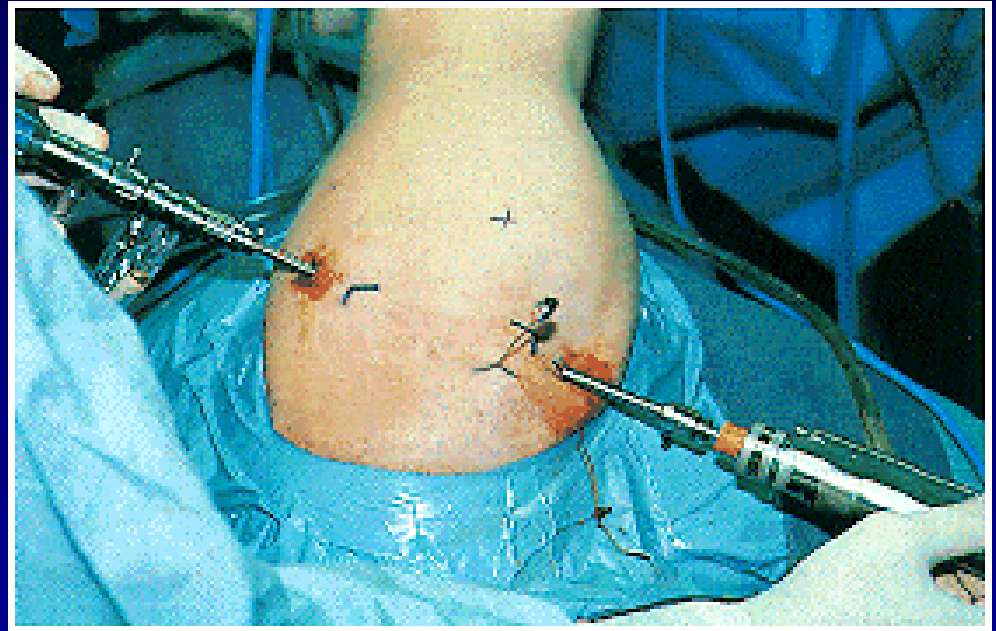
# Výhody

- Perfektní vizualizace
- Menší bolest po výkonu
- Rychlá rehabilitace
- Malá incise



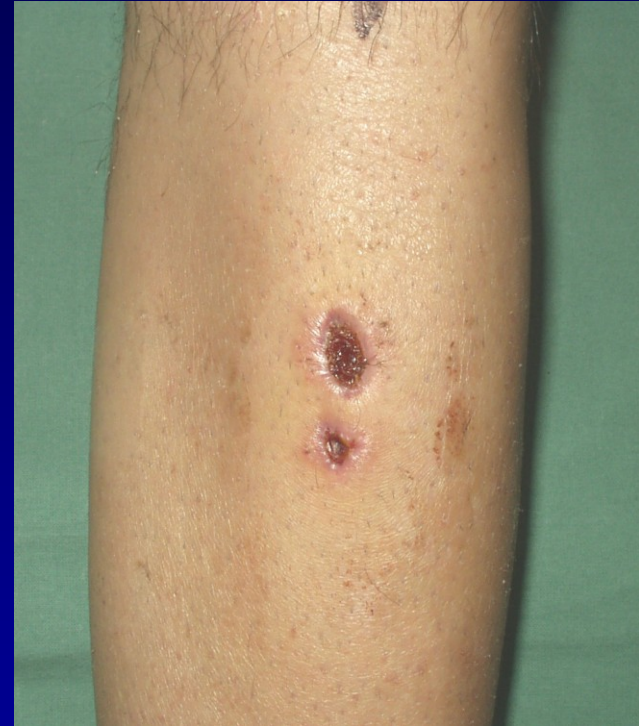# Nevýhody

- Invazivní metoda
- Turniket



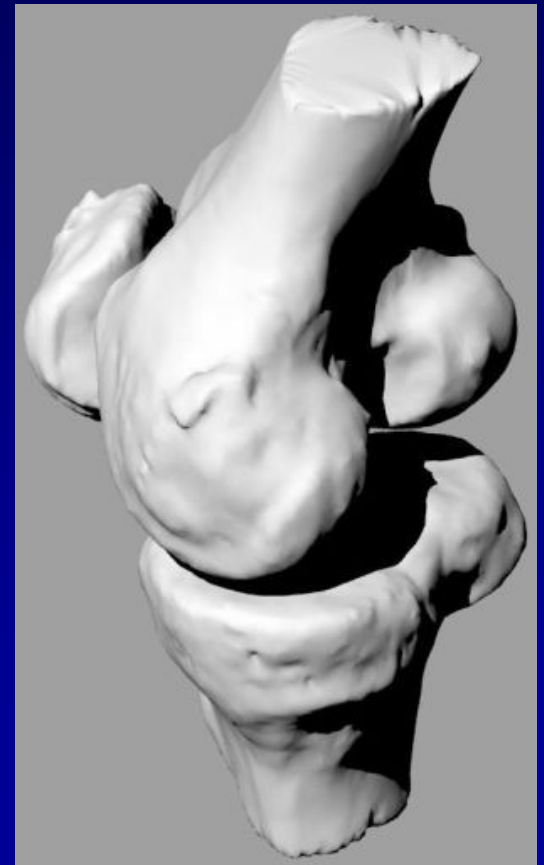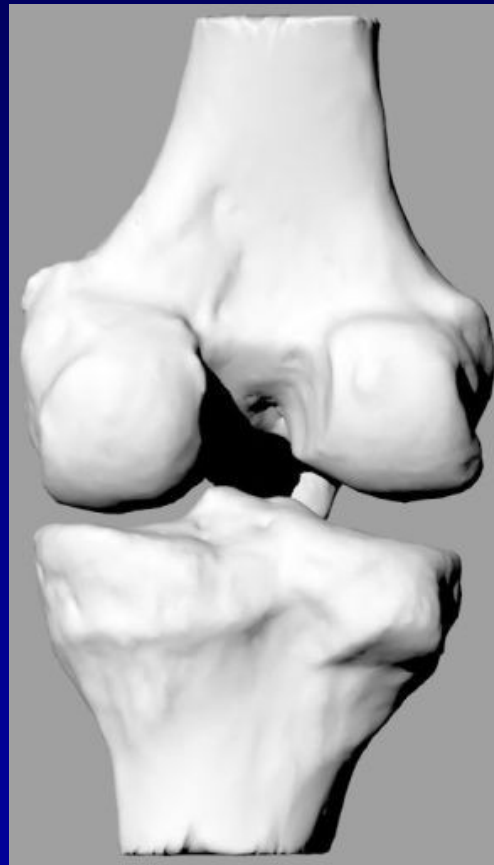
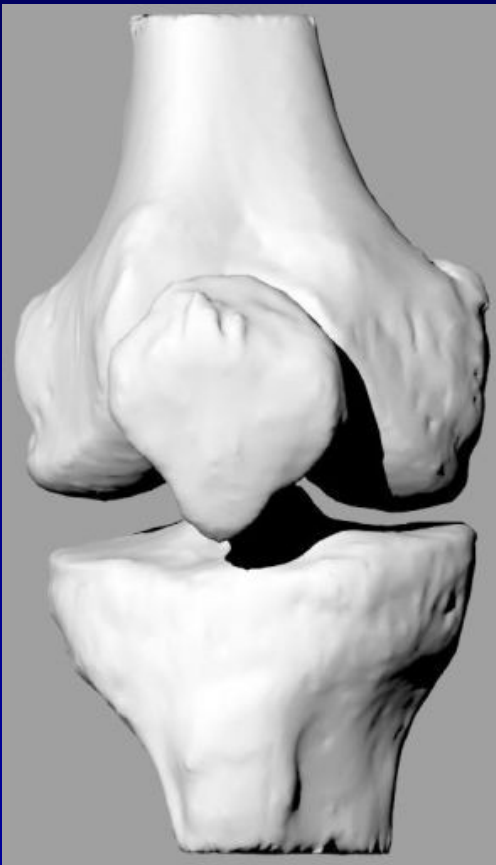# Komplikace

- Hojení rány
- Synovialitis, výpotky
- Nervové léze
- Flebotrombóza
- Infekce



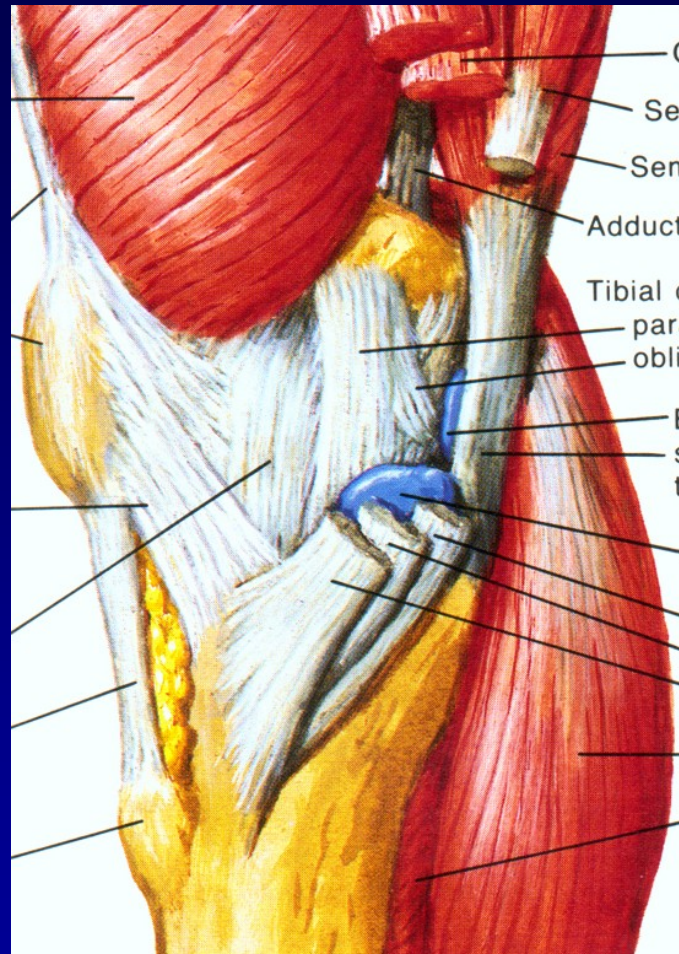
# Koleno- složitá struktura

Artikulující kosti: Femur, tibie and patela



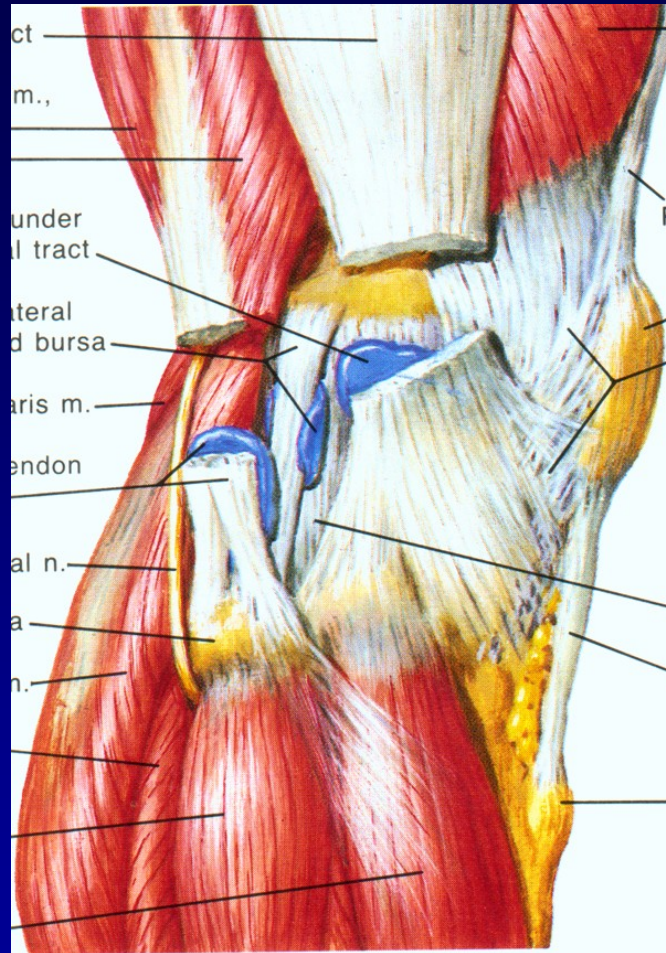


# Stabilita



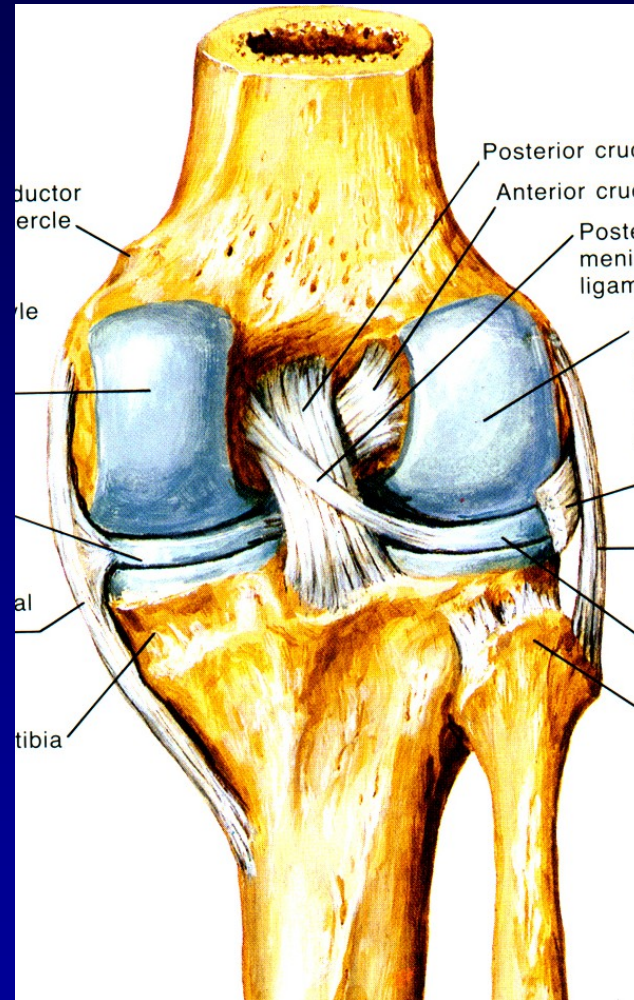
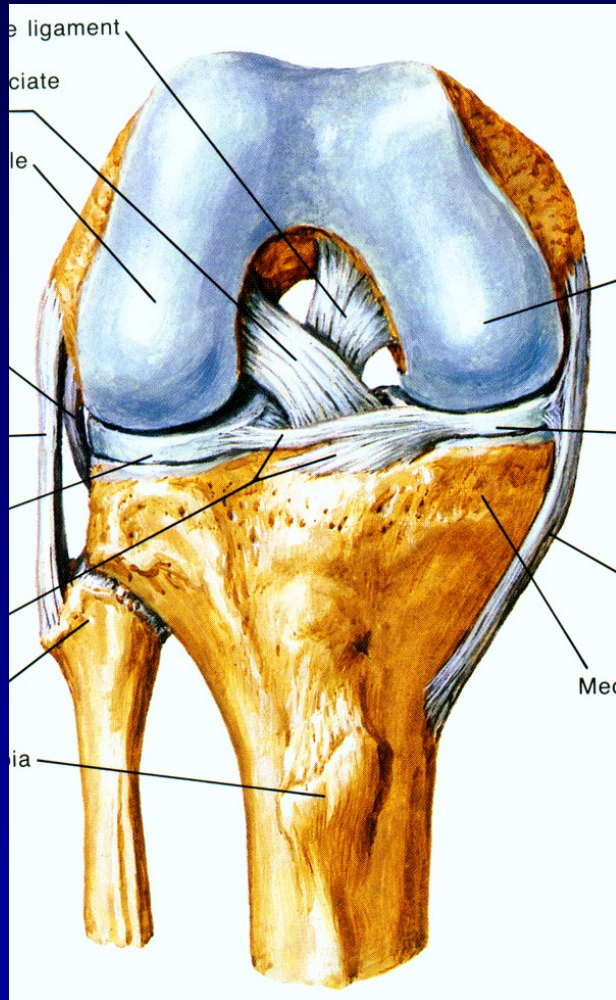
Medialní strana

# Stabilita



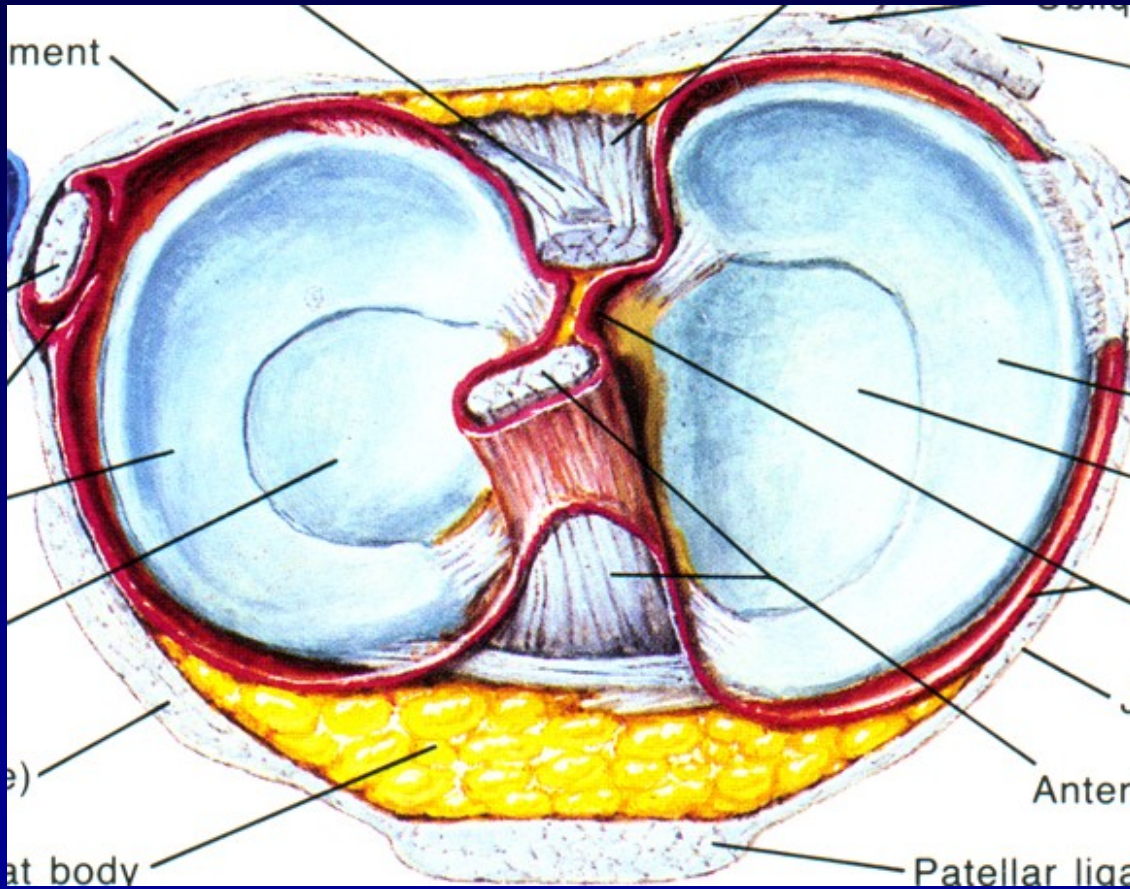
Laterální strana

# Stabilita



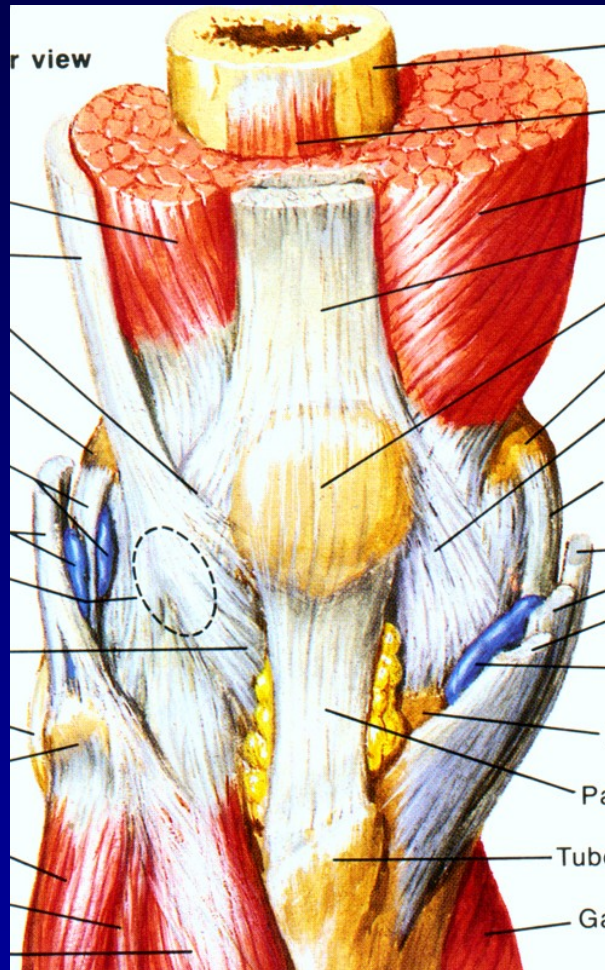
Zkřížené vazy

# Stabilita



# Menisky

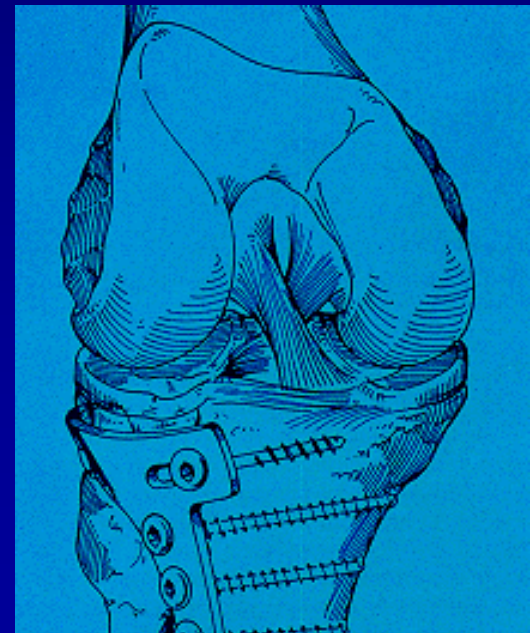
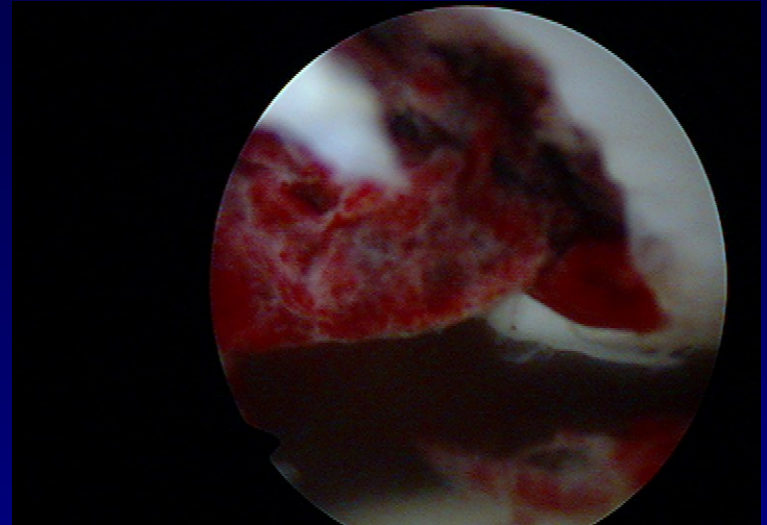
# Stabilita



Svaly

# Koleno

- Traumatologie
- Chondropatie
- Degenerativní změny



# Traumatologie

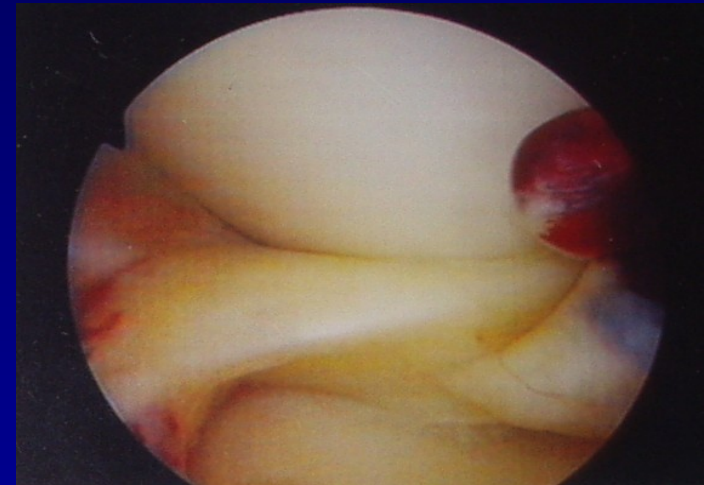Haemarthros

Léze menisků

Ruptury vazů

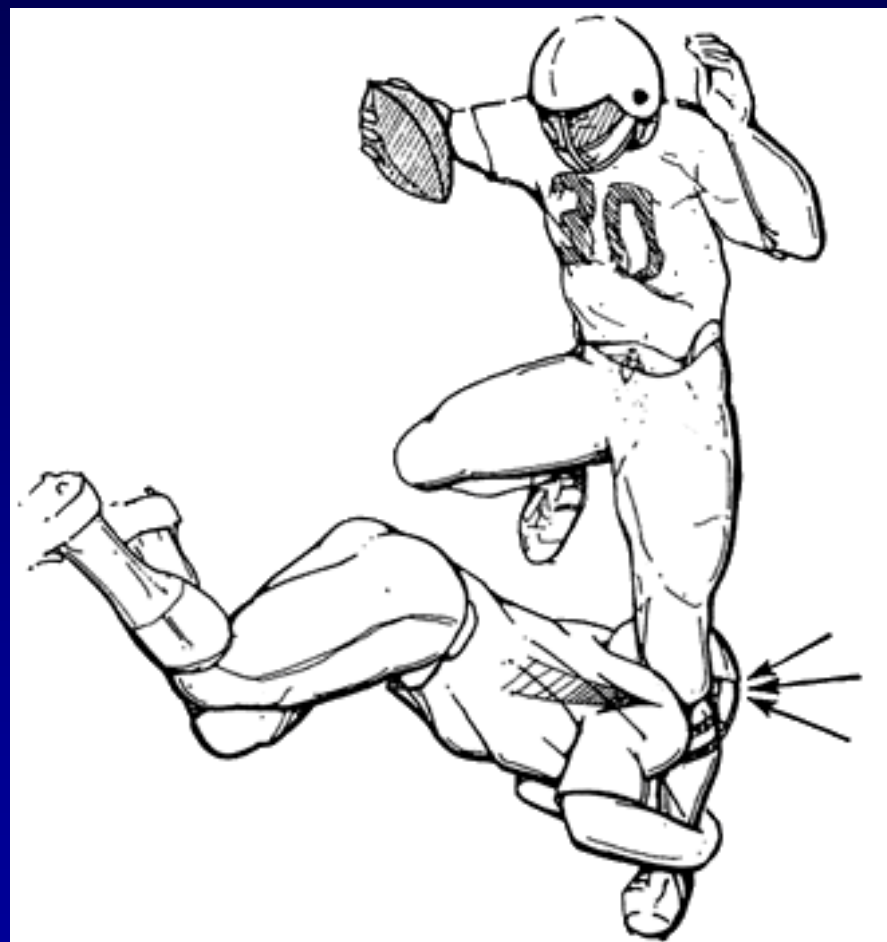Luxace pately

Transchondrální zlomeniny



# Anamnéza

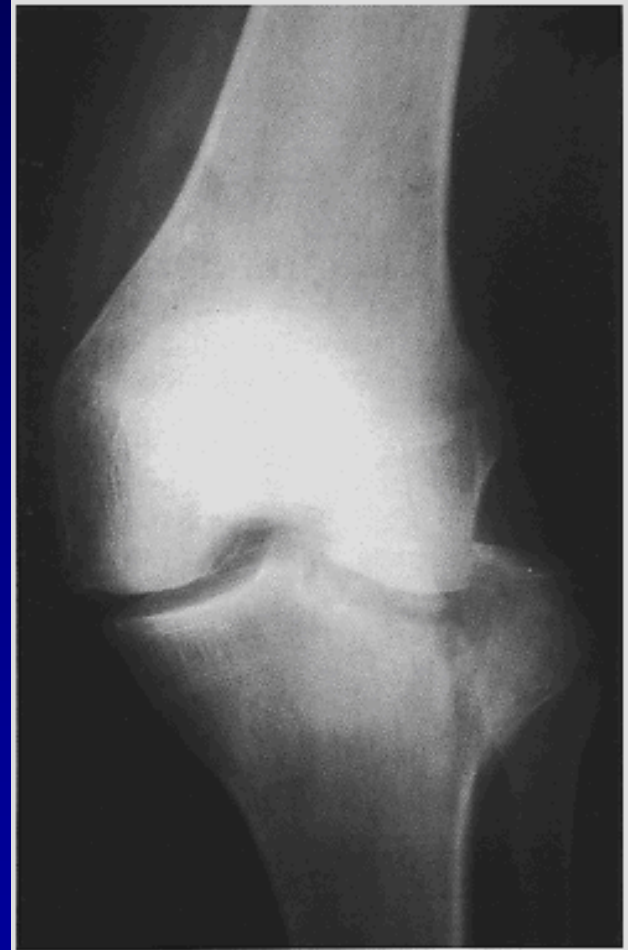- Kde
- Kdy
- Okolnosti úrazu
- Mechanismus úrazu





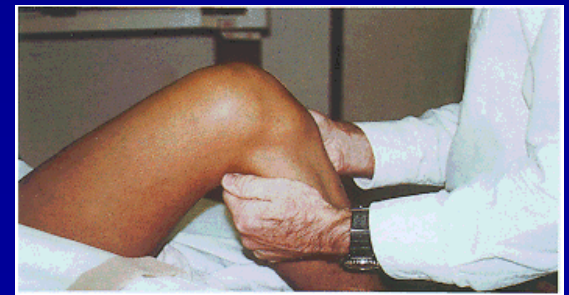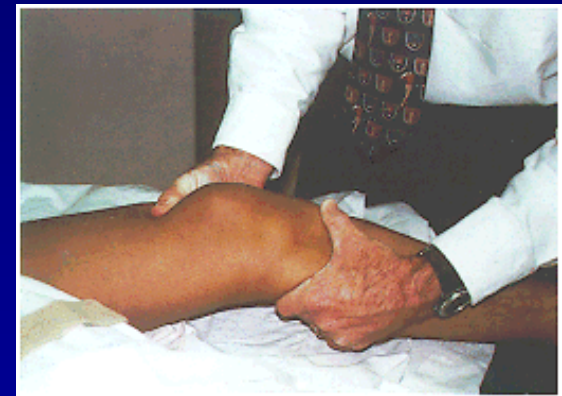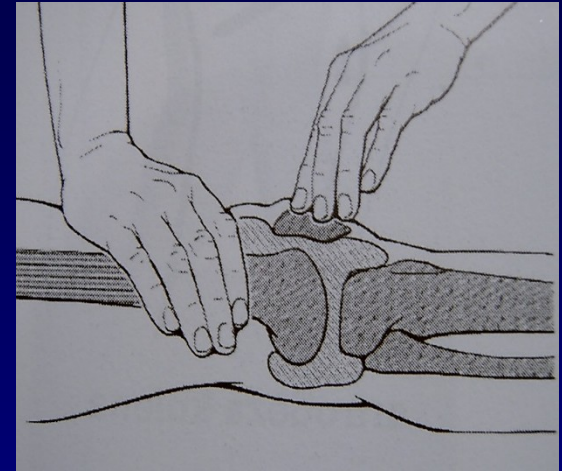
# Vyšetření

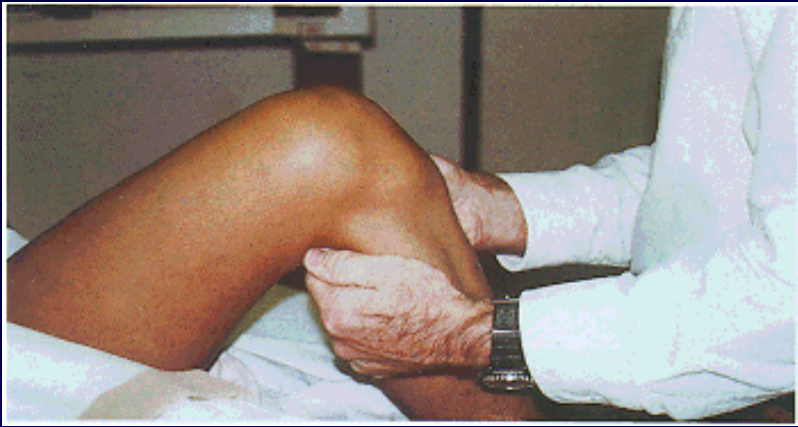- Klinické vyšetření
- Punkce kloubu
- Mastné skvrny v krvi
- RTG
- MRI
- Ultrasonografie



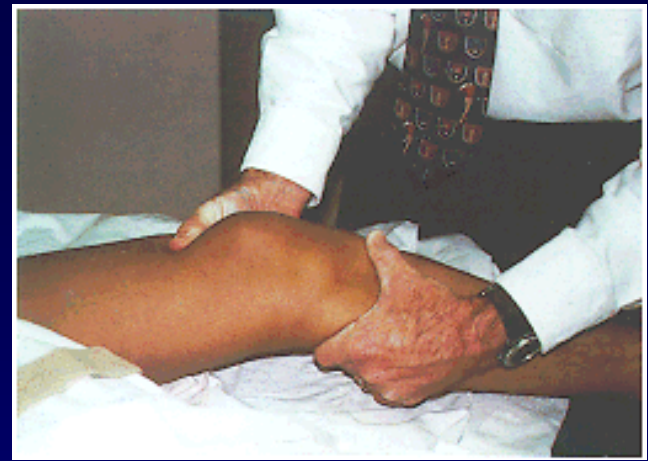# Klinické vyšetření

- Otok , hematom
- Výpotek
- Pohyb
- Palpační bolest
- Testy stability
- Manévry
- Vyšetření pately

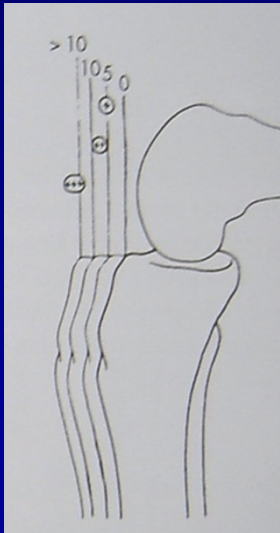




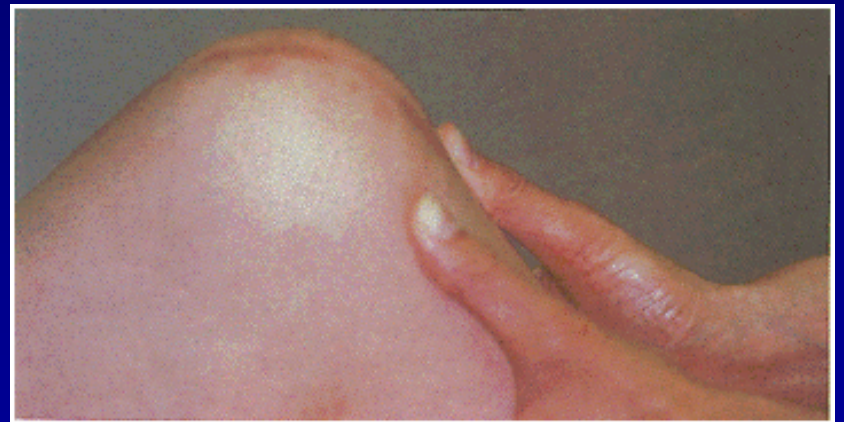Přední zásuvka



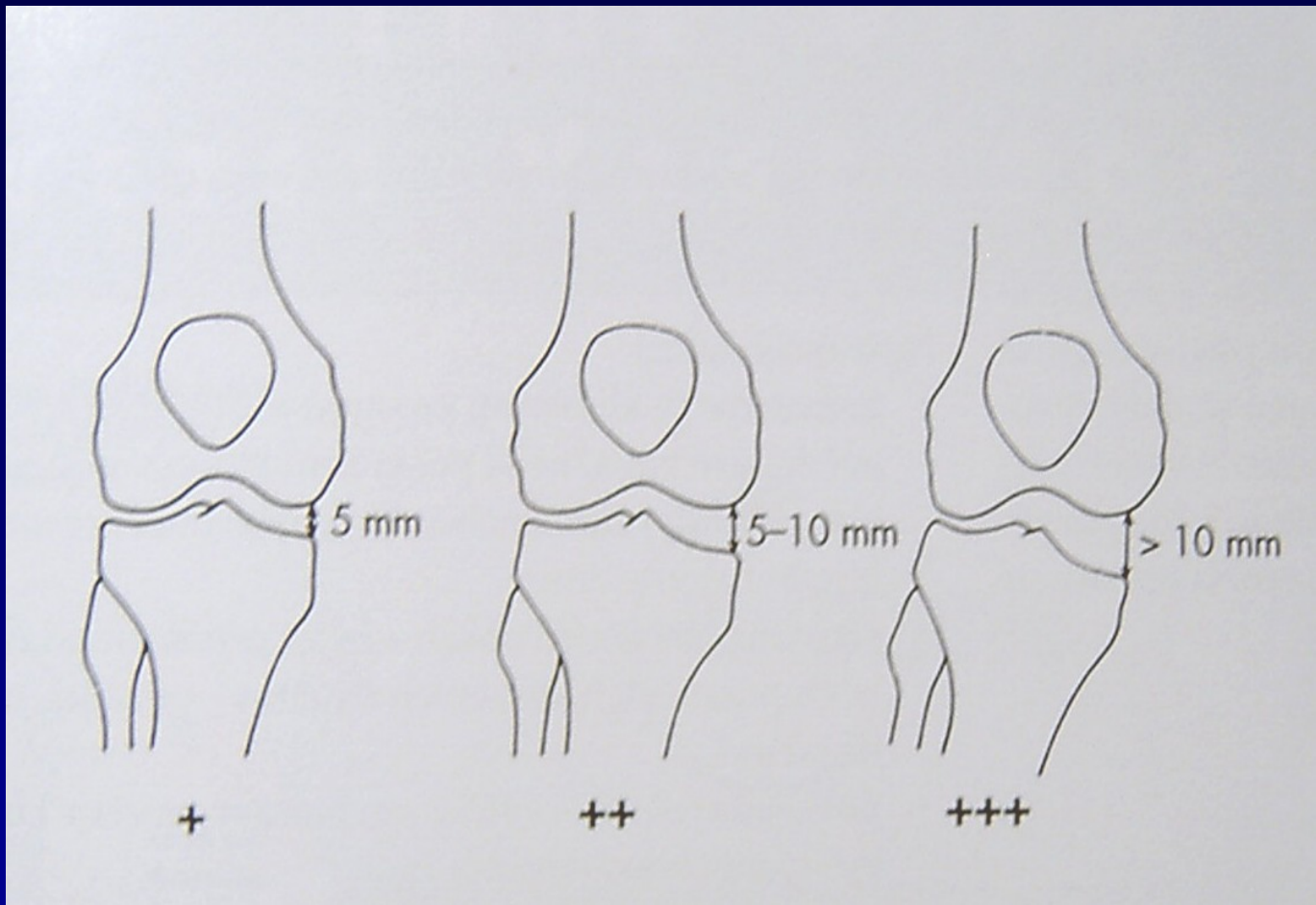
Lachmanův test



Přední zásuvka, pivot shift test



Zadní zásuvka



Valgóní stres test  
Varóní stres test

# Menisky

Mechanismus úrazu

Testy: Mc Murray

Steinmann I

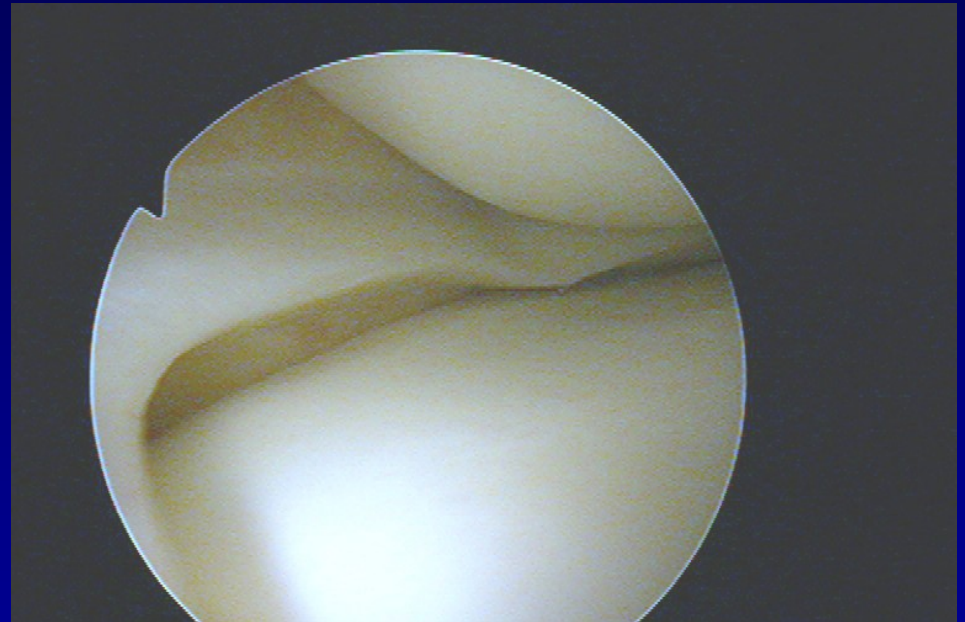
Steinmann II

Appley

Turner

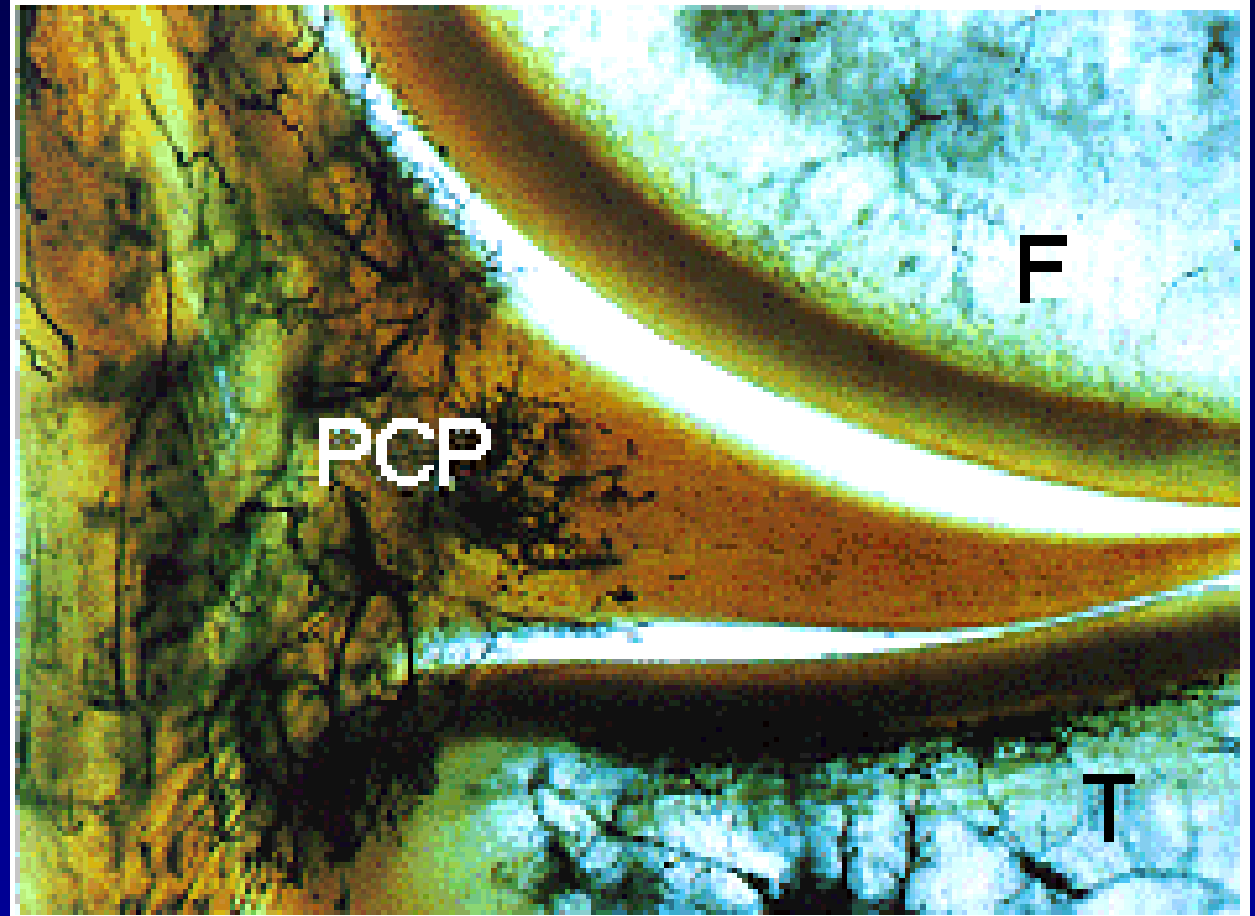
Payer

Childress- squat test



# Meniskus

- Fibrocartilago
- Vysoká elasticita
- Parakapsulární zóna- cévy

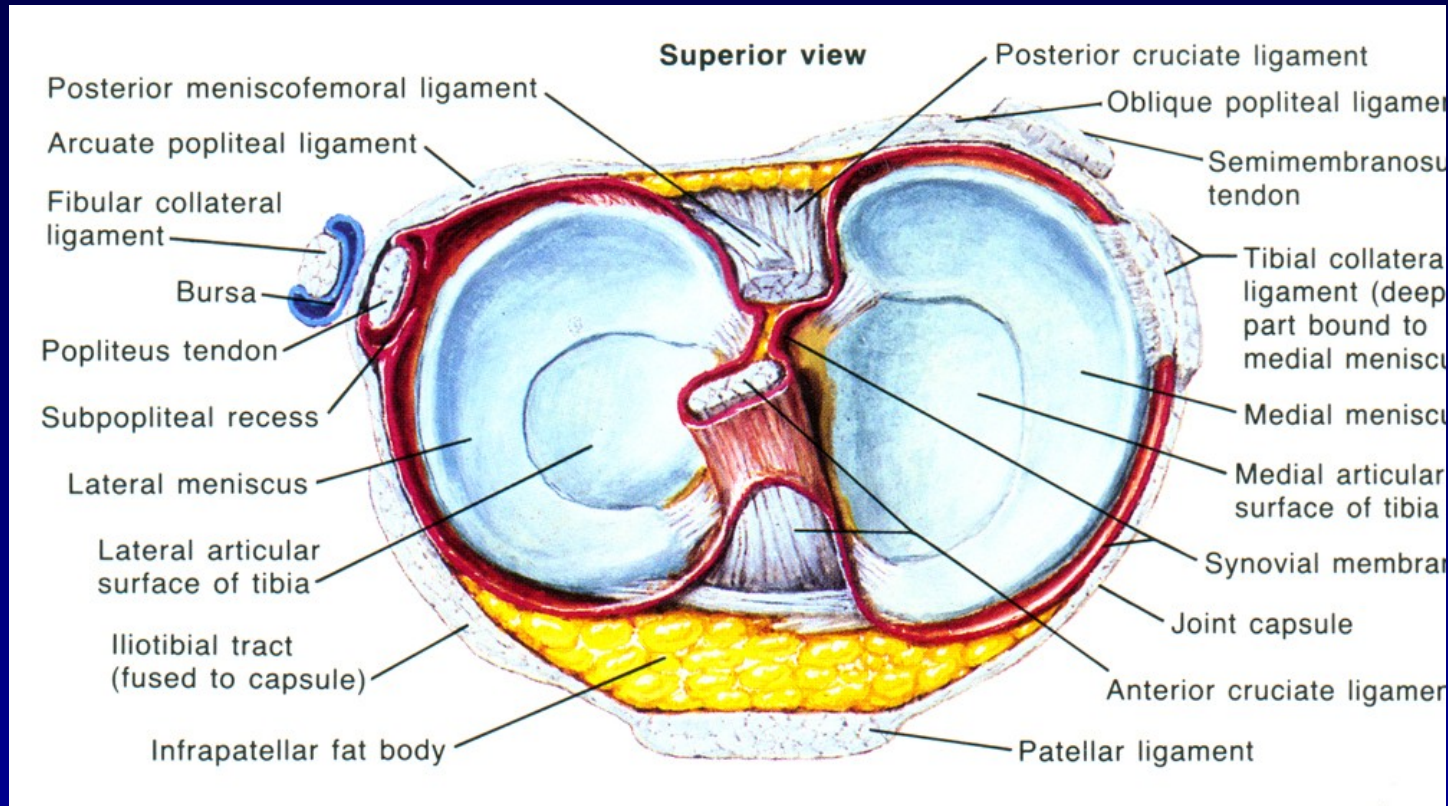


Red zone

red- white zone

white zone



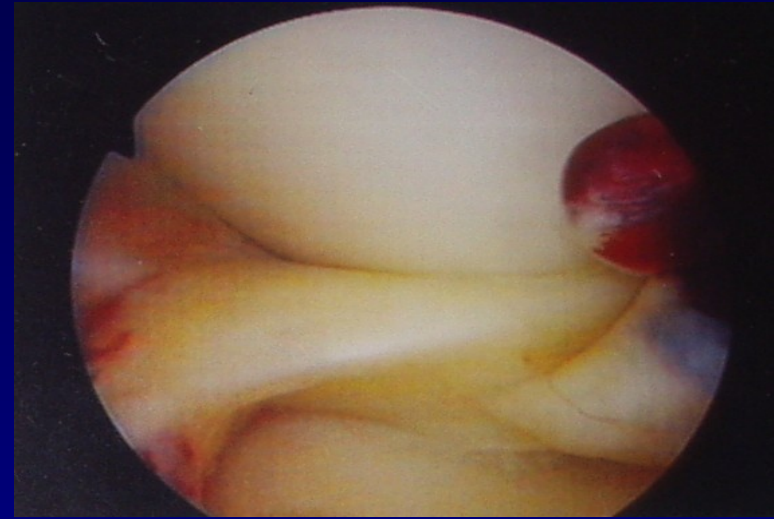
# Funkce



- nárazník
- stabilizátor
- vyrovnávač kloubních ploch
- rozdělovač kloubní tekutiny
- LM – mobilnější
- MM - zranitelnější

# Ruptury menisků

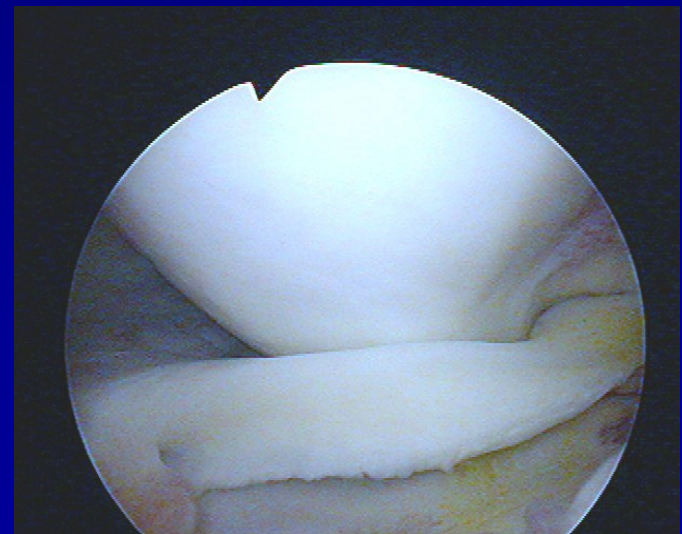
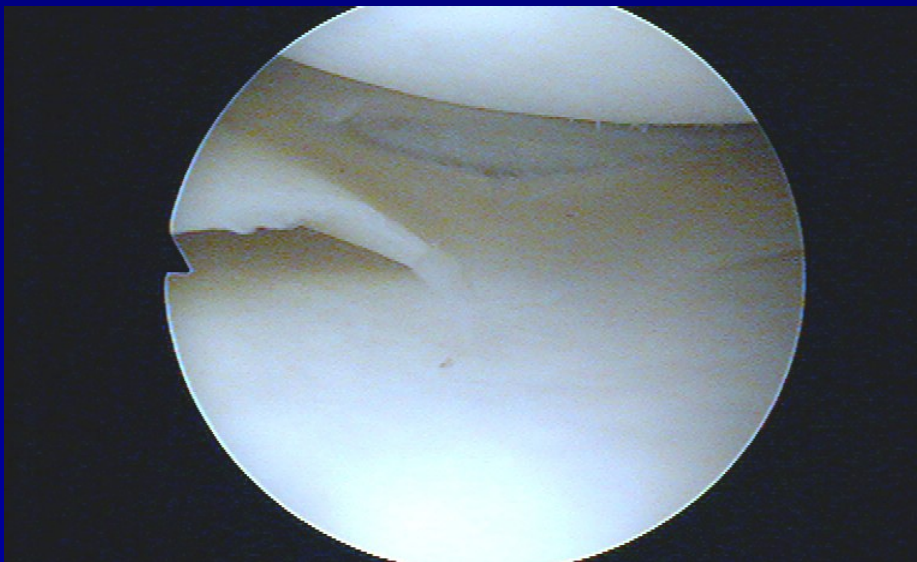
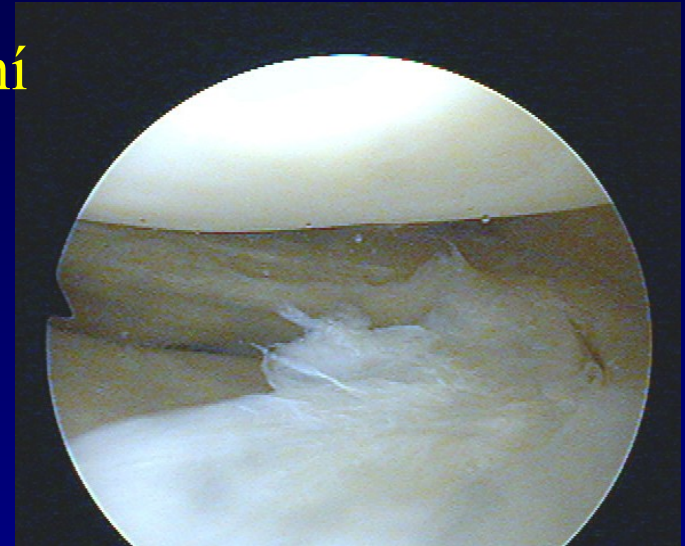
- Longitudinální, horizontální, radiální
- Typ ucho od koše
- Degenerativní léze
- Diskoidní meniskus





# Ruptury menisků

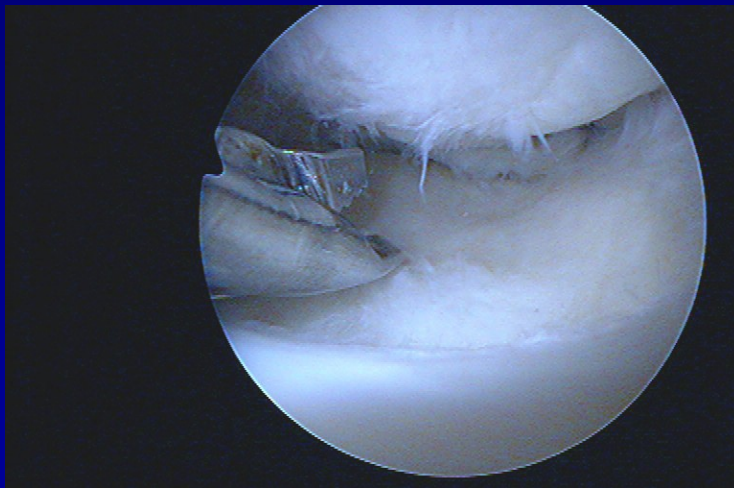
- Longitudinální, horizontální, radiální
- Typ ucho od koše
- Degenerativní léze
- Diskoidní meniskus



# Ošetření menisků

## Menisektomie

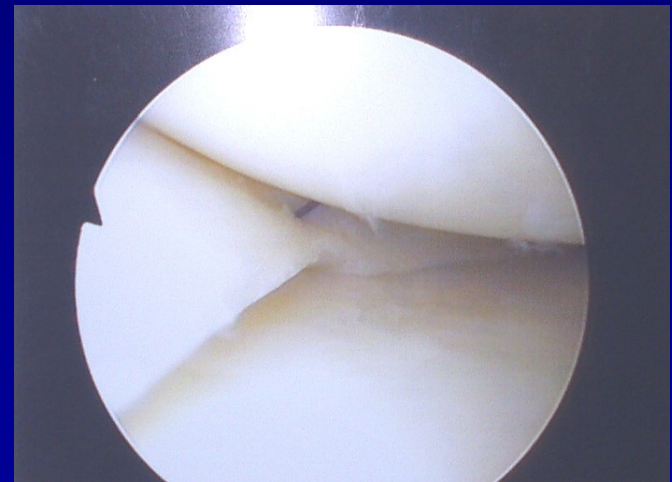
- parciální
- subtotální
- totální



**Punch „v akci“**

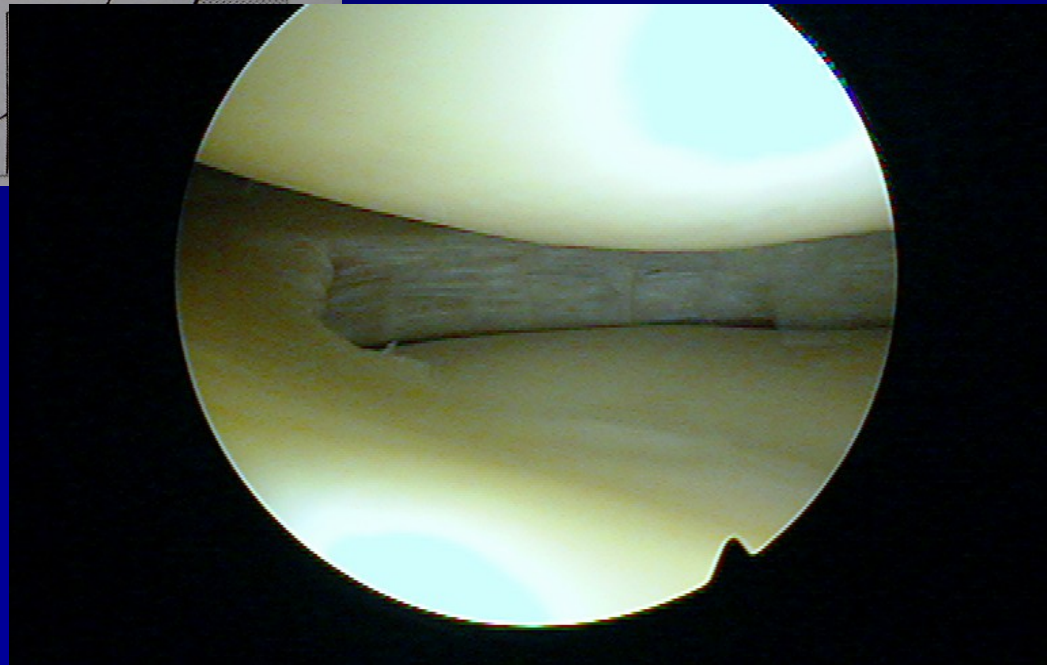
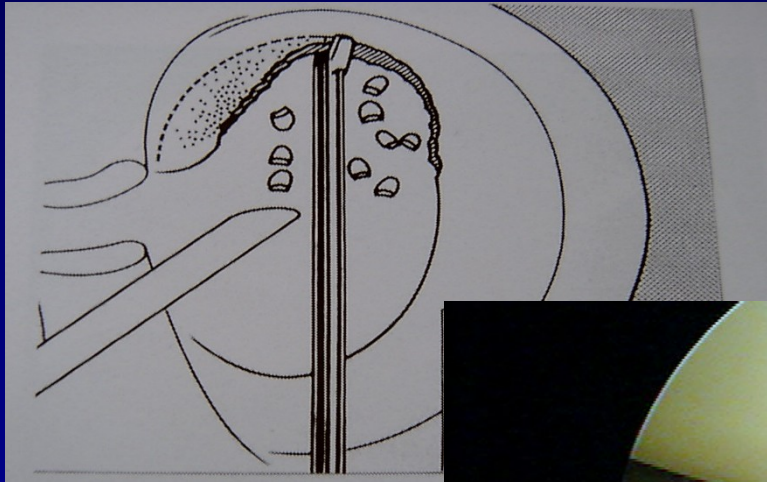
## Meniskopexe

- outside-in
- inside-out
- all-inside

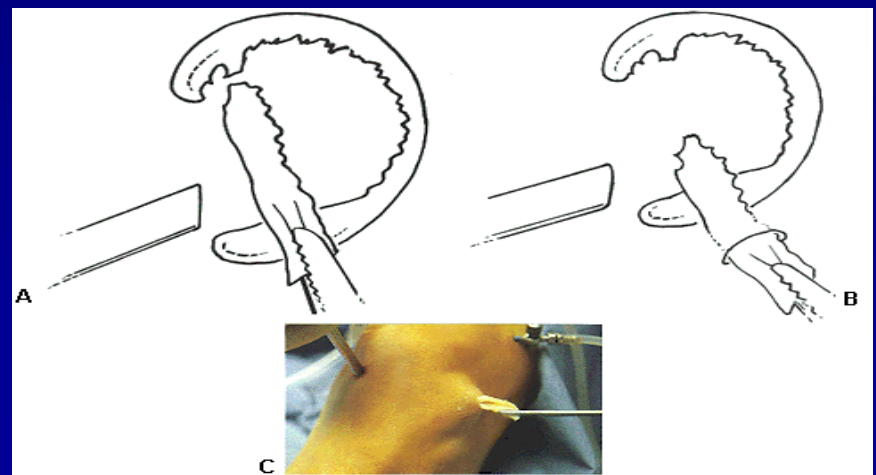
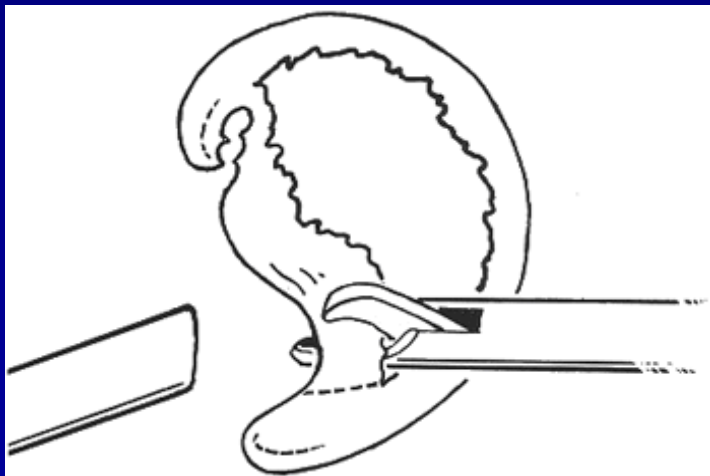
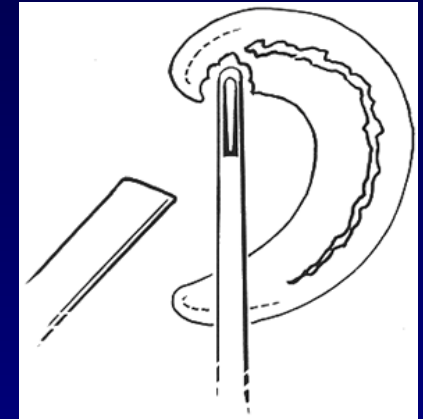
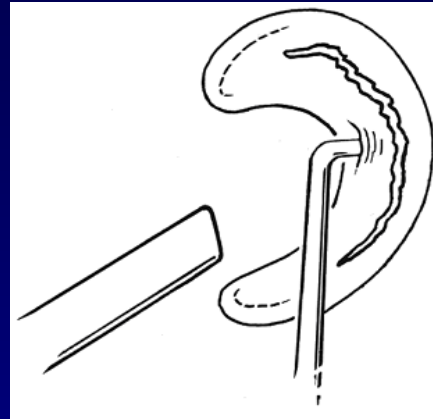
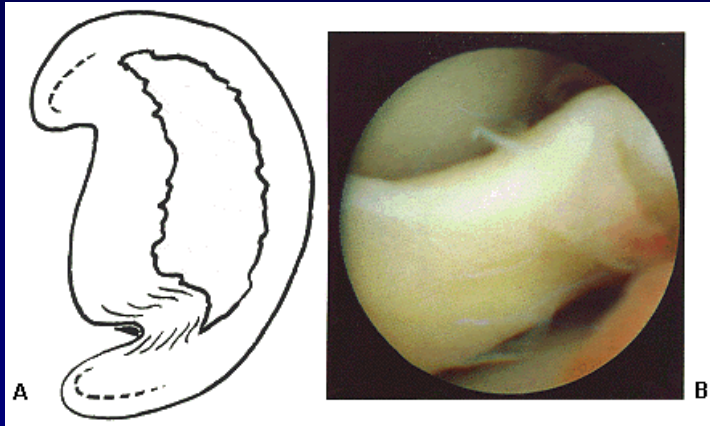


**Přišitý meniskus**

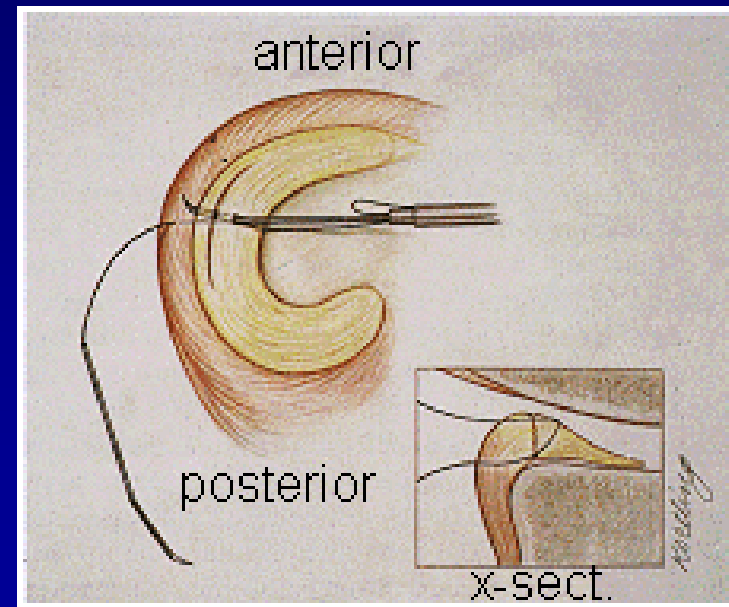
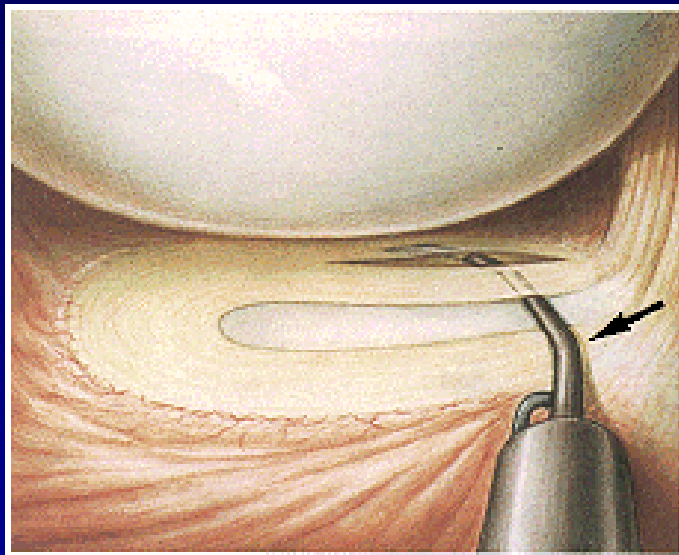
# Parciální menisektomie



# Subtotální menisektomie



# ASK meniskopexe

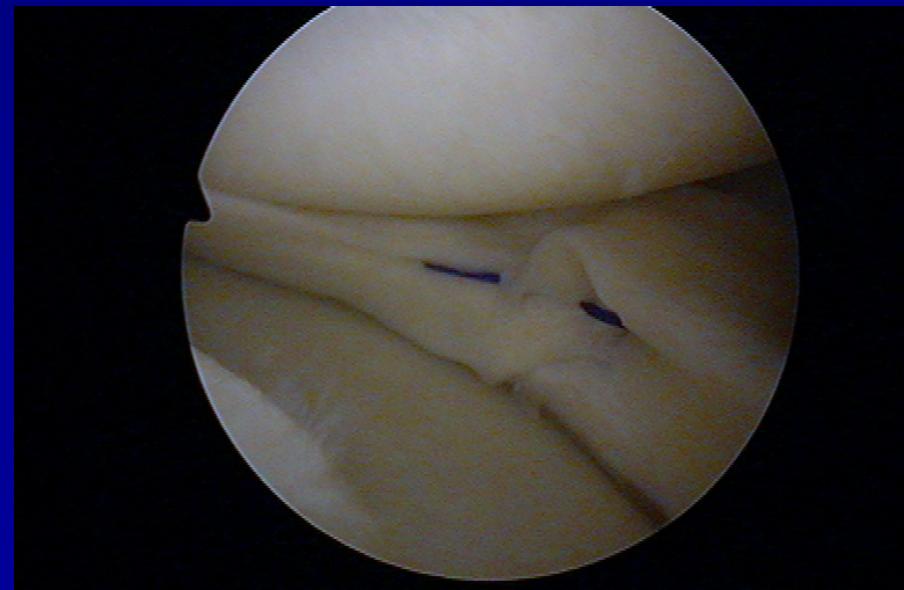
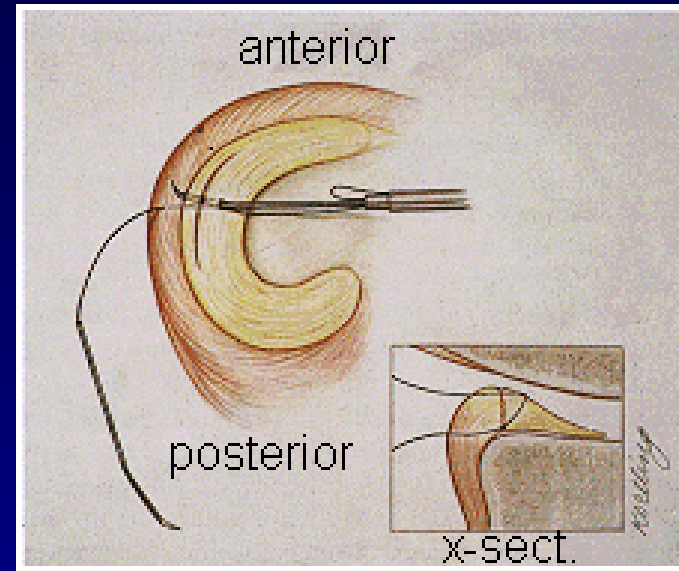


# Sutura menisku- meniscopexis

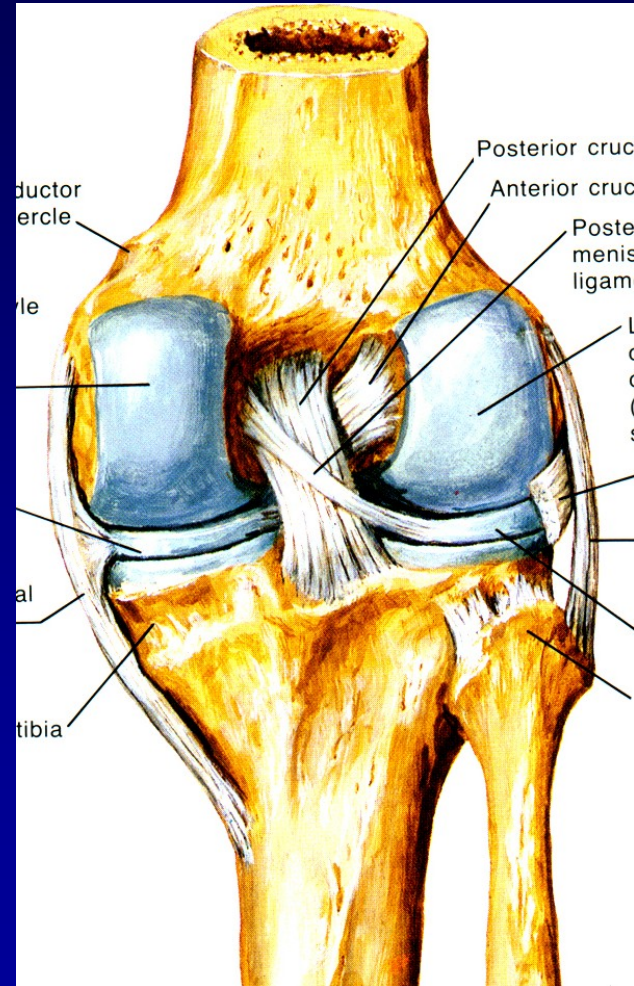
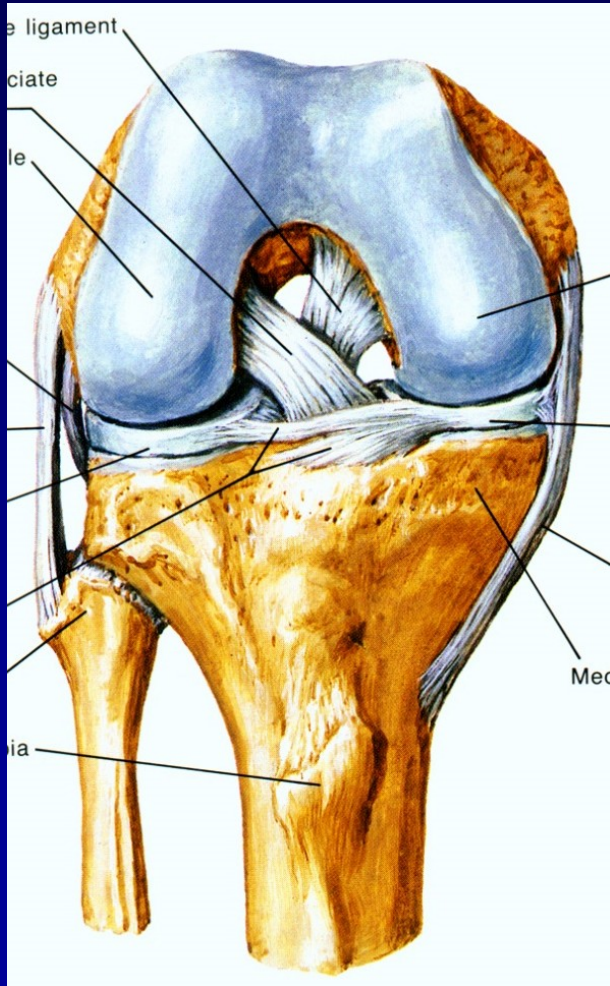
outside-in

inside-out

all-inside

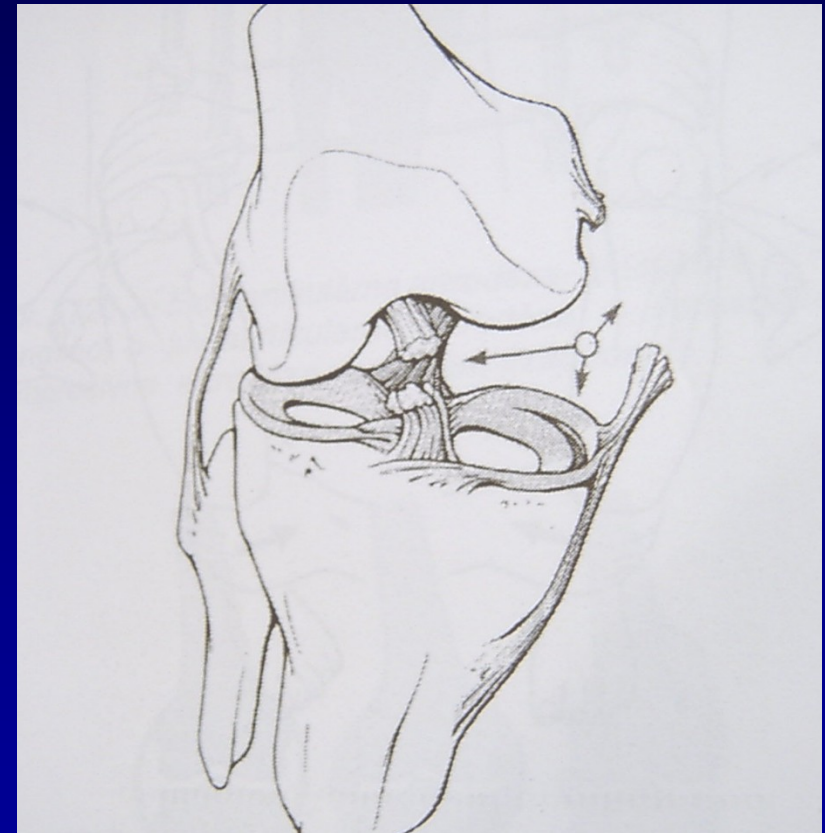

# Zkřížené vazy- ACL, PCL



# Ruptury vazů

- **Distenze**
- **Parciální ruptura**
- **Totální ruptura**
- Mechanismus poranění
- Testy stability

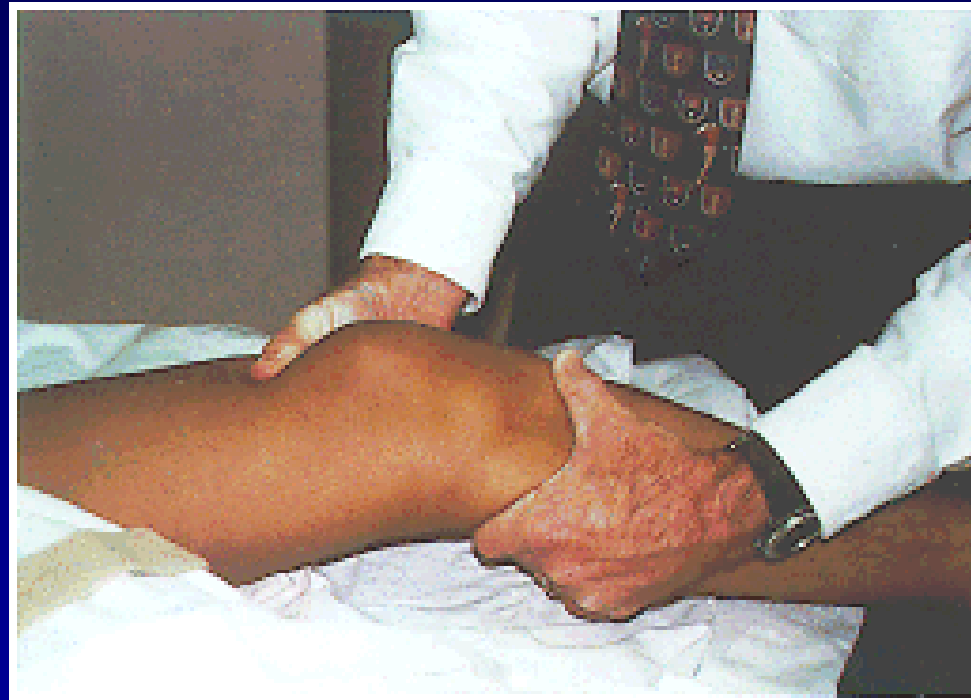


„Unhappy trias“



# Ruptura ACL

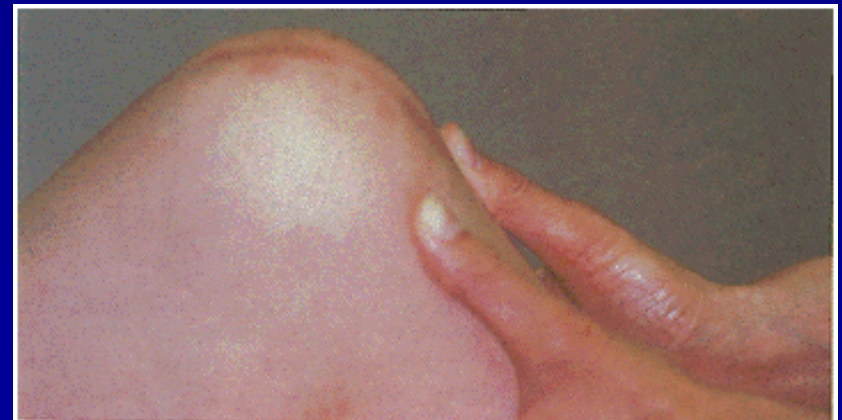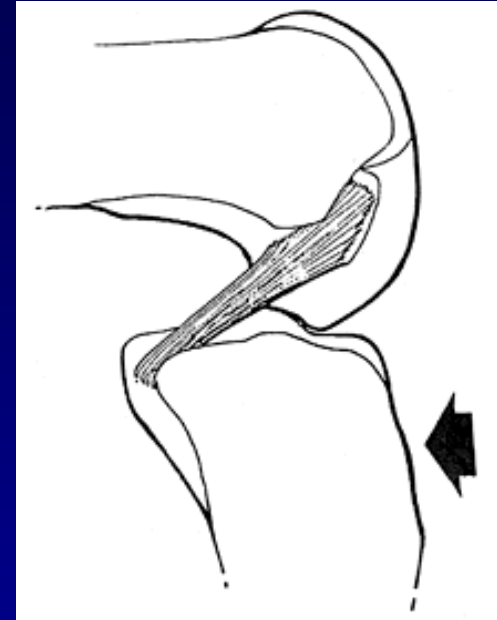
- Testy stability
- Lachmanův test
- Přední zásuvka
- Pivot-shift test



Lachman test

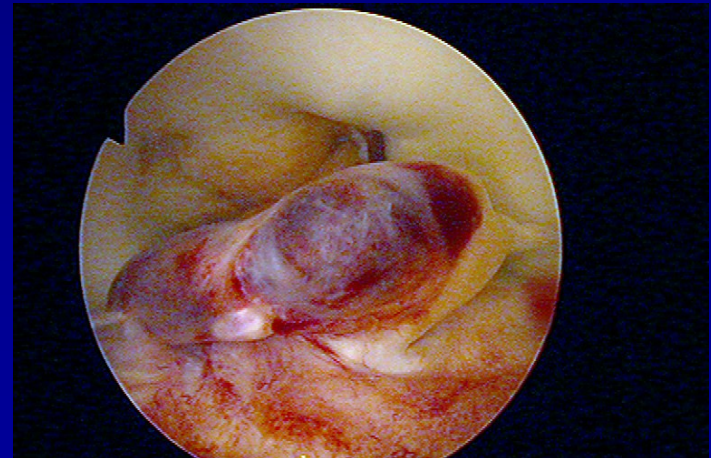
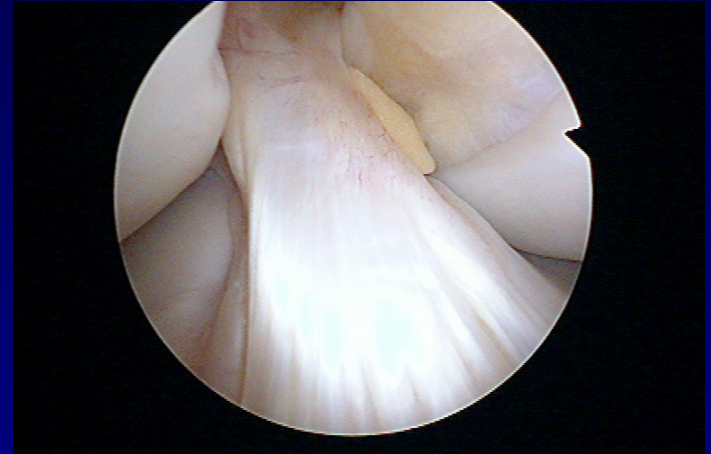# Rupture PCL

- Náraz na palubní desku
- Zadní zásuvka



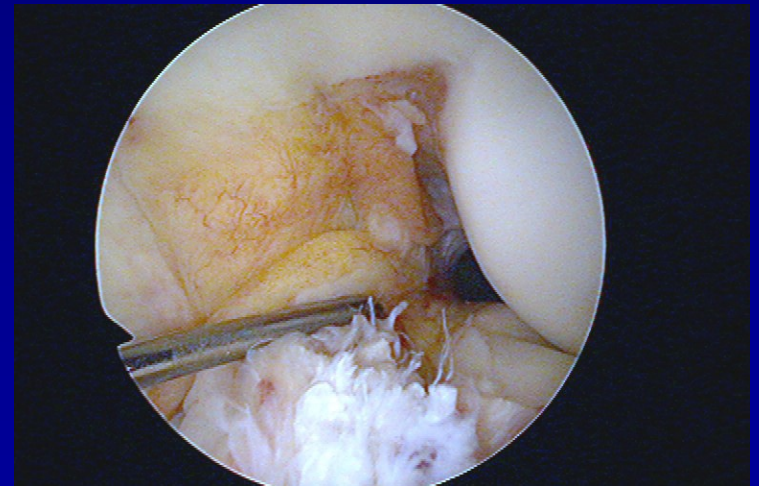
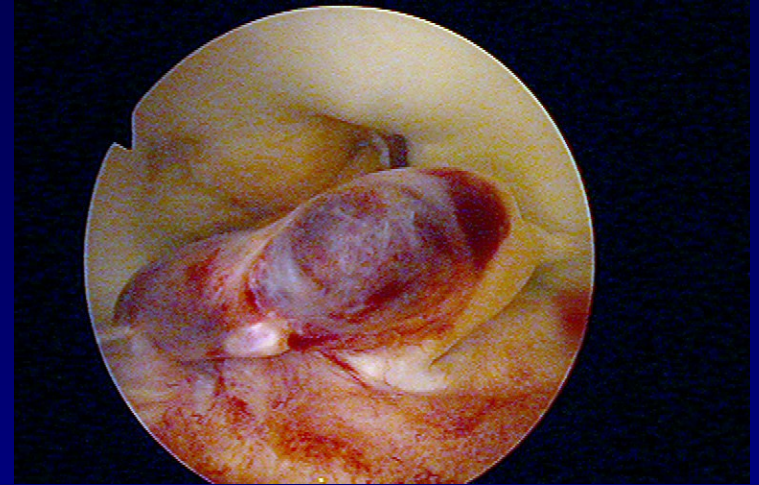
# Rupture ACL

- Časté poranění



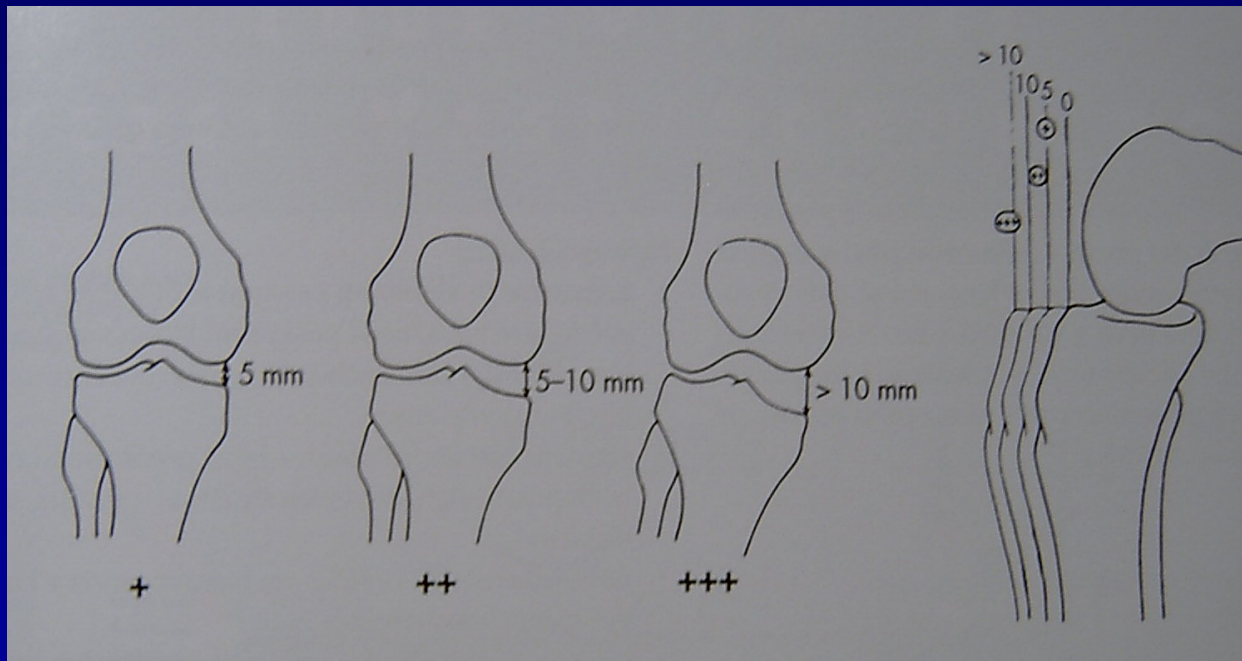
# Akutní ruptura ACL

- Debridement
- Fyzioterapie
- Omezená aktivita
- Ortéza



# Instabilita anteromediální

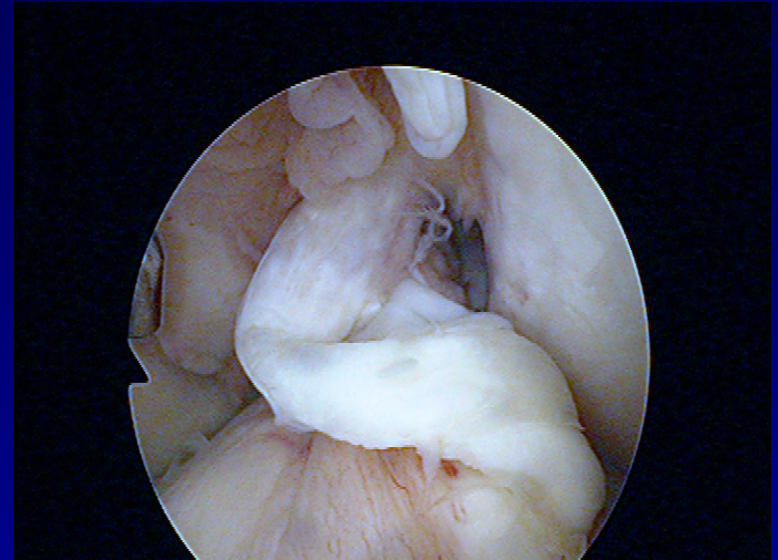
- v praxi nejčastější typ instability kolena
- následek páčení do valgozity – unhappy trias



valgus stress test + přední zásuvka

# Indikace k rekonstrukci

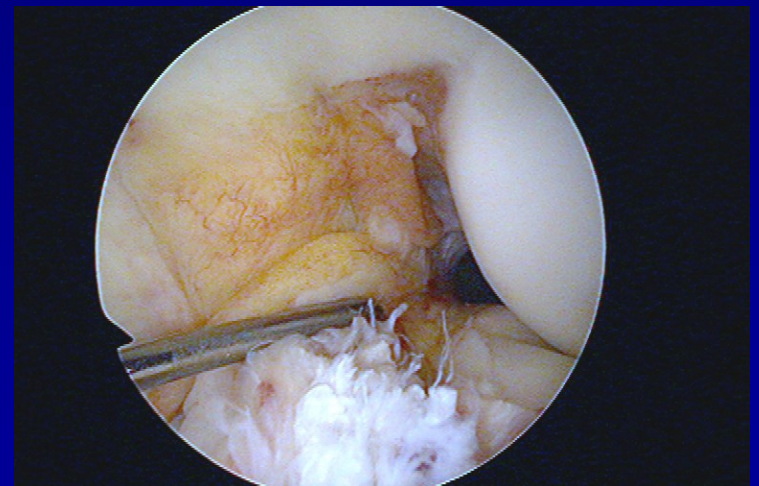
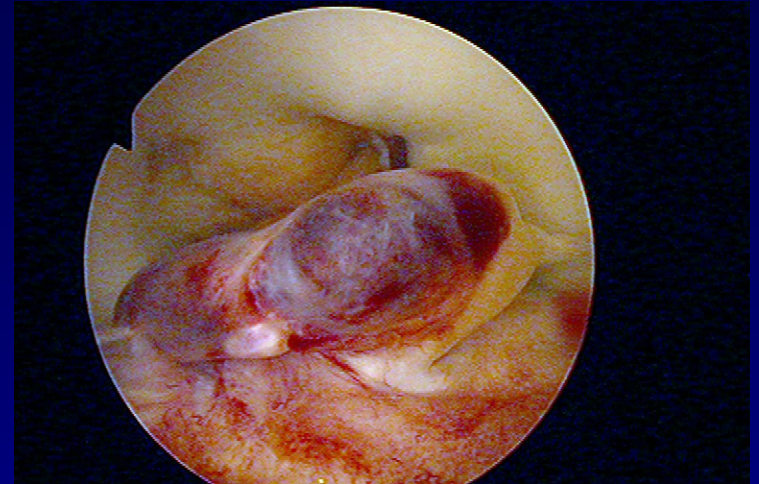
- 1/3 kompenzovaná i na sport
- 1/3 kompenzovaná jen po modifikaci sport. aktivit
- 1/3 nutnost rekonstrukce PZV



⇒ individuální přístup k pacientovi

# Akutní ruptura PZV

- **Artroskopie**
  - debridement PZV
  - ošetření přidružených poranění (menisků, chrupavek)
- **Pooperační režim**
  - RHB program - hamstringy
  - propriocepce
- **Modifikace sport. aktivit**
  - omezení rizikových sportů
  - ortéza



# Rehabilitace

- dynamická stabilita kolene s poškozeným PZV
- reedukace reflexních mechanismů

↓ absolutní síla hamstringů

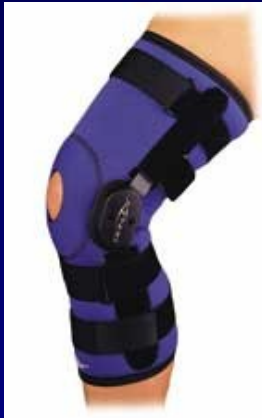↑ propriocepce



RHB → closed kinetic-chains cviky



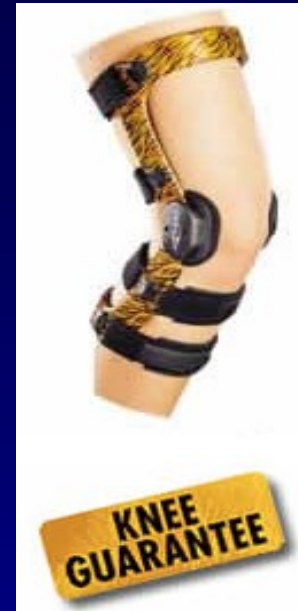# Kolenní ortézy



postranní výztuhy



skořepinové



individuální

- proprioceptivní mechanismy
- psychologický efekt

# Rekonstrukce PZV ve II. době

- selhání konzervativního postupu

## **výhody:**

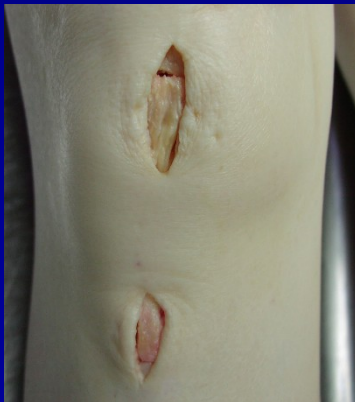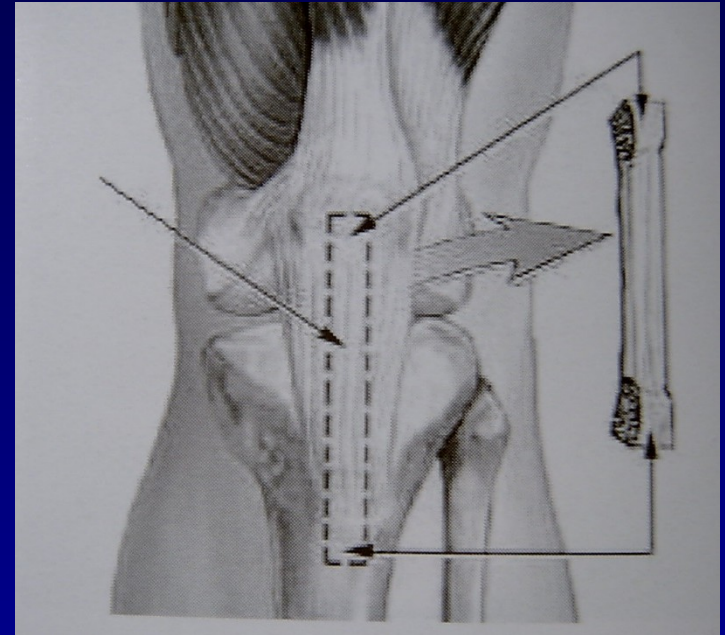
- motivovaný, spolupracující pacient, který má realistické představy o operaci, čas na RHB
- koleno s plným pohybem bez hypotrofie stehenního svalstva = **předoperační RHB**

# Typy štěpů a fixace

- štěp z kadaveru
- autoštěp – vlastní tkáň
- štěp z lig. patelae /BTB/
- šlachy hamstringů
- fixace titanovými nebo vstřebatelnými materiály
- press-fit fixace

# BTB štěp = zlatý standard

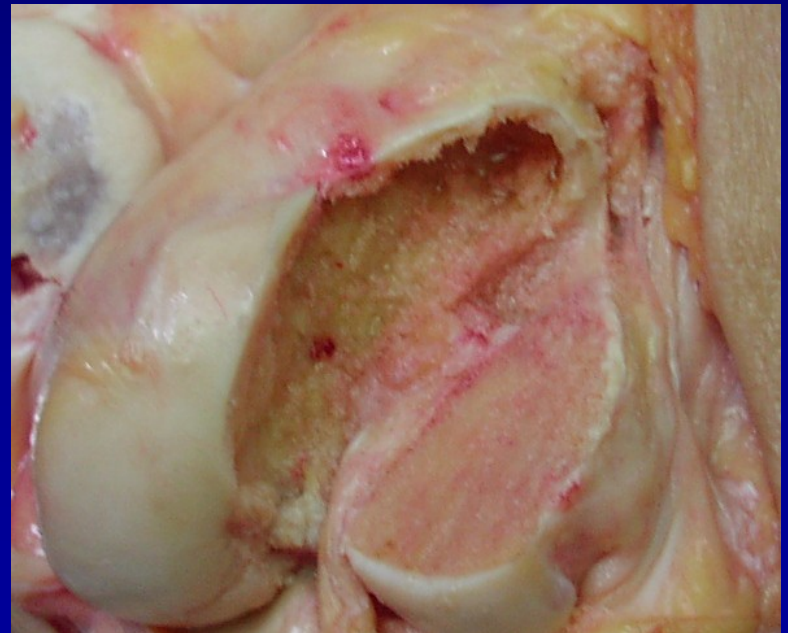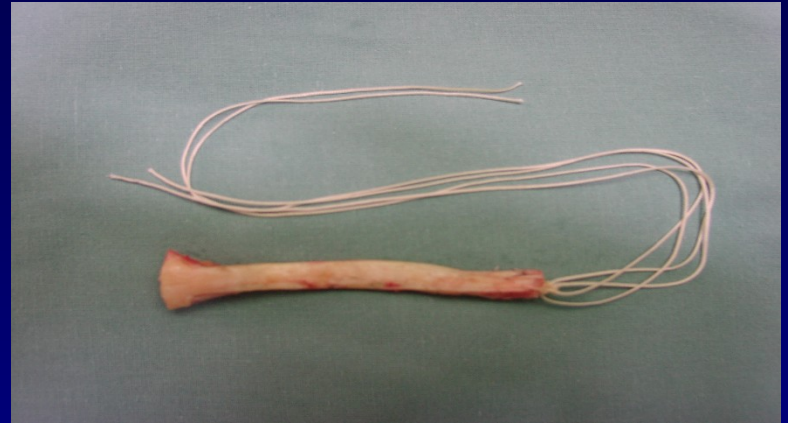
- **Bone-Tendon-Bone**
- autoštěp ze střední třetiny ligamentum patellae
- vhojení kostních bločků
- potíže z odběrového místa



- **miniincize** - šetří r. infrapatellaris n. sapheni

# BTB štěp pro **press-fit** fixaci

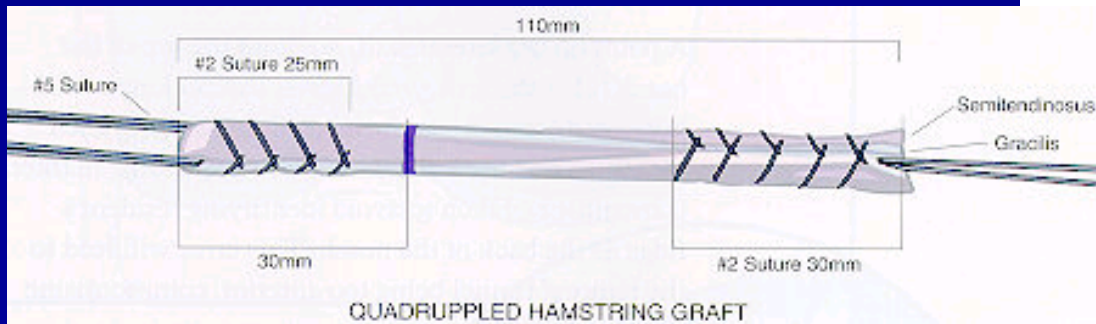
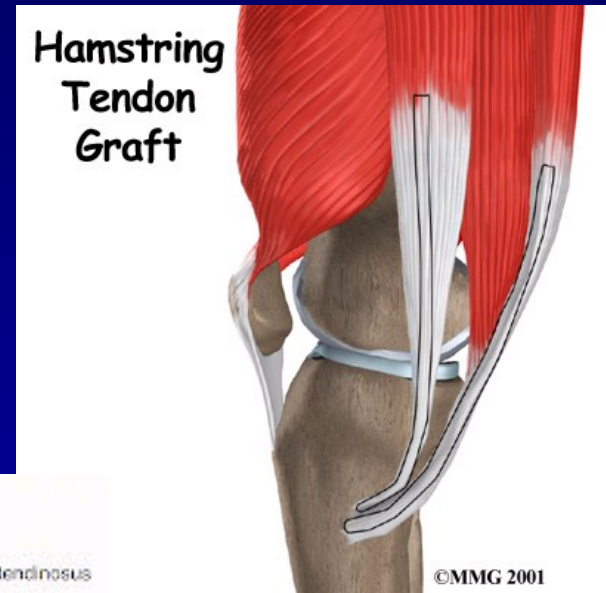
- proximální konec na řezu **lichoběžníkový tvar**
- **press-fit** fixace v **zužujícím se** femorálním kanálu



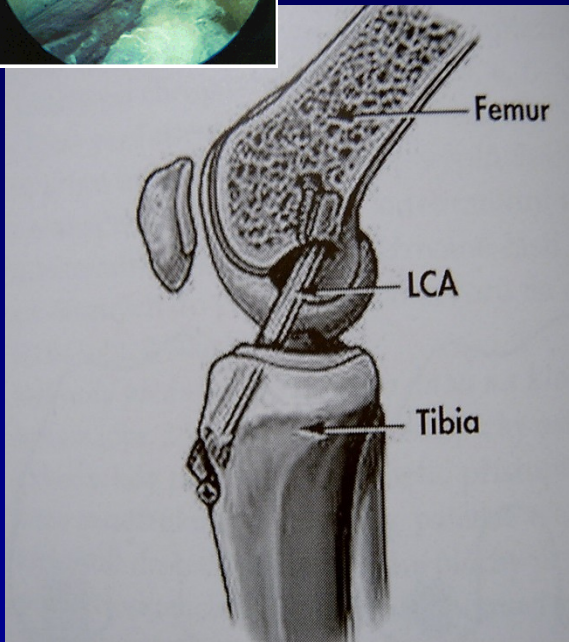
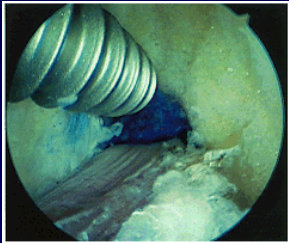
# Hamstringy

(m. semitendinosus + m. gracilis)

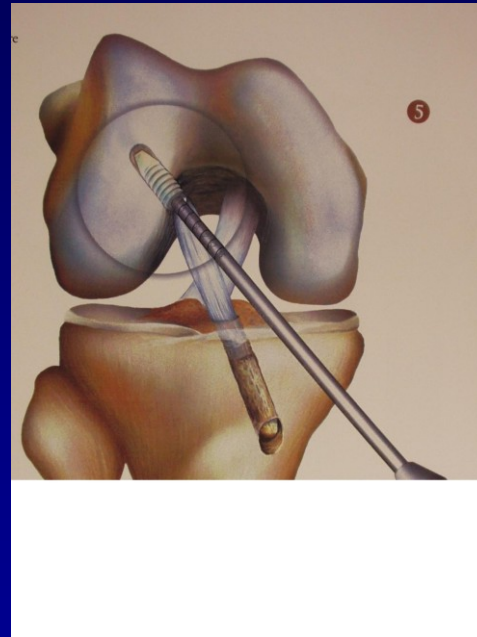
- nejsou potíže z odběrového místa
- oslabení flexorů
- častější selhání
  - B-T-B **1,9 %**
  - hamstringy **4,9%**



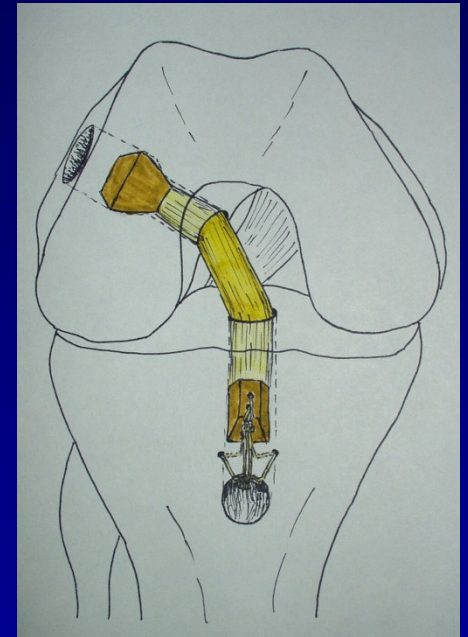
# Fixace štěpu



interferenční šroubky



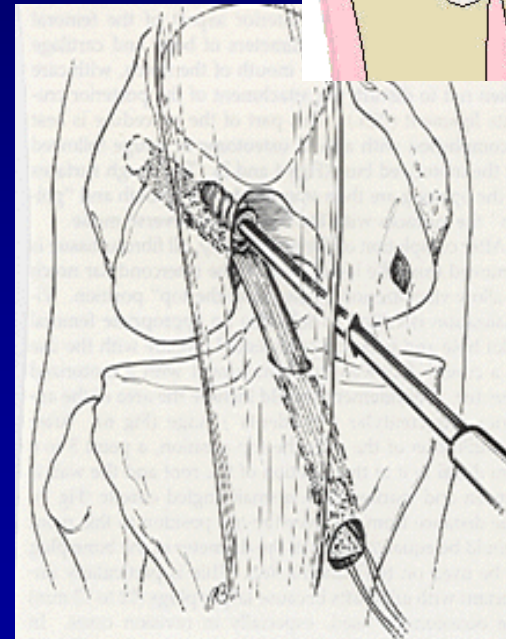
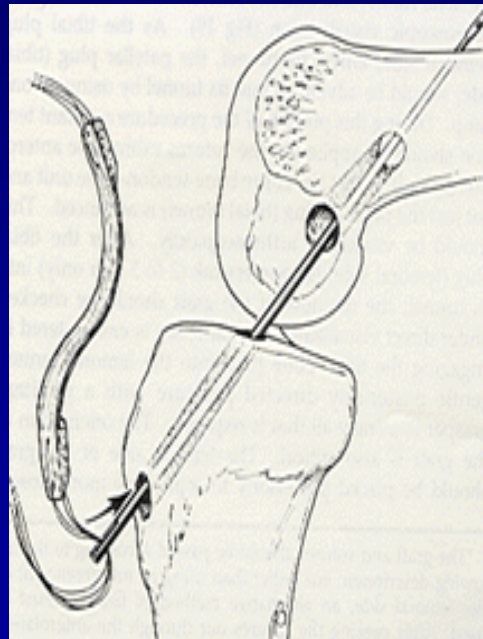
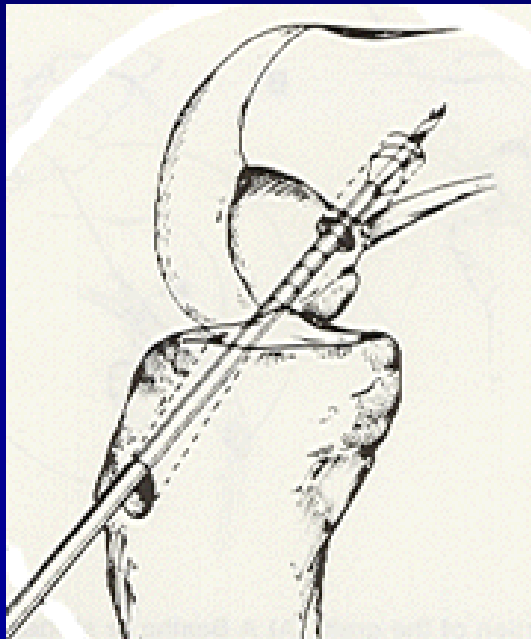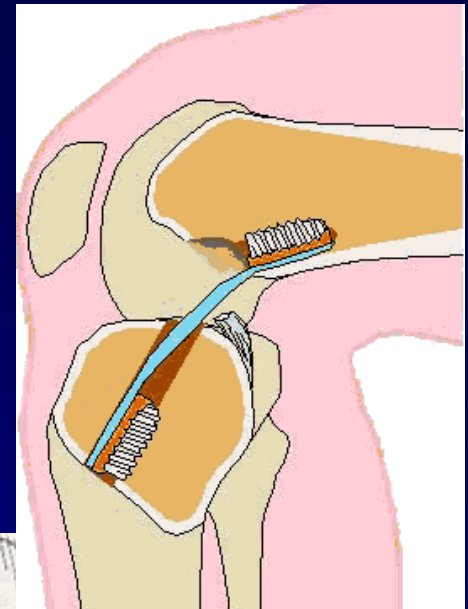
vstřebatelné klínky



press-fit

# Techniky operace

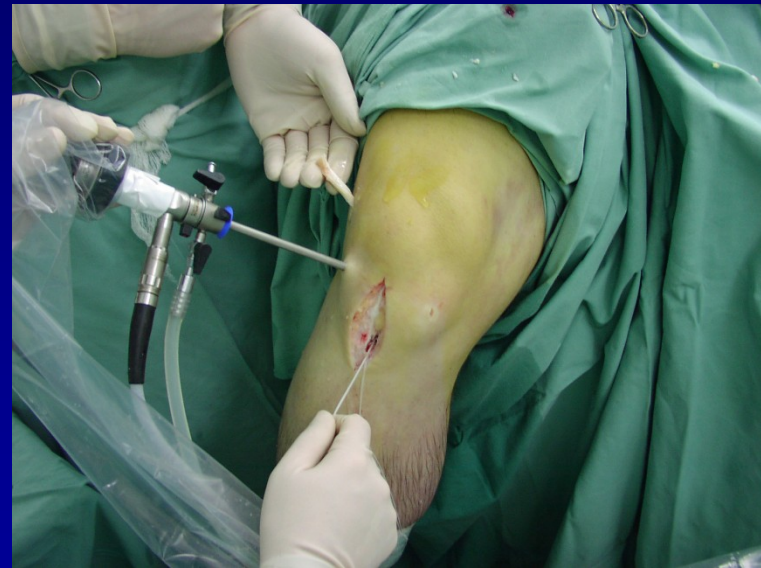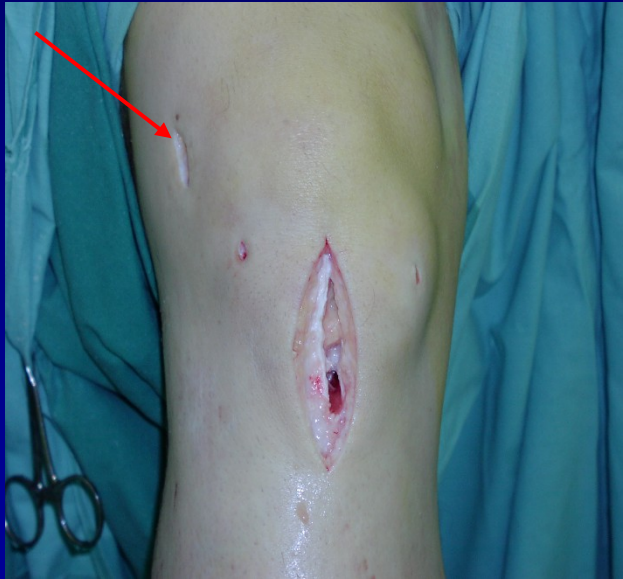- **transtibiální techniky** - štěp se protahuje přes T kanál do F kanálu



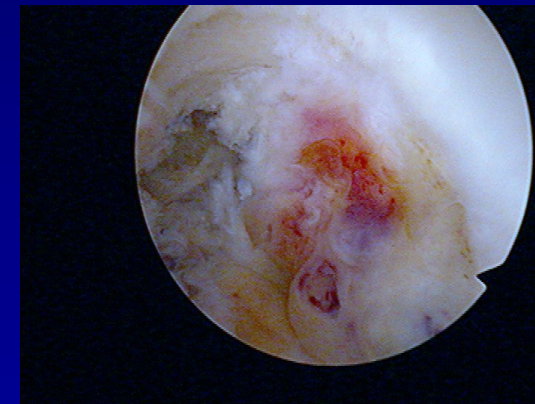
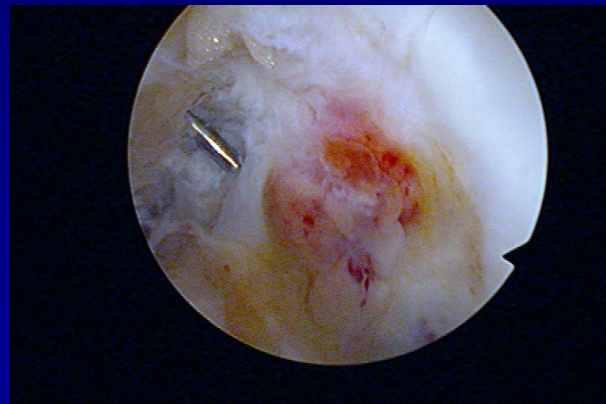
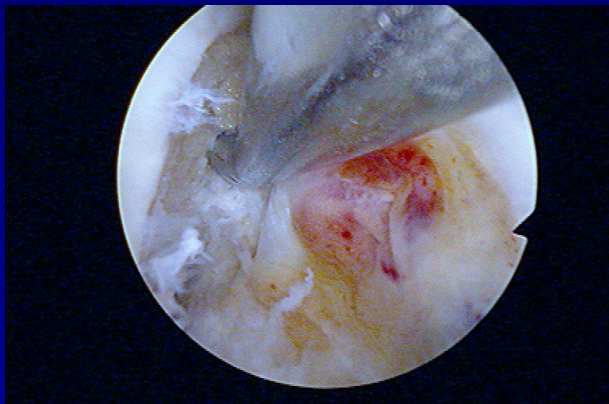
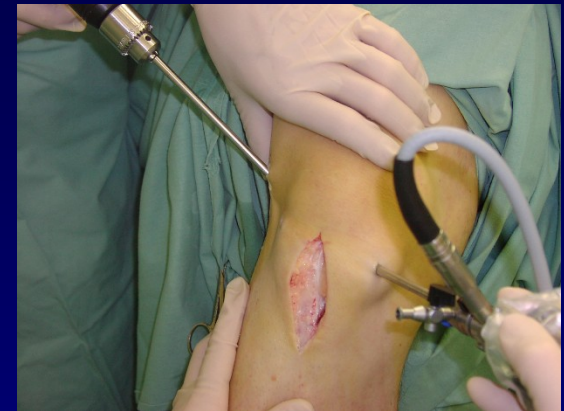
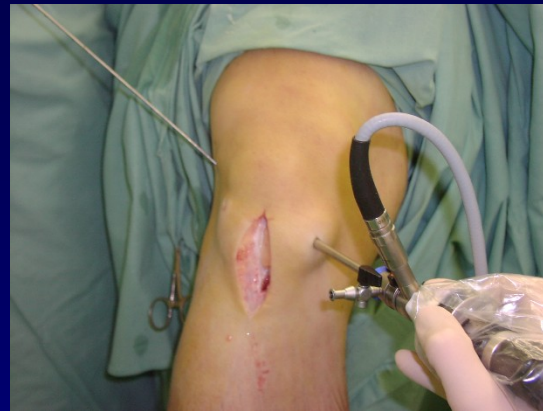
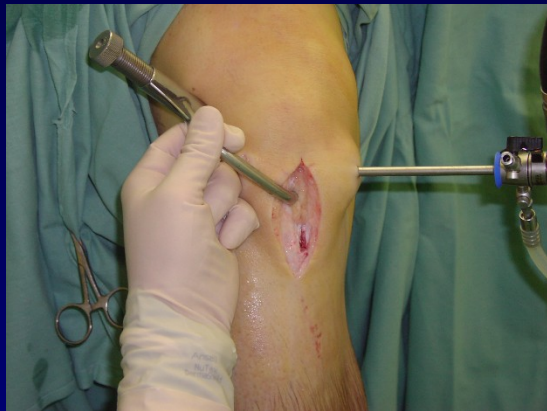# Techniky operace

- s pomocnou laterální miniincizí - štěp se protahuje přes F kanál do T kanálu

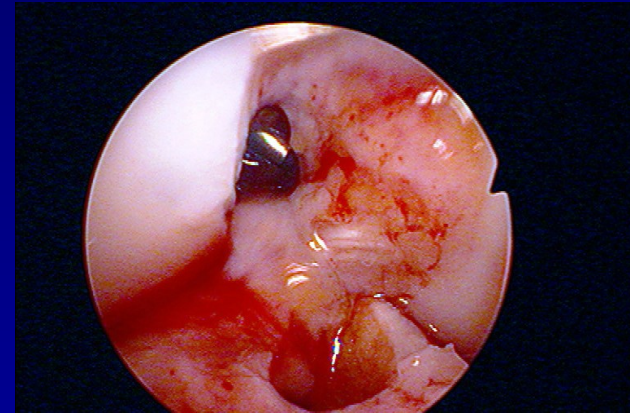
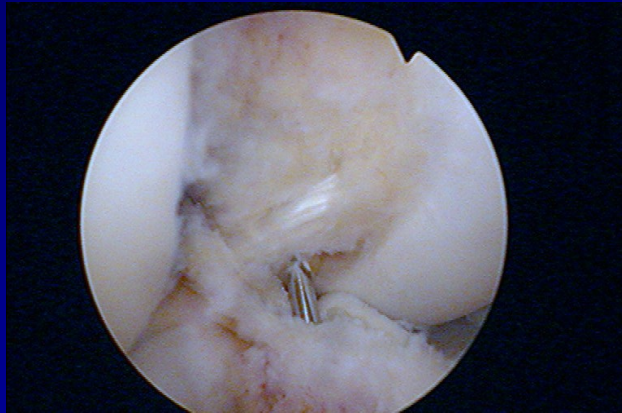
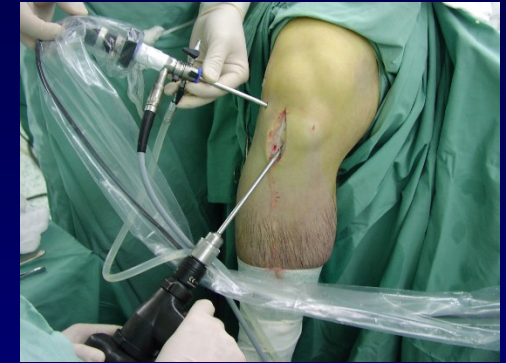
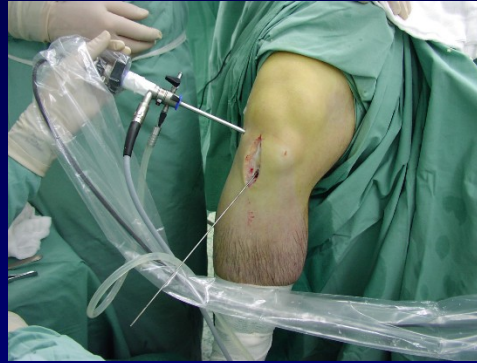
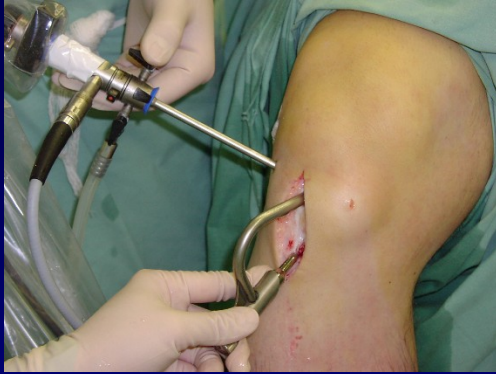# Femorální kanál



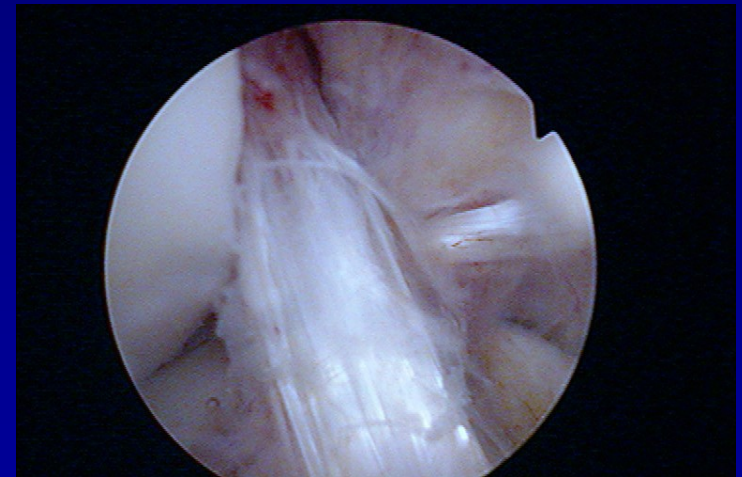
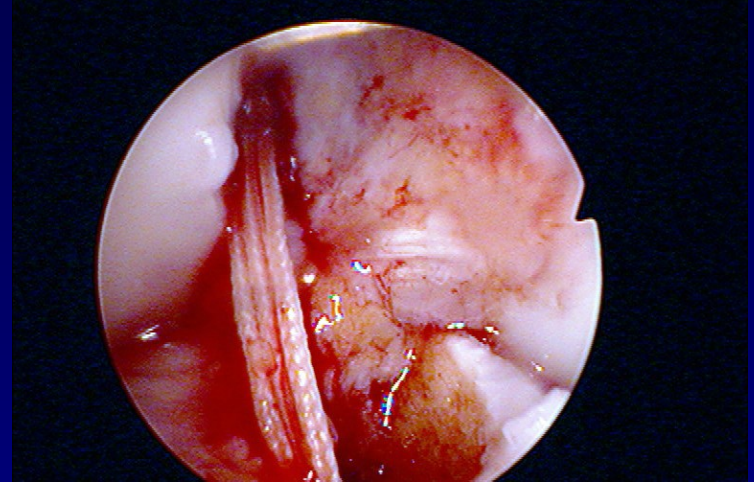
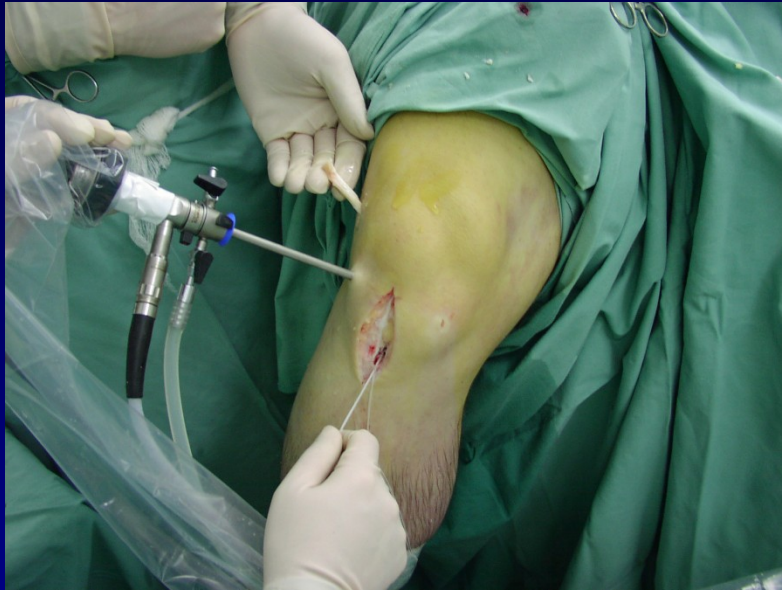femorální cílič + vrtání femorálního kanálu pod  
ASK kontrolou

# Tibiální kanál



tibiální cílič + vrtání tibiálního kanálu pod ASK  
kontrolou

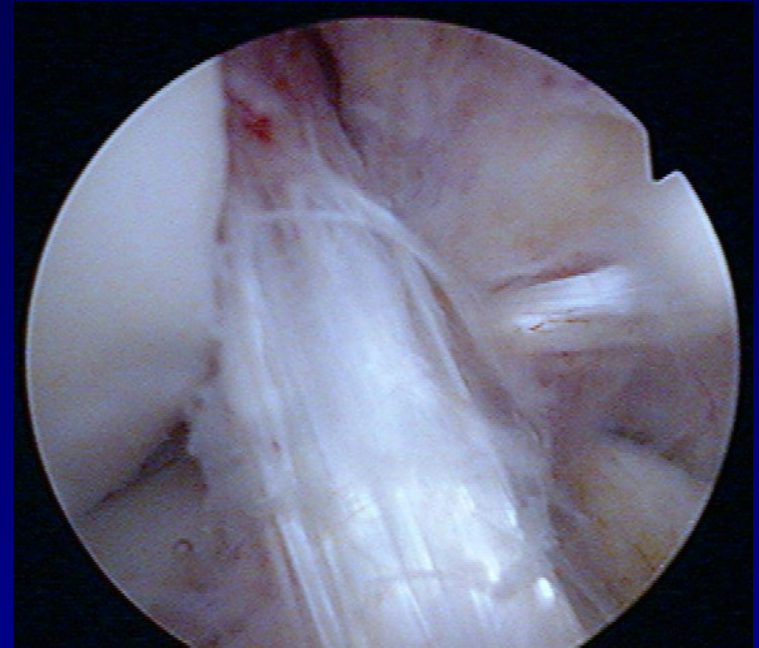
# Protažení štěpu



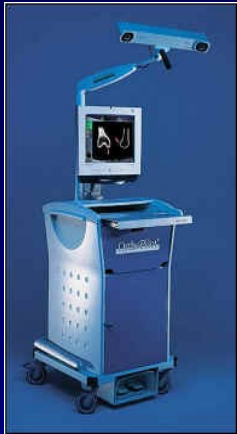
- protažení vláken nejprve přes femorální kanál a poté přes tibiální kanál
- protažení štěpu tahem za vlákna pod ASK kontrolou

# REHABILITACE

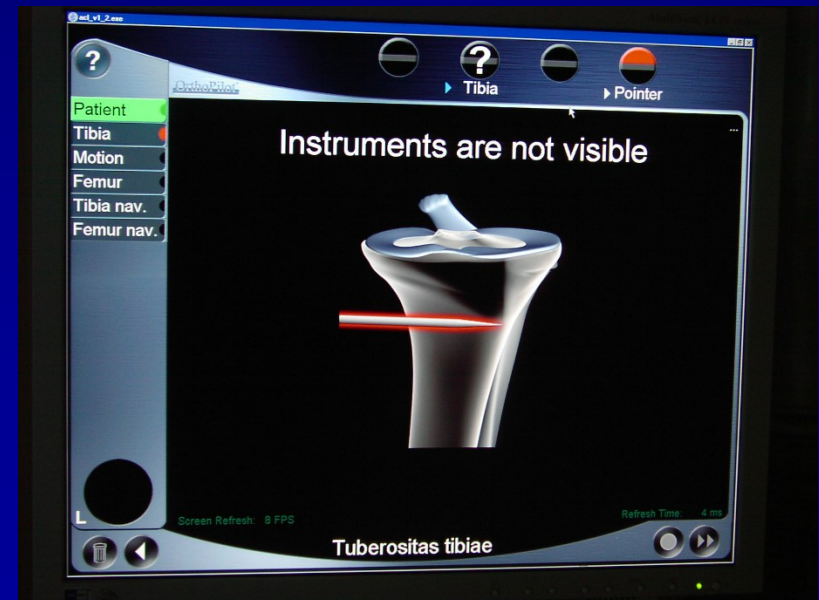
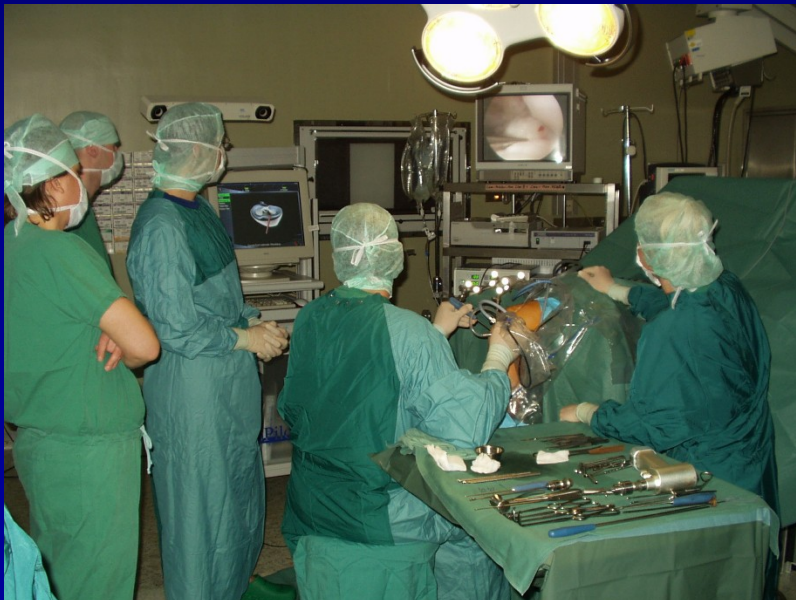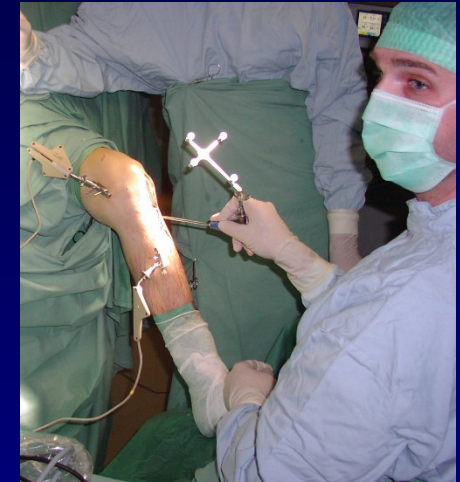- pooperační **RHB protokol**
  - ortéza 0-30 st.
  - pohyb ihned po operaci
  - polohování do plné extenze
  - 6 týdnů dlouhá ortéza s kloubem
  - revaskularizace štěpu = přestavba
  - **rizikové sporty až za 8 - 10 měsíců**



# Navigace při rekonstrukci PZV

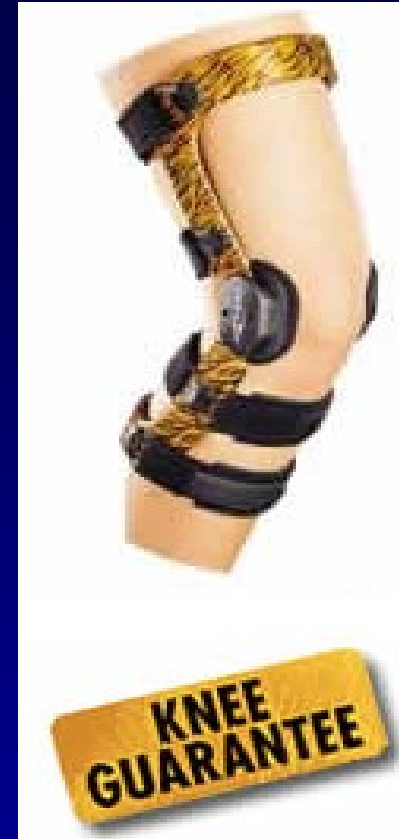

- infračervené sondy + kamera
- kinematický model, extrapolace
- navigace = cílení kanálů
- izometrická rekonstrukce





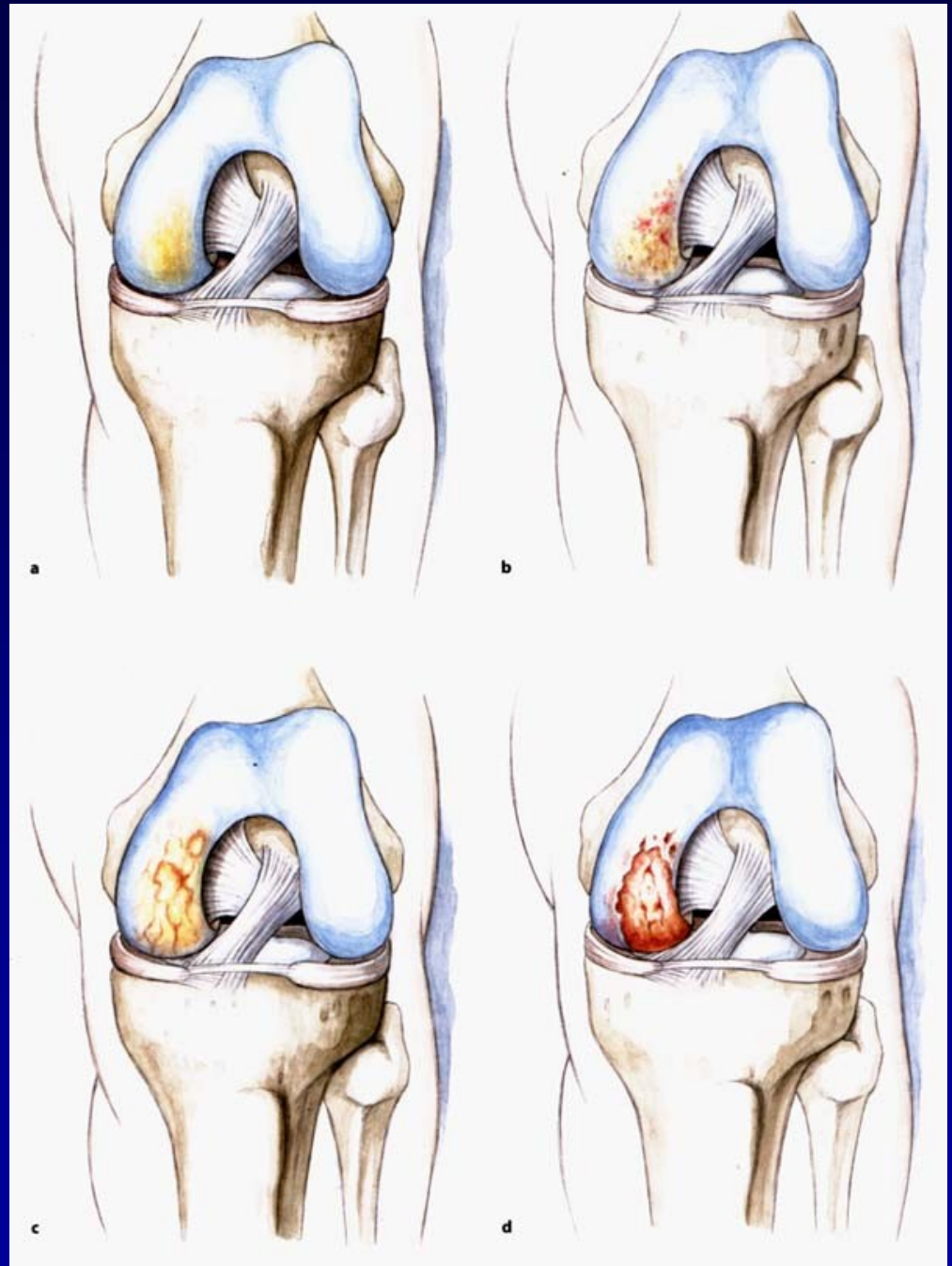
Fyzioterapie



Ortéza

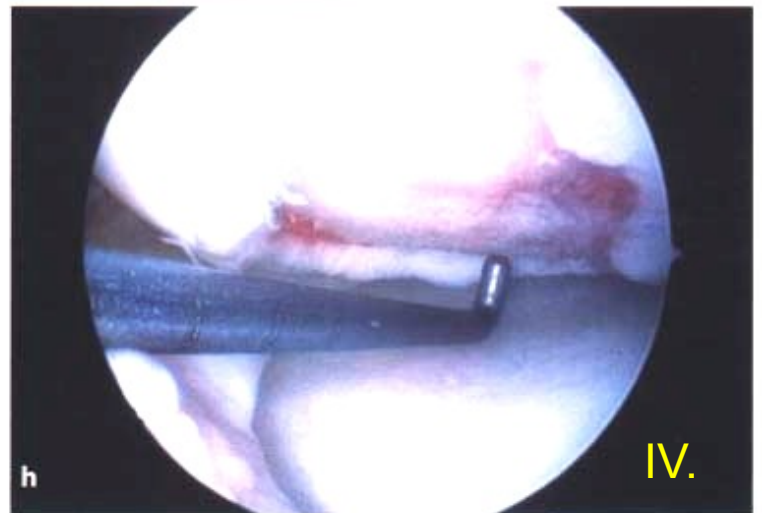
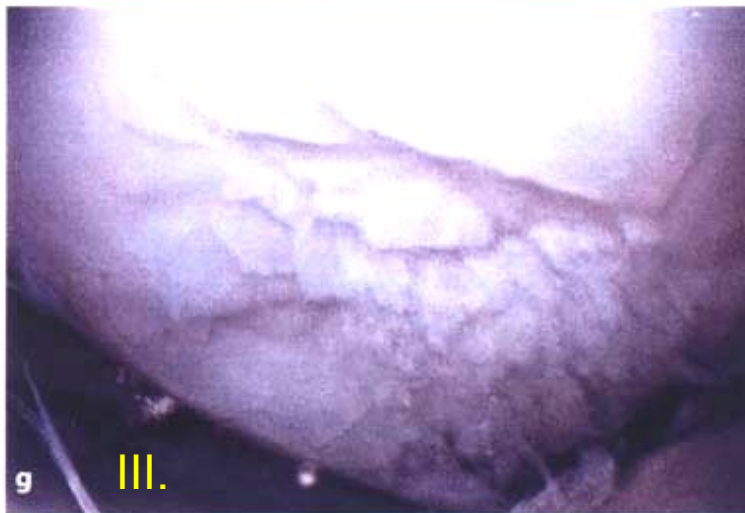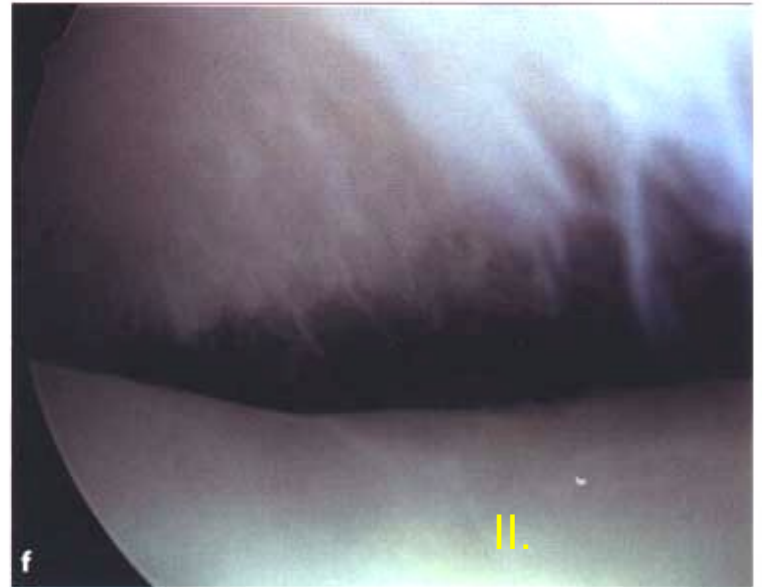
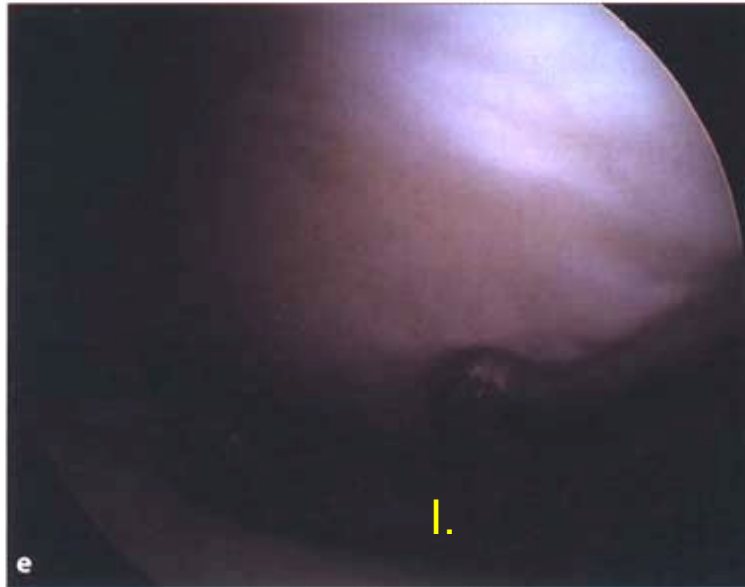# Chondropathy

Outerbridge. H.K.

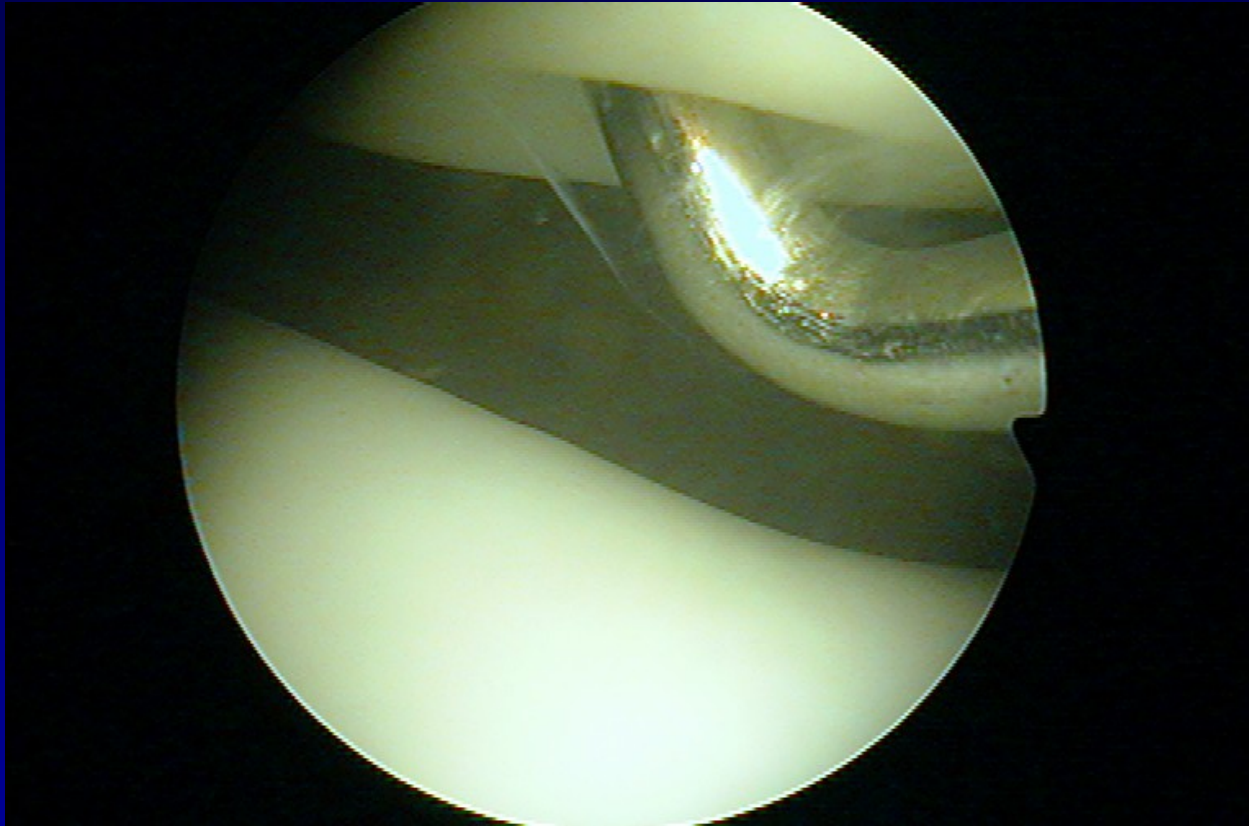




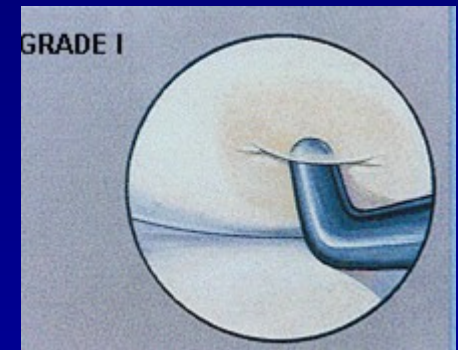
# Chondropathy



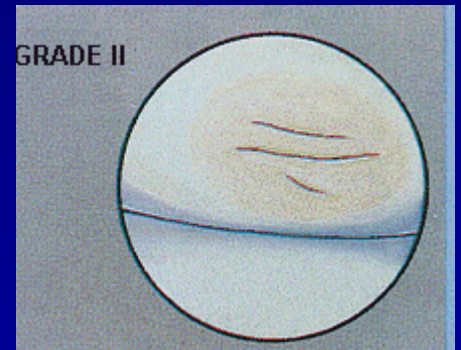
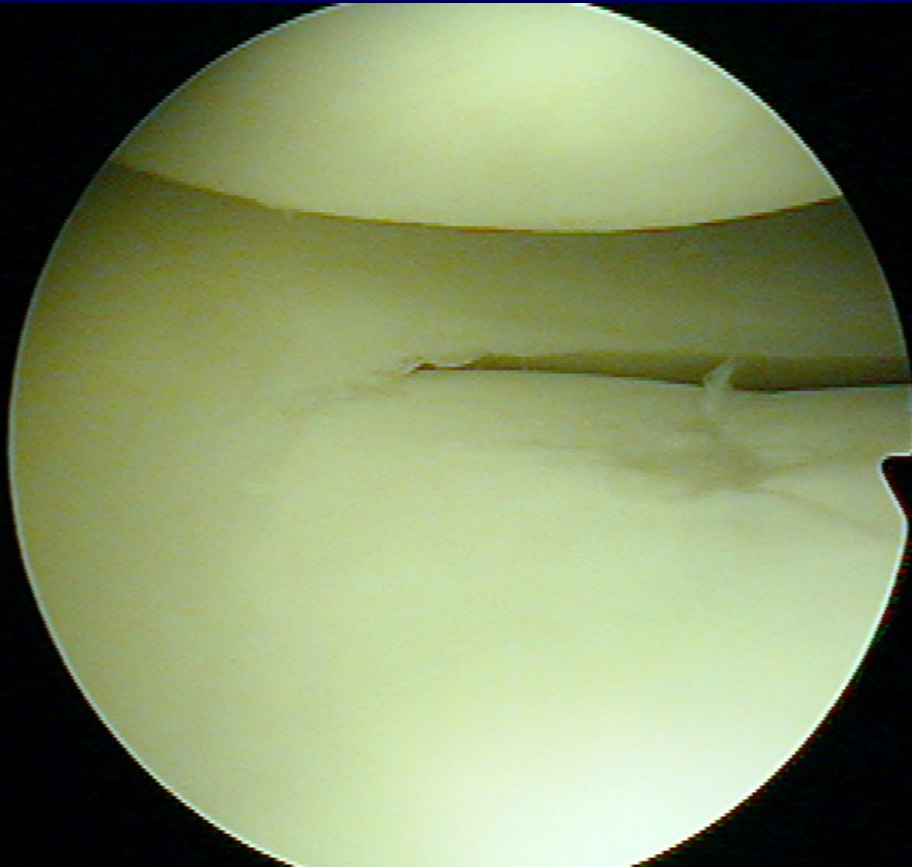
# Chondropathy I. st.



Soft cartilage

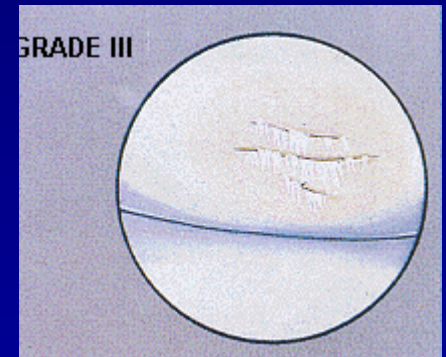
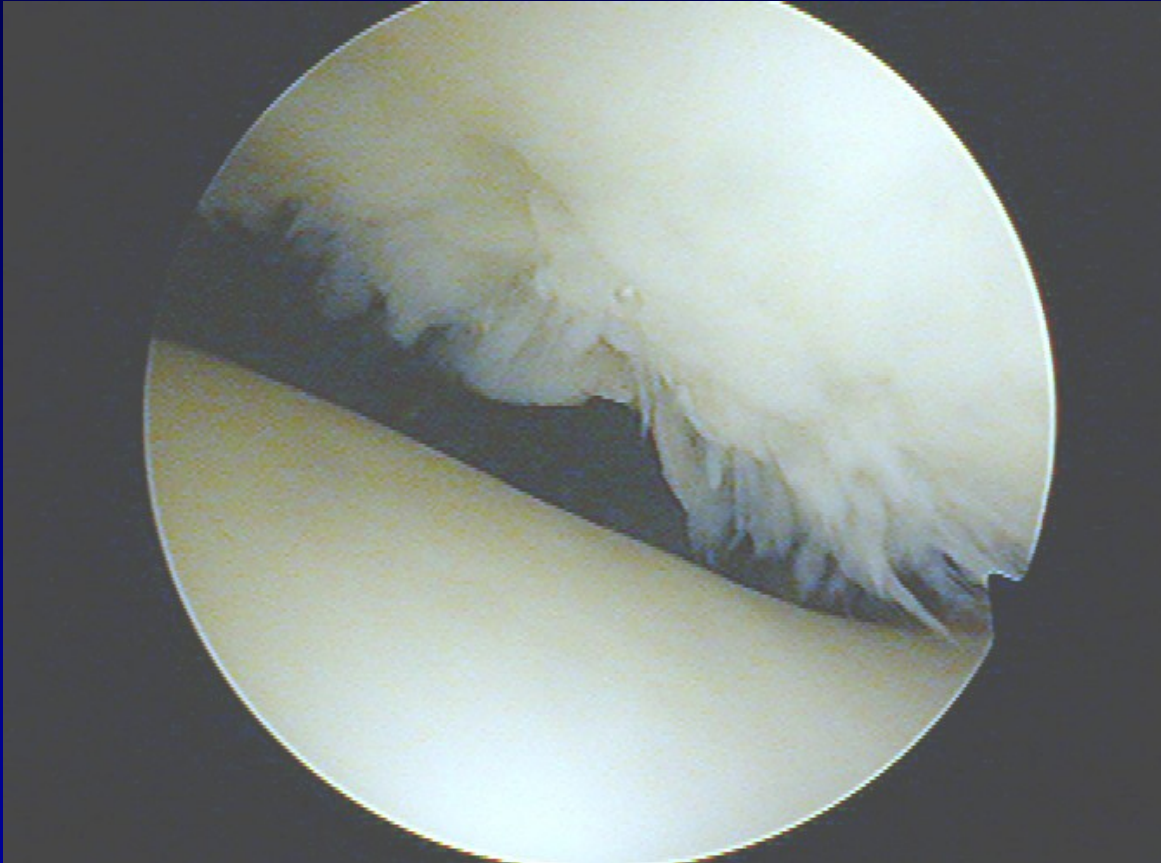


# Chondropathy II. st.



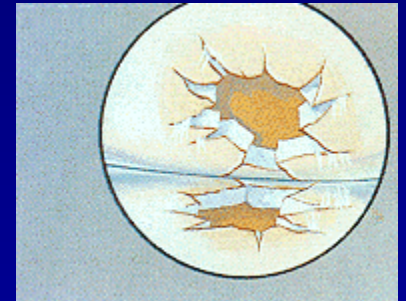
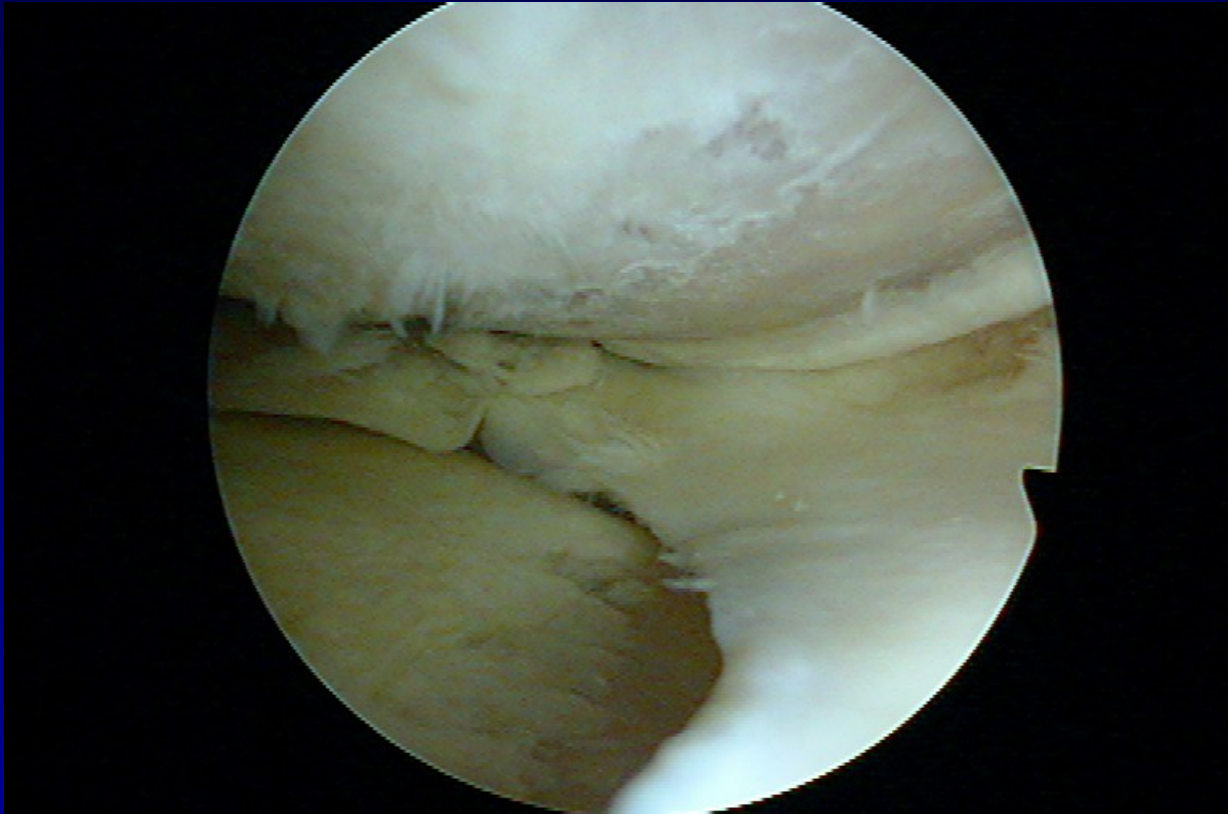
**Fissures in the cartilage**

# Chondropathy III. st.



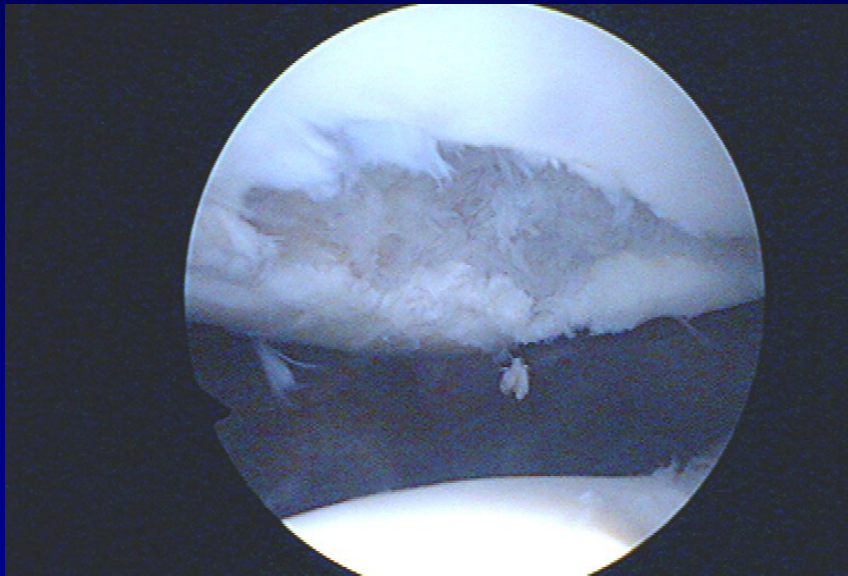
**Fibrillation- „ crab meet“**

# Chondropathy IV. st.

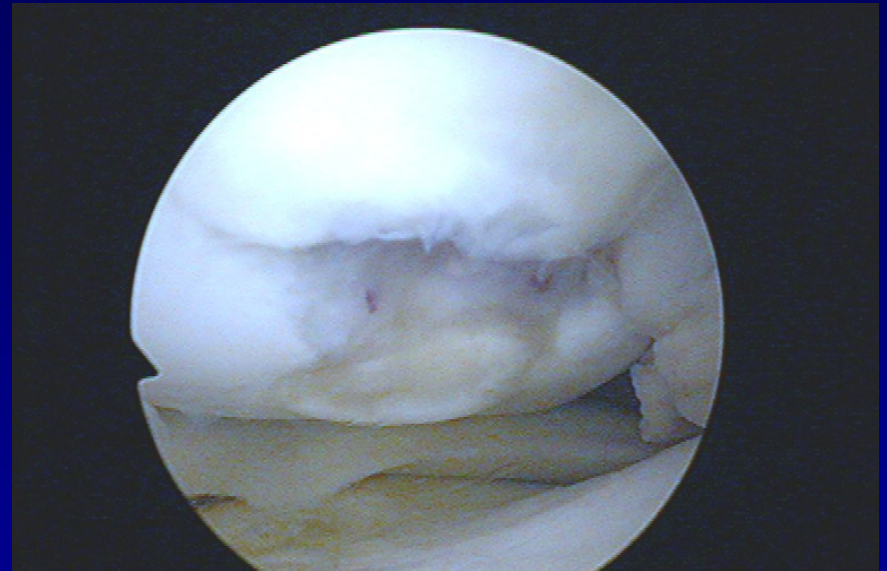


**Defects to subchondral bone**

# Defects of cartilage

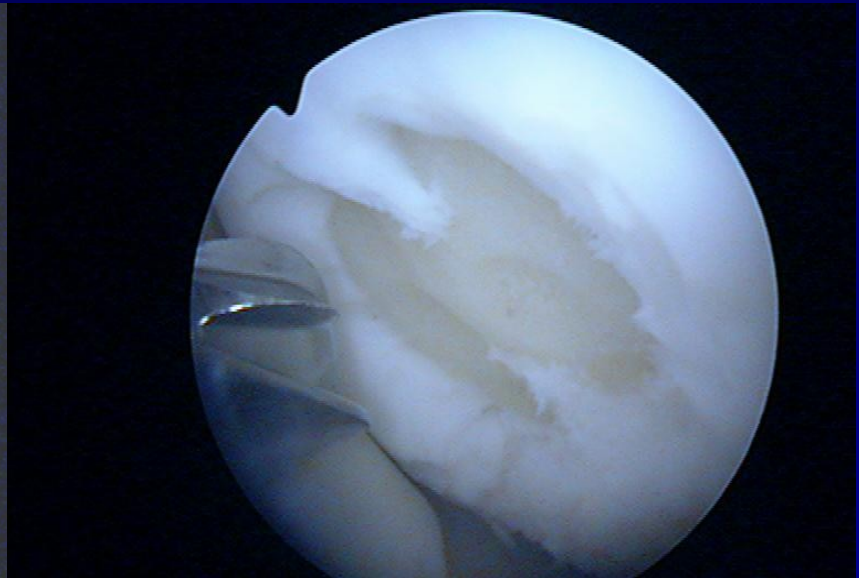
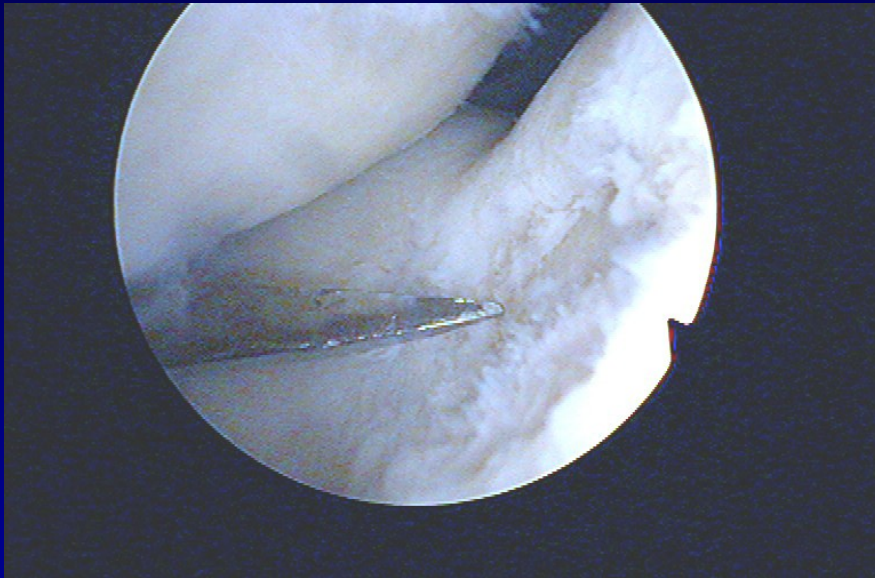


**Patella**



**Medial condyle**

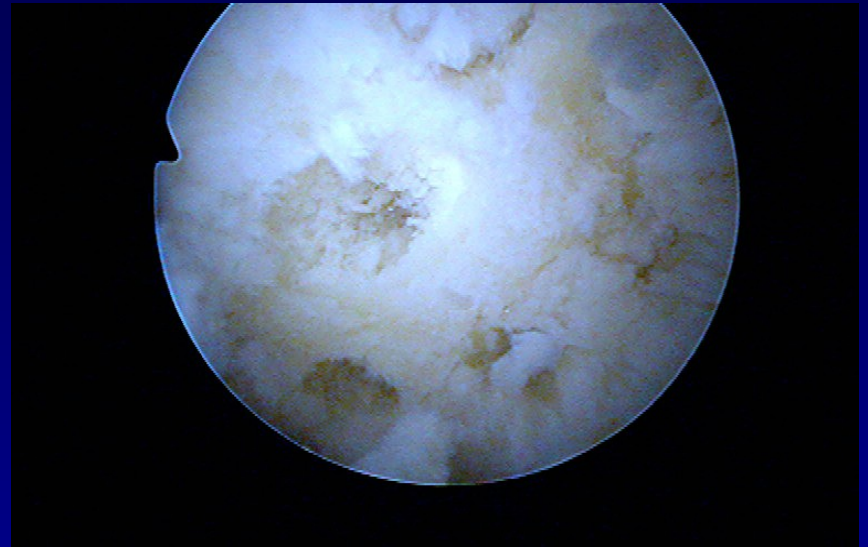
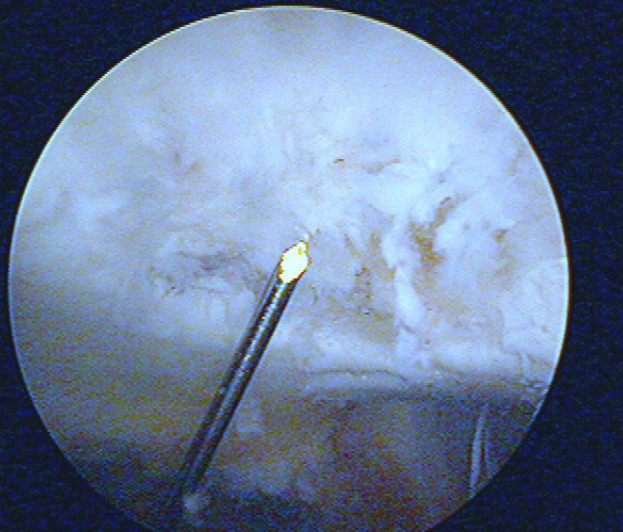
# Shaving and drilling



-

-

# Drilling



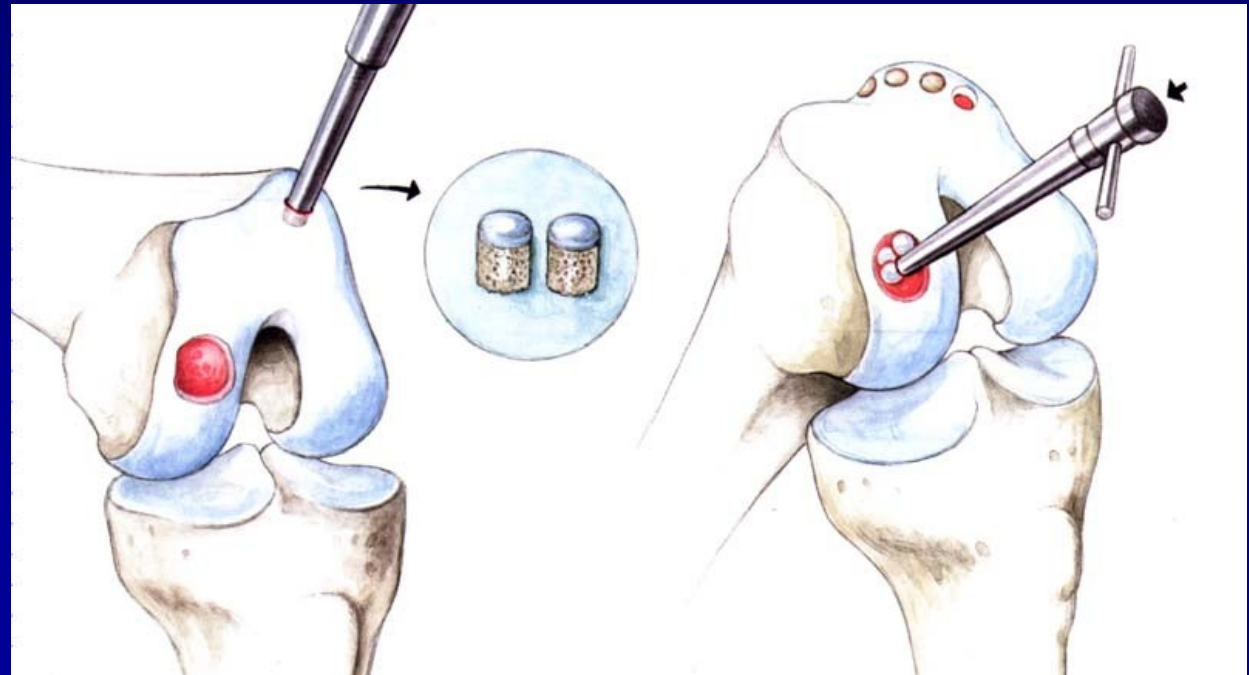
-



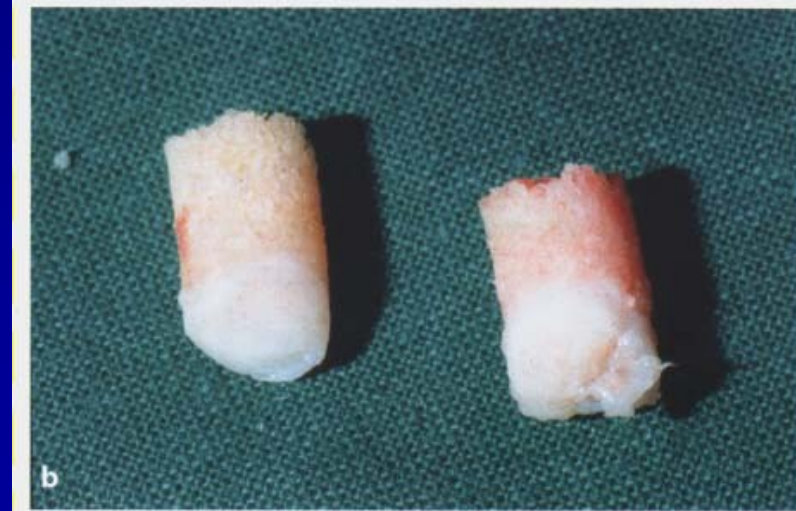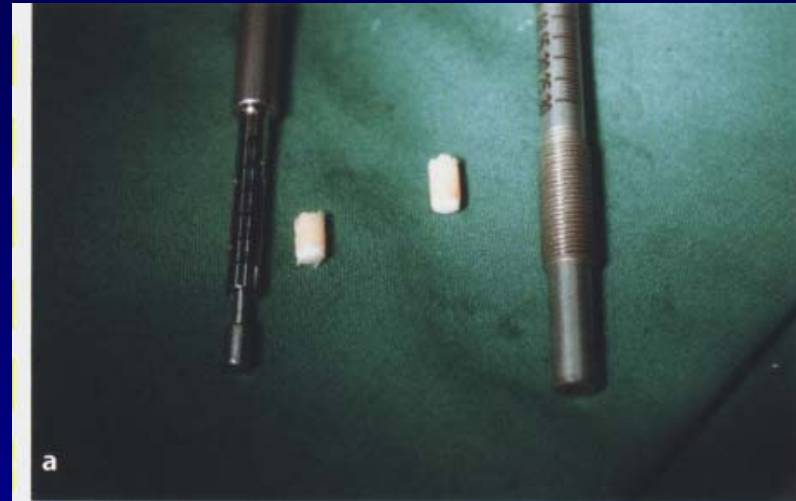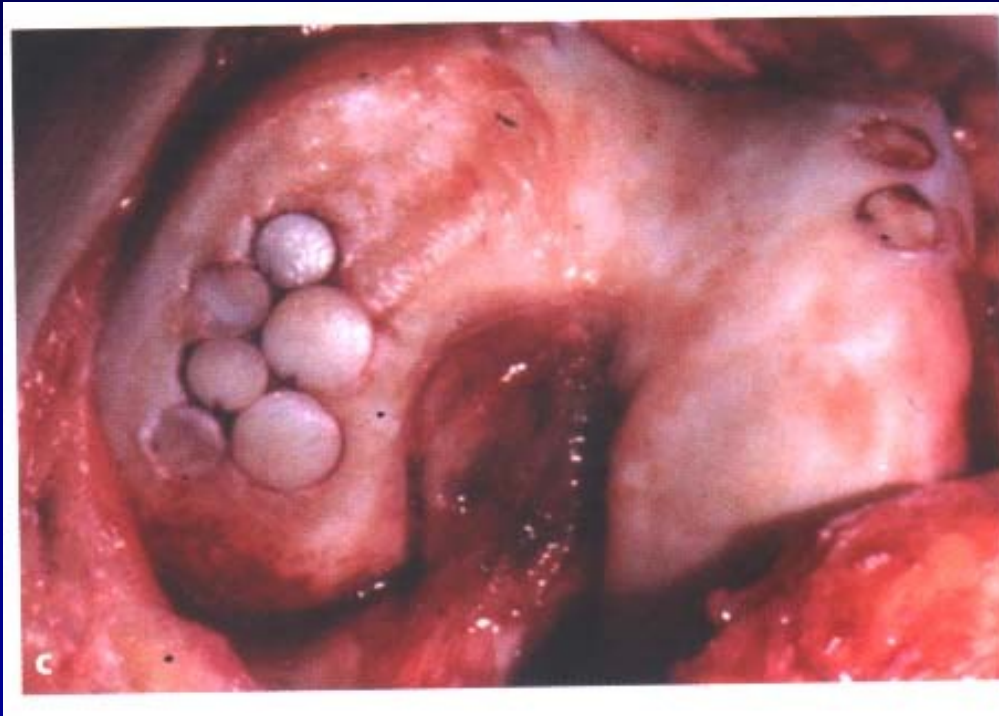# Osteochondral autograft transfer- OAT Mosaicplasty

Hangody, L., 1992

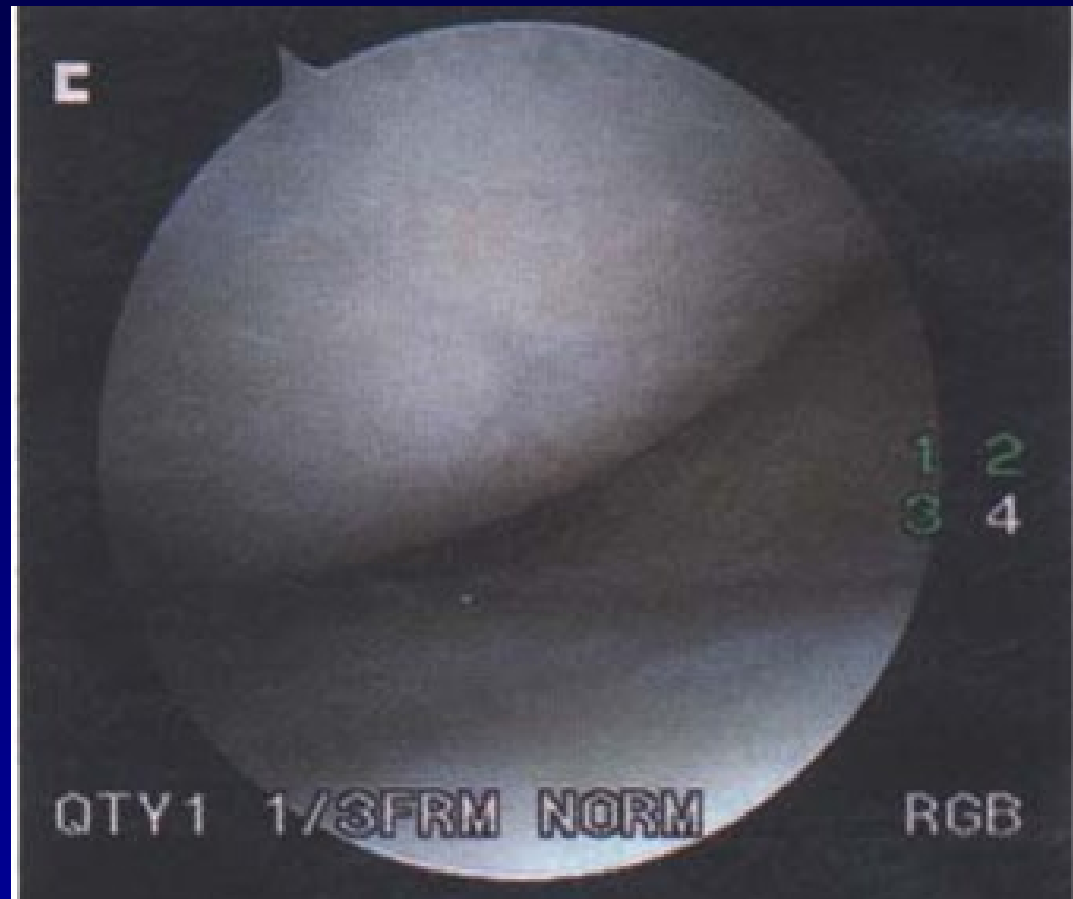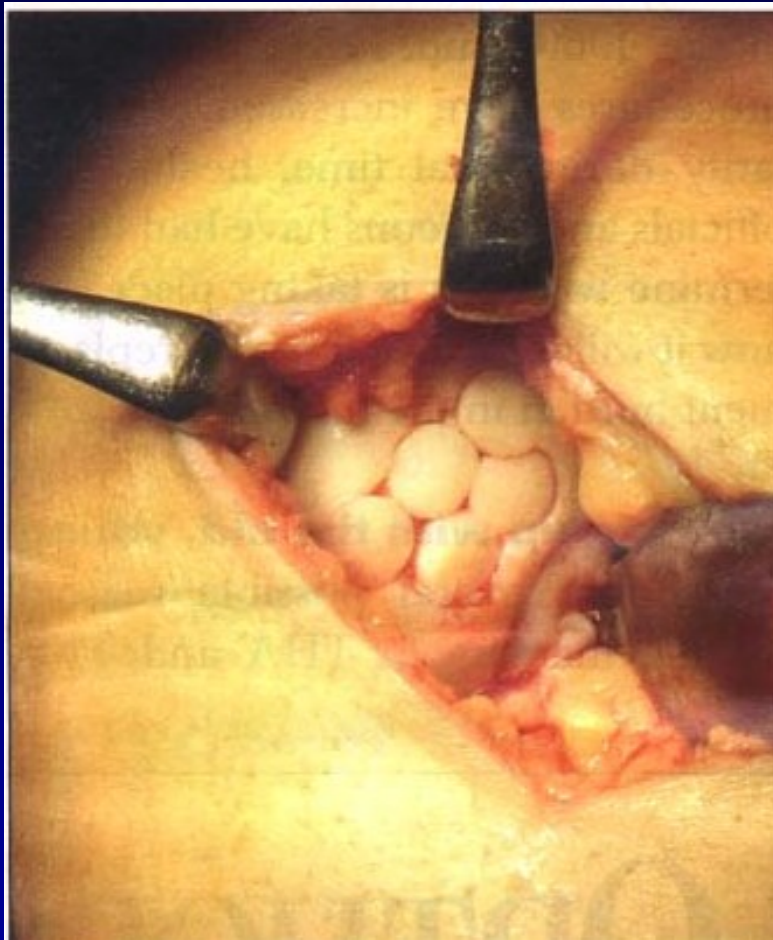
Defects up to 2 - 4 cm<sup>2</sup>



# Osteochondral autograft transfer- OAT



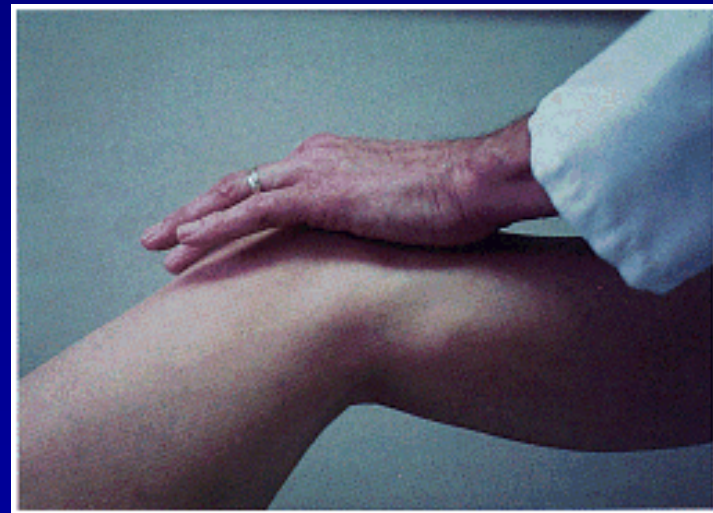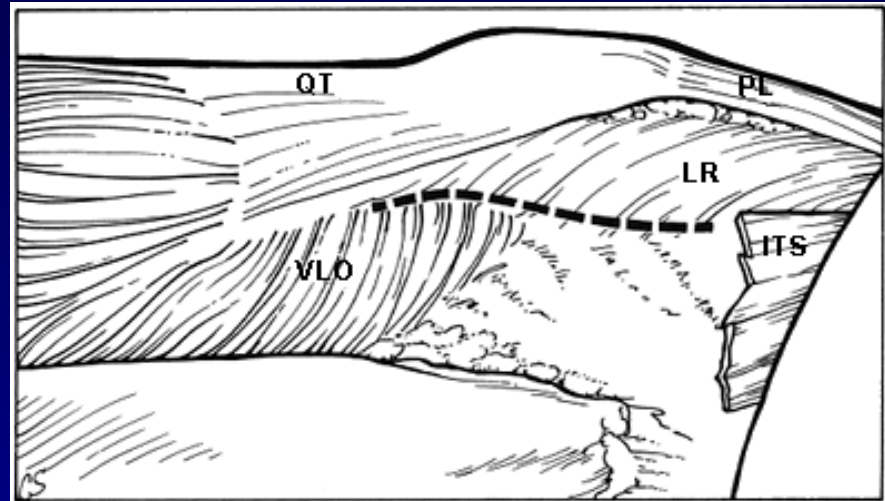
OAT



4 years after surgery

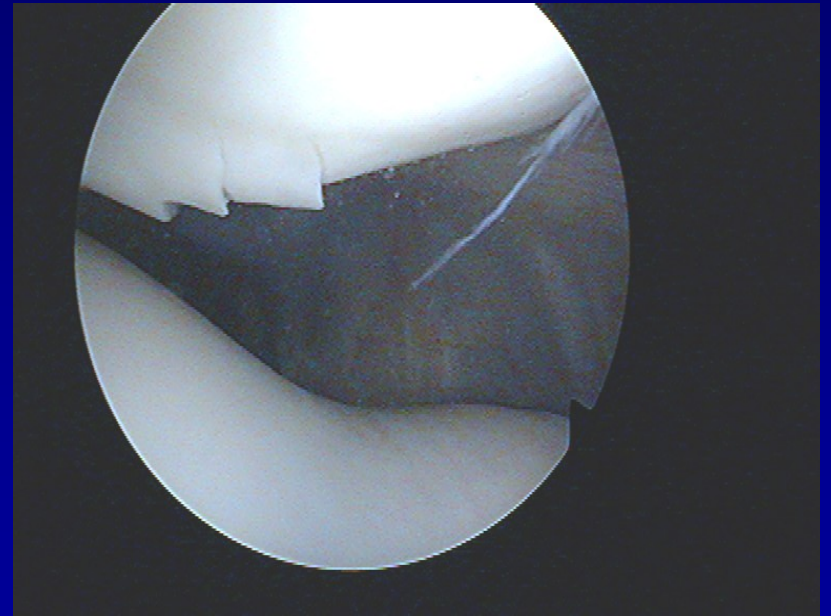
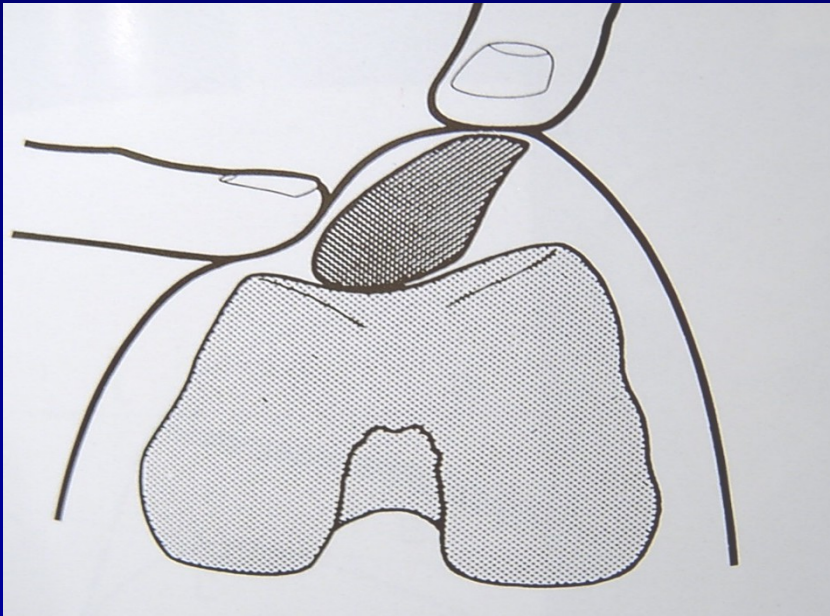
# Patella

- Chondropathy
- Subluxation
- Dislocation



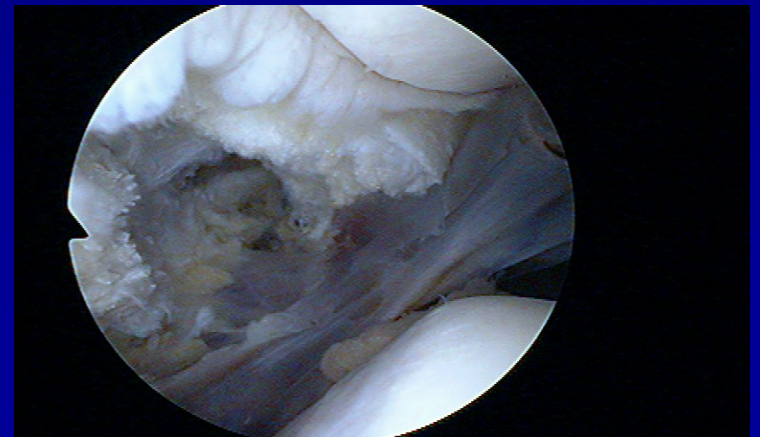
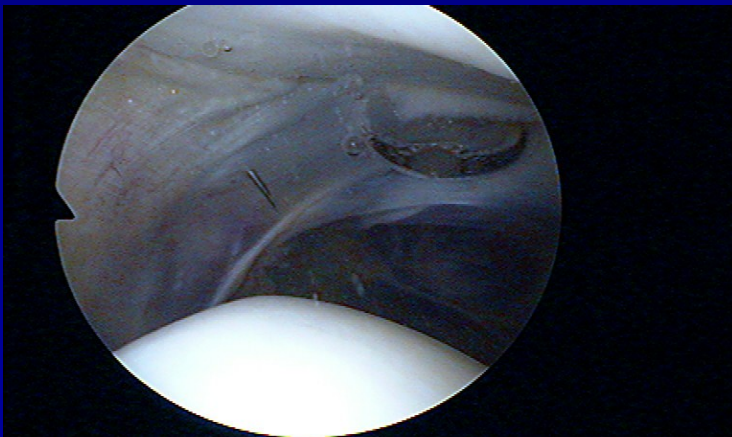
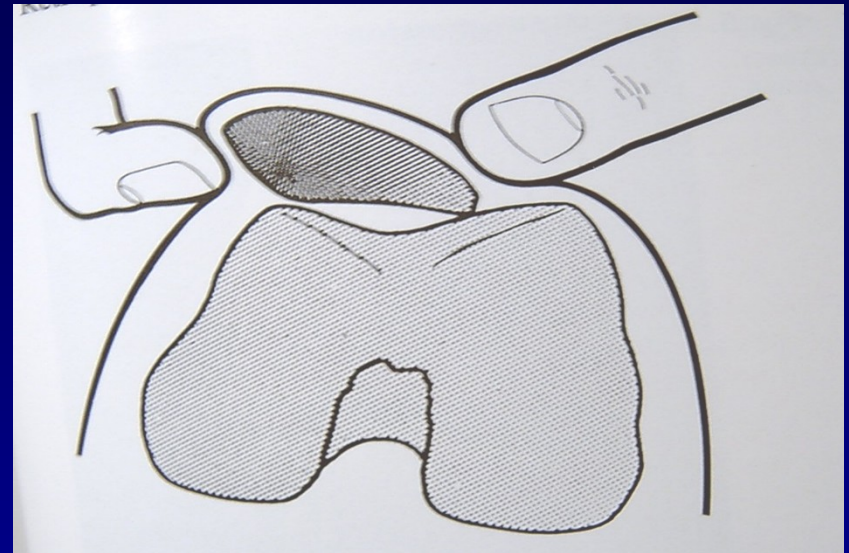
# Chondropathy of the patella

## Clinical symptoms

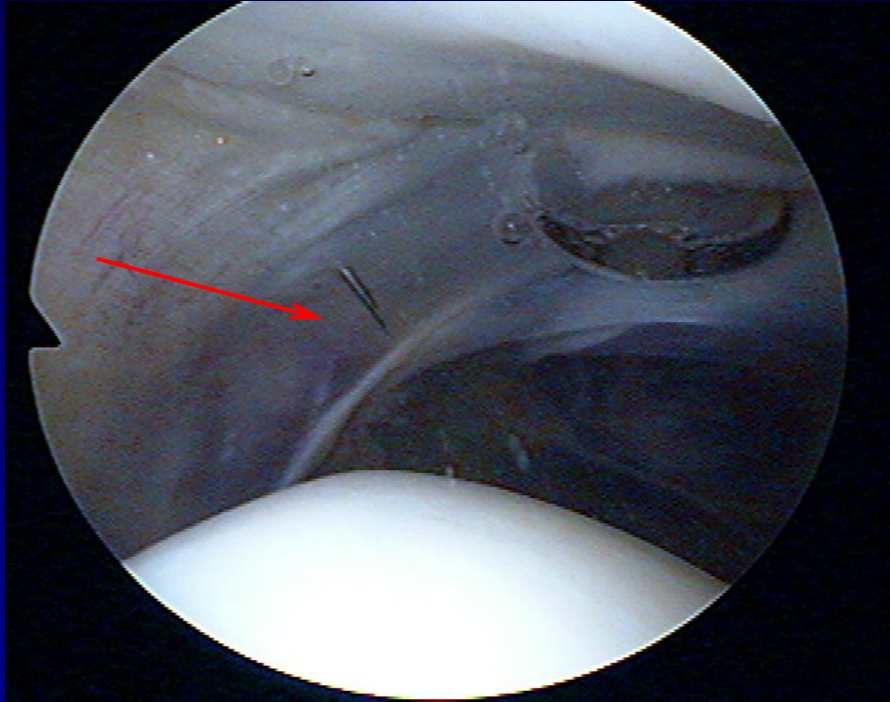


# Chondropathy of the patella

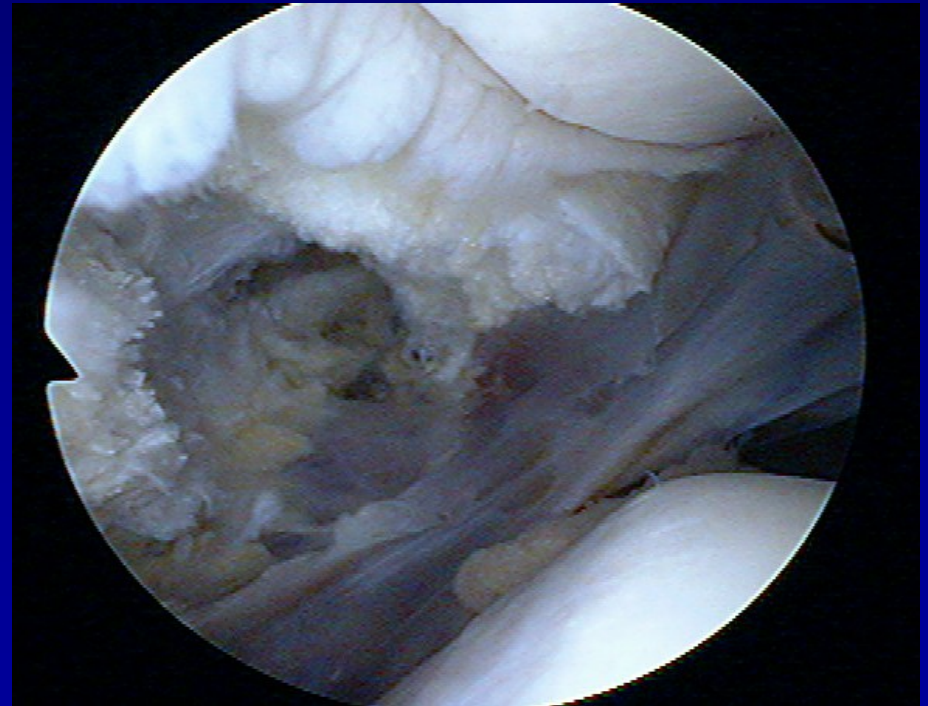
- Lateral hyperpression
- Lateral release



# Lateral release

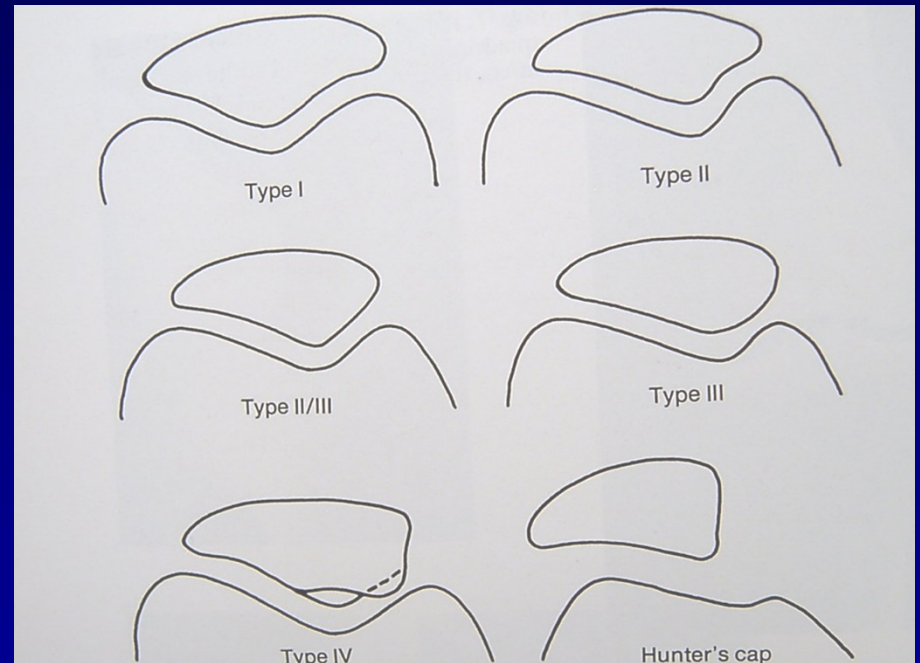


- Incision of lateral retinaculum



# Traumatic dislocation of the patella

- Always laterally
- Conservative treatment
- Operative treatment



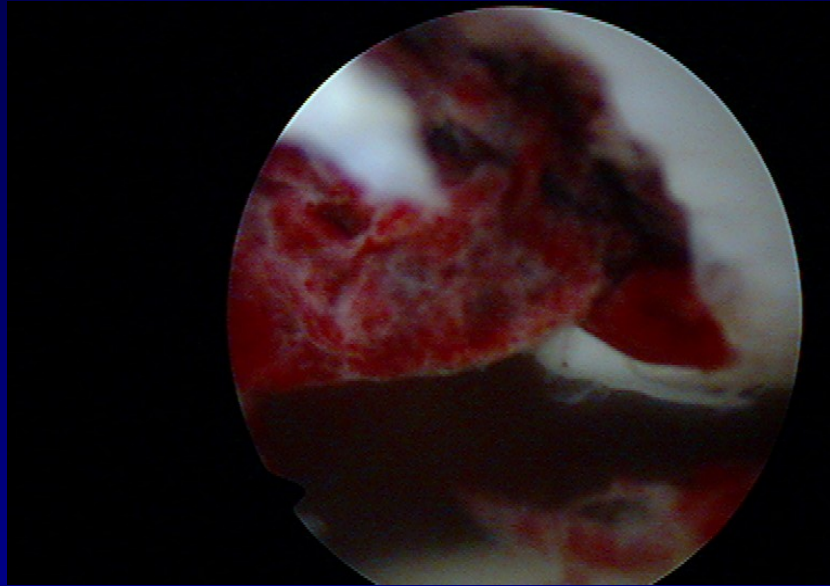
Types of patella



# Recurrent dislocation of the patella

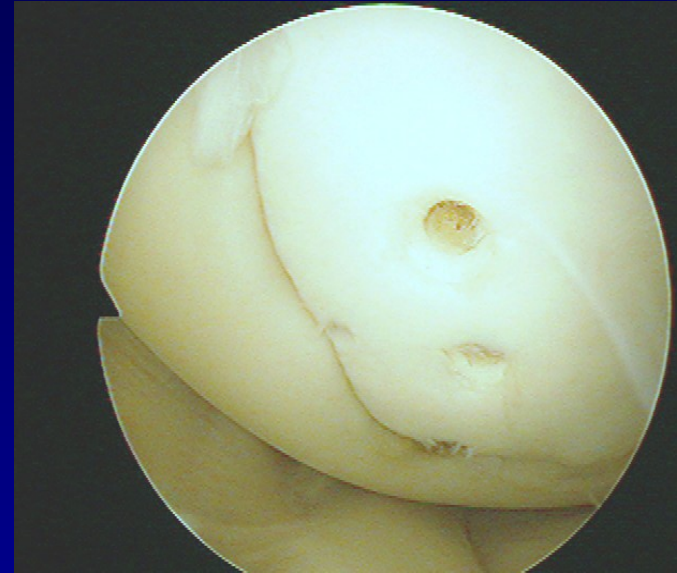
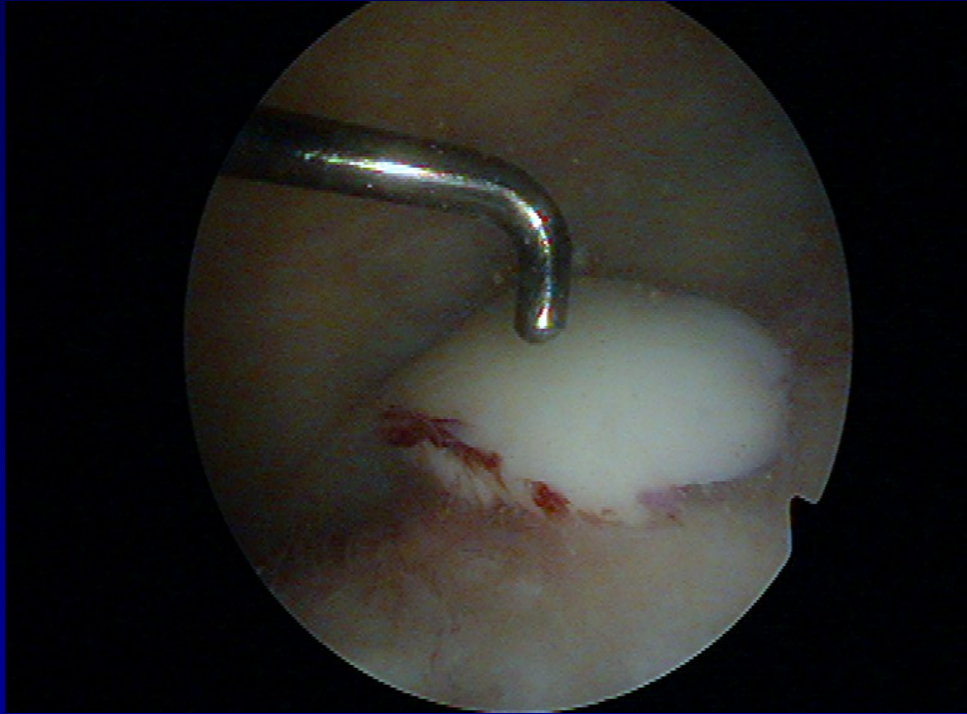
- posttraumatic
  - congenital
  - habitual
- ASK – lateral release + medial capsuloraphy
- Open surgery

# Transchondral fracture



**Removal of destroyed cartilage**

# Osteochondral fractures



Fixation by pins



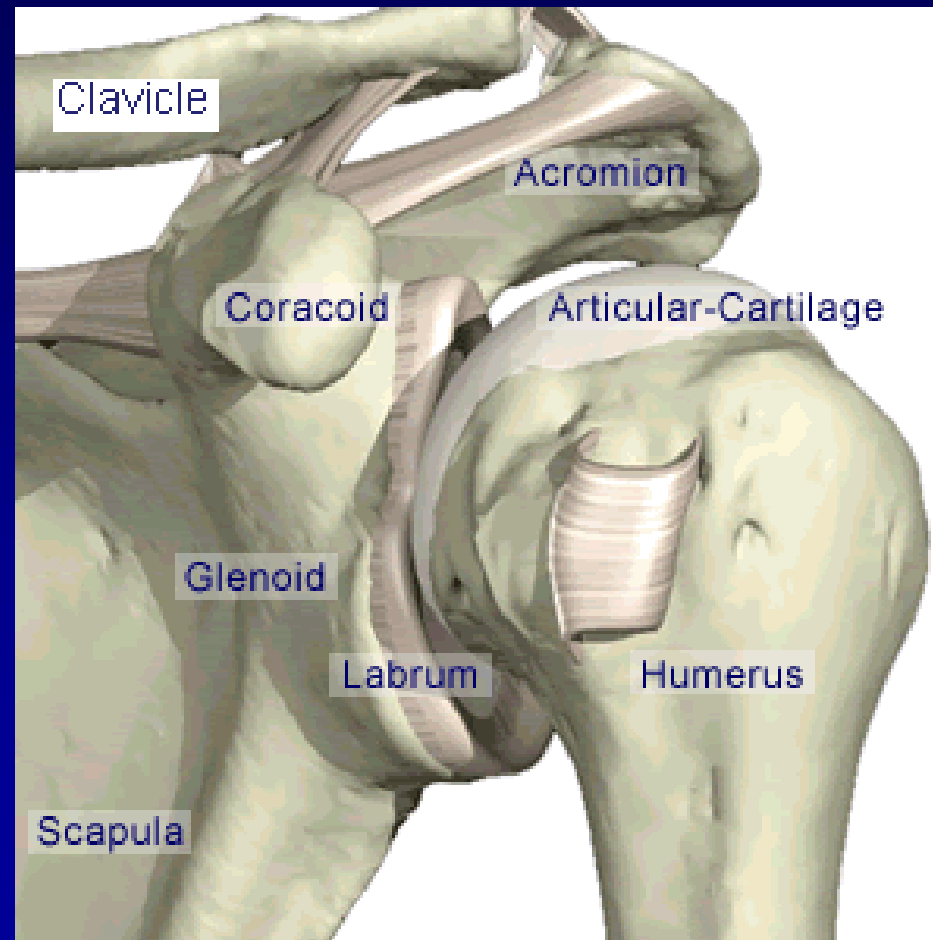
# Arthroscopy of the shoulder

Subacromial decompression

Suture of rotator cuff

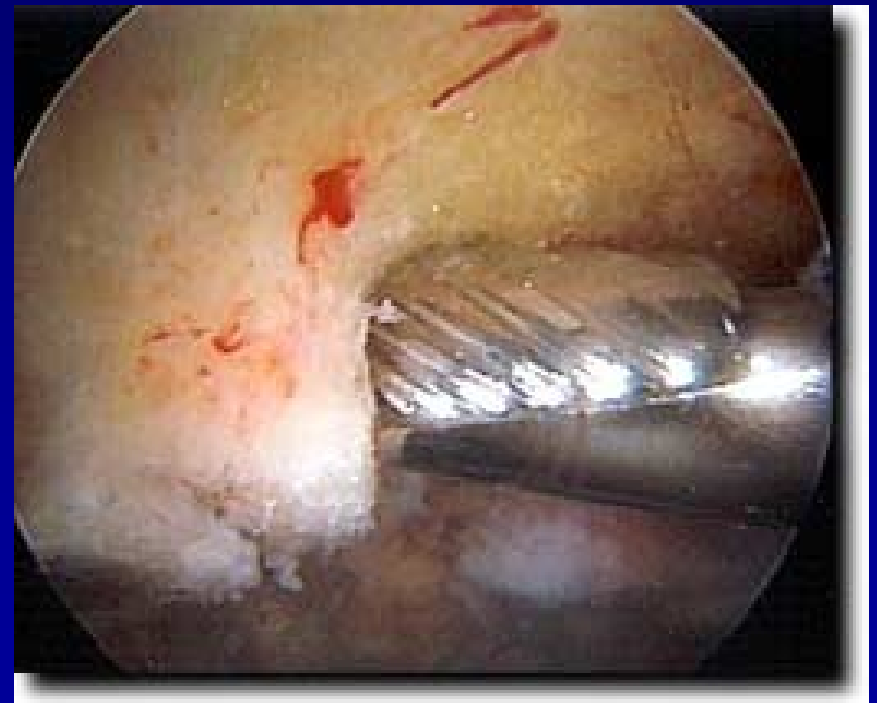
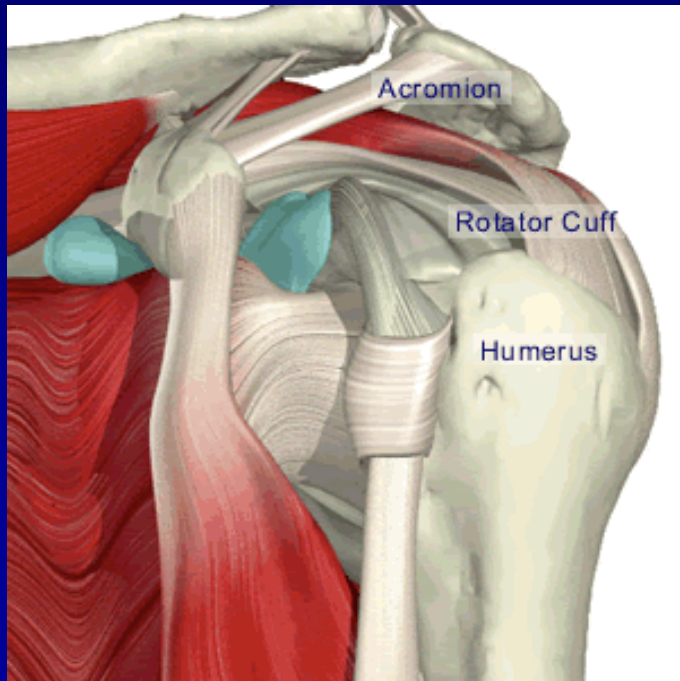
Chronic instability

SLAP lesion



# ASAD – arthroscopic subacromial decompression

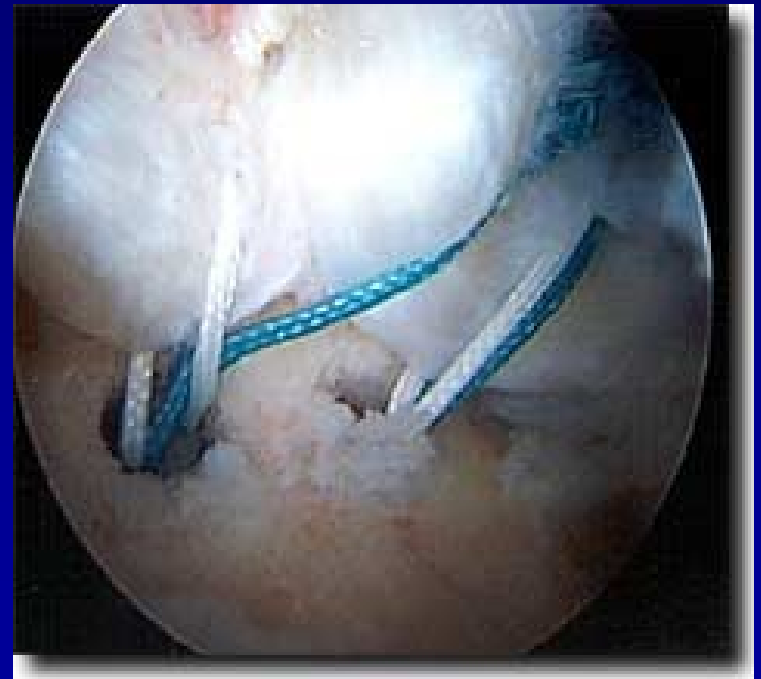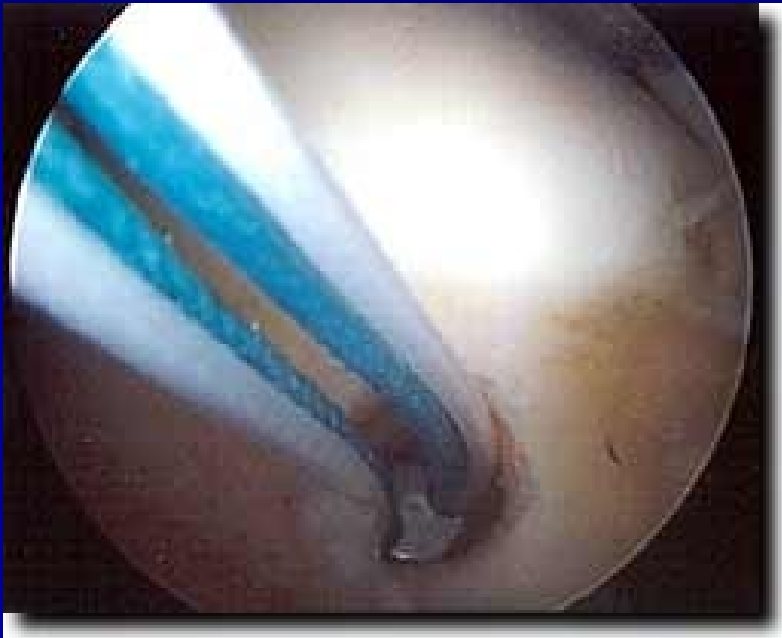- Removal of bursa
- Acromioplasty - shaver



# Rupture of rotator cuff

Suture:

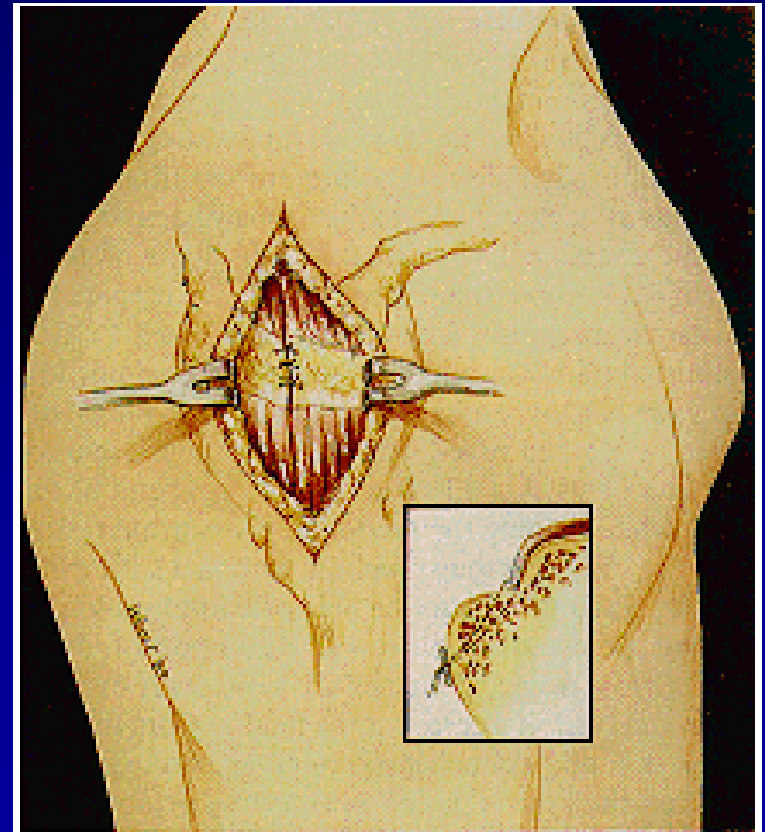
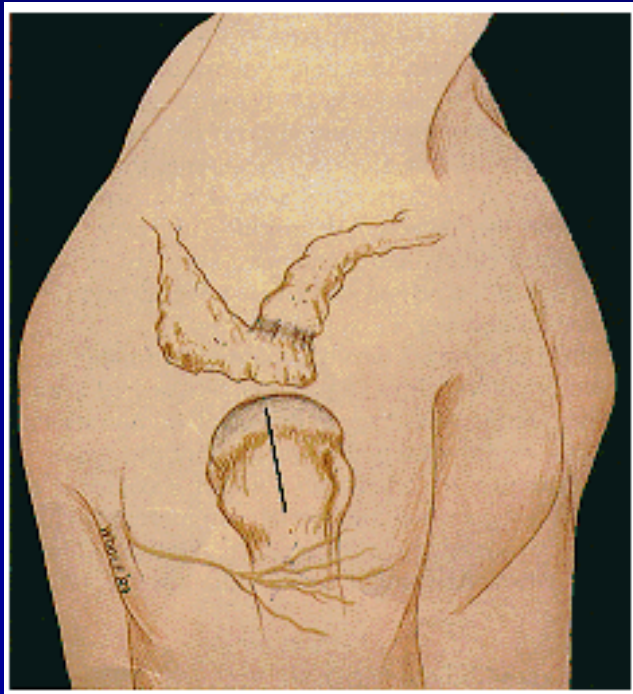
- arthroscopically



# Rupture of rotator cuff

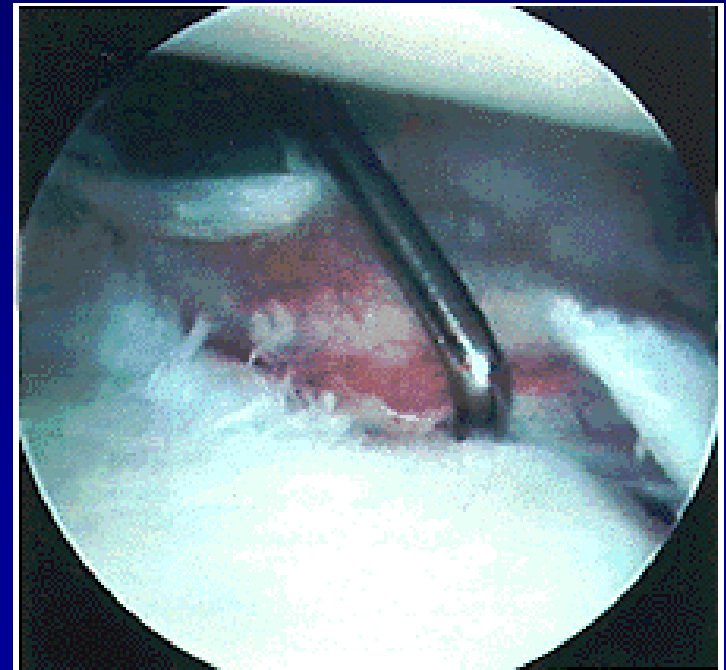
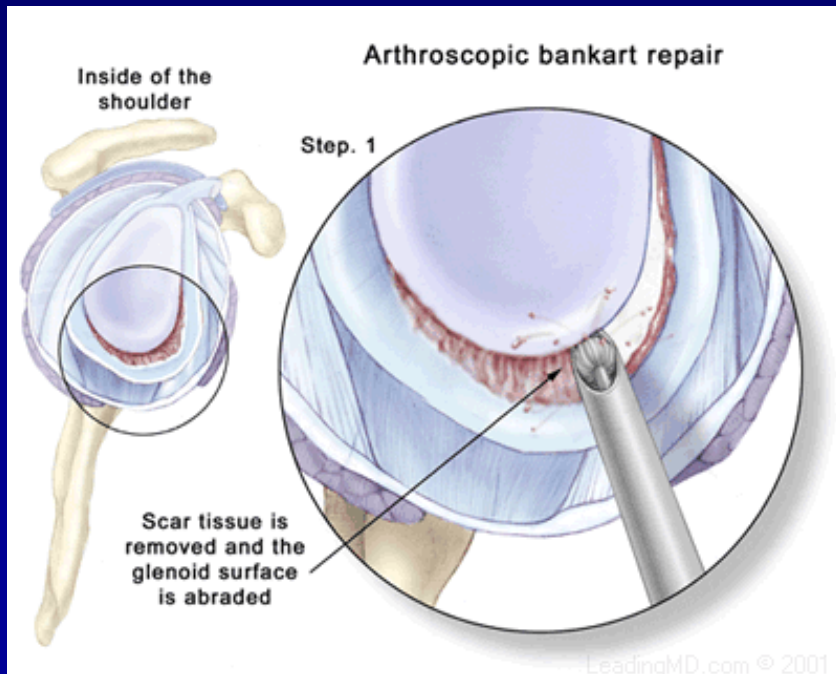
Suture:

- from small incision



# ASC- stabilisation

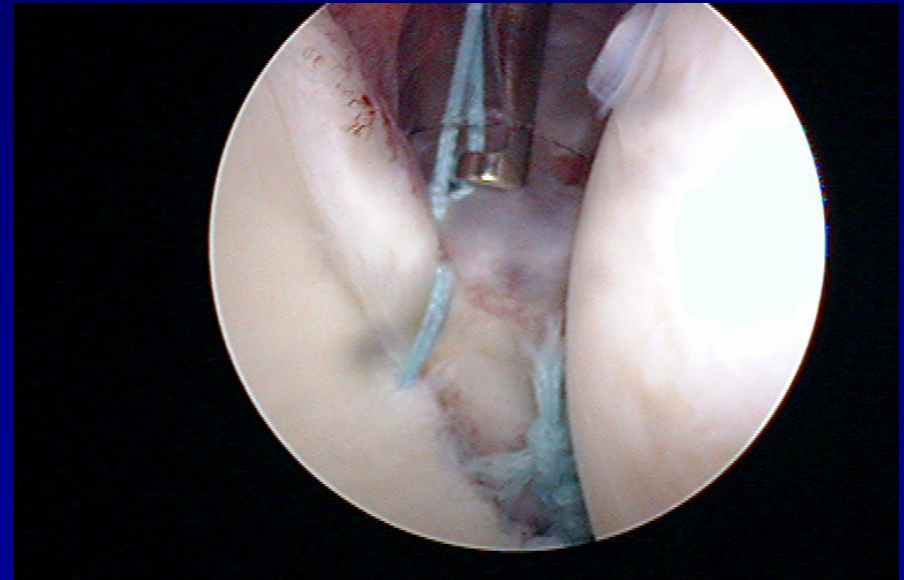
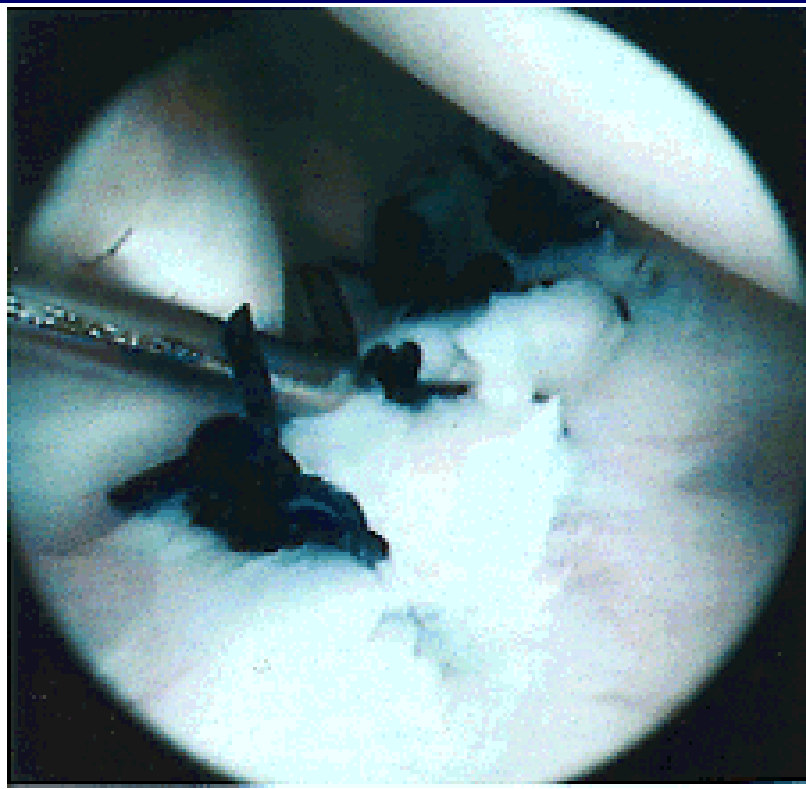
Fixation of the labrum to the bone – stitches and arrows





# ASC- stabilisation

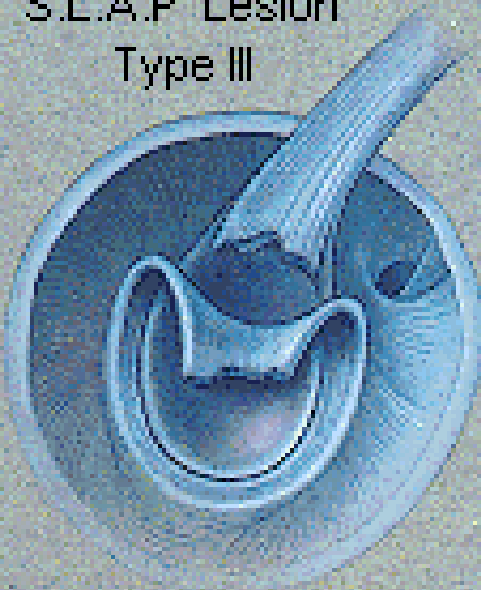- Fixation of the labrum to the bone – stitches, arrows



# SLAP lesion

Rupture of insertion of the tendon of long head of biceps

S.L.A.P. Lesion  
Type III



S.L.A.P. Lesion  
Type IV

