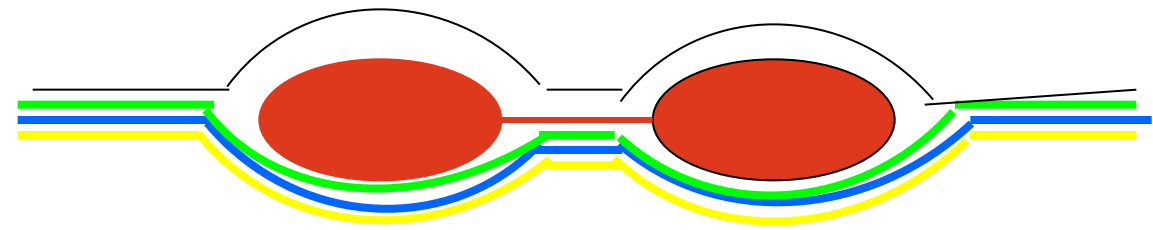
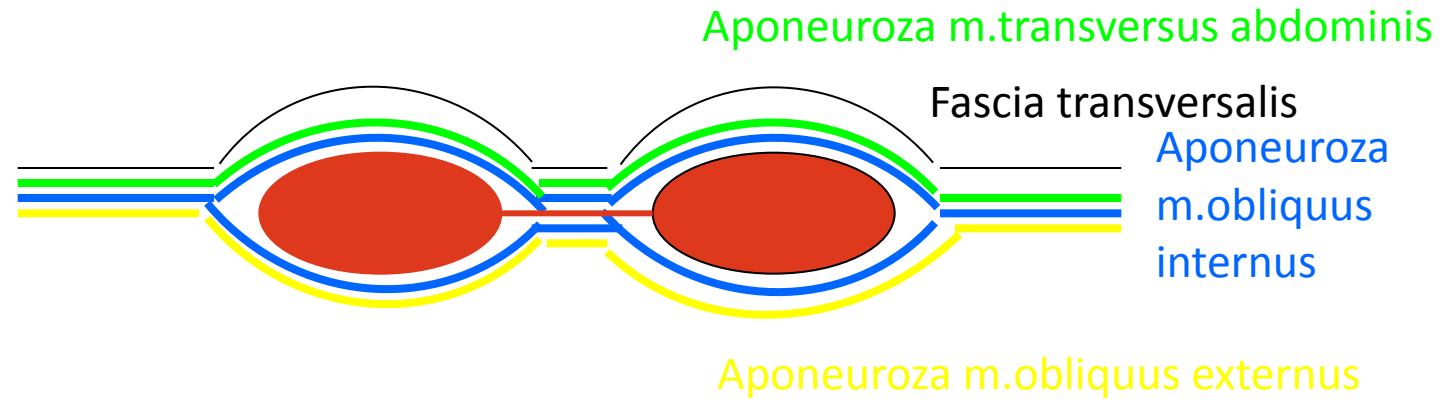
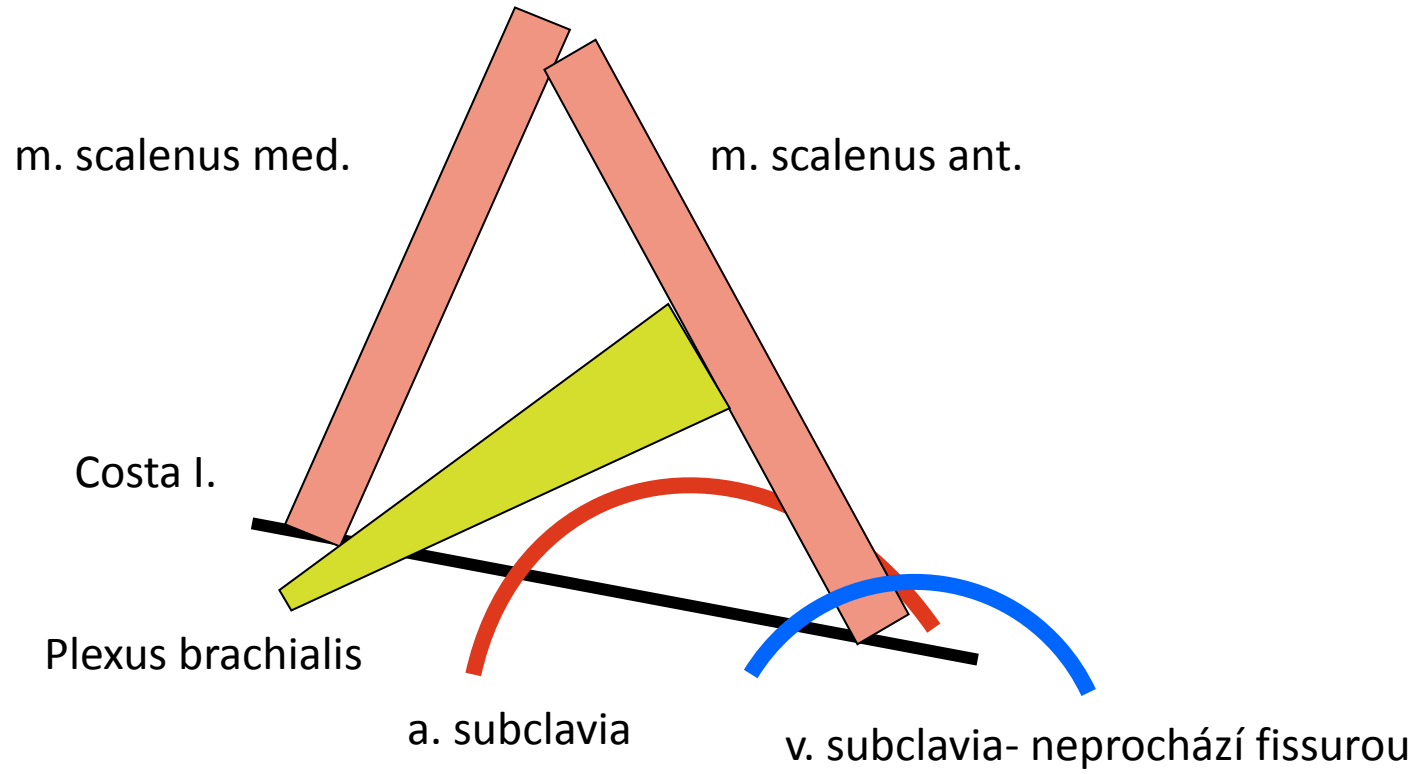


SCHÉMATA

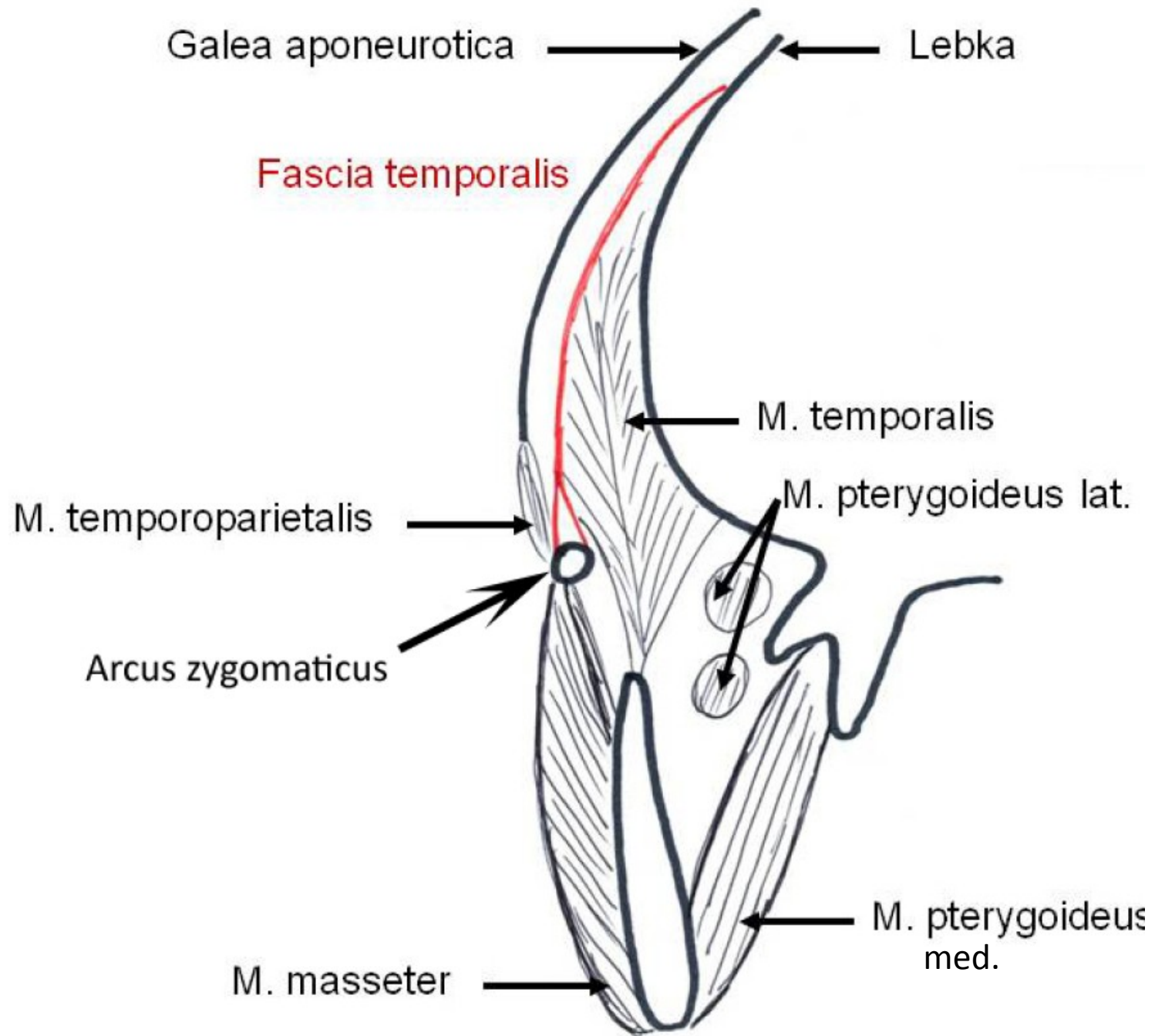
Vagina m.recti abd.

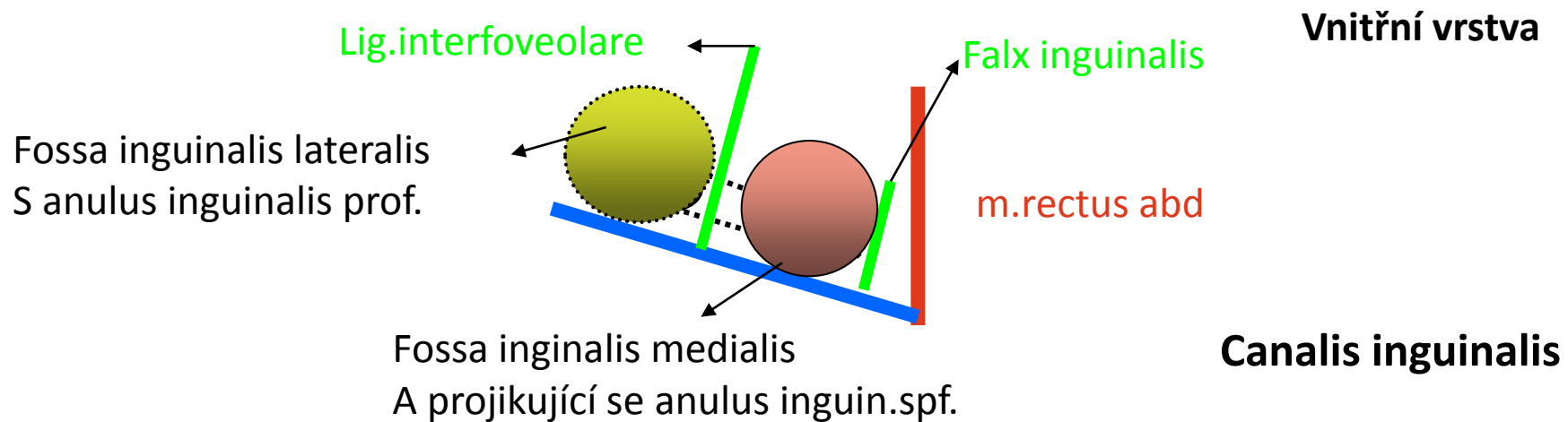
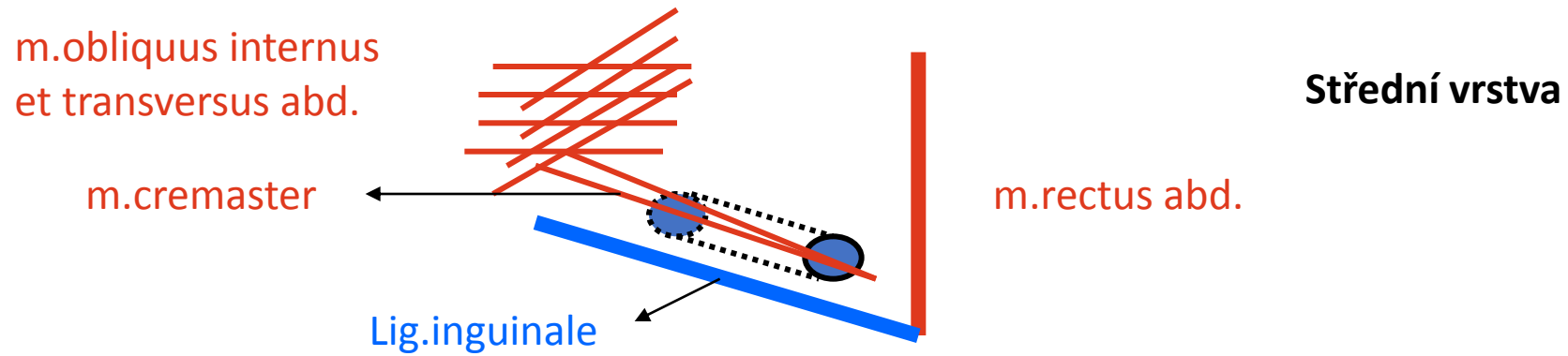
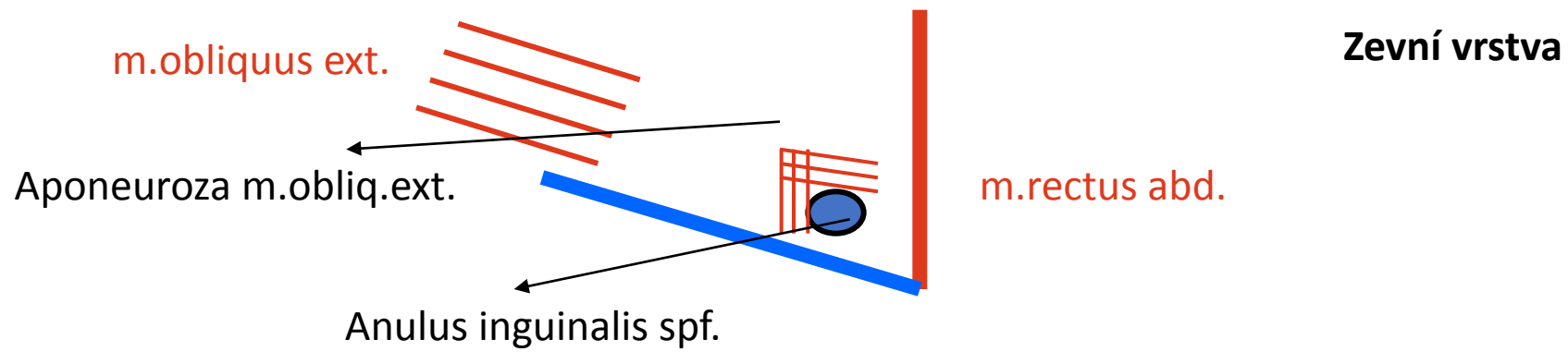


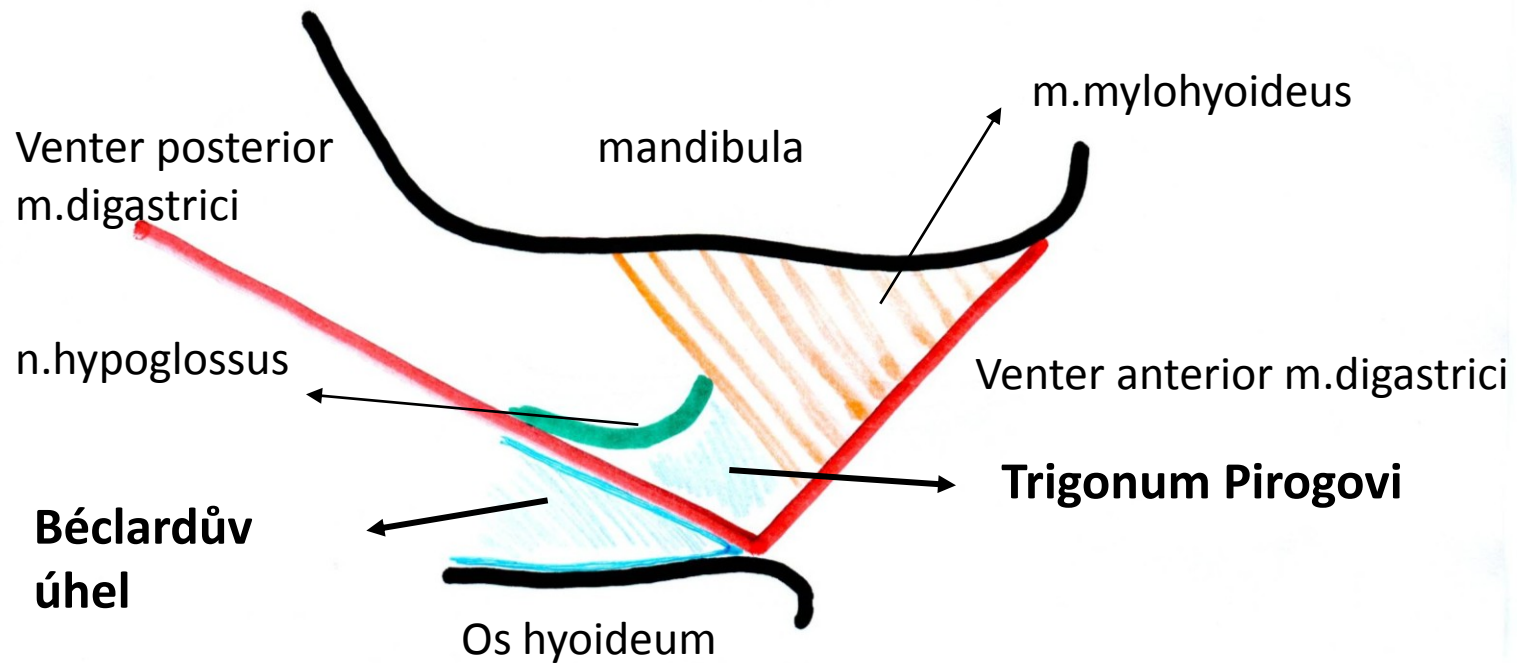
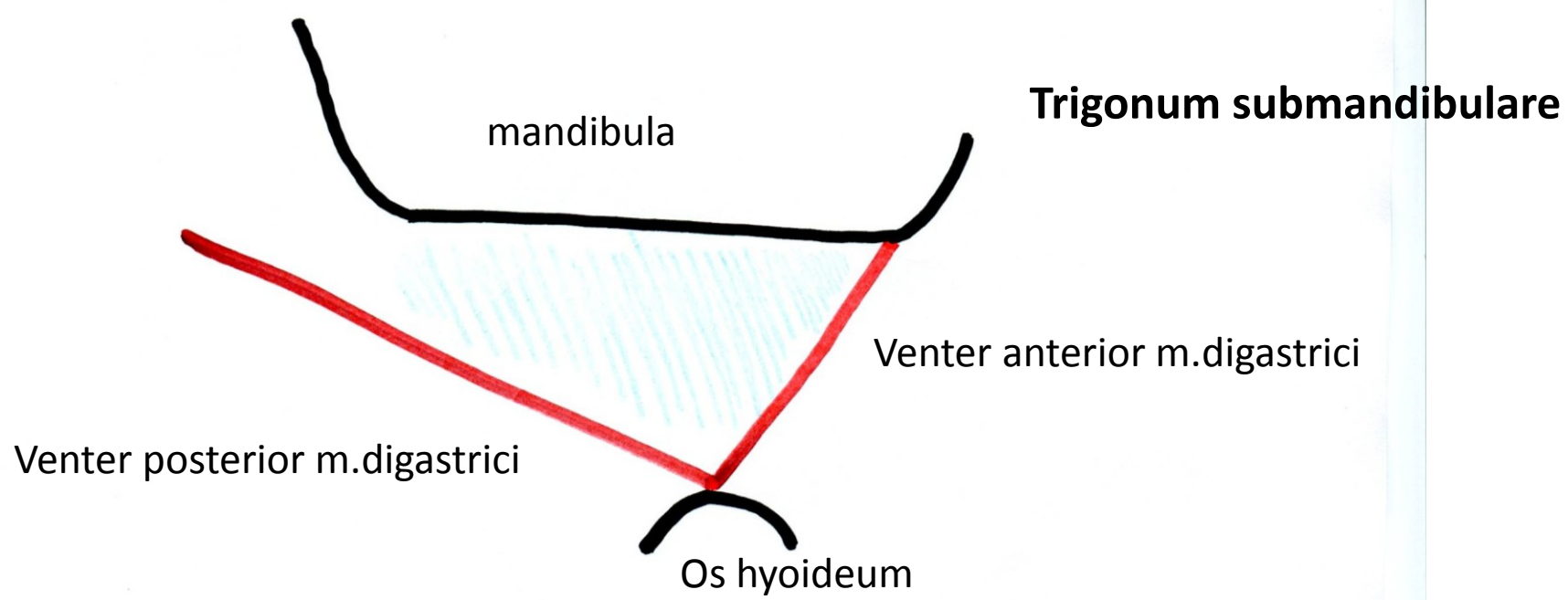
Fissura scalenorum



Fossa temporalis na frontálním řezu, úpon fascie



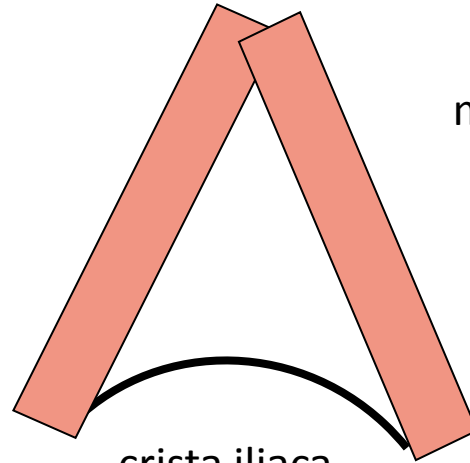




Trigonum lumbale- Petiti

m.latissimus dorsi

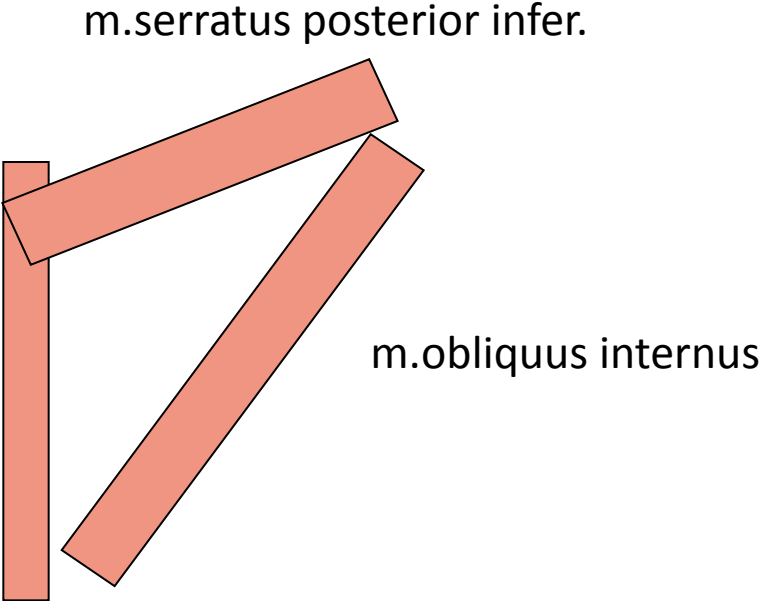
m.obliquus externus



crista iliaca

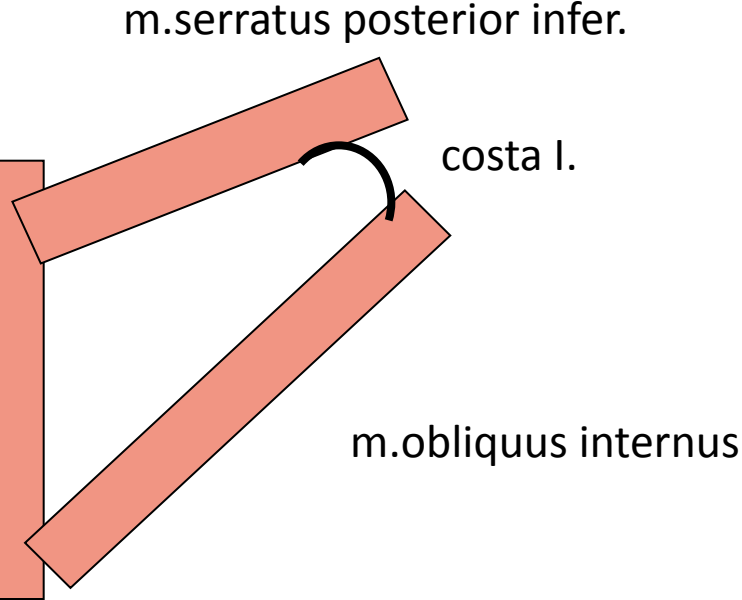
Trigonum Grynfelti

m.erector spinae

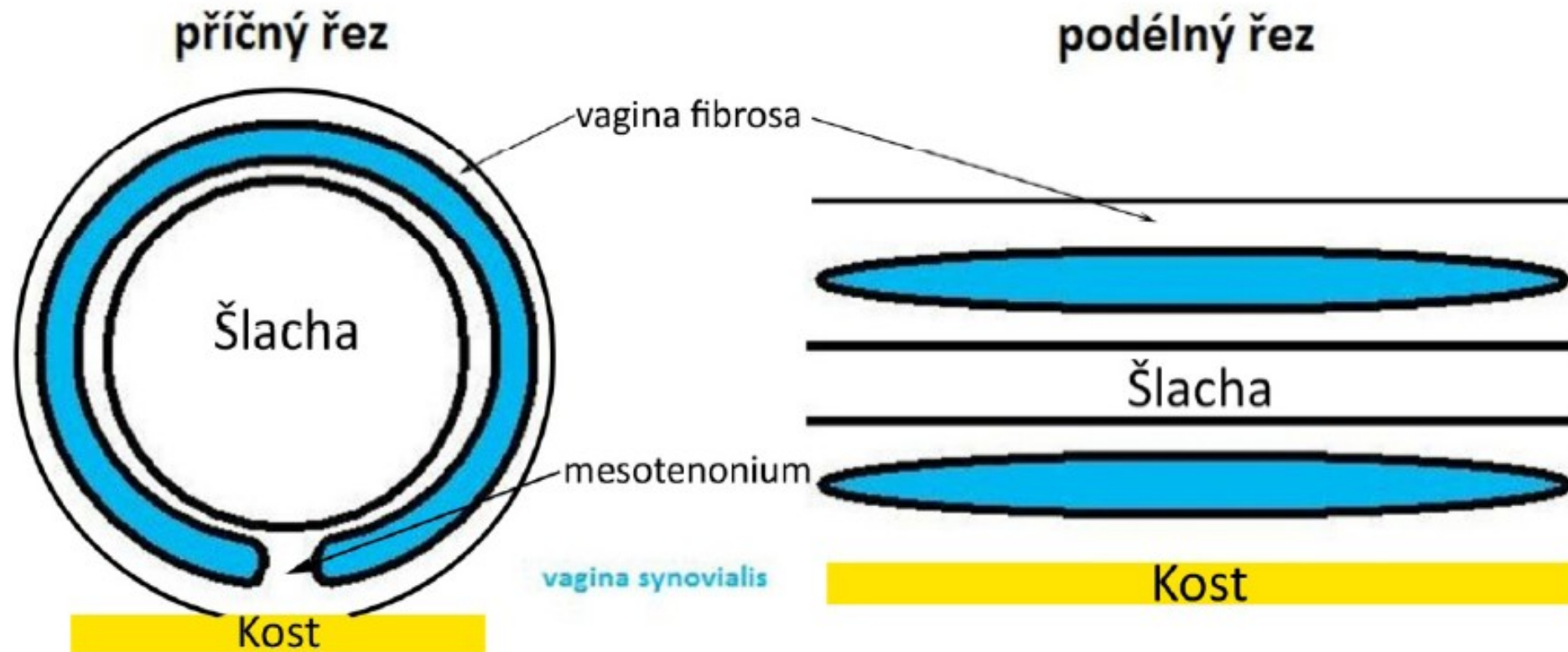


Tetragon Krausei

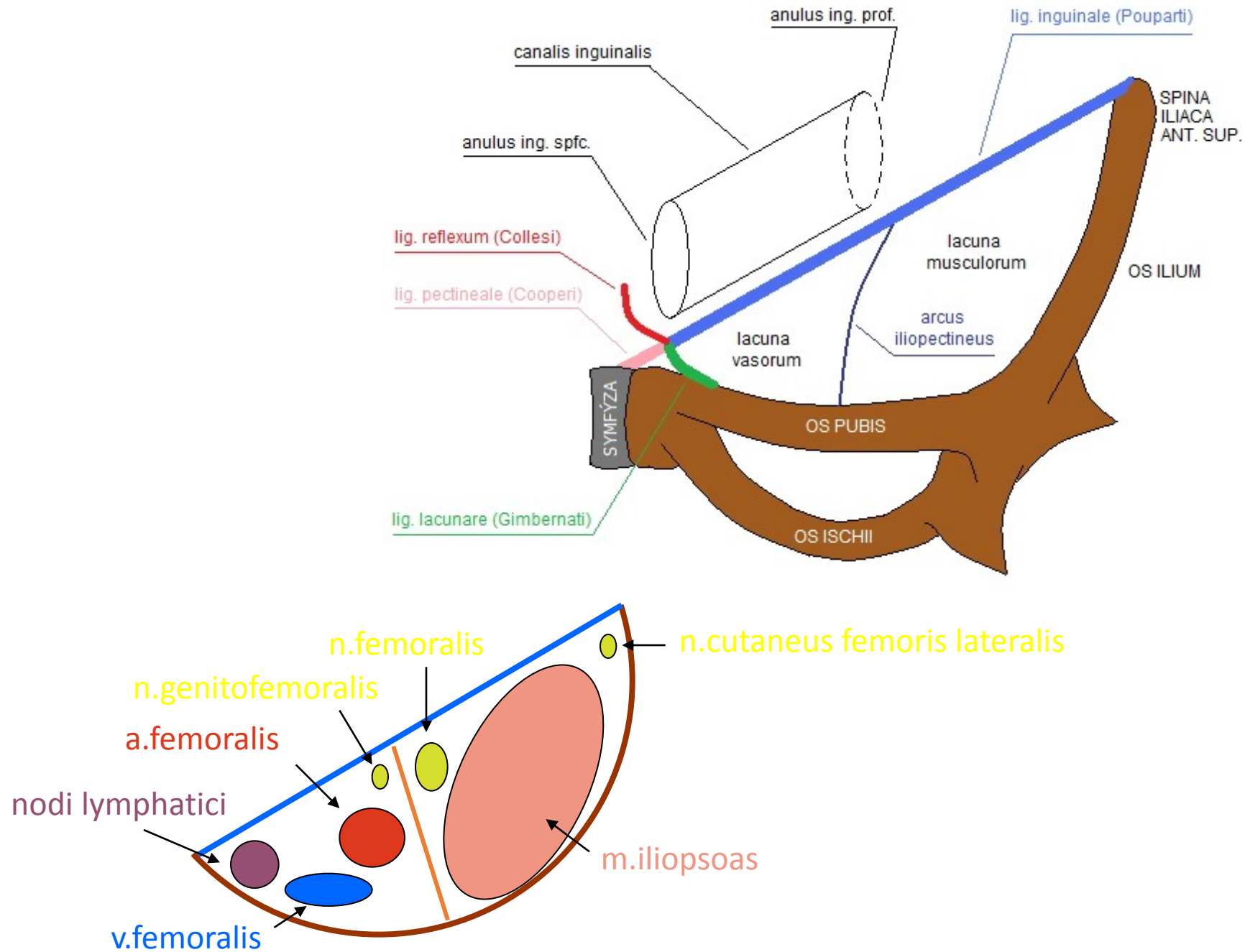
m.erector spinae



Vagina synovialis na podélném příčném řezu



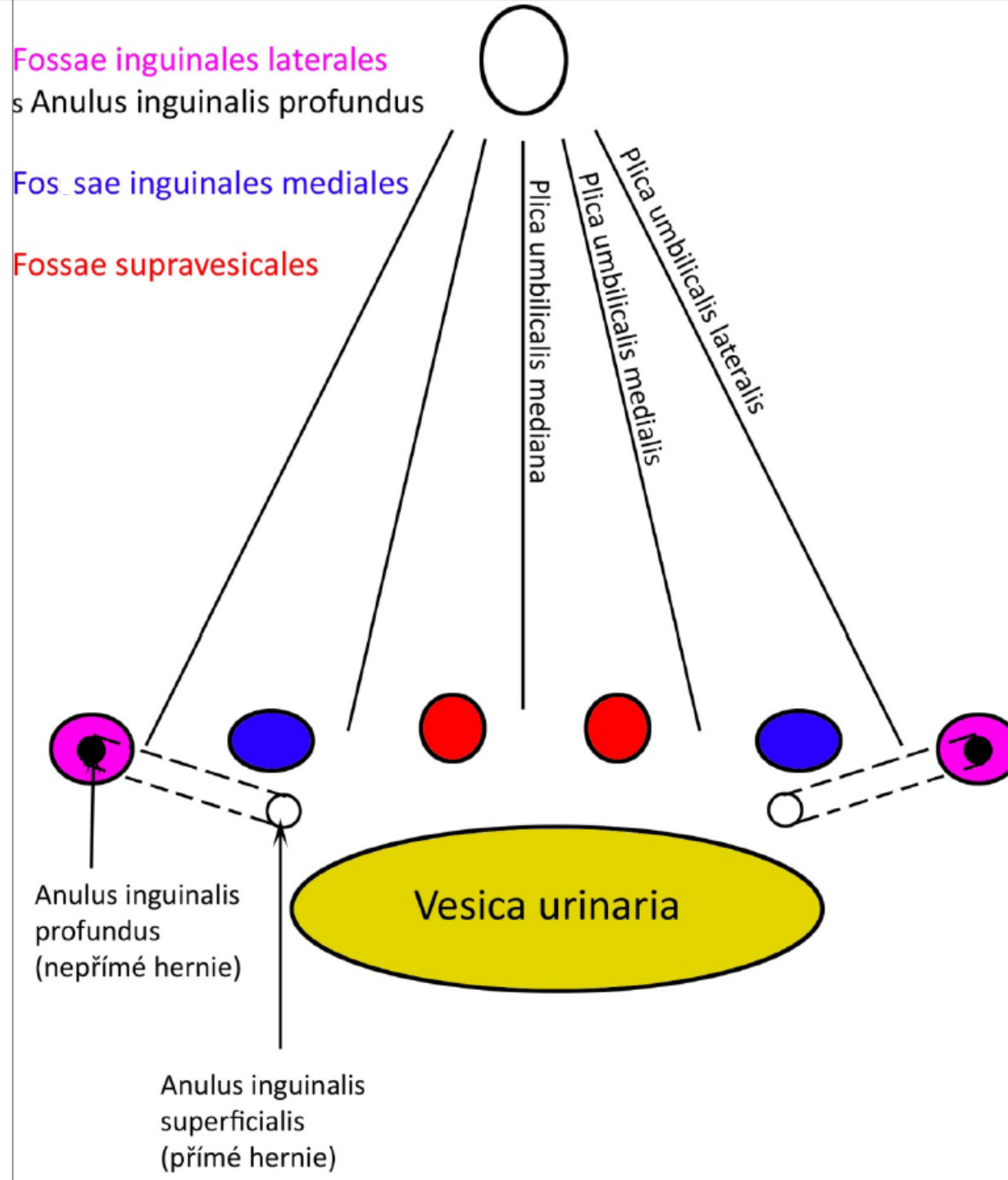
Lacuna musculorum et vasorum



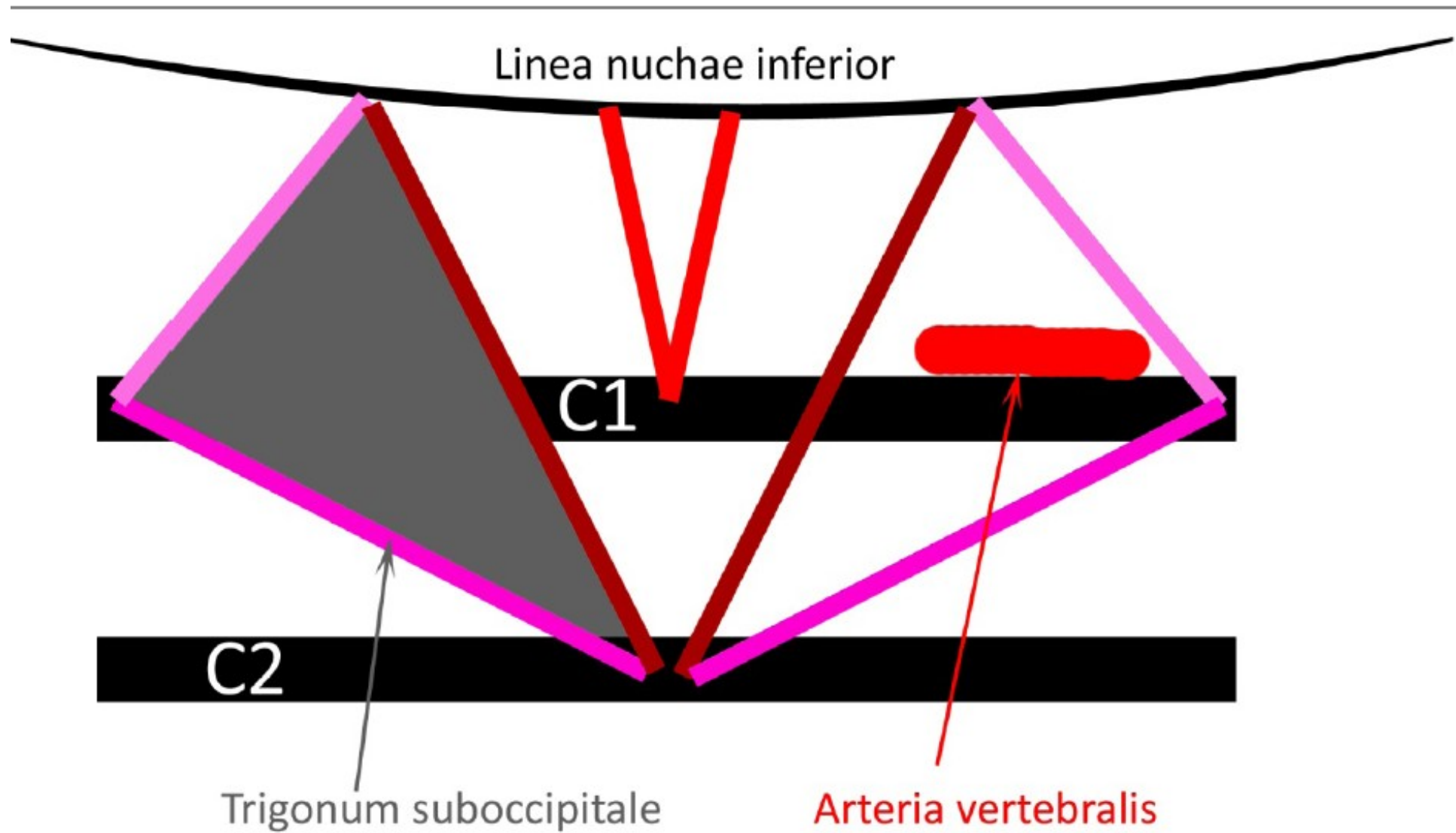
Plica umb.**mediana**=
Lig.umb.**mediale**=
obliterovaný urachus

Plica umb.**medialis**=
Lig.umb.**laterale**=
obliterovaná a.umbilicalis

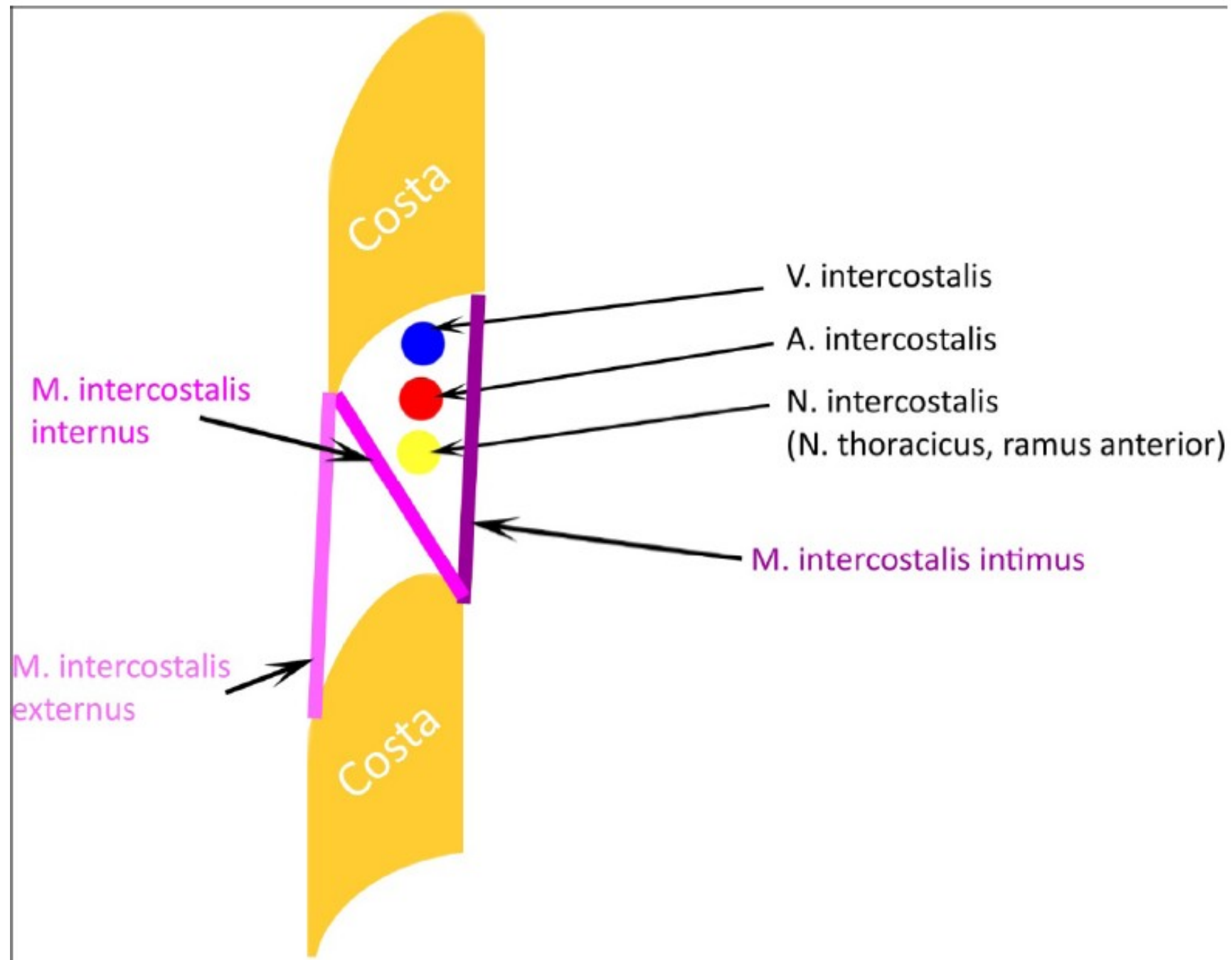
Plica umb.**lateralis**=
Lig.interfoveolare=
vasa epigastrica inferiora



Trigonum suboccipitale

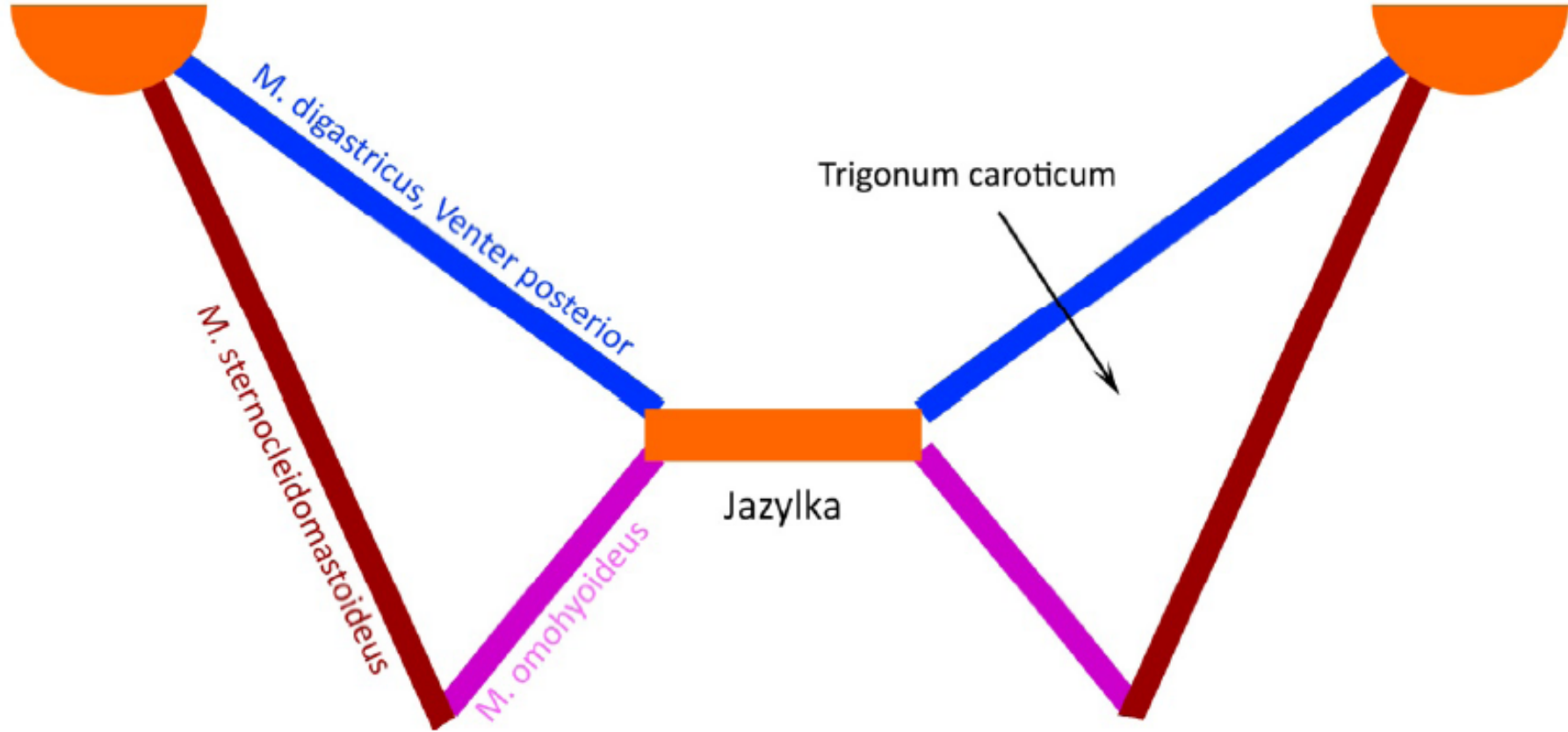


Průběh nervů a cév v mezižebří

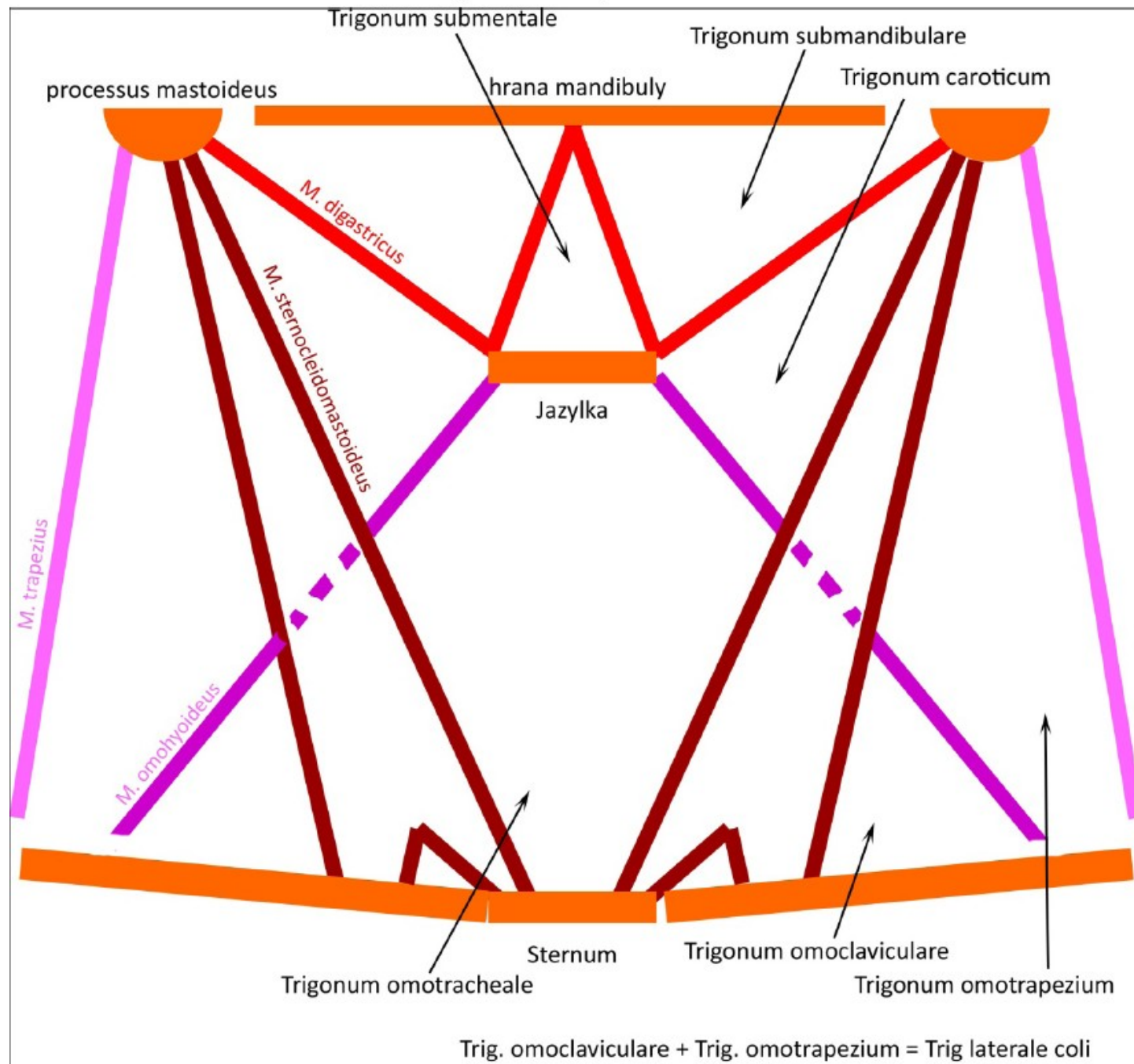


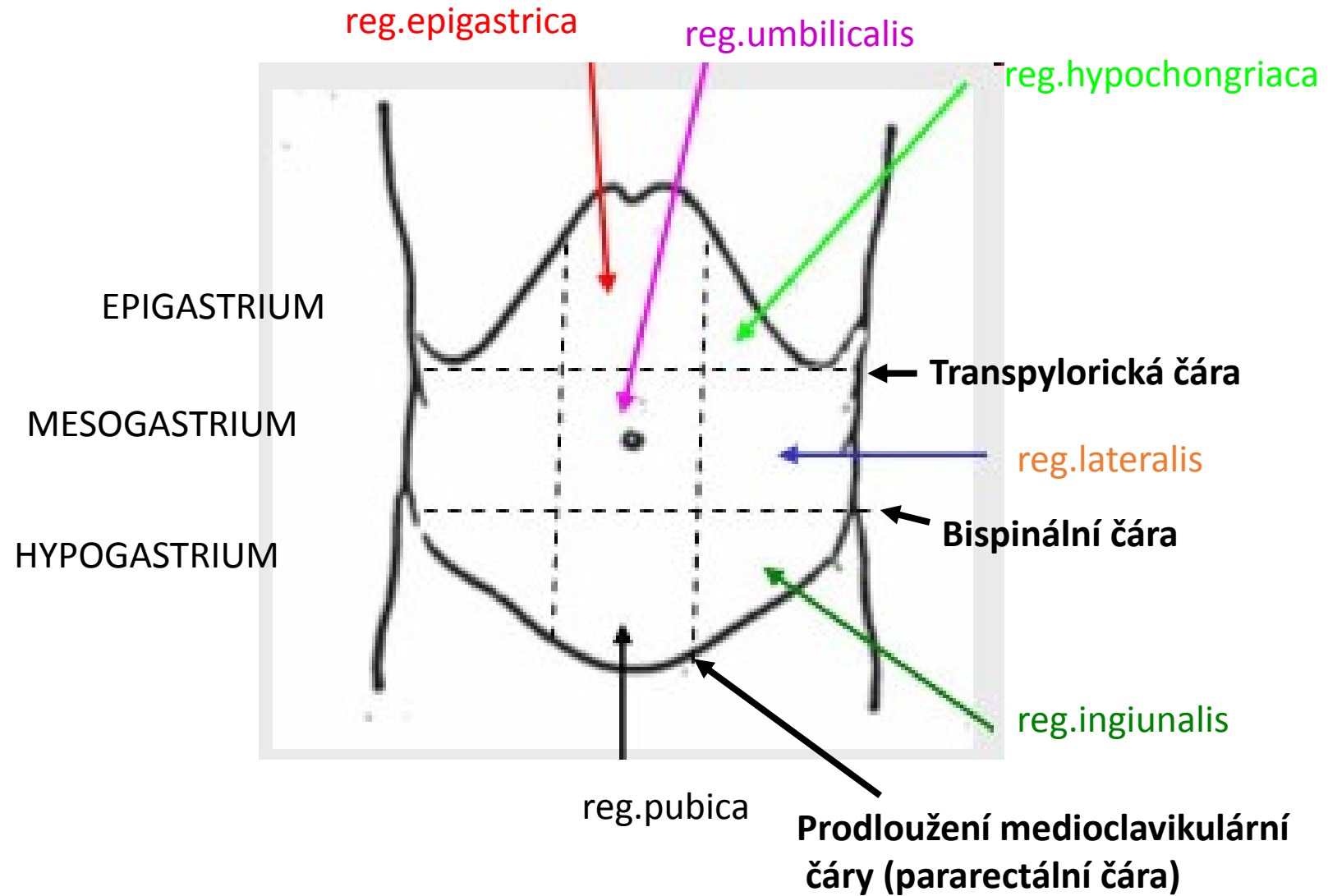
Trigonum caroticum

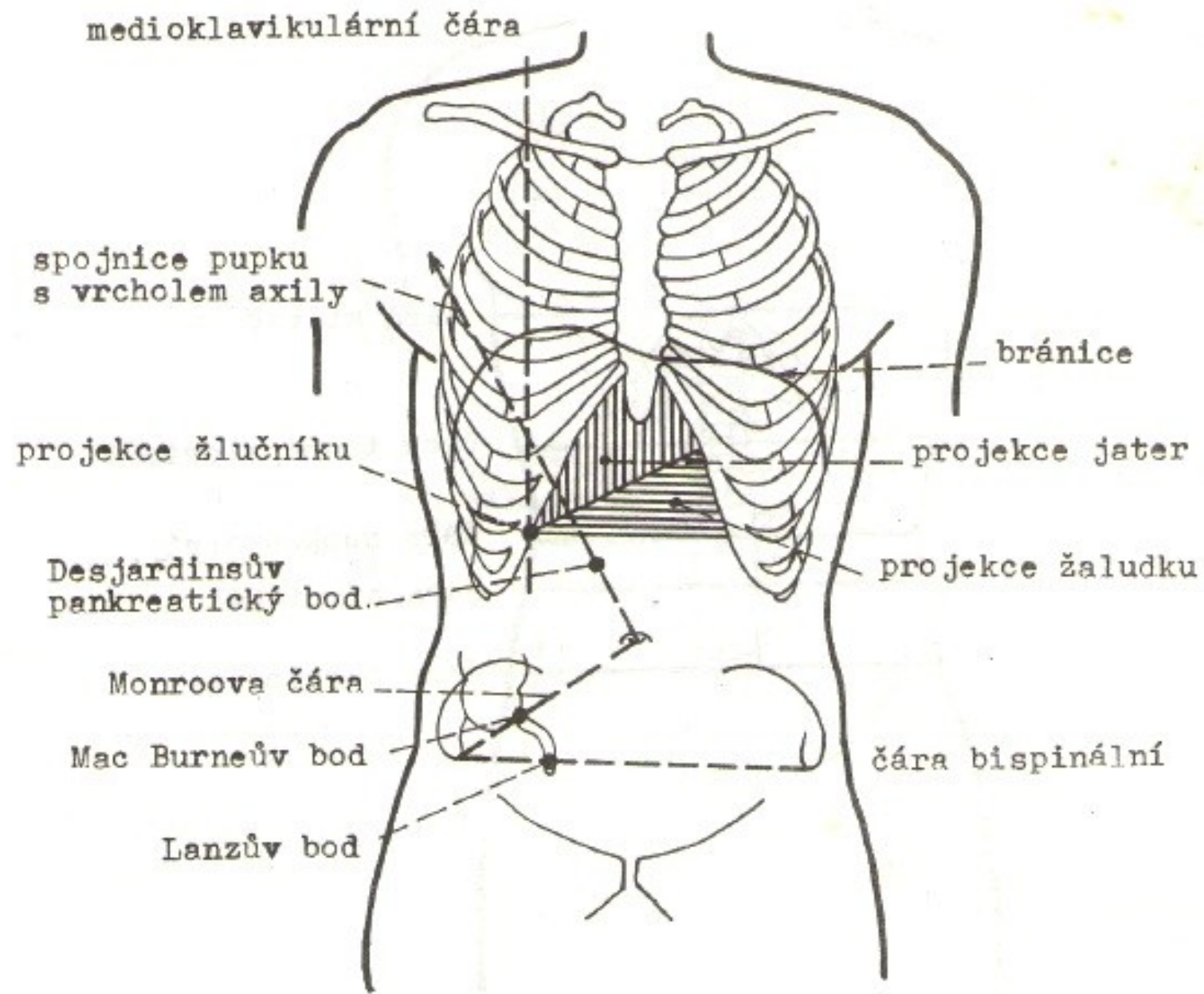
processus mastoideus



Trojúhelníky na krku







Obr.57. Projekce orgánů na přední stěnu břišní.