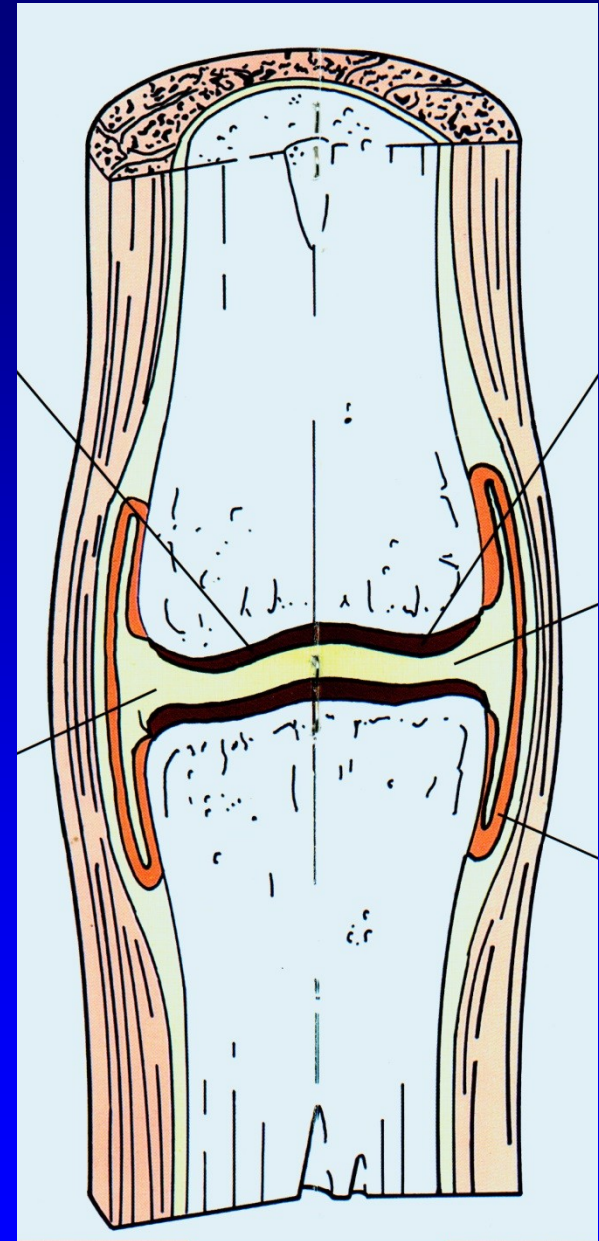


# Osteoarthritis

Z. Rozkydal

# Synovial joint

The end of bones  
Hyaline cartilage  
Ligaments  
Joint capsule  
Synovial membrane  
Synovial fluid



# Hyaline cartilage

Chondrocytes

Matrix – intercellular mass:

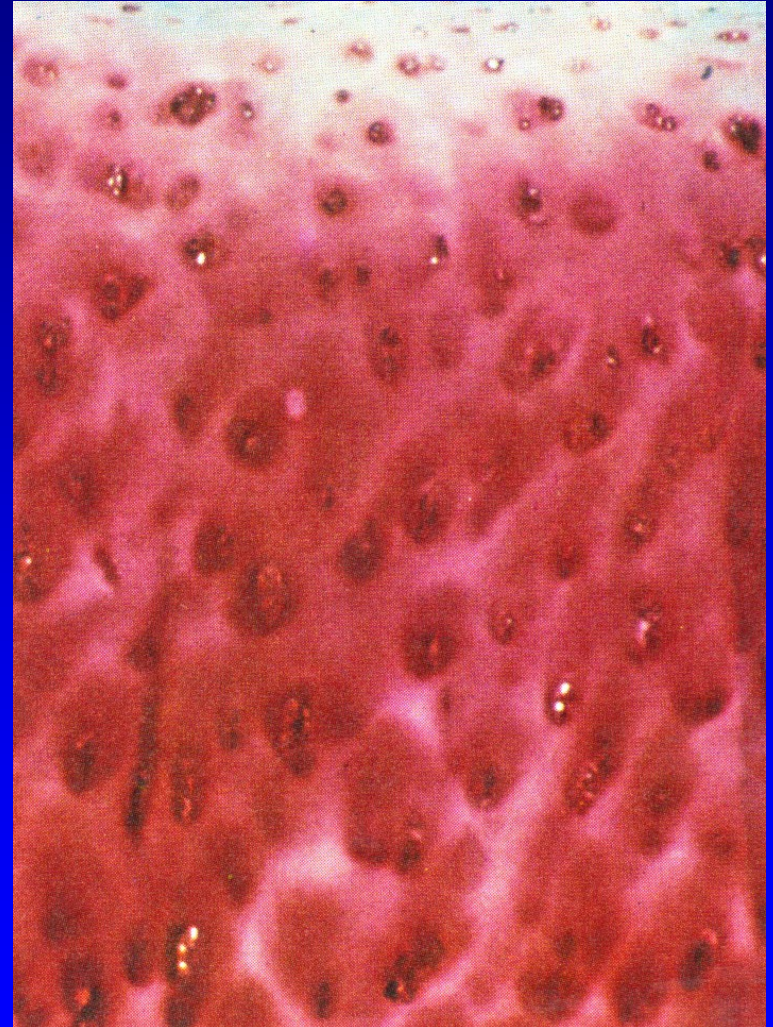
Fibrillar structure - collagen

Proteoglycans

Proteins of noncollagen nature

Hyaluronic acid

Water – 70 volume percent




# Hyaline cartilage

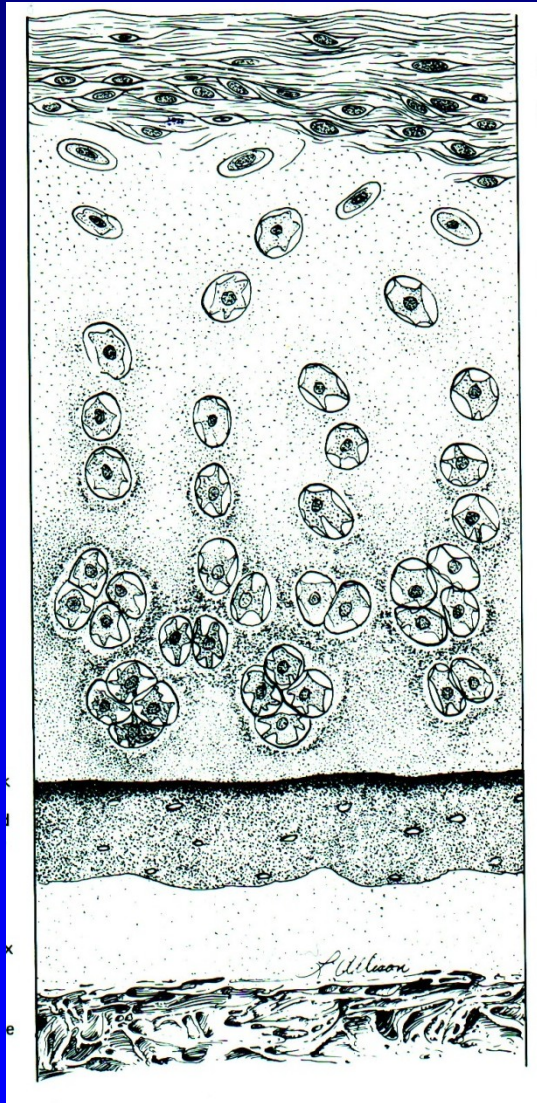
Chondrocytes- 2 percent of volume

Localised in lacunes of matrix

Isogenetic groups 2-8 cells  
from one mother cell



# Hyaline cartilage - layers



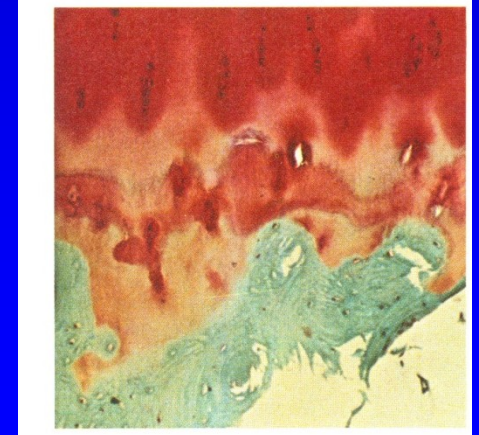
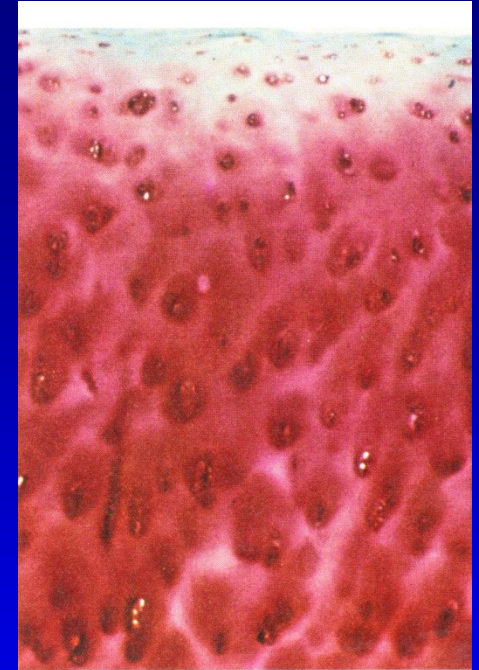
Superficial

Middle

Deep

Zone of calcifying  
cartilage

Bone



# Collagen

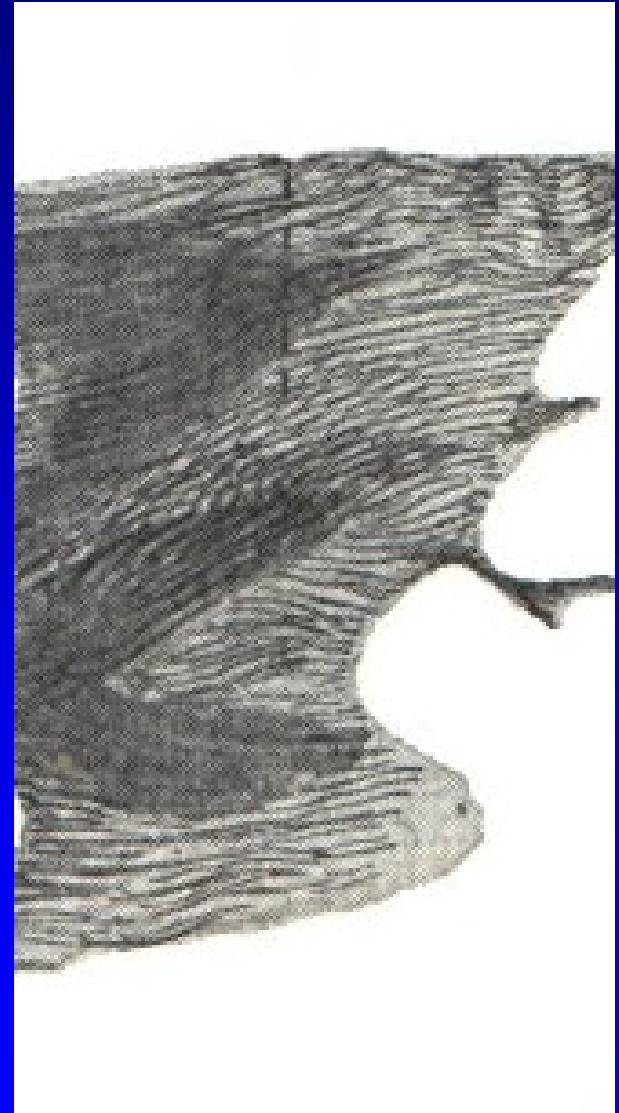Collagen type II (3 alpha-1 chains- 90 %)

Chains form fibrils

Fibrils form a three dimensional network

Parallel to the surface

In deep layers in columns



# Proteoglycans- PG

They are high hydrophylic  
- elasticity !!

Large PG - glukosaminoglycans:

Chondroitin 6- sulfate

Keratansulfate

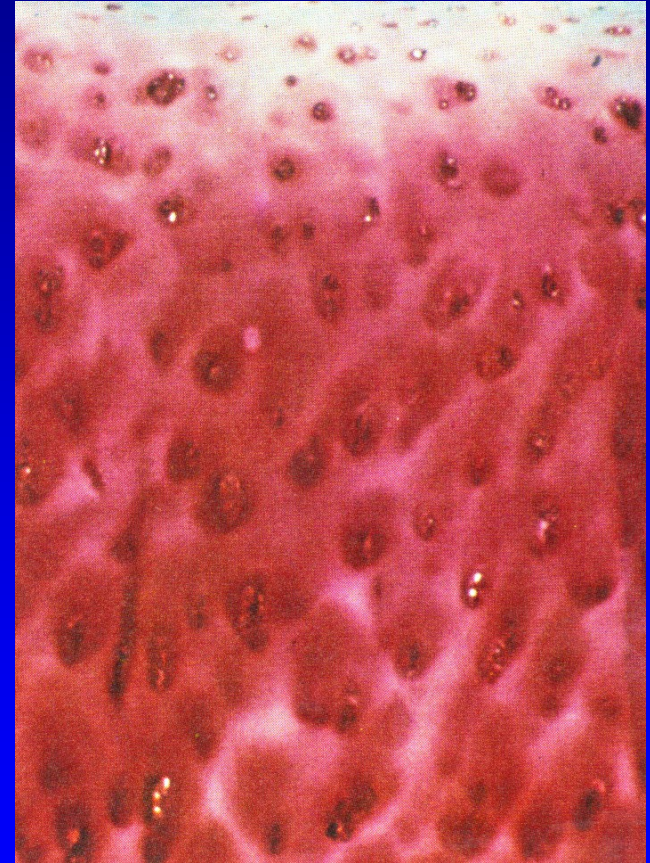
Chondroitin 4- sulfate

Small PG:

Decorin, biglycan

Agrecan – binds on hyaluronic acid

Sulfatan glukosaminoglycan



# Noncollagen proteins

Fibronectin, chondronectin

Anchorin

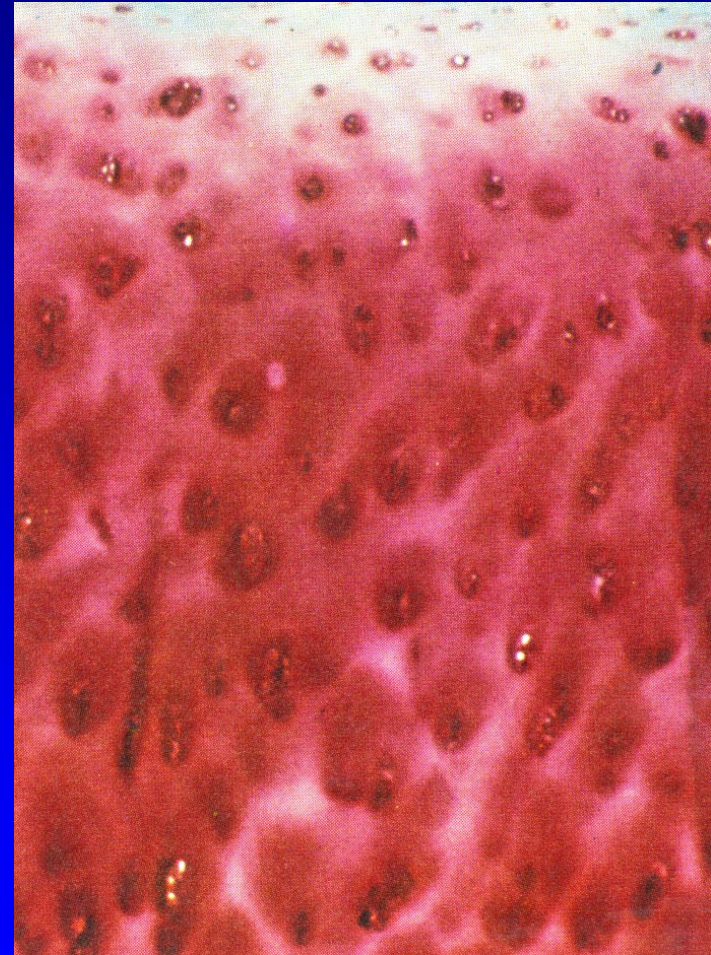
Cytocins- interleukin-1, interleukin- 6

Enzymes – metalloproteinase

(kolagenase, gelatinase)

Growth factors

Prostaglandins





# Hyaluronic acid- HA

HA + proteoglycans + collagen - intercellular mass

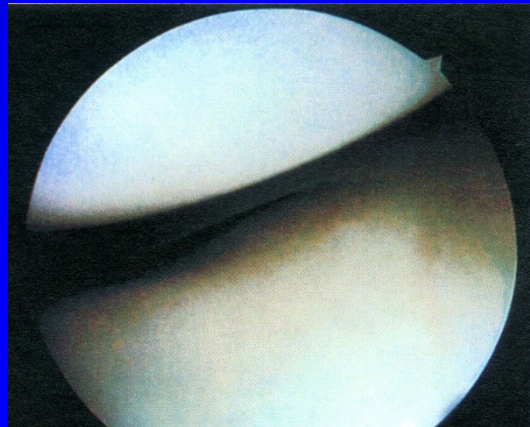
Hydrophylic, maintains homeostasis

Responsible for lubrication of the joint

Promotes transport of nutrients into the cartilage

Gives the cartilage elastic resistance

Gives rheologic properties to synovial fluid



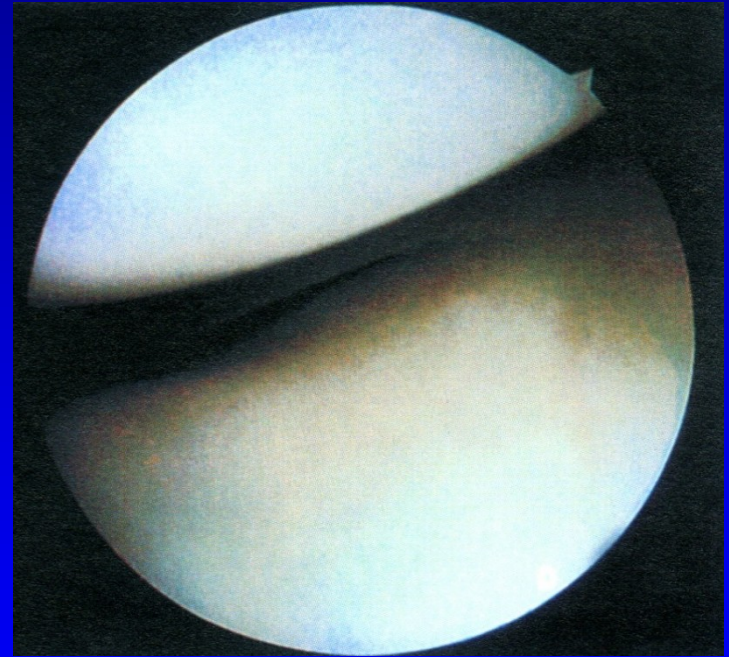
# Hyaline cartilage

High volume of water gives resistance in pressure

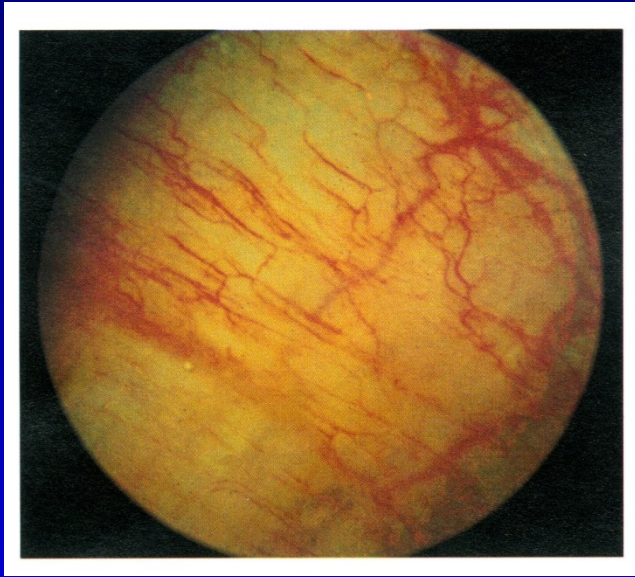Chondrocytes are nourished from synovial fluid

Cartilage has no vessels and nerves  
- low regeneration

The fluid is pushed by movements into the cartilage



# Synovial membrane



Network of vessels

It contains:

Cells A – macrophages

Cells B – produce hyaluronic acid

Cells C – mixed cells – properties of cells A and B

# Synovial fluid

Clear, slight yellowish

Viscous

The amount of 0,13-3,5 ml

Intracelular pressure:

-8 až - 12 ml H<sub>2</sub>O

Proteins- only one third  
of concentration in plasma



# Synovial fluid



Cytology:  $65/\text{mm}^3$  lymphocytes, monocytes, mononuclears

Mucin = hyaluronic acid and N-acetylglucosamin  
- gives viscosity

No fibrinogen

# Diseases of joints

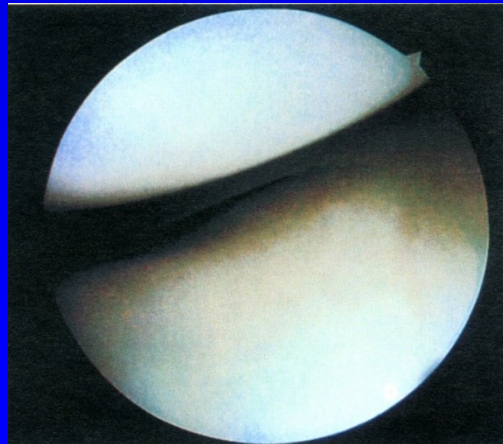
- Osteoarthritis deformans
- Rheumatoid arthritis
- Psoriatic arthritis
- Gout
- Ankylosing spondylitis
- Septic arthritis

# Diseases of joints

- Systemic arthritis (lupus erythematoses)
- Haemofilia
- Aseptic necrosis
- Osteochondritis dissecans
- Chondromatosis
- Neurogenic arthropathy
- Pigmented villonodular synovitis

# Osteoarthritis

- Degenerative, slow and progressive disease of hyaline cartilage of synovial joint
- All conditions changing the structure and function of hyaline membrane and surrounding tissues lead to osteoarthritis





# Osteoarthritis deformans

- Primary (after 40 years of age )
- Secondary – the cause is known

# Osteoarthritis

15 percent of the population

50 percent of people above 65 years

80 percent of people above 75 years

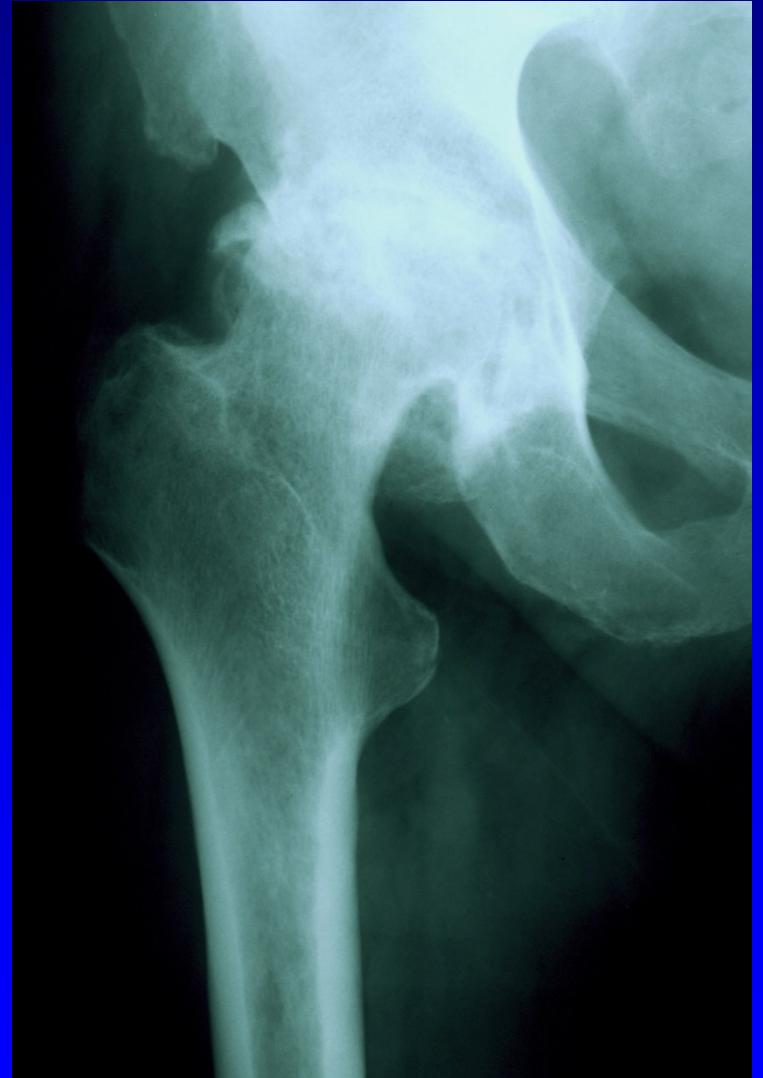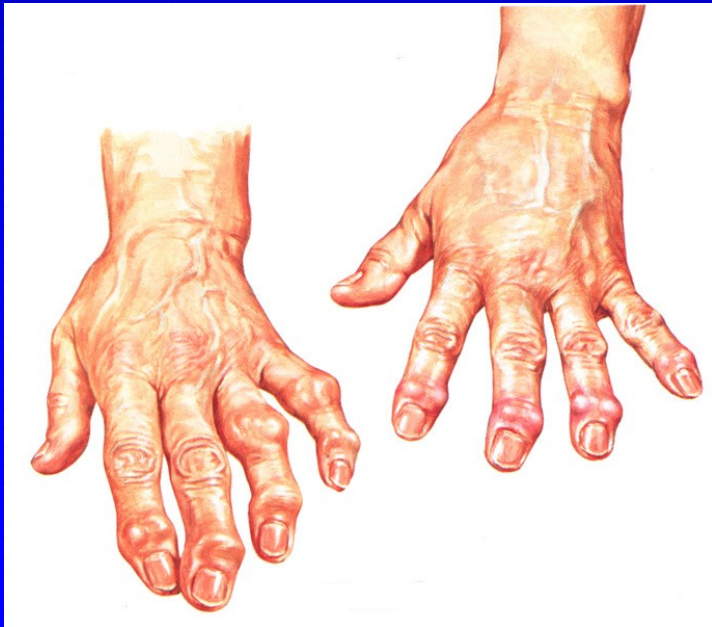# Primary O.A.

Begins over 40 y.

Small joint in hands

Cervical and lumbar spine

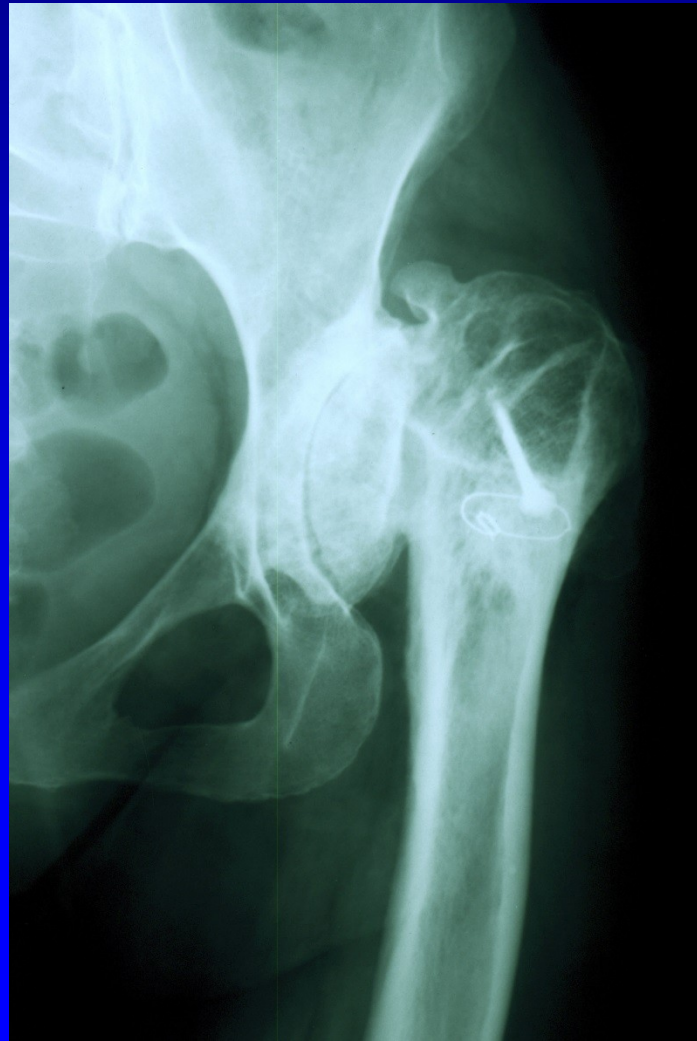Hip and knee joints



# Secondary O.A.

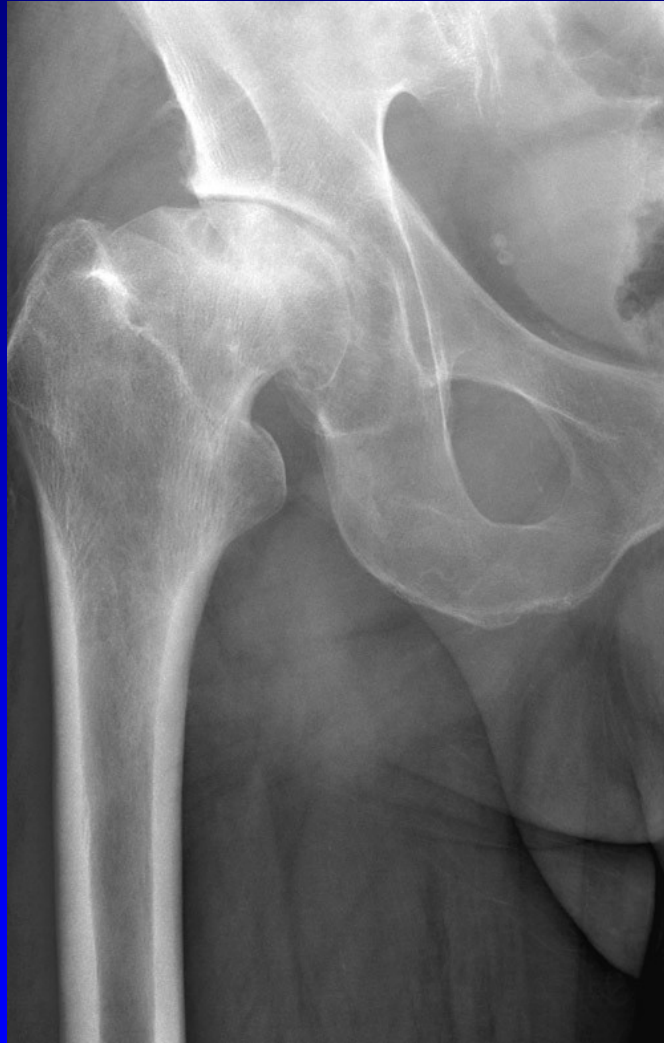1. Mechanical factors (DDH, Perthes disease, aseptic necrosis, slipped femoral epiphysis, condition after fractures)
2. Metabolic disorders (ochronosis, gout, chondrocalcinosis, Gaucher disease)
3. Hormonal disorders (acromegaly, diabetes m.)
4. Haemofilia
5. Inflamated disorders (septic arthritis, R.A.)

# DDH- developmental dysplasia of the hip joint



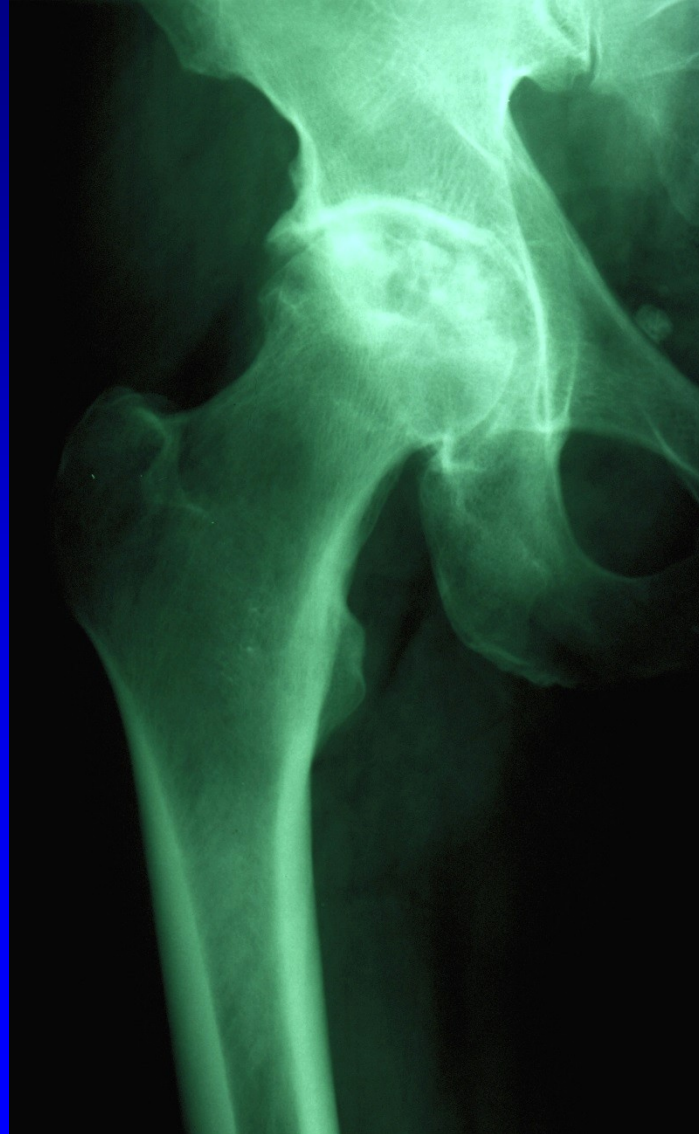Obr. 6

# Condition after Perthes disease



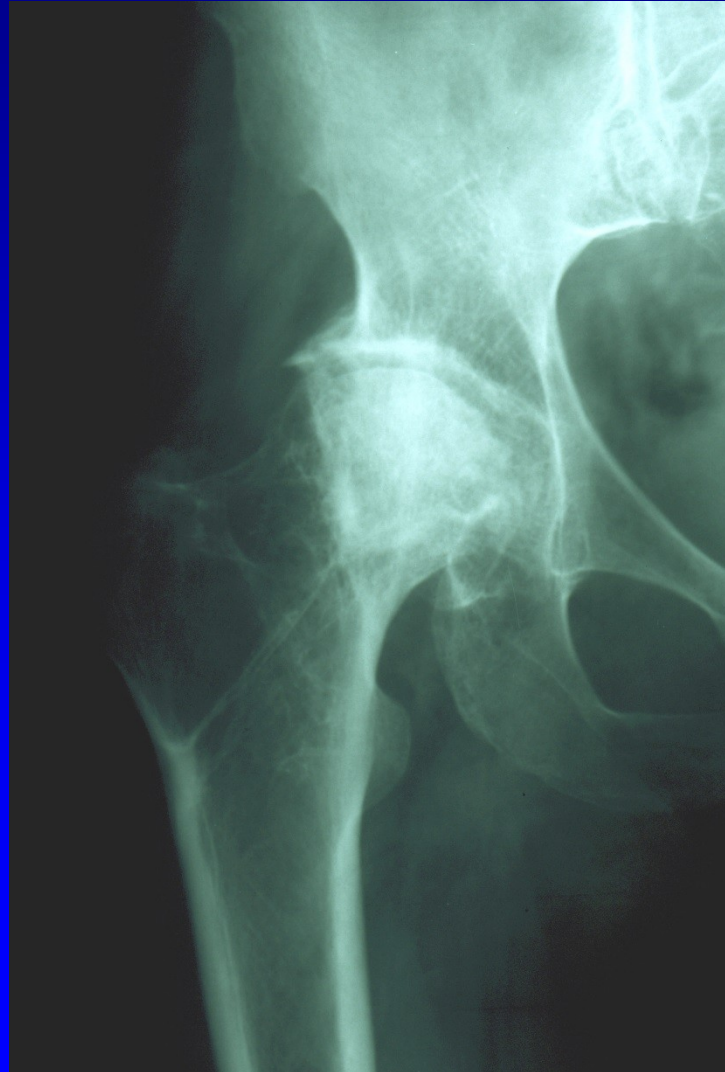
Obr. 8

# Idiopathic necrosis of the femoral head



Obr. 7

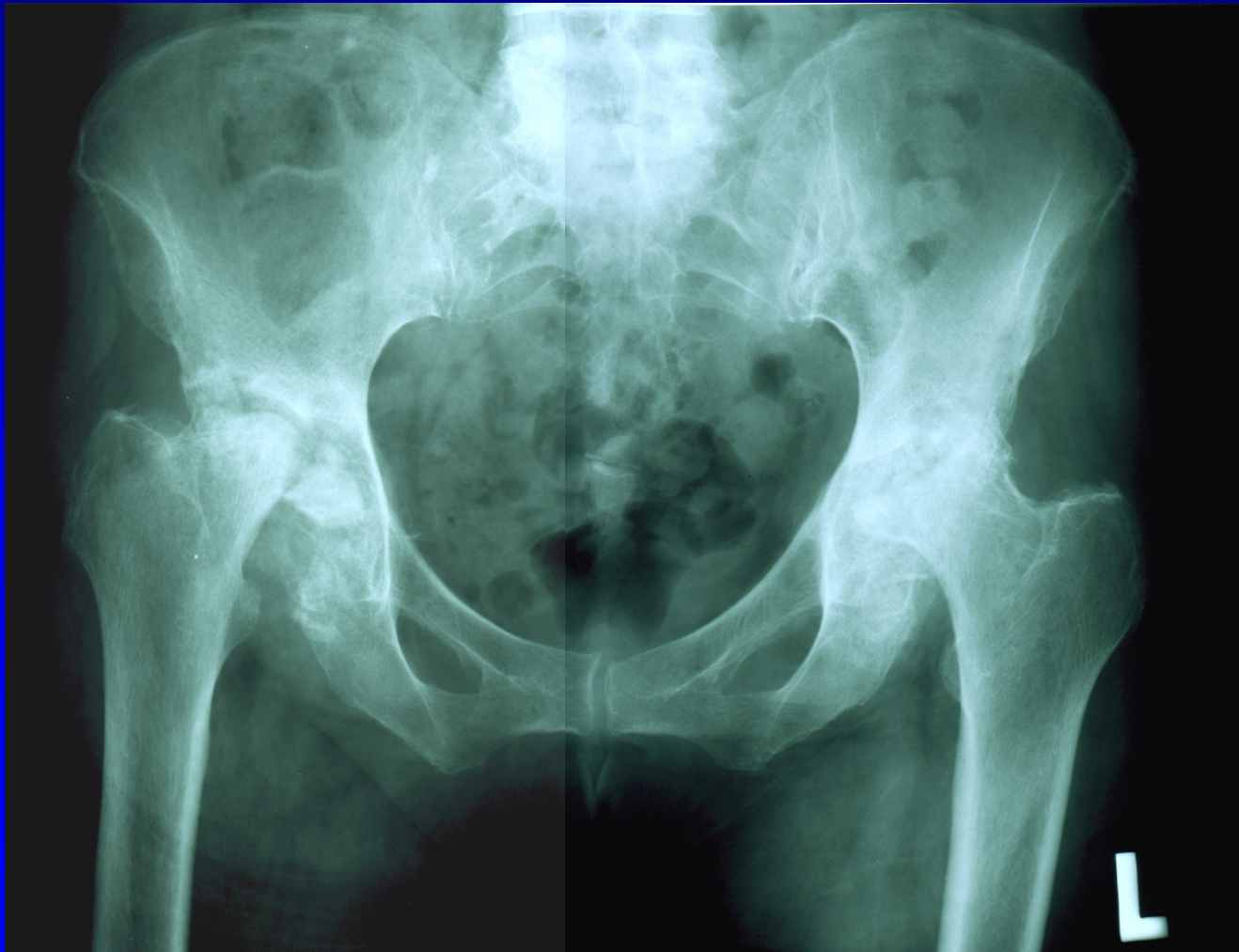
# Necrosis after femoral neck fracture



Obr. 9

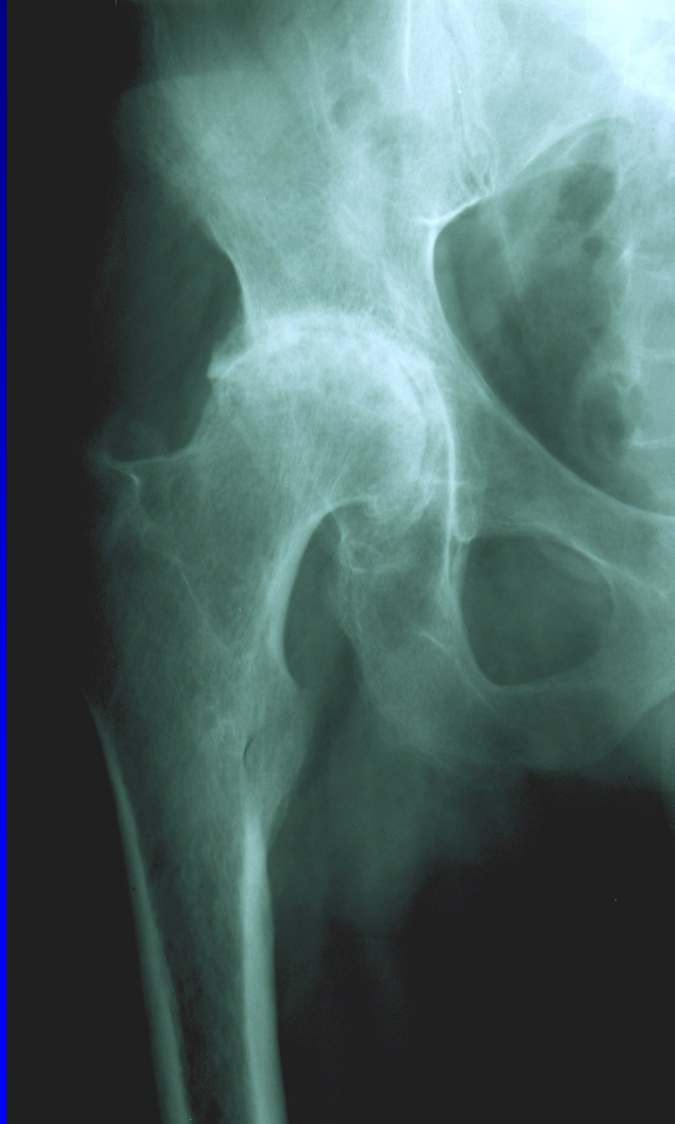


# Rheumatoid arthritis



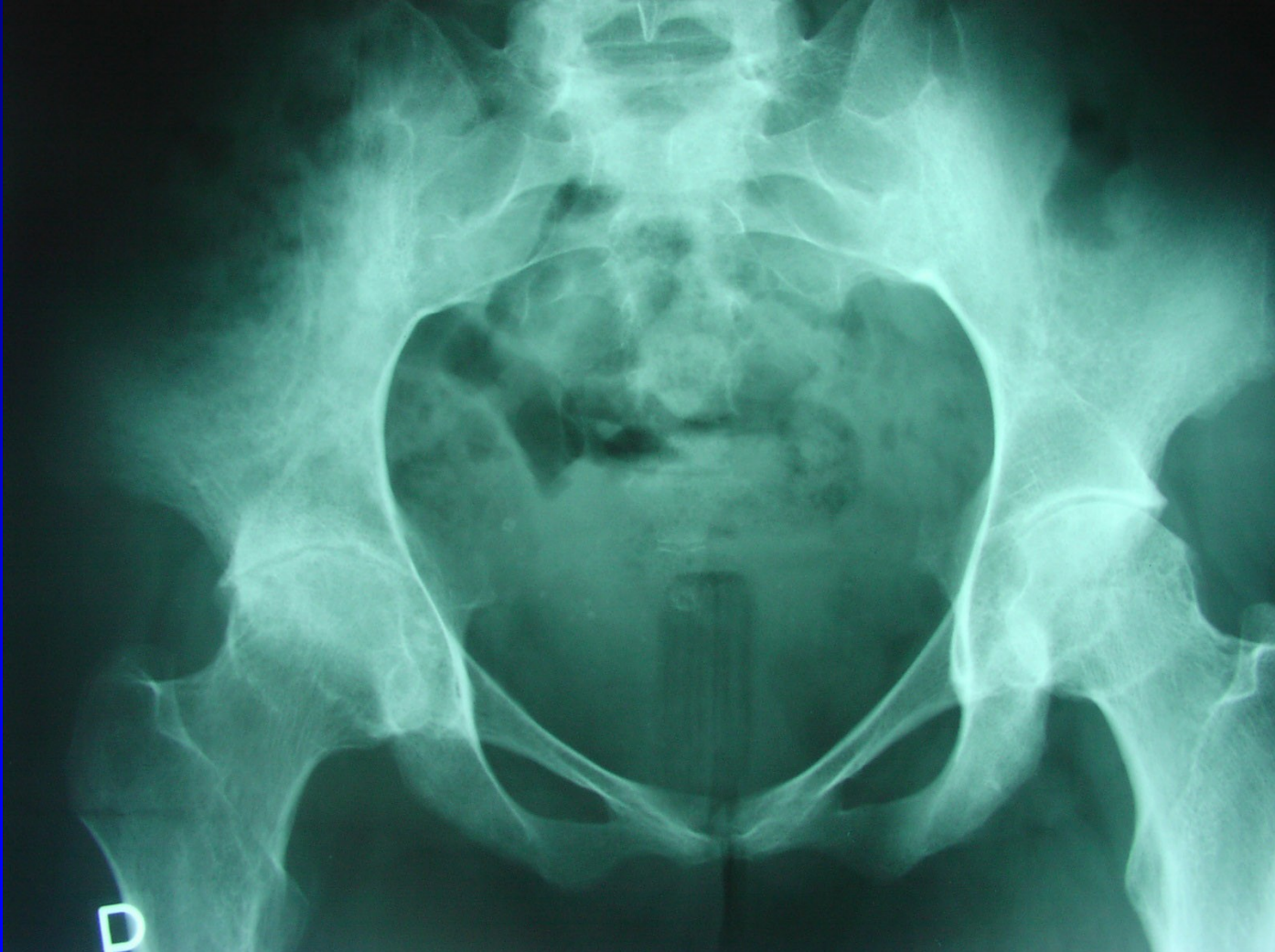Obr. 10

# Ancylousing spondylitis - hip joint



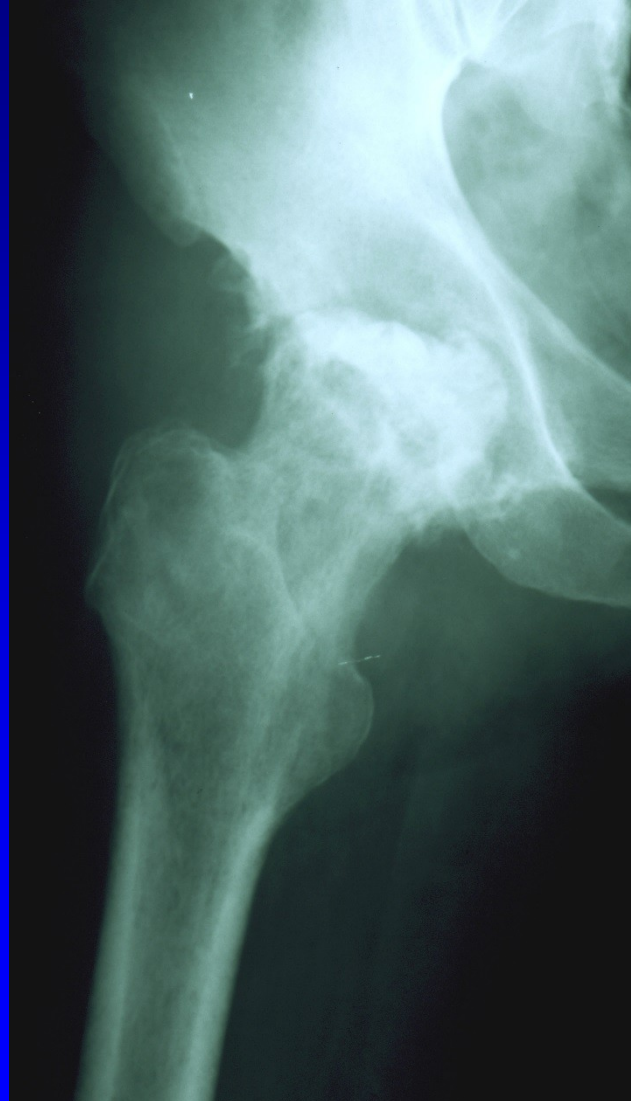
Obr. 11

# Ancyllosing spondylitis



Obr. 12

# Septic arthritis



Obr. 13

# Risk factors

Age over 50 years

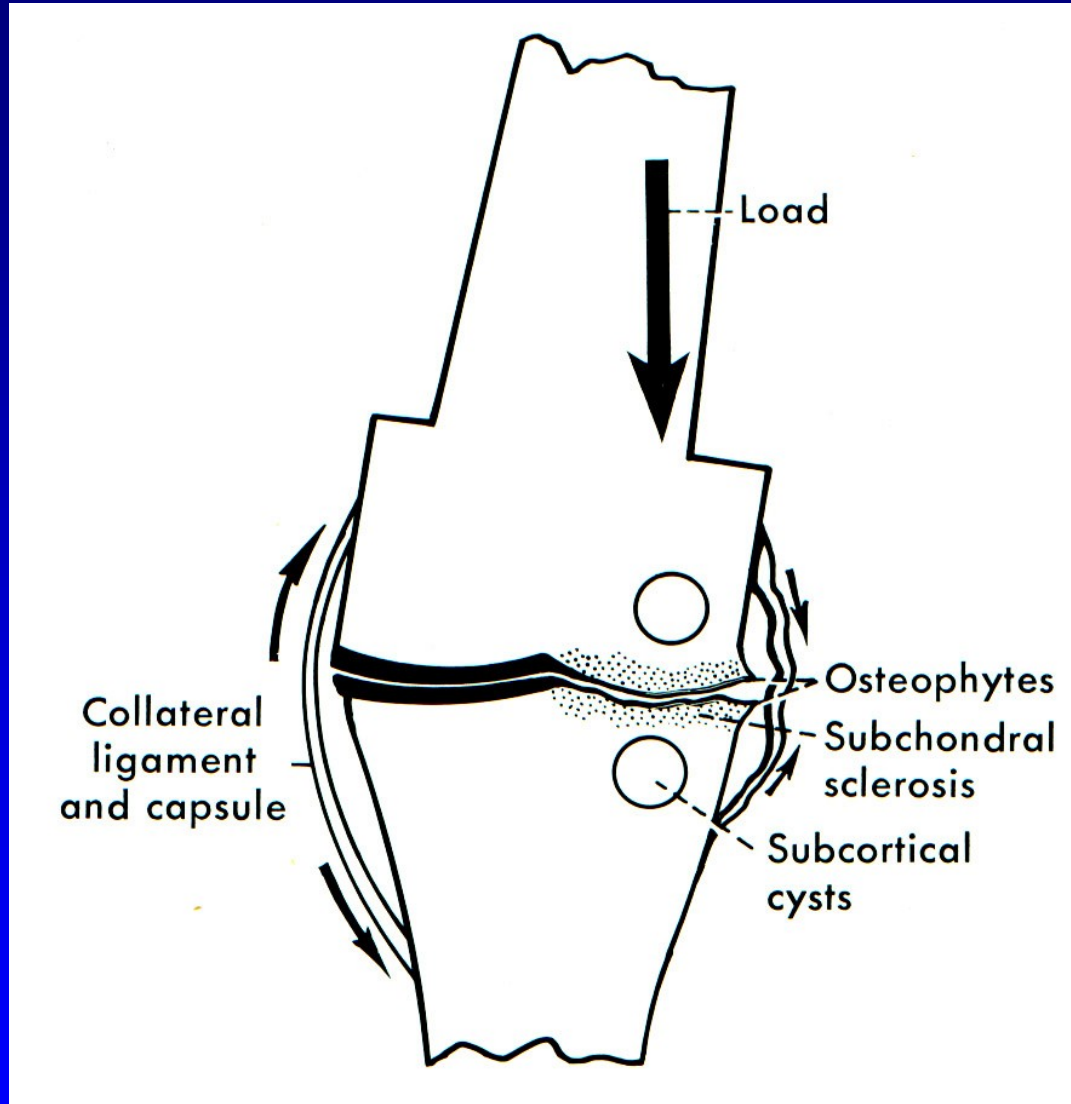
Obesity

Mutation of gene for procollagen II (COL2A1)

Autosomal gene for Heberden's nodes  
is dominant in female and recessive in male

Female are involved twice oft than male  
- after 55 years – postmenopausal defecit of  
estrogens - O.A. is more often

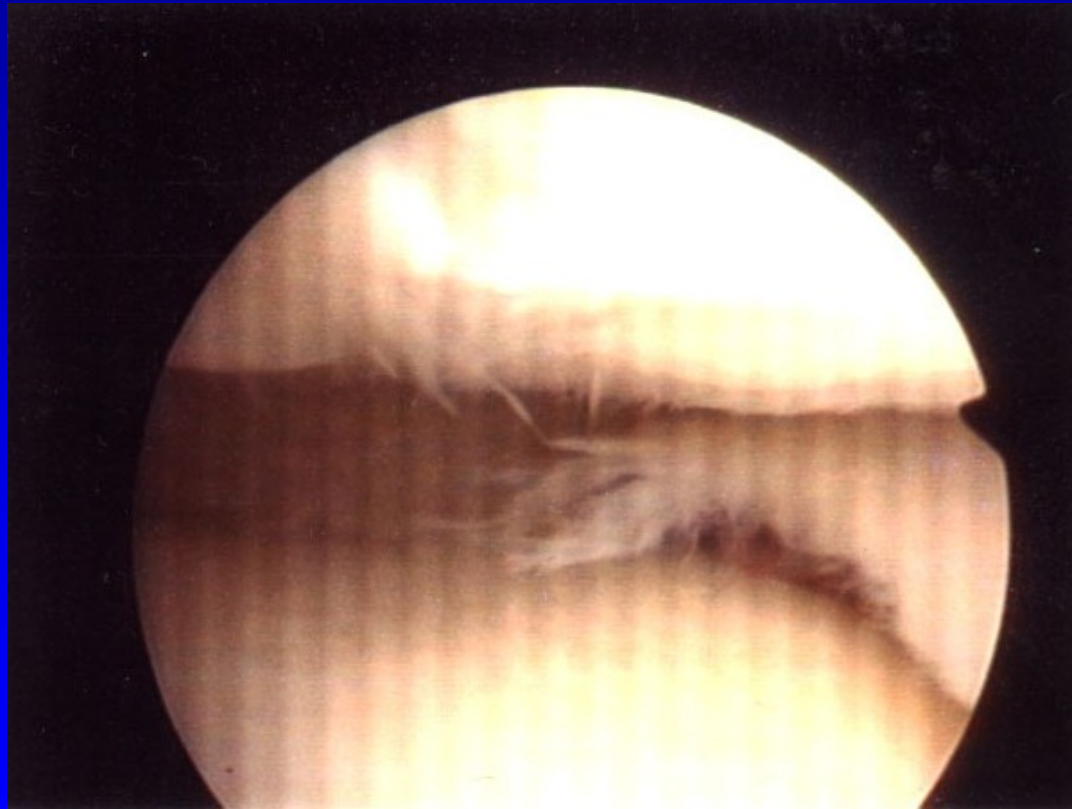
# Mechanical O.A.



Obr. 14

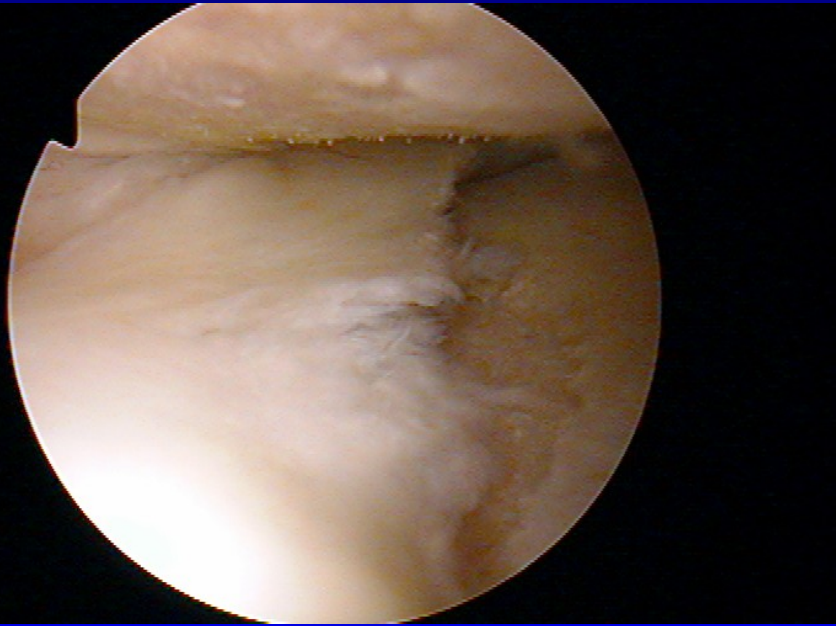
# Macroscopic changes

Cartilage is matte, soft, yellowish, fibrillations

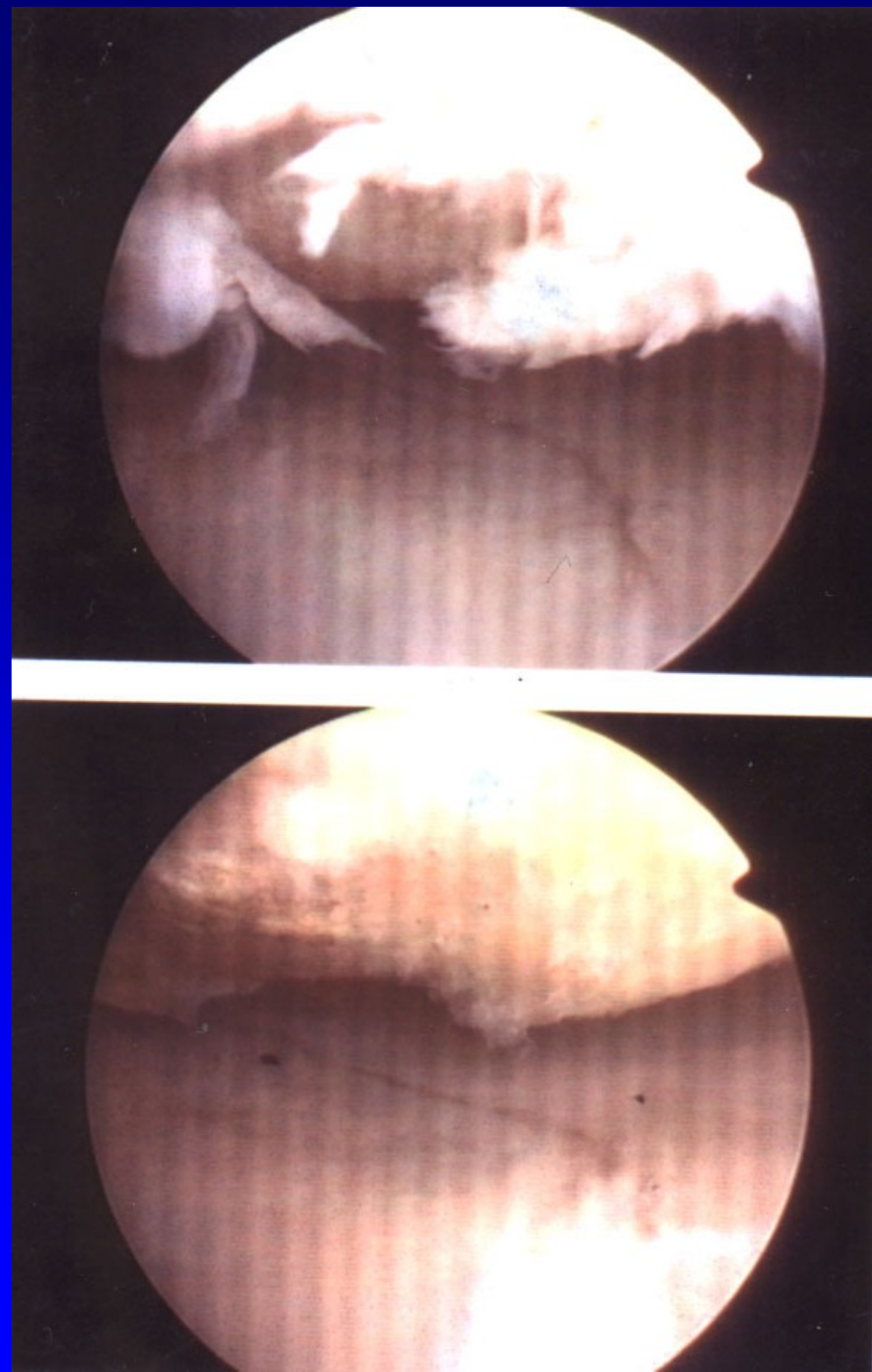


Obr. 15

# Ulcers, defects



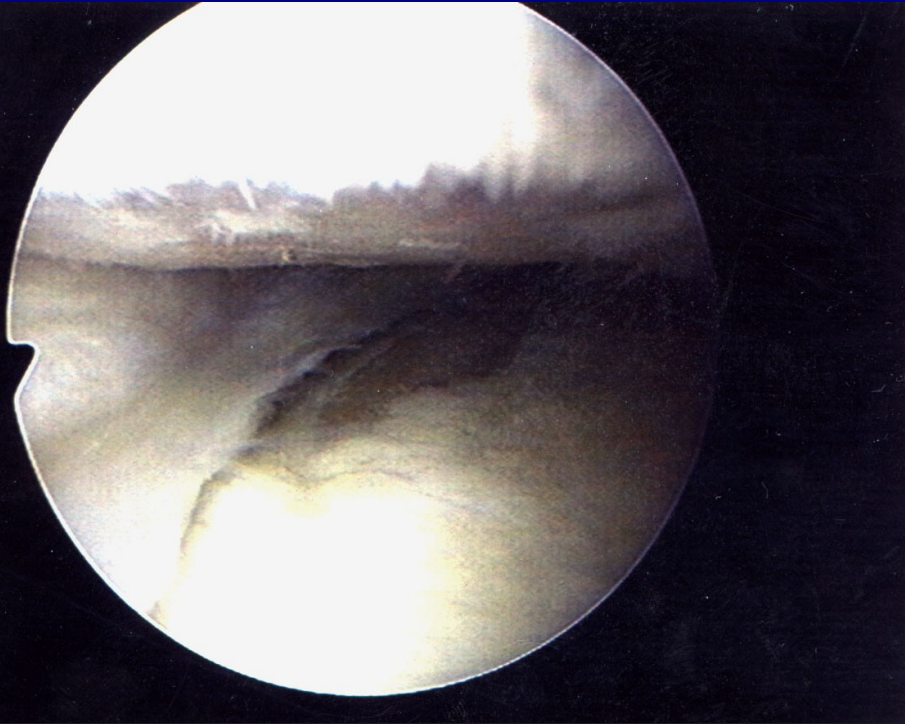
Obr. 16



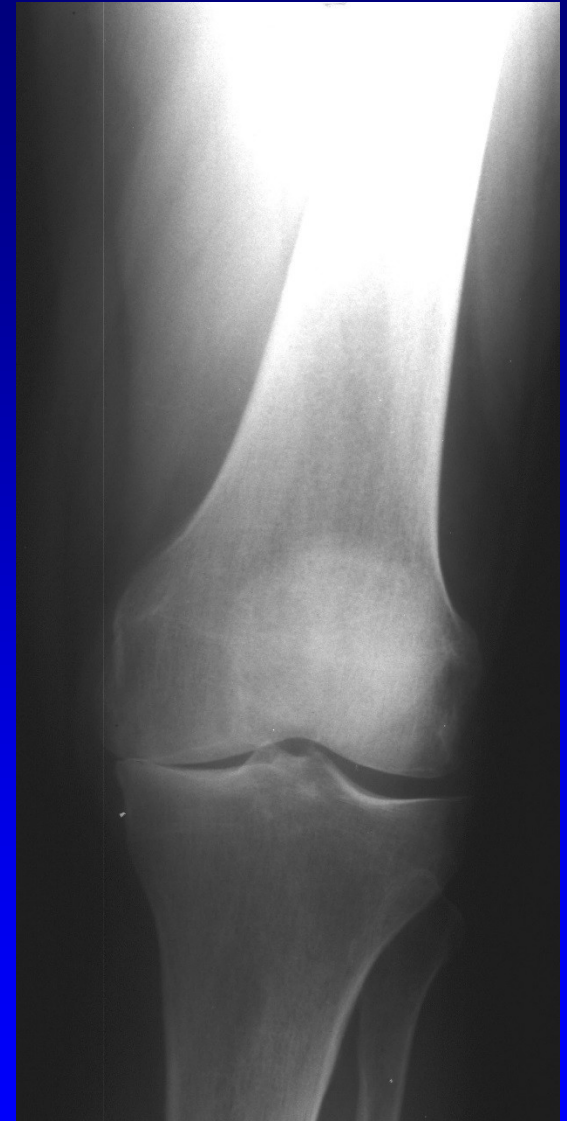
Obr. 17



Subchondral bone is sclerotic



Obr. 18



Obr. 19

# Macroscopic changes

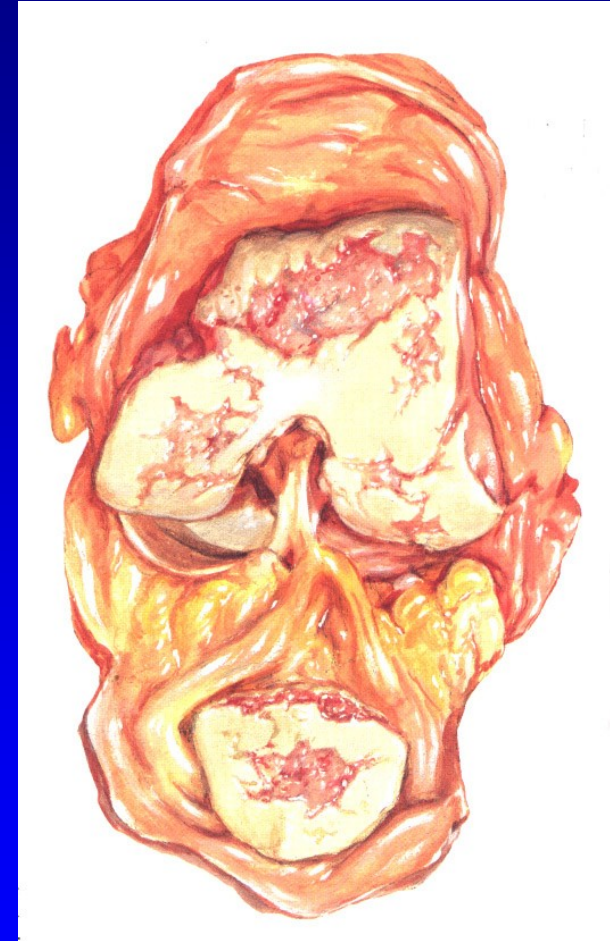Subchondral cysts

Osteophytes

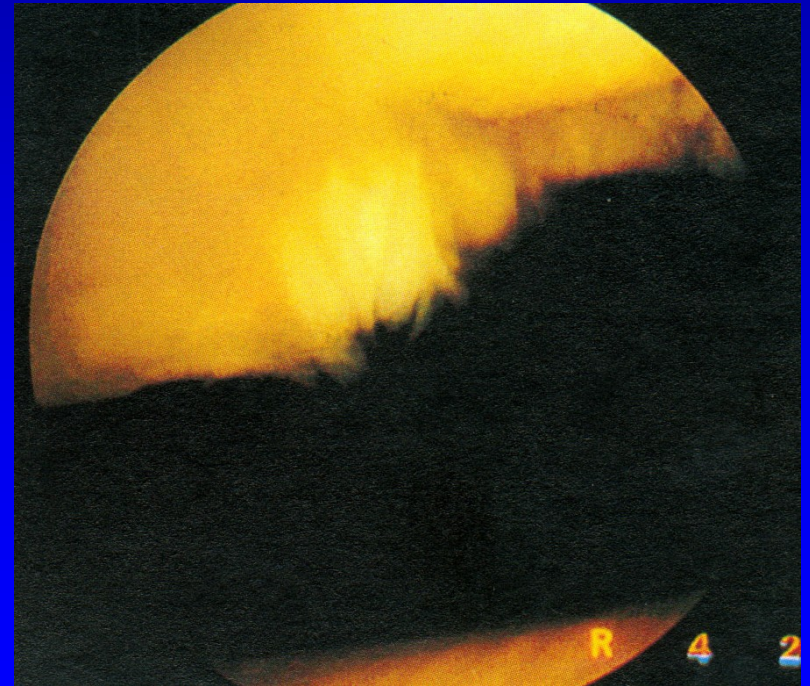
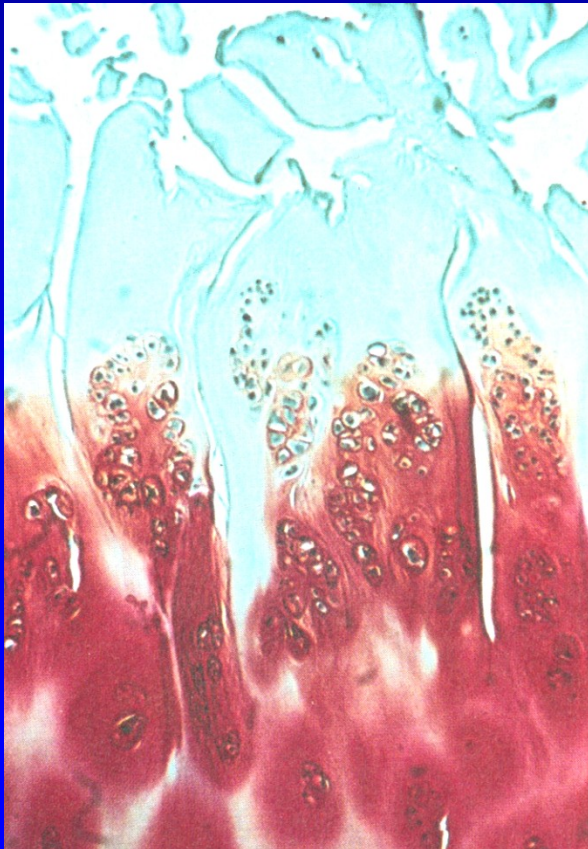
Narrowing of cartilage

Hypertrophic synovial membrane

Loose bodies

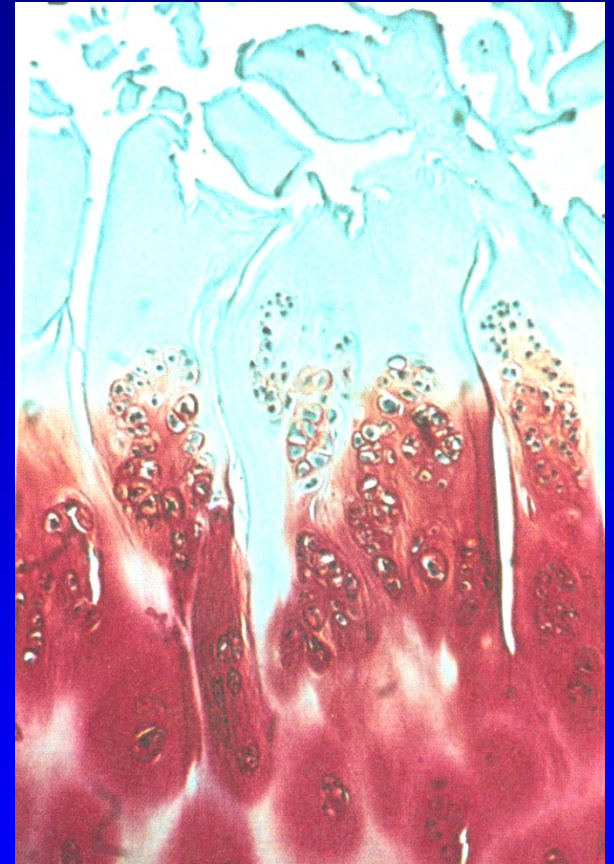


Chondrocytes make clusters in 10-20  
Irregularities of the surface  
Lamina splendens is absent, fibrillations  
Fissures, defects of cartilage  
Collagen network is disturbed



# Biochemical changes

- Higher amount of water
- Synthesis of PG is higher
- Loss of proteoglycans is high
- Chondroitin 6 sulfate - less
- Ketaransulfate- less
- Condroitin 4 sulfate is higher



# Clinical symptoms

Pain, mild, in weather changes, later is higher

Stiffness

Effusion, synovitis

Limping, difficultis in standing and walking

Muscle atrophy, joint contracture

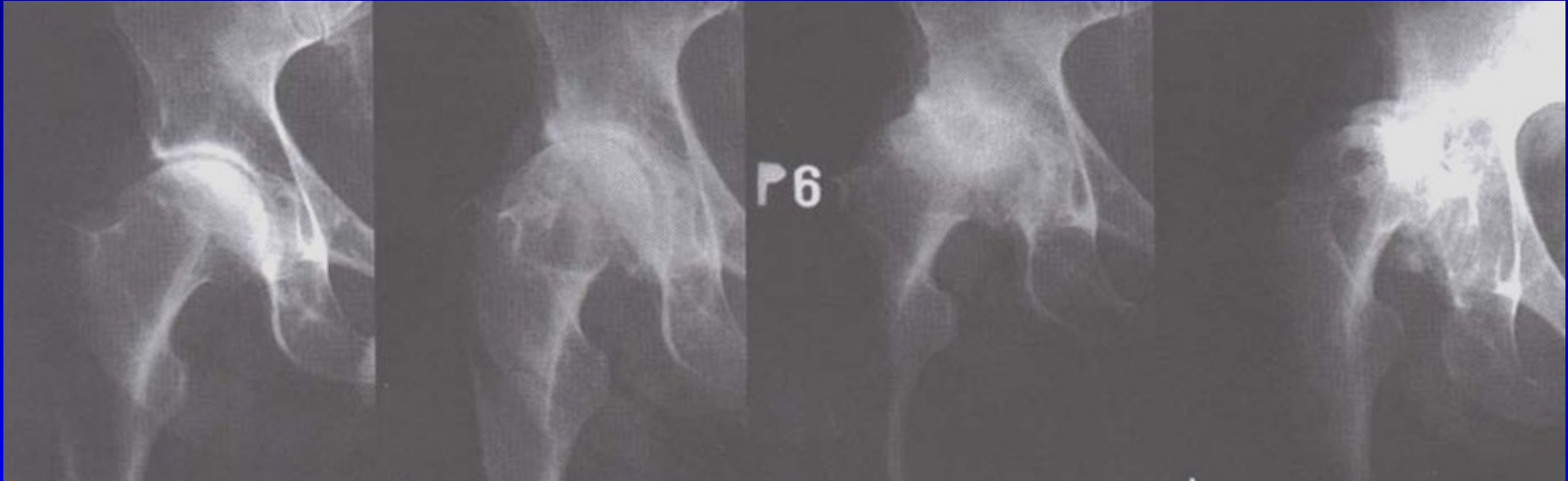
Malalignment

I.

II.

III.

IV.

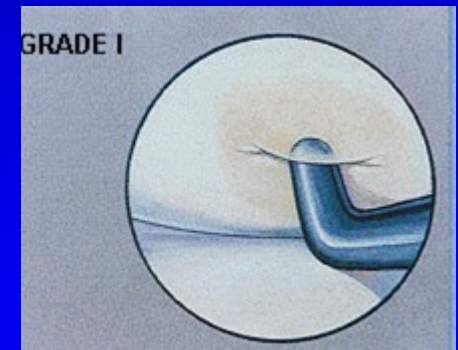
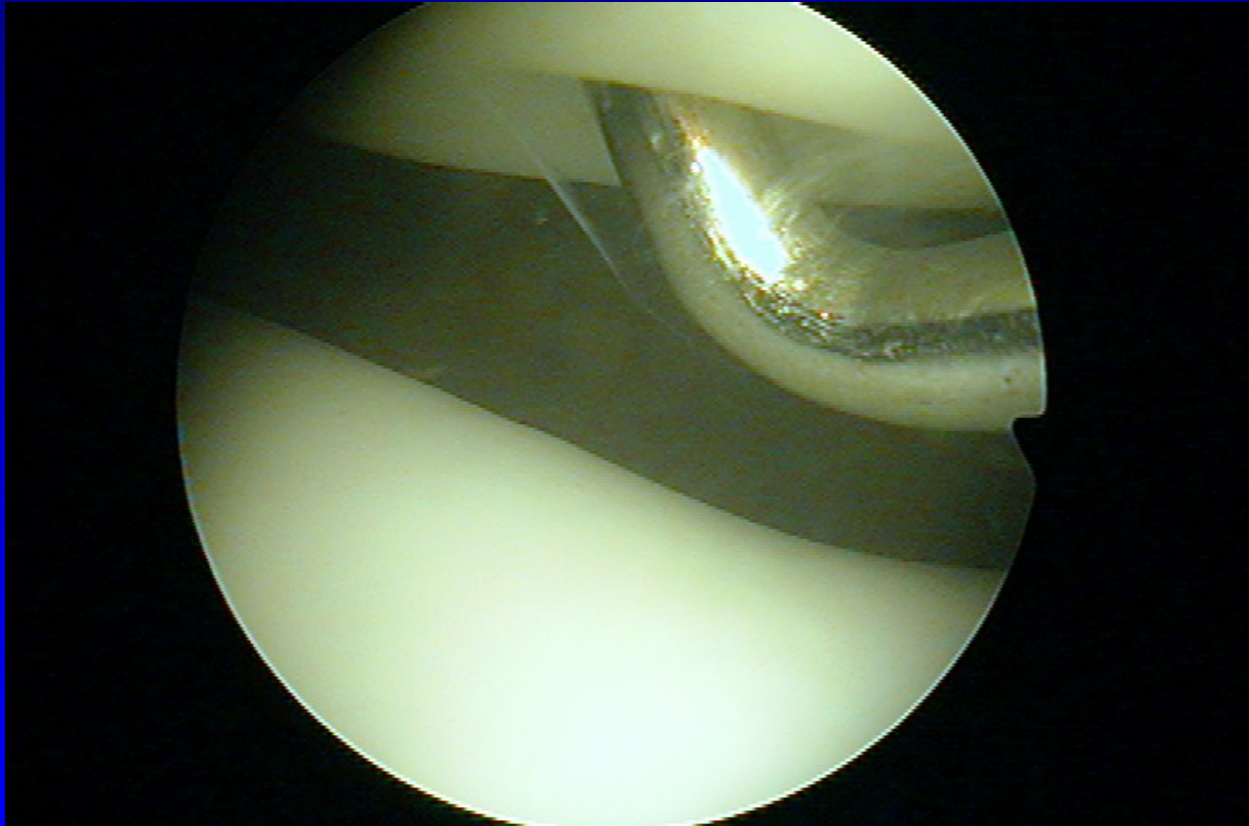


Kellgren- Lawrence classification I- IV.

# Chondropathy

- 1 Softening and swelling
- 2 Fragmentation and fissures up to 1,3 cm
- 3 Fragmentation and fissures above 1,3 cm
- 4 Erosions up to subchondral bone

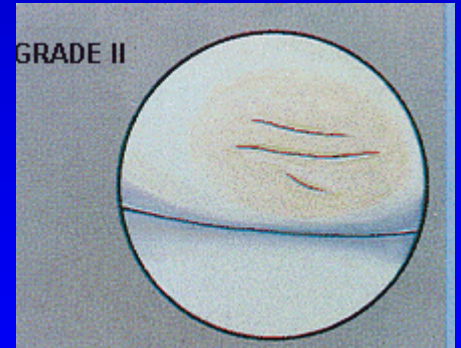
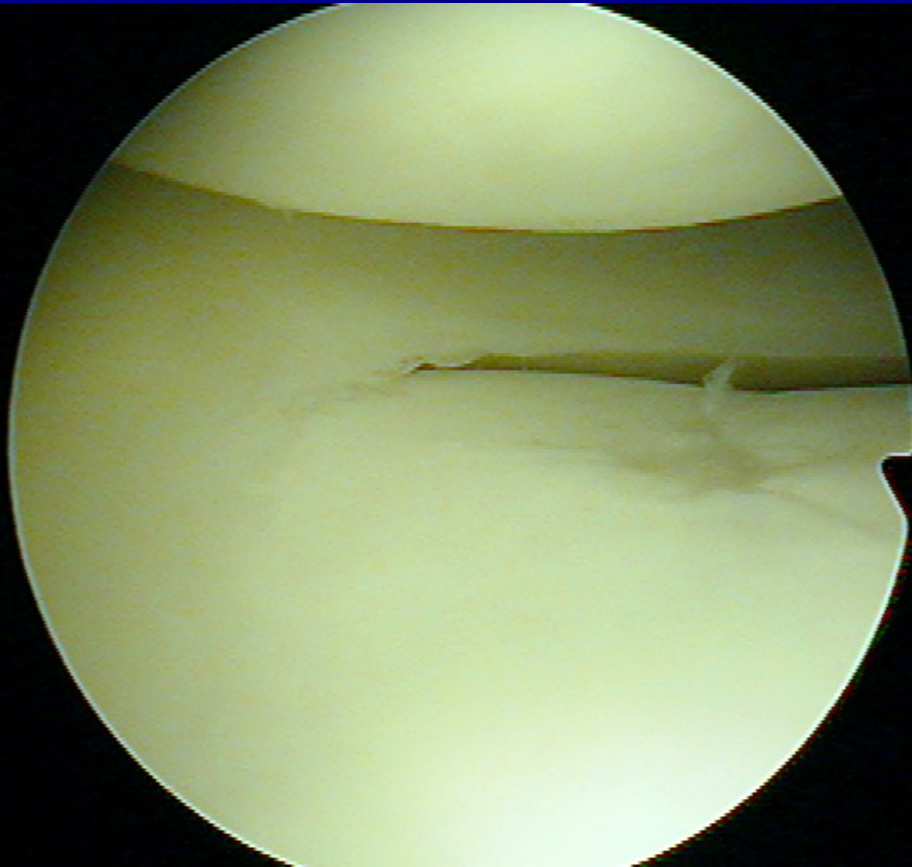
# Chondropathy I. st.



**Chondromalacia- soft cartilage**

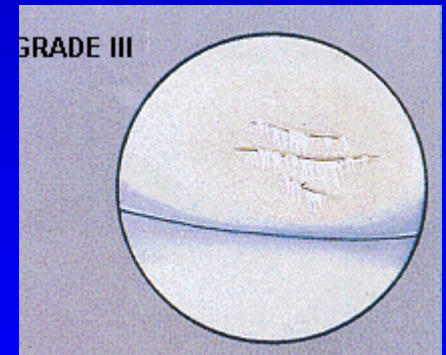
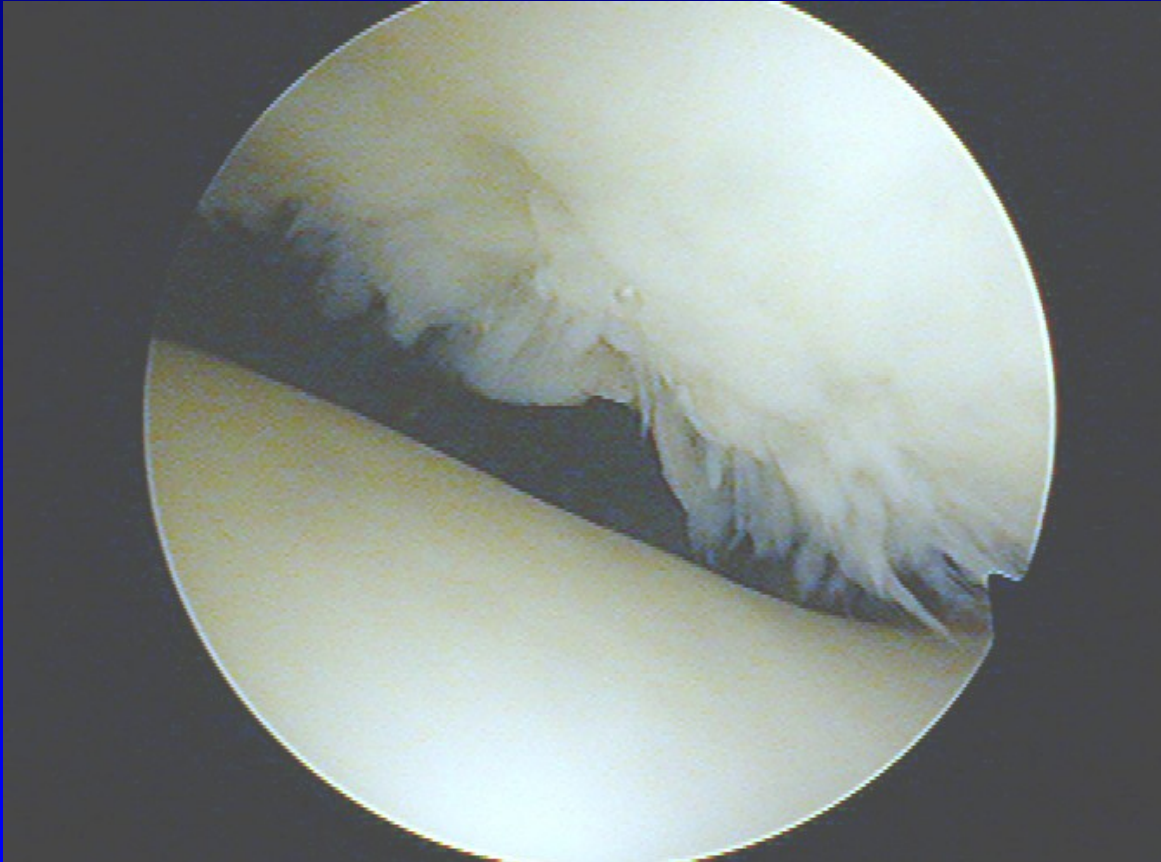


# Chondropathy II. st.



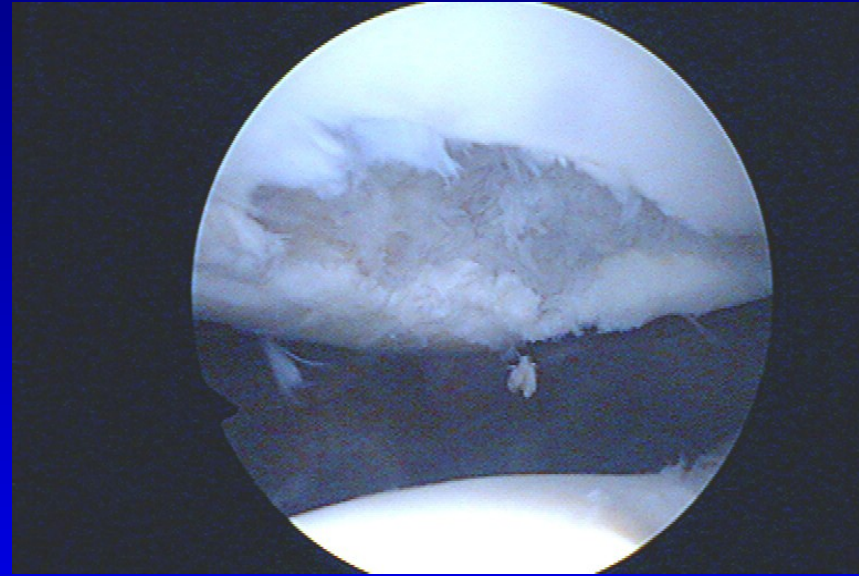
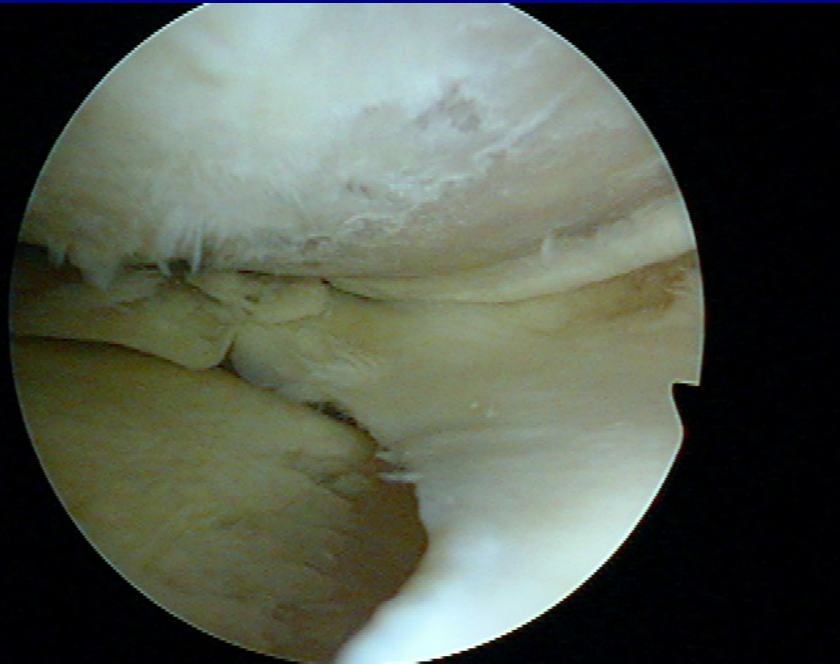
**Fissures in the cartilage**

# Chondropathy III. st.

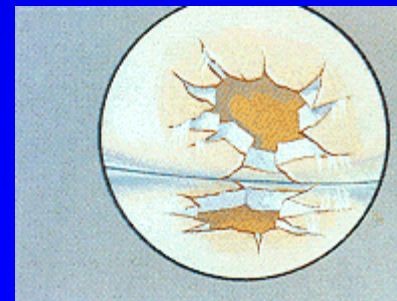


**Fibrillation- „ crab meet“**

# Chondropathy IV. st.



**Defects to subchondral bone**



# Conservative treatment

Change of life style

Low weightbearing

Loss of overweight

Crutches, sticks

Physioterapy

Physical therapy

# Conservative treatment

Analgetics nonopioid (paracetamol)

Analgetics opioid (tramadol, codein,)

Nonsteroidal antiinflammatory drugs (NSAID)

# NSAID

Inhibitors of cyclooxygenase 1 COX - 1 inhibitors

Ibuprofen

indometacin

piroxicam

naproxen

diclofenac

tiaprofenic acid

# NSAID

Inhibitors of cyclooxygenase - 2 COX 2 inhibitors

Preferred: meloxicam (Movalis, Recoxa)  
nimesulid (Aulin, Coxtral, Nimesil)

Selective : celecoxib (Aclexa)  
rofecoxib

# SYSADOA

- Symptomatic, slow acting, antiinflammatory drugs  
(chondroprotectives)

Slowly acting

Long lasting effect

Stimulation of PG and collagen

Inhibition of catabolic enzymes



# SYSADOA

1. systemic: glucosamin sulfate  
chondroitin sulfate  
diacerein  
ASU piascledine

2. local: hyaluronic acid

Combined drugs + collagen

# SYSADOA local - viscosupplementation

Hyalgan

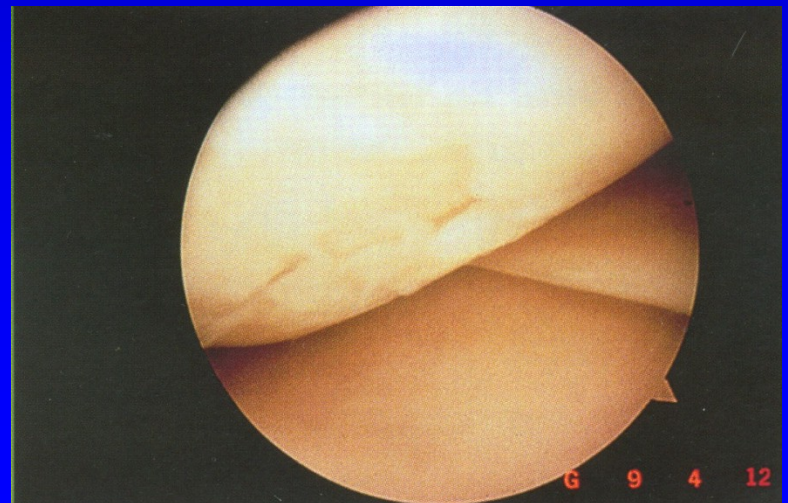
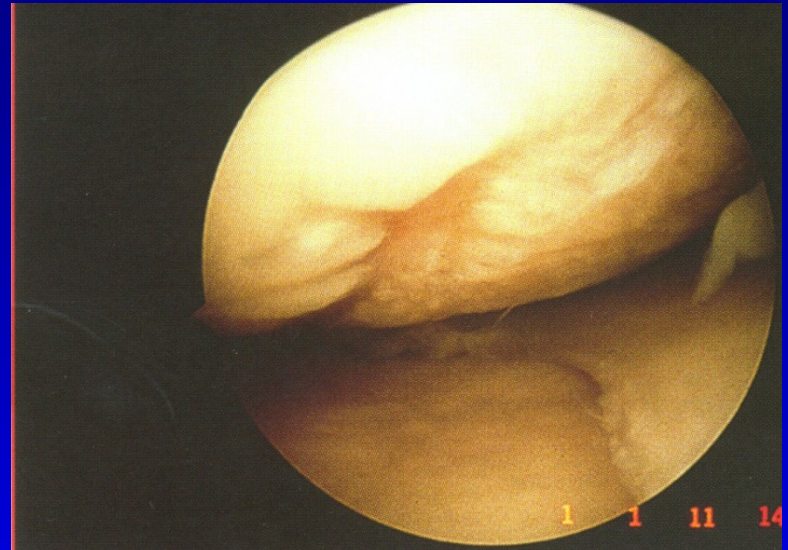
Synvisc

Synovial

Monovisc

Hyaline

Renehavis



# Local corticosteroids

Diprophos

Depo-Medrol

They influence synovitis

Do not stop progression of O.A.

Synthetic activity of chondrocytes is lower

The amount of chondrocytes and PG is lower

# Recommended treatment

Paracetamol- up to 4 g per day

NSA - + inhibitors of proton pump (omeprazol)

Chondroprotectives

Hyaluronic acid

Local corticosteroids

Pain department- in a case we can not do surgery

## Other options

PRP- platelets rich plasma

ACP- autologous conditioned serum- Orthokine

Mesenchymal stem cells ?

# Operative treatment

## Preventive surgery

- correct treatment of intraarticular fractures
- correct treatment of ligament injuries
- correct treatment of dislocations
- correct treatment of meniscal lesions
- treatment of chondromalacia
- removal of loose bodies

# Operative treatment

## Preventive surgery

- Correction of malalignment- osteotomy
- Acetabuloplasty, shelf plasty
- Replacement of cruciate ligaments
- synovectomy, debridement, shaving

# Operative treatment

Resection arthroplasty – op. sec. Keller  
op. sec. Girdlestone

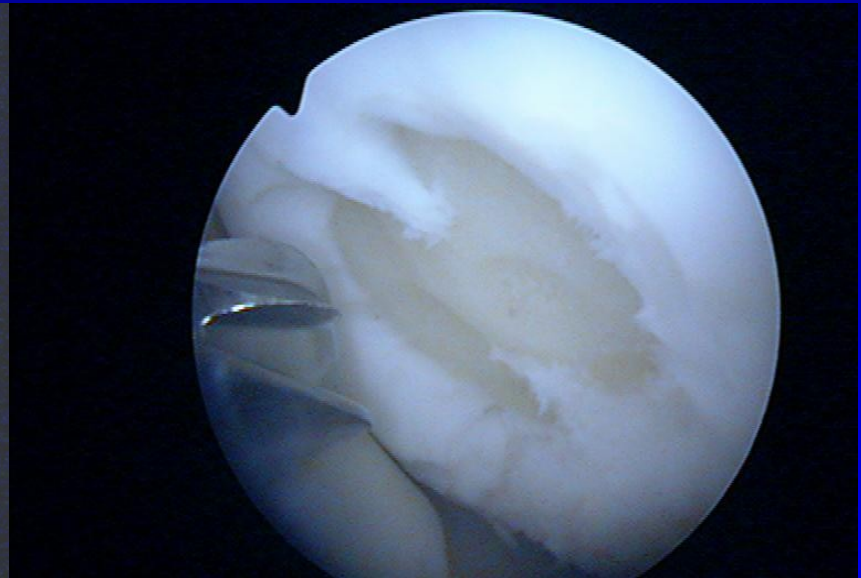
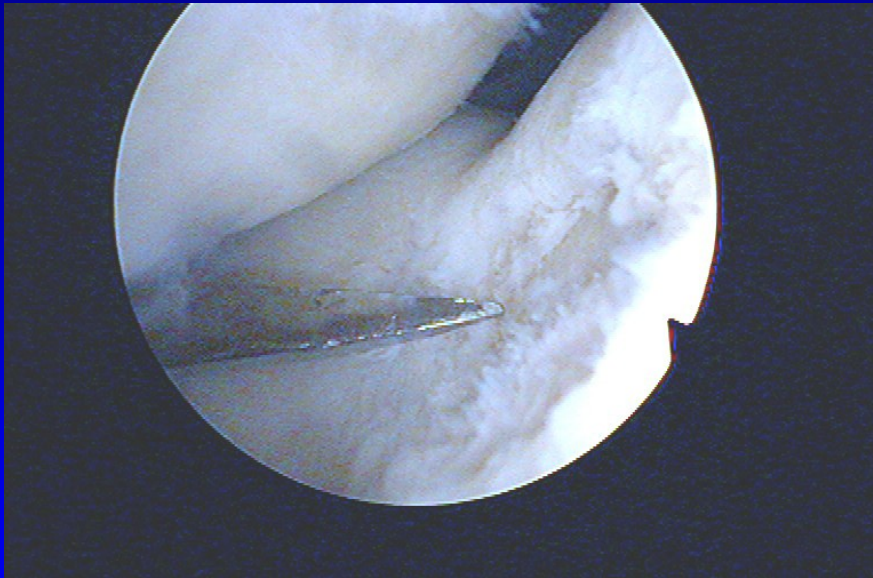
Arthrodesis

Total joint replacement



# Options for localised chondral defects

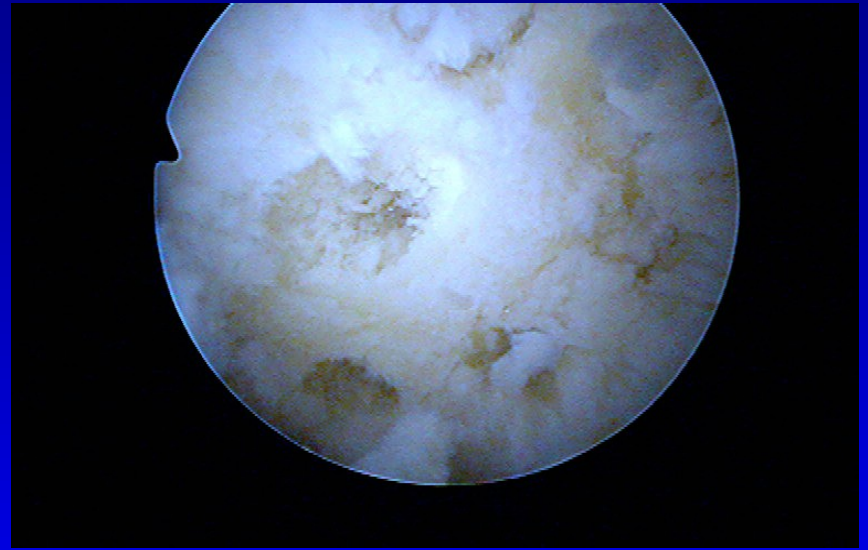
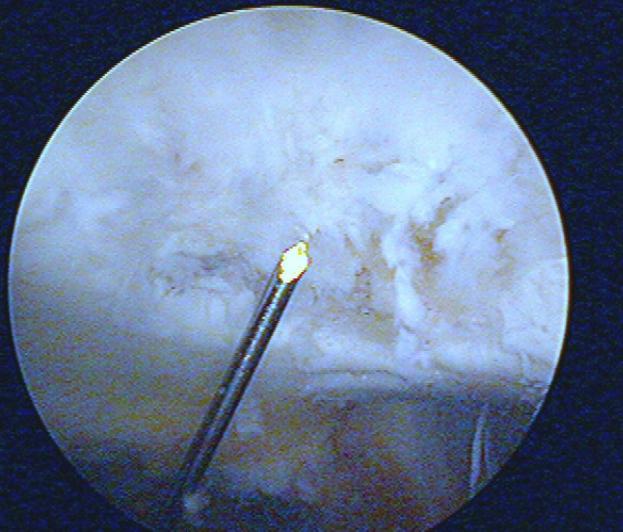
# Shaving and drilling



-

-

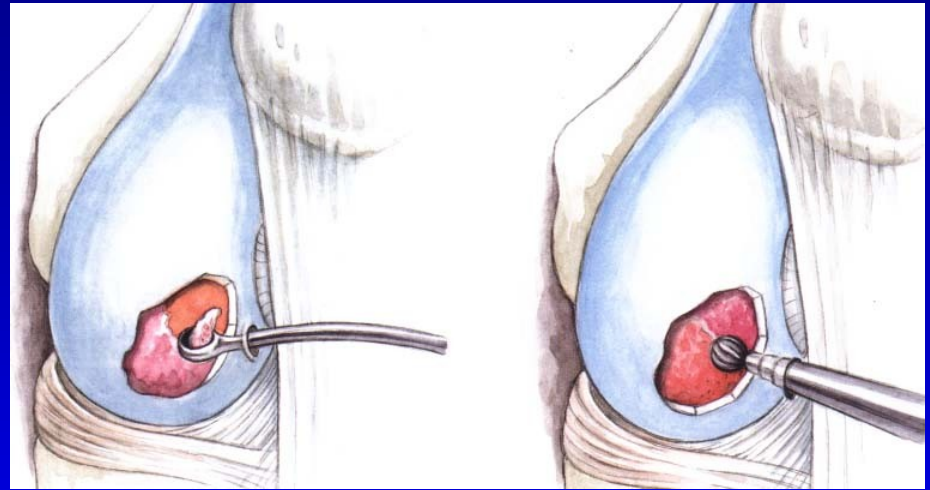
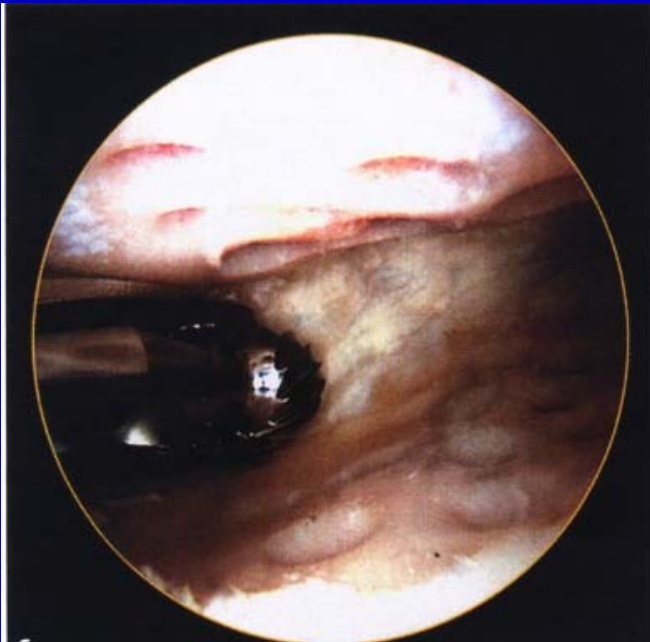
# Drilling



-

# Abrasion chondroplasty

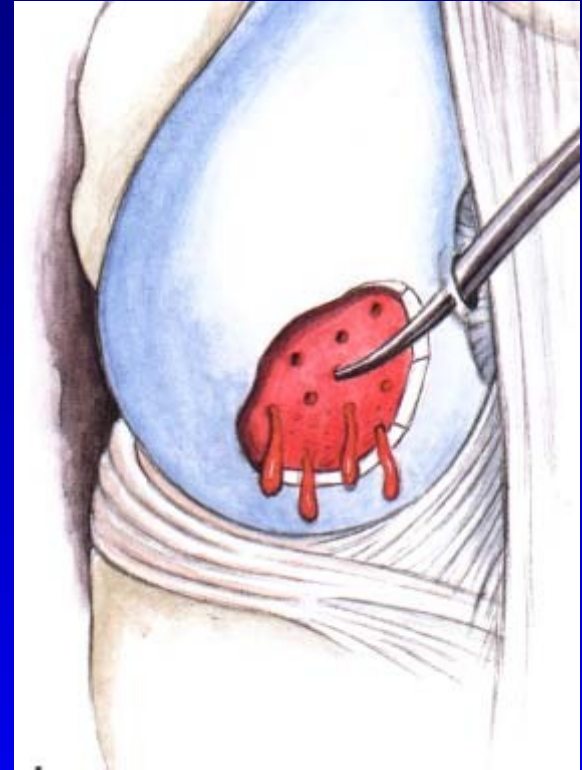Curretage  
Shaver



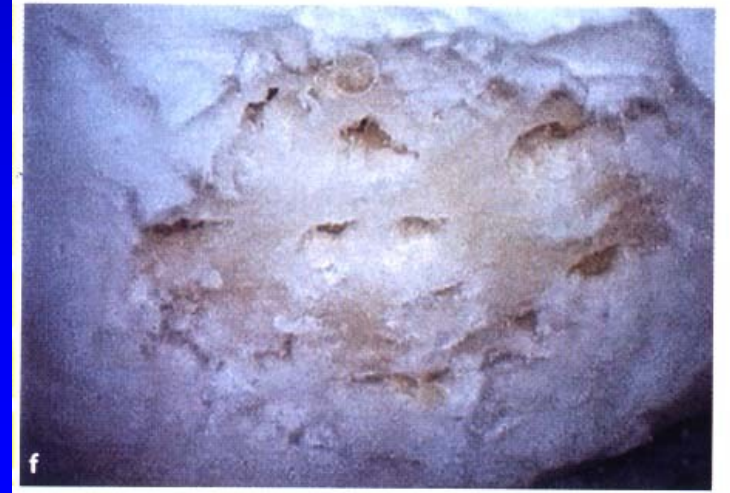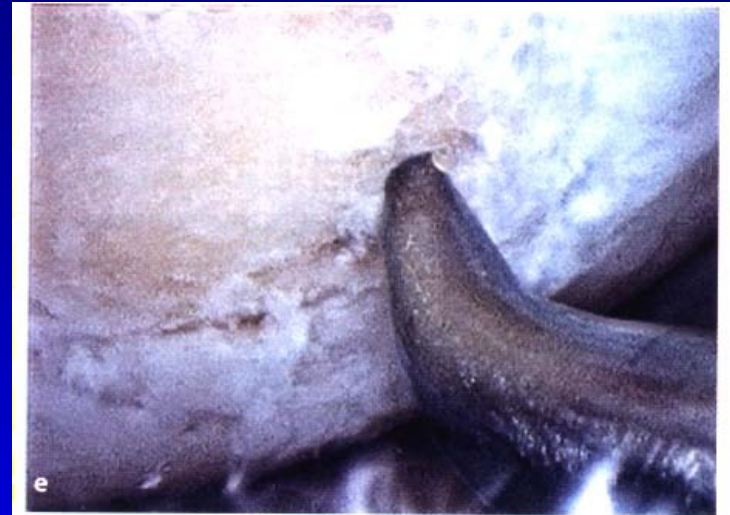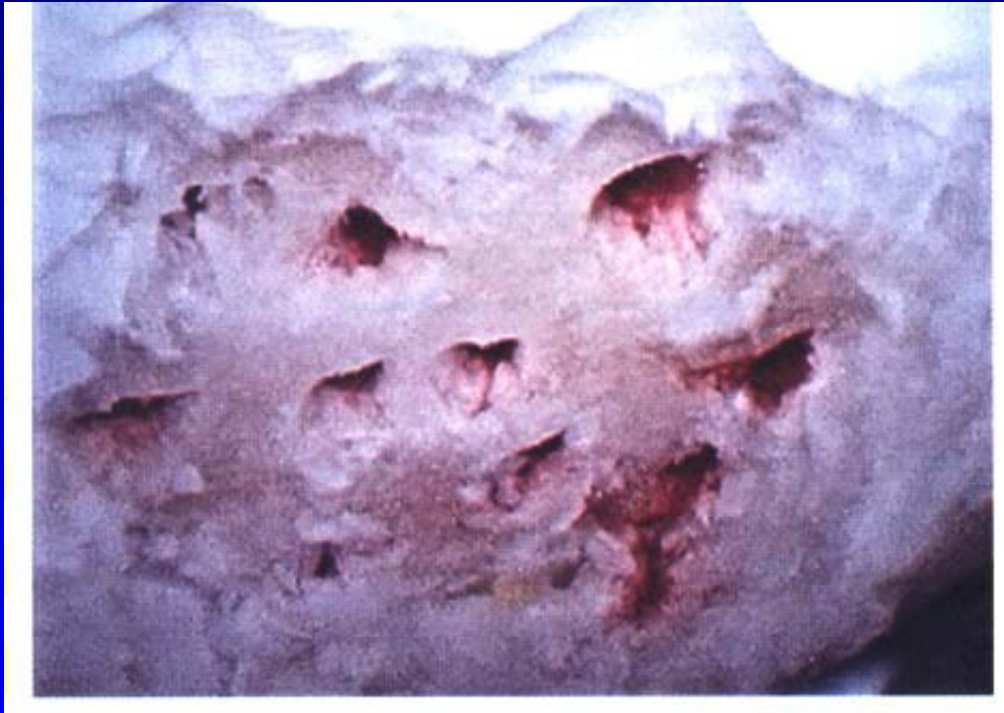# Microfractures

Perforation of subchondral bone  
- slight bleeding  
Steadman, J.R., 1999

Multipotent stem cells into  
the defects  
The aim- to create fibrocartilago

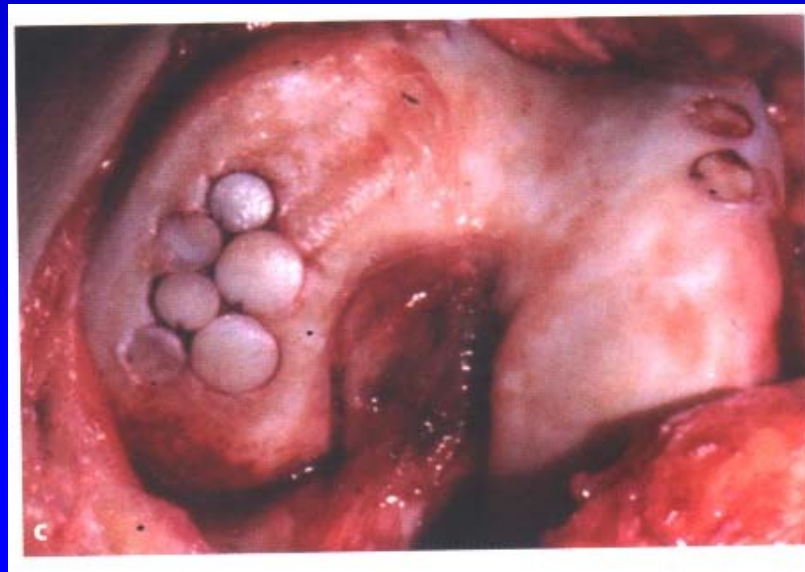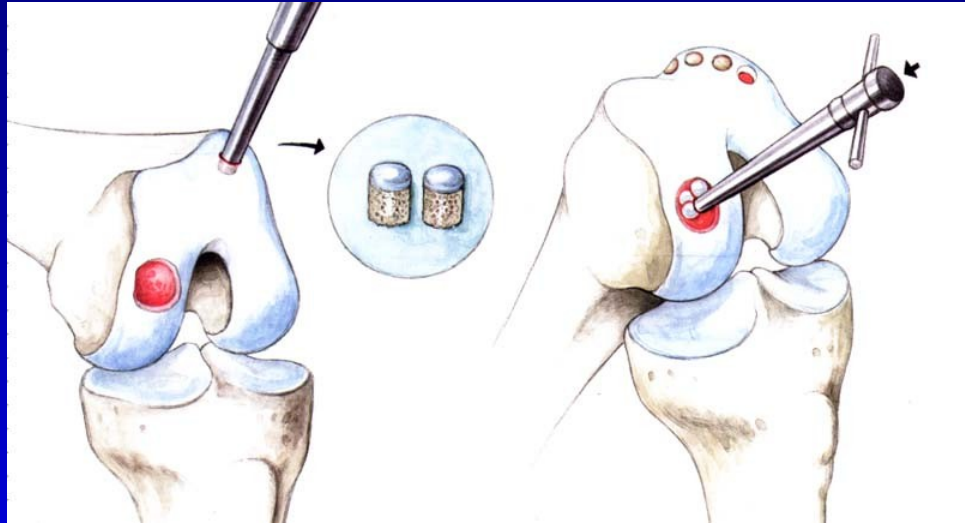


# Microfractures

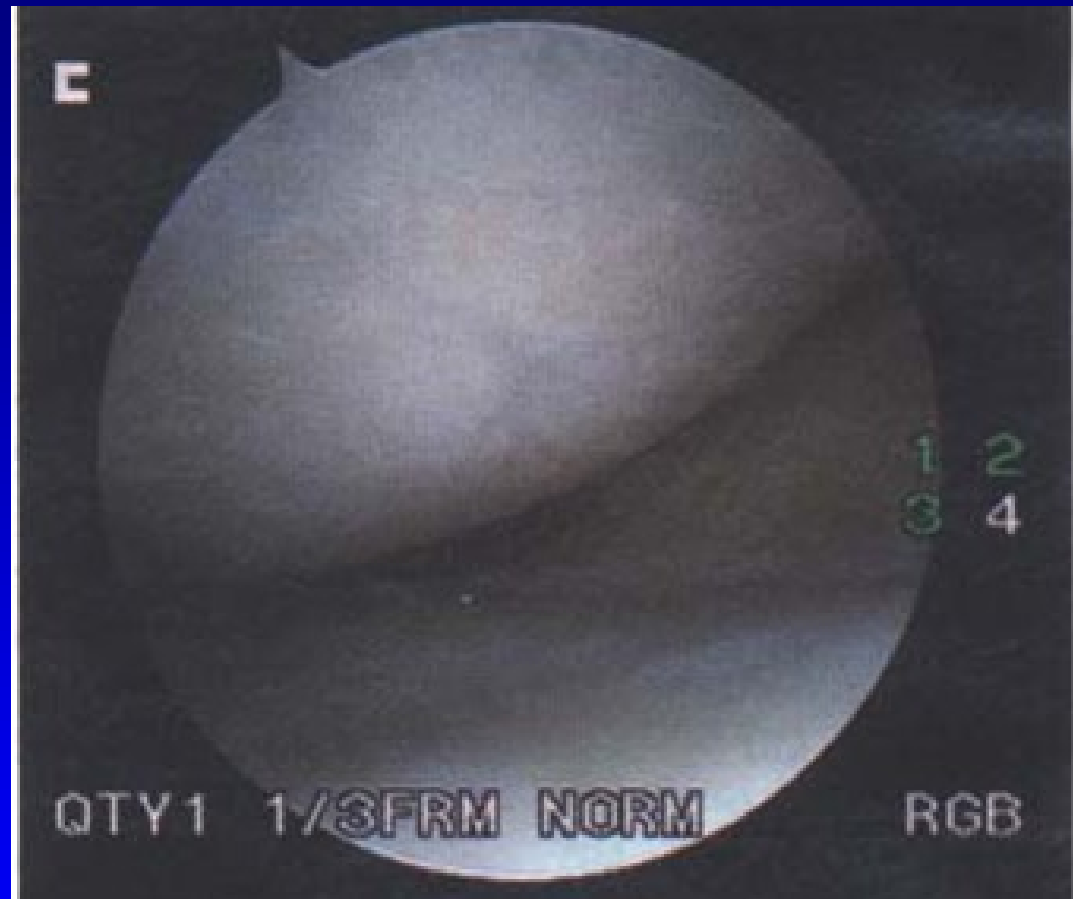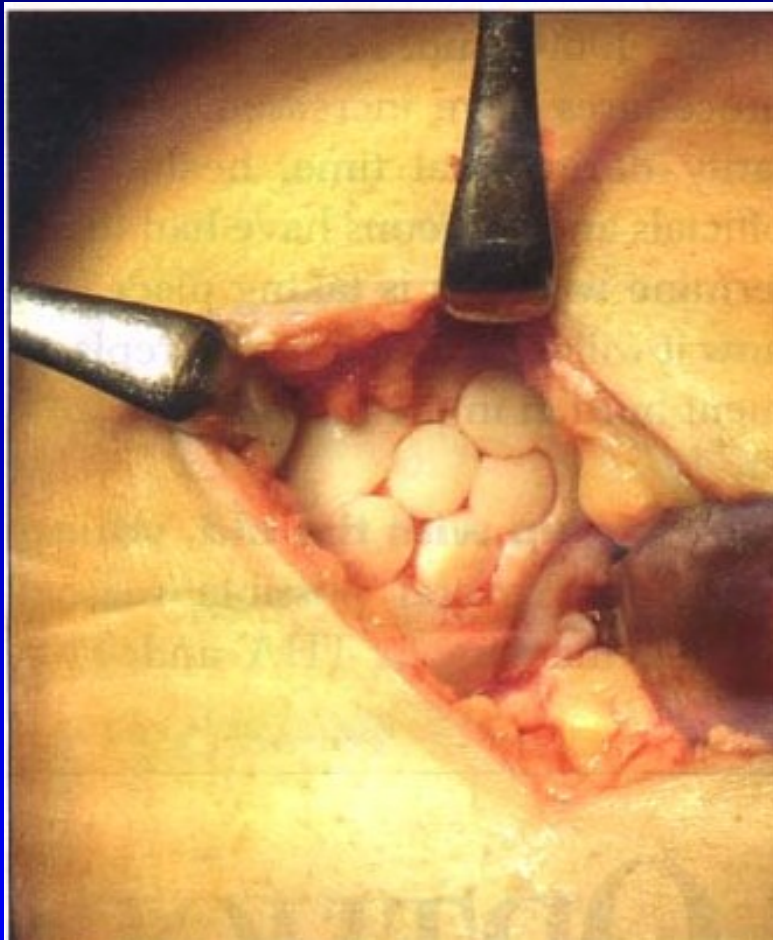


# Osteochondral autograft transfer- OAT Mosaicplasty

Hangody, L., 1992  
Defects up to 2 - 4 cm<sup>2</sup>



OAT



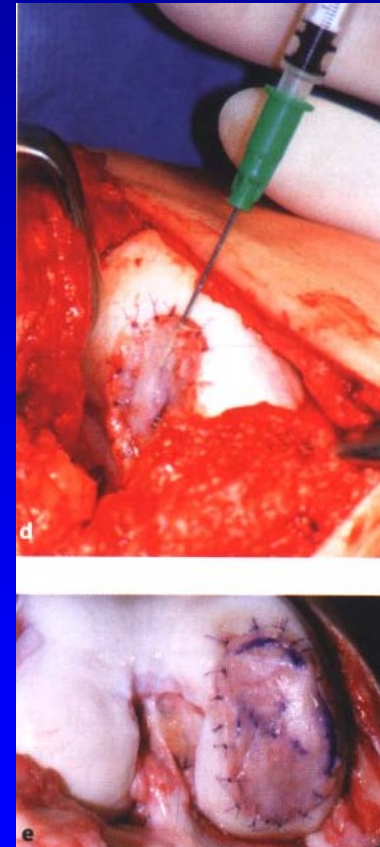
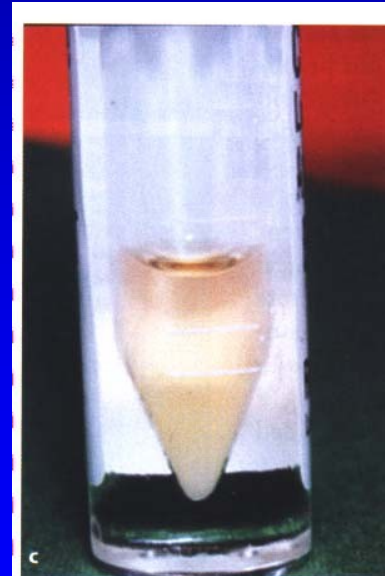
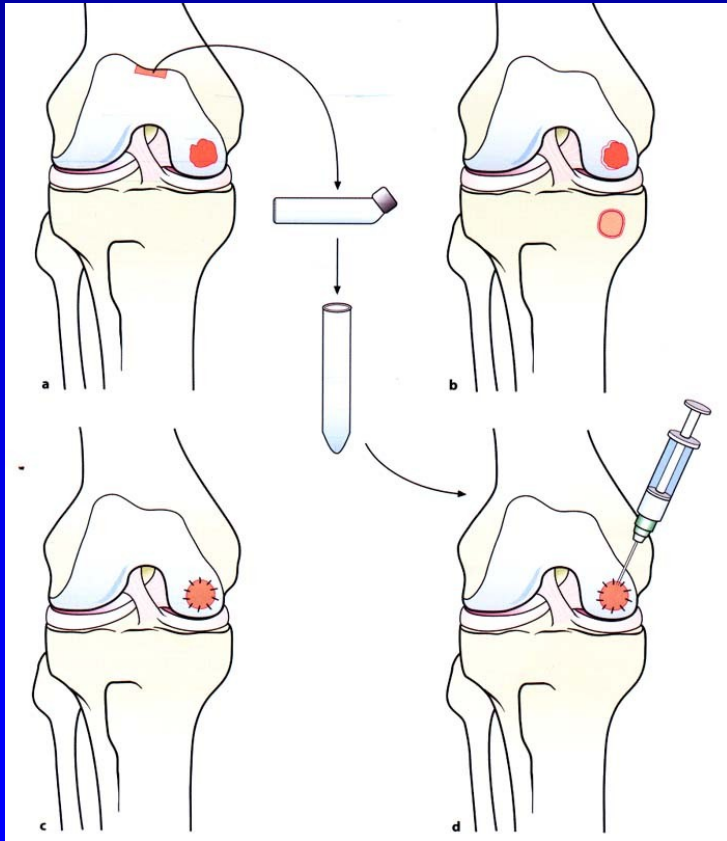
4 years after surgery



# ACI – autologous chondrocyte implantation

Transplantation of autologous chondrocytes  
into defects of cartilage

Chondrocytes in suspension under periosteal layer

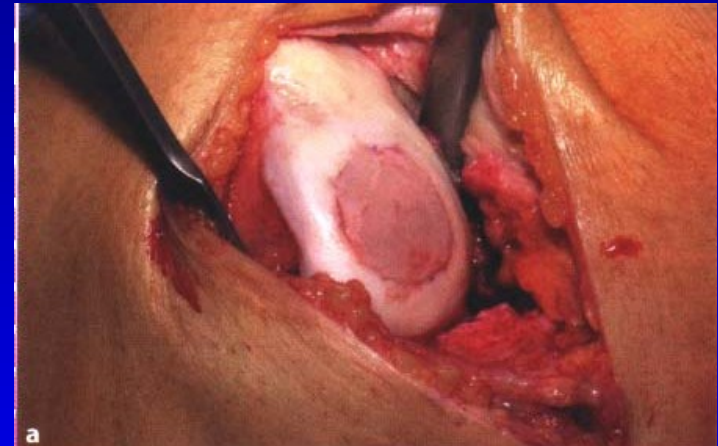


# Hyalografts and chondrografts

Scaffolds- HyaloFast, Chondrotissue...

Biodegradable

Matrix for stem cells from bone marrow  
after drilling or from serum



Collagen scaffolds

# HyaloFast- scaffold

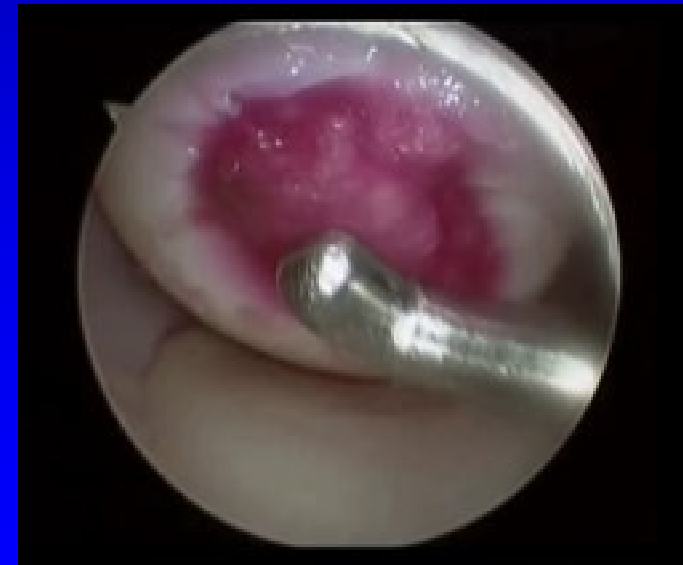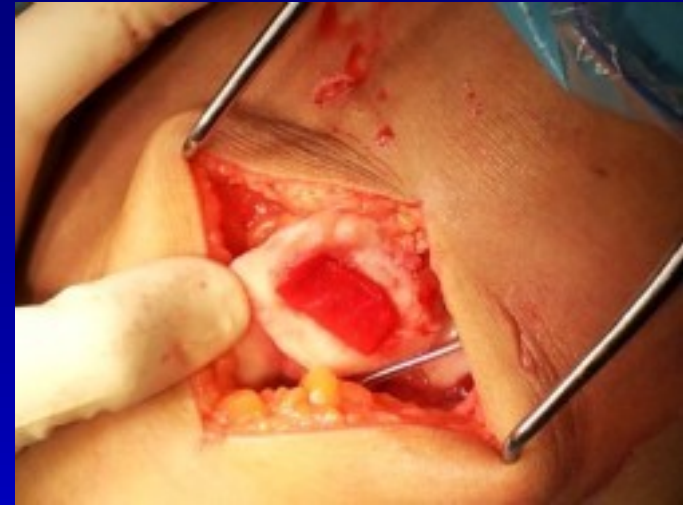Polymer of HA

No special fixation

Scaffold serves for maintaining of stem cells from bone marrow

Supports viable cells

Fills the defects of hyaline cartilage



# Diferential diagnosis

Rheumatoid arthritis

Ancylosing spondylitis

Psoriatic arthritis

Septic arthritis

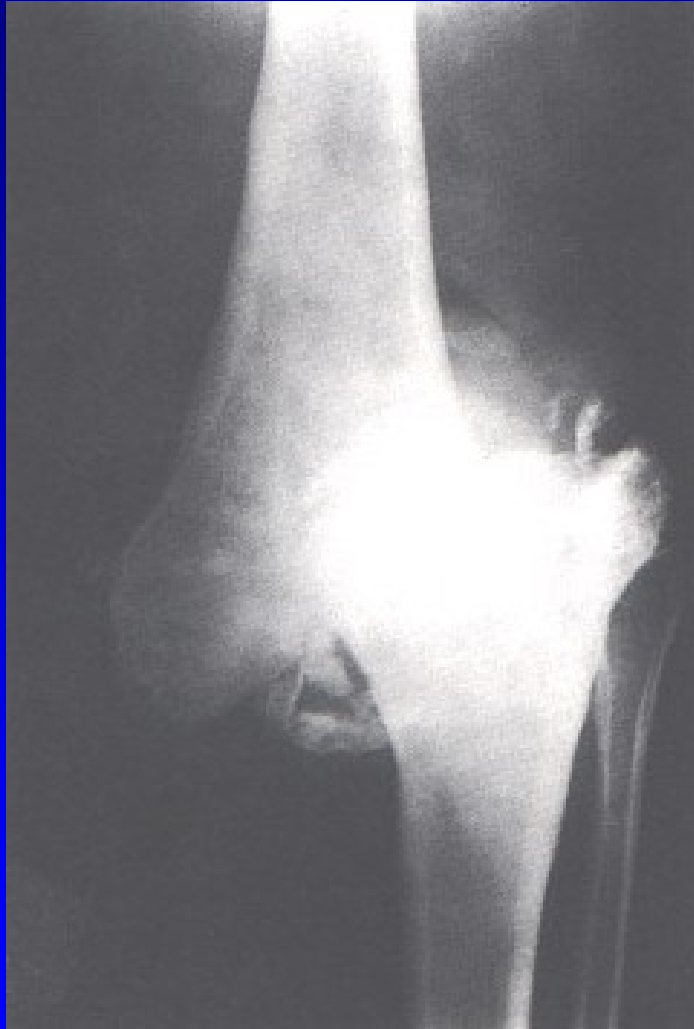Haemofilic arthropathy

Gout

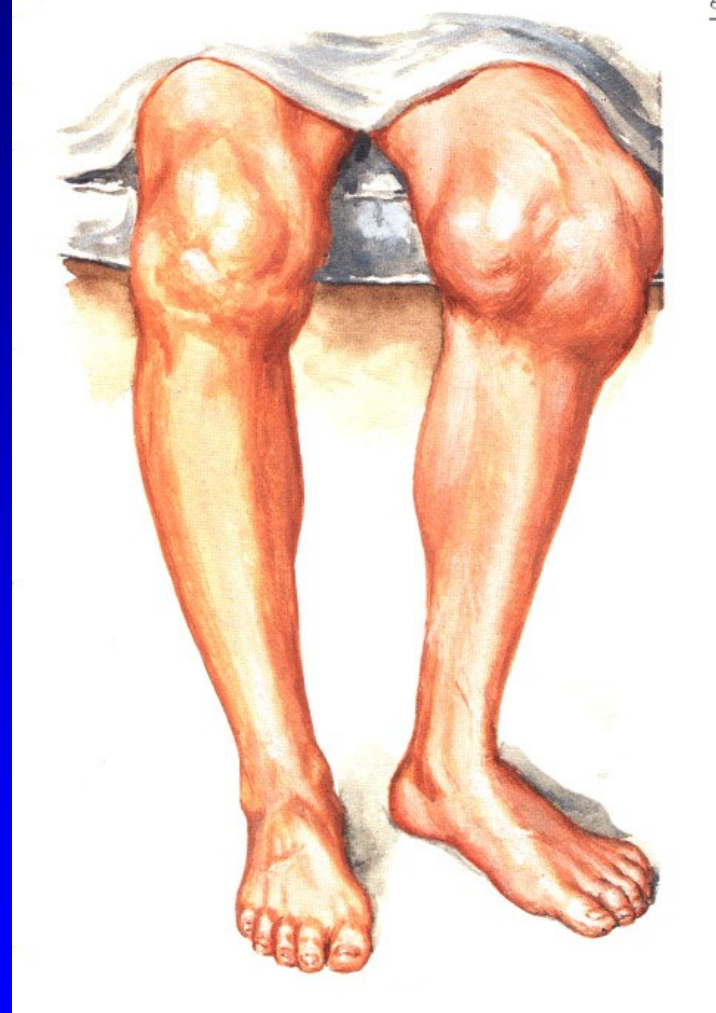
Chondrocalcinosis

Neurogenic arthropathy

# Neurogenic arthropathy

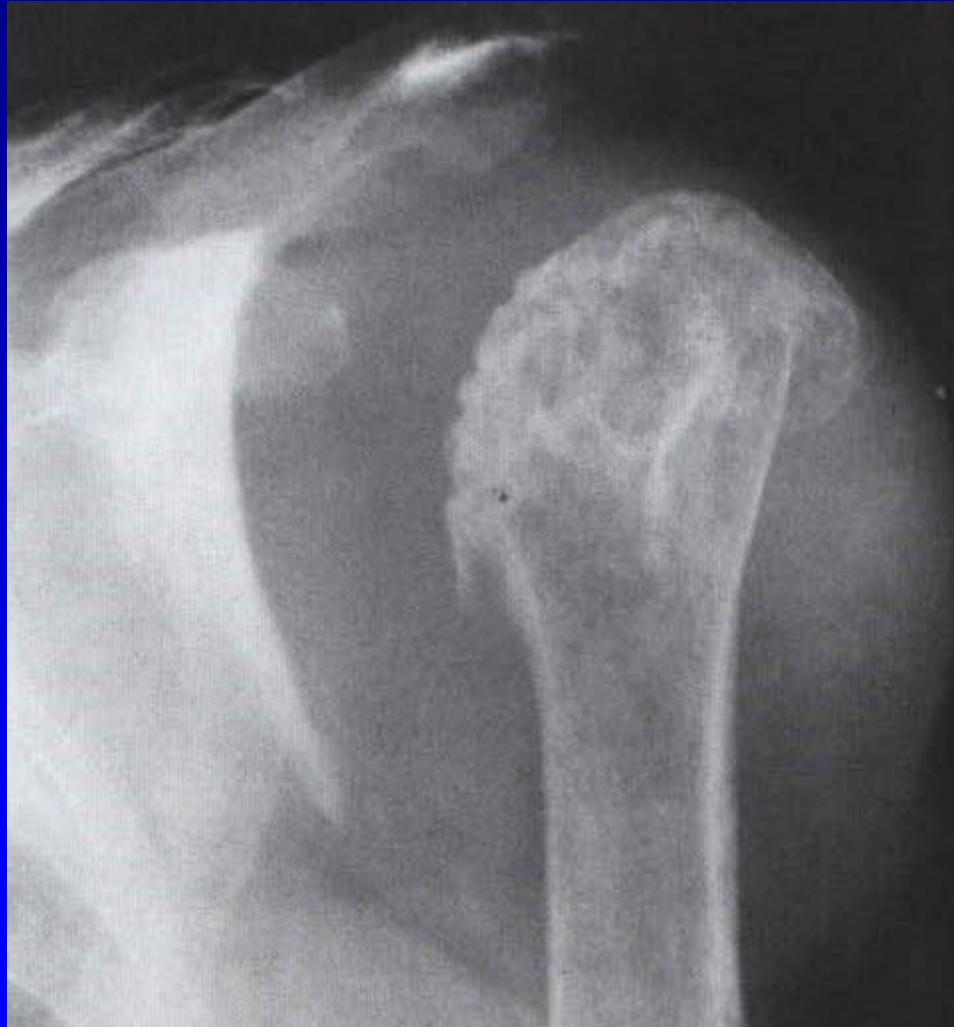

Obr. 30



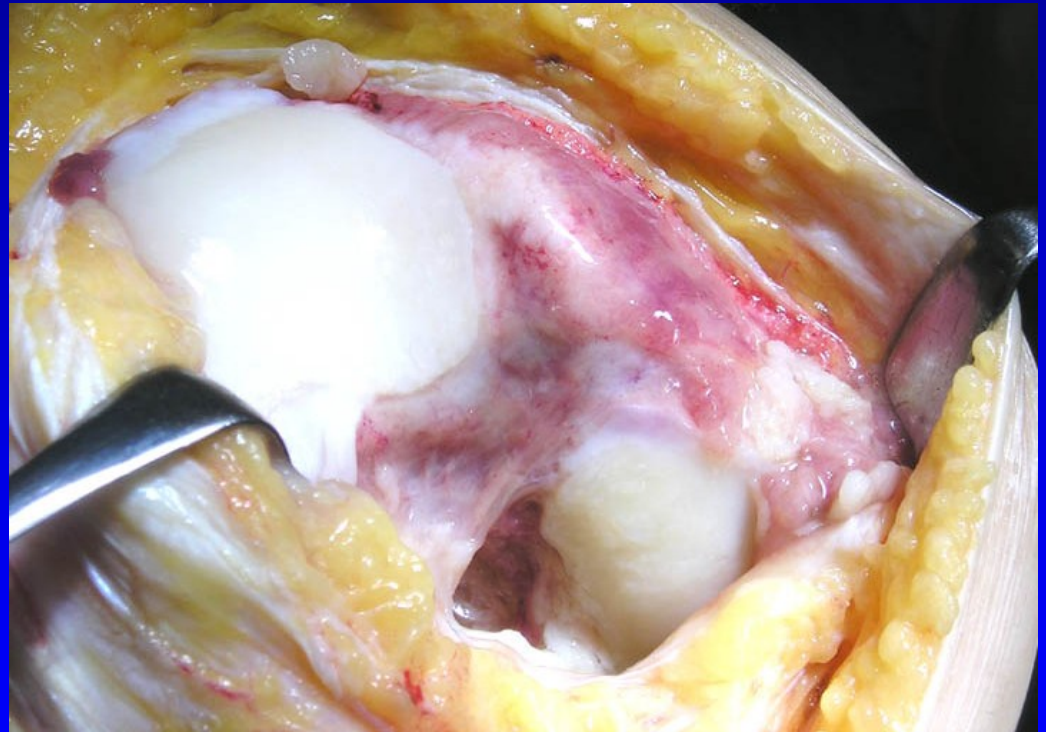
Obr. 31

# Neurogenic arthropathy

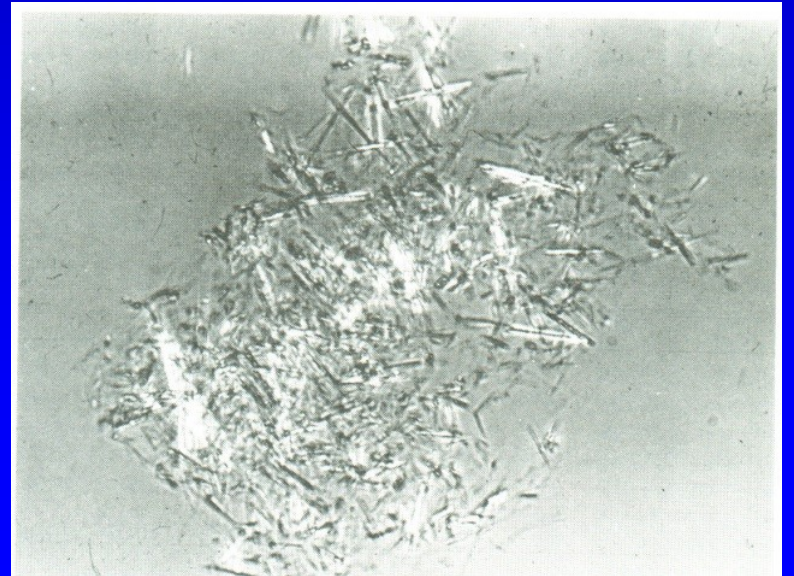
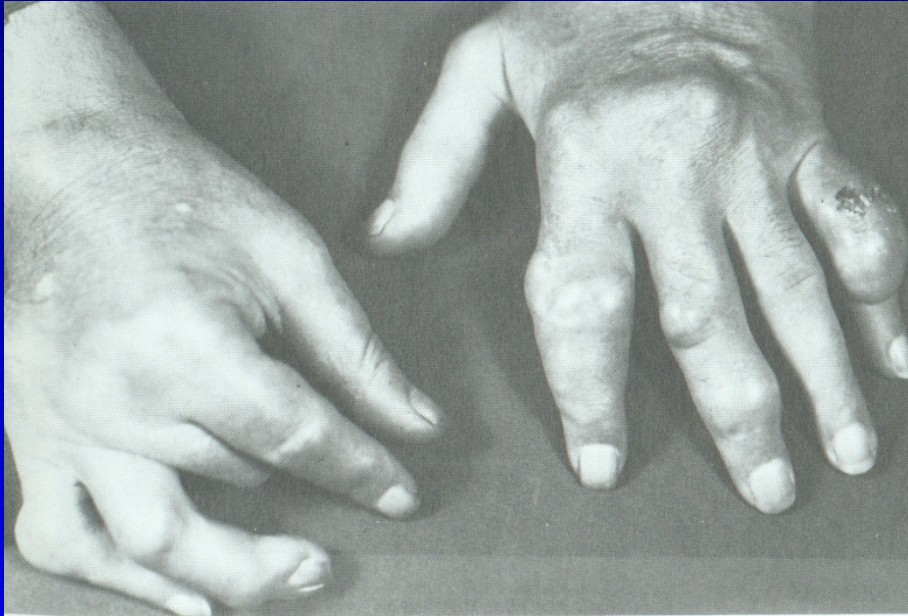

# R.A.

- R.A.
- Juvenile R.A.
  - Still's disease

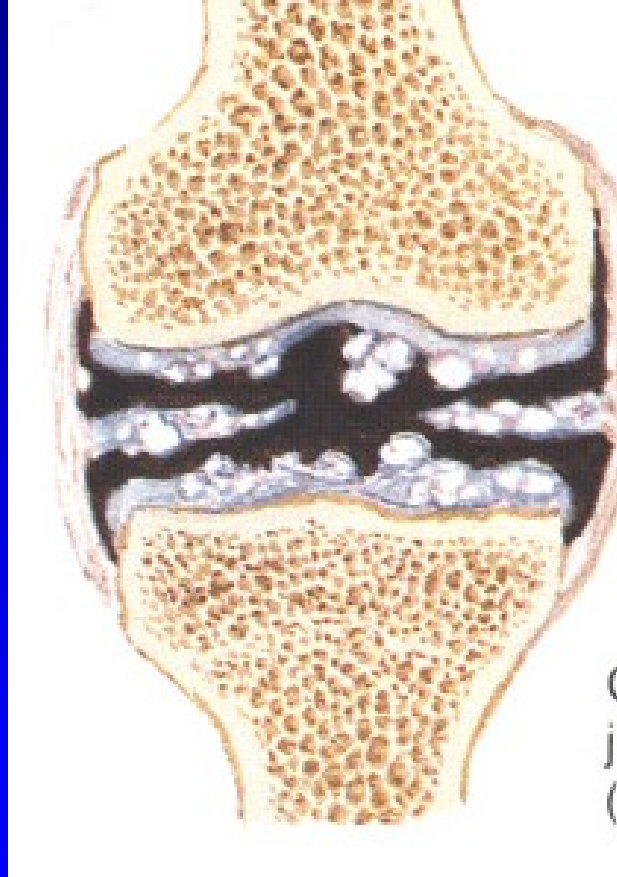


# Gout

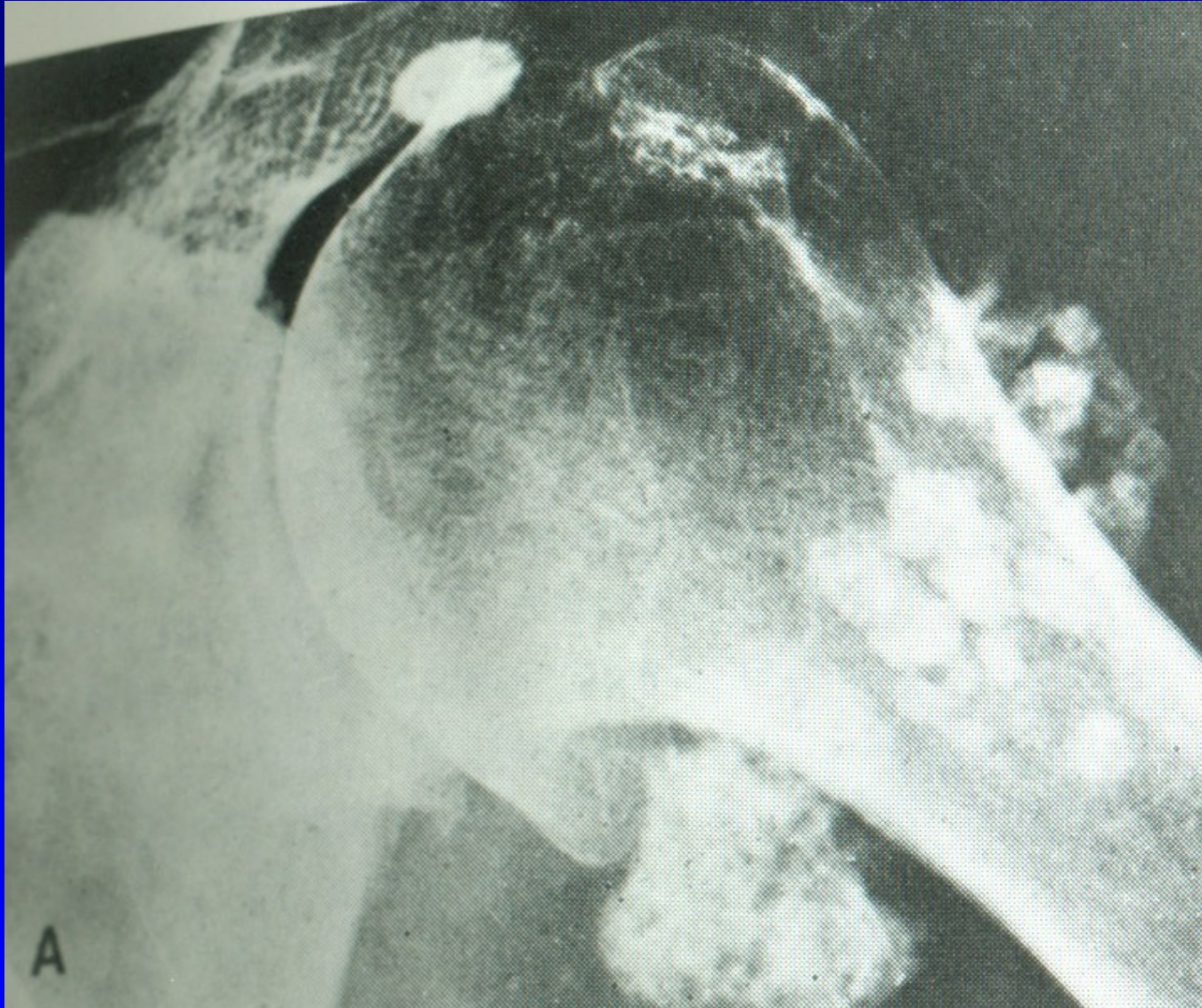



# Chondrocalcinosis



# Synovial chondromatosis



# Septic arthritis

