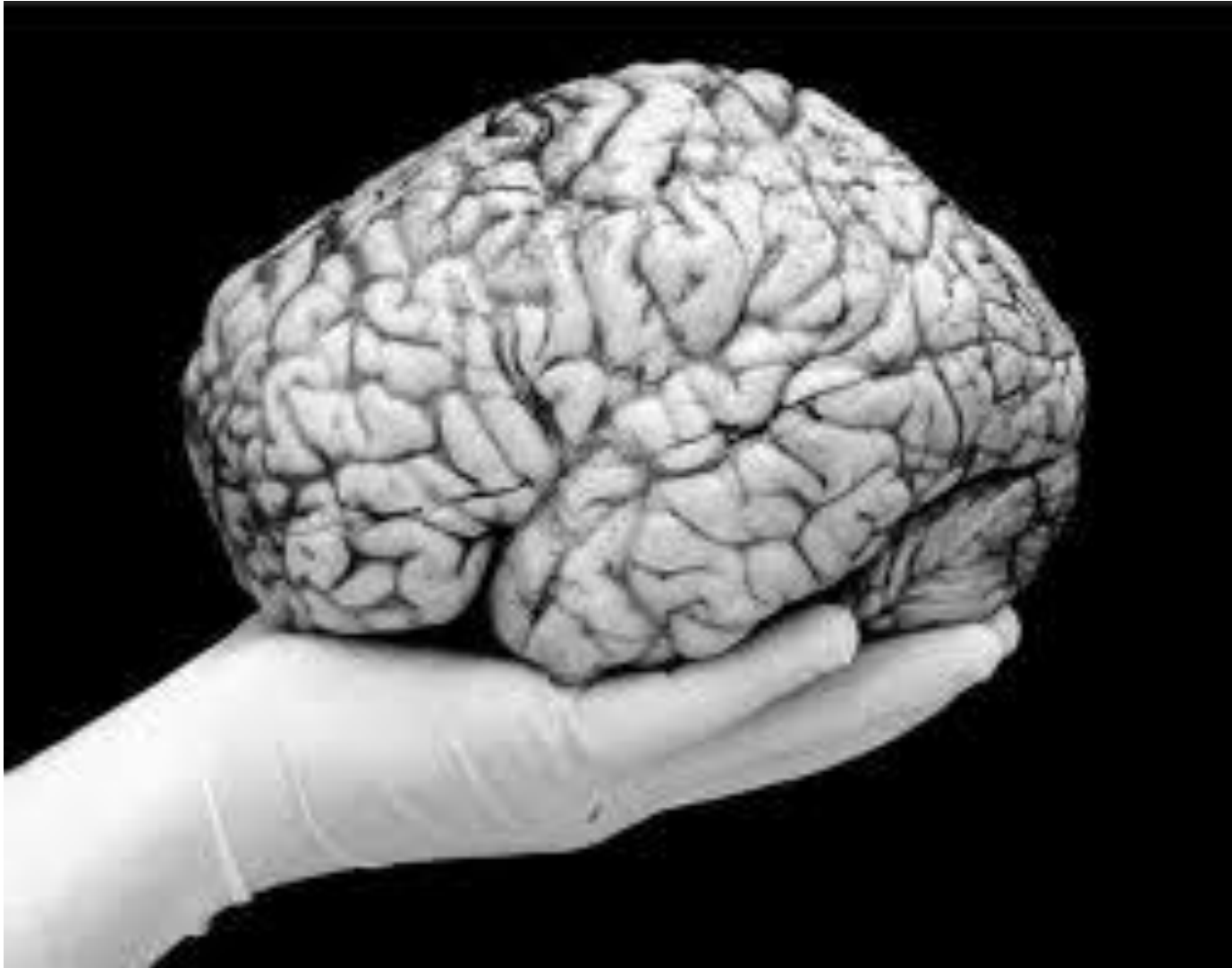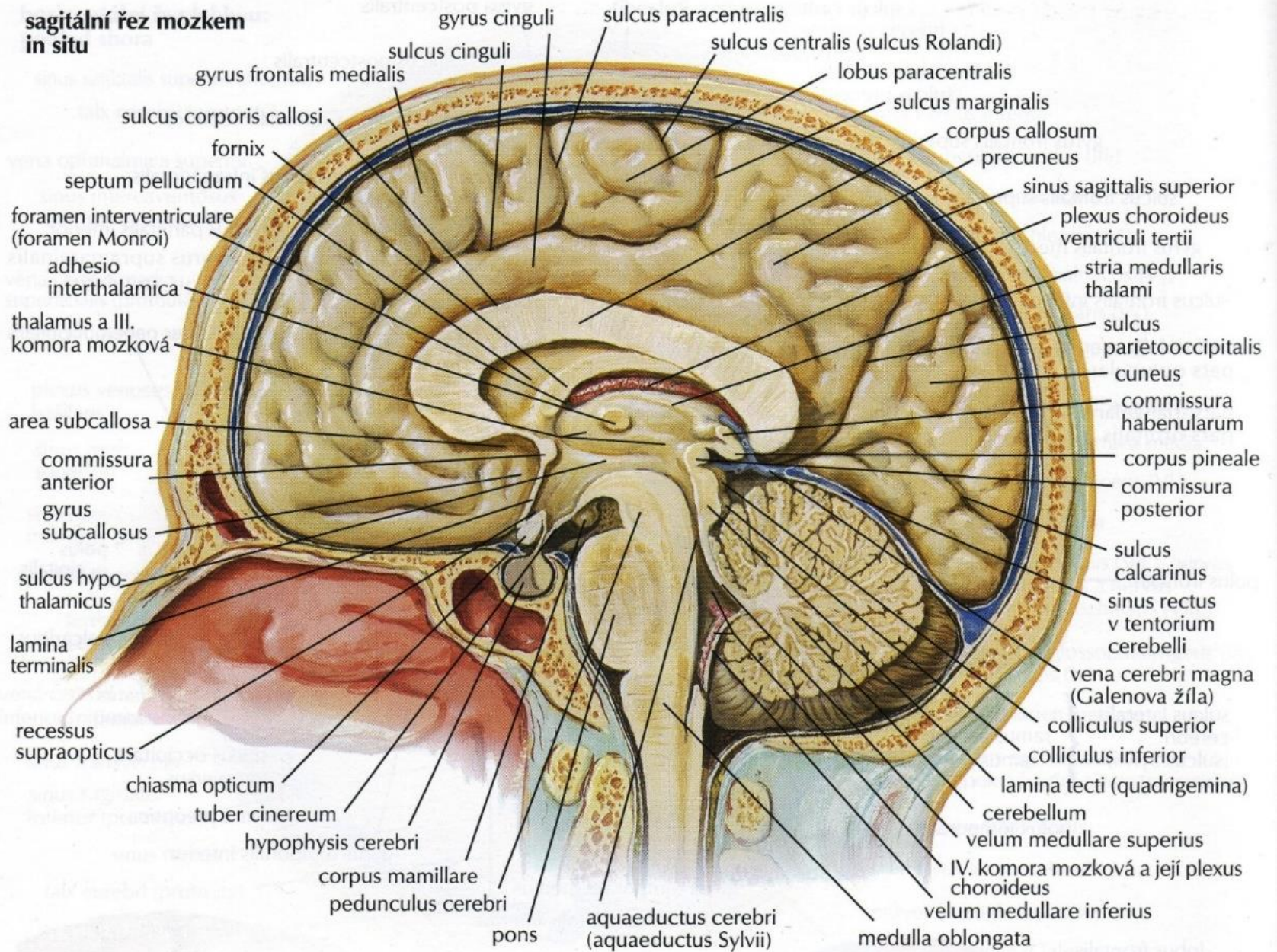
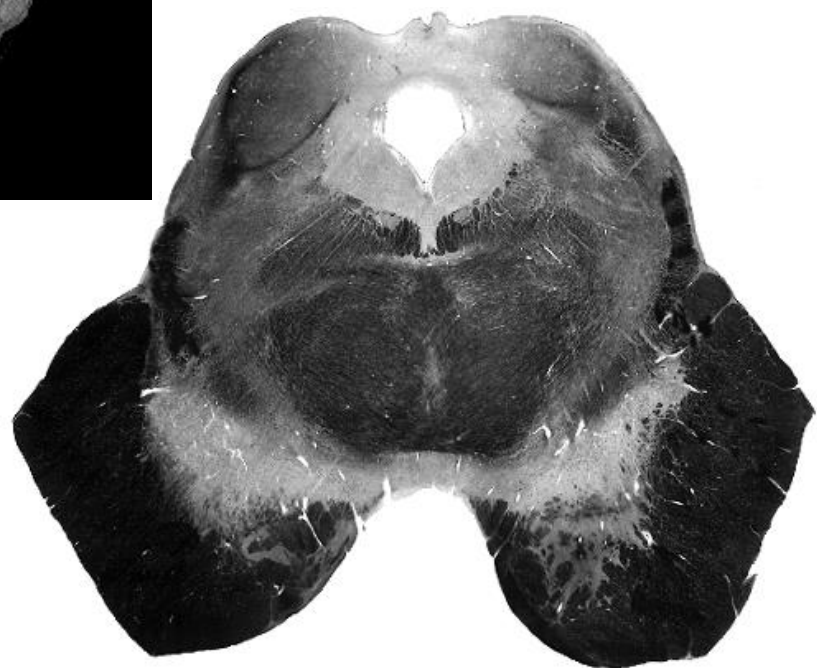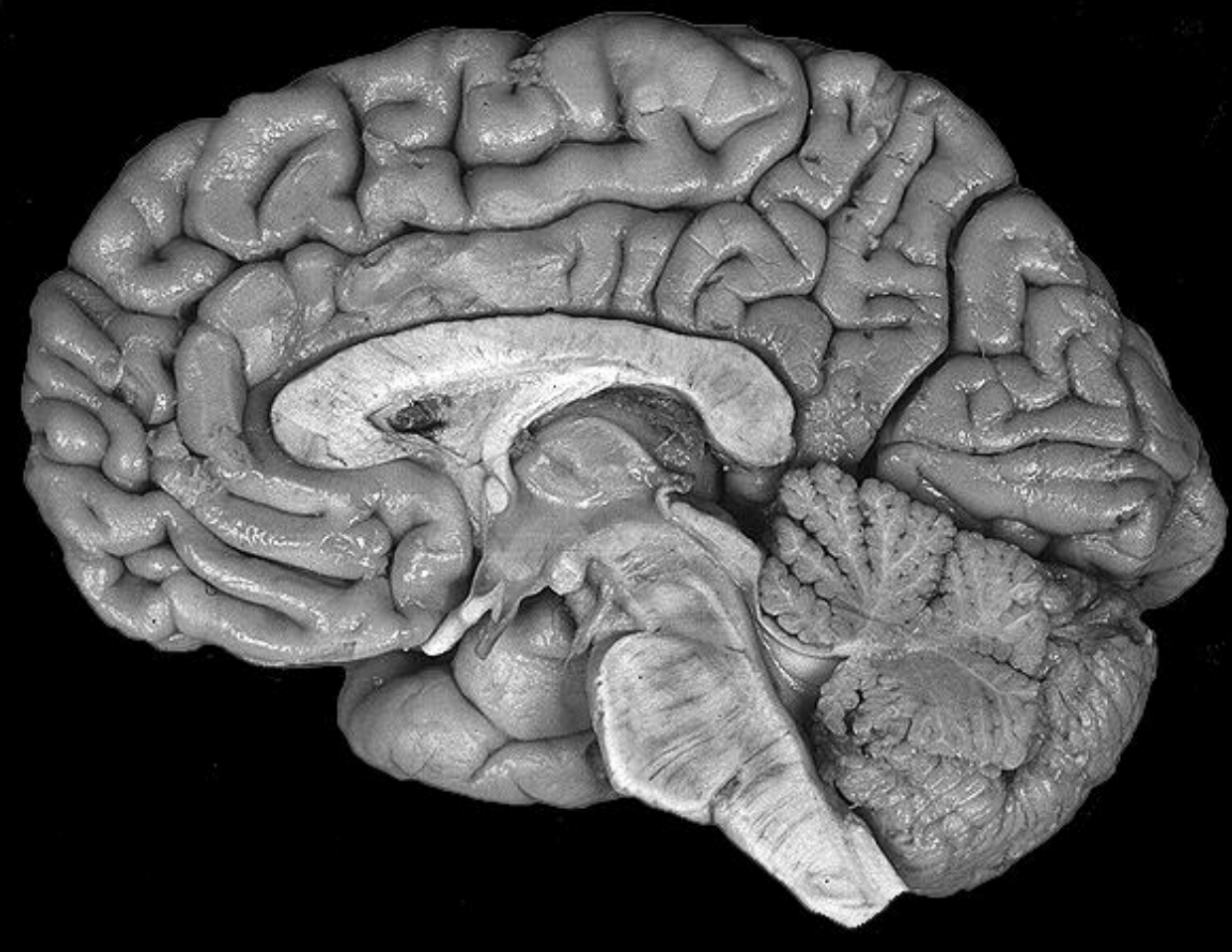


Chambers, meninges and blood supply of CNS



**sagitální řez mozem
in situ**



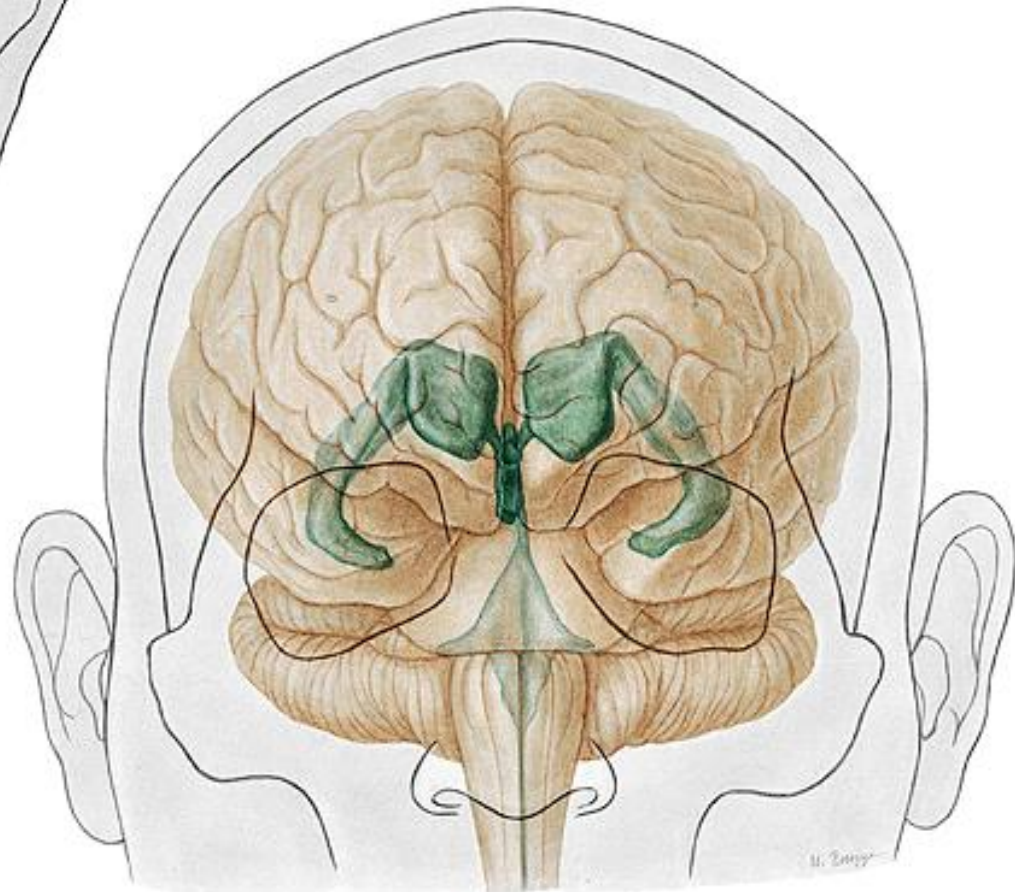
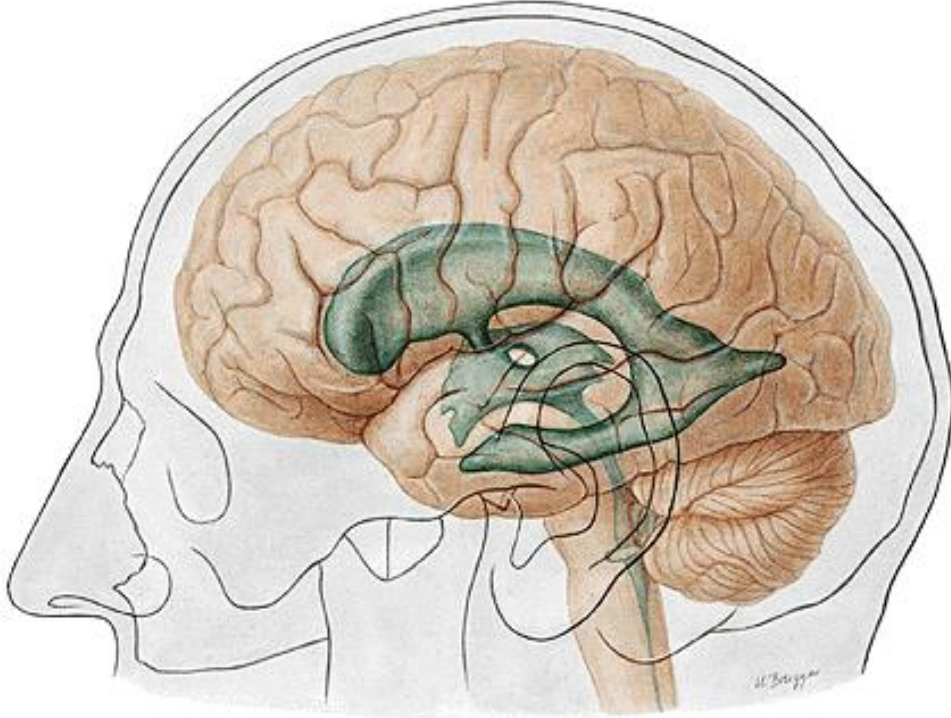


cornu frontale

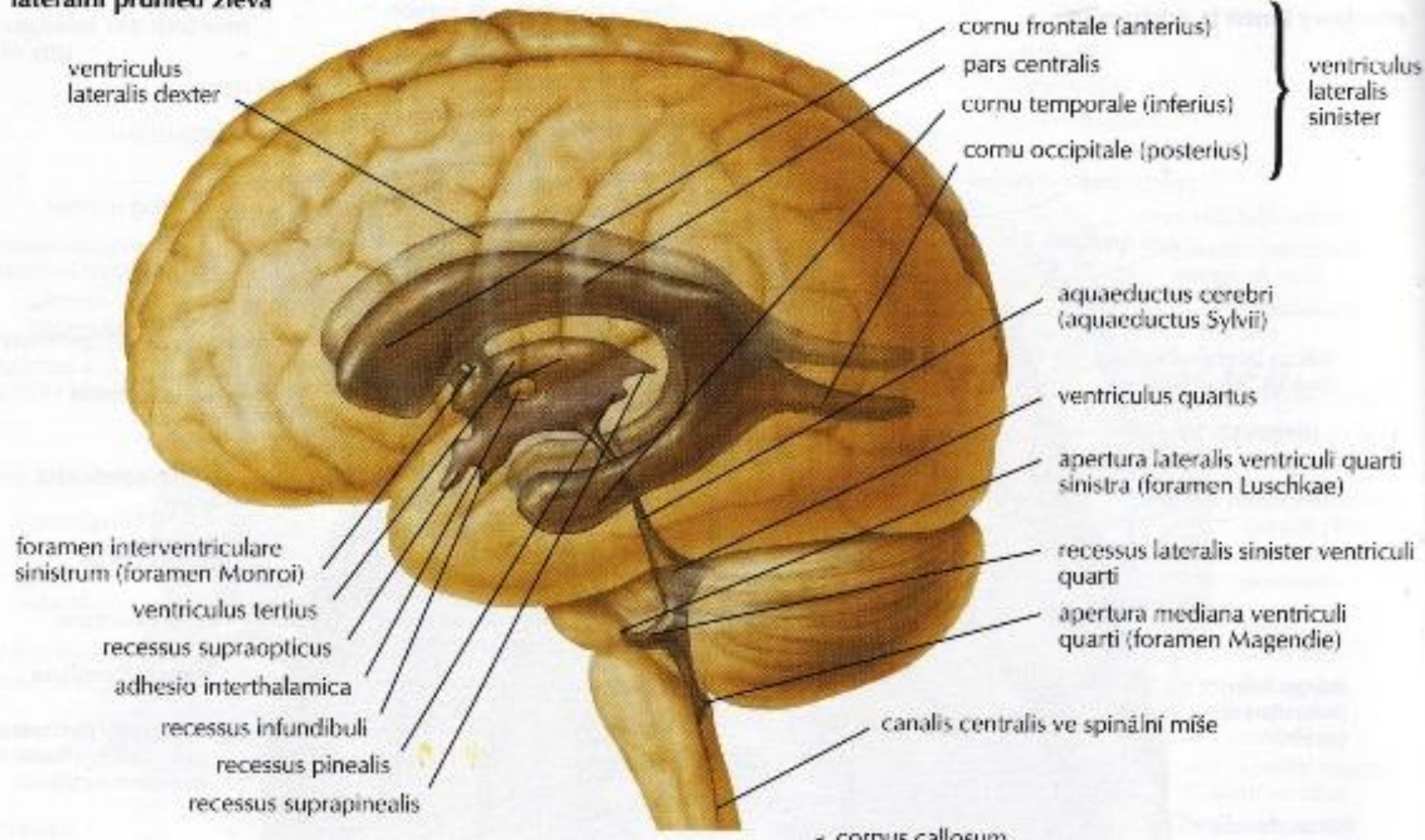
pars centralis

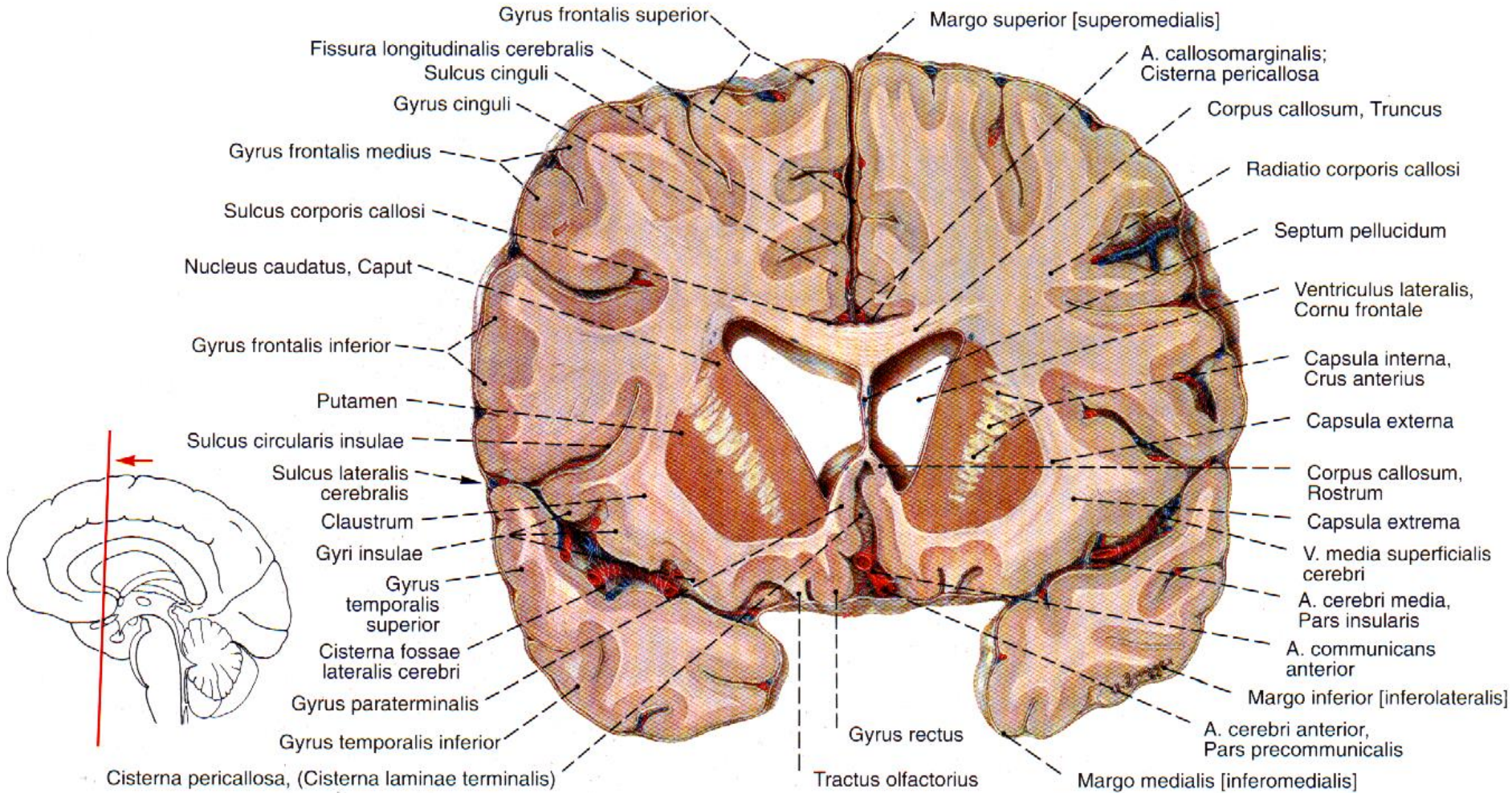
cornu occipitale

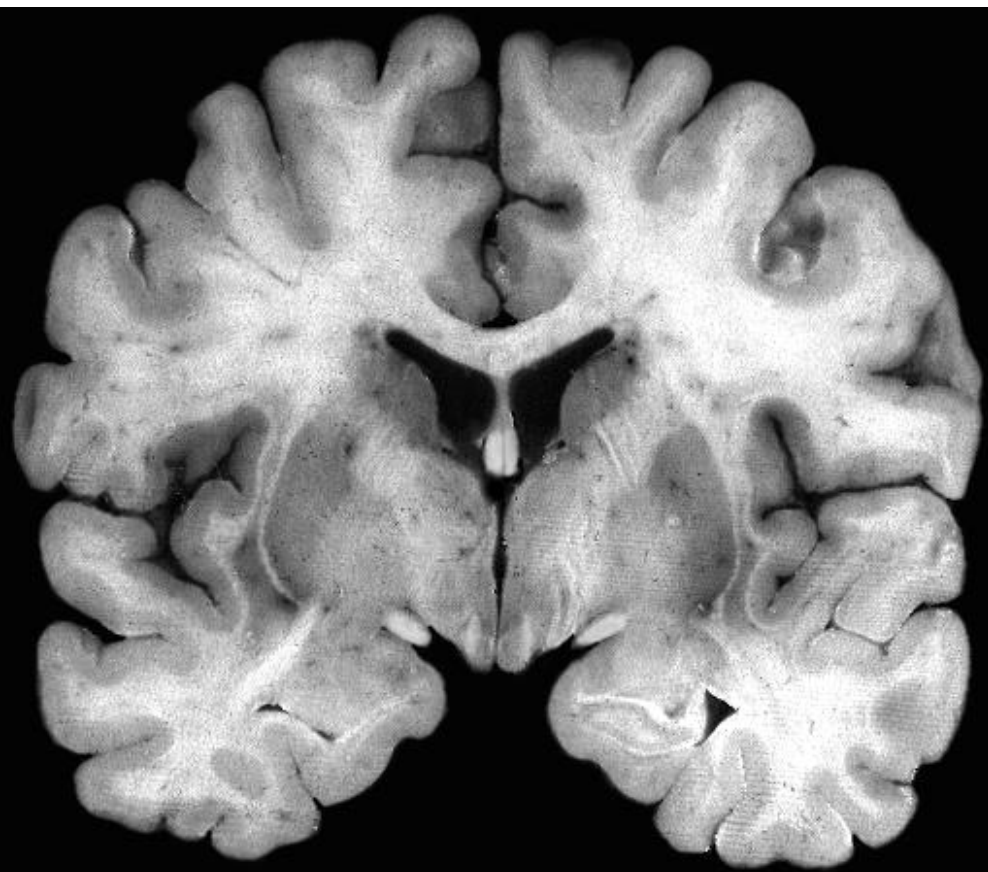
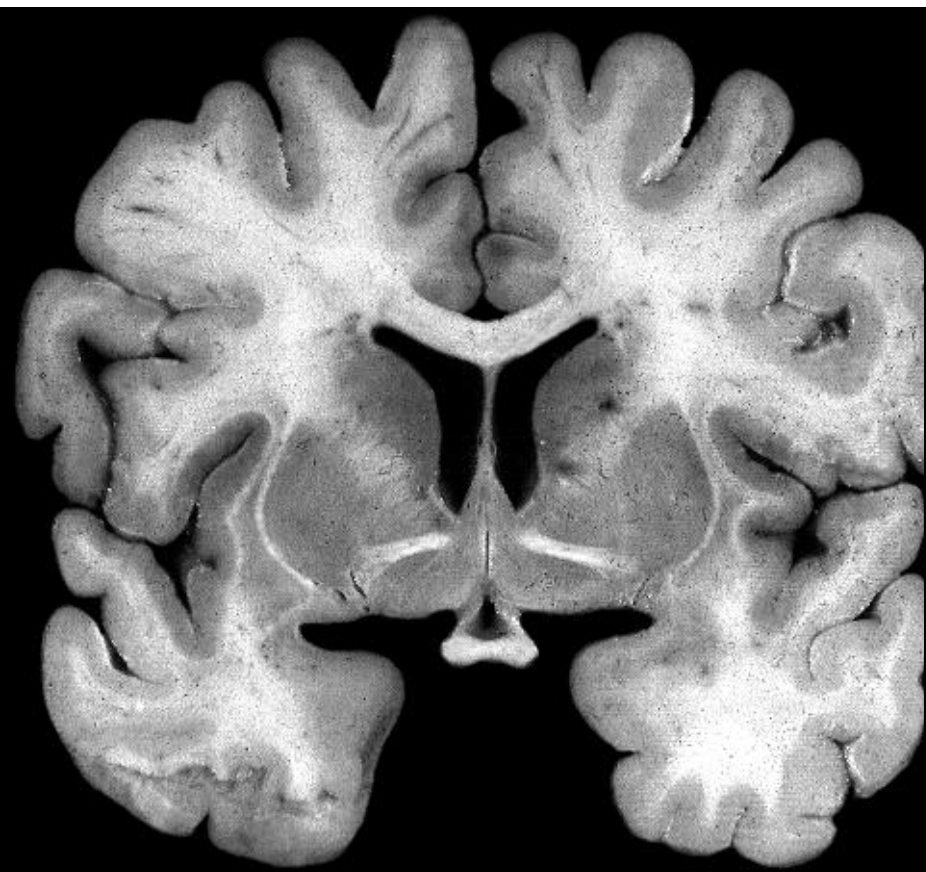
cornu temporale

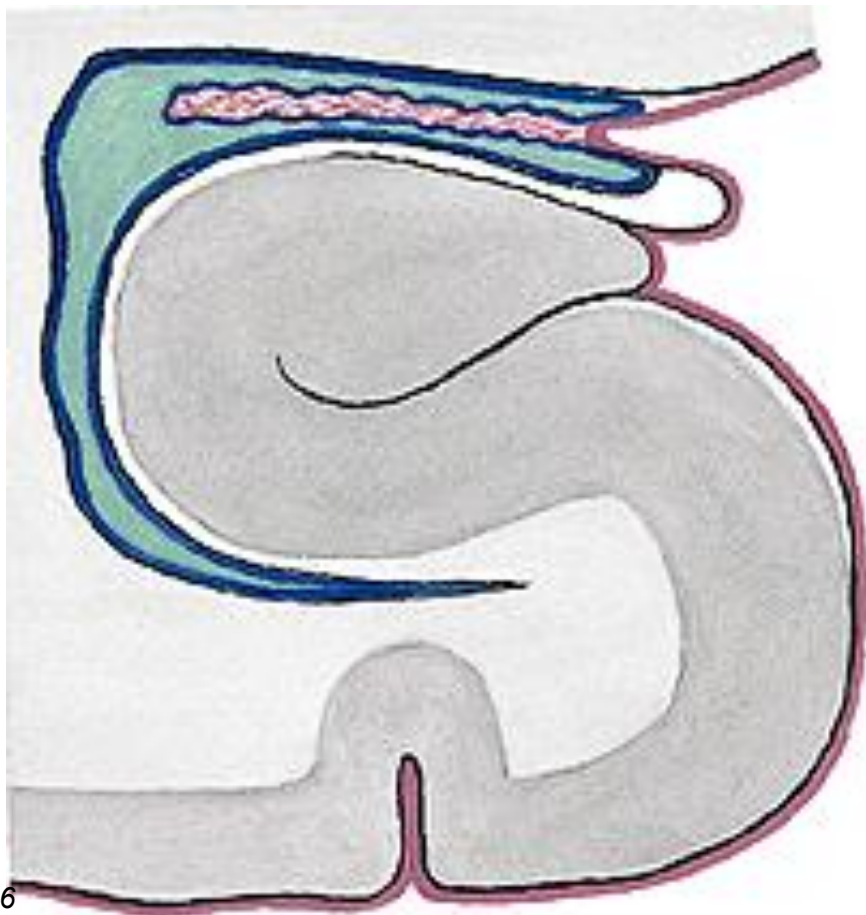
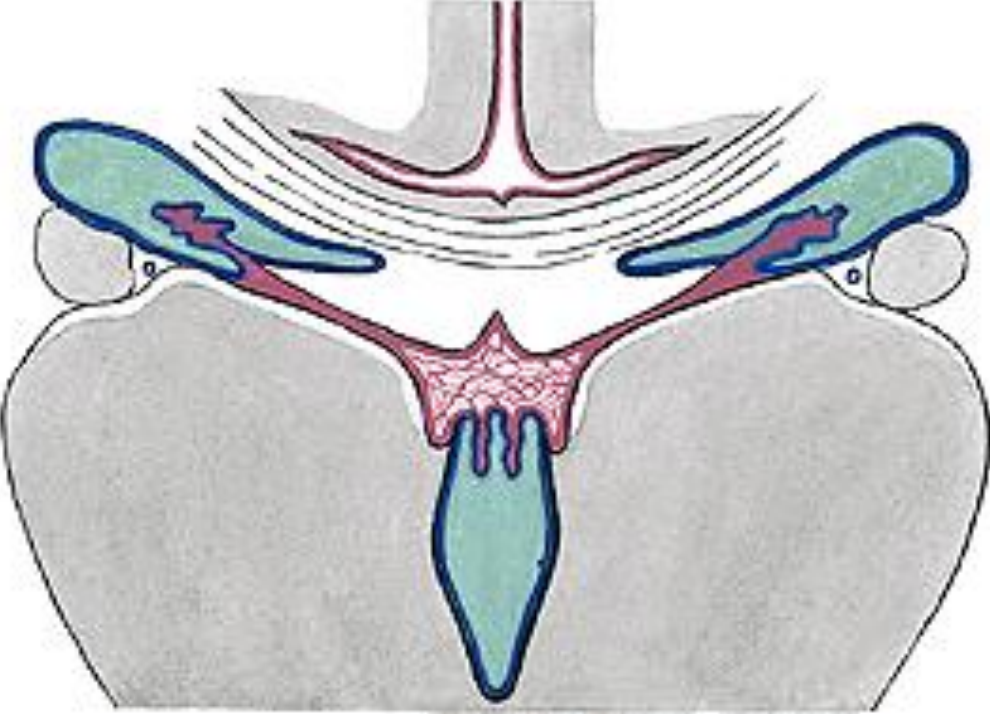


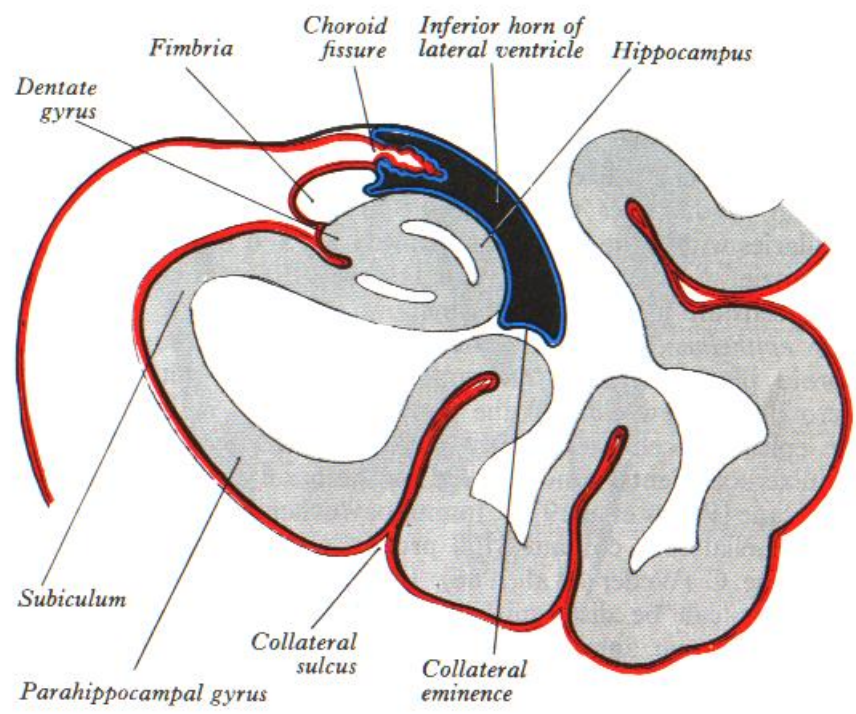
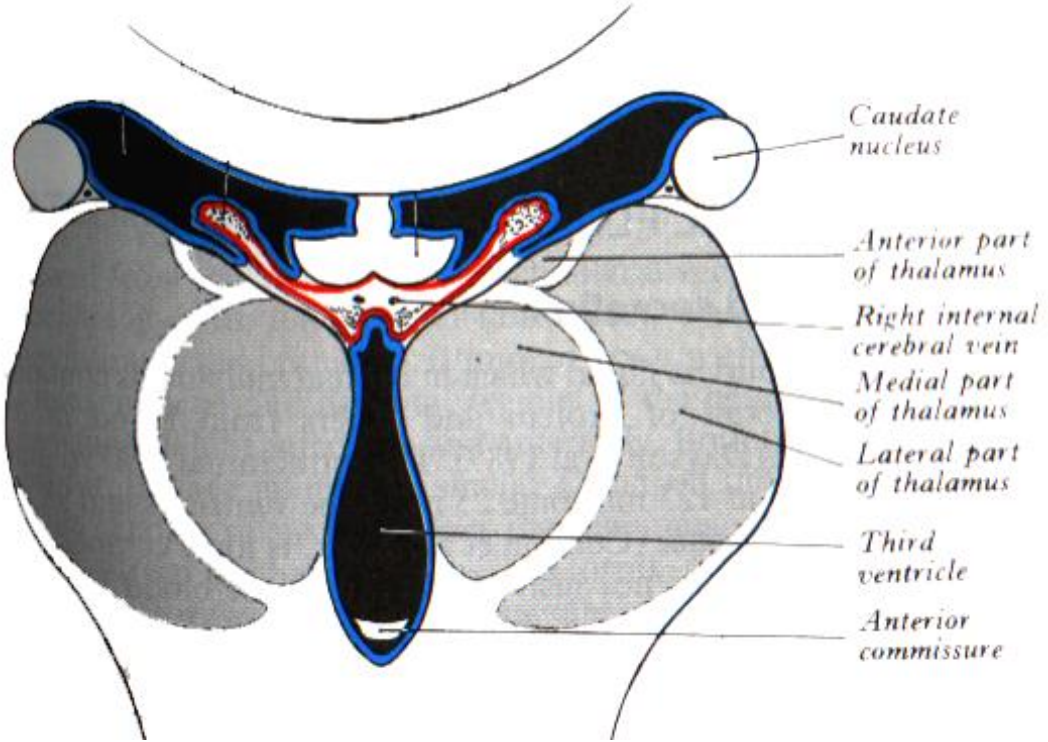
laterální průhled zleva

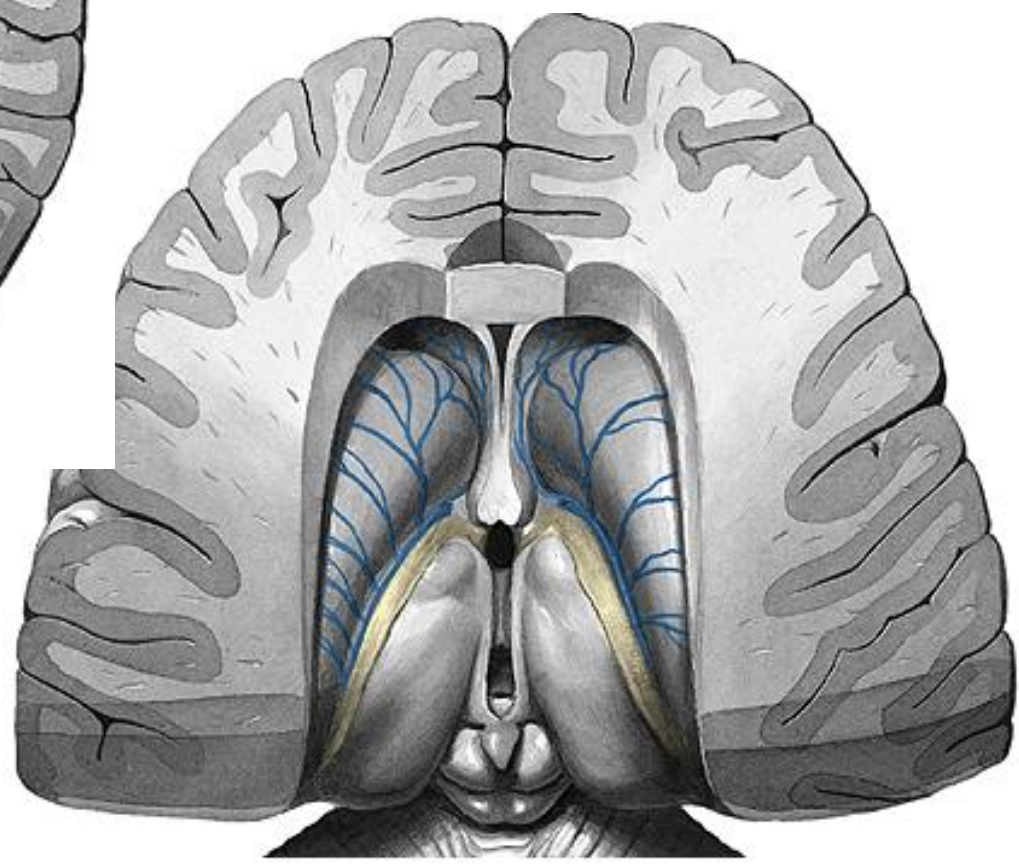
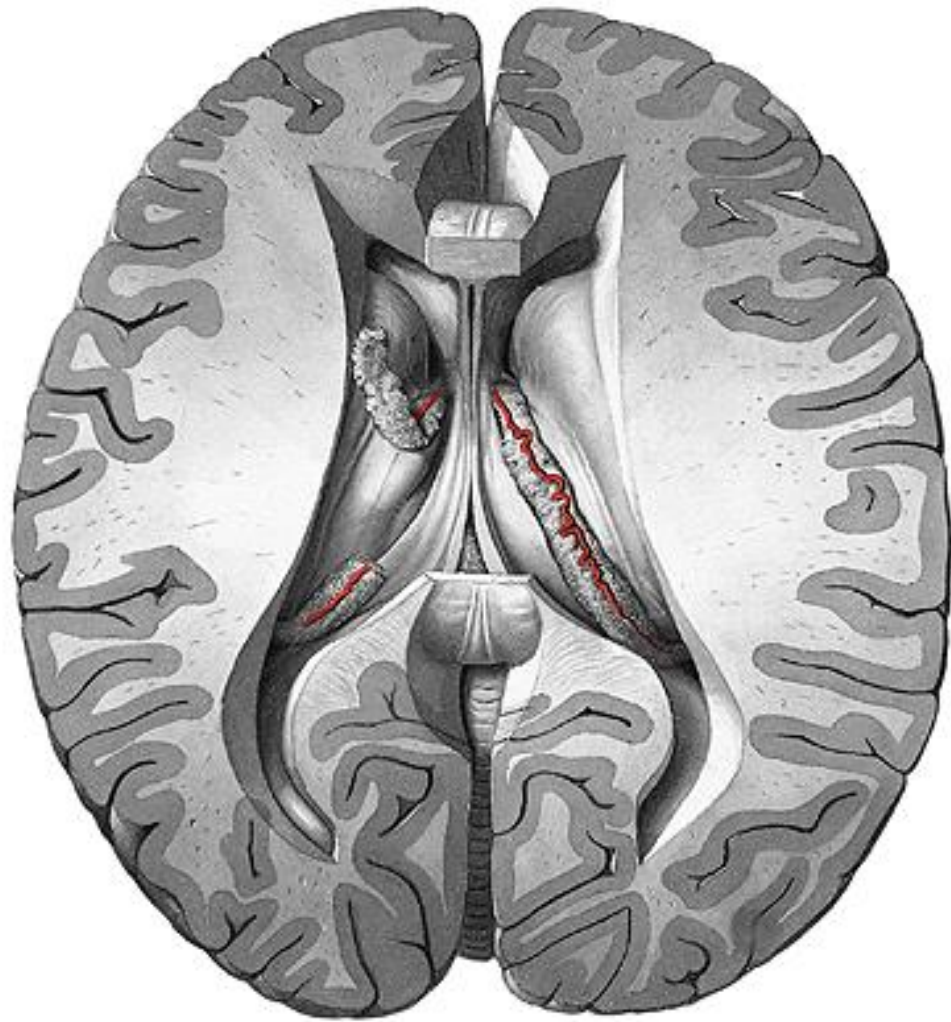




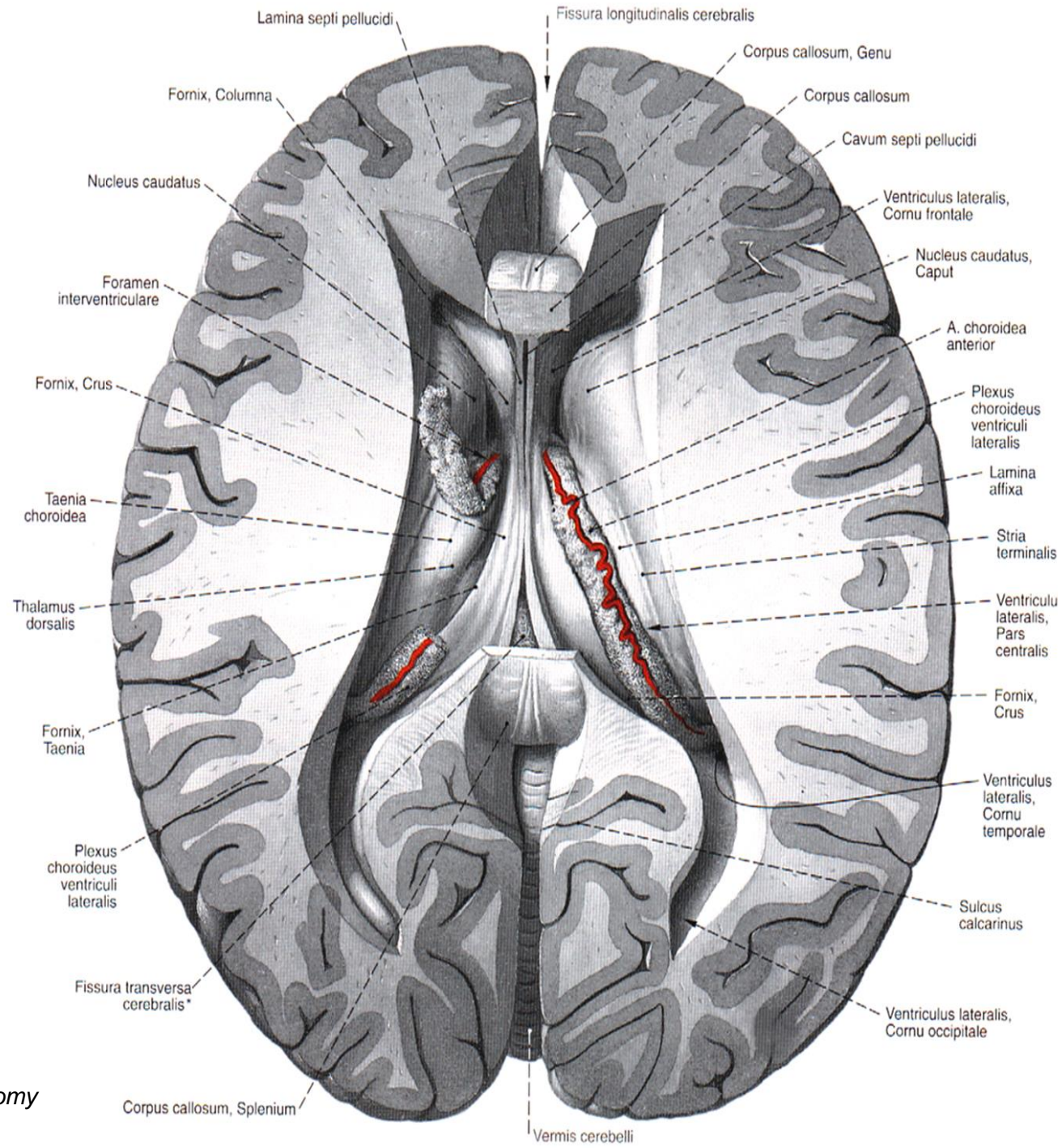




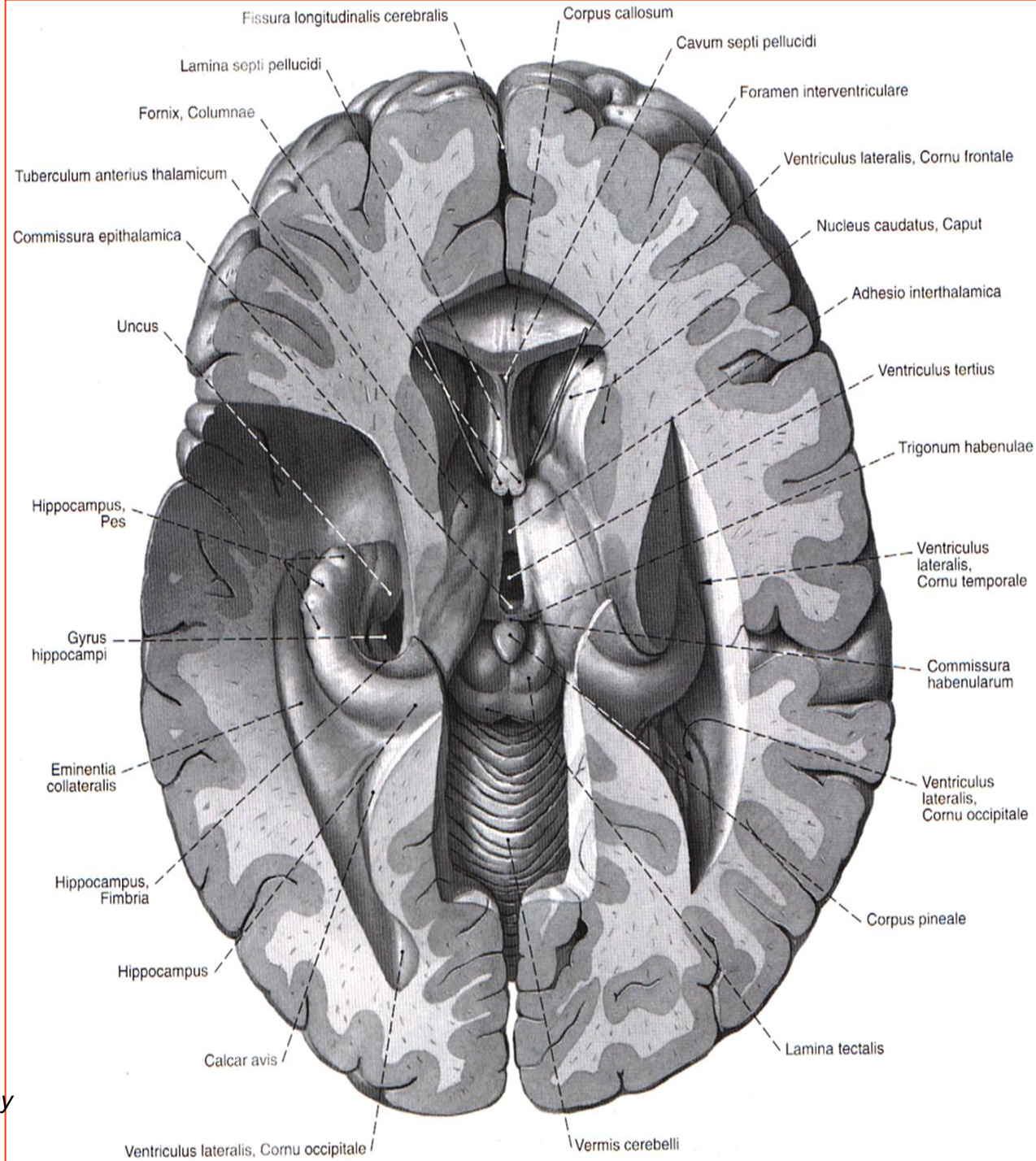




*Sobotta J, Figge FHJ. Atlas of human anatomy
Urban & Schwarzenberg, 1977*

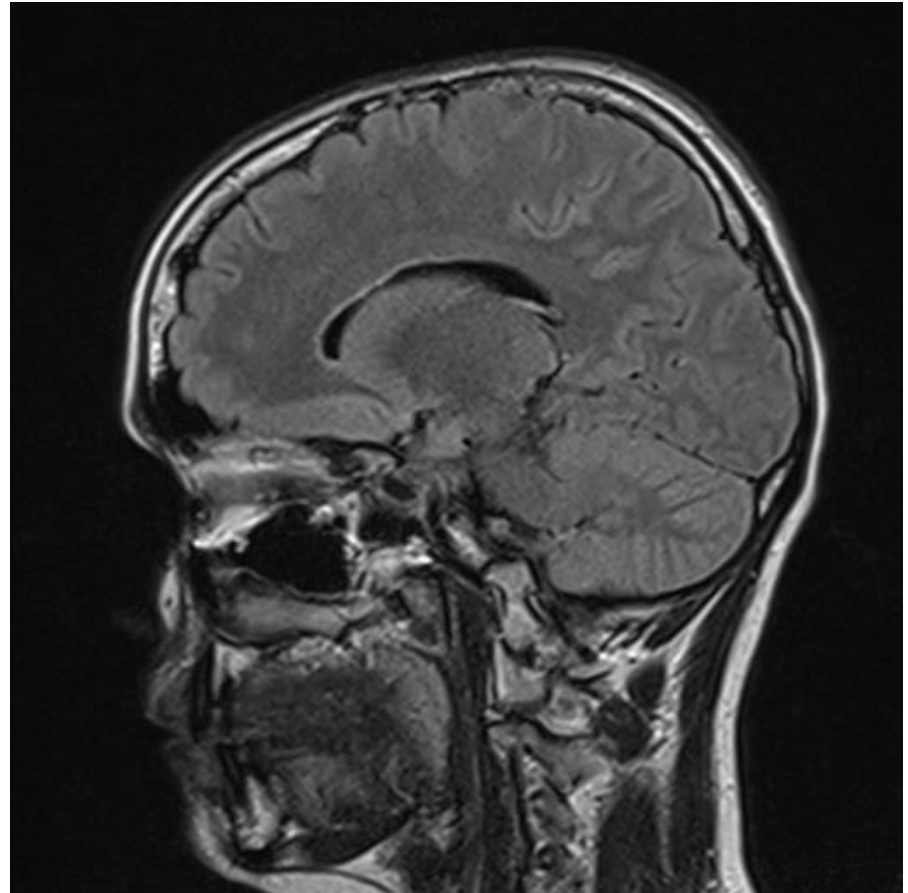
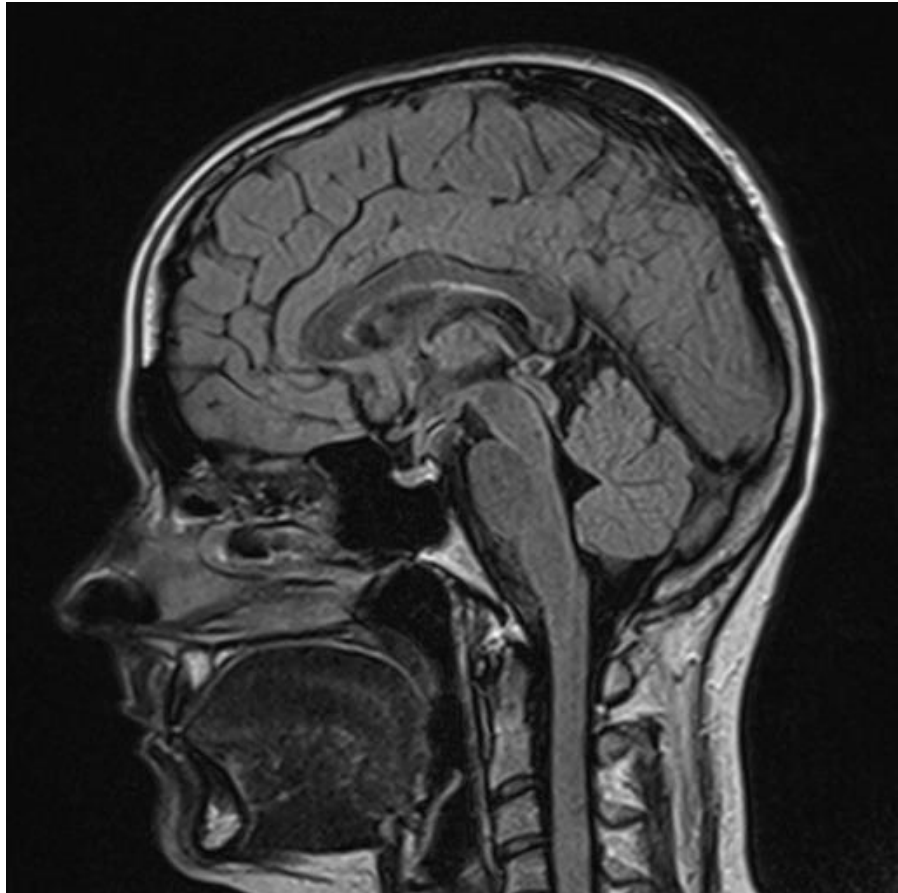


Sobotta J, Figge FHJ. Atlas of human anatomy
Urban & Schwarzenberg, 1977



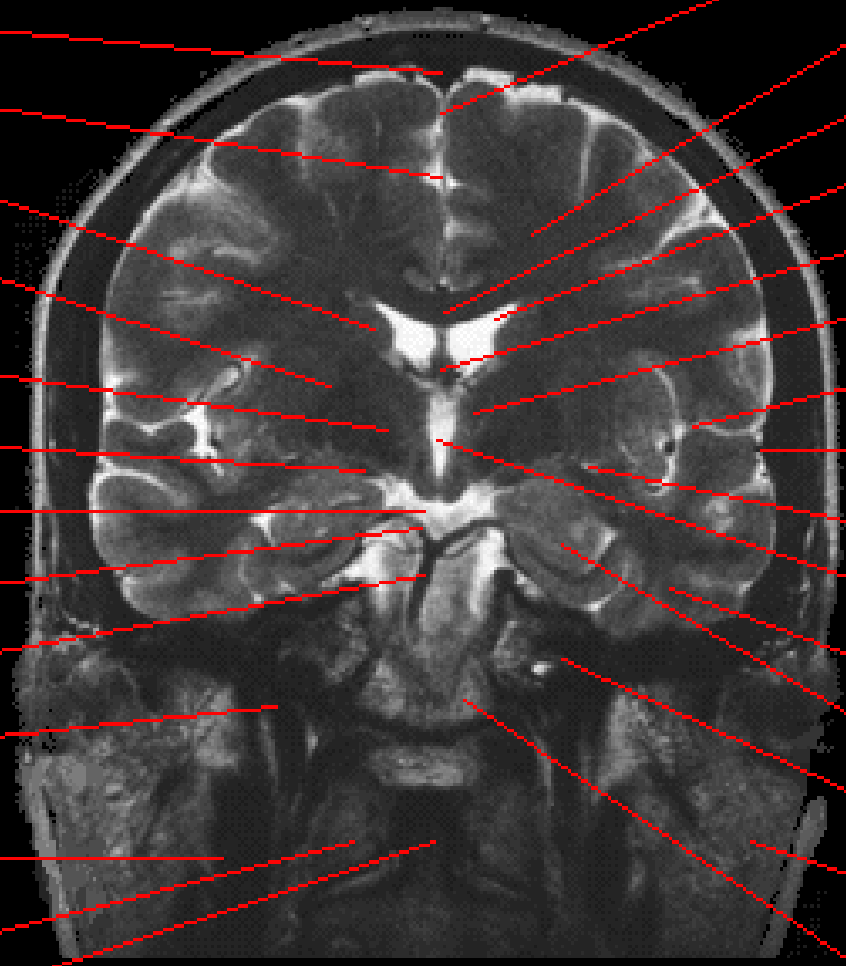
*Sobotta J, Figge FHJ. Atlas of human anatomy
 Urban & Schwarzenberg, 1977*

CT

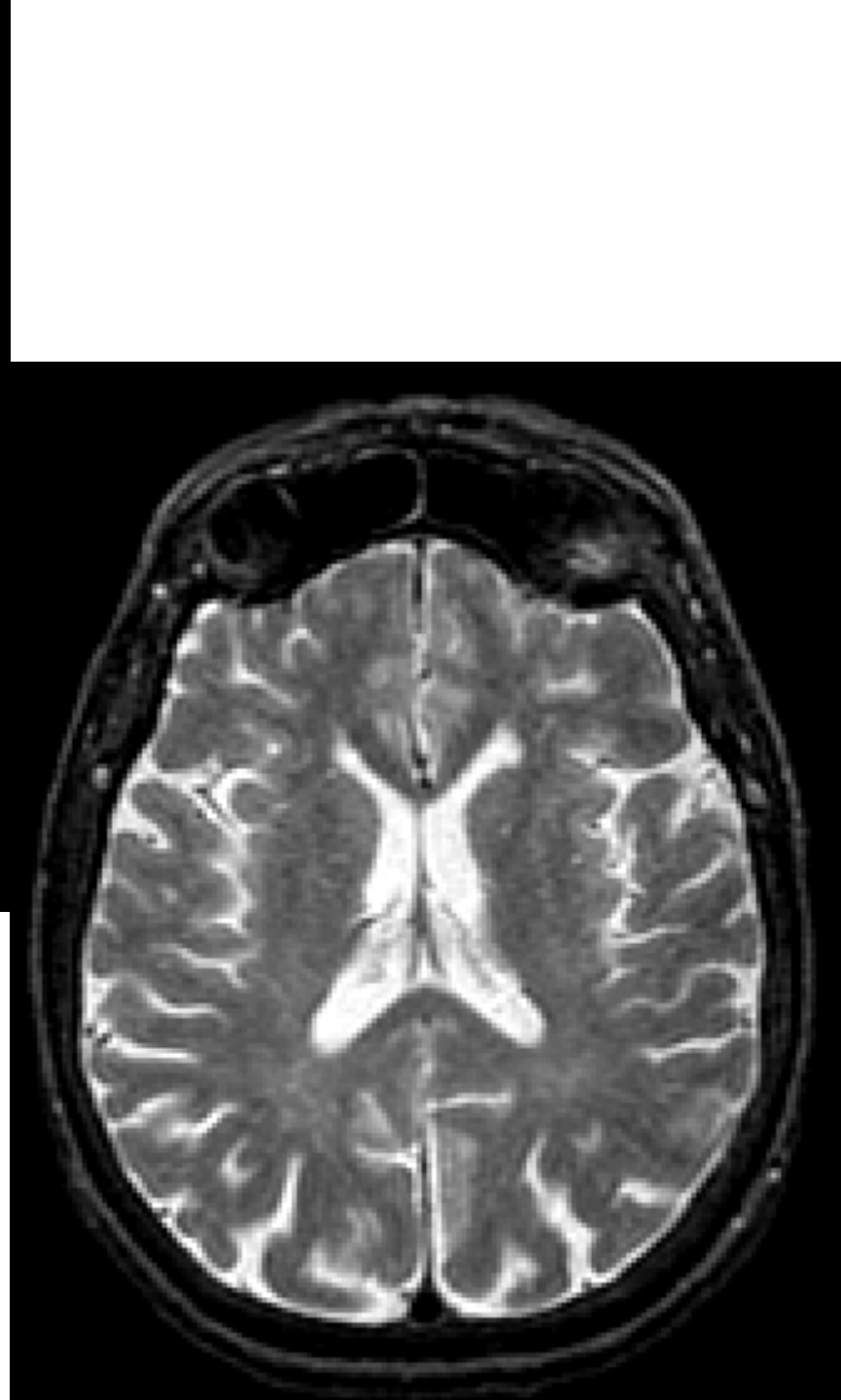
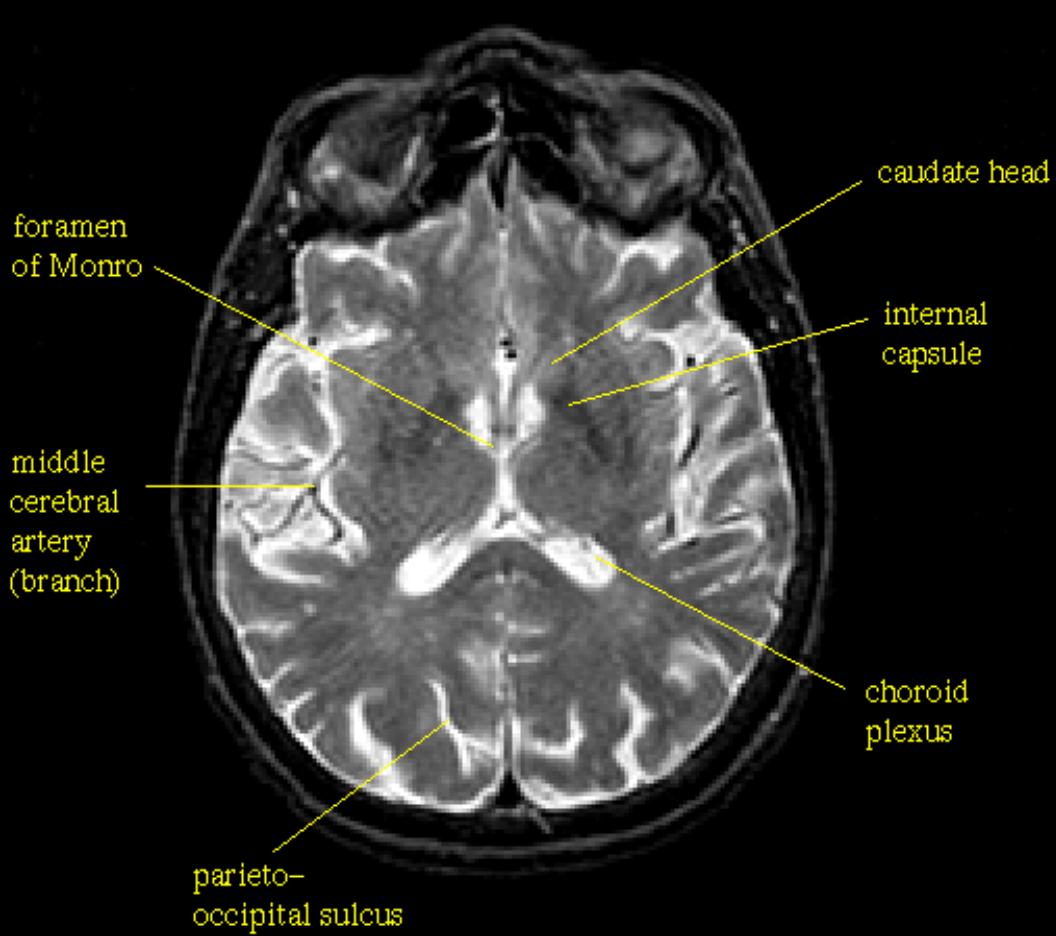


Slice 10/20

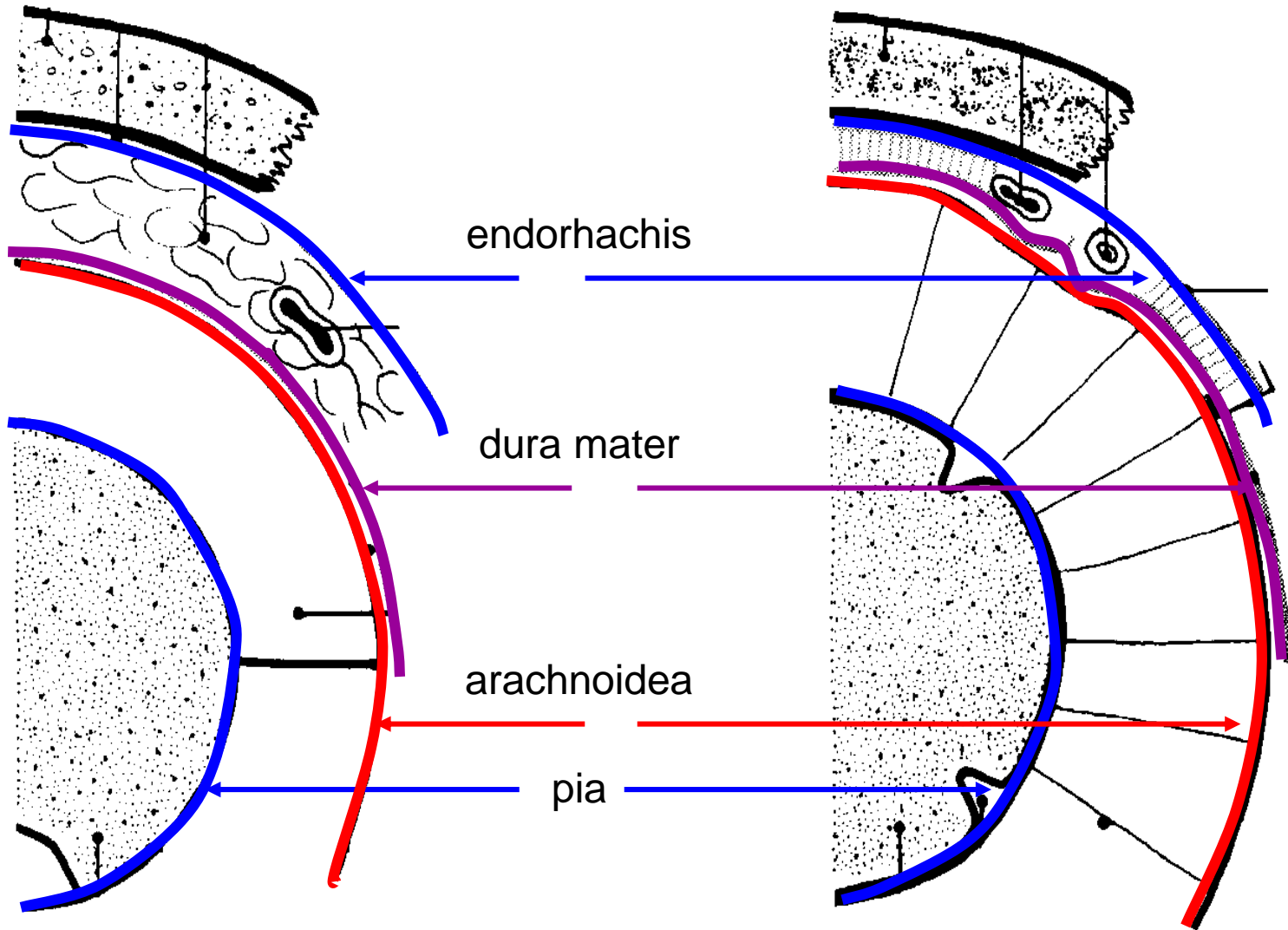
- Superior sagittal sinus
- Interhemispheric fissure
- Caudate nucleus
- Lentiform nucleus (putamen and pallidum)
- Internal capsule
- Optic tract
- Chiasmatic cistern
- Posterior communicating a.
- Basilar a.
- Internal carotid a.
- Internal jugular v.
- Atlas
- Dens of axis



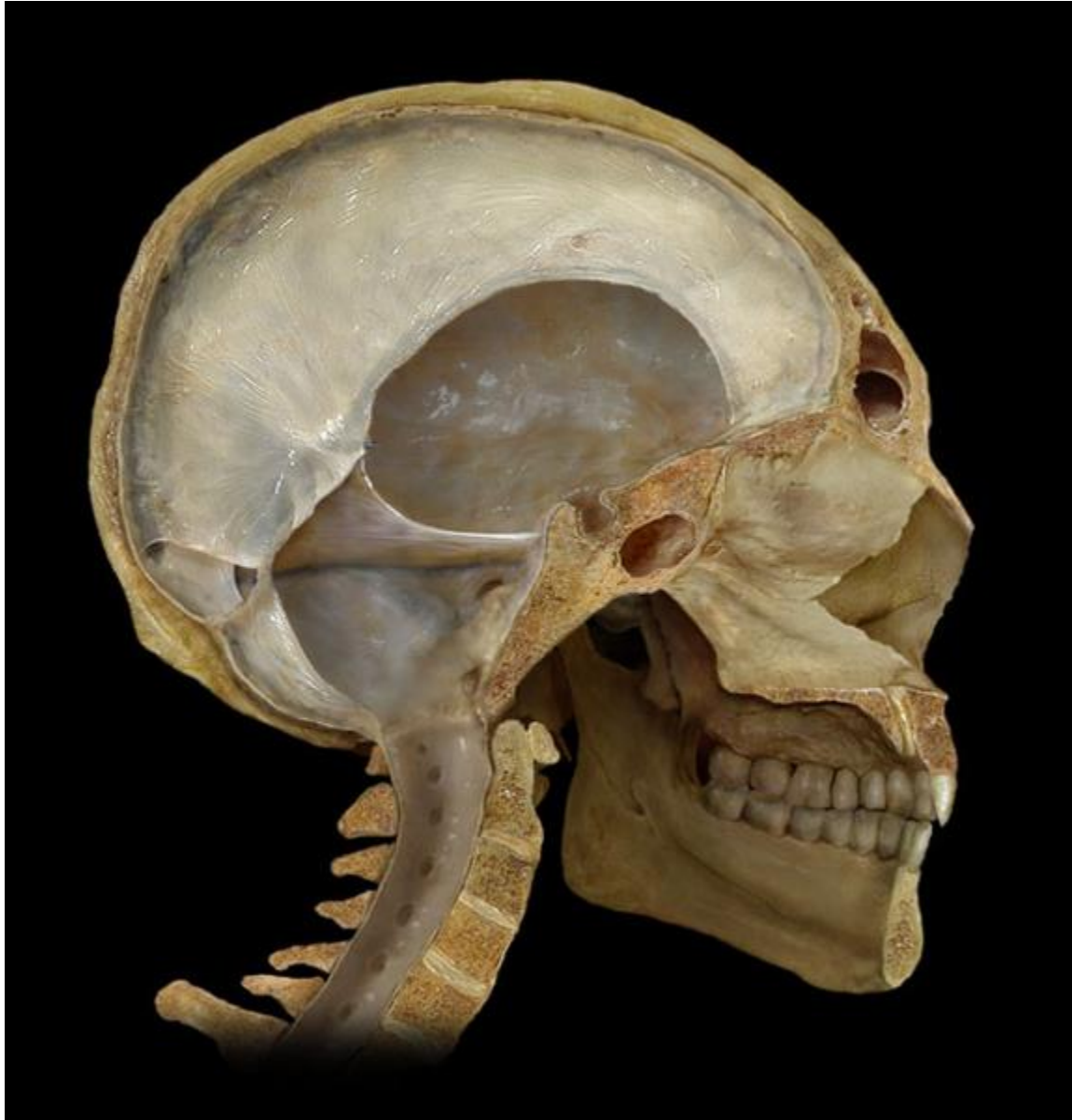
- Falx of cerebrum
- Subcortical white matter
- Corpus callosum
- Lateral ventricle
- Fornix
- Thalamus
- Lateral (sylvian) fissure
- Branches of middle cerebral a.
- Lateral ventricle (temporal horn)
- Third ventricle
- Temporal lobe
- Amygdaloid body
- Petrous pyramid
- Parotid gland
- Occipital bone



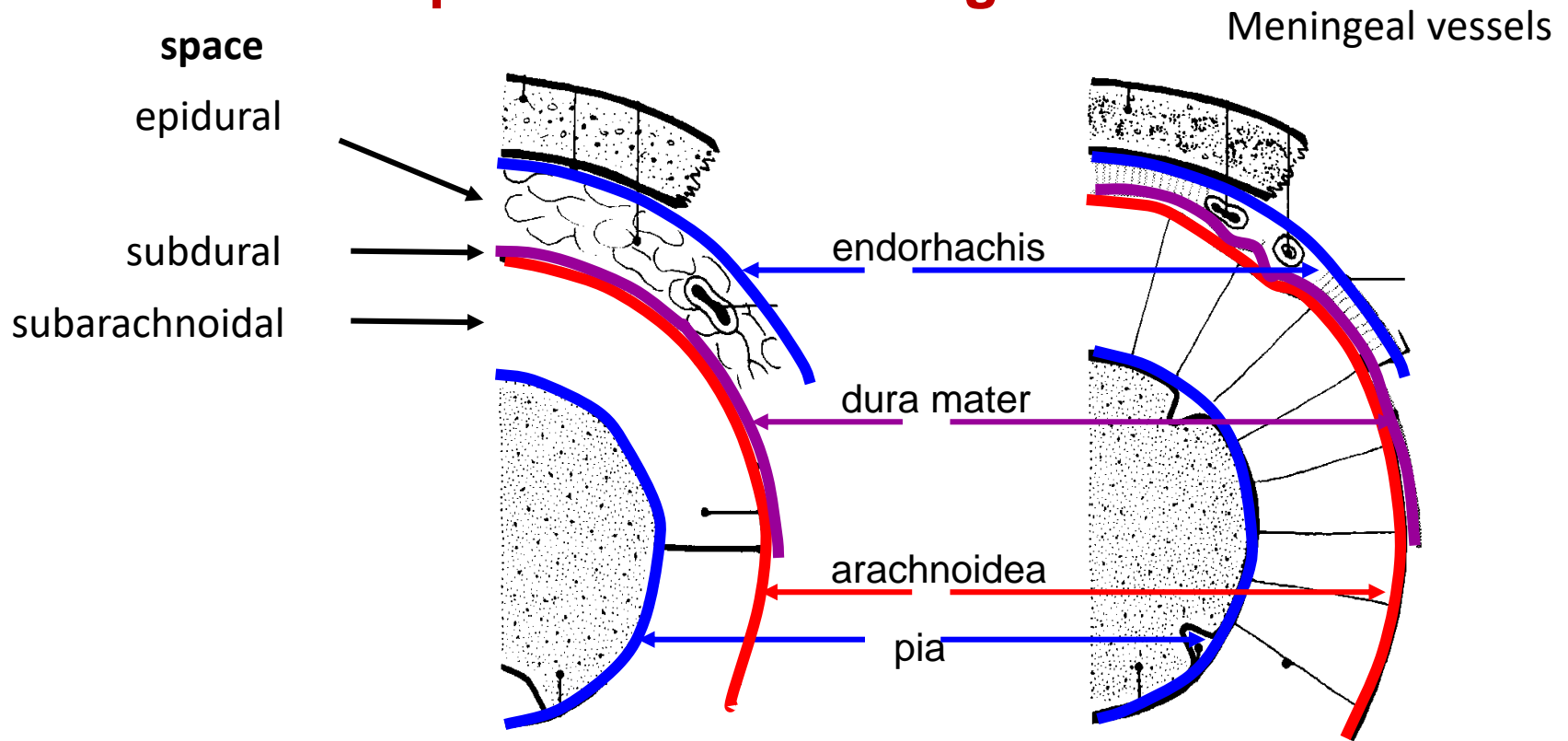
Meninges of CNS



Derivatives of the dura mater



Spaces about meninges



epidurální prostor

vyplněn vazivem a žilami

za fyziologického stavu neexistuje
traumaticky-epidurální krvácení

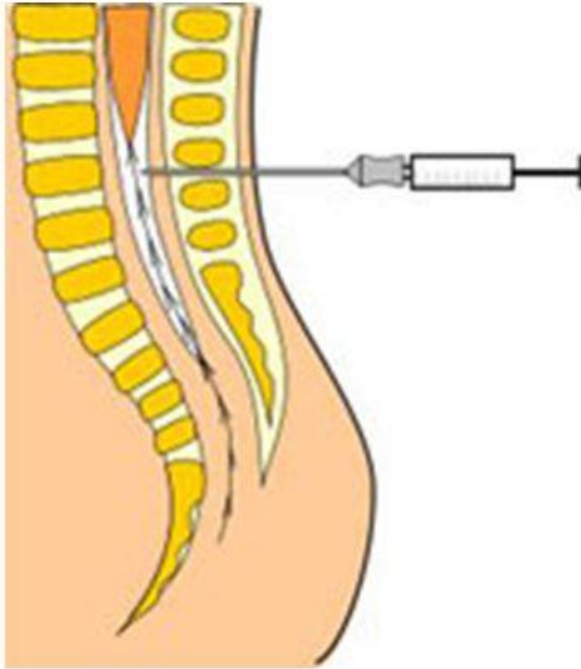
subdurální prostor

fyziologicky nepatrná štěrbina mezi dura mater a arachnoideu

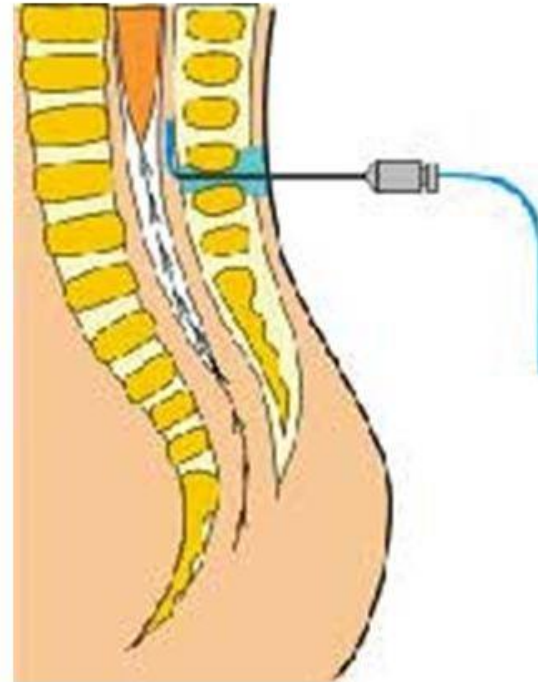
subarachnoideální prostor

mozkomíšní mok a
míšní cévy

mozkomíšní mok, cisterny, cévy
Willisova okruhu; aneuryzma,
subarachnoideální krvácení



Subarachnoid (spinal) block



Epidural administration (anaesthesia)

Innervation of meninges

Supratentorial compartment – n. trigeminus

Infratentorial compartment – spinal nerves (branches of C2 and C3)

Dura mater – blood supplied

- a. carotis interna → a. ophthalmica → a. ethmoidalis ant. → **a. meningea anterior**
- a. carotis externa → a. maxillaris → **a. meningea media**
- a. carotis externa → a. pharyngea ascendens → **a. meningea posterior**
- a. vertebralis → **rr. meningei**

Cerebrospinal fluid - liquor cerebrospinalis (CSF, liquor)

- clear and colorless liquid in CNS chambers and subarachnoid space
- In contrast to blood plasma – low level of proteins and amount of cells
(1 mm³ CSF of a healthy individual contains 1-5 cells)
- produced by secretion, about **70% in chorioid plexus of lateral chambers and roof of the IIIrd**
rest of CSF by metabolism of cells and as capillary ultrafiltrat
- 500-800 ml/day
- total volume of CSF in chamber system and subarachnoid space is 80-150 ml, but in chambers
only 15-40 ml

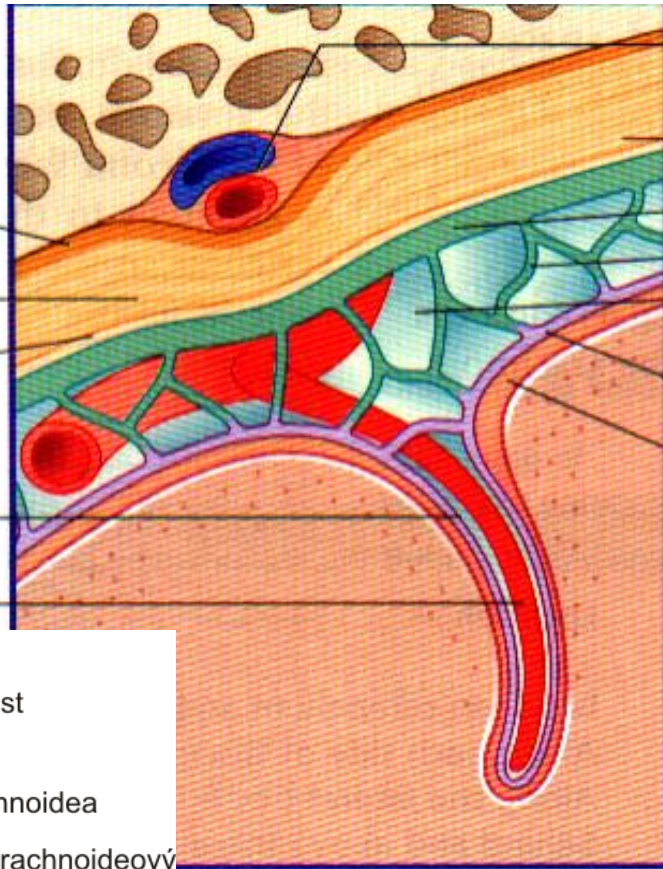Cerebrospinal fluid - function

- CSF protects the brain from damage that could cause shocks in sudden head movements
- CSF removes metabolic waste products, drugs and other substances diffused from the blood into the CNS
- CSF keeps the microenvironment of neurons and glia
- CSF has immune function
- CSF plays an important role in the integration of brain and endocrine function


C

Endosteum
 Fibrous layer of dura mater
 Cellular layer of dura mater
 Perivascular space
 Branch of cerebral artery

Meningeal vessels
 *
 Arachnoid mater
 Arachnoid trabecula
 Subarachnoid space
 Pia mater
 Subpial space



*M.J.T. FitzGerald et al. 2007.
 Clinical Neuroanatomy and Neuroscience.*

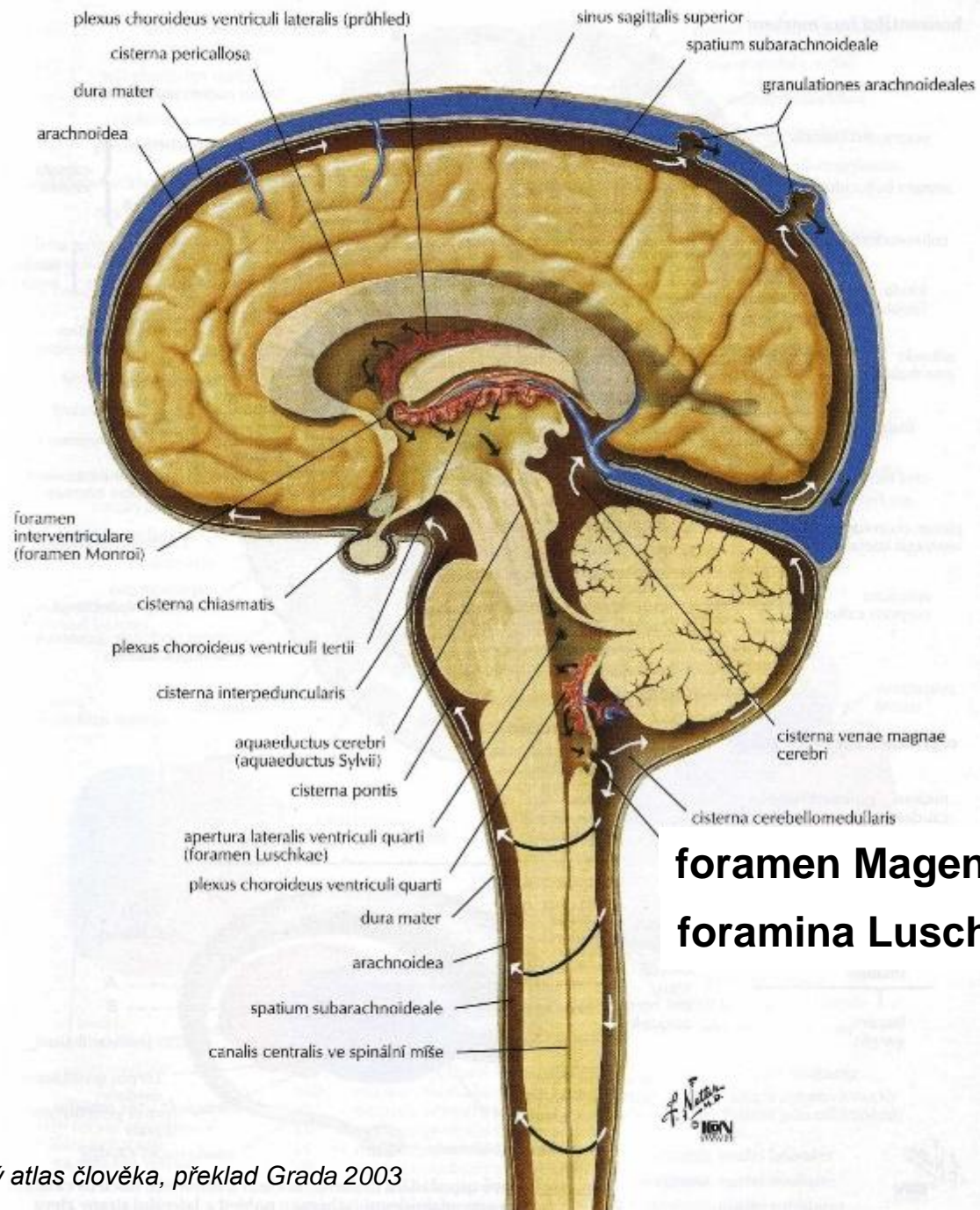


kost
 periost
 dura
 arachnoidea
 subarachnoideový
 prostor
 perivaskulární
 prostor

Perivaskular Robinn-Virchow's space

Cerebrospinal fluid - circulation

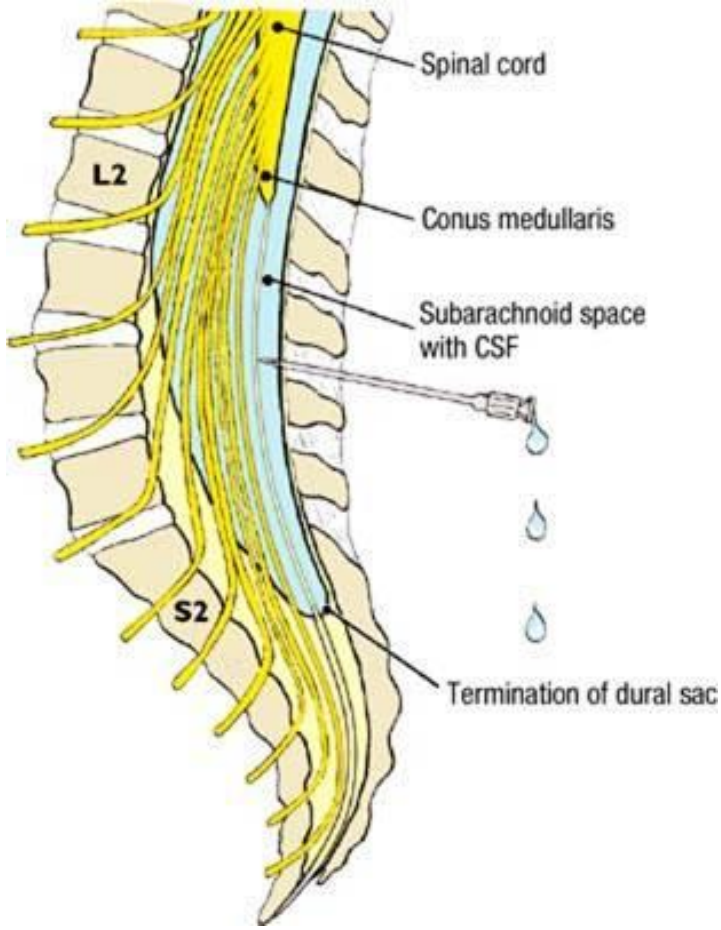
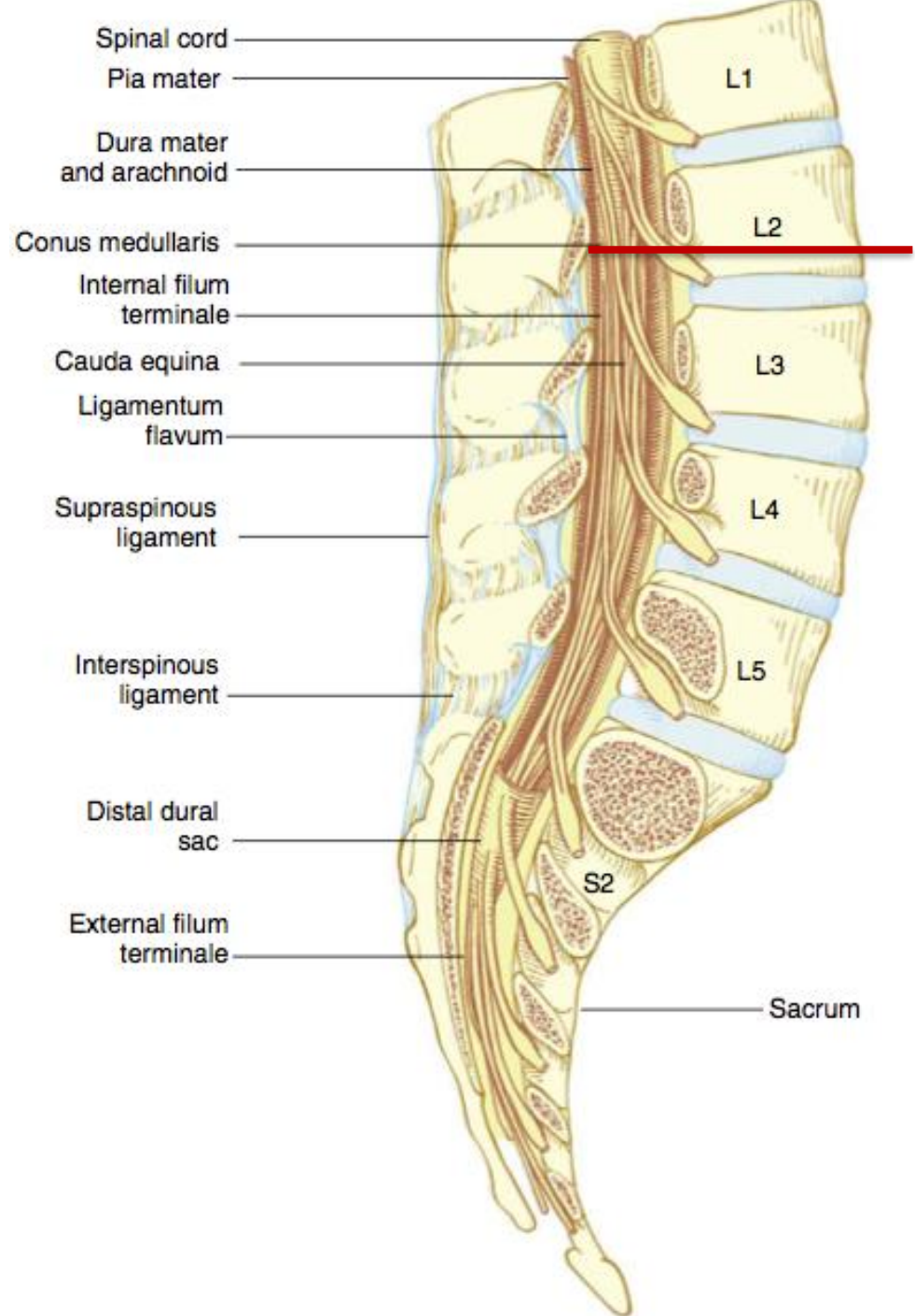
- produced in the lateral ventricles enters the IIIrd ventricle through **the interventricular foramen** (foramen Monroi)
- from the IIIrd ventricle flows through **the cerebral aqueduct** into the IVth ventricle
- from the IVth ventricle into the subarachnoid space through openings in the roof of the IVth ventricle; the larger median **foramen Magendii** (*apertura mediana ventriculi quarti*) and two lateral foramina of Luschka (*aperturae laterales ventriculi quarti*)
- most of CSF is absorbed into the venous system through **the arachnoid villi** (*granulationes arachnoideales Pacchioni*)



foramen Magendie
foramina Luschkae

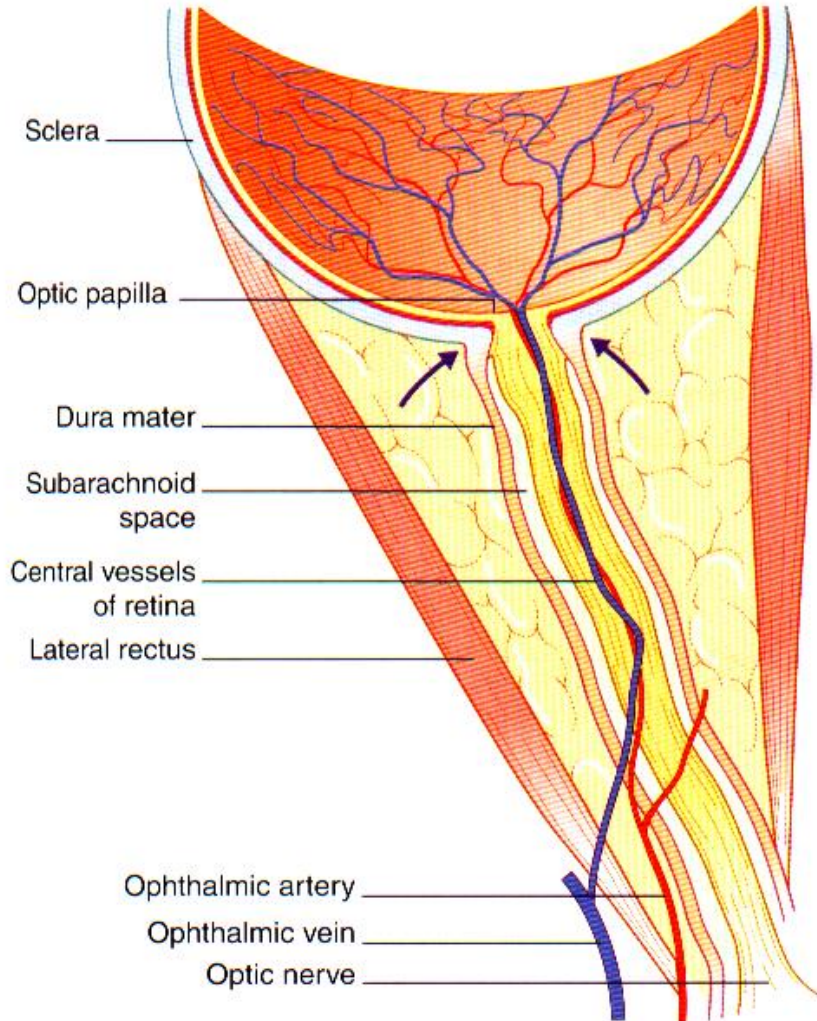
F. Netter
 M.D.
 © 1989

Lumbar puncture

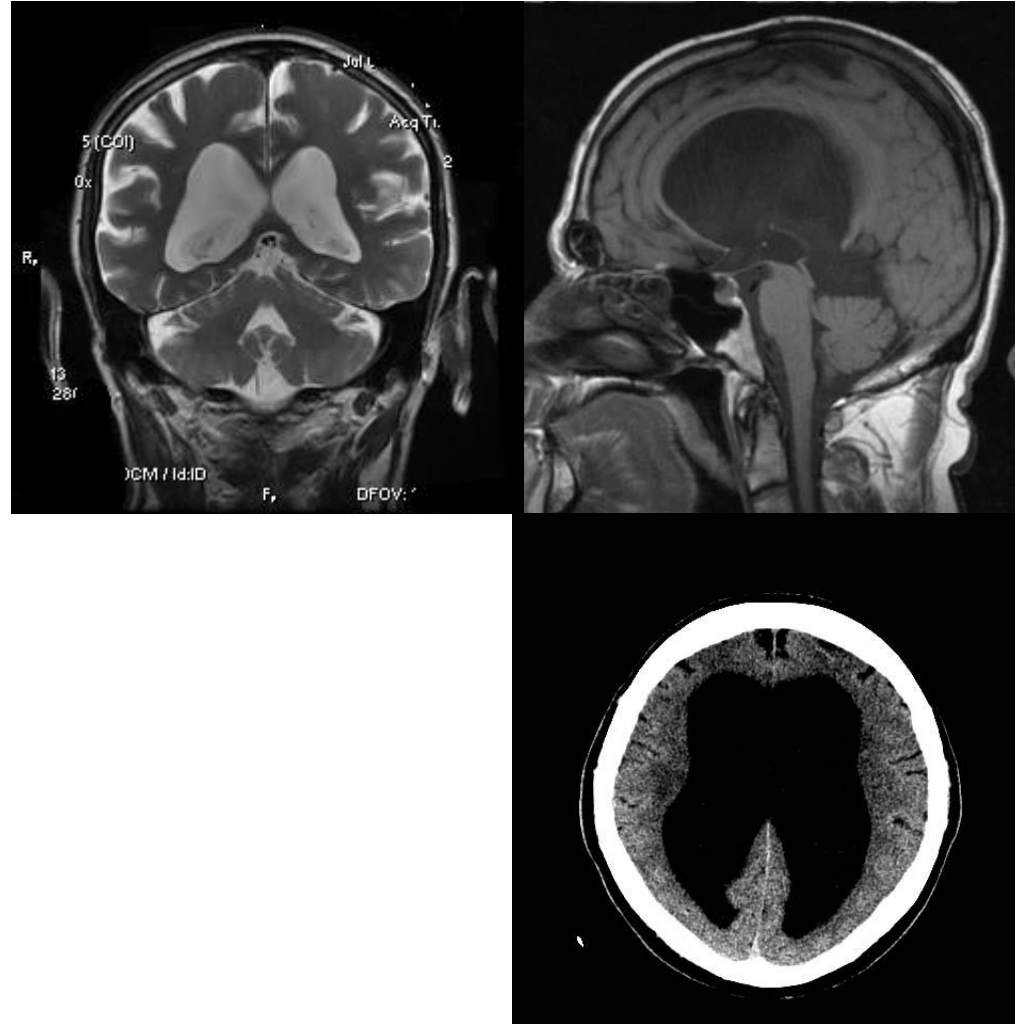


Increased pressure of CSF

Increased pressure of CSF along the optic nerve – compression of v. centralis retinae – papilledema, papillary edema



increased intracranial pressure - **Hydrocephalus**

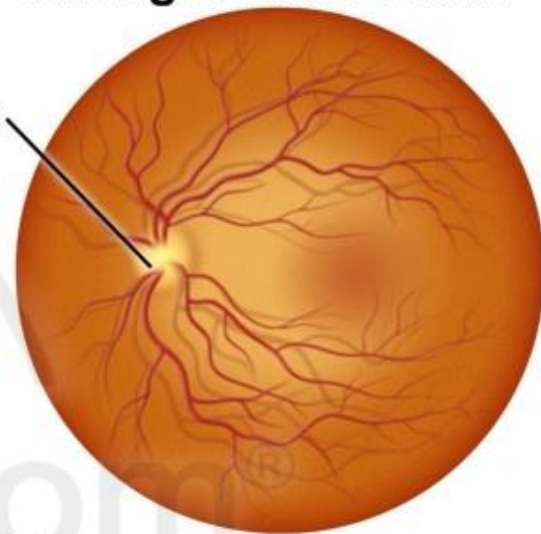
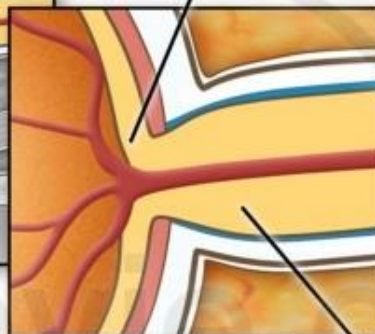
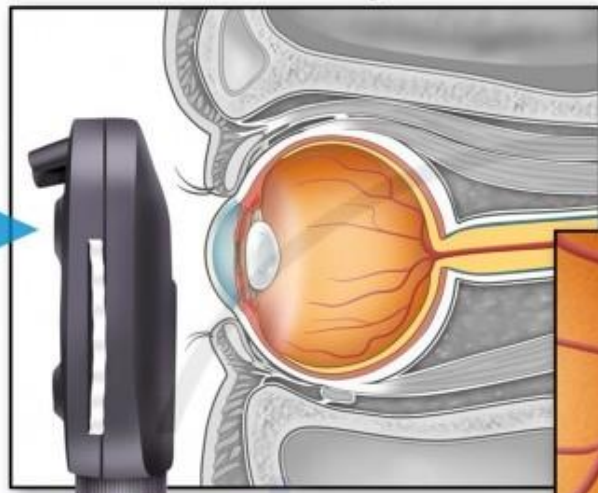


Fundus Exam - Normal vs. Papilledema

Normal eye

Normal retina as seen during fundus exam

Physician looks through ophthalmoscope

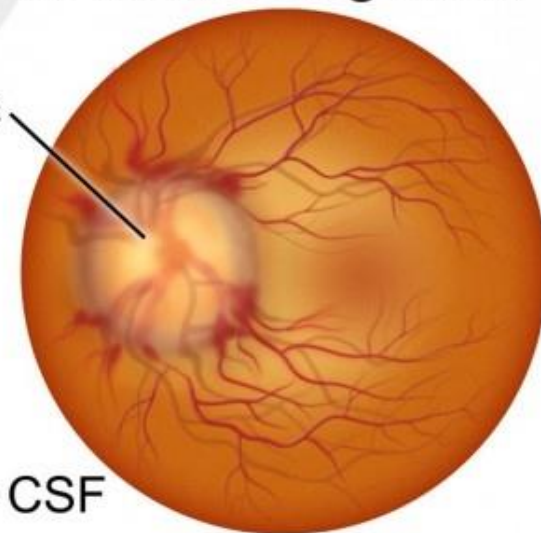
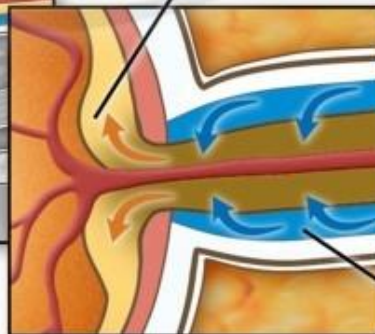
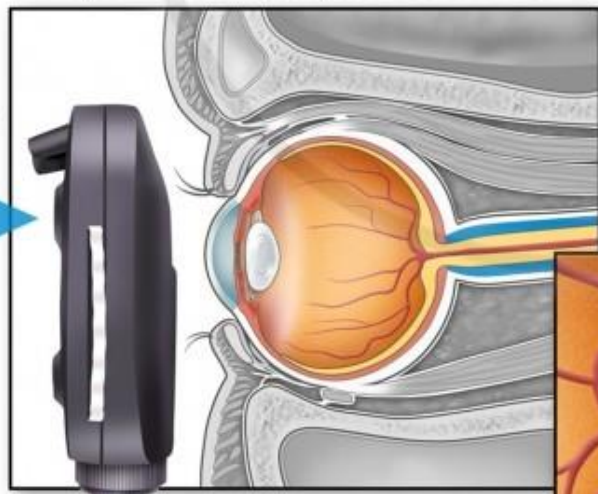


Optic nerve

Eye with papilledema

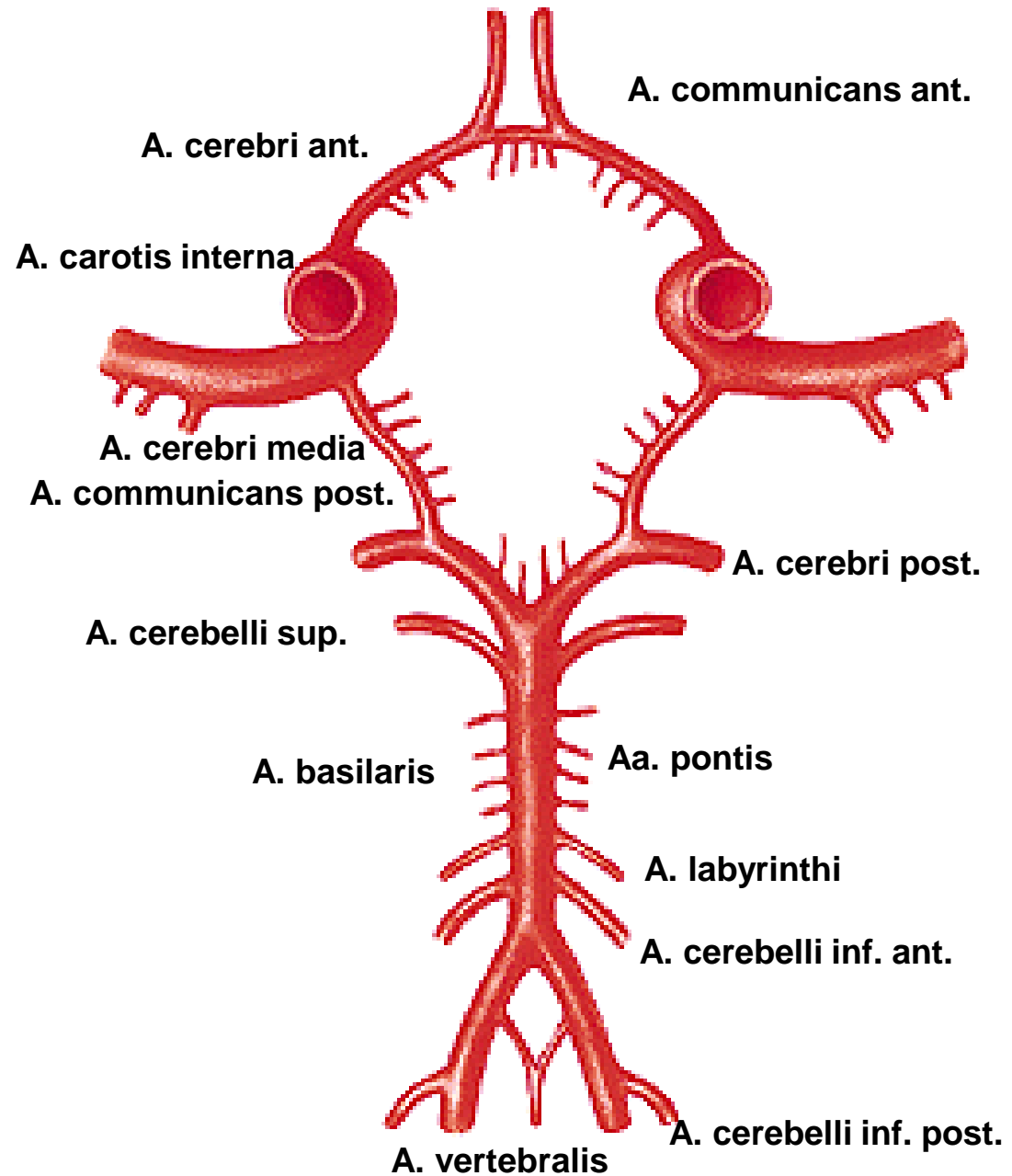
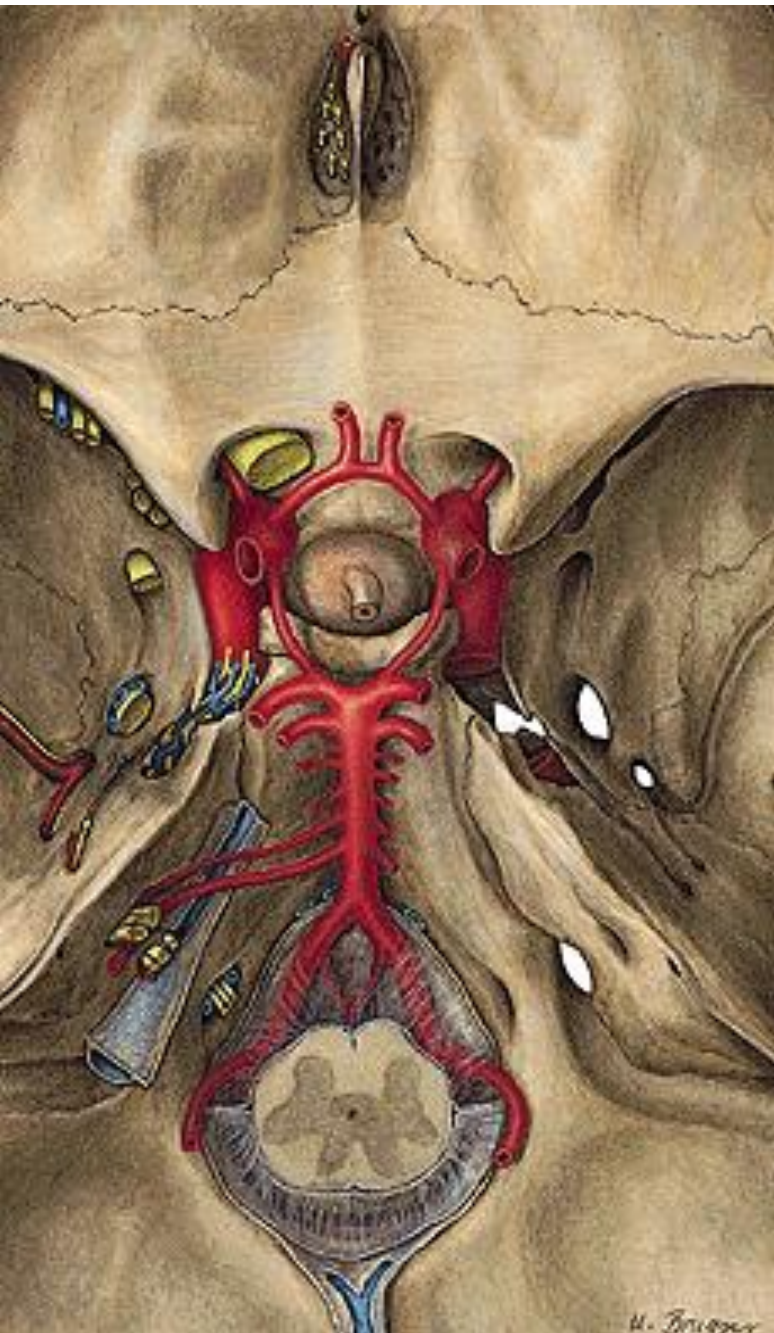Retina with papilledema as seen during exam

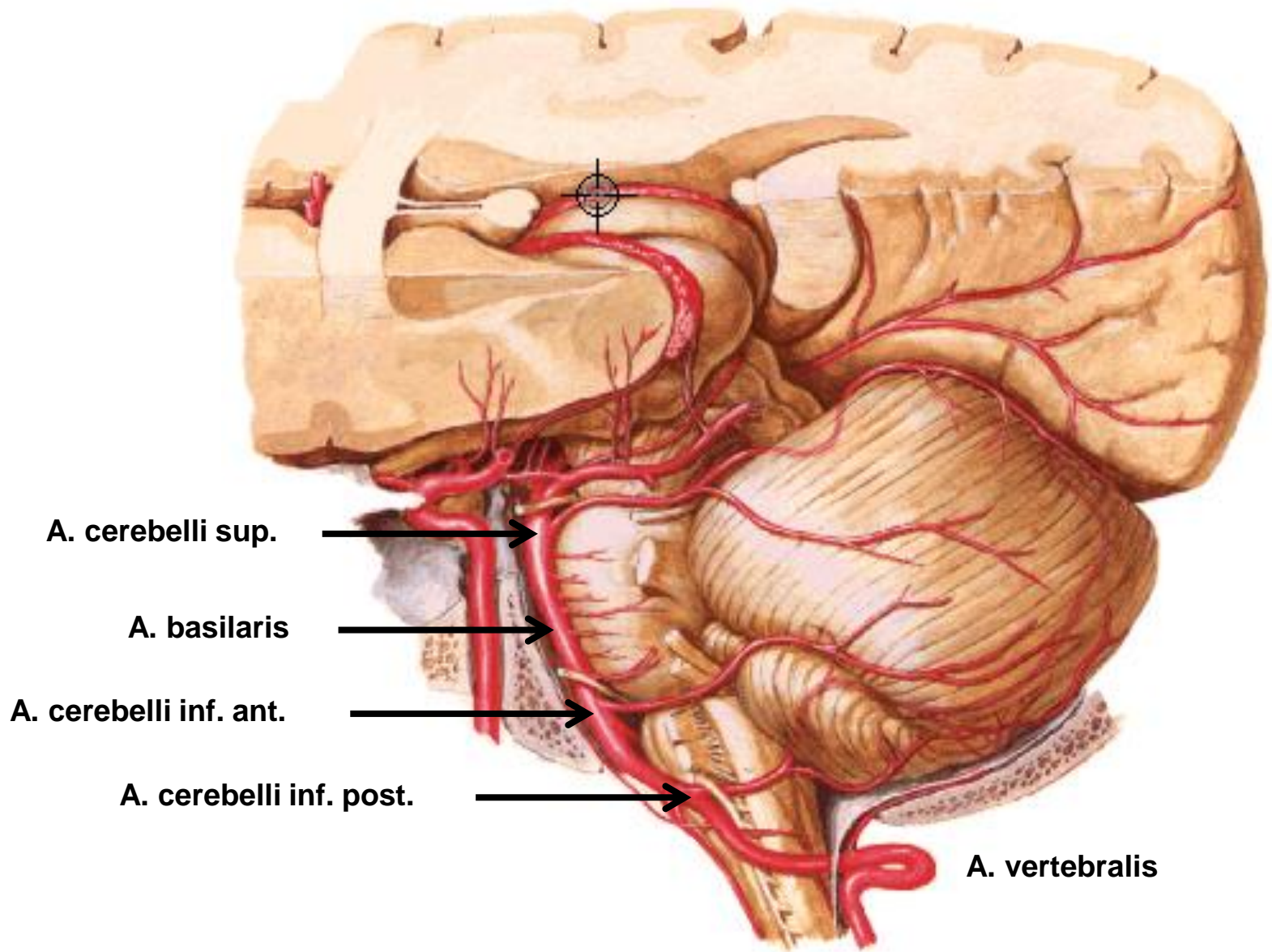
Physician looks through ophthalmoscope

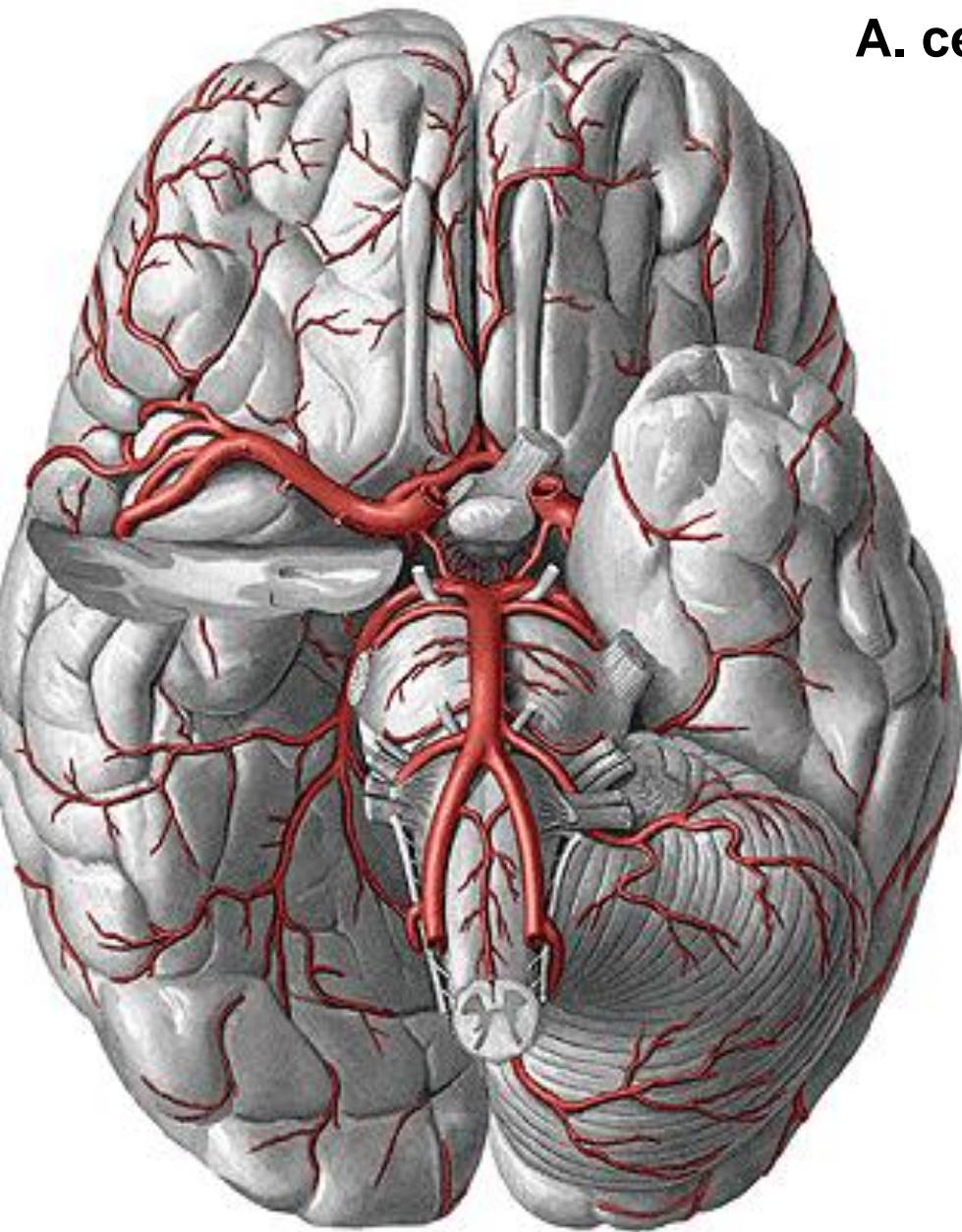


CSF

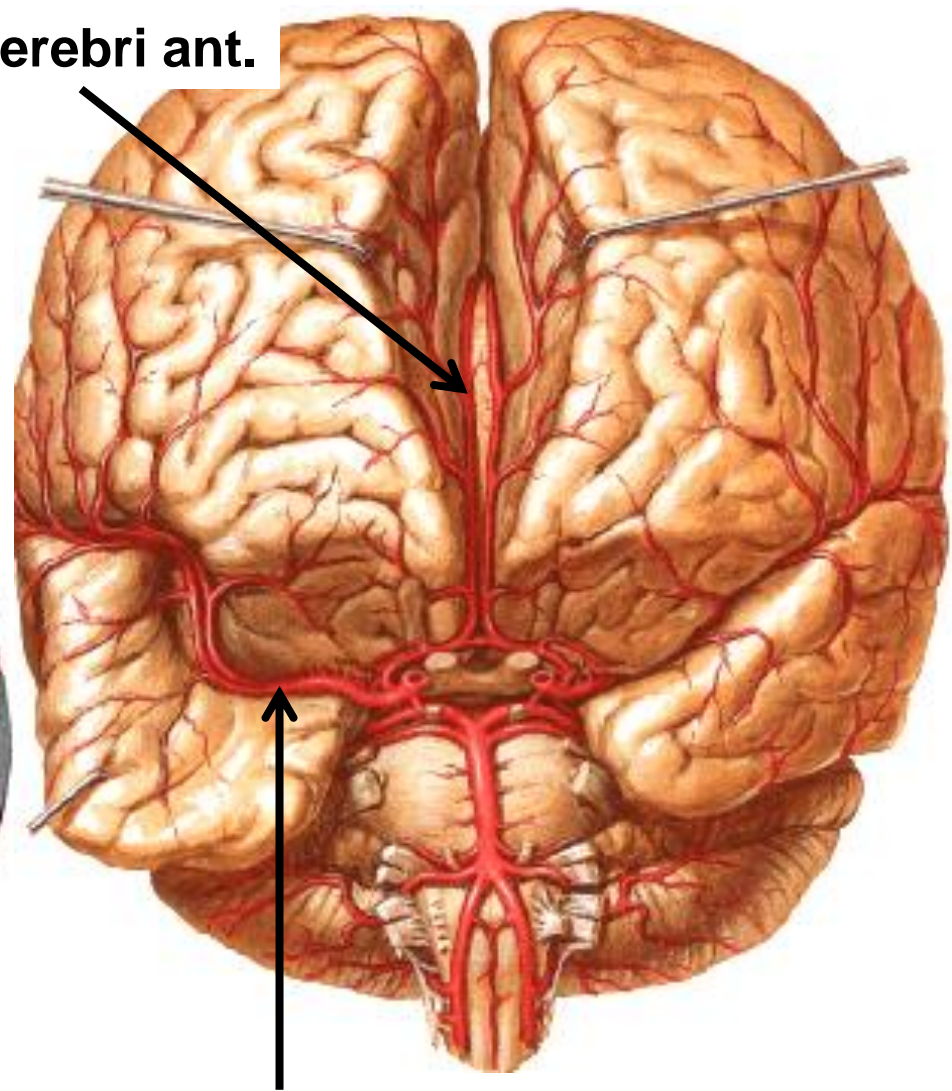
Circulus arteriosus cerebri (Willisi), Circle of Willis



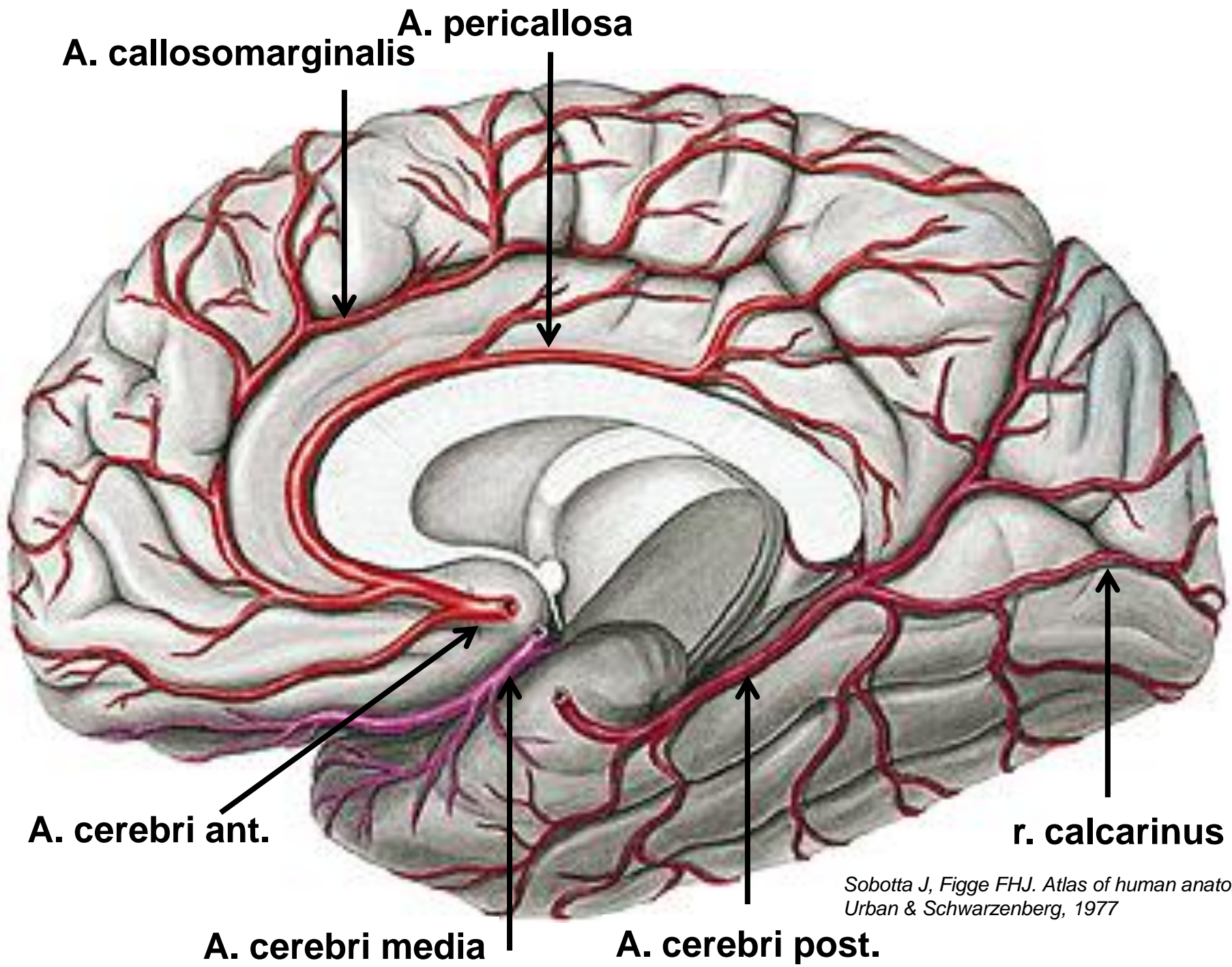




A. cerebri ant.



A. cerebri media



A. callosomarginalis

A. pericallosa

A. cerebri ant.

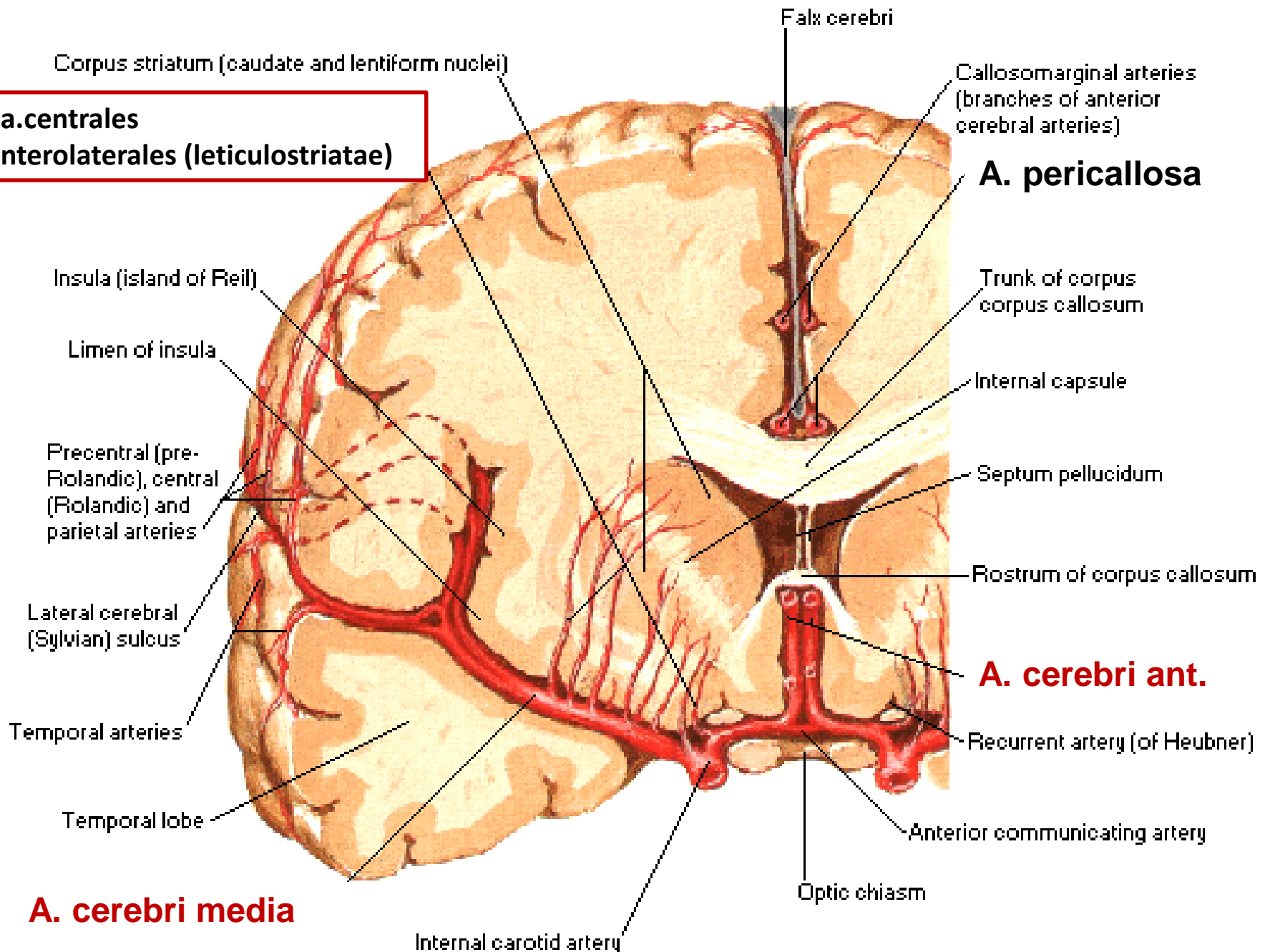
A. cerebri media

A. cerebri post.

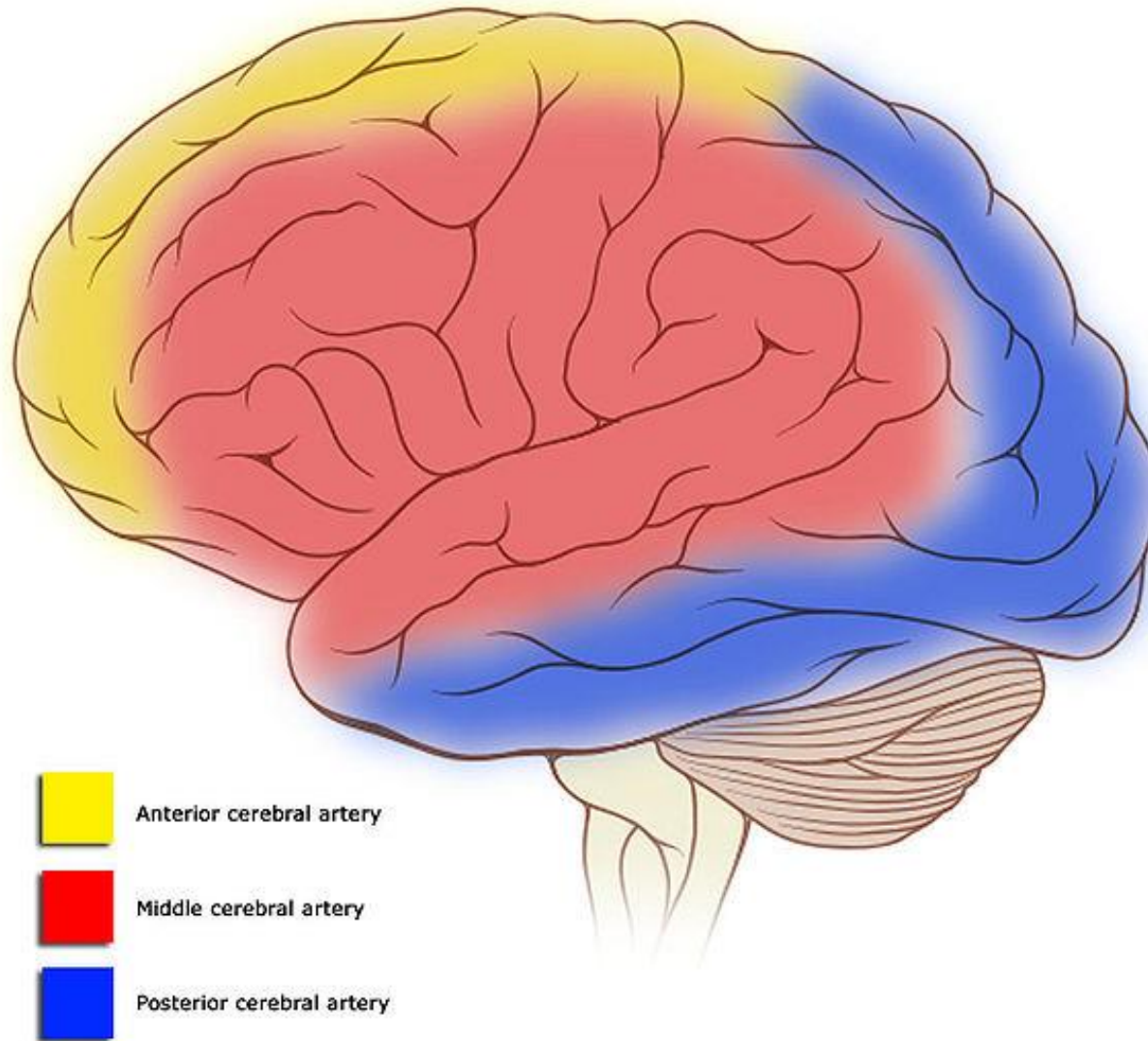
r. calcarinus

*Sobotta J, Figge FHJ. Atlas of human anatomy
Urban & Schwarzenberg, 1977*

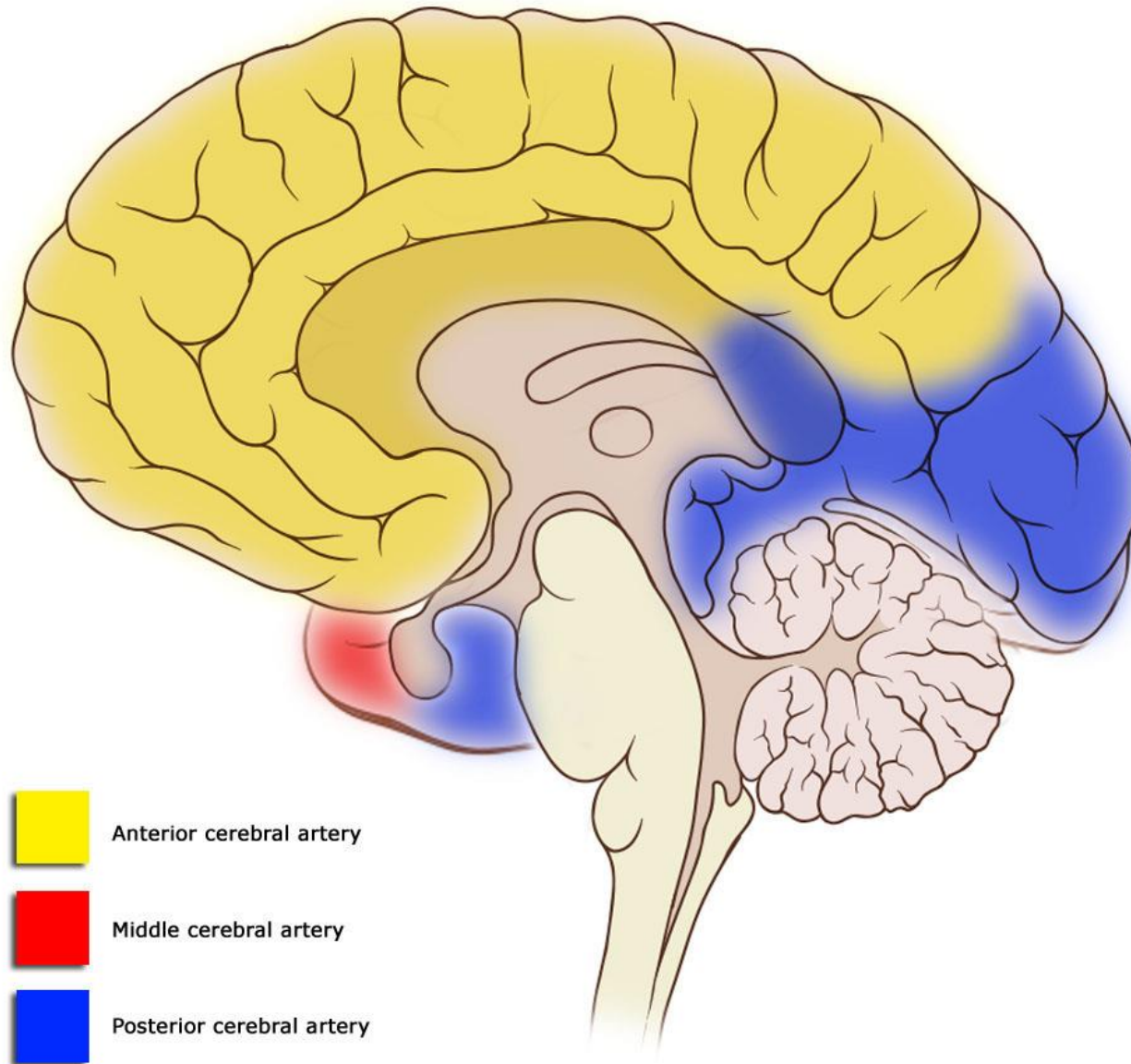
**aa.centrales
anterolaterales (lenticulostricatae)**

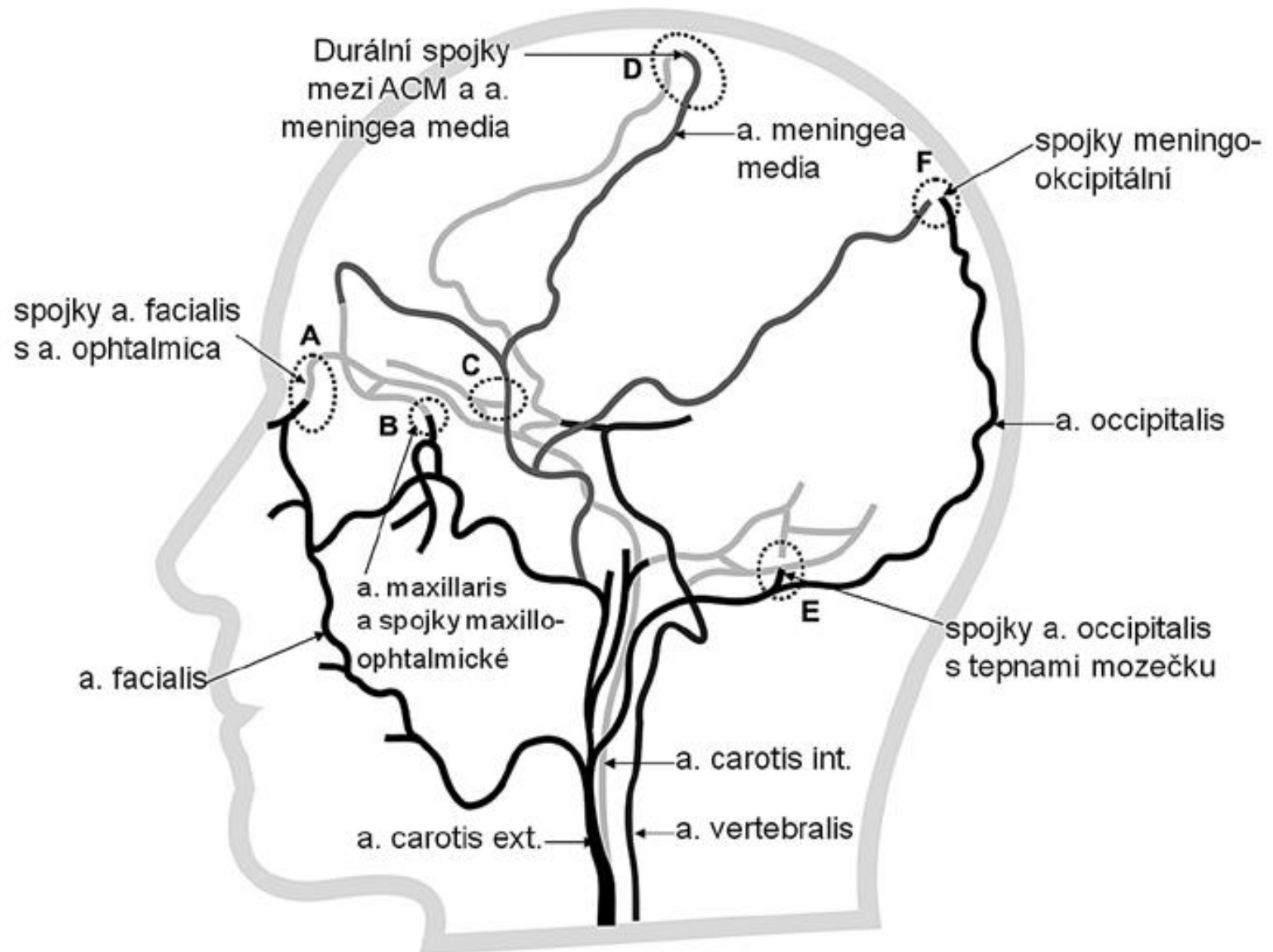


Cortical vascular territories



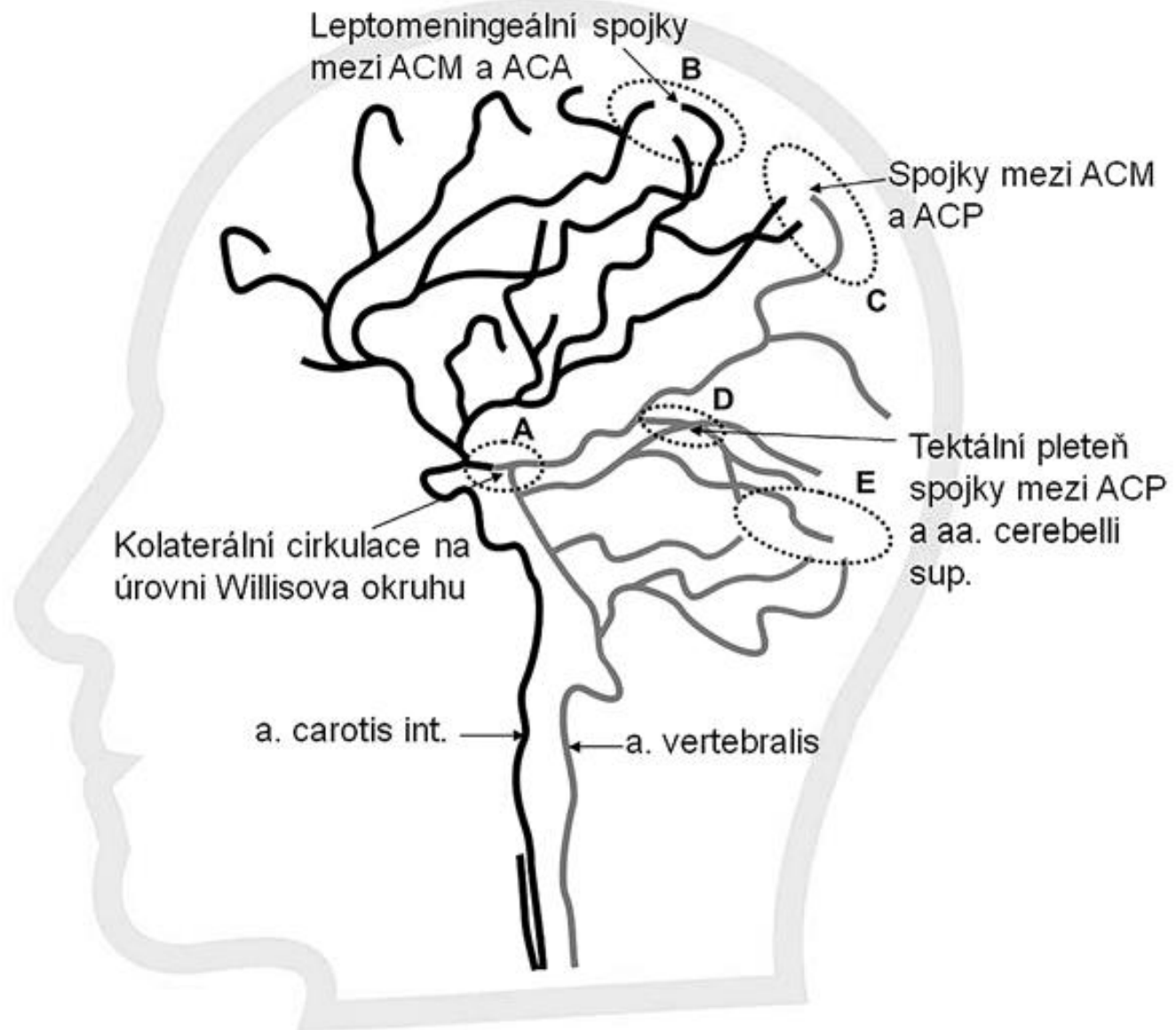
Cortical vascular territories





O. Volný, R. Mikulík (2013)
 1 Mezinárodní centrum klinického
 výzkumu (ICRC), Brno
 2 Anatomický ústav LF MU, Brno
 3 I. neurologická klinika LF MU a FN
 u sv. Anny v Brně

Extracranial system of collateral circulation



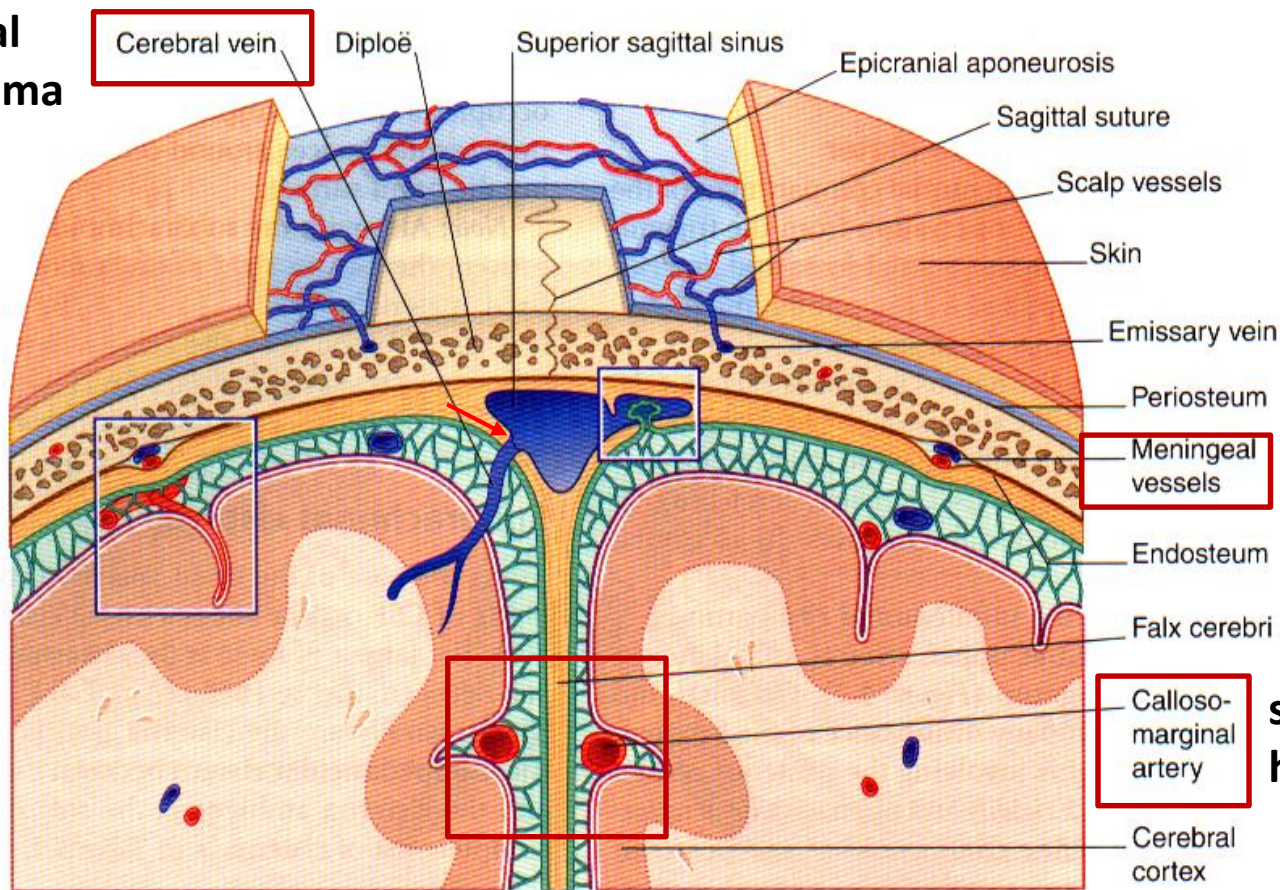
Intracranial system of collateral circulation

O. Volný, R. Mikulík (2013)
 1 Mezinárodní centrum klinického
 výzkumu (ICRC), Brno
 2 Anatomický ústav LF MU, Brno
 3 I. neurologická klinika LF MU a FN
 u sv. Anny v Brně

Bleeding

subdural
hematoma

A



epidural
hematoma

subarachnoid
hematoma

M.J.T. FitzGerald et al. 2007. *Clinical Neuroanatomy and Neuroscience*.

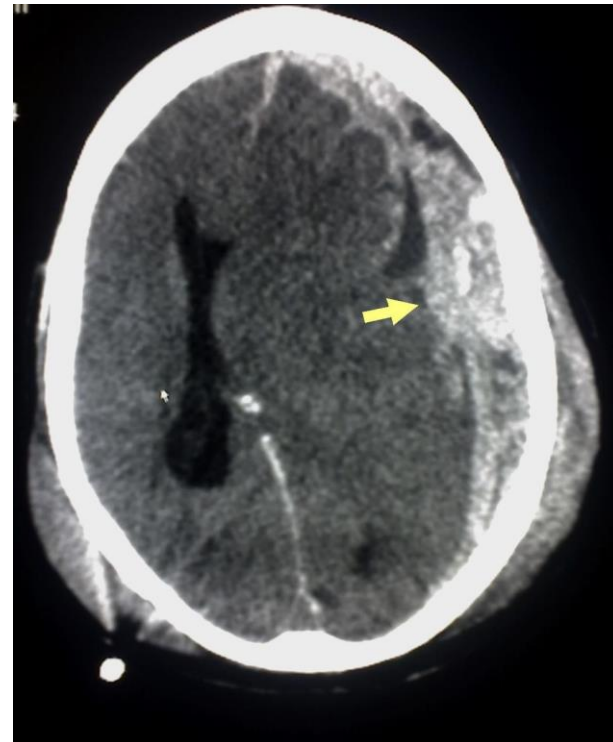
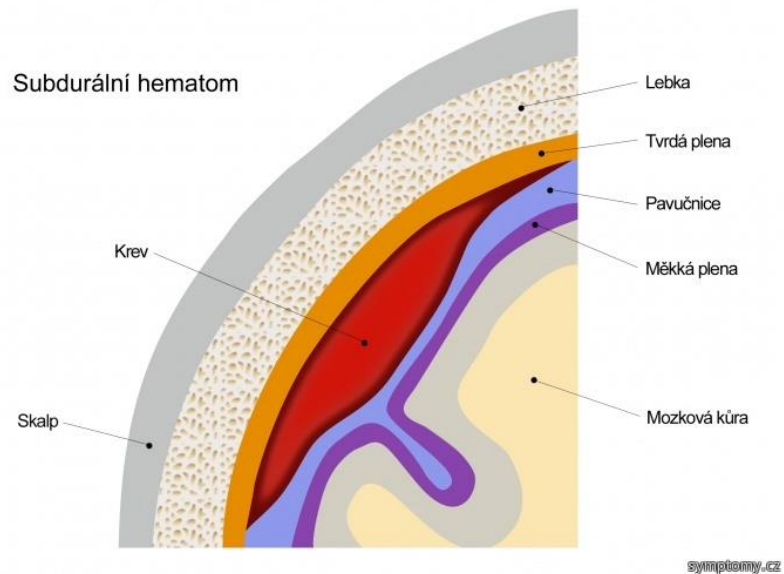
epidural hematoma – into potential epidural space after head trauma, bleeding from anterior or posterior r. of the *medial meningeal a.*

subdural hematoma – from superficial cerebral veins that run into the superior sagittal sinus

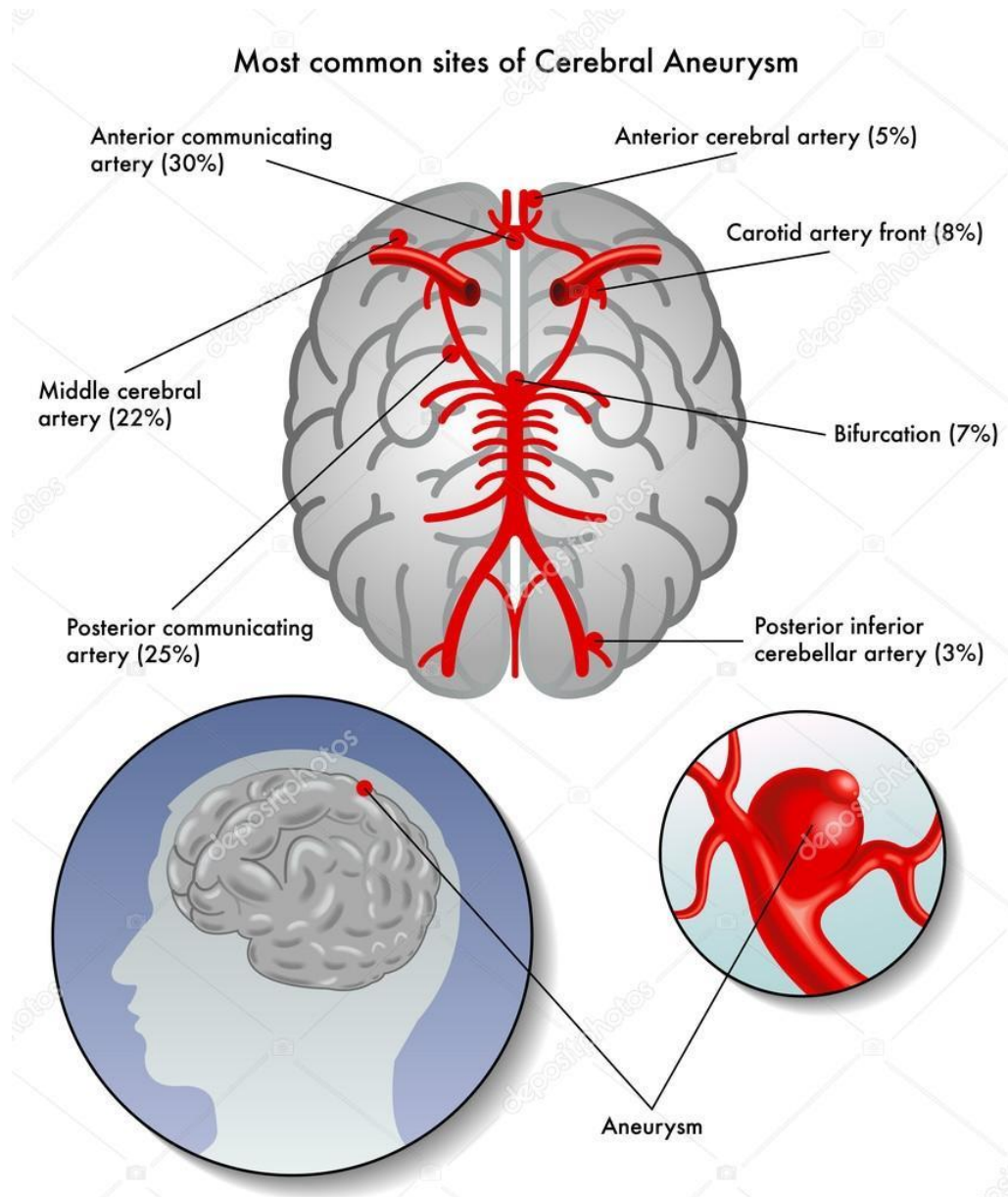
subarachnoid bleeding – bleeding from arteries of Willis circuit – frequently from aneurysm

Subdurální hematom

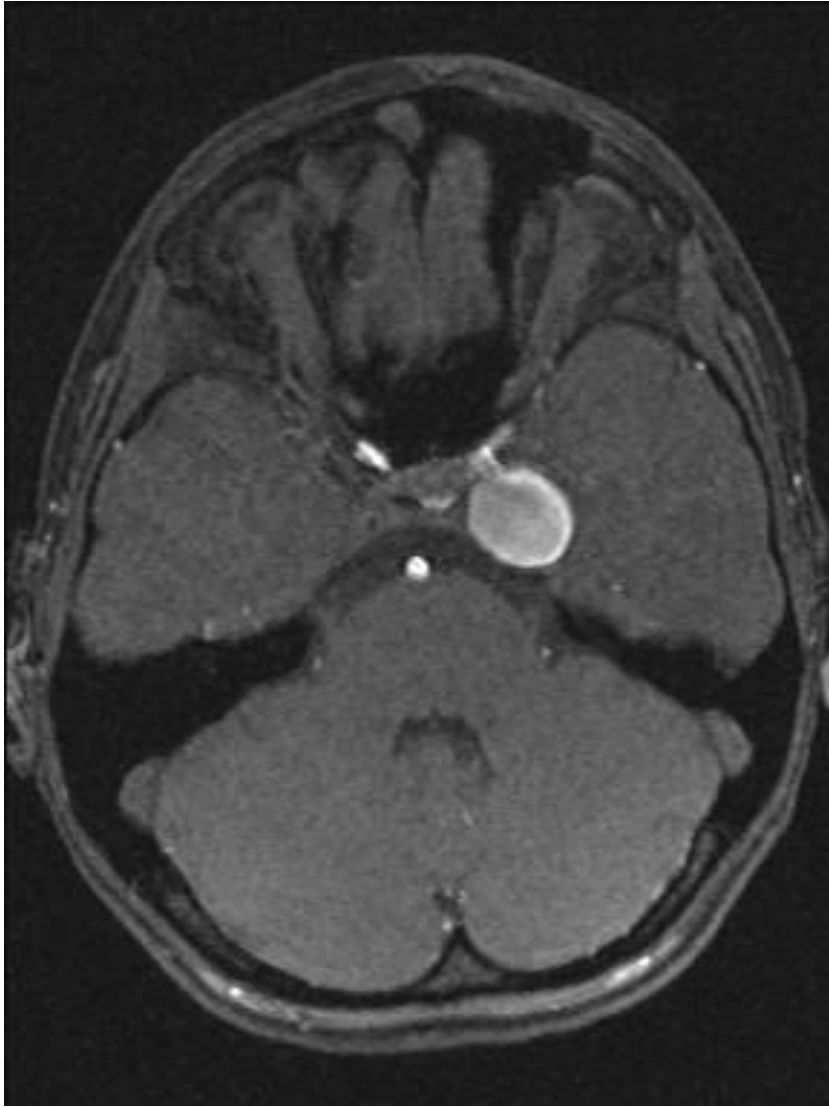po traumatického poranění mozku, mezi *dura mater* a *arachnoideu*



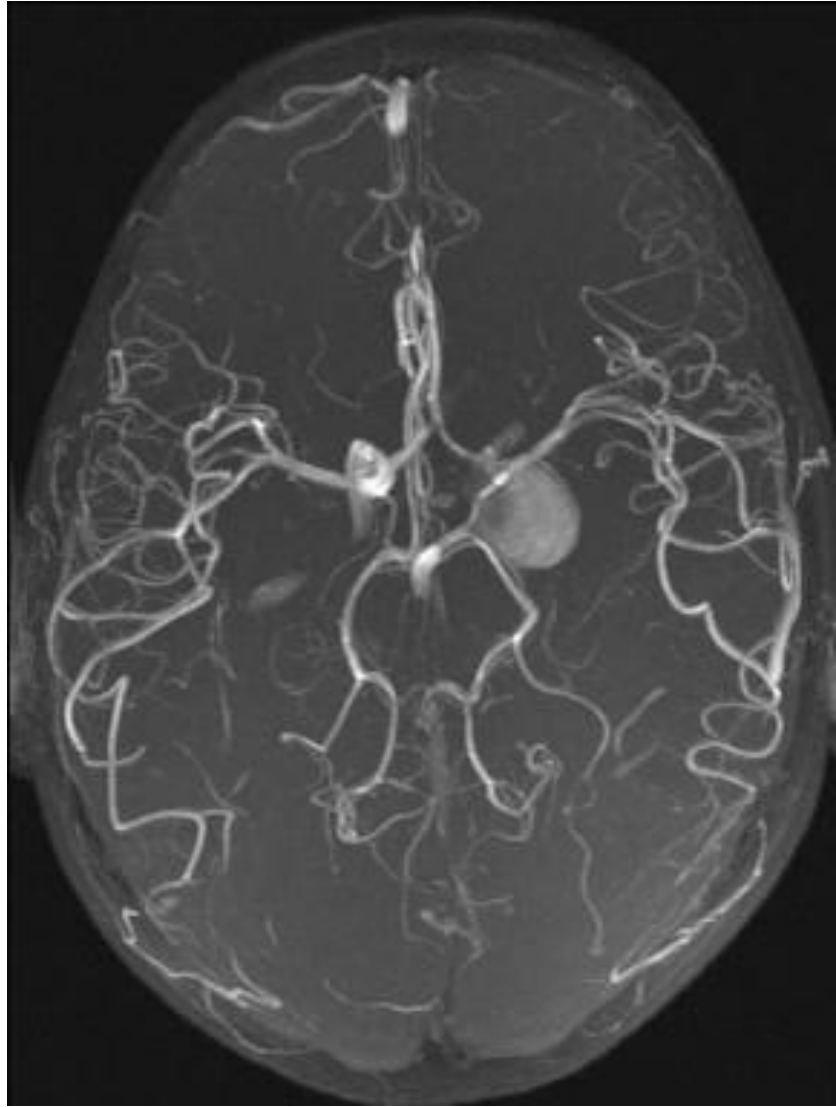
Subarachnoid bleeding



Aneurisma



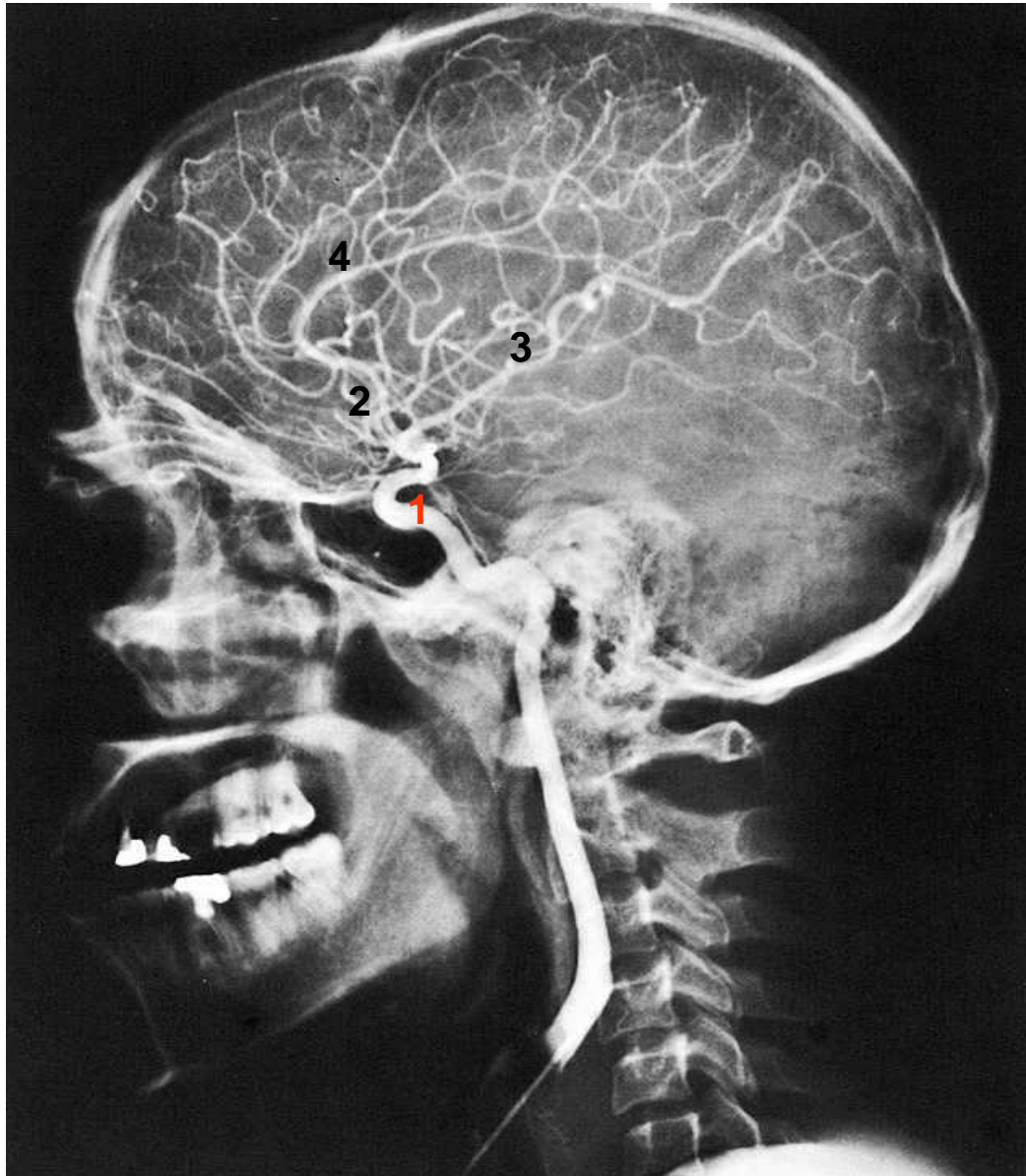
MR angiography (MRA)



CT angiography (CTA)

RTG of head

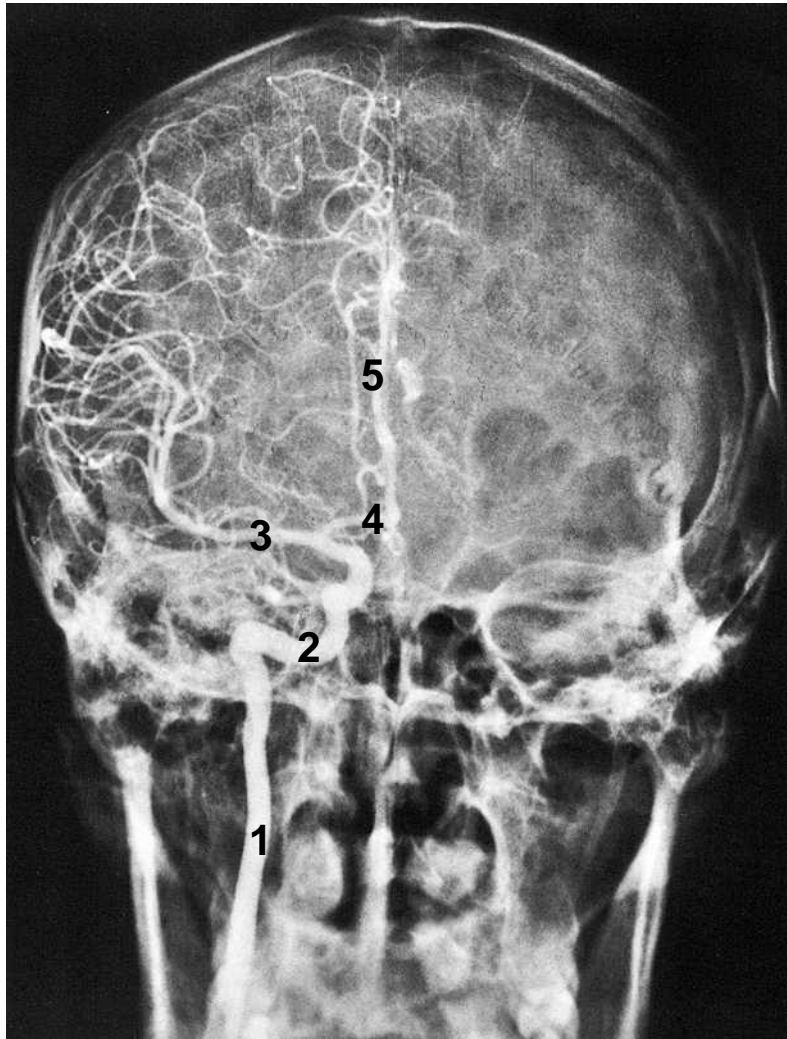
Angiography - a. carotis interna



1. siphon
2. a.cerebri anterior
3. a.cerebri media
4. a.pericallosa

RTG of head

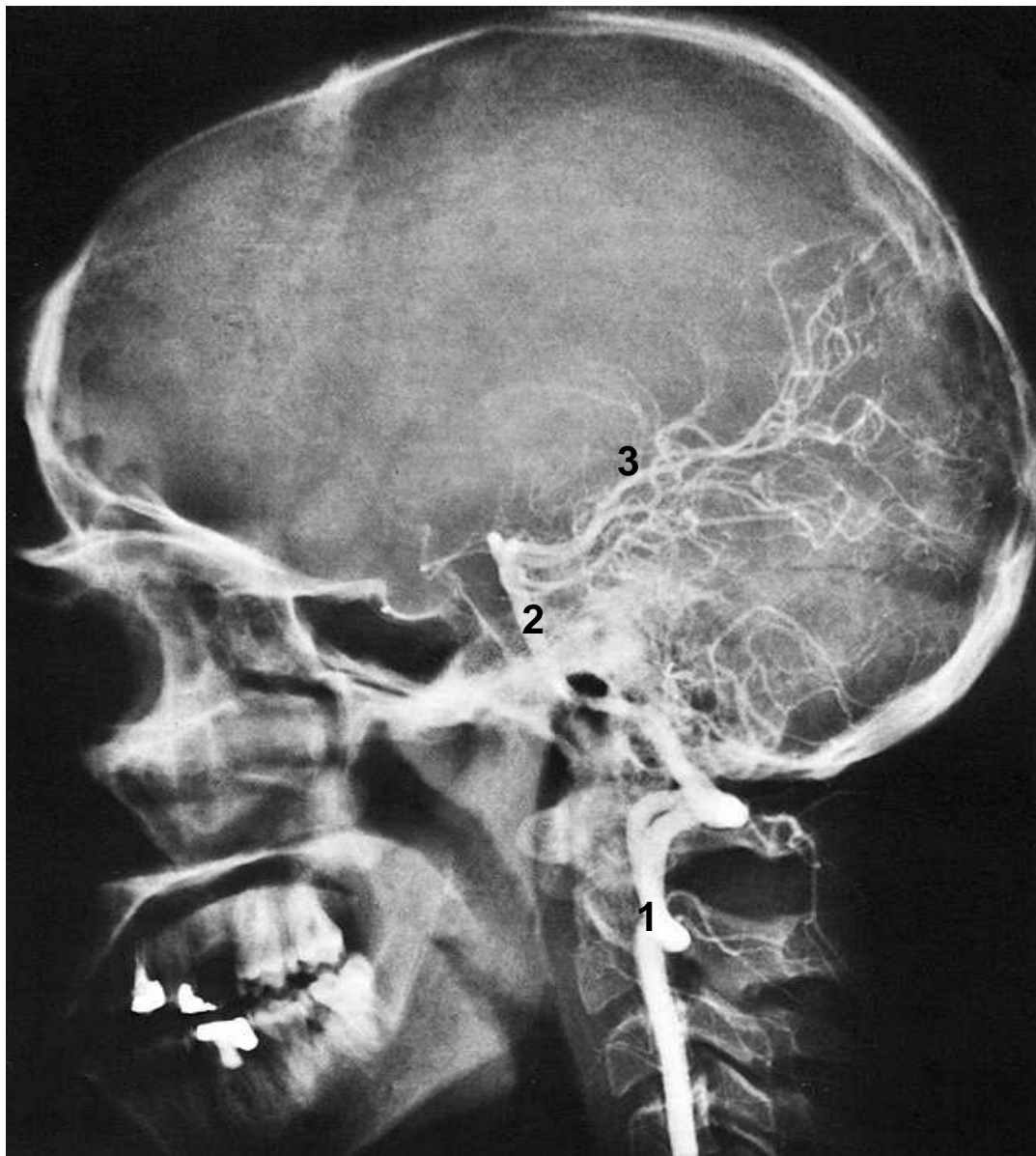
Angiography - a. carotis interna



1. a.carotis interna
2. siphon
3. a.cerebri media
4. a.cerebri anterior
5. a.percallosa

RTG of head

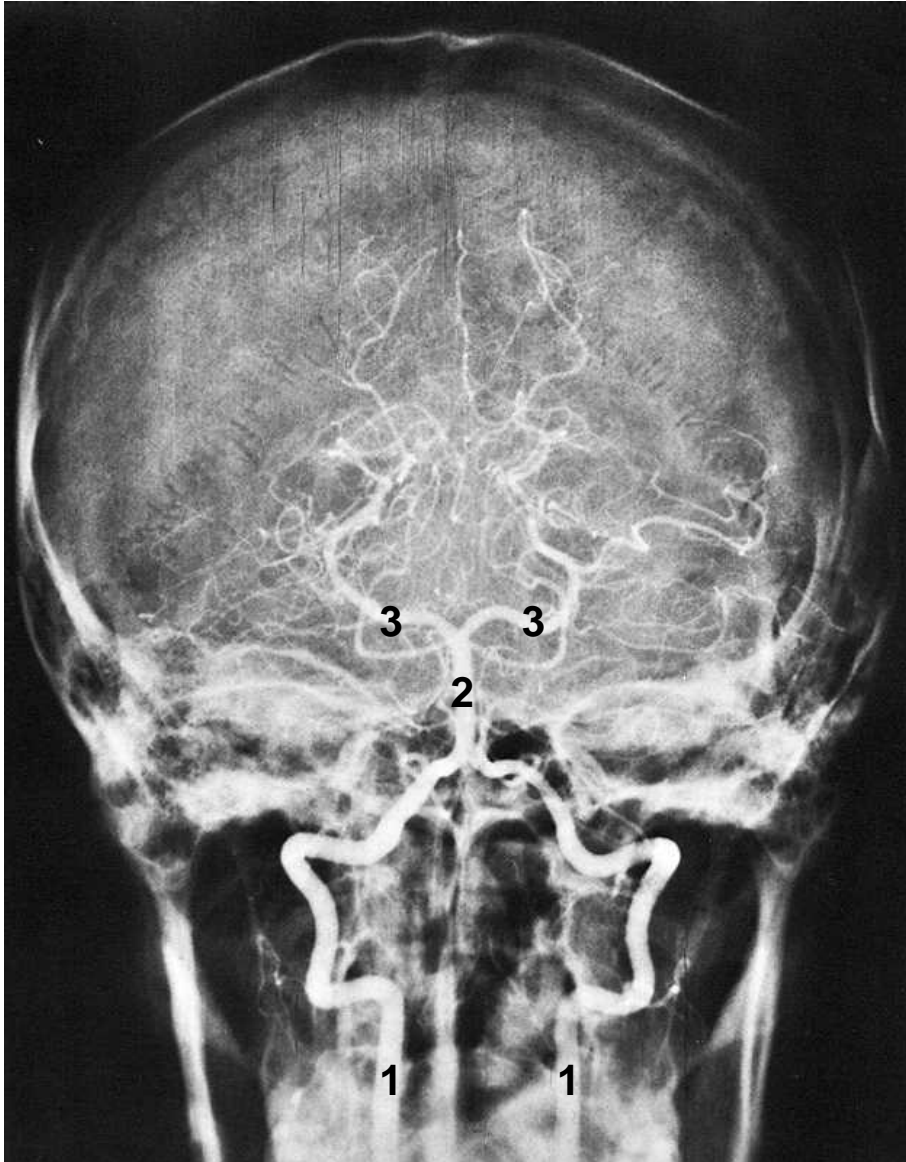
Angiography - a.vertebralis



1. A.vertebralis
2. A.basilaris
3. A.cerebri posterior

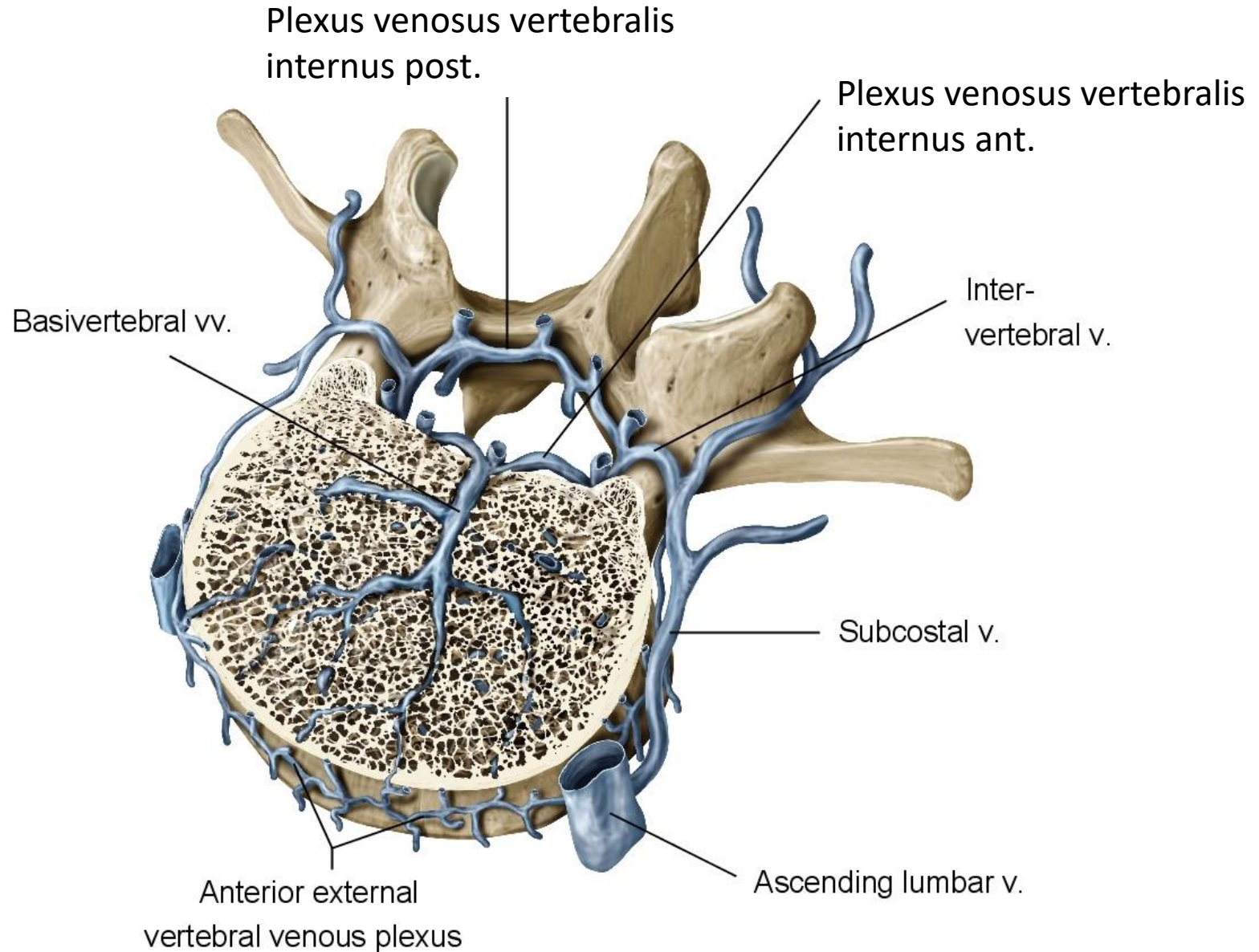
RTG of head

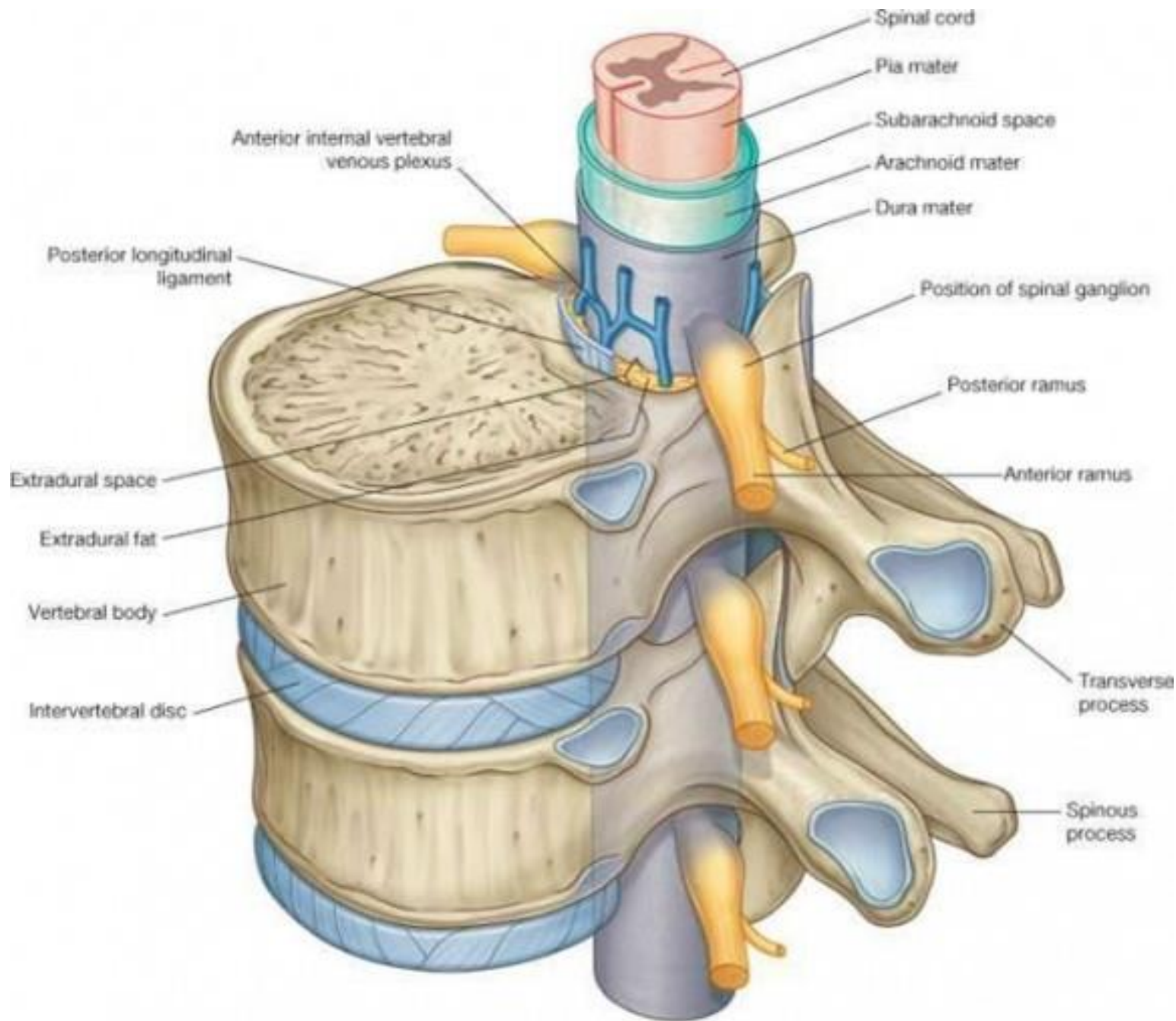
Angiography - a.vertebralis



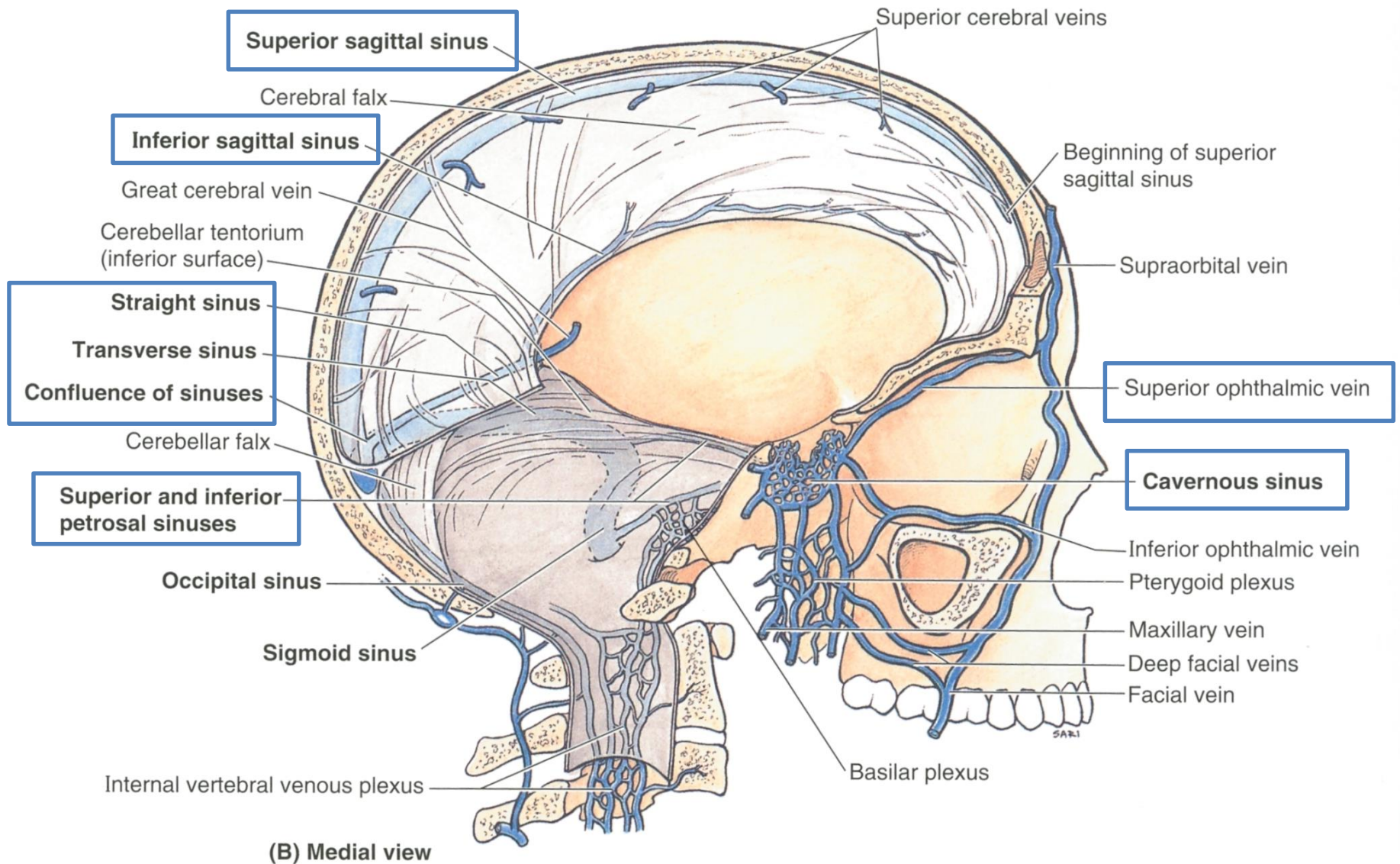
1. A.vertebralis dextra, sinistra
2. A.basilaris
3. Aa.cerebri posteriores

Venous drainage of blood

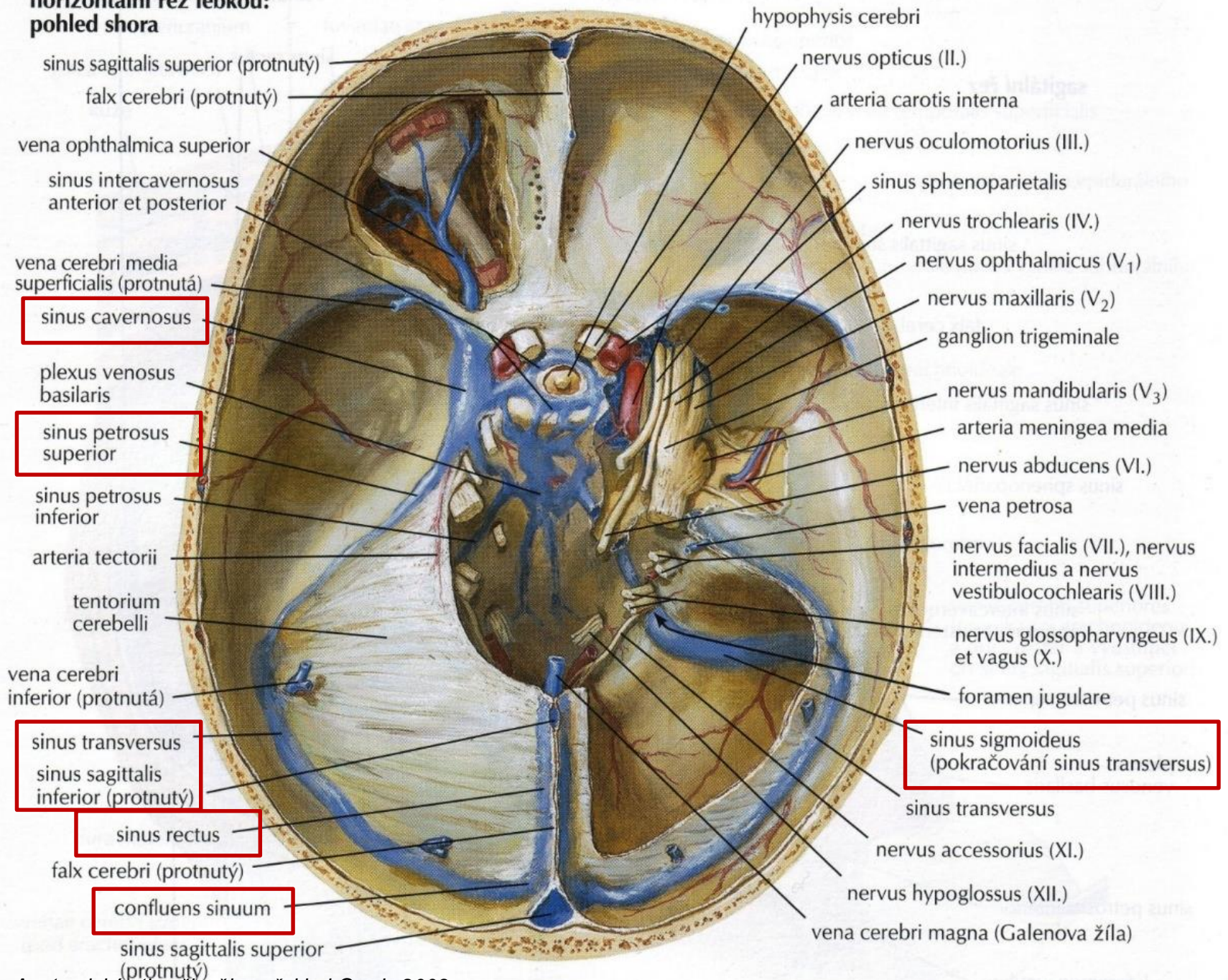


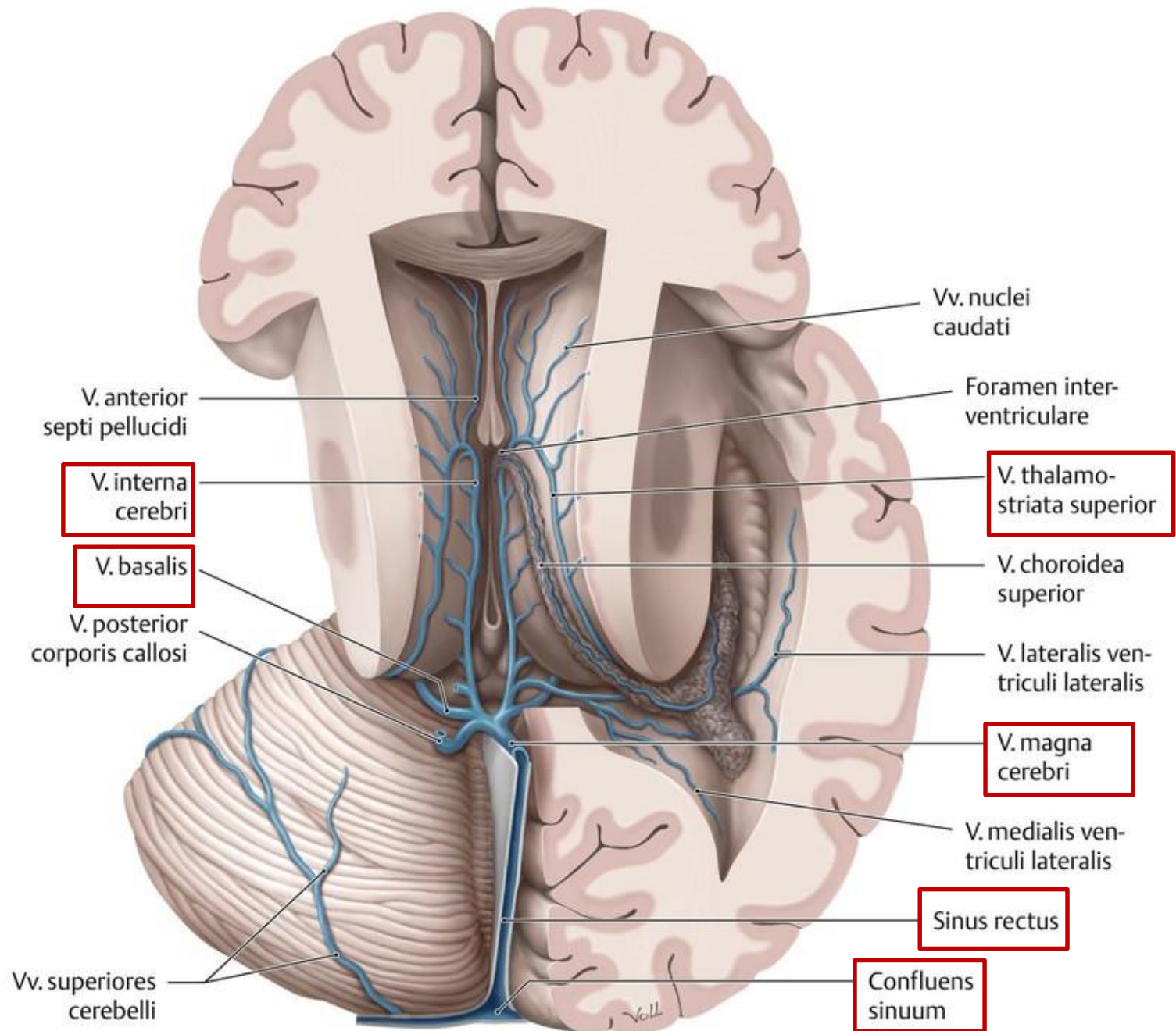


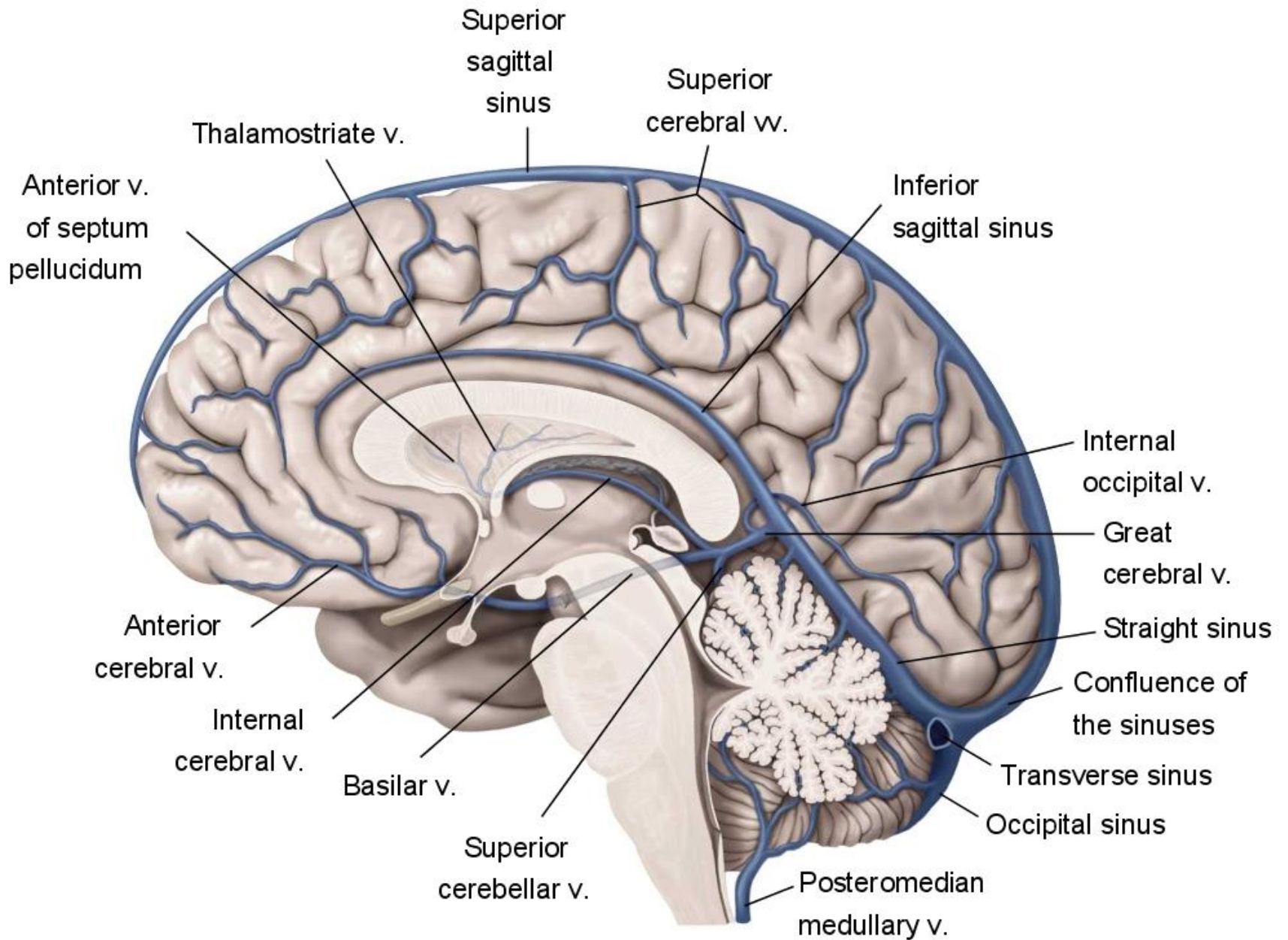
Veins and sinuses



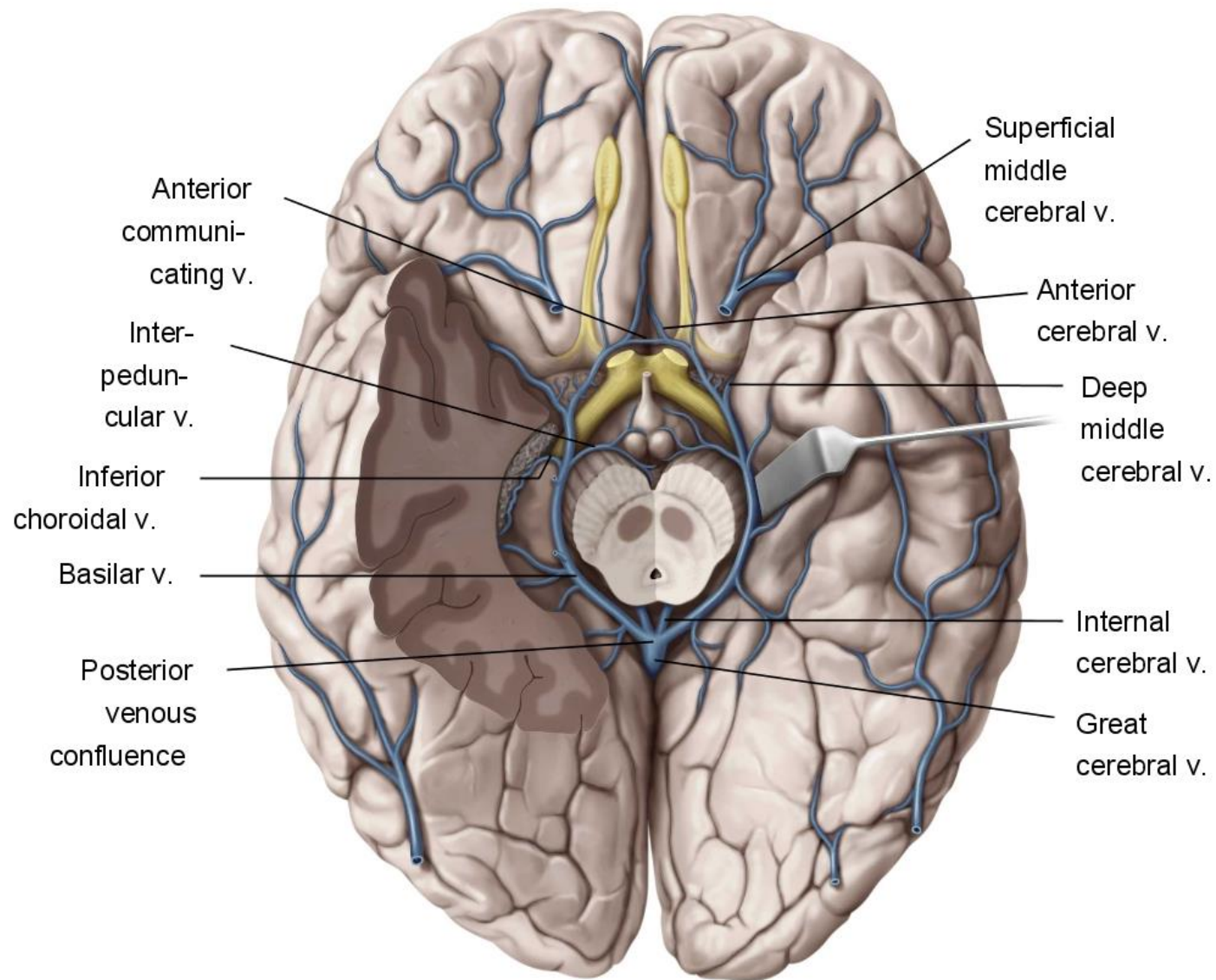
**horizontální řez lebkou:
pohled shora**







Copyright ©2008 by Thieme. All rights reserved.
 Illustrator: Markus Voll

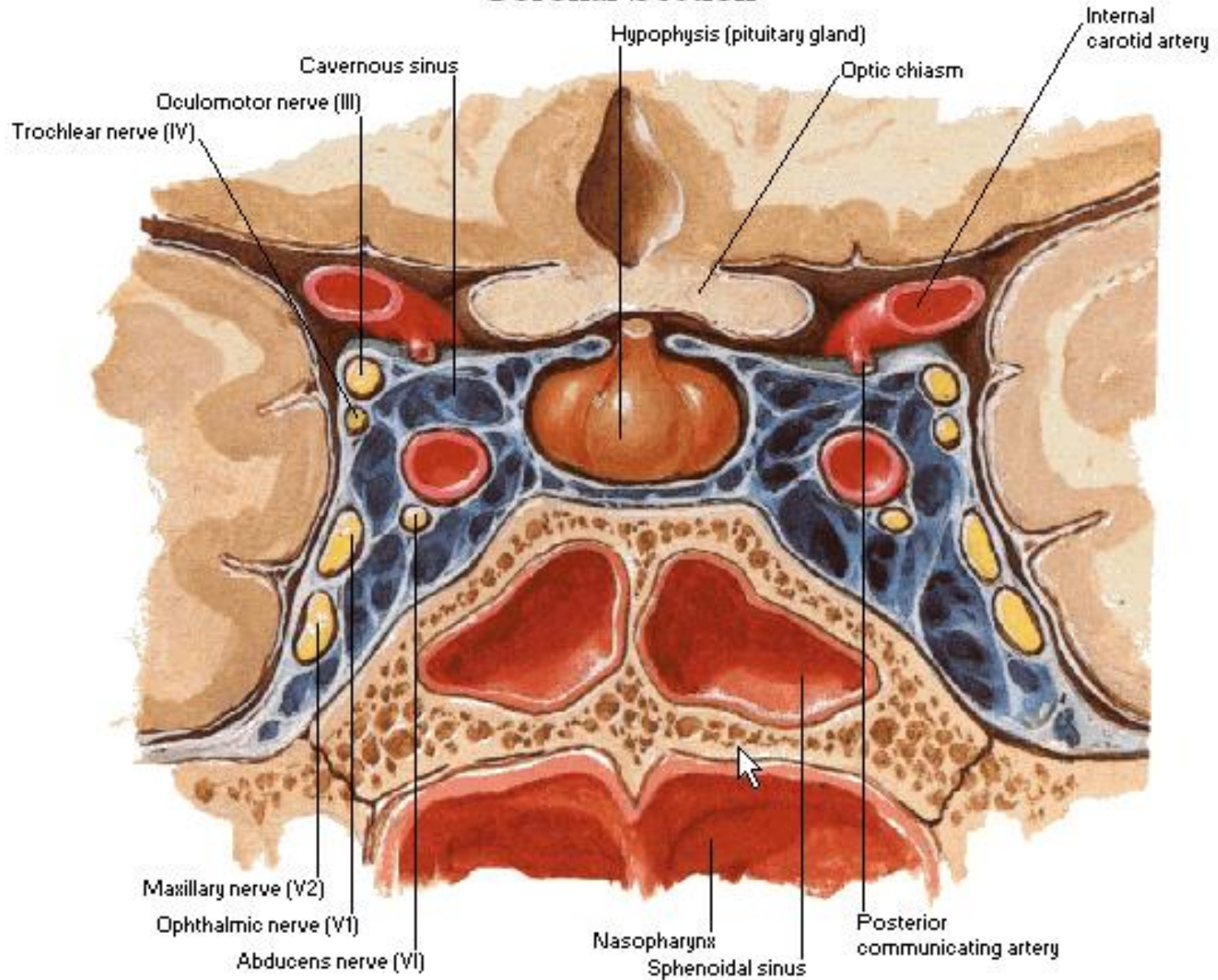


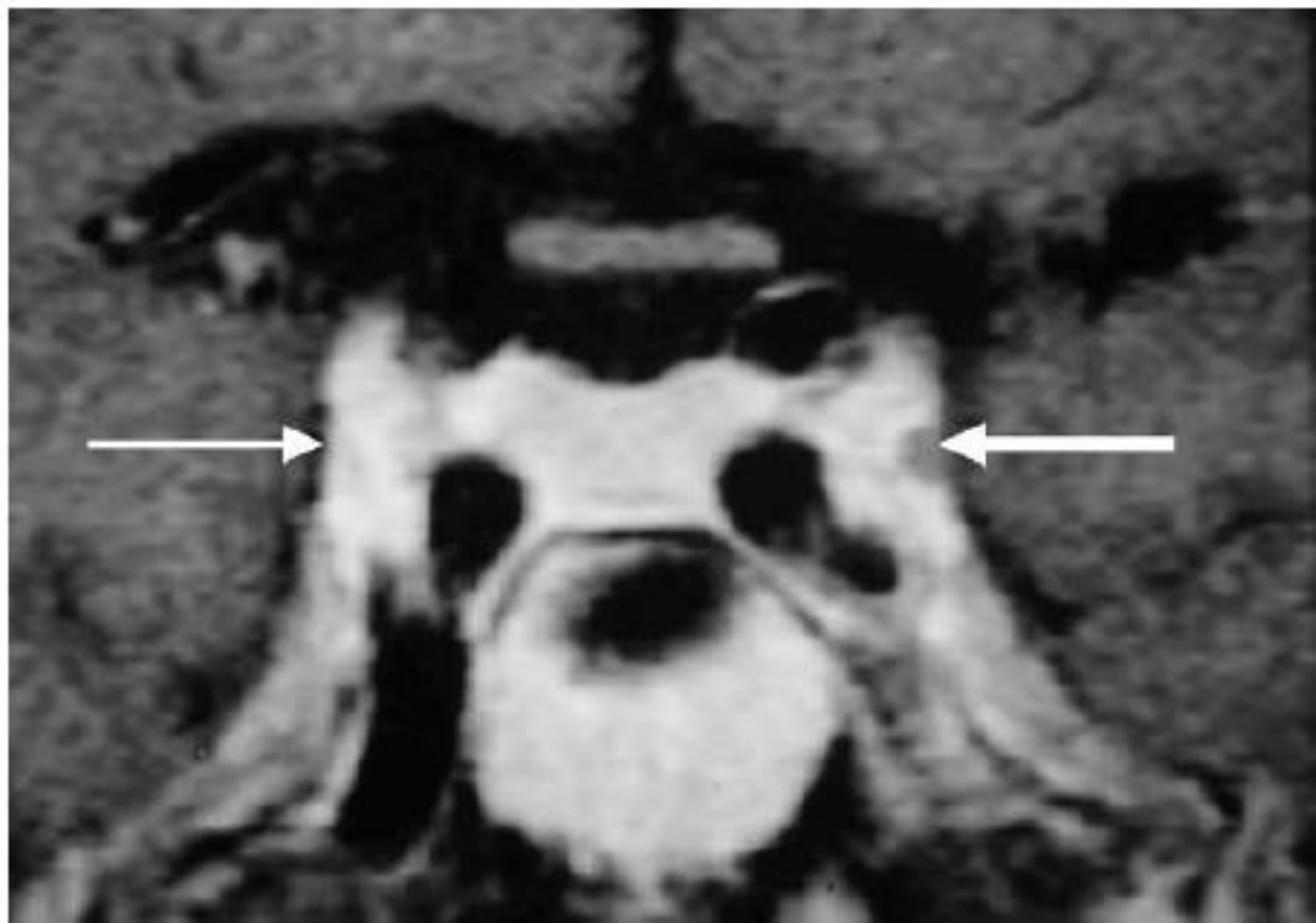
Copyright ©2008 by Thieme. All rights reserved.
 Illustrator: Markus Voll

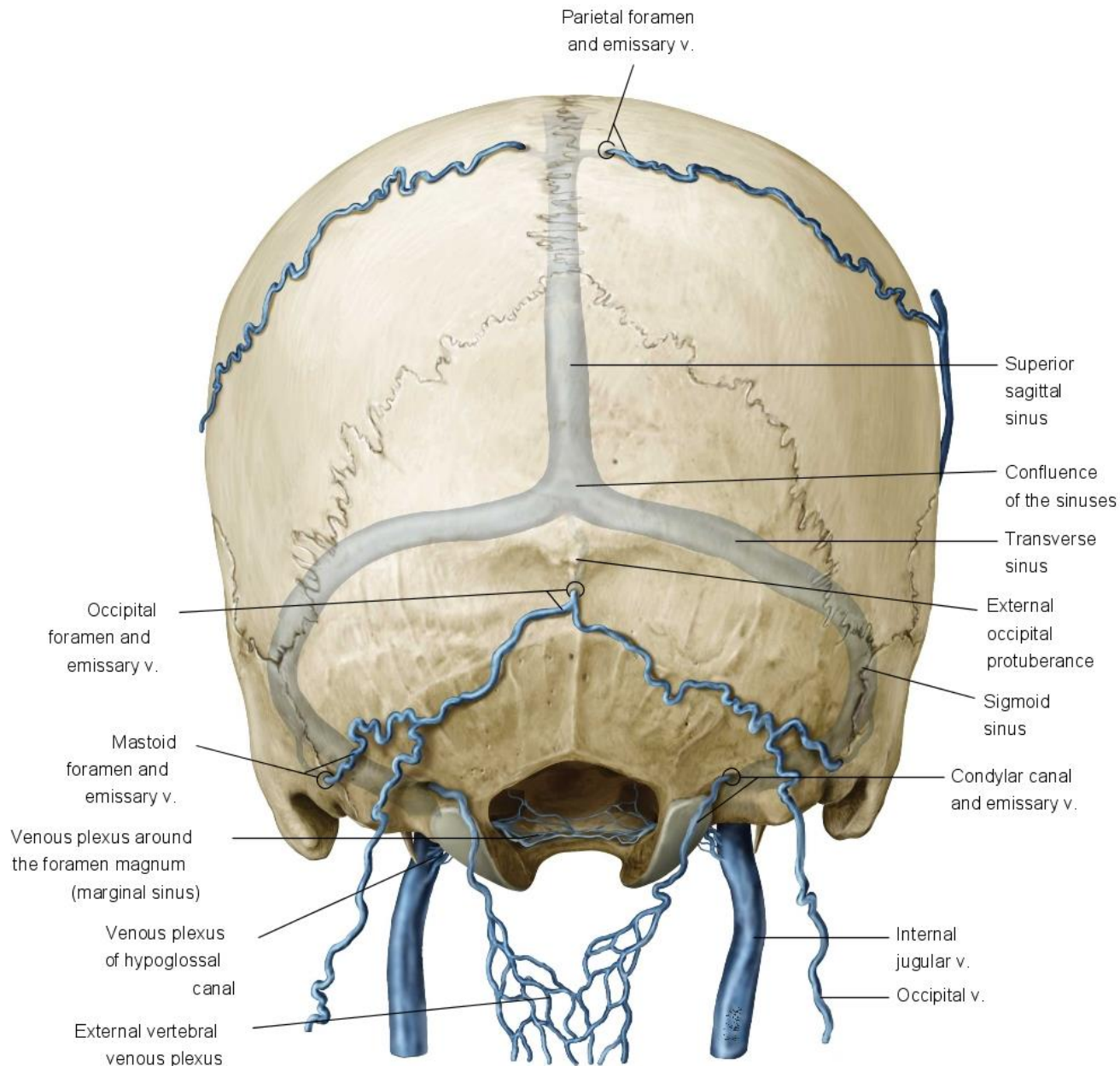
A. M. Gilroy, B. R. MacPherson, L. M. Ross Atlas of Anatomy. Thieme 2009.

Cavernous Sinus

Coronal Section







Copyright ©2008 by Thieme. All rights reserved.
 Illustrator: Karl Wesker