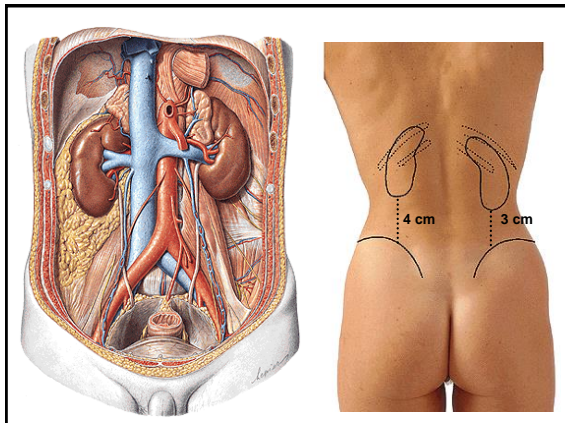
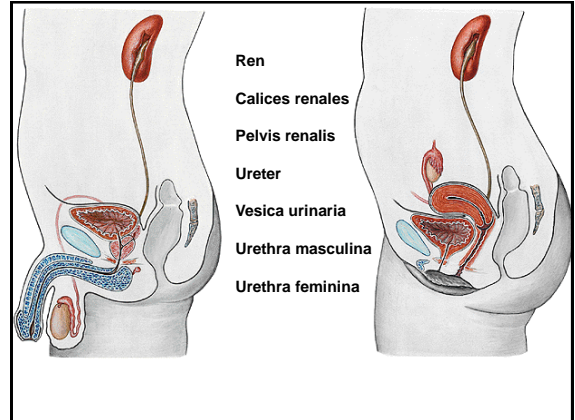
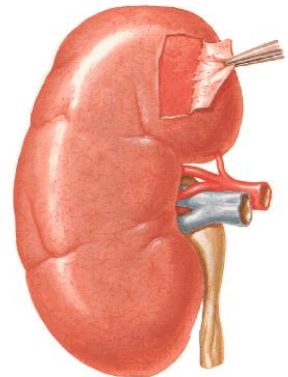


**URINARY SYSTEM
AND
MALE GENITAL SYSTEM**



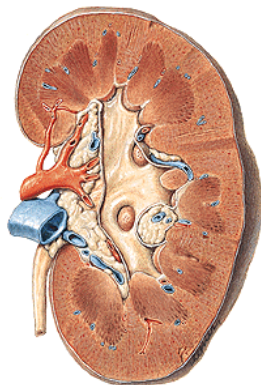
Kidney

- Extremitas superior
- Extremitas inferior
- Facies anterior
- Facies posterior
- Margo lateralis
- Margo medialis
- Capsula fibrosa
- Hilus (hilum) renalis



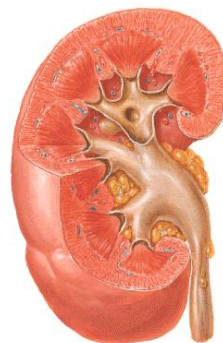
SINUS RENALIS:

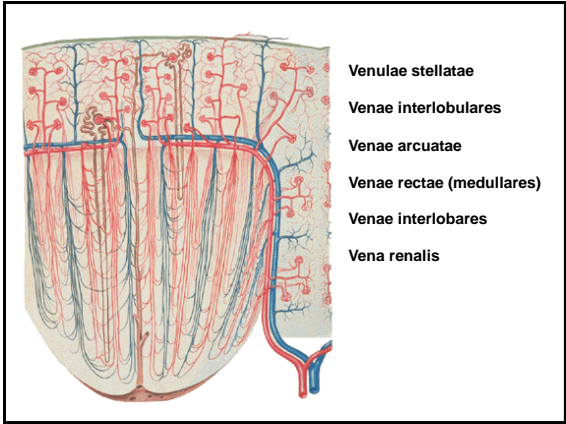
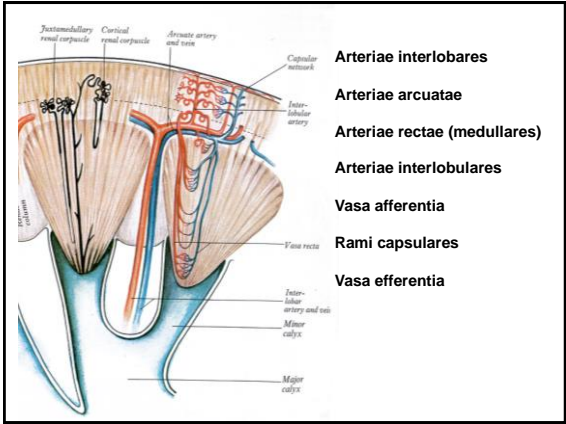
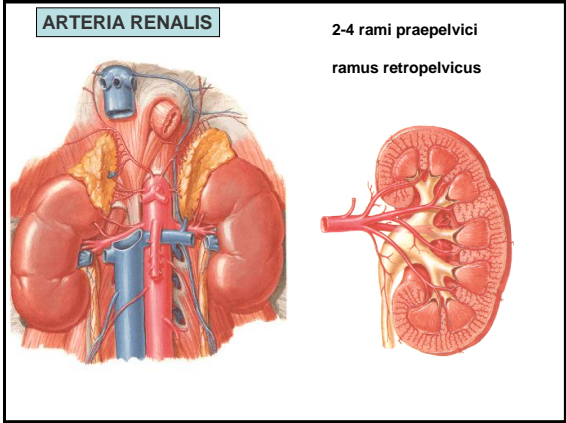
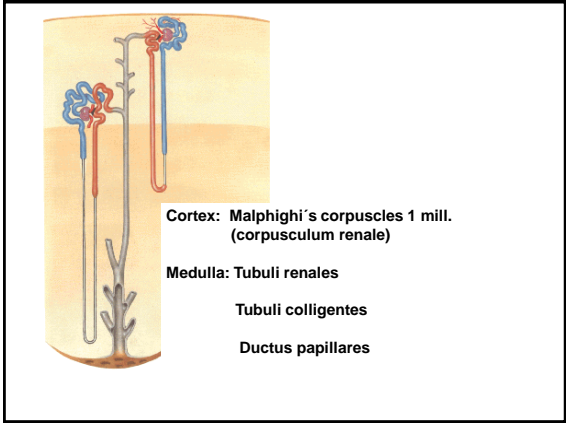
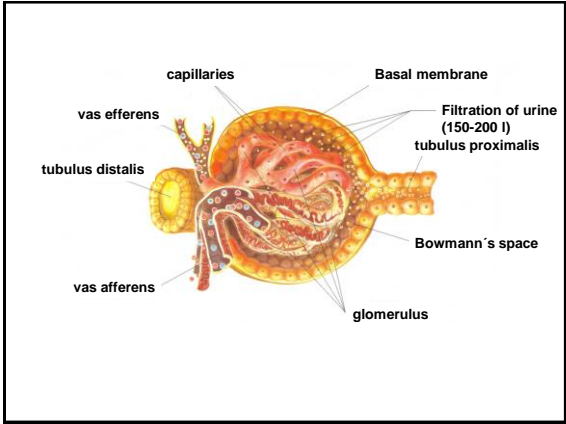
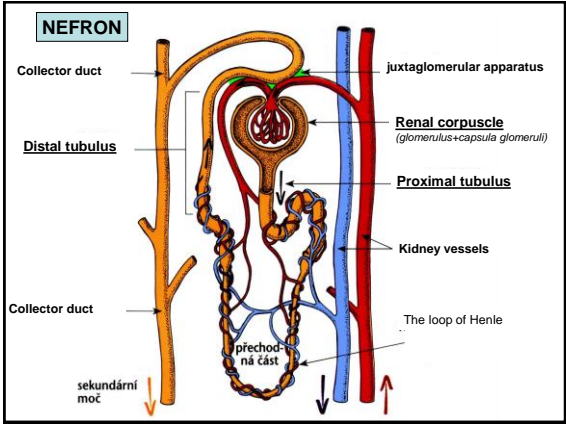
- Calices renales
- Pelvis renalis
- Arteria renalis
- Vena renalis



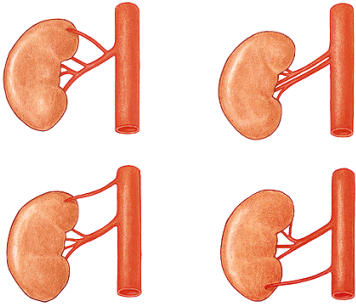
Morphology of the kidney

- Capsula fibrosa
- Cortex renalis
- Medulla renalis
- Columnae renales
- Pars radiata corticis
- Pyramides renales
- Papilla renalis
- Foramina papillaria (ductus papillares)
- Area cribrosa
- Lobulus renalis (renculus)



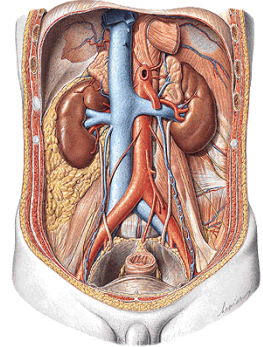
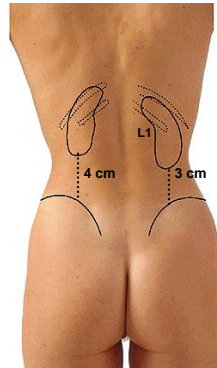


Arteriae renales accesoriae



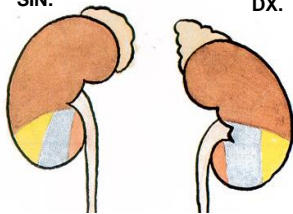
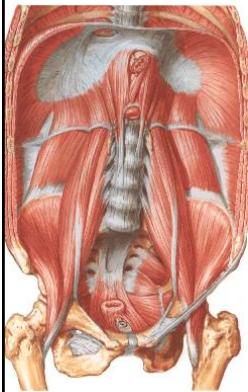
Position of the kidney

Primary retroperitoneal organ



SIN.

DX.



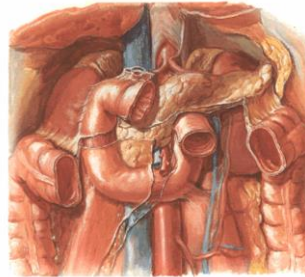
DIAPHRAGM

Musculus transversus abd.

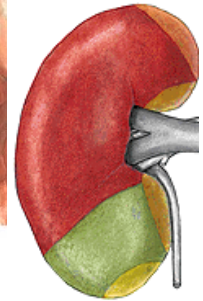
Musculus quadratus lumborum

Musculus psoas major

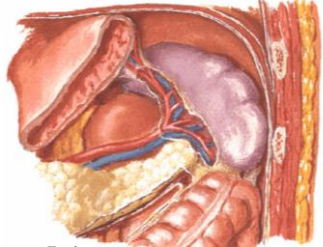
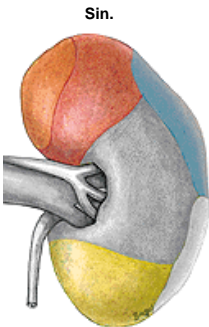
DX.



Facies: suprarenalis, hepatica,
duodenalis, colica, jejunalis



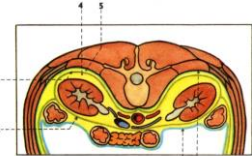
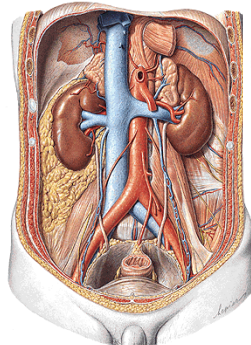
Sin.



Facies:

suprarenalis, gastrica, lienalis,
pancreatica, colica, jejunalis

Coverings of the kidney



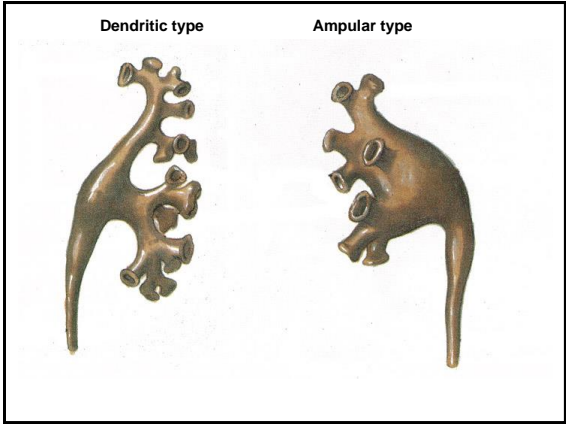
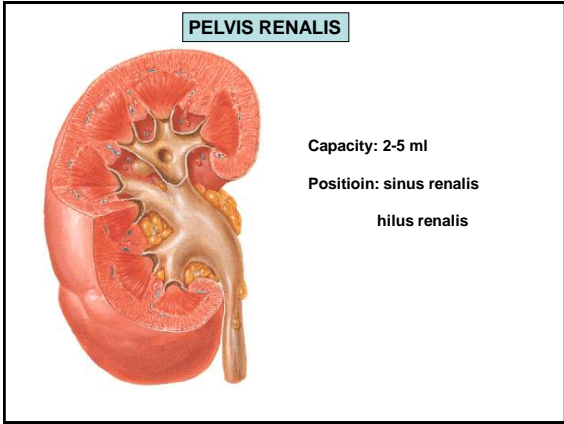
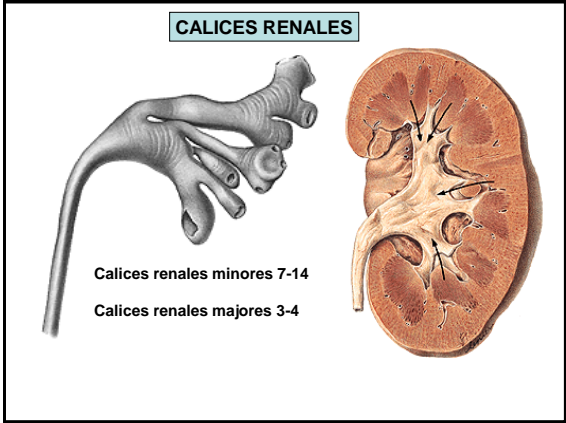
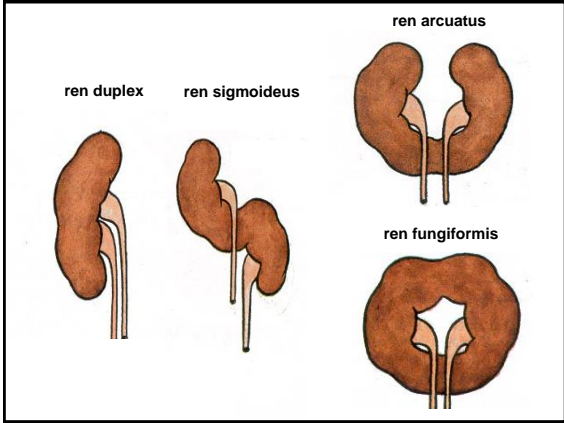
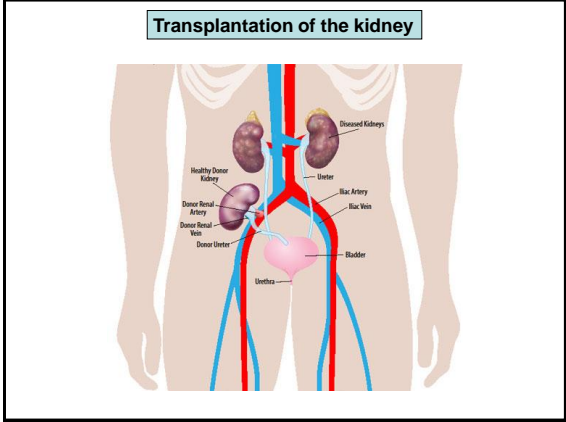
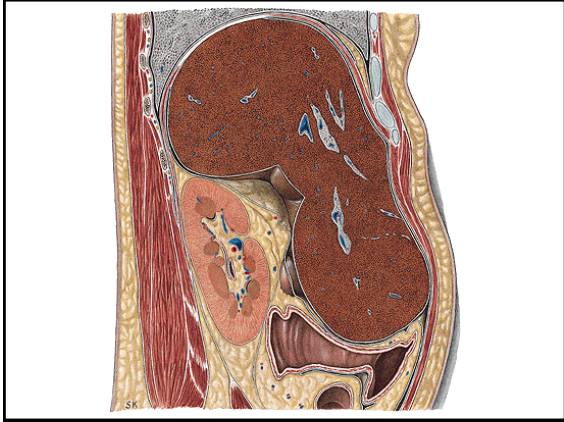
Capsula adiposa

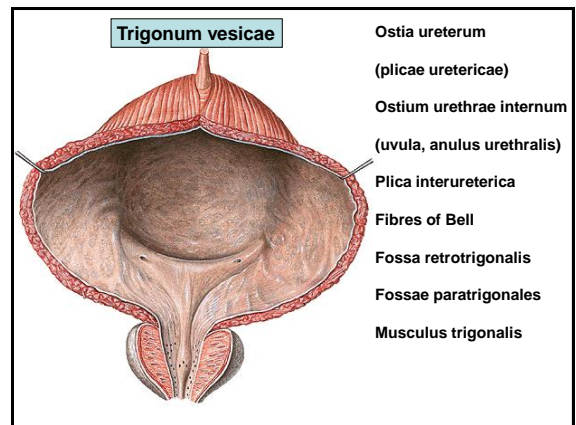
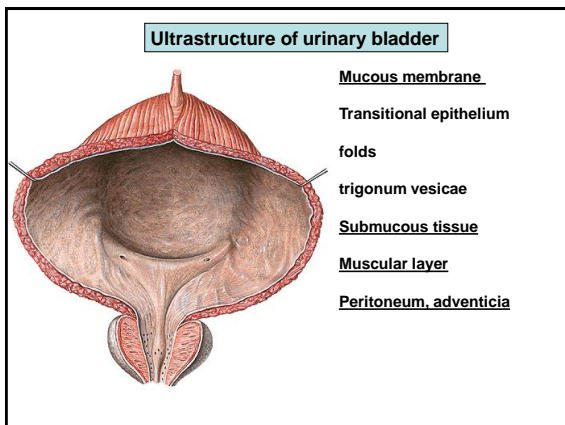
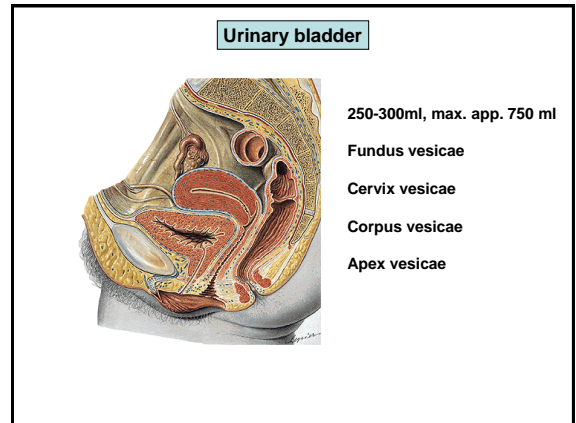
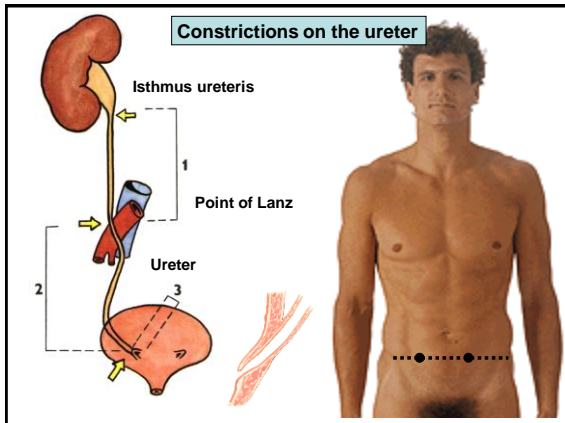
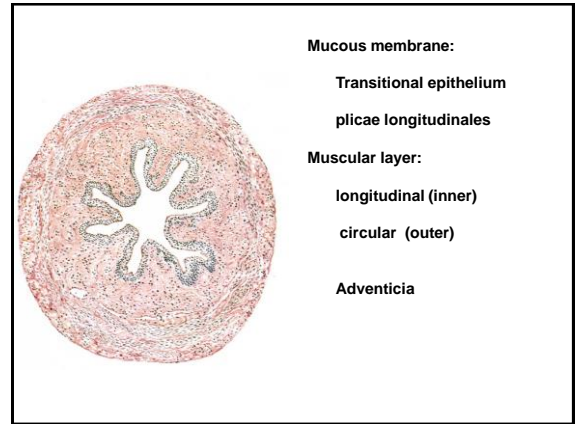
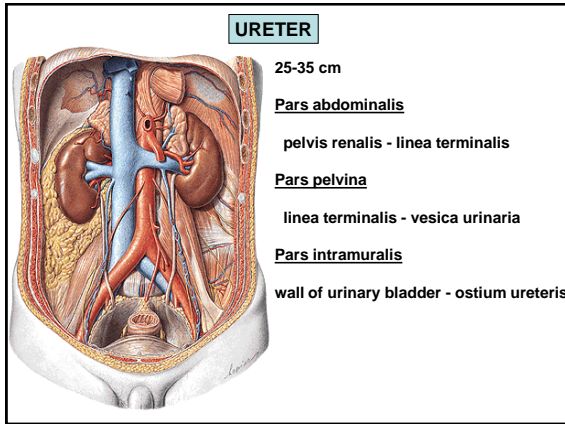
Fascia renalis

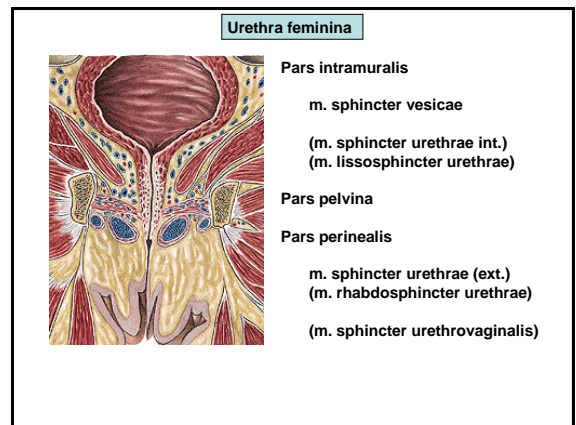
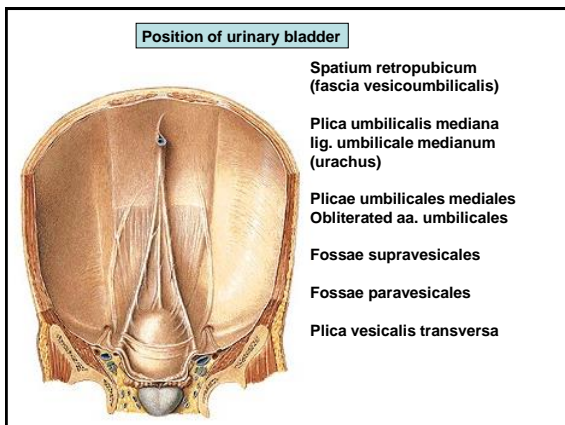
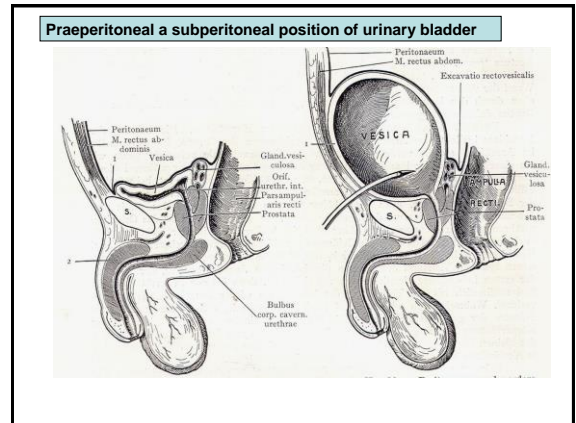
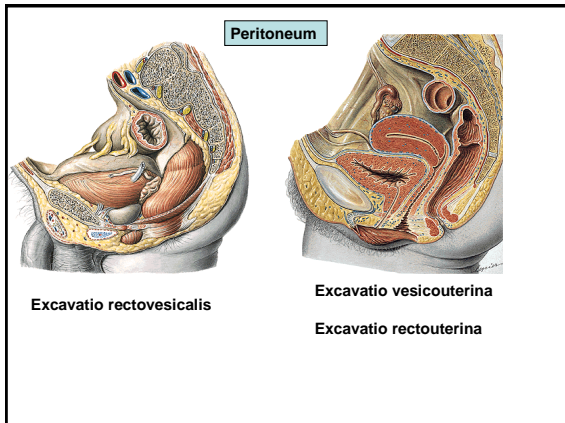
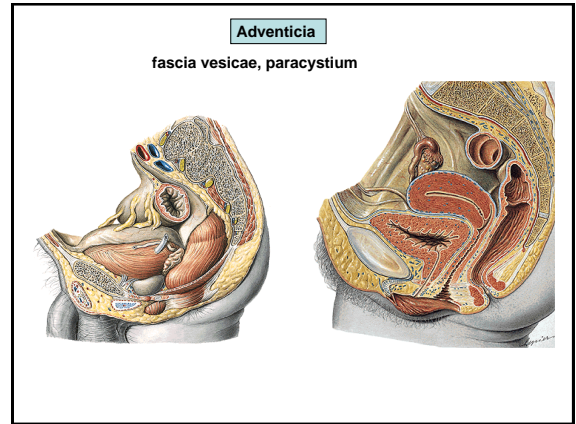
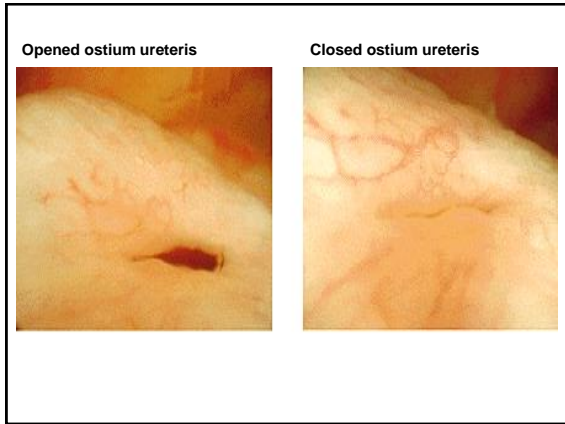
Lamina praerenalis

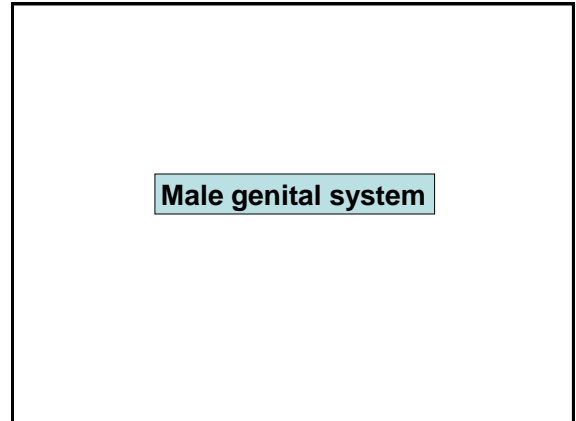
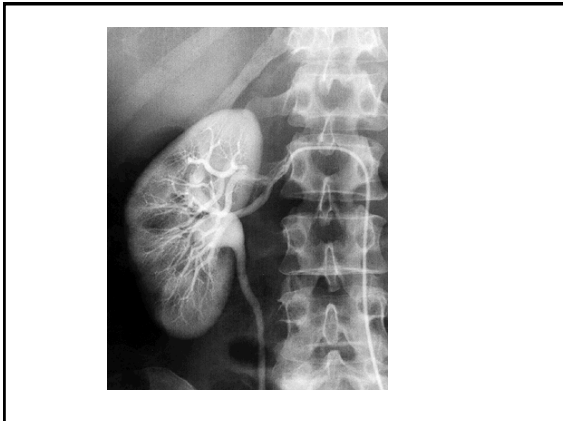
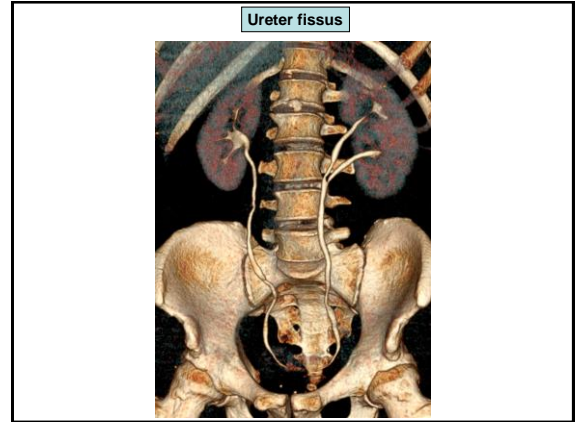
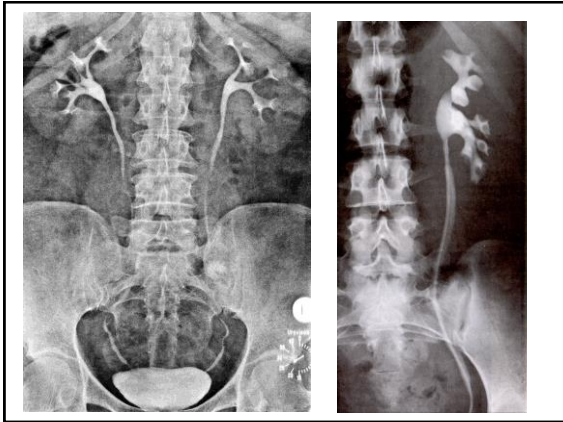
Lamina retrorenalis

Corpus adiposum pararenale









ORGANA GENITALIA MASCULINA INTERNA

TESTIS
 EPIDIDYMIS
 DUCTUS DEFERENS
 SPERMATIC CORD (FUNICULUS SPERMATICUS)
 SEMINAL VESICLES (VESICULAE SEMINALES)
 PROSTATE
 MALE URETHRA (URETHRA MASCULINA)

ORGANA GENITALIA MASCULINA EXTERNA

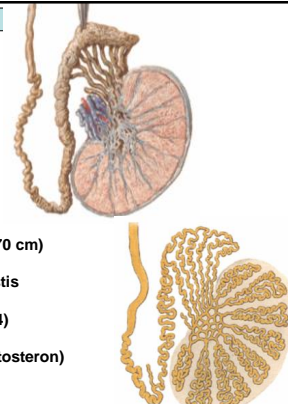
PENIS
 SCROTUM

TESTIS

4-4,5 cm 20-30 g

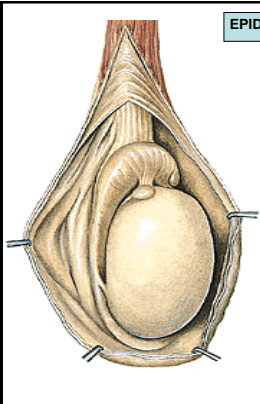
Extremitas superior
 Extremitas inferior
 Facies medialis
 Facies lateralis
 Margo anterior
 Margo posterior

MORPHOLOGY OF TESTIS



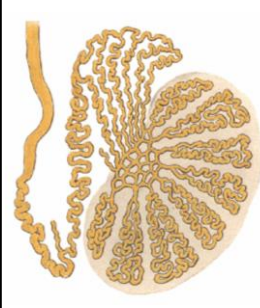
tunica albuginea
 hilum testis
 mediastinum testis
 septula testis
 lobuli testis (200-300)
 tubuli seminiferi contorti (50-70 cm)
 tubuli seminiferi recti, rete testis
 ductuli efferentes testis (10-14)
 interstitial Leydig's cells (testosteron)

EPIDIDYMIS



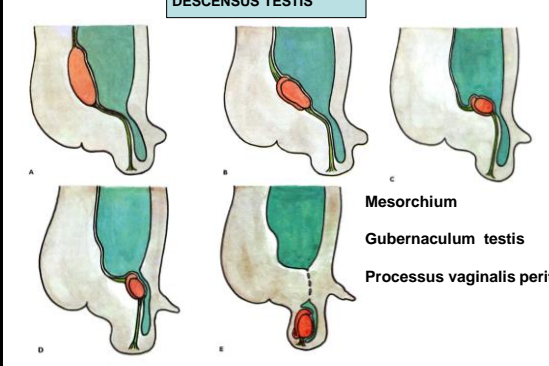
Caput epididymidis
 Corpus epididymidis
 Cauda epididymidis
 Lig. scrotale (gubernaculum testis)

MORPHOLOGY OF EPIDIDYMIS



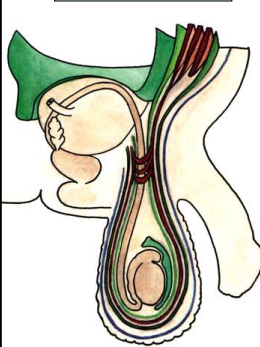
Ductuli efferentes testis (12-15)
 Lobuli epididymidis
 Ductus epididymidis
 Ductus deferens

DESCENSUS TESTIS

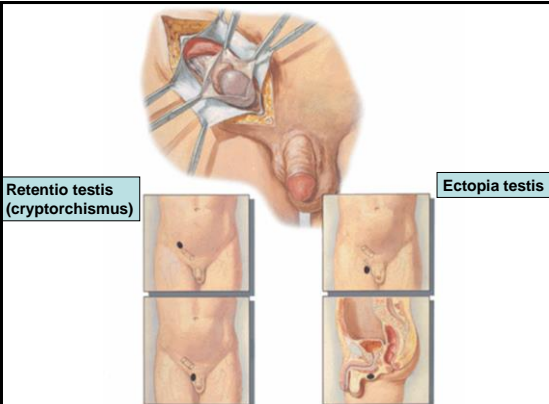


Mesorchium
 Gubernaculum testis
 Processus vaginalis perit.

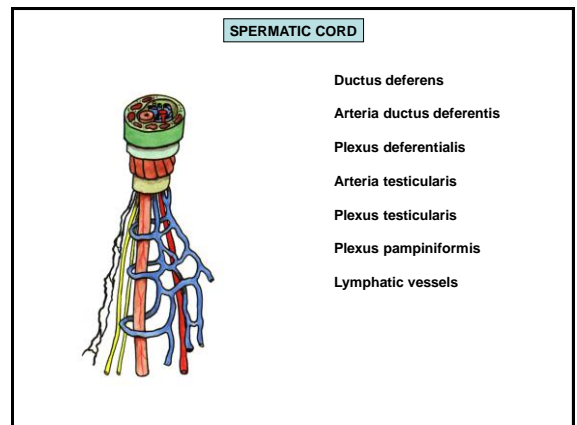
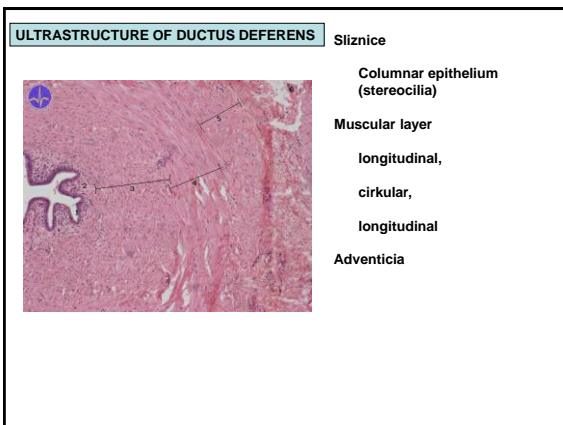
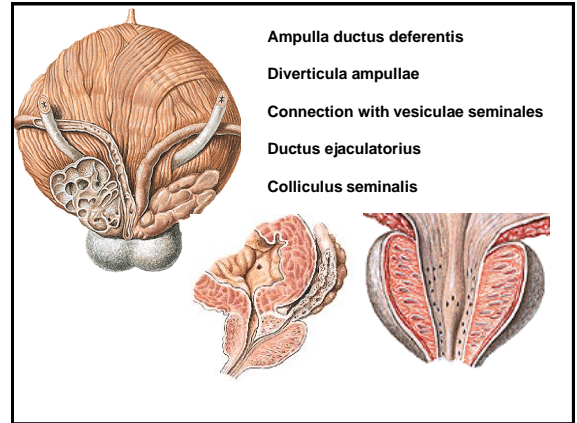
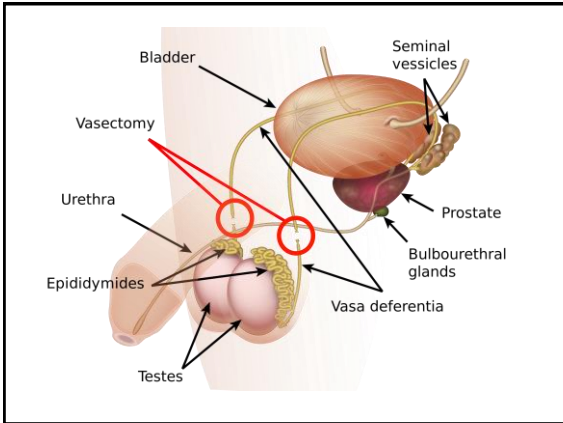
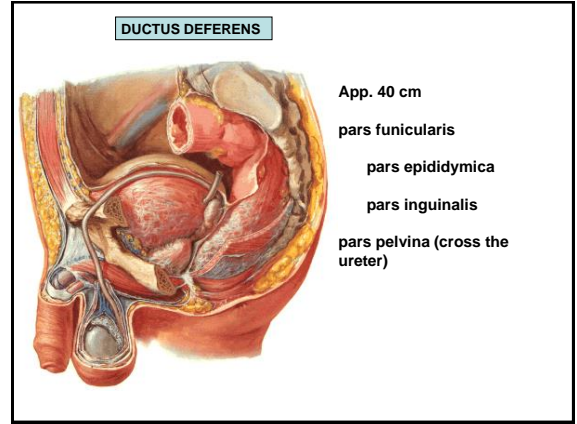
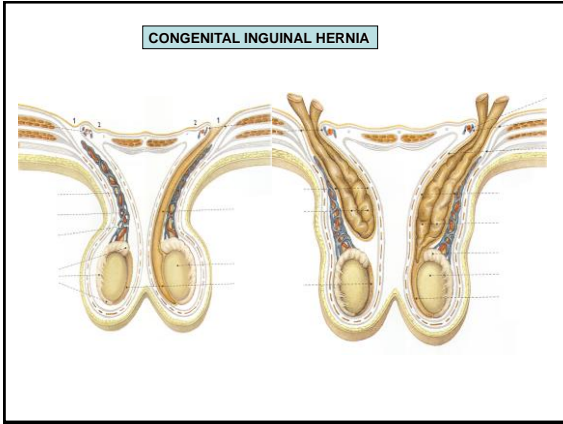
Coverings of the testis



skin
 Tunica dartos scroti
 Fascia spermatica ext.
 Musculus cremaster, fascie
 Fascia spermatica int.
 Tunica vaginalis testis
 lamina parietalis (*periorchium*)
 cavum serosum scroti
 lamina visceralis (*epiorchium*)
 Tunica albuginea



Retentio testis (cryptorchismus)
 Ectopia testis



SEMINAL VESICLES

App. 4-5 cm

Laterally from ampulla ductus deferentis

subperitoneal

(excavatio rectovesicalis, septum rectovesicale)

alkalic secret (50-80% ejaculate)

ductus excretorius + ductus deferens = ductus ejaculatorius

PROSTATE

Basis prostatae (facies vesicalis)

Apex prostatae

Facies anterior (ligg. puboprostatica)

Facies posterior

Facies laterales (inferolaterales)

30 - 50 tuboalveolar glands
15-30% of ejaculate

Lobus anterior (isthmus prostatae)

Lobus medius

Lobus posterior

Lobus dexter

Lobus sinister

4 cm

Capsula periprostatica (visc. list fascia pelvis)

Plexus venosus prostaticus

Capsula propria

Fibromuscular stroma

30 - 50 tuboalveolar glands
15-30% ejaculate

Ductuli prostatici (pars prostatica urethrae)

Clinical division of the prostate

zona glandularium periurethralium

isthmus

vnitřní zóna submukózních žláz

vnější zóna žláz

urethra

colliculus seminalis

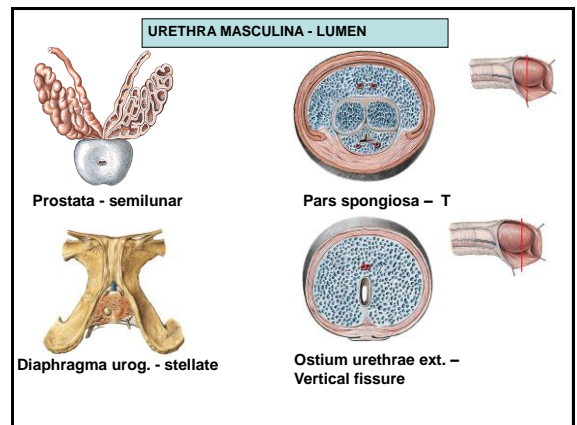
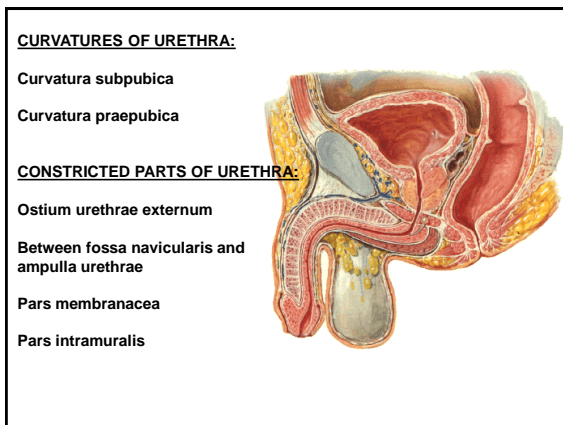
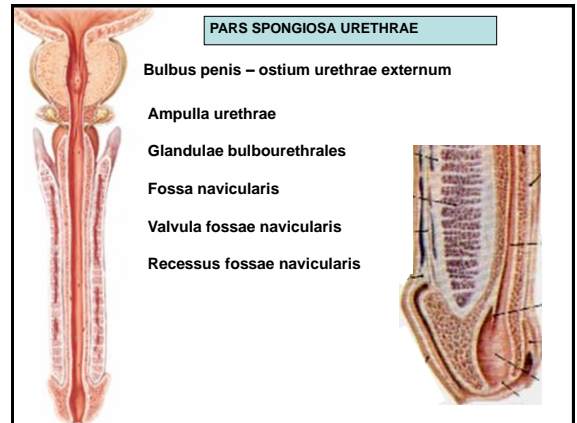
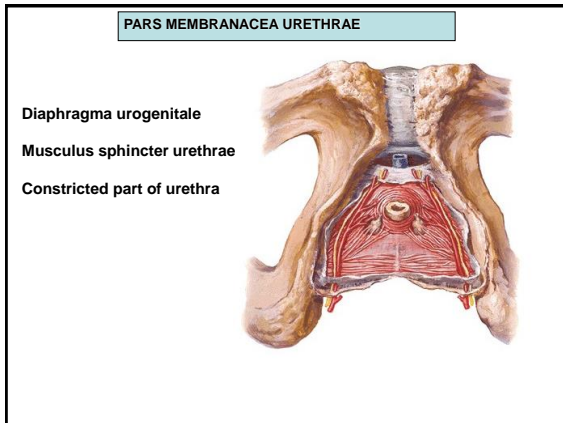
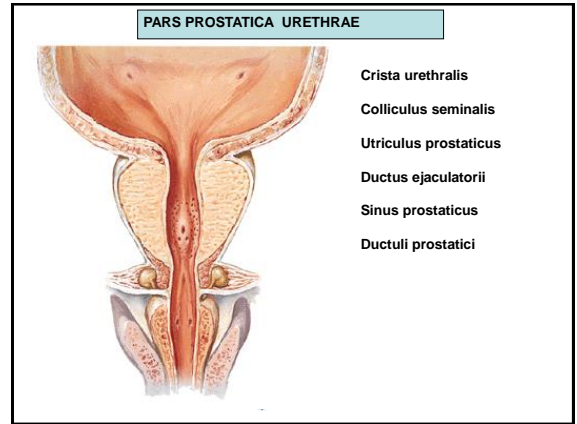
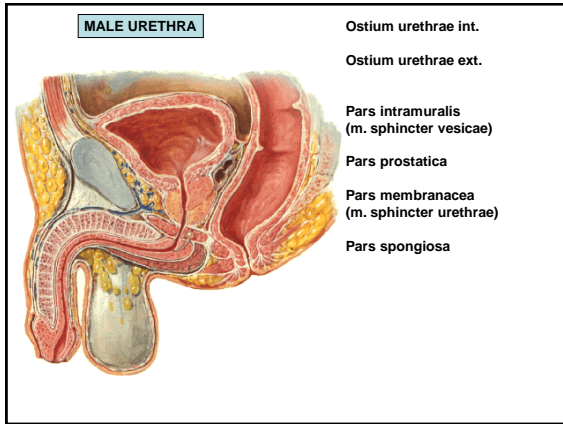
utrículus prostaticus

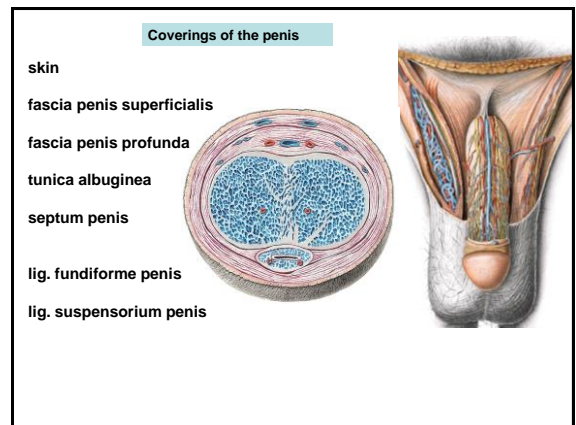
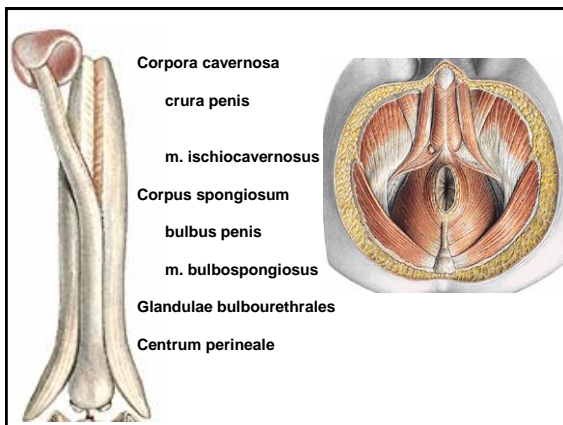
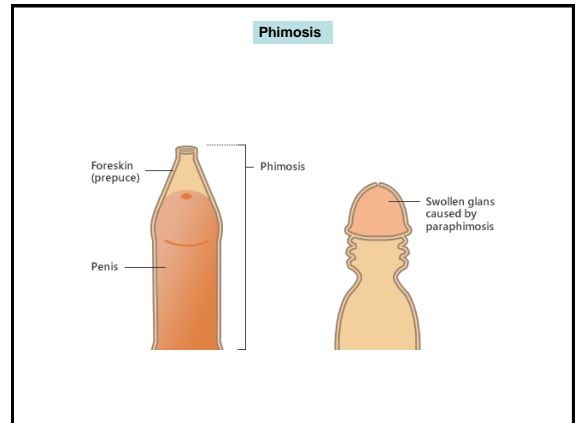
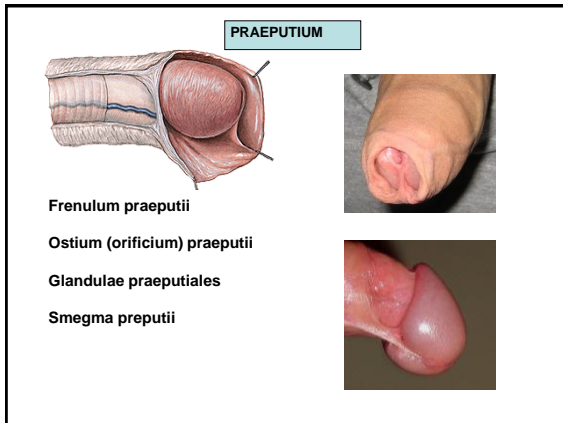
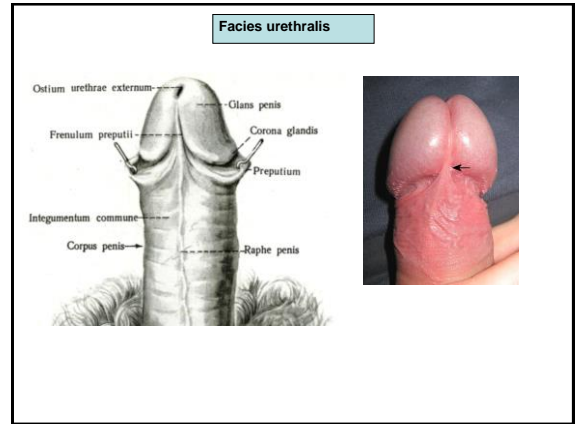
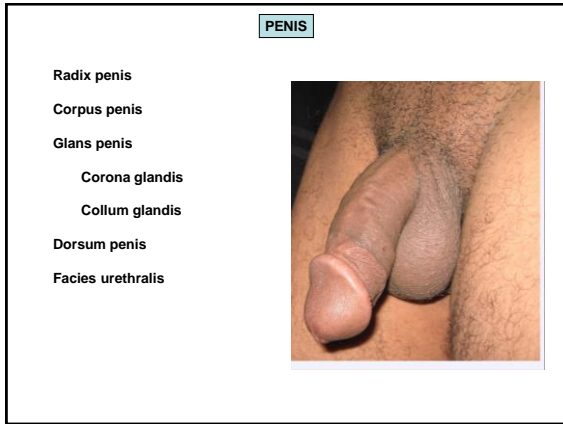
ústí ductus ejaculatorius

CYSTOSCOPY

Hypertrophy of medial lobe

Hypertrophy of lateral lobes





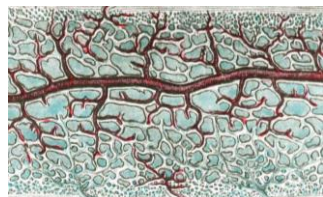
Morphology of cavernous bodies

Tunica albuginea

Trabeculae corporis cavernosi (spongiosi)

Cavernae corporis cavernosi (spongiosi)

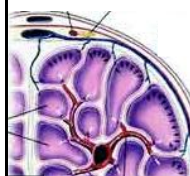
Aa. helicinae

**ERECTION**

Parasympaticus (spinal segment S₃)

Relaxation of the smooth muscles in the Ebner pads

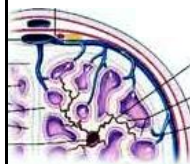
Dilation of the aa. helicinae

**DETUMESCENCE**

Sympaticus (spinal segment L_{2,3})

Contraction of the smooth in the Ebner pads

Constriction of the aa. helicinae

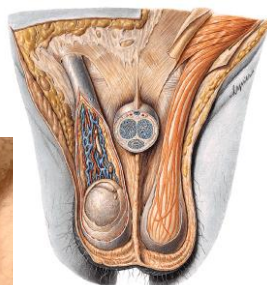
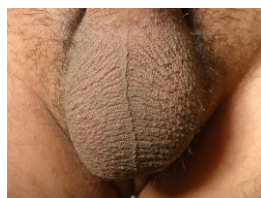**SCROTUM**

Raphe scroti, pubes

Tunica dartos scroti

Septum scroti

Cavum scroti



M. ischiocavernosus

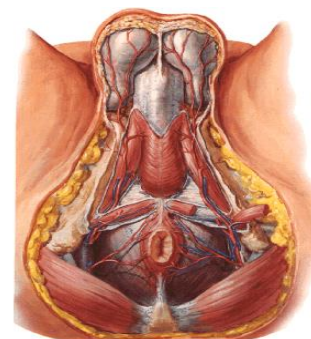
M. bulbospongiosus

M. sphincter ani externus

Fascia perinei superficialis

Spatium perinei profundum

Spatium perinei superficiale

**References:**

Putz, R. (2008):

Atlas of Human Anatomy Sobotta. Elsevier Books.

Keith L. Moore, Arthur F. Dalley (2005):

Clinically Oriented Anatomy. Williams and Wilkins.

Platzer, W., Kahle, W., Leonhardt H. (1992):

Locomotor system. Georg Thieme Verlag, Stuttgart, New York, 4th edition.

Čihák, R. (1987): Anatomie 1. Avicenum, Zdravotnické nakladatelství.