

# (VII.) Electrocardiography

Physiology

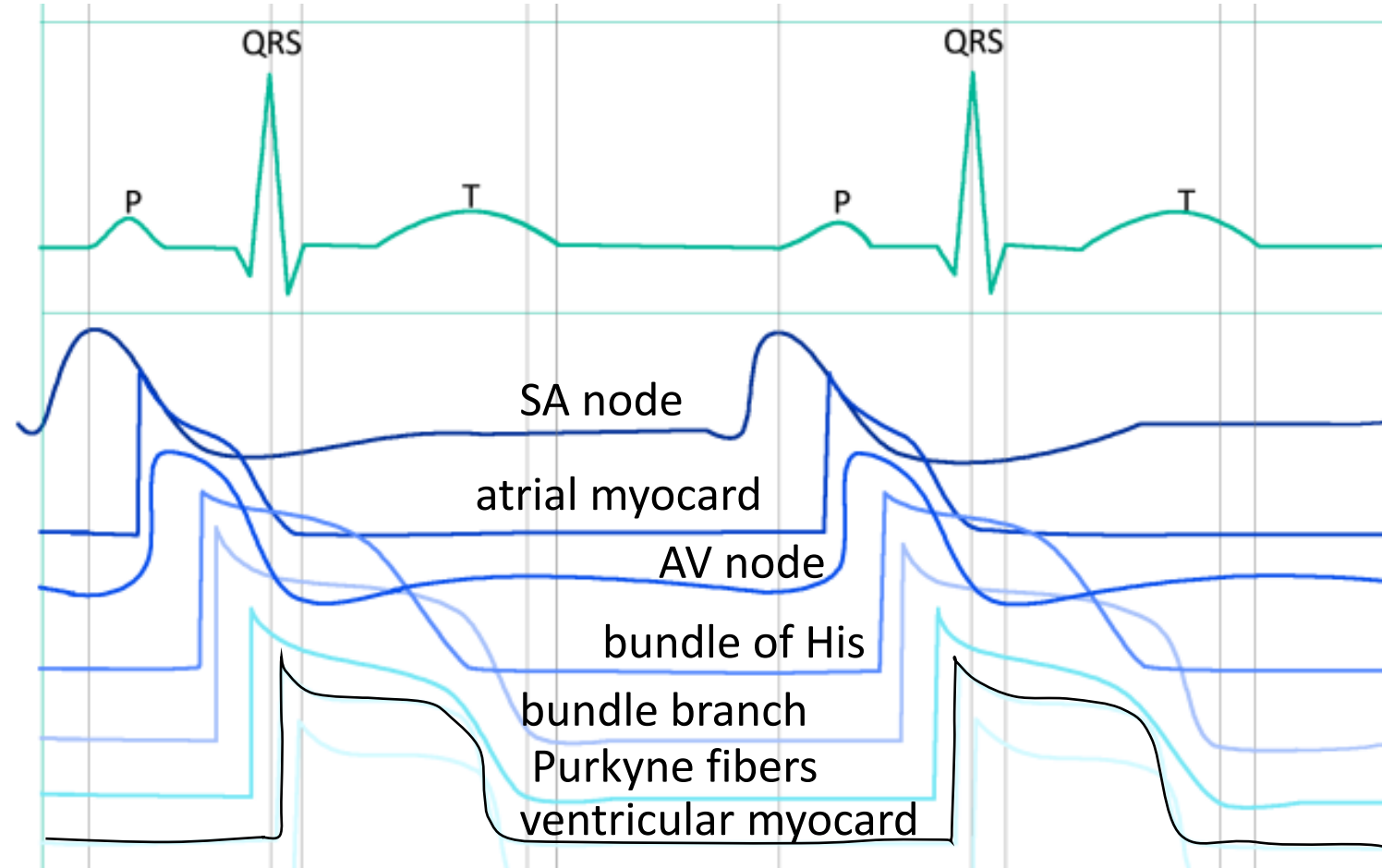
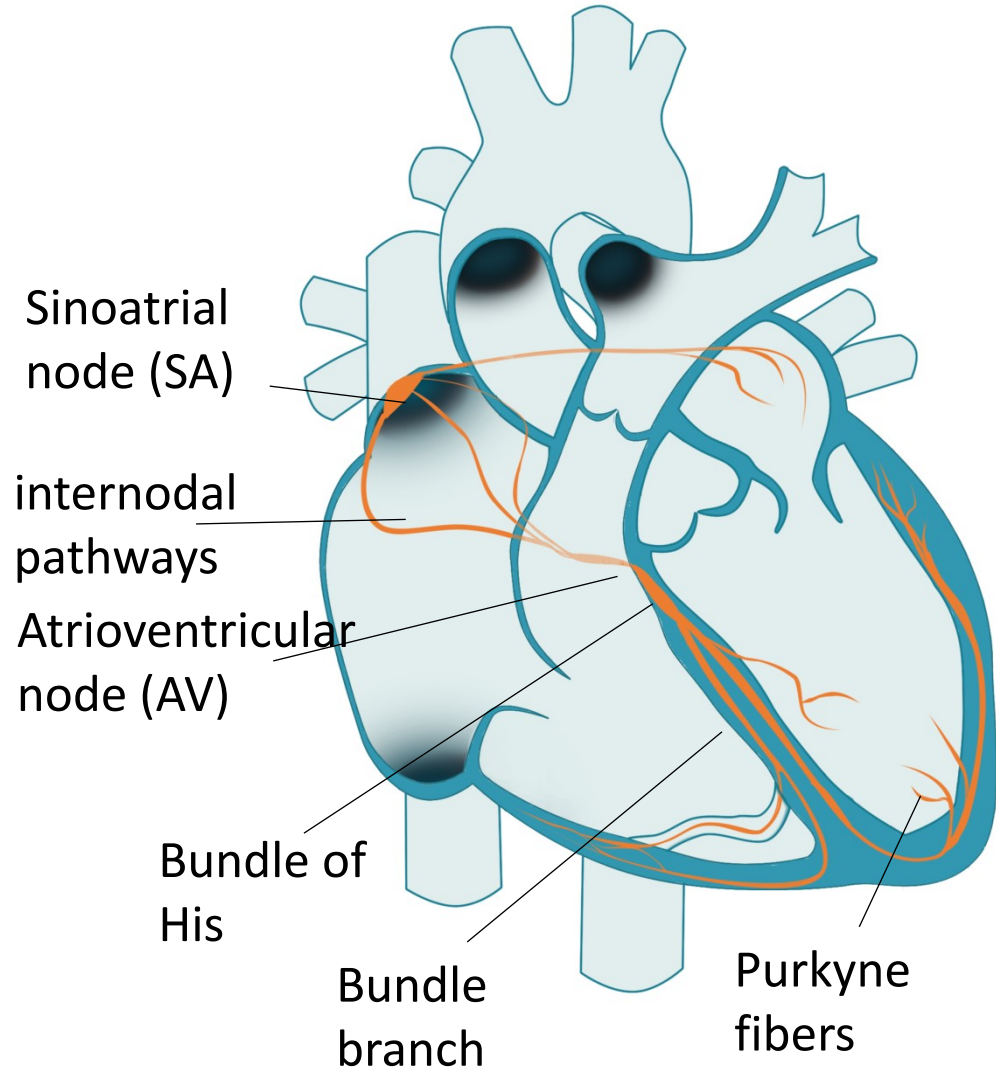
# Electrocardiography

Definition: the process of recording the electrical activity of the heart

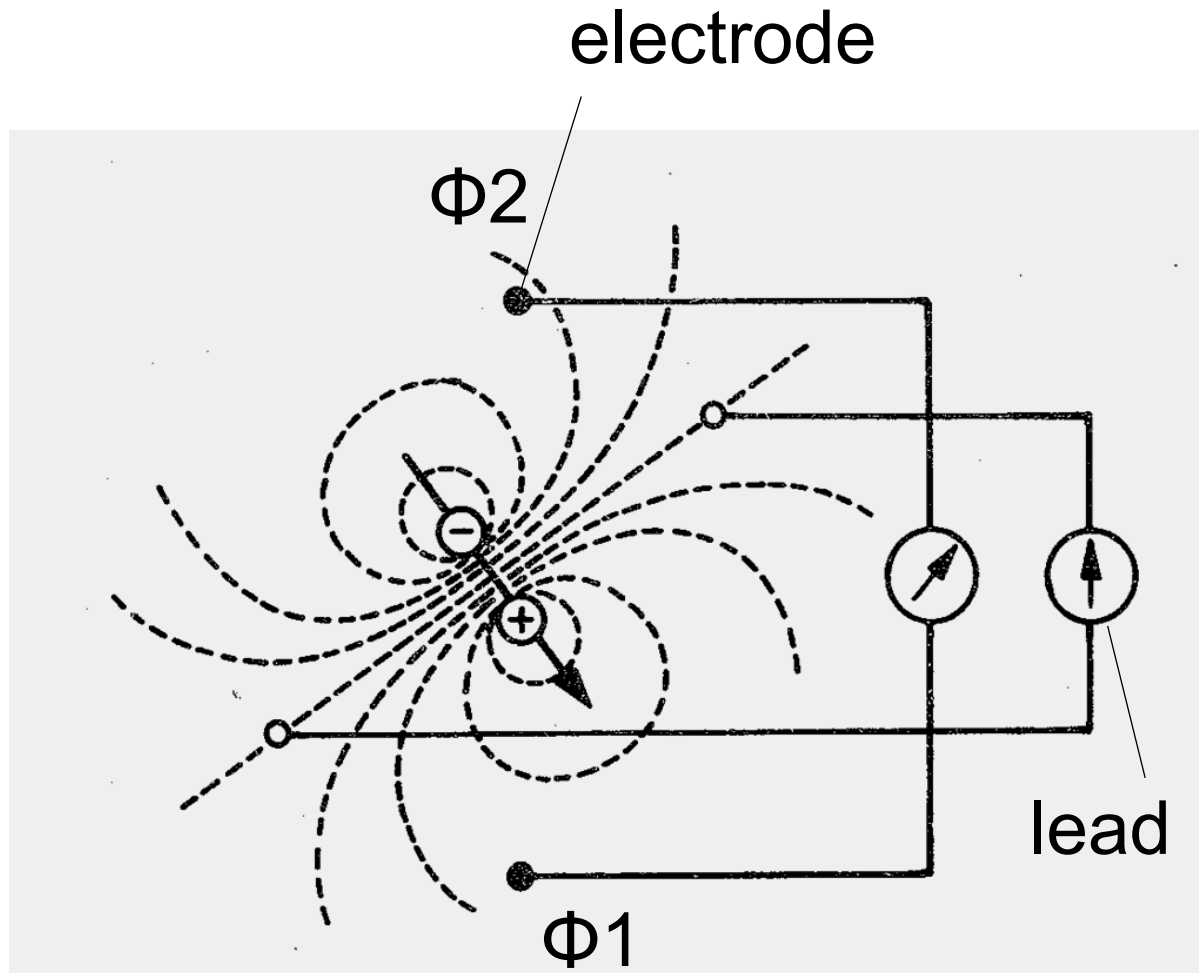
## Keywords

- Specialized excitatory and conductive system of the heart
- equipment for ECG recording
- limb and chest leads
- unipolar and bipolar leads
- heart vector, electrical axis of the heart

# Specialized excitatory and conductive system of the heart



# Electric dipole



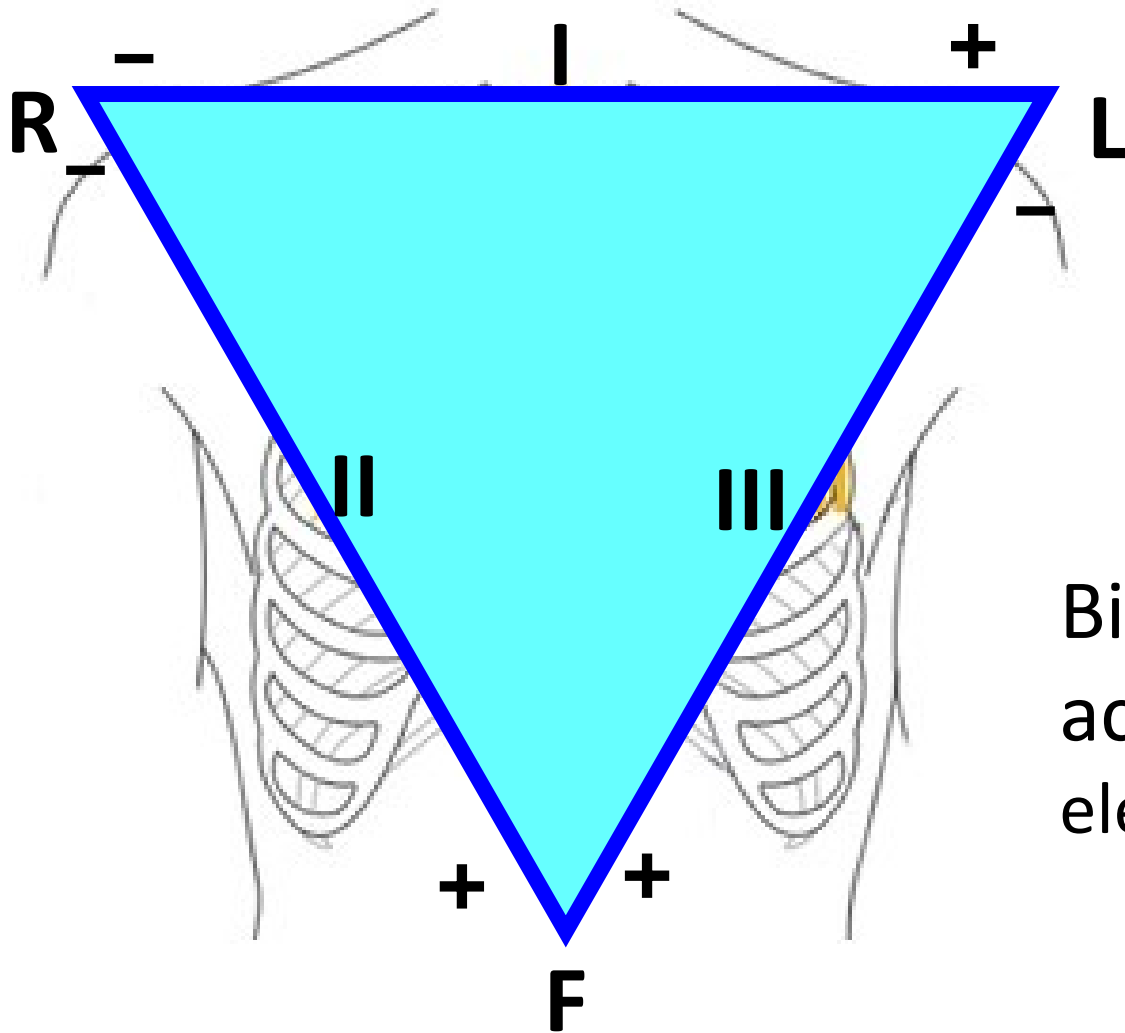
Electrode: records electrical potential ( $\Phi$ )

Elektric lead: connection of two electrodes

- Records voltage between electrodes
- Voltage: difference between el. potentials ( $V = \Phi_1 - \Phi_2$ )

# Einthoven's triangle

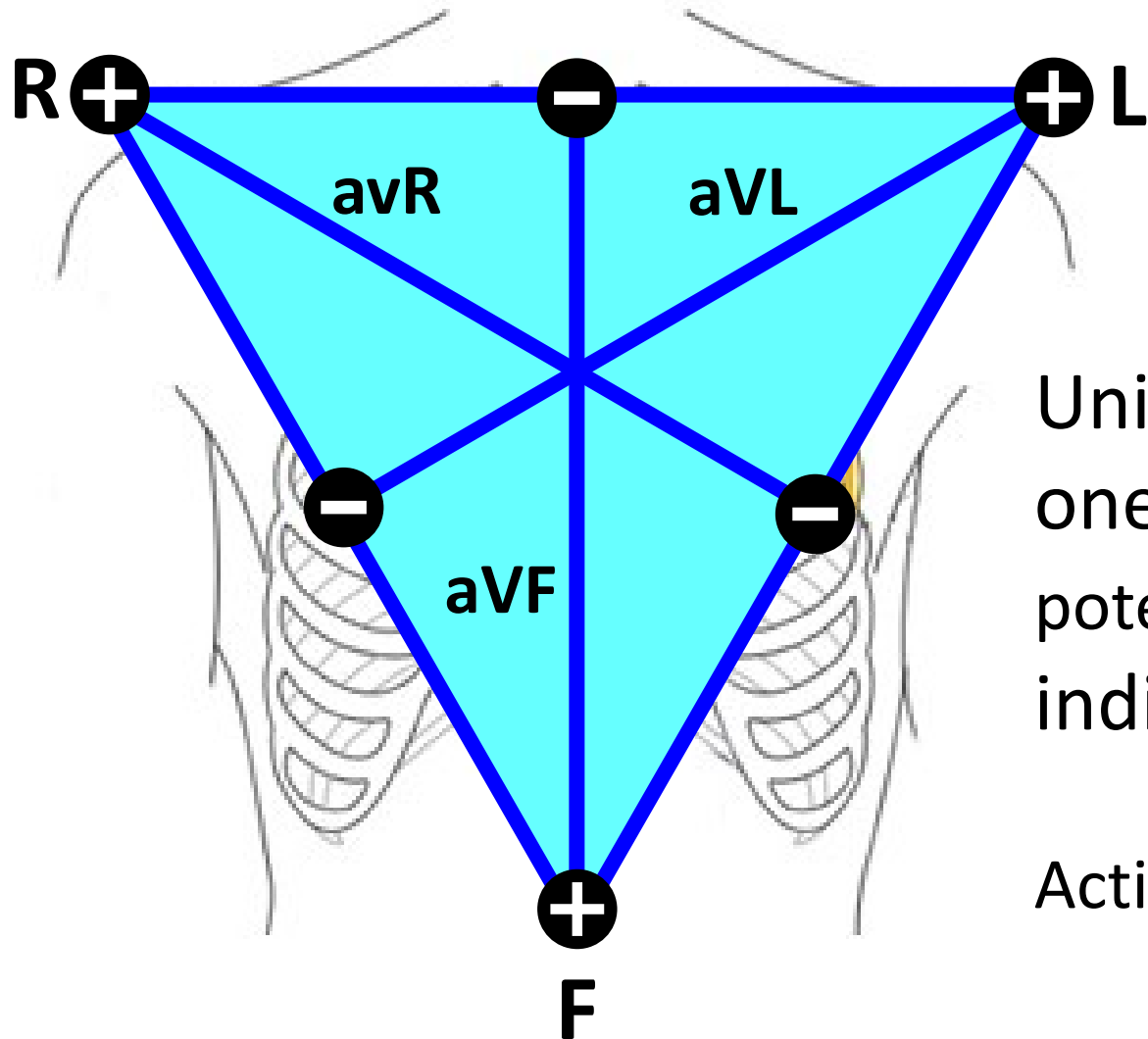
(standard, limb, bipolar leads)



Bipolar leads: both electrodes are active (variable potential en electrodes)

# Augmented leads

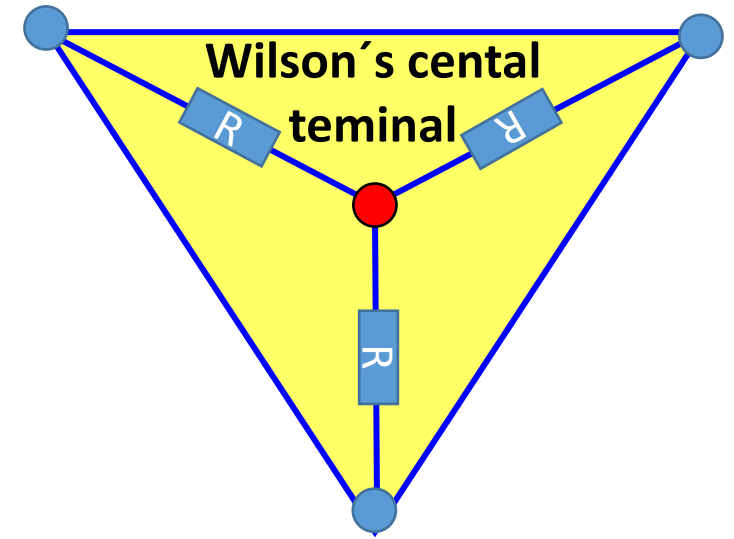
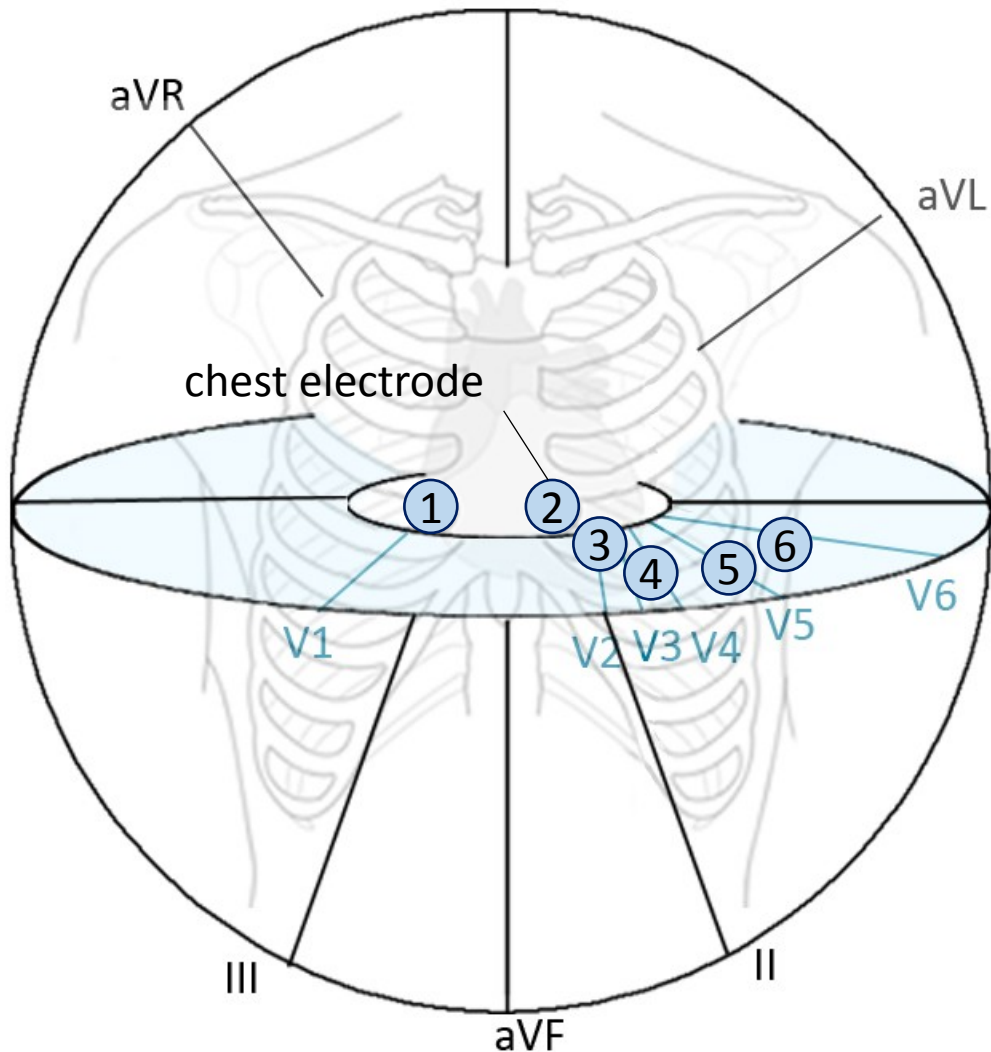
(Goldberger's, limb, unipolar leads)



Unipolar leads:  
one electrode is active (variable el. potential) and the second one is indifferent (constant el. potential)

Active electrode is always positive

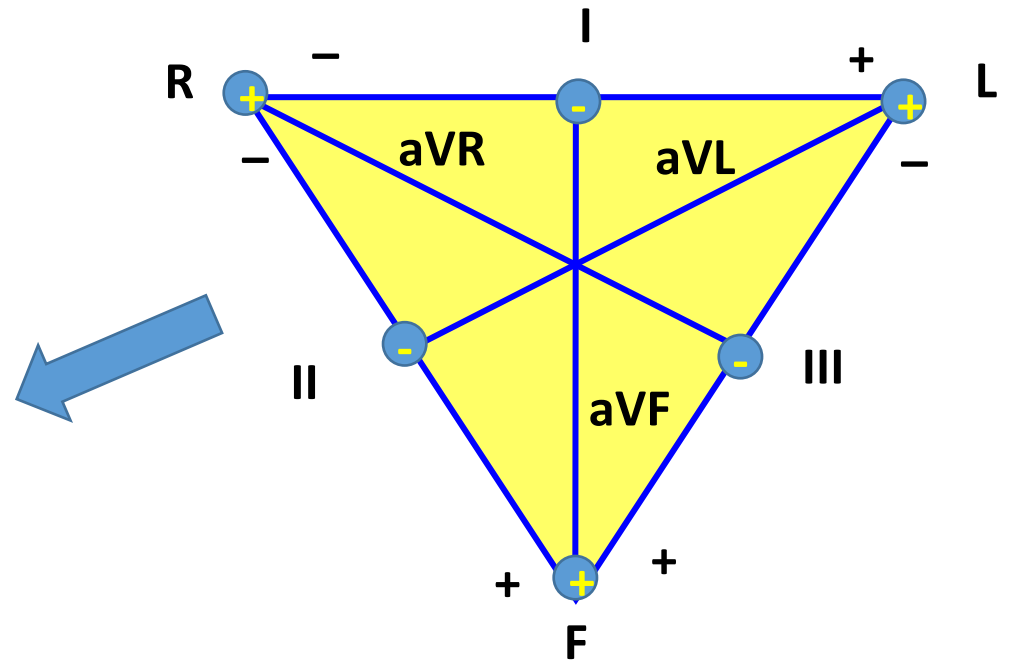
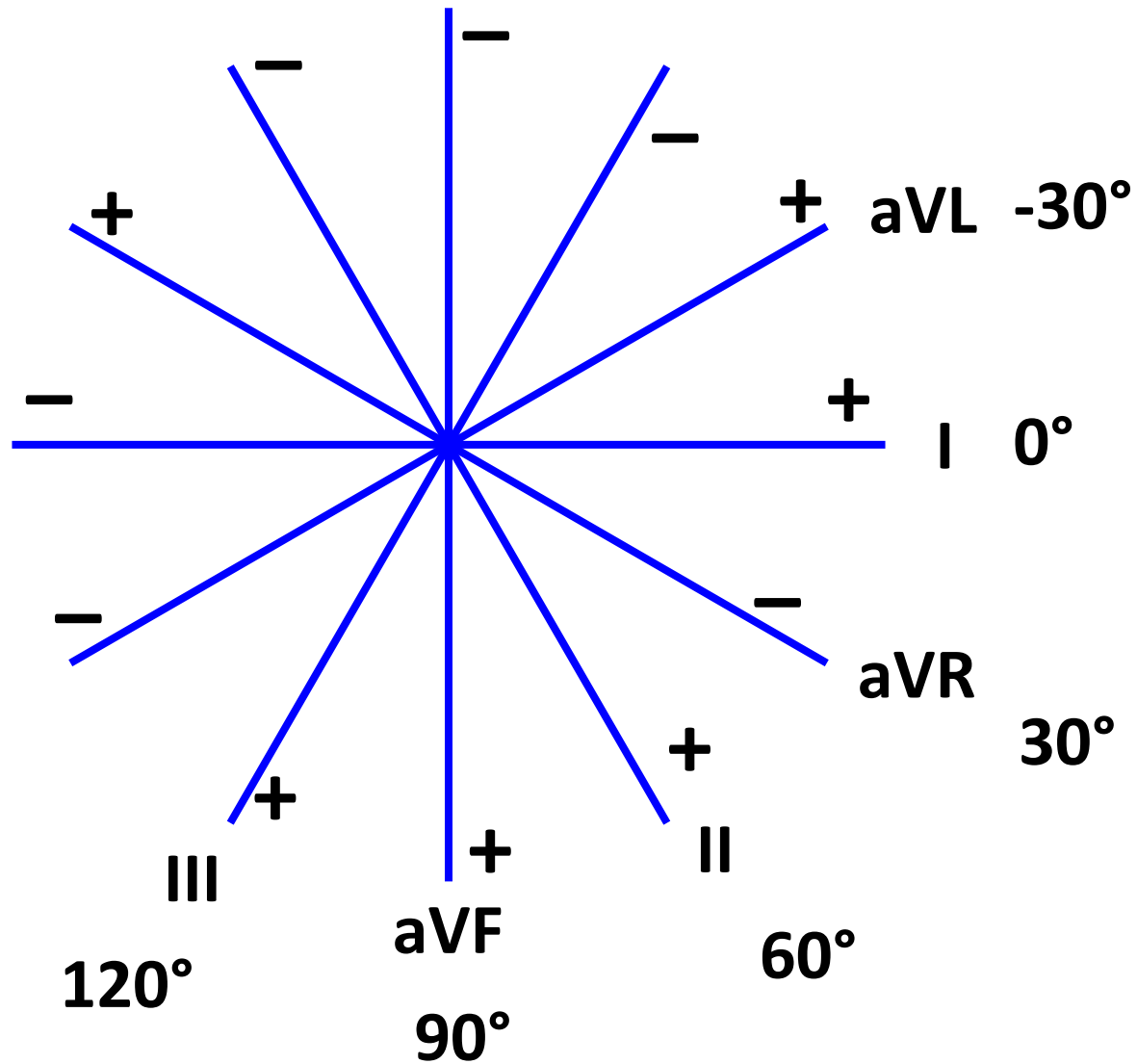
# Chest leads



Chest electrode: connection of chest electrode and Wilson's central terminal

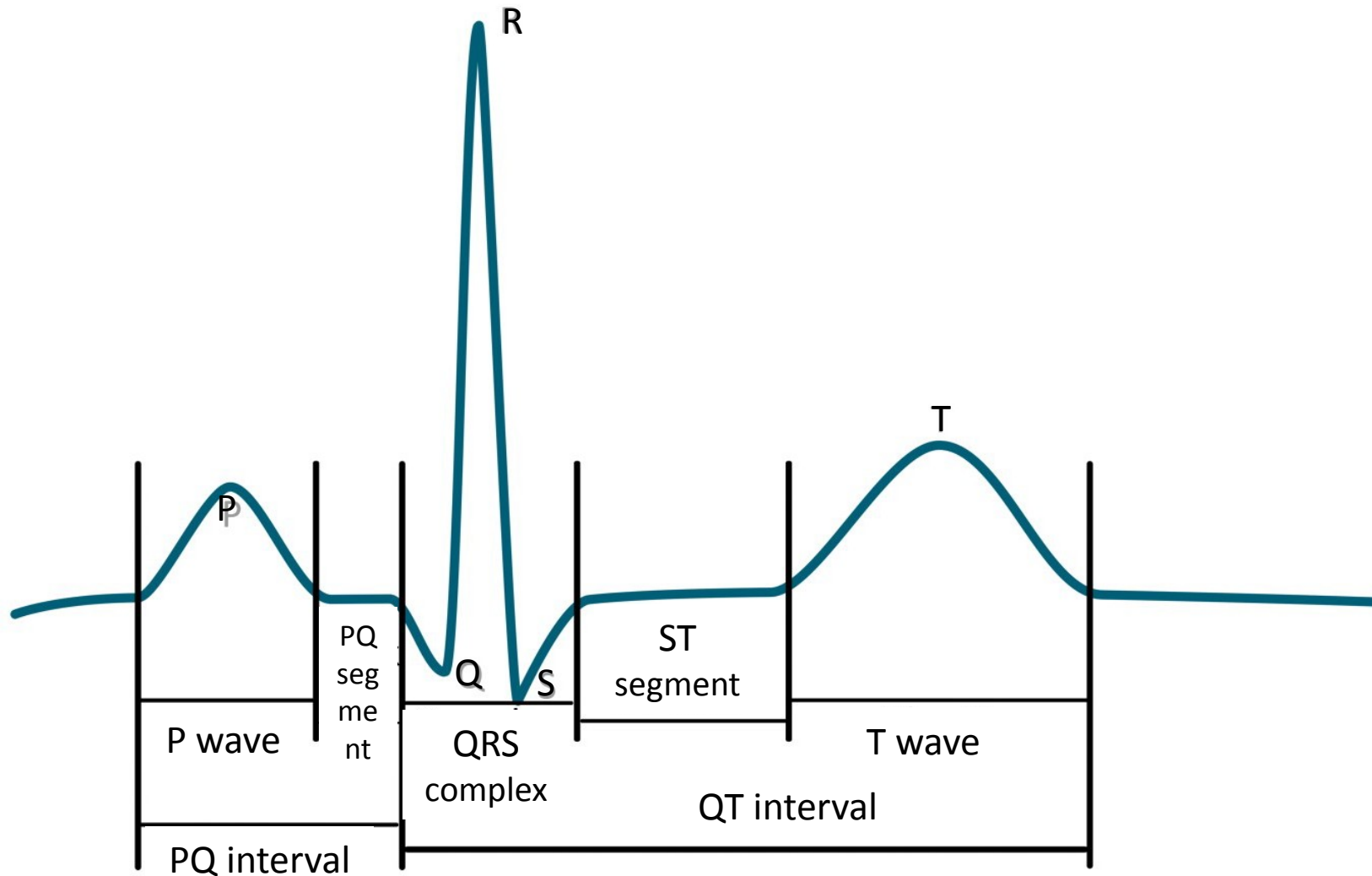
Unipolar leads:  
chest electrodes are active (positive) and  
Wilson's central terminal is indifferent (el. potential 0 mV, electrically centre of the heart)

# Leads according to Cabrera





# ECG description



name	Norm
P wave	80 ms
Interval PQ (PR)	120-200 ms
Segment PQ (PR)	50-120 ms
Q	-
QRS	80-100ms
R	-
S	-
segment ST	80-120 ms
Interval QT	>= 420ms
wave T	160 ms

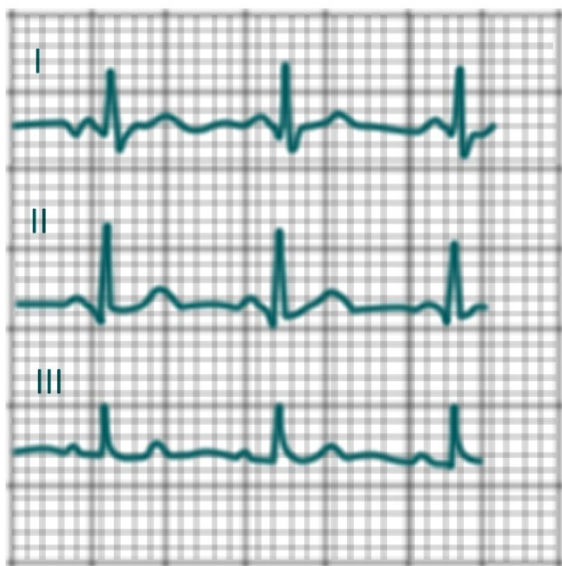formula:  $QTc = \frac{QT}{\sqrt{RR}}$

is on RR interval – correction of

# Electrical axis of heart

Average deviation of QRS complex in each lead

## 1. ORS of I,II and III lead

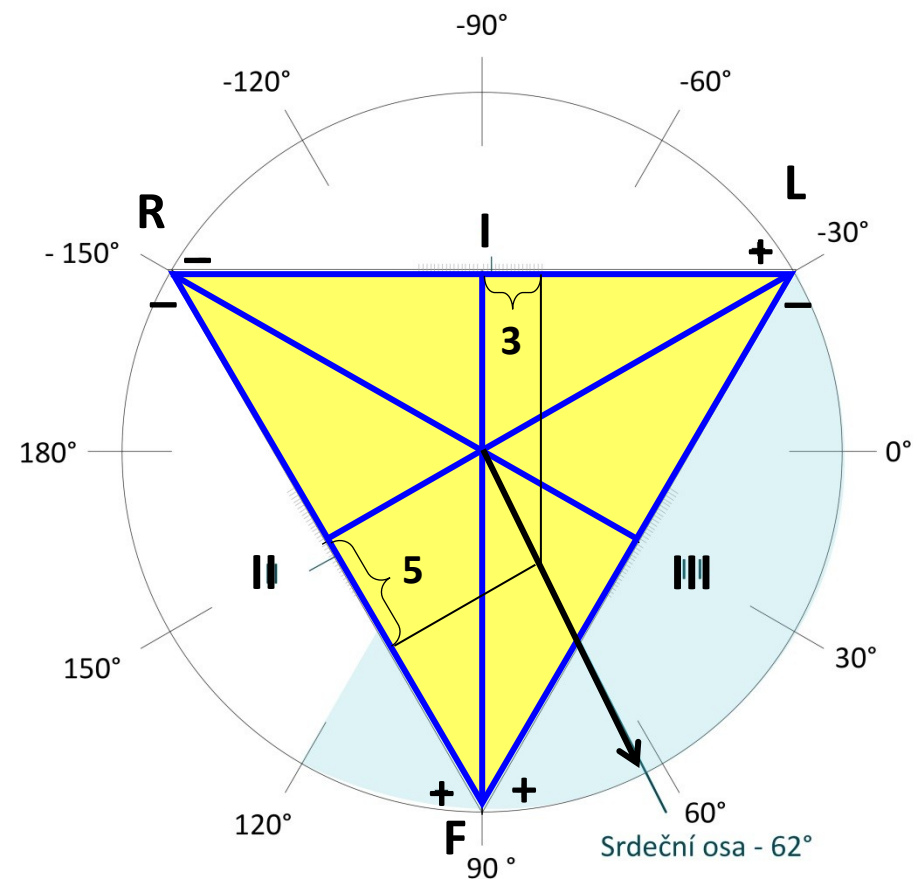


## 2. Sumation of QRS complex

I	II	III
Q = -1	Q = -1	Q = 0
R = 5	R = 6	R = 4
S = -1	S = 0	S = 0
3	5	4

Physiological interval: -30 - 110

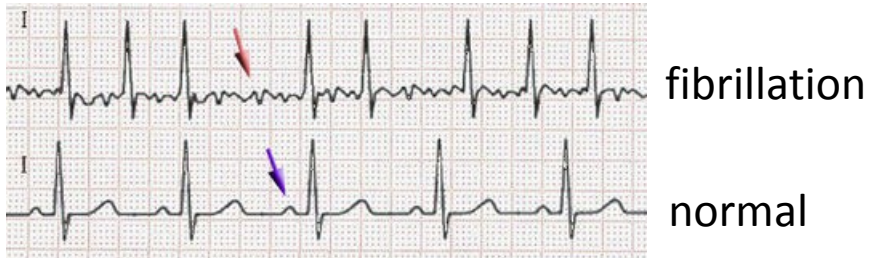## 3. Drawing in triangle



# Diagnostic use of ECG

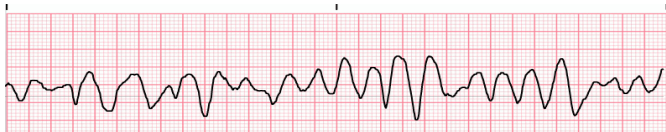## Arrhythmia: irregular heartbeat

Fibrillation: is the rapid, irregular, and unsynchronized activity of cardiac muscle fibers



### Atrial fibrillation

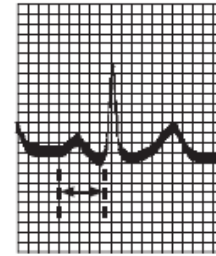
(absence of P, „jagged“ isolinia, irregular RR, HR 80 – 180 bpm)



### Ventricular fibrillation

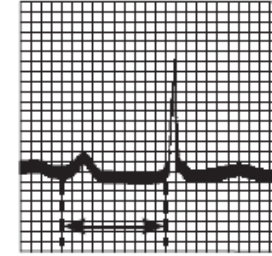
(heart cannot pump, brain damage after 3 – 5 min)

Atrioventricular block: conduction between the atria and ventricles of the heart is impaired



PR = 0.16 s

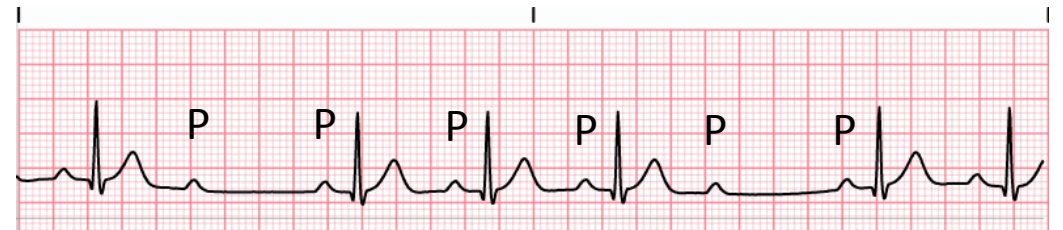
Normal complex



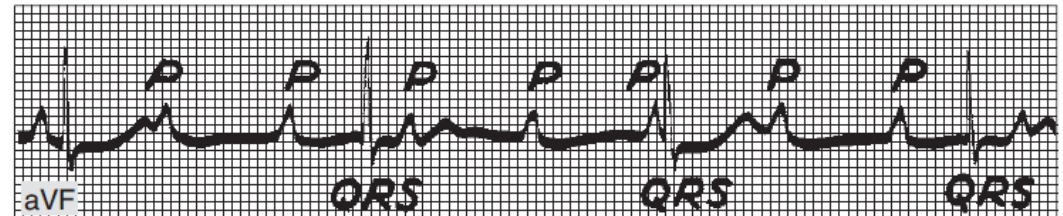
PR = 0.38 s

AV block I. degree

AV block  
II. degree



AV block  
III. degree



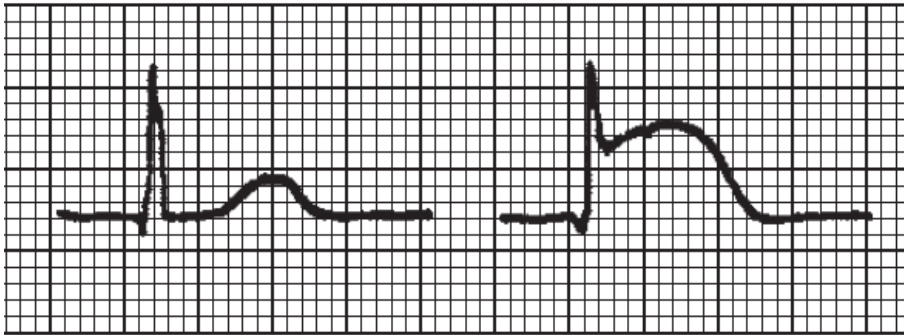
Complete heart block. Atrial rate, 107; ventricular rate, 43

# Diagnostic use of ECG

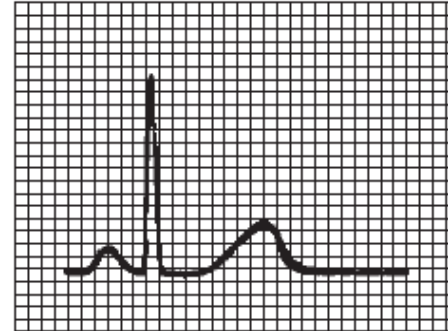
Myocardial ischemia, heart-attack

A

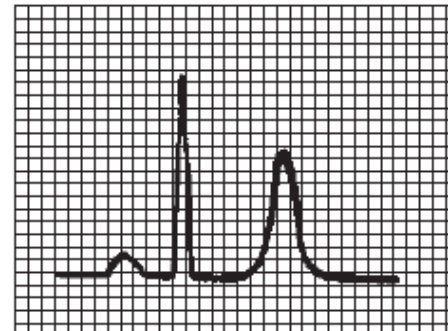
B (ST elevation)



hyperkalaemia



Normal tracing (plasma  $K^+$  4–5.5 meq/L).



Hyperkalemia (plasma  $K^+$   $>7.0$  meq/L).

# Diagnostic use of ECG

## 24-hour monitoring of ECG (Holter)

