

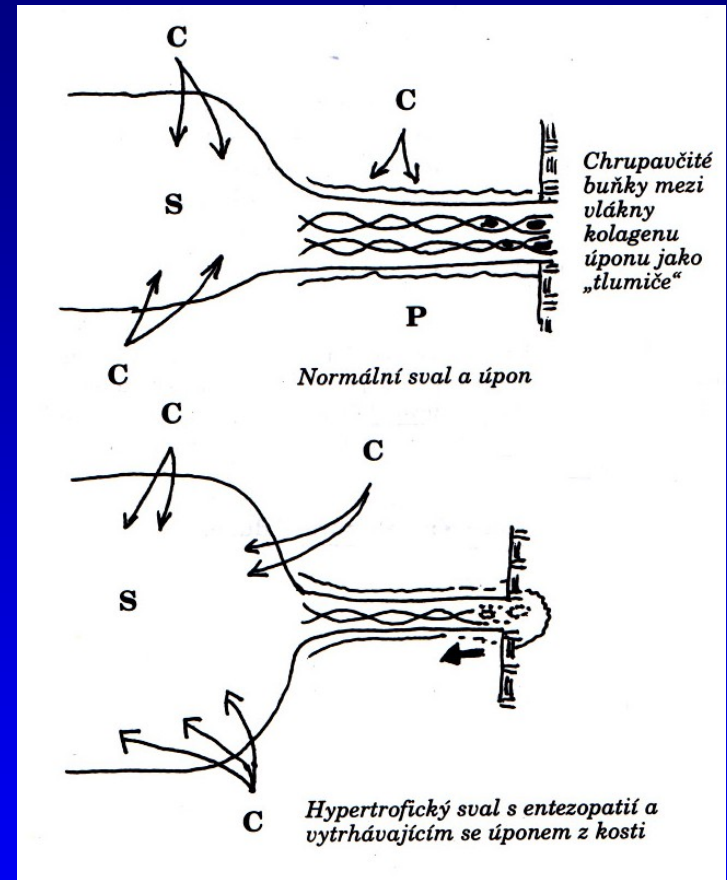
Entesopathy

Z. Rozkydal

Entezopathy

Pathological changes of insertions of tendons, ligaments and joint capsules into the bone

Dystrophia, microruptures of Sharpey's filaments from bone inflammation, periostitis ossifications, metaplasia



Tendinopathy: disorders in tendons and tendon sheaths

Cause

Acute and chronic overloading

Microtraumatisation

Repetitive movements and activities

Tennis elbow

Epicondylitis radialis humeri

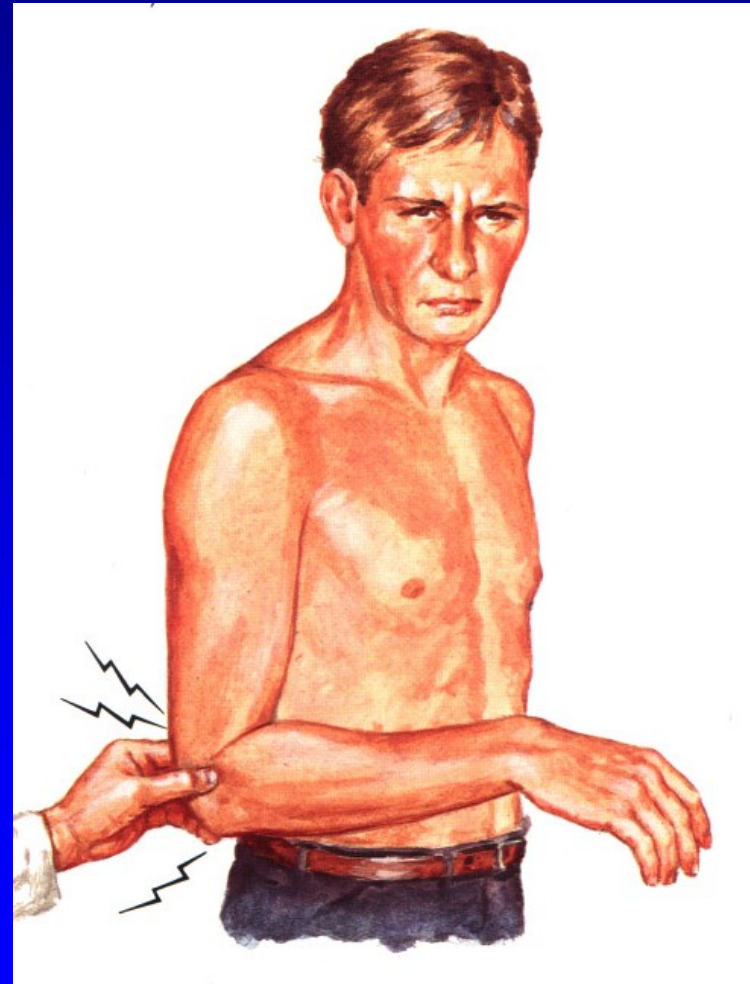
Pain with activity of extensors

Tenderness

Painful supination

Painful resisted dorsiflexion of the wrist
and of the third finger

Chair test



Tennis elbow- the cause

Entesopathy

Bursitis

Ossifications of insertion of extensors

Painful annular ligament

Painful synovial plica

Osteochondrosis dissecans

Pressure of radial nerve

Referred pain from cervical spine and shoulder

Tennis elbow

Conservative treatment

Rest, NSAID

Stretching, sling

Corticosteroids locally

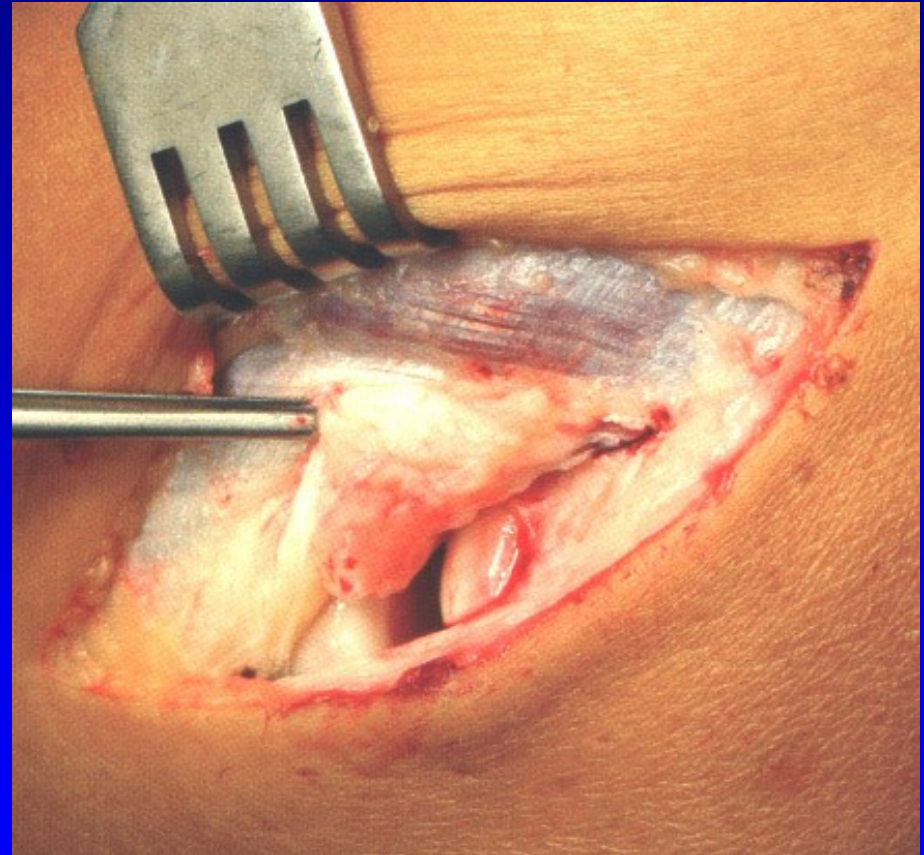
Physiotherapy

Orthosis or immobilisation

Operative treatment

Op. sec. Hohman

Op. sec. Boyd- McLeod



Golf elbow - Epicondylitis ulnaris humeri

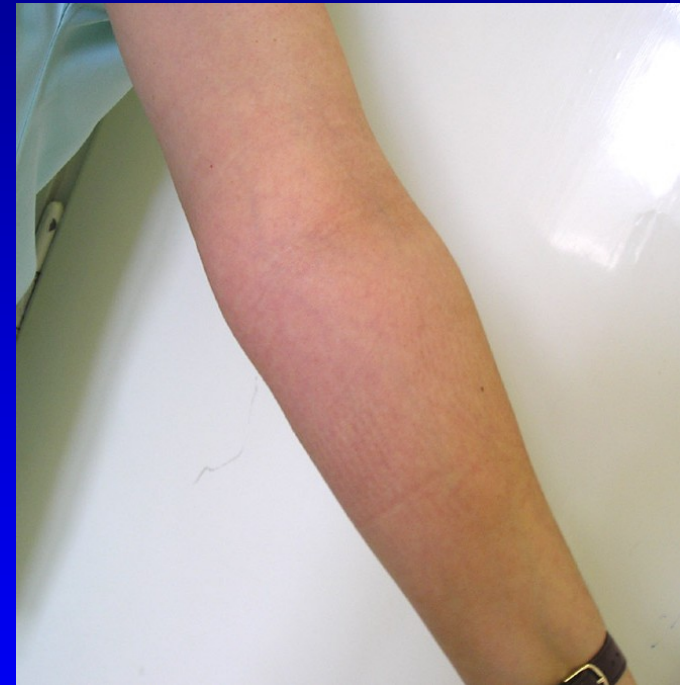
Entesopathy of insertions of flexors
on the ulnar epicondyle

Pain, tenderness

Resisted movements

Treatment:
Conservative

Operative
Distalisation of flexor's insertion



Bursitis of olecranon

Swelling and fluid
Tenderness

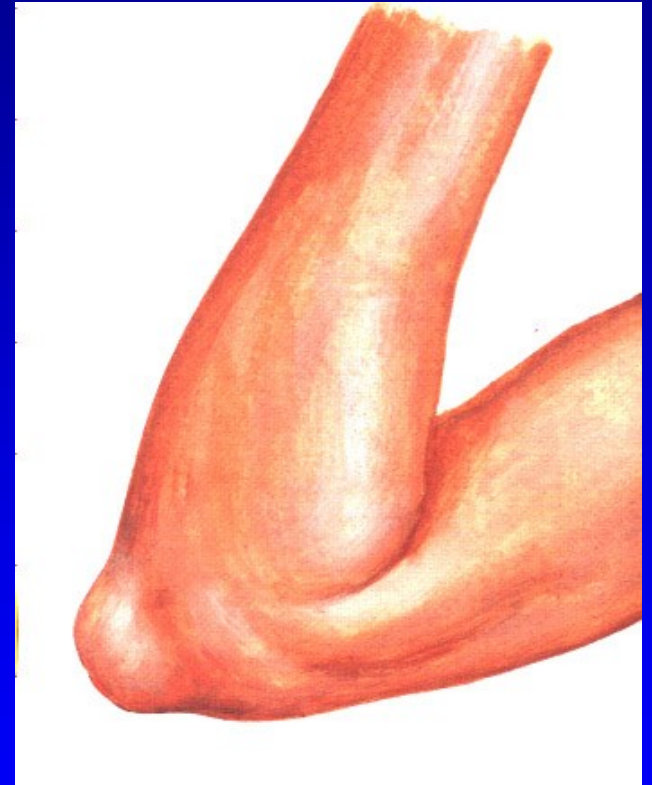
Treatment:

Aspiration, NSAID

Bandage, immobilisation

Corticoids locally

Risk of pyogenic inflammation



M. de Quervain

Stenosing tenosynovitis of
long abductor and short extensor
of the thumb

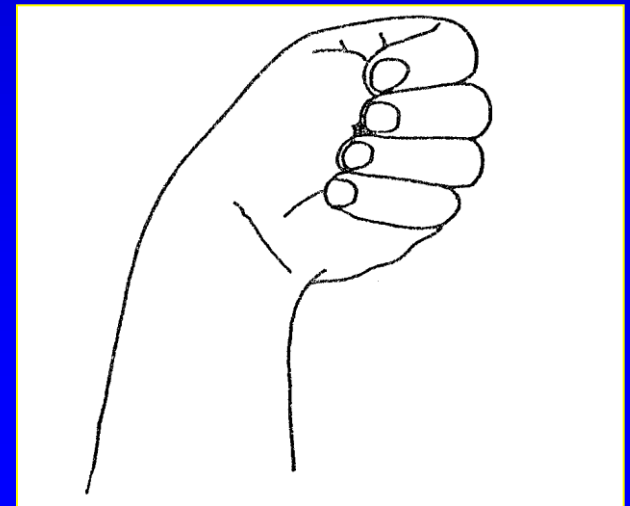
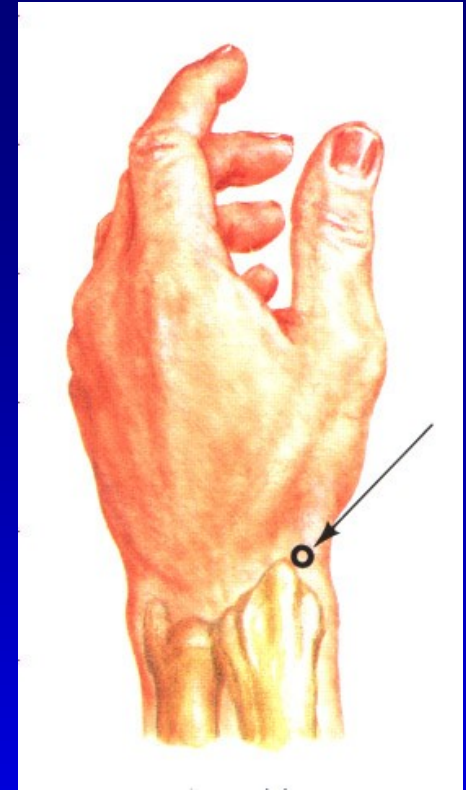Tenderness over styloid process
Finkelstein test

Treatment

Rest, orthosis, plaster

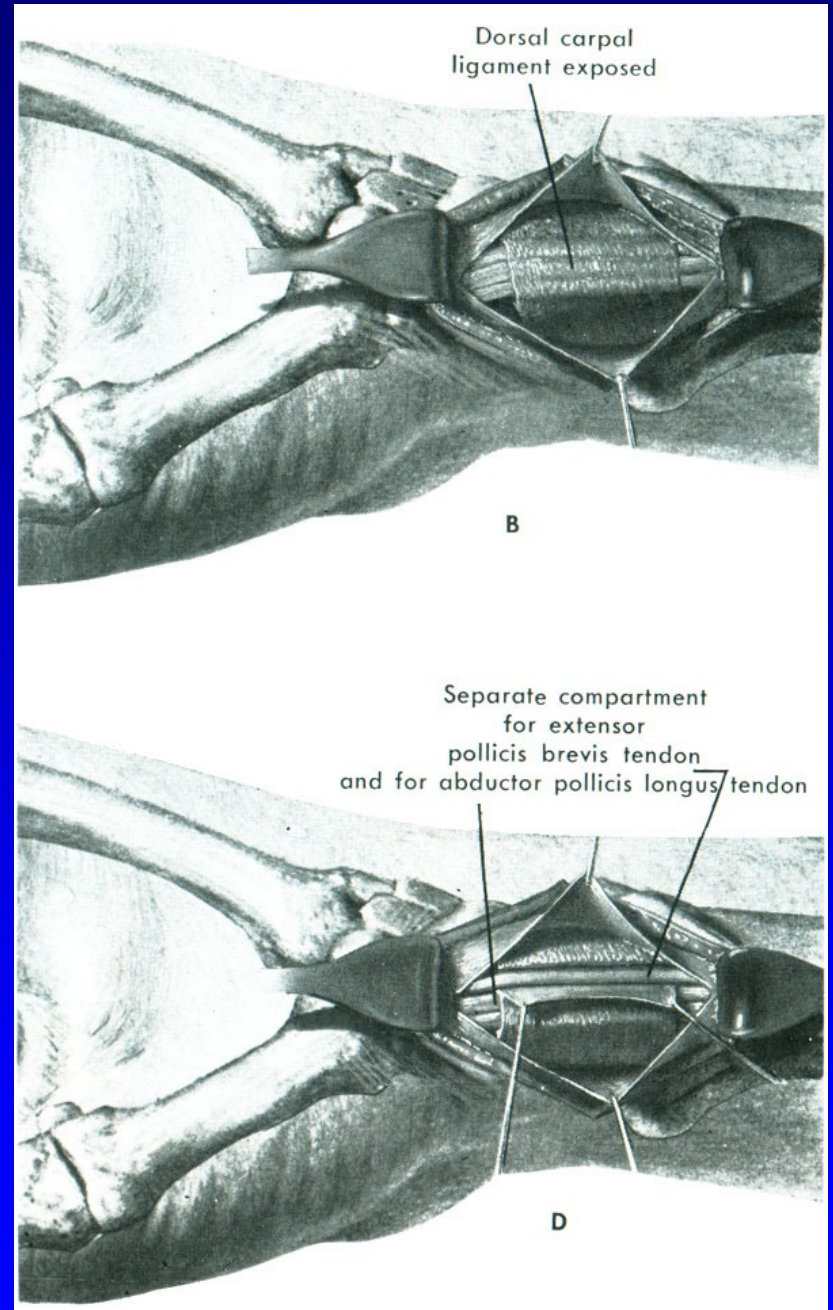
NSAID, corticoids

Surgery



M. de Quervain

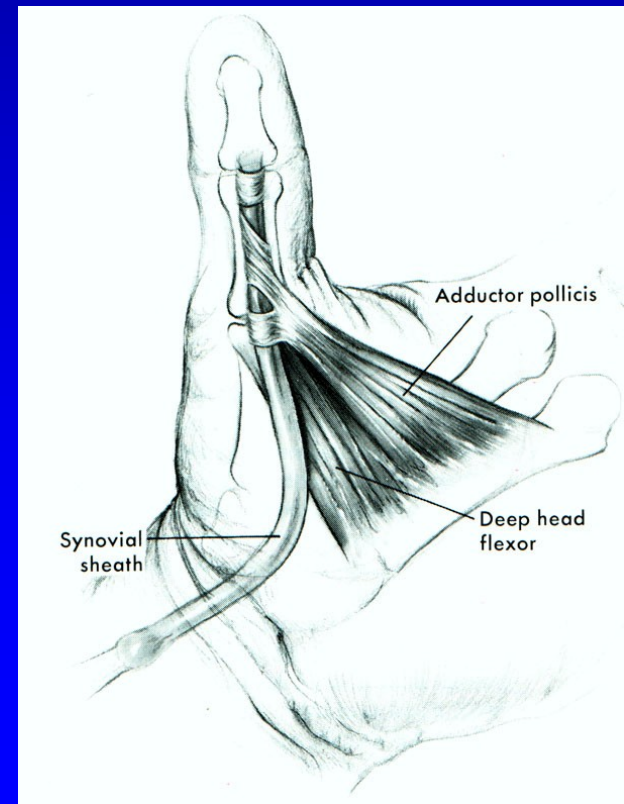
Dissection of the tendon sheat



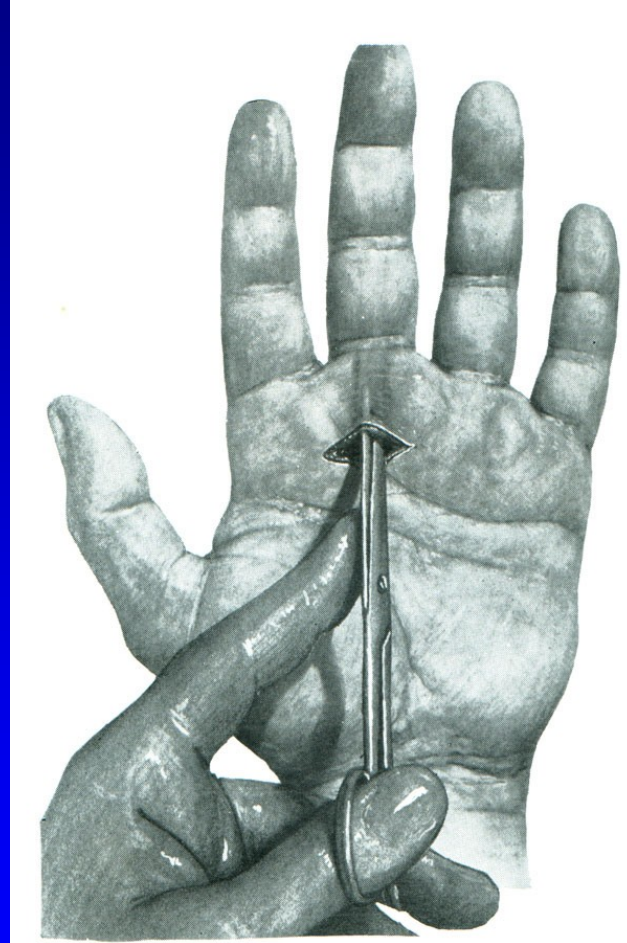Trigger thumb - pollex saltans

- Snapping of the thumb
- In childhood, in adults
- Narrowing of flexor sheath
- Enlargement of the tendon

Therapy: conservative
surgery



Trigger finger- digitus saltans



Th: corticoids, rest, surgery

Carpal tunnel syndrom

Compression neuropathy of median nerve

Pain, diminished muscle power

Hypotrophy of thenar muscles

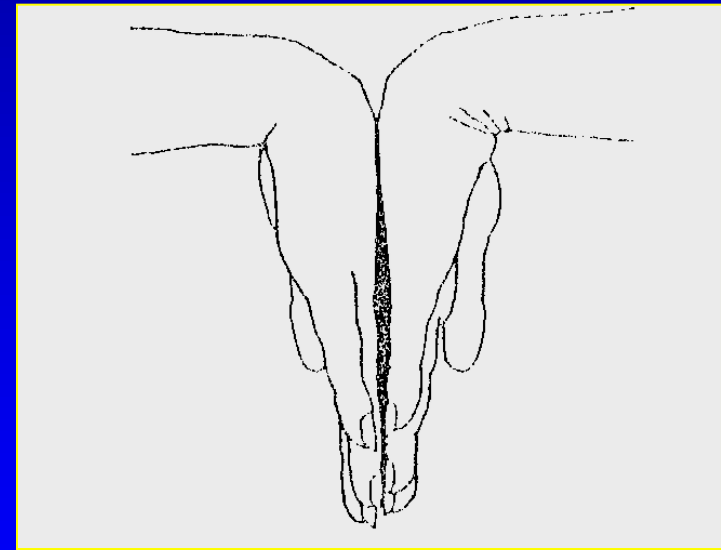
Paresthesia and numbness

Limited function of fingers

Tenderness

Tinnel sign

Phalen test

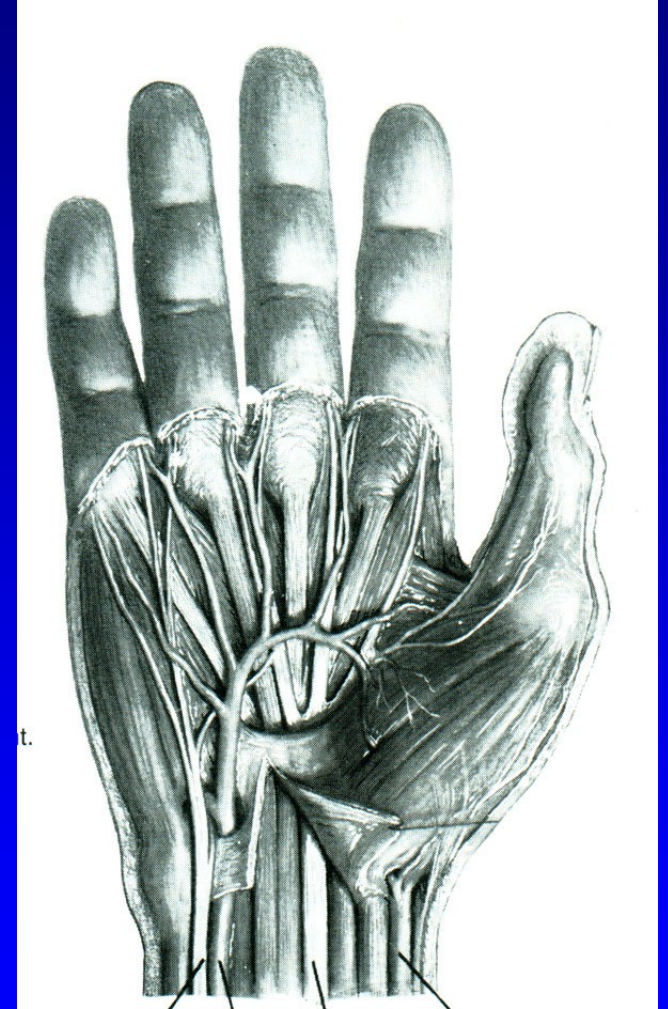

Carpal tunnel syndrom

Therapy

Conservative

Surgery



Guyon channel syndrom

Compression neuropathy of ulnar nerve
in hand

Paresthesia and numbness on
ulnar side

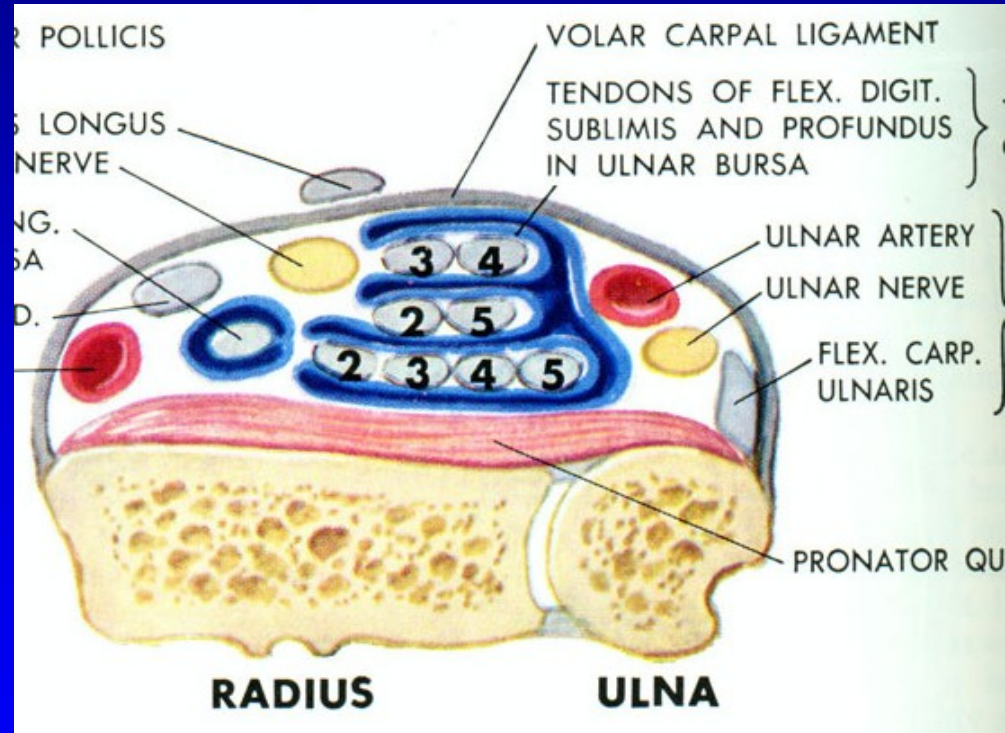
Hypotrophy of hypothenar

Limited function of 4.5. finger

Therapy

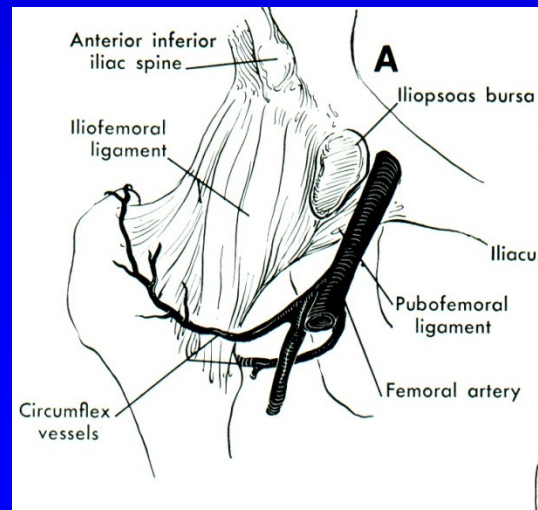
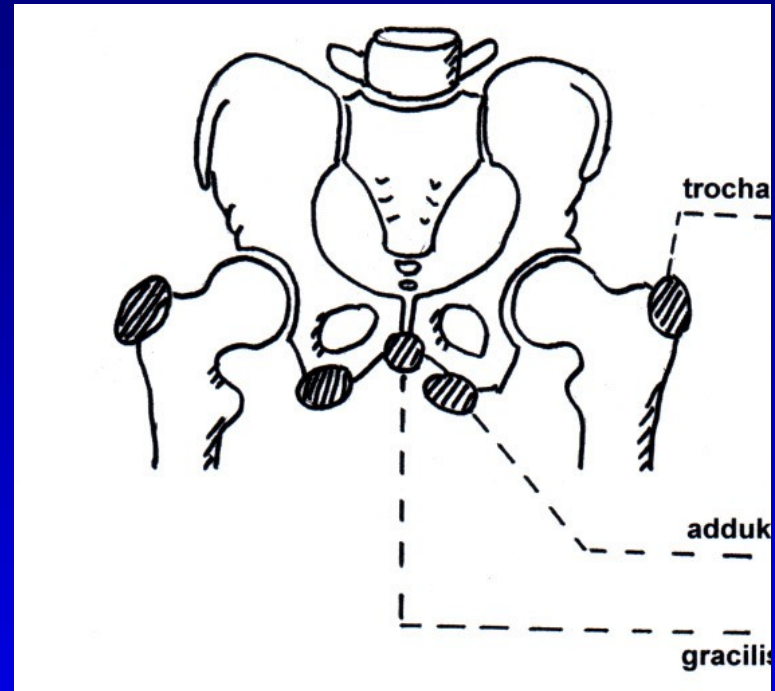
Conservative

Surgery



Bursitis and entesopathies in the hip region

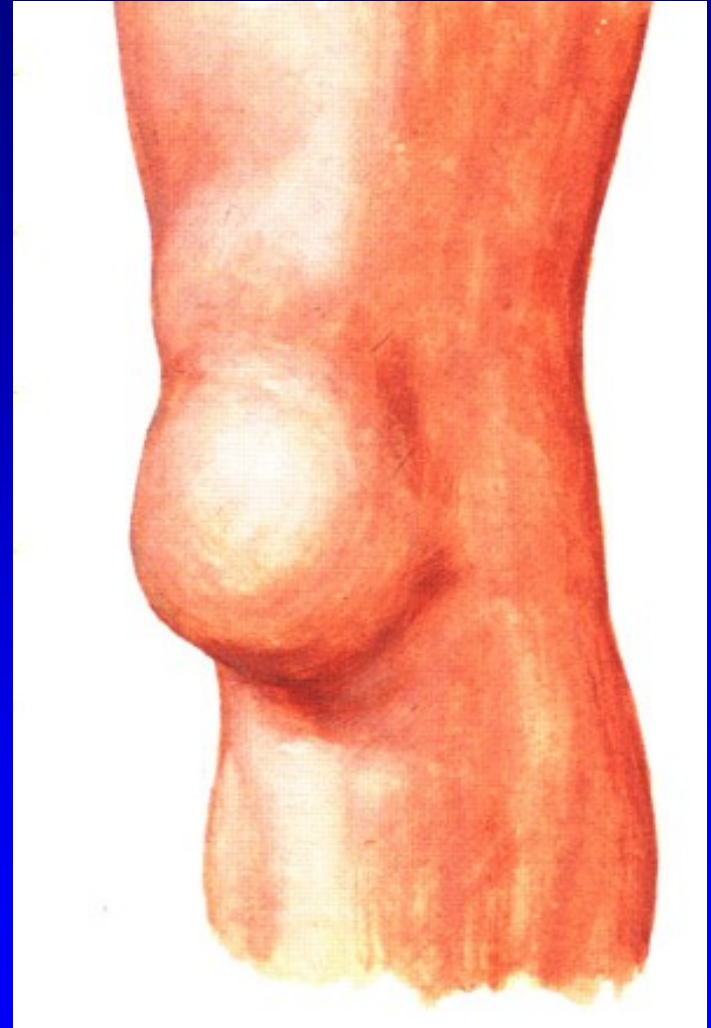
Greater trochanter
Ischial tubercle
Bursa ileopectinea
Gracilis syndrom
Spina iliaca ant. sup.
Spina iliaca ant inf.
Adductor entesopathy
Snapping hip- coxa saltans
Femoroacetabular impingement



Bursitis in the knee region

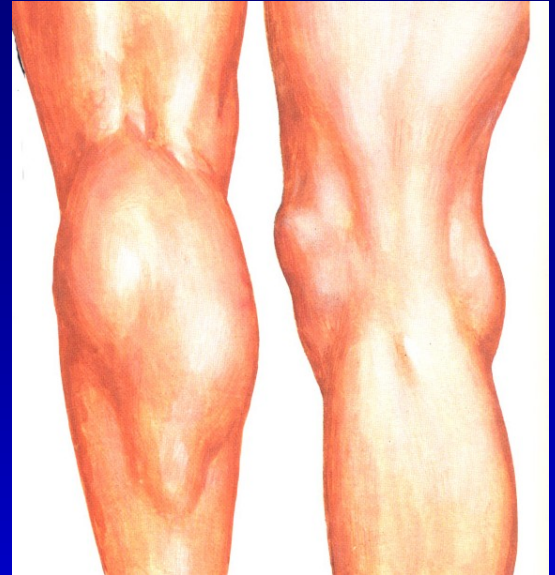
Prepatellar bursitis
Infrapatellar bursitis
Bursitis of pes anserinus

Therapy:
Rest, aspiration, corticoids
NSAID, surgery



Baker's cyst

Bursa gastrocnemio- semimembranacea
Is connected with joint space
Swelling, soft mass in popliteal region
Limited movements
Pressure onto large veins in
popliteal region.

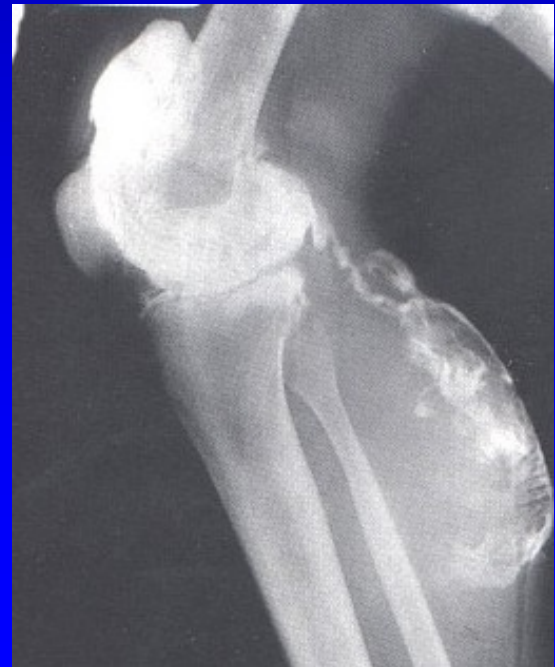

Secondary to pathology in the knee joint

Therapy:

Conservative – aspiration, local corticoids,
NSAID

Surgery



Entesopathies in knee region

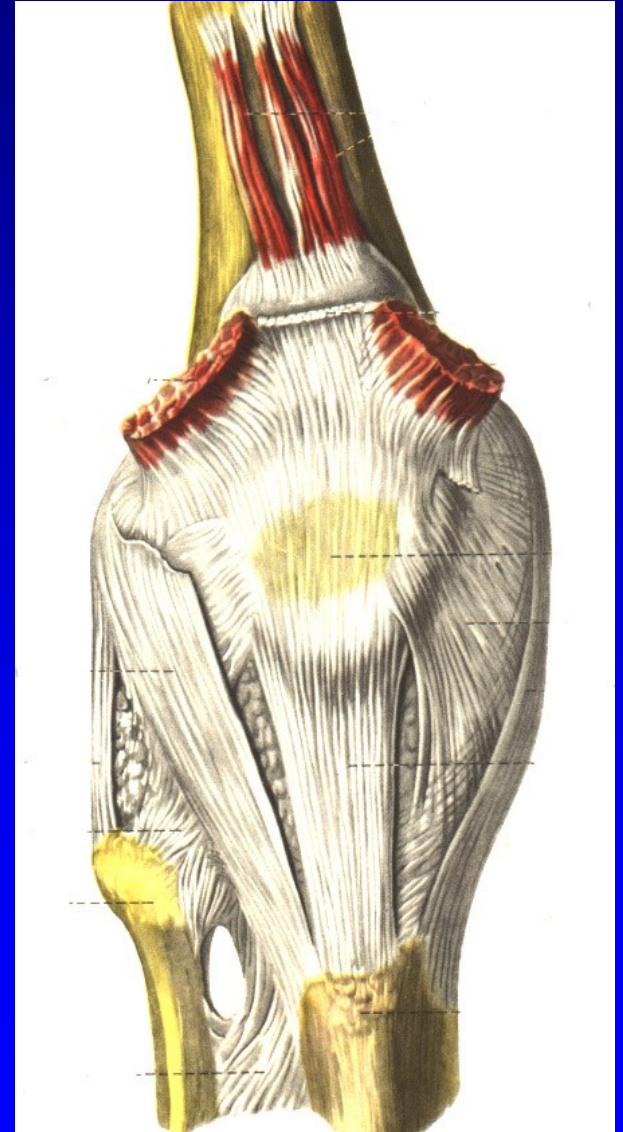
Jumper's knee

- distal pole of the patella

m. Osgood- Schlatter

Entesopathy in ligaments insertion

Entesopathy at Gerdy's tubercle



Bursitis and entesopathies in the foot

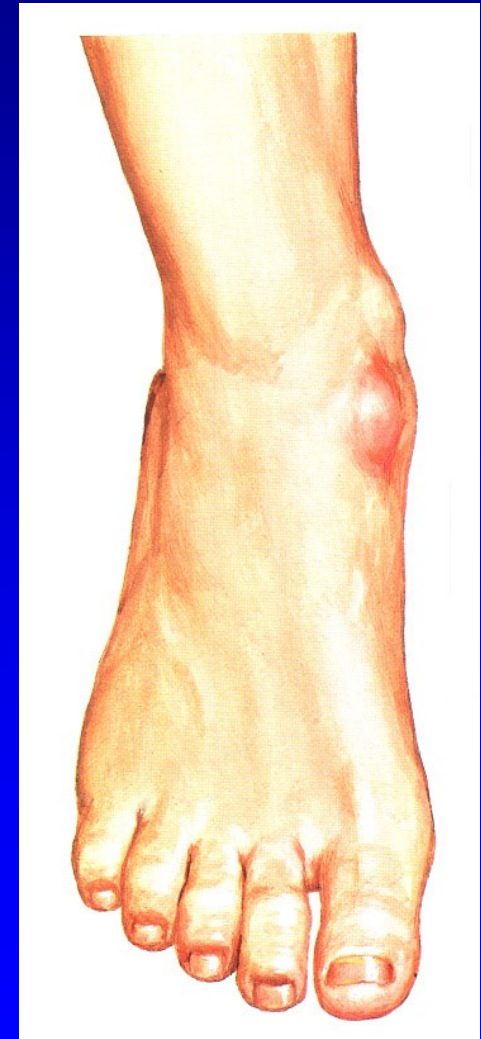
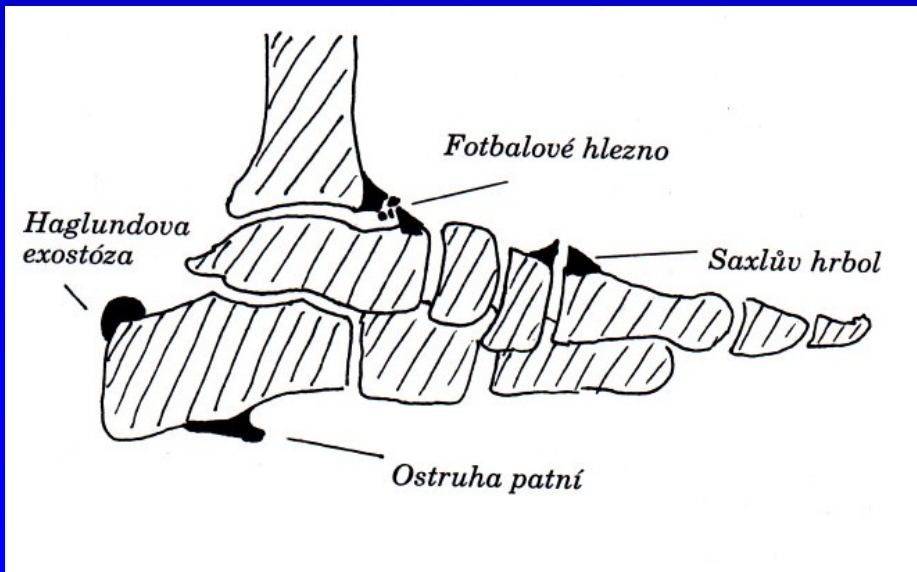
Achillodynia

Calcaneal spur

Haglund's exostosis

Osteophytes – dorsal

Os tibiale externum

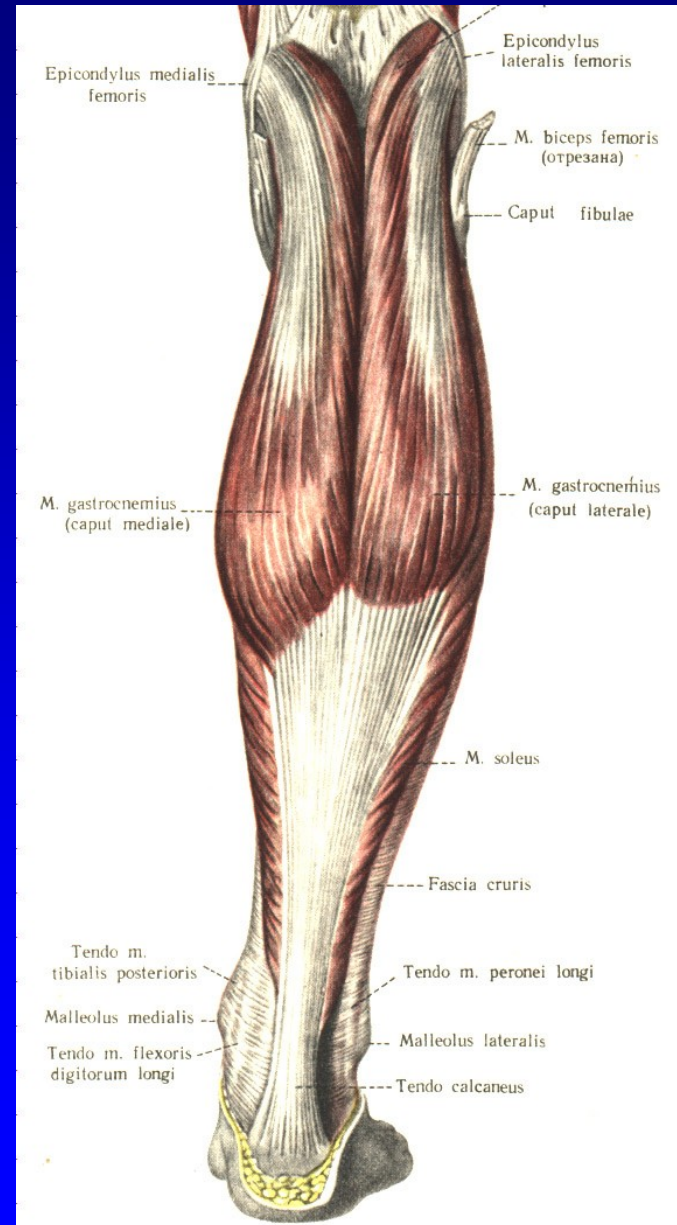


Achillodynia

Painful Achilles tendon
and it's insertion

Degeneration
Haemorrhage, ruptures
Peritenonitis

The risk of rupture



Achillodynia

Conservative treatment

Rest, taping, NSAID

Physiotherapy

Orthosis

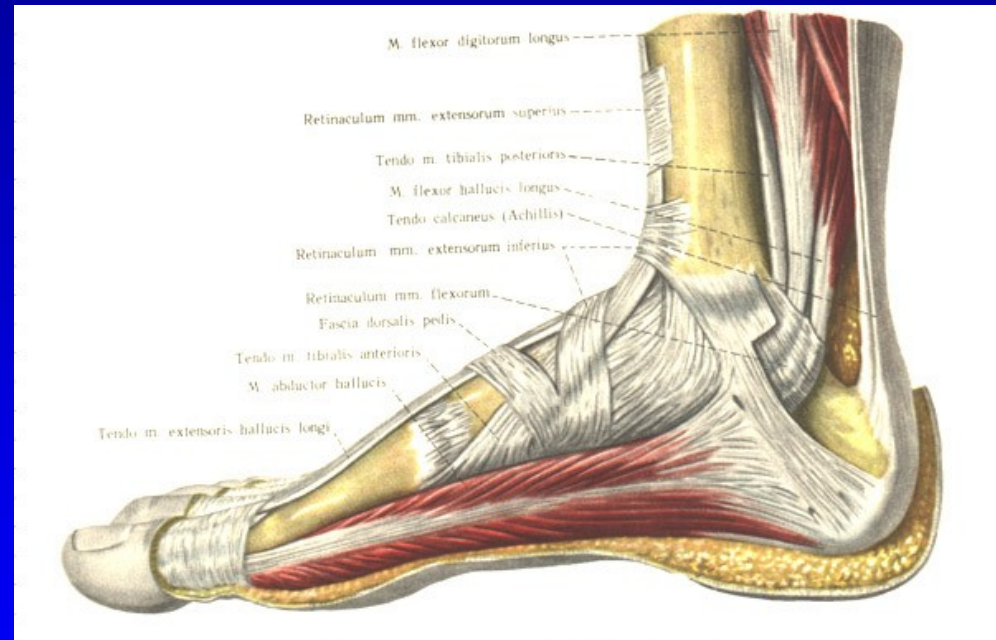
Hyaluronic acid

No corticoids !

Surgery:

Peritenonectomy

Excision of necrotic tissue



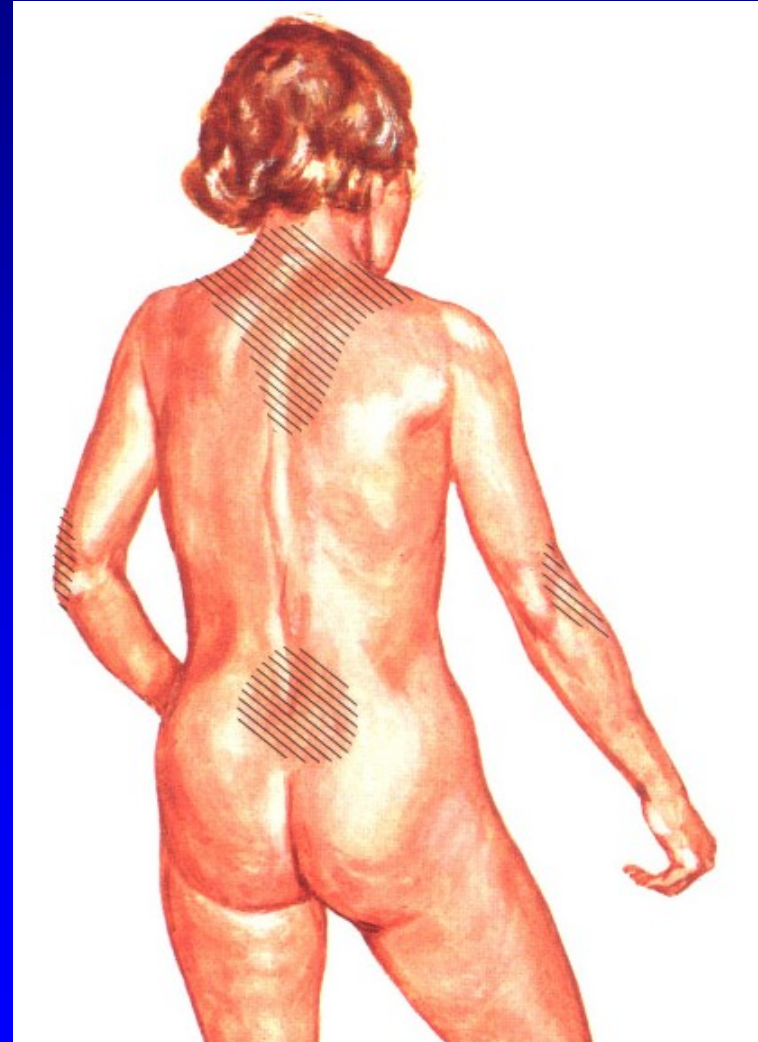Entesopathy at the spine

Painful insertions of ligaments
and tendons

Transverse or spinal processes

Scapula

Pelvis



Painful shoulder

Tenosynovitis of tendon of long head of biceps

Rupture of tendon of long head of biceps

Subacromial bursitis

Supraspinatus tendinitis

Rotator cuff rupture

Impingement syndrom

Frozen shoulder syndrom

Osteoarthritis of glenohumeral joint

Disorders of acromioclavicular joint

Inflammations

Tumors

Referred pain from cervical spine

Tenosynovitis of long head of biceps

Tenderness

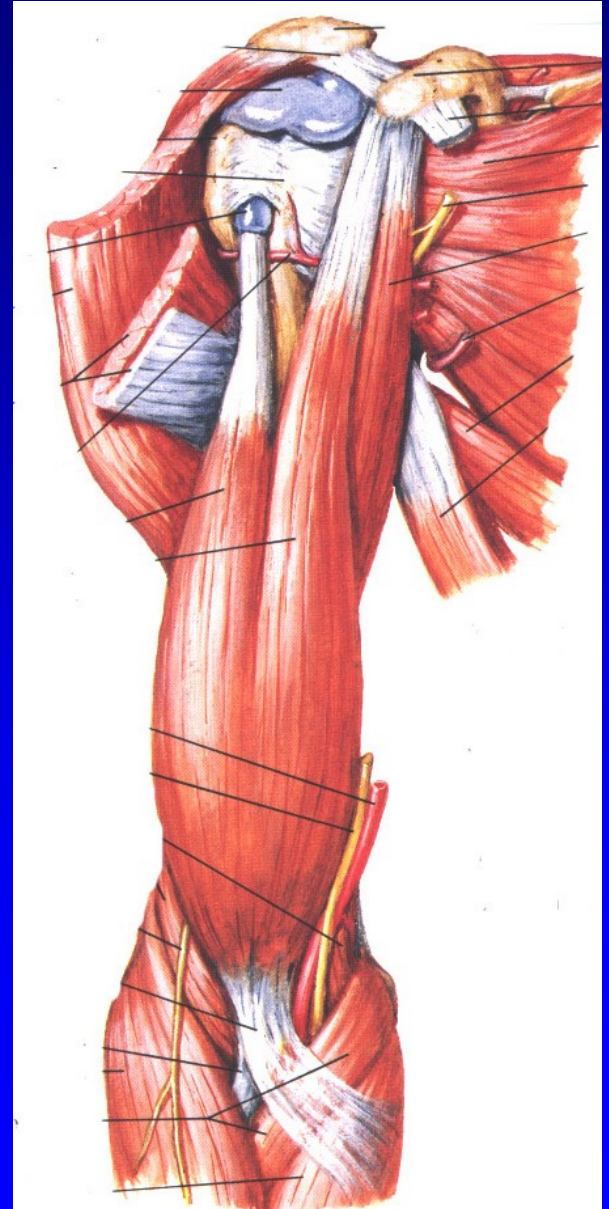
Resisted flexion and supination
of the elbow

Therapy:

Corticosteroids locally

Rest, sling

NSAID



Rupture of long head of biceps

Therapy:

Rest, sling

NSAID

Surgery – up to 40 years

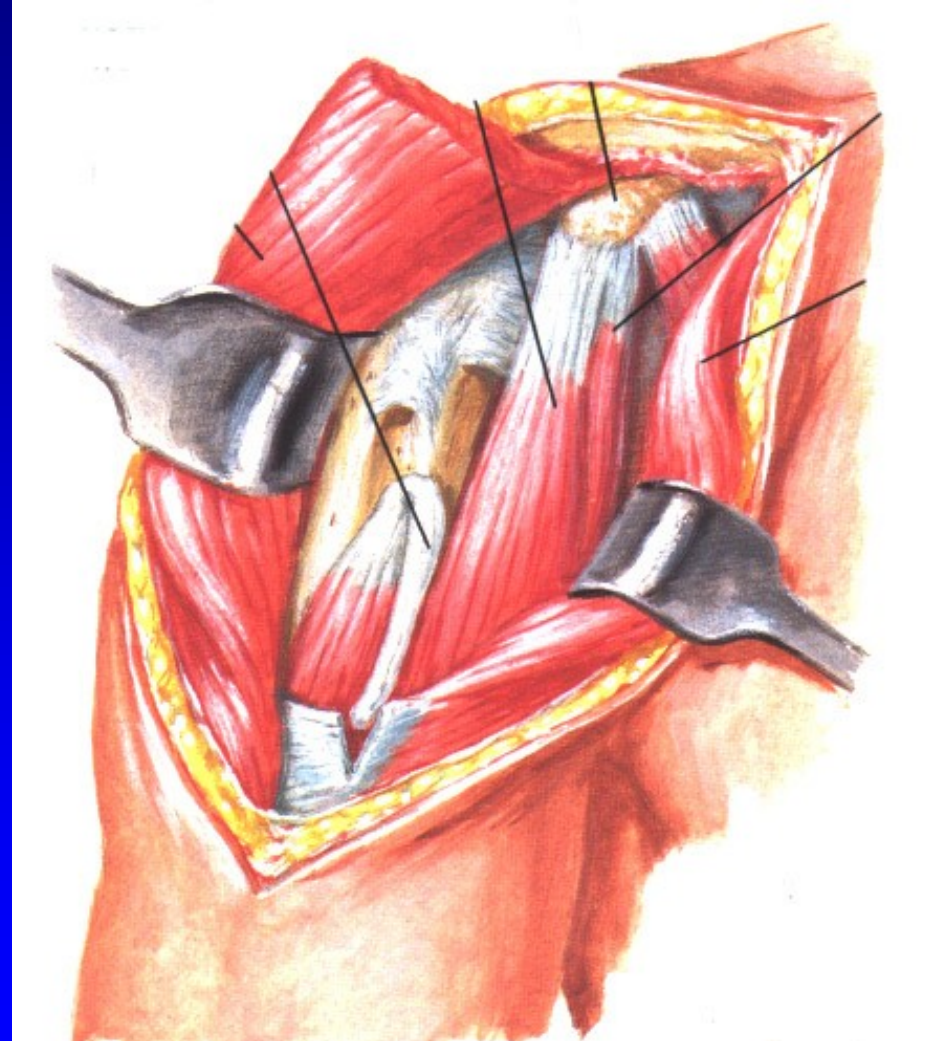
Conservative- over 40 years

Surgery:

key hole fixation to the humerus

Suture to the short head

of biceps

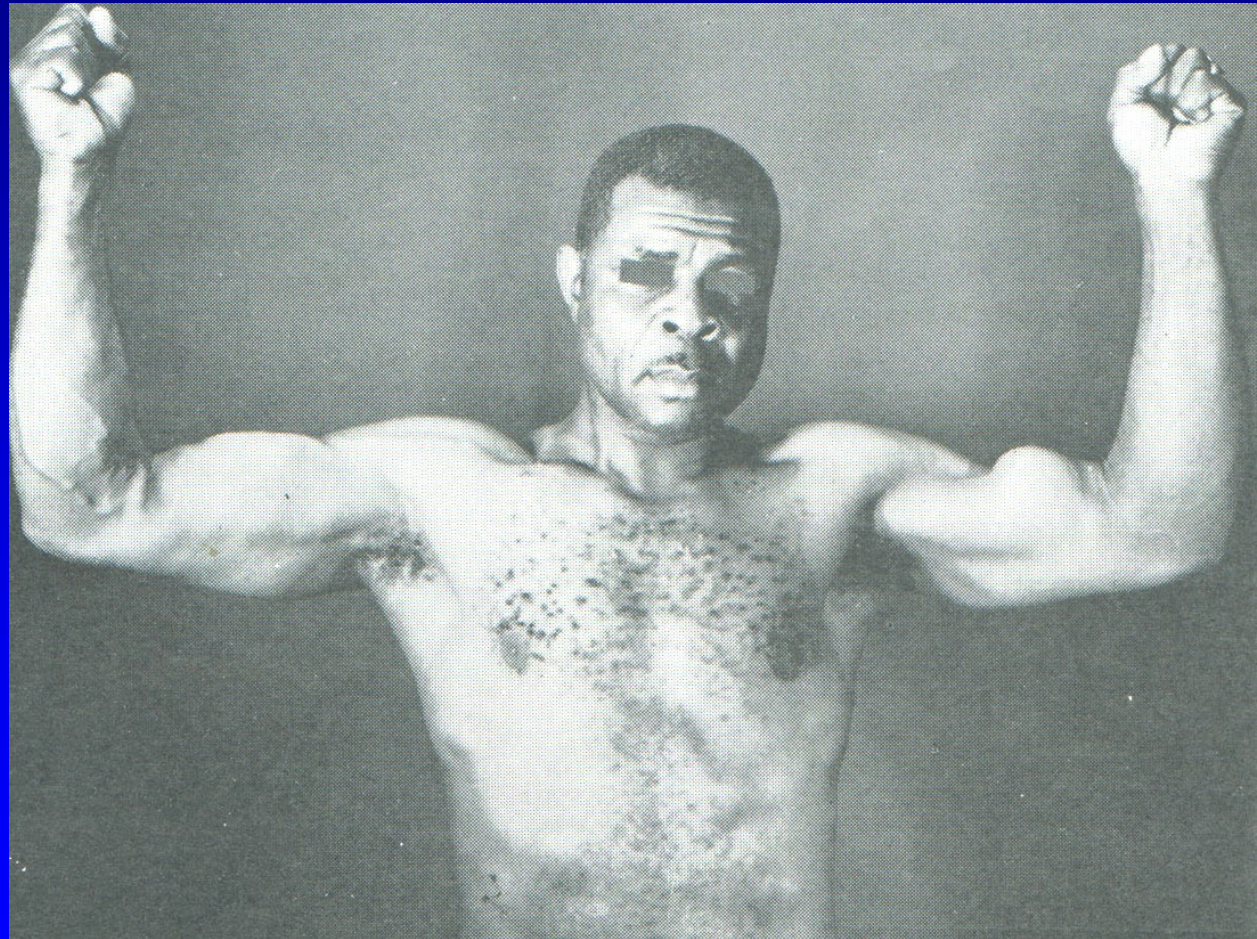


Rupture of long head of biceps

Tenderness

Distalisation of
muscle belly

Diminished strength



Subacromialis bursitis

Inflammation

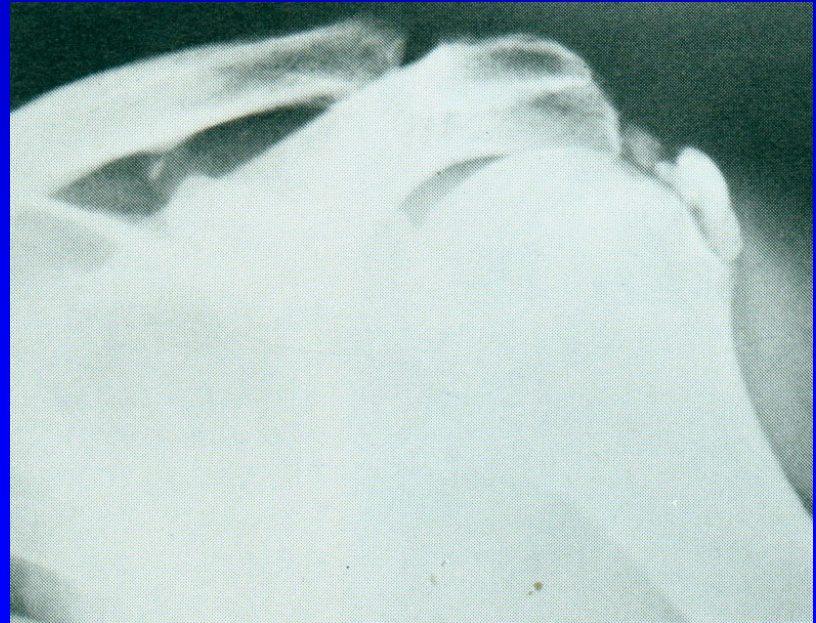
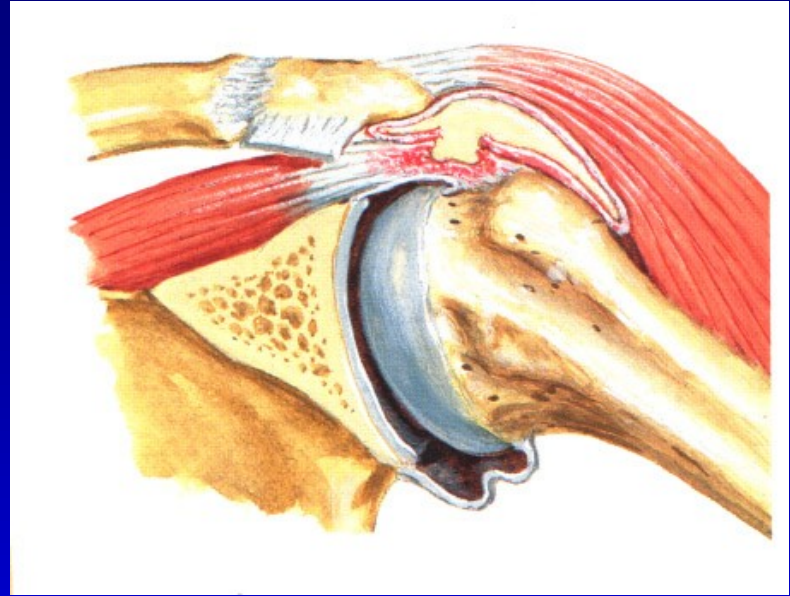
White fluid

Severe, burning pain

Restricted movements

Tenderness

Calcifications



Subacromial bursitis

Conservative treatment:

Rest, sling

Lavage with 2 needles

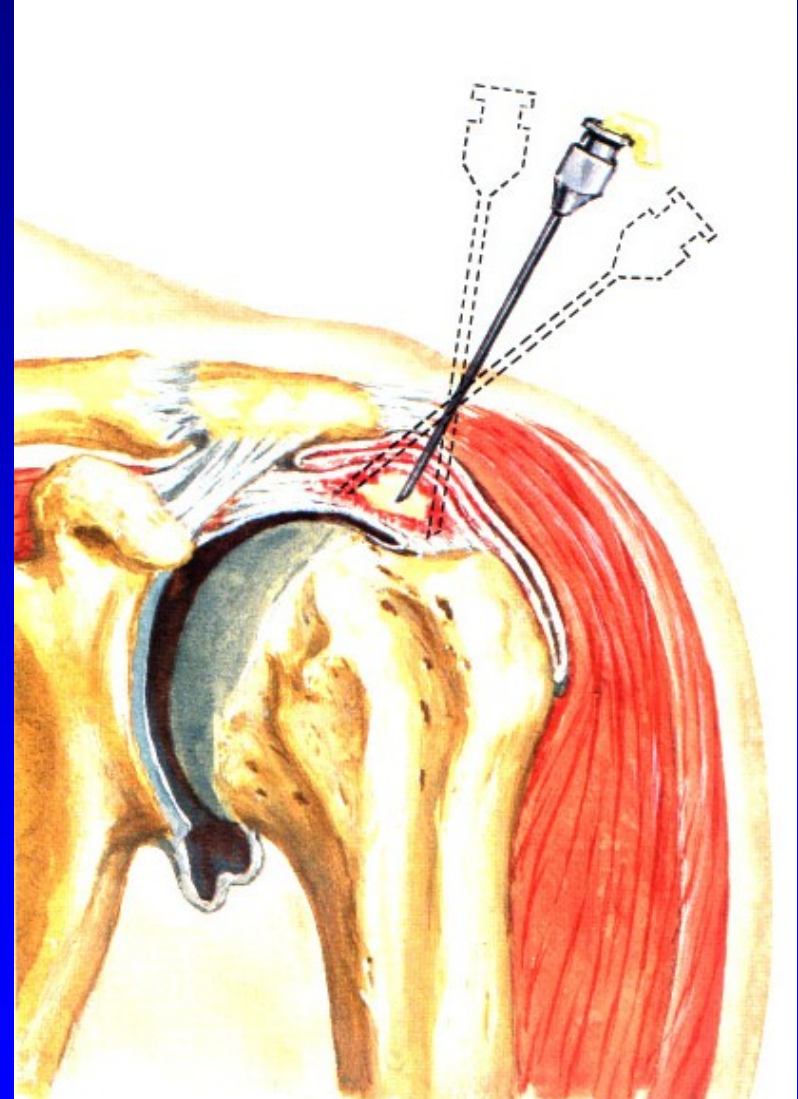
Corticosteroids locally

NSAID

Physiotherapy

Surgery:

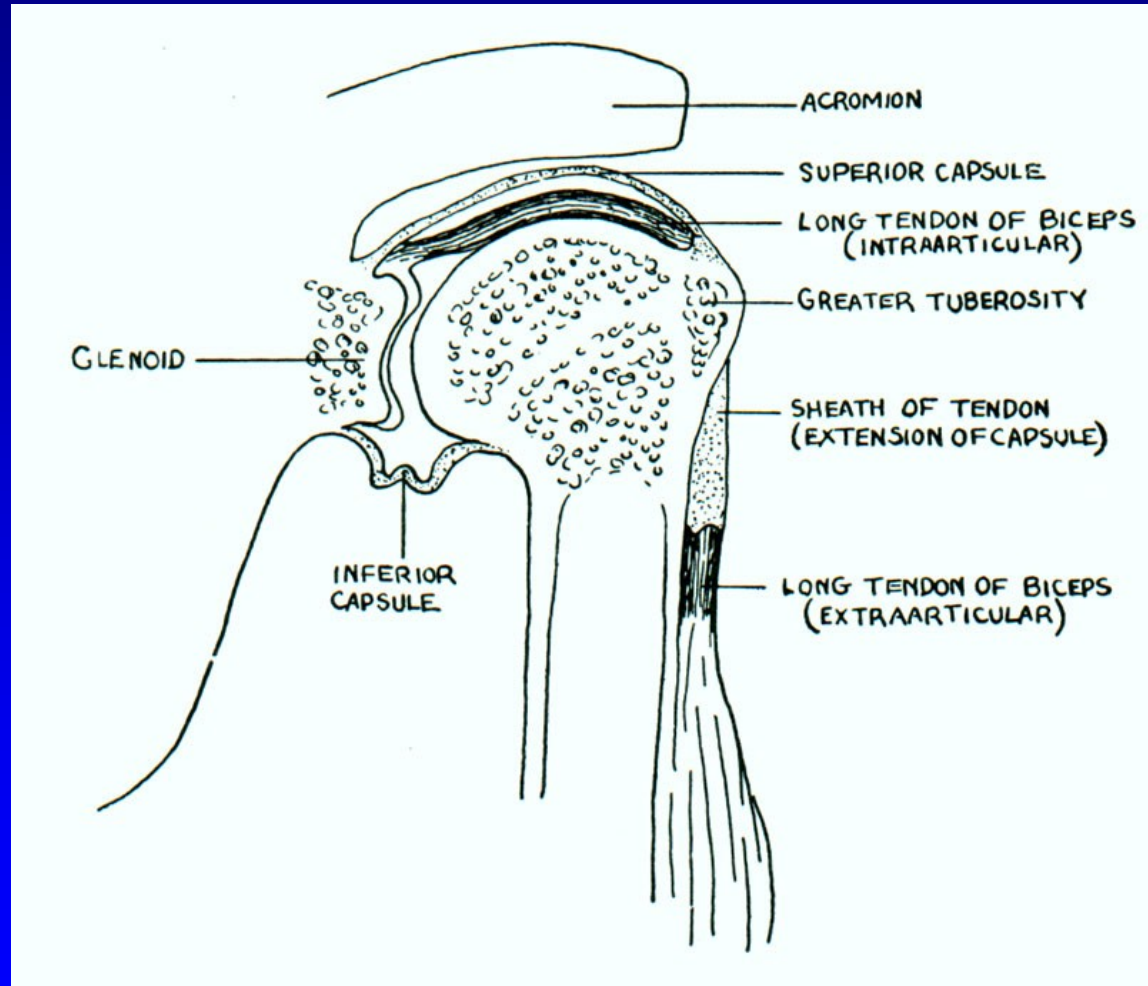
Removal of bursa



Supraspinatus tendinitis

Tenderness over greater tuberosity
Limited movements

Therapy:
Rest, NSAID
Corticosteroids
Physiotherapy



Rotator cuff

Rotator cuff:

m. supraspinatus

m. infraspinatus

m. teres minor

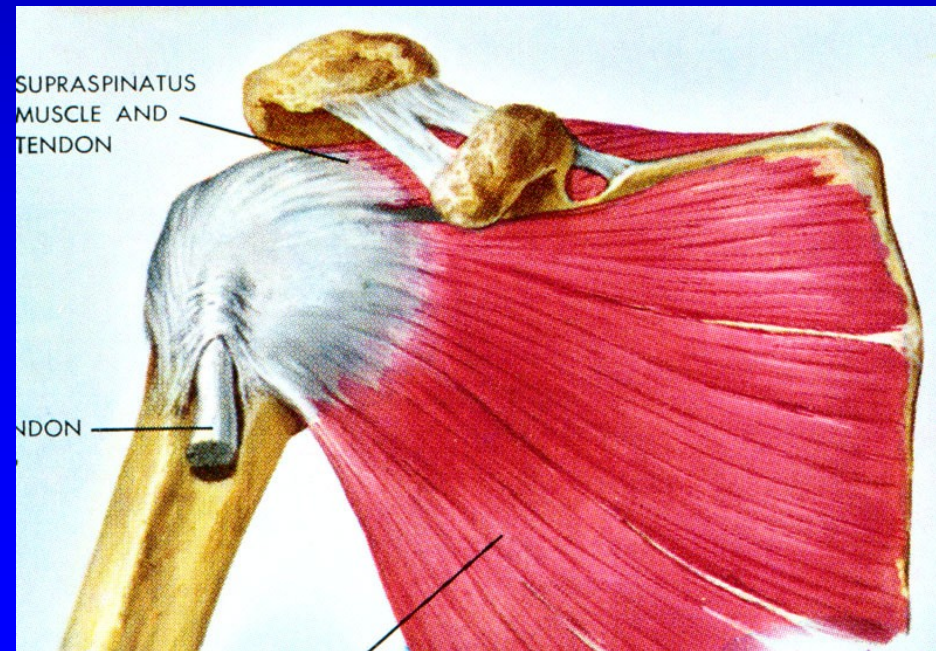
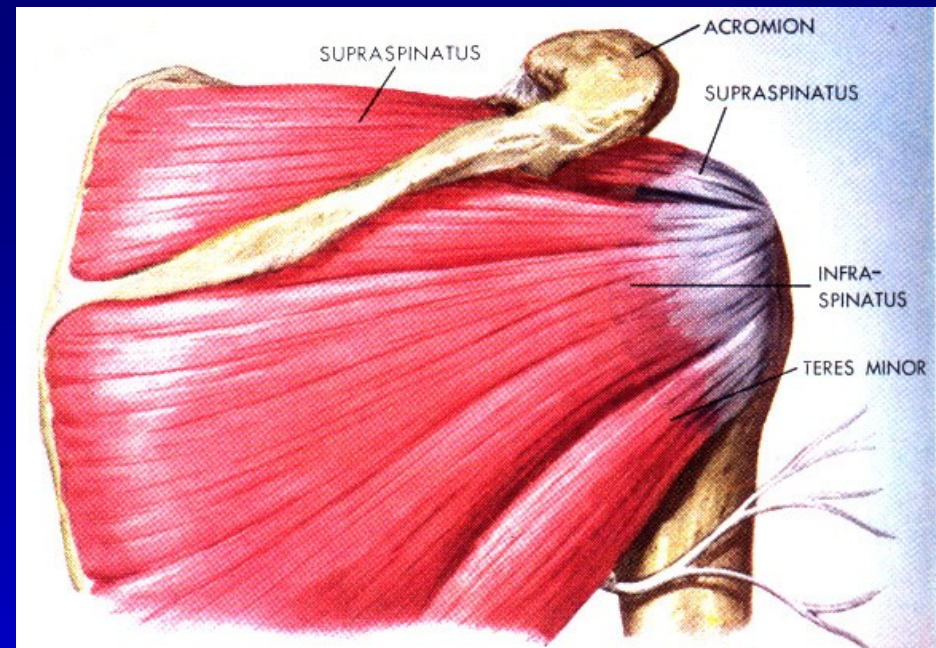
m. subscapularis

Function:

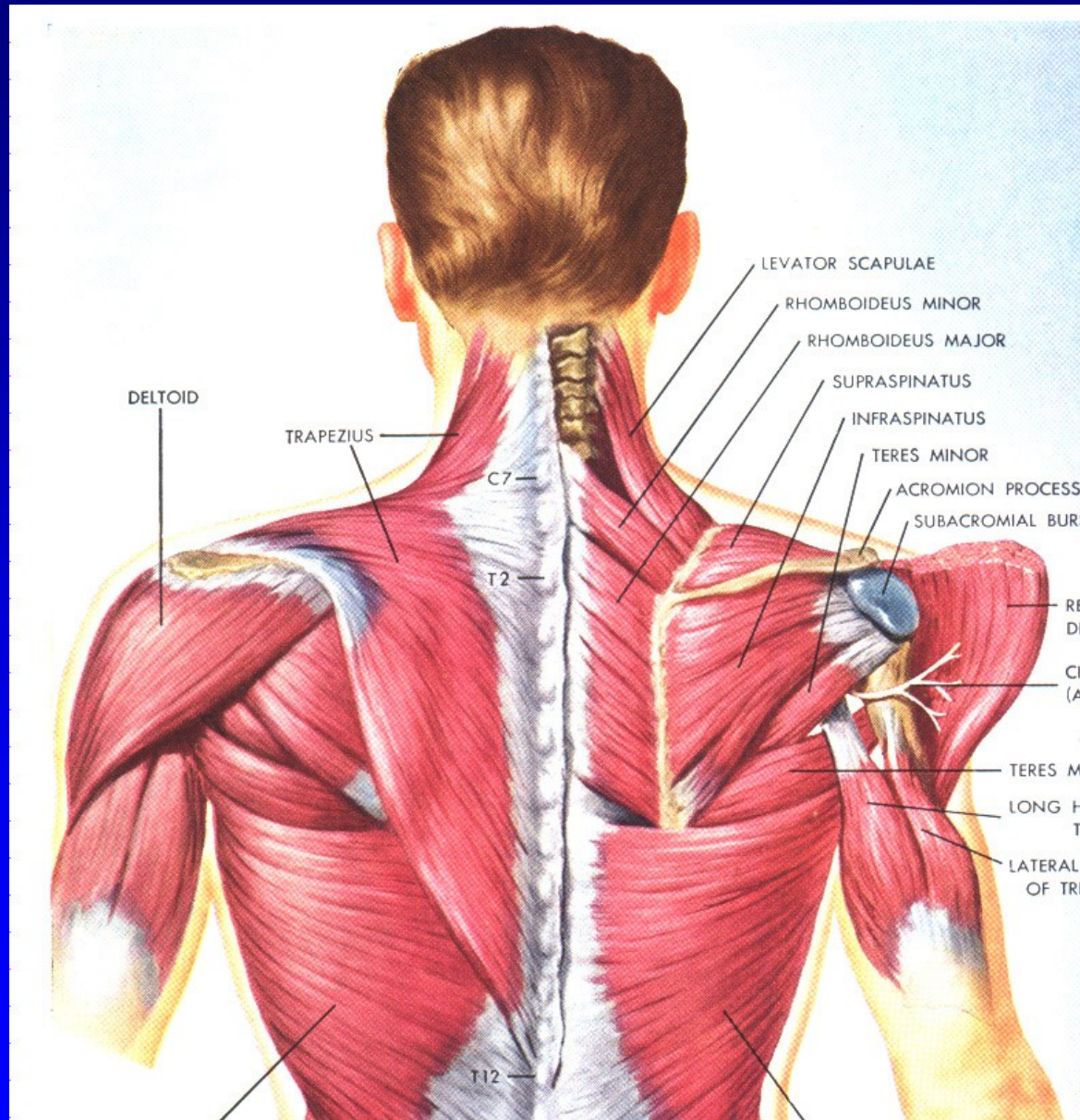
First 30° of abduction

Pressure of the humeral head
into glenoid cavity

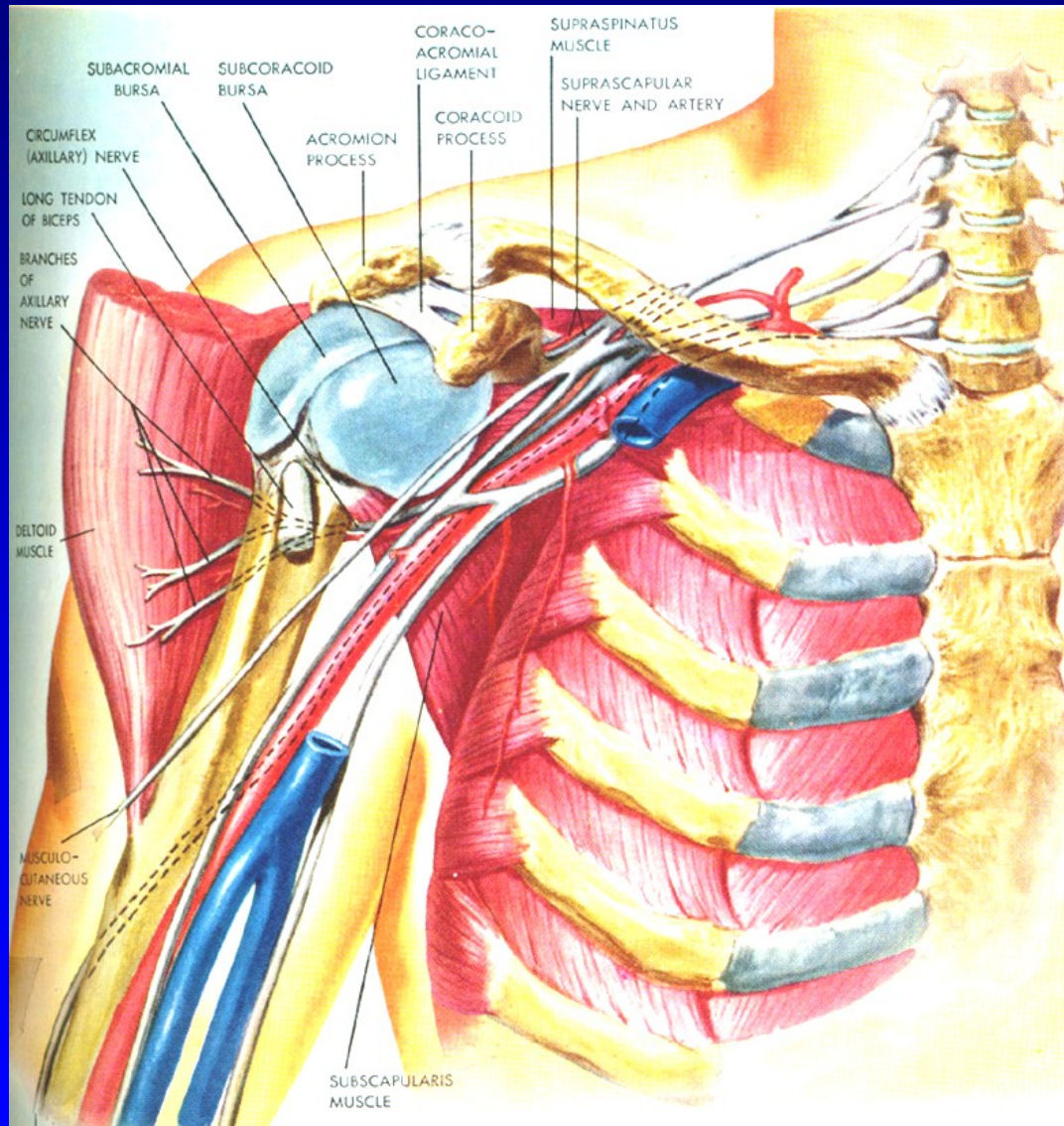
Depressor of the humeral
head



Anatomy of the shoulder



Anatomy of the shoulder



Rupture of rotator cuff

Partial rupture:

Severe pain

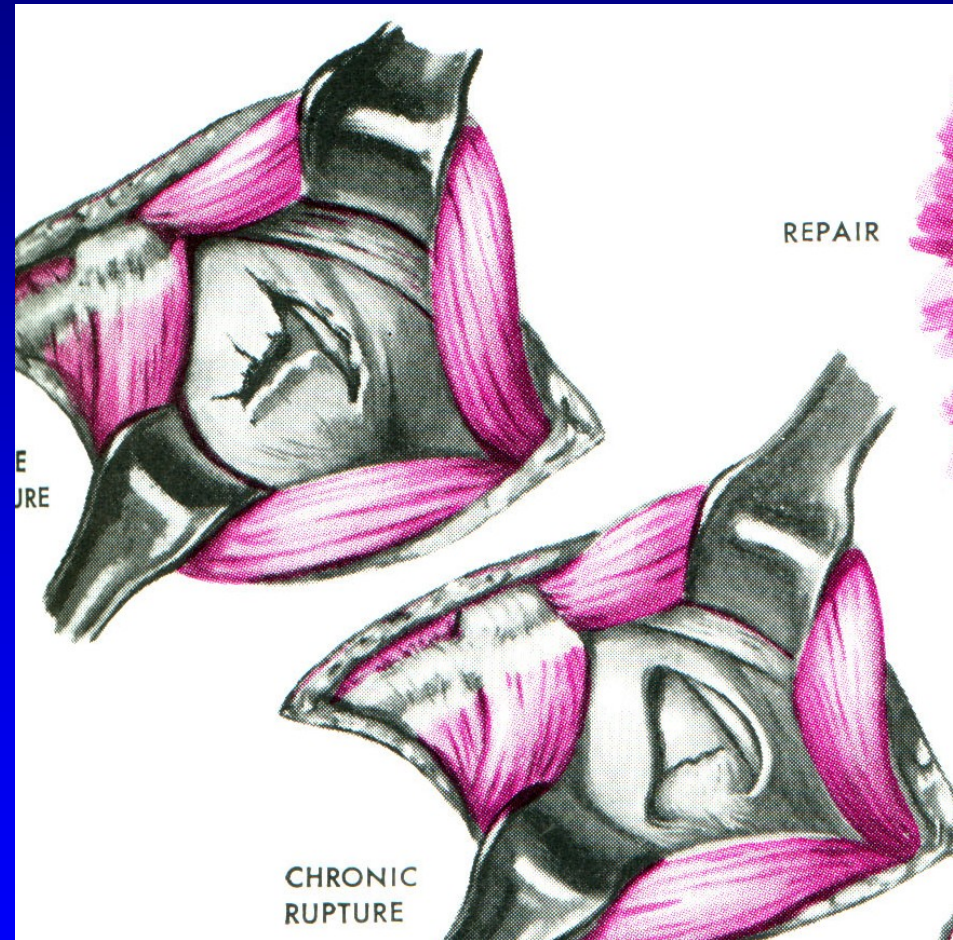
Painful arc

Painful abduction

Keeps the arm in position
of adjusted abduction

Ultrasonography

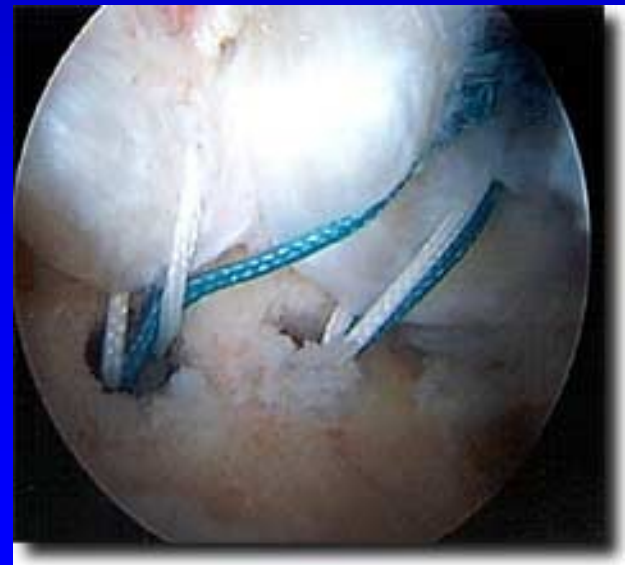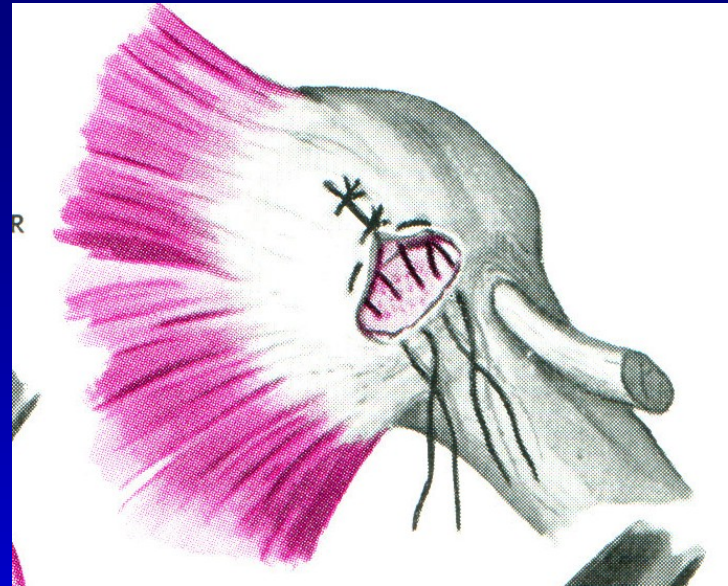Management: conservative



Rupture of rotator cuff

Complete rupture:
No active abduction
Lifting of the shoulder

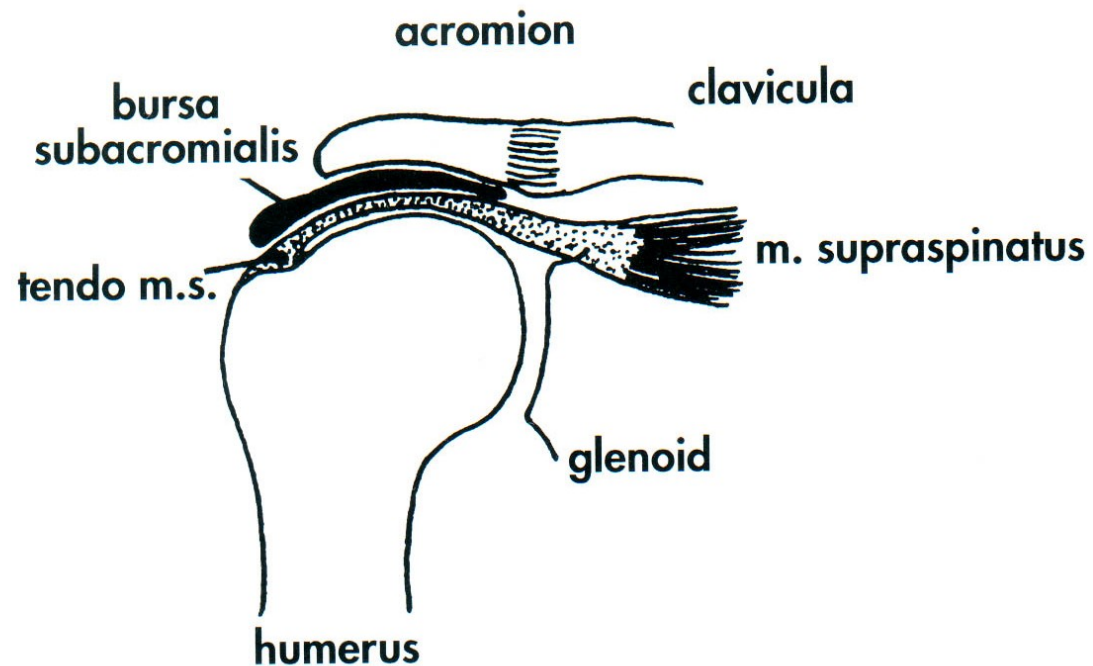
Managemet:
suture: ASC, open surgery
- attachment to greater
tuberosity



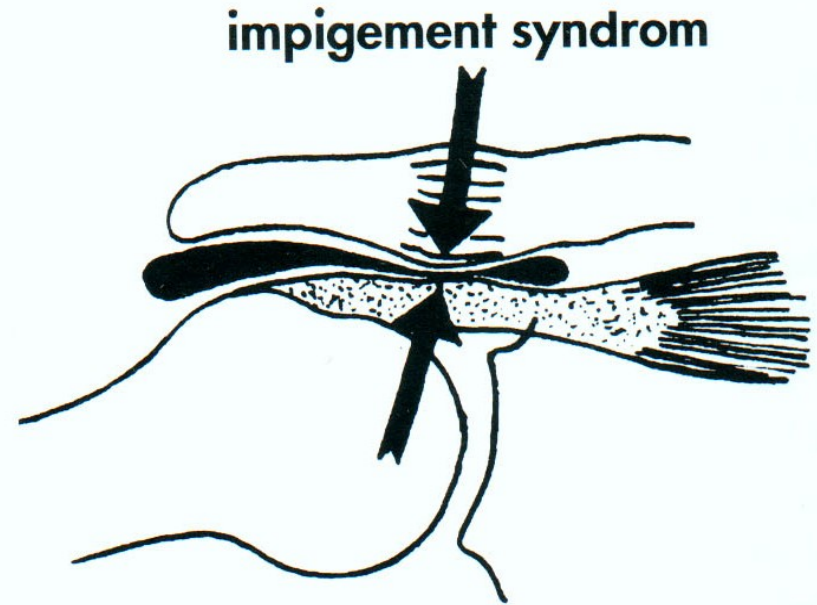
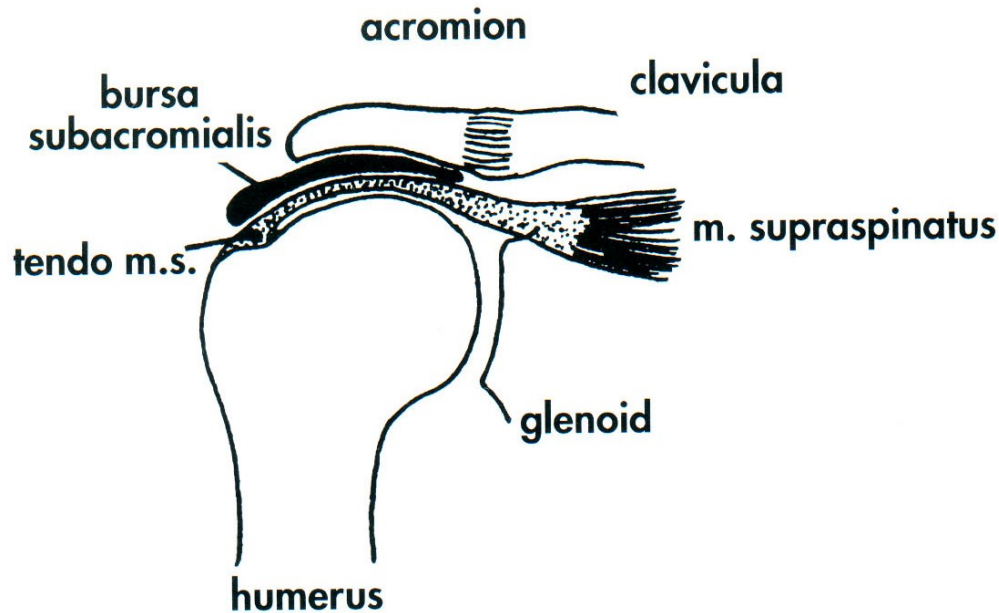
Impingement syndrom

Greater tuberosity impinges
to distal surface
of acromion and
coracoacromial ligament

Narrowing of subacromial
space

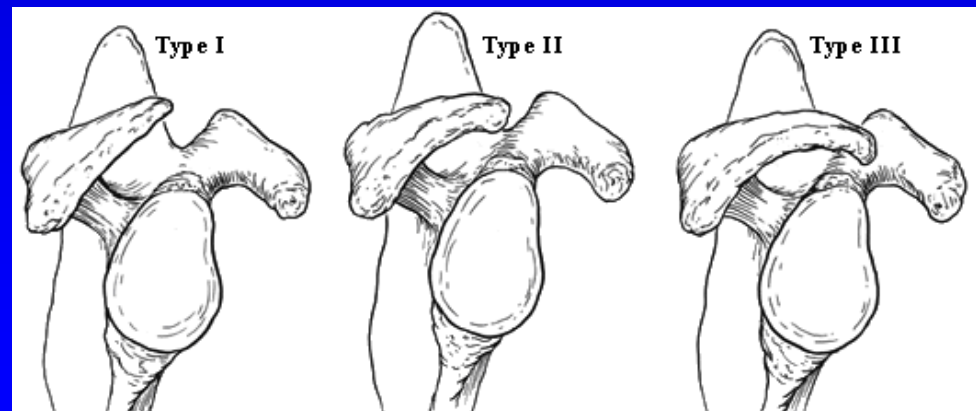


Impingement syndrom



Causes

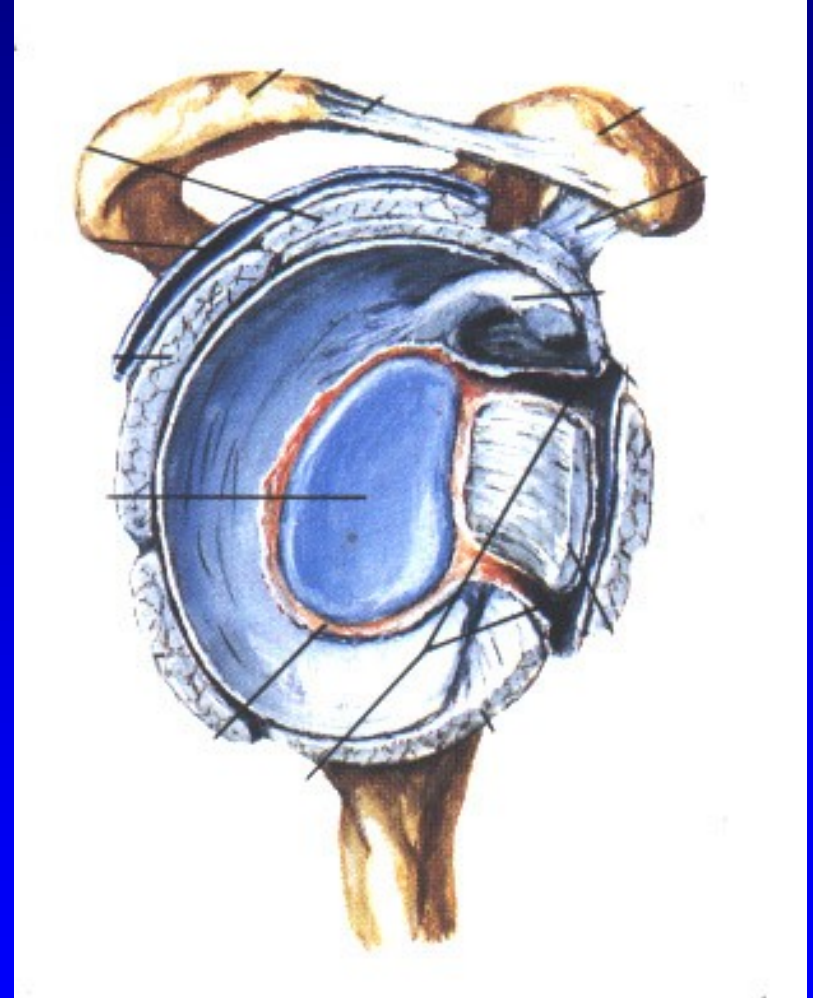
- acromion spur
- Change of acromion
- Distal osteophytes of AC
- Prominence of tuberculum maius



Impingement syndrom

Stages:

1. Swelling, hemorrhage of supraspinatus
2. Fibrosis, tendinitis, bursitis
degenerative changes of cuff
3. Rupture of rotator cuff
and long biceps tendon



Impingement syndrom

Symptoms:

Painful arc

Impingement sign

Impingement test

Jobe test

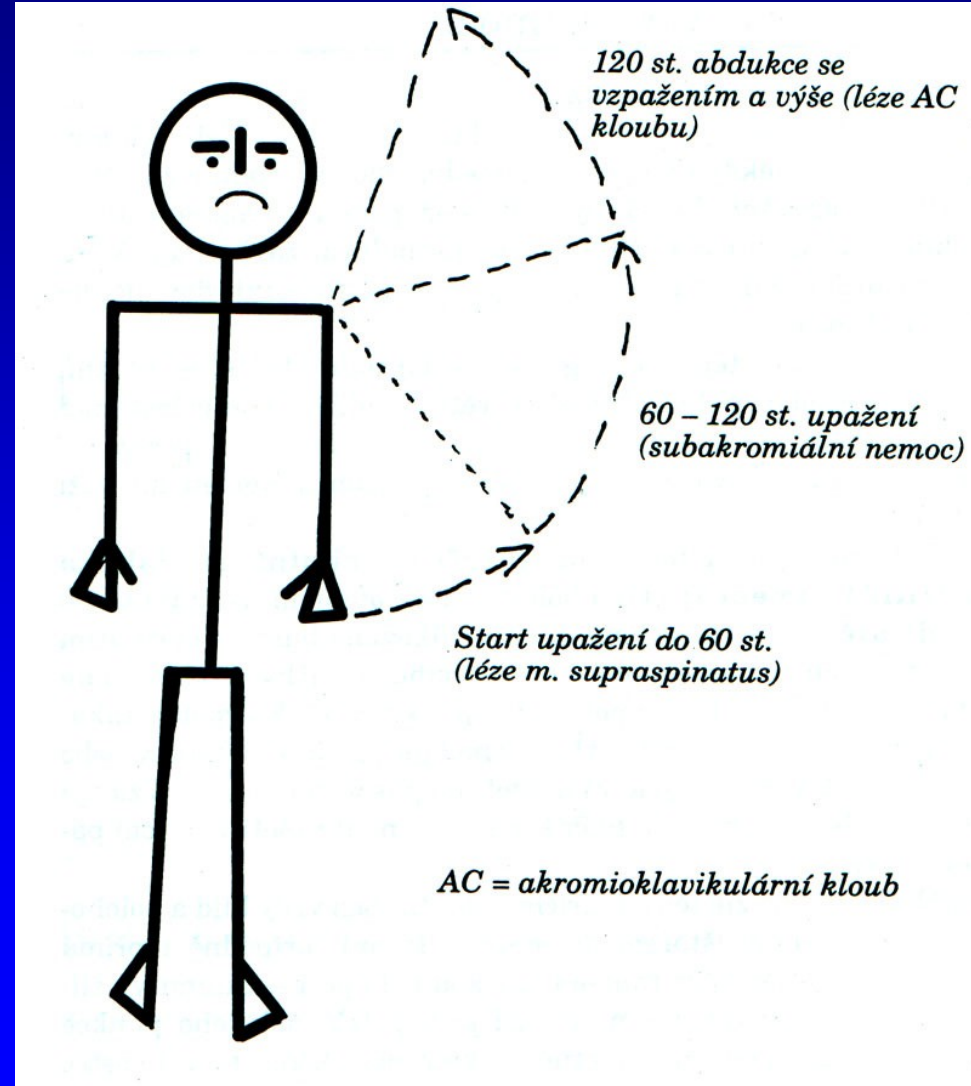
X-ray:

Narrowed subacromial space

Y view- outlet view

Arthrography

Ultrasonography



Impingement syndrom

Therapy:

1. stage: conservative

Rest, NSAID,

Physiotherapy,

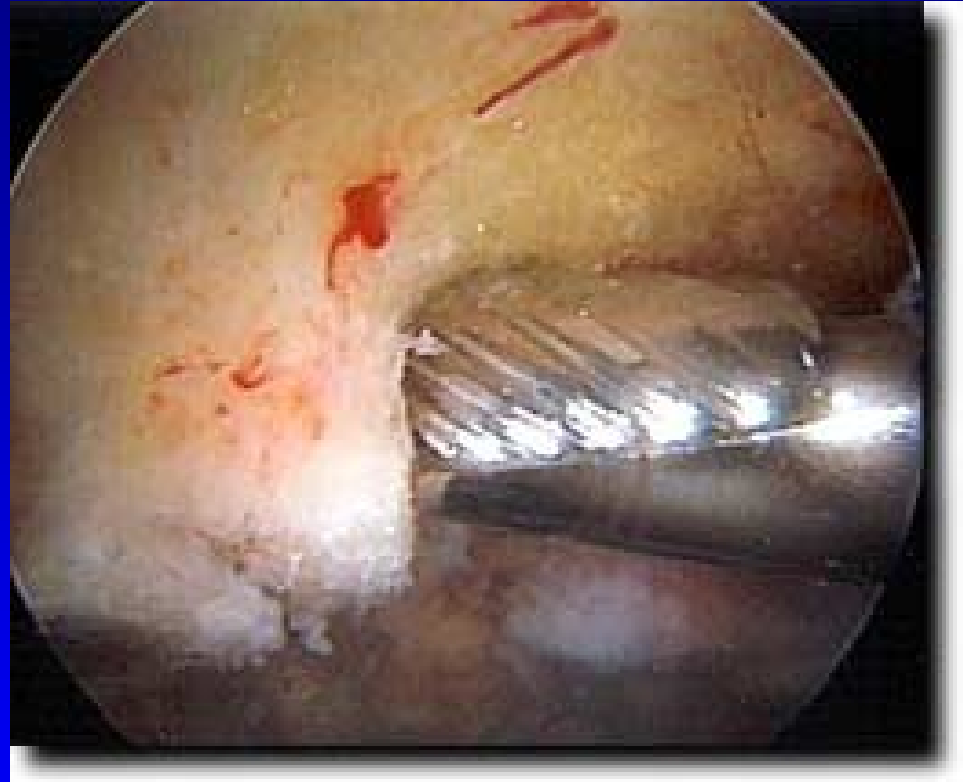
Local corticosteroids

2. stage: the same

+ bursectomy, ASAD

3. stage: ASAD

Subacromial decompression



Frozen shoulder- capsulitis adhesiva

Progressive limitation
of movements

Pain

No motivation for movement

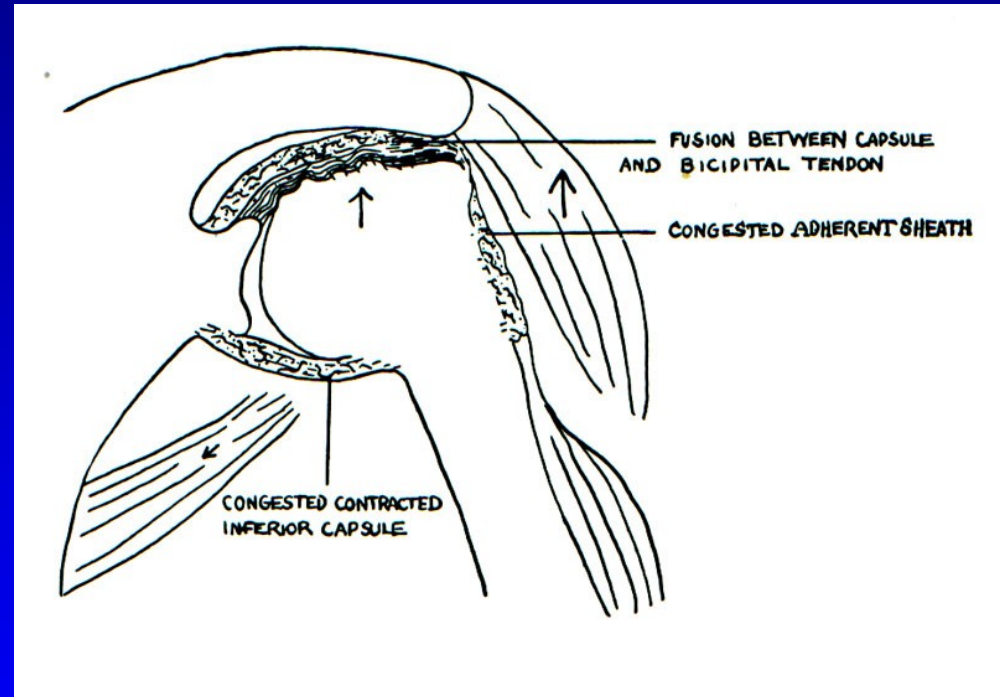
Shrinkage of capsule

Adhesions in distal recessus

Tightening of soft tissue

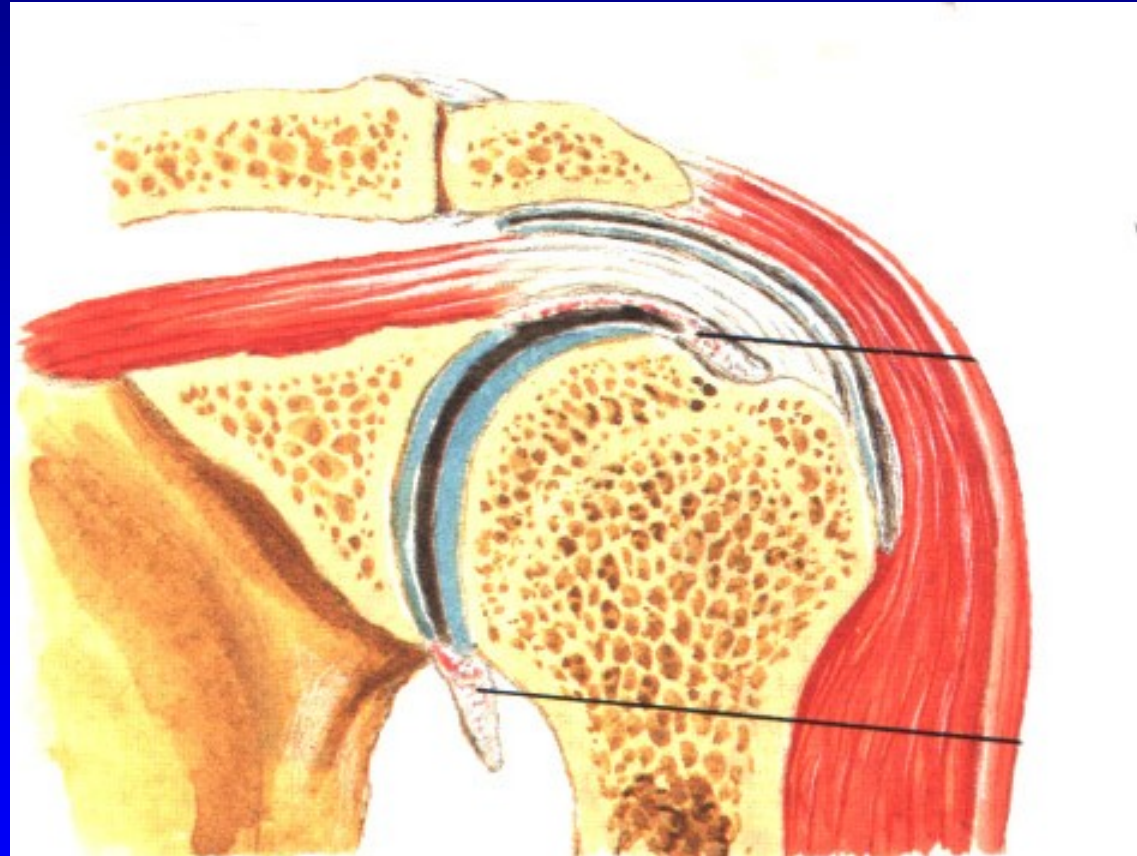
Muscle spasm

Low capacity of joint space



The cause

All conditions limiting
joint movements:
Impingement syndrom
Arthrosis of AC joint
Posttraumatic conditions
Inflammations
Thoracic outlet syndrom
Tumors of the lungs
Disorders of pleura
Cardiac disorders



Frozen shoulder

Management:

Long lasting period

Heat

Passive movements

Positioning

Active movements

Physiotherapy

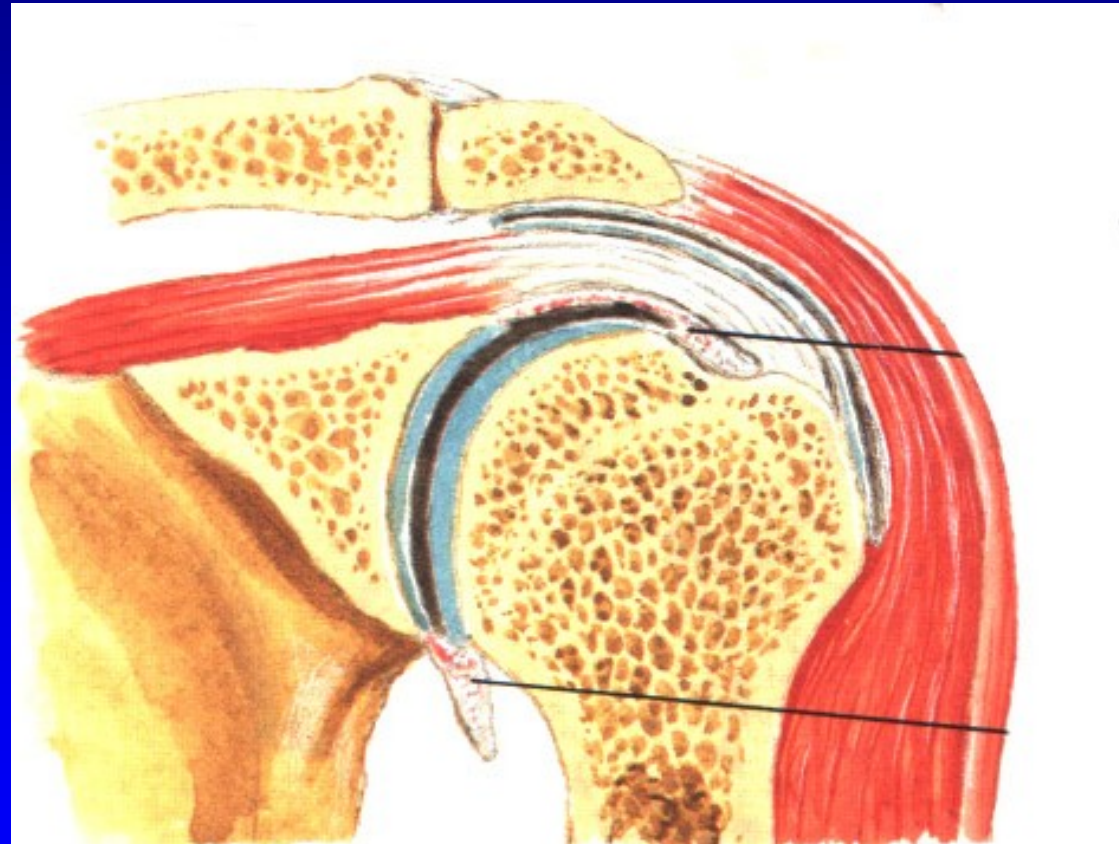
NSAID

Local corticosteroids

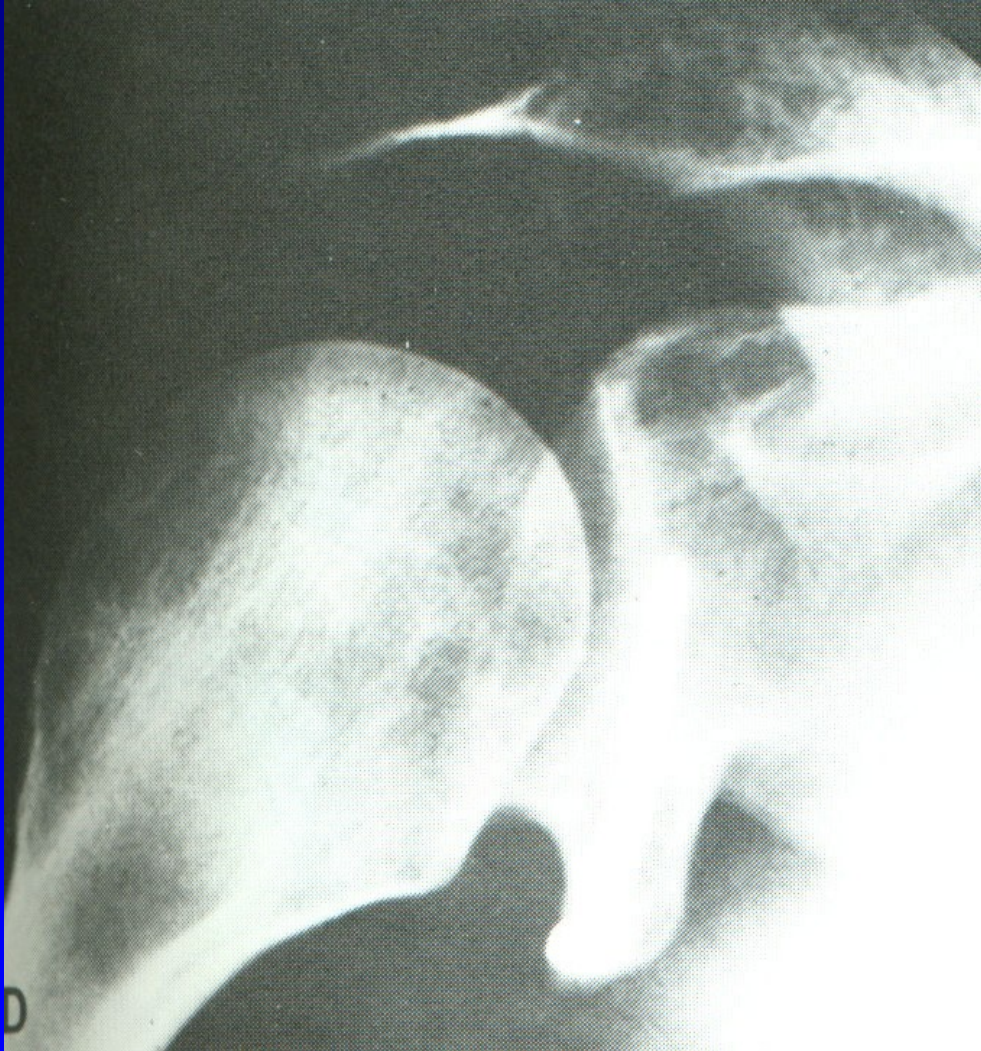ASC- decompression

Redressement force

Removal of adhesions



Glenohumeral osteoarthritis - omarthrosis

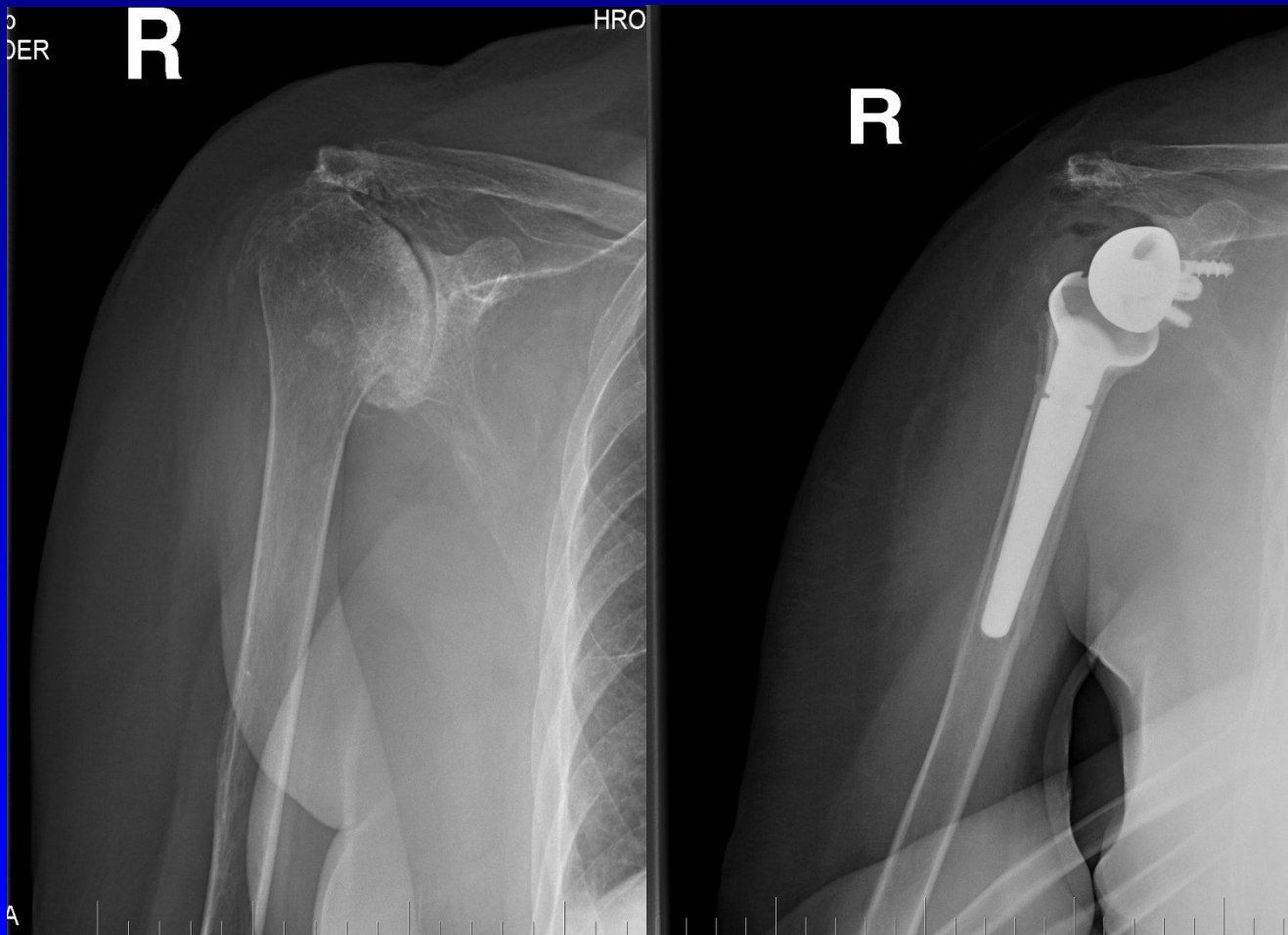


Therapy:

Conservative

Total shoulder replacement

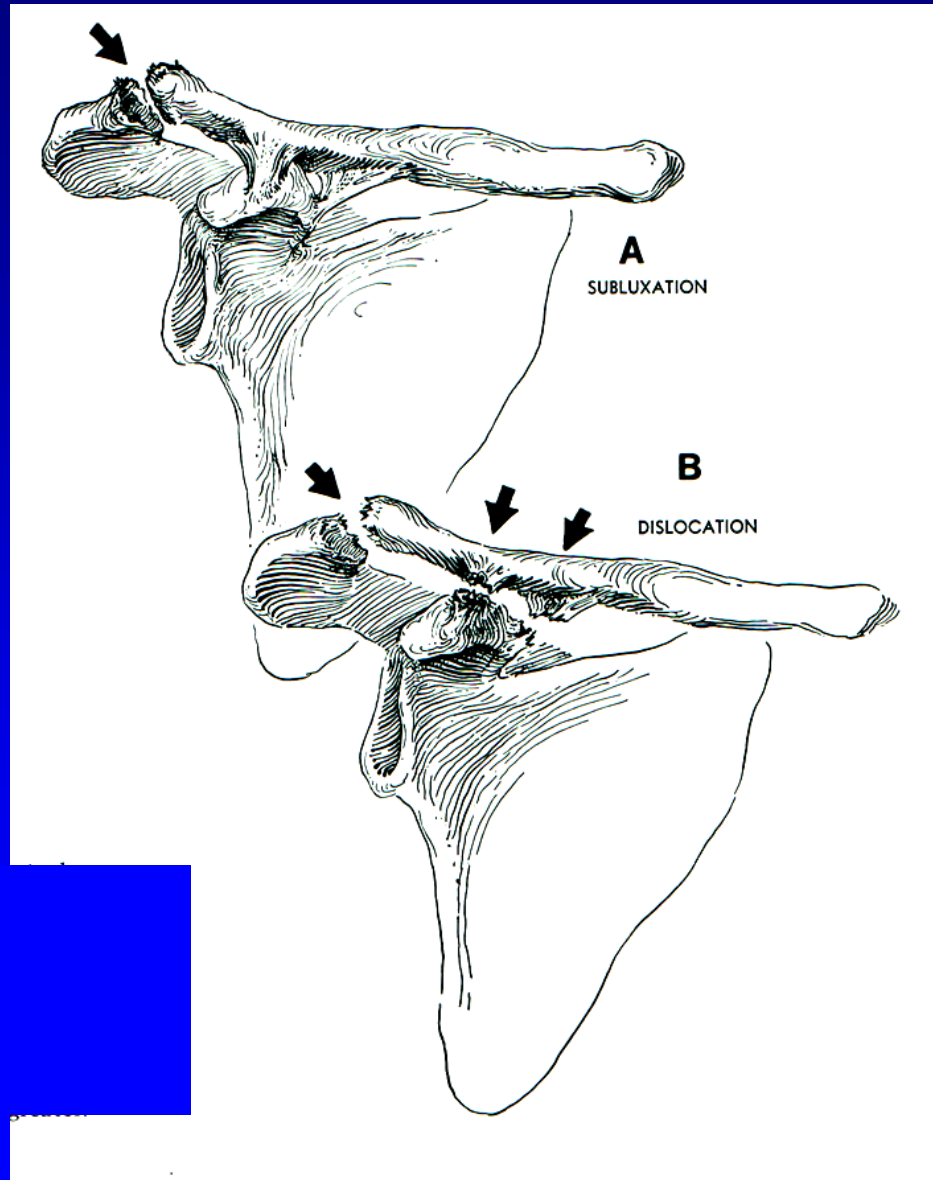
Rotator arthropathy



Reverse total shoulder arthroplasty

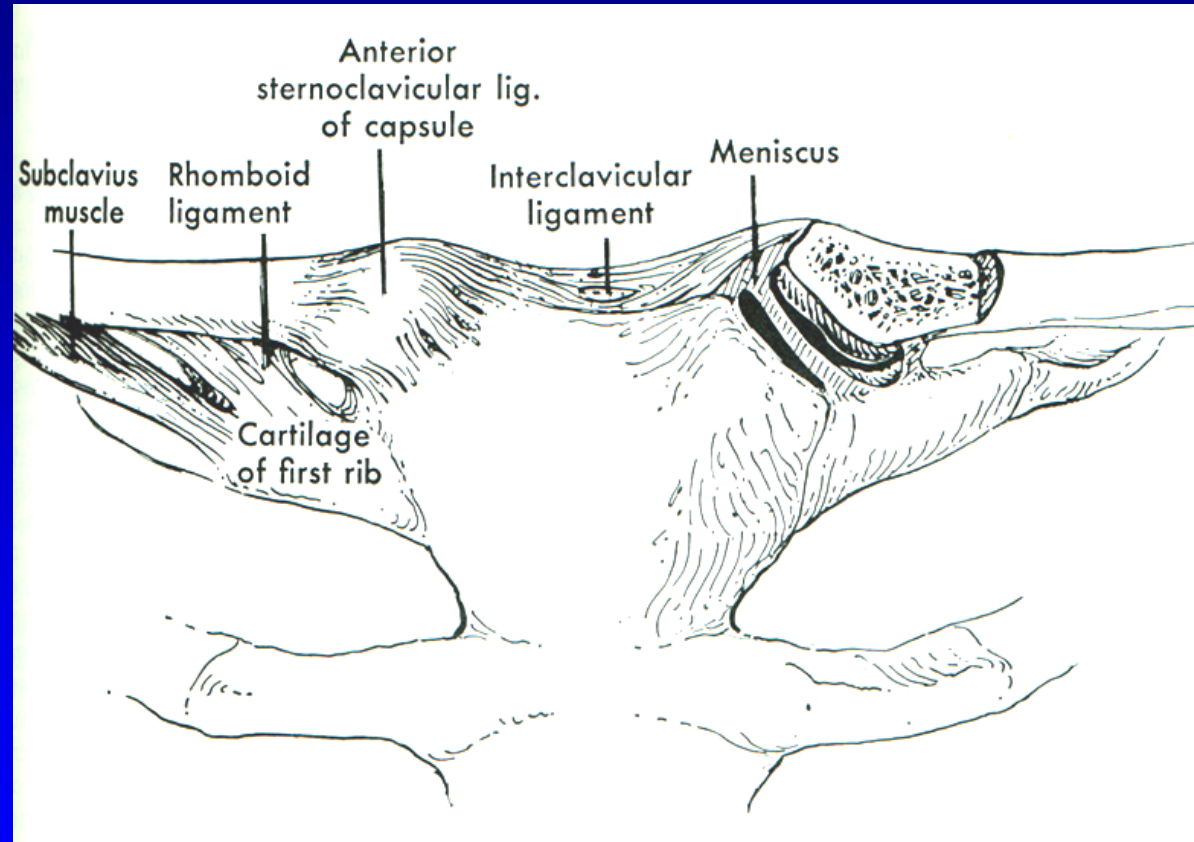
Disorders of acromioclavicular joint

Synovitis
O.A.
Sprain
Subluxation
Dislocations



Disorders of sternoclavicular joint

Synovitis
O.A.
Sprain
Subluxation
Dislocations
Chronic subluxation



Referred pain to the shoulder

Cervical spine

Thoracic outlet syndrom

Cardiac diseases

Lung and pleura disorders

Herpes zoster neuralgia