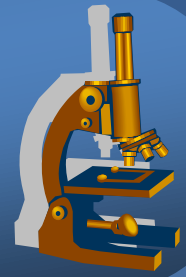


Systemic pathology



Nervous system



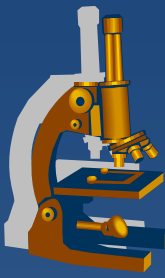
Brain swelling, ischemia

Brain swelling



- × generalised increase in the volume of brain (blood, water, ions) → clinical signs related to raised intracranial pressure / intracranial shift / herniation
- × **diffuse** (vasodilatation, oedema – vasogenic, cytotoxic, interstitial)
- × **focal** (space-occupying lesions – inflammation, tumor, trauma, vascular lesion)
- × **herniations:**
 - ⇒ *supracallosal – interhemispheric under falx cerebri*
 - ⇒ *transtentorial – temporal (3rd nerve, secondary brainstem haemorrhage)*
 - ⇒ *tonsillar – foramen magnum, vital centres compressed*

Brain swelling



xgross:

⇒ *flattened gyri, narrow sulci, slit-like ventricles*

xmicro:

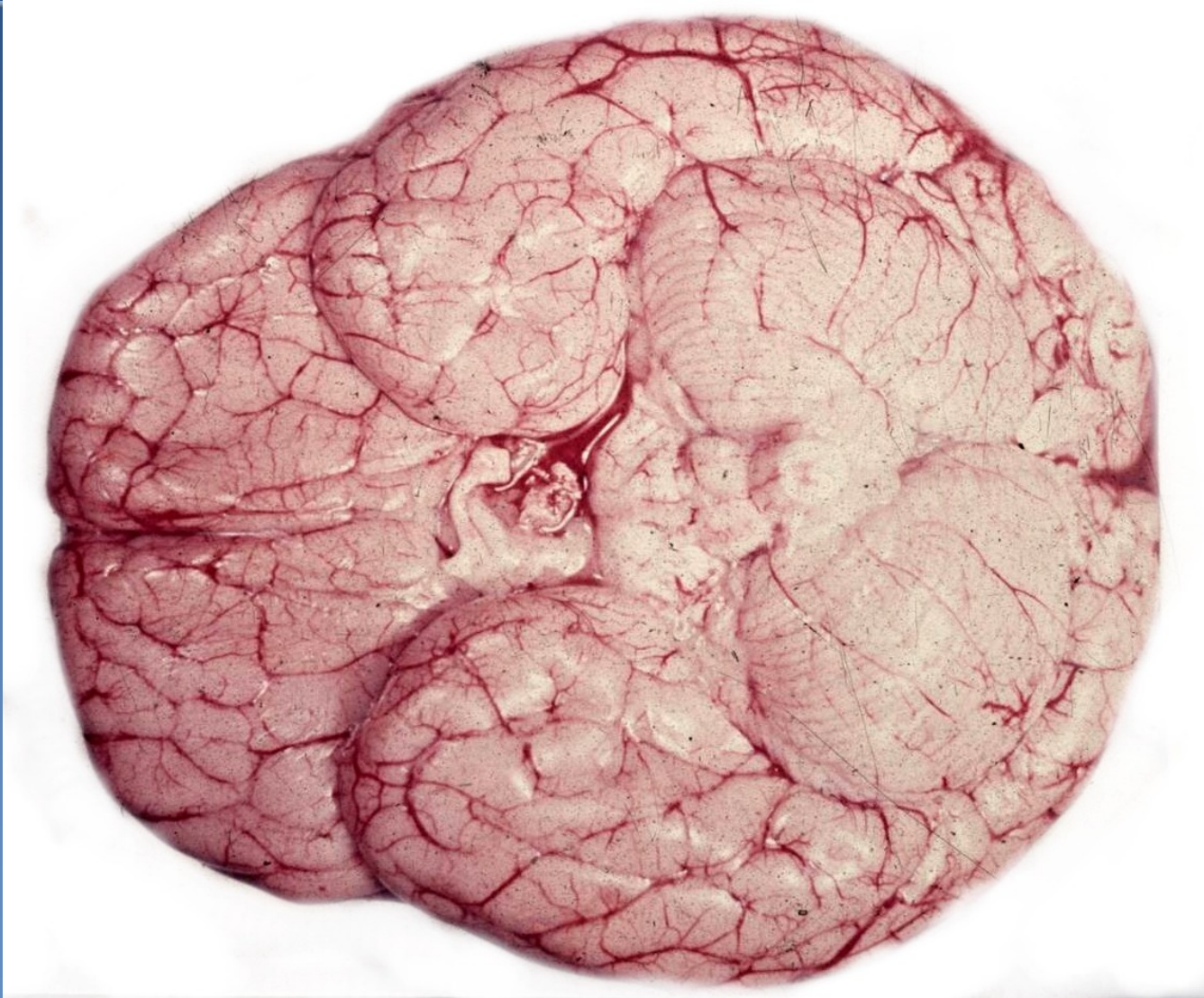⇒ *neuropil vacuolation*

⇒ *swelling of the cytoplasm and processes of astrocytes*

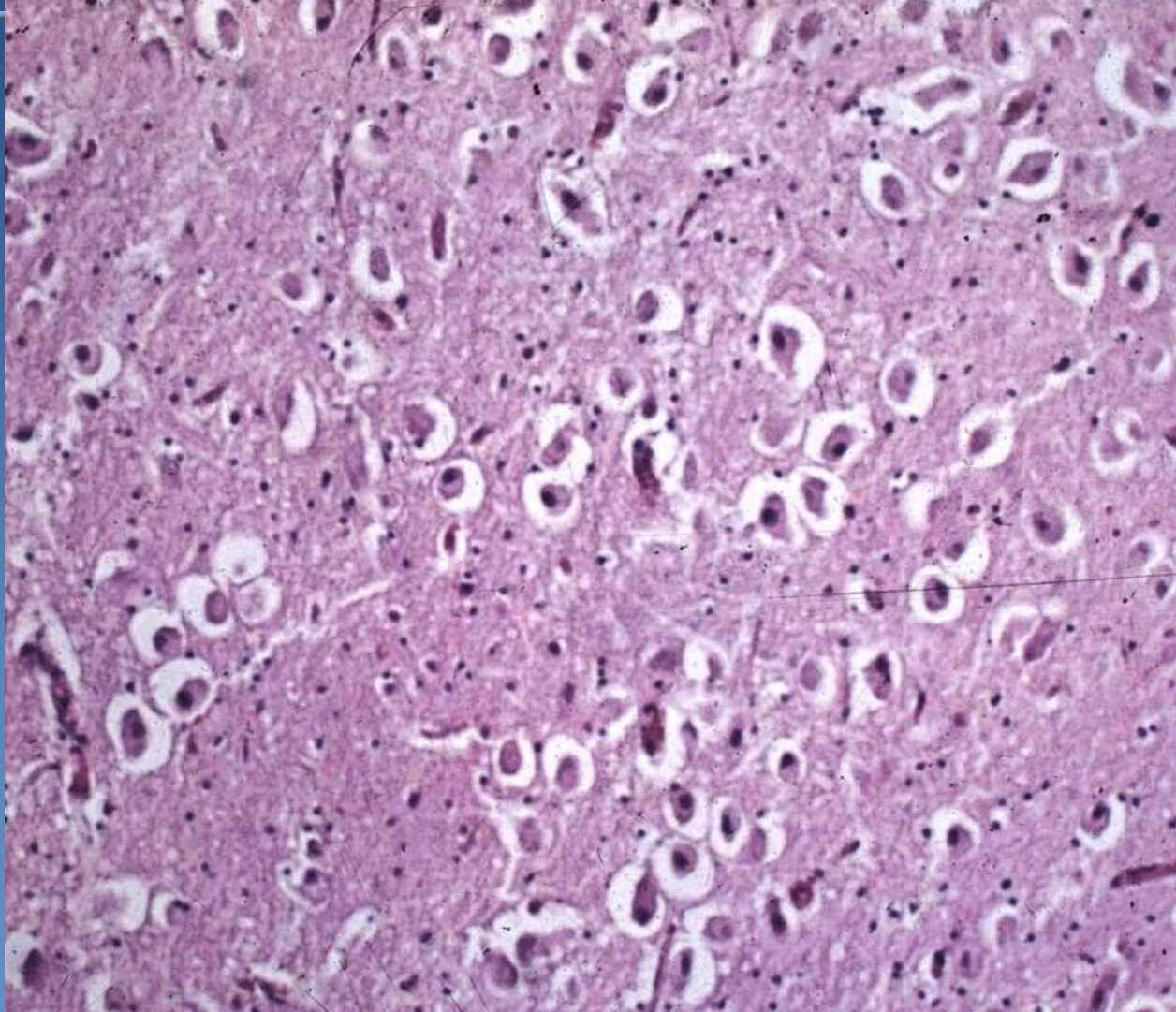
⇒ *perivascular optically empty spaces*

⇒ *myelin less vividly colored*

Diffuse brain swelling



Diffuse brain swelling



Brain swelling - pathogenesis



× main types:

⇒ *vasogenic*

- due to increased cerebral vascular permeability (esp. by neoangiogenesis)
- adjacent to tumors, abscesses, haemorrhage, ischemia

⇒ *cytotoxic*

- due to hypoxia / ischemia , toxic damage – cell membrane injury,
↑intracellular fluid

⇒ *interstitial*

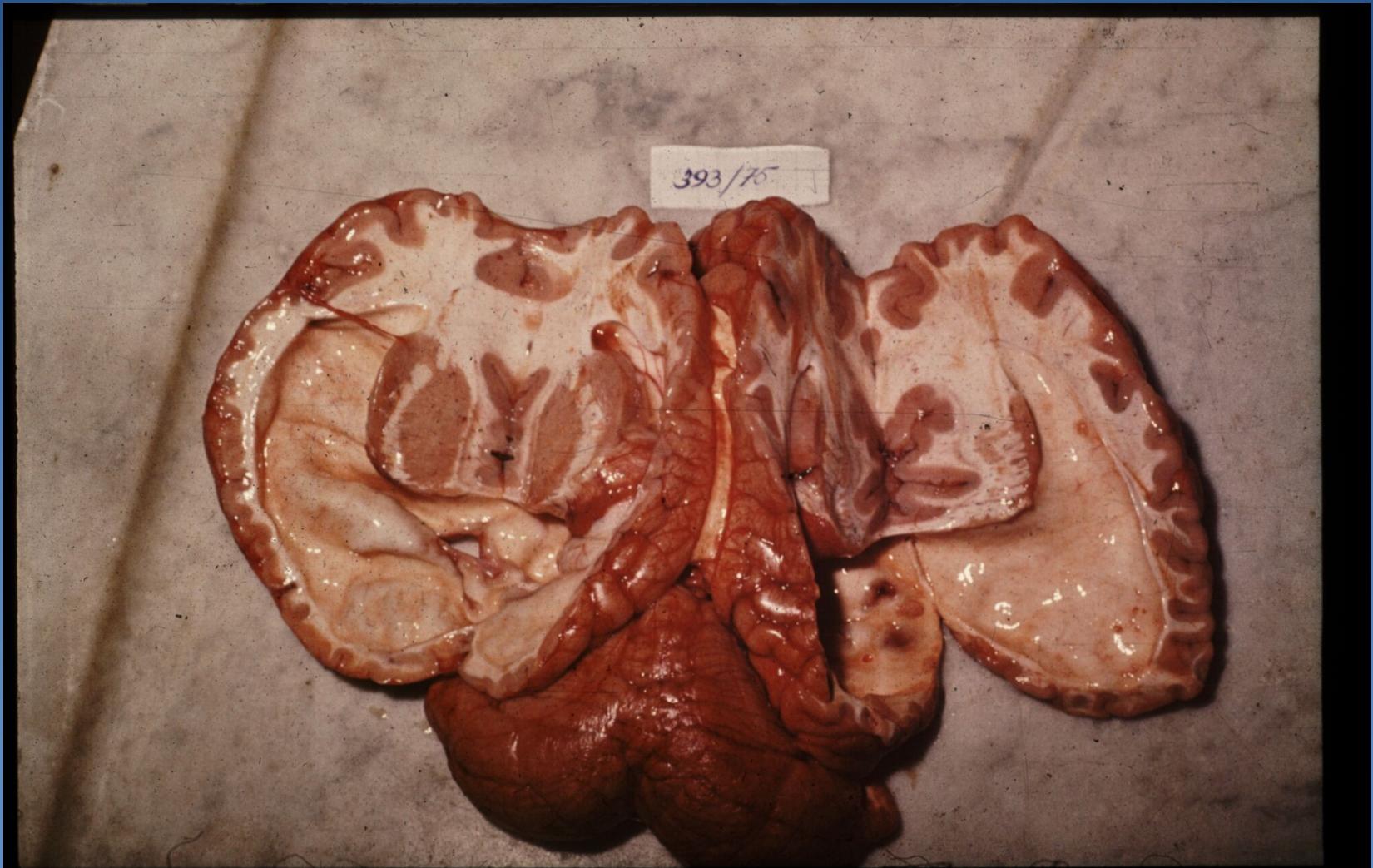- due to damage of ventricular lining (hydrocephalus, CSF diffusion into the white matter)

Hydrocephalus



- ✗ increased amount of CSF, ↑ intracranial pressure
- ✗ infants x older children, adults
- ✗ caused by:
 - ⇒ *increased CSF production*
 - ⇒ *decreased CSF resorption*
 - meningitis, subarachnoid haematoma
 - ⇒ *obstruction to CSF flow*
 - congenital x acquired – trauma, tumors, infection, blood coaguli, cyst
 - ⇒ *hydrocephalus e vacuo (secondary/compensatory)*

Hydrocephalus



Encephalomalatia ***(cerebral infarction)***



- × **colliquative necrosis**
- × **„white“ ischemic x haemorrhagic – blood reflux, venous**

- × **clinically: stroke or transient ischaemic attack – TIA**

- × **pathogenesis:**
 - ⇒ *arterial thrombosis (AS, arteritis, arteriopathy)*
 - ⇒ *thrombembolia*
 - ⇒ *venous thrombosis*
 - ⇒ *diffuse small vessel problems – spasm, vasculitis*
 - ⇒ *external pressure (haematoma)*
 - ⇒ *systemic hypoxia*

- × **the size and distribution depends on:**
 - ⇒ *diameter and localisation of affected artery*
 - ⇒ *closure promptness*
 - ⇒ *possibilities of collateral circulation*

Encephalomalatia



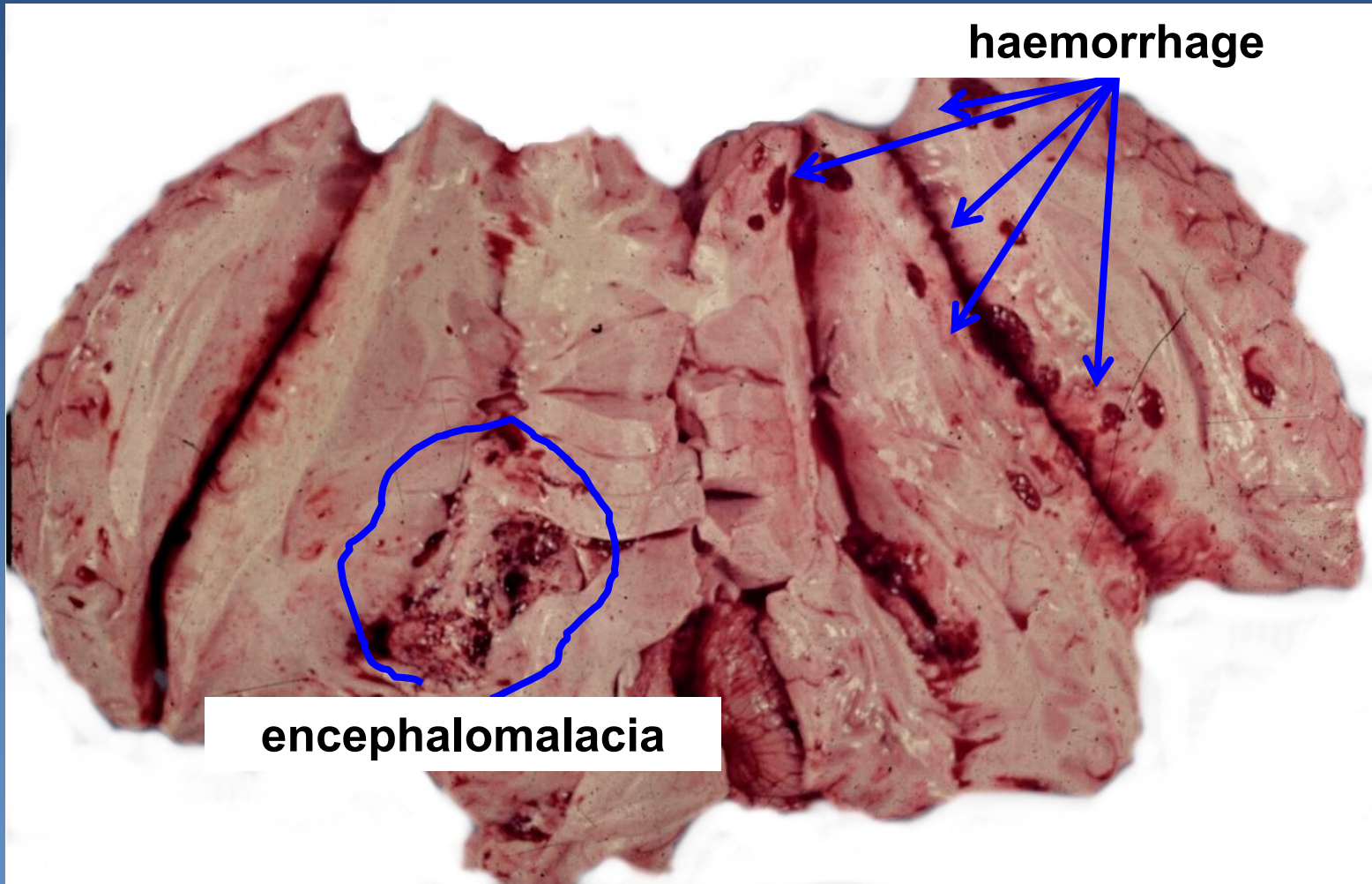
× gross:

- ⇒ approx. 24hours – affected tissue softened and swollen, loss of border between grey and white matter
- ⇒ oedema
- ⇒ infarcted tissue undergoes colliquative necrosis

× micro:

- ⇒ **neuronal ischemia** (loss of cytoplasmic basophilia, nuclei), endothelial + glial oedema
- ⇒ **neutrophils, after 2 days infiltration with macrophages** (cytoplasm filled with the lipid products of myelin breakdown)
- ⇒ **reactive astrocytes and proliferating capillaries at the edge of the infarct**
- ⇒ **Necrotic tissue phagocytosed → fluid-filled pseudocystic cavity lined by glial tissue**

Encephalomalacia (cerebral infarction)

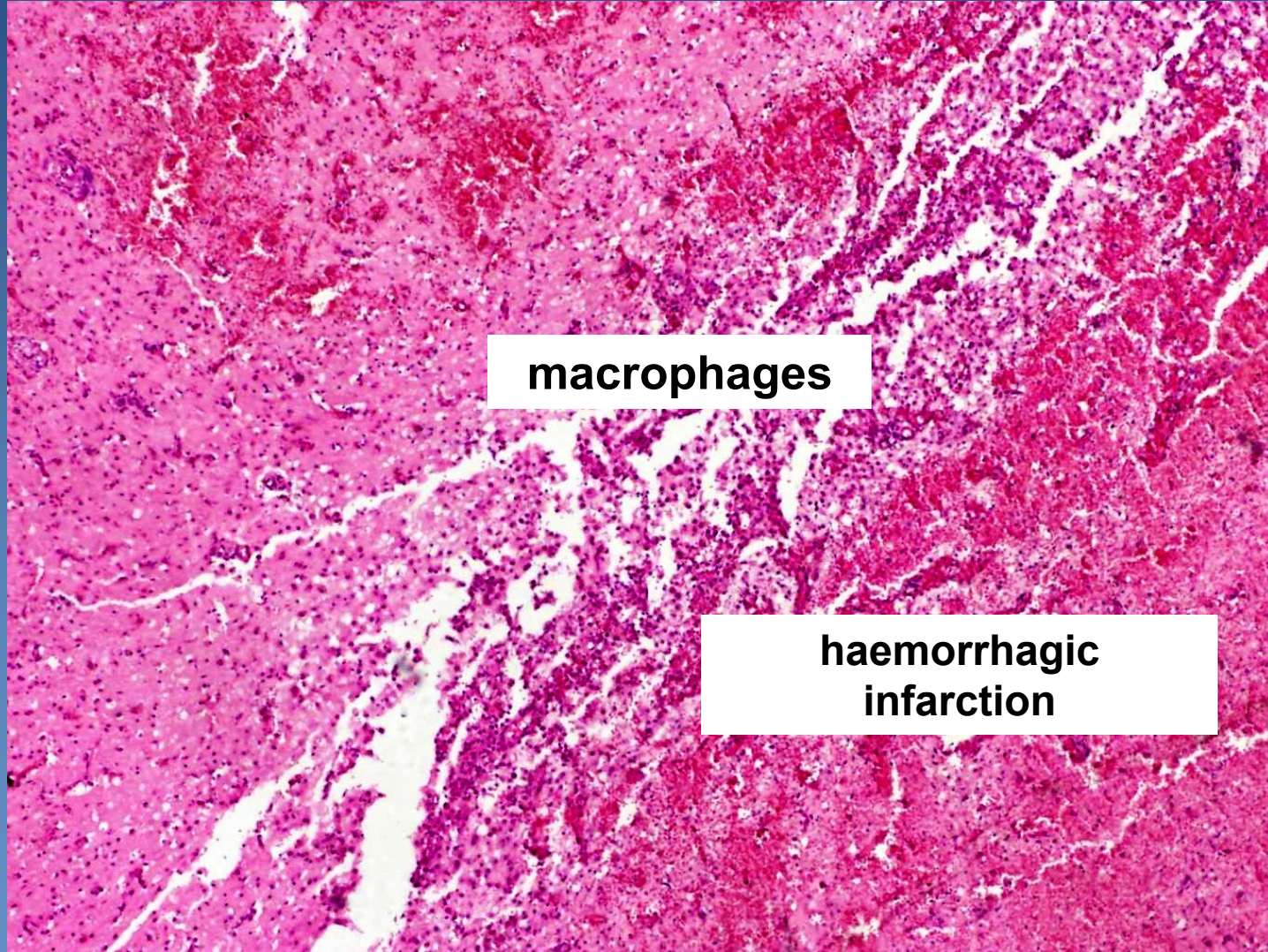


encephalomalacia

haemorrhage

Encephalomalatia

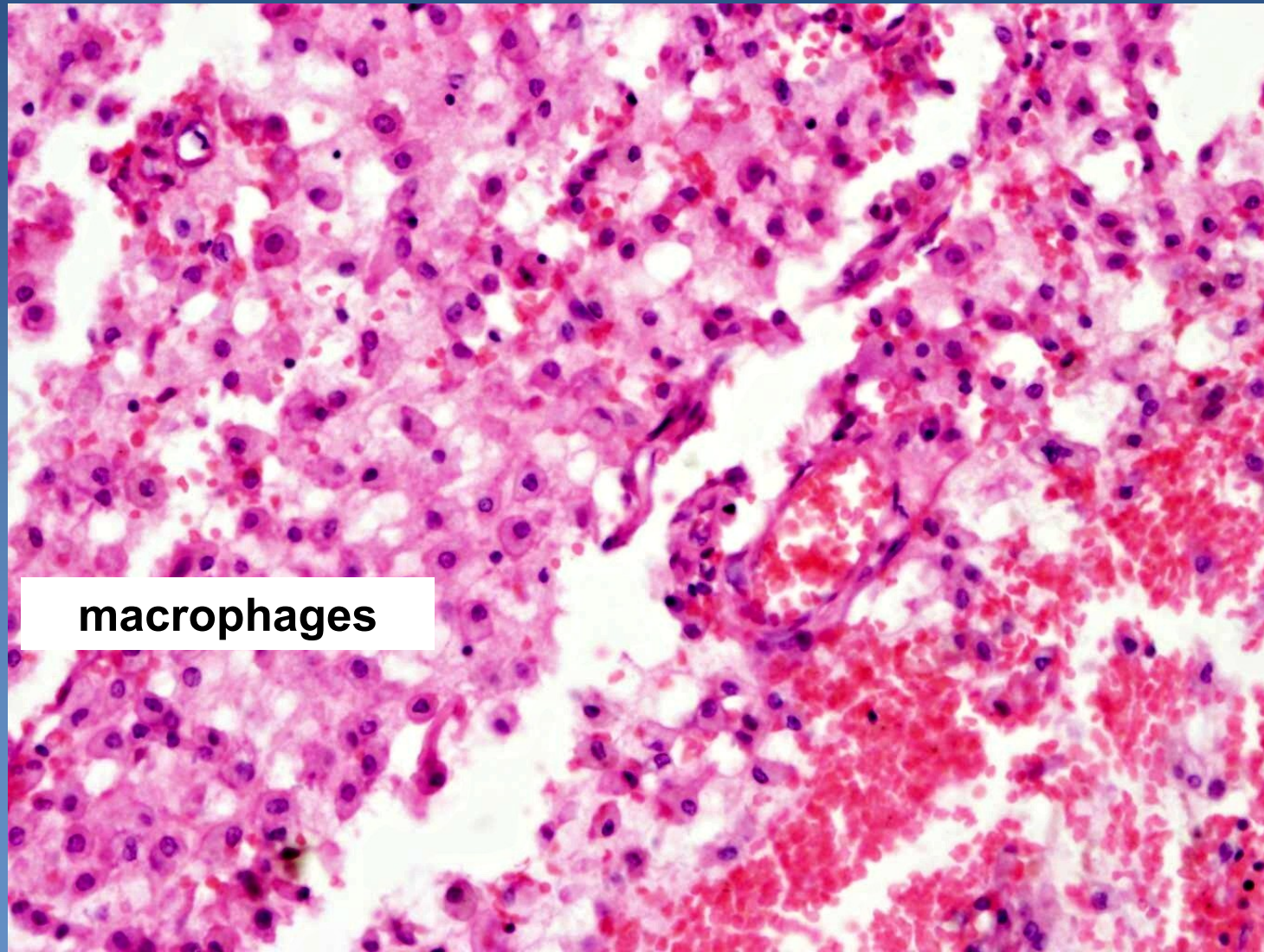
(+ reactive macrophages)



macrophages

**haemorrhagic
infarction**

Encephalomalatia



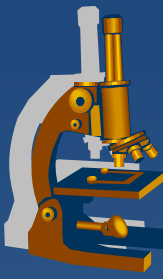
macrophages

Intracranial haemorrhage



- × **Extradural – epidural** (haemorrhage between skull and dura mater)
 - ⇒ mostly due to skull fracture (rupture of *a. meningea media*)
 - ⇒ arterial, traumatic, acute,
 - ⇒ clinically: variable lucid interval later onset of signs - increased intracranial pressure
- × **Subdural** (haemorrhage between dura and arachnoid matter)
 - ⇒ rupture of venous sinuses or small bridging veins
 - ⇒ acute x chronic (particularly in elderly - headache, memory loss and confusion, personality change)
- × **Subarachnoid** (haemorrhage between arachnoid matter and pia mater)
 - ⇒ inborn defect: aneurysm (saccular „berry“ aneurysm on the circle of Willis)
 - ⇒ AS, hypertension, tumor, coagulative disorders

Intracranial haemorrhage



× Intracerebral

⇒ nontraumatic arterial

- hypertension + regressive vessel wall changes → rupture of blood vessel
- AS
- vasculitis, amyloid angiopathy, tumors

⇒ traumatic

⇒ *premature newborn*

- extension into ventricular system, subarachnoid space - possible hydrocephalus

× Intraventricular (haemocephalus)

⇒ secondary after haemorrhage extension into ventricular system

CNS infections



xetiology

- ⇒ *bacterial incl. tb, rickettsia*
- ⇒ *viral*
- ⇒ *fungus, parasitic (protozoan, etc.)...*

- ⇒ *haematogenous spread*
- ⇒ *local extension – direct spread (adjacent inflammations)*
- ⇒ *trauma – direct implantation*
- ⇒ *along the peripheral nerves*
- ⇒ *iatrogenic infection*

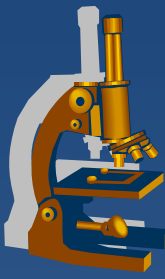
Leptomeningitis



- ⇒ *chemical (irritation)*
- ⇒ *acute pyogenic (bacterial)*
- ⇒ *acute aseptic – lymphocytic (viral)*
- ⇒ *chronic (granulomatous tuberculous; fungal)*

direct spread x blood-borne

Bacterial leptomeningitis



xsymptoms:

- ⇒ *headache, joint + muscle pain*
 - ⇒ *sleepiness, fever, vomiting, loss of consciousness, convulsion*
 - ⇒ *petechial rash*
 - ⇒ *photophobia*
 - ⇒ *signs of meningeal irritation*
 - ⇒ *sepsis*
-
- ⇒ *!! acute onset, rapid diagnosis + ATB therapy necessary*

Bacterial leptomeningitis



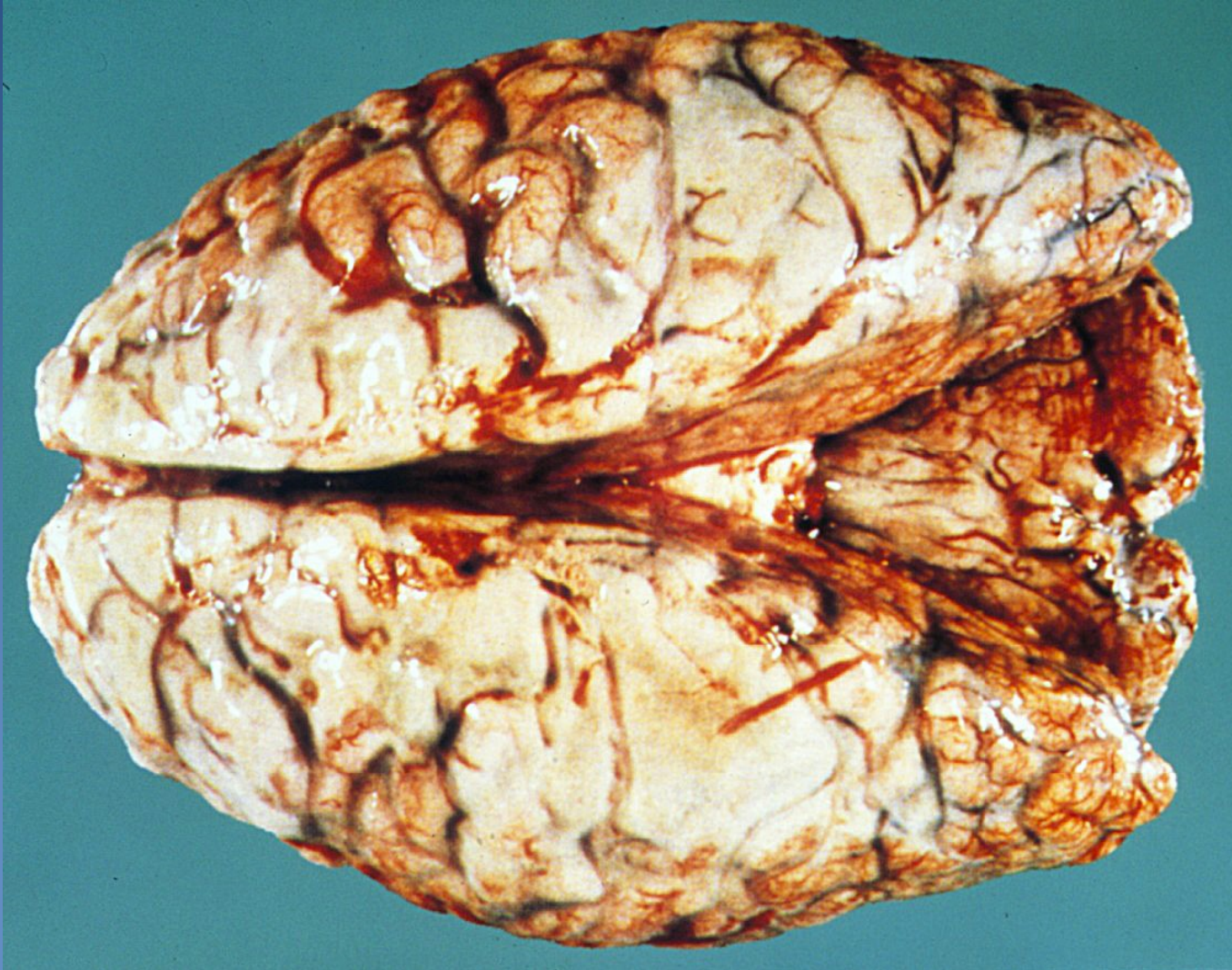×etiology:

- ⇒ *In neonates: E. coli, Str. agalactiae, Listeria*
- ⇒ *2-5 years.: Str. pneumoniae (Haemophilus now rare)*
- ⇒ *5-30 years: Neisseria meningitidis (type B)*
- ⇒ *over 30 years: Str. pneumoniae, staph., etc.*

×Gross:

- ⇒ *pia mater hyperemic, pus deposits*
- ⇒ *opaque CSF*
- ⇒ *brain swelling, sometimes cortical necrosis*

Bacterial leptomeningitis



Bacterial leptomeningitis



× micro:

⇒ *hyperemia, neutrophilic + macrophagic infiltrate, secondary phlebitis + thrombosis*

× complications:

⇒ *cerebral abscess*

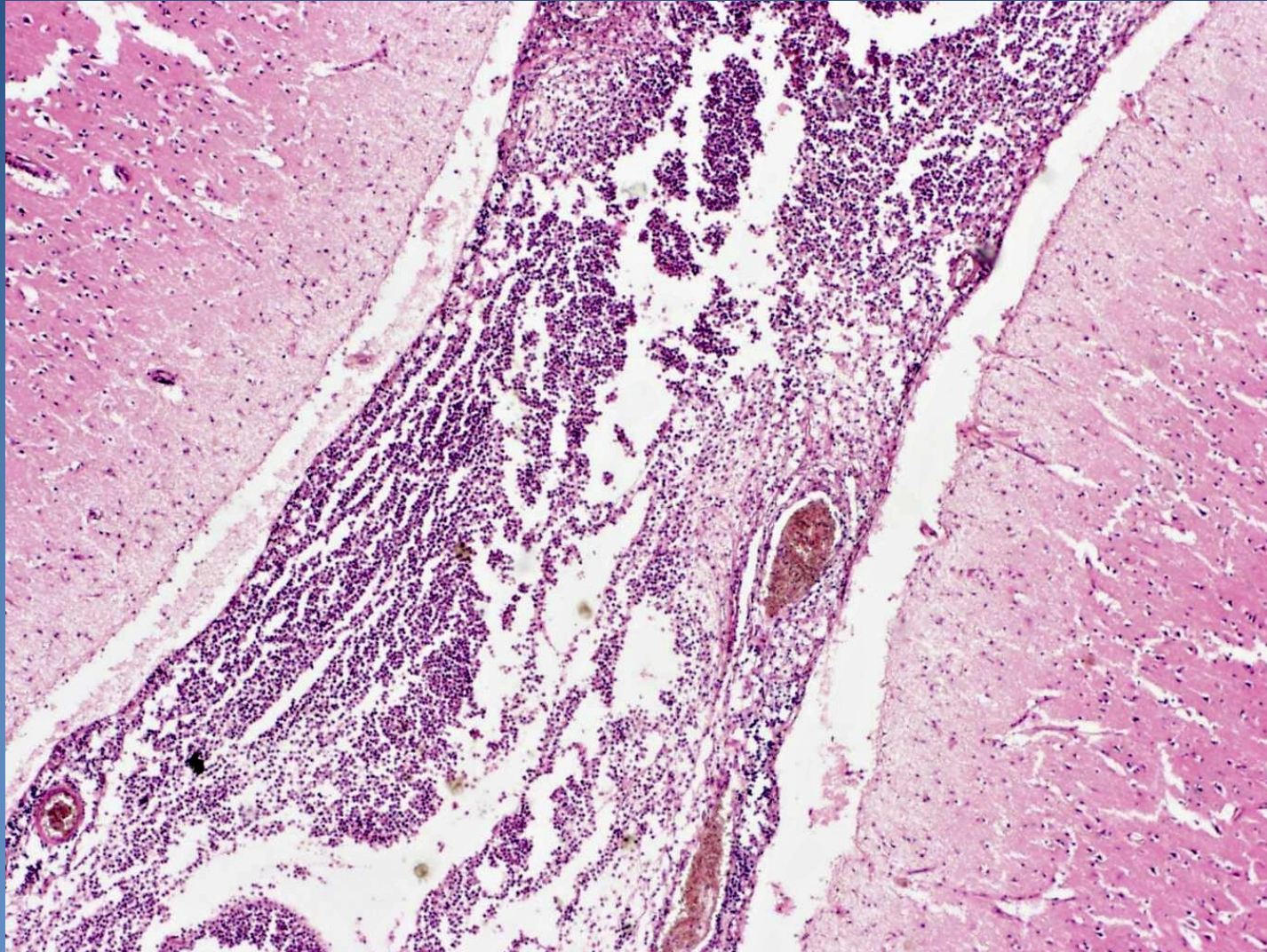
⇒ *subdural empyema*

⇒ *cerebral infarction*

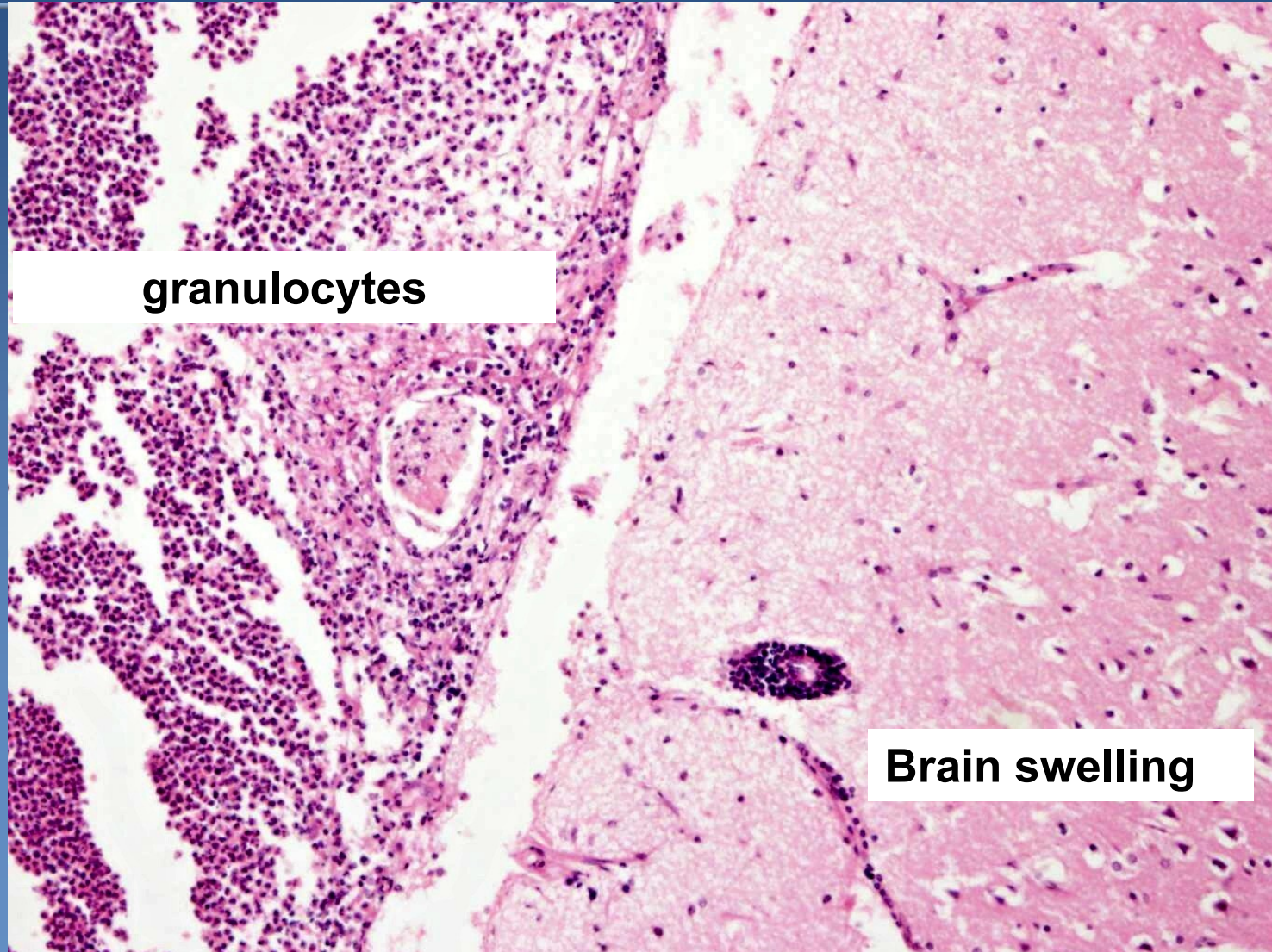
⇒ *epilepsy*

⇒ *leptomeningeal fibrosis, subarachnoid cysts, obstructive hydrocephalus*

Bacterial leptomeningitis



Bacterial leptomeningitis



granulocytes

Brain swelling

Acute aseptic meningitis



x infectious

⇒ *viral (mumps, coxackie, echoviruses, EBV, HSV)*

⇒ *usually self-limited*

⇒ *gross: hyperemic pia mater, slight edema*

⇒ *micro: lymphocytic infiltration*

x chemical or other irritant

Chronic meningitis



x granulomatous

- ⇒ *Mycobacterium tbc.*, granulomas, obliterative endarteritis
- ⇒ meningovascular neurosyphilis
- ⇒ fungi: *Cryptococcus neoformans*, *Aspergillus*, etc.

x chronic

- ⇒ Lyme disease – aseptic meningitis

x immune deficiency

- ⇒ AIDS, immunosuppression, cachexia

Tuberculous meningitis

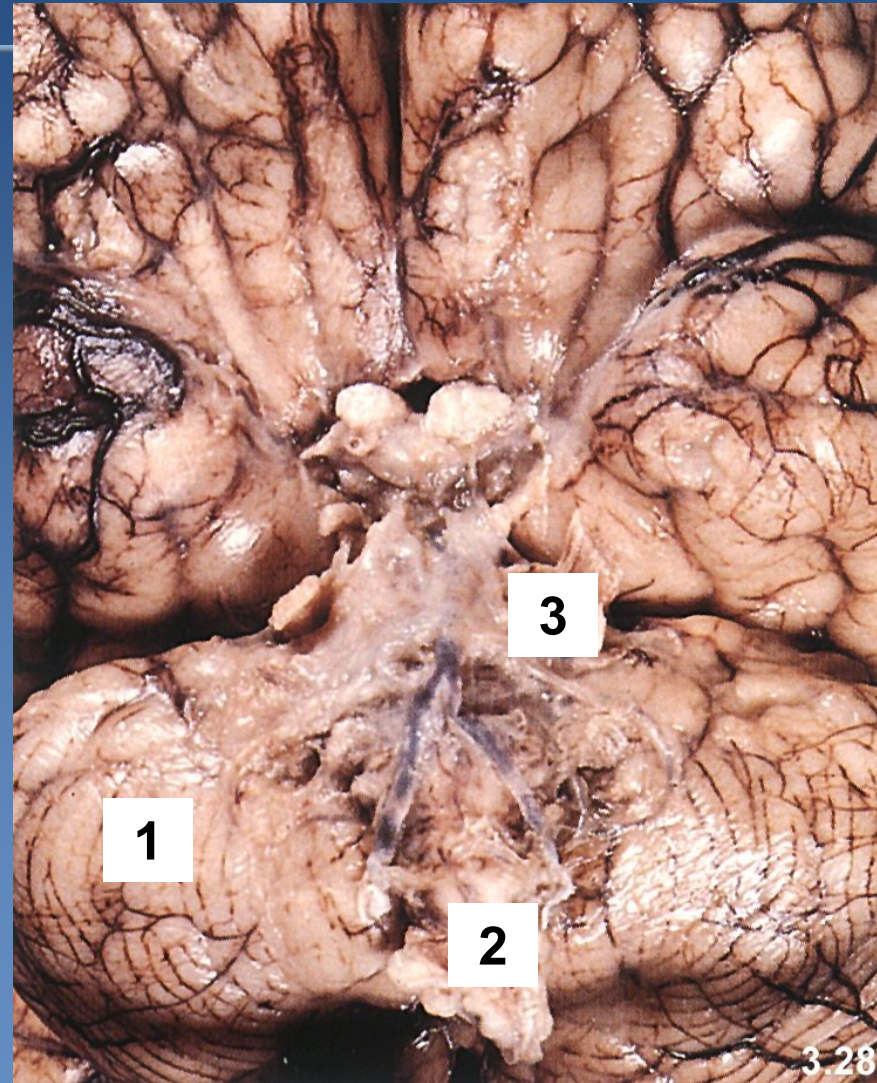


- × **etiology:** *mycobacterium tuberculosis*
- × **spread:** *usually hematogenous in primary pulmonary tuberculosis*
- × AIDS (M. avium-intracellulare complex)
- × **gross: exudative** - *thick gelatinous exudate, most marked at the base of the brain;*
 - proliferative: small white granulomas*

tuberculous meningitis



1 cerebellum
2 oblongata
**3 gelatinous
inflammatory infiltrate**



Encephalitis



× primary

⇒ *neurotropic viruses*

⇒ *anthropozoonoses - from animals transmitted to humans*

× secondary

⇒ *other underlying disease*

- *viruses (HSV, enterovirus), rickettsie, parasites (toxoplasmosis...), spirochets (lues),...*

× micro (viral encephalitis):

⇒ *neuronal damage, reactive glial changes*

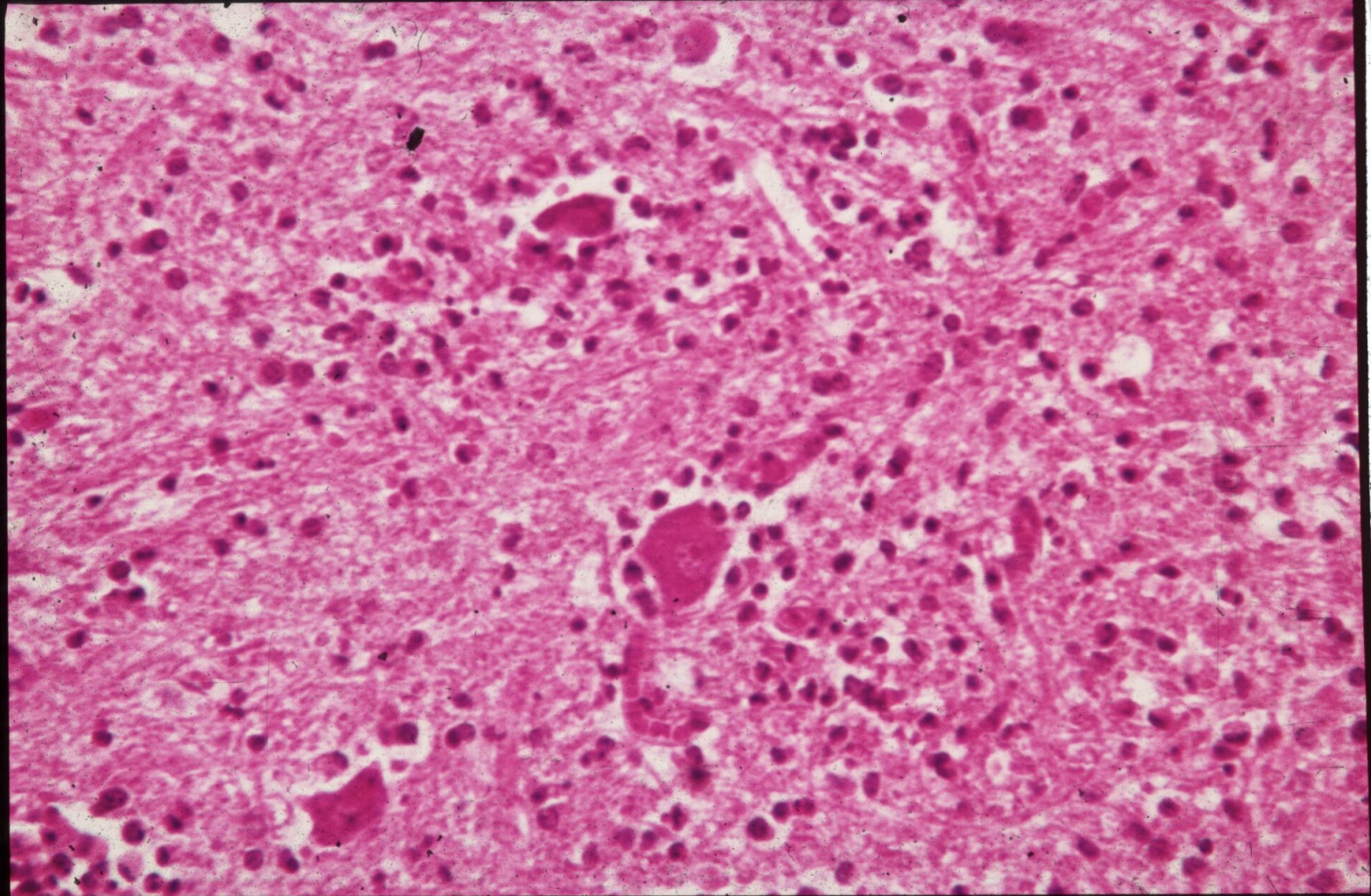
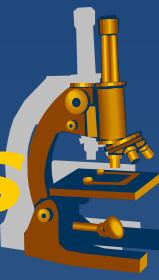
⇒ *perivascular „cuff“ infiltrate of lymphocytes, plasma cell*

Viral encephalitis - myelitis

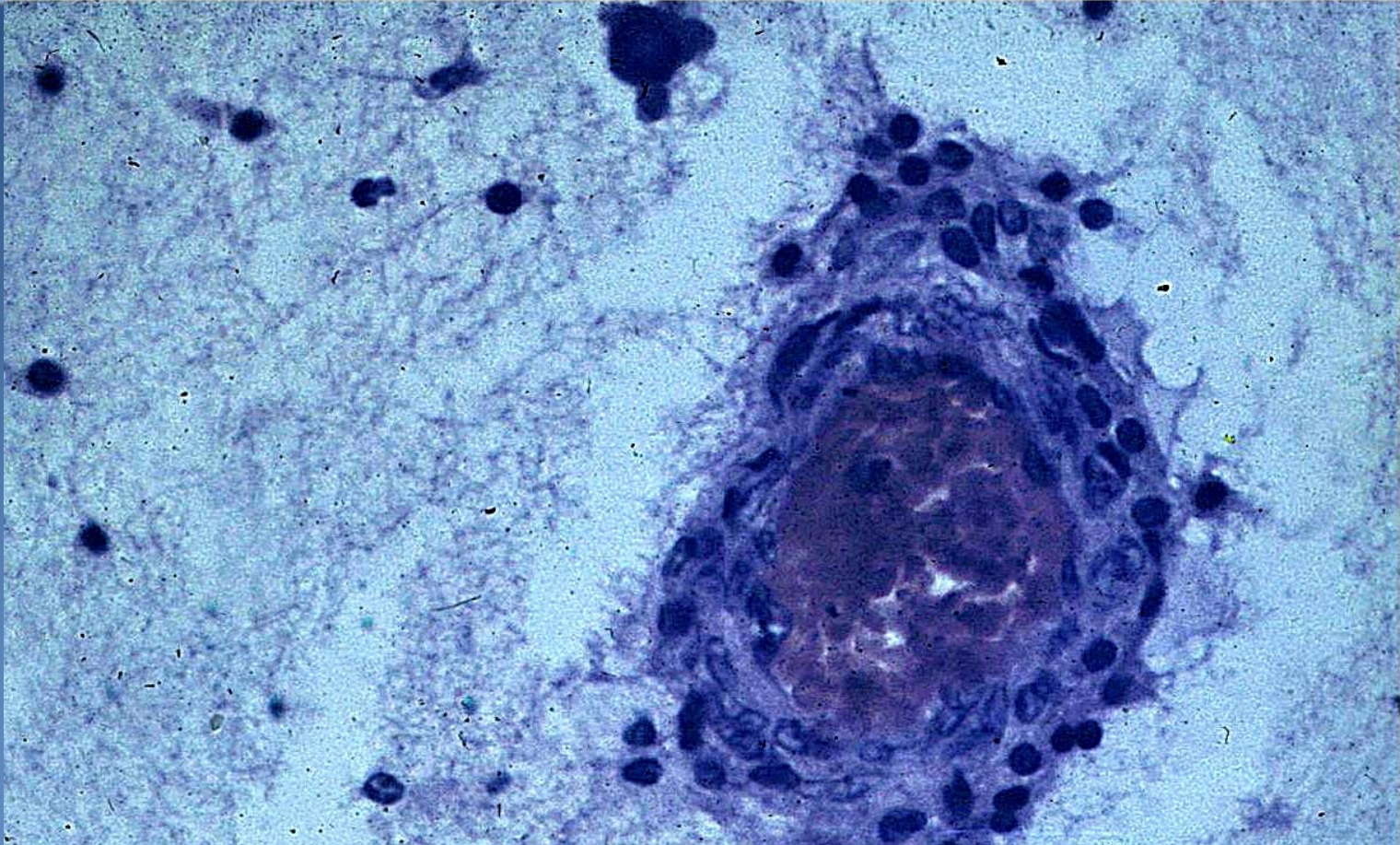


- × **usually + meningitis**
- × **spread:** *haematogenous x neural (retrograde)*
- × **tropism** - specific cell type or area involved
- × **etiology:**
 - ⇒ *arthropod-borne (tick-borne), mumps, enteroviruses (poliomyelitis), HSV, CMV, EBV, HIV, rabies*
- × **gross:**
 - ⇒ *hyperemic meninges, brain edema*
- × **micro:**
 - ⇒ *perivascular, parenchymal mononuclear cell infiltrate, glial cell reaction, oedema, neuronophagia, viral inclusions*
- × *possibility of latency, immune-mediated disease, late sequelae*

Viral encephalitis - myelitis



Viral encephalitis



perivascular infiltrate of lymphocytes + plasma cell

Viral encephalitis



x with the formation of inclusion bodies

⇒ *Rabies*

⇒ *HSV1, HSV2*

⇒ *Poliomyelitis*

x Without inclusion bodies

⇒ *tick-borne viral encephalitis*

⇒ *HIV-associated encephalitis*

Encephalitis



x Others

- ⇒ *Acute disseminated encephalomyelitis – immune-associated demyelination*
- ⇒ *Subacute sclerosing panencephalitis (measles virus)*
- ⇒ *Typhus fever - rickettsiae*
- ⇒ *Neurosyphilis*

Viral encefalitis with inclusion bodies



x rabies, lyssa

- ⇒ *incubation 3-8 weeks → with axonal retrograde flow to the brainstem, spinal cord, dorsal root ganglia, cerebral cortex, cerebellum, hippocampus*
- ⇒ *micro **Negri bodies** (eosinophilic inclusions of the size of red blood cells in the cytoplasm of neurons)*

x herpetic encephalitis (HSV1, HSV2)

- ⇒ *Frontal cortex, other parts of the gray matter*
- ⇒ *hemorrhagic necrosis, intranuclear inclusions*
- ⇒ *severe (sometimes fatal) course*

Viral encefalitis with inclusion bodies



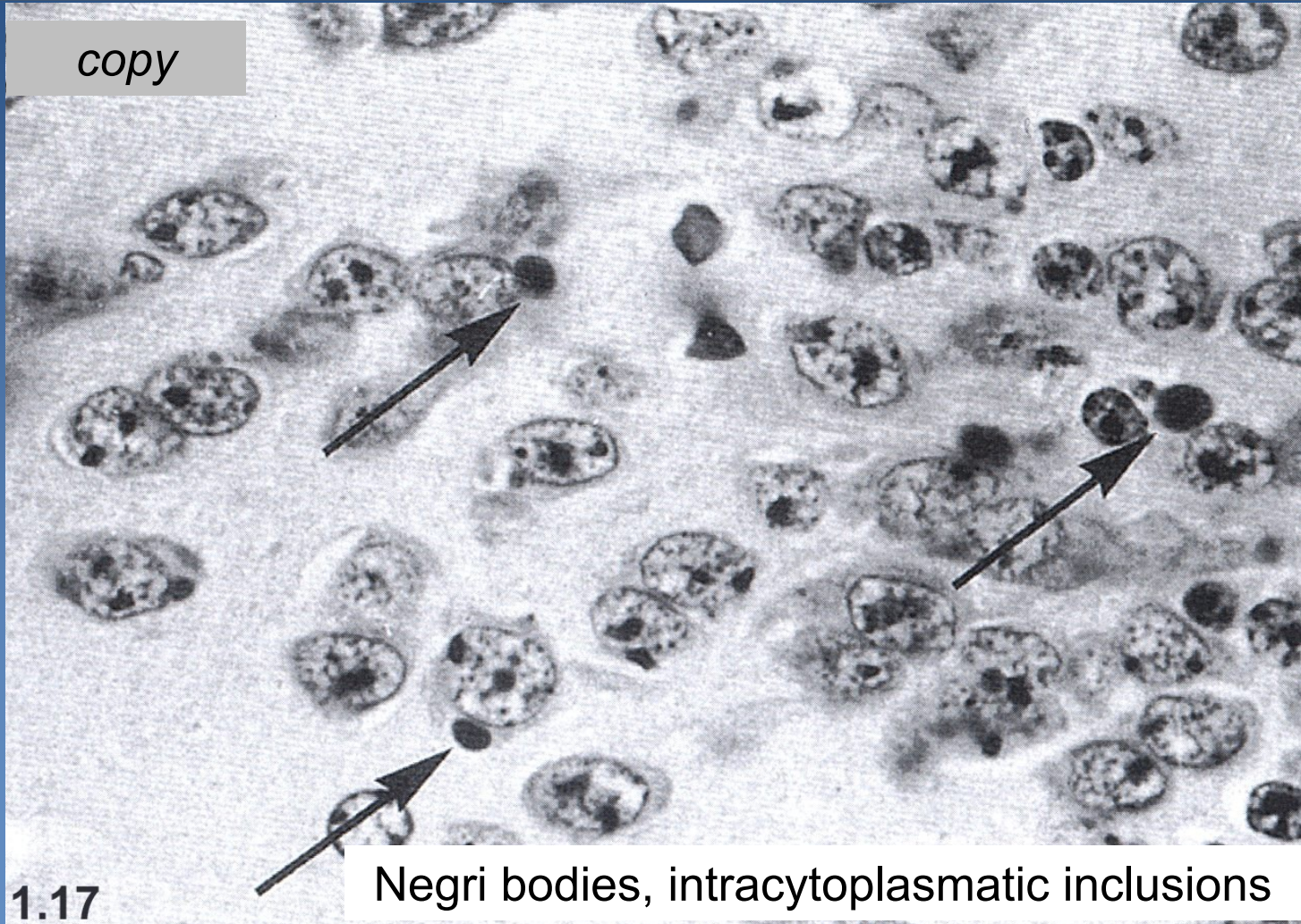
xPoliomyelitis

- ⇒ *enteroviruses, coxsackie, ECHO*
- ⇒ *pharyngitis, enteritis, myocarditis, myositis...*
- ⇒ *approx. in 10% affinity to the motoric neurons → anterior horns of the spinal cord, (gyrus precentralis) → symptoms of paralysis*
- ⇒ *anterior horns of the spinal cord markedly swollen, hyperemic*
- ⇒ *small intranuclear inclusions → neuronal necrosis → inflammatory reaction + neuronophagia → gliosis*

Rabies



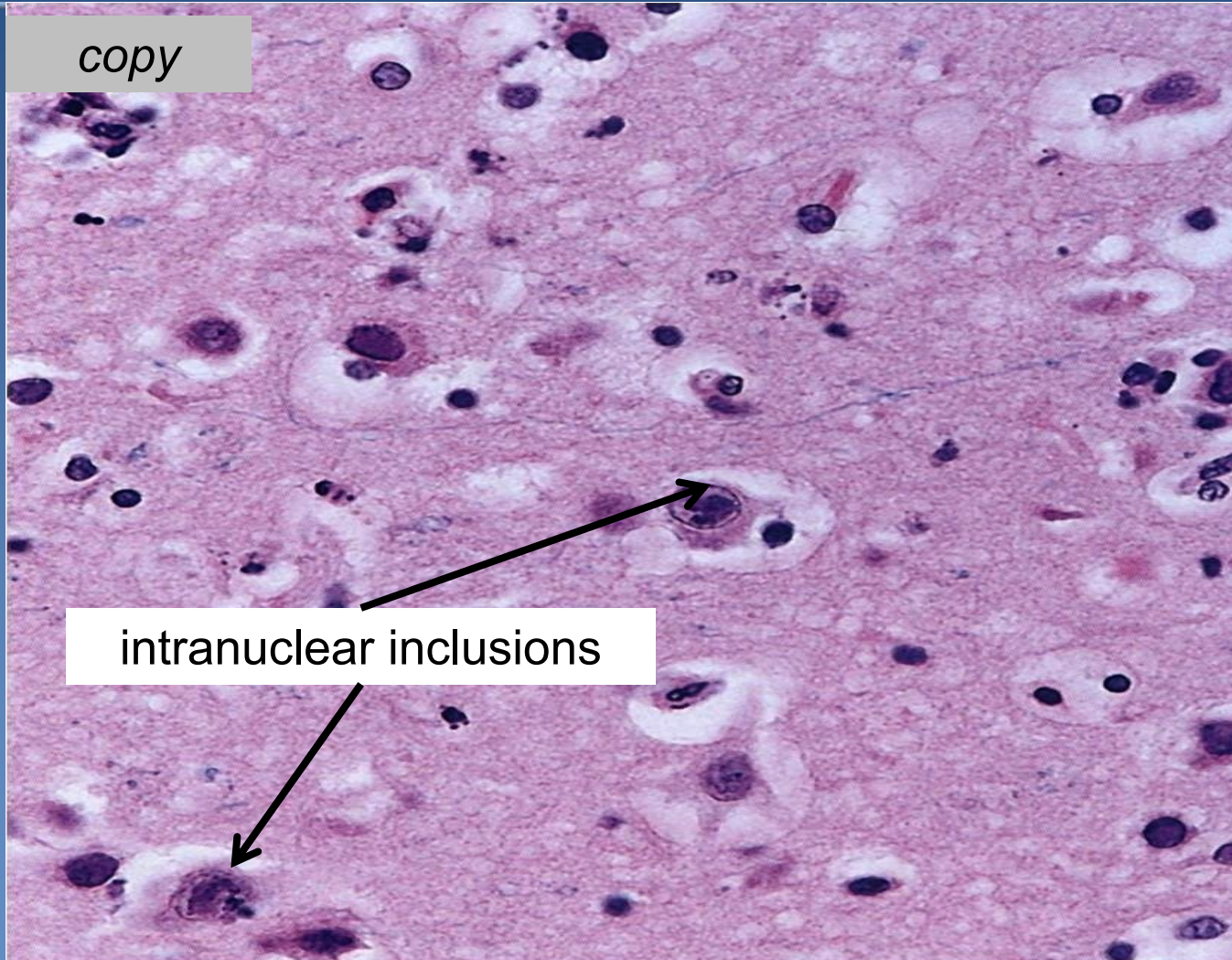
copy



1.17

Negri bodies, intracytoplasmic inclusions

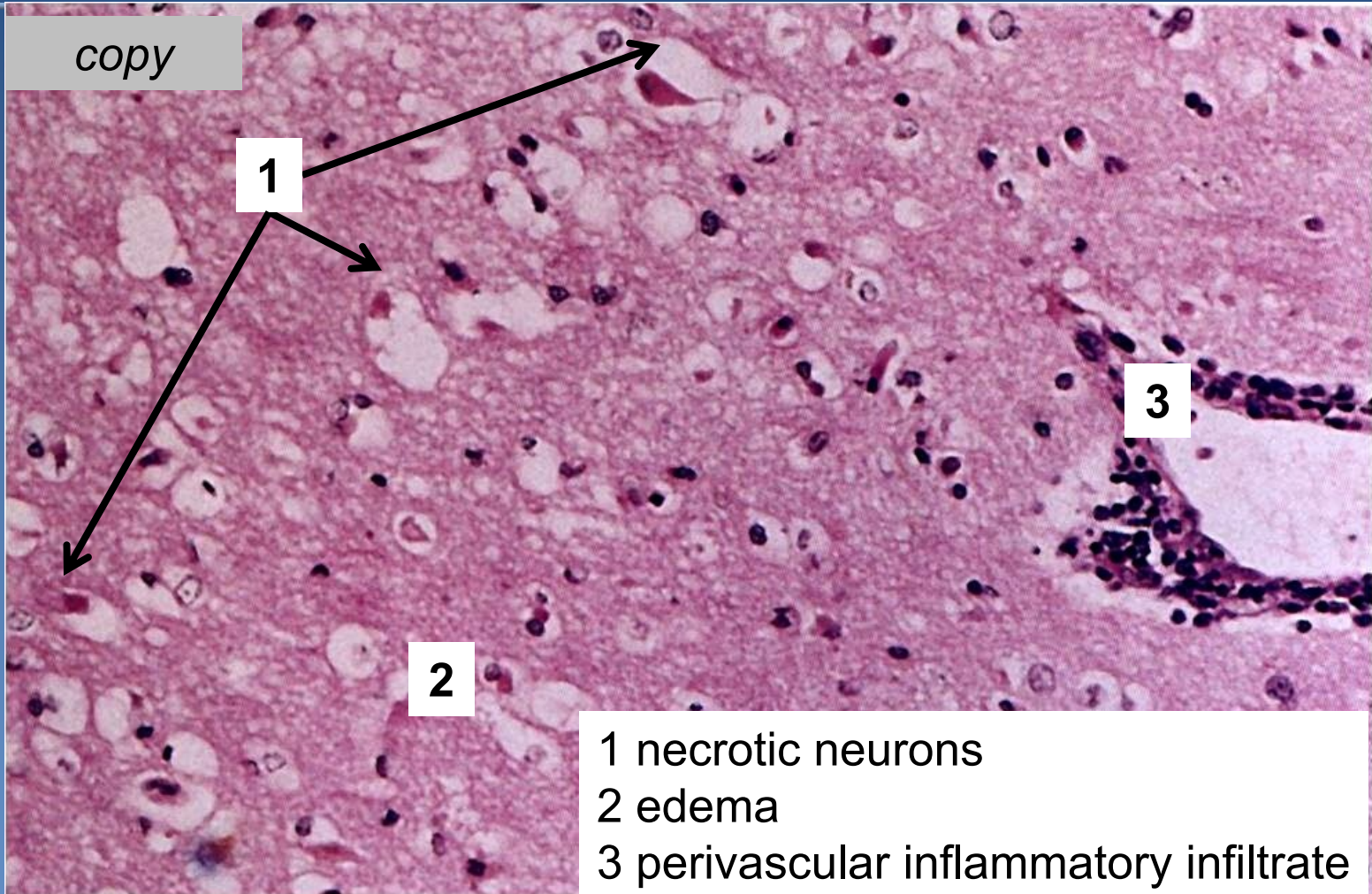
Herpetic encephalitis



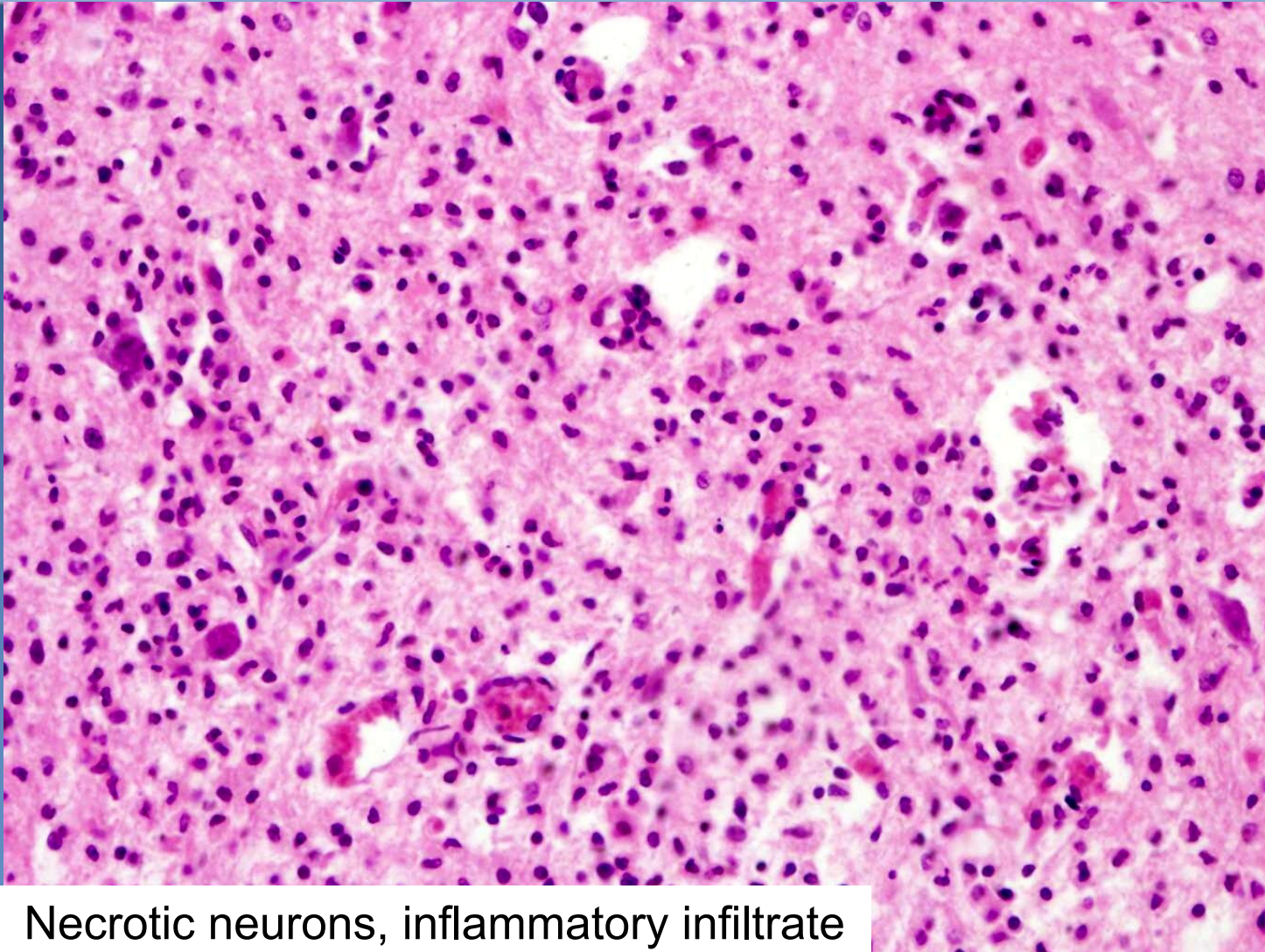
copy

intranuclear inclusions

Herpetic encephalitis

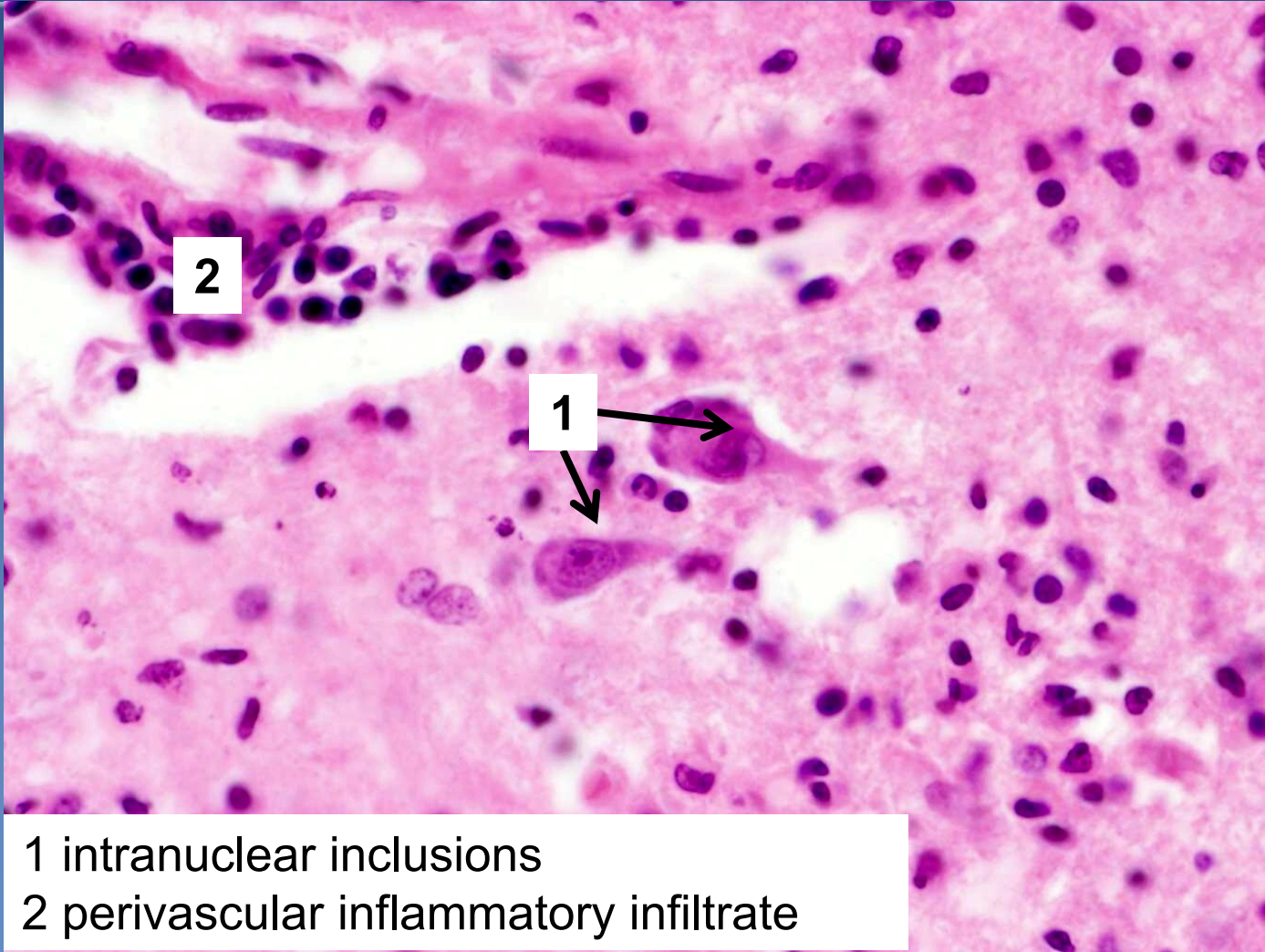


Poliomyelitis



Necrotic neurons, inflammatory infiltrate

Poliomyelitis



1 intranuclear inclusions
2 perivascular inflammatory infiltrate

Viral encephalitis without inclusion bodies



x Tick-borne encephalitis (Middle Europe)

⇒ ***mostly asymptomatic***

⇒ ***symptoms rarely***

- convulsions, confusion, delirium, coma, often with focal neurological deficits such as reflex asymmetry

⇒ ***meningeal form, meningoencephalitic or
encephalomyelitic form***

- both gray and white matter affected (panencephalitis)

Viral encephalitis without inclusion bodies



- x HIV encephalitis**

- x HIV-associated dementia**

- ⇒ *acute aseptic meningitis in 10% of HIV + patients*
- ⇒ *subacute/chronic HIV encephalitis*
- ⇒ *vacuolar myelopathy*
- ⇒ *opportunistic encephalitis (herpetic, CMV, toxoplasmosis)*

Neurosyphilis



⇒ *different CNS changes in the 2nd, 3rd stage*

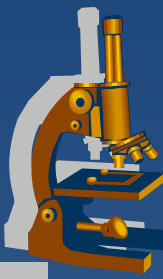
⇒ *meningovascular form*

- chronic meningitis
- obliterative (Heubner) endarteritis

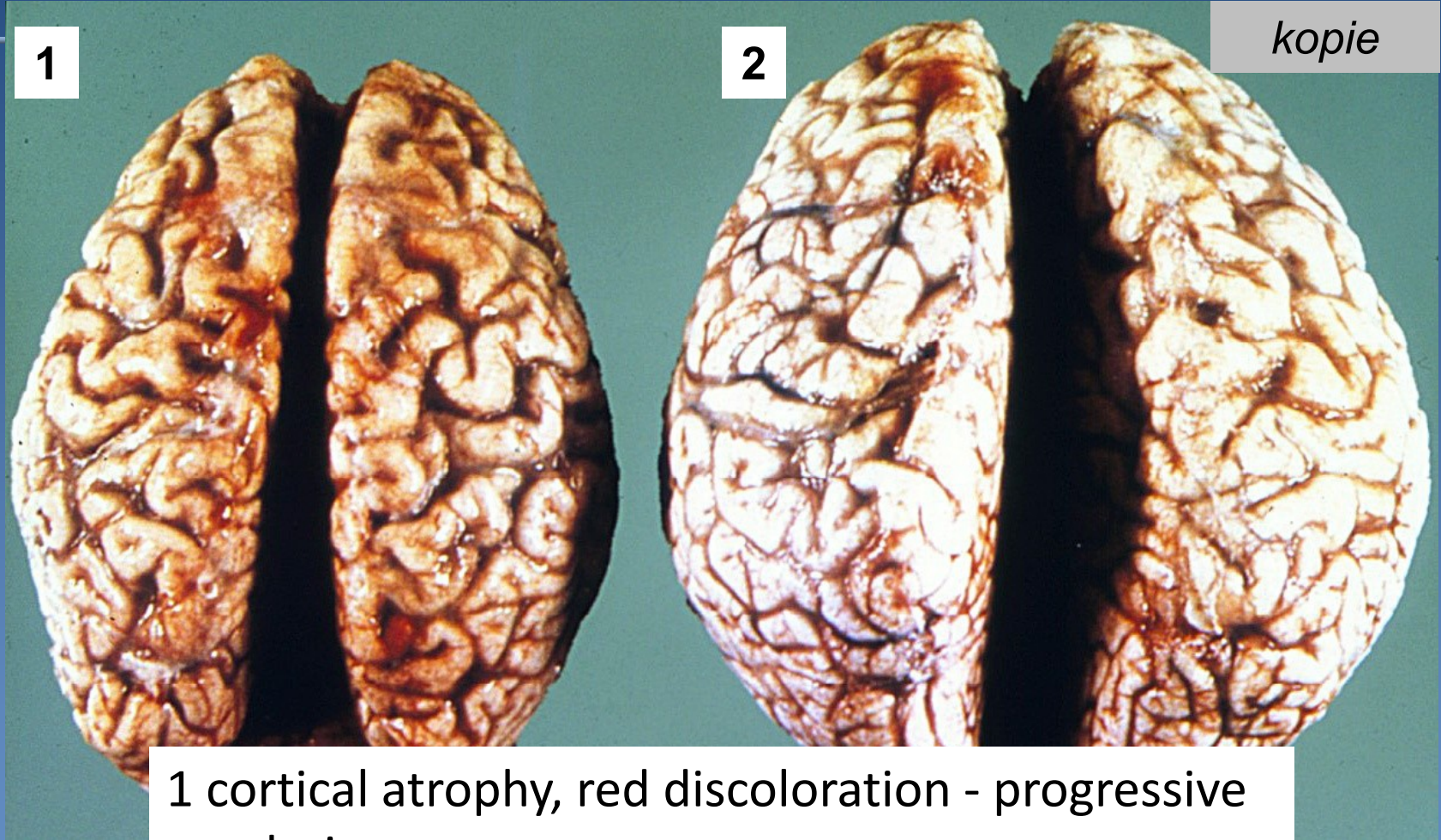
⇒ *parenchymatous form*

- atrophic cortex + hemosiderin; gummata
- progressive mental deficit → dementia
- tabes dorsalis – sensory nerves of the dorsal roots

Neurosyphilis



kopie



1

2

1 cortical atrophy, red discoloration - progressive paralysis
2 initial stage

prion encephalopathy



xPrions (*proteinaceous infectious particles*)

⇒ *protein particles capable of inducing conformational change of tissue PrPc to pathogenic PrPSc*

⇒ *micro:*

- *spongiform encephalopathy – microscopic vacuolisation*
- *numerical atrophy of neurons*
- *reactive gliosis*
- *missing inflammatory response!!*

⇒ *long incubation period, rapid progression (dementia) → ☹️*

prion encephalopathy



✘ Creutzfeldt-Jacob disease

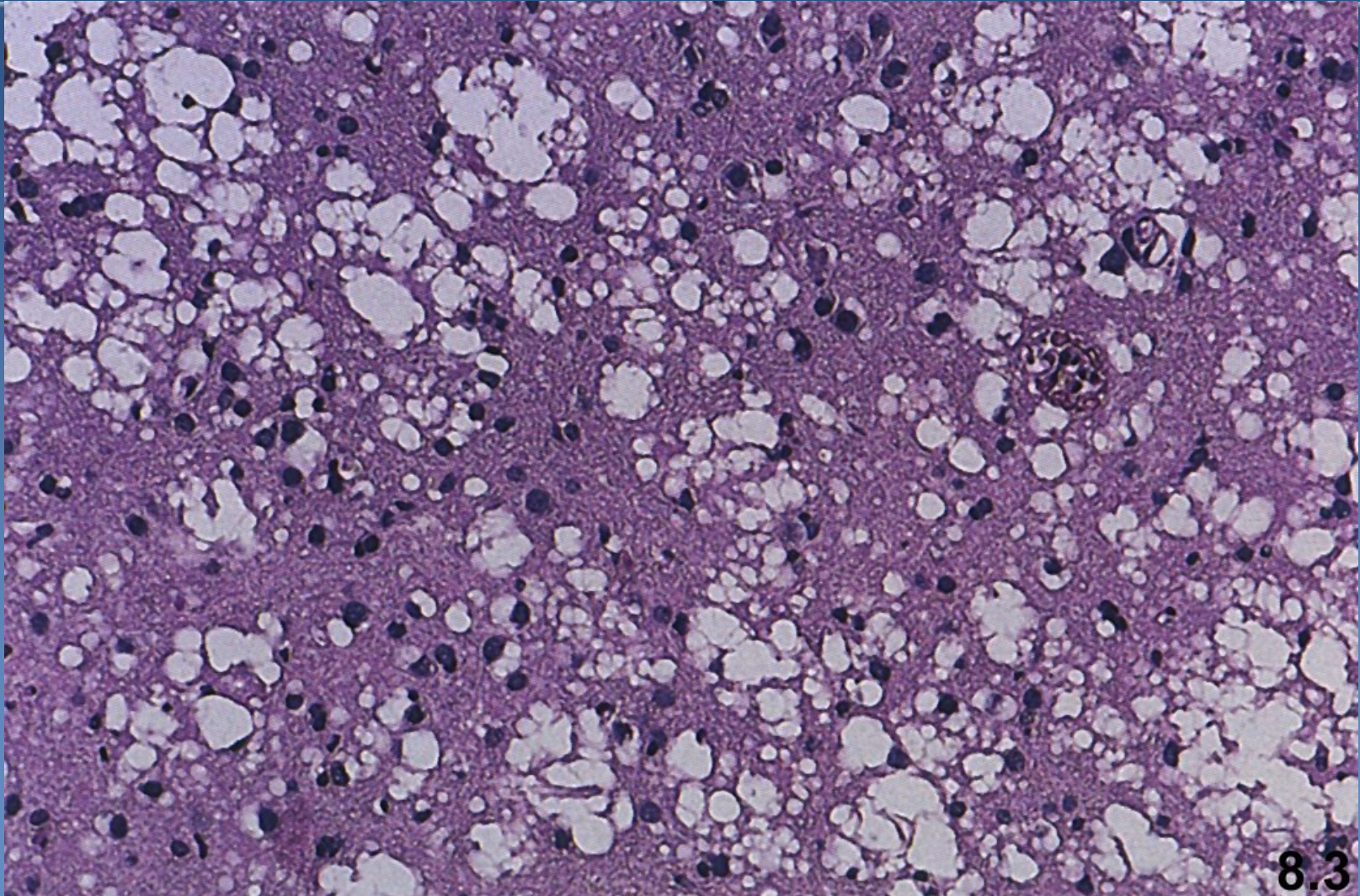
⇒ *sporadic*

⇒ *familial*

⇒ *iatrogenic*

⇒ *variant (BSE?)*

Creutzfeldt-Jacob disease





Neurodegenerative diseases

Neurodegenerative diseases



x loss of specific groups of neurons → typical clinical signs

⇒ ***apoptosis + oxygen radicals – neuronal damage***

⇒ ***pathological protein aggregates***

- disease-specific – classification

⇒ ***genetic risk***

Degenerative diseases



- ✗ cortex – Alzheimer disease – dementia
- ✗ subcortical – Parkinson d. – tremor, dyskinesia, rigidity
- ✗ amyotrophic lateral sclerosis – motor neurone loss

- ✗ **Pick's disease**
- ✗ **Huntington's disease**
- ✗ **Parkinson's disease, parkinsonism**

Alzheimer's disease



- ✗ the most common neurodegenerative condition

- ✗ pre-senile dementia

 - ⇒ possible start at the age of 50 (or sooner) → slow progression (-> 8-10+ years) → death due to inanition, bronchopneumonia

 - ⇒ M:F 1:2

 - ⇒ sporadic x familial (about 5%)

Alzheimer's disease



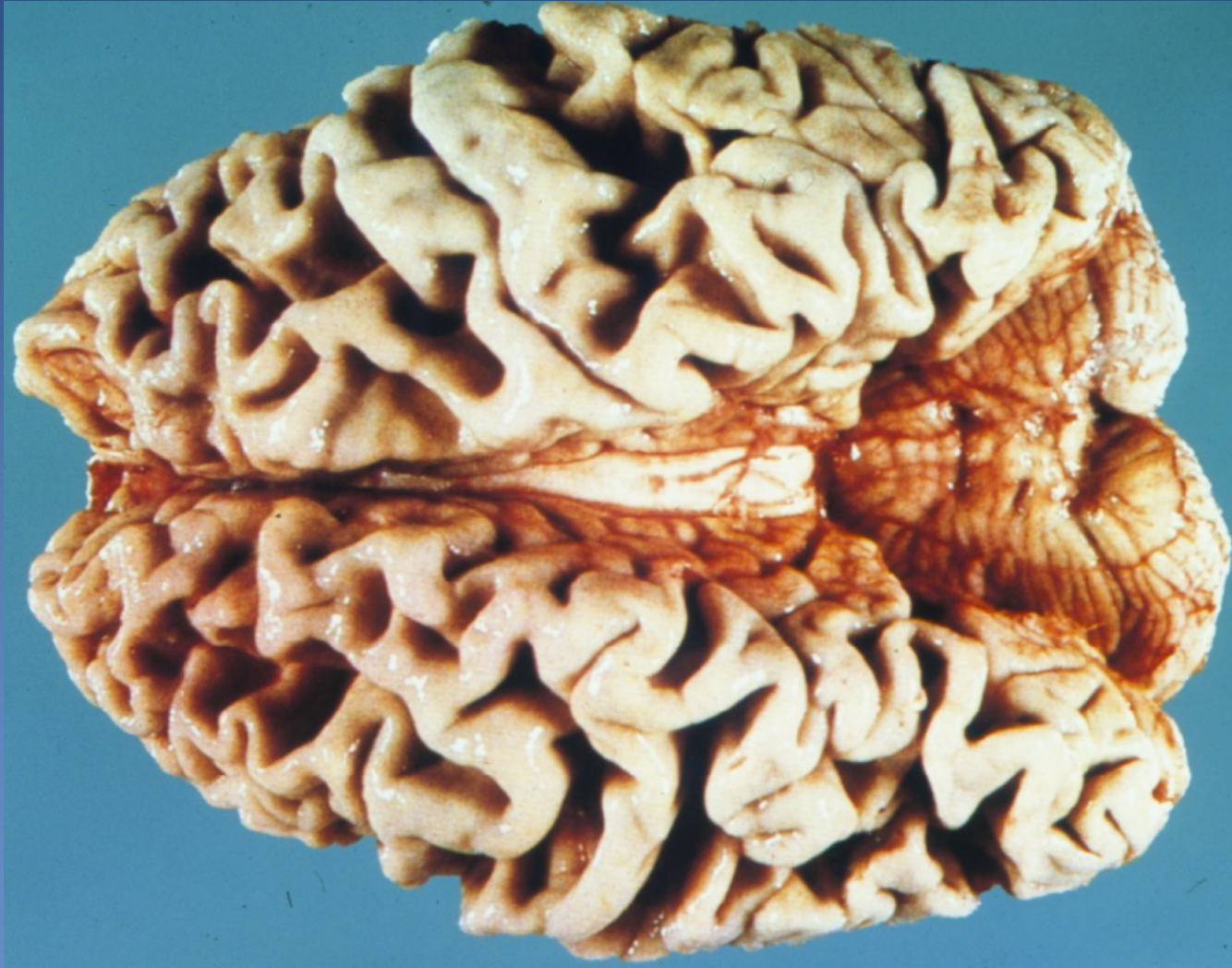x gross:

- ⇒ *marked cortical atrophy (frontal, temporal)*
- ⇒ *loss of cortical grey and white matter, secondary hydrocephalus*
- ⇒ *limbic system affected - hippocampus*

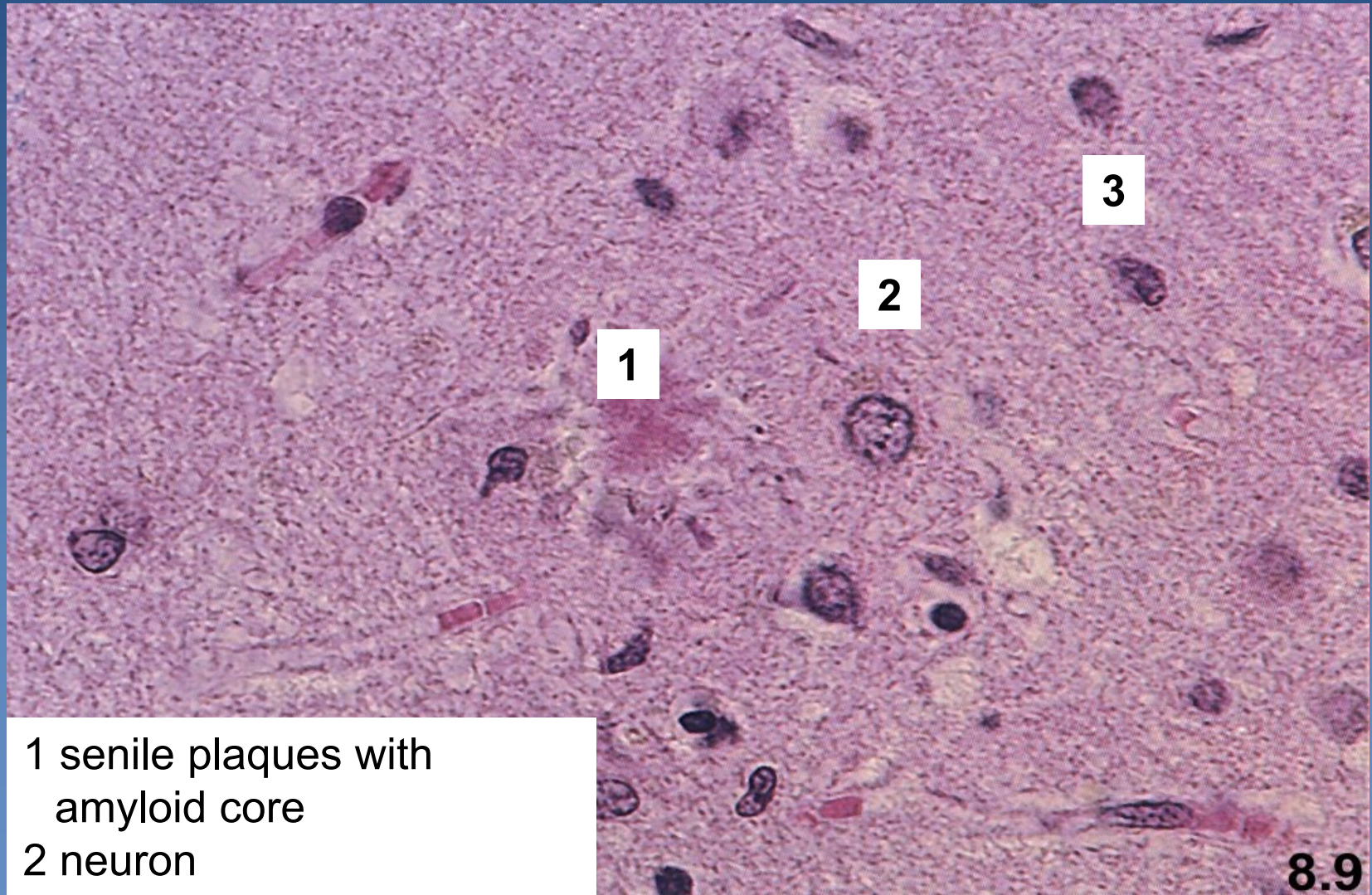
x micro:

- ⇒ *neuronal loss*
- ⇒ *A-beta amyloid plaques and neurofibrillary tangles*
- ⇒ *amyloid angiopathy - deposits in the wall of capillaries and arterioles*
- ⇒ *non-specific changes, only more pronounced*

Alzheimer's disease



Alzheimer's disease

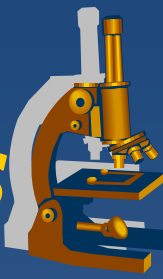


1 senile plaques with amyloid core

2 neuron

3 neurofibrilla

Frontotemporal dementias



- ✗ similar clinical picture – language deterioration, personality changes
- ✗ may have specific protein aggregates - deposits (tau)
- ✗ sporadic or rare familial
- ✗ approx. 10% of dementias

Pick's disease

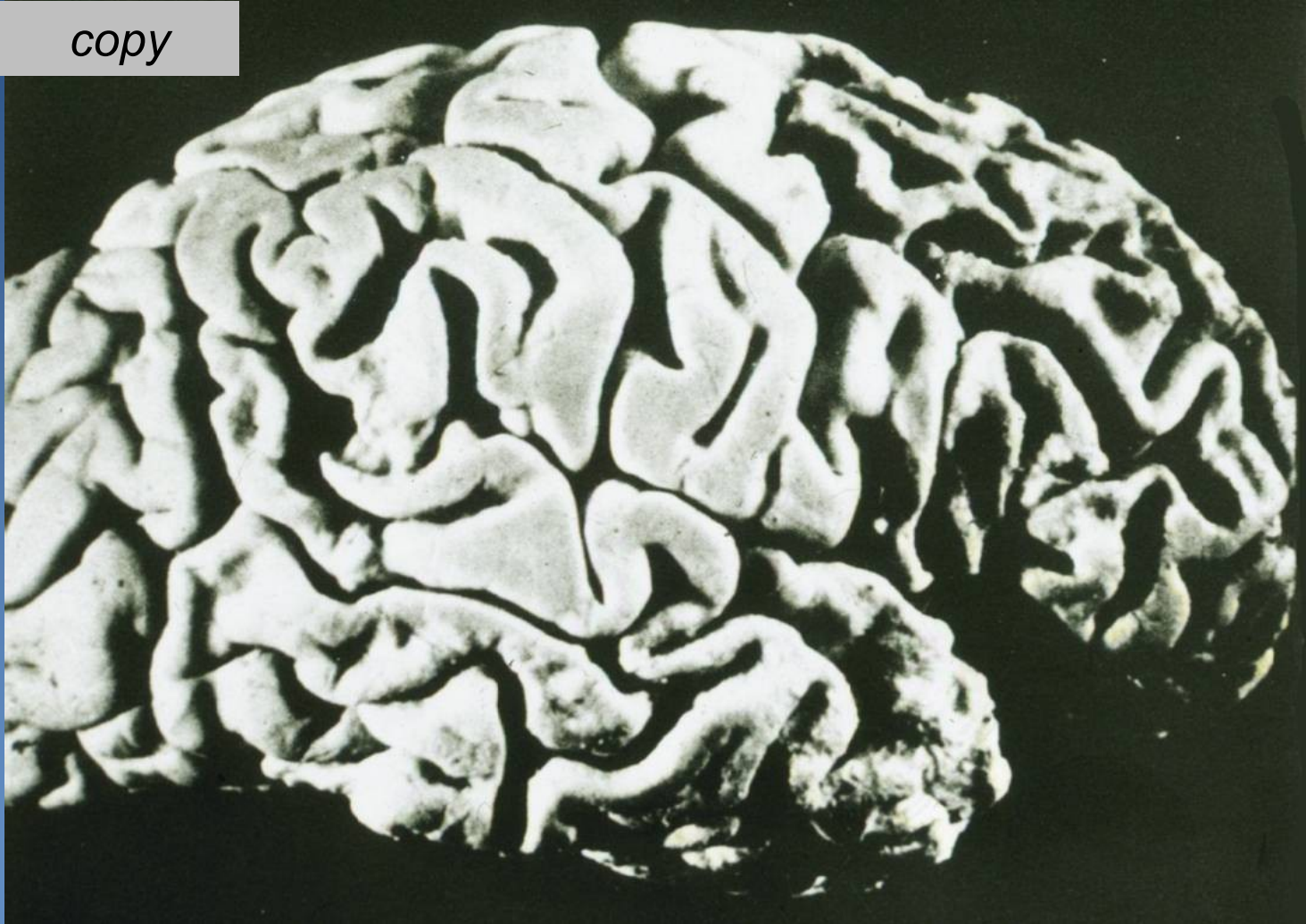


- × 5% of dementias, M>F
- × **gross**
 - ⇒ max. atrophy in **the frontal and temporal lobe** (foliate threads) - lobar atrophy
- × **micro**
 - ⇒ loss of neurons in the I.-III. cortical layers
 - ⇒ demyelination in the white matter
 - ⇒ neuron's cytoplasm with Pick bodies (filamentous inclusions), Hirani bodies, granulovacuolar degeneration

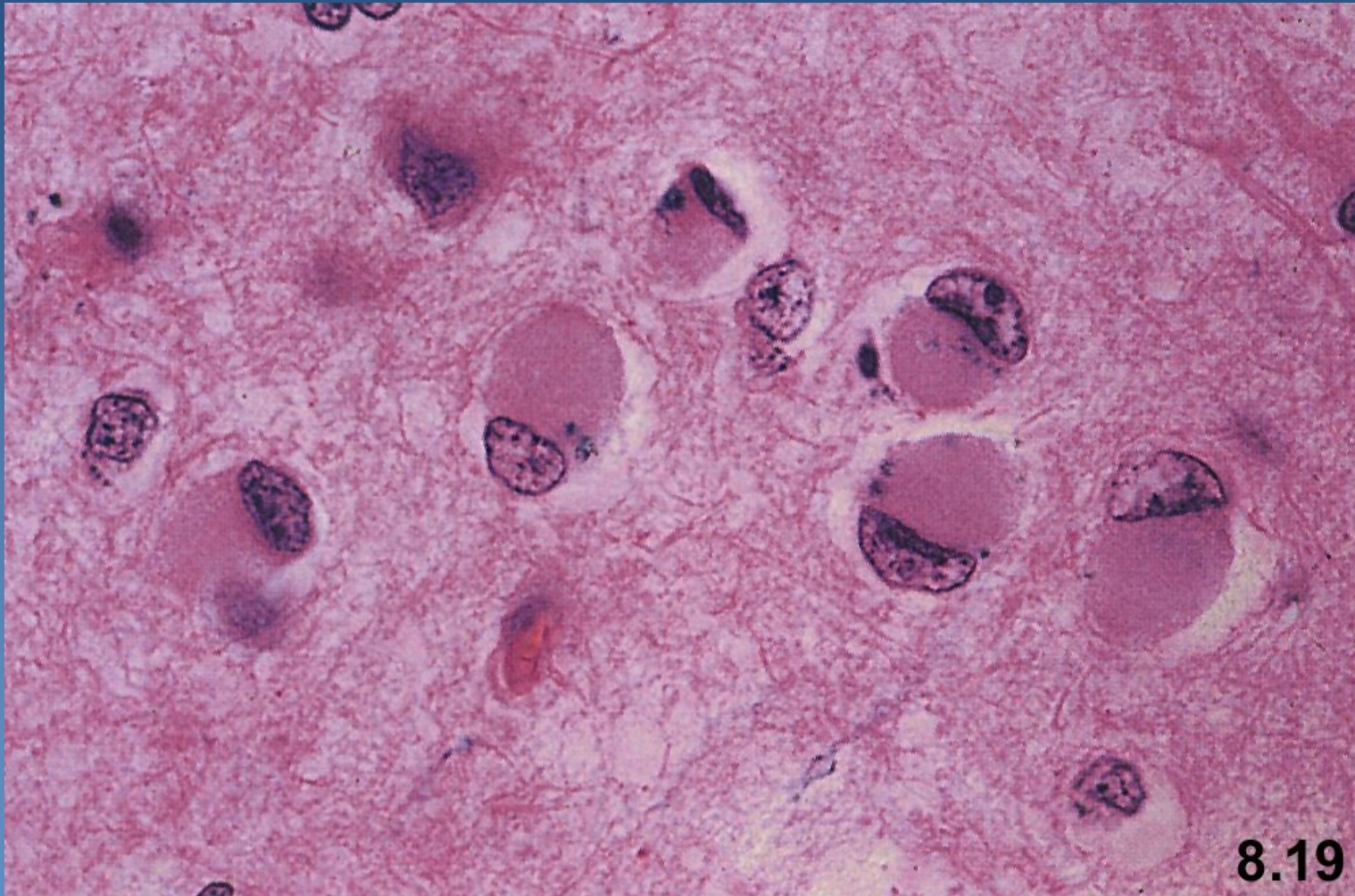
Pick's disease



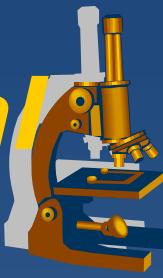
copy



Pick's disease



Degenerative diseases of basal ganglia and brainstem



x movement disorders

⇒ *rigidity*

⇒ *abnormal posturing*

⇒ *chorea*

x reduction of voluntary movements

x increase of involuntary movements

Huntington's disease



x AD

⇒ *gene on chromosome 4p – huntingtin protein*

- CAG triplet repeat, if > 35 → disease
- ↑ number of repeats → earlier onset, more rapid course

x begins after age of 30 (4th, 5th decade)

x progressive course (15-20 years)

x uncoordinated, jerky body movements, gradually dementia

Huntington's disease



x gross:

- ⇒ Atrophy of *n. caudatus* a *putamen*
- ⇒ **dilated** lateral + 3rd ventricle
- ⇒ *cortical atrophy*
- ⇒ *brain weight reduction of up to 30%*

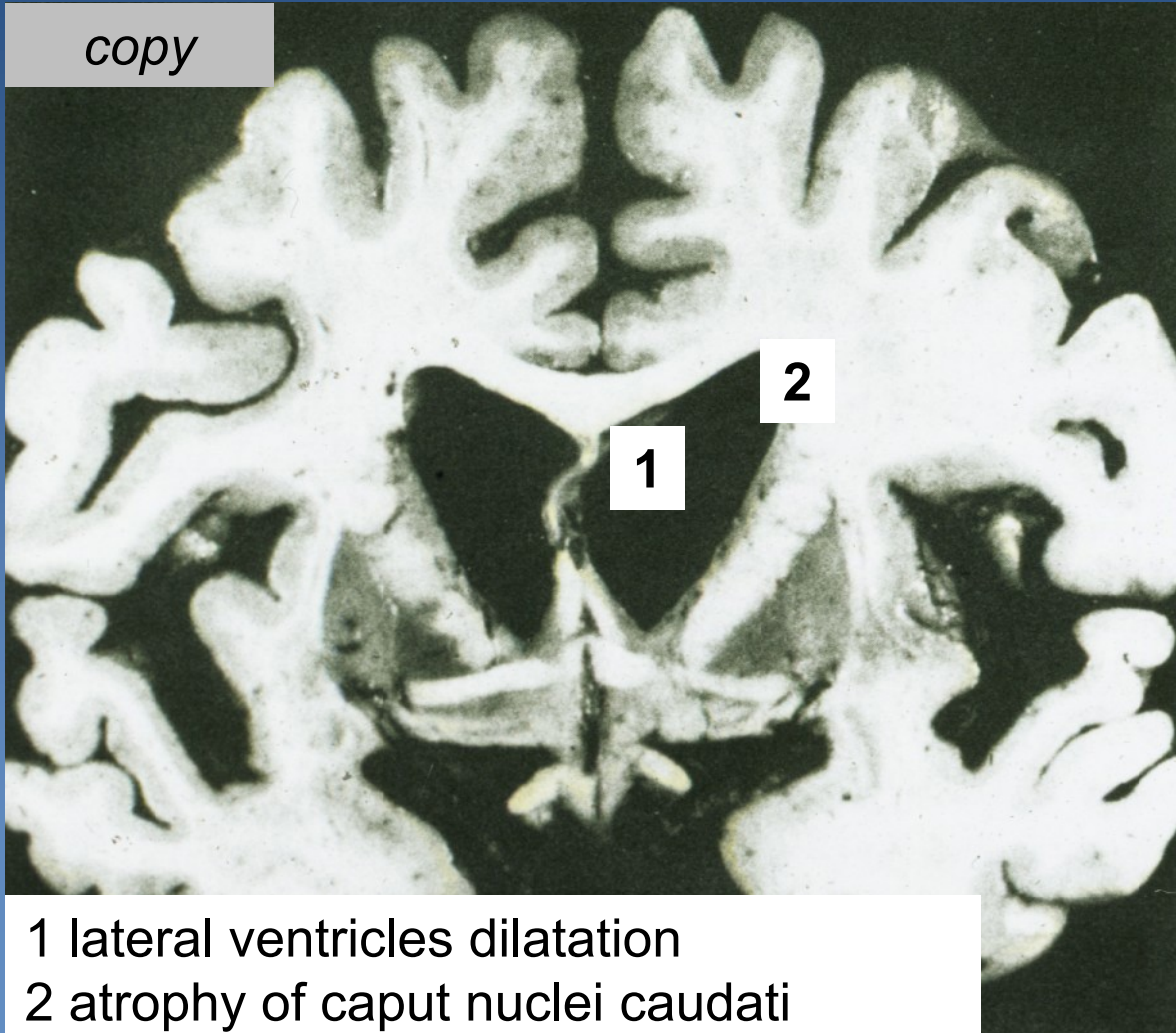
x micro:

- ⇒ *loss of neurons*
- ⇒ *fibrillary gliosis*

Huntington's disease



copy



- 1 lateral ventricles dilatation
- 2 atrophy of caput nuclei caudati

Parkinsonism



- × **clinical condition due to the damaged nigro – striatal dopaminergic system**
- × ↓ inhibitory neurotransmitter
- × stiff facial expression, muscle rigidity, slowness of voluntary movements (bradykinesia), tremor
- × **forms:**
 - ⇒ *Primary PS:*
 - **Parkinson's disease**
 - multiple system atrophy, i. e. striatonigral degeneration
 - ⇒ *Secondary PS:*
 - after encephalitis, in arteriosclerosis, after CO poisoning, other toxins, tumors, etc.

Parkinson's disease



x idiopathic

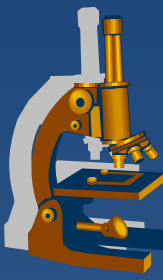
- ⇒ *mostly sporadic (exogenous, mitochondrial dysfunction?), minority familial*
- ⇒ *progressive course (10 years), may be + dementia*

x gross:

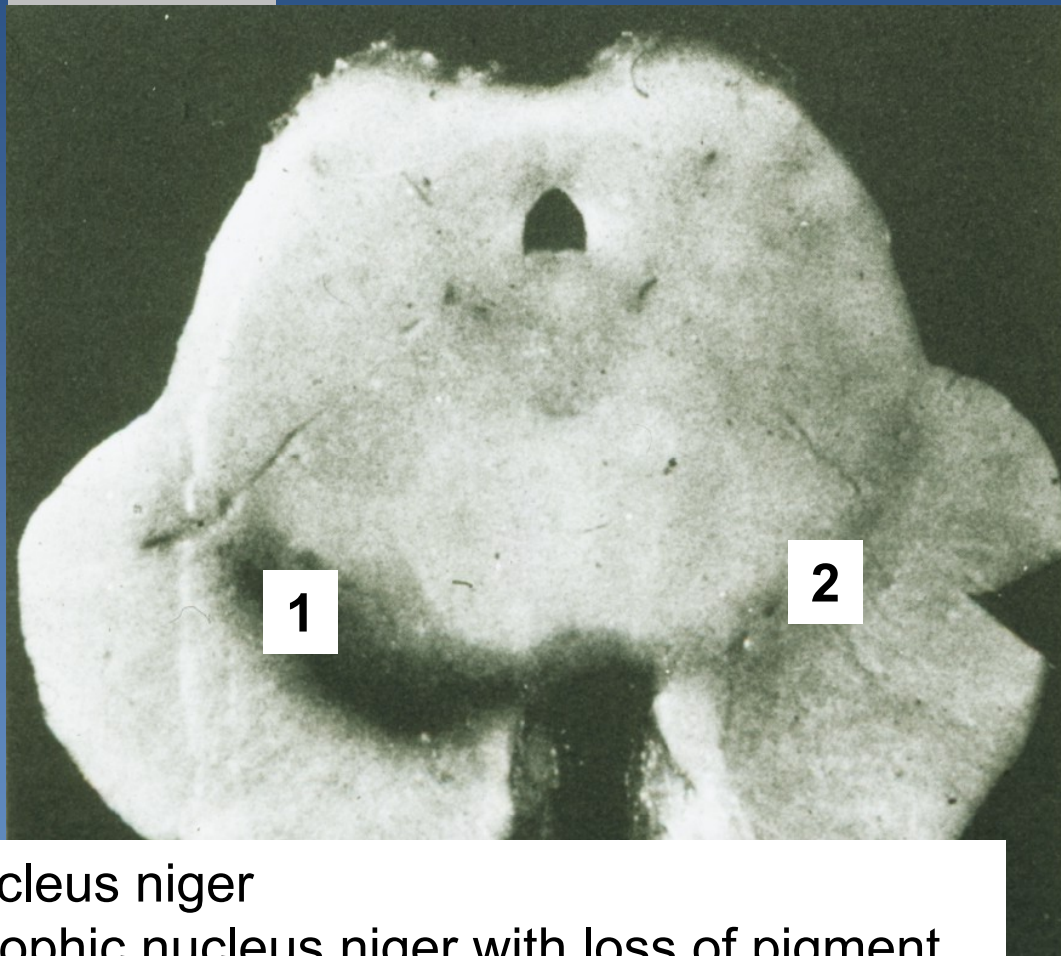
- ⇒ *minor general changes, decolorization of substantia nigra*

x micro:

- ⇒ *loss of neurons → astrogliosis*
- ⇒ *numerous Lewy bodies (α -synuclein) in the cytoplasm of damaged neurons*

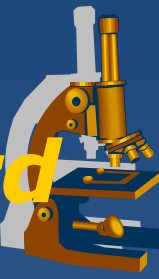


Parkinson's disease - brainstem



1 nucleus nigra
2 atrophic nucleus nigra with loss of pigment

Degenerative diseases of spinal cord



- × **Amyotrophic lateral sclerosis**
⇒ *loss of motor neurons*
- × **Spinocerebellar hereditary ataxia**
- × **Spinal muscular atrophy**

Demyelinating diseases



- ✗ **disintegration of myelin sheaths**
 - ⇒ *axonal regression*
- ✗ primary x secondary (after axonal damage)

- ✗ **multiple sclerosis**
- ✗ progressive multifocal leukoencephalopathy (JC virus)
- ✗ acute disseminated encephalomyelitis
(after viral infection, rarely vaccination)

Multiple sclerosis



✗ more frequent in **women** between 20 and 40

✗ **unclear etiology**

⇒ *autoimmune disorder triggered by exogenous factor (virus?) in susceptible host (genetics)*

✗ **progressive course, episodic acute relapses** with neurologic deficit

⇒ *variable presentation*

⇒ *sensoric, sensitive, motor dysfunction*

⇒ *ends in severe psychomotoric disturbance + cachexia*

⇒ *trophic ulcers, pressure sores, sepsis*

Multiple sclerosis



× gross:

- ⇒ *white (less commonly gray) matter with multiple, well-demarcated, gray-tan solid lesions – plaques*
 - variable size mm-cm
- ⇒ **Mostly *periventricular***, but also in optic fasciculus....

× micro:

- ⇒ **Active plaques, early (pink, softer)**
 - myelin reduction, perivascular monocyctic infiltrate + activation of macrophages → axonal destruction
- ⇒ **Inactive plaques:**
 - disappearance of oligodendrocytes and myelin, reactive gliosis, persistence of numerous nerve fibers without inflammation

Multiple sclerosis



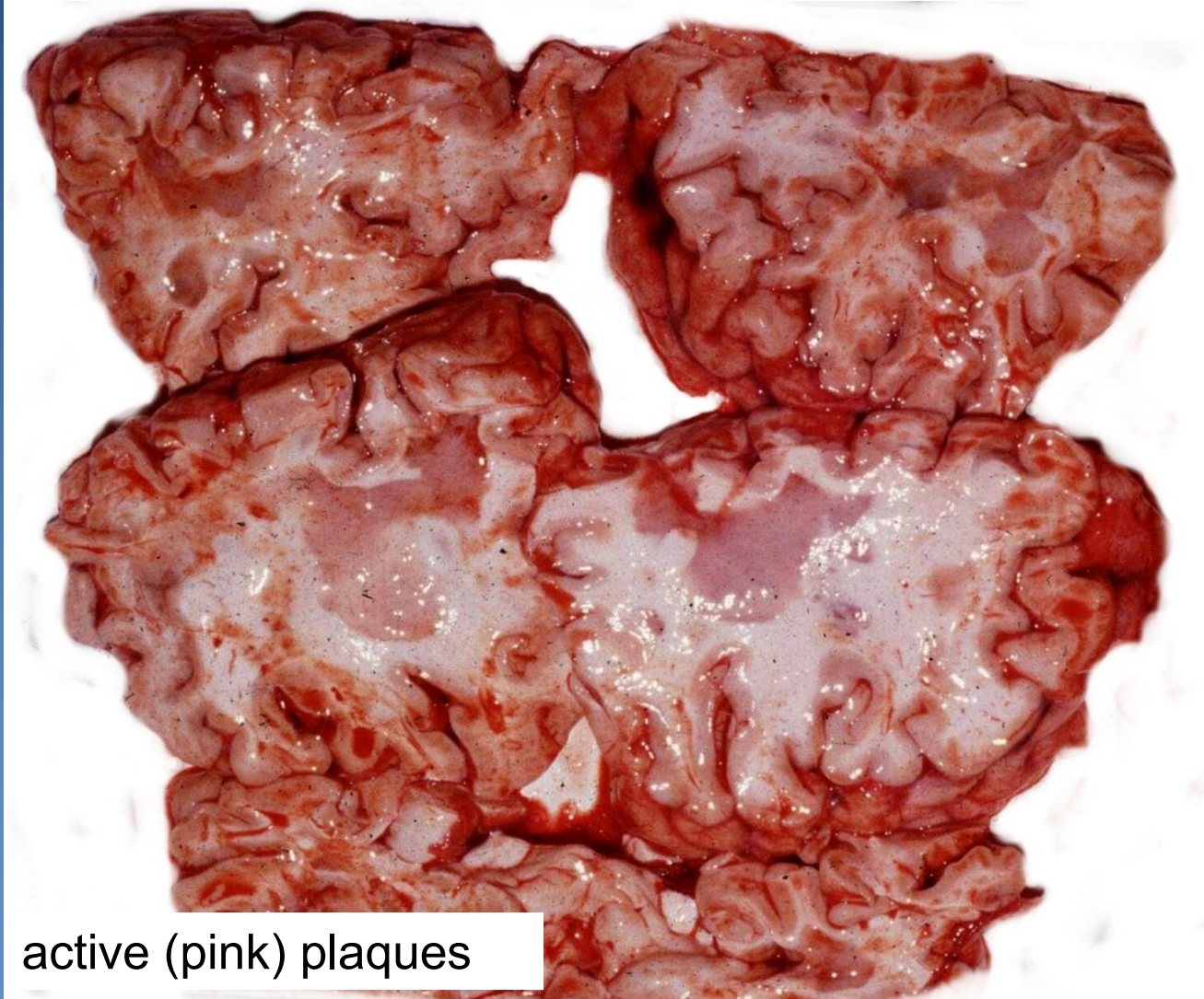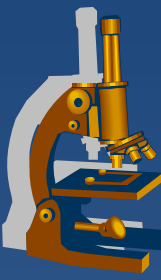
× Acute form

- ⇒ *fatal within a few weeks / months*
- ⇒ *may be in children*
- ⇒ *pink lesions (plaques) in white matter of the brainstem, spinal cord*

× Neuromyelitis optica

- ⇒ *fasciculus opticus → bilateral blindness*
- ⇒ *necrotic centre of plaques*

Multiple sclerosis



active (pink) plaques

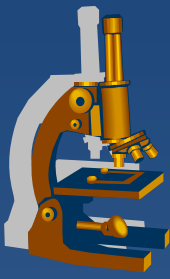


Tumors of the nervous system

neuroectodermal tumors

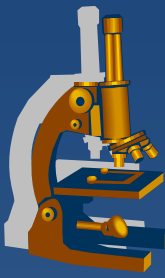


- x tumors of the central nervous system**
- x peripheral neuroectodermal tumors**
- x tumors of the autonomic nervous system**
- x melanocytic tumors**



INTRACRANIAL TUMORS

Intracranial tumors



- ✘ primary extracerebral (meningioma, schwannoma, neurofibroma)
- ✘ primary intracerebral (gliomas – astrocytoma, oligodendroglioma, ependymoma, neuronal tumors, primitive neuroectodermal tumors PNET – medulloblastoma, endocrine t., vascular t., lymphomas)
- ✘ secondary tumors – metastases, leukemic infiltration

Intracranial tumors



- ✘ focal signs according to the localisation (excitation, later loss of function)
- ✘ general raised intracranial pressure (seizures, headache, visual defects, nausea etc.)
- ✘ histologically benign brain tumors can kill the patient – growing in a position where they cannot be completely resected !

Metastatic tumors of the CNS



- ✗ CNS metastases in 25% of cancer deaths
- ✗ most common origin in adults
 - ⇒ lung ca (*small cell, adenocarcinoma*)
 - ⇒ breast ca
 - ⇒ melanoma
 - ⇒ renal
 - ⇒ colorectal
- ✗ most common origin in children
 - ⇒ leukaemia, lymphoma
 - ⇒ osteosarcoma, rhabdomyosarcoma

Biologic potential



- ✘ possible infiltrating growth of histologically benign tumors
- ✘ localisation highly important (grave consequences even in benign tumors)
- ✘ rare metastases outside the CNS

Age factor



- ✗ in children - mostly primary intracerebral
incl. PNET; infratentorially (posterior fossa)
- ✗ in adults – number of secondary t. rises
with age; mostly supratentorially

classification of intracranial tumors



- × **Astrocytic tumors**
- × **Oligodendroglial tumors**
- × **Ependymal tumors**
- × **Choroid plexus tumors**
- × **Neuronal/glioneuronal tumors**
- × **Pineal tumors**
- × **Embryonal tumors**

Astrocytic tumors




- x Diffuse (fibrillary) astrocytoma (Grade II)**
- x Anaplastic astrocytoma (Grade III)**
- x Glioblastoma (Grade IV)**

- x Pilocytic astrocytoma (Grade I)**
- x Pleomorphic xanthoastrocytoma (Grade II)**
- x subependymal giant cell astrocytoma (Grade I)**

Astrocytic tumors


Diffuse (fibrillary) astrocytoma



- × low grade - grade II/IV (WHO)
- × slow growth, high degree of differentiation
- × !! intrinsic tendency for malignant progression to anaplastic astrocytoma → glioblastoma
- × in all age groups
 - ⇒ mostly young adults, $M > F$
- × **Anywhere in the brain** - poorly demarcated or infiltrative tumor

Astrocytic tumors

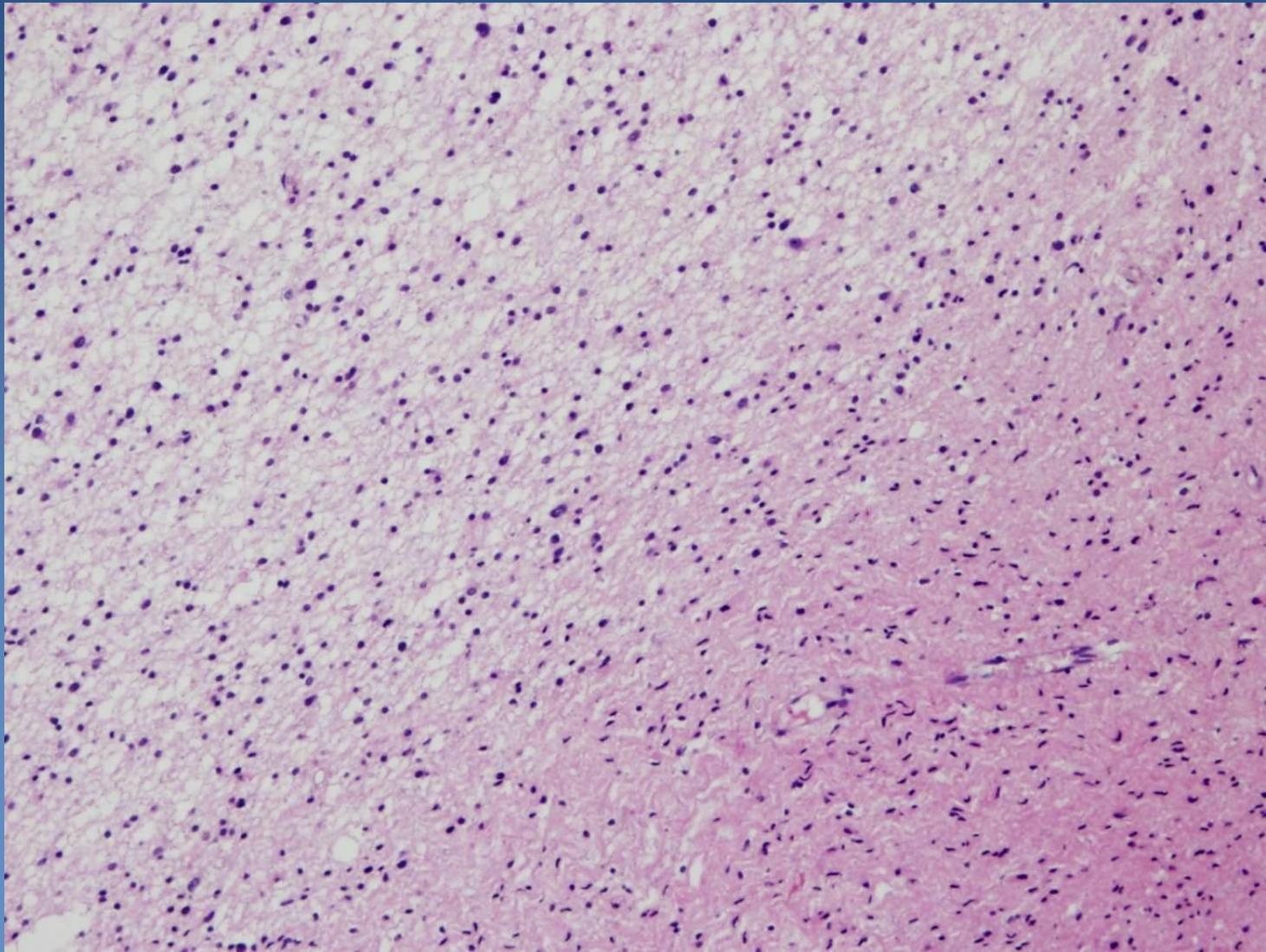
Diffuse (fibrillary) astrocytoma



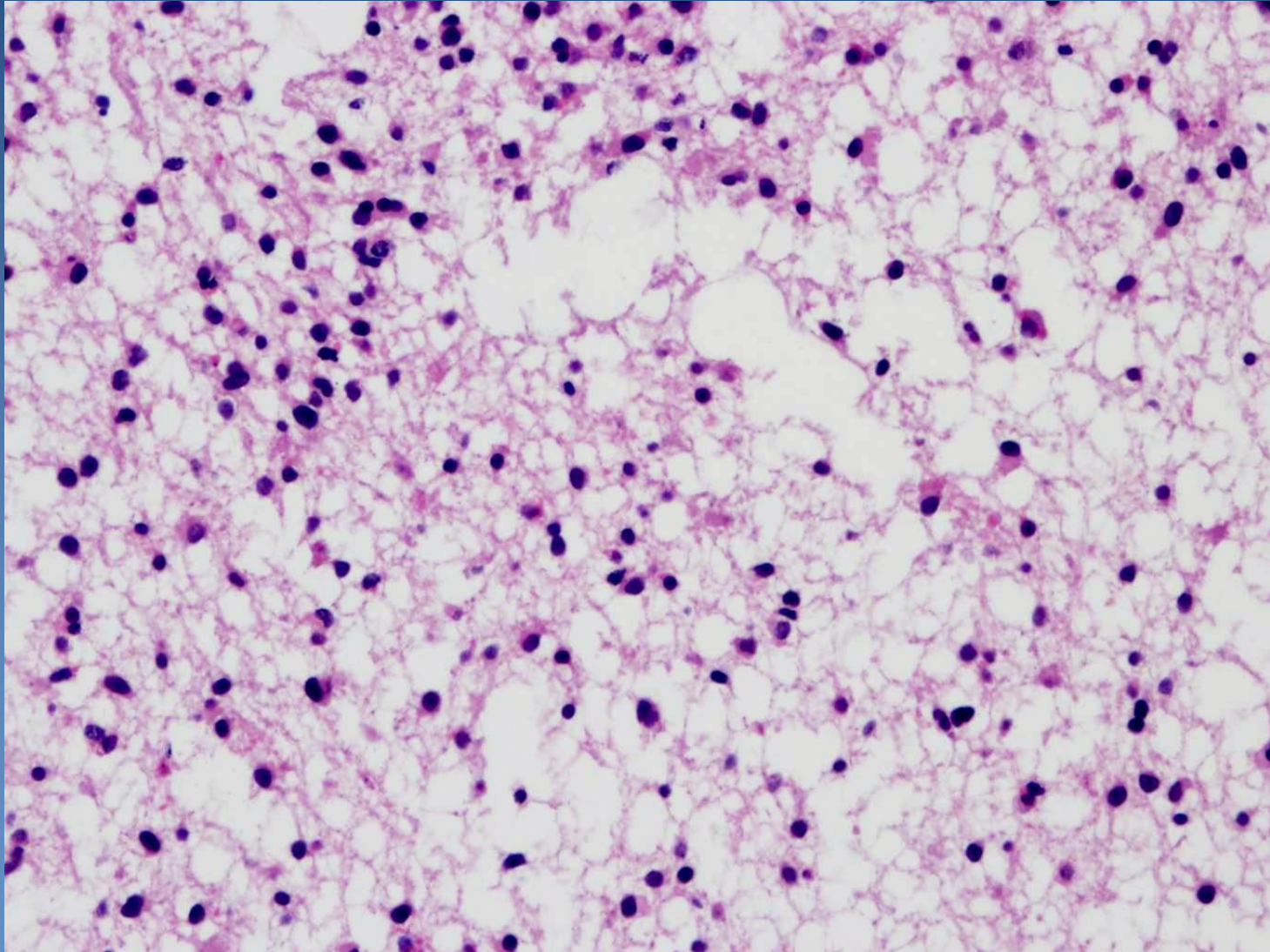
xmicro:

- ⇒ *well-differentiated fibrillary, gemistocytic (mass of eosinophilic cytoplasm), rare protoplasmic astrocytes*
- ⇒ *slightly increased cellularity in comparison with normal tissue tumor*
- ⇒ *stroma often microcystic*
- ⇒ *usually no mitotic activity*
- ⇒ *without necrosis or microvascular proliferation*

Diffuse (fibrillary) astrocytoma



Diffuse (fibrillary) astrocytoma



Astrocytic tumors

Glioblastoma



- x grade IV/IV (WHO) – anaplastic glioma**
- x most common and most malignant primary brain tumor**
- x typically in adults, usually 45-75 years of age**
- x mostly de novo – primary glioblastoma**
 - ⇒ *short history, >60 years of age*
- x possible transformation from preexisting astrocytoma gr. II or III – secondary glioblastoma,**
 - ⇒ *history 1-10 yrs, around 45 years of age*
- x rapidly growing, infiltrative (very poor prognosis)**
- x gross:**
 - ⇒ *variable appearance – white and firm regions, yellow and soft parts, foci of necrosis, cysts, hemorrhages*

Astrocytic tumors

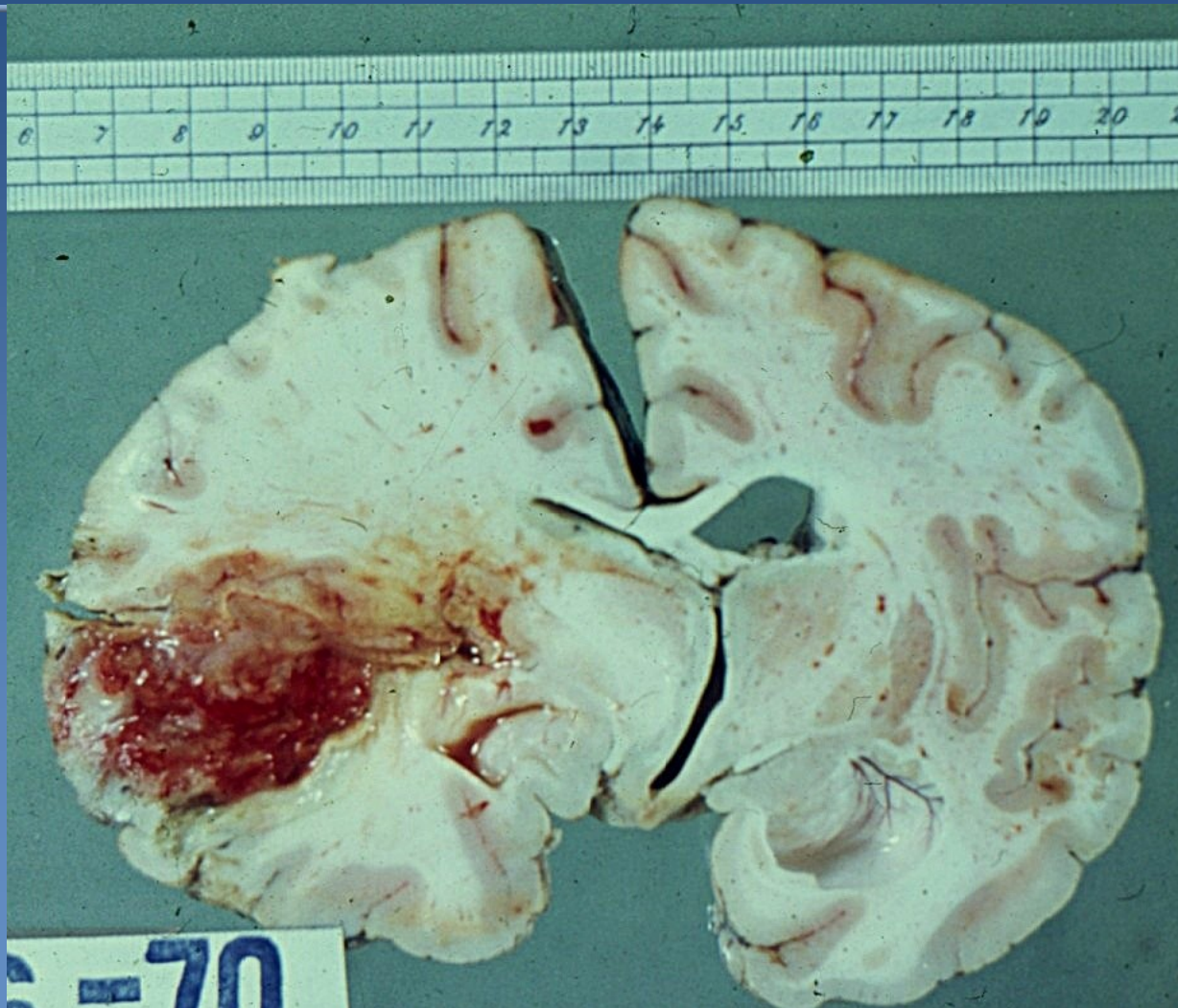
Glioblastoma



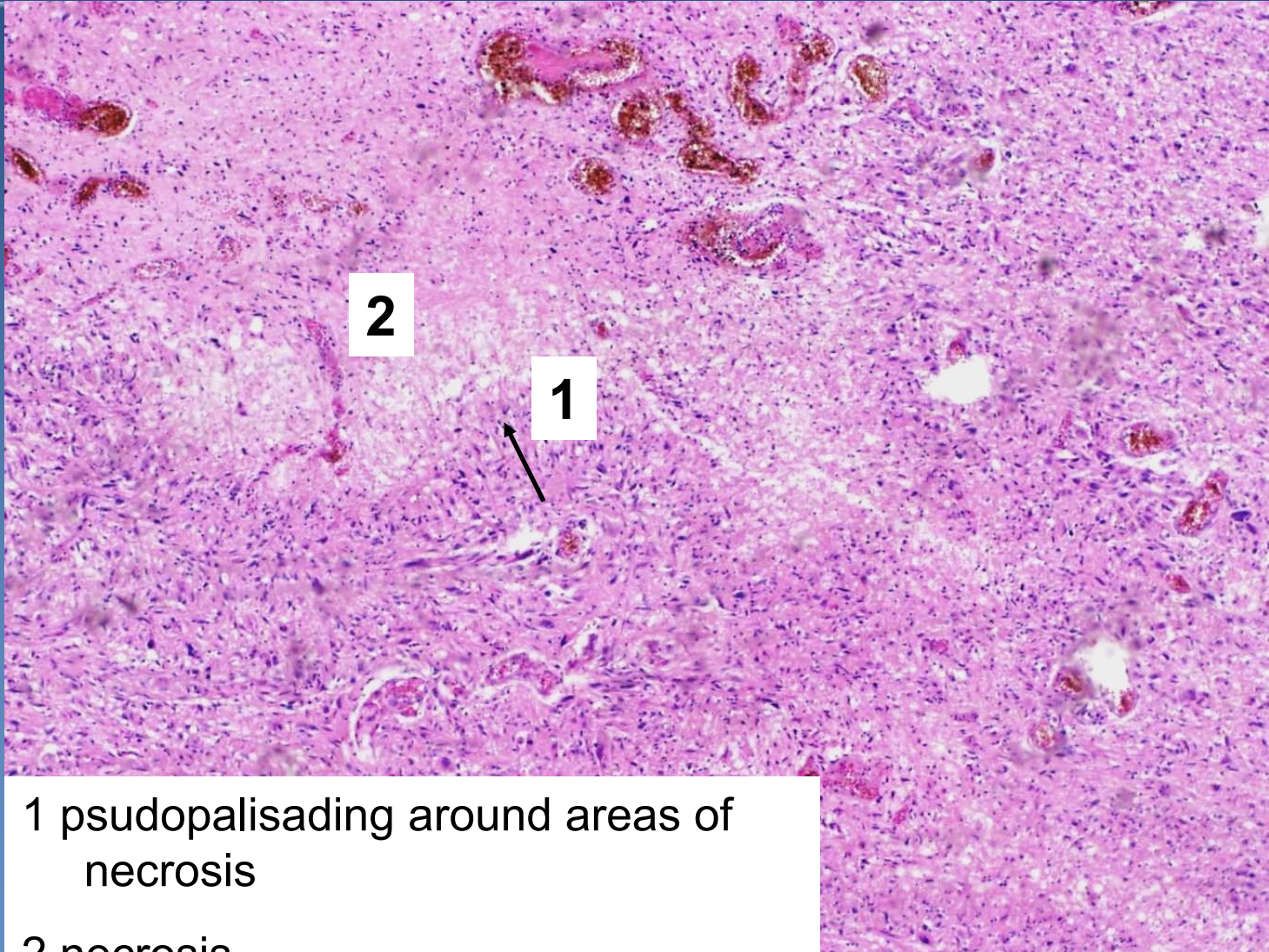
xmicro:

- ⇒ *pleomorphic tumor cells - severe cellular and nuclear atypia*
- ⇒ *tumor is regionally heterogeneous*
 - alternation of pleiomorphic and more regularly arranged areas
- ⇒ *high mitotic rate*
- ⇒ ***conspicuous microvascular proliferation and / or necrosis***
- ⇒ *pseudopalisading of tumor cells around necrotic areas*

Glioblastoma



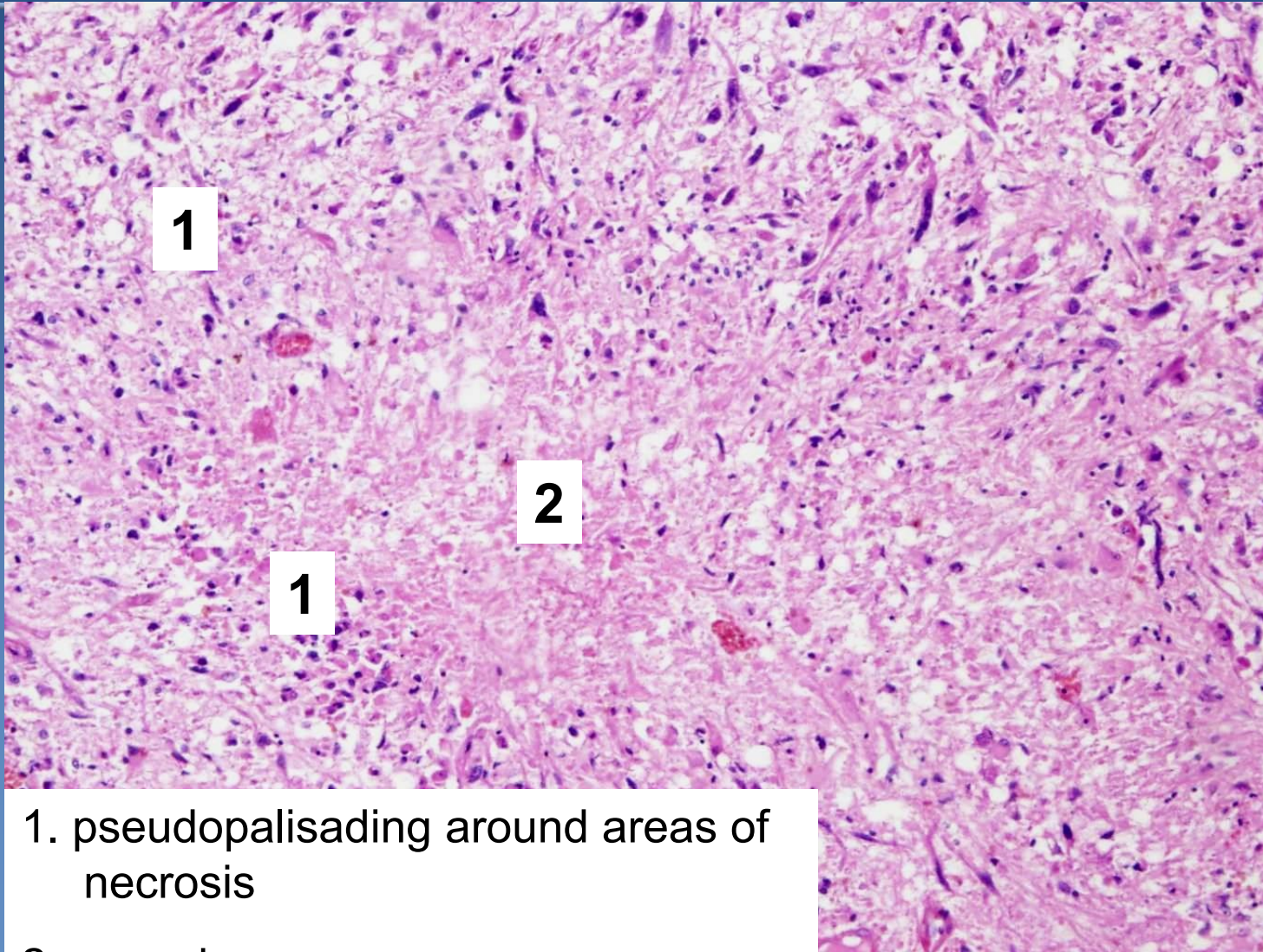
Glioblastoma



1 pseudopalisading around areas of
necrosis

2 necrosis

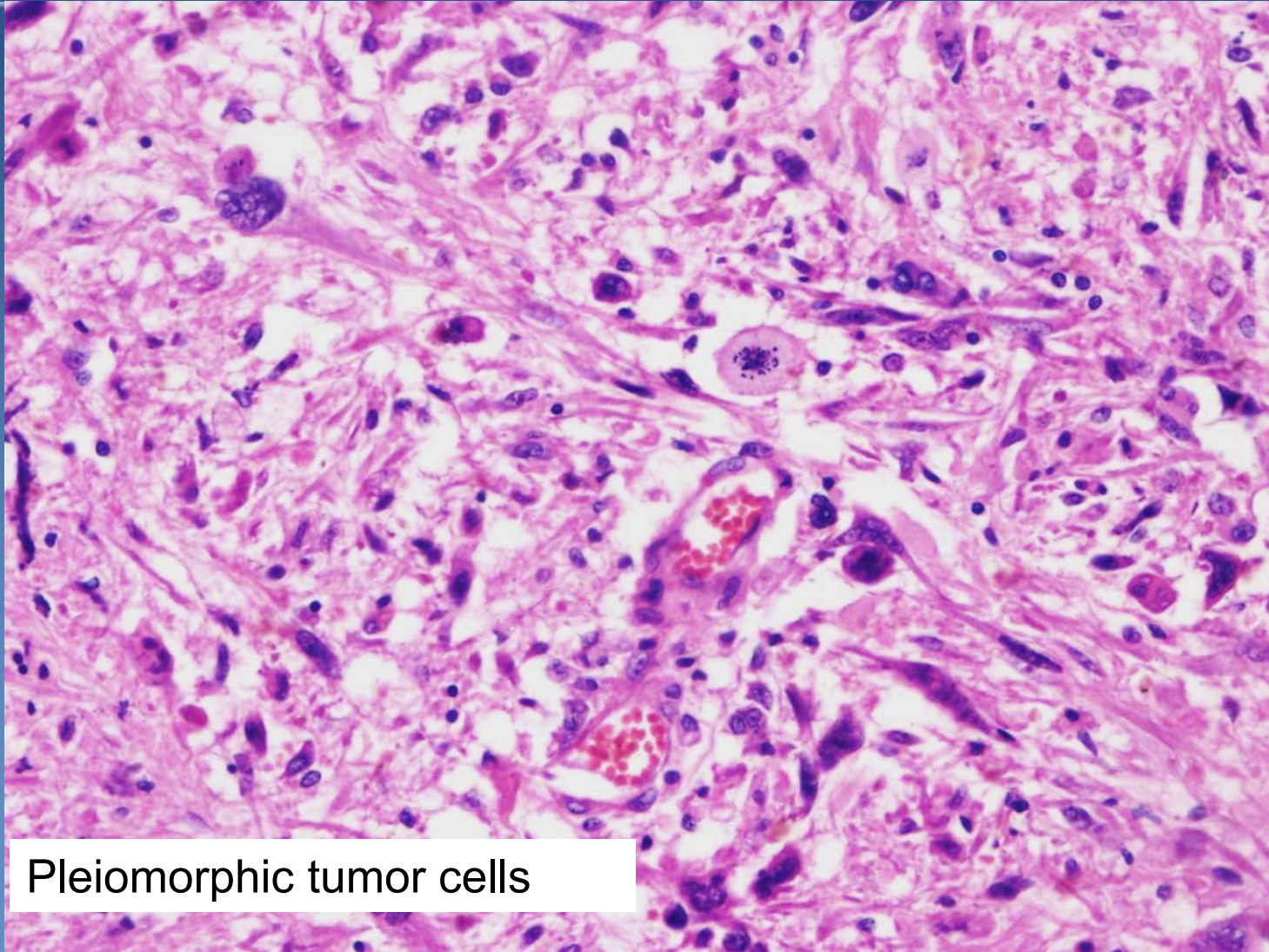
Glioblastoma



1. pseudopalisading around areas of necrosis

2 necrosis

Glioblastoma



Pleiomorphic tumor cells

Astrocytic tumors

Pilocytic astrocytoma



× **grade I (WHO)**

× **grows very slowly**

× growth begins in childhood - clinical signs manifest around age of 20 (and later); in cerebellum or near III. and IV. ventricle, resection possible

× **micro:**

⇒ ***biphasic structure solid / cystic***

- compact region with bipolar tumor astrocytes with eosinophilic Rosenthal fibers
- microcystic, sparsely cellular areas with multipolar tumor cells with granular eosinophilic bodies and eosinophilic globules

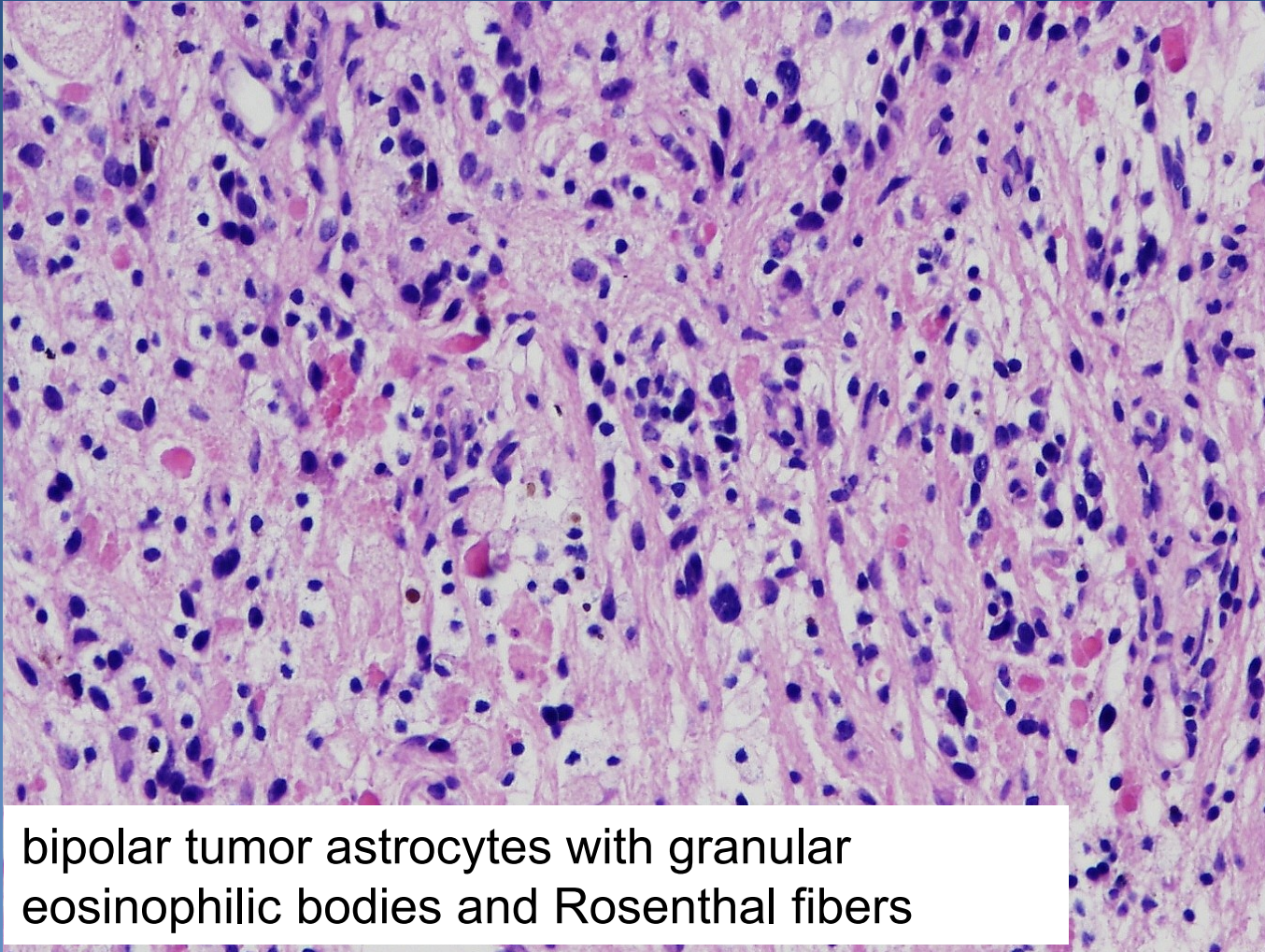
⇒ *degenerative atypia and calcification*

⇒ *infrequent mitosis, sm. nuclear pleiomorphism and hyperchromasia*

⇒ *glomeruloid vascular endothelial proliferation often*

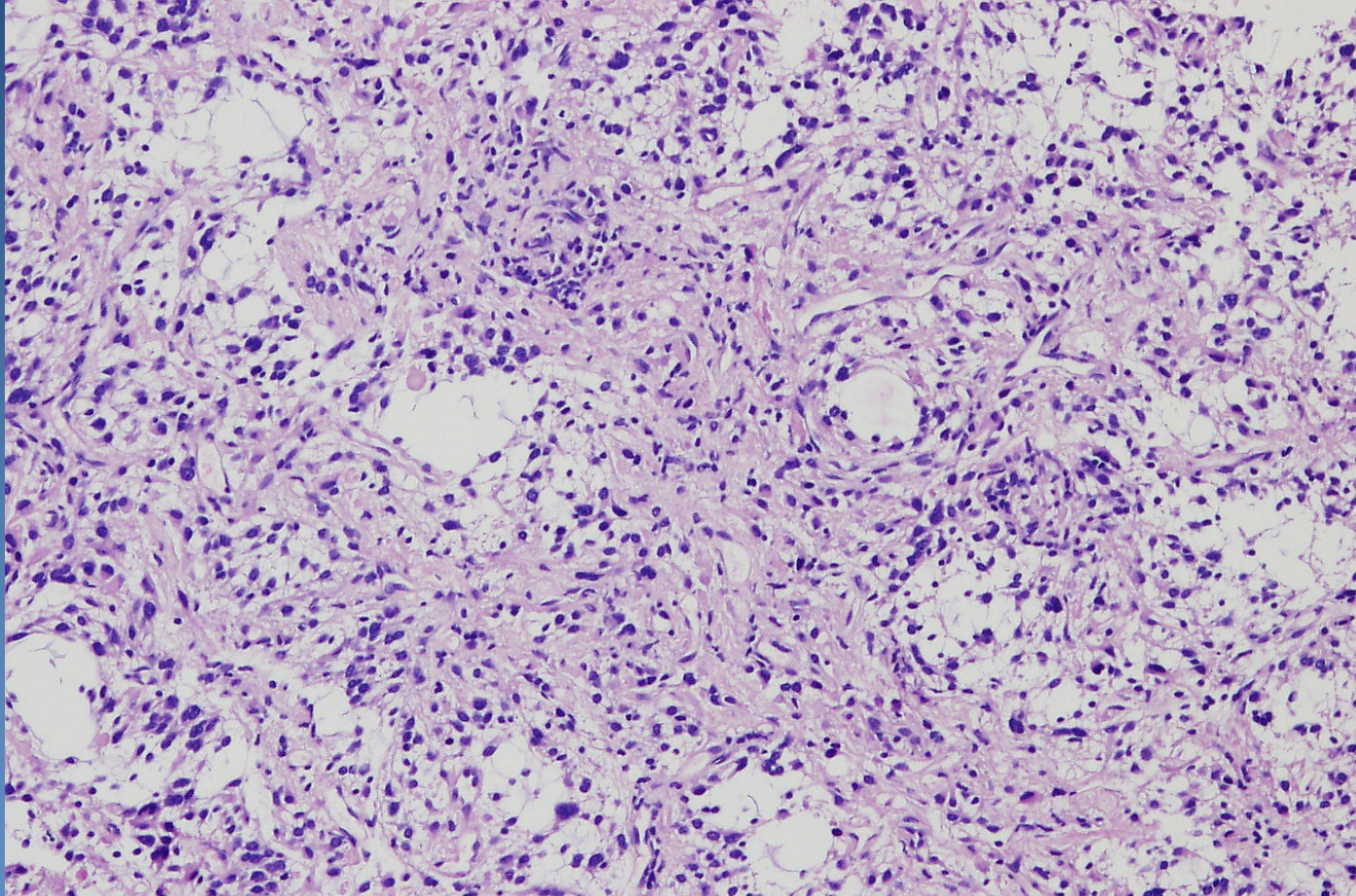
⇒ *small necrosis possible*

Pilocytic astrocytoma



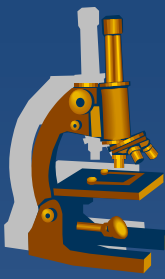
bipolar tumor astrocytes with granular eosinophilic bodies and Rosenthal fibers

Pilocytic astrocytoma



Microcystic areas with multipolar tumor cells

Oligodendroglial tumors



- × **Oligodendroglioma (Grade II/IV)**
- × Anaplastic oligodendroglioma (Grade III)
- × Mixed oligoastrocytomas (Grade II, III)

Oligodendroglial tumors

Oligodendroglioma



× grade II (WHO)

× in adults; slow growth

× Micro:

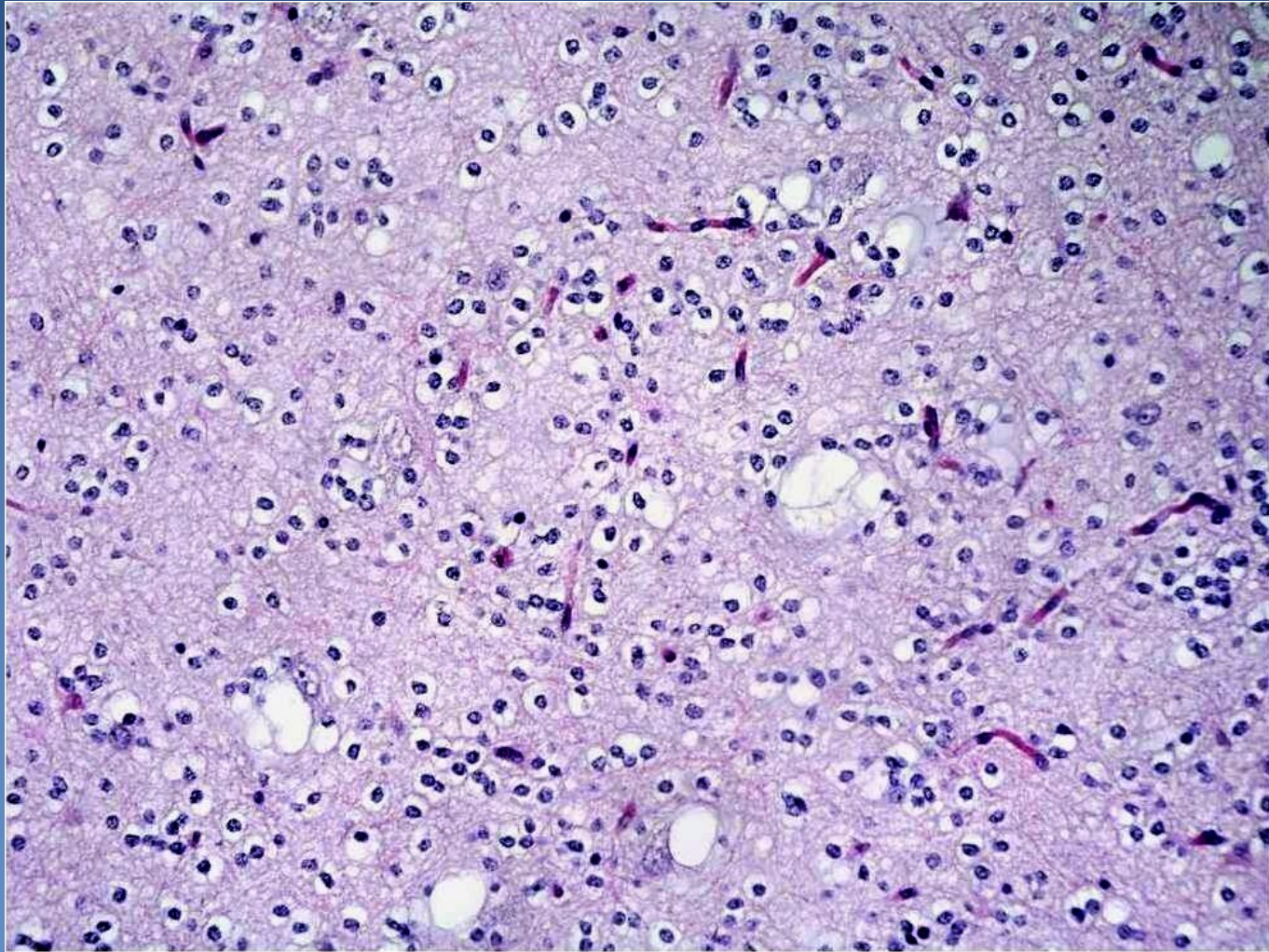
⇒ *uniform tumor cells with round nuclei and perinuclear halos*

⇒ *microcalcifications (X-ray)*

⇒ *areas of mucoid degeneration*

⇒ *abundant branching capillaries*

Oligodendroglioma



Ependymal tumors



- × Ependymoma (grade II)
- × Anaplastic ependymoma (grade III)
- × Myxopapillary ependymoma (grade I)
- × Subependymoma (grade I)

Ependymal tumors

Ependymoma



x grade II (WHO)

x in children - usually around IV. ventricle, in adults - spinal cord, with neurofibromatosis type 2

x micro:

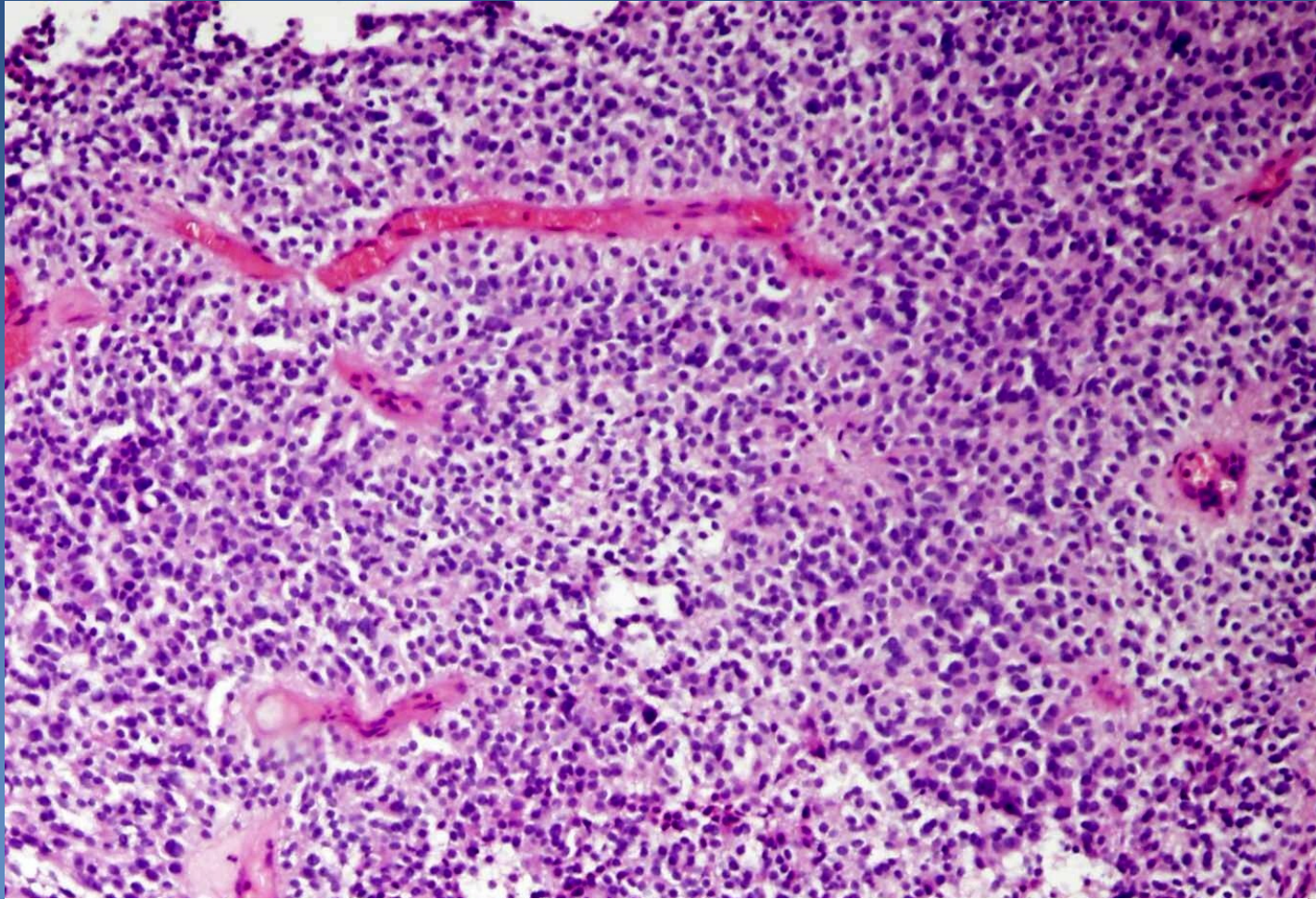
⇒ *fusiform cells with long processes, uniform round to oval nuclei*

⇒ *fine fibrillary background*

⇒ *canalicular formations, perivascular pseudorosettes*

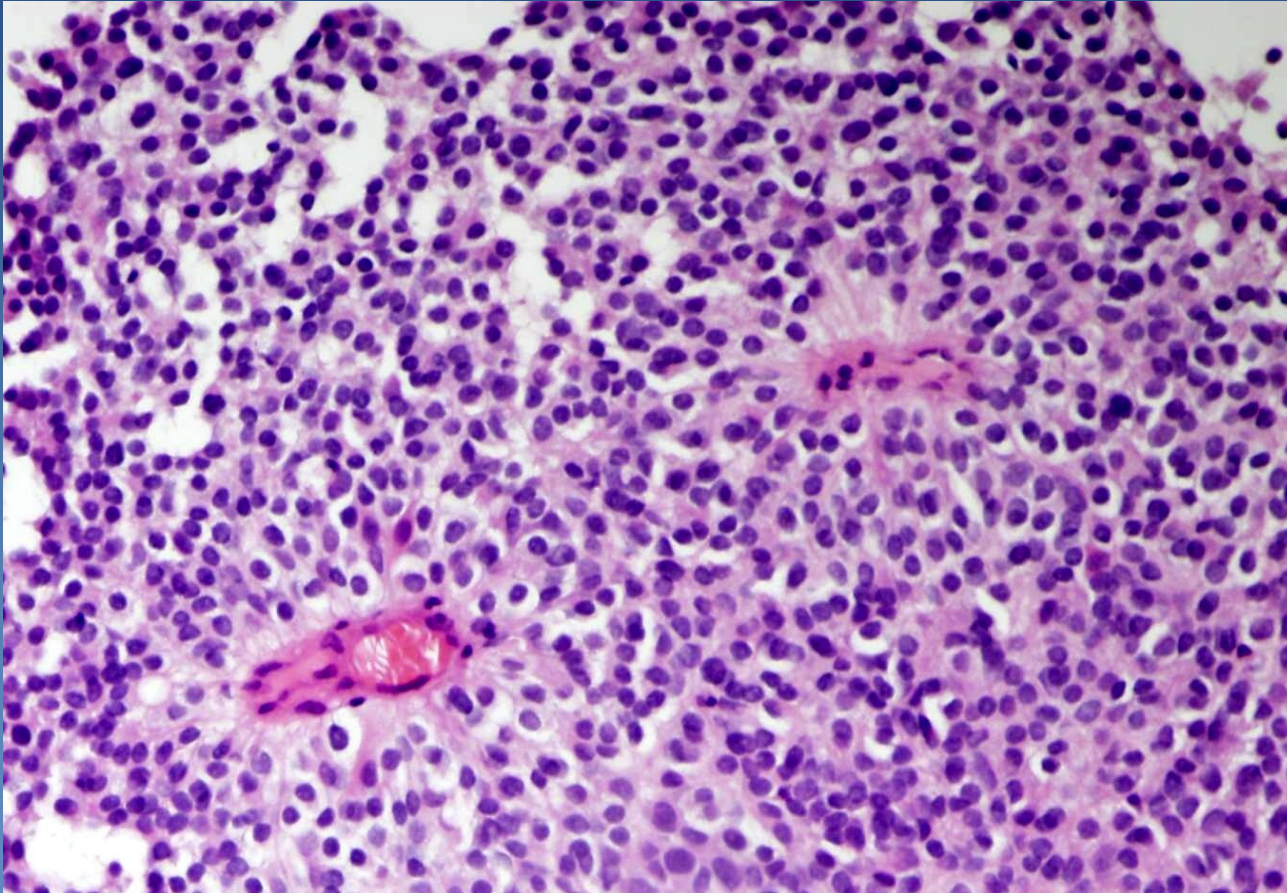
⇒ *sporadic or no mitotic figures*

Ependymoma



Perivascular pseudorosettes, uniform population of tumor cells

Ependymoma



Perivascular pseudorosettes, uniform population of tumor cells

Tumors of the choroid plexus



- × Choroid plexus papilloma (grade I)
- × Atypical choroid plexus papilloma (grade II)
- × Choroid plexus carcinoma (grade III)

Embryonal tumors



x Primitive aggressive malignant tumors of childhood

x Tumors "of small blue cells" grade IV

⇒ *Medulloblastoma*

⇒ *Supratentorial primitive neuroectodermal tumor*

⇒ *Ependymoblastoma*

⇒ *Retinoblastoma*

⇒ ...

Embryonal tumors

Medulloblastoma



x grade IV (WHO)

x tumor of first two decades of life

x highly malignant but radiosensitive

x in cerebellum, midline in children

⇒ *local infiltration, meningeal and CSF spread → hydrocephalus*

⇒ *gross – focal pink/grey tumor*

x micro:

⇒ *highly cellular*

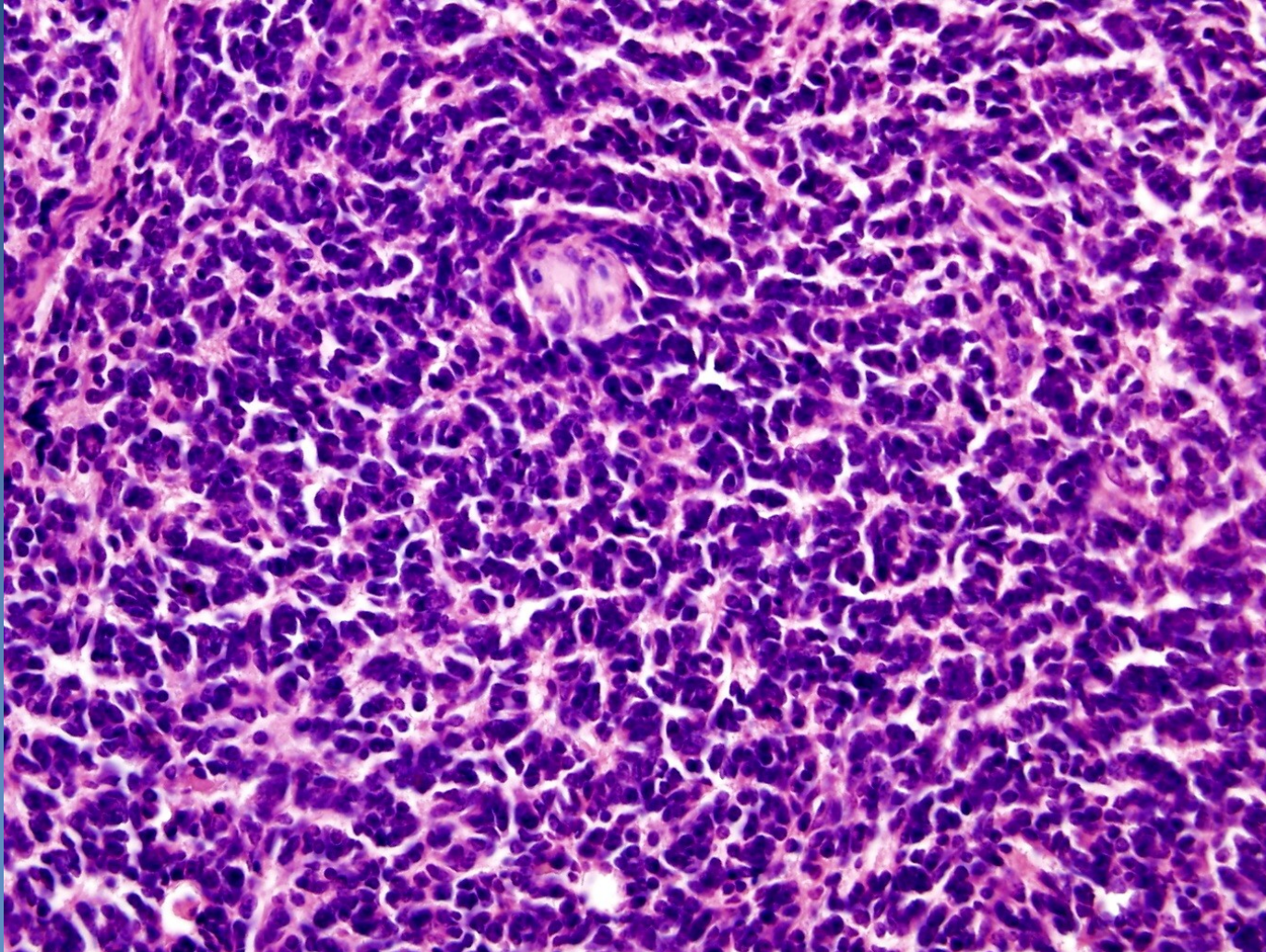
⇒ *small hyperchromatic nuclei, carrot-shaped*

⇒ *neuroblastic Homer-Wright's rosettes*

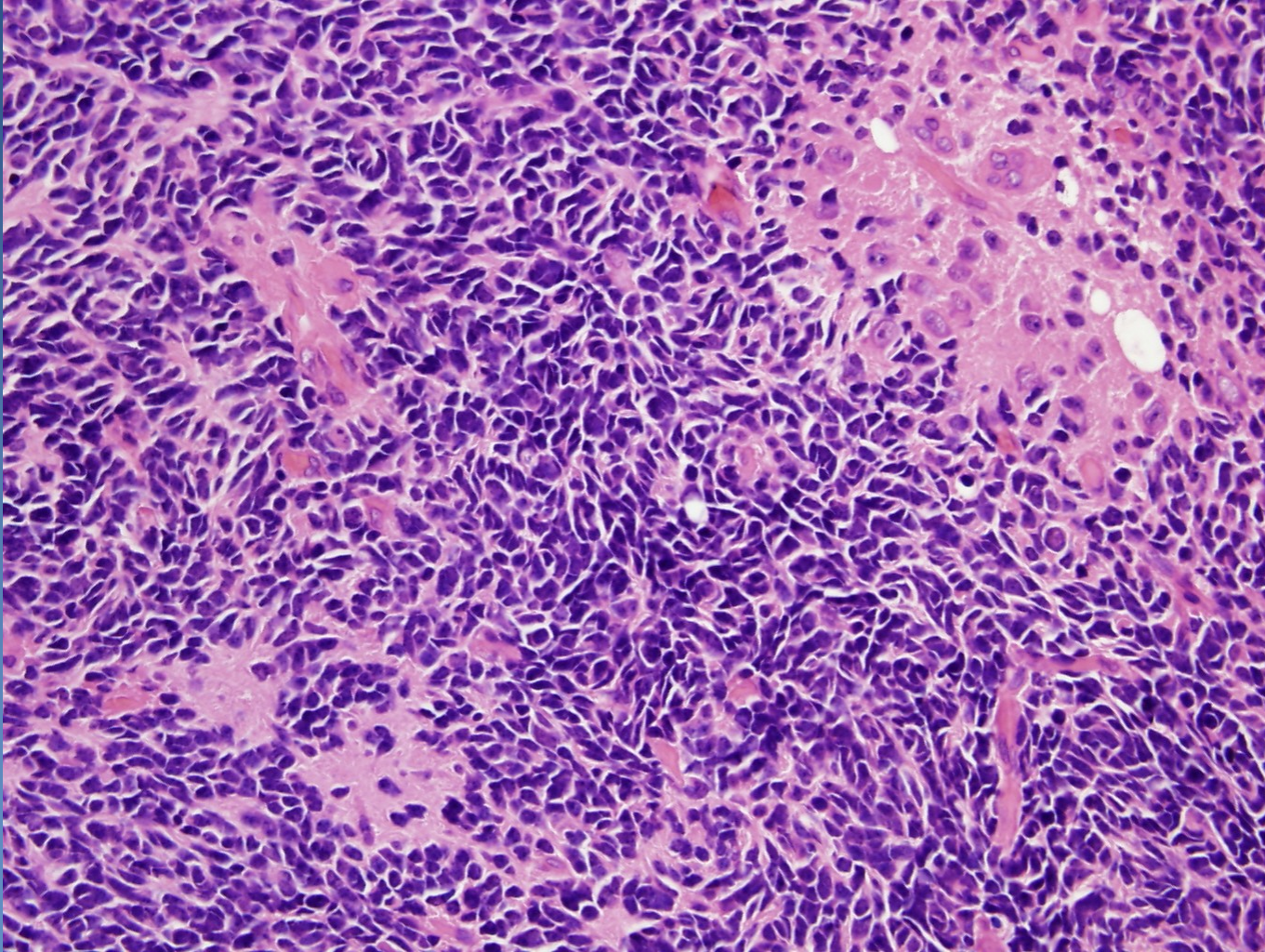
⇒ *high mitotic activity*

⇒ *differentiation to neuronal / other cells possible*

Medulloblastoma



Medulloblastoma



Tumors of the meninges



× Meningioma (Grade I)

- ⇒ *(Syncytial (+)*
- ⇒ *Fibroblastic (+)*
- ⇒ *Transitional (+)*
- ⇒ *Psammomatous*
- ⇒ *Angioblastic*
- ⇒ *Microcystic)*

× (Atypical meningioma, chordoid and clear cell (Grade II)

× Rhabdoid, papillary, anaplastic (Grade III)

×+ solitary fibrous tumor of meninges,
(hemangiopericytoma), sarcomas,....)

Tumors of the meninges

Meningioma



- x grade I (WHO classification)**
- x usually benign, common (20% of all intracranial tumors), adults**
- x predominantly on the hemispherical convexity**
- x origin from arachnoidal cap cells**

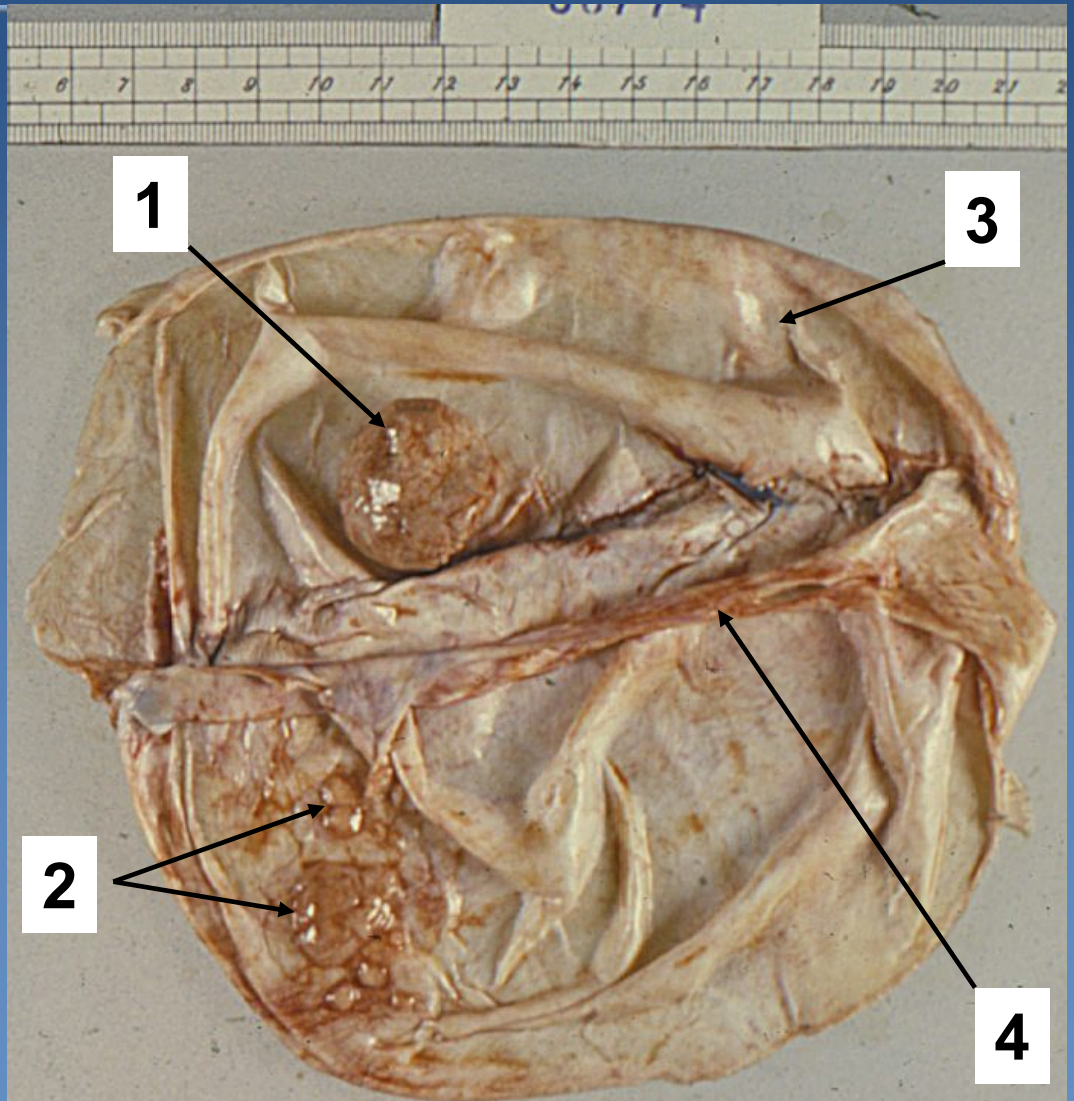
- x gross:**
 - ⇒ *usually solitary, well demarcated, firm, whorl-like pattern on cut surfaces*
 - ⇒ *attached to the dura, cortical compression, rare skull invasion*

- x micro:**
 - ⇒ *highly variable*
 - ⇒ *whorls, bundles*
 - ⇒ *common laminated calcific concretions – psammoma bodies (X-ray)*

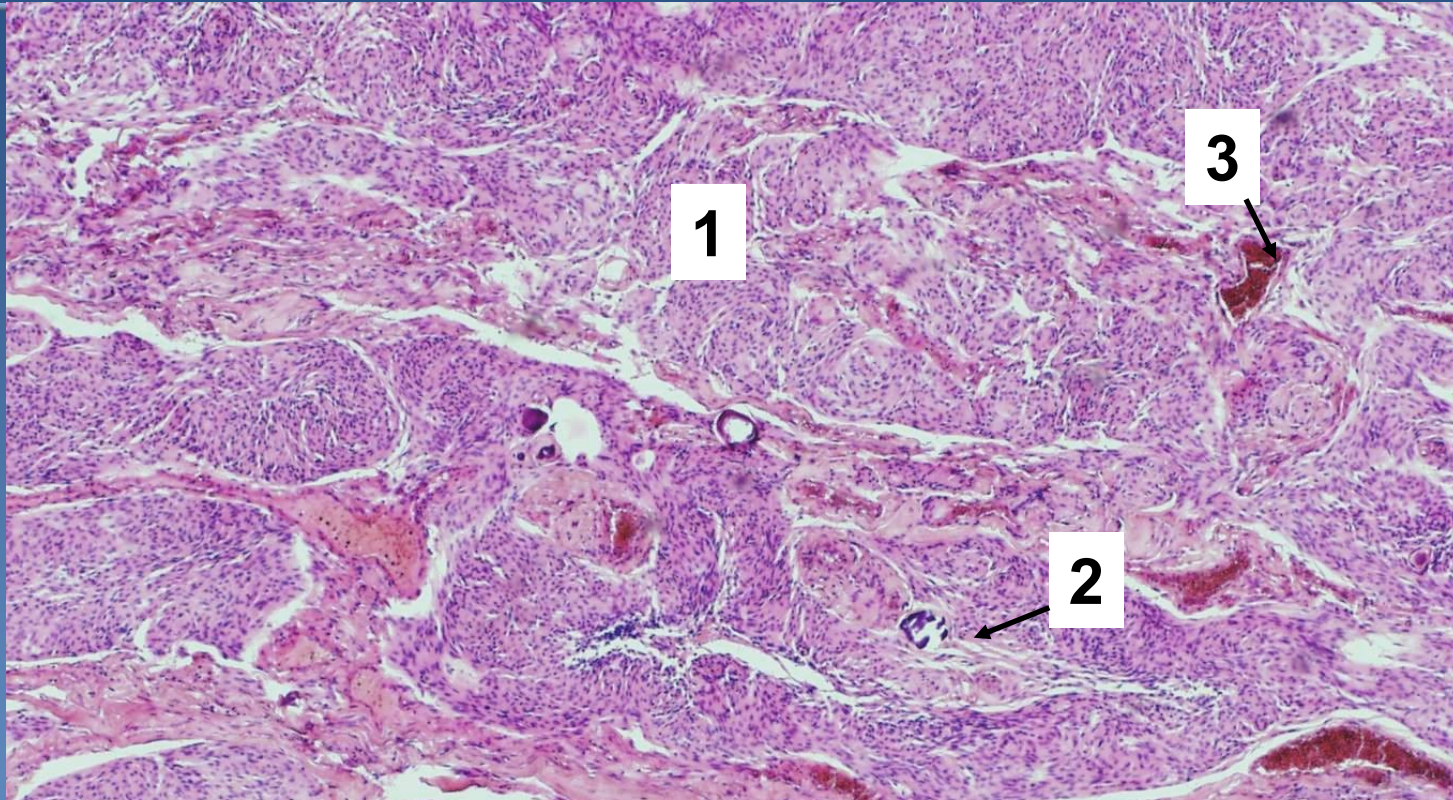
Meningioma



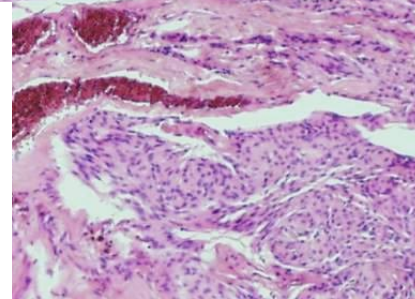
1. Lobular meningioma
2. Flat meningiomas
3. Dura mater
4. Falx cerebri



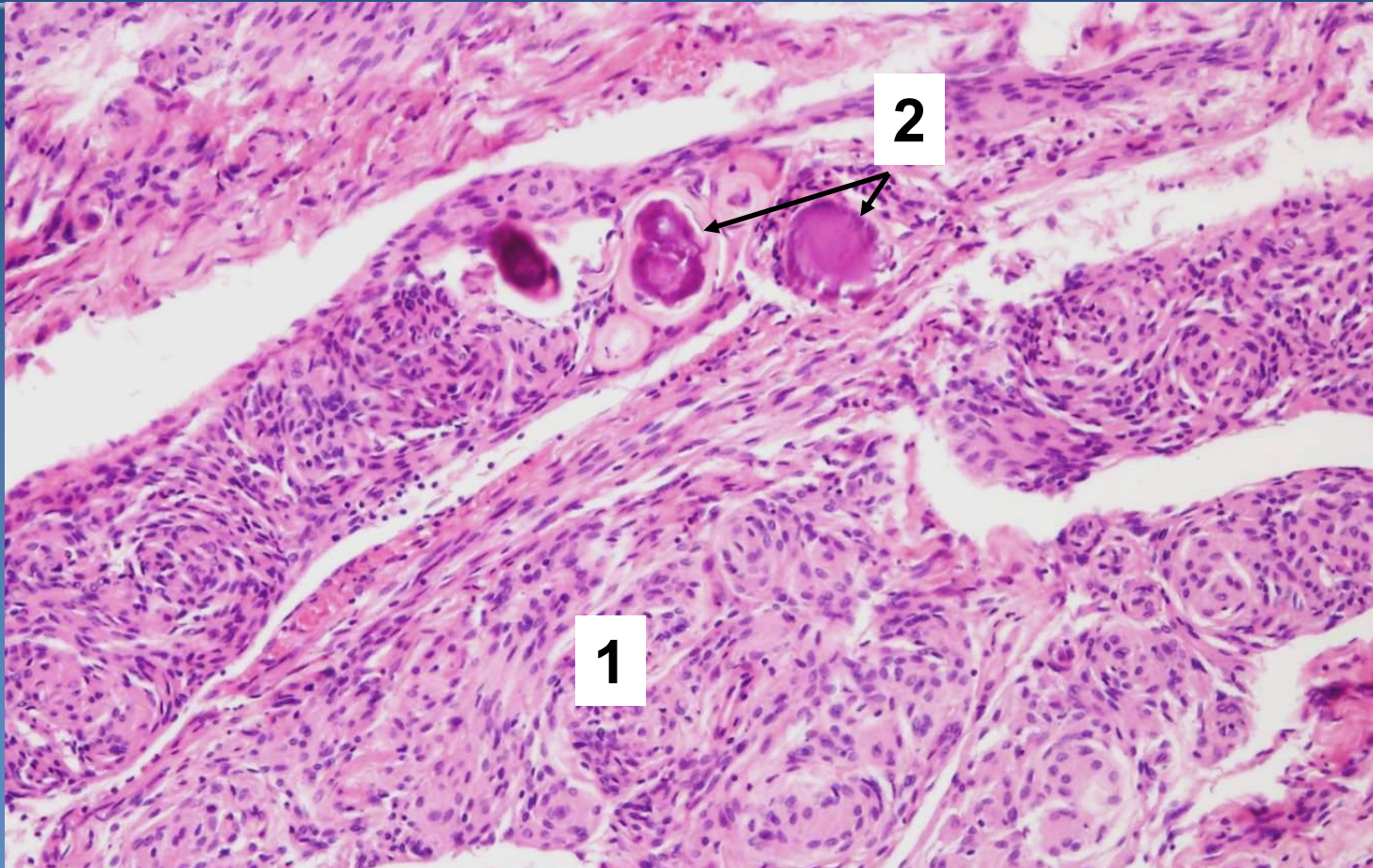
Meningioma



1. whorl formations of meningothelial cells
2. psammoma bodies
3. vessels



Meningioma



1. whorl formations of meningothelial cells
2. psammoma bodies



Peripheral nerve sheath tumors

Benign tumors



- × Schwannoma
- × neurofibroma (solitary; multiple - neurofibromatosis type 1)
- × perineurioma
- × neurothecoma
- × granulosa cell tumor

Schwannoma



- peripheral myelinisation

- ✗ in connection with **peripheral nerve**
- ✗ **intracranial - cerebellopontine angle – VIII. nerve „acoustic neuromas**
- ✗ **compression (excitation, later loss of function)**

✗ **gross:**

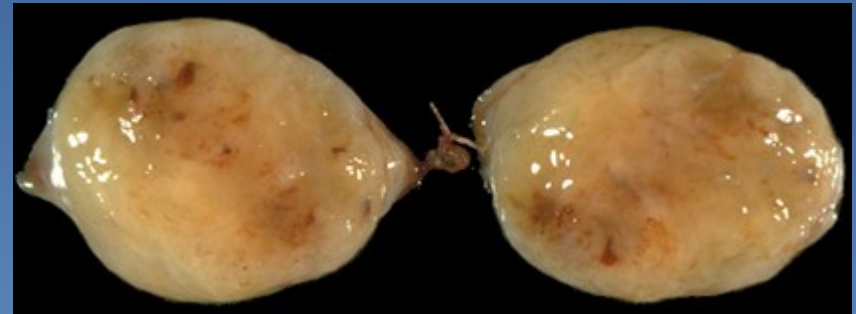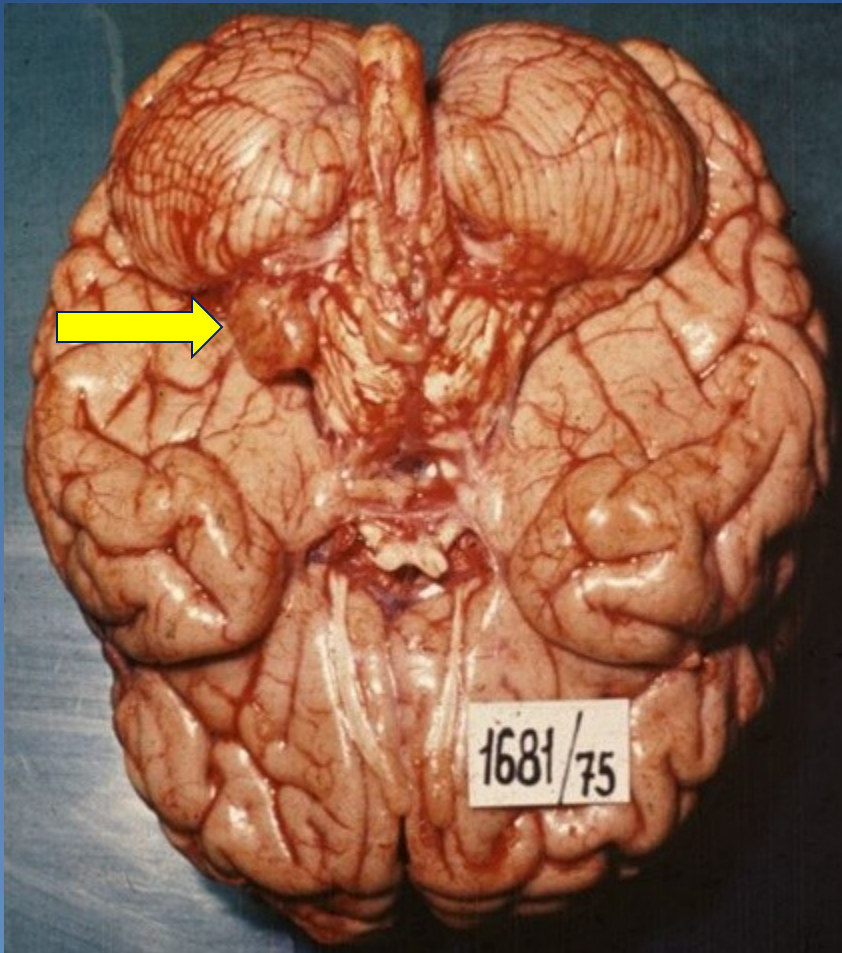
⇒ *well-circumscribed encapsulated lesion, may be attached to the nerve*

✗ **micro:**

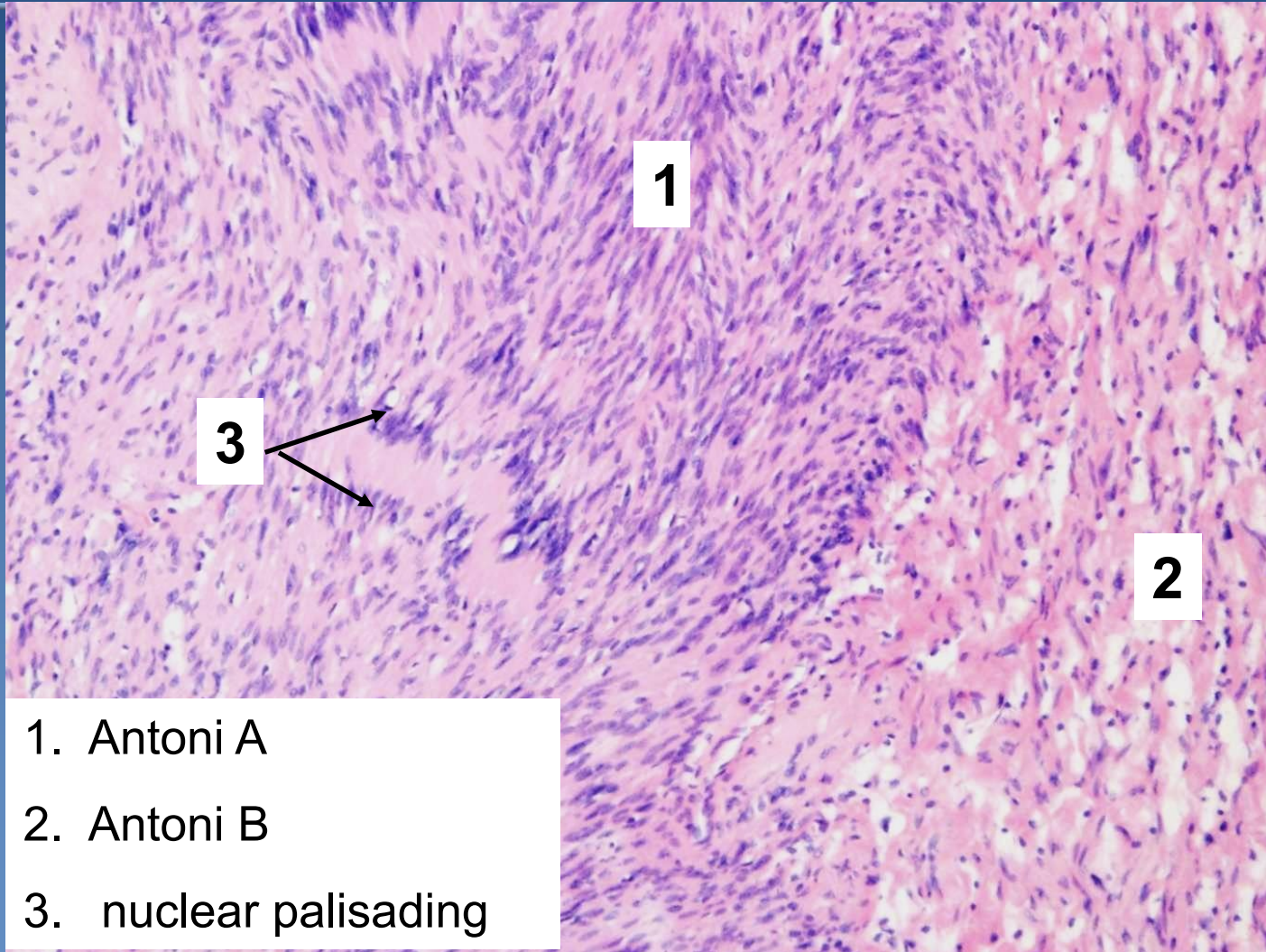
⇒ *cellular areas of densely packed spindle cells (**Antoni A pattern**, Verocay bodies – nuclear palisading)*

⇒ *intermixed with looser, myxoid regions (**Antoni B pattern**)*

Schwannoma

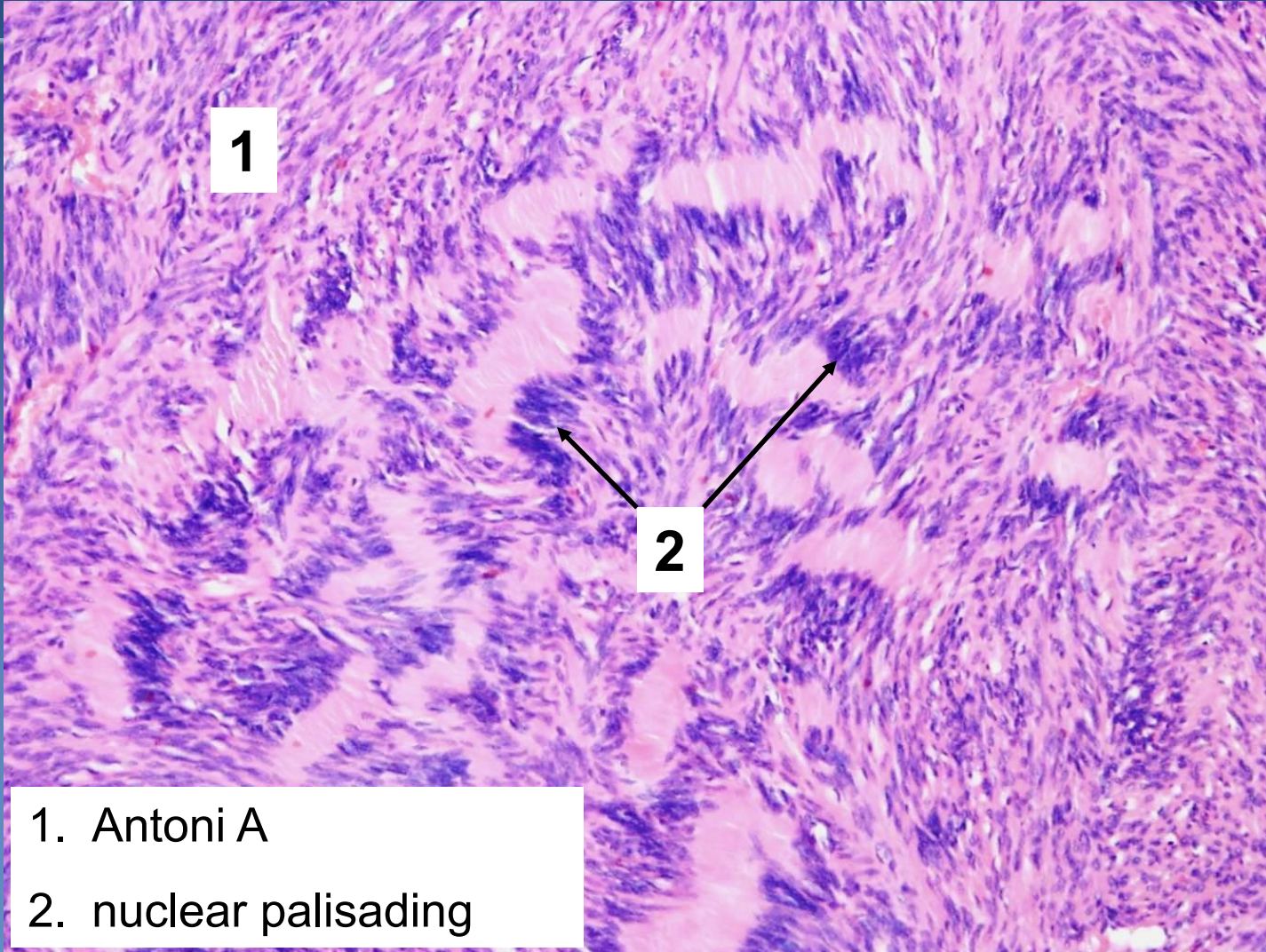


Schwannoma



1. Antoni A
2. Antoni B
3. nuclear palisading

Schwannoma



1. Antoni A
2. nuclear palisading

Neurofibroma



- × peripheral nerve sheath tumor
- × solitary x multiple (neurofibromatosis I. , II. type)
- × **cutaneous x plexiform** (*along nerves, possible malignant transformation*)

× gross:

⇒ *unencapsulated soft roundish nodules*

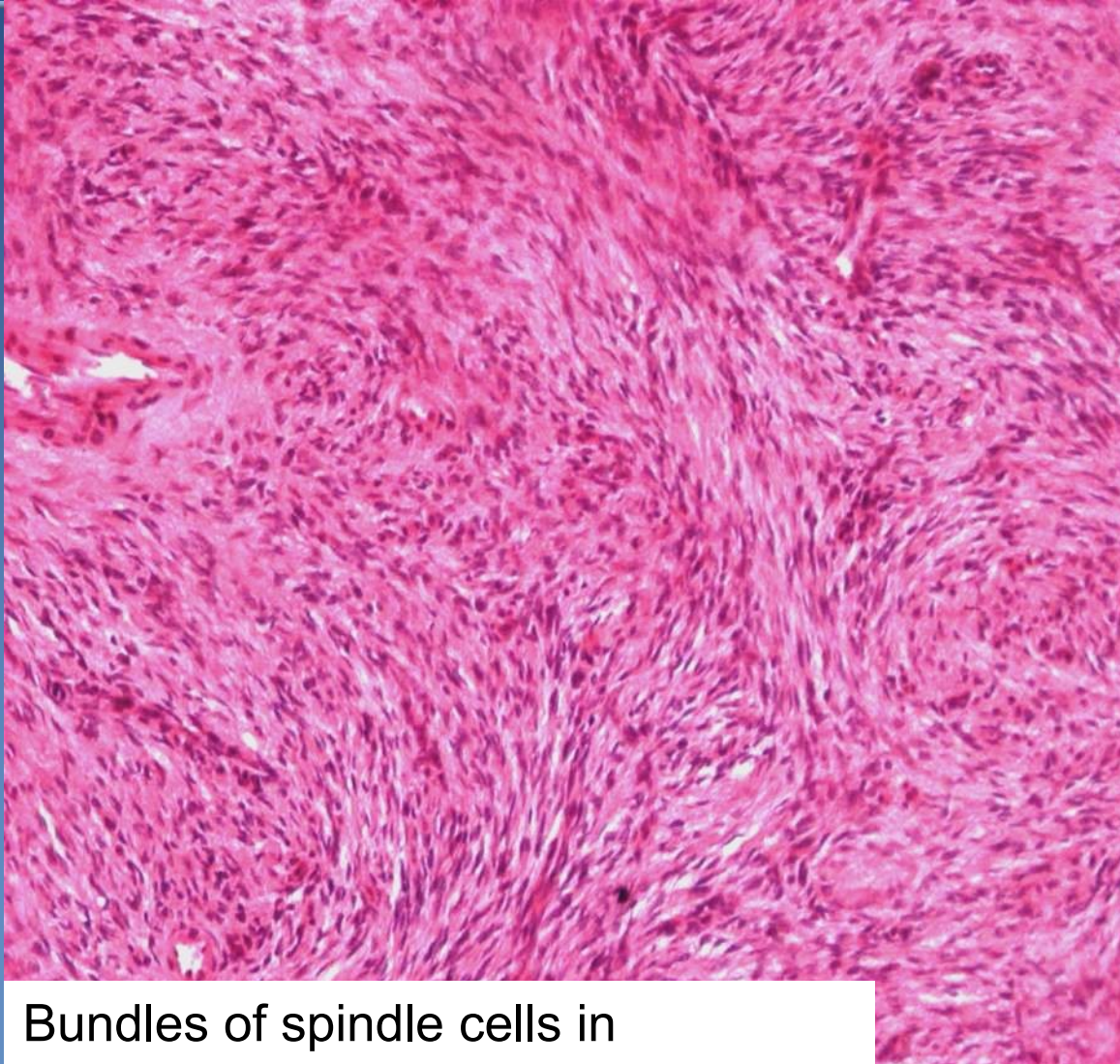
× micro:

⇒ *spindle cells, „S“ and „C“ shaped*

⇒ *extracellular loose myxoid or collagenous matrix*

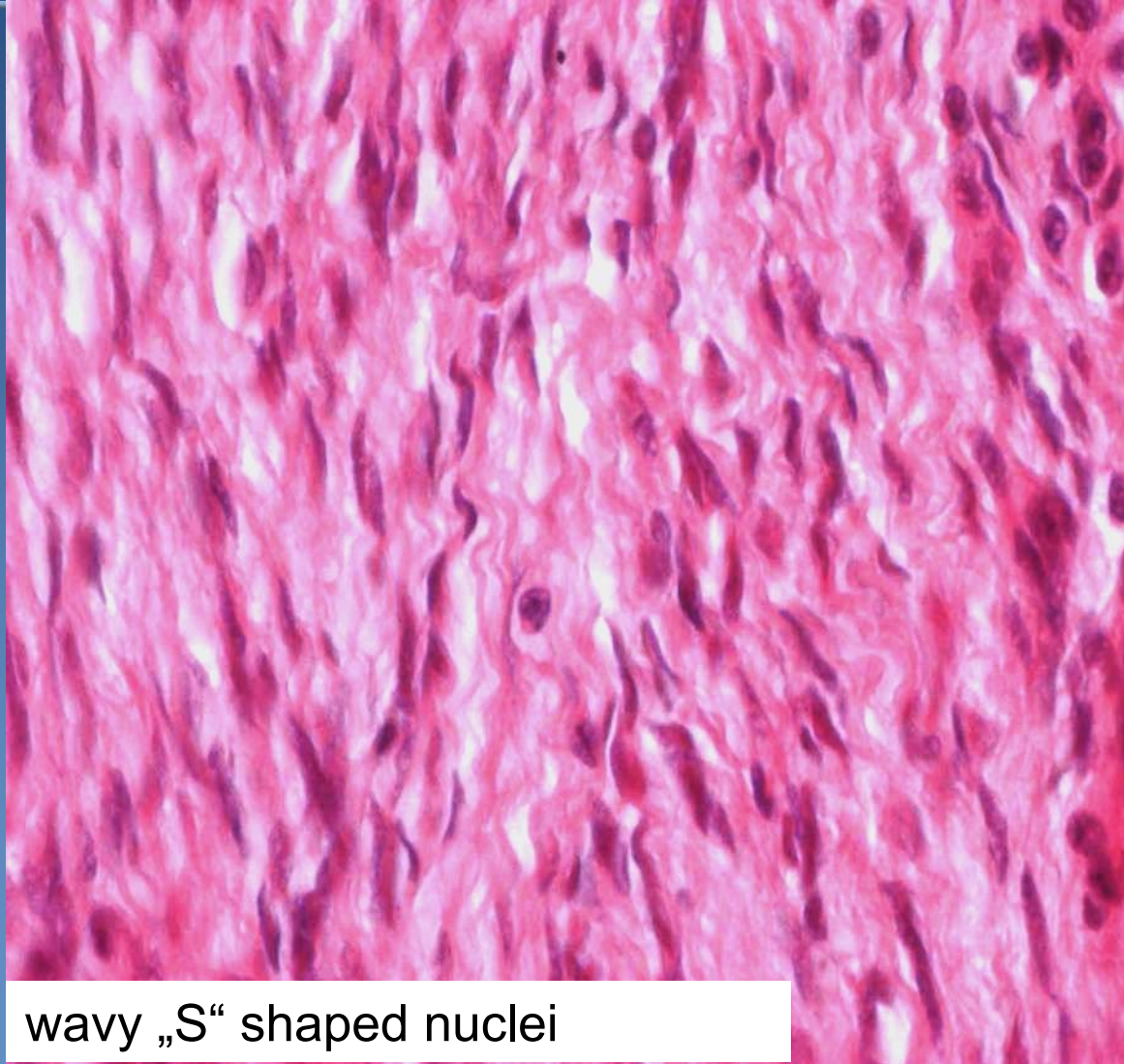
⇒ *sporadic small vascular lumina*

neurofibroma



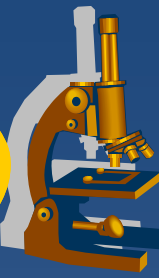
Bundles of spindle cells in collagenous stroma

neurofibroma



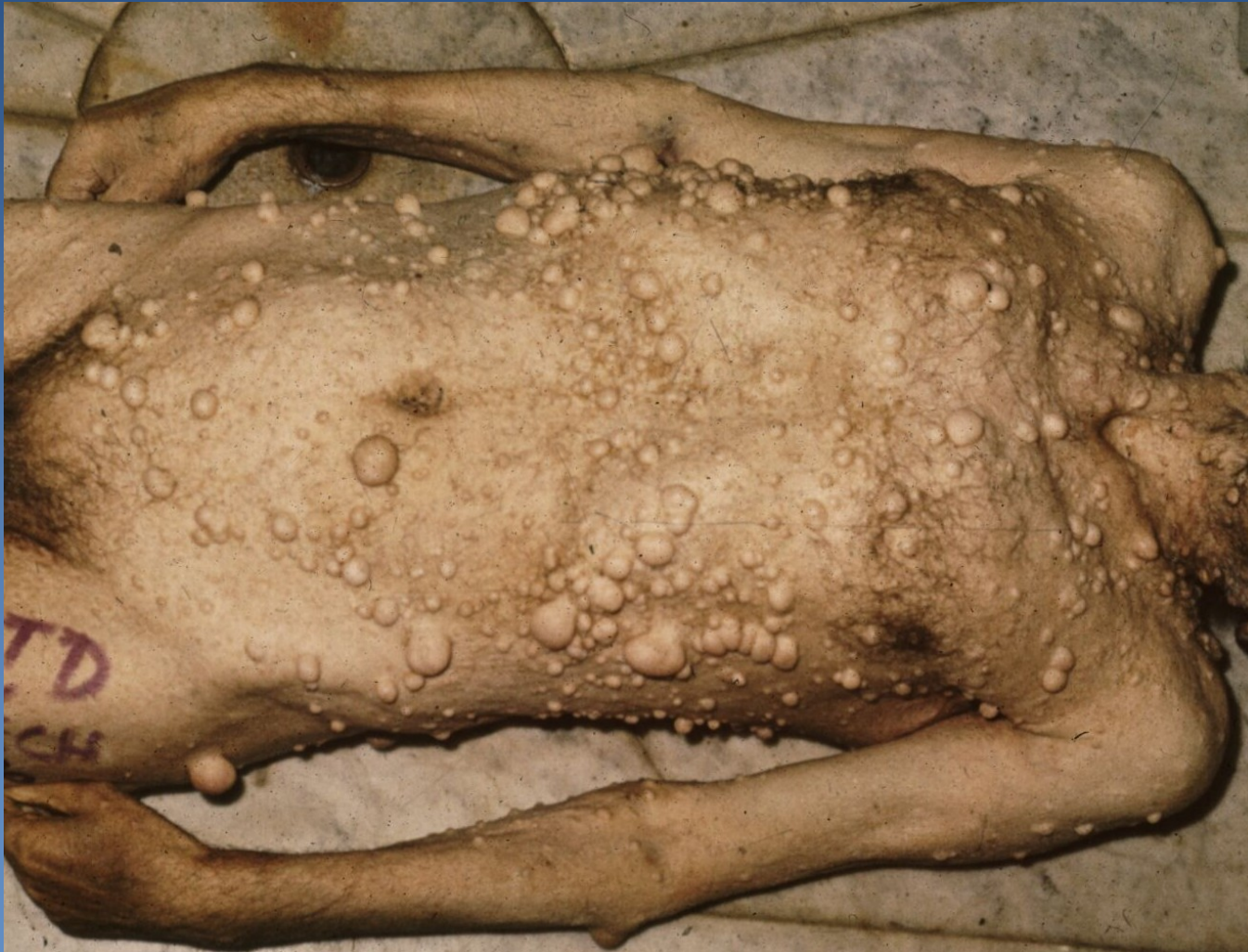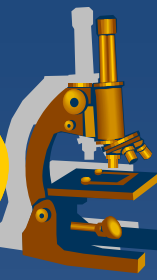wavy „S“ shaped nuclei

Neurofibromatosis (type I)



- ✗ von Recklinghausen's disease
 - ⇒ AD, frequency 1:3000, chromosome 17, defect of tumor suppressor gene
- ✗ **multiple neurofibromas, mostly on skin**, in any localisation - retroperitoneum, orbit, tongue, GIT, melanin-containing variants
- ✗ **hyperpigmented skin lesions** (café-au-lait spots), **pigmented iris hamartomas** (Lisch nodules)
- ✗ in approx. 3% of patients malignant transformation
- ✗ ↑ **risk of development of other tumors** (*optic gliomas, meningiomas, pheochromocytomas*)

Neurofibromatosis (type I)



Malignant tumors



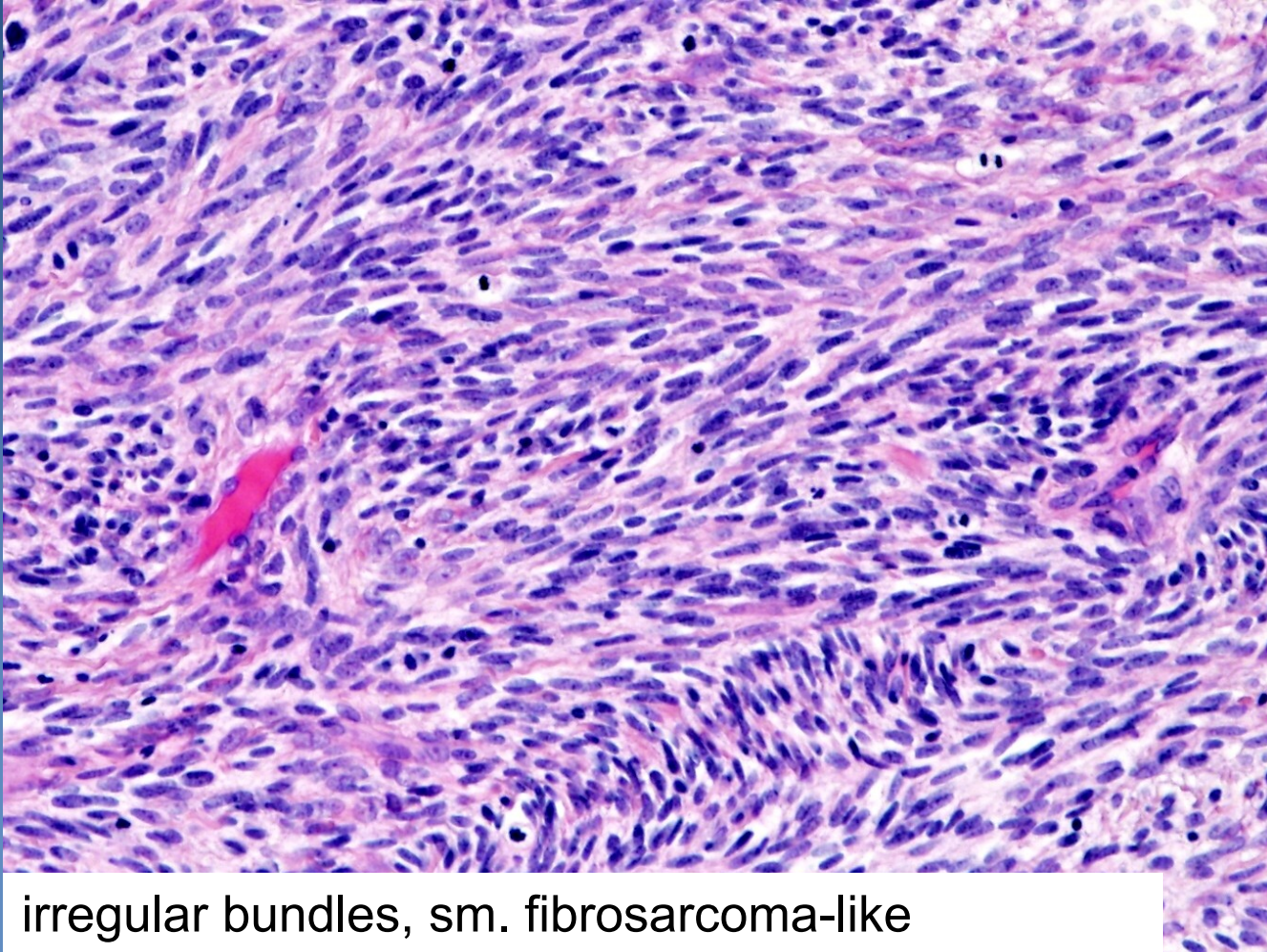
x malignant peripheral nerve sheath tumor (MPNST)

- ⇒ „neurogenic sarcomas“ arising from the peripheral nerve sheath
- ⇒ 50% occur in patients with neurofibromatosis type 1, adults
- ⇒ aggressive, recurrent, metastases (lung, bones)
- ⇒ gross: foci of necrosis, hemorrhage
- ⇒ micro: fibroblast-like cells with elongated nuclei, frequent mitotic figures, areas of necrosis

x primitive neuroectodermal tumors (PNET)

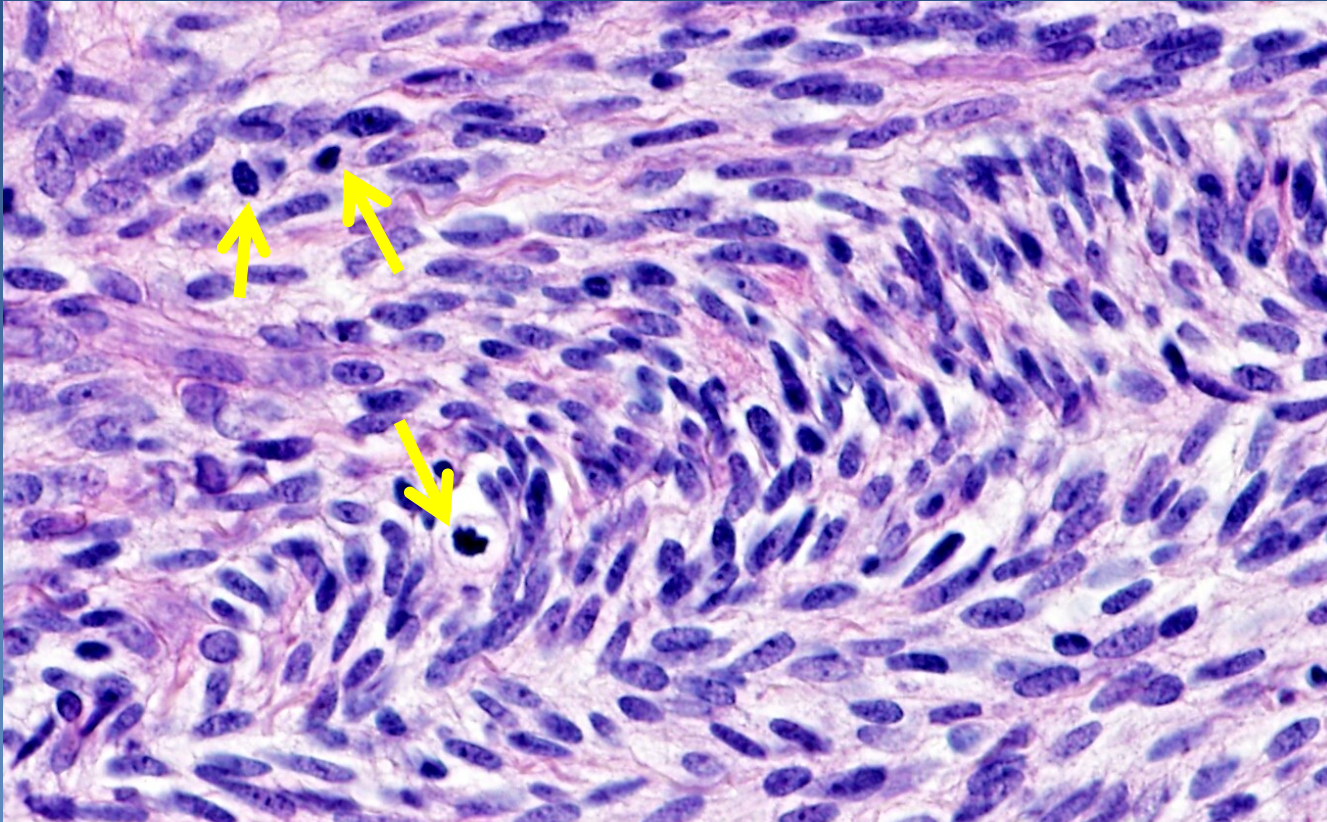
- ⇒ bone tumor

MPNST



irregular bundles, sm. fibrosarcoma-like

MPNST



Hyperchromatic nuclei of spindle cells

Mitoses (arrows)



TUMORS OF THE AUTONOMIC NERVOUS SYSTEM

Tumors of the parasympathetic system



x paraganglioma, chemodectoma

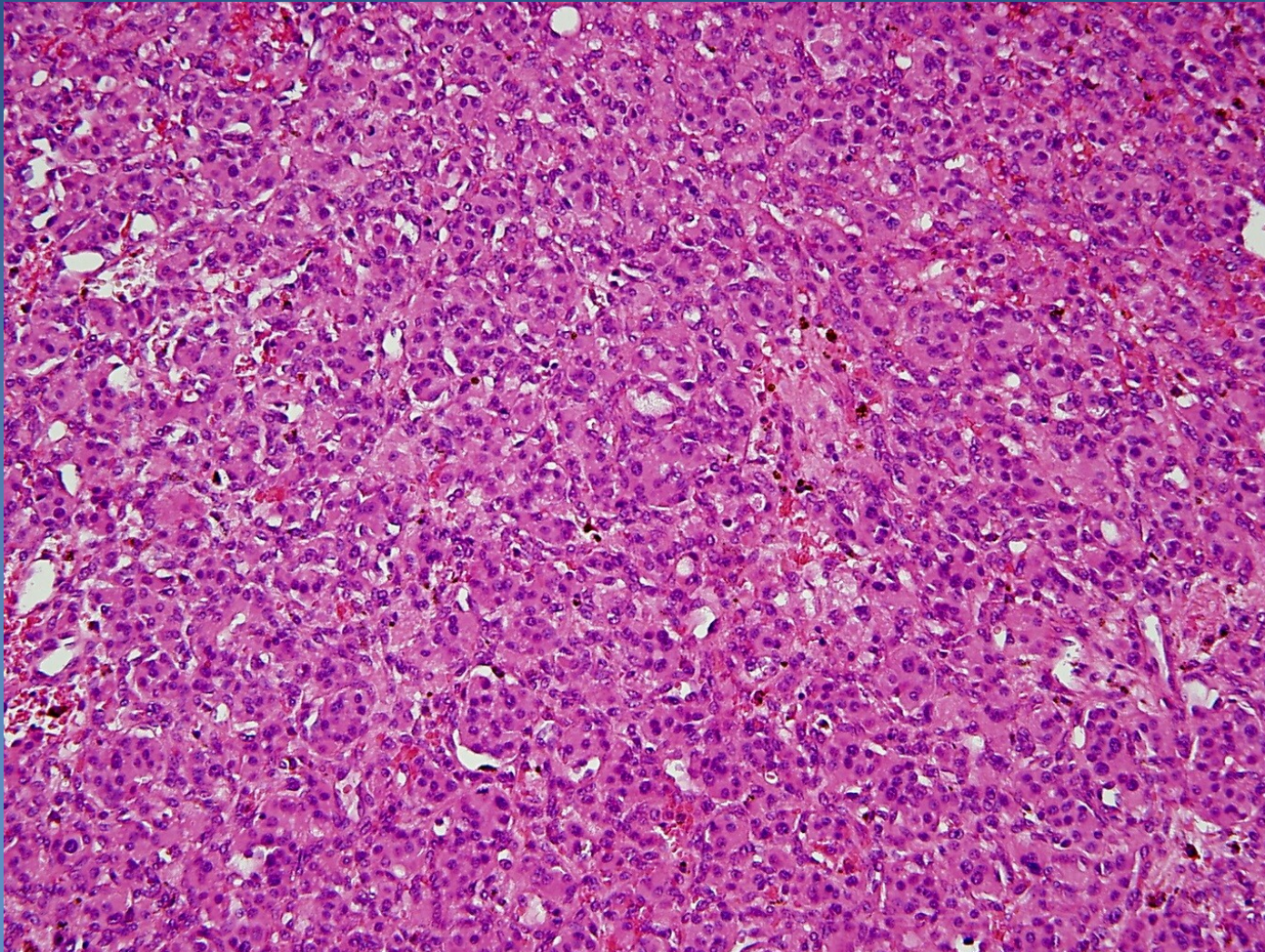
⇒ *originate from extraadrenal paraganglia*

- glomus tympanicum and jugulare, vagal bodies, carotid bodies, laryngeal, aorticopulmonary
 - pressure changes: $\downarrow P_aO_2$, $\uparrow P_aCO_2$ a $\uparrow pH$ → reflex stimulation of respiratory and cardiovascular system

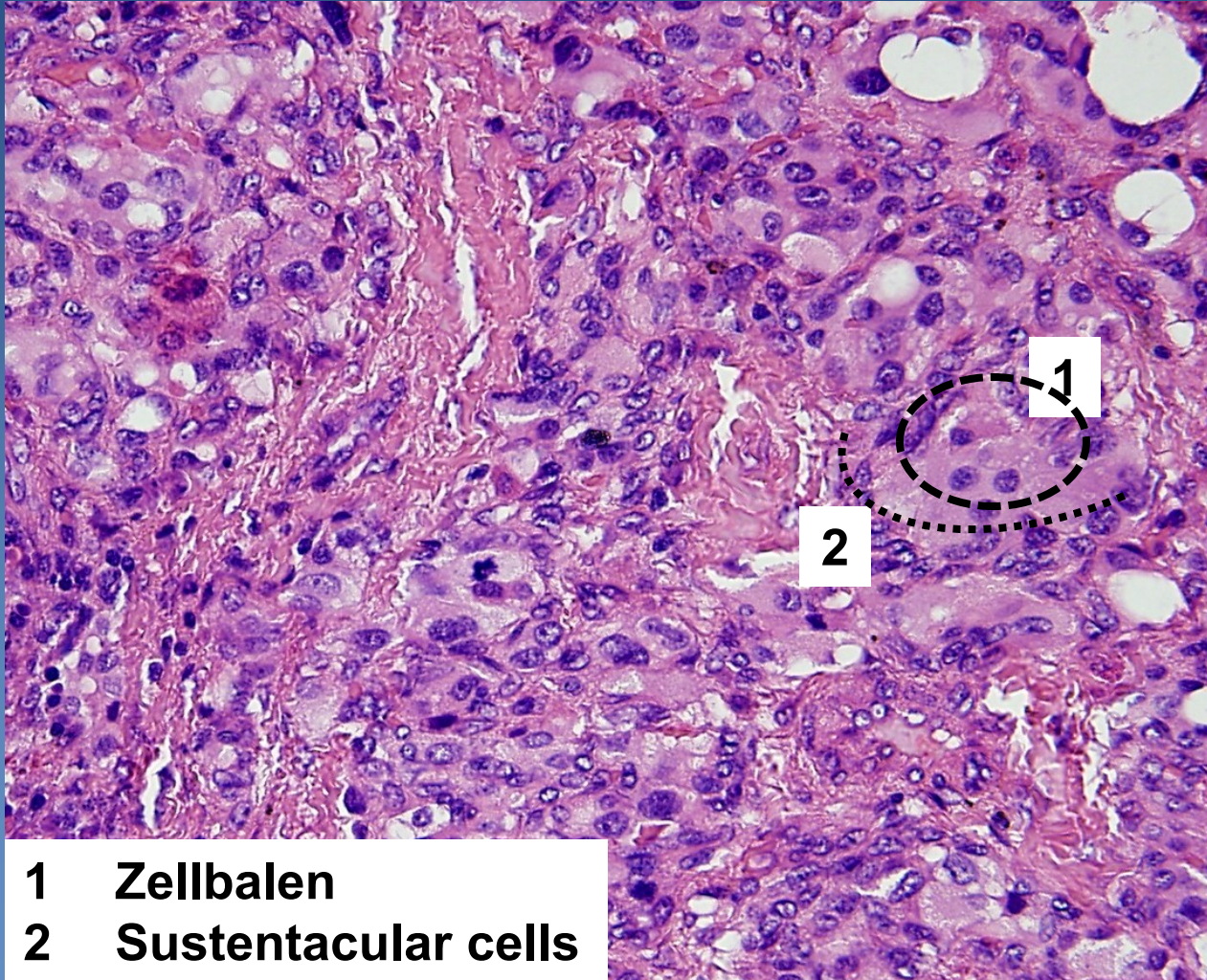
⇒ *micro:*

- organoid (solid alveolar) formation of cells:
 - chief cells - polygonal to oval; in distinctive cell nests, „Zellballen“)
 - **supporting** (sustentacular) **spindle cells**
- separated by thin fibrovascular stroma

Paraganglioma

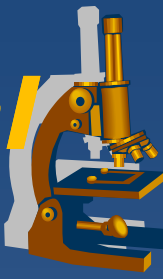


Paraganglioma



- 1 Zellbalen
- 2 Sustentacular cells

Tumors of the sympathoadrenal system



× Paragangliomas

× Pheochromocytoma

⇒ Adrenal medullary paraganglioma

⇒ **Gross:**, circumscribed lesions, usually confined to the adrenal, yellow-tan (hemorrhage, necrosis)

⇒ 10% associated with familial syndromes (MEN 2A, 2B, ..), 10% extra-adrenal, in adrenal location 10% bilateral, 10% biologically malignant)

× Neuroblastoma → ganglioneuroblastoma → ganglioneuroma

⇒ spontaneous or chemotherapy-induced maturation

⇒ even regression possible

⇒ variable prognosis, according to age and stage

Neuroblastoma



- ✗ most common extracranial solid tumor in childhood
- ✗ usually sporadic, 1% germline mutation of ALK (anaplastic lymphoma kinase)-gene
- ✗ mostly in adrenal medulla, paravertebral sympathetic ganglia
- ✗ large tumors haemorrhagic, necrotic

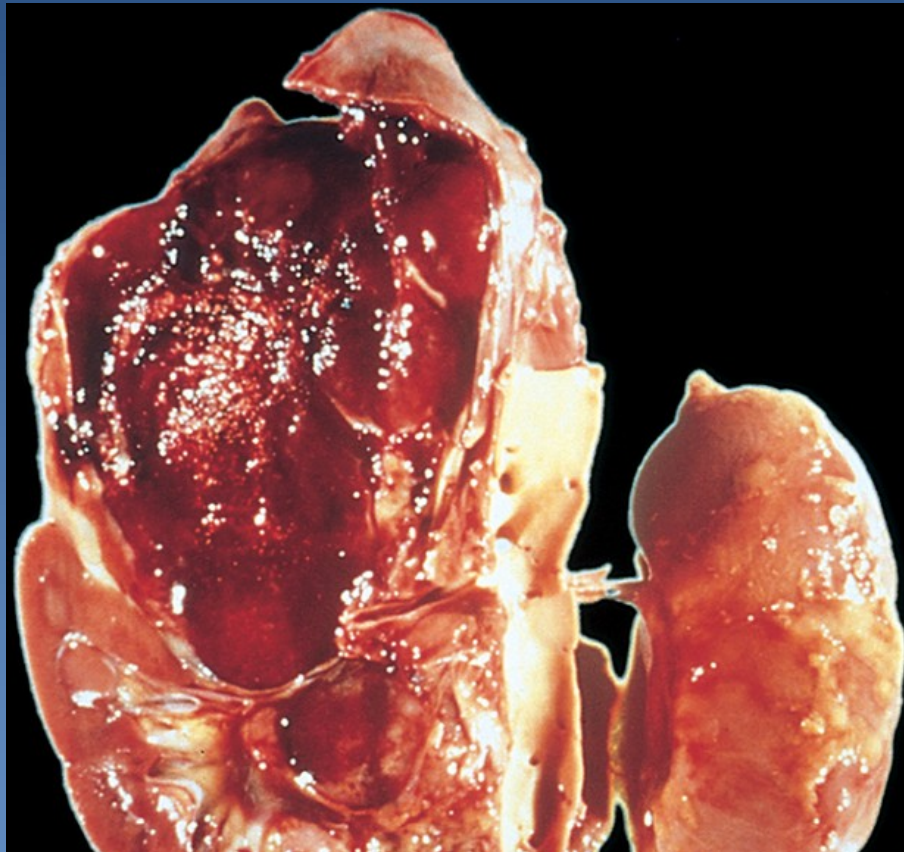
Neuroblastoma



xMicro:

- ⇒ *small round cells, hyperchromatic nuclei („small blue cells“)*
- ⇒ *extracellular eosinophilic fibrillary stroma*
- ⇒ *Homer-Wright rosettes*
- ⇒ *commonly high mitotic activity, caryorrhexis*

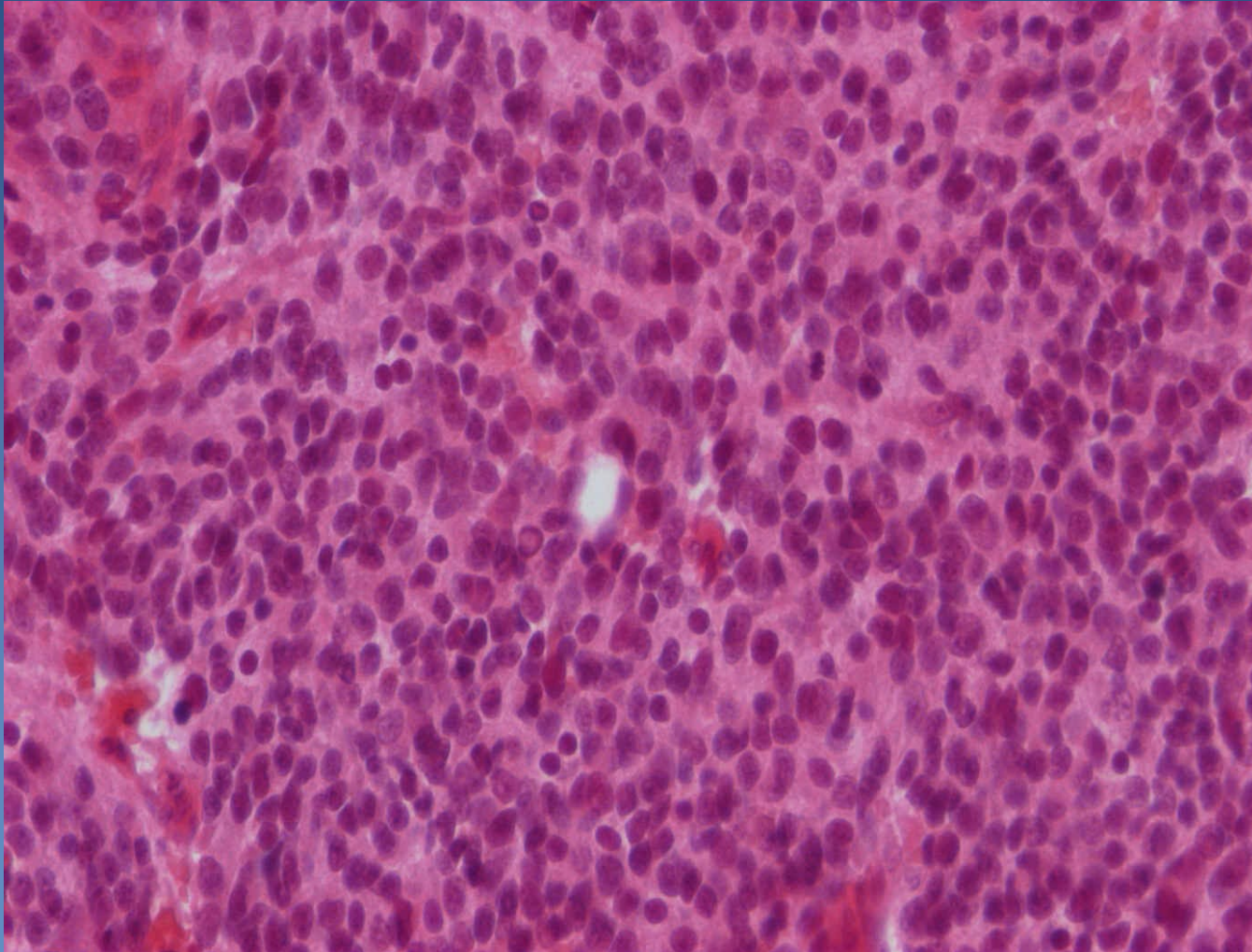
Neuroblastoma



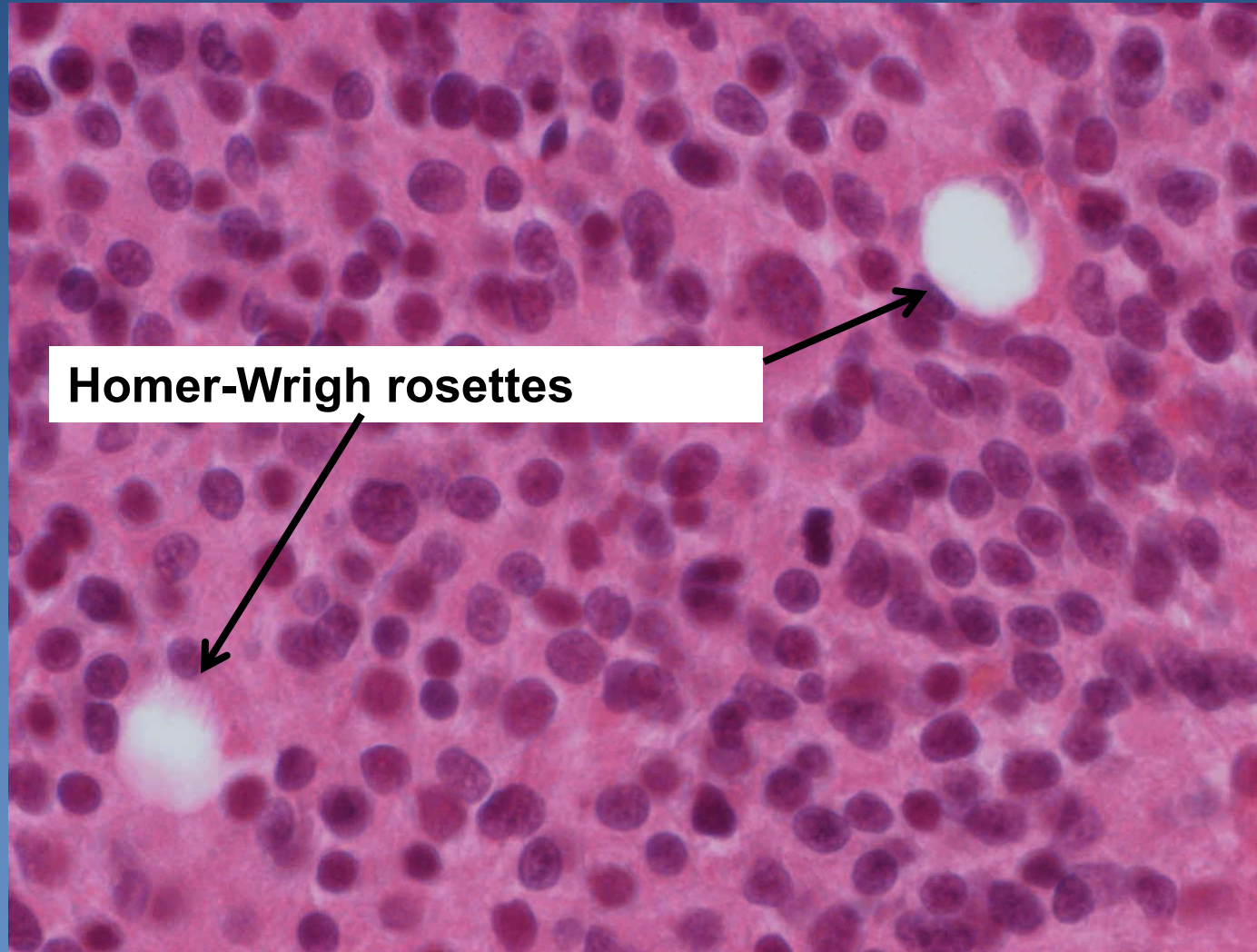Necrotic haemorrhagic adrenal tumor

Kumar et al: Robbins & Cotran Pathologic Basis of Disease, 9th Edition.
Copyright © 2009 by Saunders, an imprint of Elsevier, Inc. All rights reserved.

Neuroblastoma



Neuroblastoma



Homer-Wright rosettes