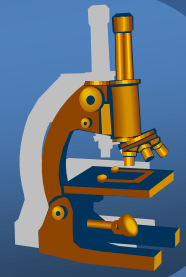
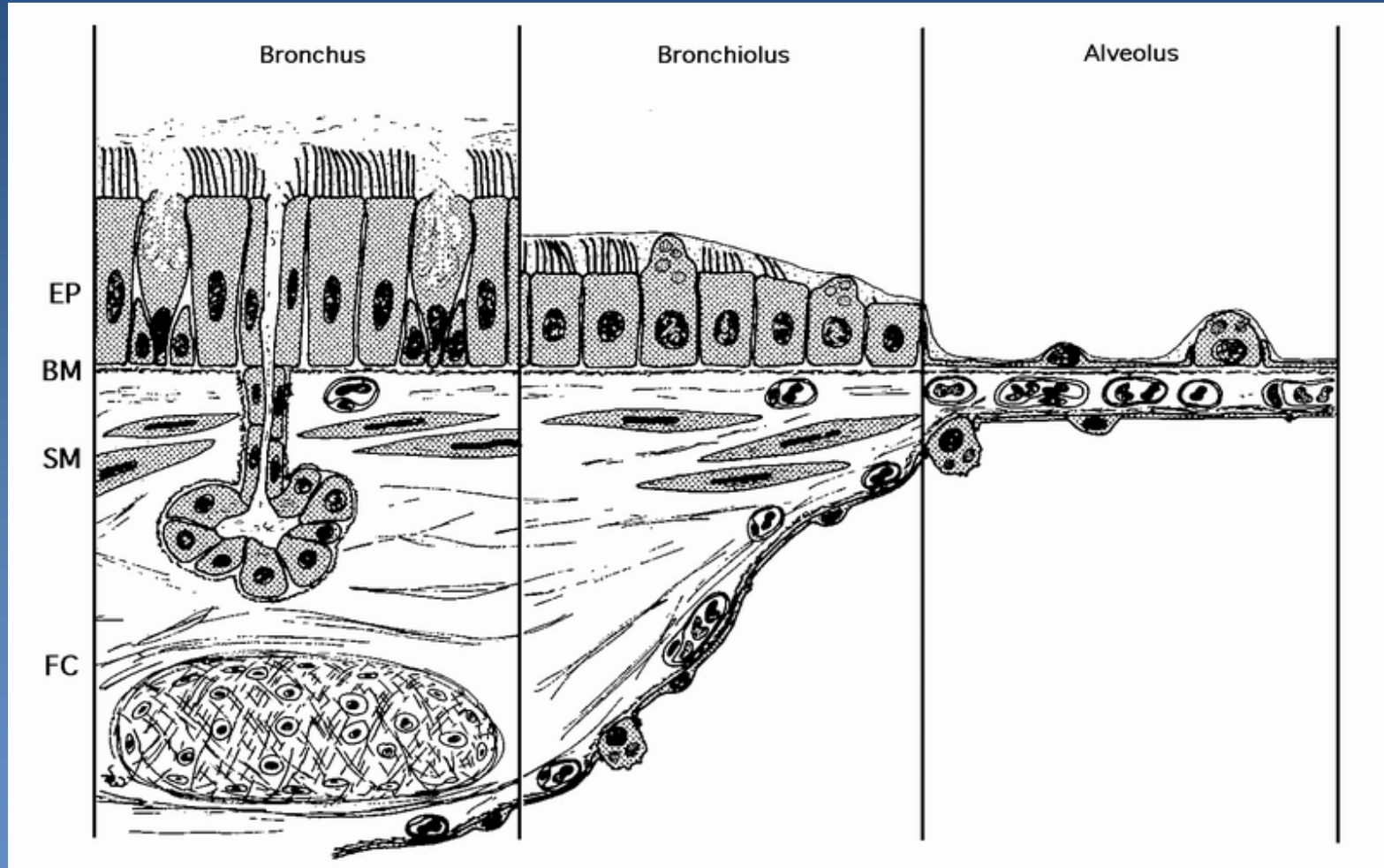


Systemic pathology

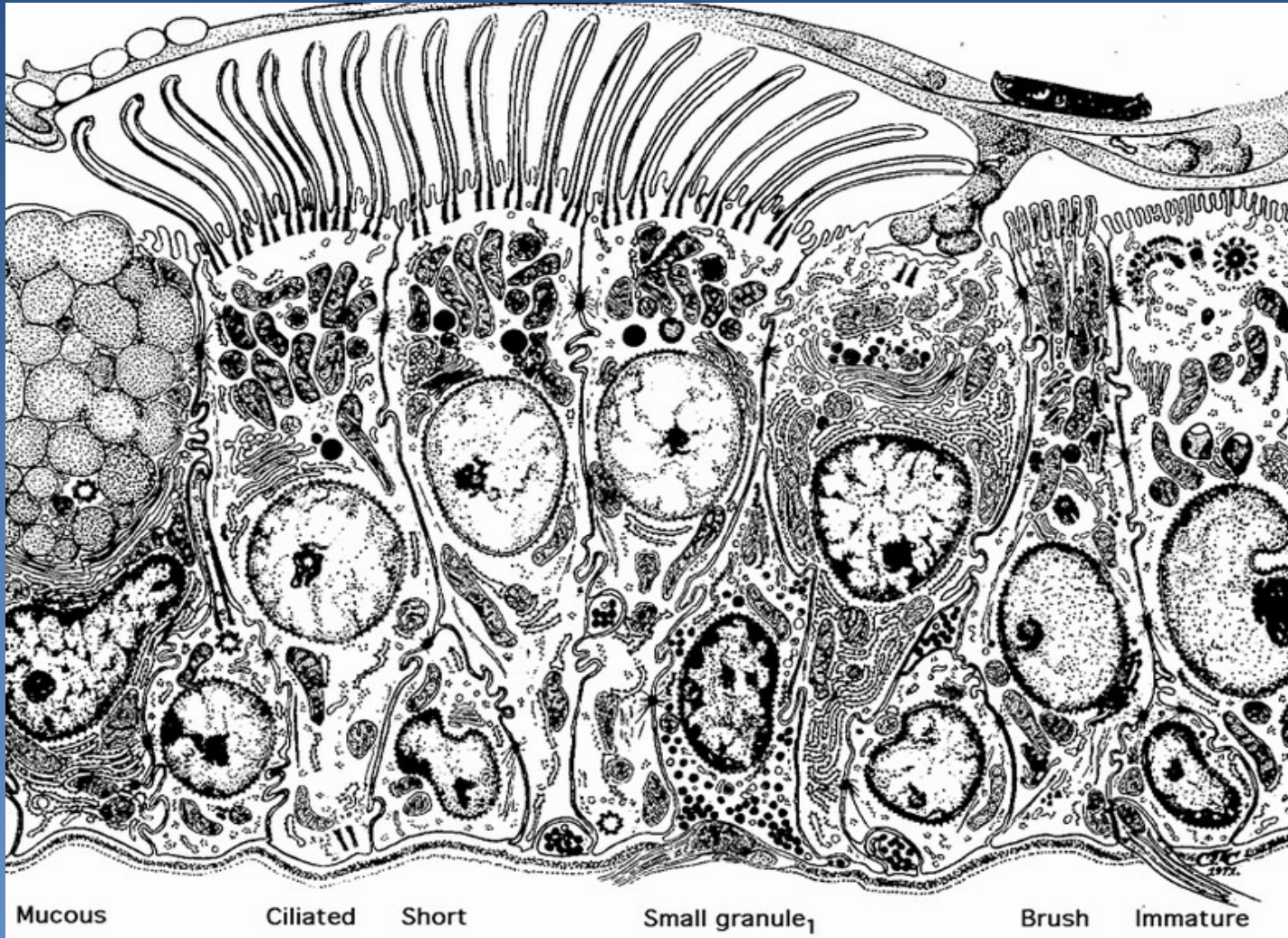


The respiratory tract

Histology of respiratory tract



Cellular components of bronchial mucosa



Mucous

Ciliated

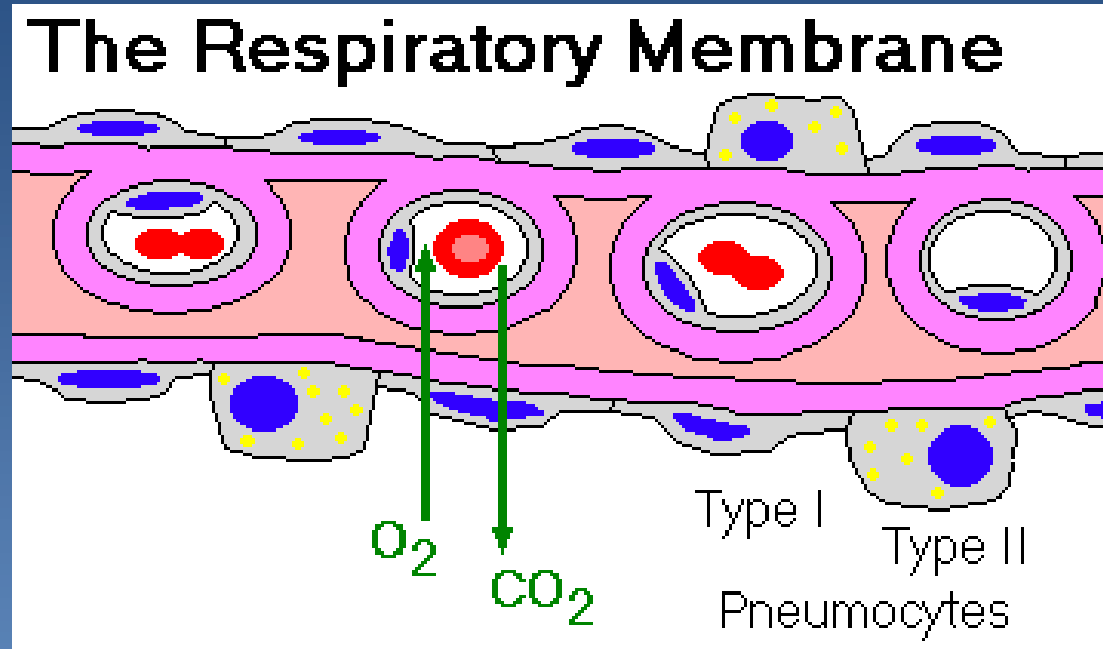
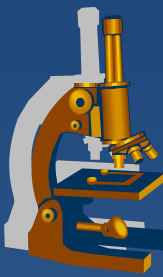
Short

Small granule₁

Brush

Immature

The respiratory membrane



Chronic polypous rhinitis



- x chronic proliferative inflammation
- x aetiology:
 - ⇒ *chronic irritation*
 - ⇒ *allergy*
 - ⇒ *repeated acute inflammations*

Polypous chronic rhinitis



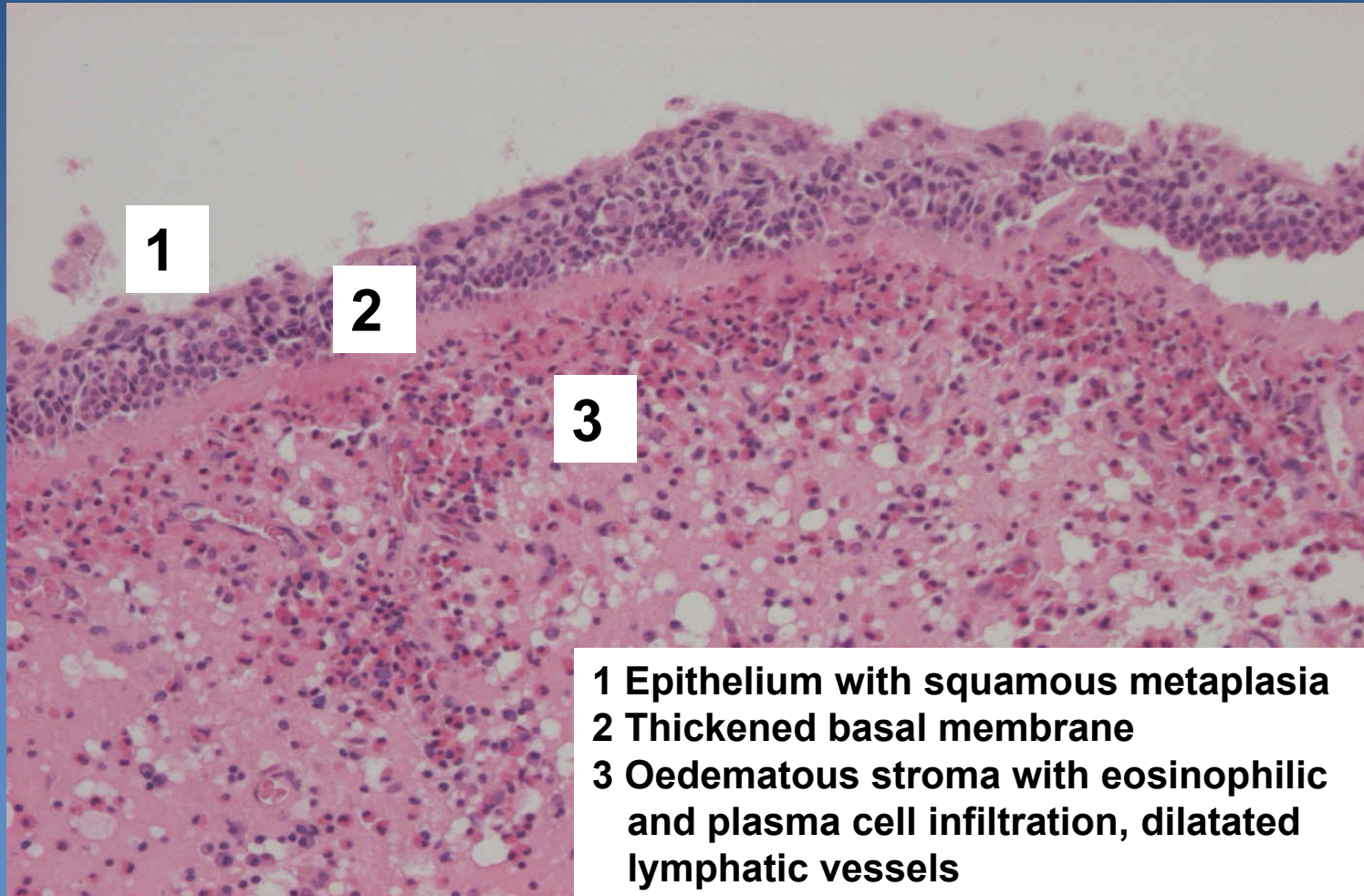
x Gross:

- ⇒ *mucosal polyps, often multiple*
- ⇒ *variable size (mm – 2 cm)*

x Micro:

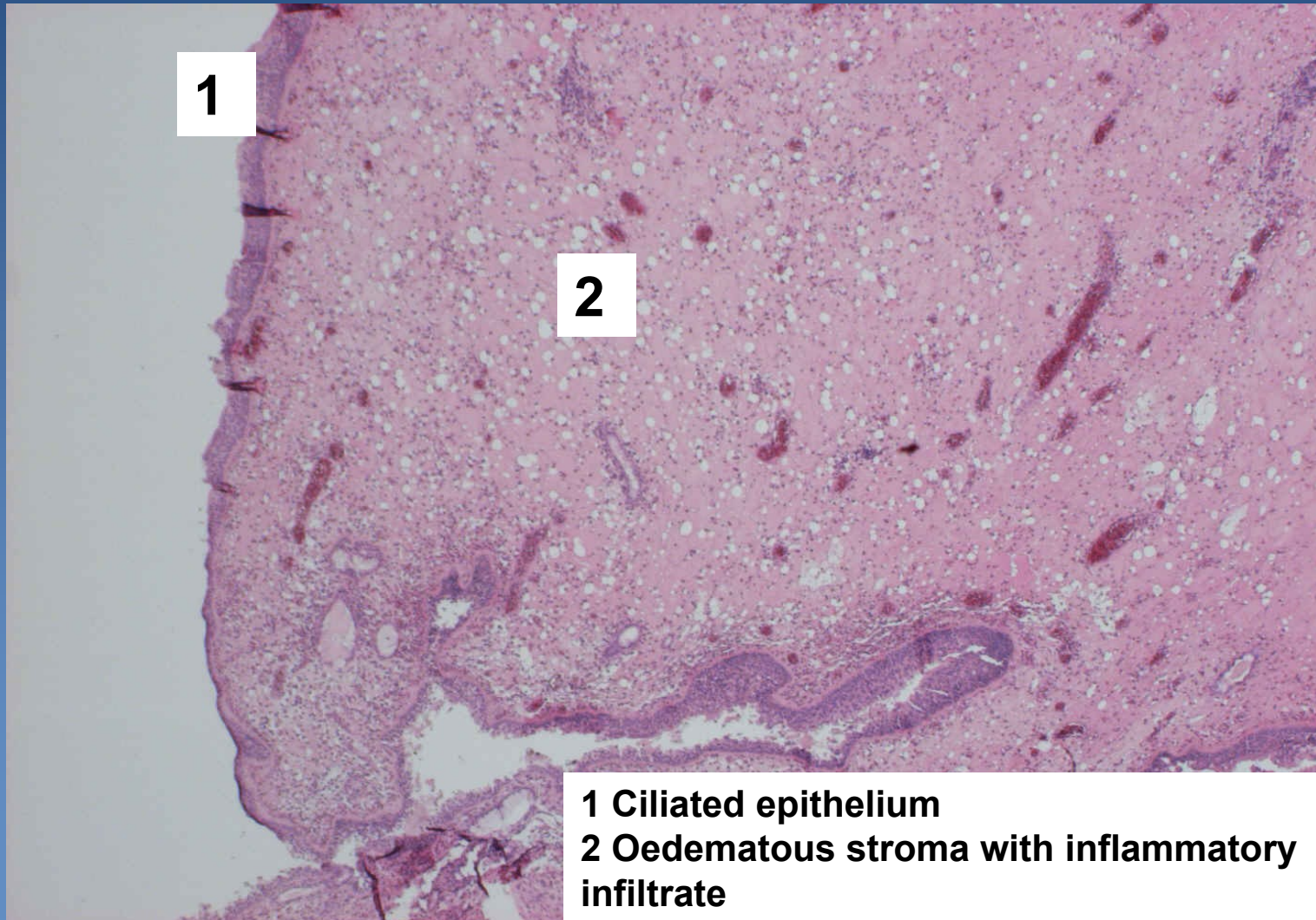
- ⇒ *oedematous mucosal connective tissue*
- ⇒ *lymphoplasmocytic reactive infiltration, admixture of eosinophils, event. neutrophils*
- ⇒ *mucinous hyperplasia*
- ⇒ *covered by hyperplastic respiratory epithelium, squamous metaplasia possible*

Polypous chronic rhinitis



- 1 Epithelium with squamous metaplasia**
- 2 Thickened basal membrane**
- 3 Oedematous stroma with eosinophilic and plasma cell infiltration, dilatated lymphatic vessels**

Polypous chronic rhinitis

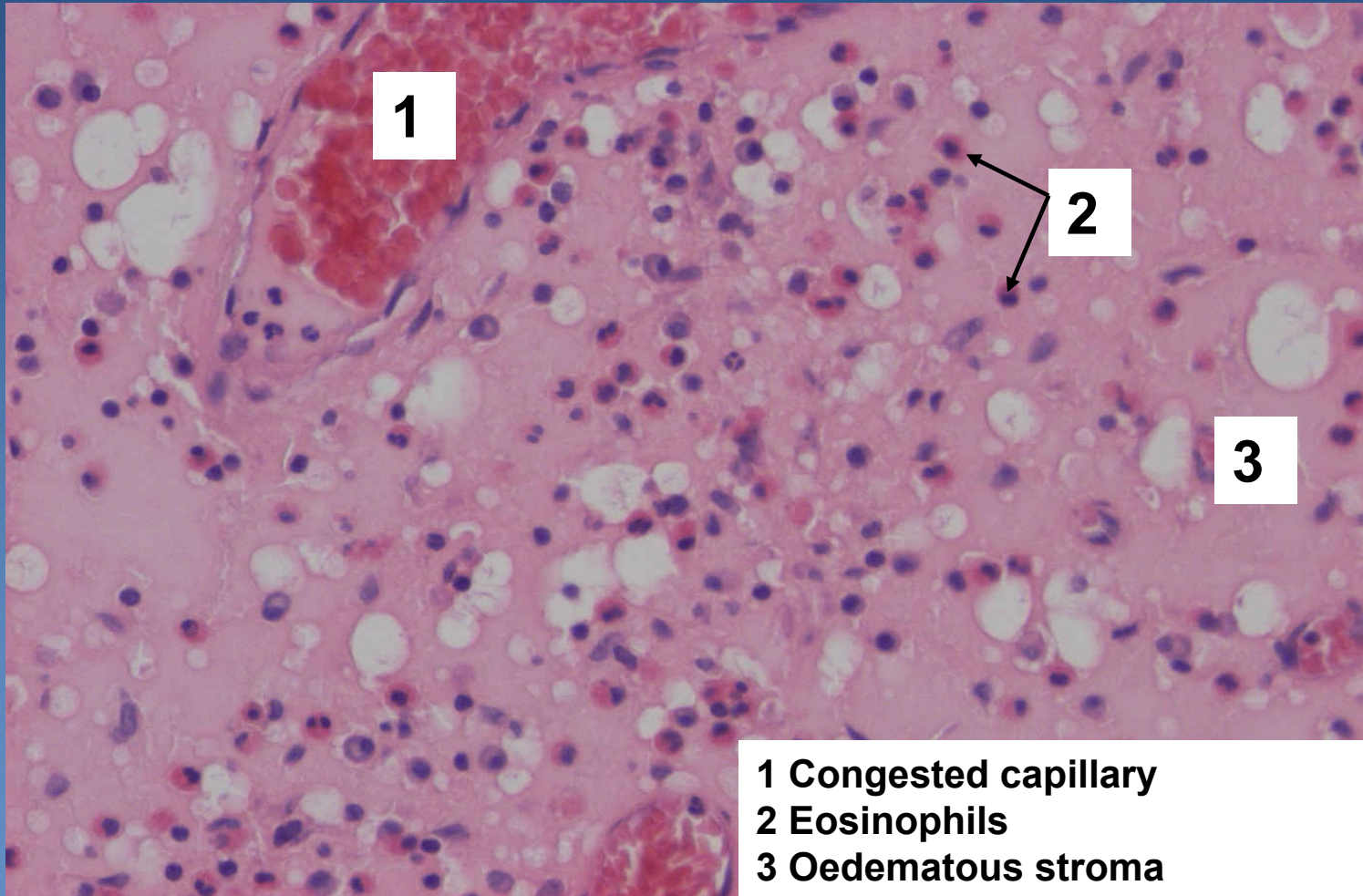


1

2

1 Ciliated epithelium
2 Oedematous stroma with inflammatory infiltrate

Polypous chronic rhinitis

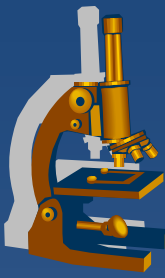


Asthma bronchiale



- ✗ recurrent attacks of bronchospasm with expiratory dyspnoea
- ✗ status asthmaticus:
 - ⇒ *increased frequency of attacks – permanent bronchospasm*
 - ⇒ *may be lethal*
- ✗ etiology:
 - ⇒ *Hypersensitivity I.type*
- ✗ variants:
 - ⇒ *Extrinsic (environmental factors):*
 - Atopic, IgE → mast cells degranulation..., bronchioconstriction, increased vascular permeability and mucus secretion + eosinophils activation
 - ⇒ *Intrinsic:*
 - hyperreactive URT, non-atopic

Asthma bronchiale



× Gross (patients who died during status asthmaticus):

⇒ *acute emphysema*

⇒ *mucus plugs in peripheral bronchi and bronchioles*

× Micro:

⇒ *intraluminal:*

- mucus, eosinophils, Charcot-Leyden crystals, cellular detritus

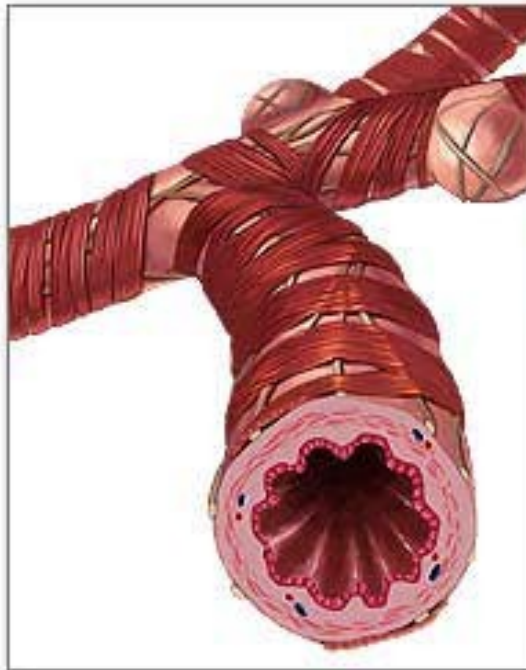
⇒ *bronchial wall:*

- oedema of the mucous membrane
- thickening (collagenisation) of the sub-basement membrane tissue
- mucous glands hypertrophy, eosinophil-rich inflammatory infiltrate

Asthma bronchiale



Normal bronchiole

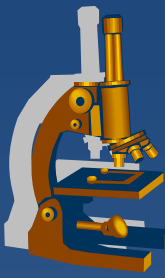


Asthmatic bronchiole



copy

Bronchiectasis



- ✘ permanent abnormal dilatation of bronchi
- ✘ arising from the weakening of the walls or changes in air pressure
- ✘ morphology:
 - ⇒ *cylindrical*
 - ⇒ *saccular*
 - ⇒ *fusiform*

Bronchiectasis



x aetiology:

⇒ *congenital/hereditary conditions:*

- incomplete development of bronchial wall
- Kartagener syndrome
 - primary ciliary dysgenesis

⇒ *acquired:*

- chronic inflammations
- changes of the pressure
 - chronic pulmonary collapse

Bronchiectasis



x complications:

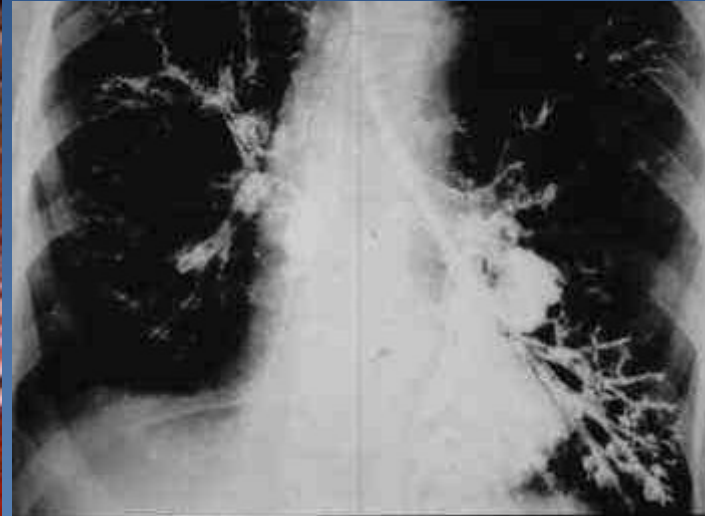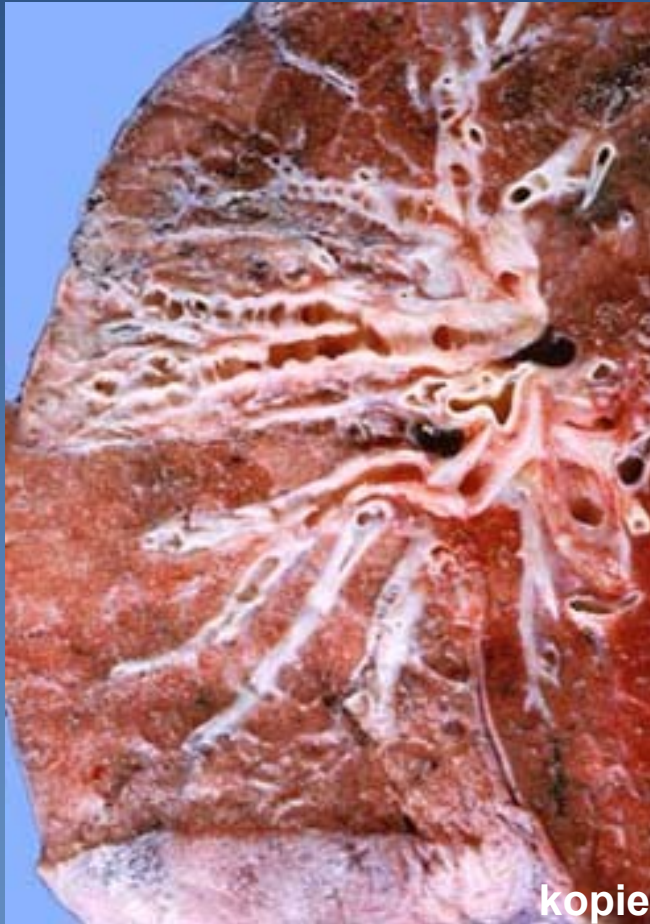⇒ *inflammations:*

- chronic purulent bronchitis
- bronchopneumonia including abscess formation

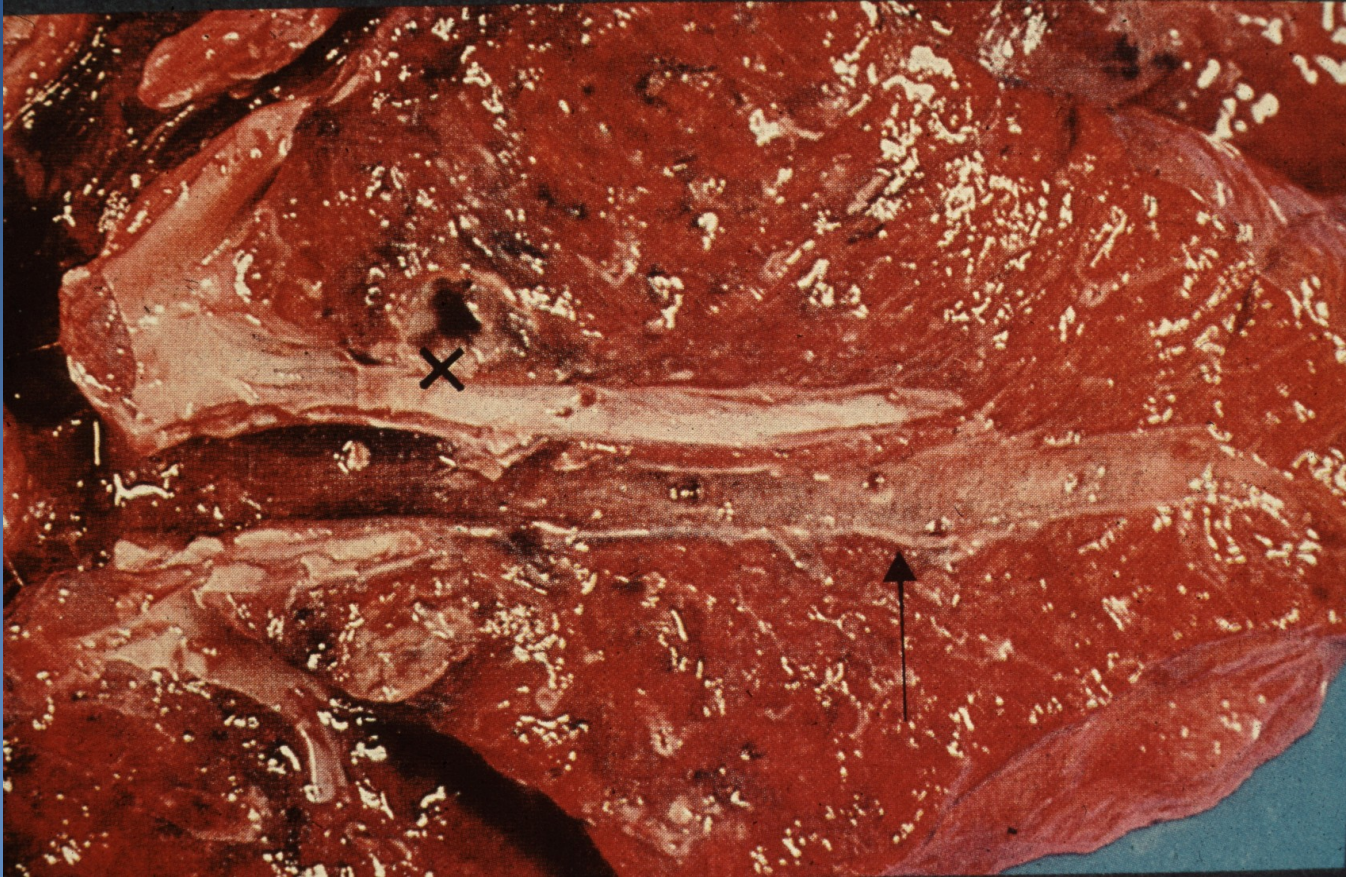
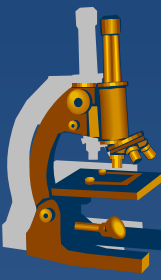
⇒ *fibrosis, pulmonary hypertension and cor pulmonale*

⇒ *secondary AA amyloidosis*

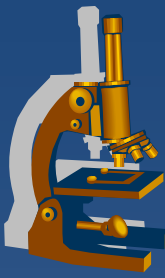
Bronchiectasis



Bronchiectasis



Pulmonary emphysema



- × regressive change (atrophy)
- × abnormal permanent enlargement of the airspaces in pulmonary tissue
- × aetiology (combination of several factors):
 - ⇒ *smoking*
 - ⇒ *deficiency of α 1-antitrypsin*
- × types:
 - ⇒ *alveolar:*
 - acute
 - chronic
 - ⇒ *interstitial – airway rupture (trauma)*

Alveolar emphysema



x acute:

- ⇒ *alveolar septa are not destroyed*
- ⇒ *rather pulmonary hyperinflation or distention*

x chronic:

- ⇒ *permanent enlargement of airspaces distal to terminal bronchioles*
- ⇒ *destruction of alveolar walls*
- ⇒ *part of COPD (chronic obstructive pulmonary disease)*
 - combination of chronic bronchitis and chronic emphysema

Alveolar emphysema



× types:

⇒ **centrilobular (centriacinar):**

- upper lobes – apex, more in males,
- most commonly seen in smokers without congenital -antitrypsin deficiency (but + chronic bronchitis), possible professional disease - dust

⇒ **panacinar:**

- often lower lung zones; significant microscopic changes; -antitrypsin deficiency, old age

⇒ **distal acinar (paraseptal):**

- adjacent to pleura, upper lobes foci of fibrosis, formation of cystlike structures – **bullae** (pneumothorax risk)

⇒ **irregular:**

- associated with scarring, usually postinflammatory

Alveolar emphysema



x Gross:

⇒ *enlarged, voluminous lungs, light, pale, dry, emphysematous bullae*

x Micro:

⇒ *thinning and destruction of alveolar walls*

⇒ *deformation of bronchiolar walls*

⇒ *chronic inflammatory changes*

Emphysema



x pathogenesis and complications:

thinning of alveolar walls and capillaries →

reduced blood supply →

complete destruction of alveolar walls →

difficult expiration + decreasing of lung capacity →

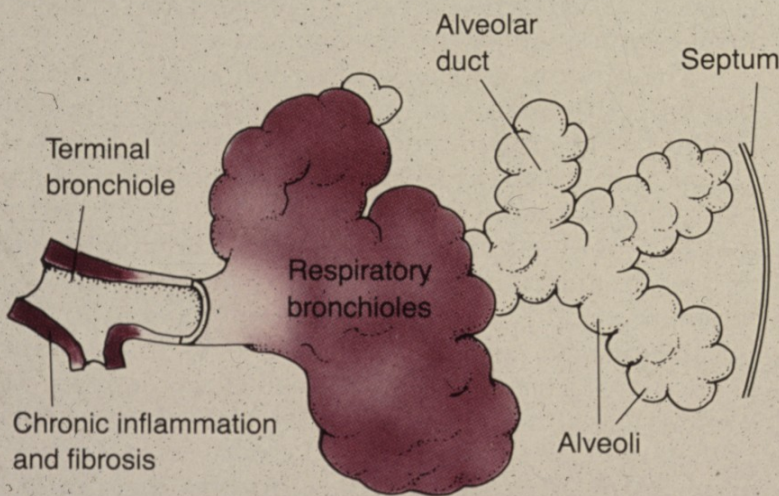
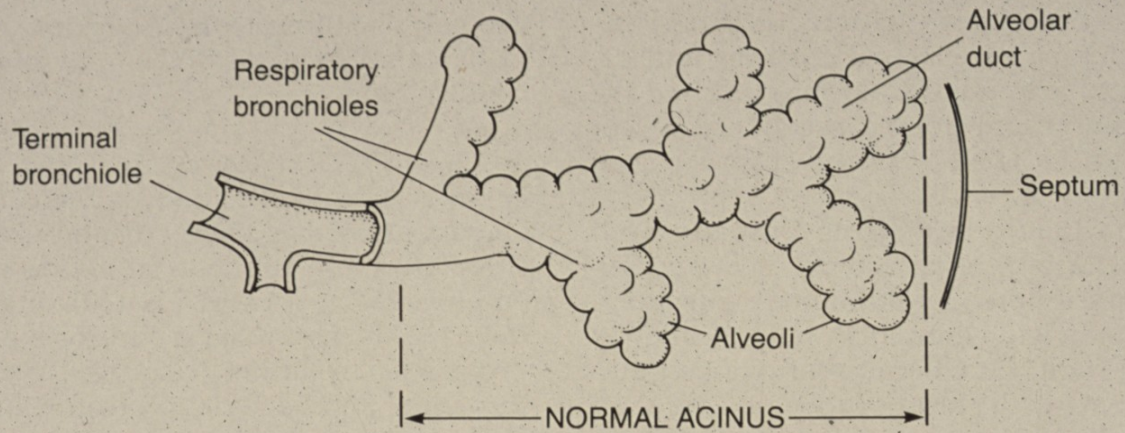
hypoxemia →

vasoconstriction →

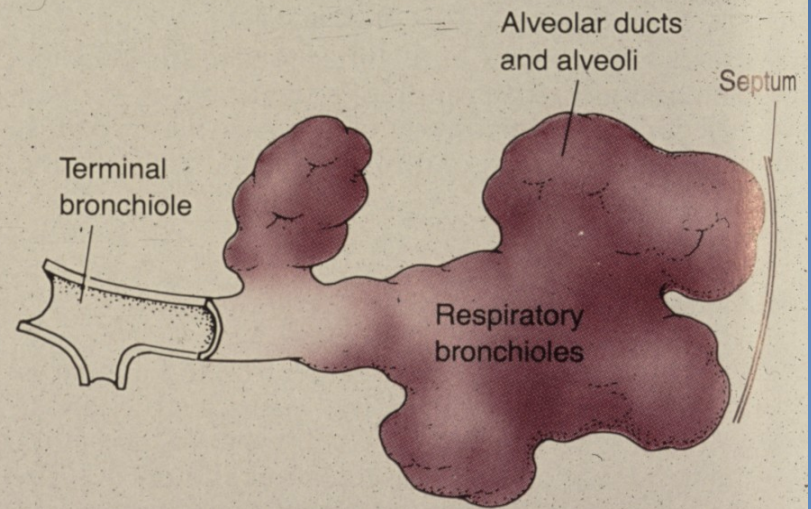
secondary pulmonary hypertension → →

cor pulmonale

Emphysema



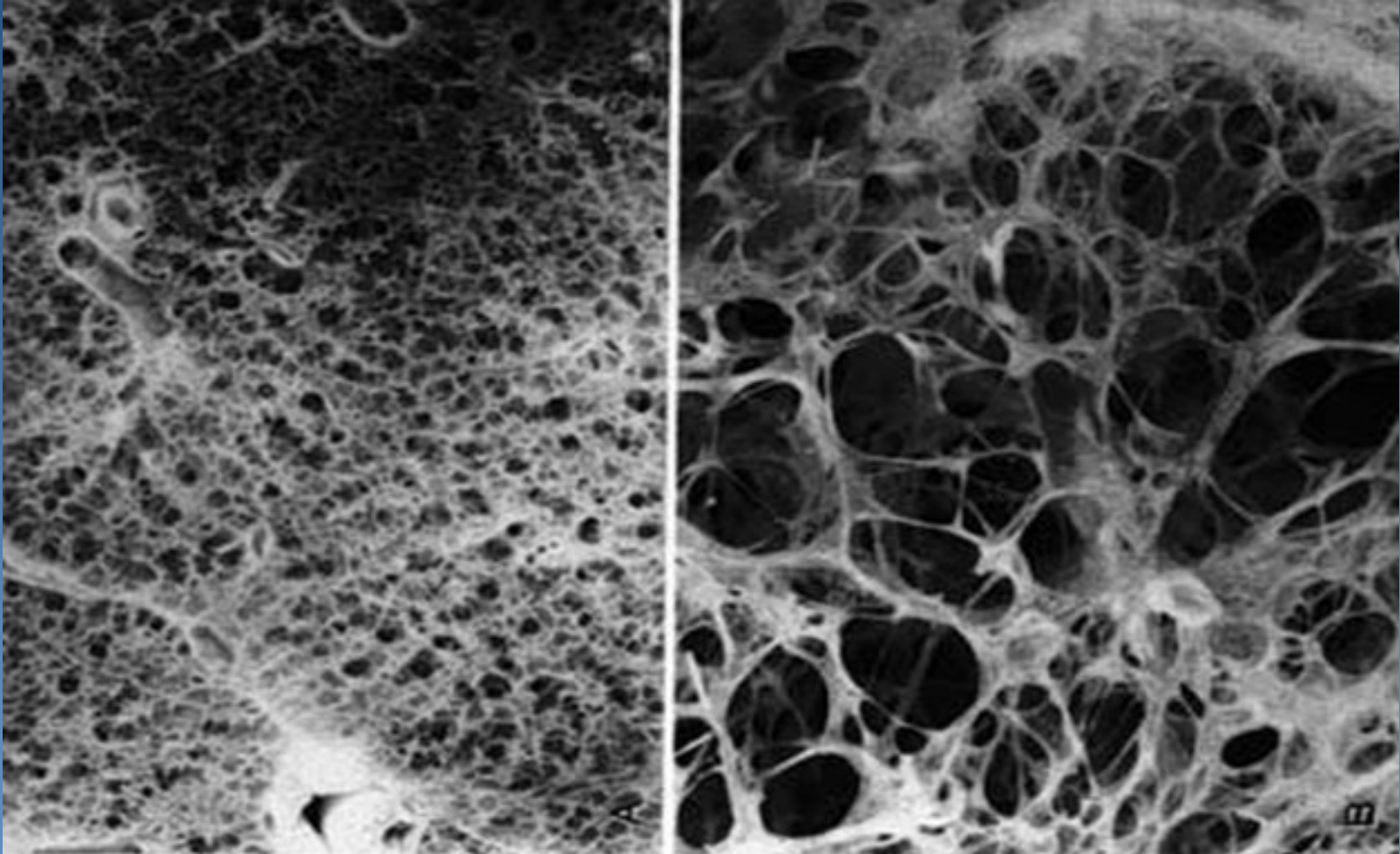
CENTRILOBULAR EMPHYSEMA



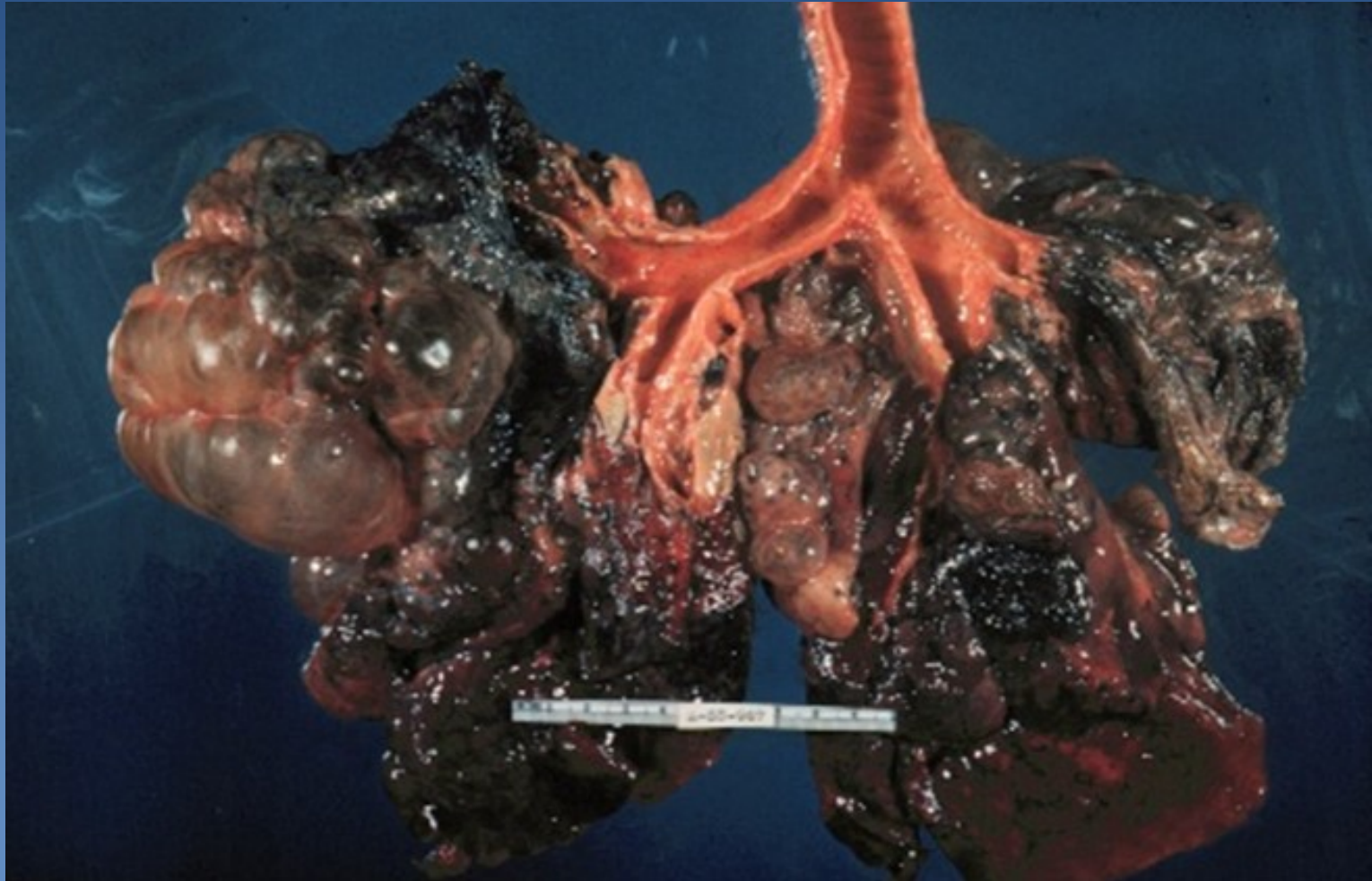
PANACINAR EMPHYSEMA

FIGURE 12-32

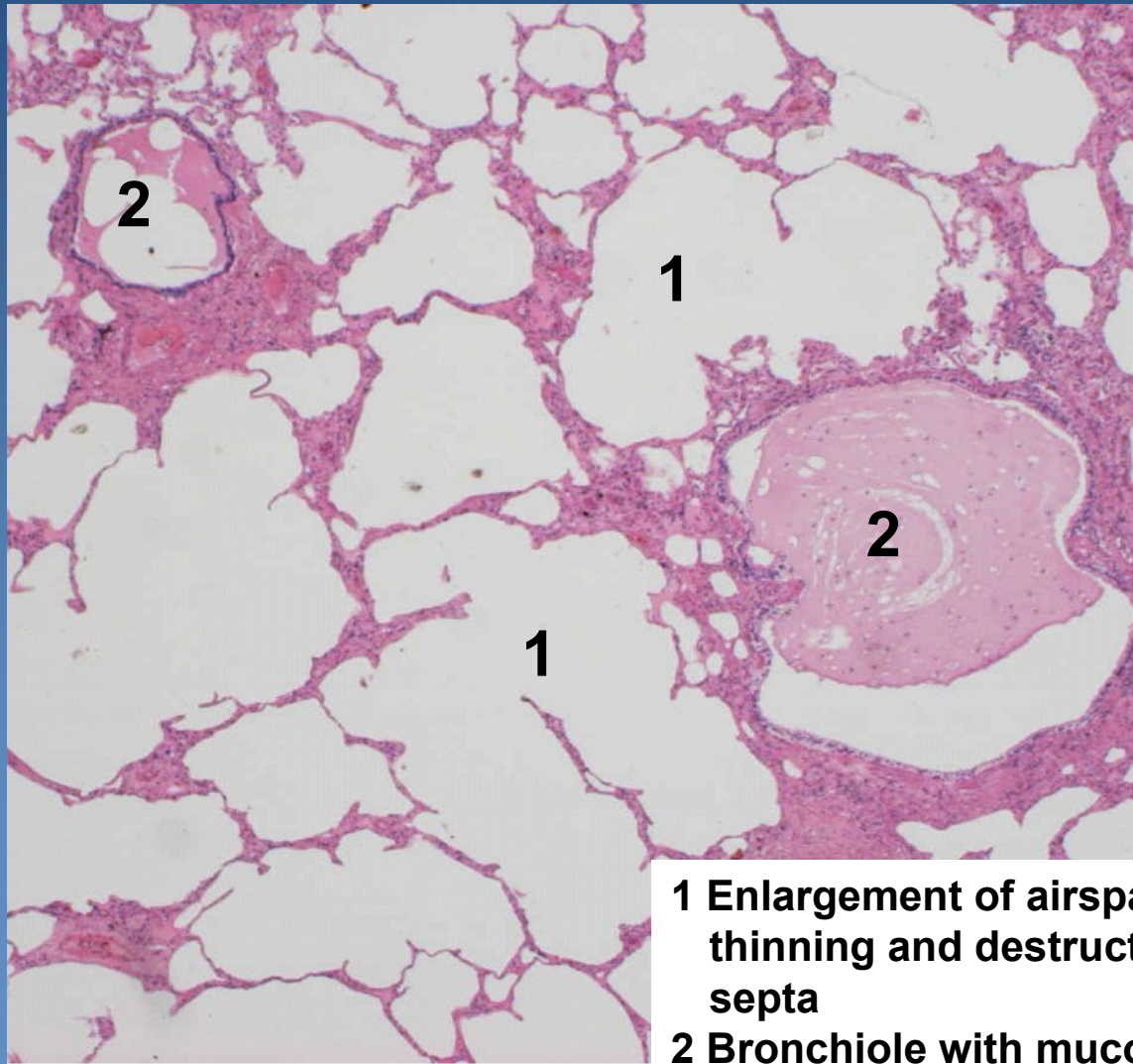
Normal lung and pulmonary emphysema



Bullous emphysema



Panacinar emphysema



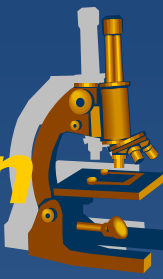
- 1** Enlargement of airspaces with thinning and destruction of alveolar septa
- 2** Bronchiole with mucous secretions

Hemorrhagic pulmonary infarction



- × aetiology:
 - ⇒ *thrombembolism of a. pulmonalis branches in the setting of compromised cardiovascular status (passive venous congestion)*
- × typically hemorrhagic
- × often in lower lung lobes adjacent to pleura
- × often multiple
- × healing:
 - ⇒ *granulation tissue, later formation of fibrous scar*

Hemorrhagic pulmonary infarction



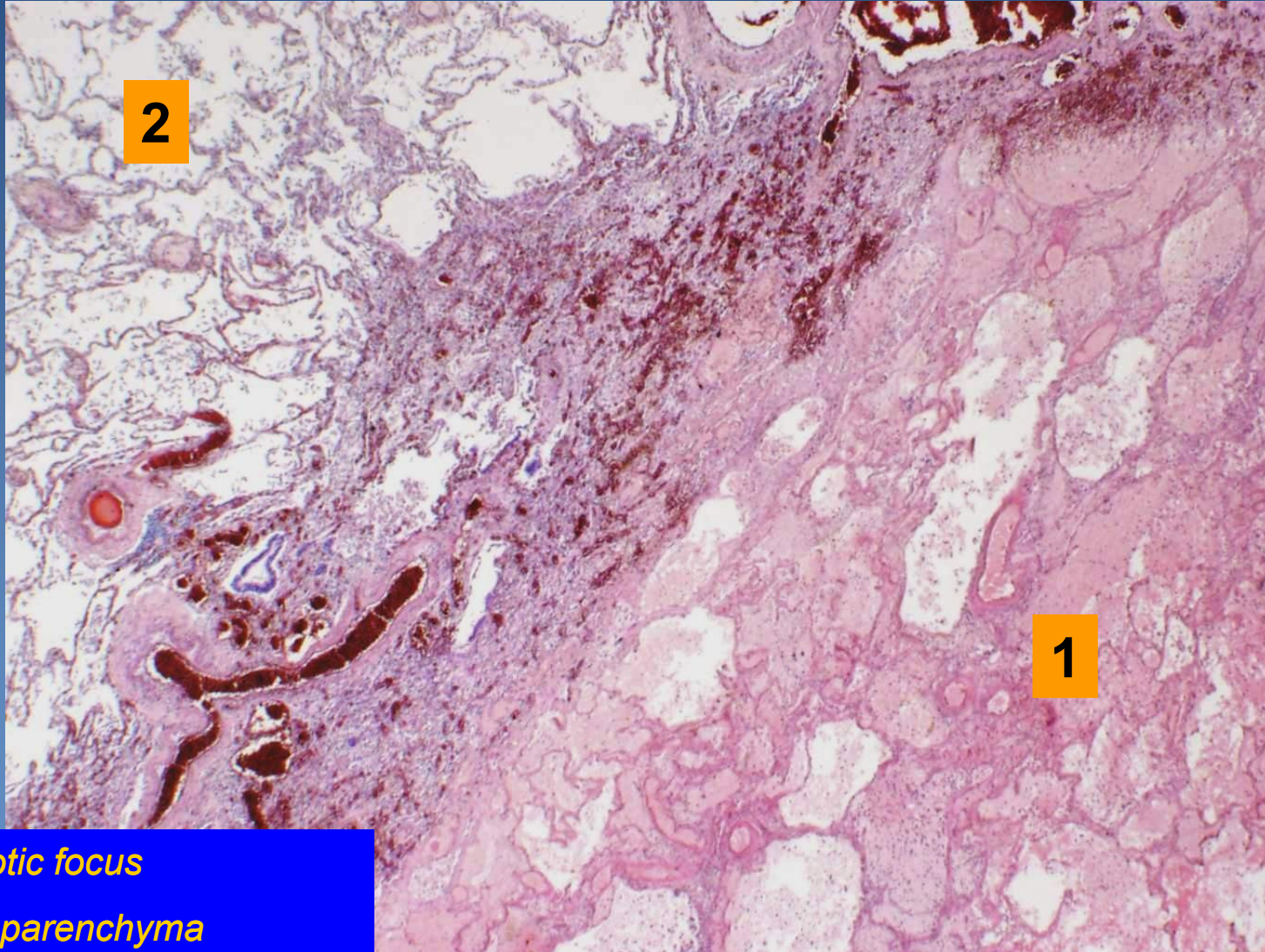
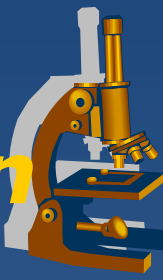x Gross:

- ⇒ *wedge-shaped focus of tissue with sharp borders*
- ⇒ *dark red-blue (new), yellowish-grey (older)*
- ⇒ *variable size*
- ⇒ *solid consistency*

x Micro:

- ⇒ *coagulative necrosis of lung parenchyma*
- ⇒ *large extravasations of erythrocytes*
- ⇒ *formation of abscess at secondary infection*
- ⇒ *reactive acute fibrinous pleuritis*
- ⇒ *healing – scarring + emphysema (diff.dg. x tumor)*

Hemorrhagic pulmonary infarction

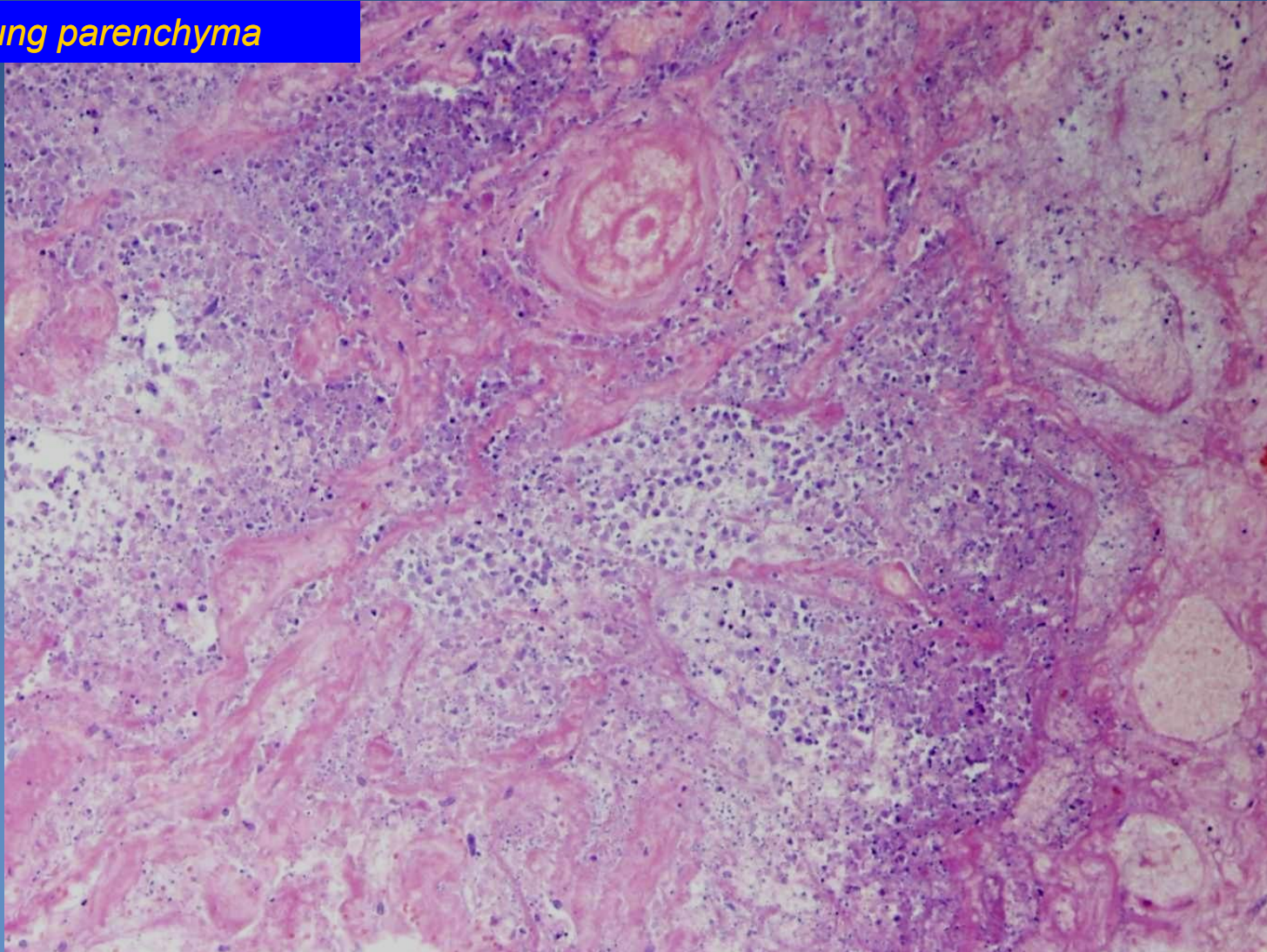


1. Necrotic focus
2. Lung parenchyma

Hemorrhagic pulmonary infarction



Necrotic lung parenchyma



Chronic pulmonary venous congestion



✗ associated with chronic left-sided cardiac insufficiency

⇒ **etiology:**

- ischemic heart disease, systemic hypertension, valvular disorders, cardiomyopathy

✗ clinically („asthma cardiale“):

⇒ **cough**

- rusty sputum

⇒ **shortness of breath (dyspnoea)**

- ortopnoea
- paroxysmal nocturnal dyspnoea
 - relieved by sleeping with elevated head („additional pillows needed“)

Chronic pulmonary venous congestion



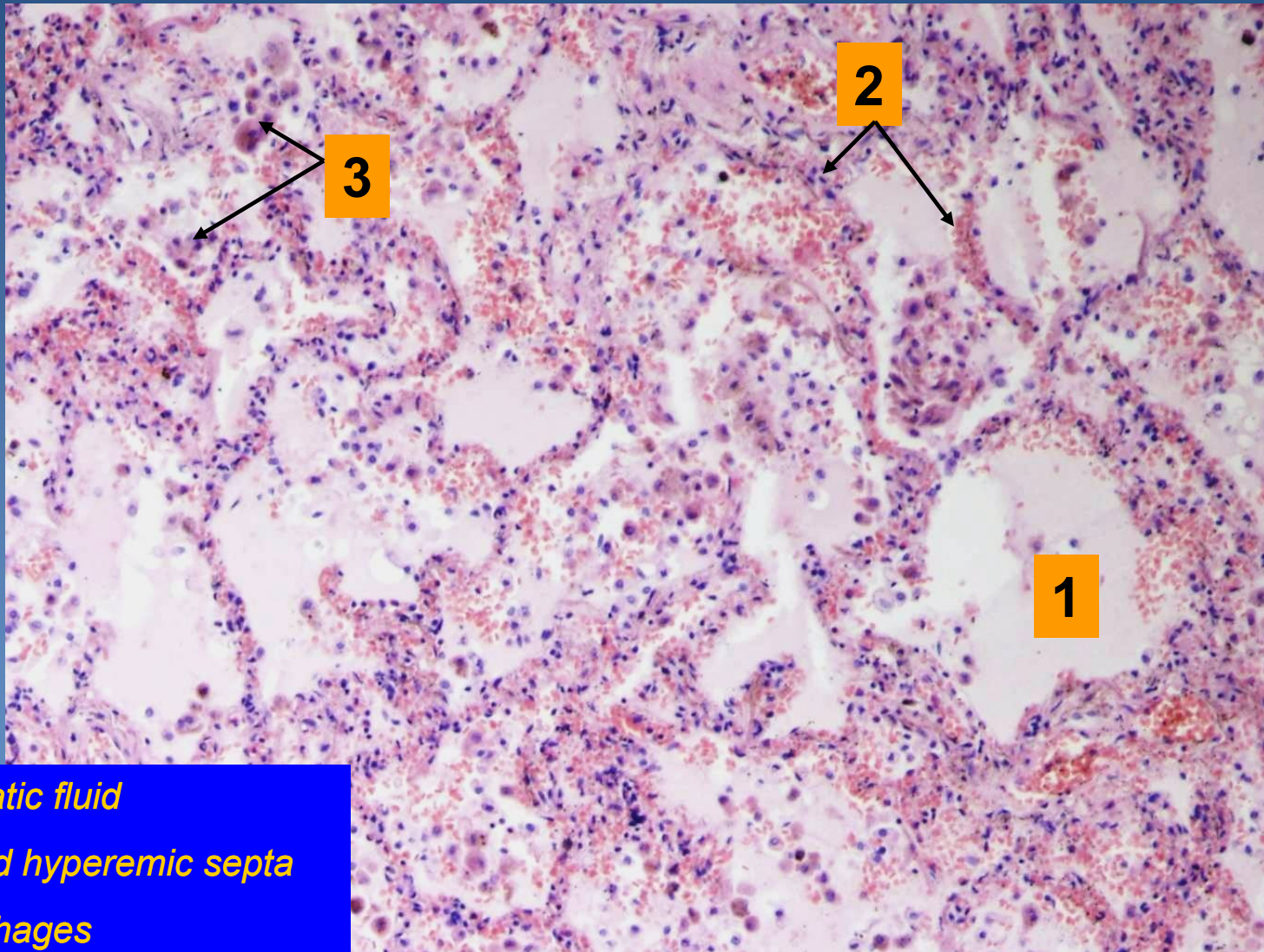
x Gross:

- ⇒ *slightly enlarged lungs*
- ⇒ *solid consistency*
- ⇒ *rusty-brown color*
 - rusty/cyanotic lung induration

x Micro:

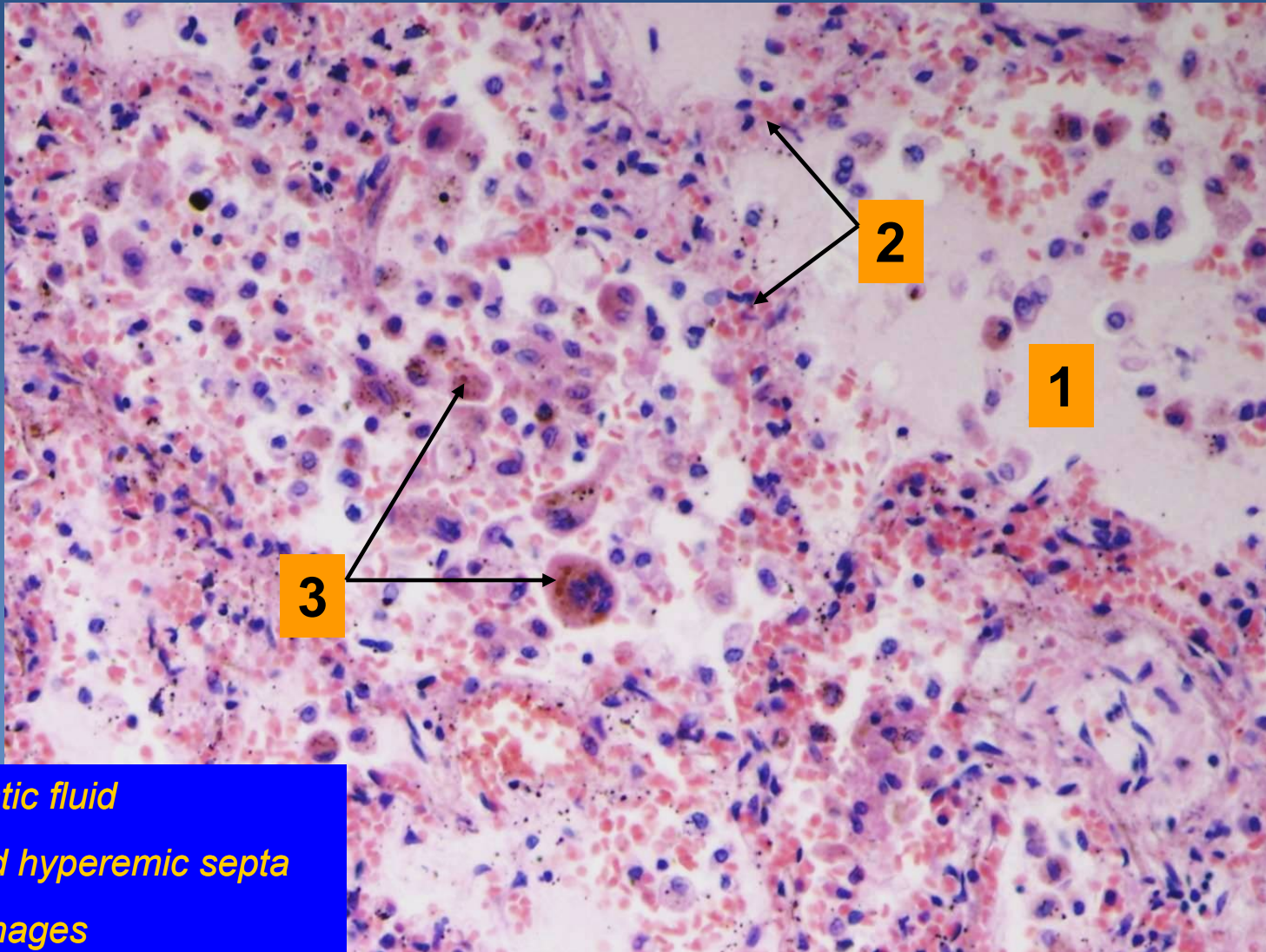
- ⇒ *congestion of alveolar capillaries*
- ⇒ *alveolar hemorrhage with siderophages:*
 - histiocytes with cytoplasmic granules of hemosiderin
- ⇒ *fibrotization of alveolar walls*

Chronic pulmonary venous congestion



- 1. Oedemetic fluid*
- 2. Enlarged hyperemic septa*
- 3. Siderophages*

Chronic pulmonary venous congestion

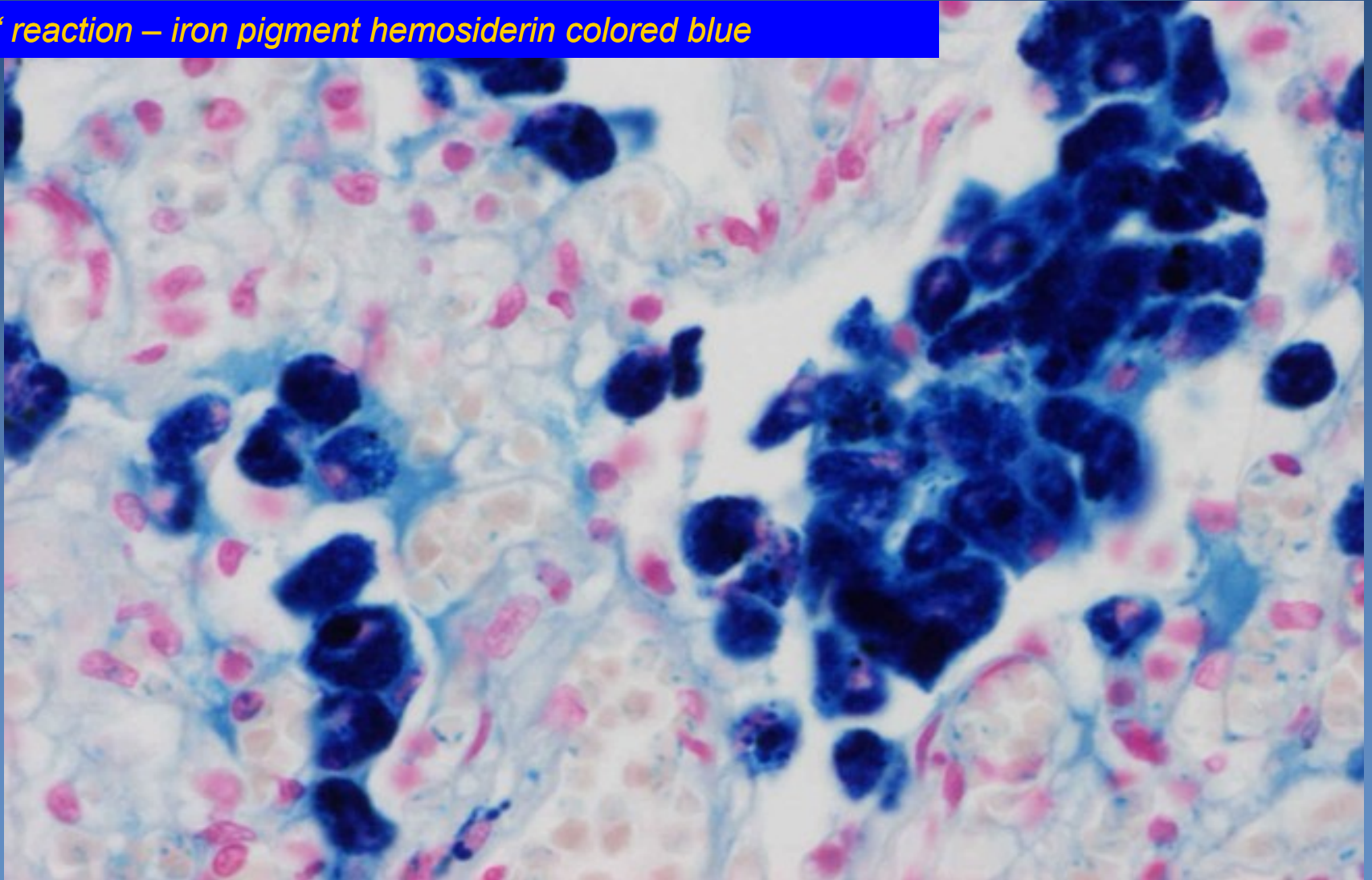


- 1. Oedemetic fluid*
- 2. Enlarged hyperemic septa*
- 3. Siderophages*

Chronic pulmonary venous congestion



Pertl's reaction – iron pigment hemosiderin colored blue



Alveolar oedema



- ✗ fluid accumulation in alveoli
- ✗ clinically:
 - ⇒ *expectoration of bubbly watery pinkish sputum*
- ✗ pathogenesis:
 - ⇒ *↑ vascular permeability (injury to the alveolar-capillary wall)*
 - ⇒ *↑ vascular hydrostatic pressure*
 - ⇒ *↓ intravascular osmotic pressure*
 - ⇒ *lymphatic drainage obstruction*

Alveolar oedema



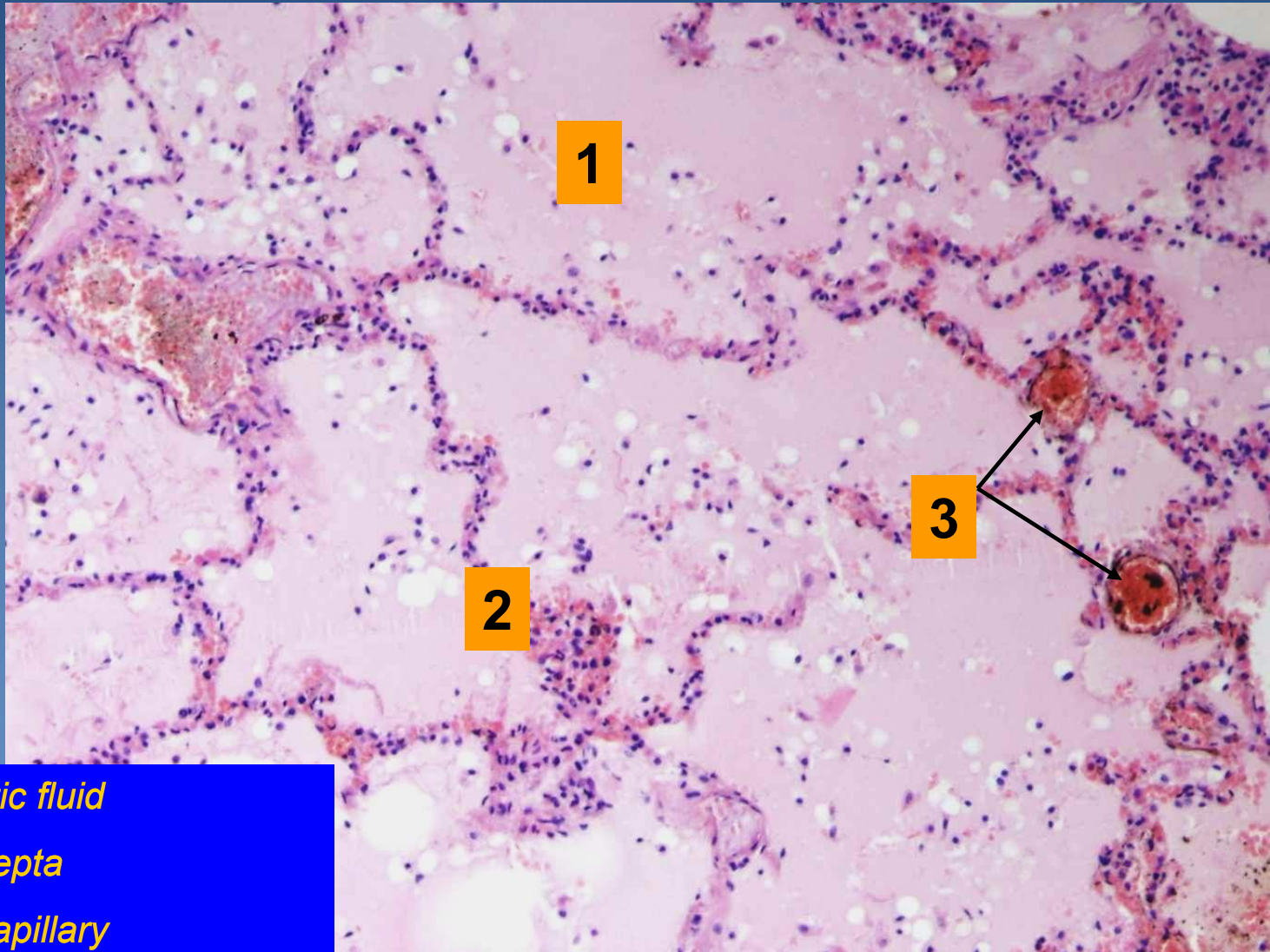
x Gross:

- ⇒ *lungs enlarged, heavy, congested*
- ⇒ *bubbly fluid flowing out of the tissue +/- present in bronchi*

x Micro:

- ⇒ *alveoli filled with pink, homogenous fluid + air bubbles*
- ⇒ *dilatation and hyperemia of alveolar wall capillaries*

Alveolar oedema



1

2

3

1. Oedematic fluid

2. Dilated septa

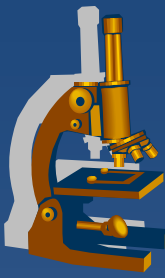
3. Dilated capillary

Amniotic fluid aspiration



- ✘ minor aspiration usual during birth
 - ⇒ *clinically insignificant*
- ✘ massive aspiration associated with fetus asphyxia
 - ⇒ *umbilical cord or placental disorders*
- ✘ clinic:
 - ⇒ *changes in fetal heart rate – immediate medical intervention necessary!*

Amniotic fluid aspiration



x Micro:

⇒ keratin masses in bronchi and alveoli

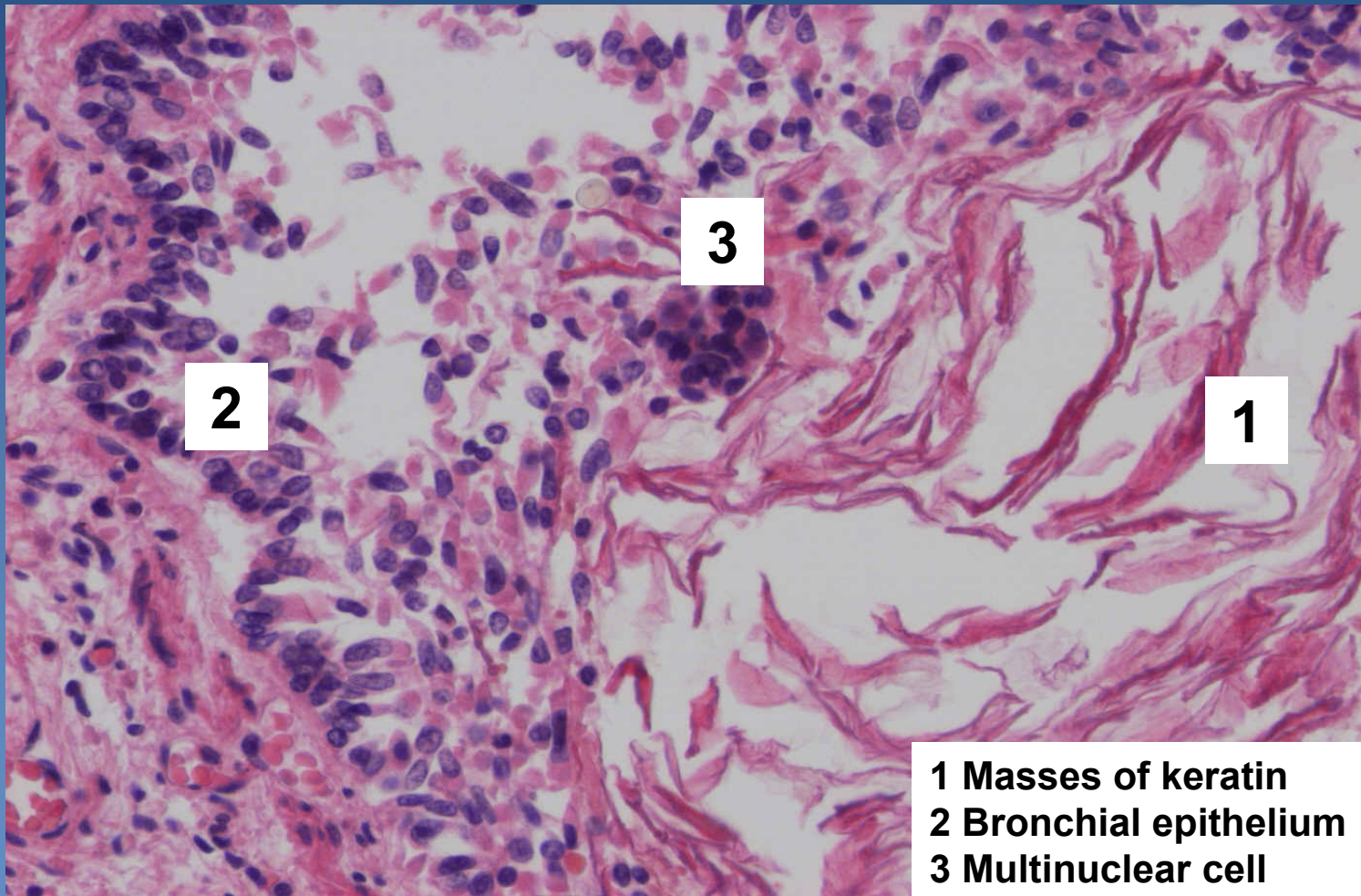
⇒ amniotic cells

⇒ lanugo (thin primary hairs)

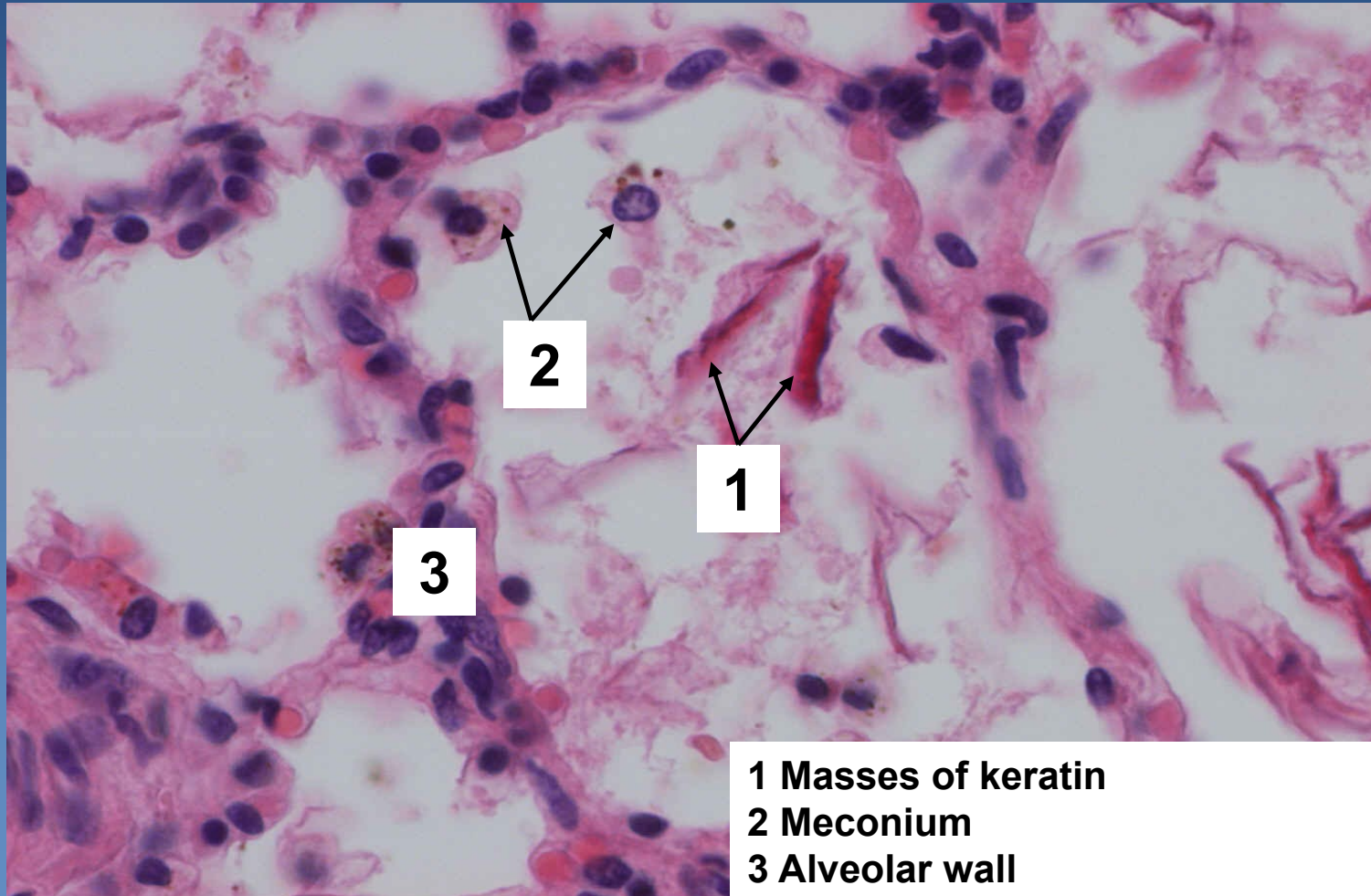
⇒ meconium bodies (from fetus intestinal content)

*⇒ infected amniotic fluid → fetal death, adnate **pneumonia***

Amniotic fluid aspiration, keratin in bronchiole



Amniotic fluid aspiration, keratin in alveoli



- 1** Masses of keratin
- 2** Meconium
- 3** Alveolar wall

Pulmonary inflammations - classification



x superficial:

⇒ *lobar pneumonia*

⇒ *bronchopneumonia*

x interstitial

⇒ *purulent (abscess, gangrene)*

⇒ *non-purulent*

- infectious (acute) – atypical pneumonia
- non-infectious (chronic)

Lobar pneumonia



- ✗ superficial diffuse **fibrinous** inflammation
- ✗ affecting major part / entire lobe of a lung
 - ⇒ *similar histological features in the same time*
 - ⇒ *older/immunocompromised patients → lethal without antibiotic therapy*
- ✗ untreated – 4 stages:
 - ⇒ *congestion (+ oedema)*
 - ⇒ *red hepatization (inflammatory infiltrate + congestion)*
 - ⇒ *grey hepatization (fibrin)*
 - ⇒ *resolution (resorption)*

Lobar pneumonia



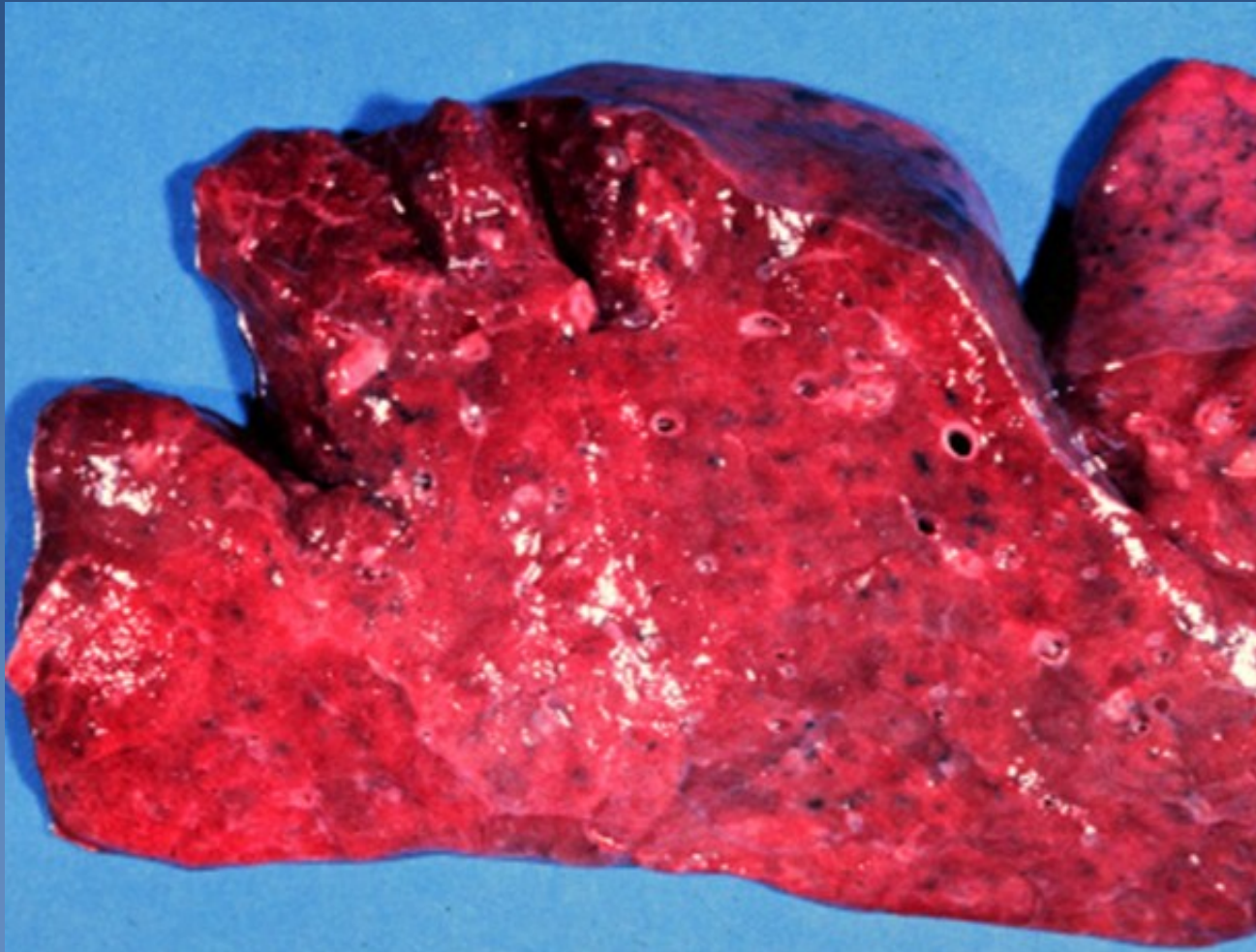
x healing:

⇒ *ad integrum*

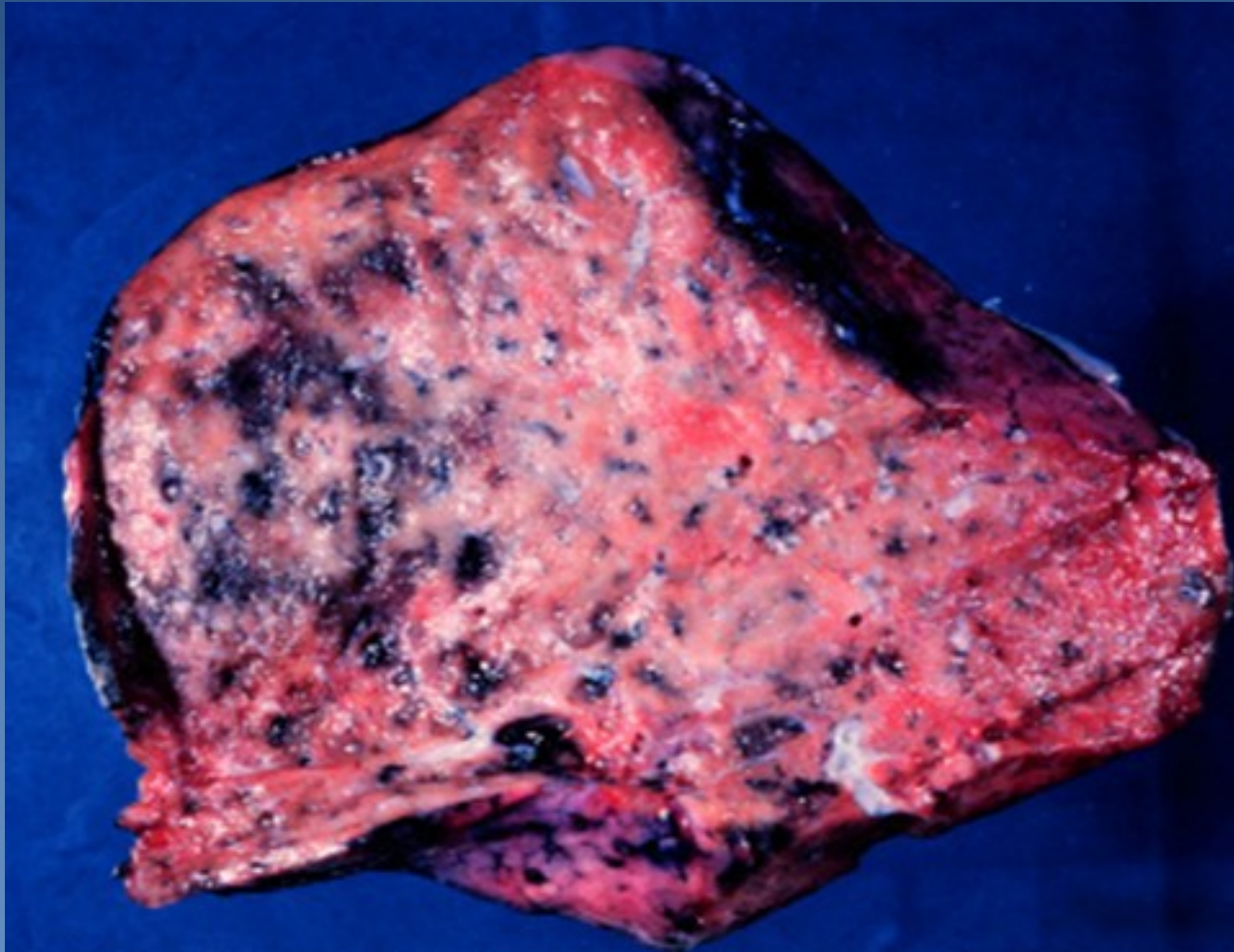
⇒ *complications:*

- empyema
- abscess
- carnification
- sepsis
- metastatic purulent inflammation
 - e.g. leptomeningitis, pericarditis, endocarditis...

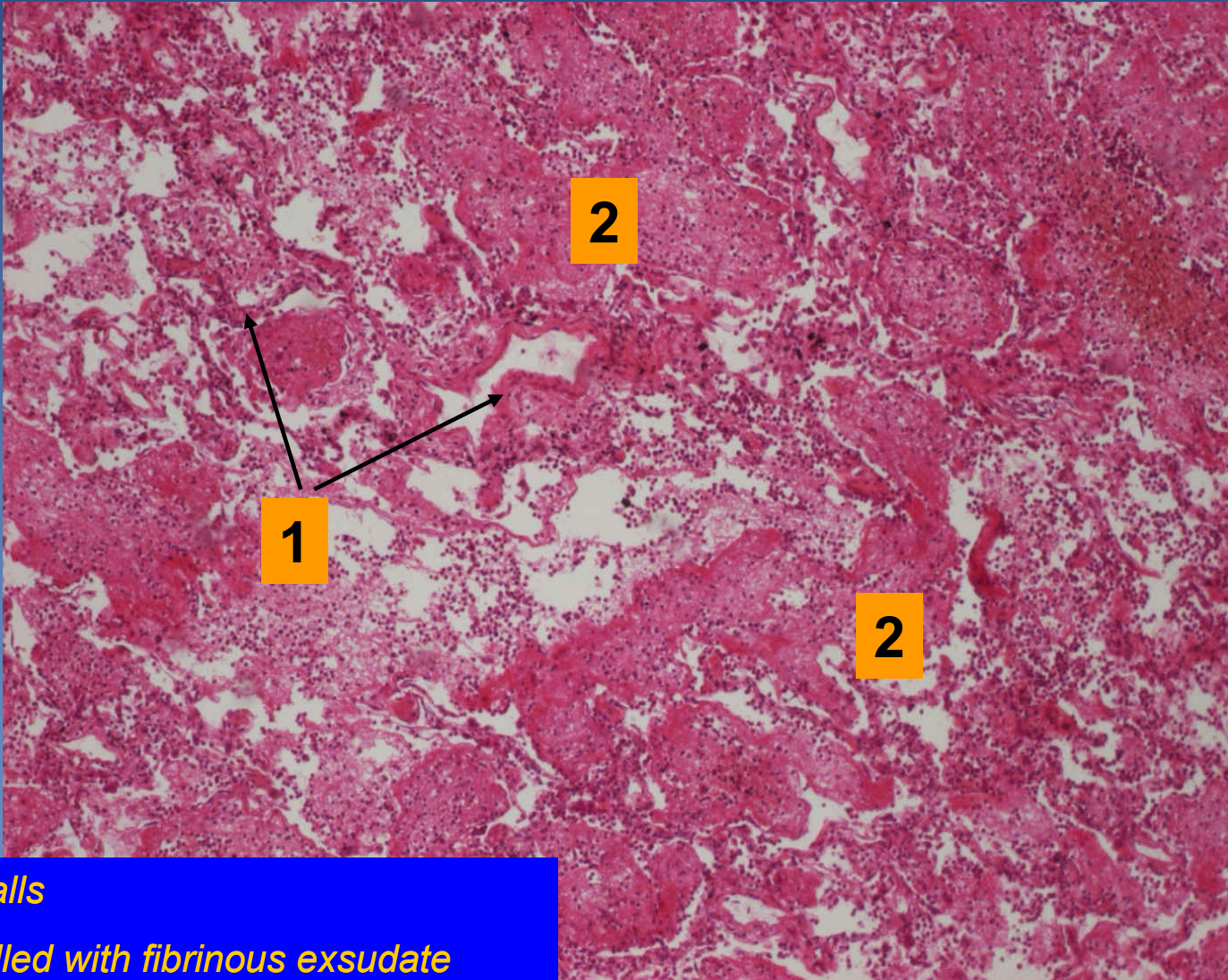
Lobar pneumonia, red hepatization



Lobar pneumonia, grey hepatization



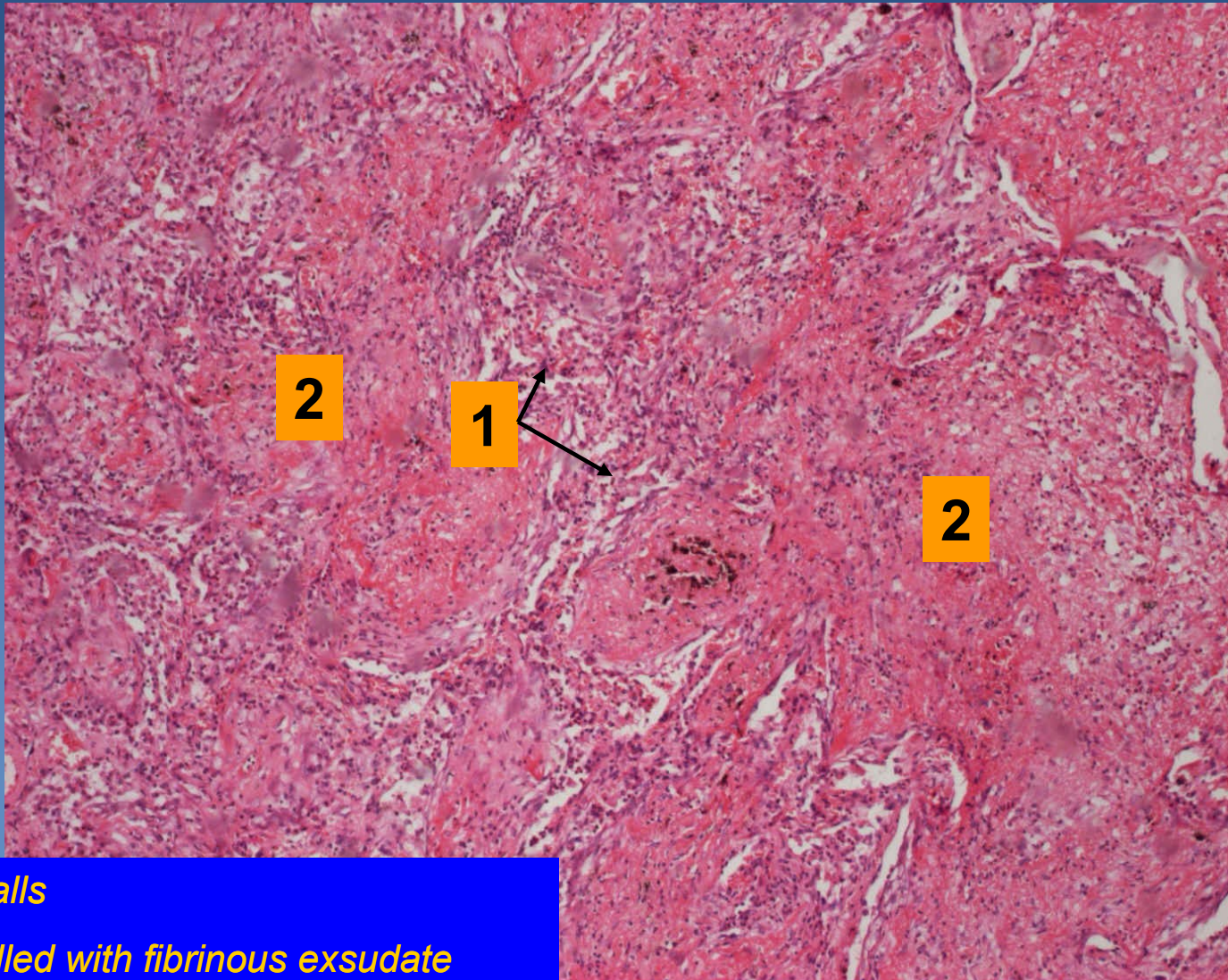
Lobar pneumonia



1. Alveolar walls

2. Alveoli fulfilled with fibrinous exudate

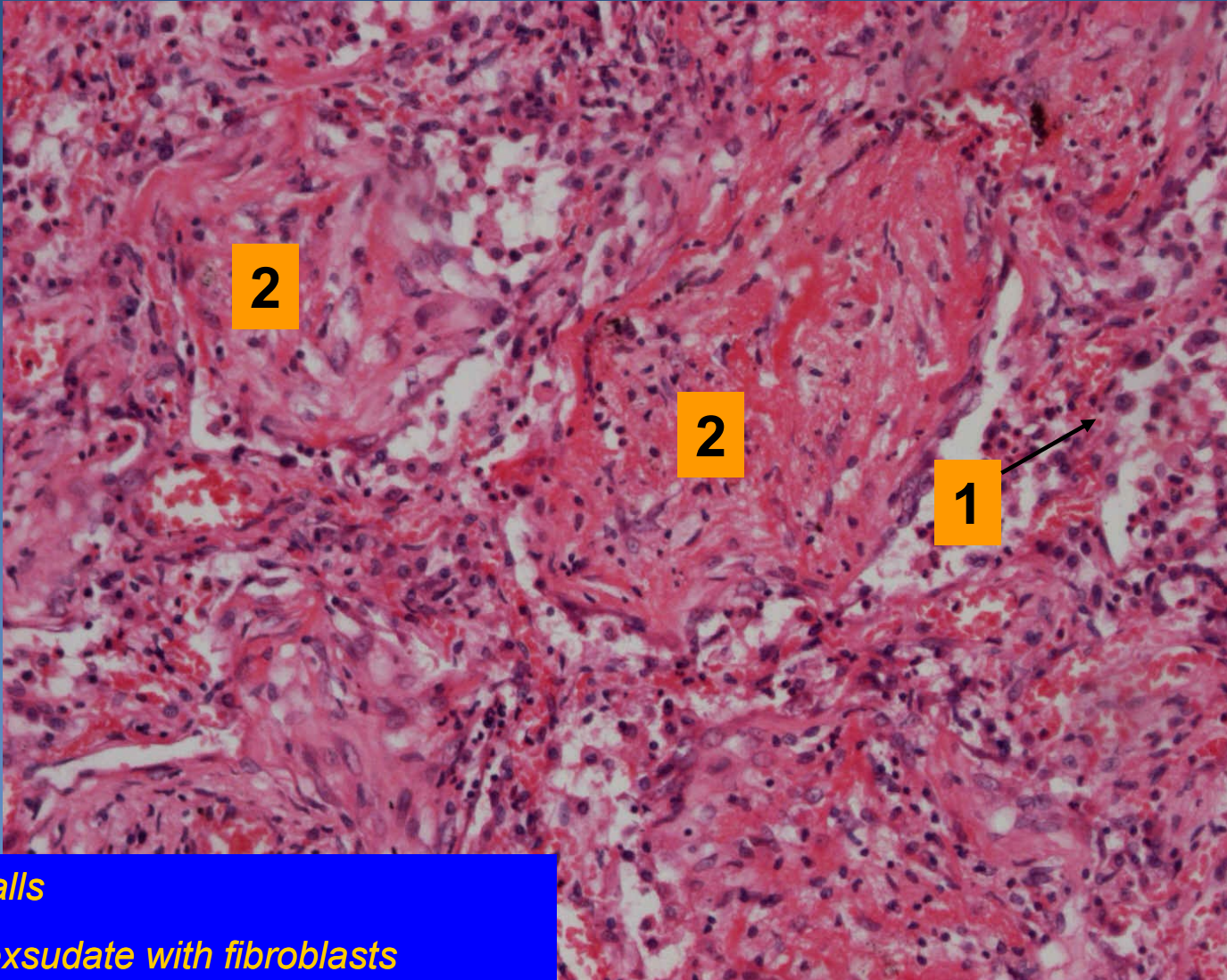
Lobar pneumonia



1. Alveolar walls

2. Alveoli fulfilled with fibrinous exsudate

Lobar pneumonia



2

2

1

1. Alveolar walls

2. Fibrinous exsudate with fibroblasts

Bronchopneumonia



- ✗ superficial type of pneumonia characterized by multiple foci of isolated, acute consolidation, affecting one or more pulmonary lobules
- ✗ inflammation spreads from bronchi
- ✗ aetiology:
 - ⇒ *streptococcus, staphylococcus, haemophilus, klebsiella*
 - ⇒ *legionella – micro:*
 - fibrinous purulent bronchopneumonia associated with fibrinous pleuritis
- ✗ possible secondary confluent inflammation, overlap patterns
- ✗ inflammatory complications:
 - ⇒ *pleuritis*
 - ⇒ *abscess*
 - ⇒ *sepsis*

Bronchopneumonia



× Gross:

⇒ *oedema, hyperemic tissue with small grey-yellow foci*

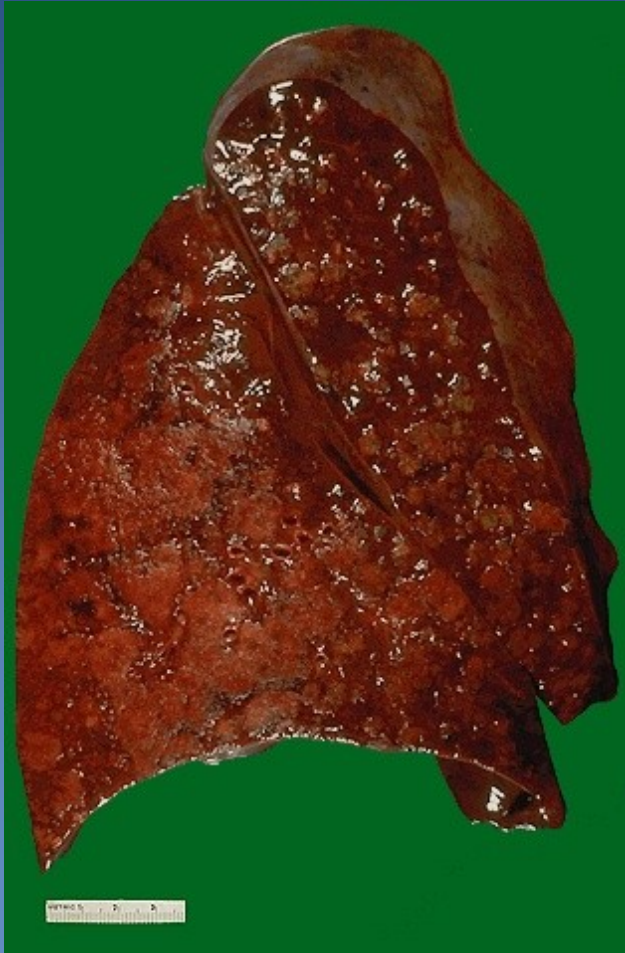× Micro:

⇒ *types of exsudate:*

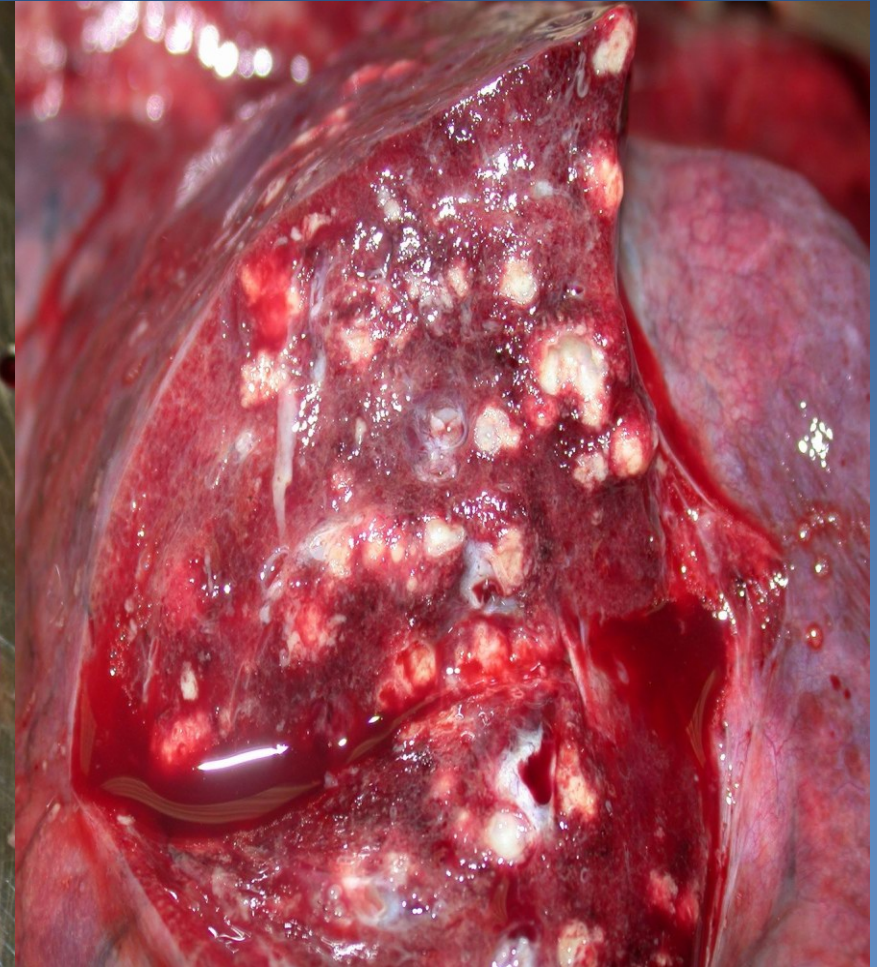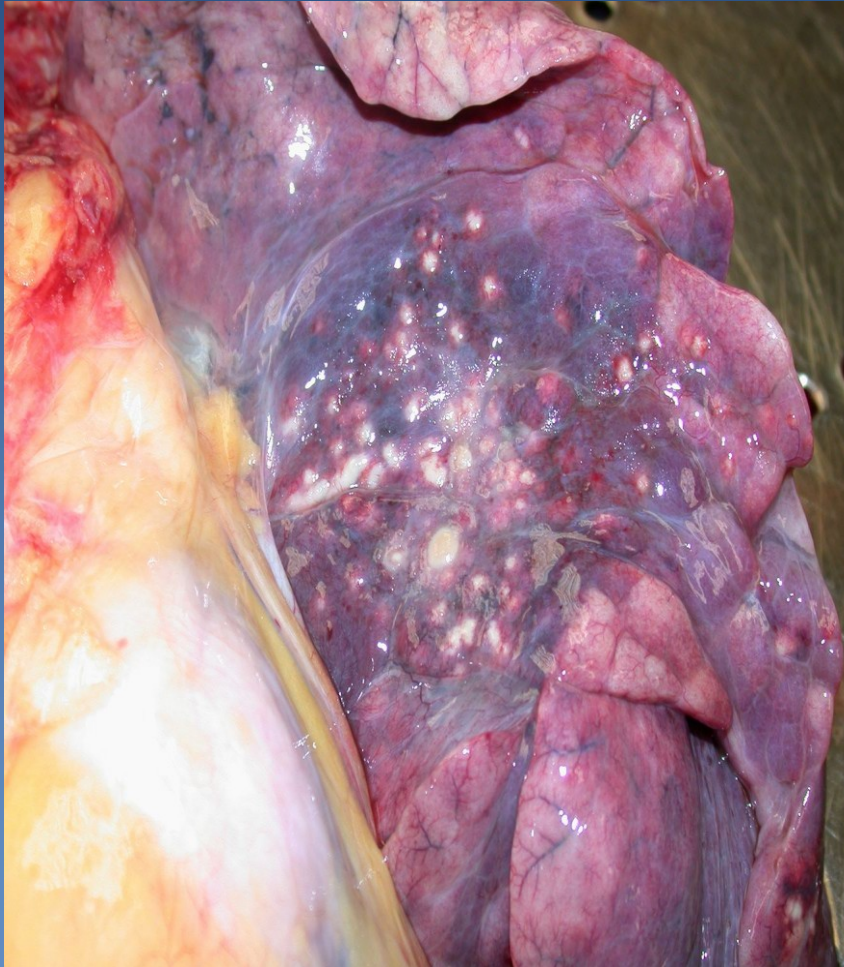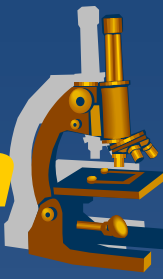- serous
- fibrinous
- suppurative (purulent)

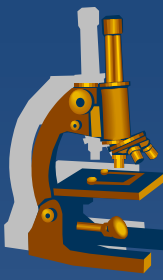
⇒ ***abscessing form*** – *suppurative destruction of alveolar walls*

Bronchopneumonia

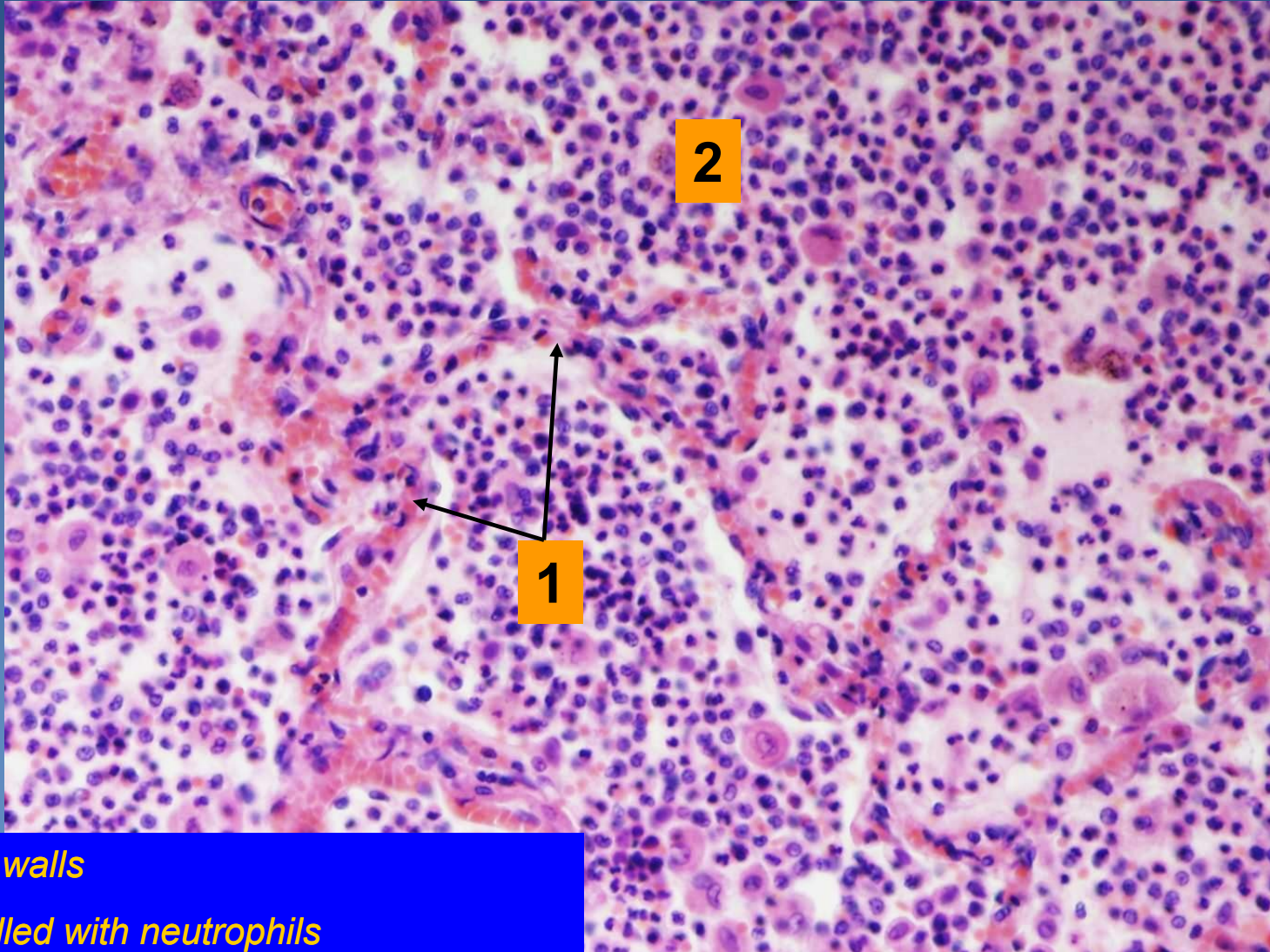


Abscessing bronchopneumonia





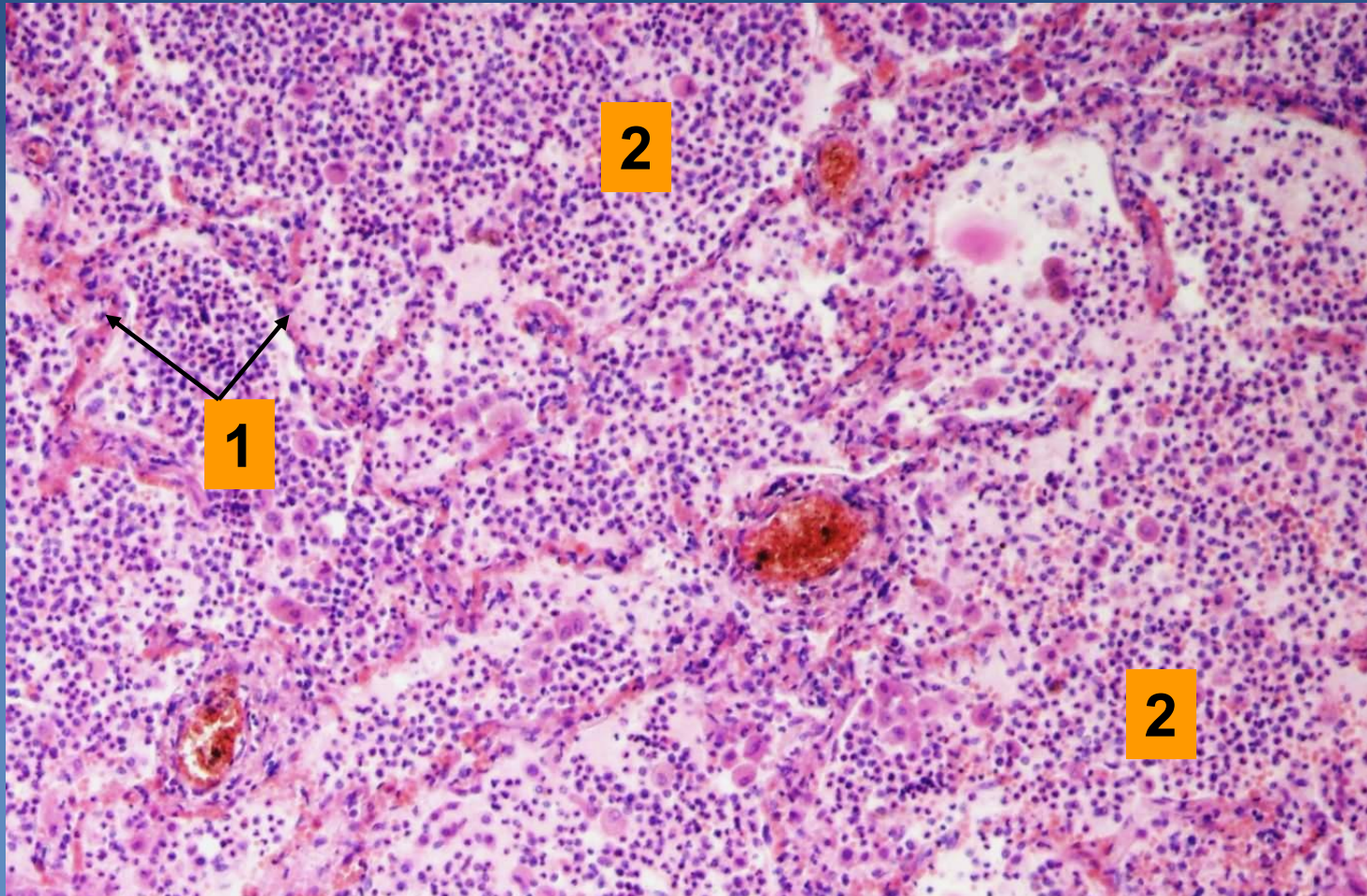
Purulent bronchopneumonia



1. Alveolar walls

2. Alveoli filled with neutrophils

Abscessing bronchopneumonia



1. Alveolar walls

2. Abscess with destruction of alveolar walls

Infectious interstitial pneumonia



x Etiology:

- ⇒ *viruses (incl. rubeola, varicella)*
- ⇒ *mycoplasma, chlamydia, coxiella, etc.*
- ⇒ *pneumocystis*

x Symptoms:

- ⇒ *fever, dyspnoea, dry cough, auscultation may be normal (empty alveoli), x massive changes on X-ray*

x Healing:

- ⇒ *ad integrum*
- ⇒ *secondary bacterial pneumonia*
- ⇒ *cryptogenic organizing pneumonia possible*

Infectious interstitial pneumonia



x Micro:

⇒ 1) *common histological features:*

- oedema and dilatation of alveolar walls
- interstitium with mononuclear infiltrate (lymphocytes, macrophages, plasma cells)
- possible ARDS - „hyaline membranes“ formation
 - necrotic pneumocytes and fibrin
 - eosinophilic material lining the lumen of alveoli

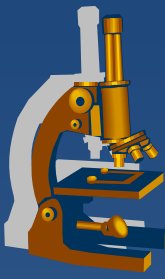Infectious interstitial pneumonia



⇒ 2) *inclusion pneumonia:*

- typical inclusions and cytopathologic changes of pneumocytes
- **CMV:**
 - large pneumocytes with basophilic intranuclear inclusions
- **Varicella, adenovirus:**
 - intranuclear inclusions
- **Measles:**
 - giant cell pneumonia
 - multinucleated cells in alveoli and bronchioli (Warthin-Finkeldey cells)
- **Pneumocystis pneumonia**

Pneumocystis pneumonia



x etiology:

⇒ *Pneumocystis jirovecii*

(opportunistic fungal infection, immunocompromised patients)

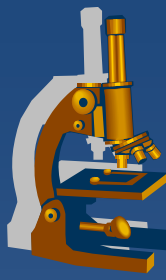
x Micro:

⇒ *widened alveolar septa, intraalveolar bubbly eosinophilic material:*

- pneumocystis capsules

⇒ *special histological stains:*

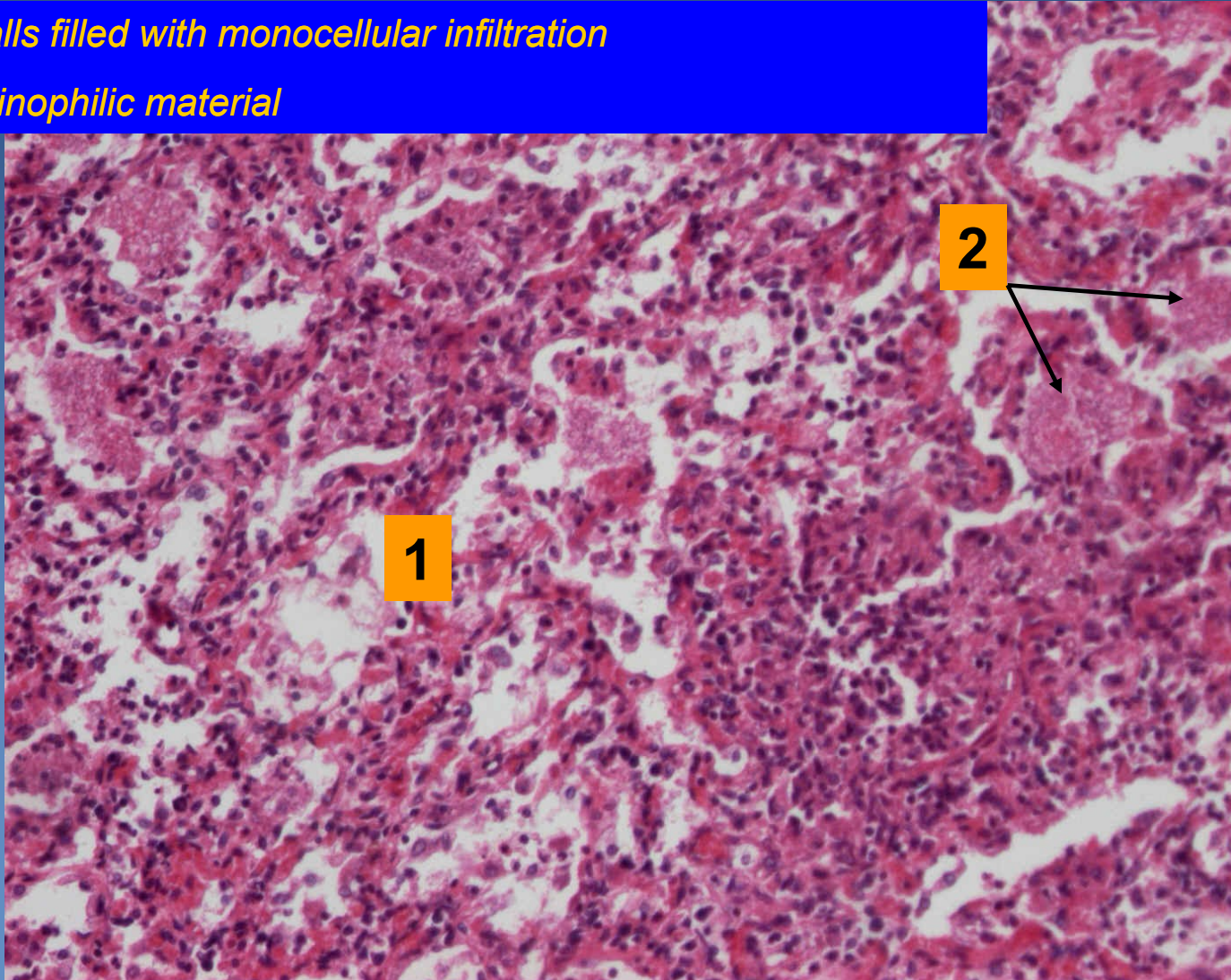
- Grocott silver impregnation (black)
- Giemsa (blue)
- PAS



Pneumocystis pneumonia

1. Alveolar walls filled with monocellular infiltration

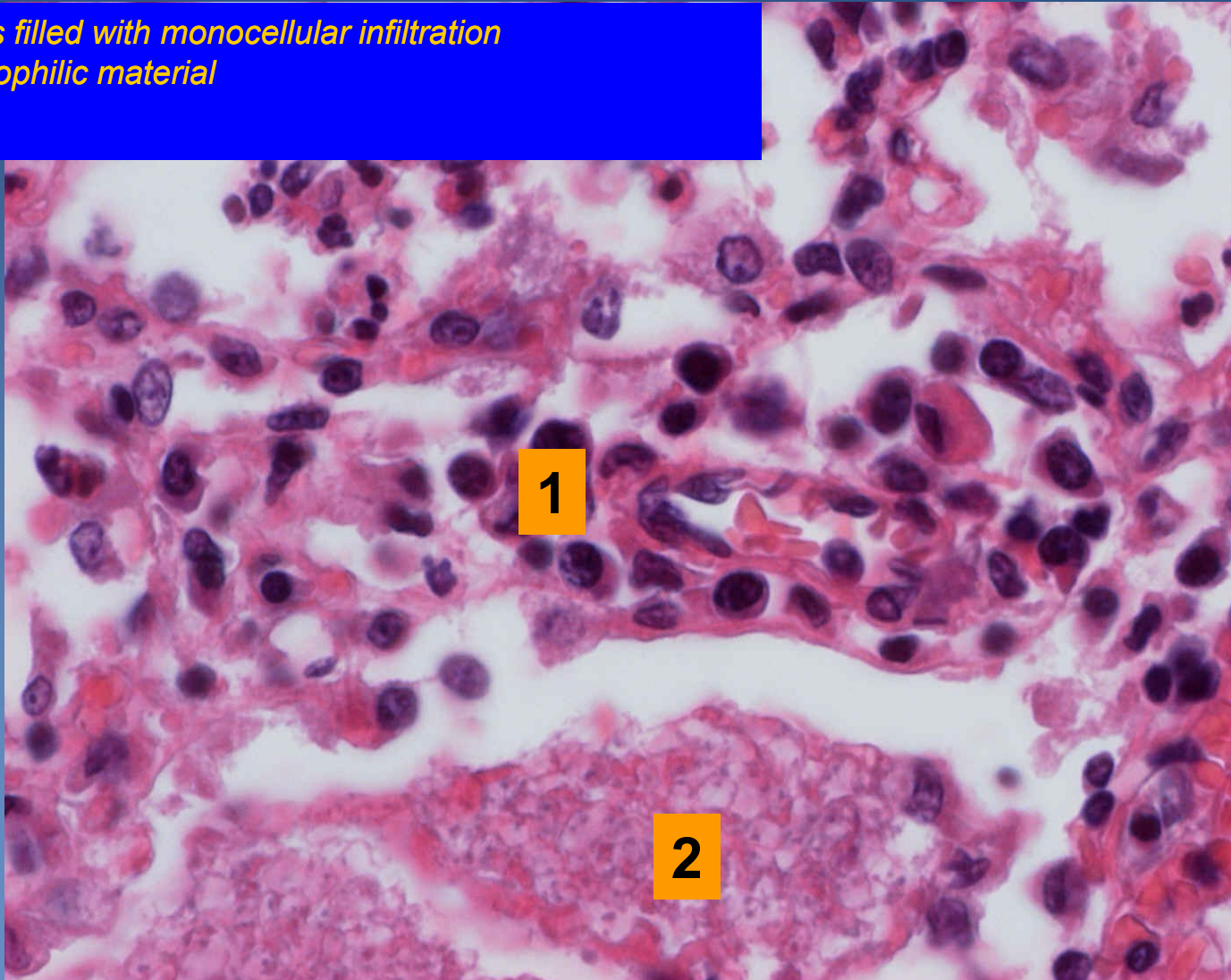
2. Bubbly eosinophilic material



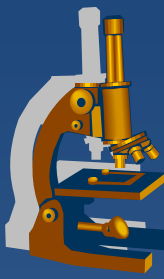
Pneumocystis pneumonia



1. Alveolar walls filled with mononuclear infiltration
2. Bubbly eosinophilic material



Neinfekční intersticiální pneumonie



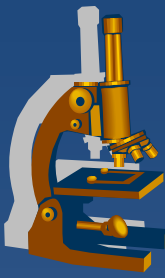
x Klasifikace:

⇒ *Kryptogenní fibrotizující alveolitida (idiopatická intersticiální pneumonie)*

- Běžná
- Nespecifická
- Deskvamativní
- Obrovskobuněčná

⇒ *Extrinzická fibrotizující alveolitida (hypersenzitivní pneumonitida)*

Idiopathic pulmonary fibrosis



✗ usual interstitial pneumonia“ (UIP):

⇒ **70% of all of idiopathic interstitial pneumonias**

⇒ **etiology:**

- in some collagenosis or in association with abnormalities of serum proteins
- smoking
- unclear

⇒ **dismal prognosis: lung transplantation**

⇒ **Mikro:**

- subpleural and a paraseptal foci of fibroblasts/fibrosis and chronic inflammatory infiltrate, cystic spaces - honeycombing
- irregular distribution of histological features – temporal heterogeneity

Idiopathic pulmonary fibrosis



✗ non-specific interstitial pneumonia (NSIP):

⇒ *commonly women, without link with smoking*

⇒ *better prognosis*

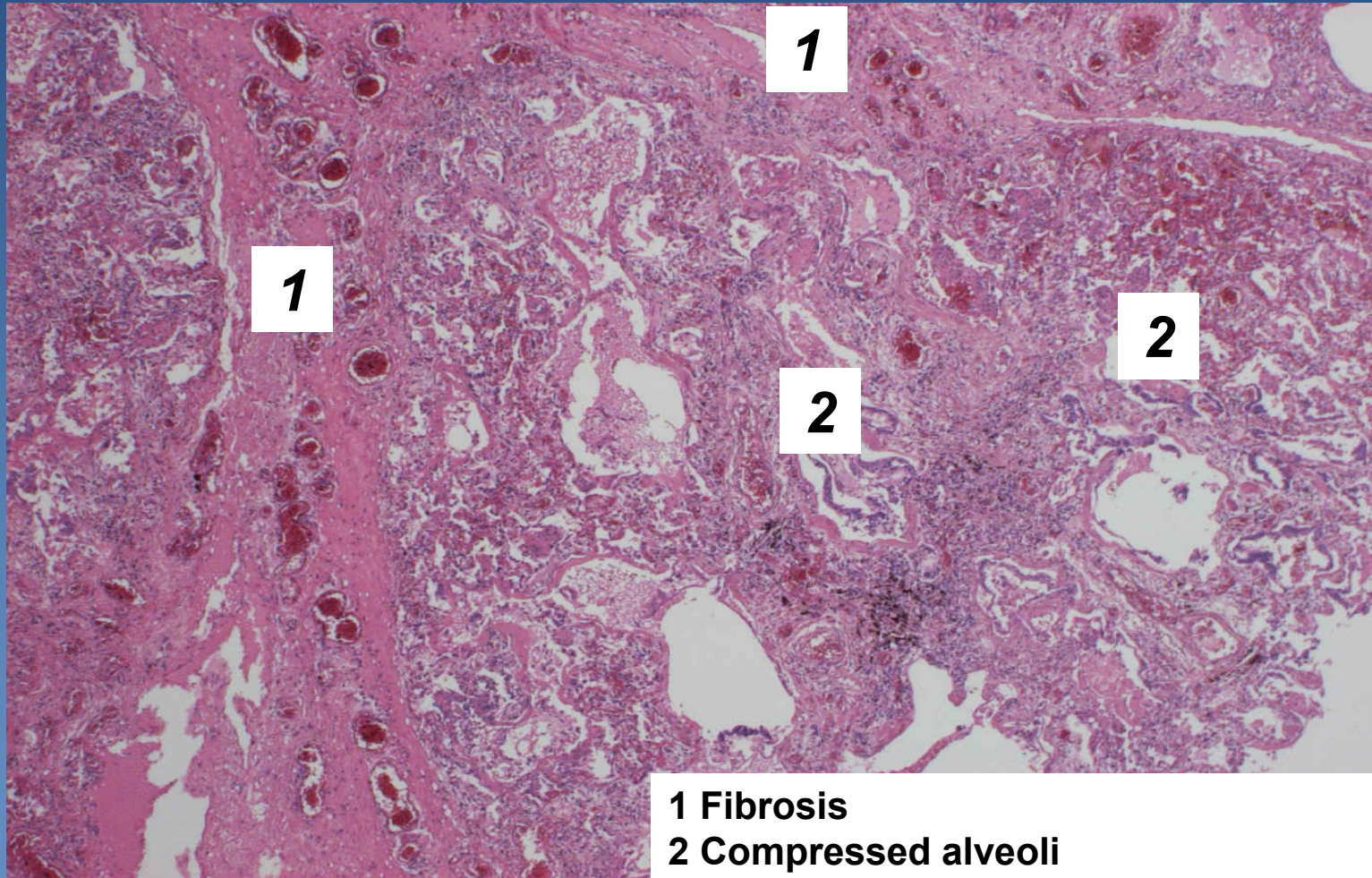
- treated with corticosteroids

⇒ **Micro:**

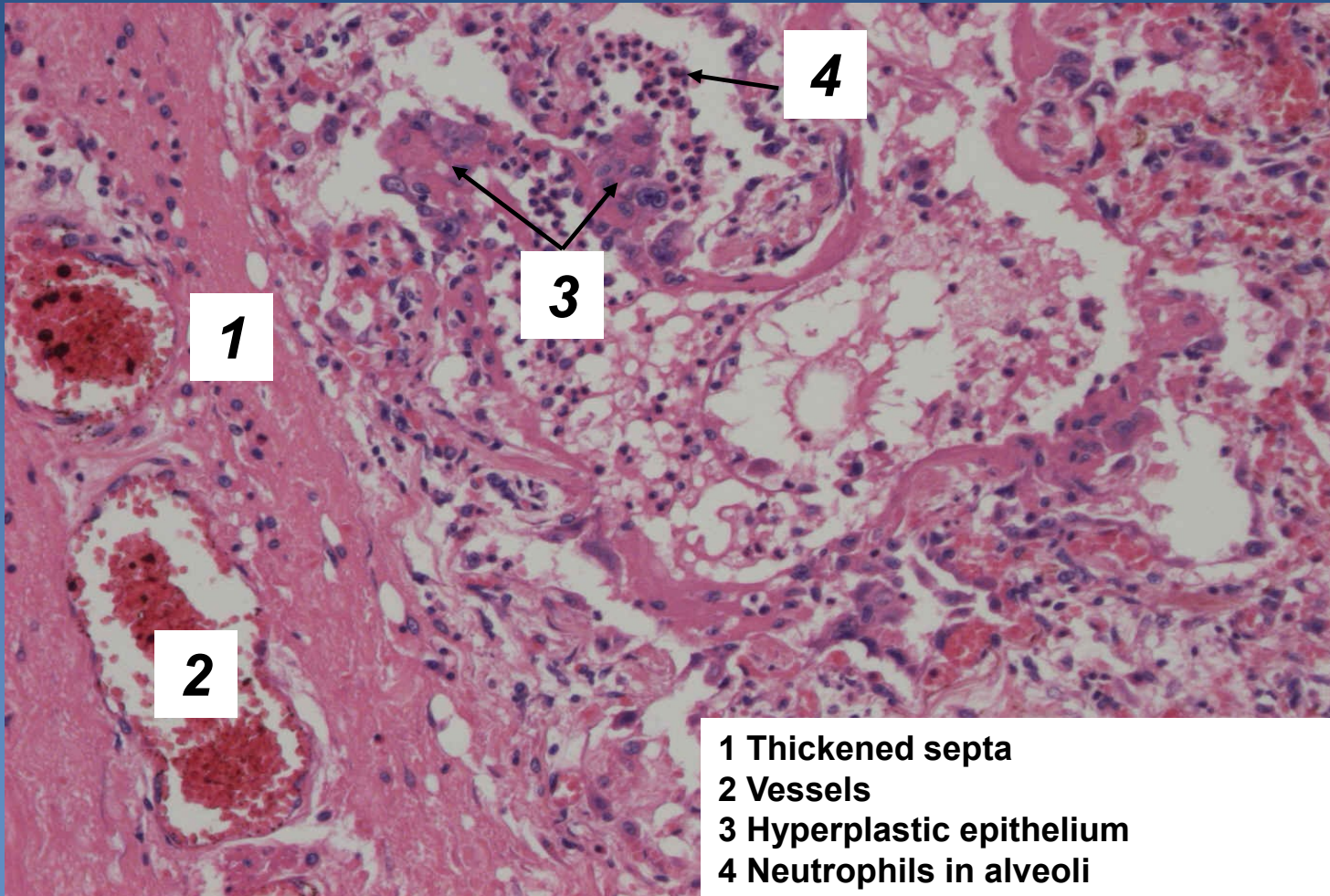
- chronic interstitial inflammation +/- fibrosis
- no honeycombing
- regular distribution of changes

-

Usual interstitial pneumonia

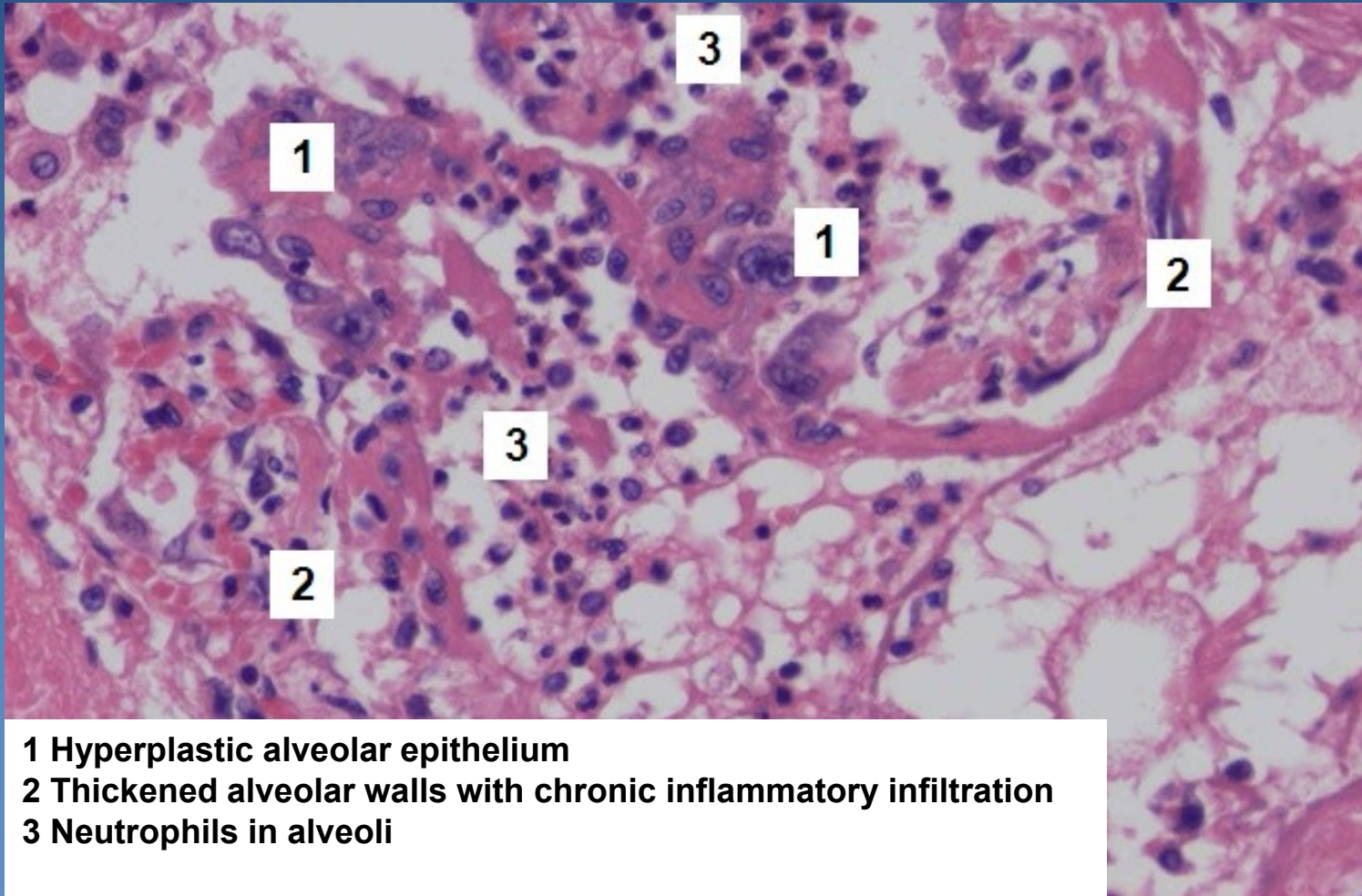


Usual interstitial pneumonia



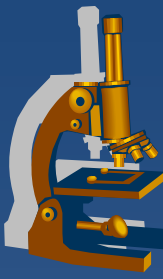
- 1 Thickened septa
- 2 Vessels
- 3 Hyperplastic epithelium
- 4 Neutrophils in alveoli

Usual interstitial pneumonia



- 1 Hyperplastic alveolar epithelium
- 2 Thickened alveolar walls with chronic inflammatory infiltration
- 3 Neutrophils in alveoli

Pneumoconiosis



- ✗ an occupational and restrictive lung disease caused by the inhalation of specific dust
- ✗ sequels: inert (simple), fibrous, allergic, neoplastic
- ✗ high fibrogenicity of cristalline silica dust and asbestos
- ✗ 3 basic types:
 - *coal-worker`s pneumoconiosis*
 - ⇒ *silicosis*
 - ⇒ *asbestosis*

Silicosis



- ✘ Chronic progressive pneumoconiosis
- ✘ Silicene dioxide particles (0,2-2 μ m) toxic to macrophages – focal necrosis + release of fibrogenic factors - fibrosis
- ✘ X-ray – reticular fibrosis, nodules, diffuse fibrosis
- ✘ lung insufficiency
- ✘ cor pulmonale

Silicosis



- × Gross (stages):

- ⇒ *reticular fibrosis*

- ⇒ *silicotic nodules*

- ⇒ *progressive massive fibrosis*

- × Micro:

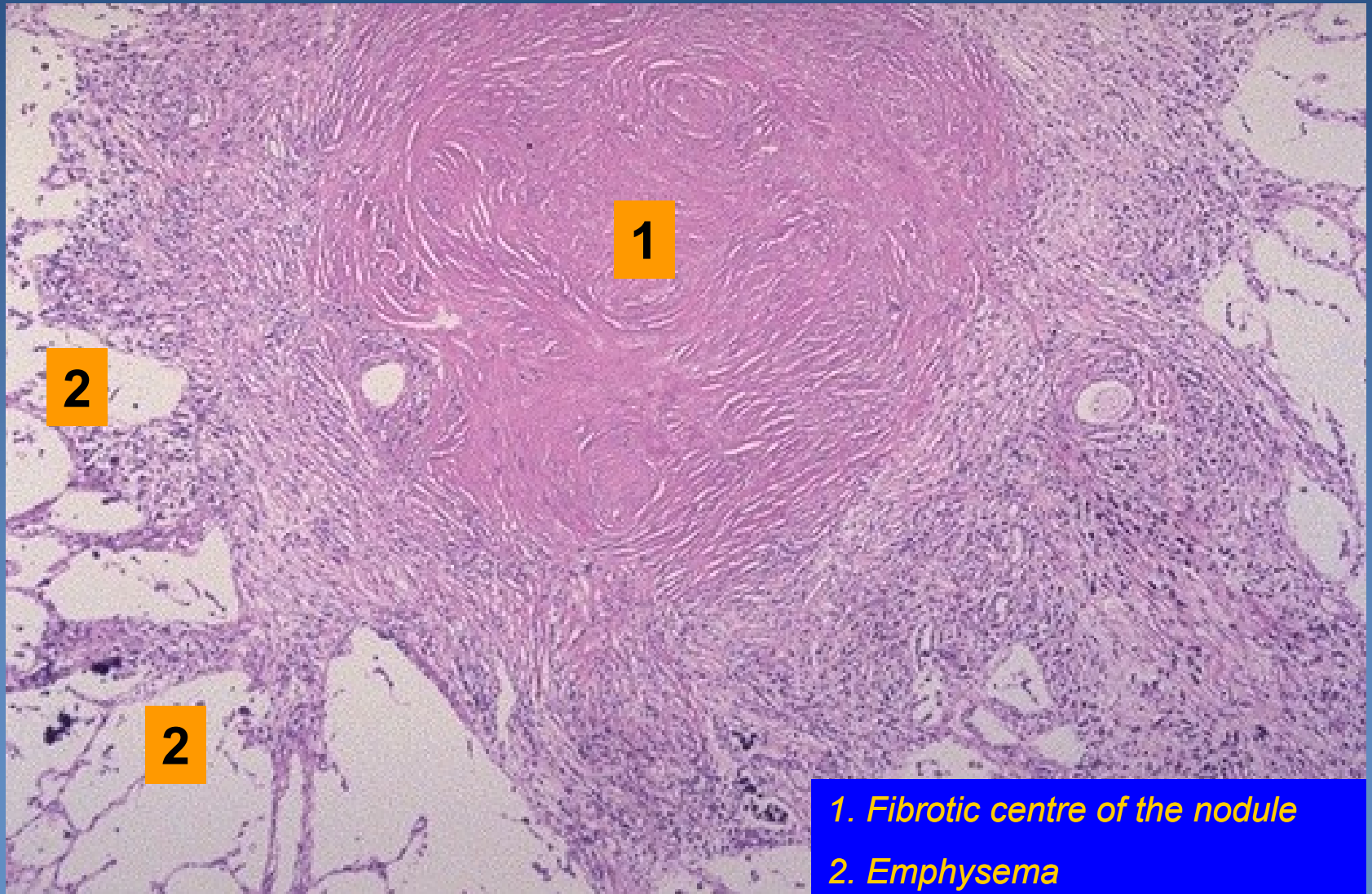
- ⇒ *nodules with concentric arrangement of hyalinized fibers and necrosis*

- ⇒ *anthracophages in the periphery of the nodule*

- ⇒ *emphysema in adjacent pulmonary tissue*

- ⇒ *particles seen under polarized light*

Silicotic nodule - lung

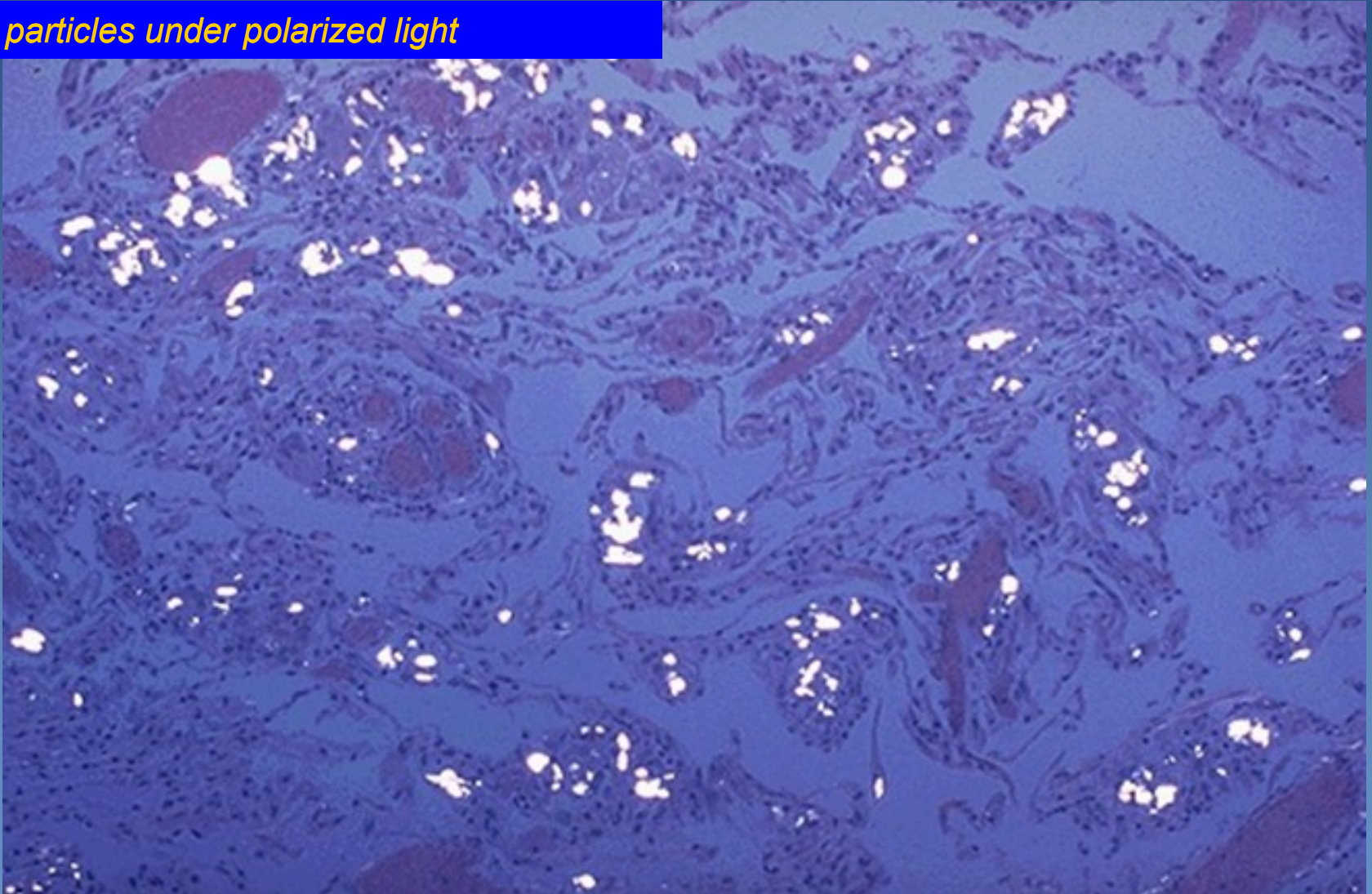


- 1. Fibrotic centre of the nodule*
- 2. Emphysema*

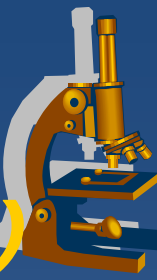
Pulmonary silicosis



Silica particles under polarized light

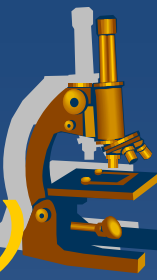


Diffuse alveolar damage (Acute Respiratory Distress Syndrome)



- × DAD (ARDS, RDS)
- × clinical:
 - ⇒ *progressive respiratory insufficiency associated with shortness of breath and hypoxia, high mortality*
- × Etiology:
 - ⇒ **Primary ARDS:**
 - lung inflammation/infection, aspiration of gastric content, mechanical trauma incl. chest contusion, fat embolism, near-drowning, ionizing radiation, inhaled irritants (smoke, chemicals),
 - ⇒ **Secondary ARDS:**
 - trauma (head) or sepsis
 - acute pancreatitis
 - renal insufficiency (uremia)
 - burns
 - hematologic conditions – DIC, multiple transfusions
 - chemical injury (heroin overdose, acetylsalicylates, ...)

Diffuse alveolar damage (Acute Respiratory Distress Syndrome)



x Gross:

- ⇒ *heavy lung*
- ⇒ *dark red color*
- ⇒ *boggy*

x Micro:

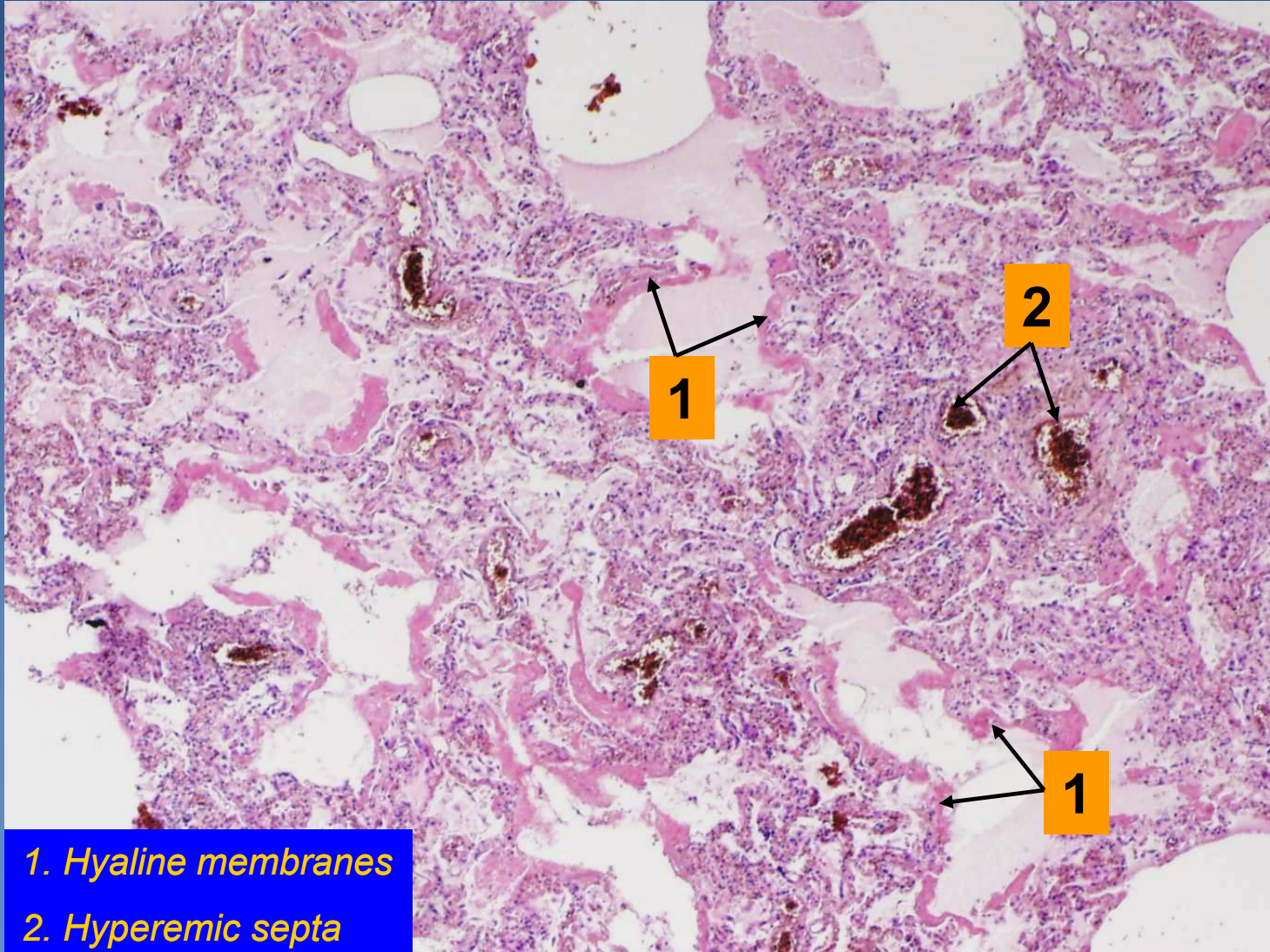
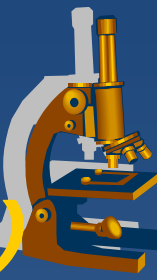
⇒ *exsudative phase:*

- capillary congestion, oedema, hyaline membranes formation within 48 hours

⇒ *proliferative phase:*

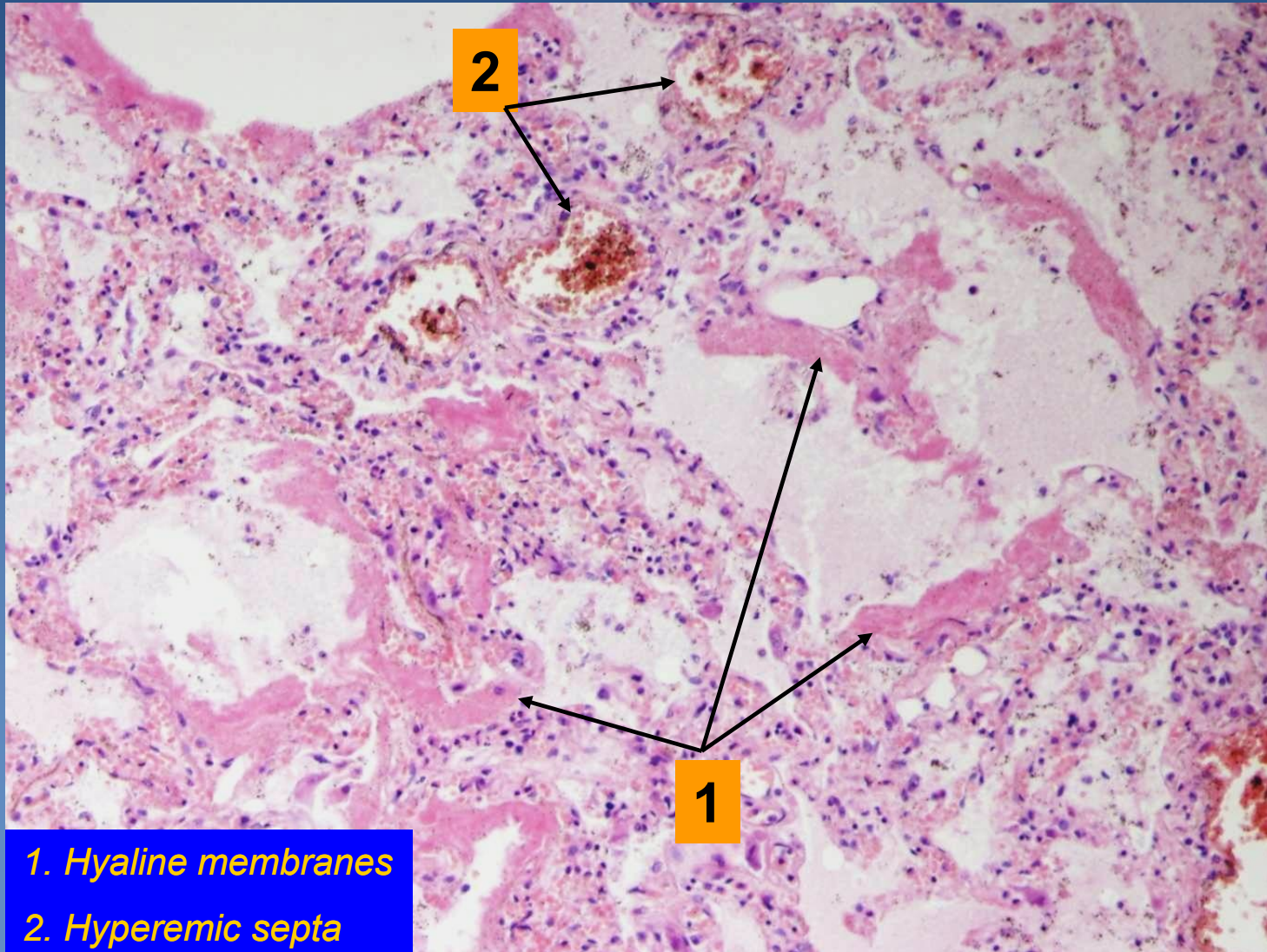
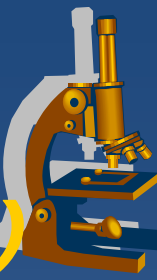
- epithelium regeneration (type II. pneumocytes)
- hyaline membranes ingested by macrophages
- proliferation of fibroblasts in alveolar walls -> pulmonary fibrosis possible

Diffuse alveolar damage (Acute Respiratory Distress Syndrome)



1. Hyaline membranes
2. Hyperemic septa

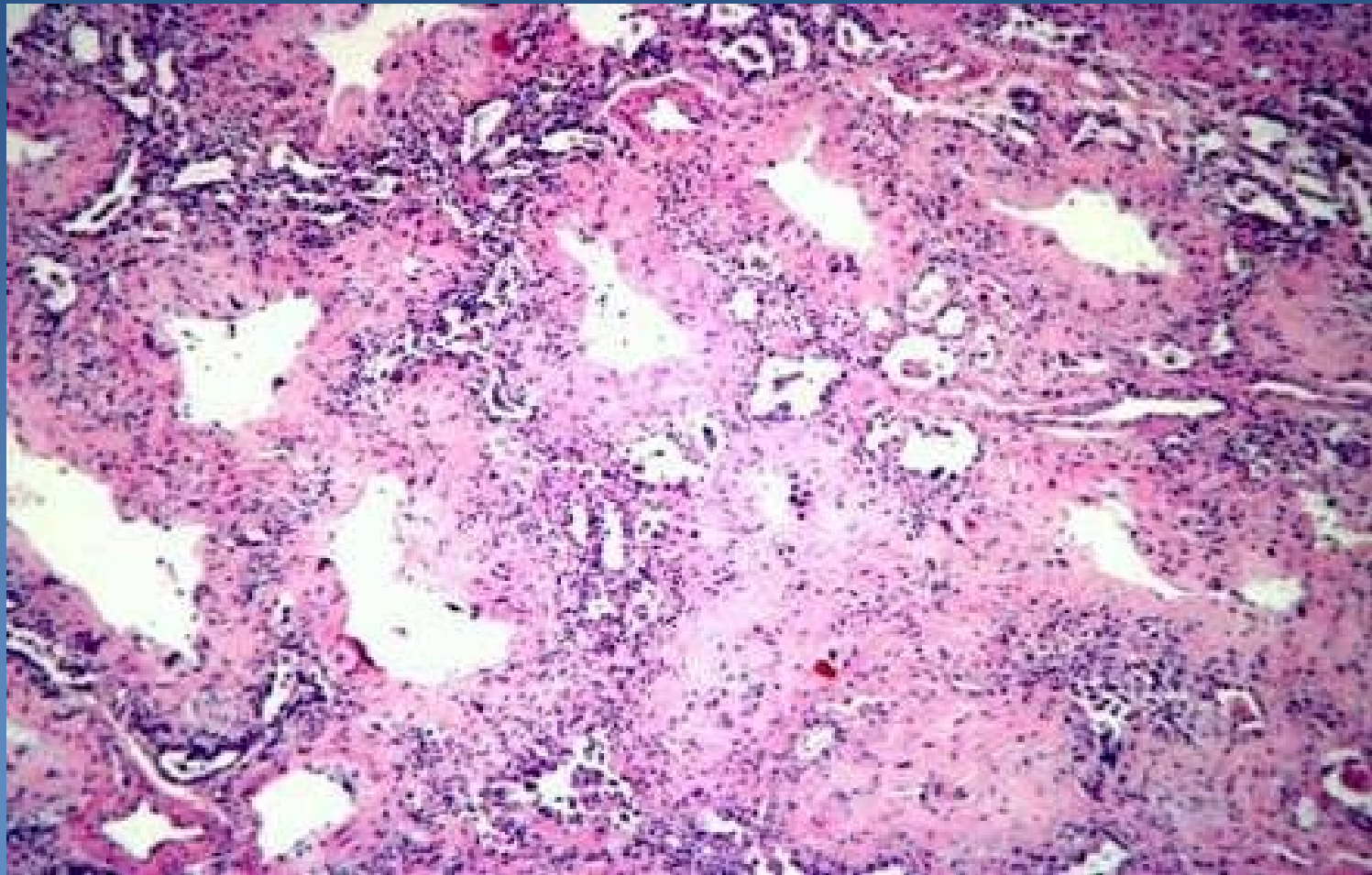
Diffuse alveolar damage (Acute Respiratory Distress Syndrome)



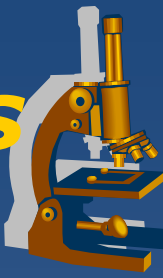- 1. Hyaline membranes
- 2. Hyperemic septa



6.3 DAD, proliferative phase - fibrotic stage – distinctly thickened interalveolar septa with a chronic inflammatory infiltrate.



Granulomatous inflammations - Tuberculosis



x aetiology

⇒ *Mycobacterium tuberculosis*, *M. bovis*

⇒ special *Ziehl-Neelsen stain*

- PCR more sensitive

x delayed-type hypersensitivity

(type IV. hypersensitivity)

⇒ *T cells-mediated immune memory response to TBC antigens (granulomas)*

Tuberculosis – morphological features



- × **tbc granuloma** – *proliferative form*
 - ⇒ *host resistance*
 - ⇒ *specific granulation tissue: epithelioid macrophages + Langhans giant cells*

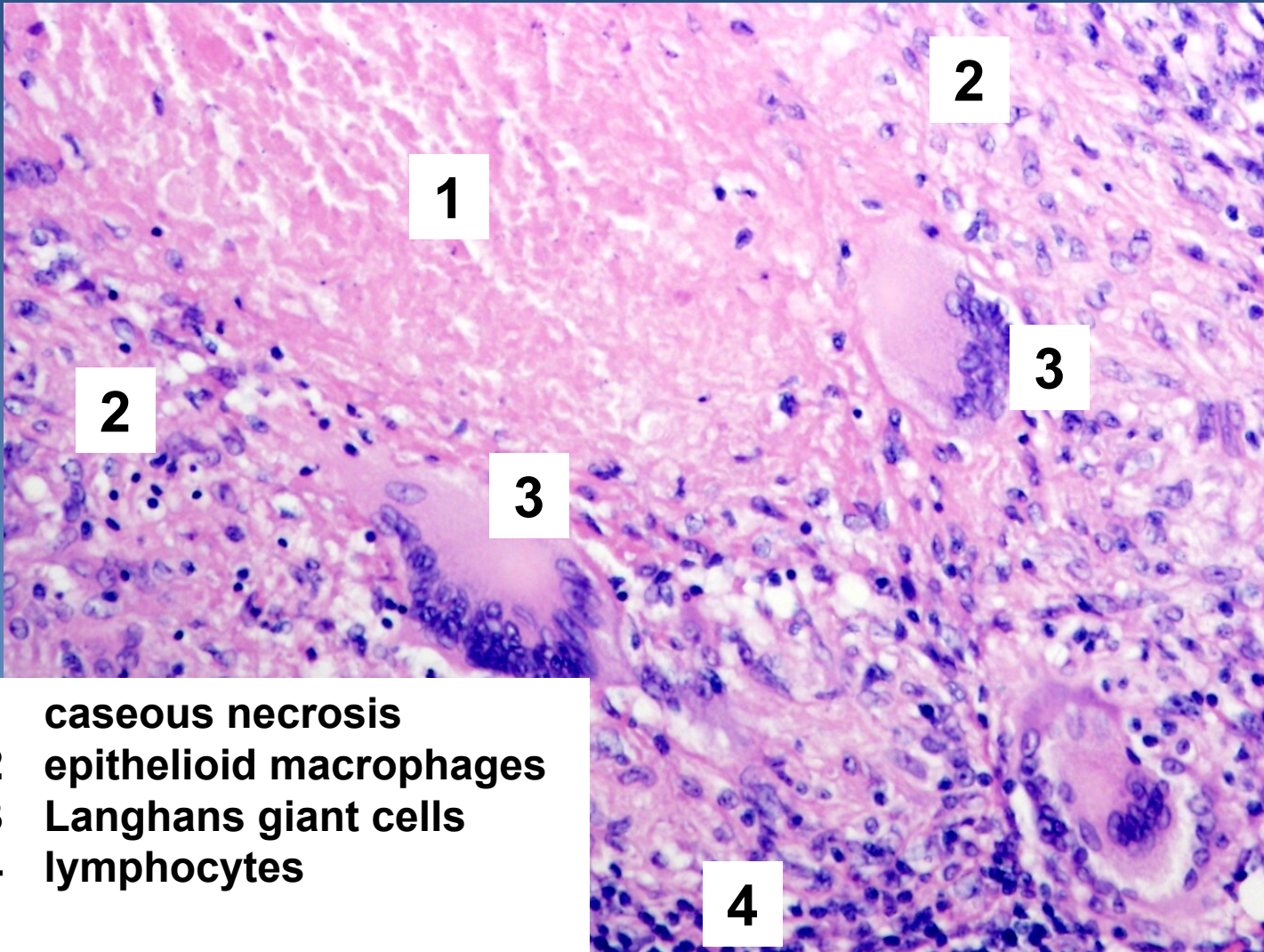
- × **tbc exsudate** – *exsudative form (meningitis)*
 - ⇒ *allergy*
 - ⇒ *serofibrinous exsudate + Orth cells (macrophages)*

- + **caseification**
 - ⇒ *cheese-like, caseous necrosis – sensitization?*

- + **colliquation (liquefaction)**
 - ⇒ *after release of proteolytic enzymes by neutrophils*

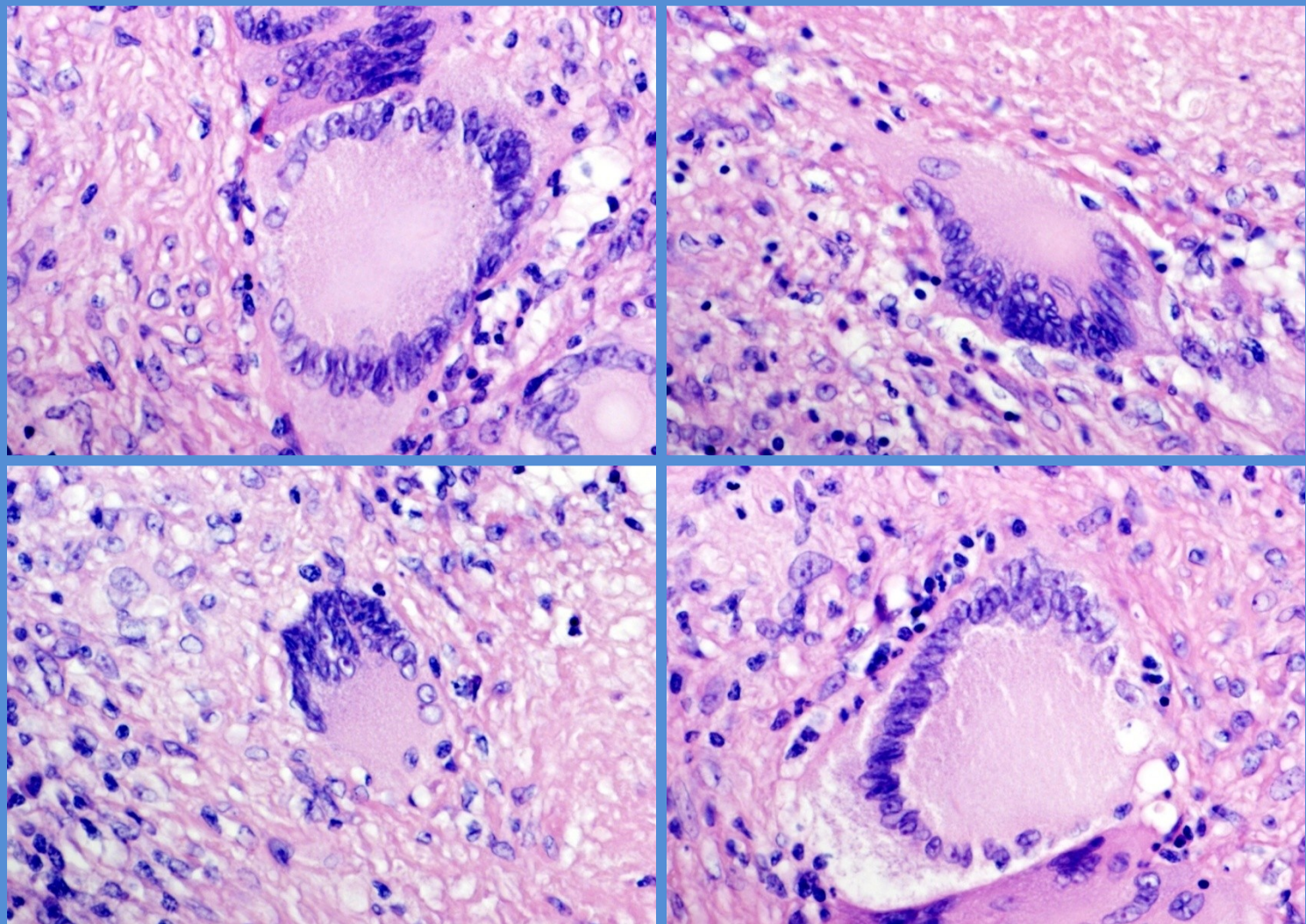
- + **calcification**

Tbc granuloma

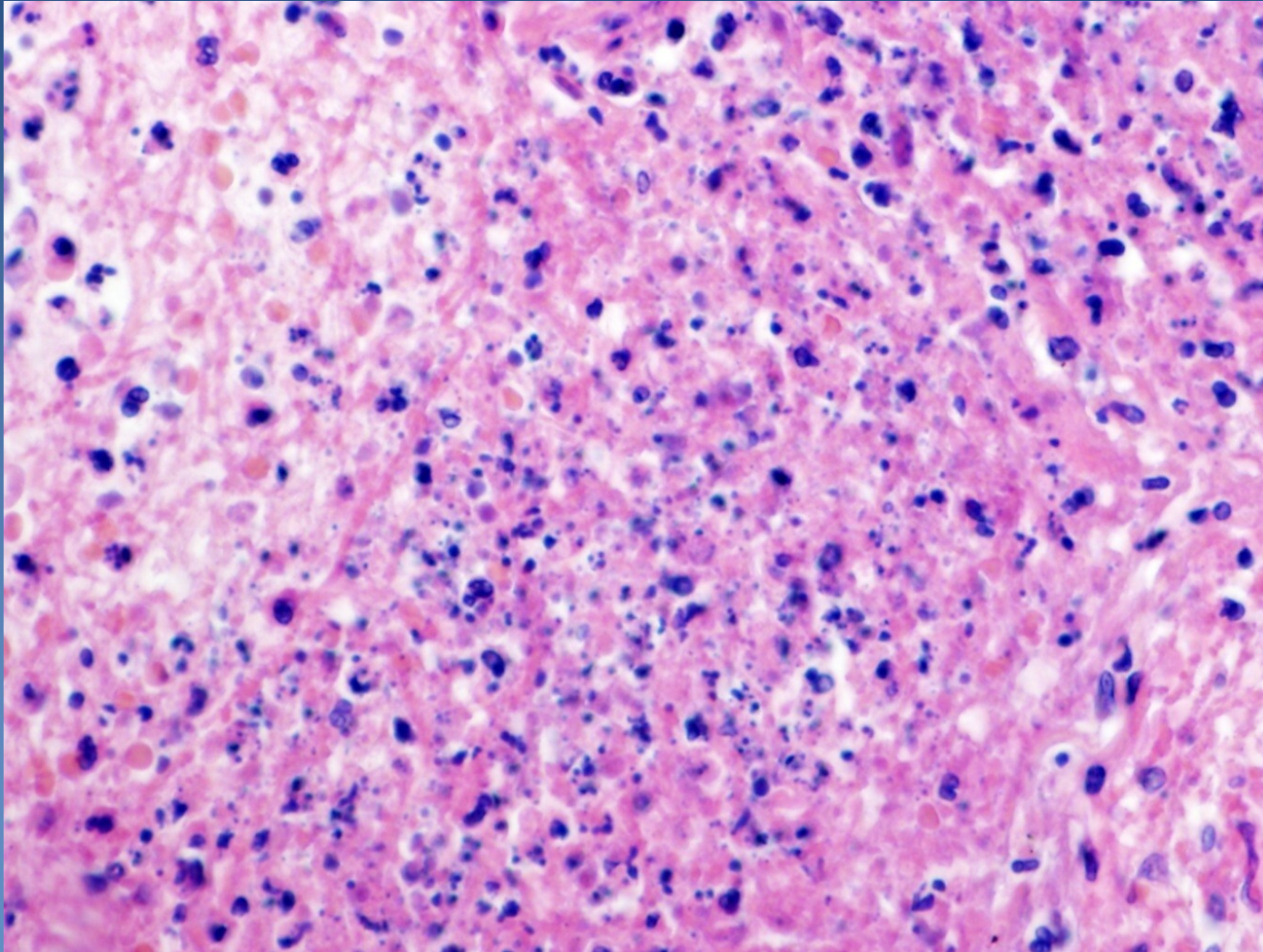
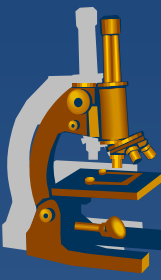


- 1 caseous necrosis
- 2 epithelioid macrophages
- 3 Langhans giant cells
- 4 lymphocytes

Langhans giant cells



Caseous necrosis



Sarcoidosis



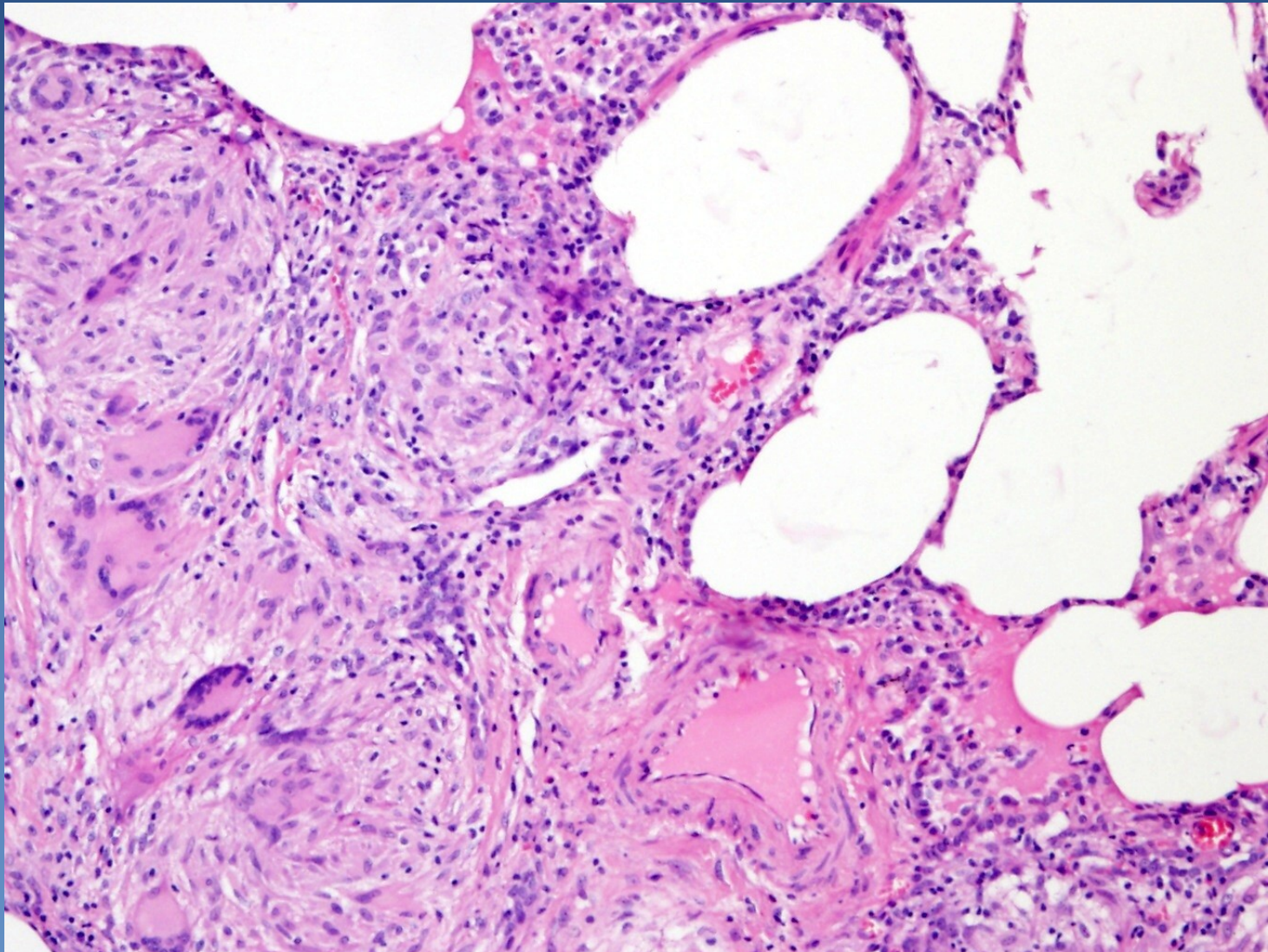
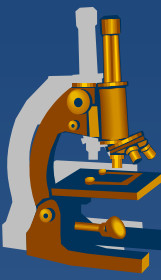
- ✗ chronic granulomatous inflammatory disease of unknown aetiology

- ✗ affected tissue:
 - ⇒ *mediastinal lymph nodes, lungs, skin, eye*
 - ⇒ *granulomas can affect any organ*

- ✗ small regular granulomas similar to TBC granulomas, but without caseous necrosis, fibrosis usually more pronounced
- ✗ cytoplasmic bodies of Langhans giant cells, not specific:
 - ⇒ *asteroid inclusions*
 - ⇒ *Schaumann bodies*

- ✗ dg. *per exclusionem* – necessary elimination of TBC, fungal infection etc.

Sarcoidosis



Pulmonary chondrohamartoma



- ✘ hamartoma? benign tumor?
- ✘ incidental X-ray finding
- ✘ differential diagnosis x malignant tumors important!

Pulmonary chondrohamartoma



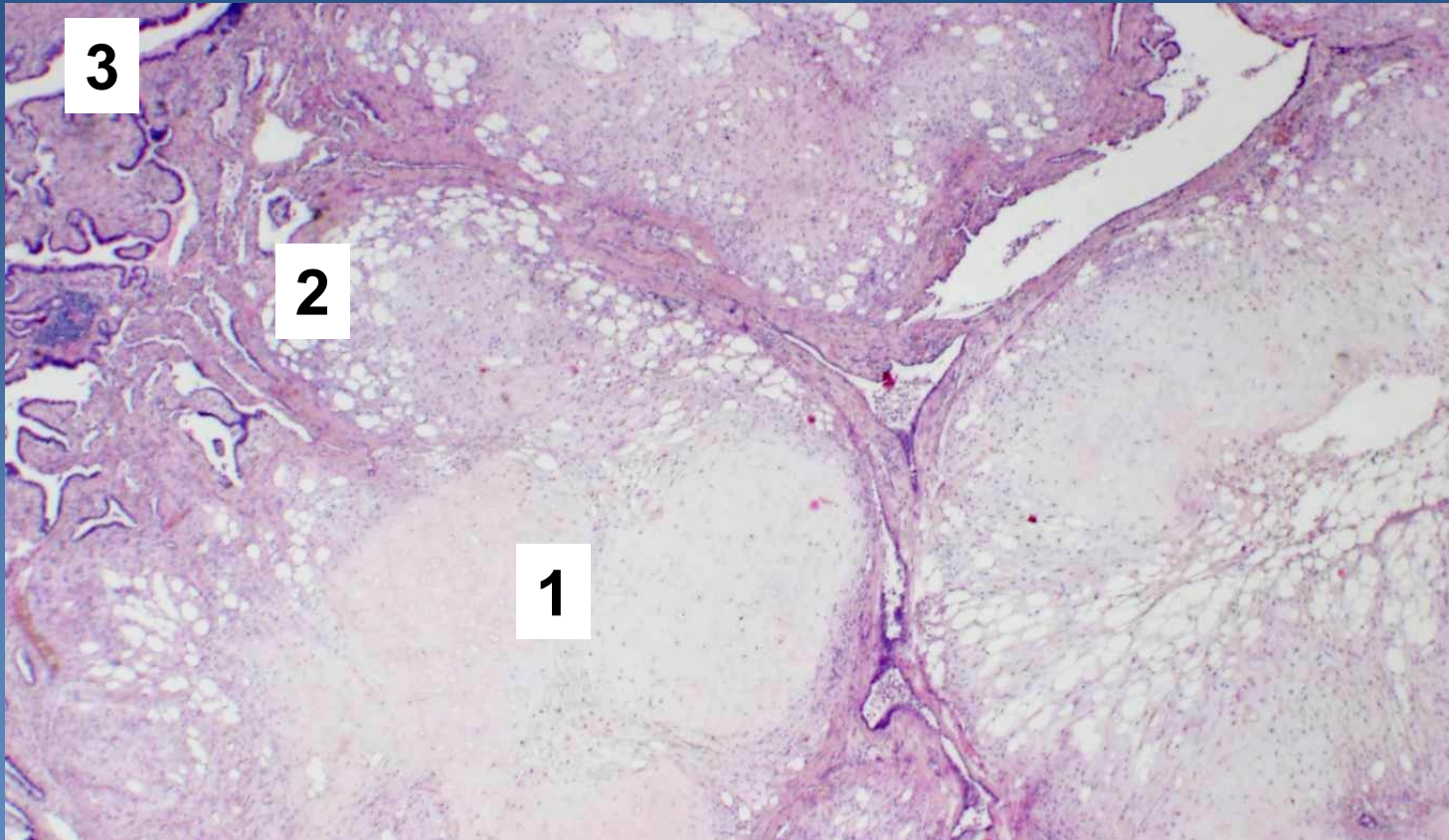
x Gross:

- ⇒ whitish yellow*
- ⇒ well demarcated*
- ⇒ lobular structure*

x Generally formed of mixture of homologous non-organised afunctional tissues :

- ⇒ cartilage*
- ⇒ connective tissue*
- ⇒ fat*
- ⇒ tubular structures with epithelium*

Pulmonary chondrohamartoma

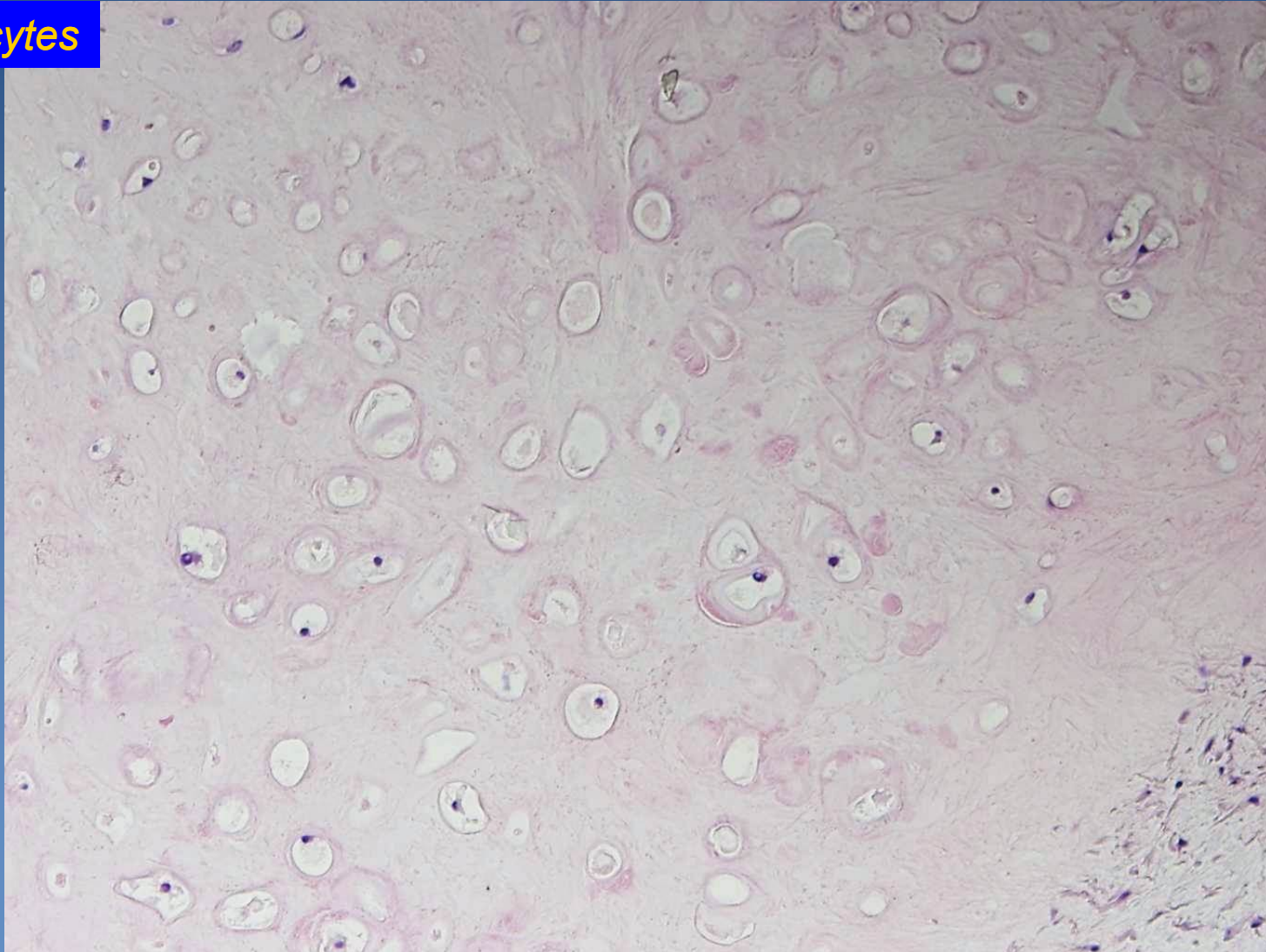


- 1. Cartilage*
- 2. Fat tissue*
- 3. Tubular structures with respiratory epithelium*

Pulmonary chondrohamartoma



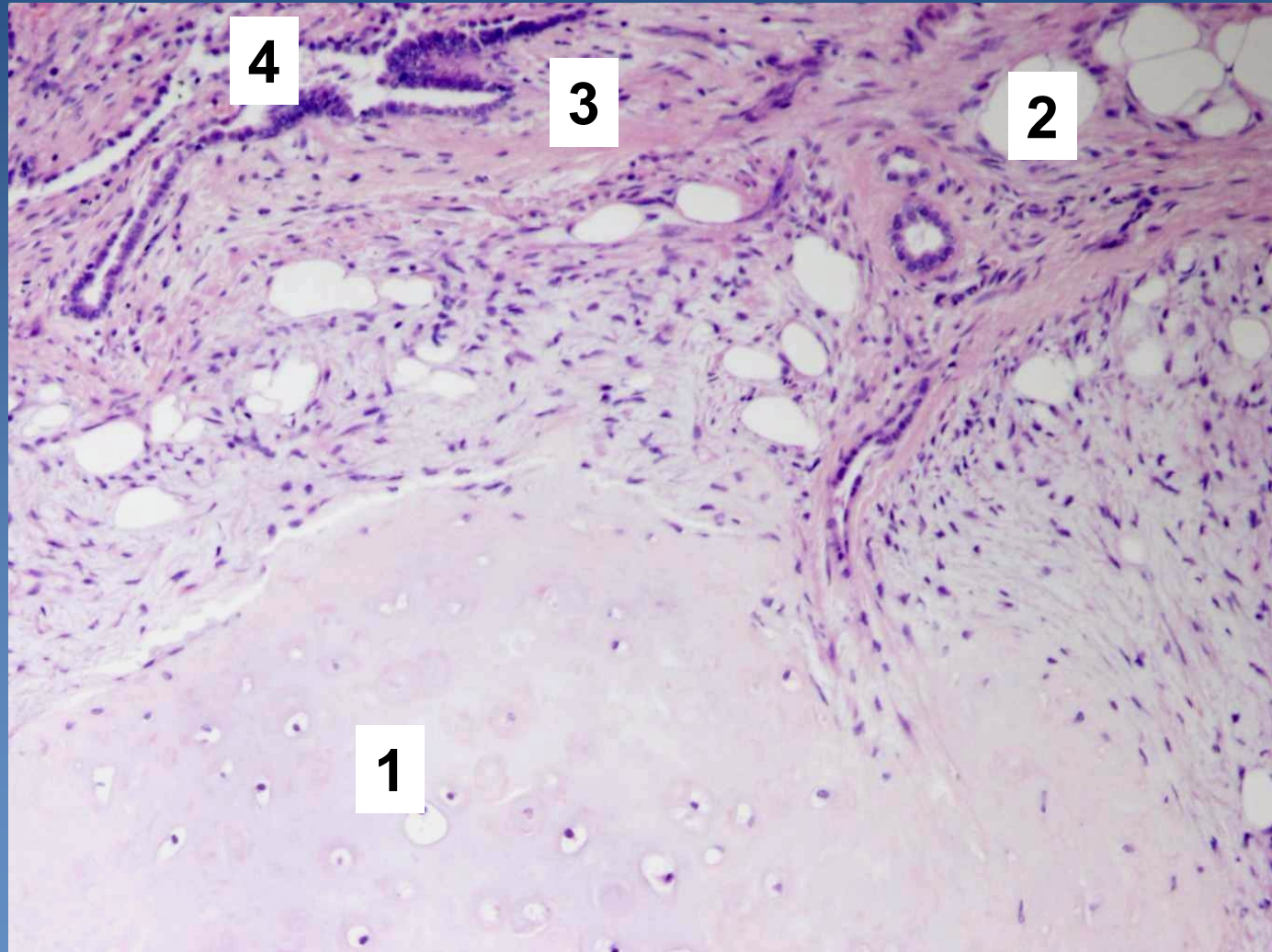
Chondrocytes



Pulmonary chondrohamartoma



1. Cartilage
2. Fat tissue
3. Connective tissue
4. Tubular structures



Bronchogenic carcinoma



× incidence:

- ⇒ *in CZE males 100/100 000 (the most common malignancy of men),*
- ⇒ *females 25/100 000 (the 3rd most common malignancy of women, ↑ tendency)*

× aetiology:

⇒ *smoking*

- generally 20X higher risk in smokers
- 20 cigarettes/day = 20 years, 40 cigarettes/day = 10 years...
- magic threshold 200000 cigarettes

⇒ *asbestos, Hg, Ni, As*

⇒ *ionization*

⇒ *radioactive radon*

⇒ *dust particles*

⇒ *familial predisposition*

Bronchogenic carcinoma



- ✗ Most common primary malignancy
- ✗ 5 year survival 5 – 7 %
- ✗ 4 – 7 decenium, more commonly males
- ✗ Clinical symptoms:
 - ⇒ *weight loss, chronic cough, haemoptysis, dyspnoea, chest pain, paraneoplastic syndromes (ACTH, ADH, PTH)*

Bronchogenic carcinoma



✘ local complications:

⇒ *depends on the localization of the tumor:*

- lung collapse, bronchiectasis, bronchopneumonia, gangrene
- Jeros cavern
 - destruction of vascular wall by necrotic mass of tumor
 - fatal bleeding

⇒ *paraneoplastic syndromes*

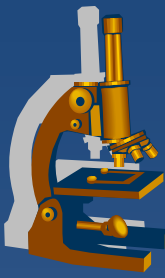
- Aberrant production of peptide hormones (ACTH,ADH,PTH,..)

✘ clinical types:

⇒ *small cell lung carcinoma (SCLC)*

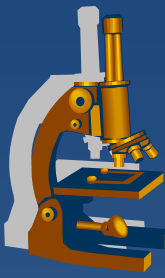
⇒ *non-small cell lung carcinoma (NSCLC)*

Small cell lung carcinoma



- × undifferentiated (high grade) neuroendocrine tumor
- × 20 % of all bronchogenic carcinomas
- × associated with **smoking**
- × localized in **lung hilus**
- × early metastatic spread, widespread dissemination
 - ⇒ *lymphatic and hematogenous (LN, liver, brain, bones, kidney, adrenals, ...)*

Small-cell lung carcinoma



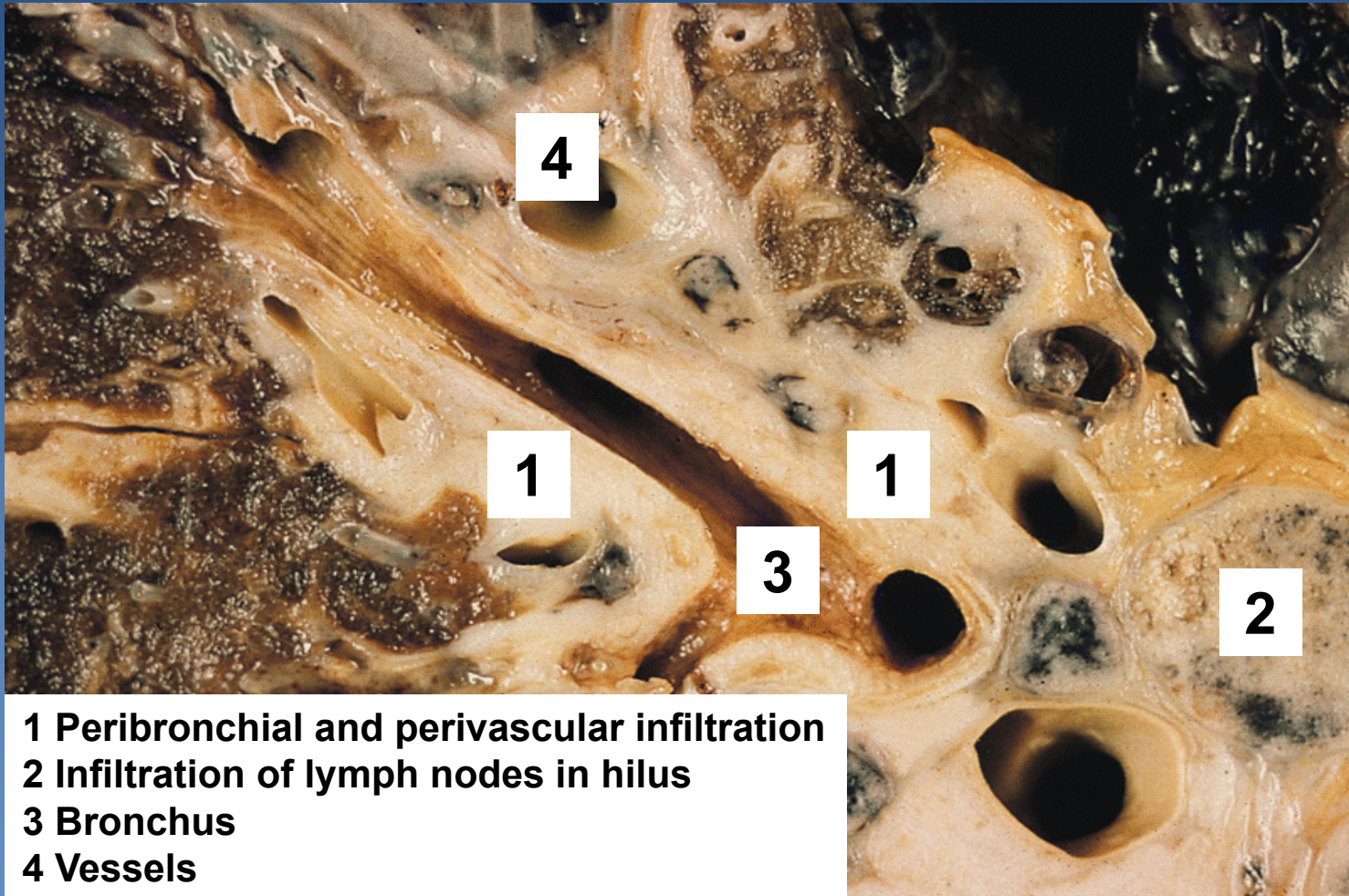
× histologic types:

- ⇒ *small cell („oat cell carcinoma“)*
- ⇒ *intermediate (now included into small cell type)*
- ⇒ *combined*

× Micro:

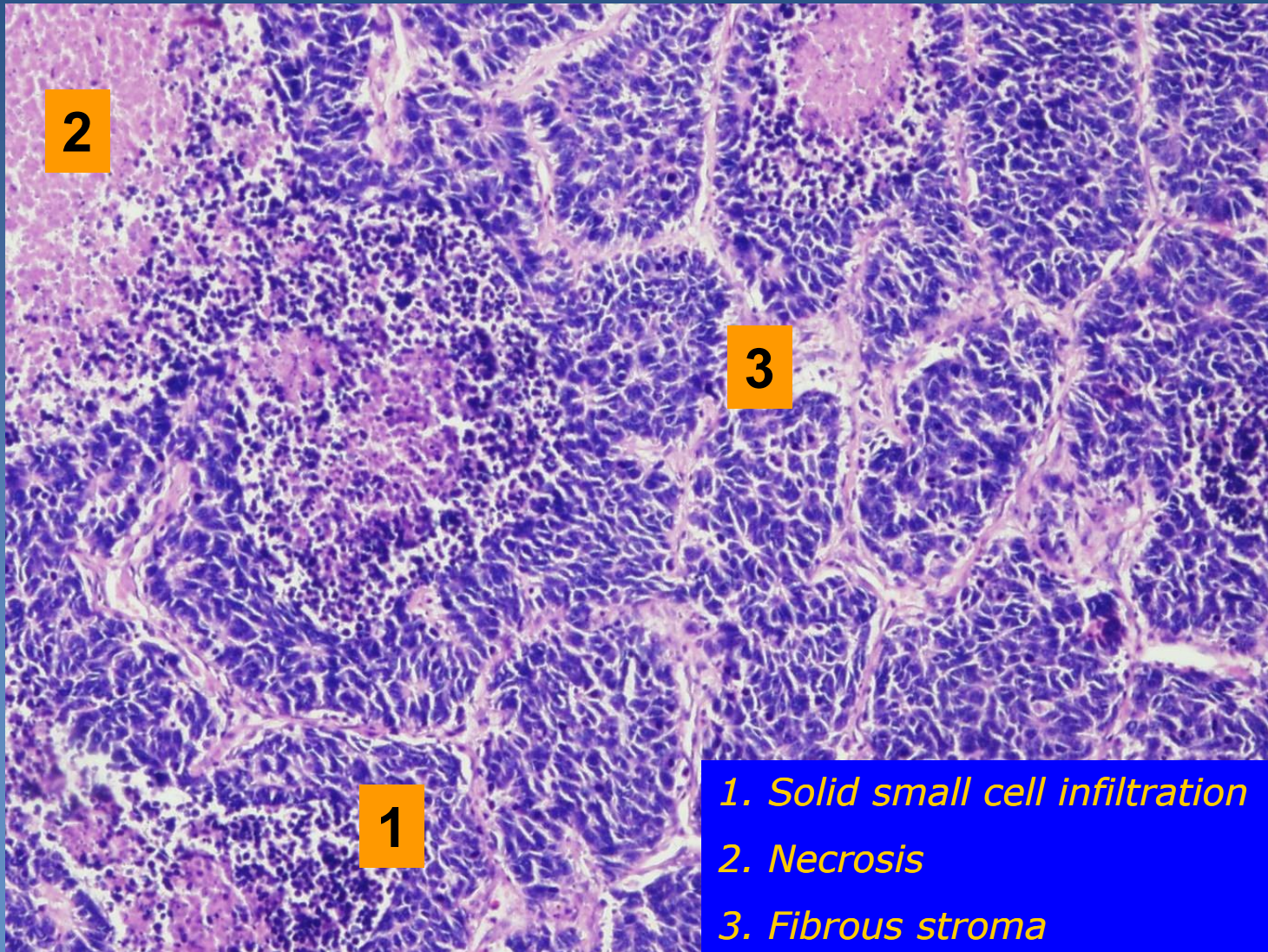
- ⇒ *small cells with scant cytoplasm (size < 3 lymphocytes)*
- ⇒ *small round - elongated dark blue nuclei without obvious nucleoli (oat cell carcinoma)*
- ⇒ *solid growth*
- ⇒ *neurosecretory granules in cytoplasm*
 - chromogranin, synaptophysin

Small-cell lung carcinoma



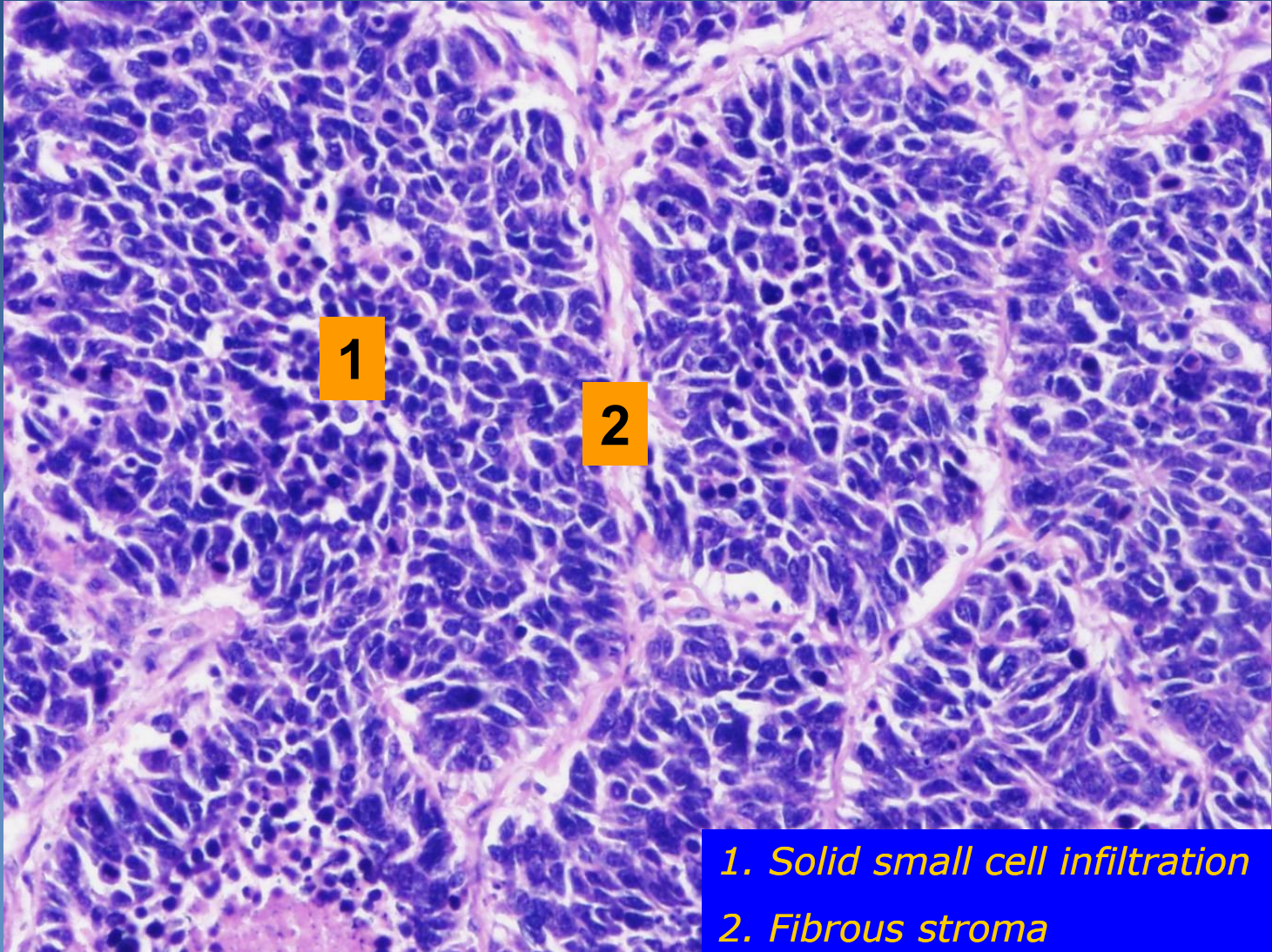
- 1 Peribronchial and perivascular infiltration**
- 2 Infiltration of lymph nodes in hilus**
- 3 Bronchus**
- 4 Vessels**

Small-cell lung carcinoma



- 1. Solid small cell infiltration*
- 2. Necrosis*
- 3. Fibrous stroma*

Small-cell lung carcinoma



- 1. Solid small cell infiltration*
- 2. Fibrous stroma*

Non-small cell lung carcinoma



× squamous cell carcinoma

× adenocarcinoma

⇒ *adenocarcinoma in situ*

⇒ *minimally invasive:*

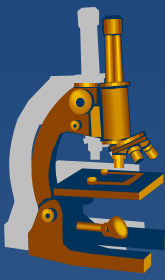
- non-mucinous
- mucinous
- mixed

⇒ *invasive:*

- lepidic
- acinar
- papillary
- micropapillary
- solid

× large cell lung carcinoma

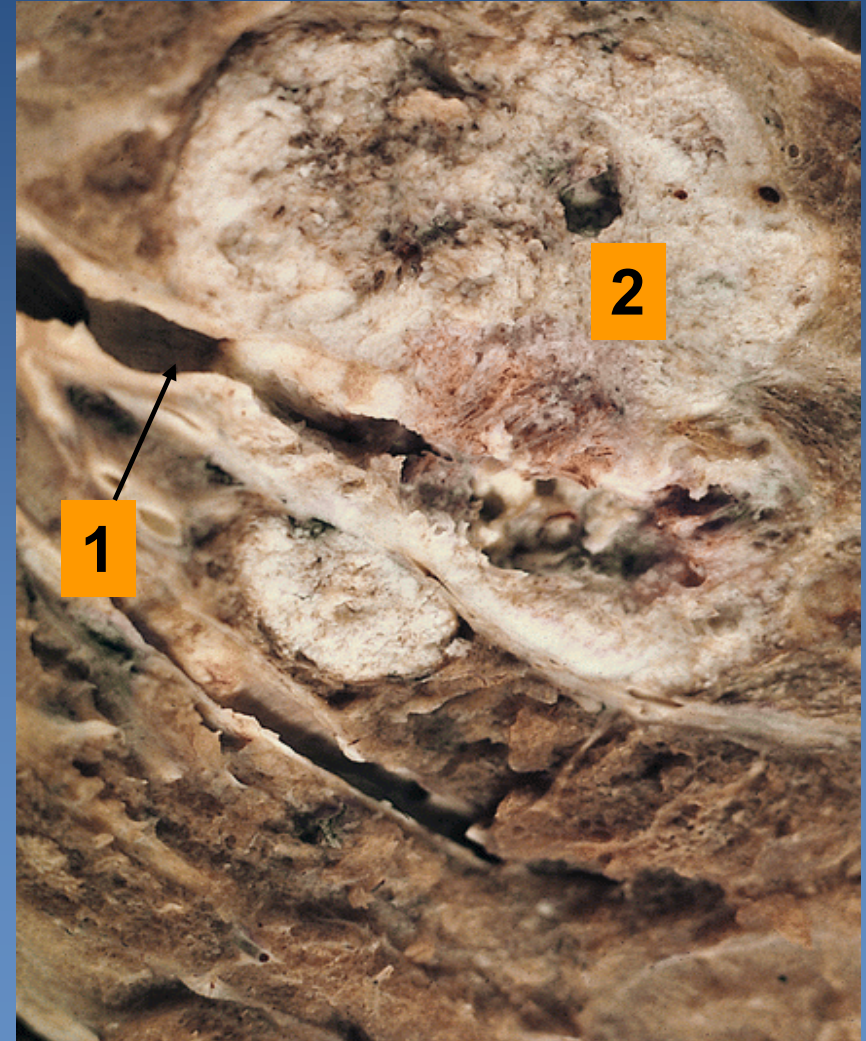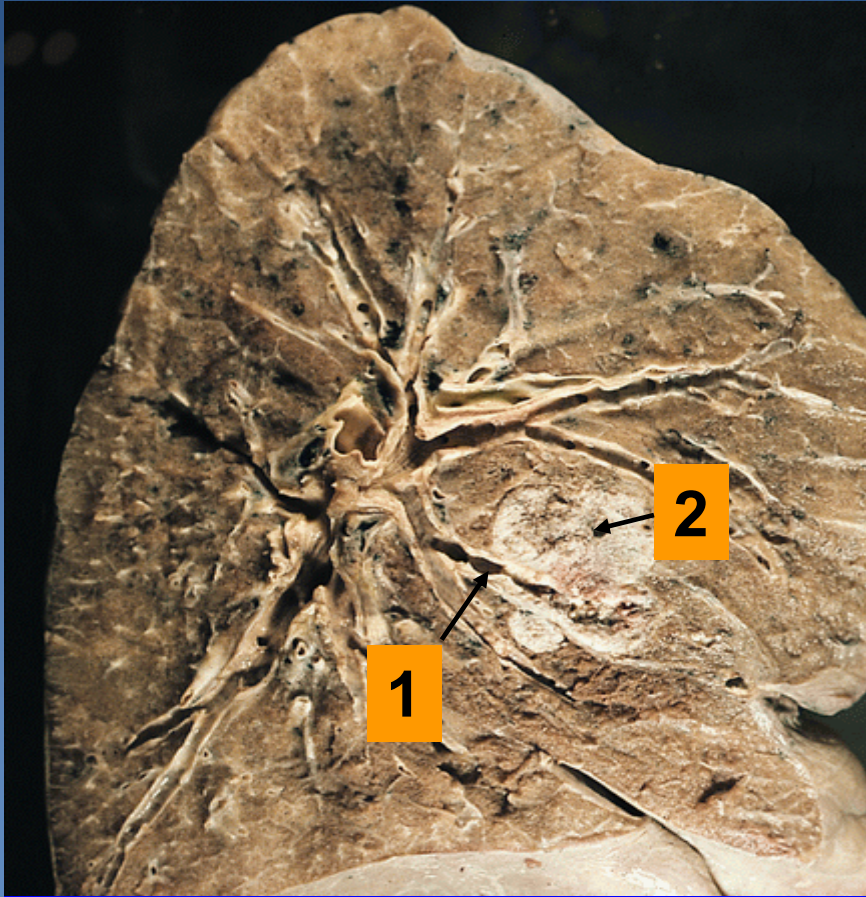
× other, incl. mixed



Squamous cell carcinoma

- ✗ male 40%, female 20%
- ✗ strongly associated with smoking
- ✗ typical perihilar localisation (central > peripheral)
- ✗ commonly slow progression from squamous metaplasia – dysplasia – ca in situ
 - ⇒ *late metastases*
- ✗ Micro:
 - ⇒ *squamous cell carcinoma of common type*
 - polygonal shaped cells in solid nests, keratin pearls, cell junctions
 - ⇒ *variable differentiation*

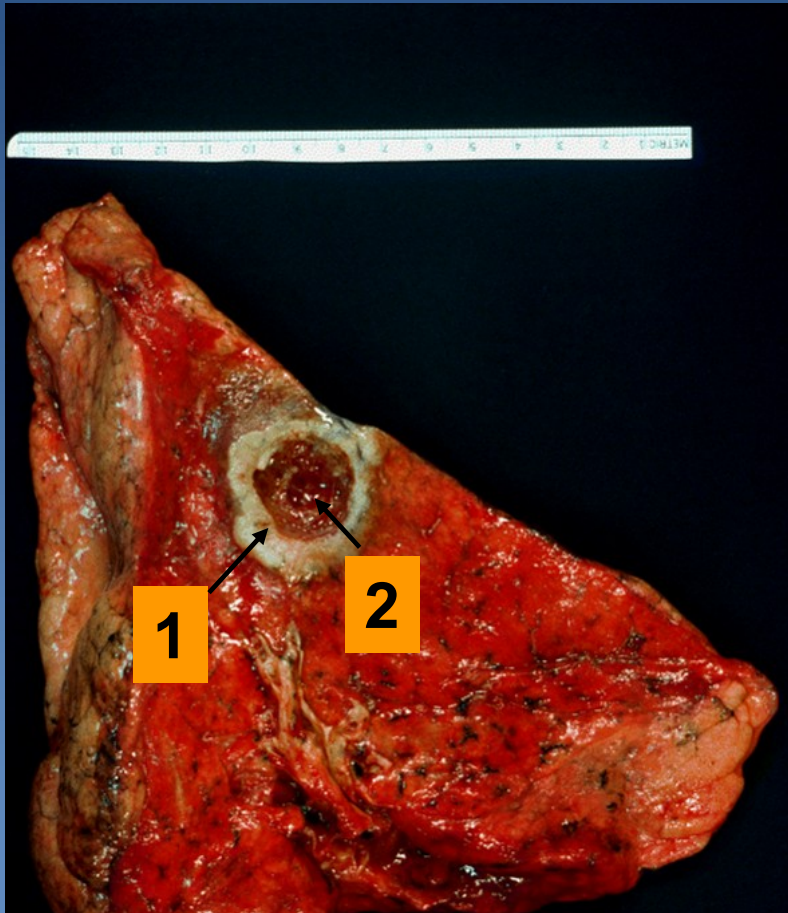
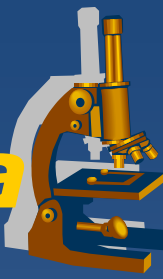Squamous-cell lung carcinoma



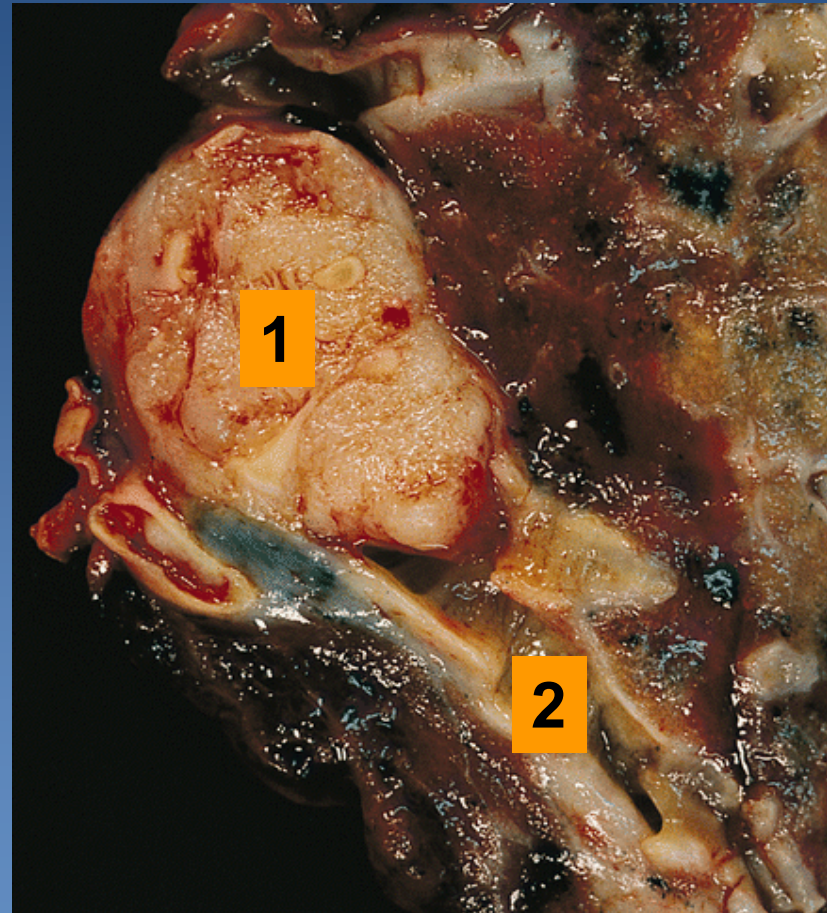
1. Segmental bronchus

2. Tumor

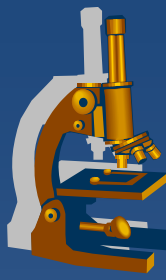
Squamous cell lung carcinoma



1. Tumor localized in the periphery
2. Central necrosis

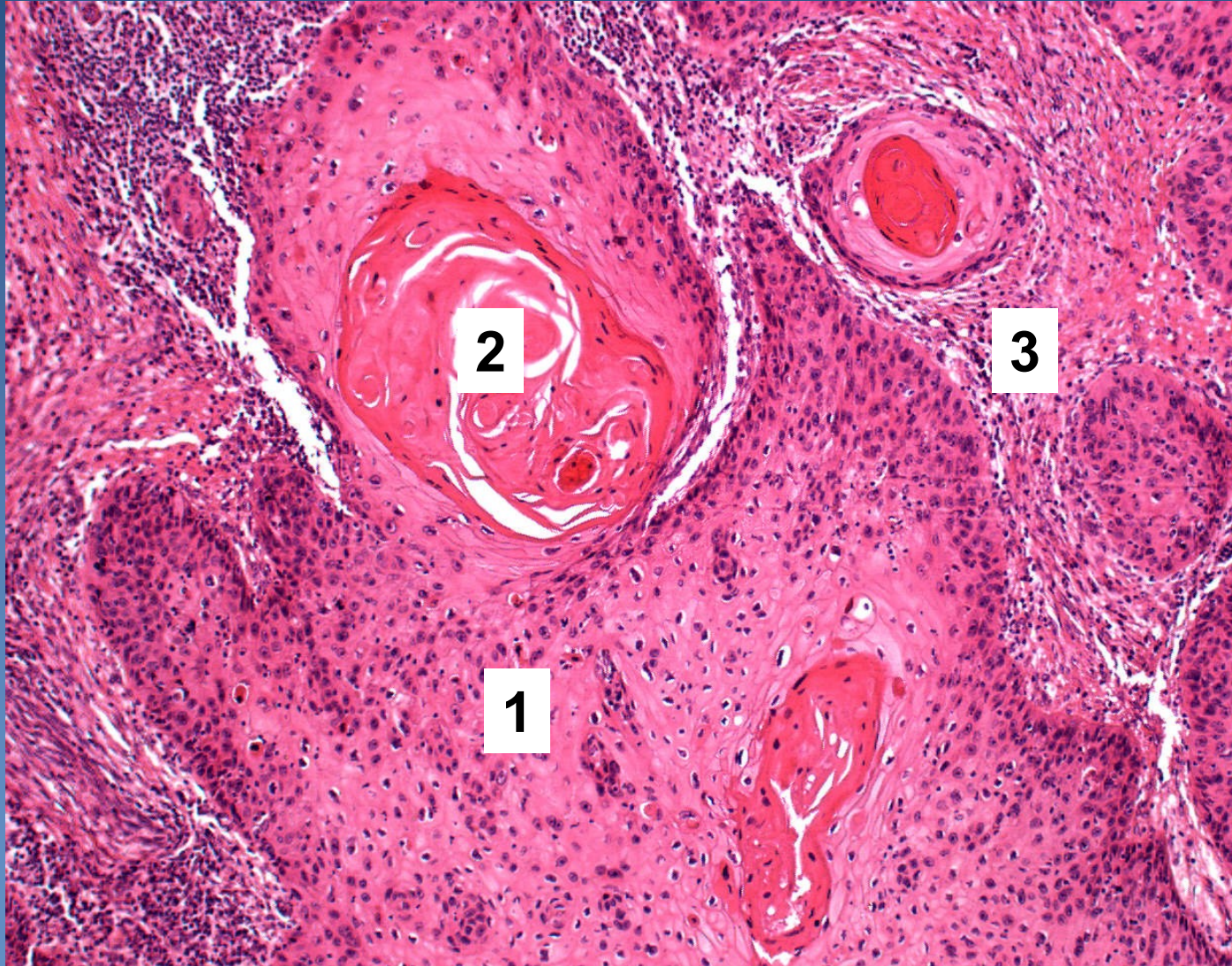


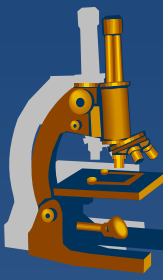
1. Tumor in bronchus
2. Segmental bronchus



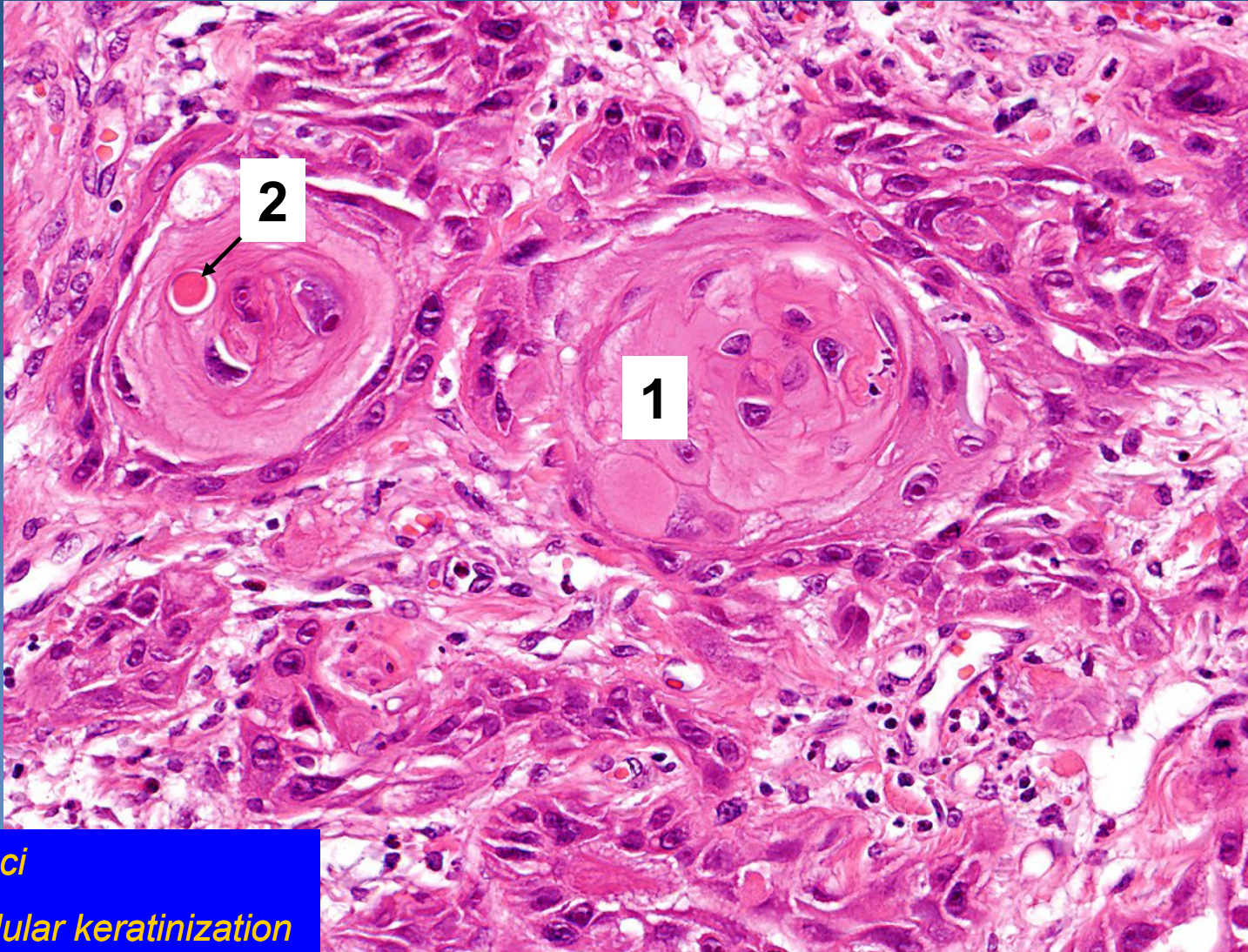
Squamous cell carcinoma

1. *Solid nests of malignant keratinocytes*
2. *Keratin pearls*
3. *Stroma of the tumor*

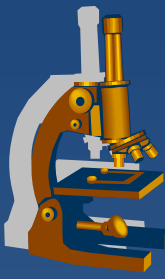




Squamous cell carcinoma

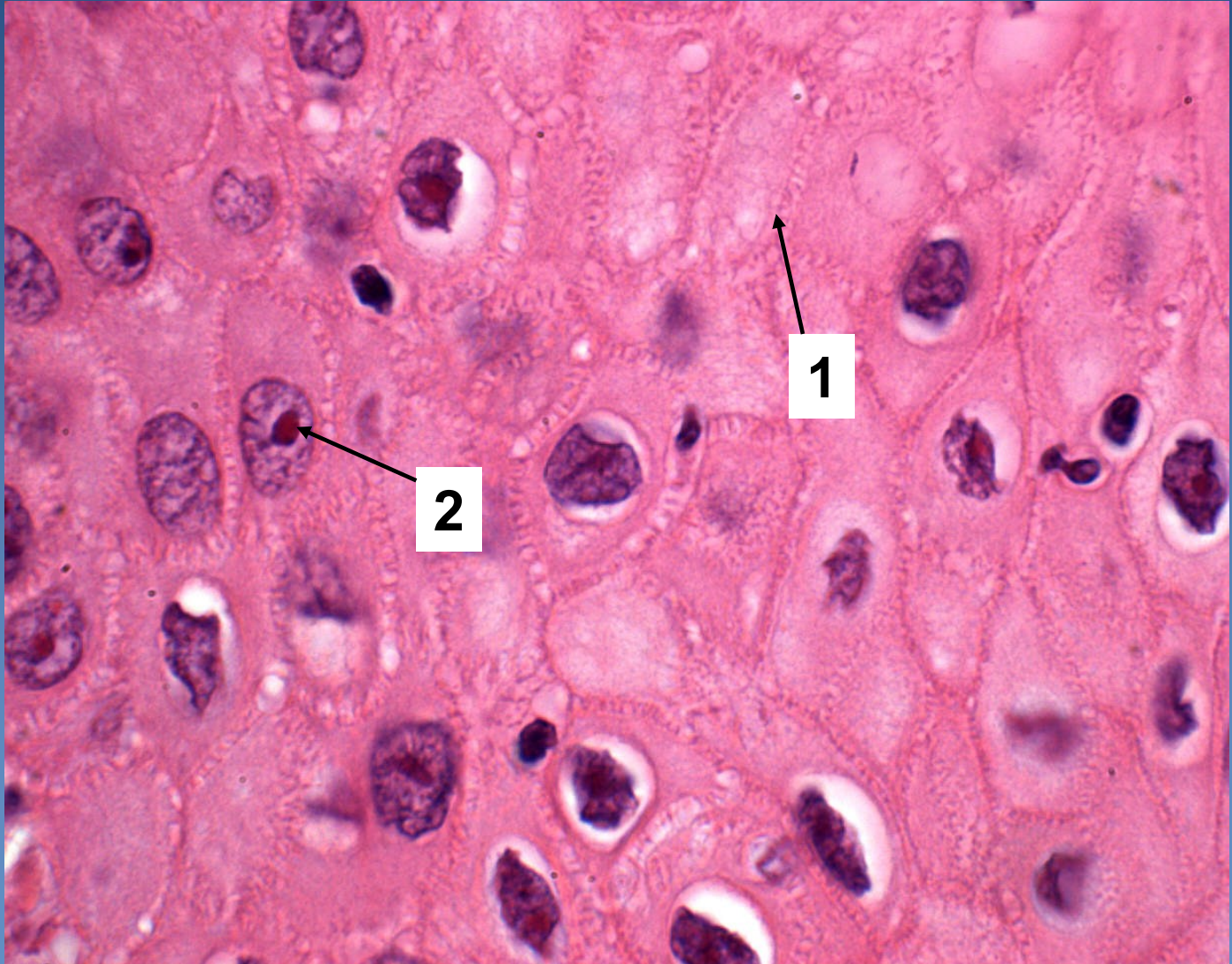


- 1. *Tumor foci*
- 2. *Monocellular keratinization*



Squamous-cell carcinoma

1. *Cell junctions*
2. *Nucleus with prominent nucleoli*



Adenocarcinoma



- ✗ male 20%, female 40%;
- ✗ most cases in smokers, but the most common type in non-smokers
- ✗ typically localized in the periphery, subpleural
 - ⇒ *late symptoms !!!* *Commonly accidental finding on X-ray/CT*
- ✗ formerly used term:
 - ⇒ *bronchioloalveolar adenocarcinoma (BAC) no more in use (but still present in WHO classification of lung tumors)*

Adenocarcinoma



× classification:

⇒ *Adenocarcinoma in situ - AIS (size ≤ 3 cm):*

- non/mucinous (earlier BAC),
- mucinous
- mixed
- no stromal/vascular/pleural invasion present

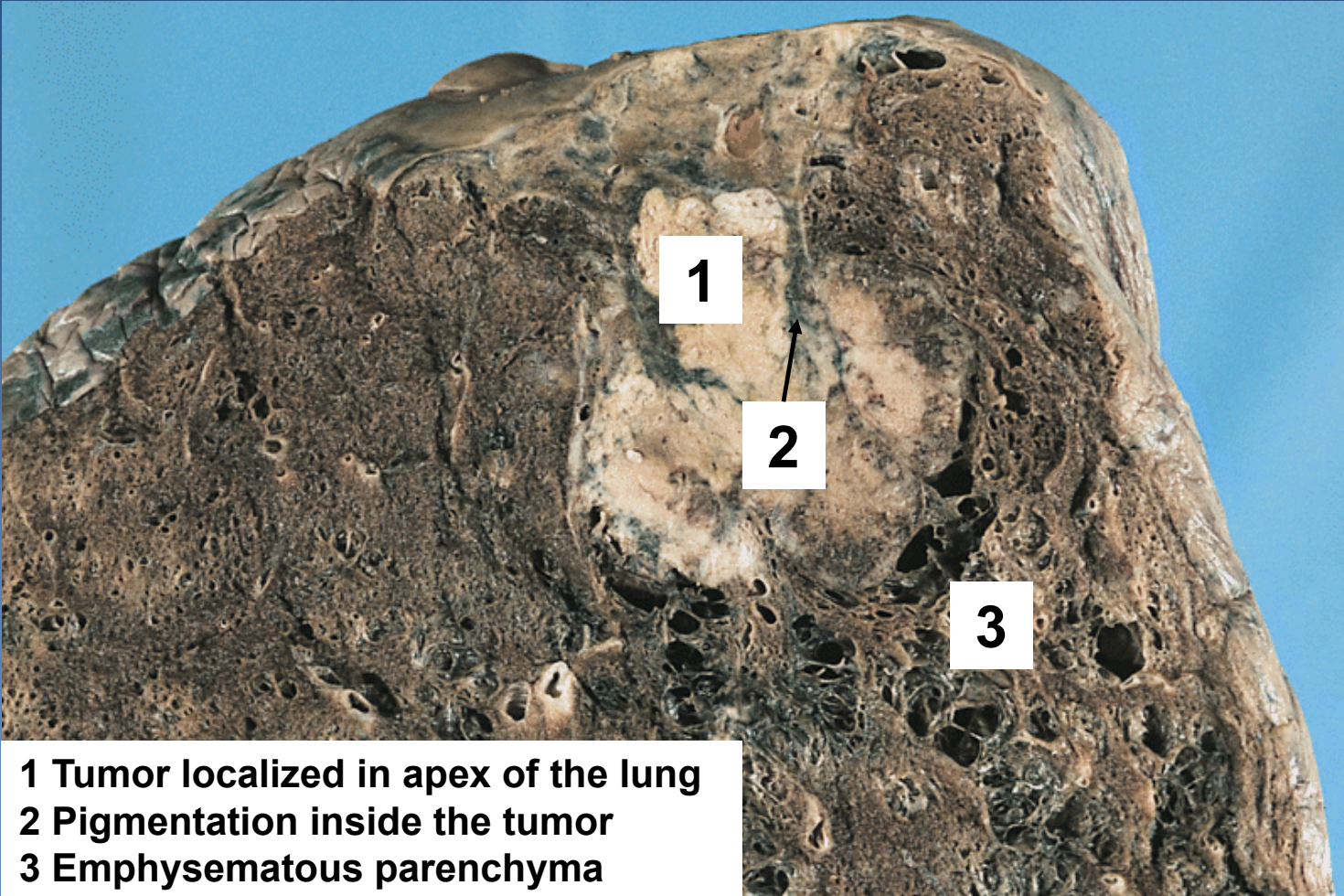
⇒ *Minimally invasive ACA (size ≤ 3 cm and ≤ 5 mm invasion): idem*

- apart of lepidic growth other types of spread (papillary, solid....) or stromal invasion present
- no vascular/pleural invasion present

⇒ *Invasive ACA:*

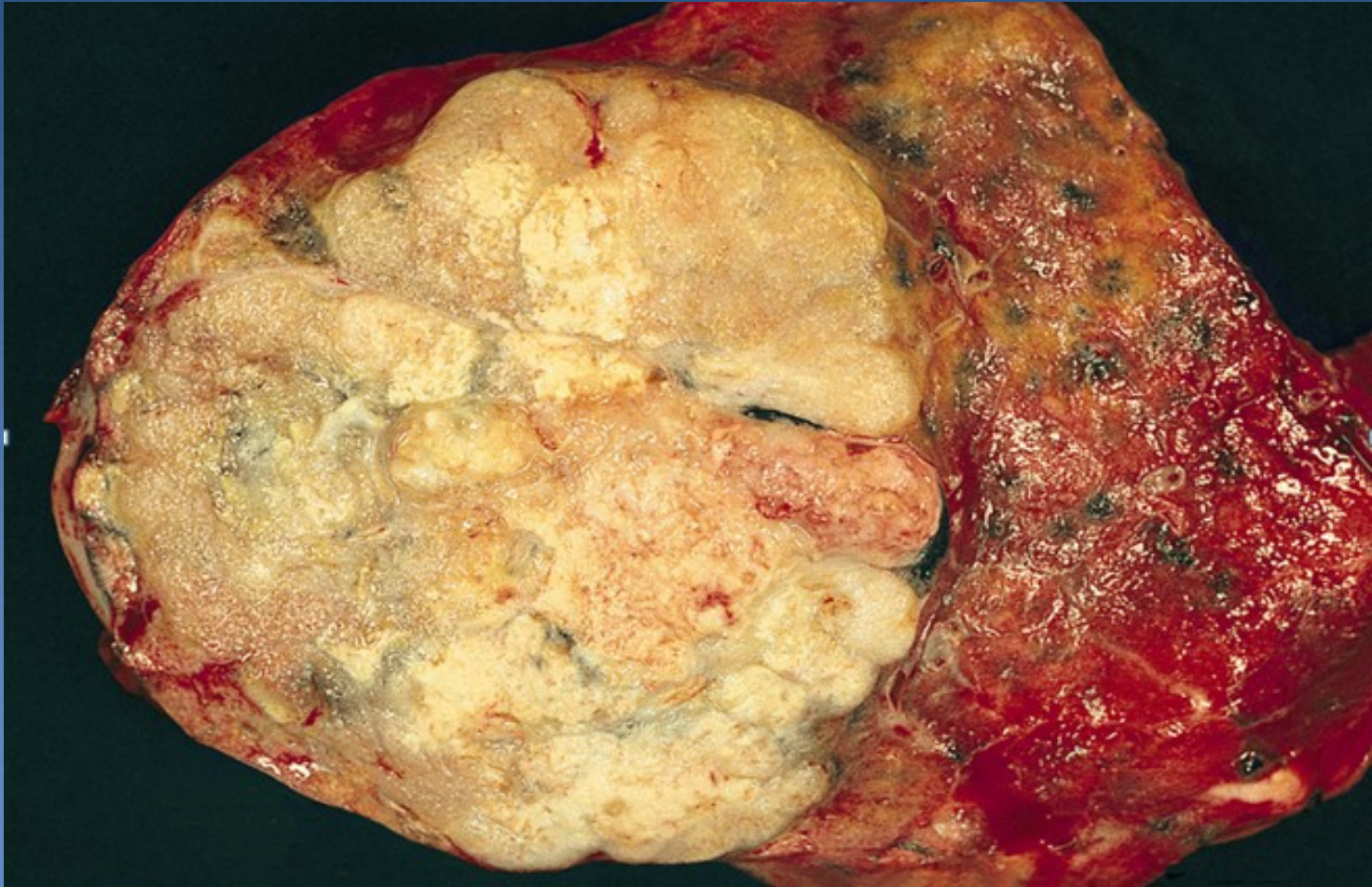
- Lepidic
- Acinar
- Papillary
- Micropapillary
- Solid

Adenocarcinoma

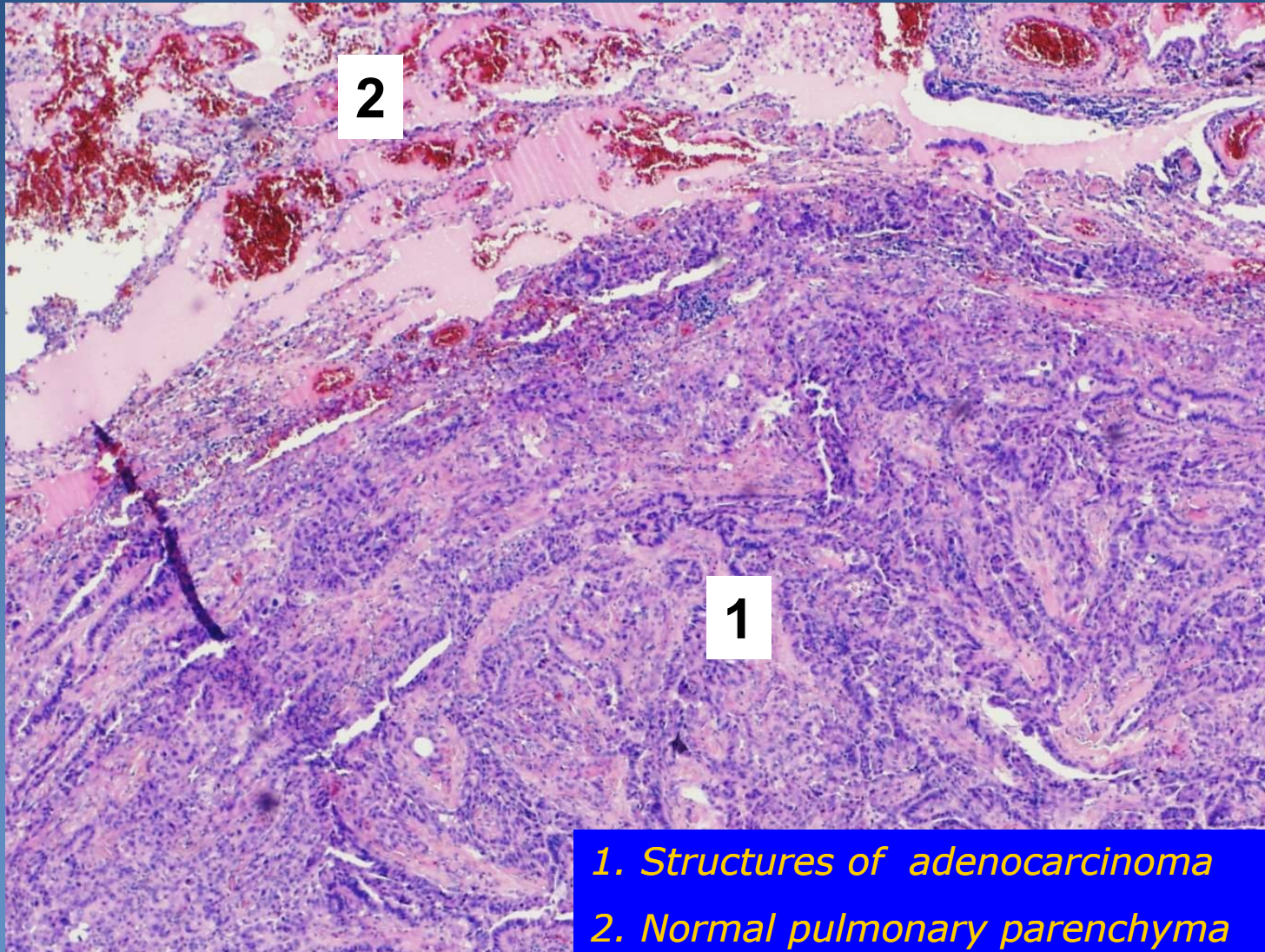


- 1 Tumor localized in apex of the lung
- 2 Pigmentation inside the tumor
- 3 Emphysematous parenchyma

Adenocarcinoma

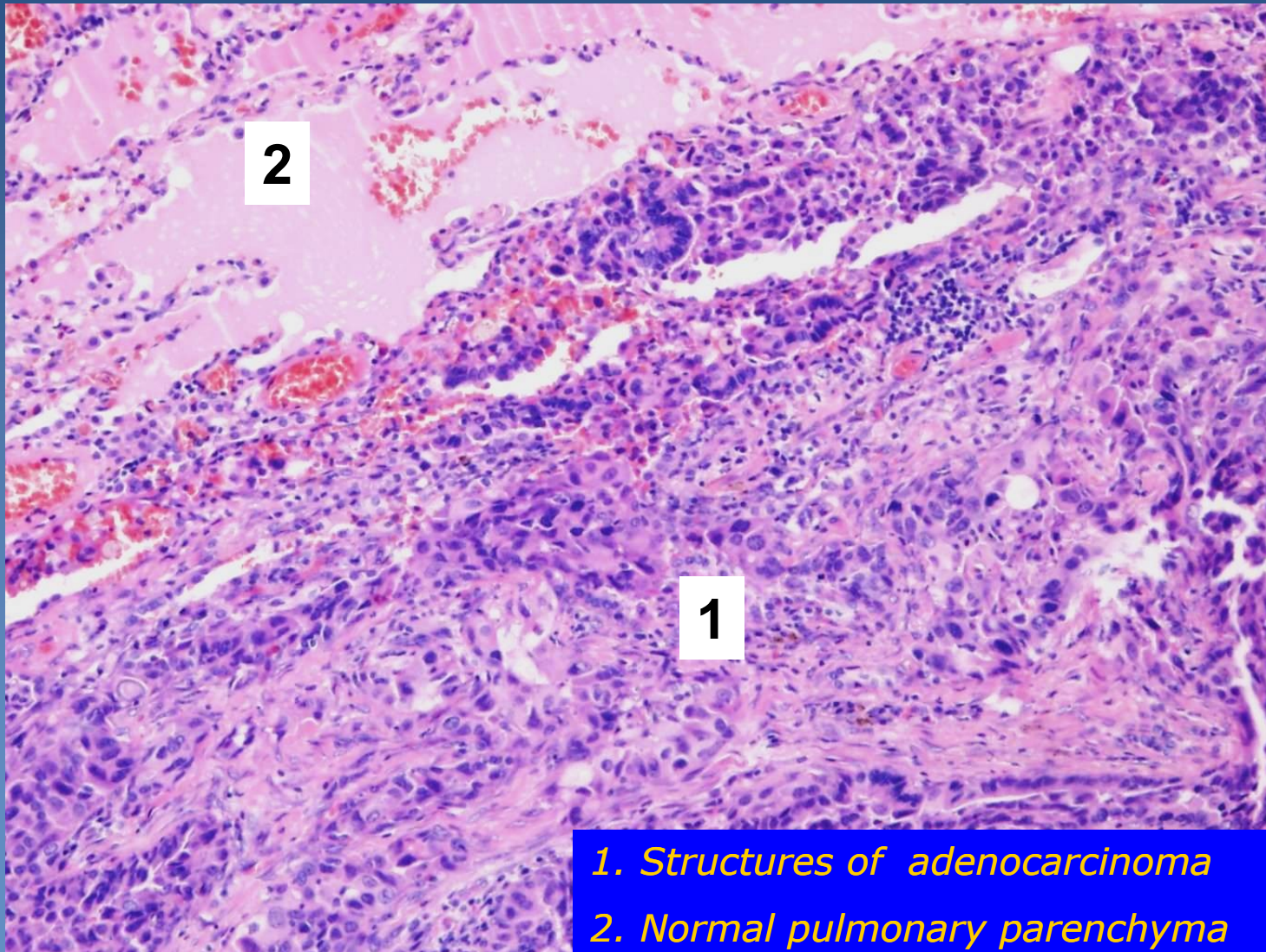


Adenocarcinoma



1. Structures of adenocarcinoma
2. Normal pulmonary parenchyma

Adenocarcinoma

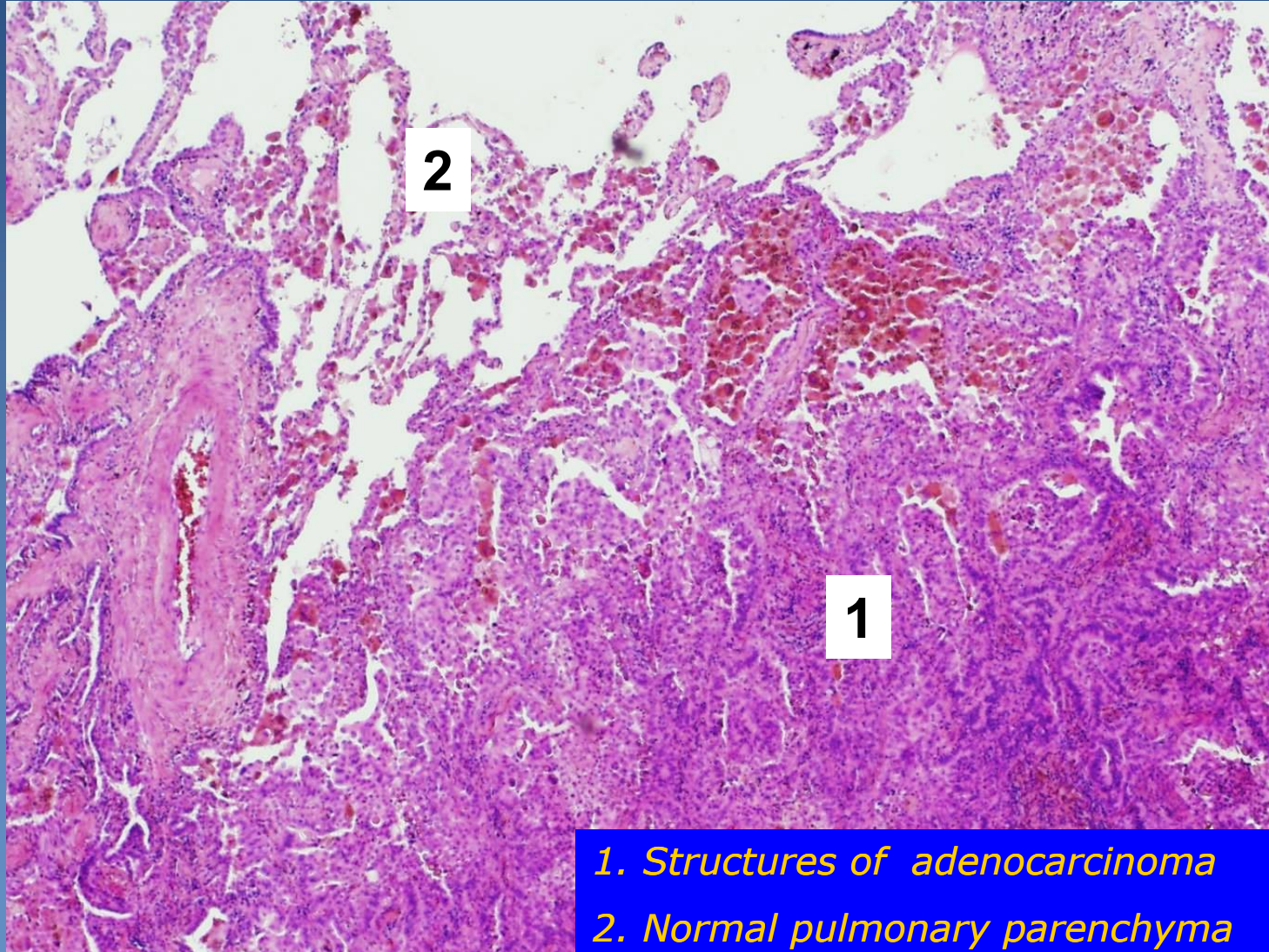


2

1

- 1. Structures of adenocarcinoma
- 2. Normal pulmonary parenchyma

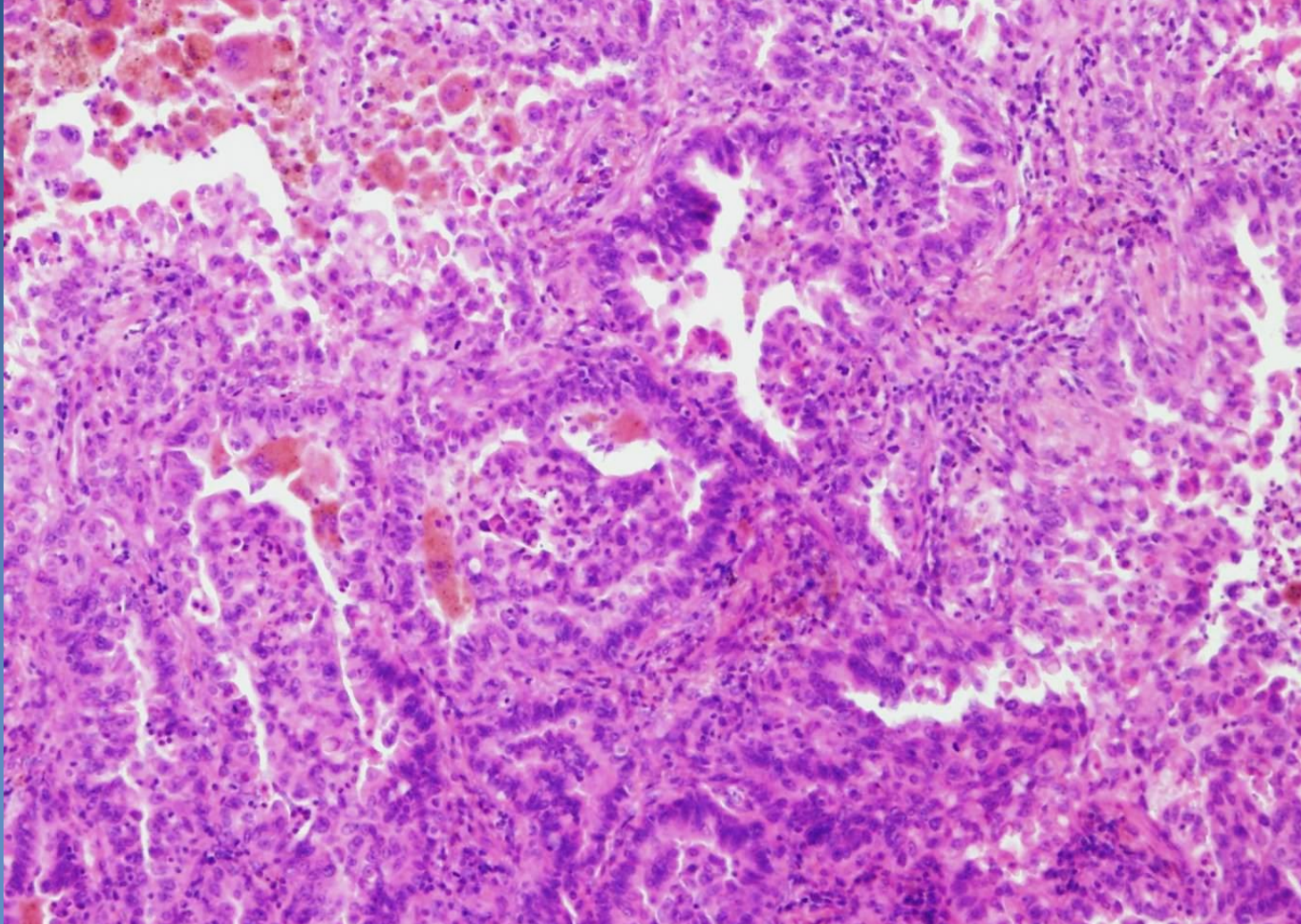
Adenocarcinoma



Adenocarcinoma



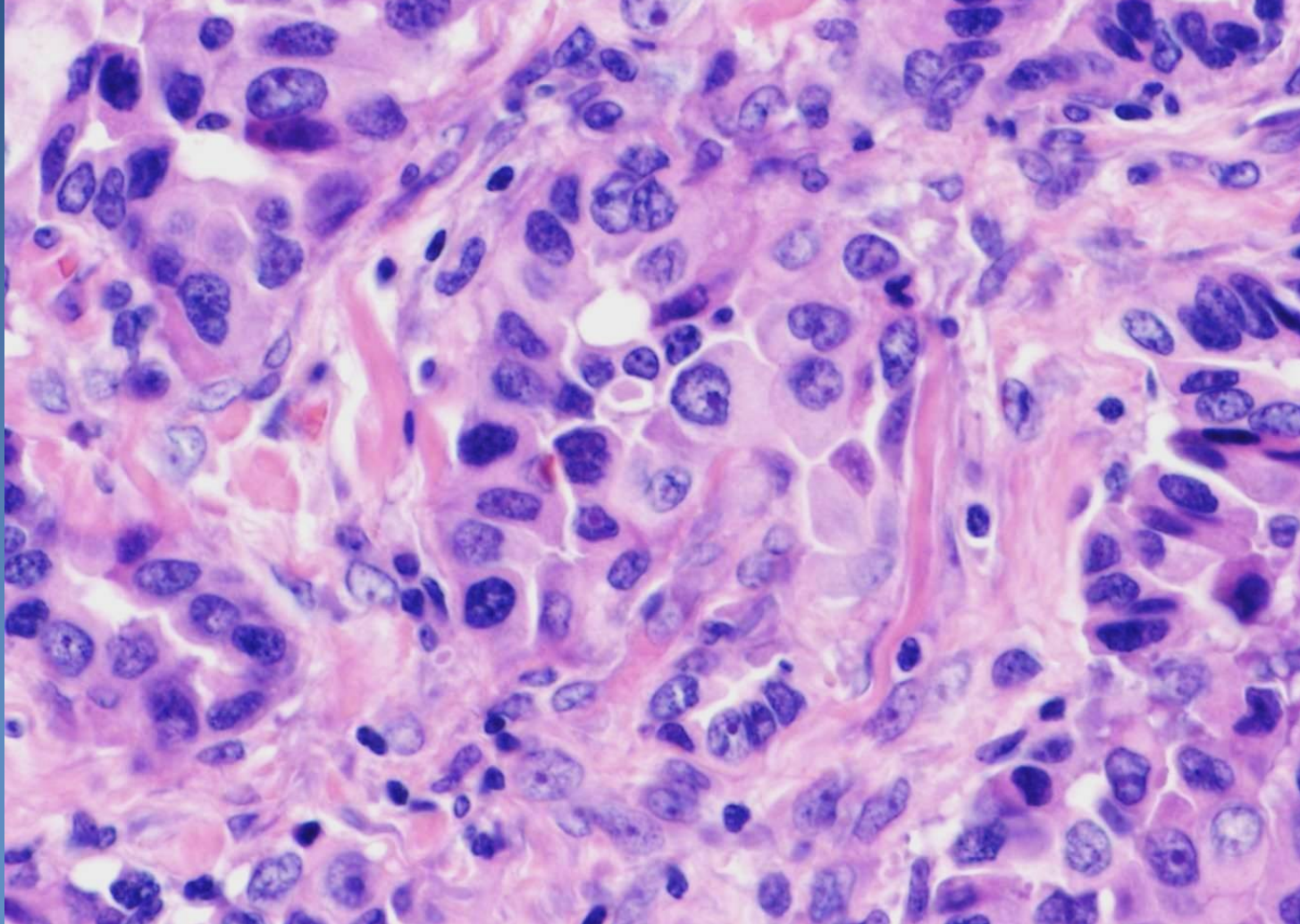
Structures of an acinary and papillary formed adenocarcinoma



Adenocarcinoma



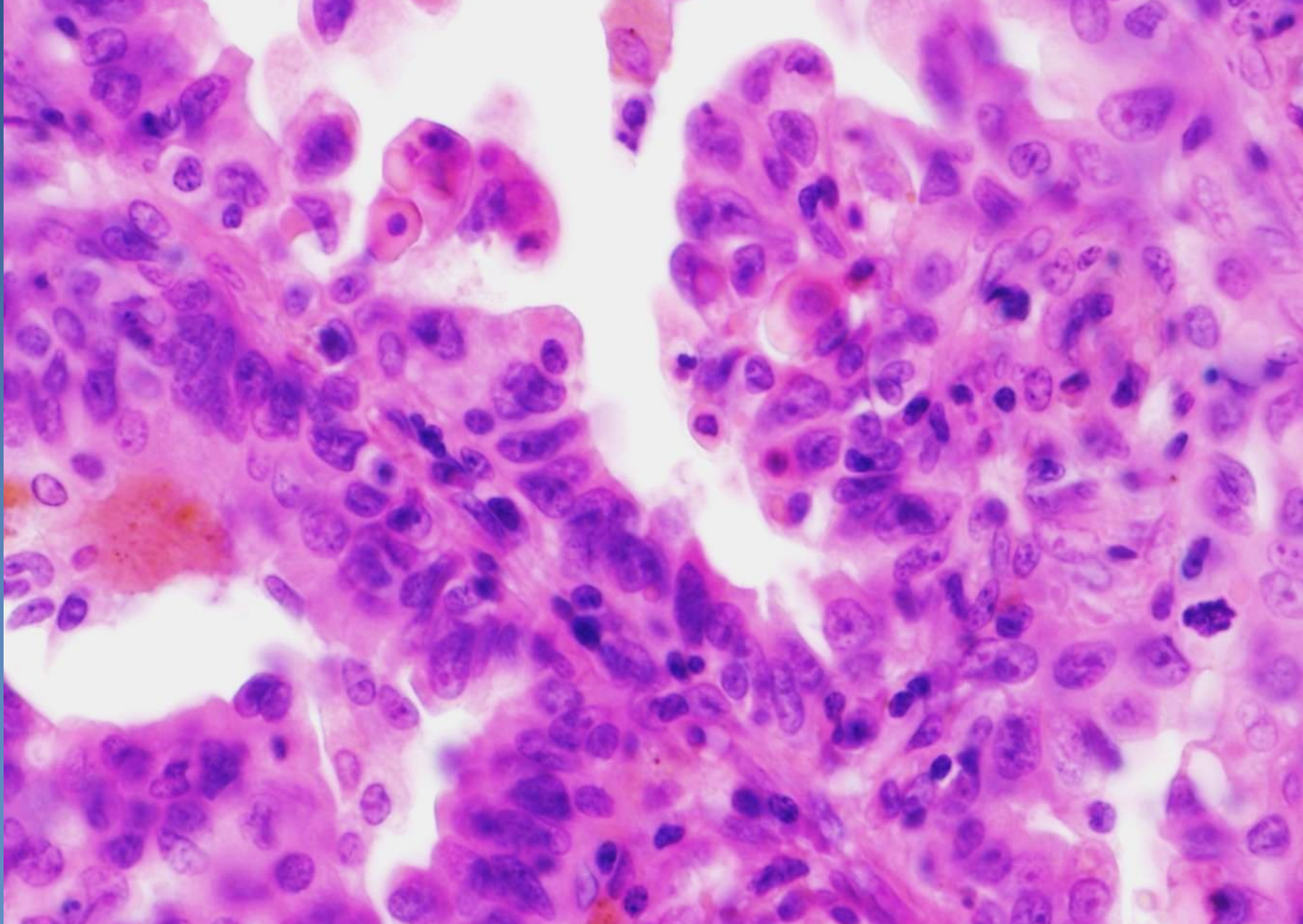
Cytology of malignant cells - anisocytosis and anisokaryosis

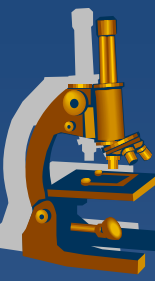


Adenocarcinoma

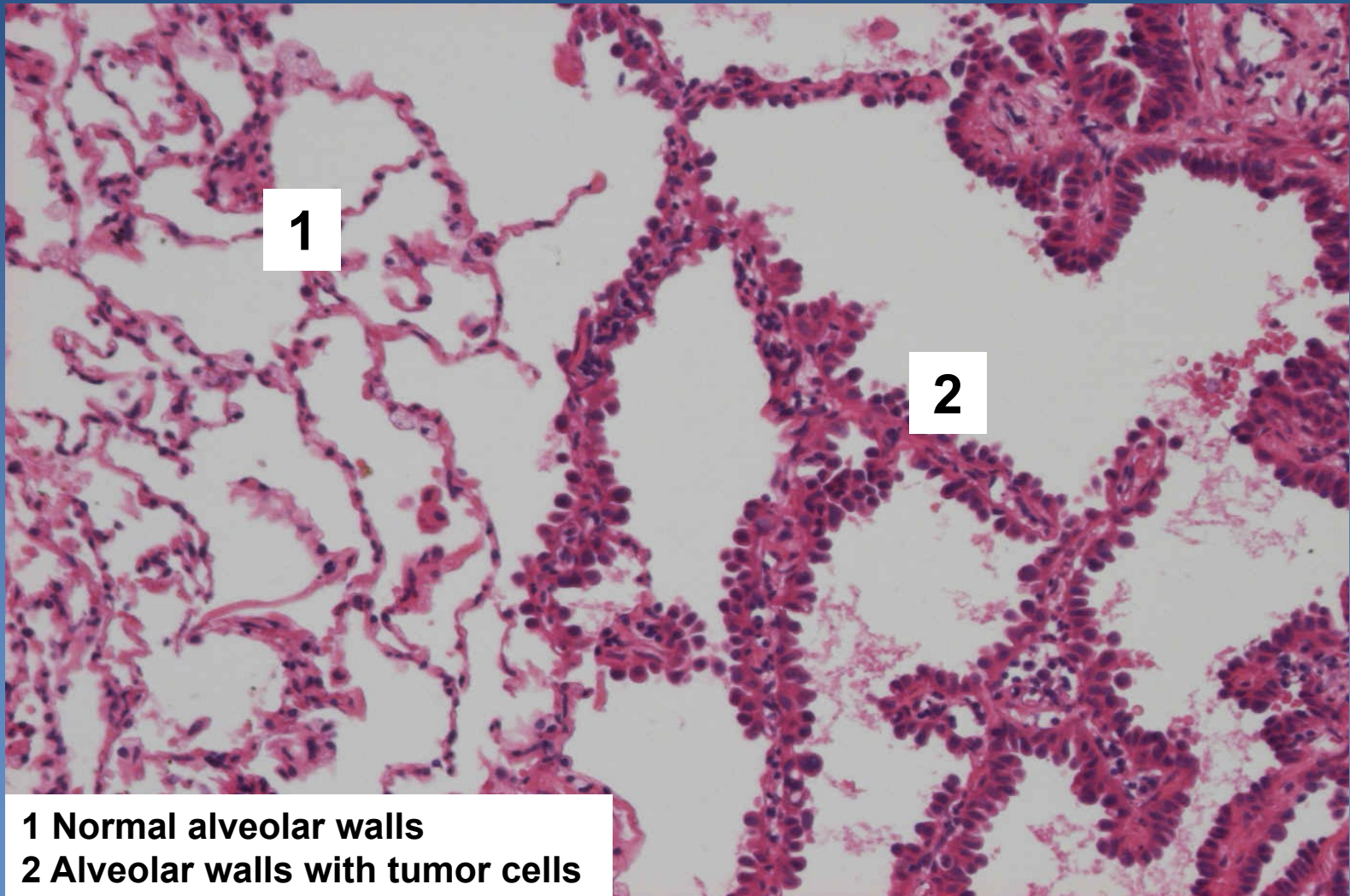


Cytology of malignant cells - anisocytosis and anisokaryosis





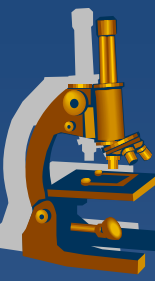
AIS/minimally invasive ACA non/mucinous (earlier BAC)



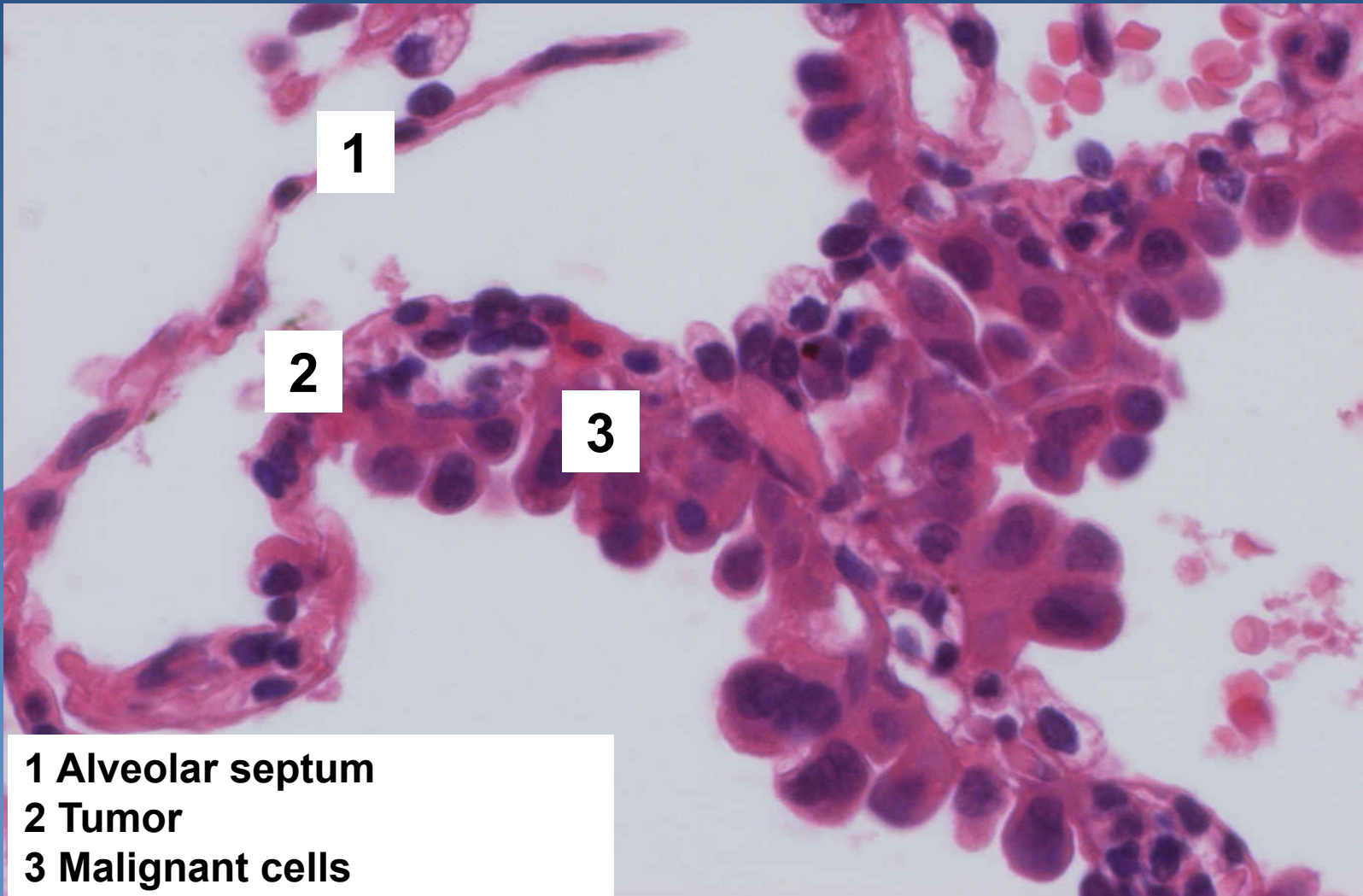
1

2

**1 Normal alveolar walls
2 Alveolar walls with tumor cells**



AIS/minimally invasive ACA non/mucinous (earlier BAC)

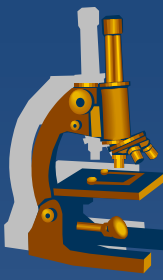


- 1 Alveolar septum**
- 2 Tumor**
- 3 Malignant cells**

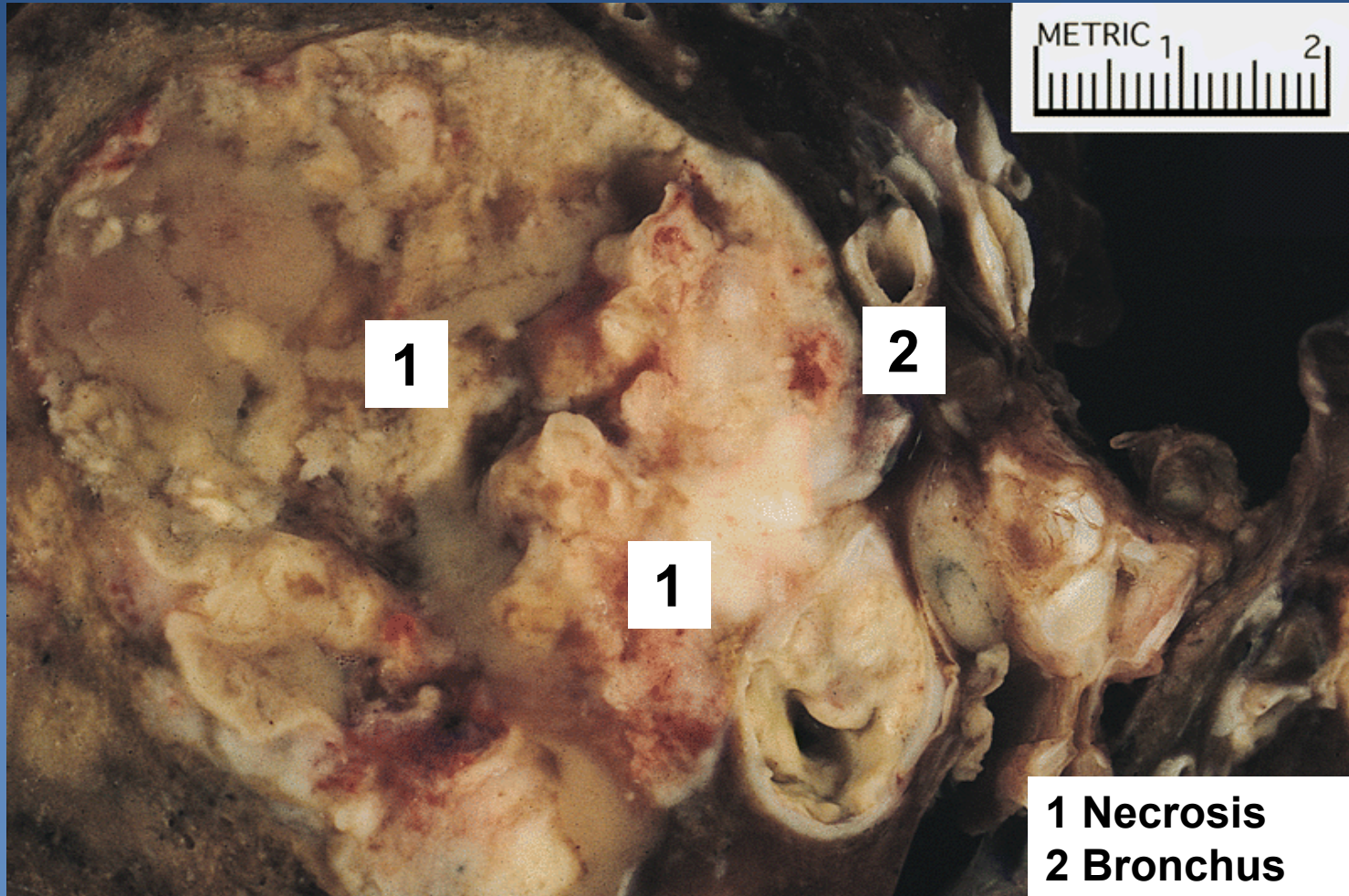


Large cell lung carcinoma

- x undifferentiated non-small cell carcinoma*
- x Micro:*
 - ⇒ atypical pleomorphic cells*
 - ⇒ absent features of small cell carcinoma, adenocarcinoma or squamous cell carcinoma*



Large cell lung carcinoma

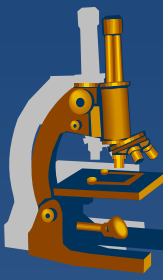


1

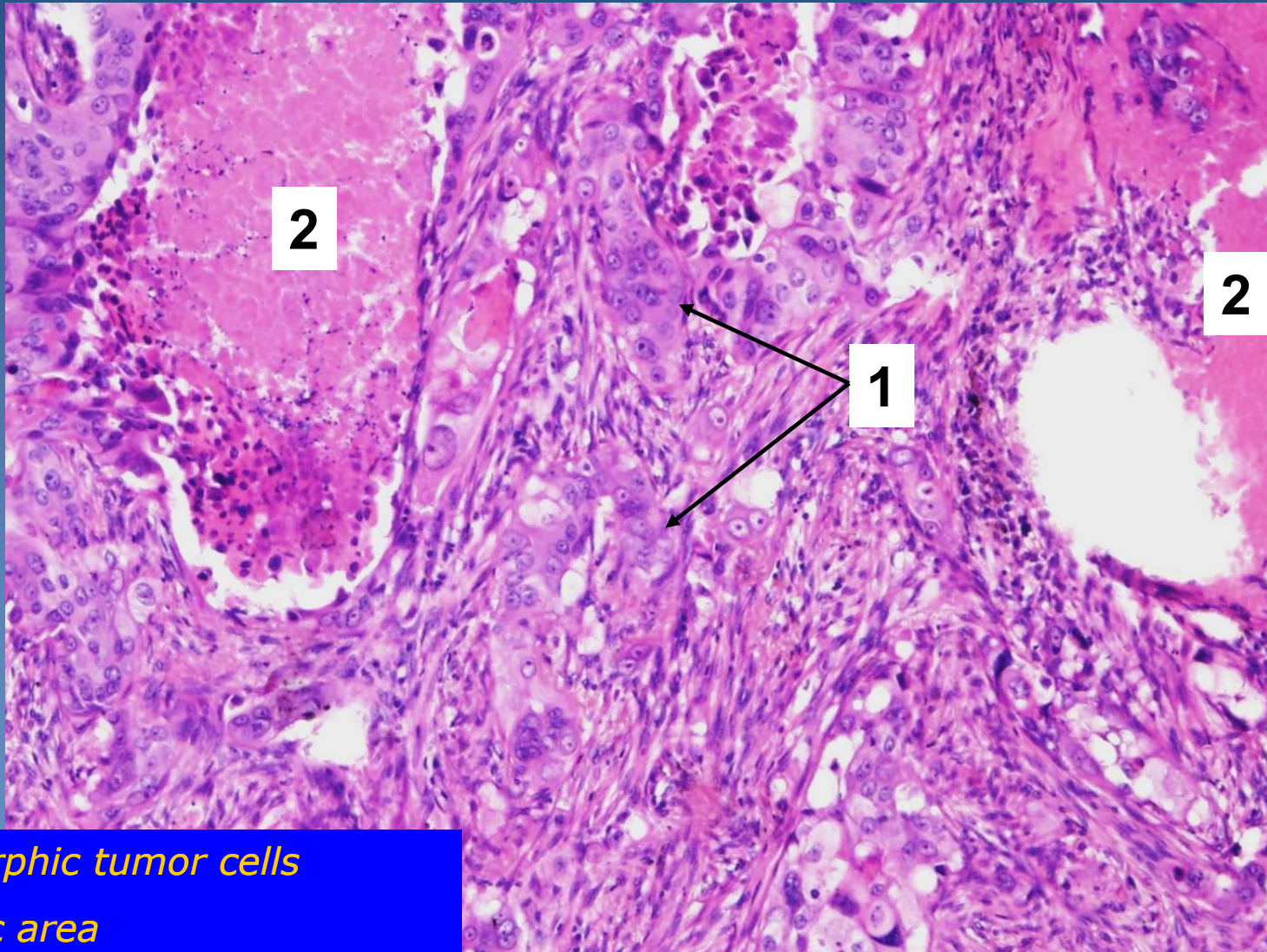
2

1

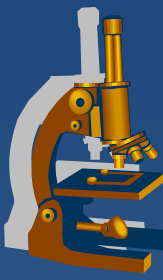
1 Necrosis
2 Bronchus



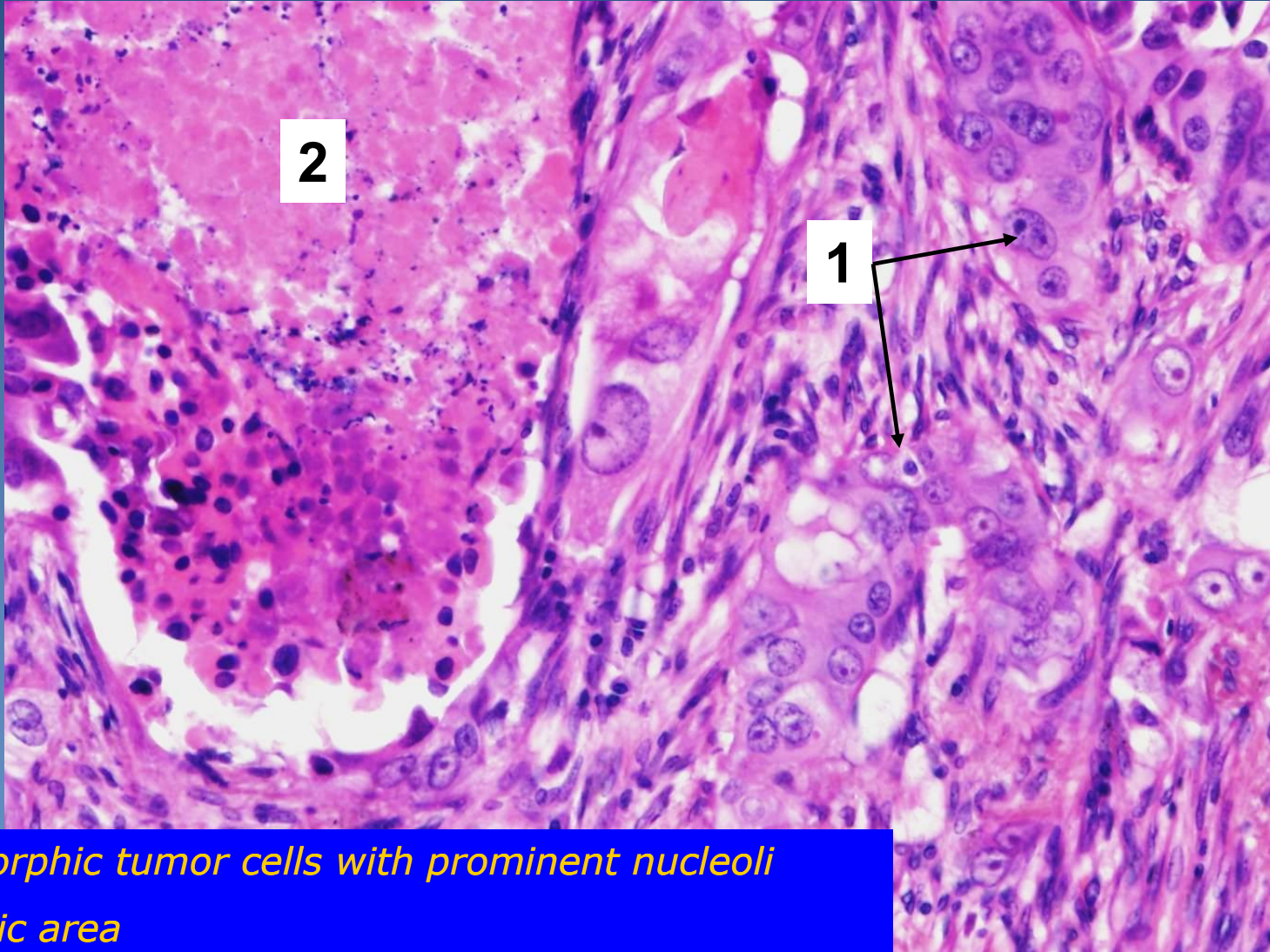
Large cell lung carcinoma



- 1. Pleomorphic tumor cells*
- 2. Necrotic area*



Large cell lung carcinoma



- 1. Pleomorphic tumor cells with prominent nucleoli*
- 2. Necrotic area*