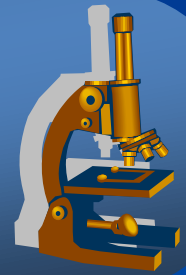


# *General pathology histopath. practice*

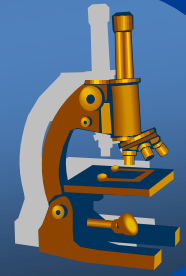


## General pathology II.

Circulation disorders

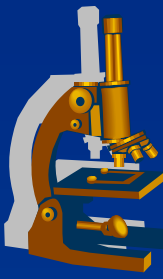
Inflammation I

# *Circulation disorders*



# *Circulation disorders*

---



- × Local
- × Systemic
- × Shock

# *Circulation disorders*

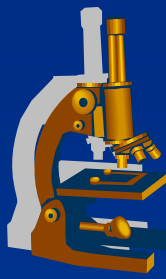
## **LOCAL**

---



- x Thrombosis
- x Embolism
- x Haemorrhage
- x Oedema
- x Hyperemia
- x Ischemia
- x Infarction

# Thrombosis



× main cause of local circulation disorders

» **intravital** formation of a pathological blood clot (thrombus) **within vascular system**, due to platelets aggregation + transformation of fibrinogen into fibrin  
possible obstruction of the blood flow through the circulatory system«

## Circulation disorders

× Local

⇒ **thrombosis**

⇒ *embolism*

⇒ *hemorrhage*

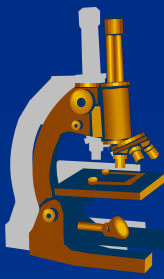
⇒ *oedema*

× Systemic

⇒ *cardial*

⇒ *extracardial*

# Thrombosis



## 3 basic pathogenetic mechanisms:

### ⇒ endothelial cell injury

- the most important (trauma, AS, immune complexes, viruses, bacteria, inflammations, toxins) – FXII activation

### ⇒ blood flow disturbance

- stagnation past the point of injury, venous stasis in leg veins

### ⇒ blood constituents change, coagulopathy

- congenital: e.g. genetic mutation FV (Leiden)
- acquired: hormonal contraception, tumor dissemination, DIC, hyperlipidemia, smoking

## **Circulation disorders**

### ×Local

⇒ **thrombosis**

⇒ *embolism*

⇒ *hemorrhage*

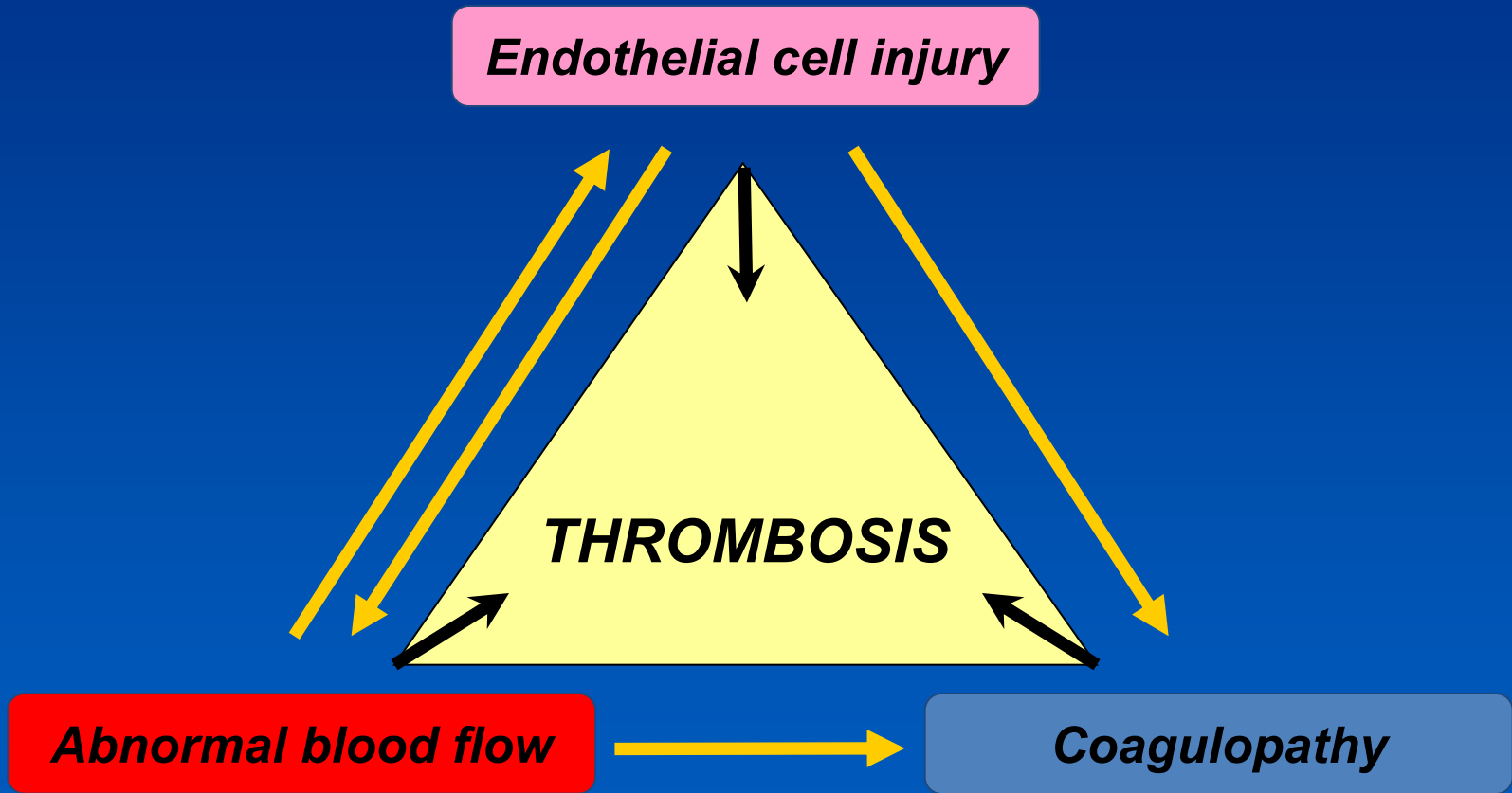
⇒ *oedema*

### ×Systemic

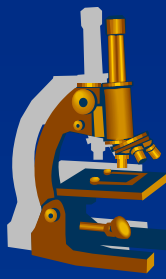
⇒ *cardial*

⇒ *extracardial*

# Pathogenetic mechanism



# Thrombosis



## GROSS:

- ⇒ *mural thrombus (cardial cavities, arteries)*
- ⇒ *obturating (veins)*

## **Circulation disorders**

### ×Local

- ⇒ **thrombosis**
- ⇒ *embolism*
- ⇒ *hemorrhage*
- ⇒ *oedema*

### ×Systemic

- ⇒ *cardial*
- ⇒ *extracardial*



# Thrombosis



## MICRO:

### ⇒ *red*

- erythrocytes, in leg veins - stasis

### ⇒ *white*

- thrombocytes, fibrin – cardial valves – turbulent flow

### ⇒ *mixed*

- combination of both (stratified thrombus, e.g. cardial and aortic aneurysm)

### ⇒ *fibrin thrombus*

- microscopic size, in small calibre arteries and capillaries, fibrin + platelets, CNS, kidney, lungs by shock, infections

## **Circulation disorders**

### × Local

#### ⇒ **thrombosis**

⇒ *embolism*

⇒ *hemorrhage*

⇒ *oedema*

### × Systemic

⇒ *cardial*

⇒ *extracardial*

# Thrombosis

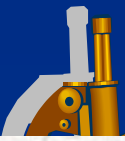


## FATE OF THROMBI

- ⇒ *vessel wall hypoxia » platelet grow factors » reparative fibroproductive inflammation» thrombus fixation to the vessel wall » fibroblasts » **thrombus retraction** » **recanalization** + ORGANIZATION*
- ⇒ *growth of the thrombus*
- ⇒ *breaking off of the thrombus ⇨ embolism*
- ⇒ *fibrinolysis*

## **Circulation disorders**

- ×Local
  - ⇨ **thrombosis**
  - ⇨ *embolism*
  - ⇨ *hemorrhage*
  - ⇨ *oedema*
- ×Systemic
  - ⇨ *cardial*
  - ⇨ *extracardial*



Source: Robbins basic pathology

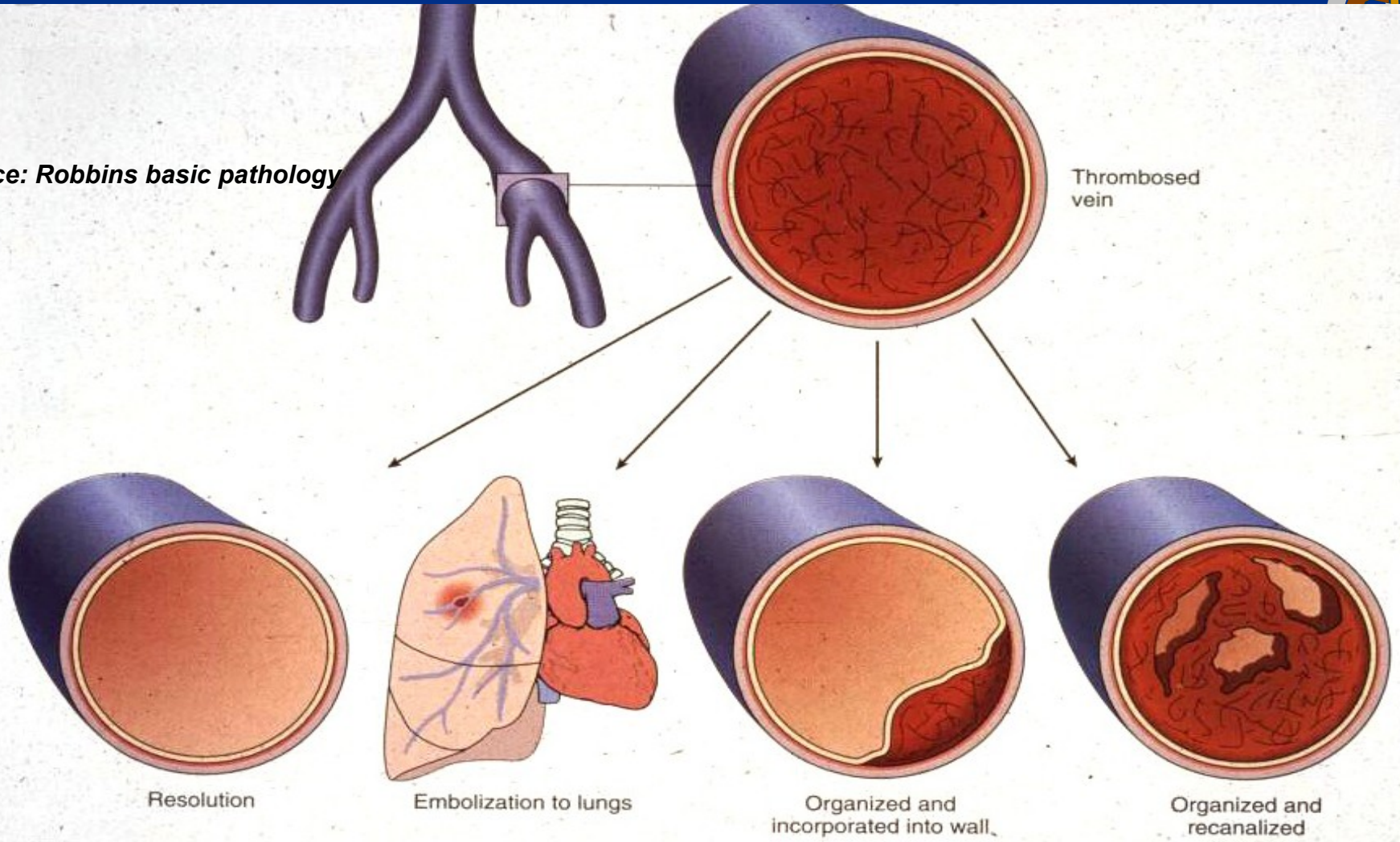
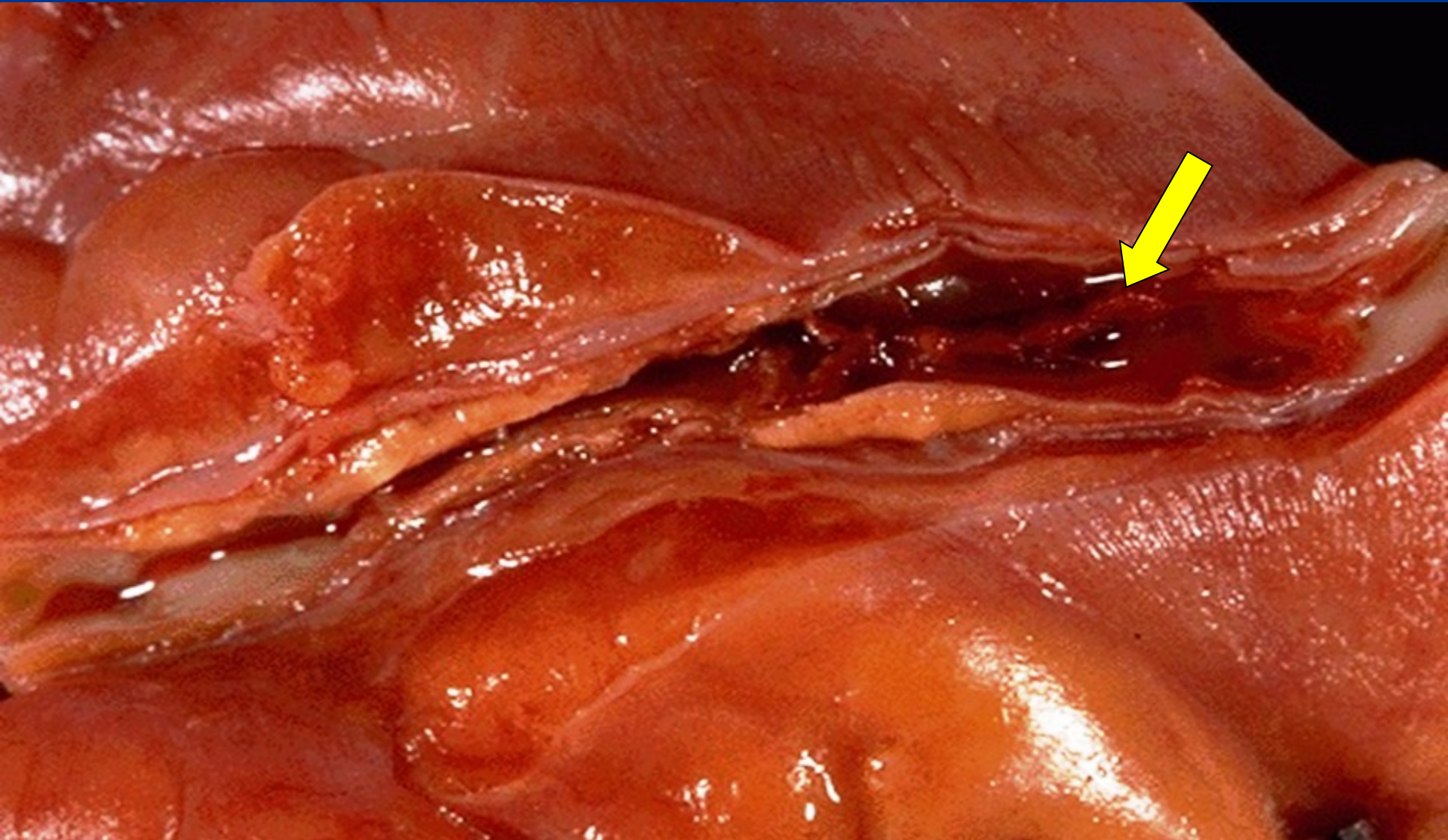

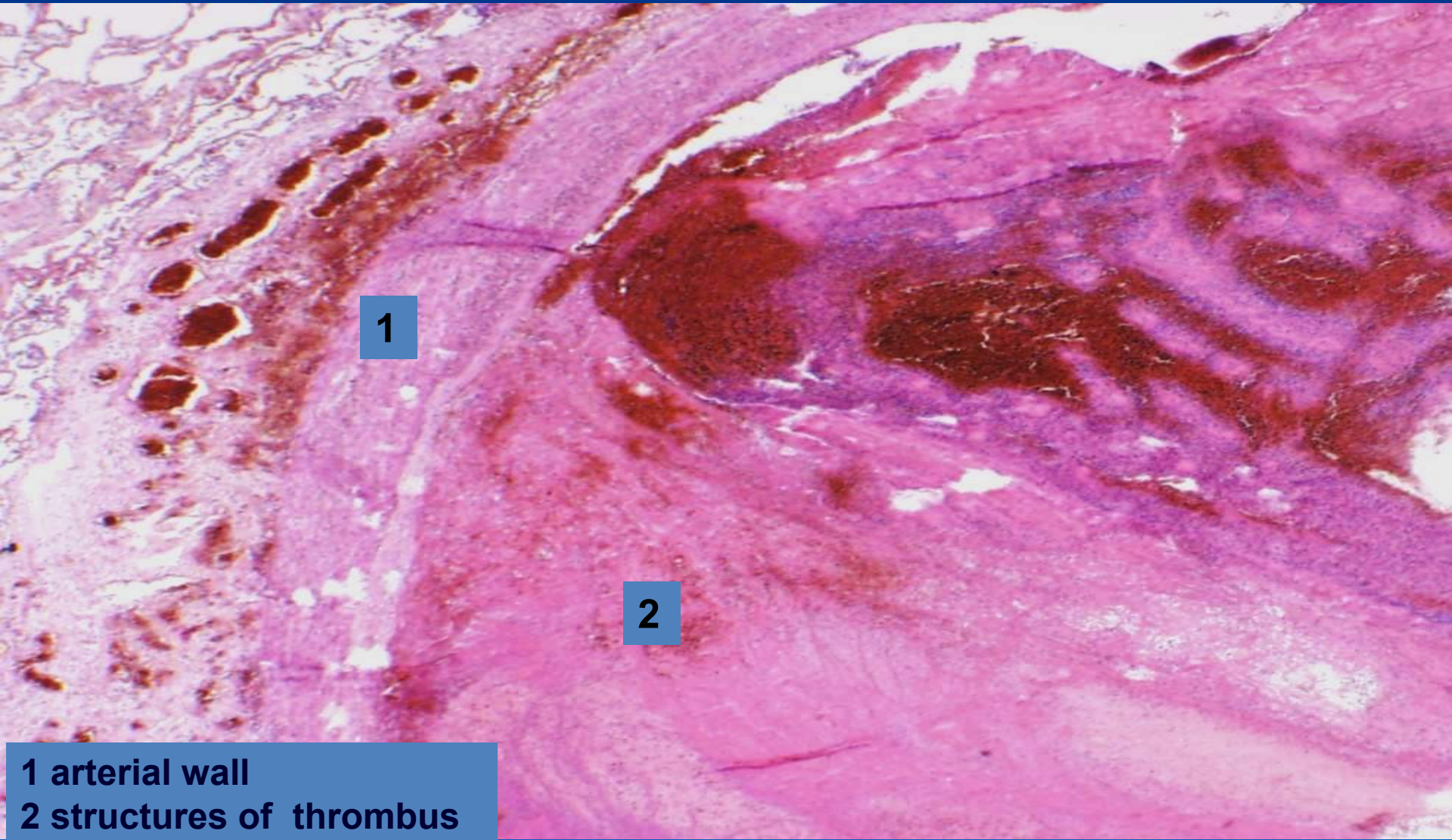
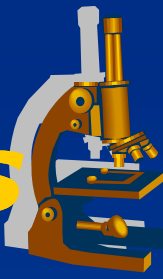


Figure 4-10

# ***Coronary artery thrombosis***



# Organized mixed thrombus



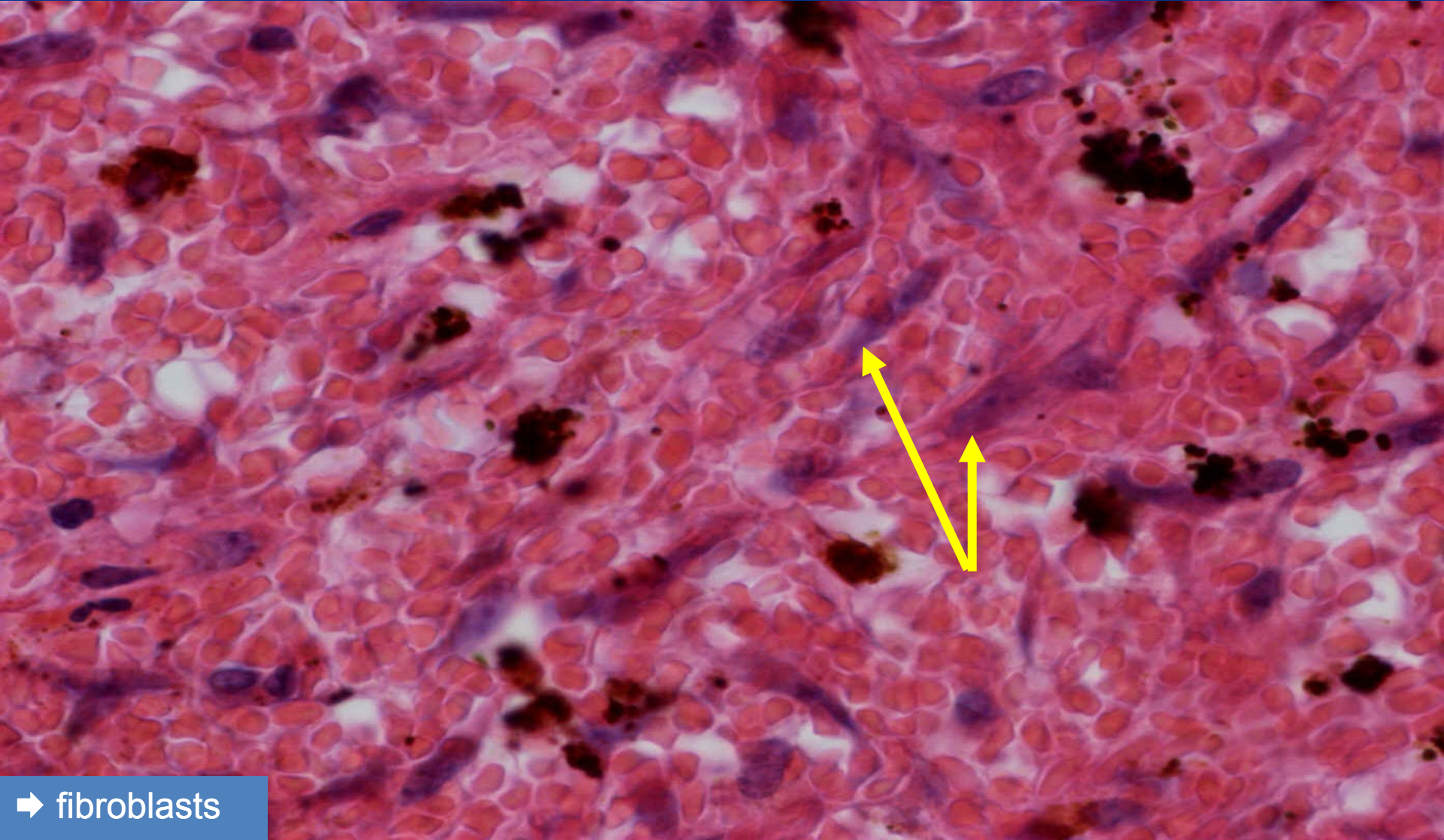
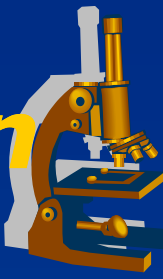
1

2

1 arterial wall  
2 structures of thrombus

# *Mixed thrombus - organization*

*(detail 600x)*



➔ fibroblasts

# Microcirculation thrombosis DIC



× Acquired coagulopathy, mortality 40%

× Etiopathogenesis:

*release of tissue factor (a part of the cell membranes) into blood or endothelial damage*

× Causes:

⇒ **Obstetric complications:**

- intravenous embolism of amniotic fluid
- placental abruption

⇒ **Infections**

- meningococcal, staphylococcal sepsis, acute pancreatitis

⇒ **Shock**

⇒ **Tissue trauma** (burns, major surgery)

# DIC



## x 1<sup>st</sup> phase: hypercoagulation

### ⇒ *Morphology:*

- multiple fibrin thrombi in the microcirculation
- brain, lungs, kidney, heart, liver – ischemia, multi-organ failure
- microangiopathic haemolytic anaemia

## x 2<sup>nd</sup> phase: hypocoagulation:

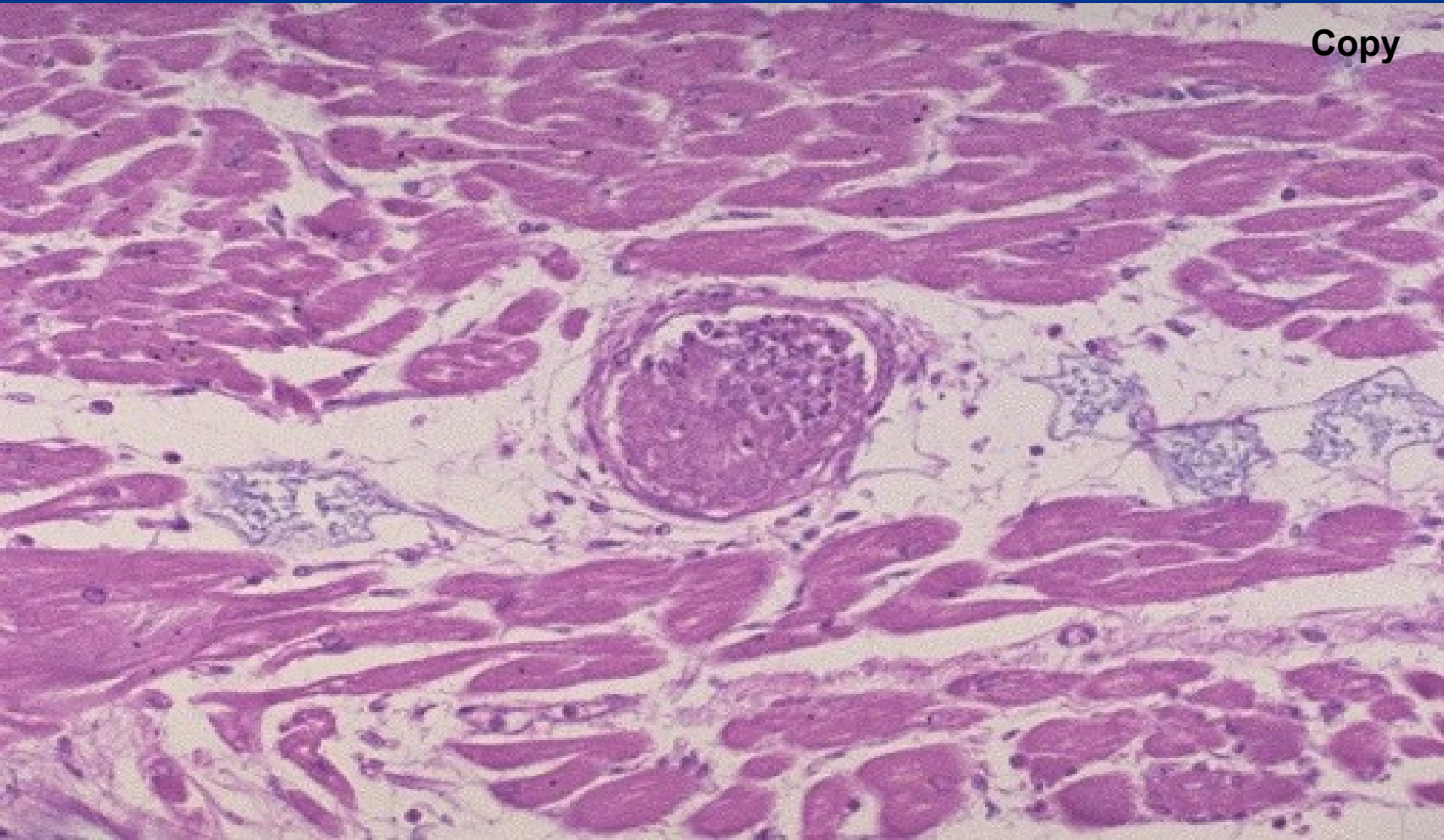
- ⇒ *consumption of coagulation factors/fibrin degradation products*
- ⇒ *extreme hypocoagulability, fatal bleeding (surgical wounds, mucous membranes)*



# *Fibrin thrombus*



Copy



# Embolism



= a mass of movable material in the vascular system able to become lodged within a vessel and **block its lumen.**

## × thrombembolism:

⇒ *most common*

⇒ *from veins (deep v. of legs) into pulmonary arteries*

⇒ *from heart/aorta into systemic arteries*

## × paradoxical embolism:

⇒ *from veins into arteries via foramen ovale apertum*

## Circulation disorders

### × Local

⇒ *thrombosis*

⇒ **embolism**

⇒ *hemorrhage*

⇒ *oedema*

### × Systemic

⇒ *cardial*

⇒ *extracardial*

# Embolism



## × Localization:

- ⇒ *venous embolism*
- ⇒ *arterial embolism*
- ⇒ *paradoxical embolism*
- ⇒ *portal embolism*

## **Circulation disorders**

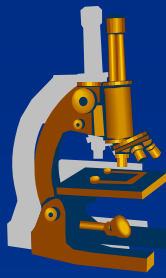
### × Local

- ⇒ *thrombosis*
- ⇒ **embolism**
- ⇒ *hemorrhage*
- ⇒ *oedema*

### × Systemic

- ⇒ *cardial*
- ⇒ *extracardial*

# Embolism



## × Classification:

- ⇒ *thrombotic*
- ⇒ *air*
- ⇒ *fat*
- ⇒ *cellular (tumor dissemination)*
- ⇒ *subcellular (DNA)*
- ⇒ *amniotic fluid*

## **Circulation disorders**

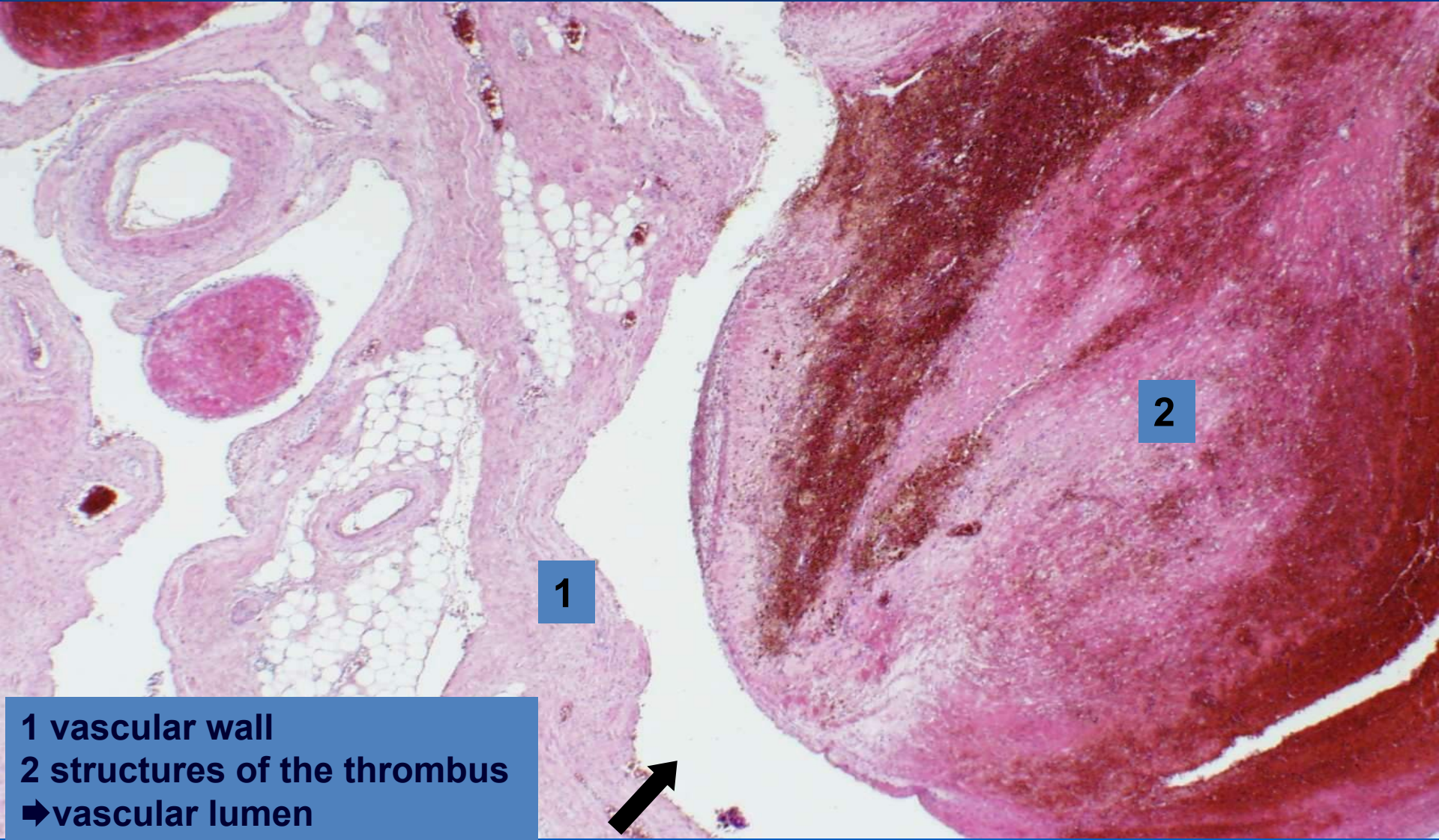
### × Local

- ⇒ *thrombosis*
- ⇒ ***embolism***
- ⇒ *hemorrhage*
- ⇒ *oedema*

### × Systemic

- ⇒ *cardial*
- ⇒ *extracardial*

# *Partially organized mixed blood clot*

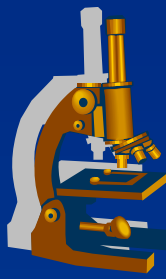


1

2

1 vascular wall  
2 structures of the thrombus  
➡vascular lumen

# Haemorrhage



= loss of blood from the circulatory system, accumulation of blood in the intersticium – HAEMATOMA

## ✗ localization:

⇒ *external x internal*

## ✗ origin:

⇒ *arterial, venous, capillary*

## ✗ appearance:

⇒ *petechiae, ecchymosis (subcutaneous), apoplexy (massive)*

## Circulation disorders

### ✗ Local

⇒ *thrombosis*

⇒ *embolism*

⇒ ***hemorrhage***

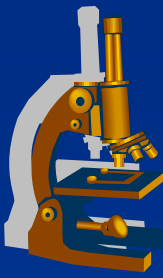
⇒ *oedema*

### ✗ Systemic

⇒ *cardial*

⇒ *extracardial*

# Oedema



Abnormal accumulation of fluid in the intersticium.

## × Types:

⇒ *localized*

⇒ *generalized*

## ***Circulation disorders***

### × Local

⇒ *thrombosis*

⇒ *embolism*

⇒ *hemorrhage*

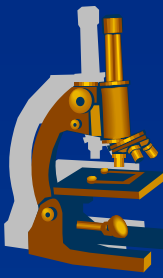
⇒ ***oedema***

### × Systemic

⇒ *cardial*

⇒ *extracardial*

# Oedema



## × Causes:

- ⇒ *venous: ↑ intravenous pressure (e.g. chronic cardiac failure)*
- ⇒ *inflammatory: increase of endothelial permeability*
- ⇒ *hypoalbuminaemic: reduced oncotic pressure*
- ⇒ *lymphostatic oedema*

## **Circulation disorders**

### × Local

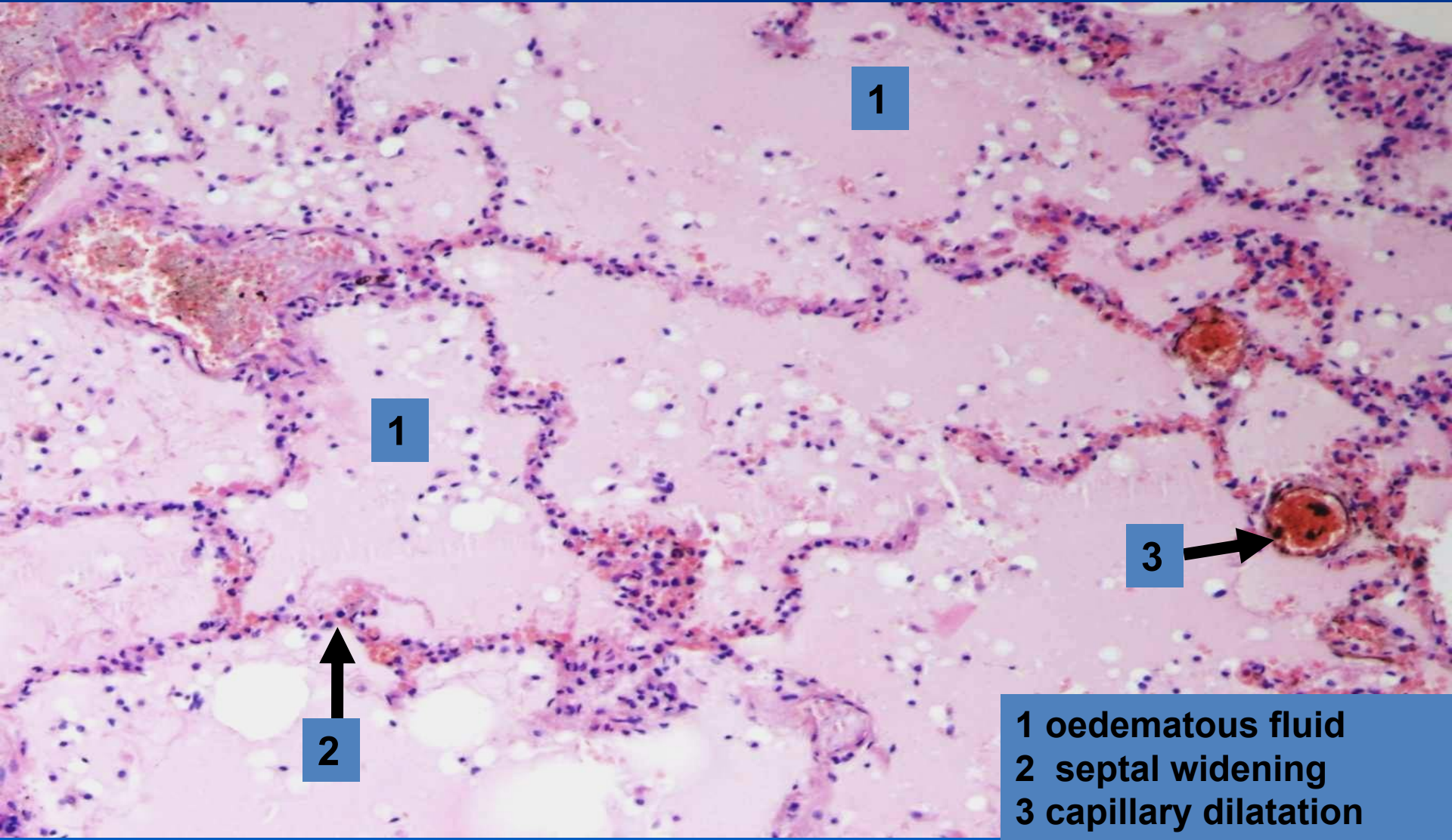
- ⇒ *thrombosis*
- ⇒ *embolism*
- ⇒ *hemorrhage*
- ⇒ ***oedema***

### × Systemic

- ⇒ *cardial*
- ⇒ *extracardial*



# *Pulmonary oedema*



1

1

3

2

1 oedematous fluid  
2 septal widening  
3 capillary dilatation

# Circulation disorders

## SYSTEMIC



### CAUSES:

#### × HEART

*(ischemic heart disease, myocarditis, cardiomyopathy, pericarditis, valvular heart disease, endocarditis)*

#### × VESSELS

*(systemic hypertension, pulmonary hypertension)*

#### × BLOOD DISORDERS

*(polycythemia vera, anemia)*

### Circulation disorders

#### × Local

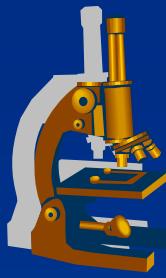
- ⇒ thrombosis
- ⇒ embolism
- ⇒ hemorrhage
- ⇒ oedema

#### × Systemic

- ⇒ cardiac
- ⇒ extracardial

# ***Circulation disorders***

## ***SYSTEMIC***



**x All causes subsequently manifest as**  
***HEART FAILURE***

Left ventricle failure

Right ventricle failure

Congestive heart failure – both ventricles

⇒ „forward“ failure – usually low cardiac output

⇒ „backward“ failure – venous congestion

cardiogenic shock

### ***Circulation disorders***

**x Local**

⇒ thrombosis

⇒ embolism

⇒ hemorrhage

⇒ oedema

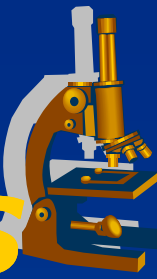
**x Systemic**

⇒ cardiac

⇒ extracardial

# *Circulation disorders*

## **MORPHOLOGICAL ASPECTS**



### **× HEART:**

#### ⇒ *Dilatation (without hypertrophy)*

- acute cardiac failure (pulmonary embolism)

#### ⇒ *Hypertrophy*

- **concentric** × **eccentric** (+ dilatation)
- Starling`s principle, depletion of adaptation mechanisms

### ***Circulation disorders***

#### **× Local**

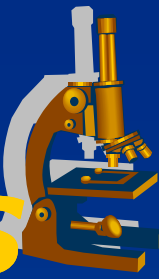
- ⇒ *thrombosis*
- ⇒ *embolism*
- ⇒ *hemorrhage*
- ⇒ *oedema*

#### **× Systemic**

- ⇒ **cardial**
- ⇒ *extracardial*

# *Circulation disorders*

## **MORPHOLOGICAL ASPECTS**



### **× EXTRACARDIAL**

- ⇒ *venous congestion +/- cyanosis*
- ⇒ *oedema (pulmonary, systemic)*
- ⇒ *induration*

### *Circulation disorders*

#### **× Local**

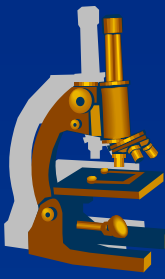
- ⇒ *thrombosis*
- ⇒ *embolism*
- ⇒ *hemorrhage*
- ⇒ *oedema*

#### **× Systemic**

- ⇒ *cardial*
- ⇒ ***extracardial***

# *Heart failure*

---



**x LV x RV**

**x ACUTE x CHRONIC failure**

# Heart failure



## × LV failure:

⇒ *acute - morphology:*

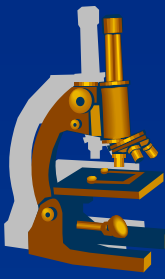
- congestion in pulmonary circulation
- pulmonary oedema

⇒ *chronic - morphology:*

- chronic pulmonary venous congestion – „brown“ lung induration (siderophages), later signs of RV failure

# ***Pulmonary oedema***

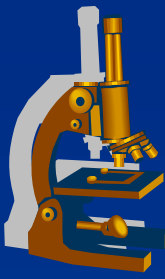
---



- ✘ Left-sided heart failure  
*(LV insufficiency, mitral stenosis)*
  
- ✘ congestion in pulmonary veins, capillaries



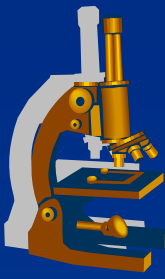
# ***Pulmonary oedema***



## **x** GROSS:

- ⇒ *enlarged, heavy lung of tougher consistency,*
- ⇒ *fluid running out from tissue and bronchi*
- ⇒ *in chronic venous congestion: superimposed oedema in the setting of tougher, rusty tissue*

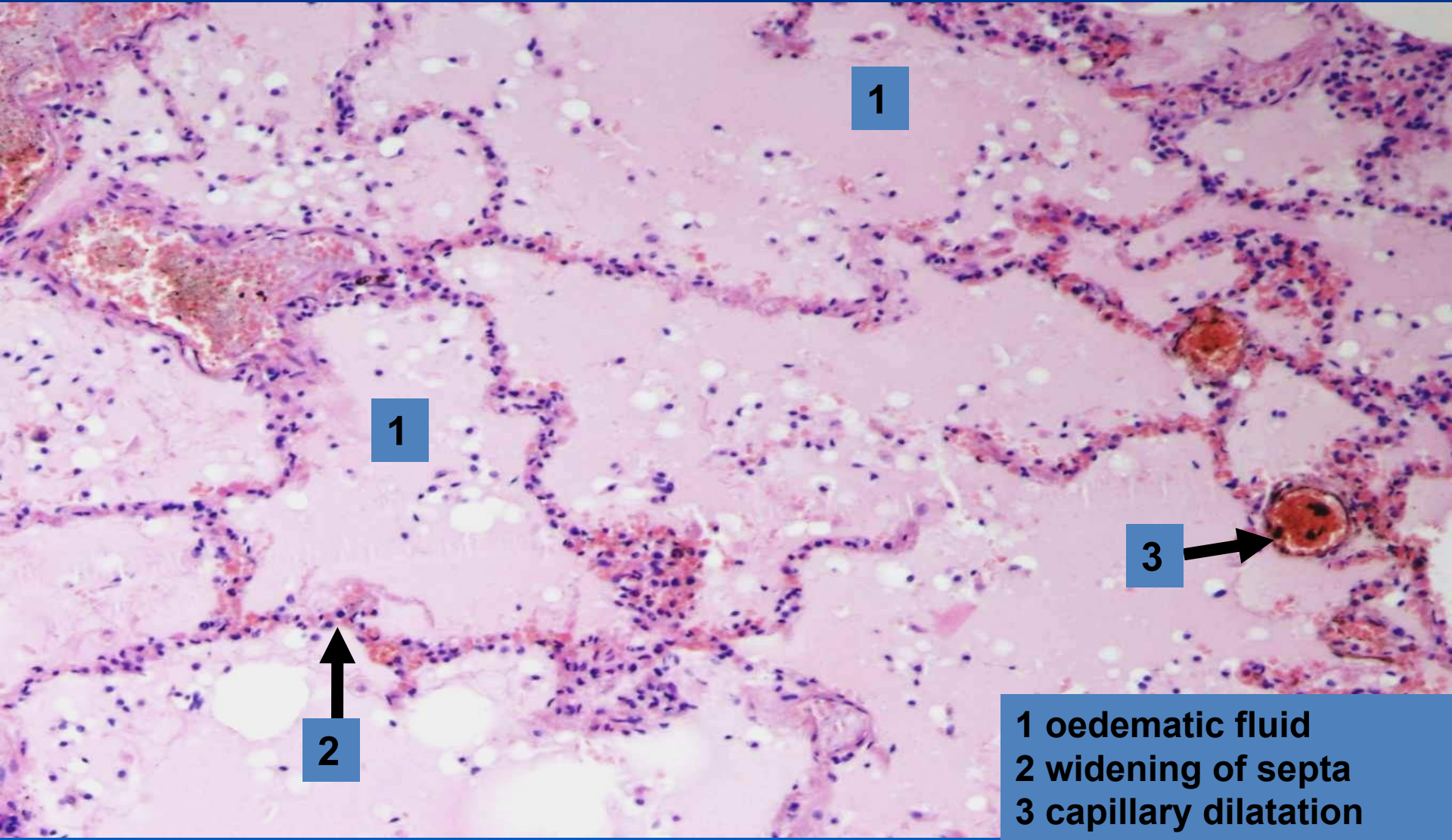
# ***Pulmonary oedema***



## **x** MICRO:

- ⇒ *dilatated septal capillaries filled with blood*
- ⇒ *widened septa*
- ⇒ *intraalveolar homogenous eosinophilic material (oedematic fluid)*
- ⇒ *long-standing: extravasation and breakdown of red blood cells (haemosiderin, siderophages)*

# *Pulmonary oedema*



1

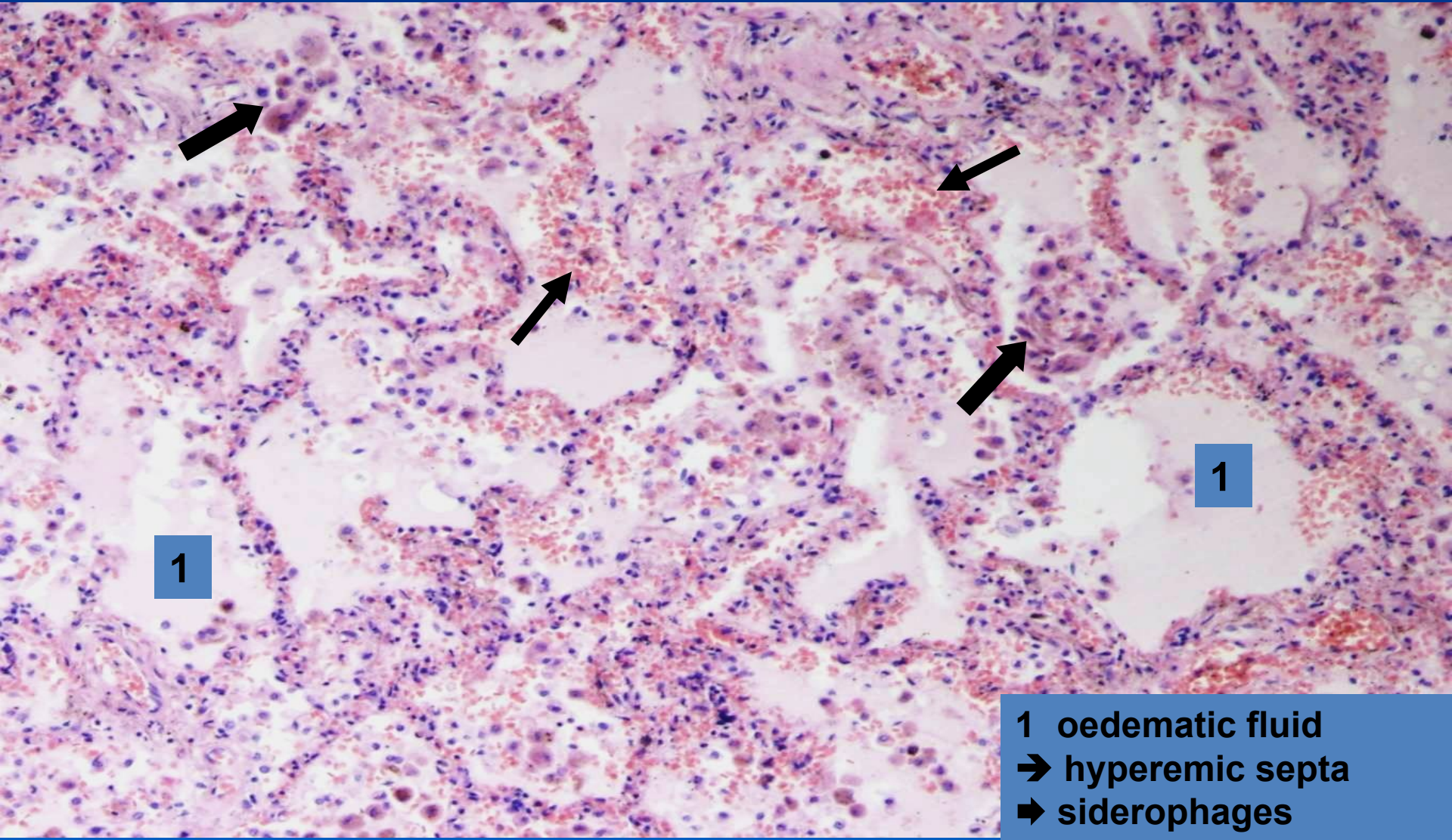
1

3

2

1 oedematous fluid  
2 widening of septa  
3 capillary dilatation

# *Chronic pulmonary venous congestion*

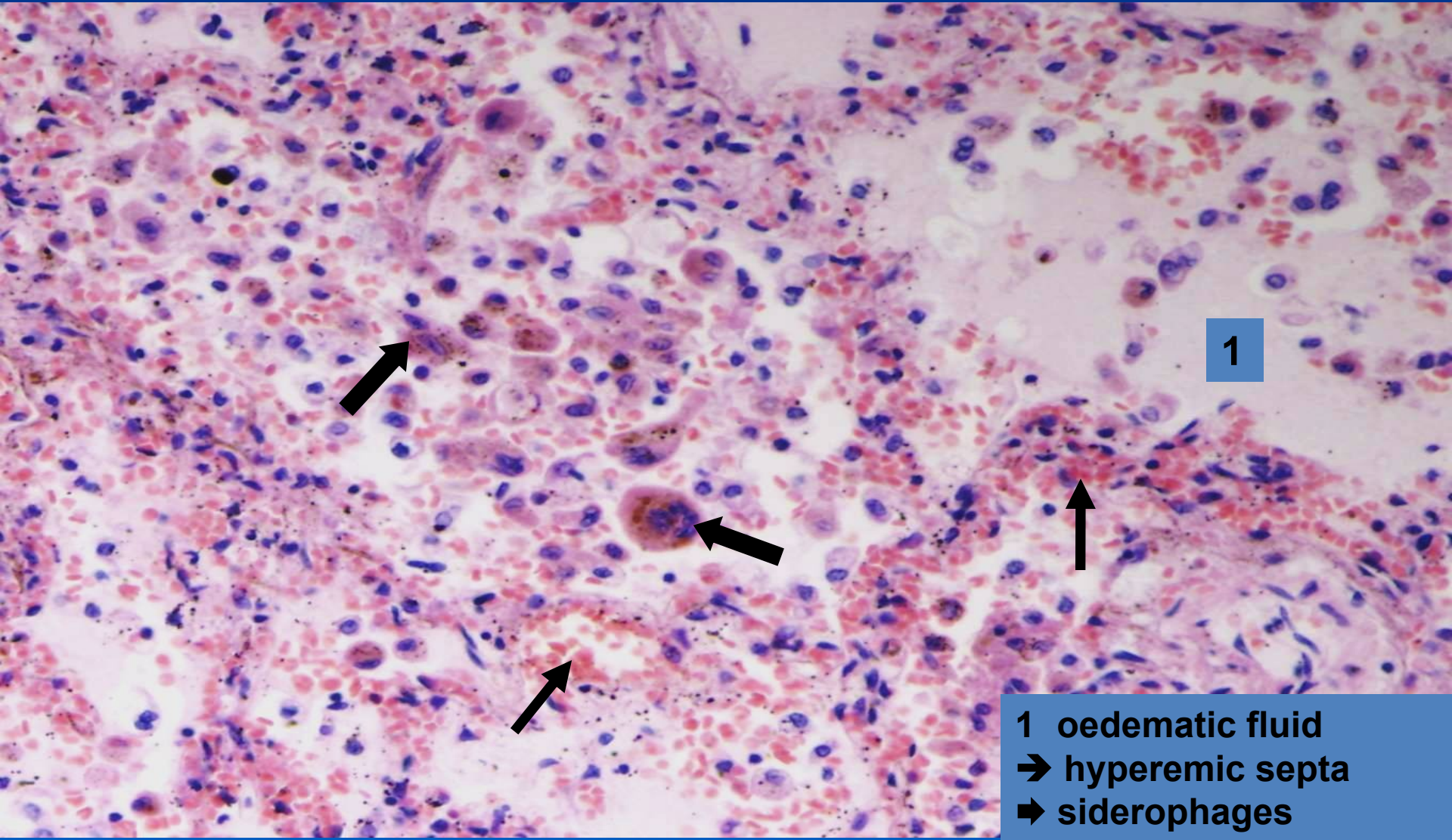


1

1

1 oedematous fluid  
→ hyperemic septa  
➡ siderophages

# ***Chronic pulmonary venous congestion (detail)***



1

1 oedemetic fluid  
→ hyperemic septa  
➡ siderophages

# Heart failure



## x RV insufficiency:

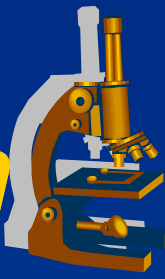
### ⇒ *acute - morphology:*

- acute cor pulmonale (massive thrombembolism)
- acute congestion in systemic circulation (splanchnic region) → congestive necrosis

### ⇒ *chronic - morphology:*

- chronic hepatic venous congestion, congestion in portal region (spleen, mucous membranes of GIT), kidneys
- congestive skin/soft tissue changes – trophic, oedemas
- venous congestion in brain

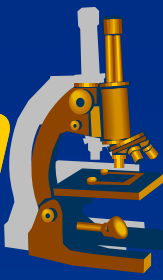
# *Hepatic venous congestion*



## **x** GROSS:

- ⇒ *enlarged, heavy liver*
- ⇒ *dark – reddish brown color*
- ⇒ *cardiac fibrosis (induration)*
- ⇒ *combination with chronic hypoxemic steatosis –  
**nutmeg liver***

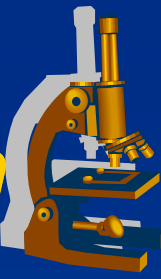
# ***Hepatic venous congestion*** ***("nutmeg" liver)***





# *Hepatic venous congestion*

---



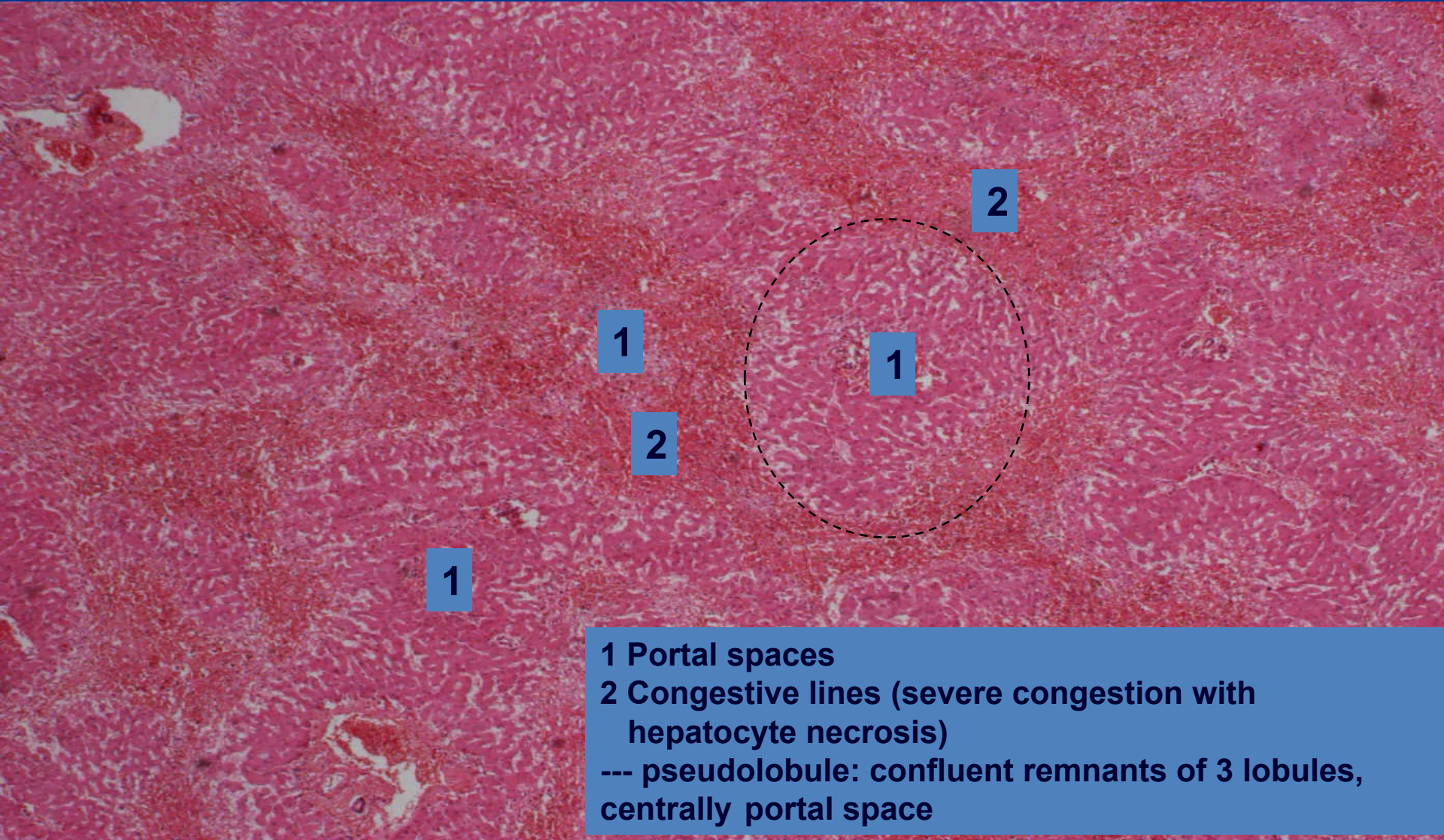
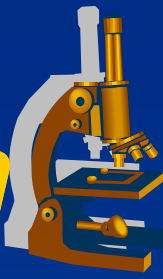
## **x** MICRO:

⇒ *central veins and sinusoidal dilatation*

⇒ *centrolobular hepatocytic atrophy, necrosis*

⇒ *„lines“ of congestion*

# Hepatic venous congestion

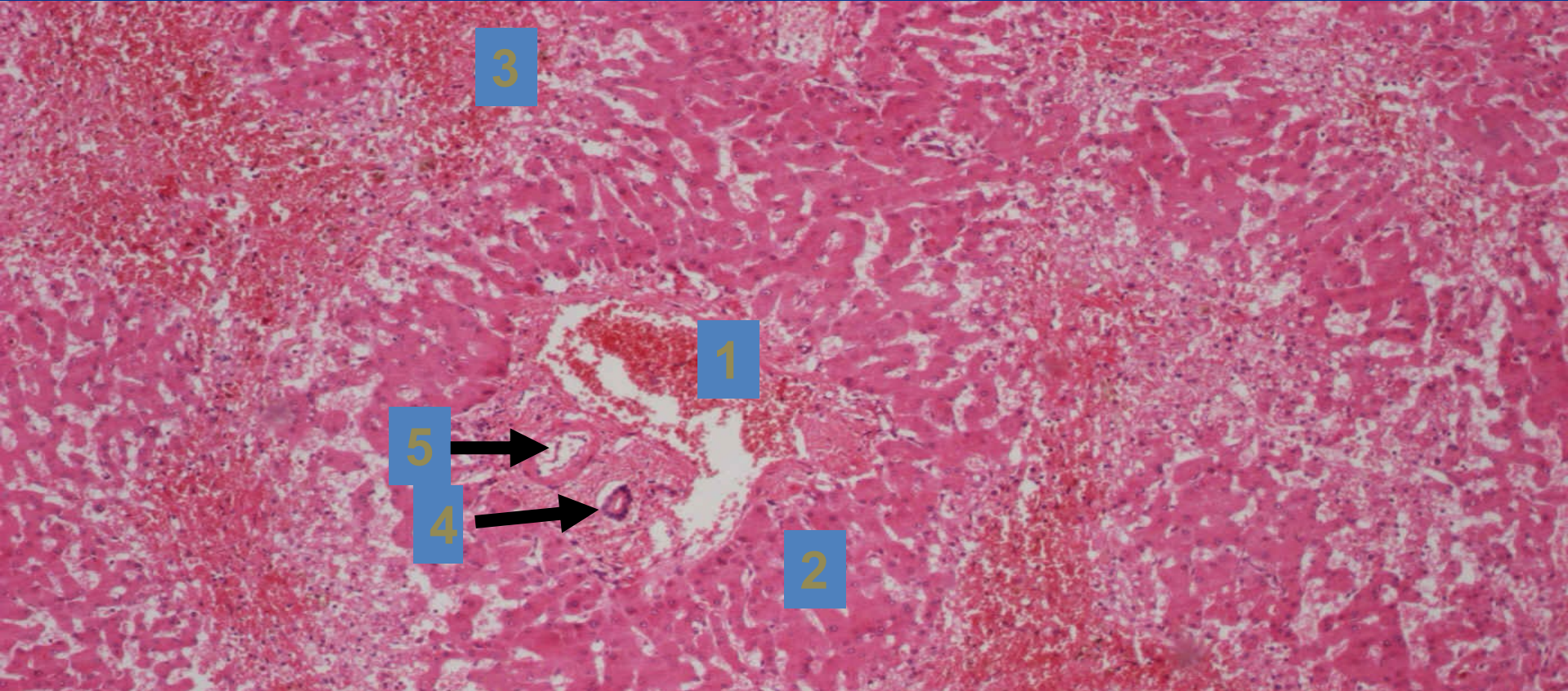
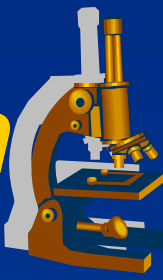


1 Portal spaces

2 Congestive lines (severe congestion with hepatocyte necrosis)

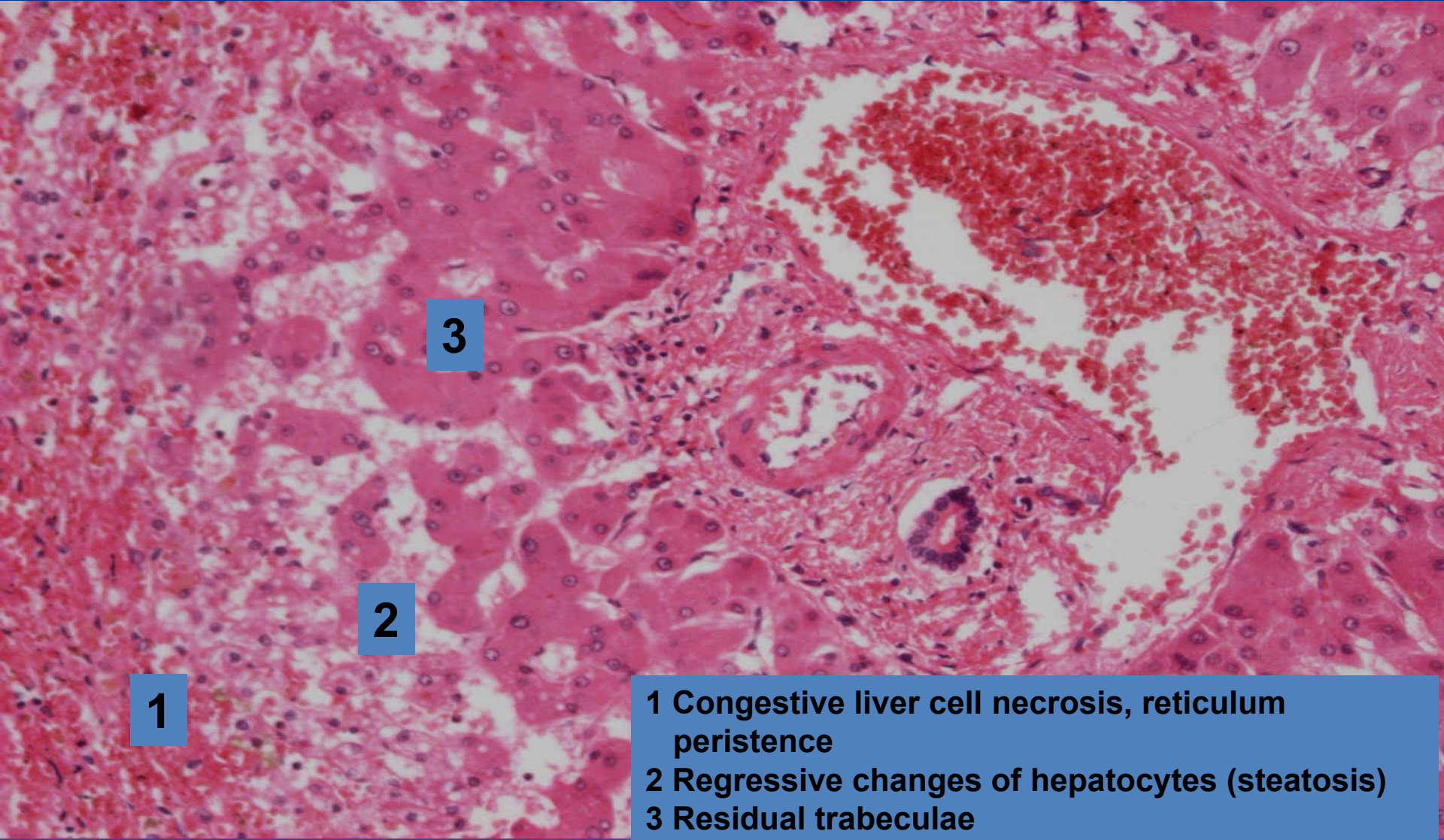
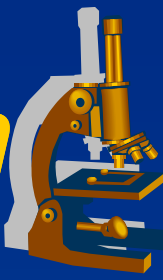
--- pseudolobule: confluent remnants of 3 lobules, centrally portal space

# *Hepatic venous congestion* (*"nutmeg" liver*), detail



- 1 Portal space-dilatation of portal vein branch
- 2 Pseudolobule
- 3 Congestion lines
- 4 Bile duct
- 5 Hepatic artery branch

# ***Hepatic venous congestion*** ***("nutmeg" liver), portal area detail***



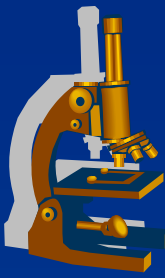
**1**

**2**

**3**

- 1 Congestive liver cell necrosis, reticulum peristence**
- 2 Regressive changes of hepatocytes (steatosis)**
- 3 Residual trabeculae**

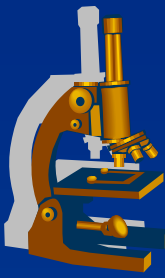
# Shock



» *Life-threatening medical condition that occurs due to inadequate substrate for aerobic cellular respiration. In the early stages this is generally an inadequate tissue level of oxygen (low organ perfusion).*«

✘ **Lethal without adequate medical therapy.**

# Shock



## ✘ Factors:

### ⇒ *Insufficient circulating volume (hypovolaemic)*

- ↓ peripheral vascular resistance
- ↑ vascular wall permeability
- blood loss

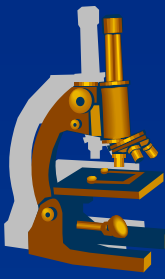
### ⇒ *Low cardiac output (cardiogenic)*

- Acute heart failure

(acute myocardial infarction, massive pulmonary embolism, cardiac tamponade, tension pneumothorax)

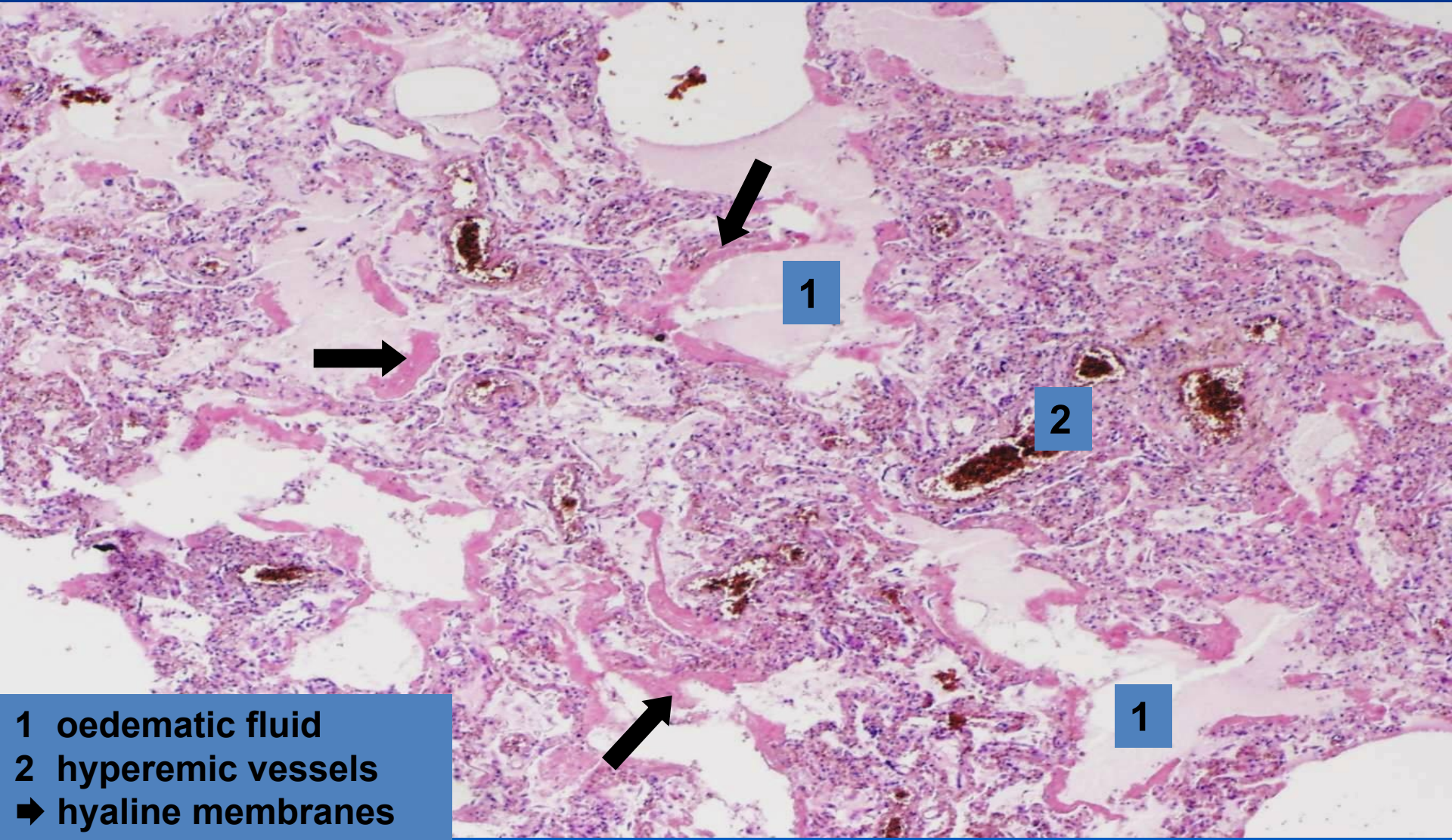
### ⇒ *Infection (bacterial toxæmia)*

# ***Shock - MORPHOLOGY***



- x Multiple organ failure (organ ischemia)**
  - ⇒ *brain***
  - ⇒ *heart***
  - ⇒ *kidney – acute tubular necrosis (ATN)***
  - ⇒ *lungs – diffuse alveolar damage/ acute respiratory distress syndrome (DAD/ARDS)***
  - ⇒ *adrenal glands, gastrointestinal tract***

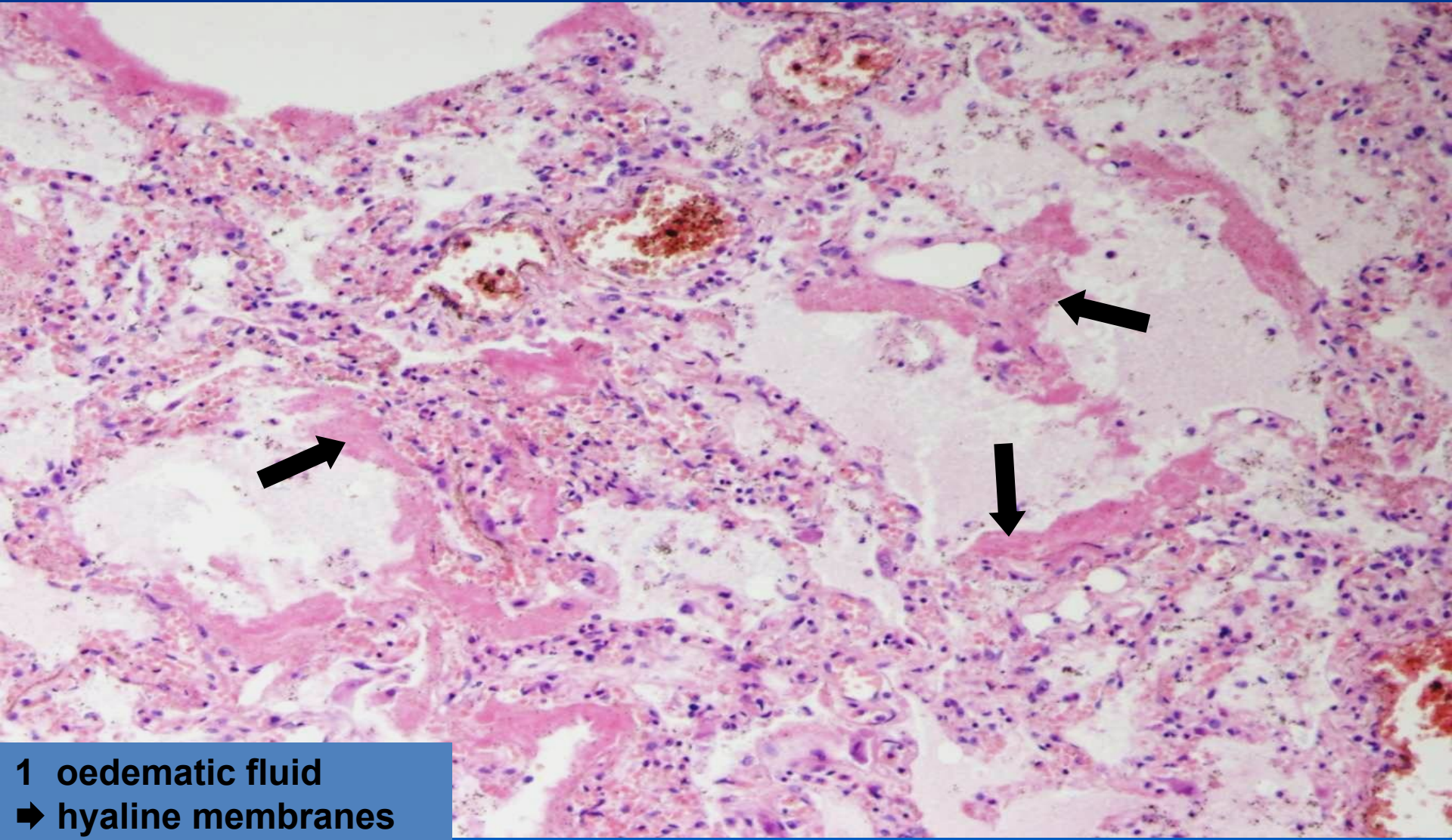
# ***DAD/ARDS***



- 1** oedematous fluid
- 2** hyperemic vessels
- ➔ hyaline membranes

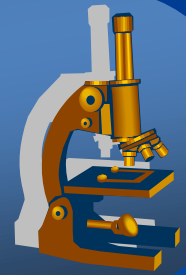


# ***DAD/ARDS*** ***(detail)***

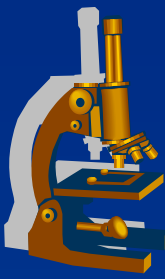


**1 oedemetic fluid**  
**➔ hyaline membranes**

# *Inflammation*



# Inflammation



= *PROTECTIVE RESPONSE* intended to eliminate harmful agents, accompanied with **alterative, exudative, proliferative components and immune response.**

✗ types:

⇒ *acute inflammation*

⇒ *chronic inflammation*

⇒ *nonspecific inflammation*

⇒ *granulomatous inflammation (specific)*

# *Inflammation*



## **x** Macroscopic appearances:

⇒ *rubor (redness)*

⇒ *calor (heat)*

⇒ *dolor (pain)*

⇒ *tumor (swelling)*

⇒ *functio laesa (loss of function)*

# *Inflammation*



## **x** Microscopic appearances:

### ⇒ **ALTERATION:**

- regressive changes, necrosis

### ⇒ **EXUDATION:**

- vascular leakage of protein-rich fluid and blood cells
- *exudate X transudate*

# *Inflammation*

---



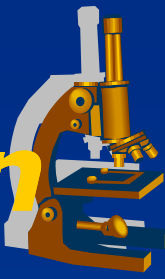
## ⇒ ***PROLIFERATION:***

- proliferation of fibroblasts and capillaries
- formation of granulation and fibrous tissue

## ⇒ ***IMMUNE RESPONSE:***

- antigen presentation
- T and B-lymphocytes reaction
- production of antibodies by plasma cells
- memory cells

# ***NONSPECIFIC inflammation***



## Classification:

### ⇒ ***alterative:***

- alteration of tissue
- *viral hepatitis, prion diseases [Creutzfeld-Jacob, BSE], diphtheric myocarditis*

### ⇒ ***exudative:***

- most common, exudation prevails
- superficial and deep
- *serous, fibrinous, nonpurulent, purulent, gangrenous*

### ⇒ ***proliferative:***

- formation of fibrous tissue

# ***Alterative inflammation*** ***(liver necrosis)***

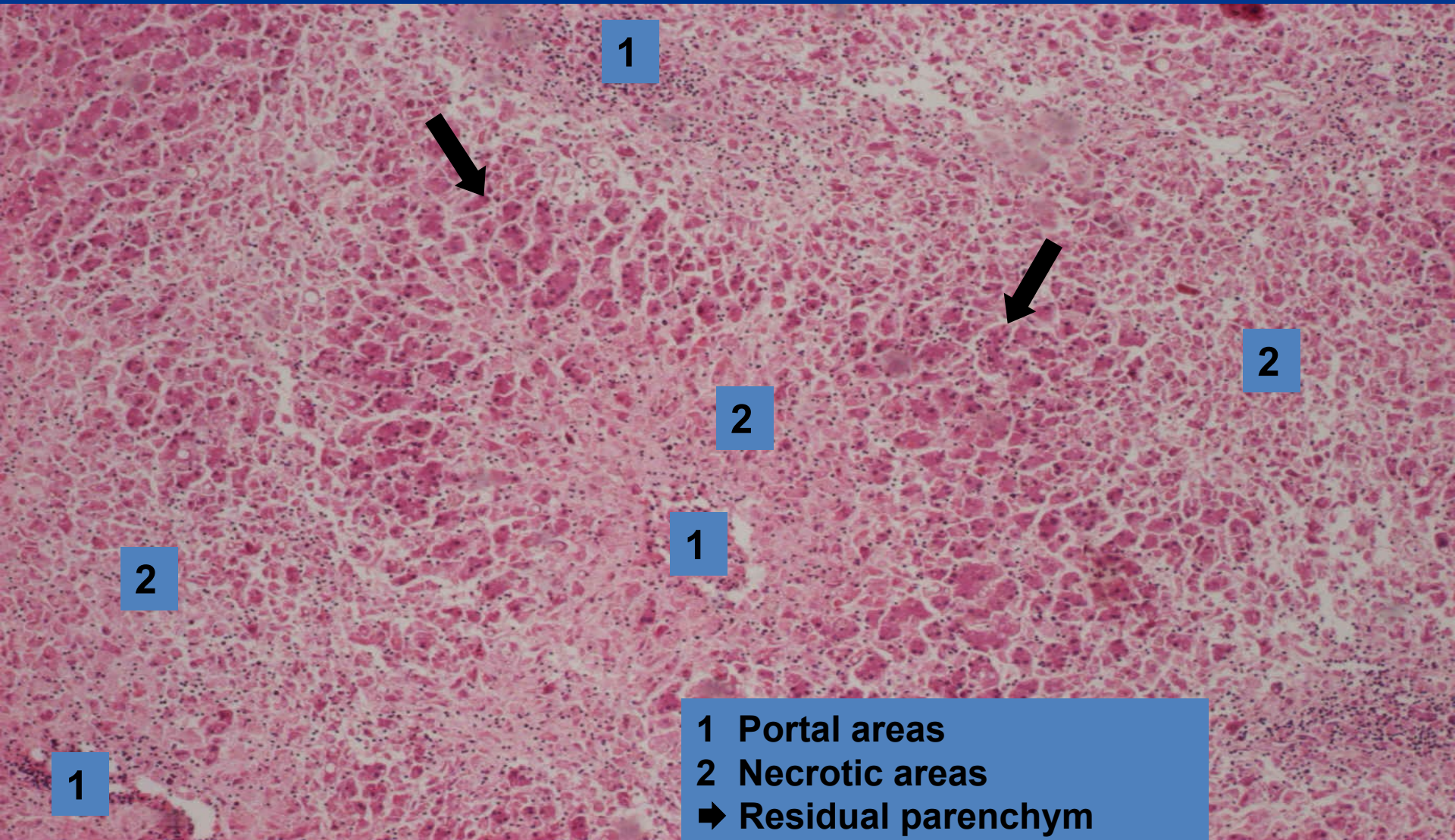


copy





# *Alterative inflammation* *(massive necrosis)*



1



2

2

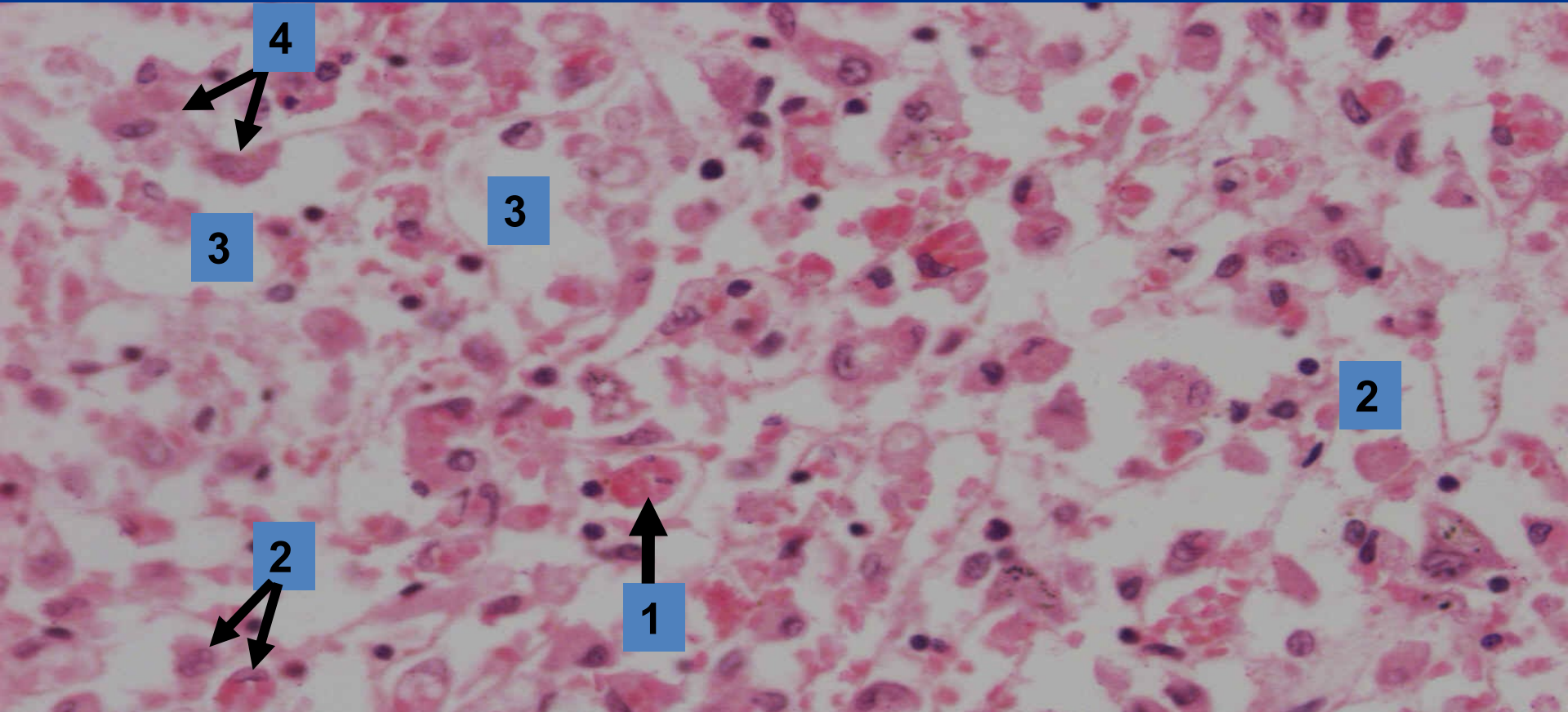
1

2

1

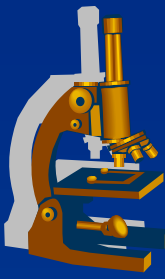
- 1 Portal areas
- 2 Necrotic areas
- ➔ Residual parenchyma

# ***Alterative inflammation*** ***(massive necrosis - detail)***



- 1 Necrotic cell**
- 2 Regressively changed hepatocytes**
- 3 Sinusoids**
- 4 Kupffer cells**

# ***Exudative inflammation***



**x** topography of inflammatory changes:

⇒ ***superficial*** (*mucous membrane, serous membranes, skin*)

⇒ ***deep*** (*interstitium*)

**x** exudate components:

⇒ ***serous***

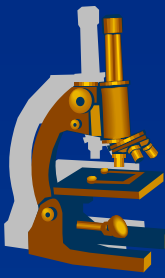
⇒ ***fibrinous***

⇒ ***nonpurulent***

⇒ ***purulent***

⇒ ***gangrenous***

# *Exudative inflammation*



**x**serous:

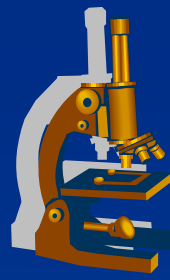
⇒ *watery exudate*

- few proteins (fibrinogen)
- in mucous membranes – catarrhal (mucus)

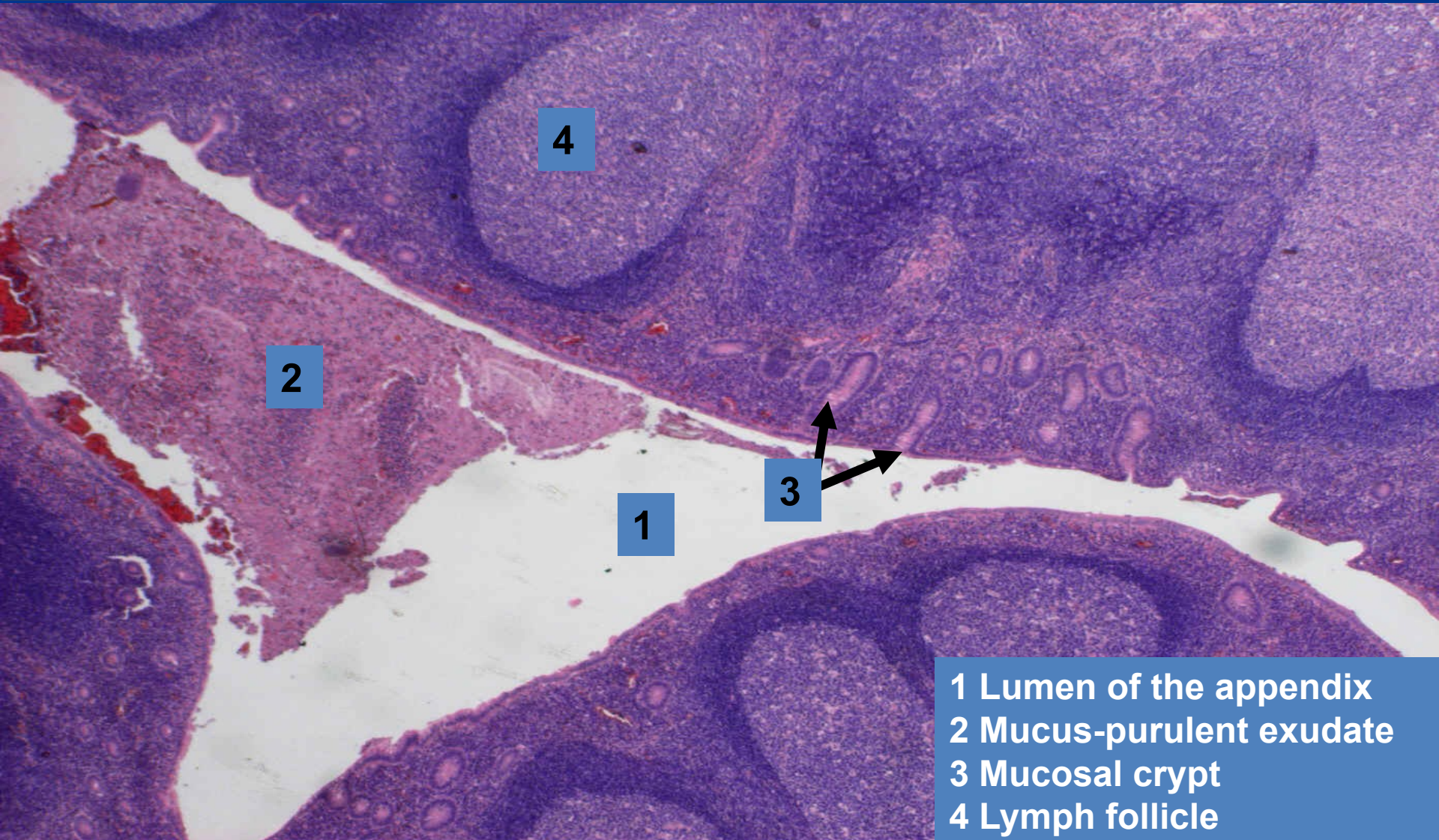
⇒ *heals by inhibition of exudation*

⇒ *examples:*

- **superficial:** catarrhal appendicitis
- **deep (interstitial):** urticaria (hives)



# ***Acute catarrhal appendicitis*** ***(superficial serous inflammation)***



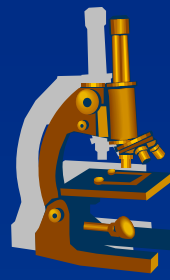
2

4

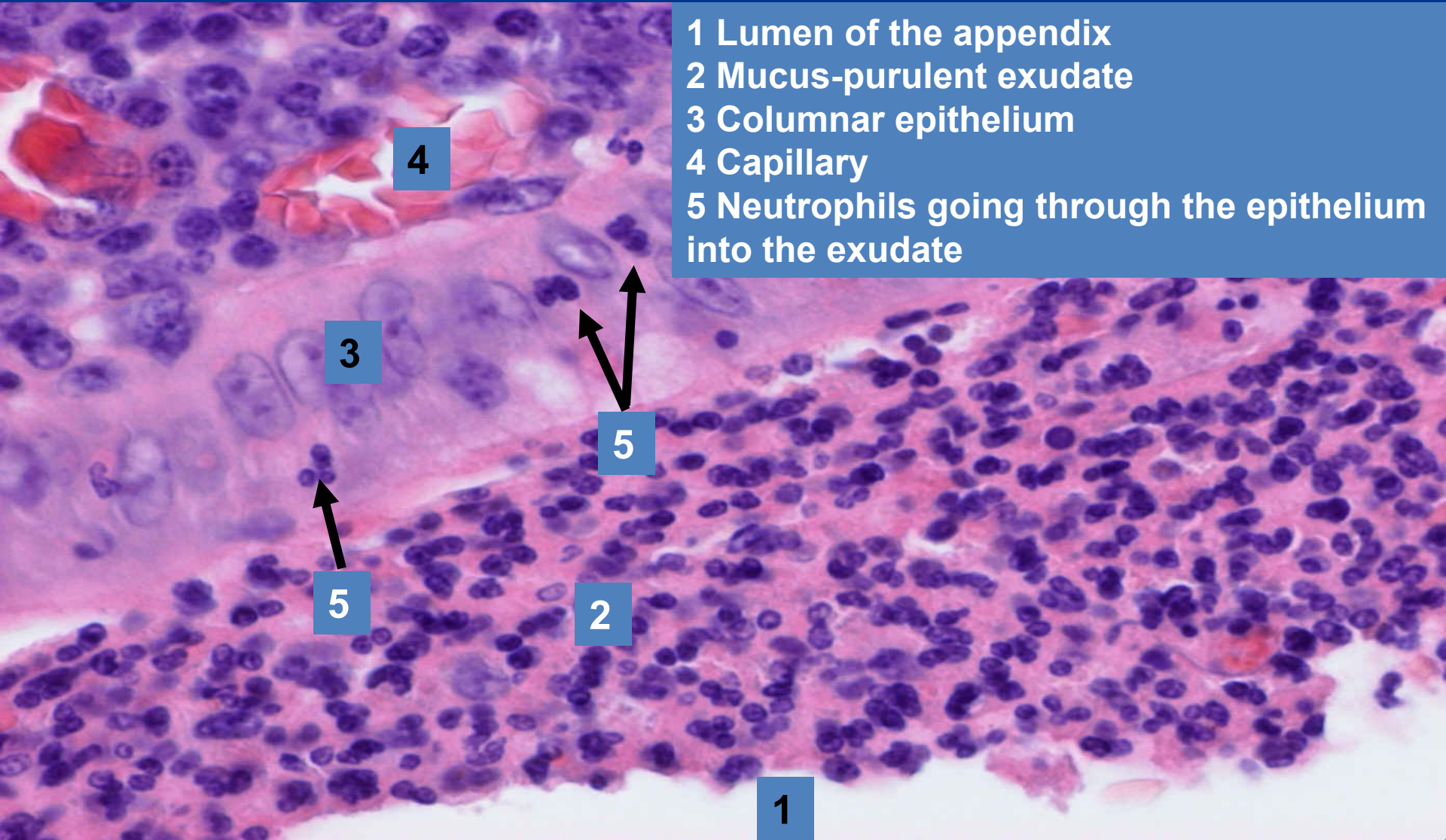
1

3

- 1 Lumen of the appendix
- 2 Mucus-purulent exudate
- 3 Mucosal crypt
- 4 Lymph follicle

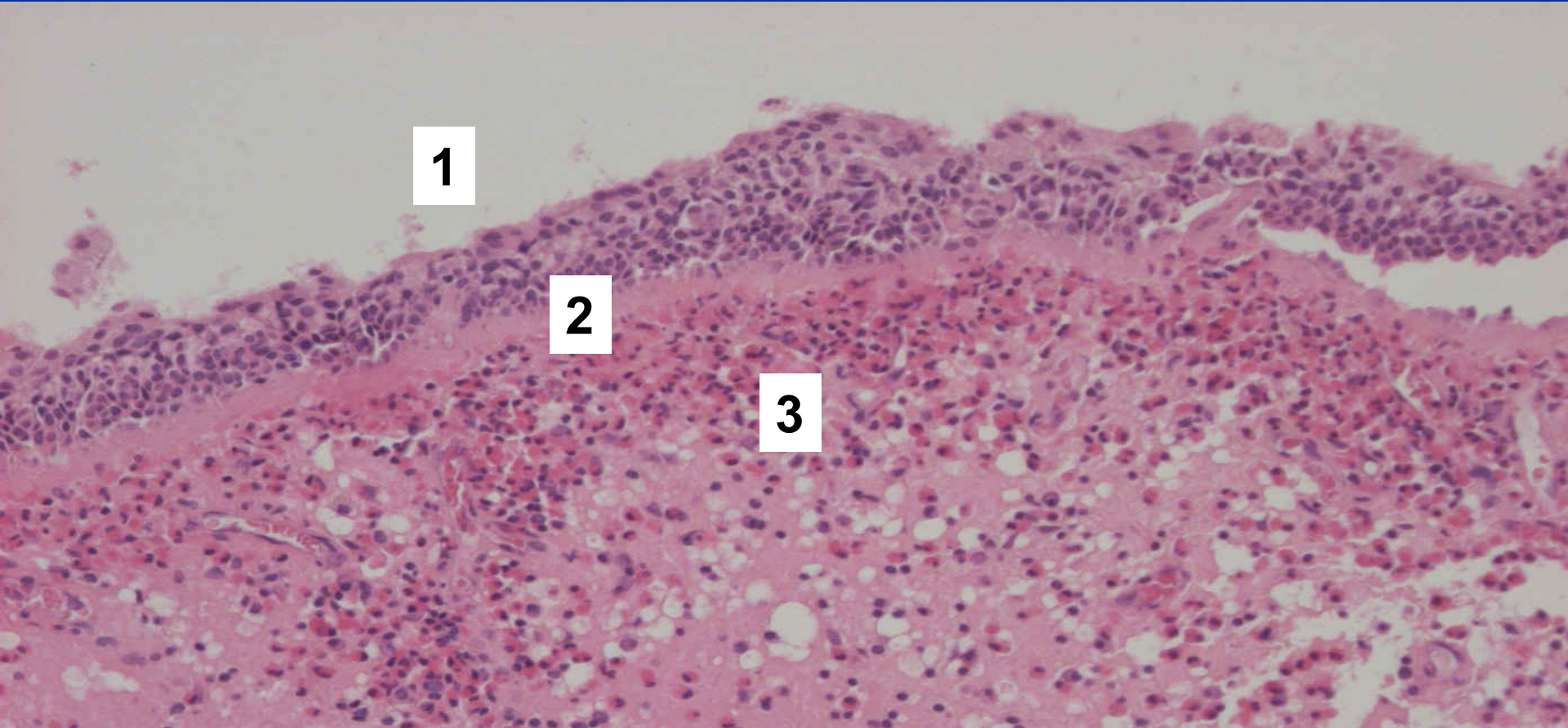


# ***Acute catarrhal appendicitis*** ***(superficial serous inflammation)***



- 1 Lumen of the appendix
- 2 Mucus-purulent exudate
- 3 Columnar epithelium
- 4 Capillary
- 5 Neutrophils going through the epithelium into the exudate

# ***Polypous chronic rhinitis*** ***(superficial serous inflammation)***



- 1 Epithelium with squamous metaplasia**
- 2 Thickened basal membrane**
- 3 Oedematous stroma with eosinophilic and plasma cell infiltration, dilatated lymphatic vessels**

# ***Polypous chronic rhinitis*** ***(superficial serous inflammation)***



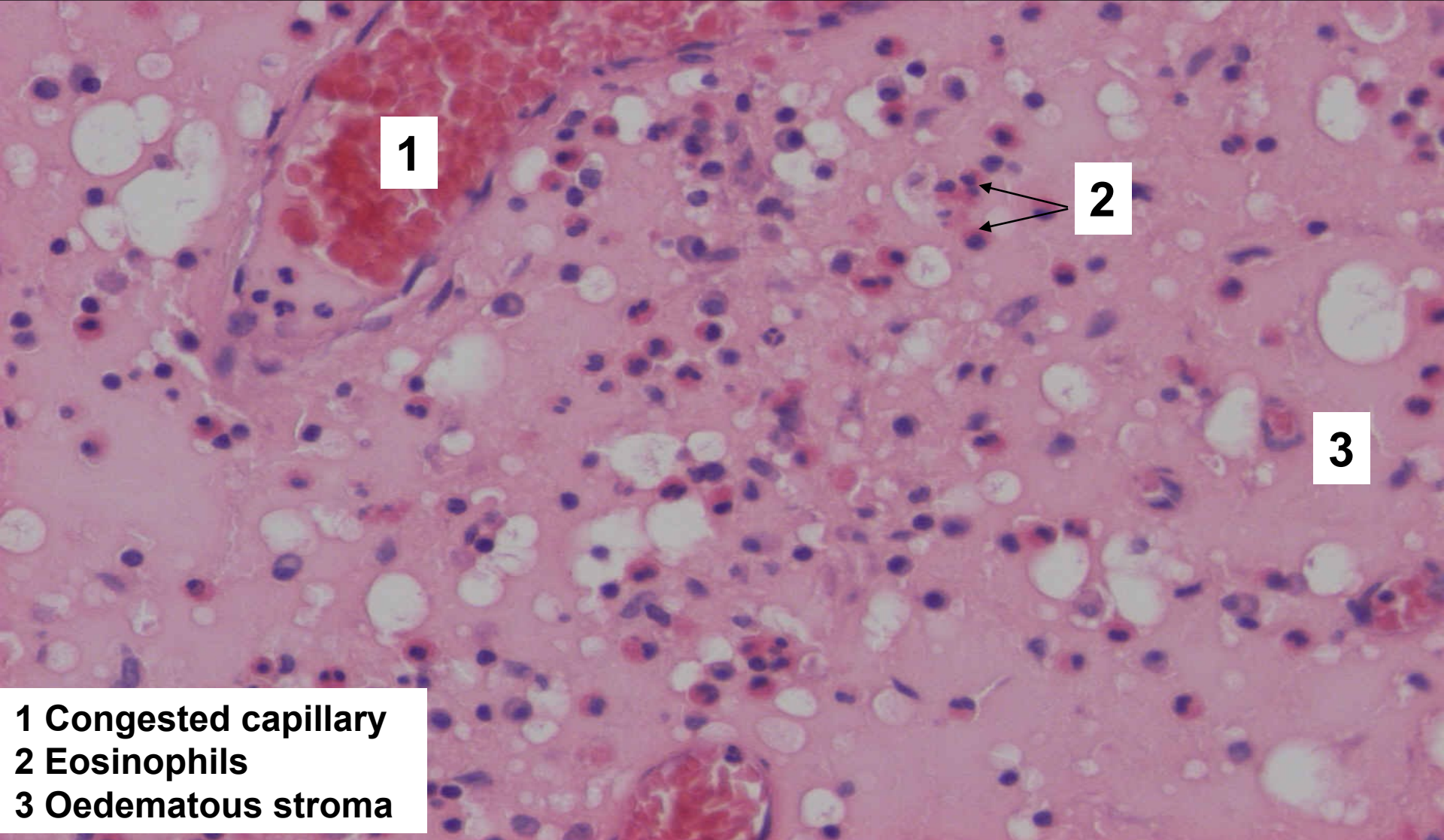
**1**

**2**

**1 Ciliated epithelium**  
**2 Oedematous stroma with  
inflammatory infiltrate**



# ***Polypous chronic rhinitis*** ***(superficial serous inflammation)***



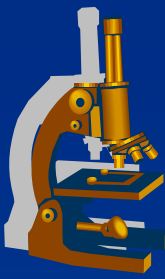
**1**

**2**

**3**

- 1 Congested capillary**
- 2 Eosinophils**
- 3 Oedematous stroma**

# Exudative inflammation



## x fibrinous:

⇒ *content of fibrinogen – fibrin*

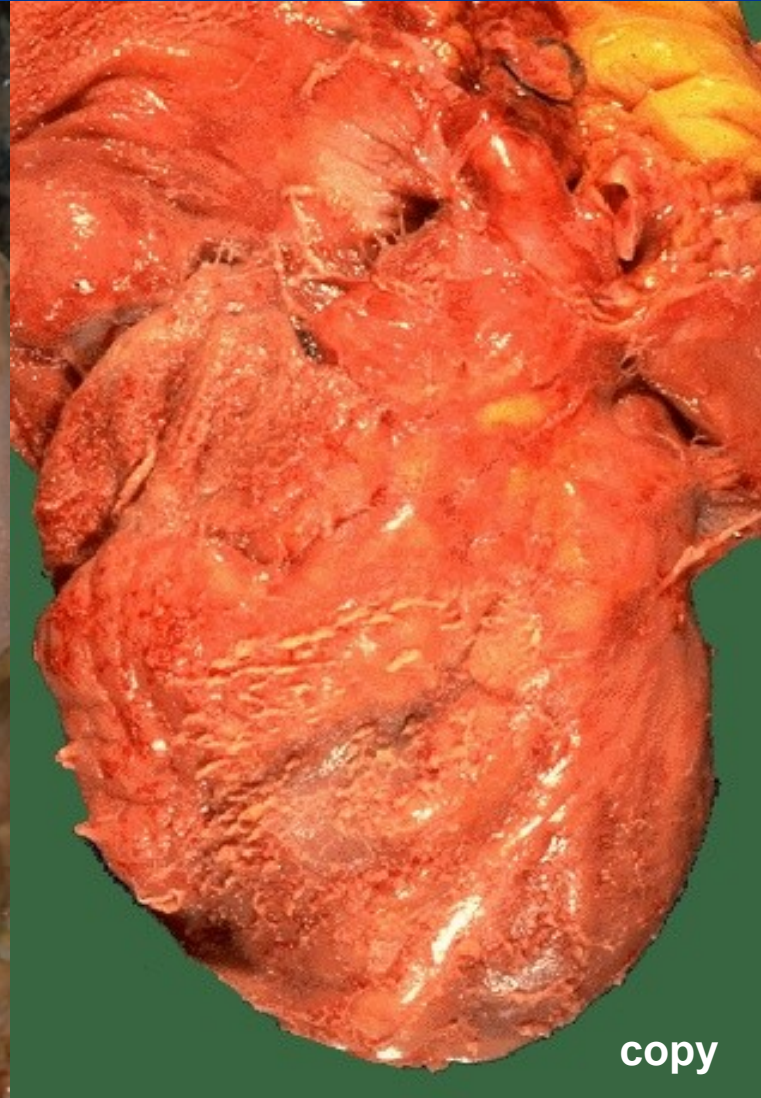
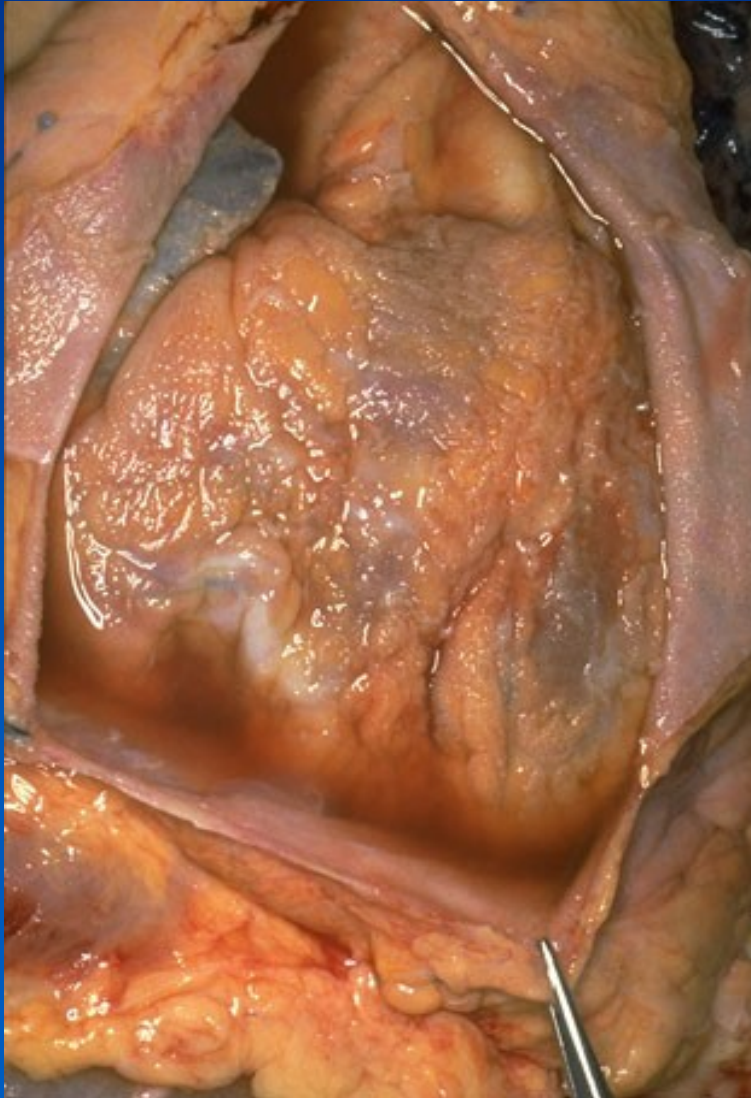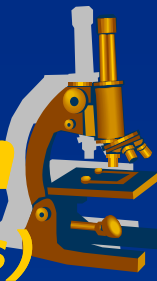
- gross: yellow-greyish *plaques*
- micro: eosinophilic fine fibers

⇒ *healing is more complicated (productive inflammation)*

⇒ *examples:*

- superficial inflammation of serous membranes:
  - **fibrinous pericarditis** (upon uremia) = cor villosum, hirsutum
- superficial infl. of mucous membranes (**PSEUDOMEMBRANES**):
  - **plaque-like inflammations**
- deep:
  - **rheumatic fever**

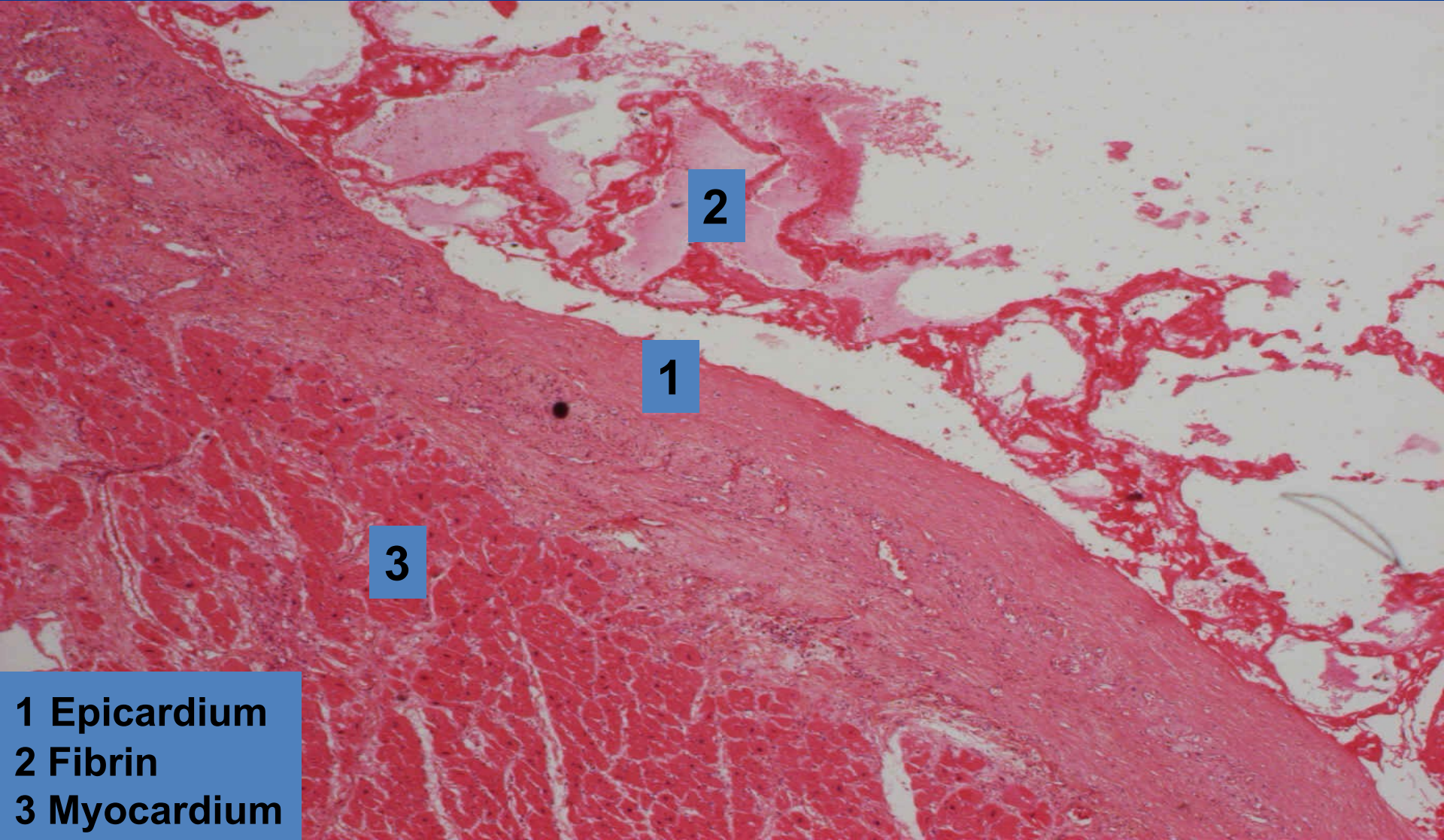
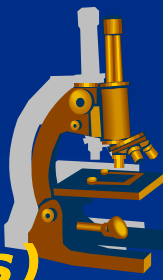
# ***Fibrinous pericarditis – cor villosum*** ***(superficial fibrinous inflammation of serous membranes)***



copy

# ***Fibrinous pericarditis***

***(superficial fibrinous inflammation of serous membranes)***



2

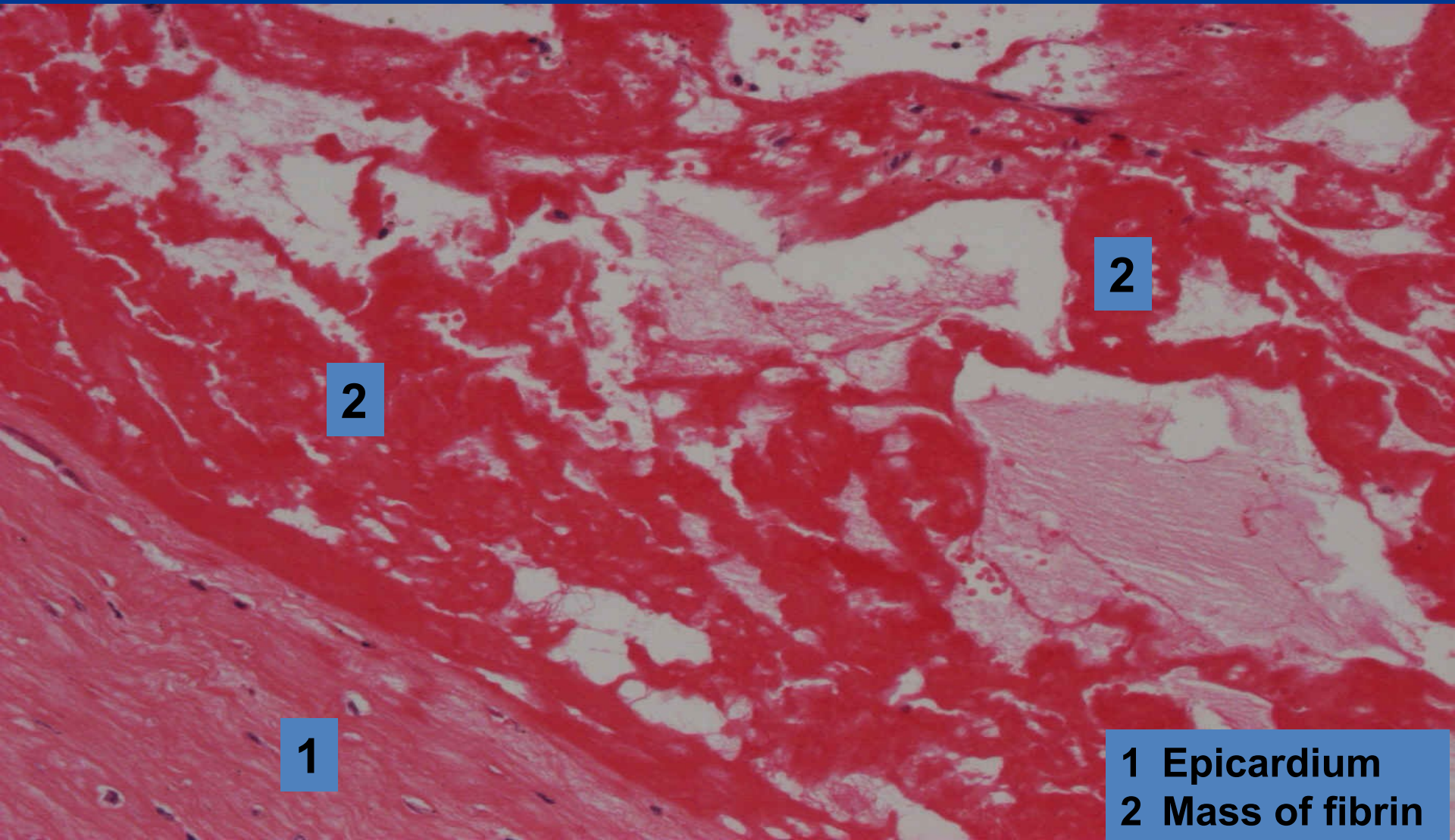
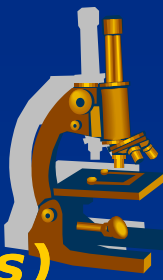
1

3

- 1 Epicardium
- 2 Fibrin
- 3 Myocardium

# ***Fibrinous pericarditis***

***(superficial fibrinous inflammation of serous membranes)***

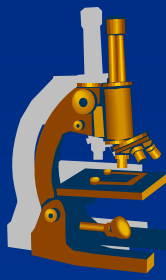


2

2

1

1 Epicardium  
2 Mass of fibrin



# ***Exudative fibrinous mucosal inflammation***

---

Classification due to mucosal damage:

**x croupous**

⇒ *little alteration, plaque is loose on the surface*  
(*croupous pneumonia*)

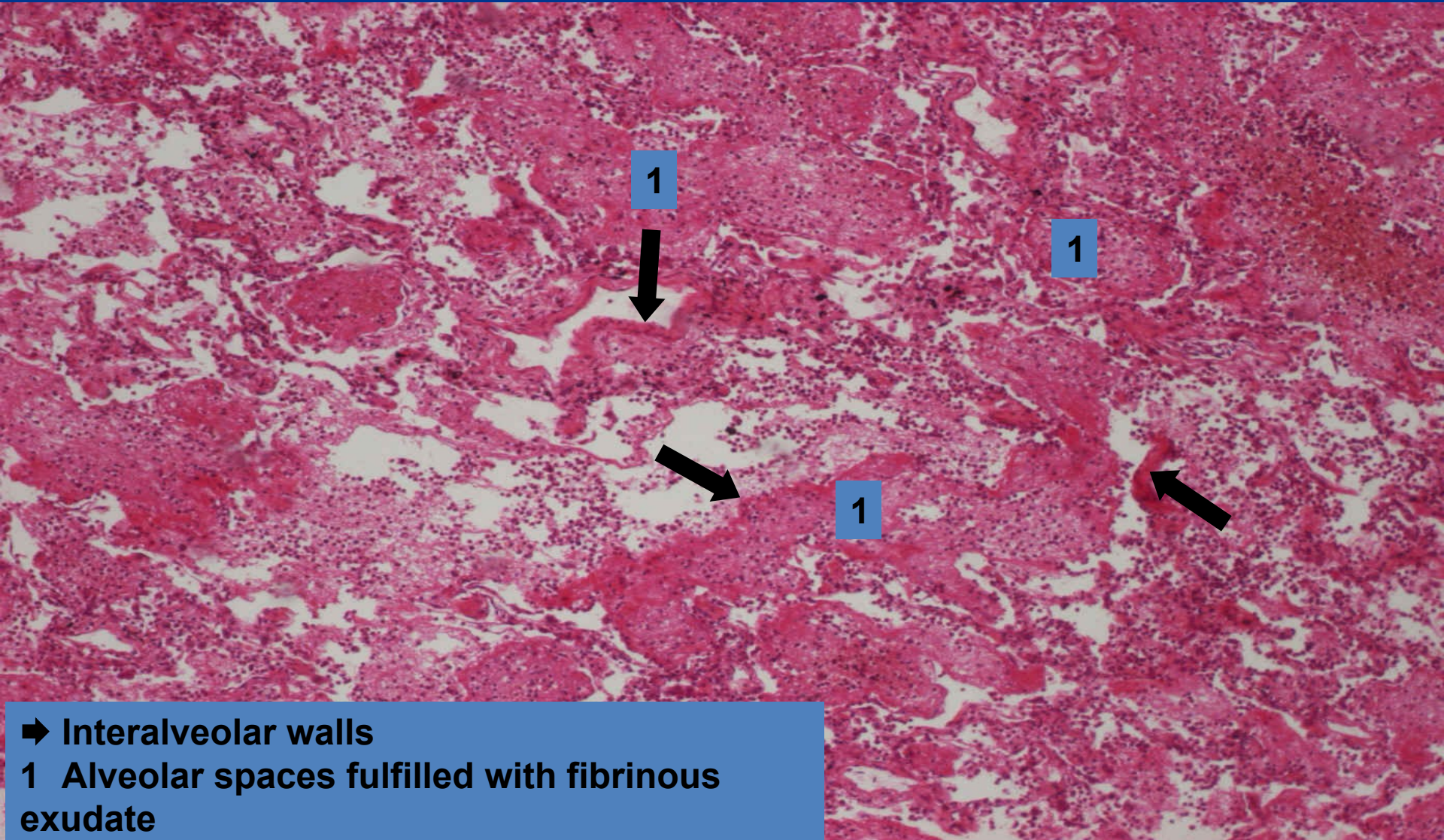
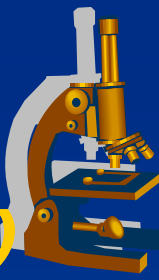
**x diphtheric**

⇒ *deeper mucosal necrosis, after the pseudomembrane is peeled off »*  
*ulcus*  
(*pseudomembranous colitis*)

**x escharotic**

⇒ *extensive deep necrosis*  
(*necrotising tracheitis in flu*)

# ***Lobar pneumonia*** ***(superficial fibrinous mucosal inflammation)***



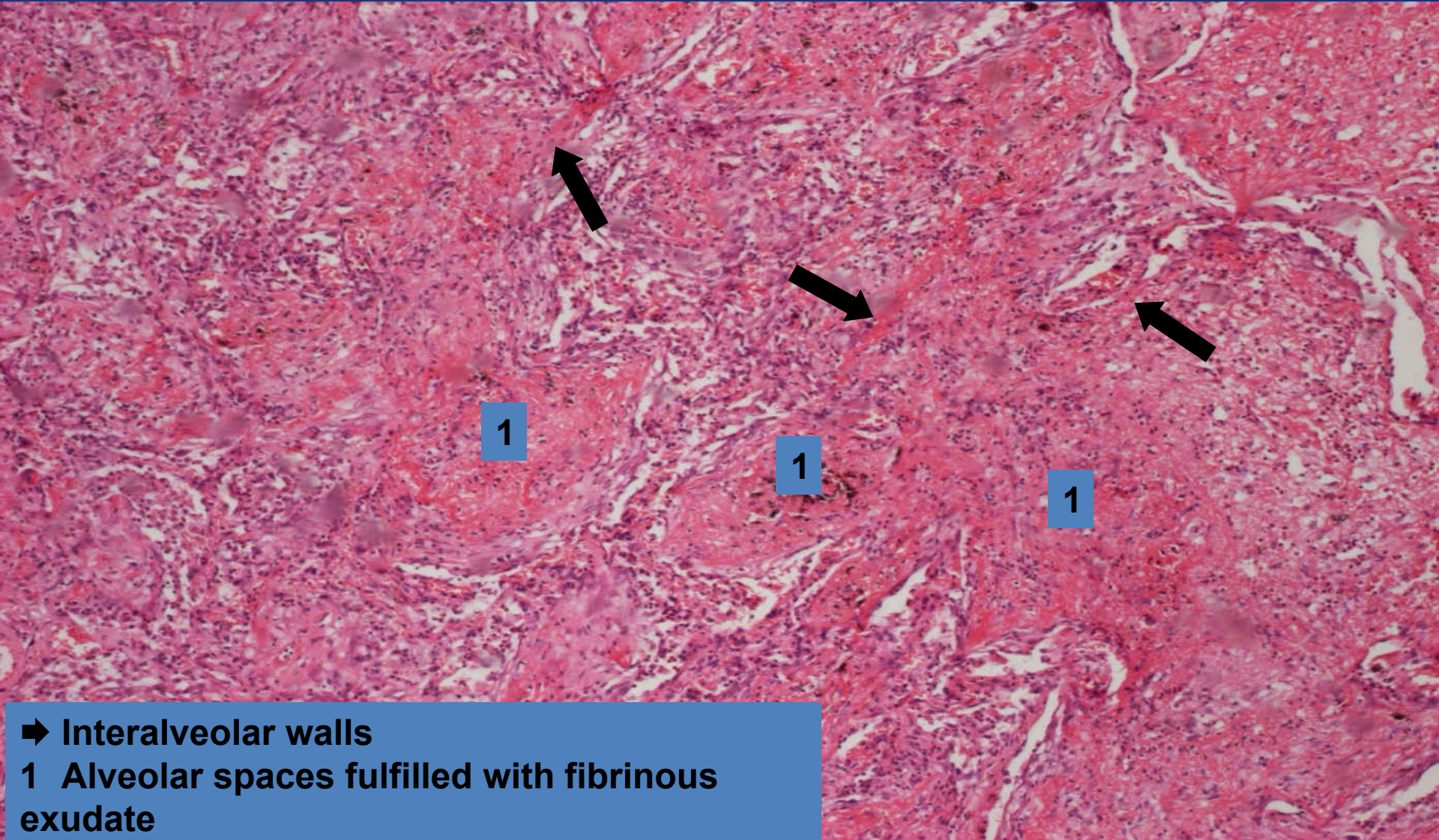
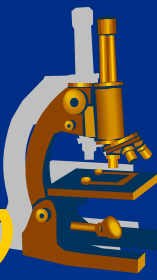
1

1

1

➡ Interalveolar walls  
1 Alveolar spaces fulfilled with fibrinous exudate

# ***Lobar pneumonia*** ***(superficial fibrinous mucosal inflammation)***



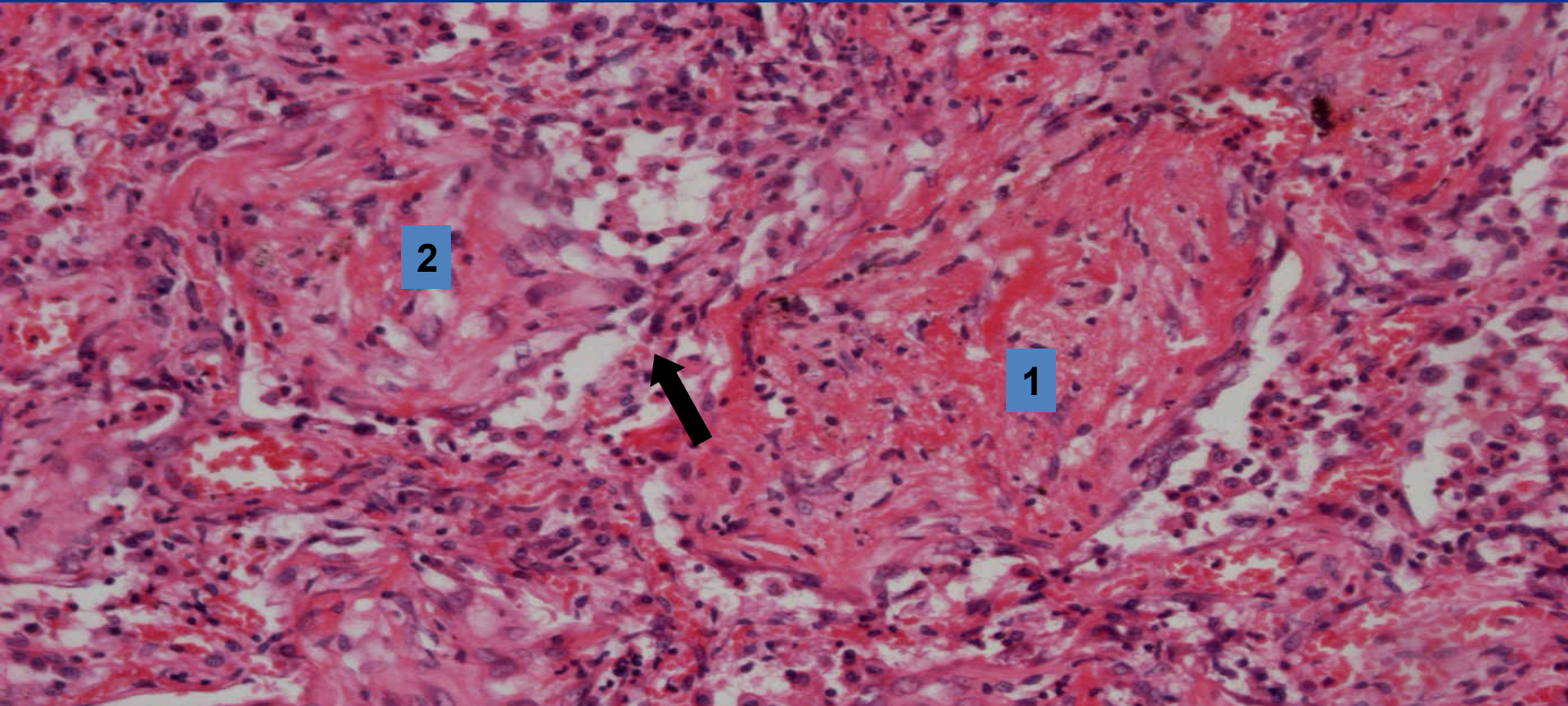
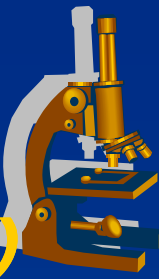
➡ Interalveolar walls

1 Alveolar spaces fulfilled with fibrinous exudate



# ***Lobar pneumonia - detail***

***(superficial fibrinous mucosal inflammation)***



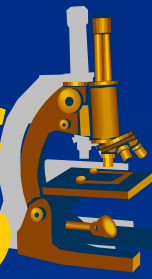
2

1

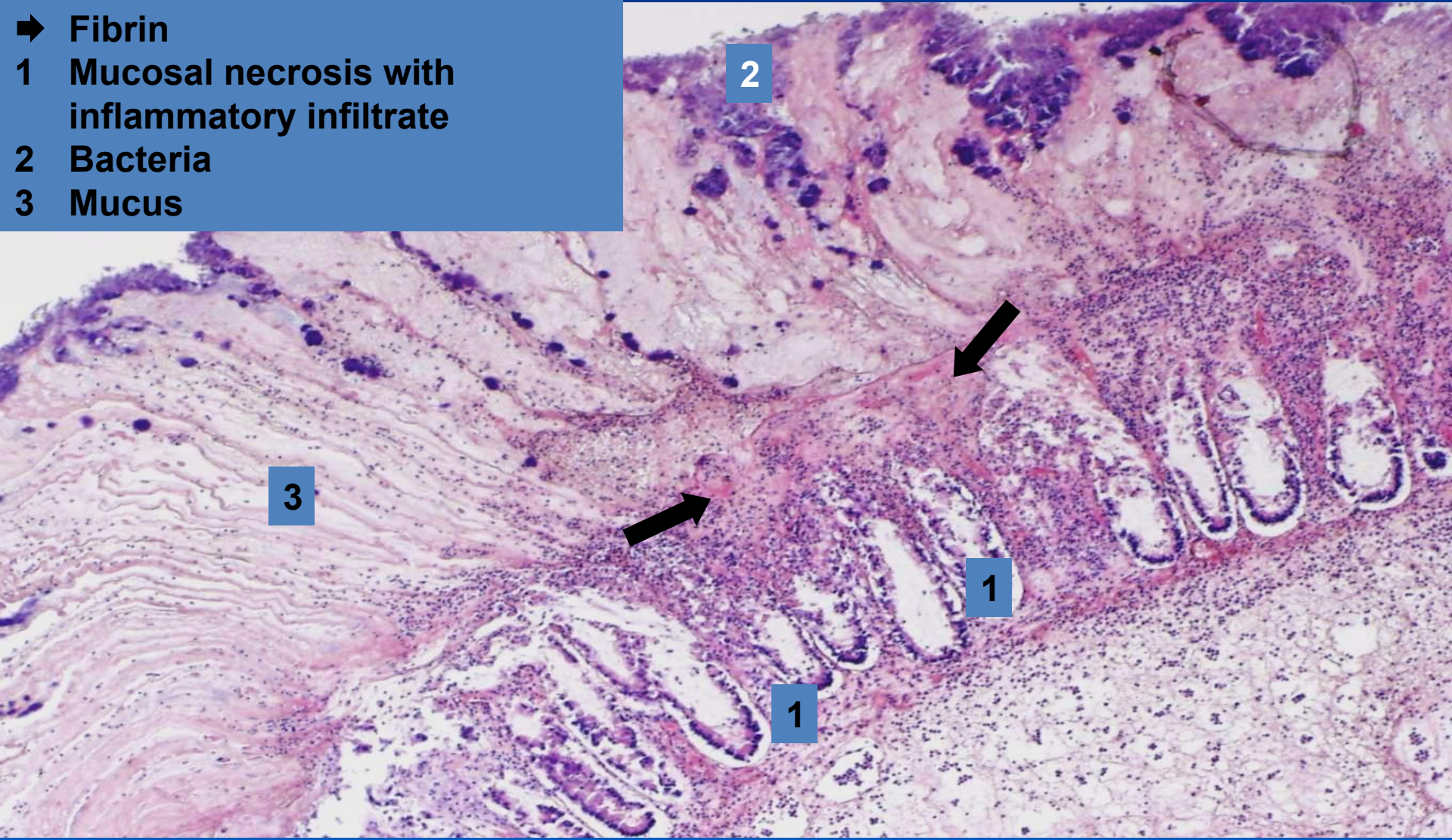


- ➔ Interalveolar wall
- 1 Croupous (fibrinous) exudate
- 2 Fibrinous exudate with fibroblasts (beginning of organization)

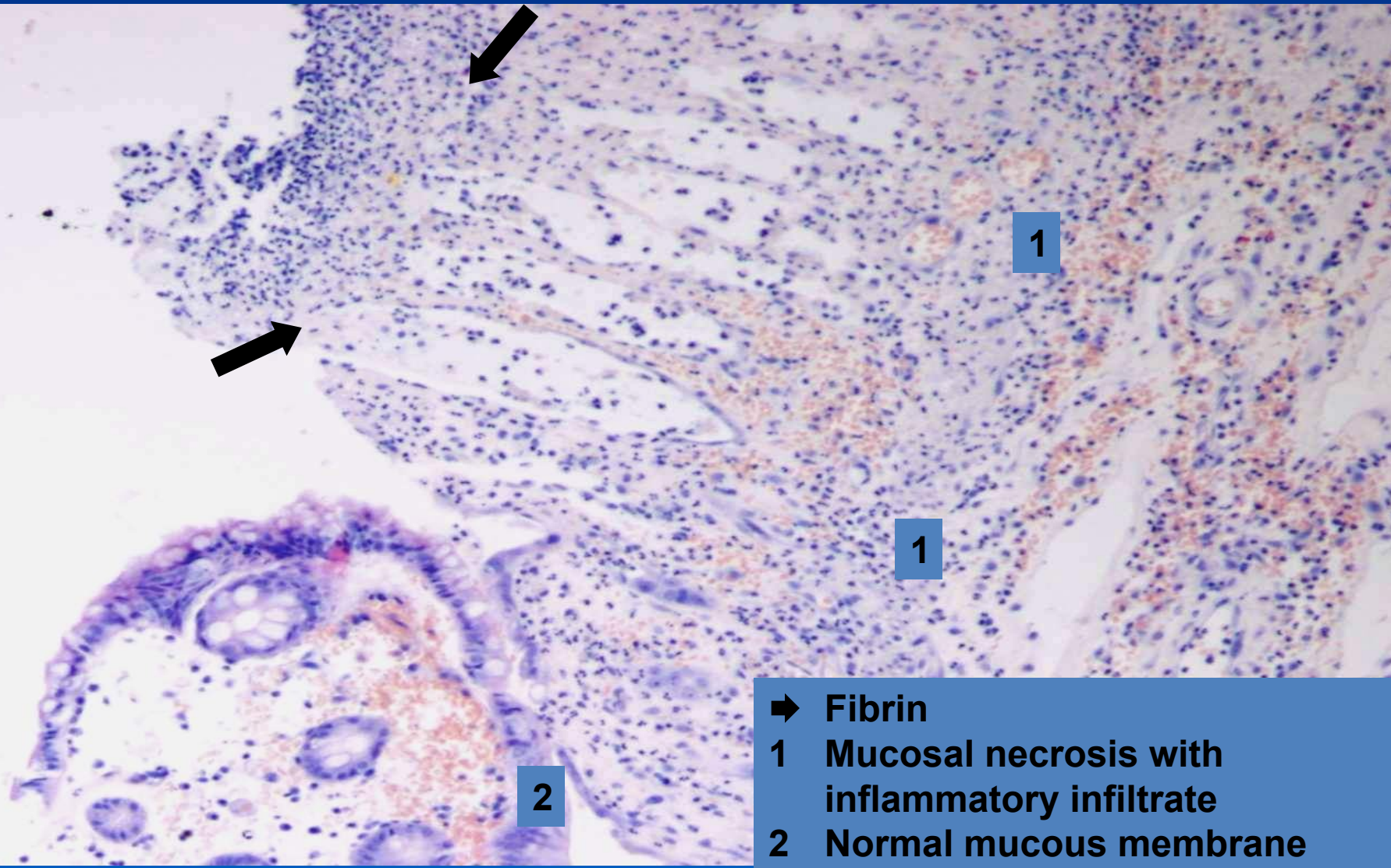
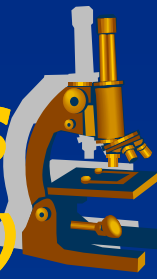
# ***Pseudomembranous colitis*** ***(superficial fibrinous mucosal inflammation)***



- ➔ Fibrin
- 1 Mucosal necrosis with inflammatory infiltrate
- 2 Bacteria
- 3 Mucus



# ***Pseudomembranous colitis*** ***(superficial fibrinous mucosal inflammation)***



- ➔ Fibrin
- 1 Mucosal necrosis with inflammatory infiltrate
- 2 Normal mucous membrane

# *Rheumatic fever*



- ✗ Relapsing inflammatory disease esp. in children (1-5 weeks after streptococcal A infection)
- ✗ forming of antibodies cross-reactive with antigens in the heart, joints...
- ✗ dg. based on anamnesis and 2 of 5 main (Jones) criteria:  
*erythema marginatum, chorea, carditis, subcutaneous nodules, migratory polyarthrititis of the large joints*

# Rheumatic fever



## xGROSS:

- ⇒ **vegetations** - (friable, bulky, wart-like outgrowths) on the edges of the heart valves (mainly aortic and mitral)
- ⇒ after years leaflet thickening and commissural fusion
- ⇒ thickening, shortening and fusion of the chordae tendinae

## xMICRO:

- ⇒ **Aschoff bodies** – inflammatory lesion within the heart
- ⇒ fibrinoid necrosis of fibrous tissue
- ⇒ central zone of degenerating with surrounding chronic inflammatory infiltrate (lymphocytes, plasma cells, histiocytes, activated macrophages called Antischkow cells)

# *Exudative inflammation*



## **x** purulent:

⇒ **PRODUCTION OF PUS:**

*neutrophil-rich exudate*

⇒ **GROSS:**

*superficial pus, pus accumulation (abscess)*

⇒ *heals by inhibition of exudation and/or by proliferative inflammation*

⇒ **examples:**

- **superficial inflammation of meninges:**
  - purulent meningitis
- **superficial mucosal inflammation:**
  - catarrhal-purulent bronchopneumonia
- **deep (interstitial):**
  - phlegmona (e.g. phlegmonous appendicitis)
  - abscess

# Purulent leptomeningitis



## Aetiology:

- ✗ *Escherichia coli* and  $\beta$  streptococci
  - ⇒ *in newborns*
- ✗ *Haemophilus influenzae*
  - ⇒ *in infants and children*
- ✗ *Neisseria meningitis*
  - ⇒ *in adolescents and young adults*
- ✗ *Streptococcus pneumoniae* and *Listeria monocytogenes*
  - ⇒ *in old people*

# ***Purulent leptomeningitis***



## **SYMPTOMS:**

### **x meningeal irritation:**

⇒ *headache, photophobia, irritation, nuchal rigidity, consciousness failures*

### **x lumbar puncture:**

⇒ *opaque or purulent liquor with higher CSF pressure*



# ***Purulent leptomeningitis*** **MORPHOLOGY**



## **x GROSS:**

- ⇒ *congested and leaked pia mater with pus*
- ⇒ *purulent-opaque liquor*

## **x MICRO:**

- ⇒ *meninges infiltrated with neutrophils*
- ⇒ *vessels congested with blood, thrombosis » hemorrhagic brain infarction*

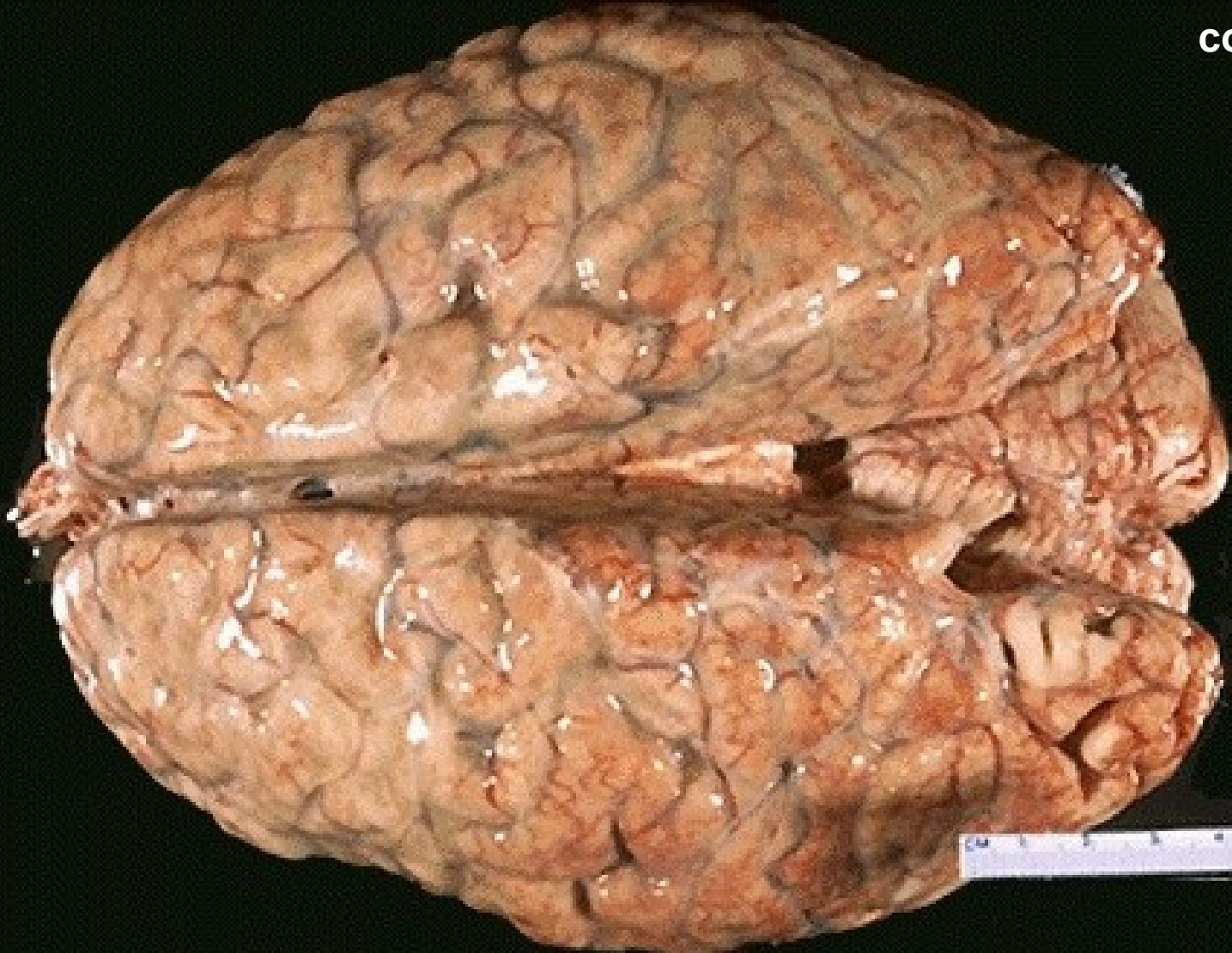## **x COMPLICATIONS:**

*possible fibrosis of meninges resulting in hydrocephalus;  
epilepsy*

# ***Purulent leptomeningitis*** ***(superficial purulent inflammation)***

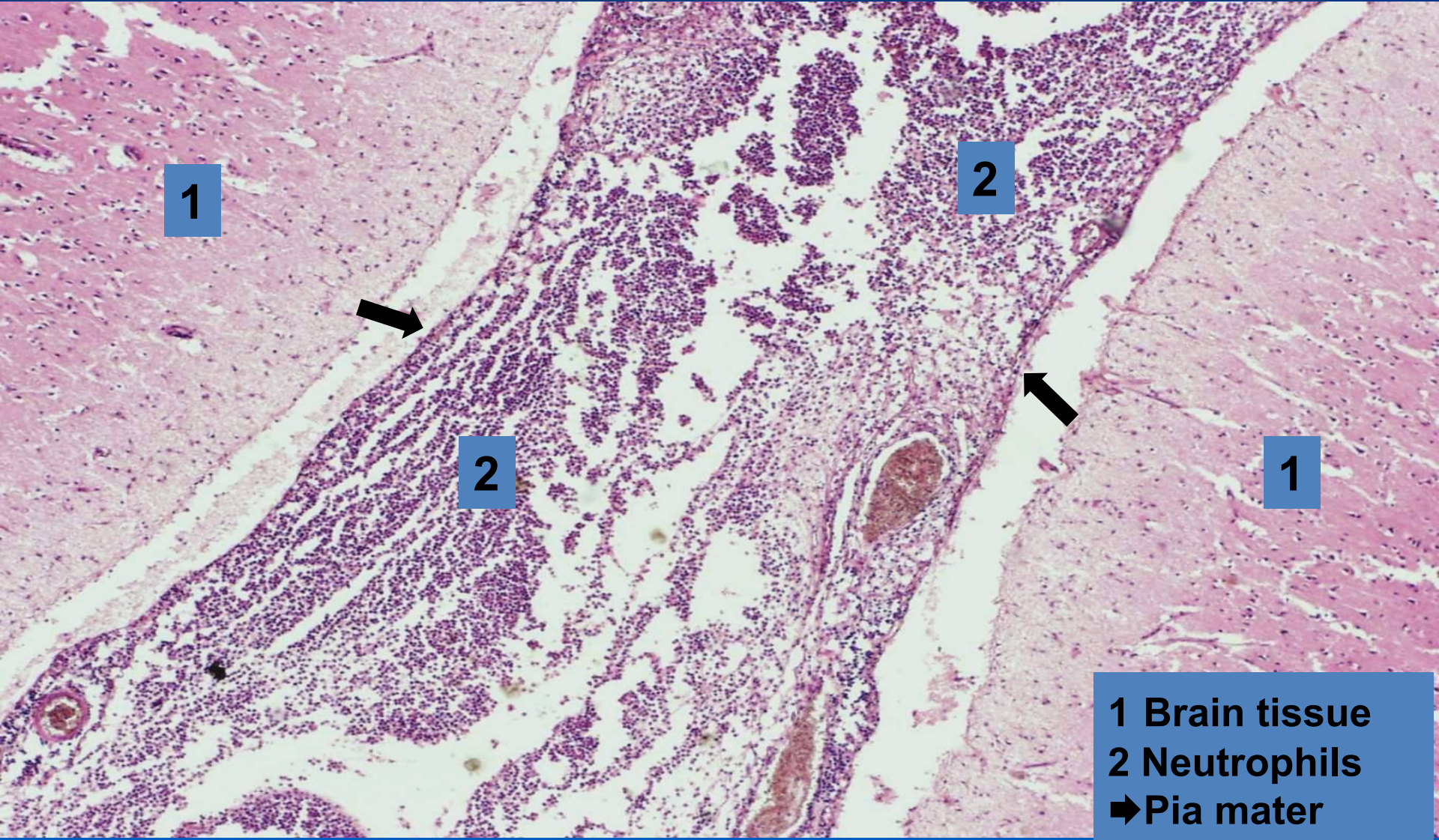


copy



# ***Purulent leptomeningitis***

***(superficial purulent inflammation)***



1

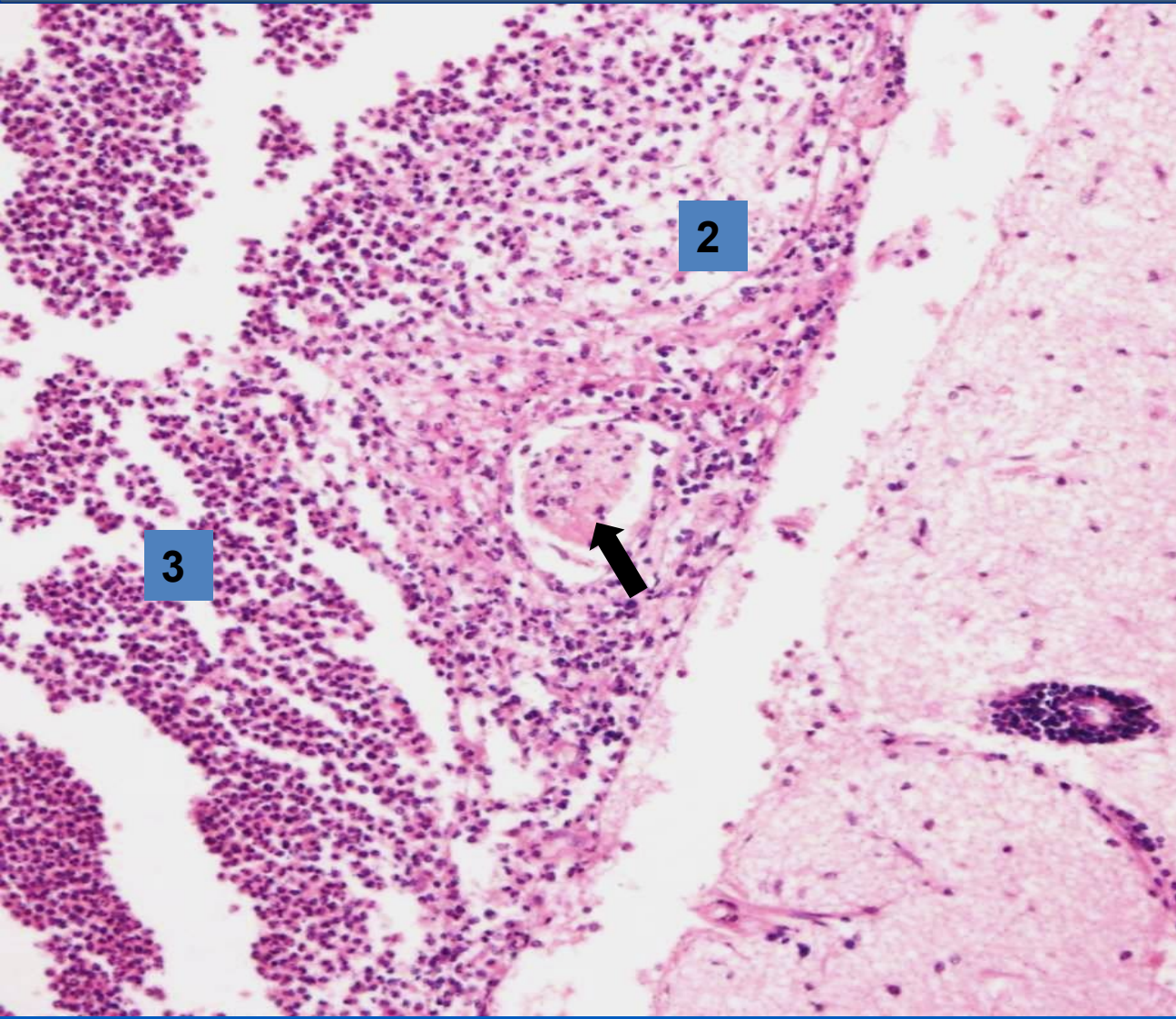
2

2

1

1 Brain tissue  
2 Neutrophils  
➔ Pia mater

# ***Purulent leptomeningitis*** ***(superficial purulent inflammation - detail)***



- 1 Brain cortex
- 2 Pia mater with purulent infiltrate
- 3 Neutrophils
- ➔ Arteriole in pia mater

2

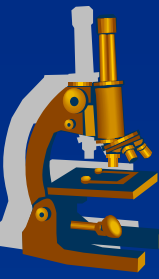
3

1

# ***Bronchopneumonia***

***(Superficial purulent mucosal inflammation)***

---



## **x GROSS:**

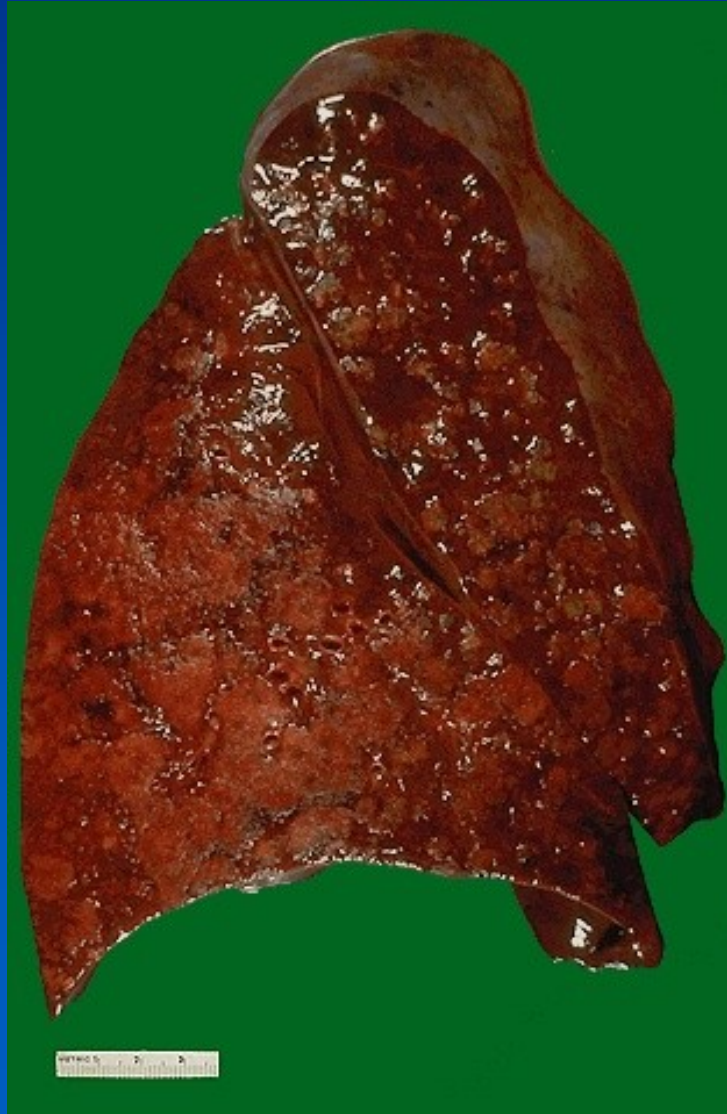⇒ *various stages of inflammation in the lung at the same time*

## **x MICRO:**

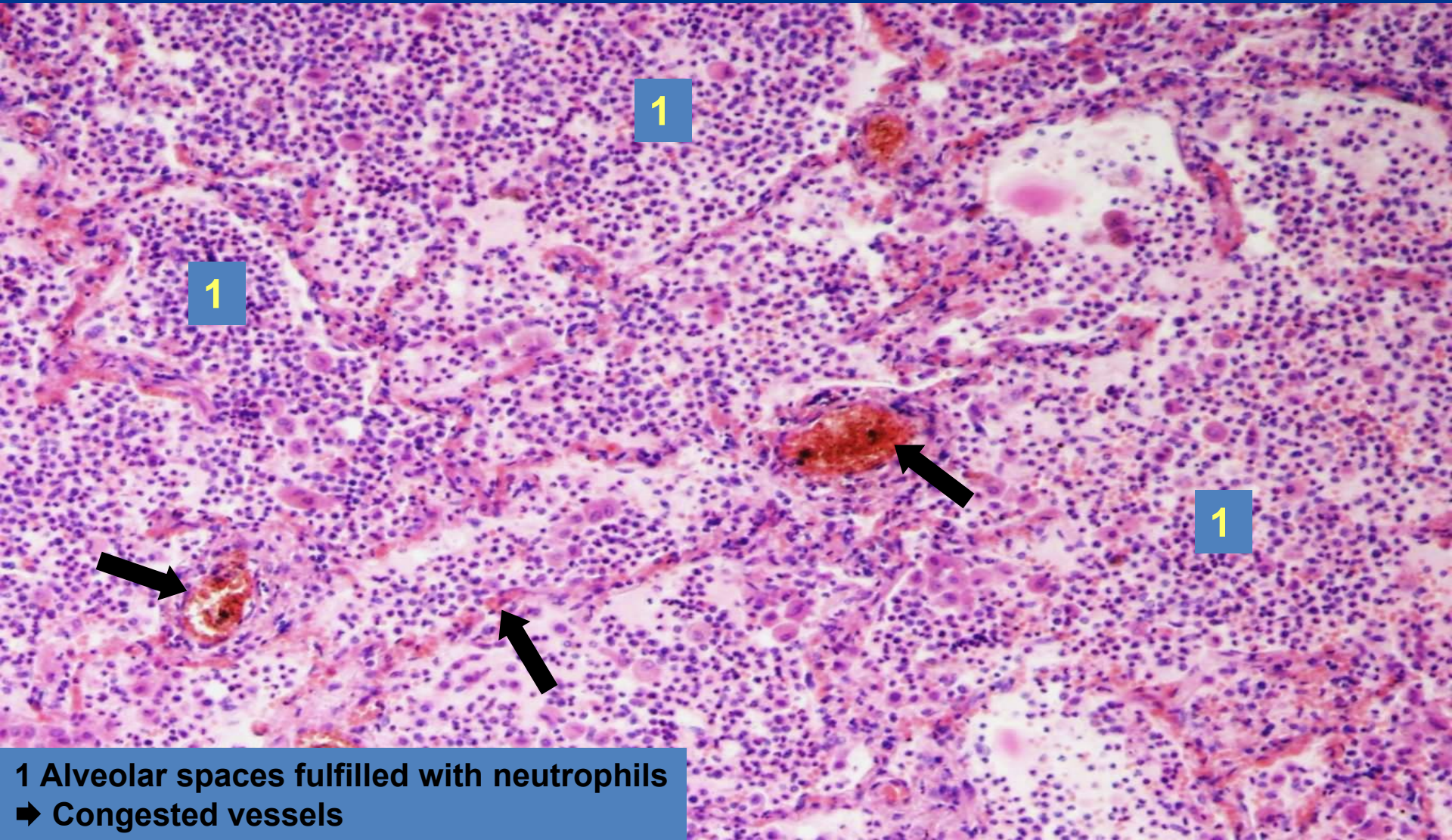
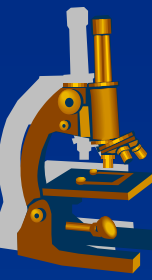
⇒ *alveolar spaces fulfilled with neutrophils*

⇒ *small amount of fibrin in the exudate compared to lobar pneumonia*

# *Bronchopneumonia*



# ***Purulent bronchopneumonia*** ***(superficial purulent mucosal inflammation)***



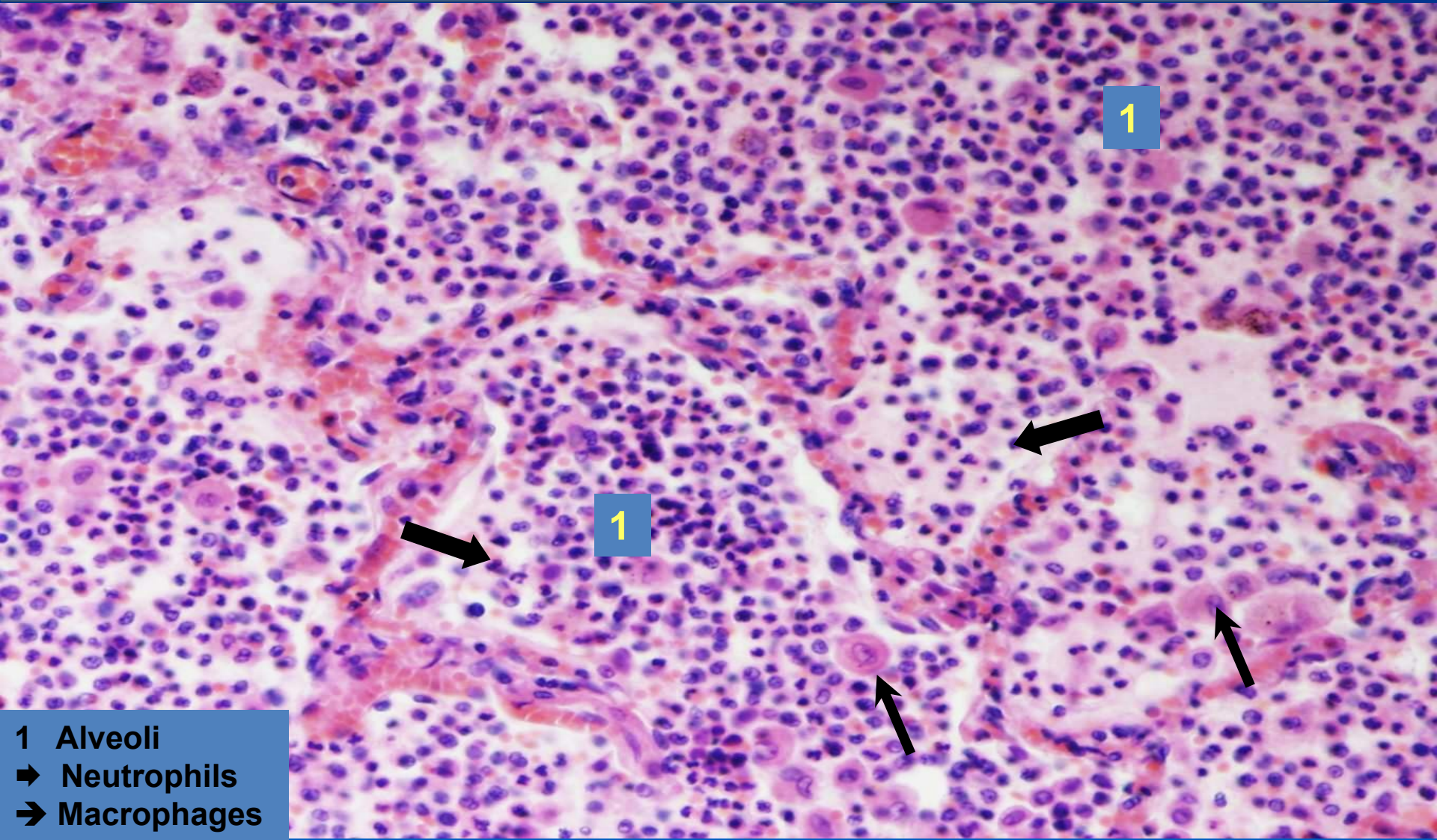
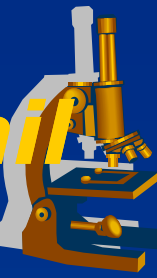
1

1

1

1 Alveolar spaces fulfilled with neutrophils  
➔ Congested vessels

# ***Purulent bronchopneumonia - detail*** ***(superficial purulent mucosal inflammation)***



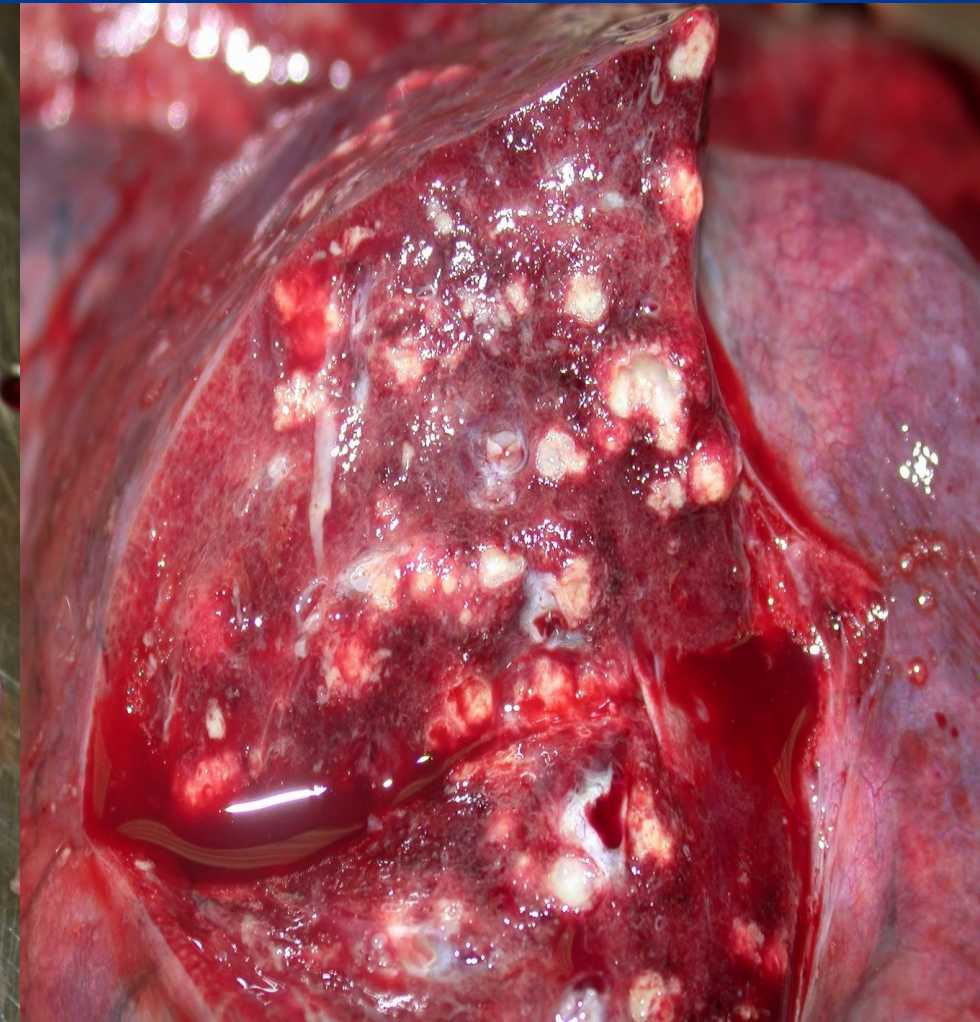
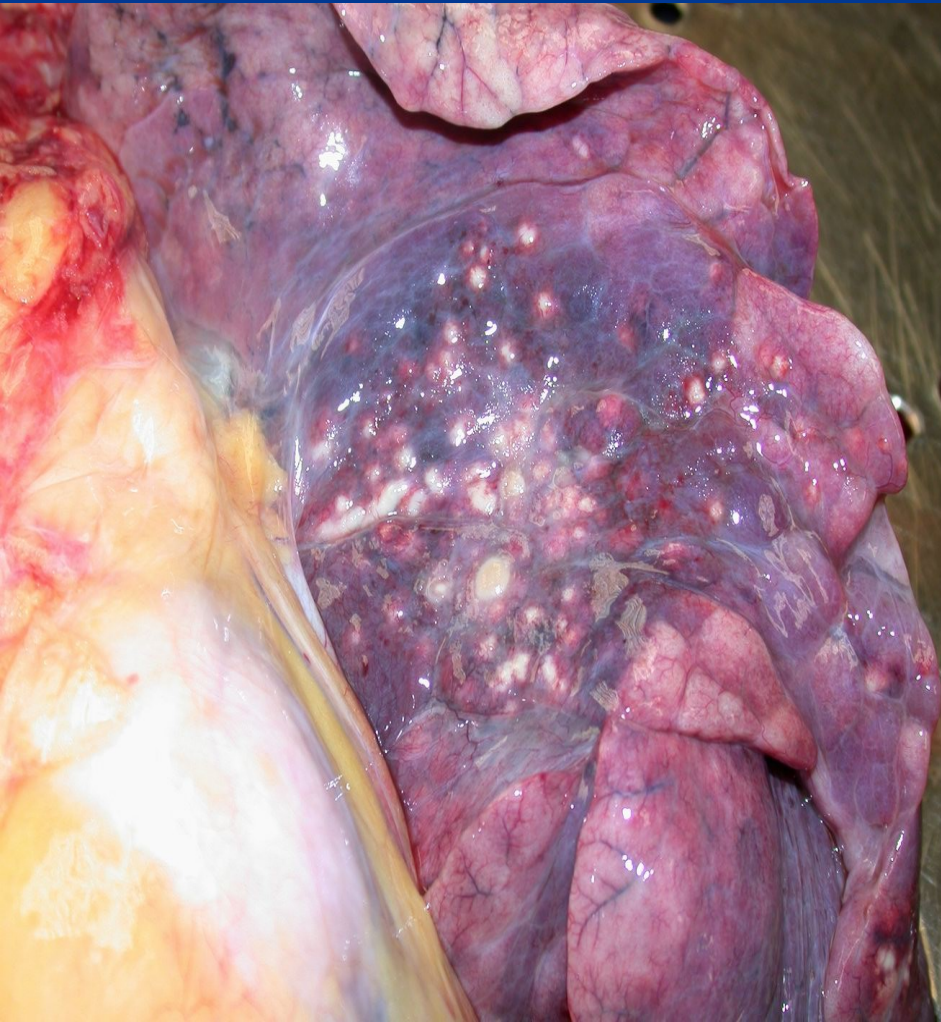1

1

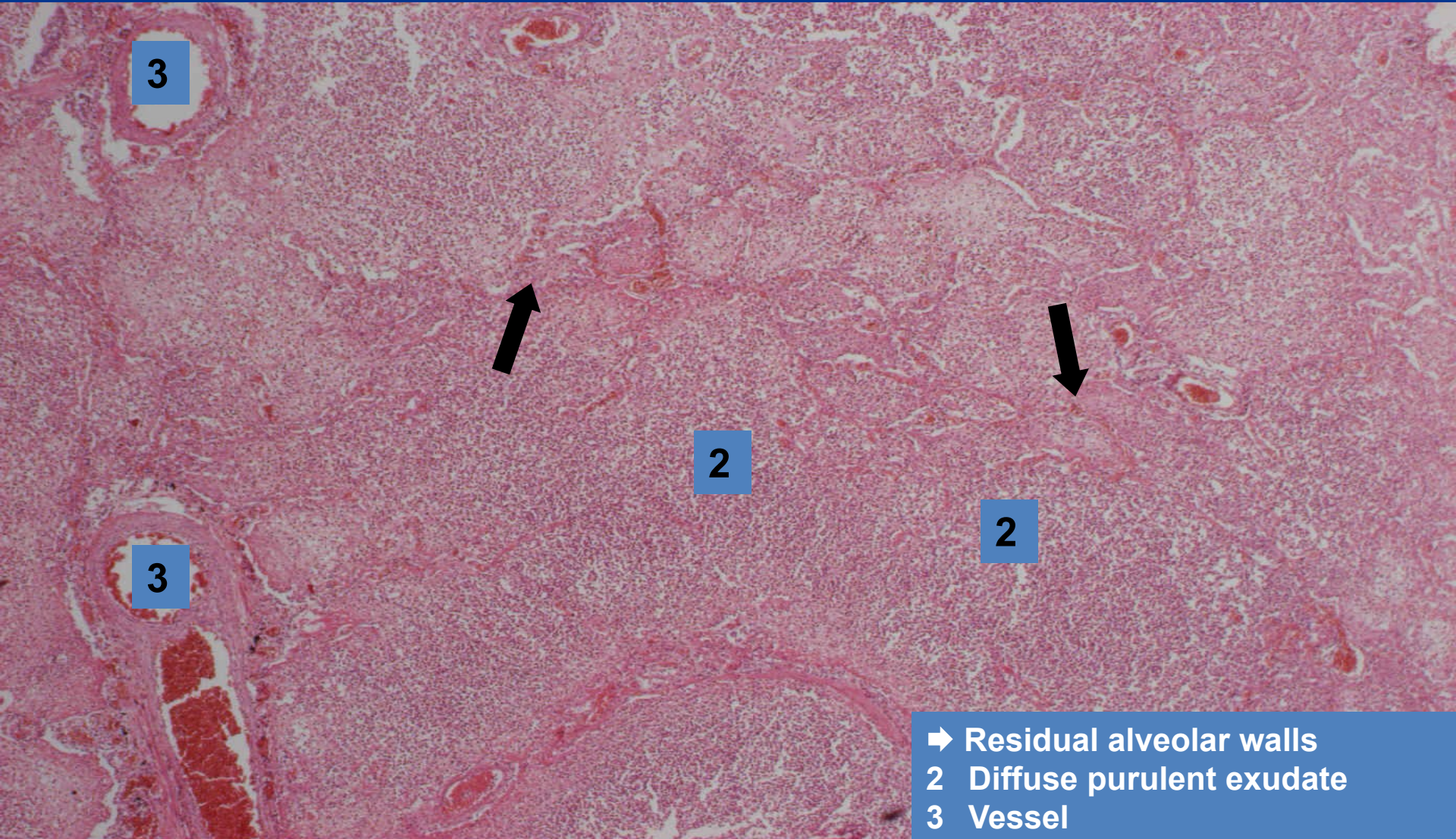
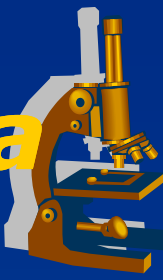- 1 Alveoli
- ➔ Neutrophils
- ➔ Macrophages



# ***Abscessing bronchopneumonia*** ***(abscessing purulent inflammation)***

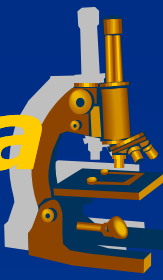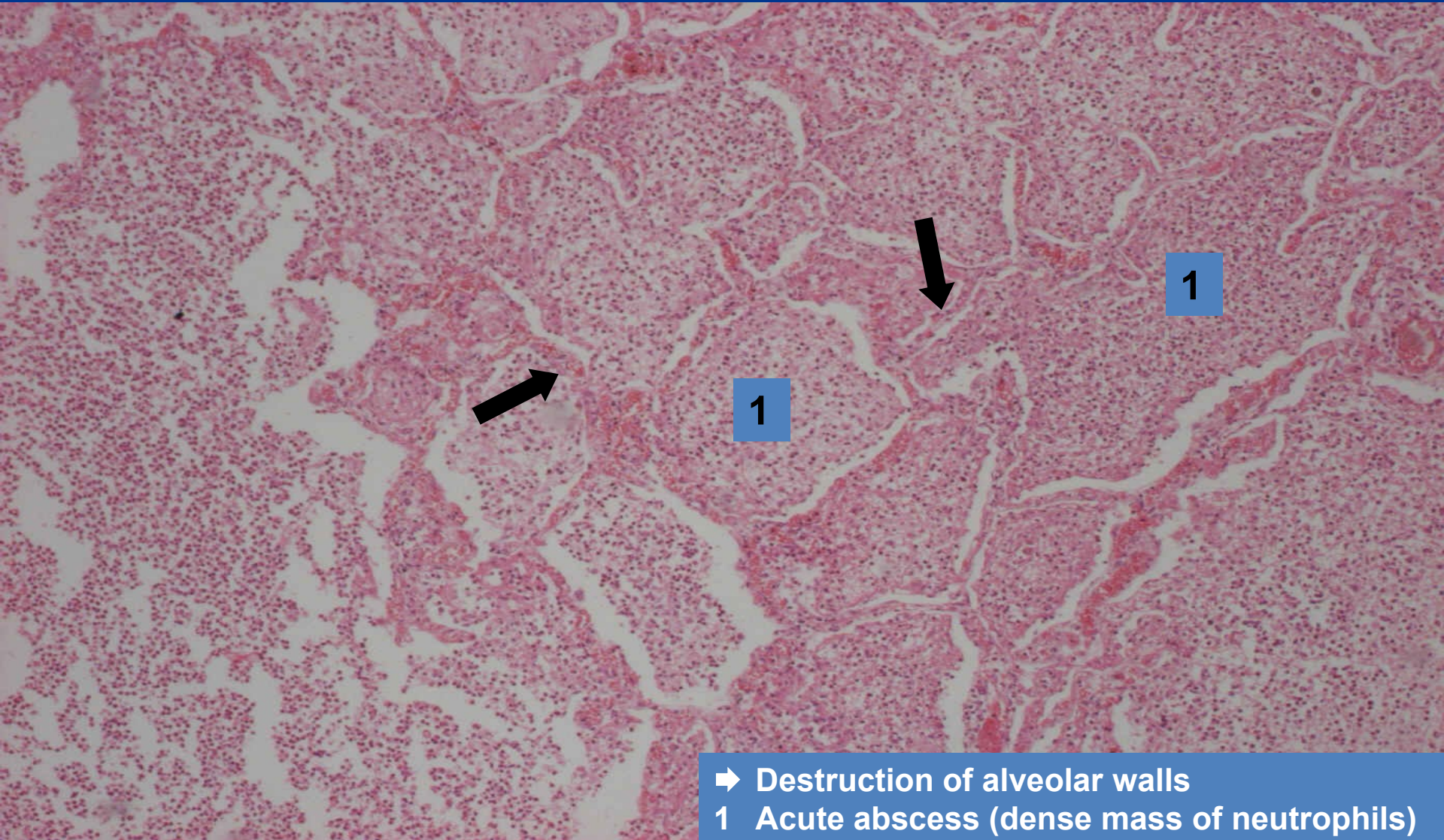


# ***Abscessing bronchopneumonia*** ***(abscessing purulent inflammation)***



- ➔ Residual alveolar walls
- 2 Diffuse purulent exudate
- 3 Vessel

# ***Abscessing bronchopneumonia*** ***(abscessing purulent inflammation)***



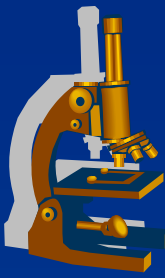
- ➔ Destruction of alveolar walls
- 1 Acute abscess (dense mass of neutrophils)

# ***Phlegmonous appendicitis*** ***(interstitial purulent inflammation)***



- x** most common cause of „acute abdomen“, surgical intervention necessary.
- x** **CLINICALLY:**
  - ⇒ *in any age, commonly children – young adults.*
  - ⇒ *right mesogastric or hypogastric pain; nausea, vomiting, rectal raised temperature, sensitive abdomen, leukocytosis.*

# *Phlegmonous appendicitis*



## **x MORPHOLOGY:**

### ⇒ **GROSS:**

- hyperemic serosa, hemorrhage, pus.

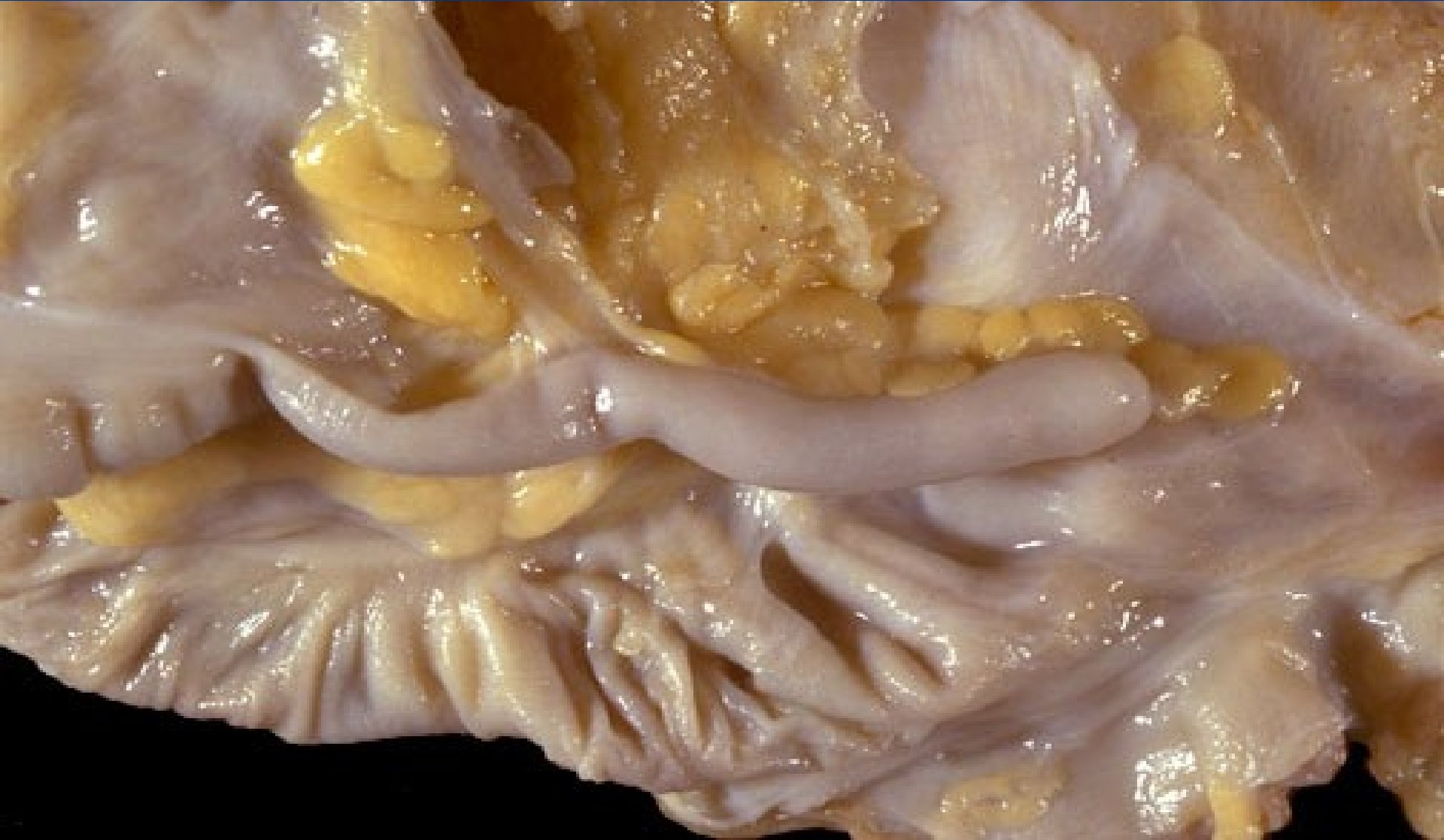### ⇒ **MICRO:**

- diffuse interstitial neutrophilic infiltration (phlegmona), purulent periappendicitis.

## **x COMPLICATIONS:**

- ⇒ *perforation, purulent peritonitis, pyelophlebitis, portal thrombosis, pyemia, liver abscessi, sepsis.*

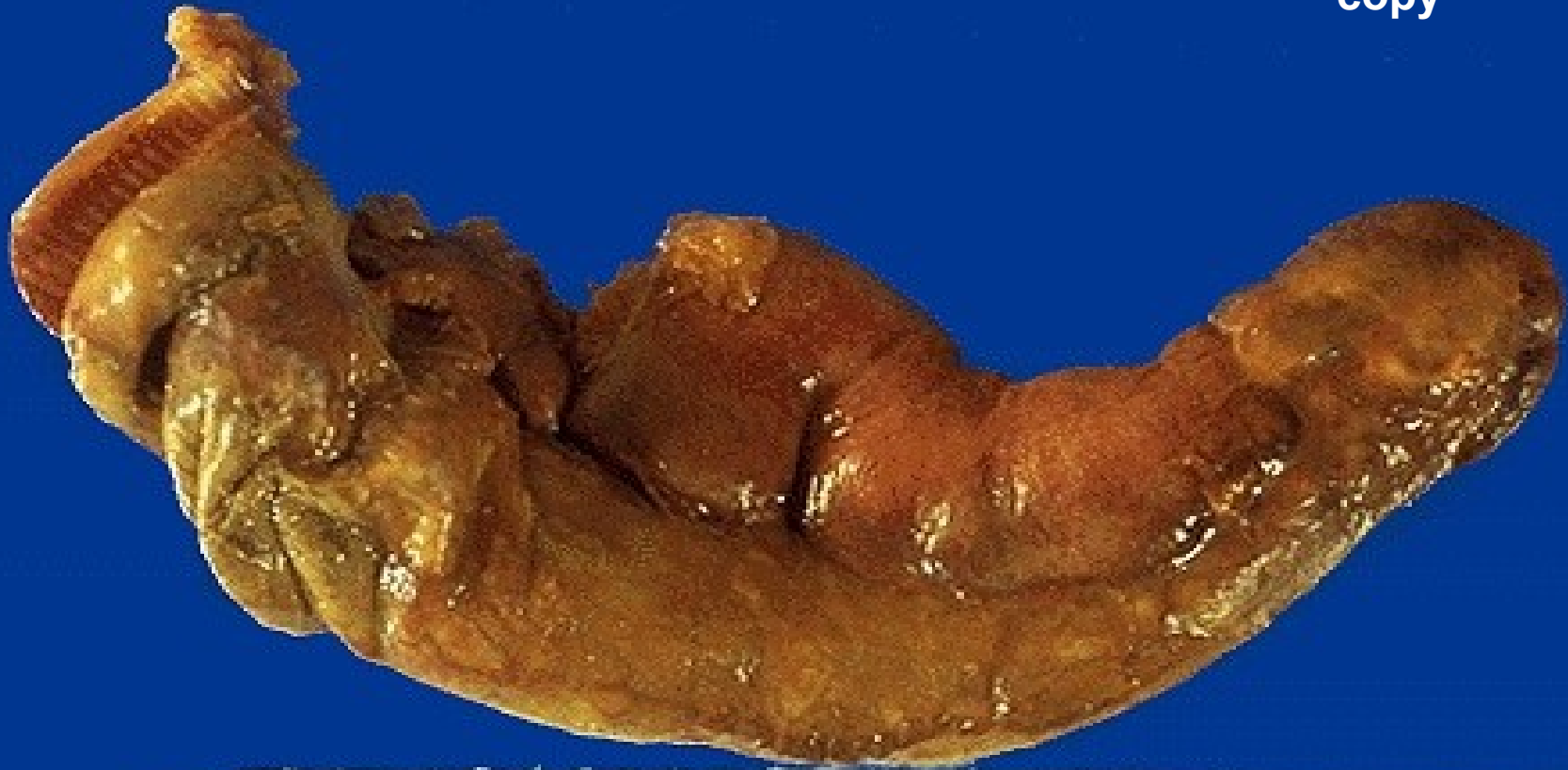# ***Appendix - normal***



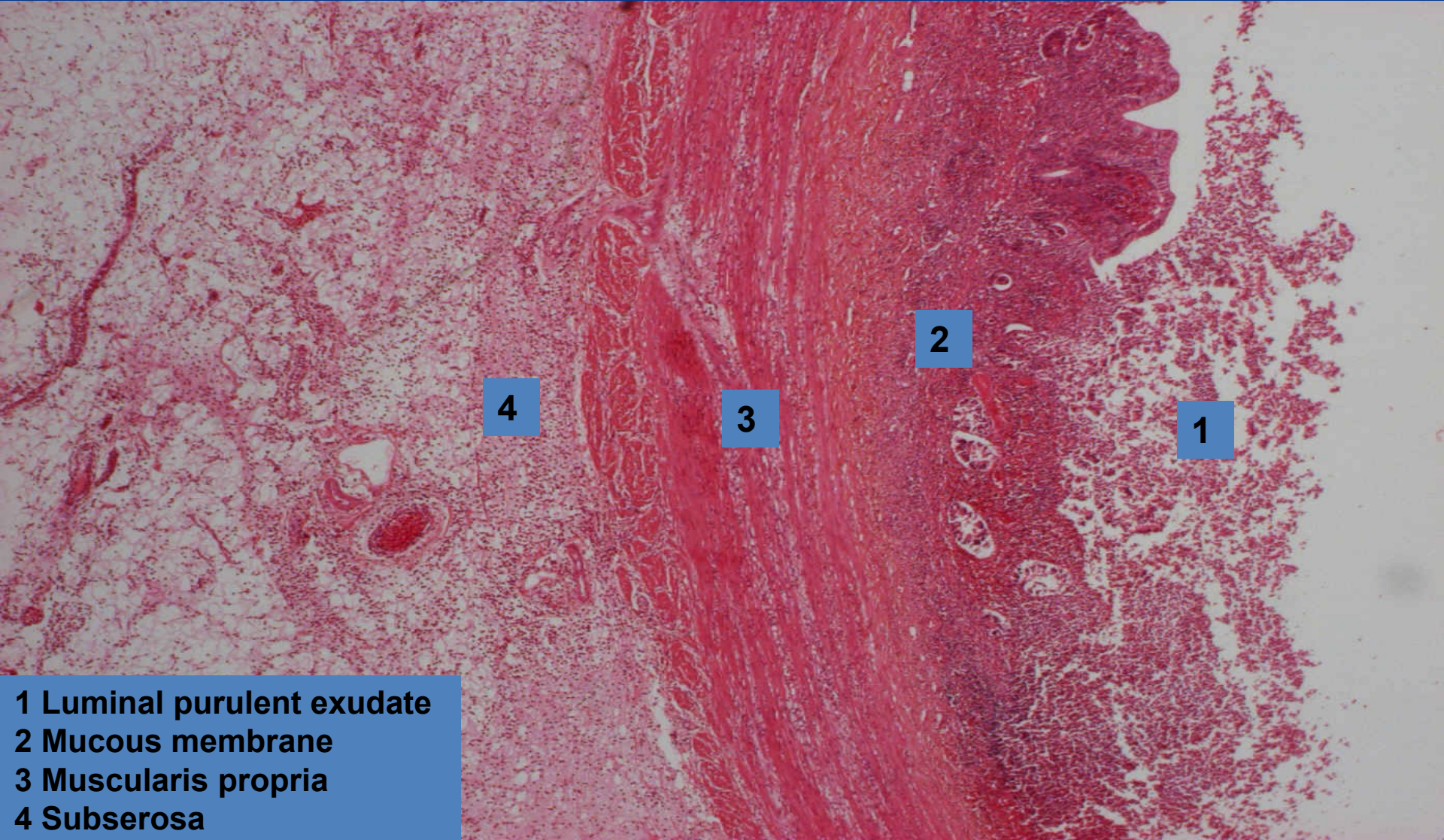
# *Phlegmonous appendicitis* (*interstitial purulent inflammation*)



copy



# ***Phlegmonous appendicitis*** ***(interstitial purulent inflammation)***



4

3

2

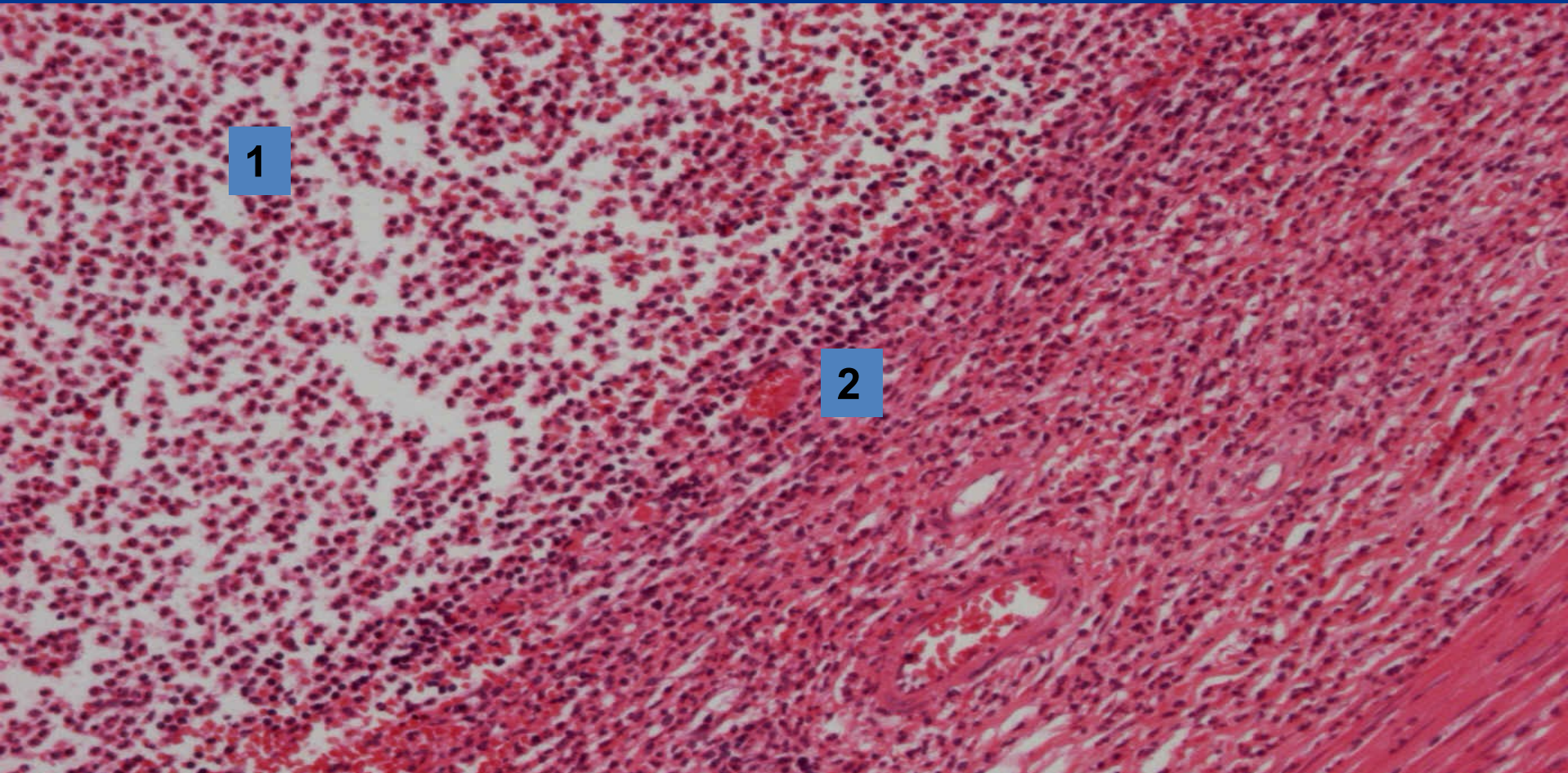
1

- 1 Luminal purulent exudate
- 2 Mucous membrane
- 3 Muscularis propria
- 4 Subserosa



# *Phlegmonous appendicitis*

*(interstitial purulent inflammation)*



1

2

3

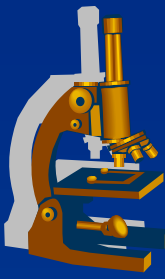
- 1 Luminal purulent exudate
- 2 Mucosa with diffuse neutrophilic infiltration – absence of epithelium
- 3 Muscularis propria

# *Acute pyelonephritis*



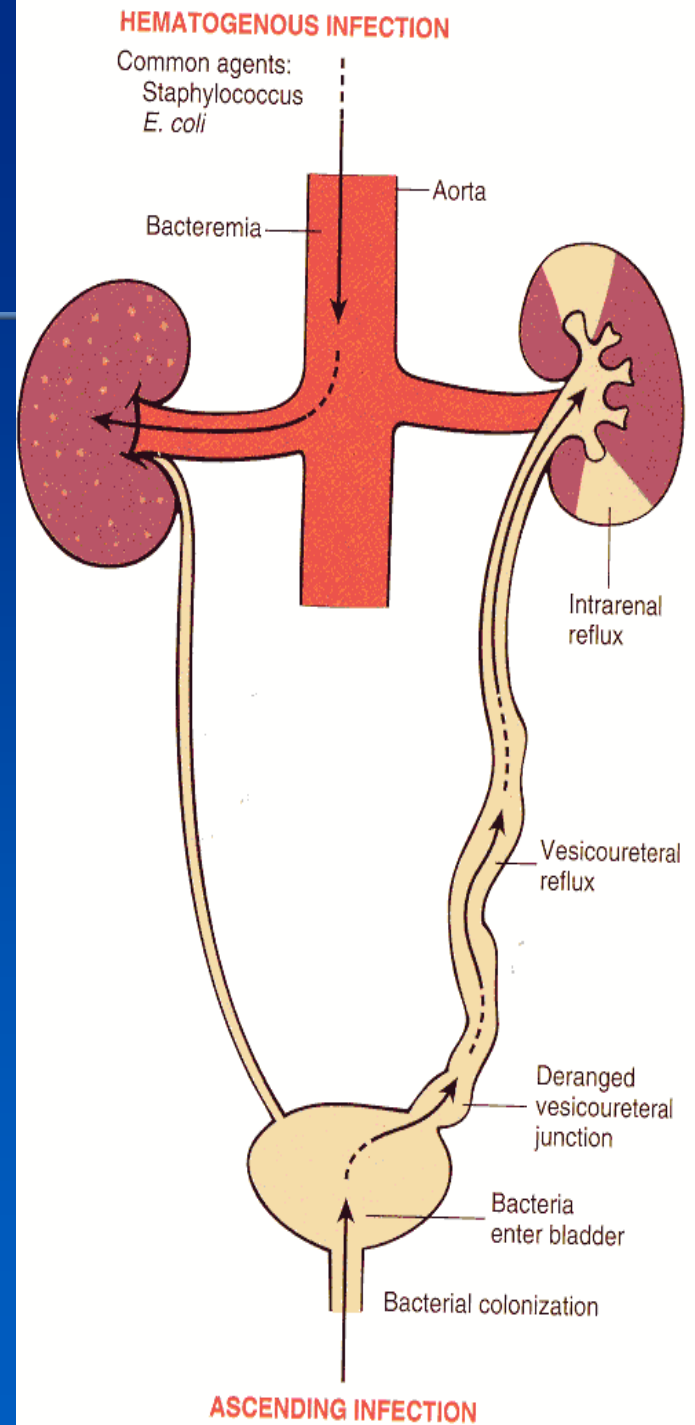
- ✗ Common purulent renal inflammation, bacterial infection by *Escherichia coli*, *Proteus*, *Klebsiella*, *Enterobacter*
- ✗ **Ascending** infection by urine reflux in urinary tract inflammation
- ✗ **Descending (haematogenous)** infection in septicaemia, rare

# Acute pyelonephritis

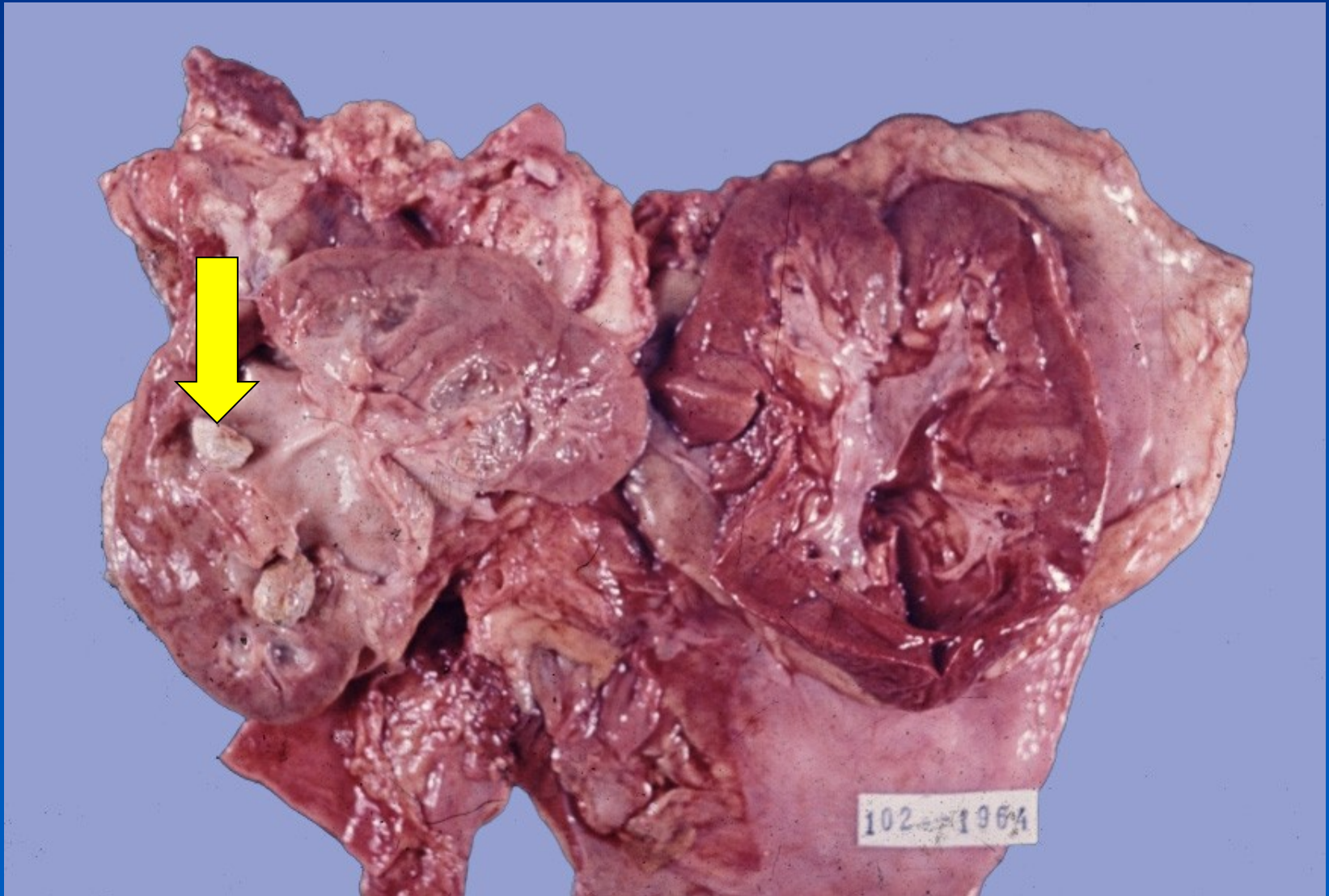


- ✗ Facilitated by DM, gout, all causes of obstructive uropathy (e.g. nephrolithiasis, tumors, urinary tract anomalies incl. vesicoureteric and intrarenal reflux)
- ✗ Instrumental interventions (cathetrization, cystoscopy)
- ✗ GROSS:
  - ⇒ *enlarged kidney, cortical and medullary abscesses*
- ✗ MICRO:
  - ⇒ *purulent neutrophilic exudate in tubules and interstitium, oedema*

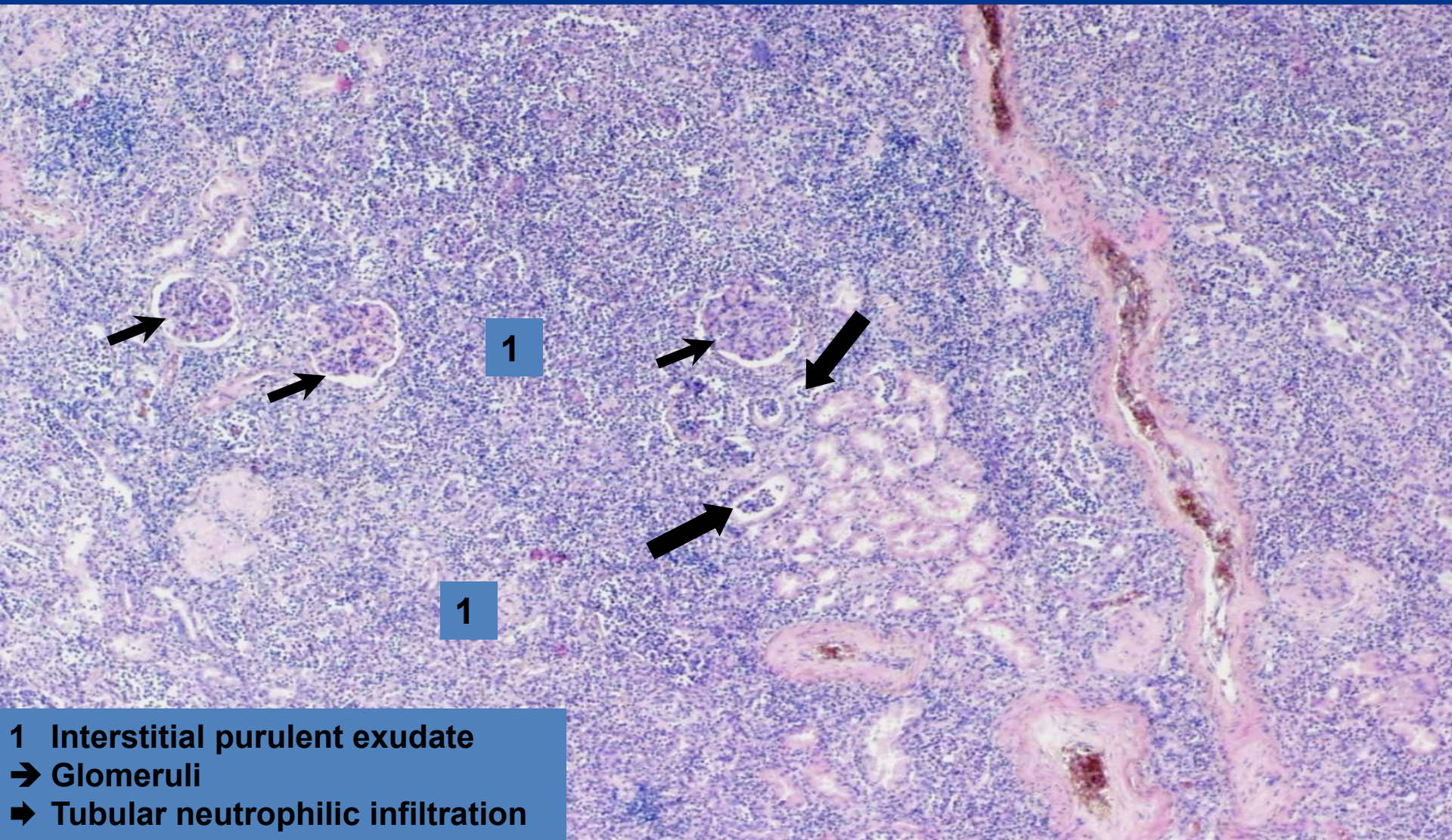
# Acute pyelonephritis



# *Acute pyelonephritis with nephrolithiasis*



# ***Purulent pyelonephritis*** ***(interstitial purulent inflammation)***

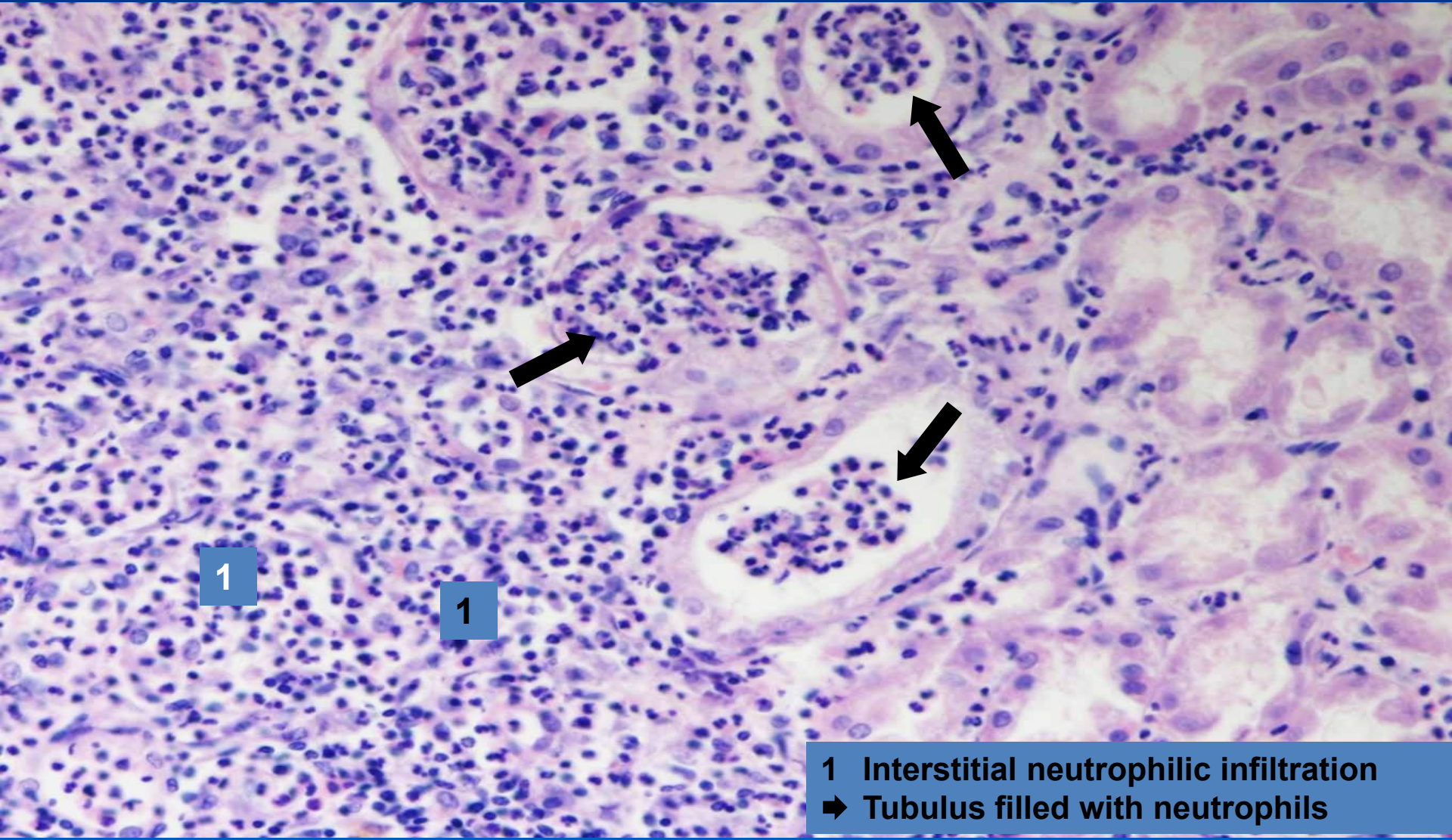


1

1

- 1 Interstitial purulent exudate
- ➔ Glomeruli
- ➔ Tubular neutrophilic infiltration

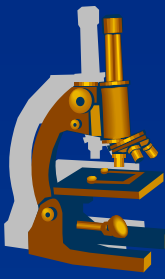
# ***Purulent pyelonephritis*** ***(interstitial purulent inflammation)***



- 1 Interstitial neutrophilic infiltration
- ➔ Tubulus filled with neutrophils

# ***Exudative inflammation***

---



**x** gangrenous:

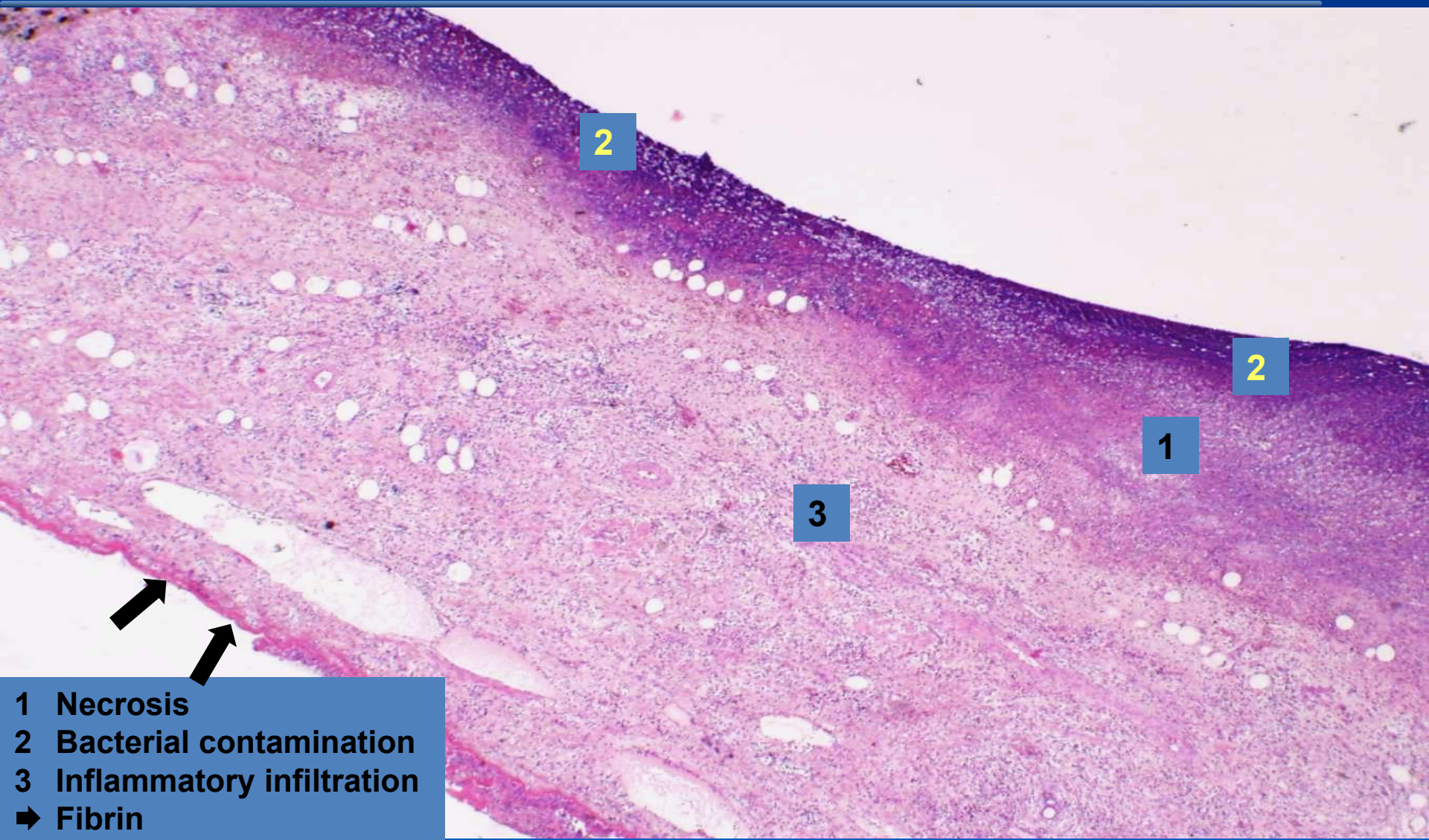
⇒ ***necrosis modified with putrid bacteria***

⇒ ***examples:***

- gangrenous cholecystitis

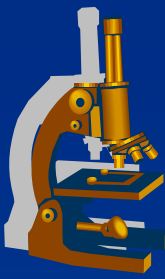


# ***Gangrenous cholecystitis*** ***(gangrenous inflammation)***



- 1 Necrosis
- 2 Bacterial contamination
- 3 Inflammatory infiltration
- ➔ Fibrin

# *Exudative inflammation*



✗ non-purulent:

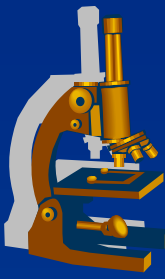
⇒ *exudate made by **chronic inflammatory cells***

*(lymphocytes, plasma cells = mononuclear inflammatory infiltration)*

⇒ *examples:*

- interstitial pneumonia
- Hashimoto`s lymphocytic thyreoiditis

# Primary (atypical) interstitial pneumonia



## x etiology:

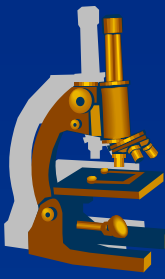
- ⇒ *viral (influenza A, B; RSV, adenoviruses, rhinoviruses, HSV, CMV)*
- ⇒ *small bacteria (Mycoplasma pneumoniae)*
- ⇒ *fungi (Pneumocystis carinii).*

## x symptoms:

- ⇒ *fever, dyspnoea, dry cough, auscultation may be normal (empty alveoli), x massive changes on X-ray*

## x possible in normal hosts, more common in immunosuppressed

# ***Primary (atypical) interstitial pneumonia***



## **x GROSS:**

⇒ *focal or diffuse regions of hyperaemia, in fulminant cases with consolidation (ARDS – adult respiratory distress syndrome).*

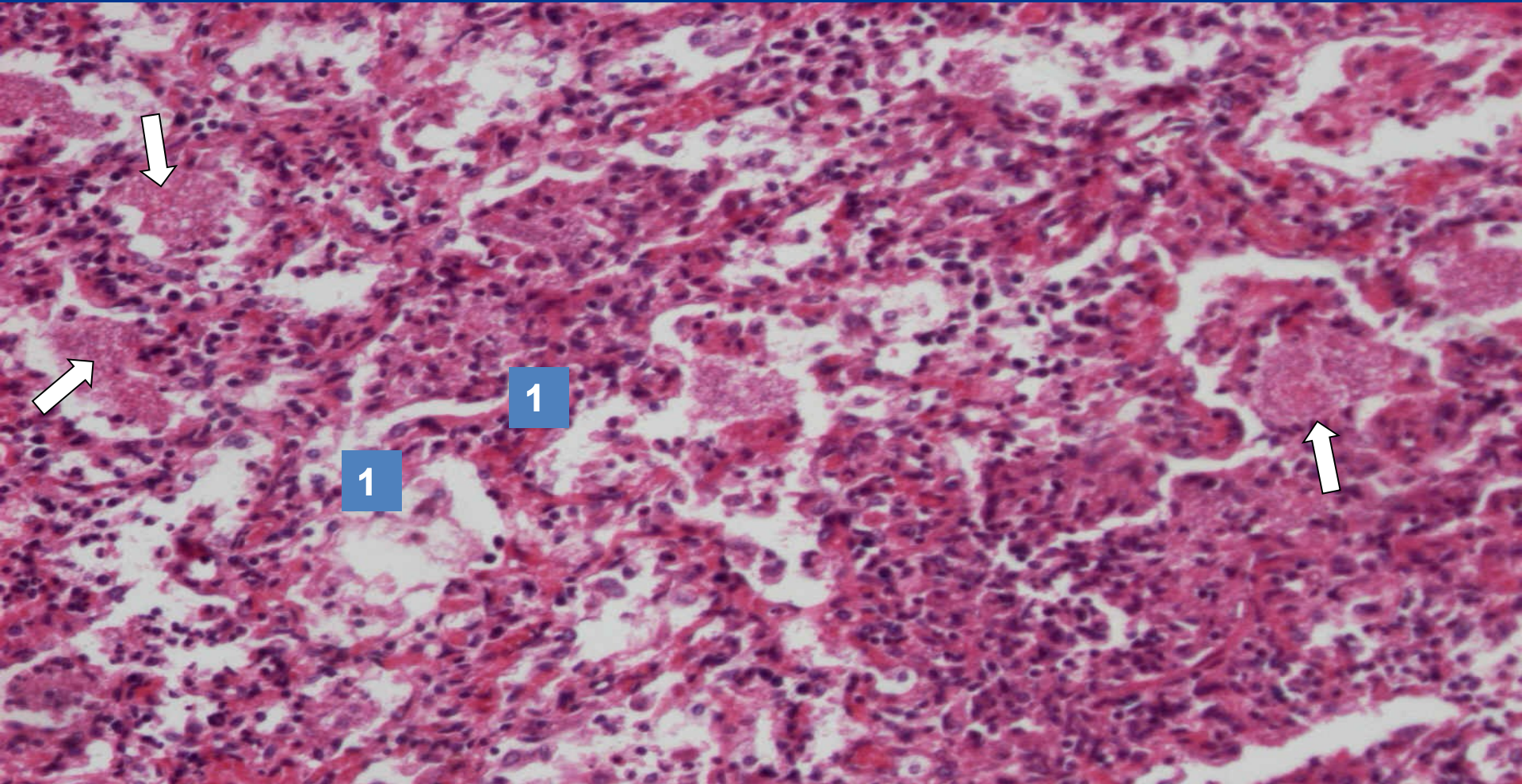
## **x MICRO:**

⇒ *interstitial pneumonitis - oedematous septa with mononuclear infiltrate.*

⇒ *hyaline membranes (ARDS)*

⇒ *common secondary bacterial infection*

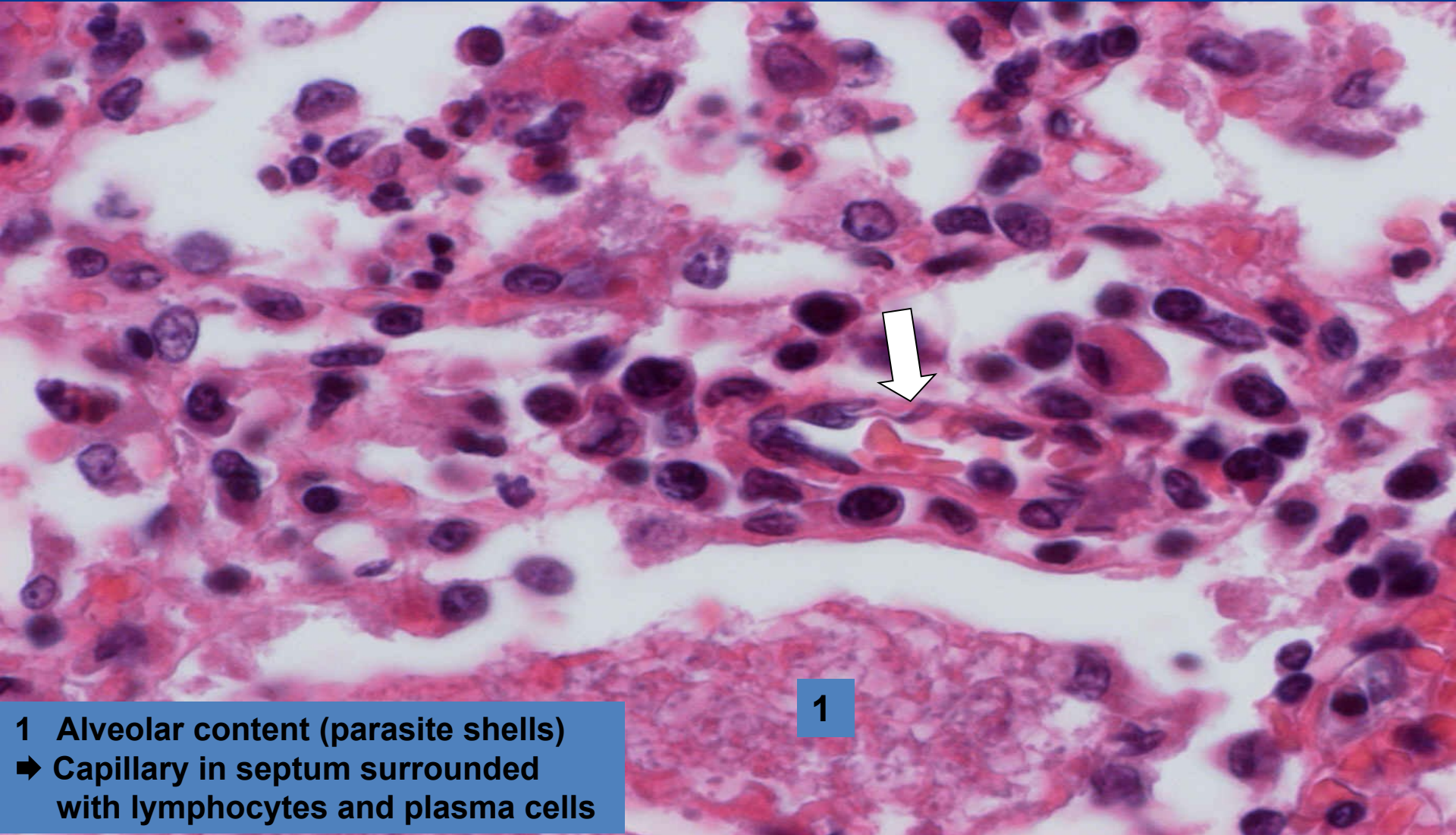
# *Interstitial pneumocystic pneumonia* *(non-purulent inflammation)*



1 Alveolar septa filled with mononuclear infiltration  
➔ Alveolar content (parasite shells)

# *Interstitial pneumocystic pneumonia - detail*

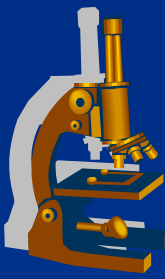
*(non-purulent inflammation)*



1

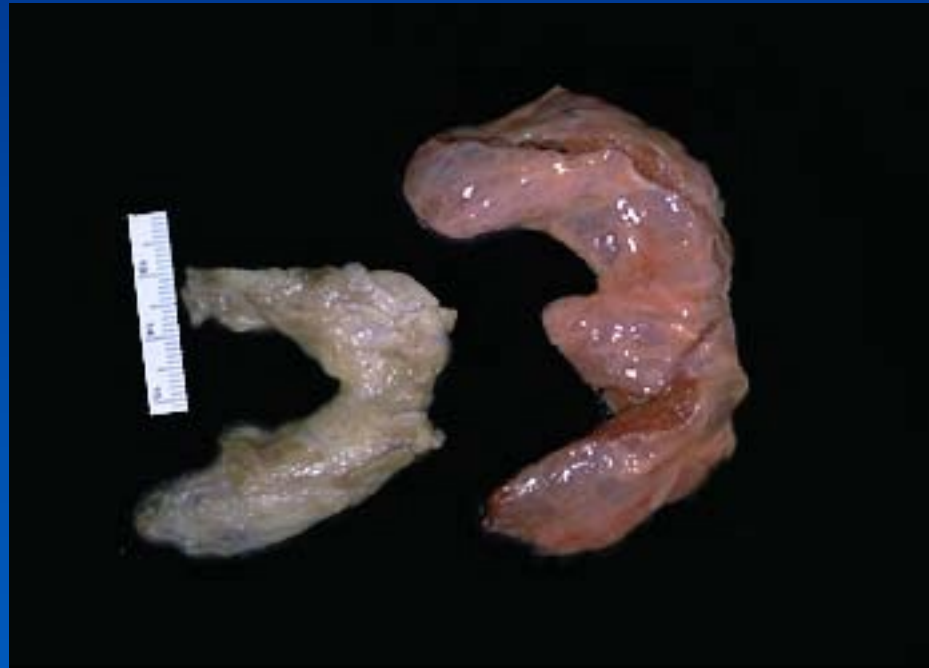1 Alveolar content (parasite shells)  
➔ Capillary in septum surrounded with lymphocytes and plasma cells

# *Hashimoto thyroiditis*



- x autoimmune
- x antibodies against various th. antigenes
- x loss of th. follicular cells
- x lymphocytic infiltration
- x neoformation of lymphoid follicles
- x risk of other autoimmune diseases, thyroid tumors

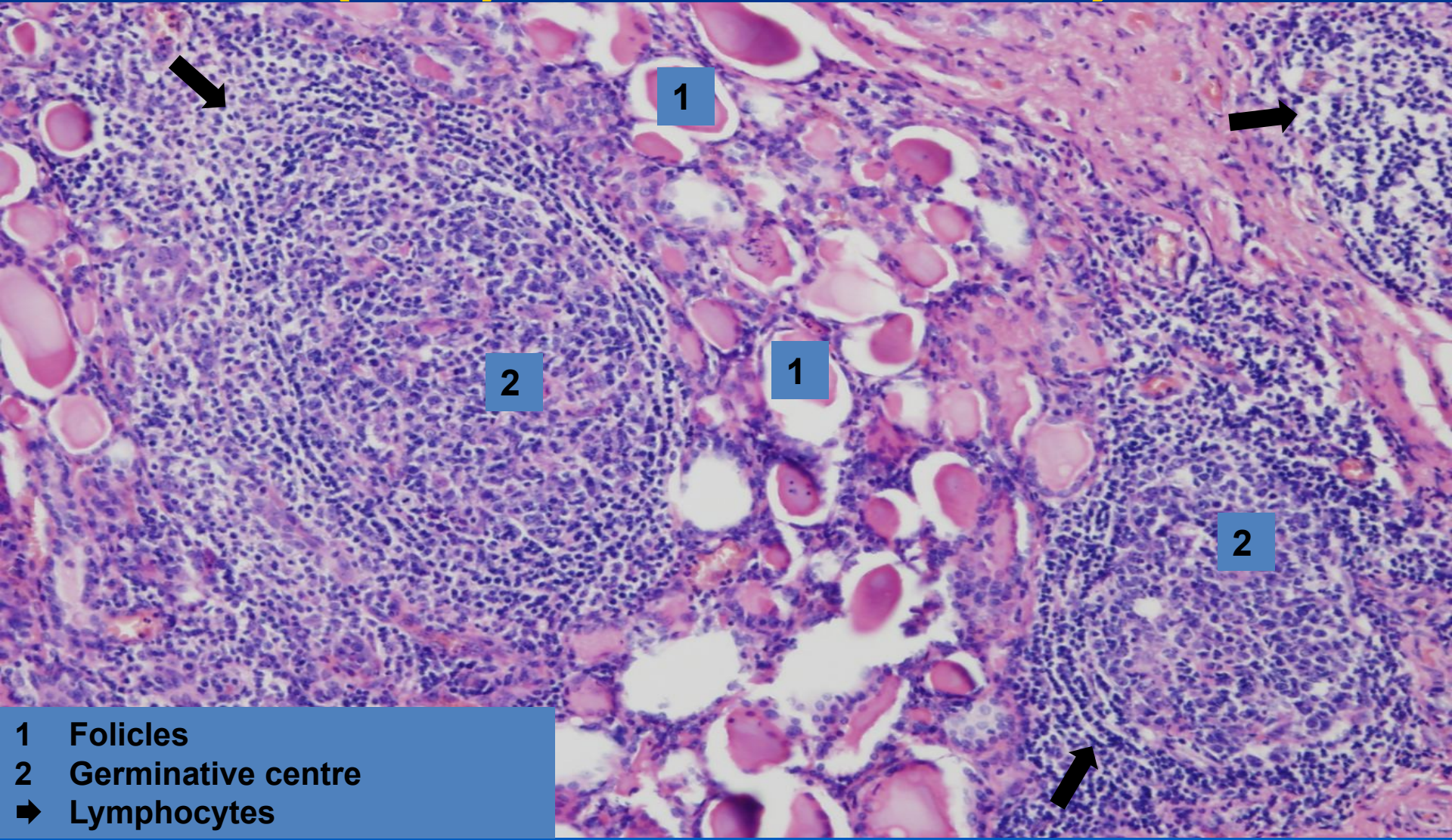
# *Chronic thyreoiditis*





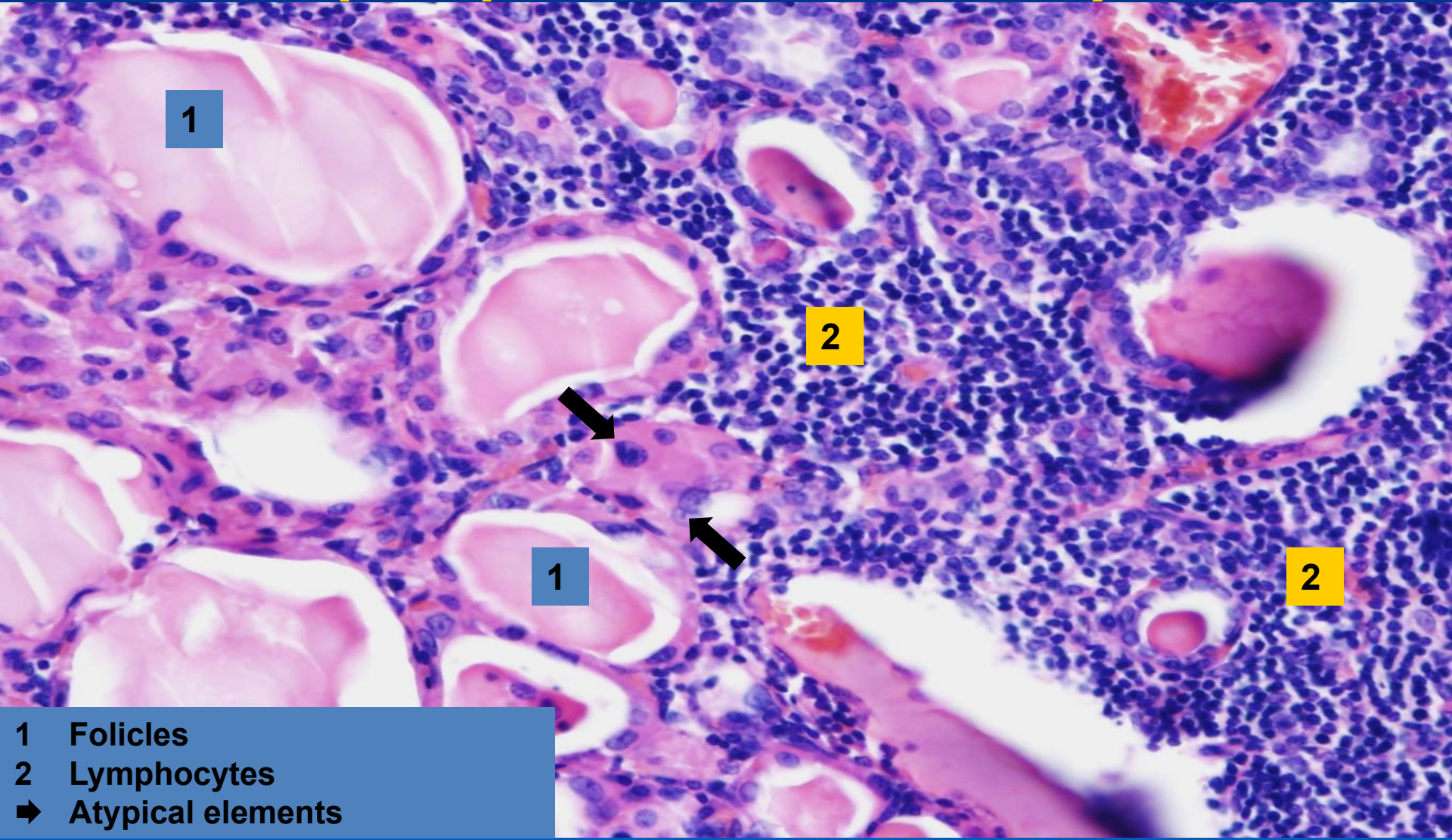
# *Hashimoto`s lymphocytic thyreoiditis*

*(non-purulent inflammation)*



- 1 Follicles
- 2 Germinative centre
- ➡ Lymphocytes

# *Hashimoto`s lymphocytic thyreoiditis – detail (non-purulent inflammation)*



1

2

1

2

- 1 Follicles
- 2 Lymphocytes
- ➔ Atypical elements