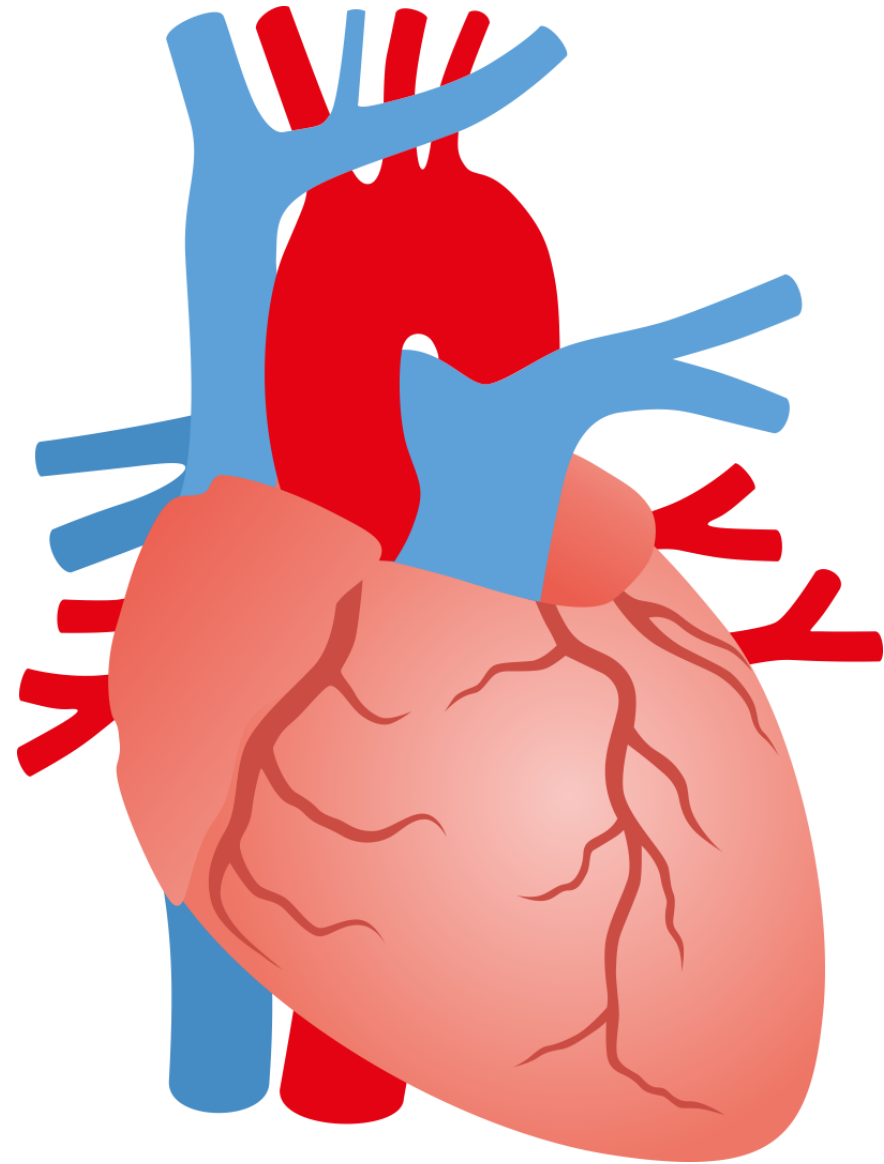


MUNI

HEART (COR)

Dentistry – Anatomy II
RNDr. Michaela Račanská, Ph.D.



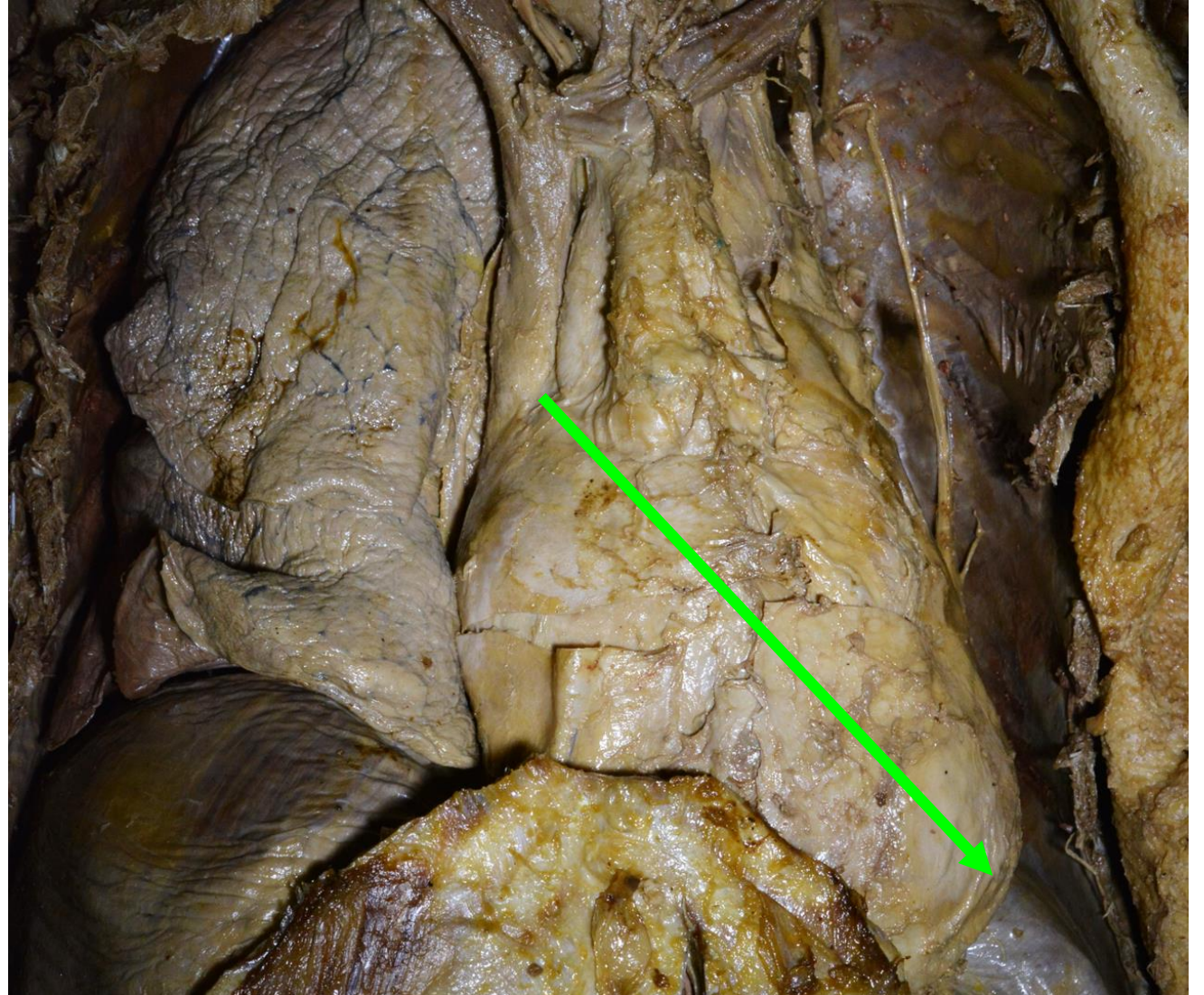
Syntopy

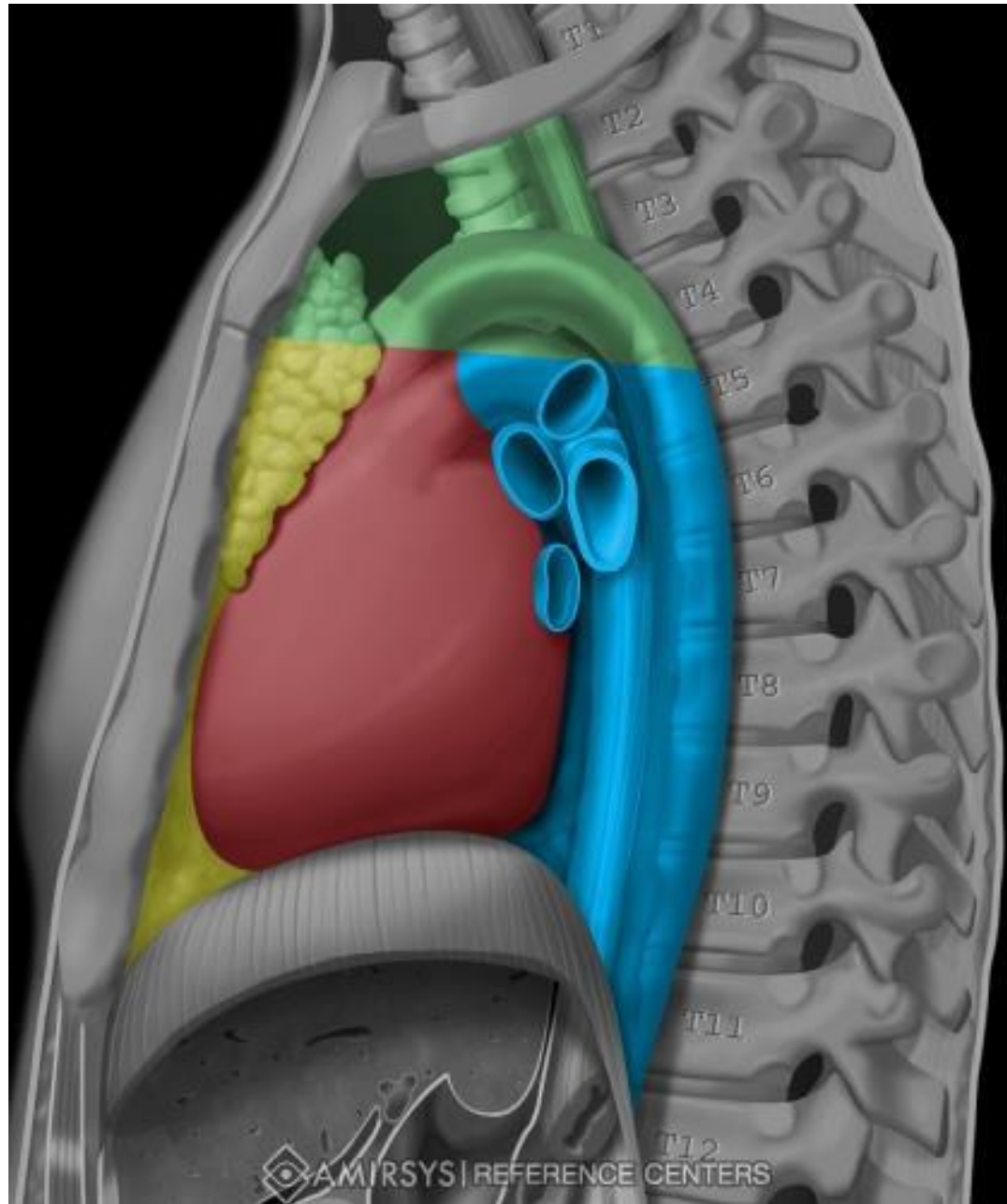
- above the diaphragm, in the inferior middle mediastinum
- 2/3 left, 1/3 right
- unpaired, hollow, muscular organ of cone shape
- 4.5% of the body weight (fist-sized)

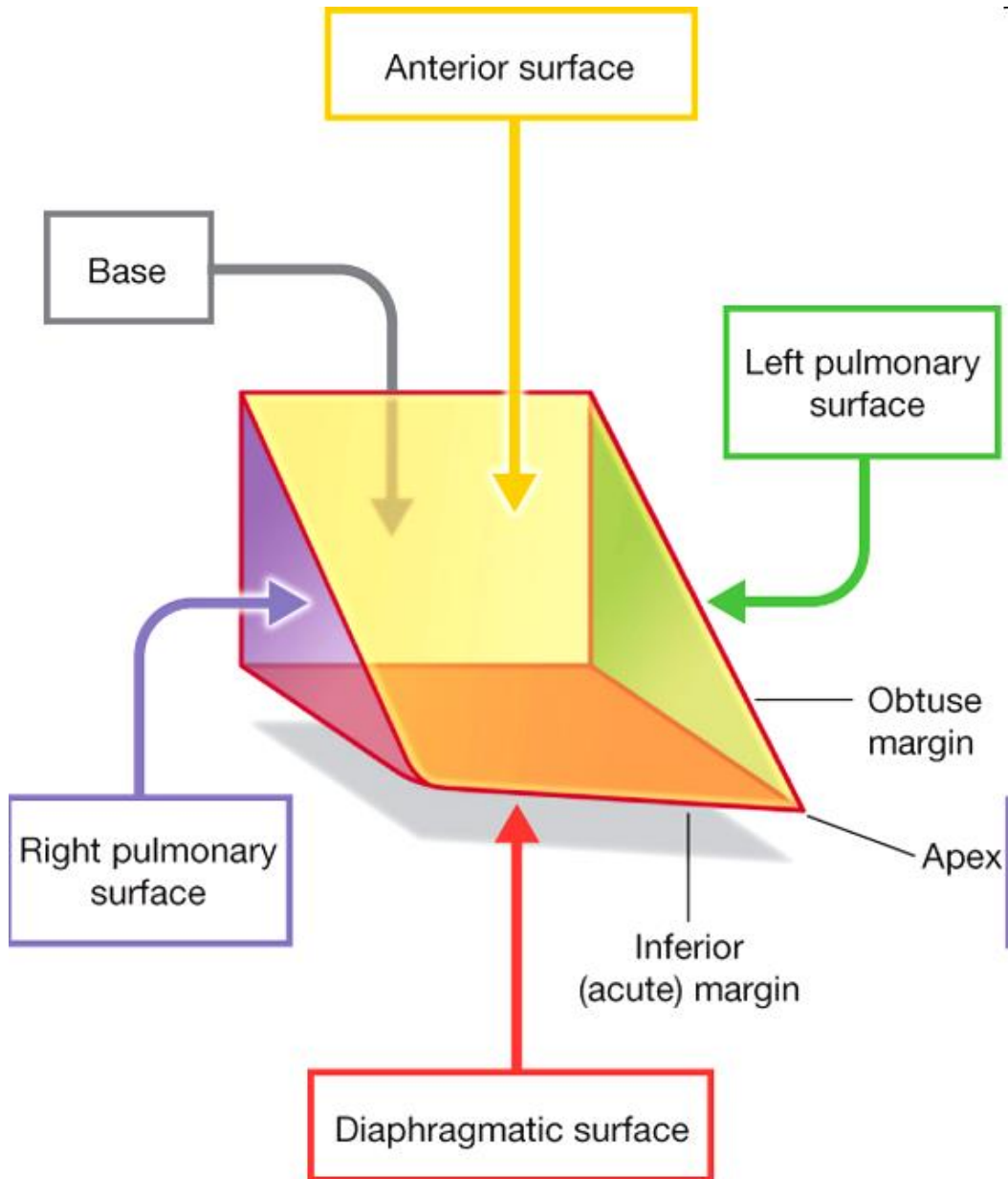
Adult 240 – 320 g

Newborn 20 – 30 g

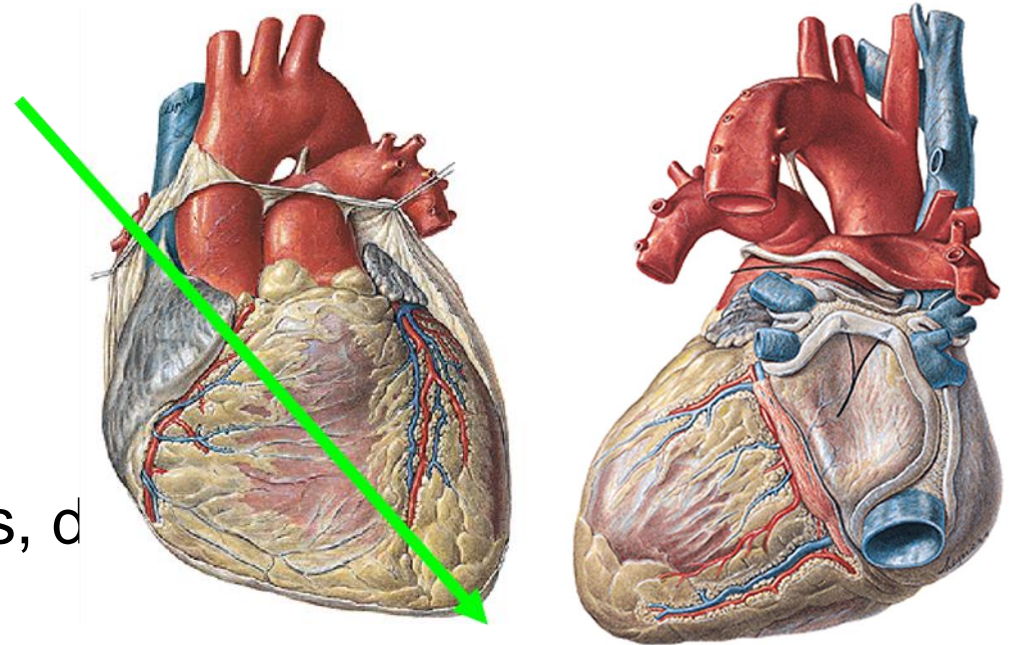
Longitudinal axis of the heart







Drake: Gray's Anatomy for Students, 2nd Edition.
 Copyright © 2009 by Churchill Livingstone, an imprint of Elsevier, Inc. All rights reserved.



Base

cran., dors, d

Apex

caud., ventr., sin.

Heart axis

Facies anterior (sternocostalis)

Facies inferior (diaphragmatica)

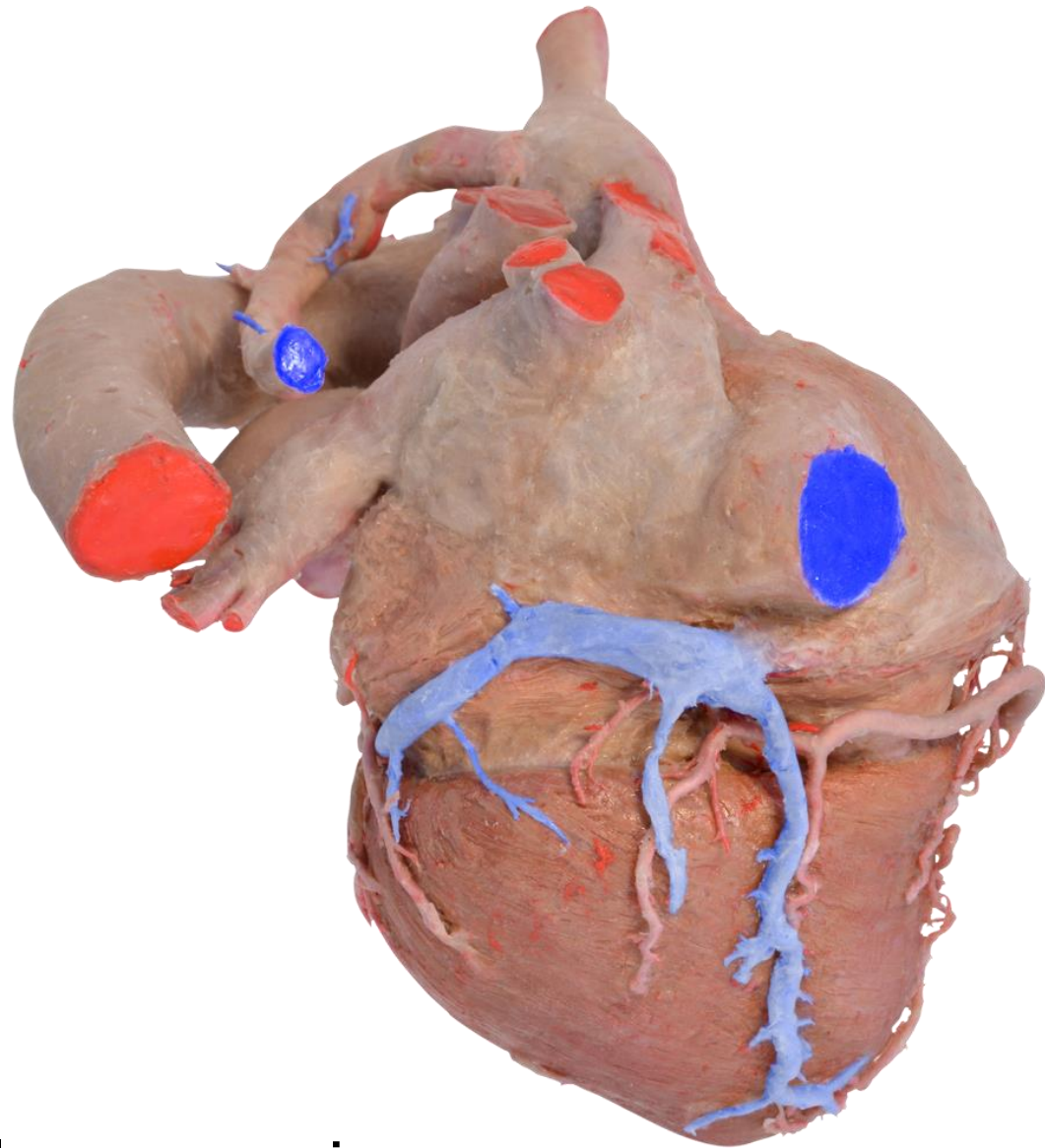
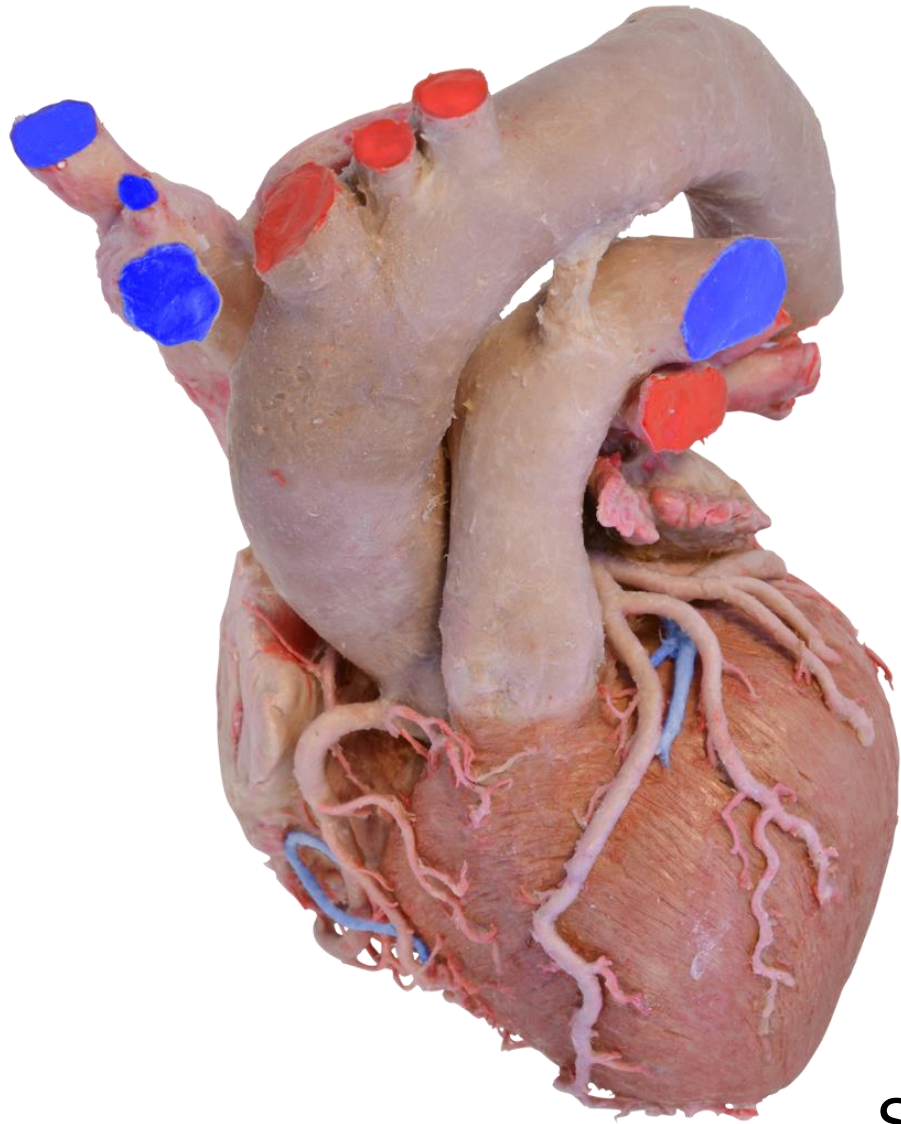
Margo dexter (acutus)

Margo sinister (obtusus)

Sulcus coronarius

Sulcus interventricularis ant. et post.

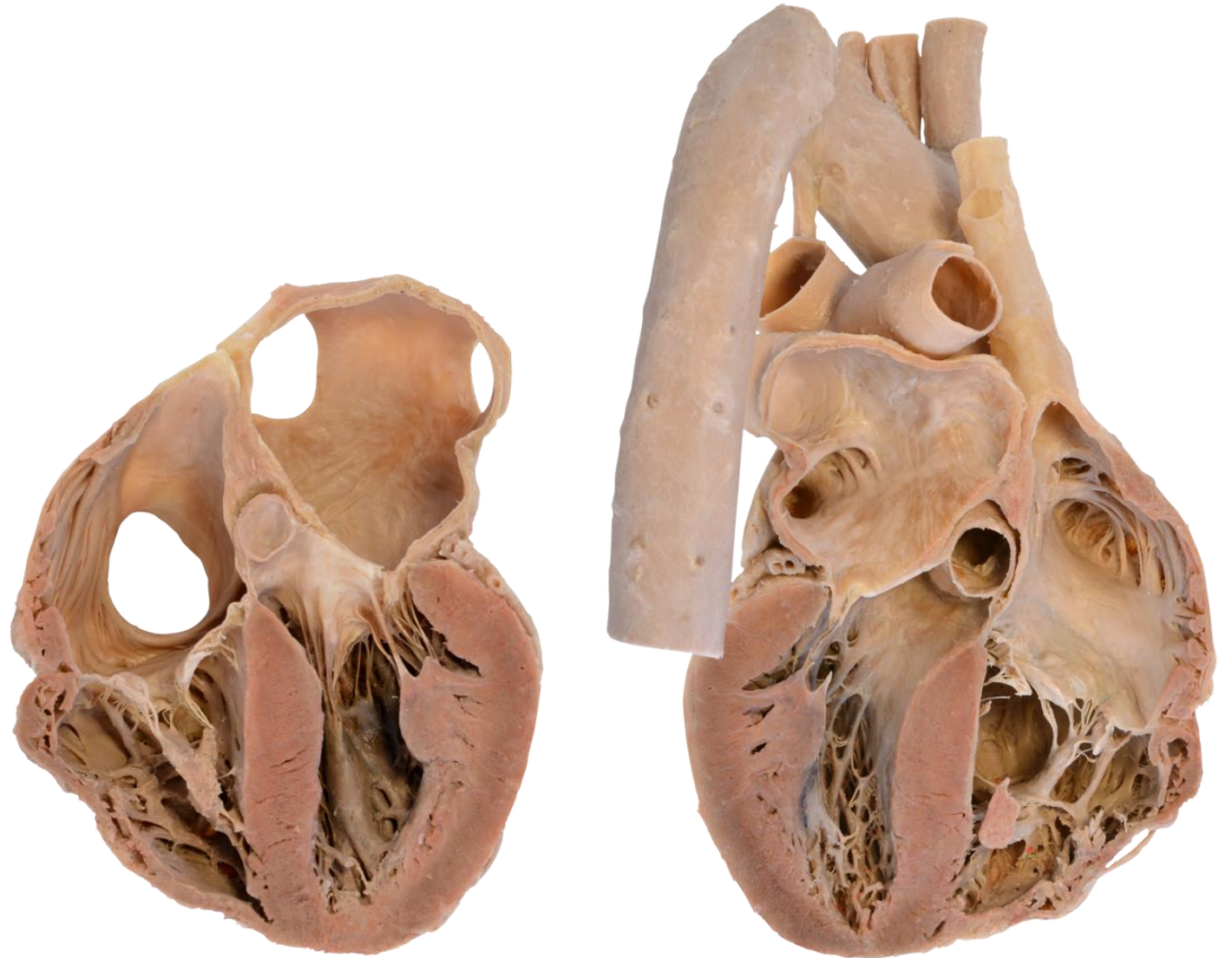
Auricula dextra et sinistra



Sulcus coronarius
Sulcus interventricularis ant. et post.

The chambers of the heart

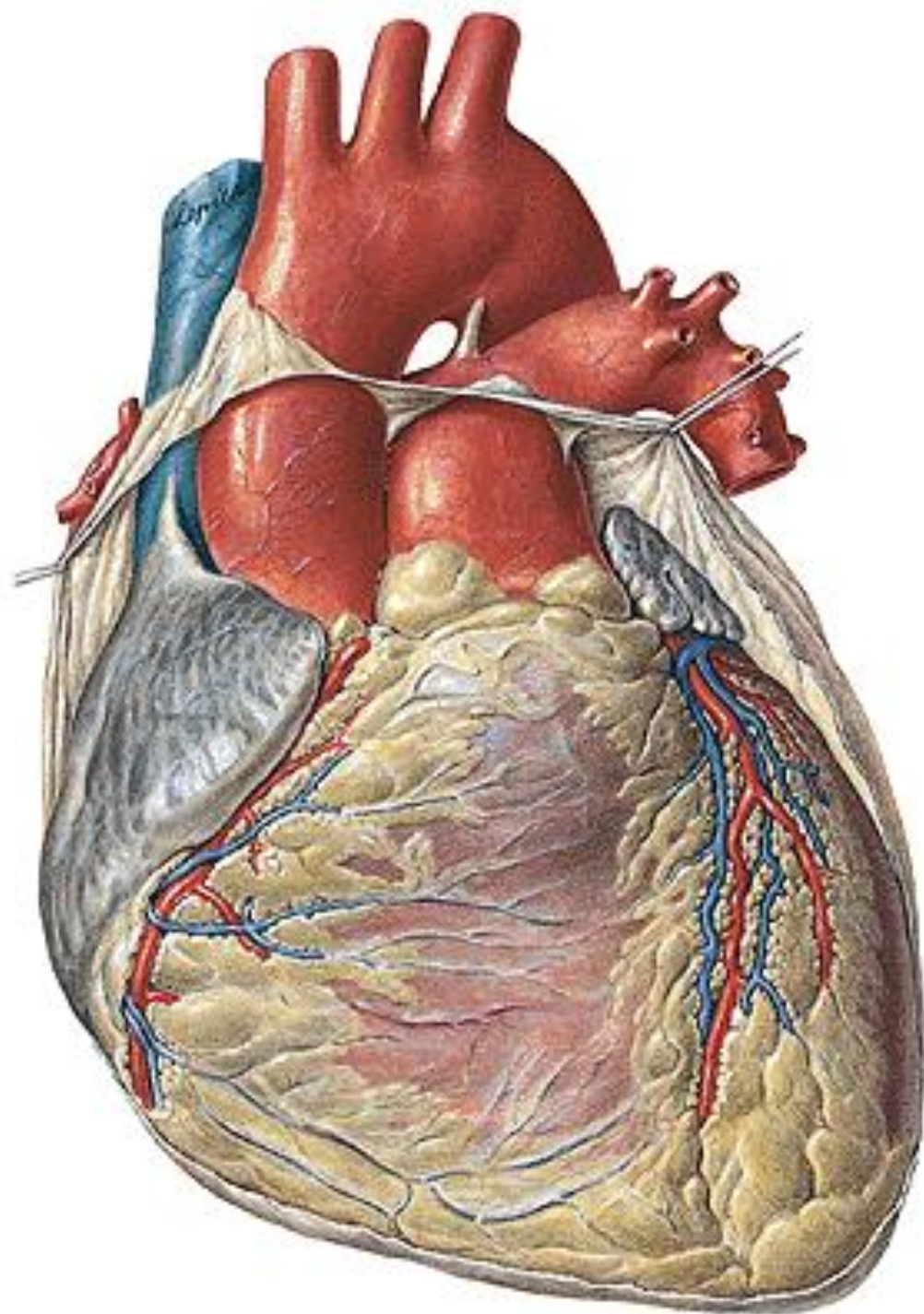
- Atrium dextrum
- Atrium sinistrum
- Ventriculus dexter
- Ventriculus sinister



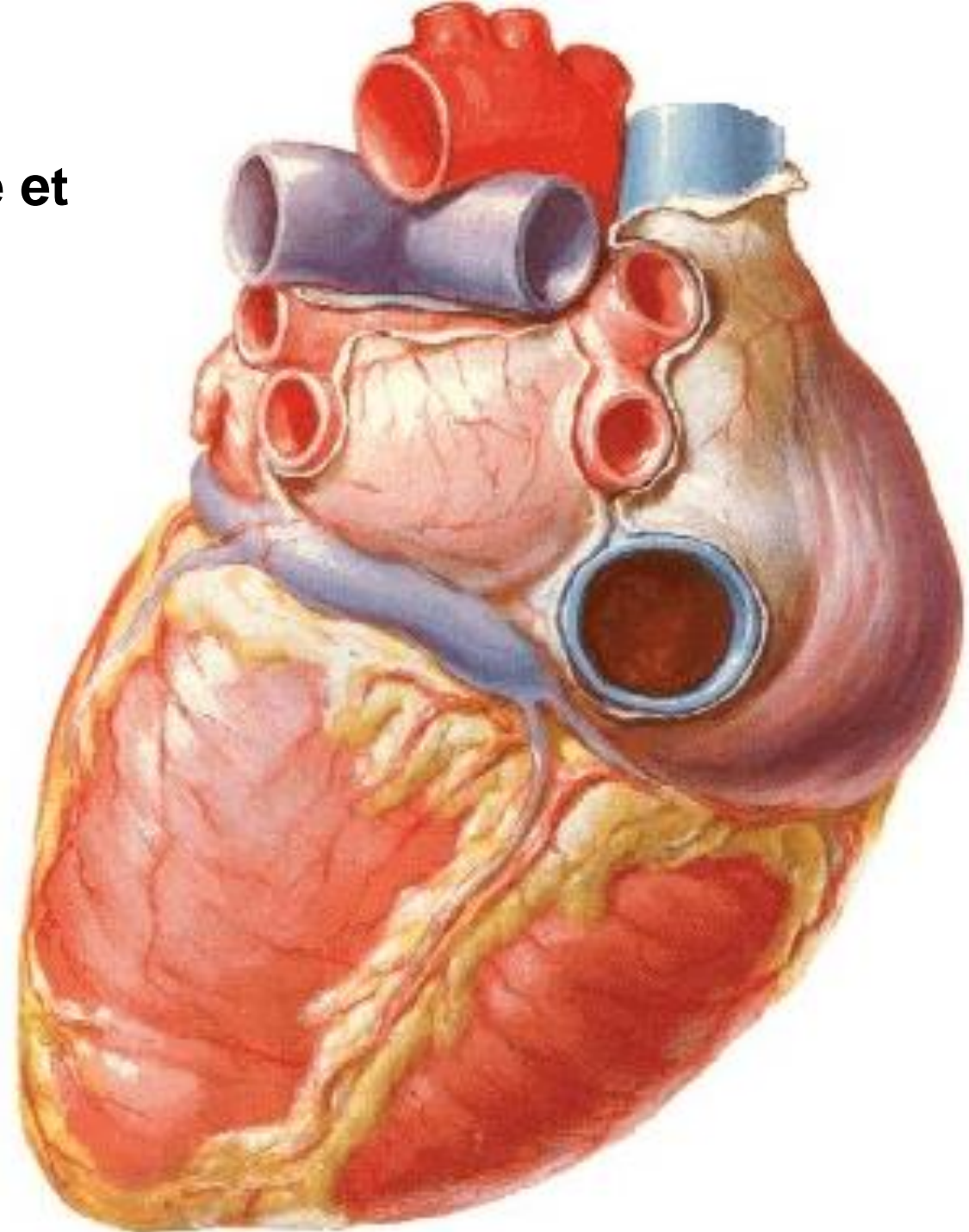
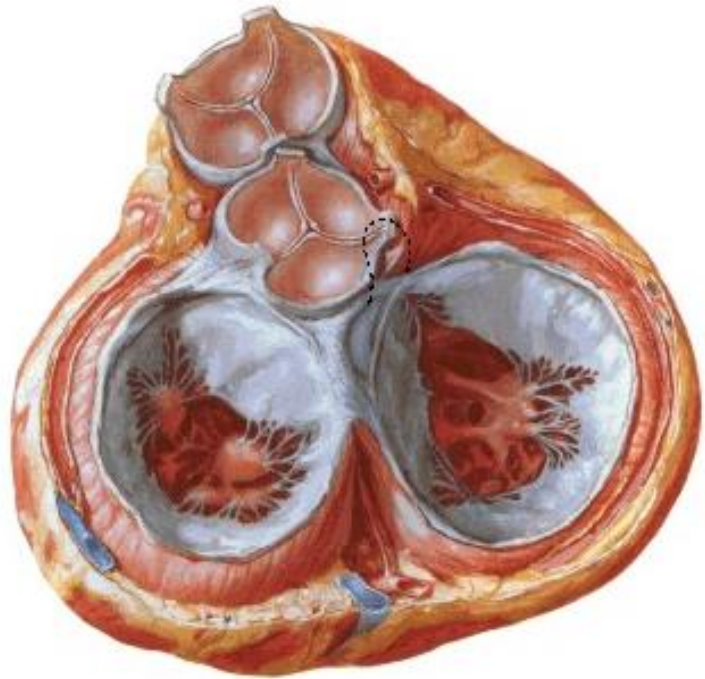
Septum interatriale

Septum interventriculare

Atrium dextrum
- vena cava sup. et inf.
Ventriculus dexter
- truncus pulmonalis



Atrium sinistrum
vv. pulmonales dextrae et
sinistrae
Ventriculus sinister
- aorta



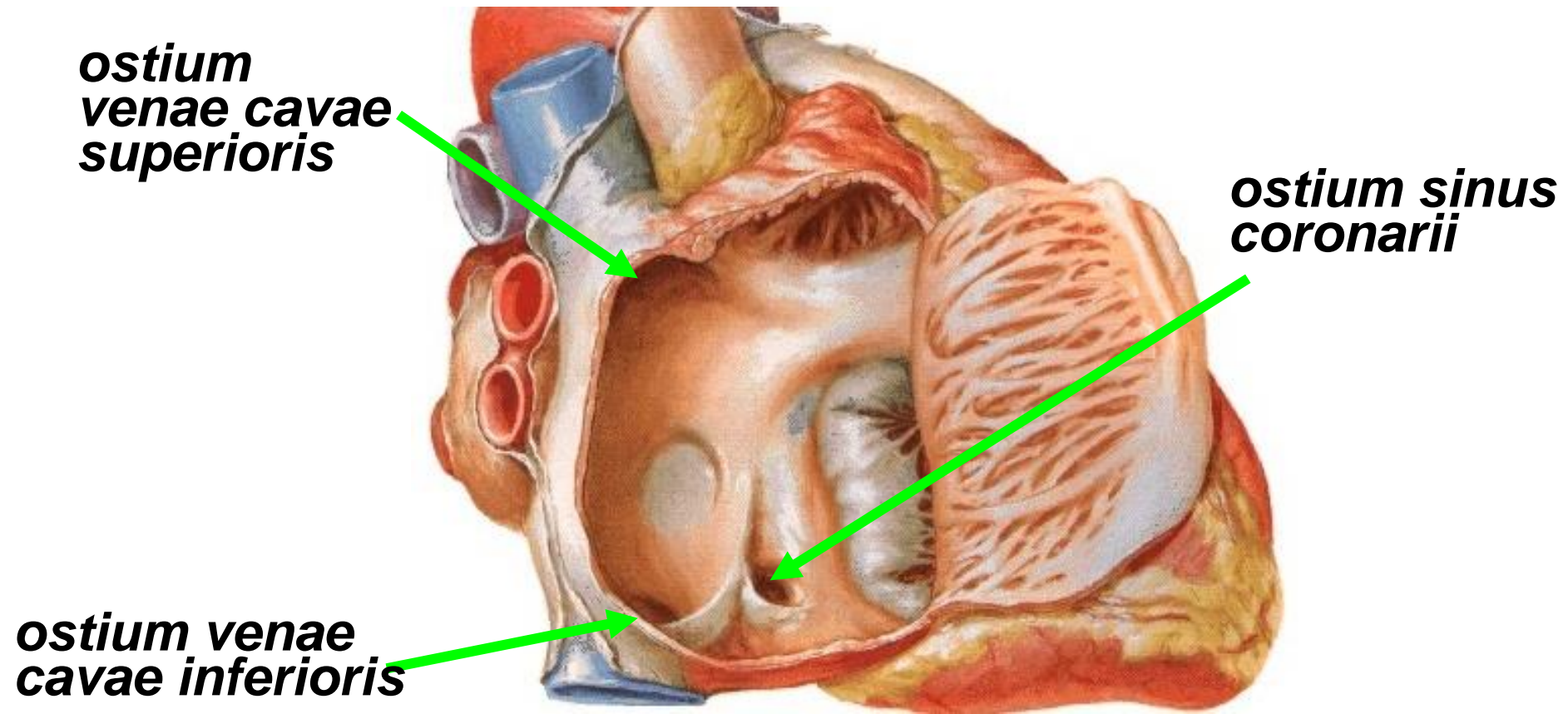
Atrium dextrum – cube with six walls

outcome: vena cava superior et vena cava inferior

sinus coronarius (the venous sinus of the heart)

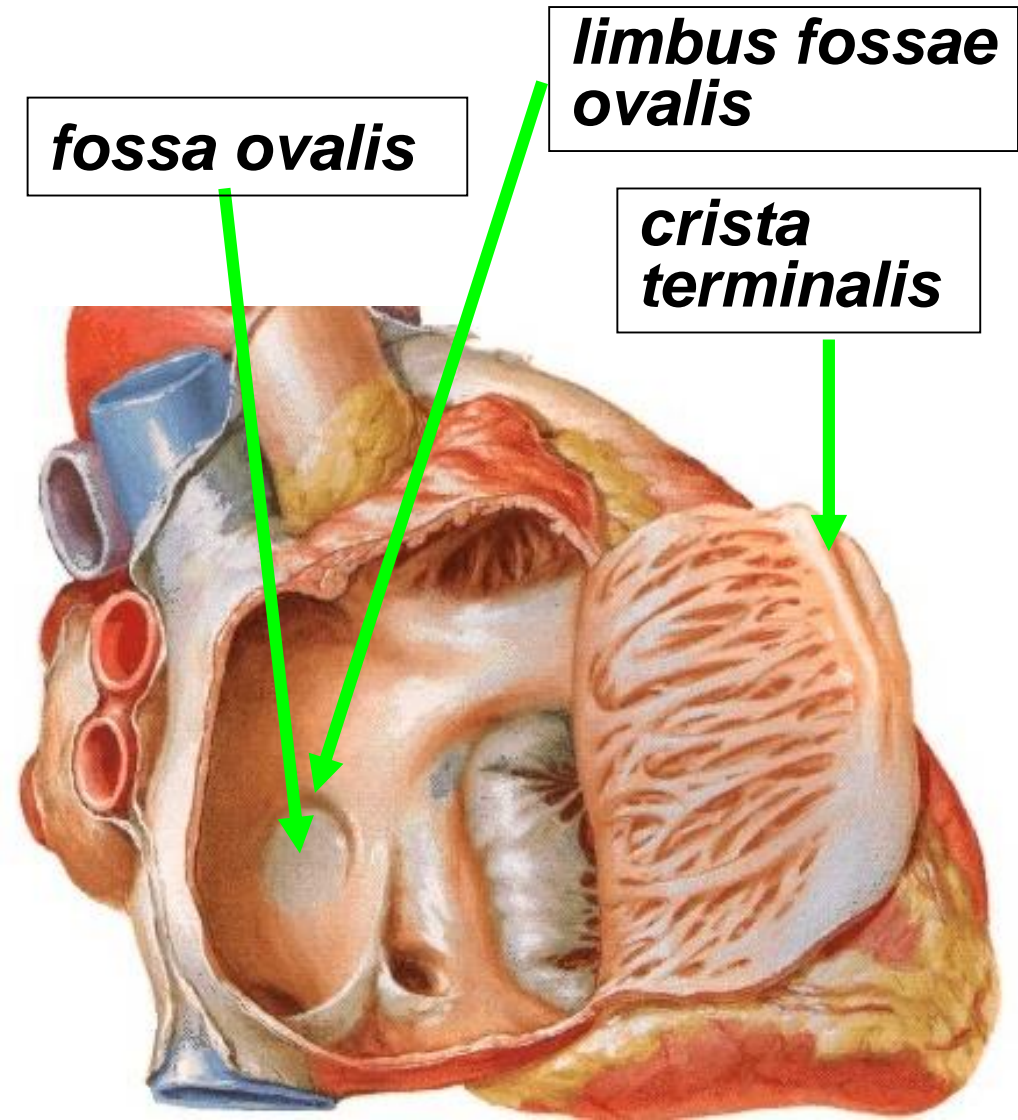
1) Superior wall - ostium venae cavae superioris

2) Inferior wall - ostium venae cavae inferioris, ostium sinus coronarii and ostia venae cordis anteriores



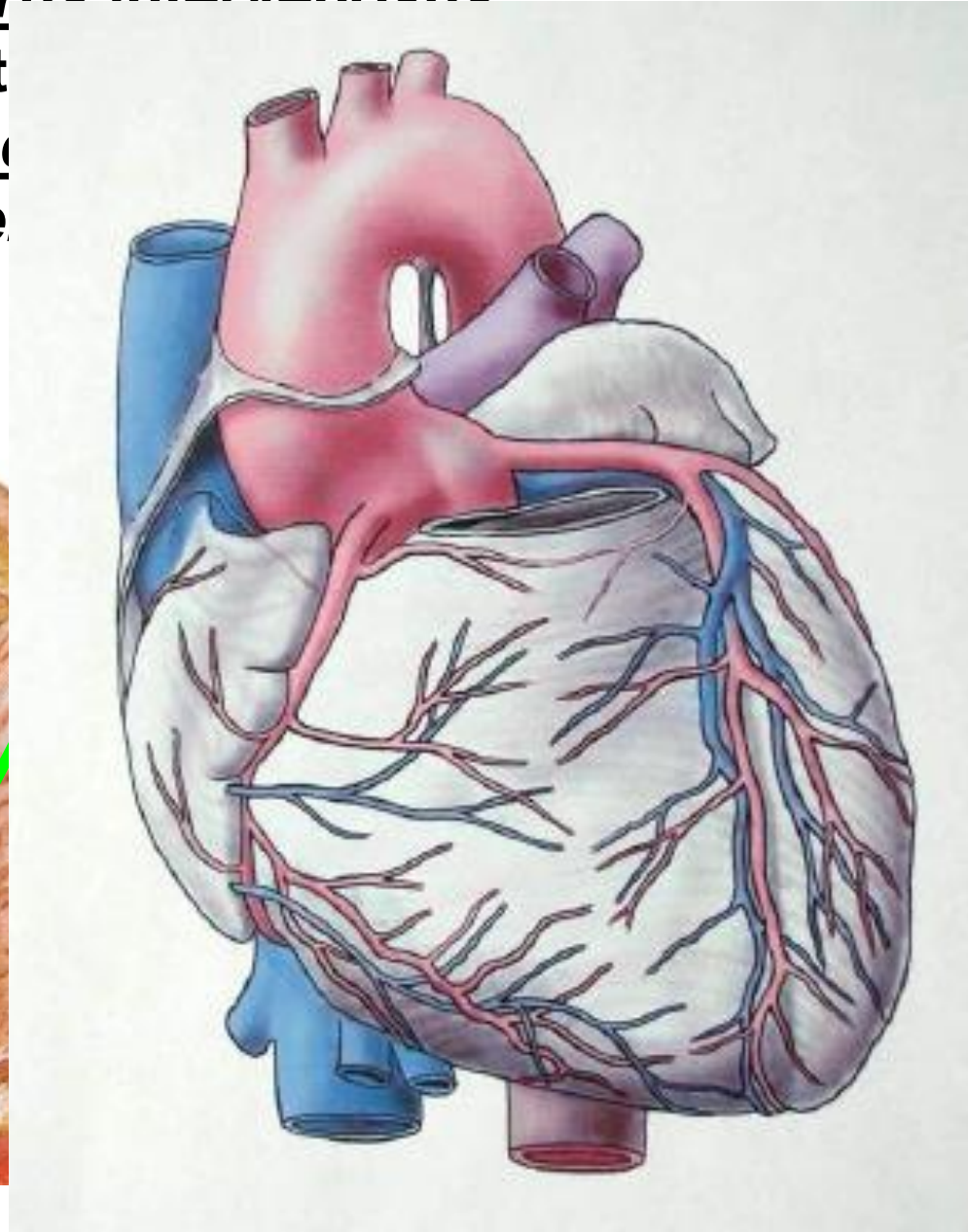
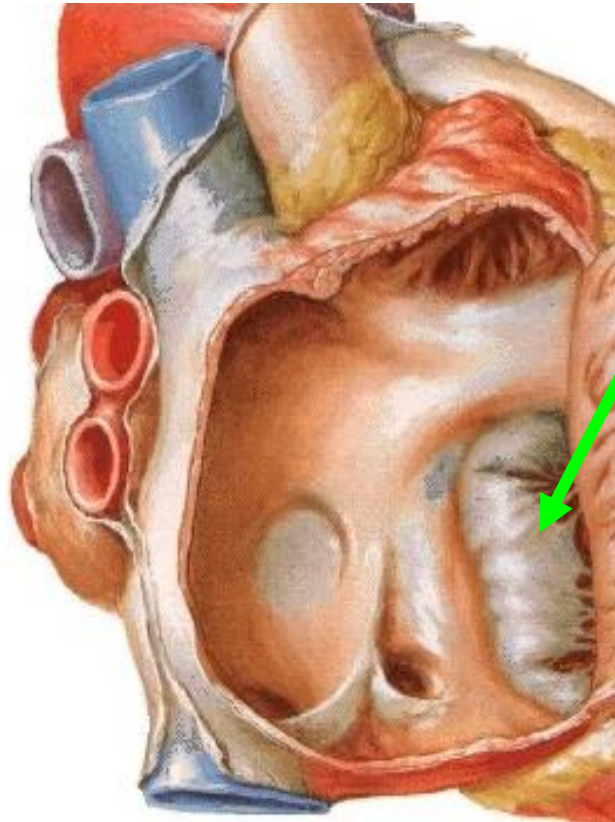
3) Medial wall - septum interatriale with fossa ovalis with slightly raised edge (limbus fossae ovalis)

4) On the lateral wall - crista terminalis, which separates the posterior part – sinus venosus from the anterior one

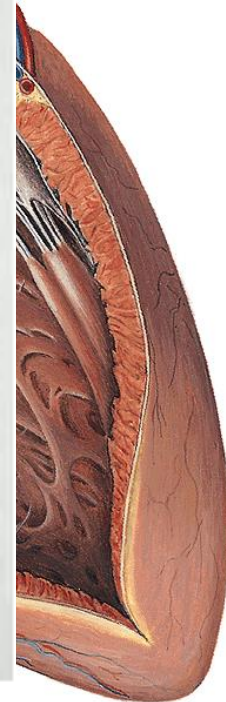

5) Posterior wall – between openings of both venae cavae, it vaults dorsally as torus intervenosus

6) Anterior wall corresponds to the ostium atrioventriculare (tricuspidalis), right to the opening of the dextra (mm. pectinati)



torus intervenosus



VENTRICULUS DEXTER

Pars trabecularis - trabeculae carnae (inflow part)

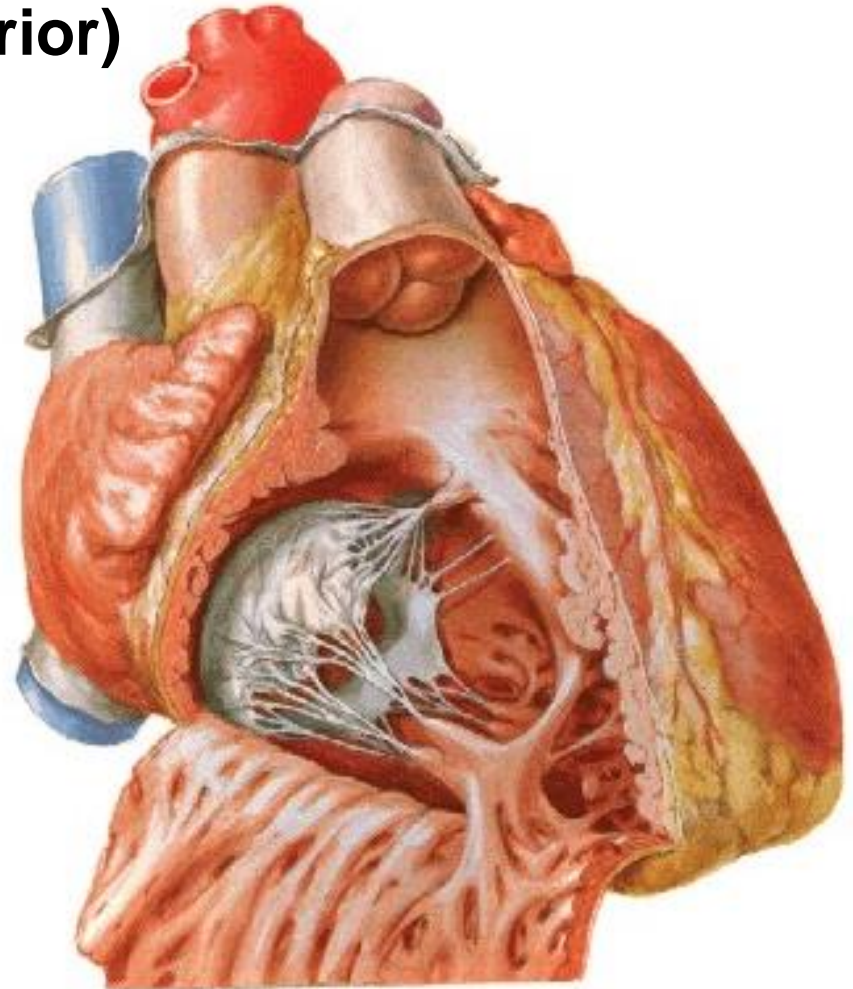
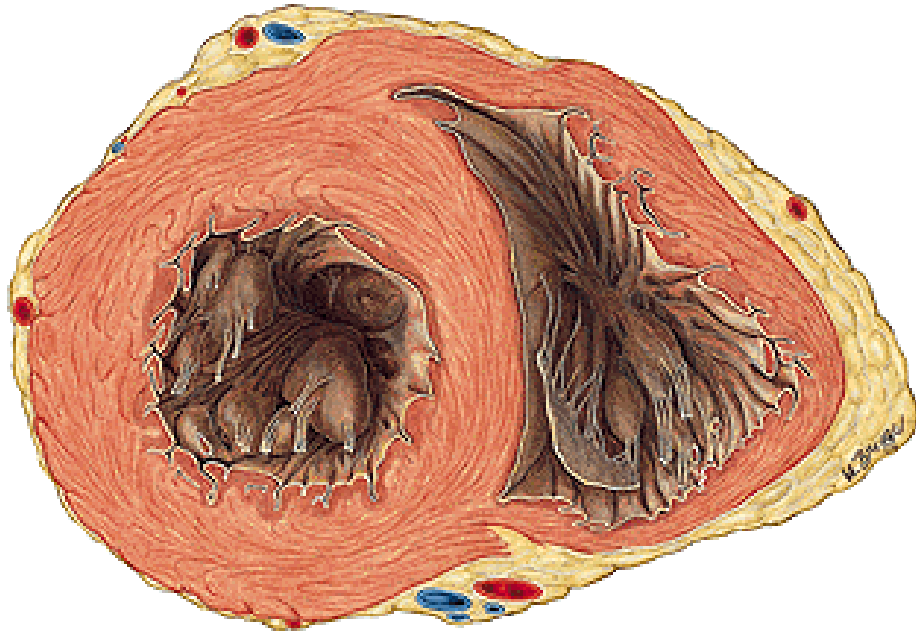Crista supraventricularis, trabecula septomarginalis

Ostium atrioventriculare dextrum, valva tricuspidalis

– cuspis ant., septalis, post.

Musculi papillares (anterior, septalis, posterior)

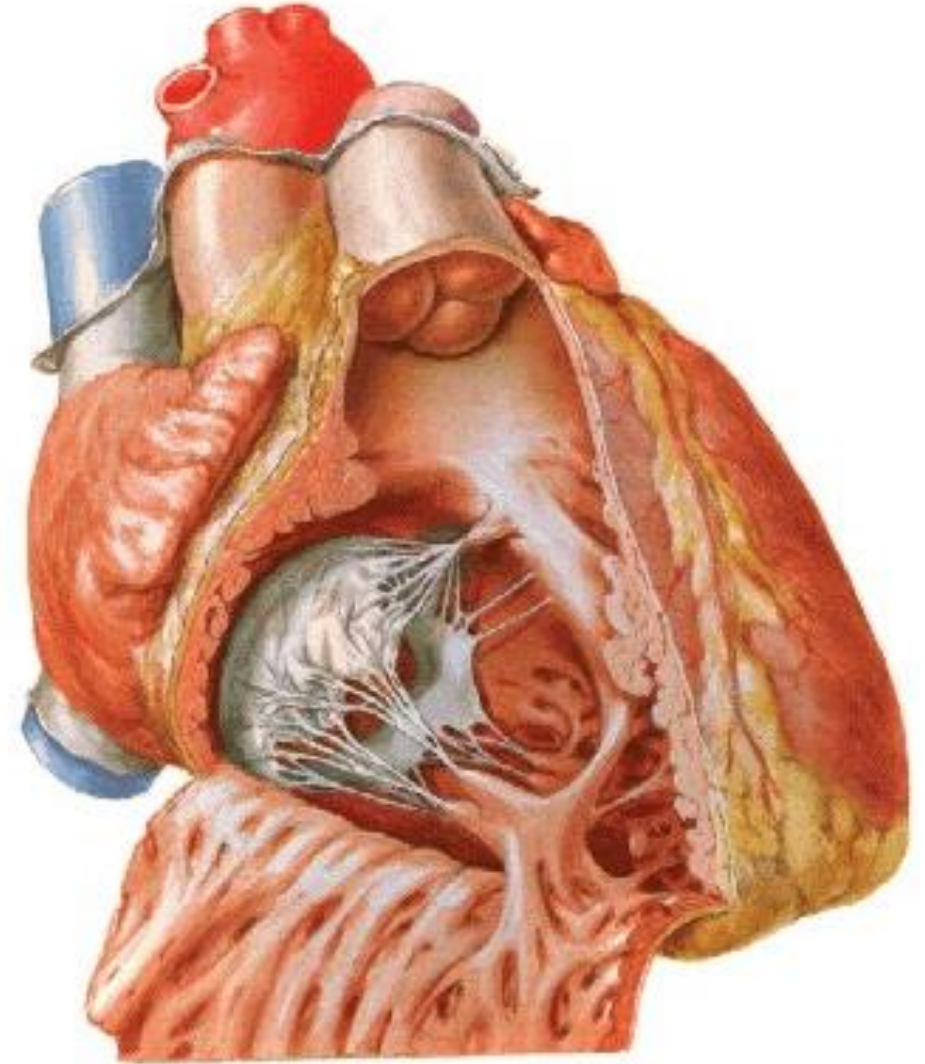
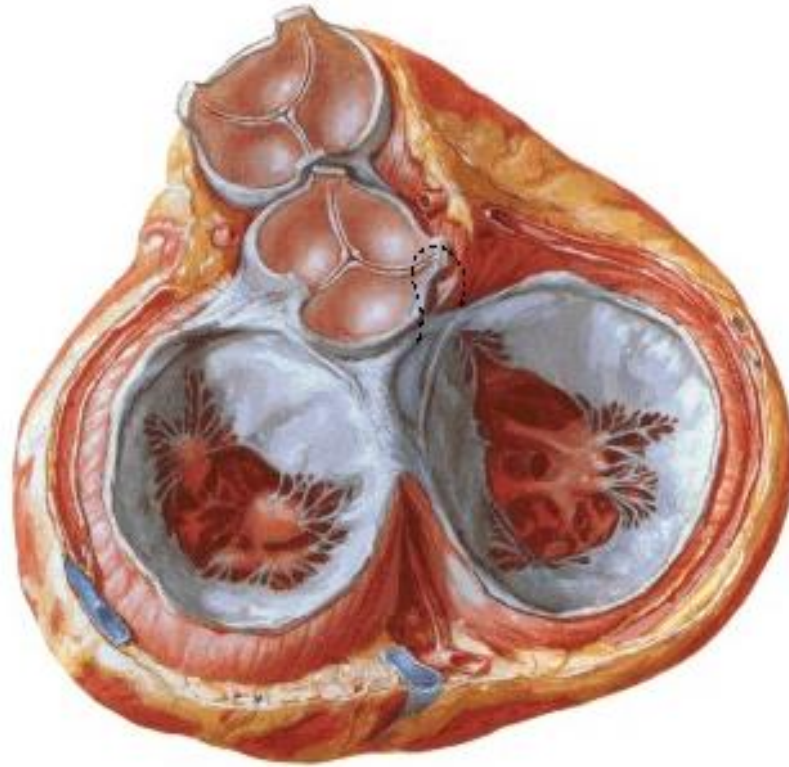
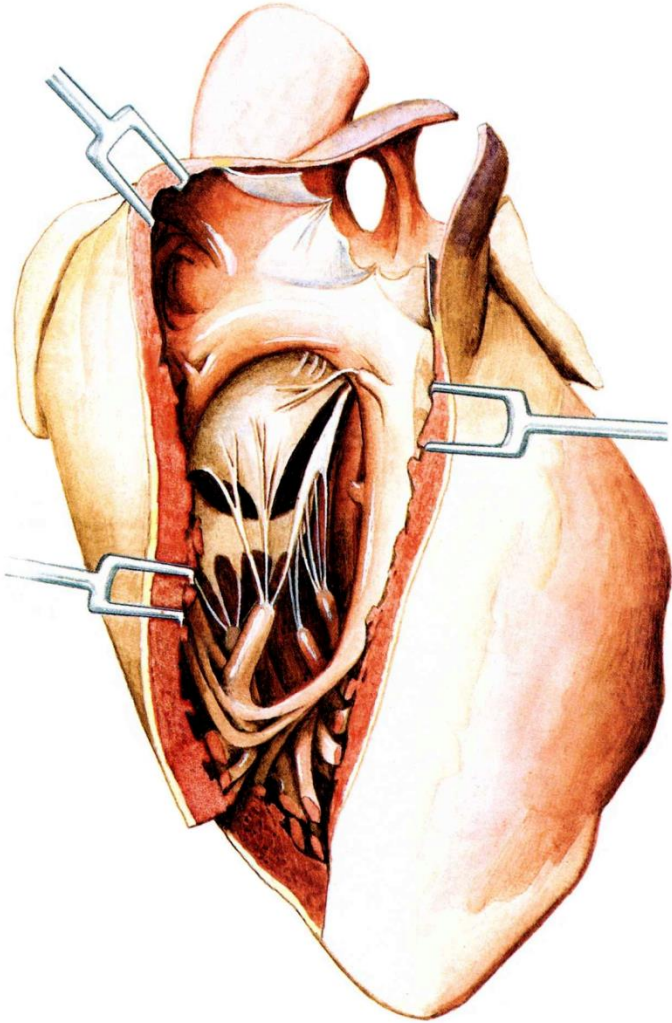
Chordae tendineae



VENTRICULUS DEXTER

Pars glabra – conus arteriosus (outflow part)

Ostium trunci pulmonalis – valva trunci pulmonalis –
valvula semilunaris ant., dx., sin. – lunula, nodulus. sinus



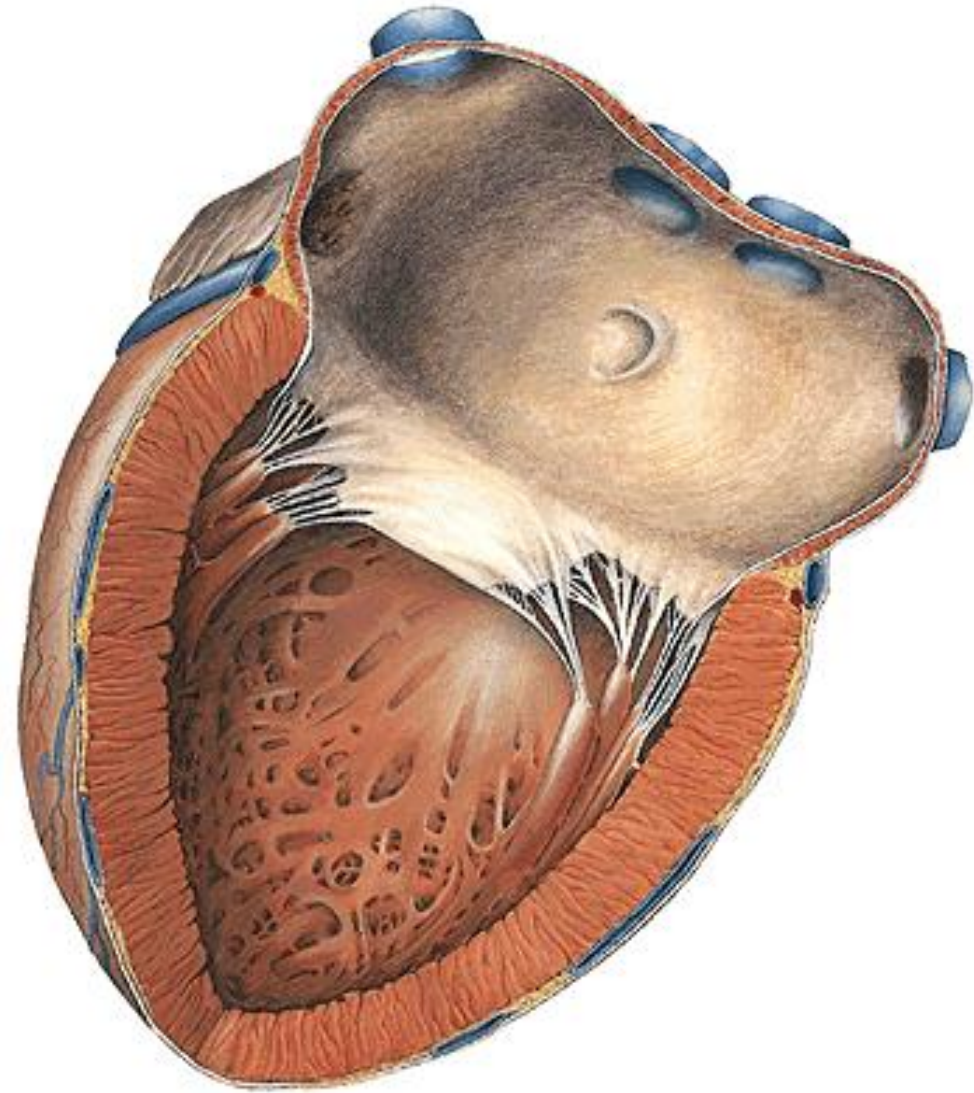ATRIUM SINISTRUM

Ostia venarum pulmonalium

Septum interatriale – fossa ovalis

Auricula sinistra – muscoli pectinati

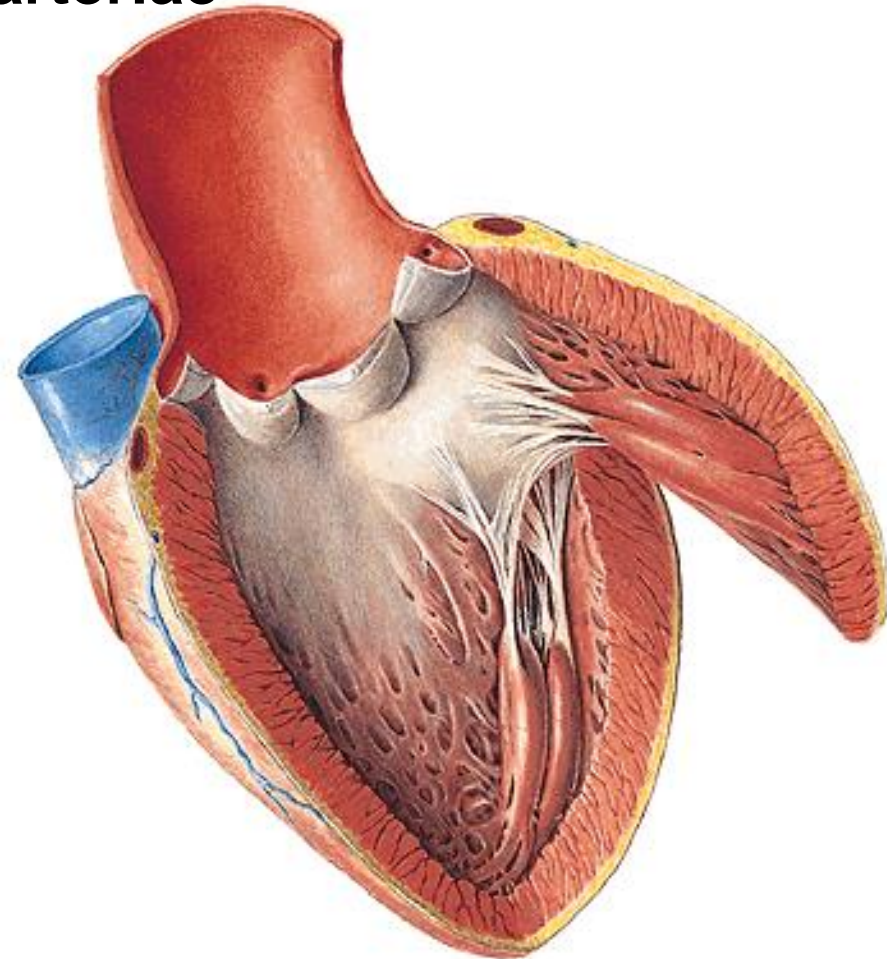
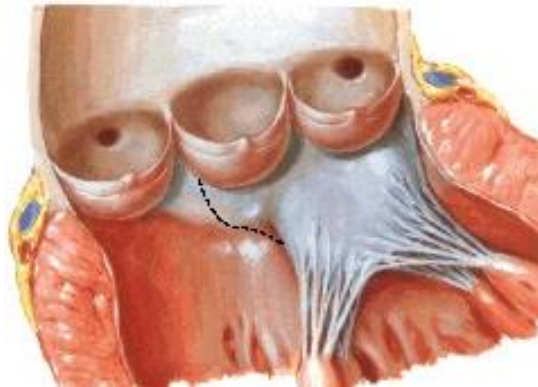
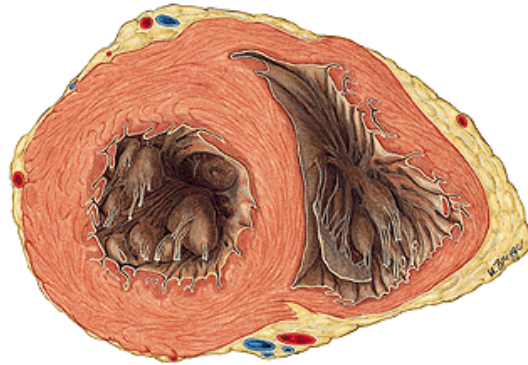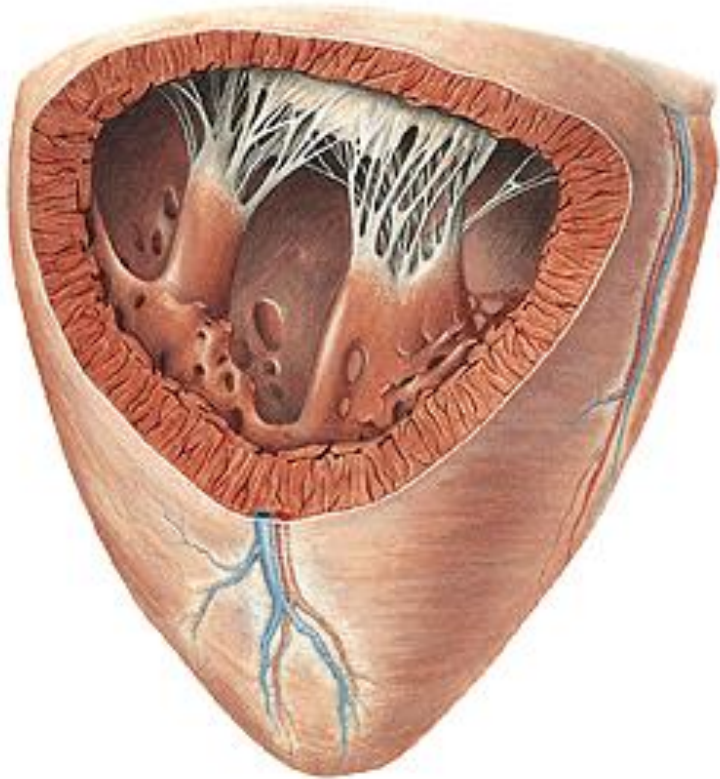
Ostium atrioventriculare sin.



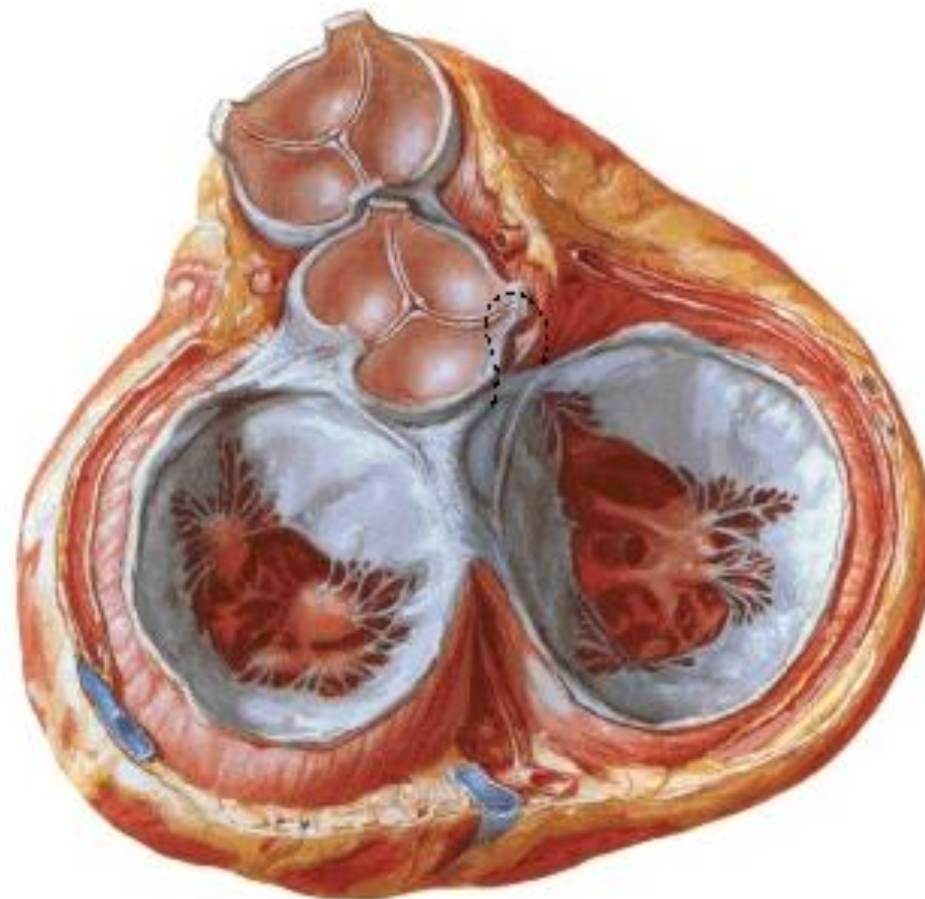
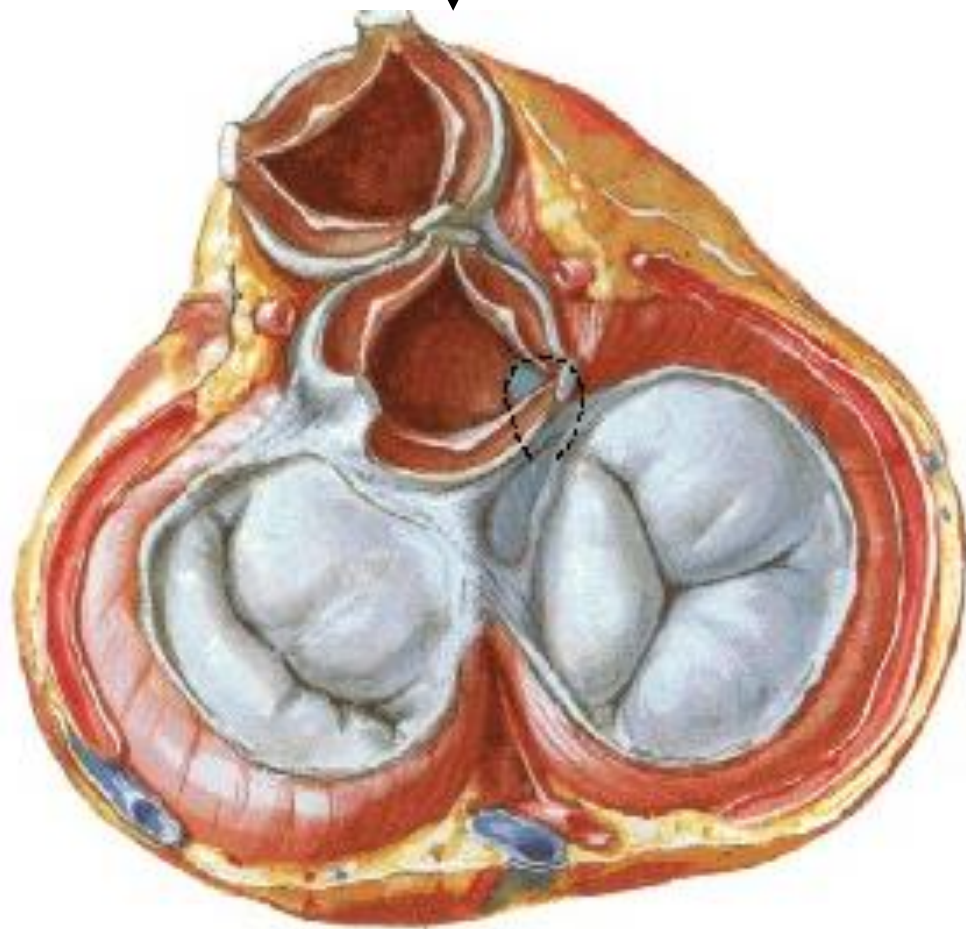
VENTRICULUS SINISTER

Ostium atrioventriculare sin.– valva bicuspidalis (mitralis) –
cuspis ant. et post. – m. papillaris ant. et post. – chordae
tendineae

Ostium aortae – valva aortae – valvula semilunaris dx., sin.
et post. – lunula, nodulus, sinus aortae dx. et sin. – arteriae
coronariae, bulbus aortae

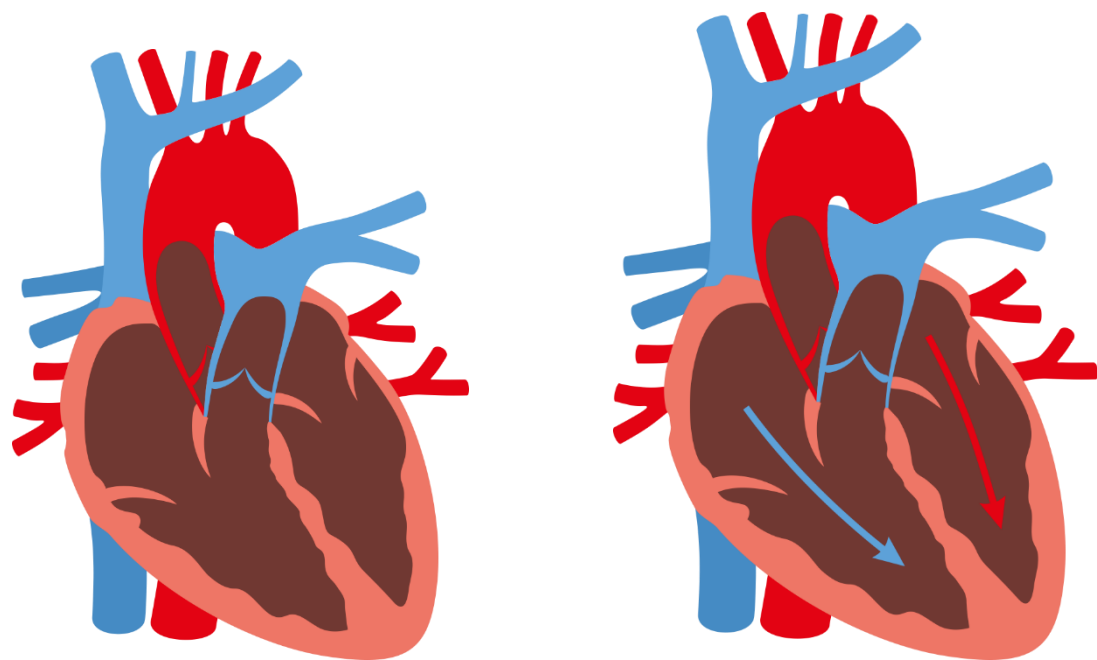


SYSTOLE

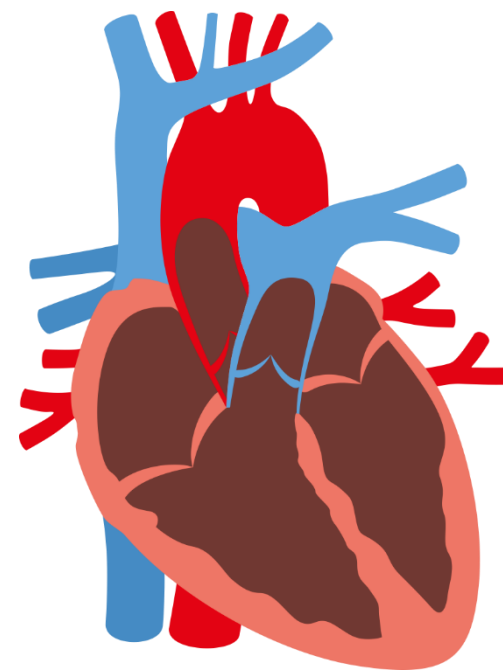
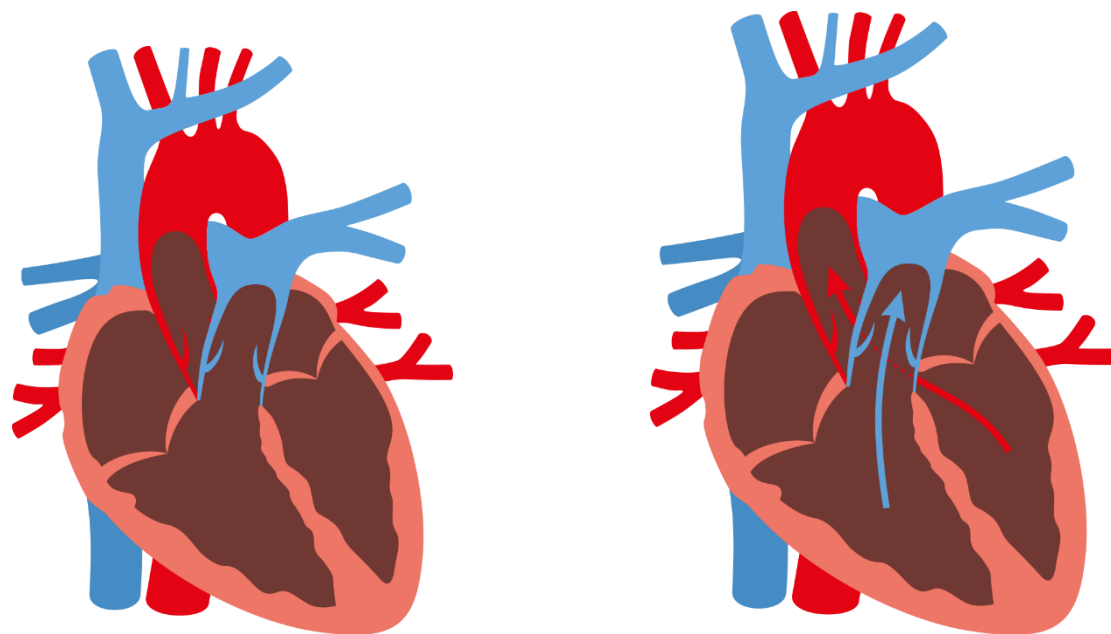


DIASTOLE

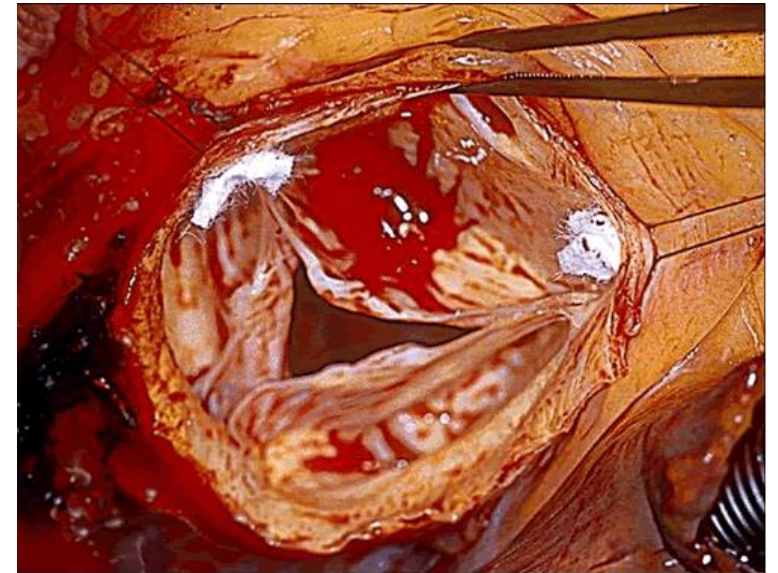
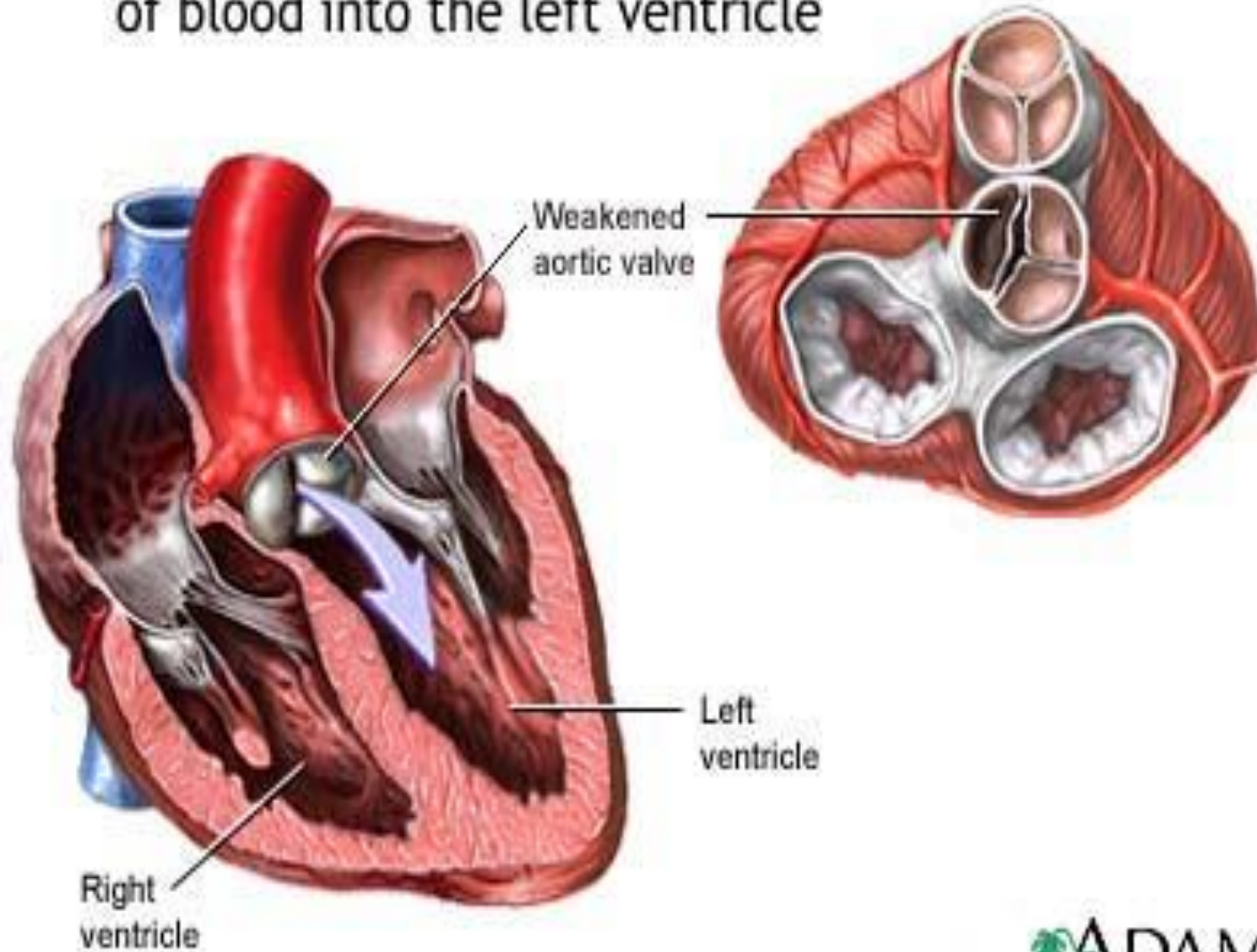
DIASTOLE



SYSTOLE

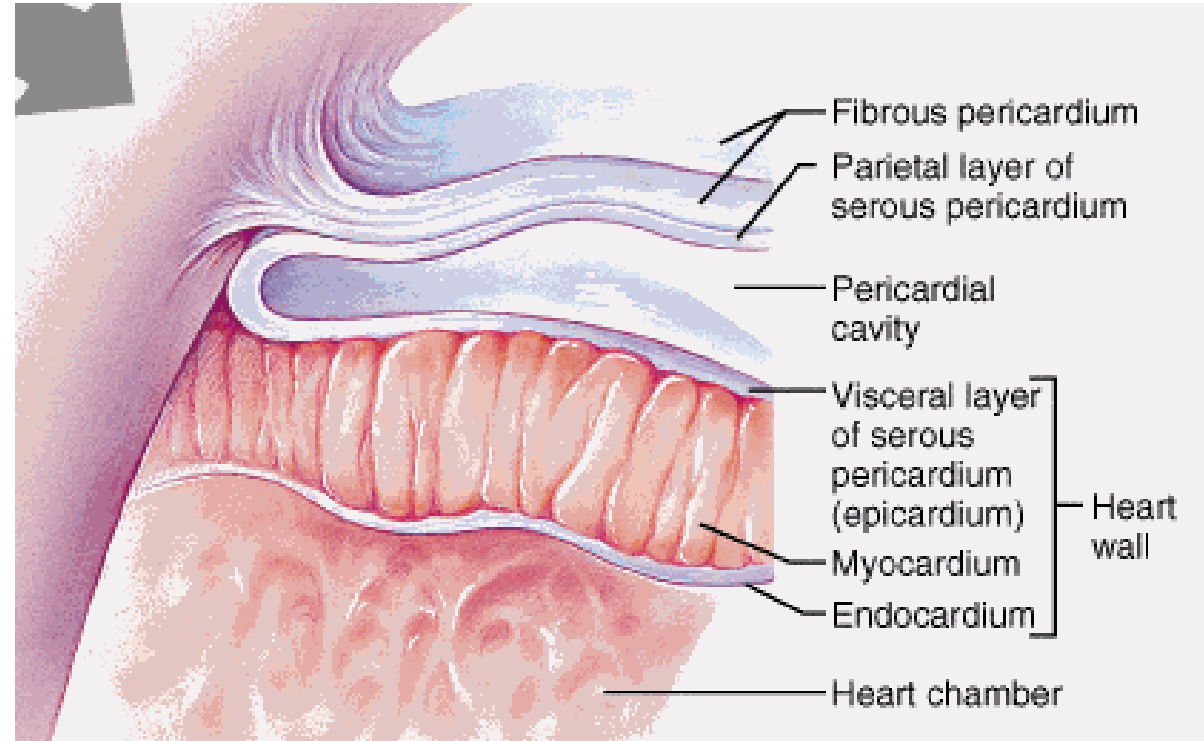


Failure of the aortic valve to close tightly causes back flow of blood into the left ventricle



The structure of the heart

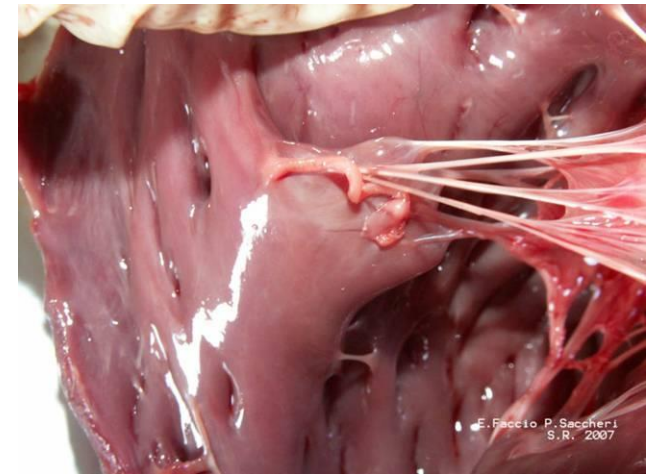
1. Endocardium
2. Myocardium
 - A. working
 - B. conductive
3. Pericardium



1. Endocardium

Thin, smooth and glossy fibrous membrane

Covers all cardiac chambers and surface of all the valves



2. Myocardium

Main component of the cardiac wall

working myocardium (contractions of cardiac compartments)

conductive myocardium (conductive system of heart)

A) Working myocardium: (muscles of atriums and muscles of ventricles are separated)

a) Muscles of atriums– 2 layers, spf. layer – common for both atriums, deep layer- separate

b) Muscles of ventricles (thicker)

3 layers:

- Superficial layer: common, arranged into bands which create whirl (*vortex cordis*)
- middle layer is separate, bands oriented circularly
- deep layer organized in reticular arrangement, forms underlay of mm. papillares and trabecular system

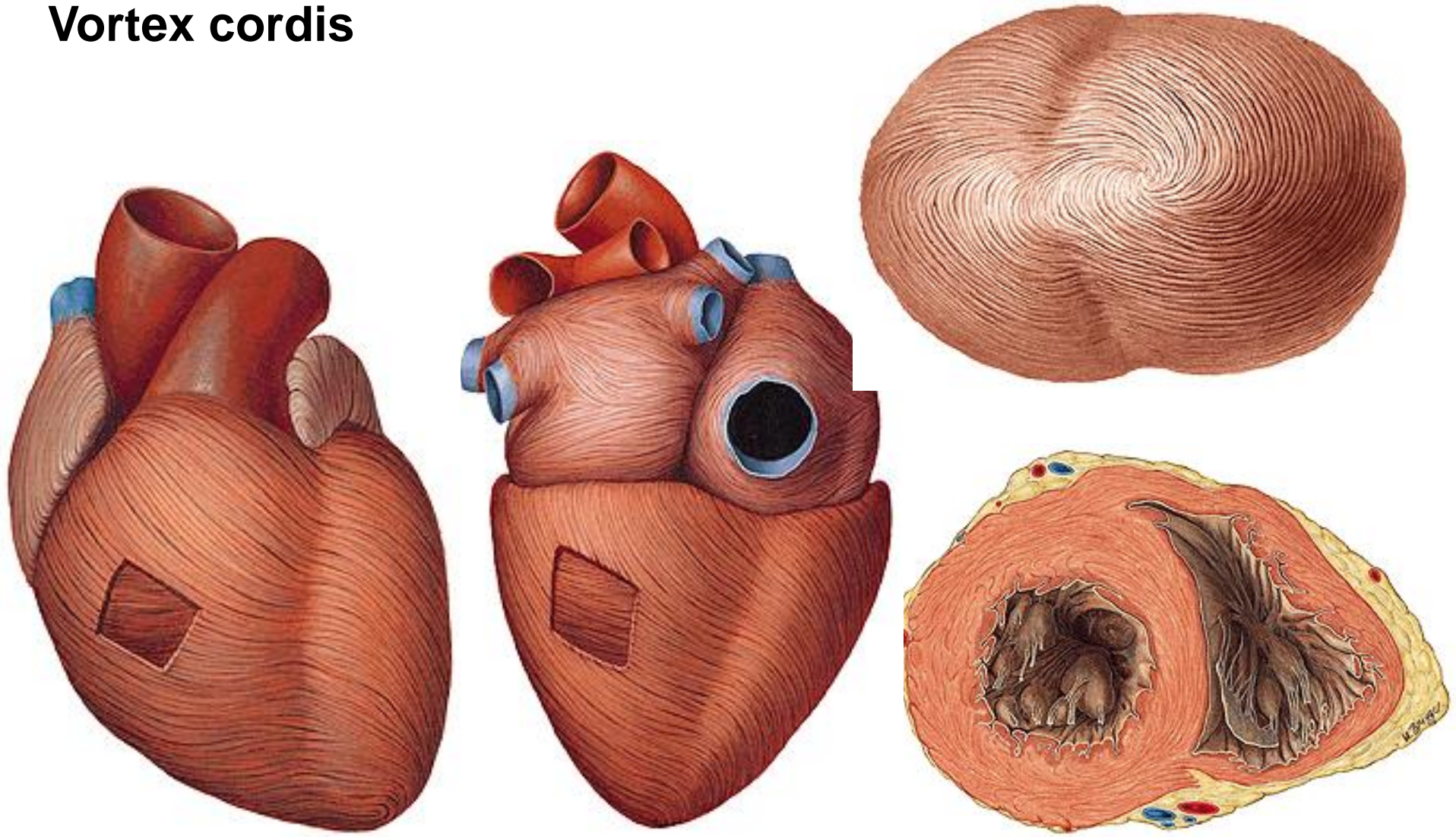
muscles of atriums and ventricles are separated by cardiac skeleton !

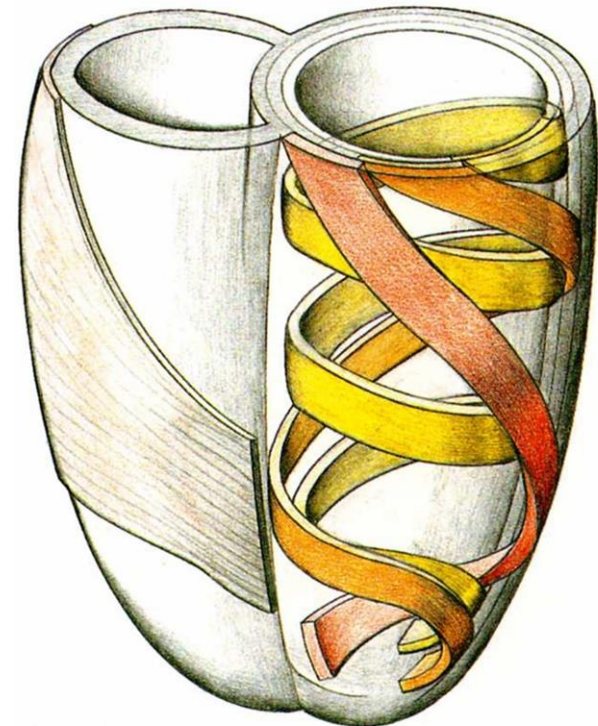
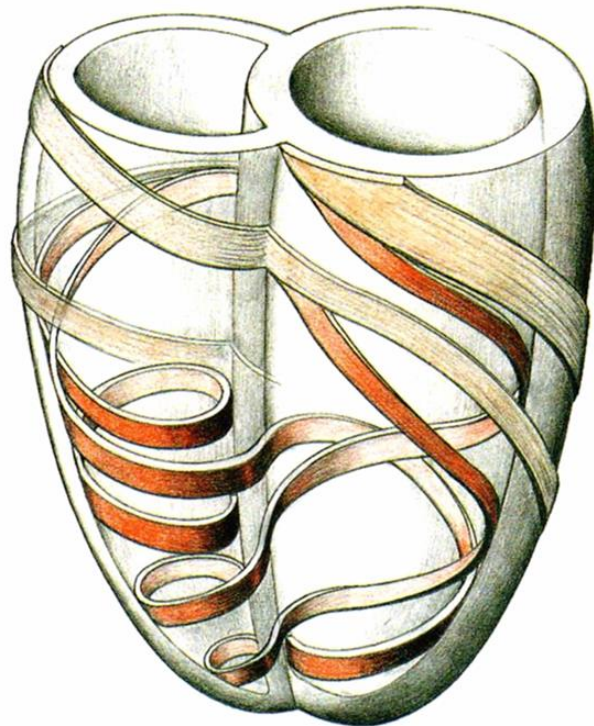
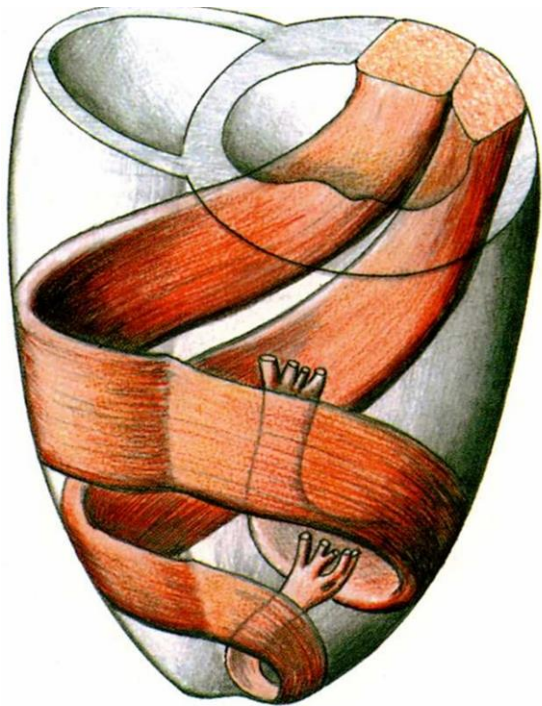
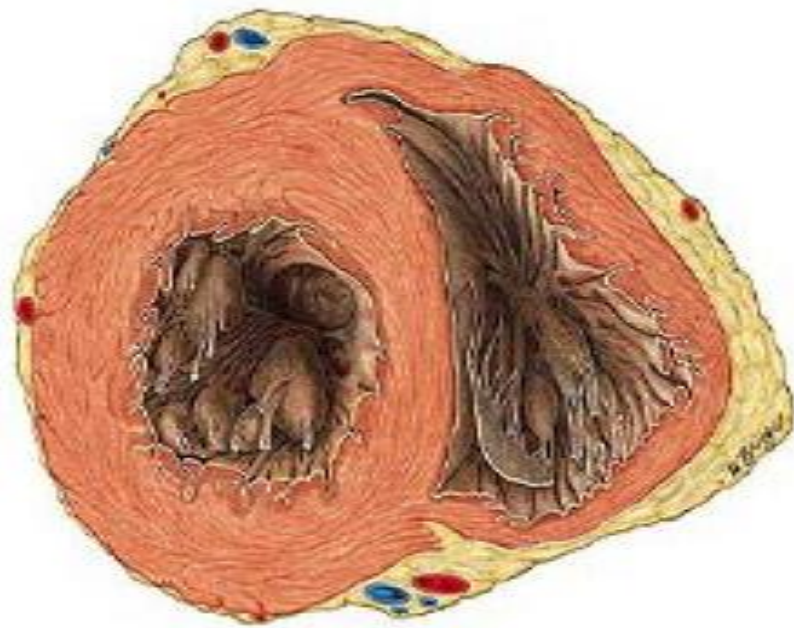
MYOCARDIUM

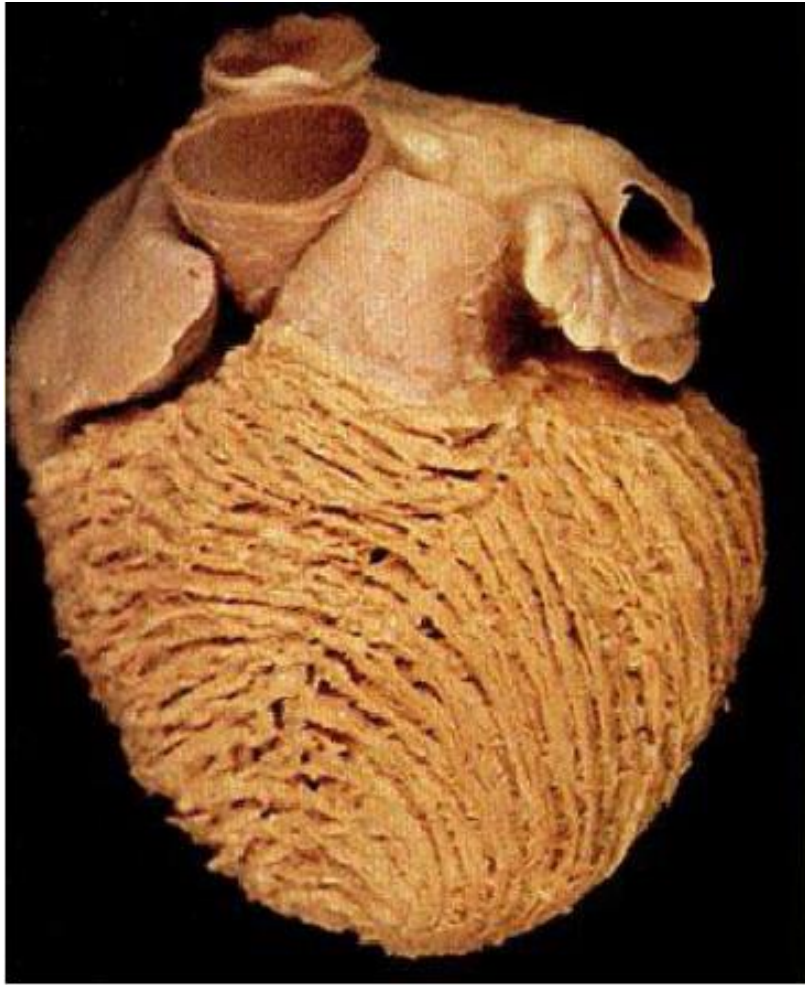
Mm. pectinati

Trabeculae carneae, mm. papillares

Vortex cordis





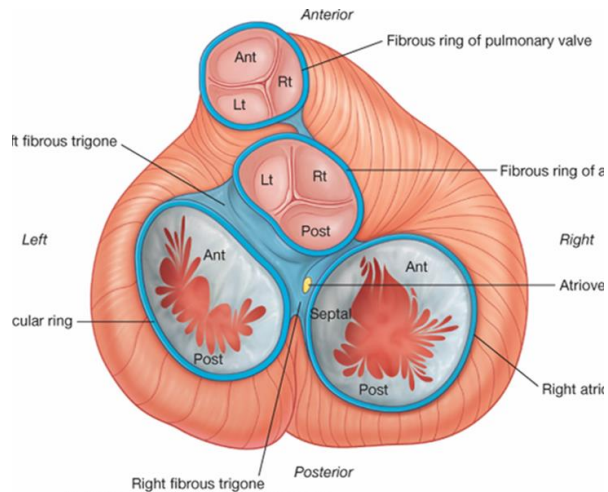


The fibrous skeleton of the heart

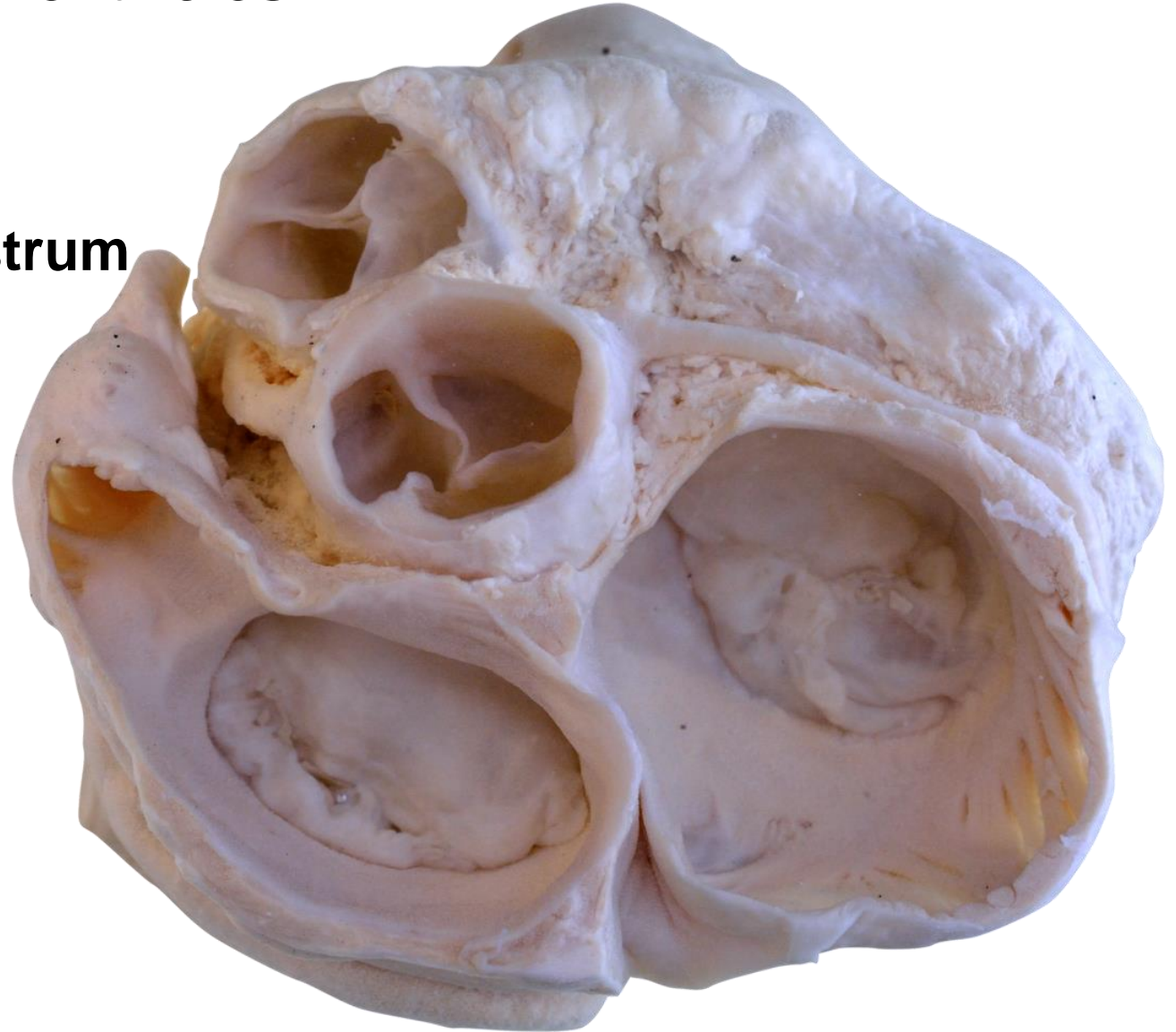
Consists of fibrous connective tissue (forms fibrous arches, anuli fibrosi), on borderline between atrias and ventricles

Anulus fibrosus dexter, sinister,
aorticus, trunci pulmonalis

Trigonum fibrosum dextrum et sinistrum

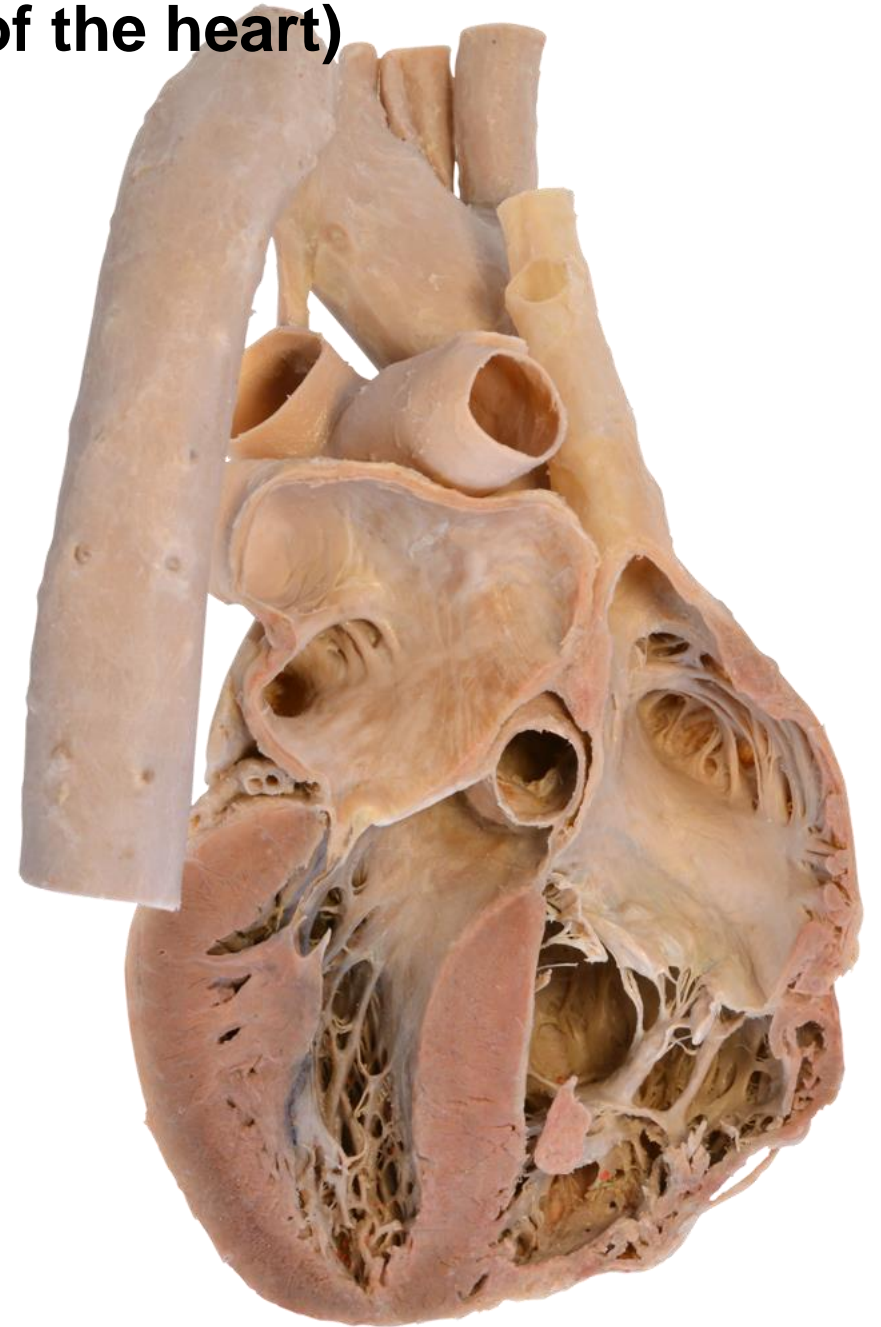
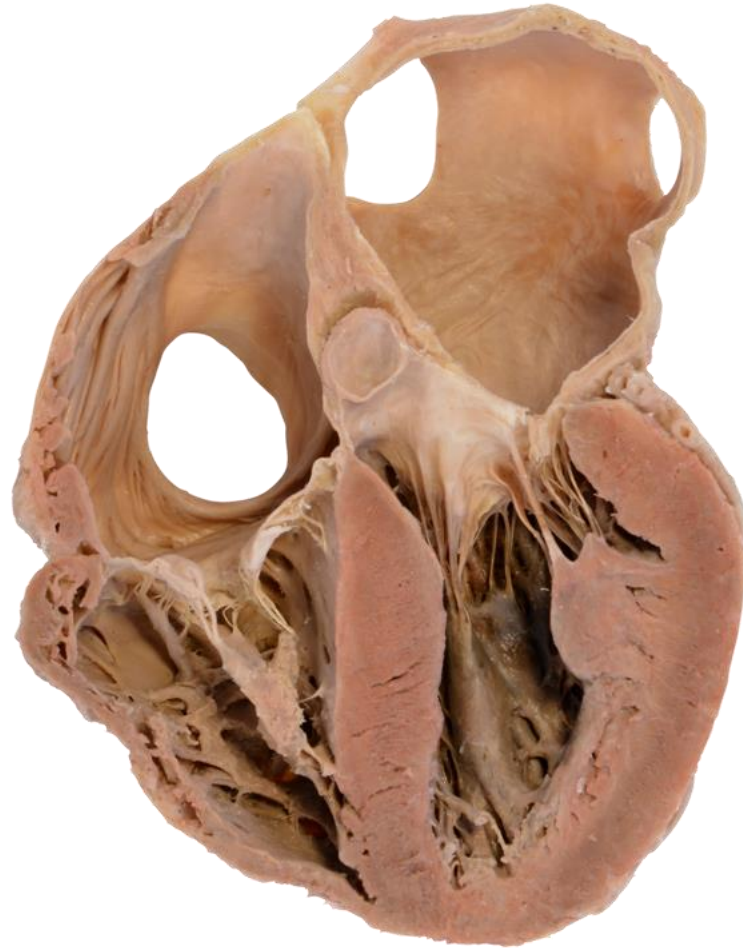
Drake: Gray's Anatomy for Students, 2nd Edition.
Copyright © 2009 by Churchill Livingstone, an imprint of Elsevier, Inc. All rights reserved.

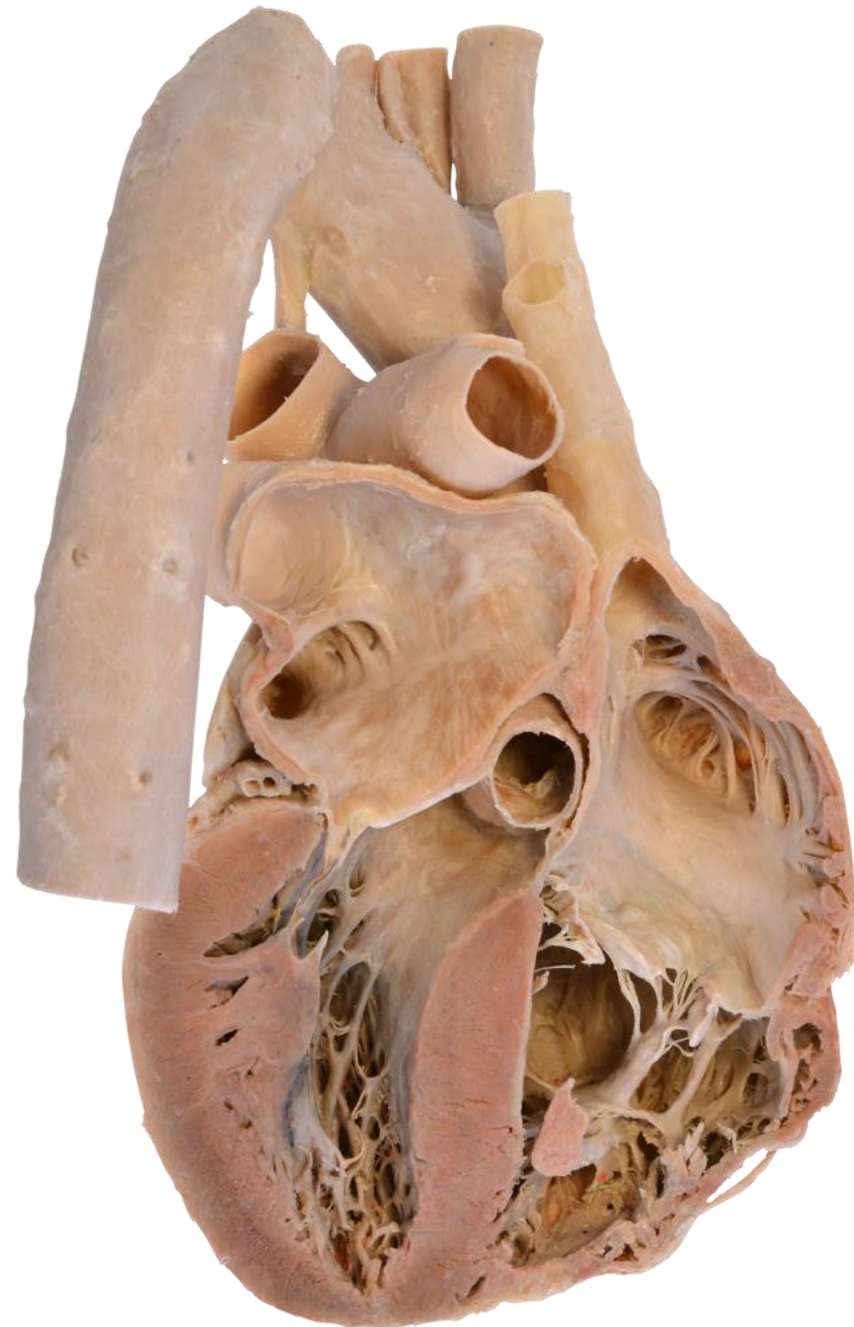
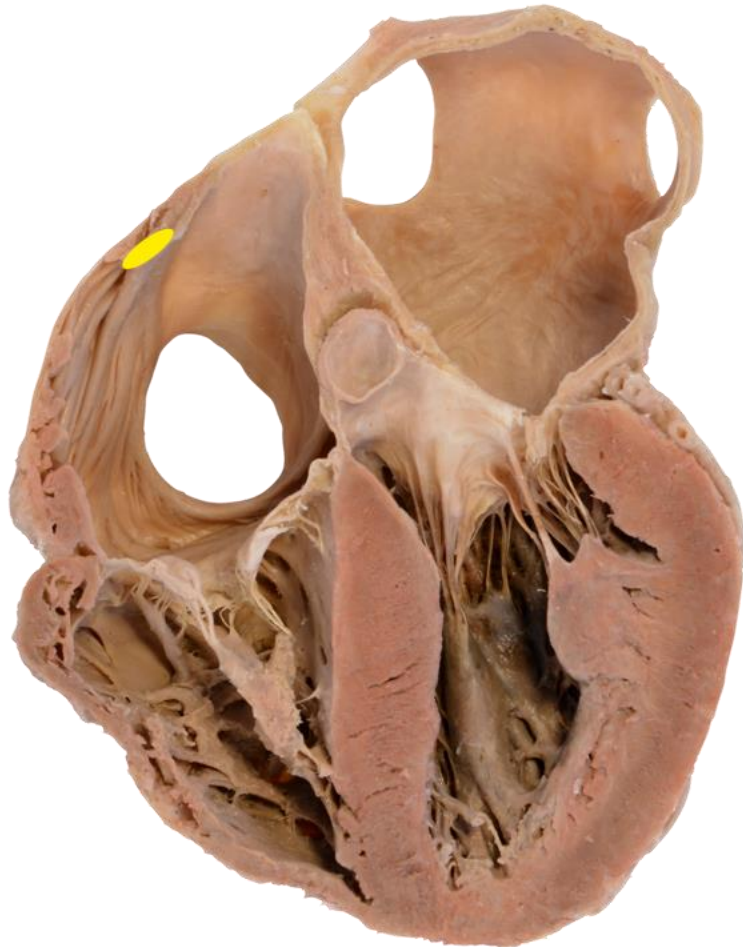
**B) Conductive myocardium (conductive system of the heart)
(Complexus stimulans cordis)**

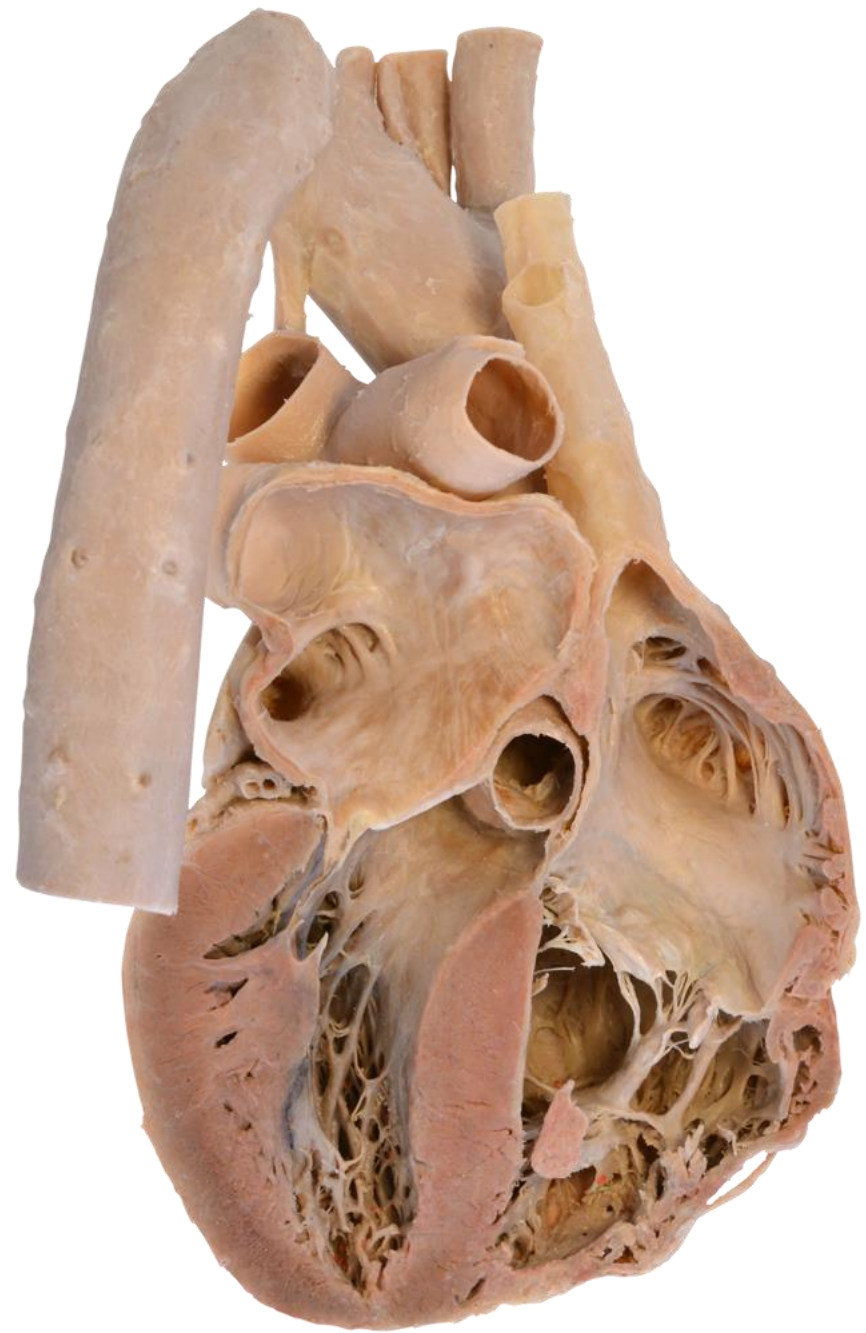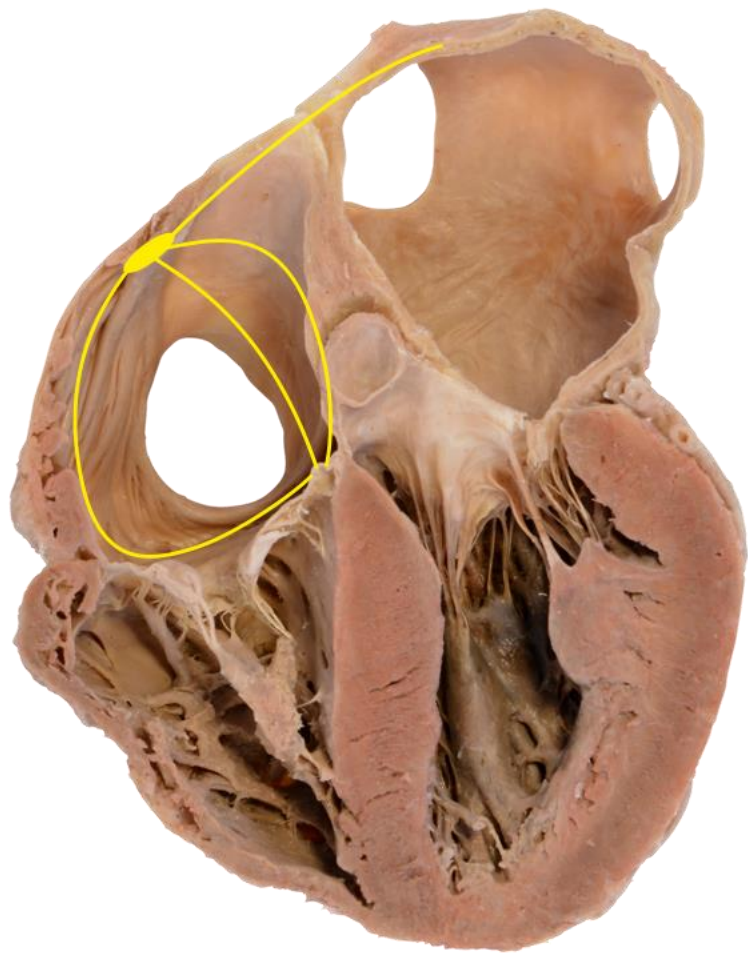
**Consists of an unique type of myocardium,
its cells generate impulses which are stimuli
for the muscular contractions**



Nodus sinuatrialis in the right atrium– generates impulses (70/min)

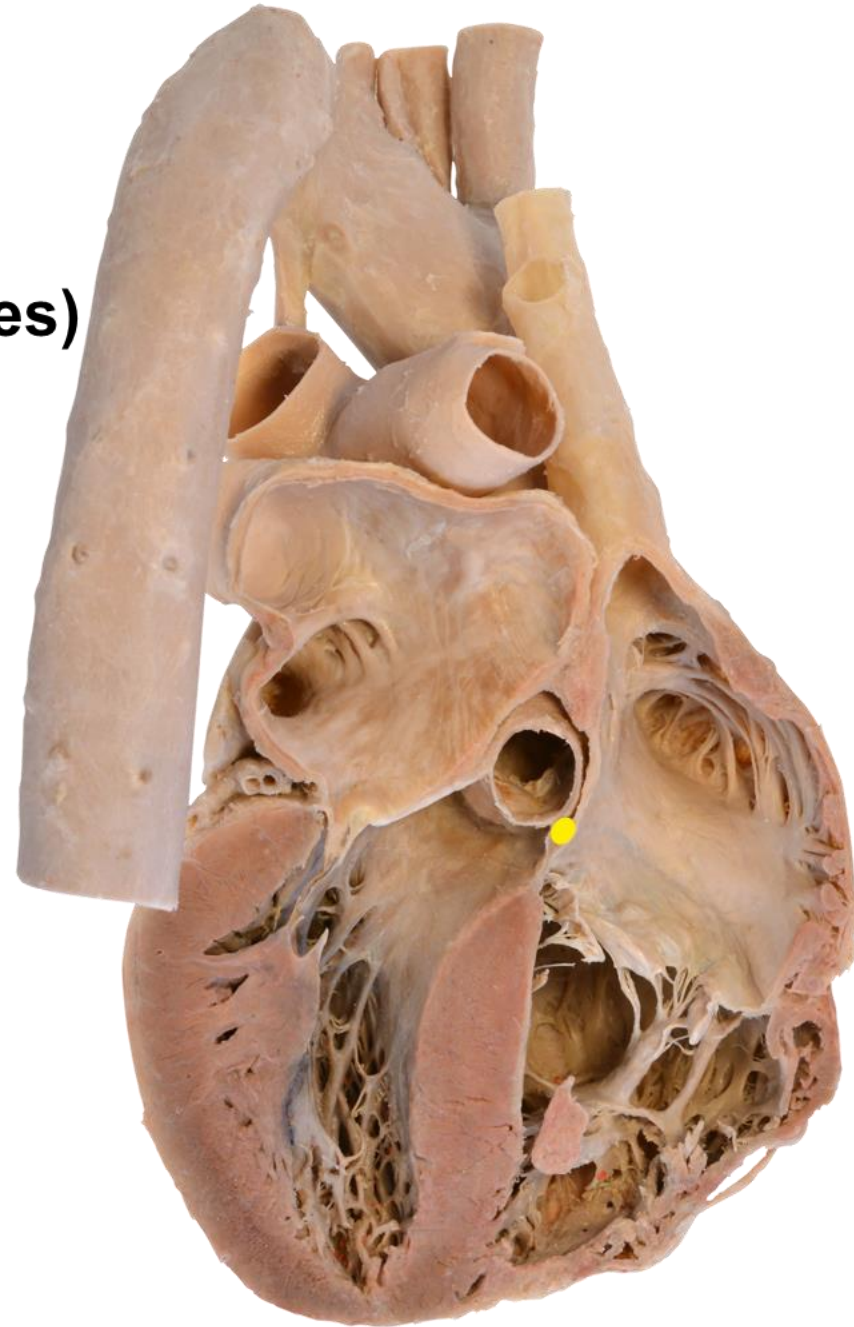
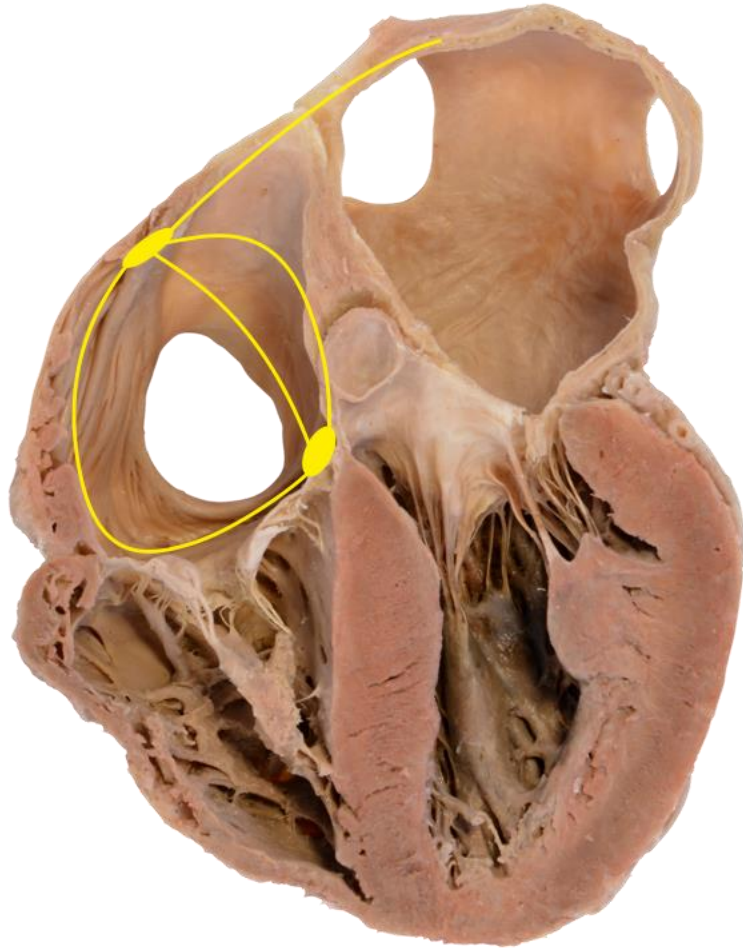


Bachmann interatrial, anterior, middle and posterior internodal tracts)

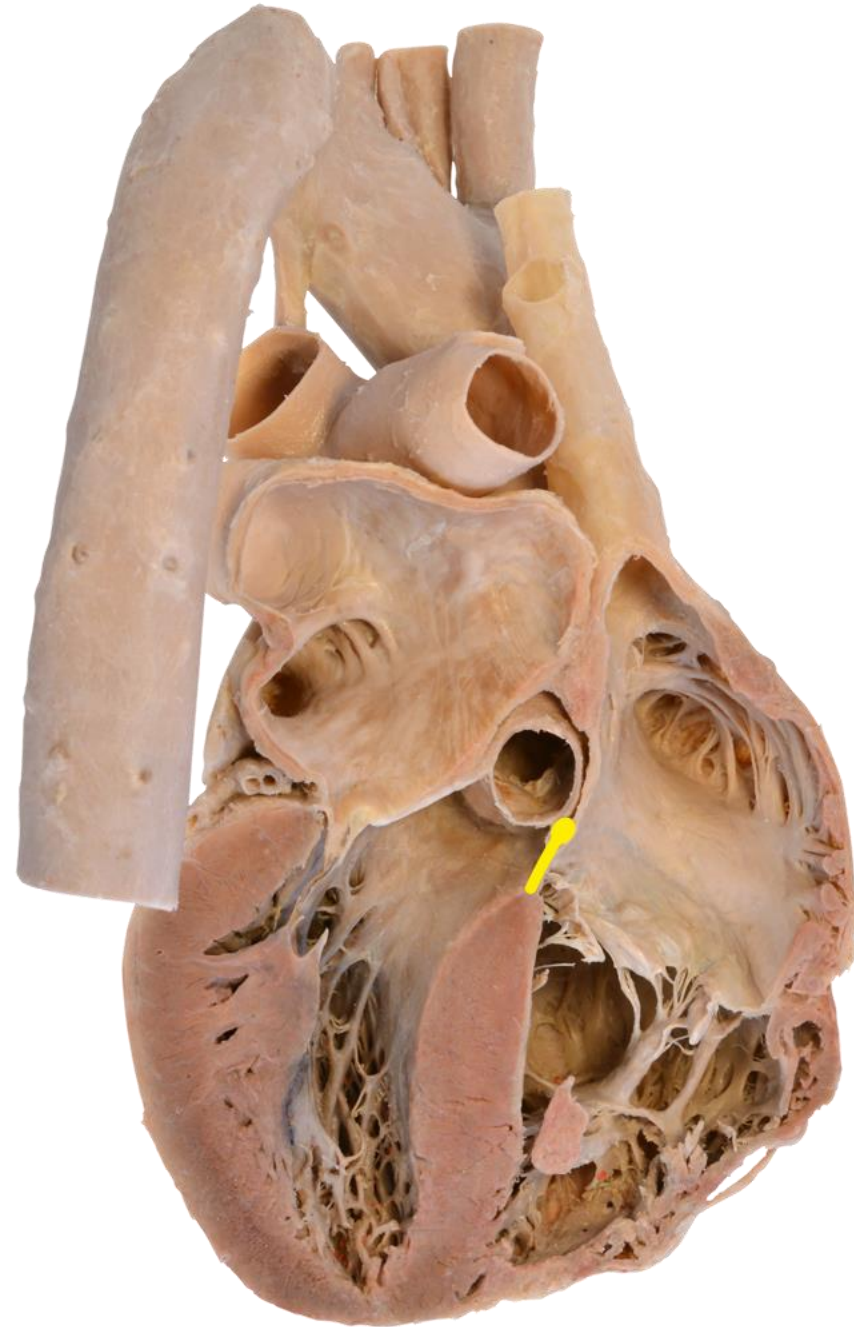
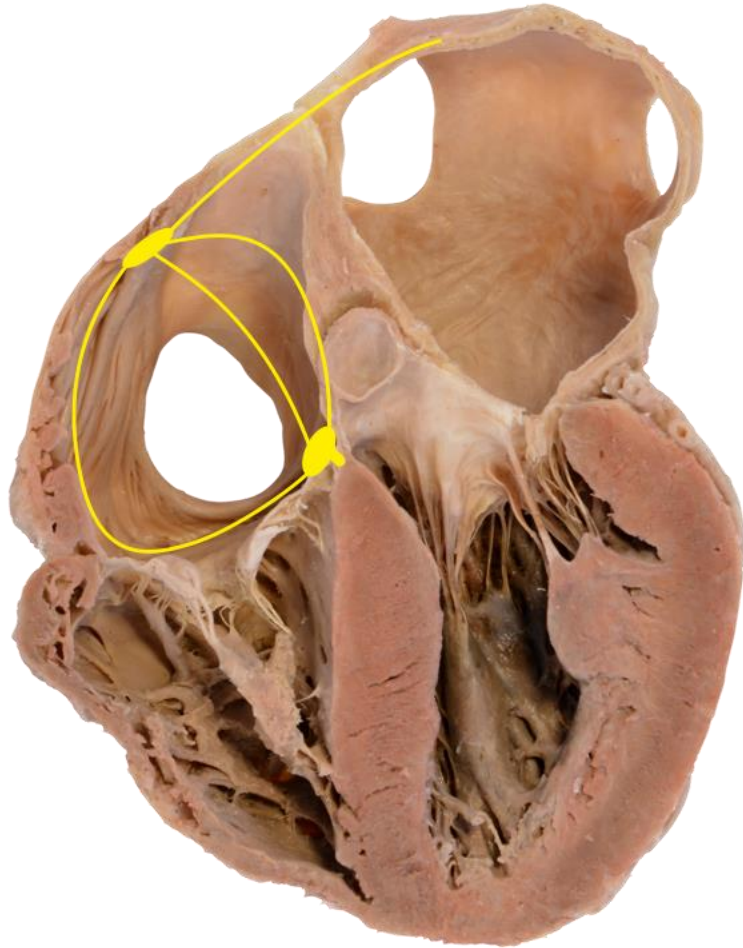


Nodus atrioventricularis in the right atrium under the endocardium of septum

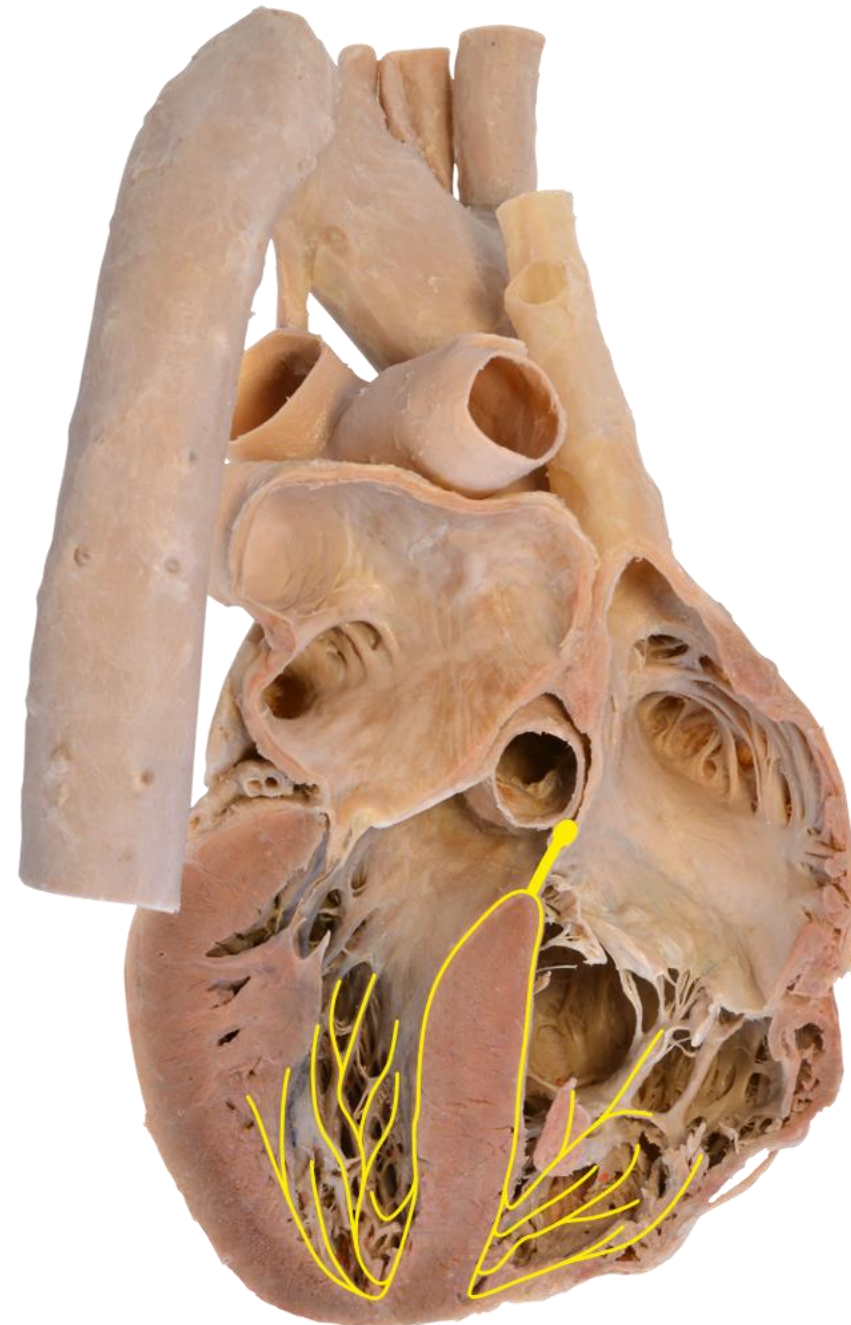
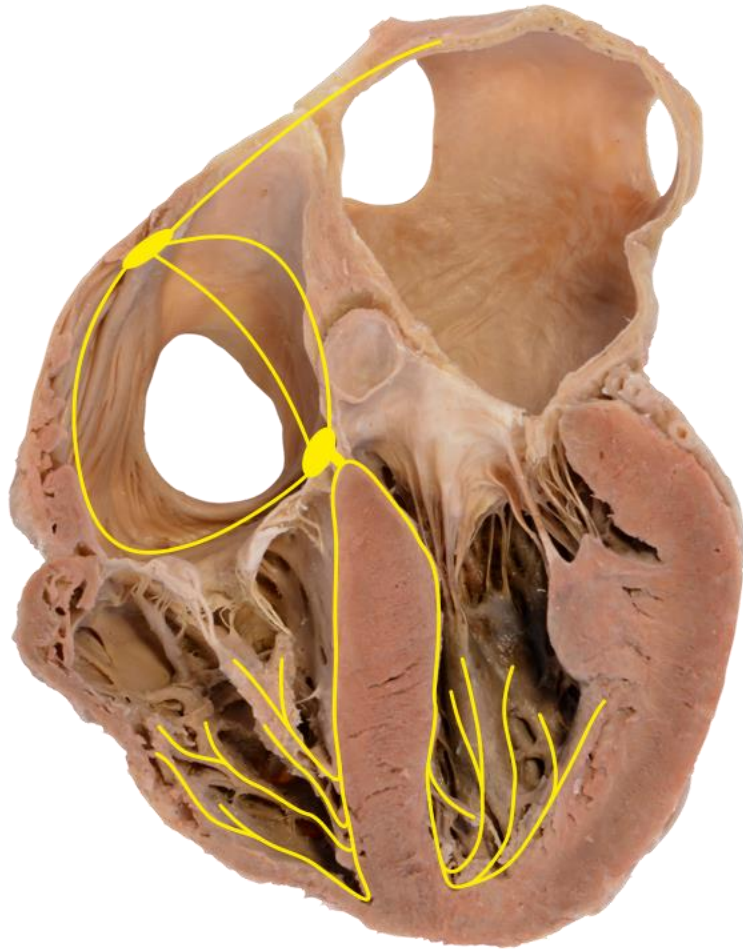
(accessory AV connections – Kent fibres)



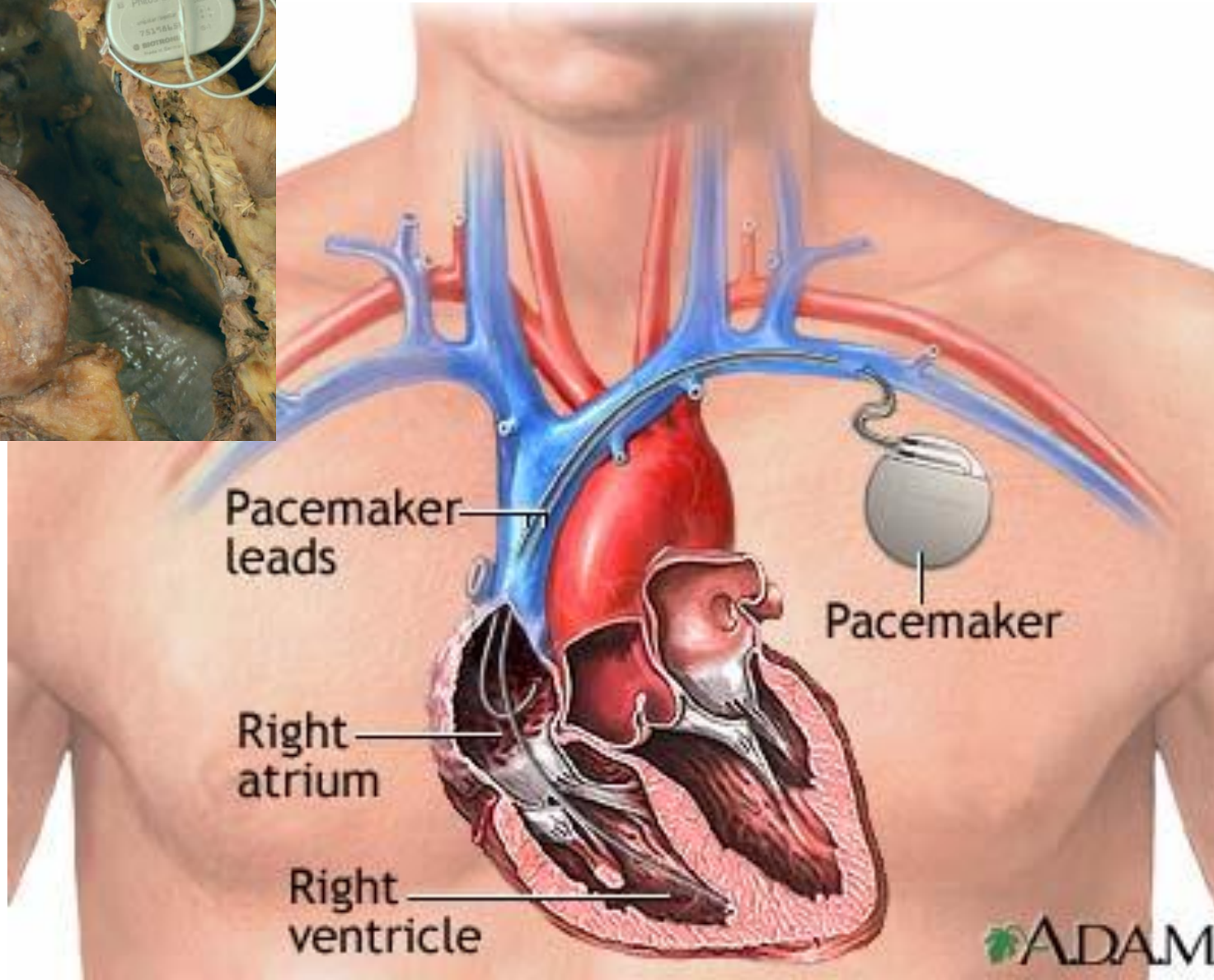
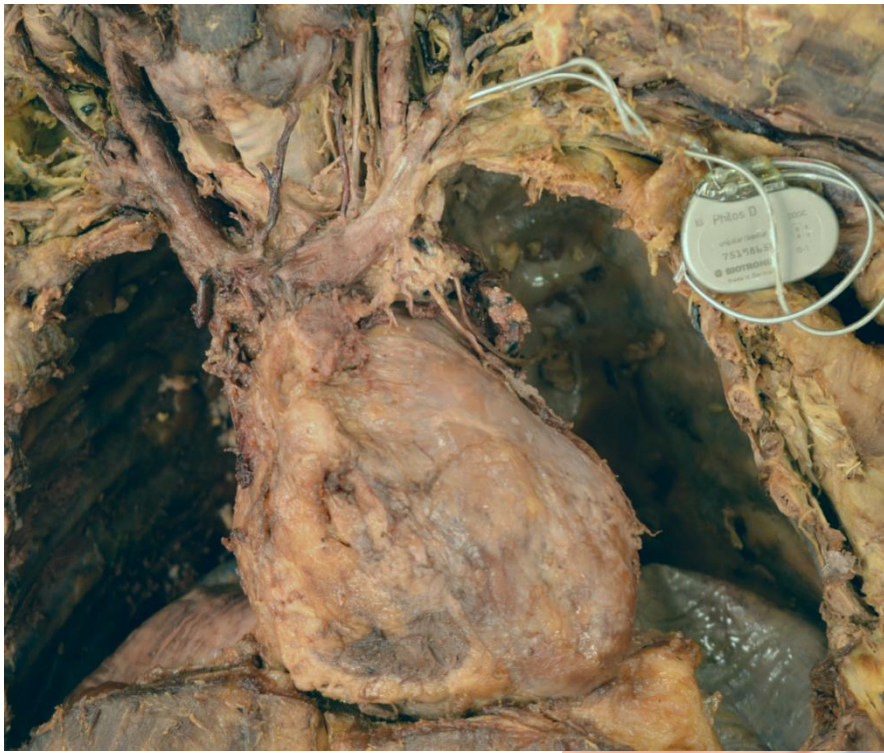Fasciculus atrioventricularis (His)
passes through aperture in
trigonum fibrosum dextrum
into interventricular septum
and divides into two branches



Crus dextrum et crus sinistrum –
head toward myocardium of
right and left ventricle
Purkyně (Purkinje) fibres create
large subendocardial net

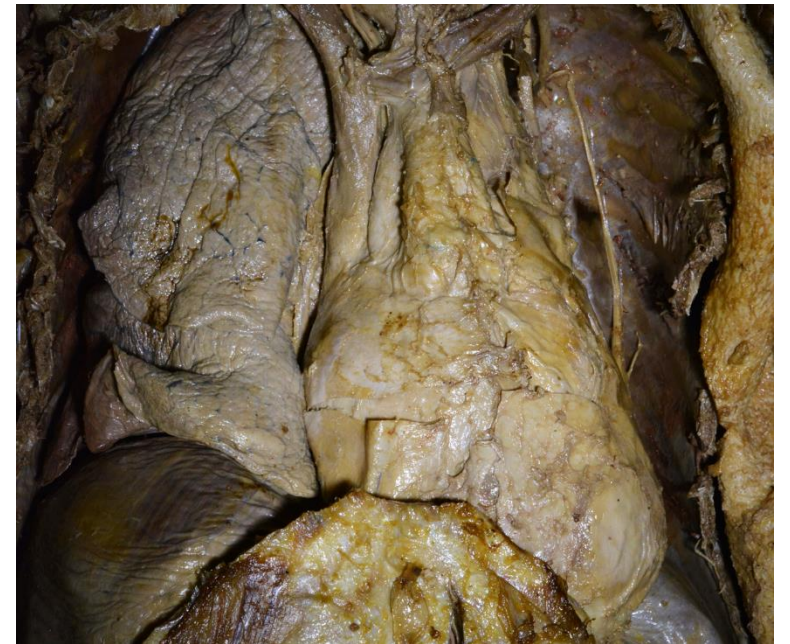
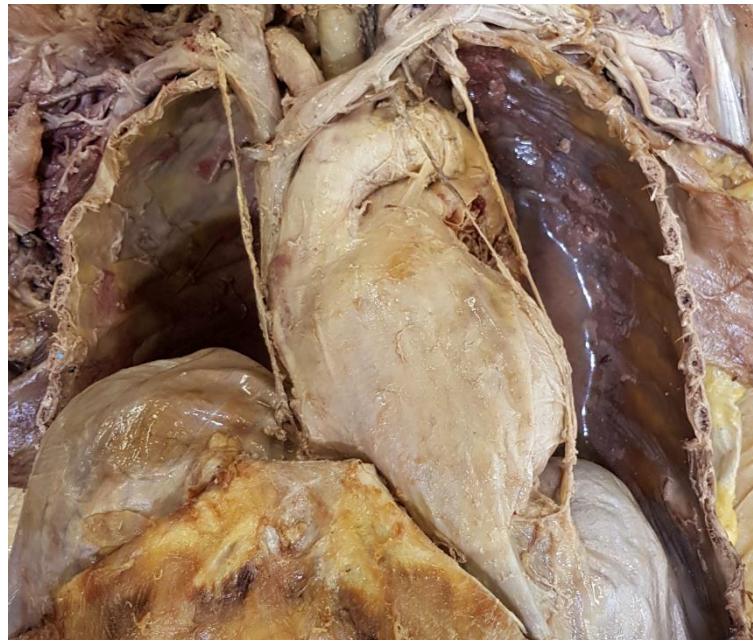
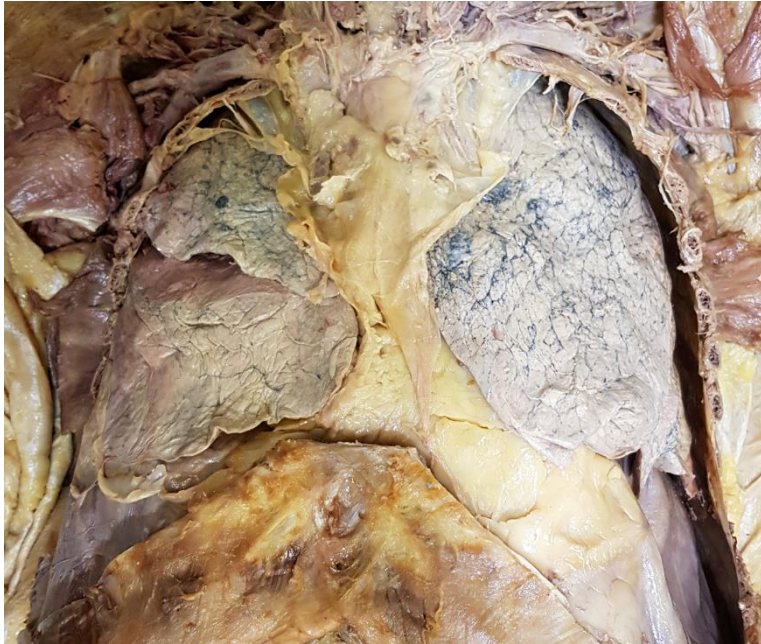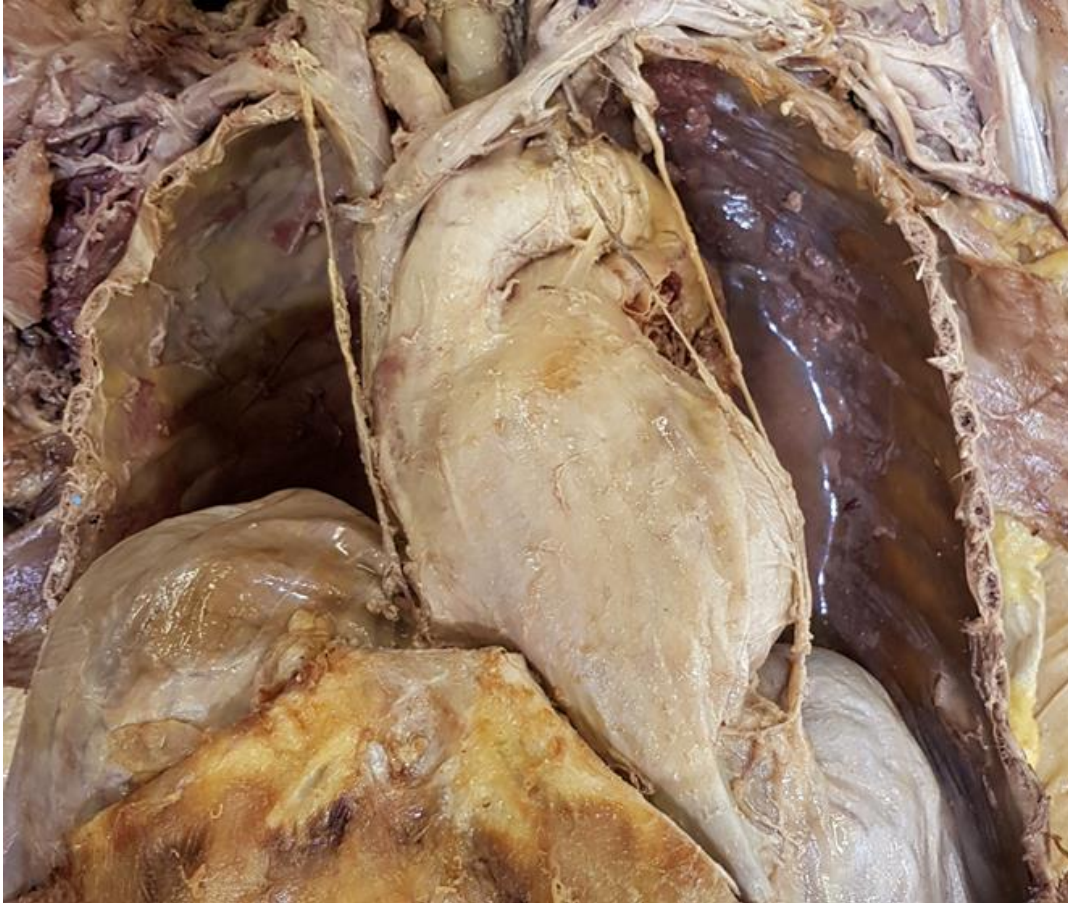Artificial pacemaker



3. The Pericardium

The heart is stored in a firm fibrous sac, it has two layers:
external layer– *pericardium fibrosum*
internal layer– *pericardium serosum*





PERICARDIUM FIBROSUM

- **basis (facies diaphragmatica)**
- **cupula**
- **pars sternalis,**
- **partes laterales**
- **pars dorsalis**

Ligg. pericardiacophrenica

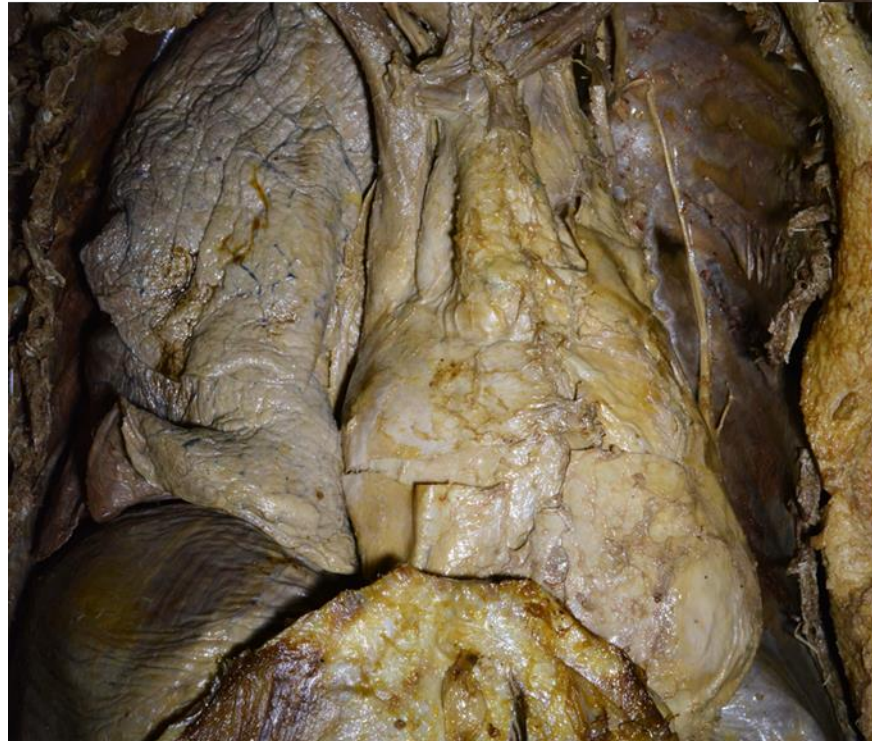
Ligg. sternopericardiaca

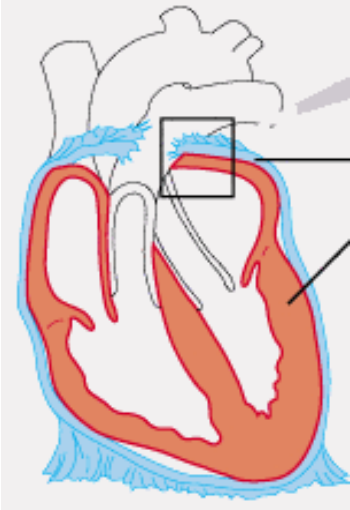
A. et v. pericardiacophrenica

N. phrenicus

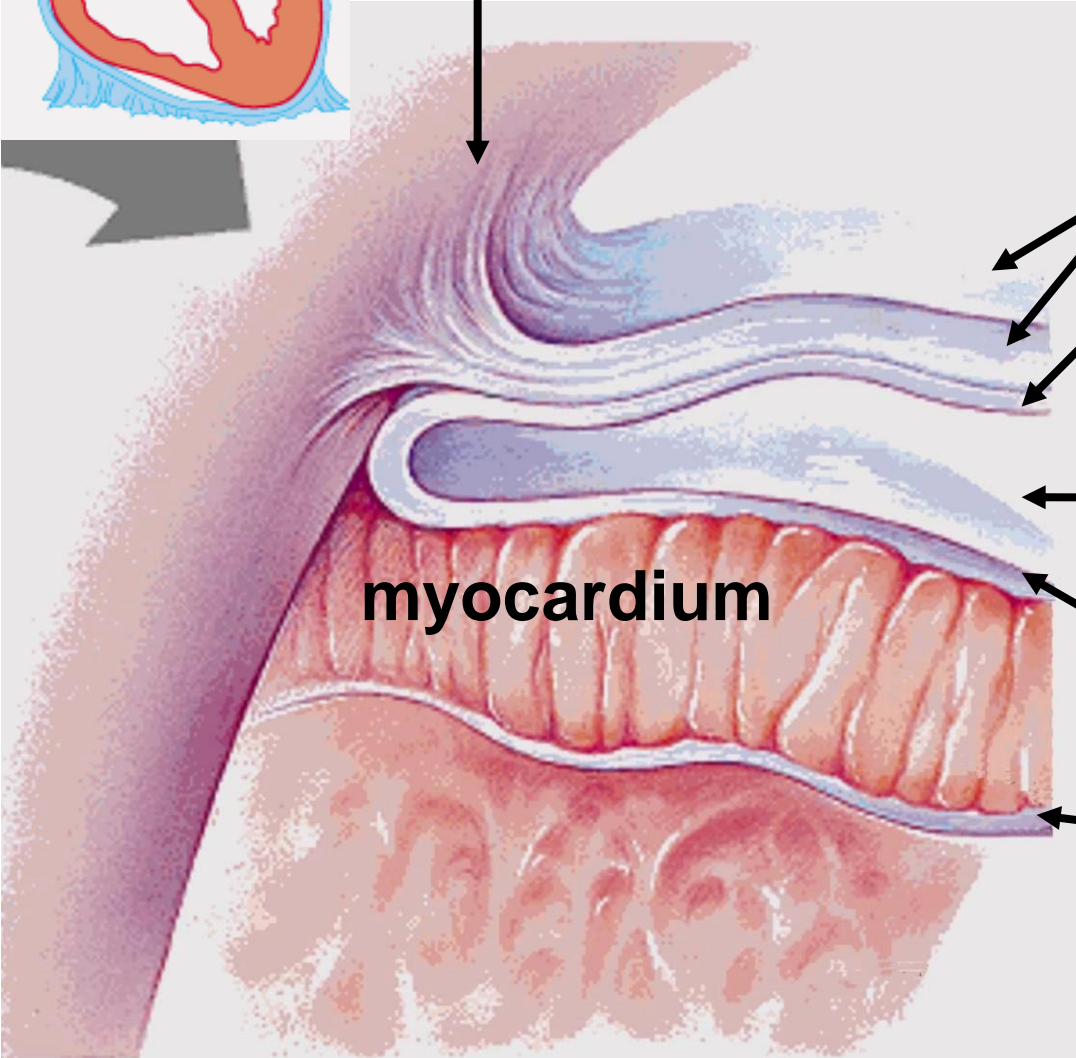
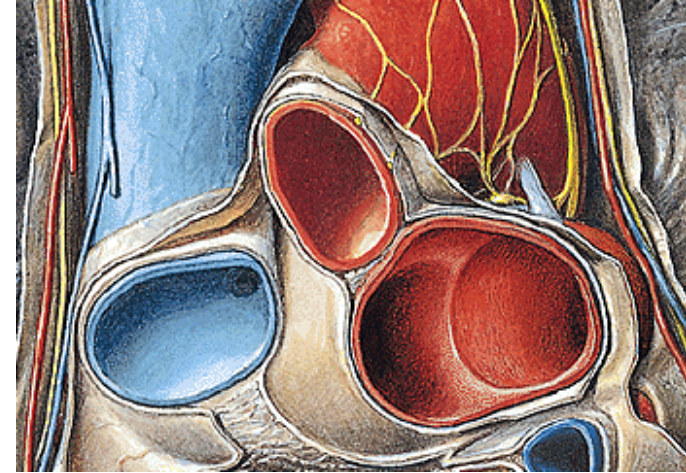
PERICARDIUM SEROSUM

- lamina parietalis
- lamina visceralis (epicardium)
- cavitas pericardii – liquor pericardii





truncus pulmonalis



pericardium fibrosum

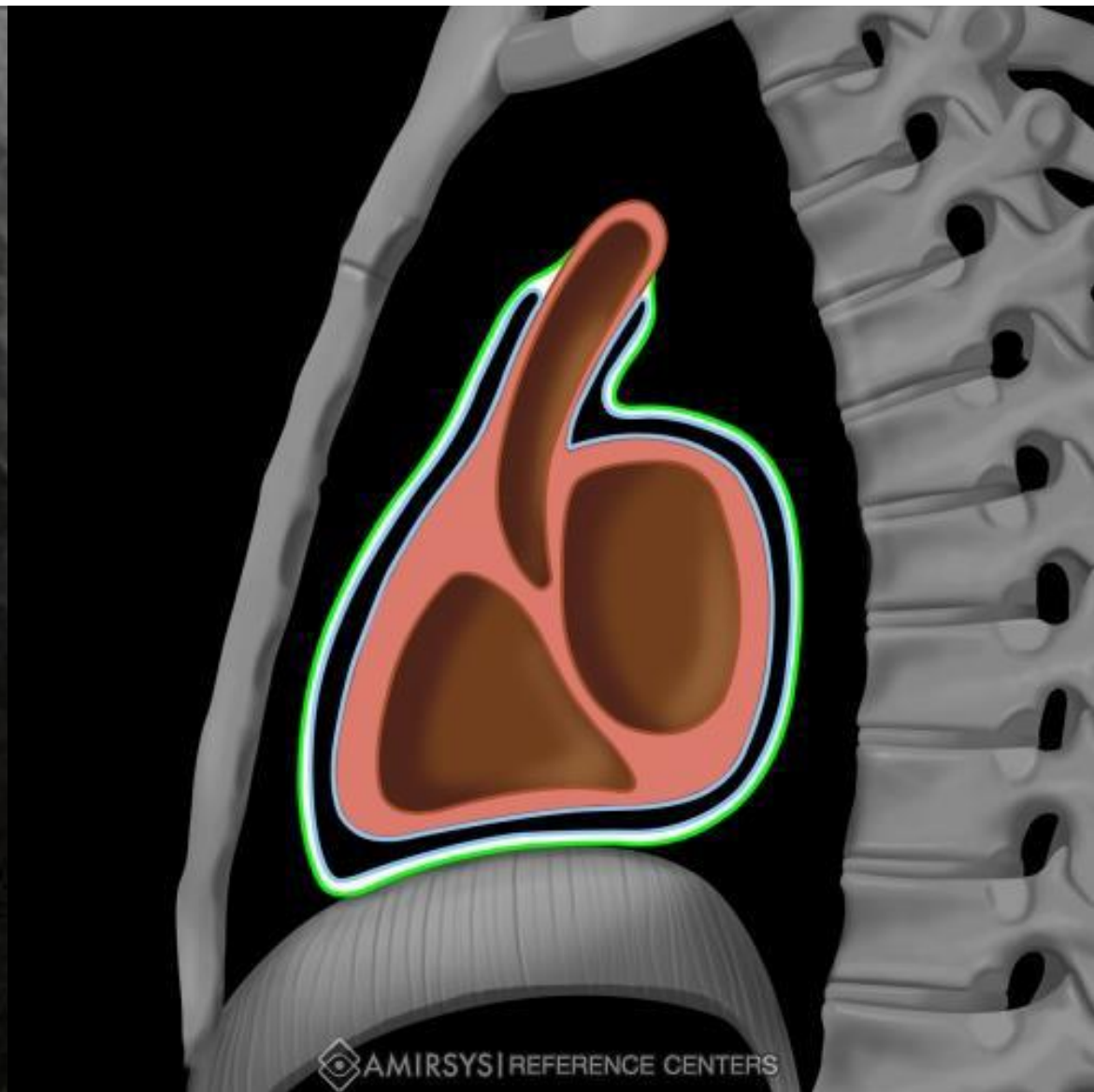
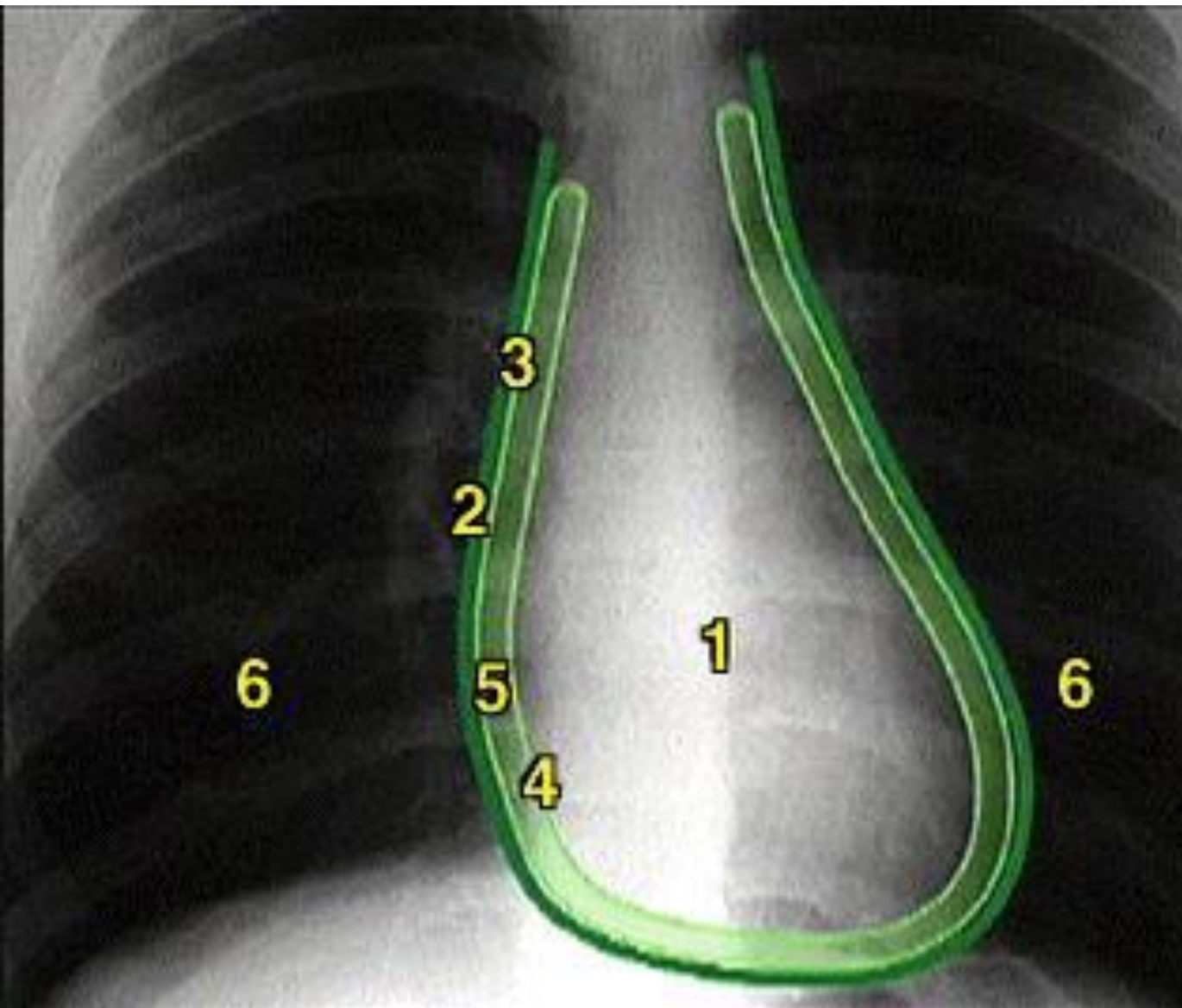
**pericardium serosum
(lamina parietalis)**

**cavum serosum
pericardii**

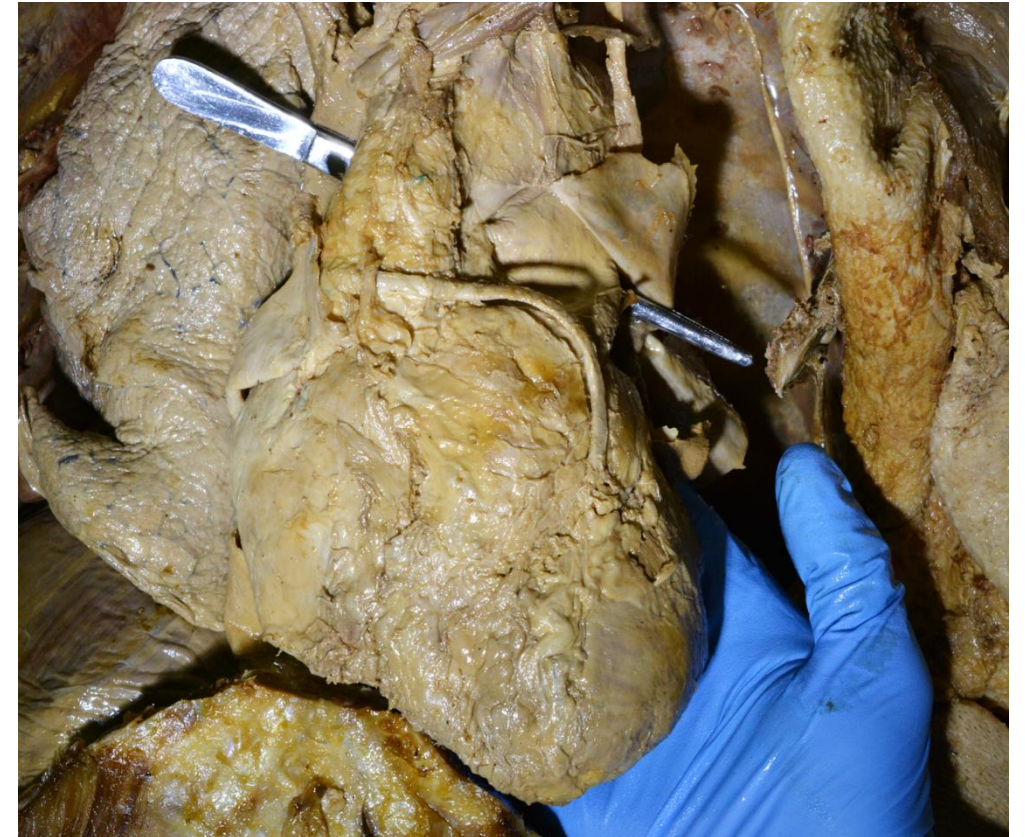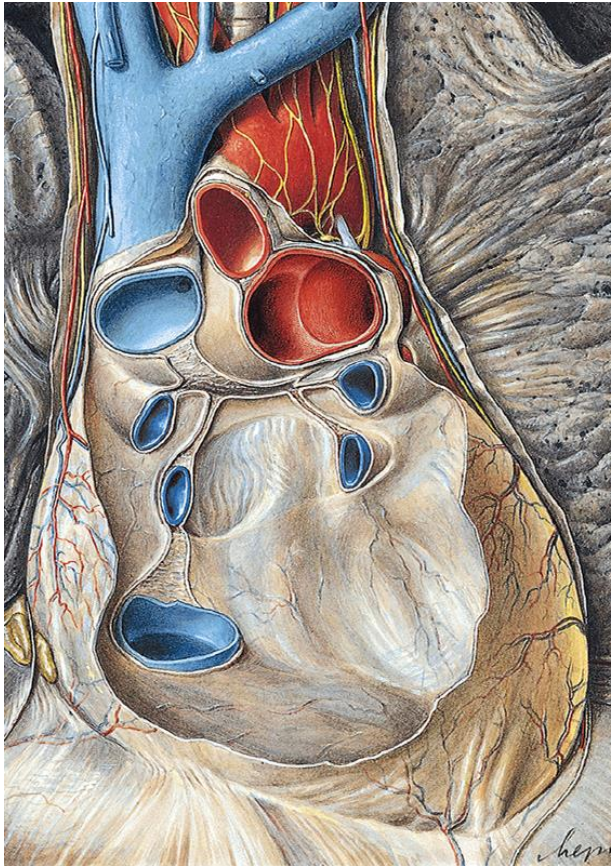
**pericardium serosum
(lamina visceralis)**

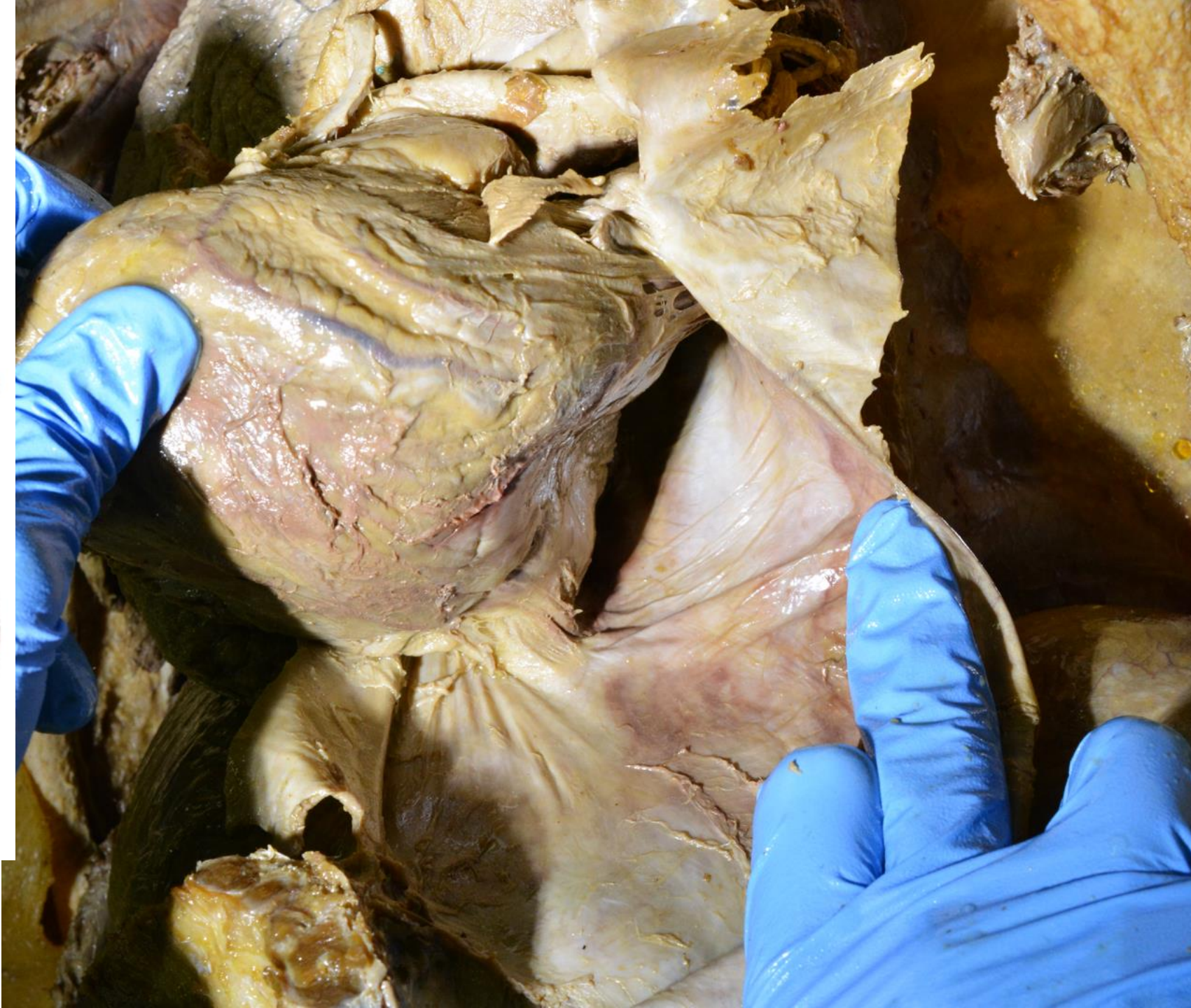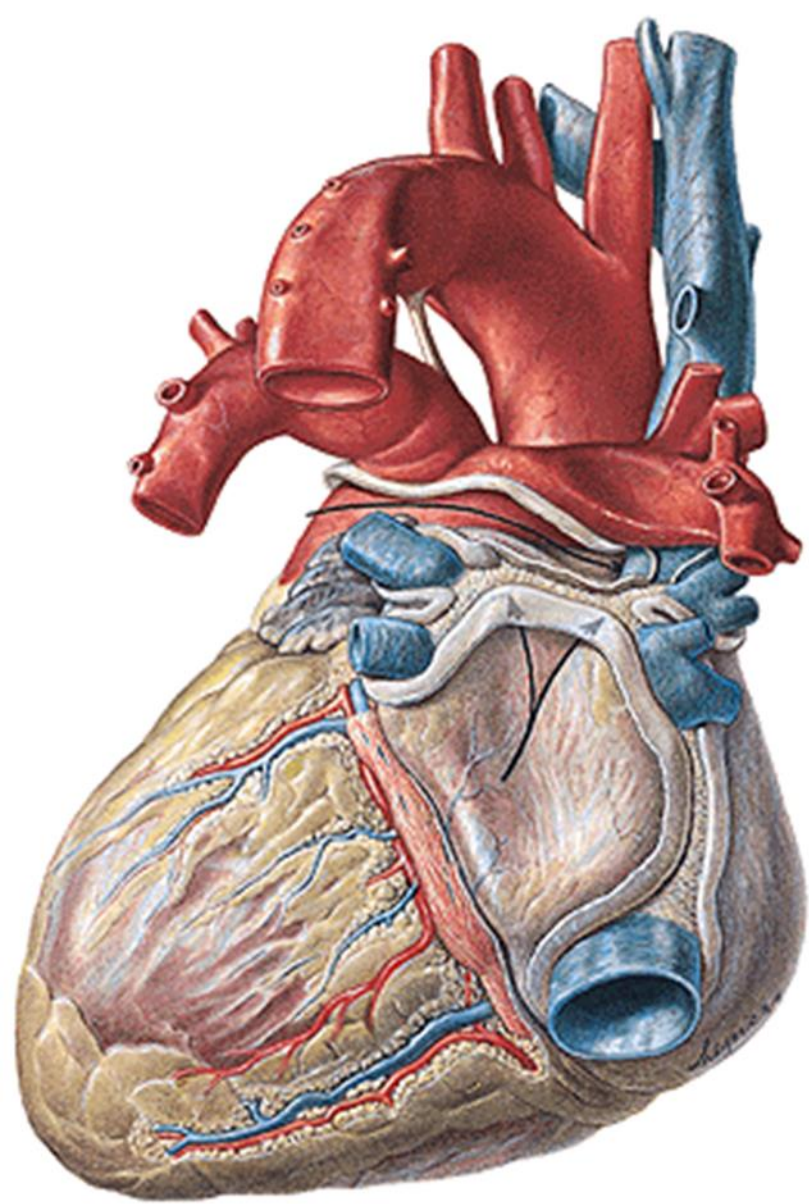
endocardium

myocardium



Both sheets pass into each other in two places:
porta arteriarum - sinus transversus pericardii
porta venarum - sinus obliquus pericardii



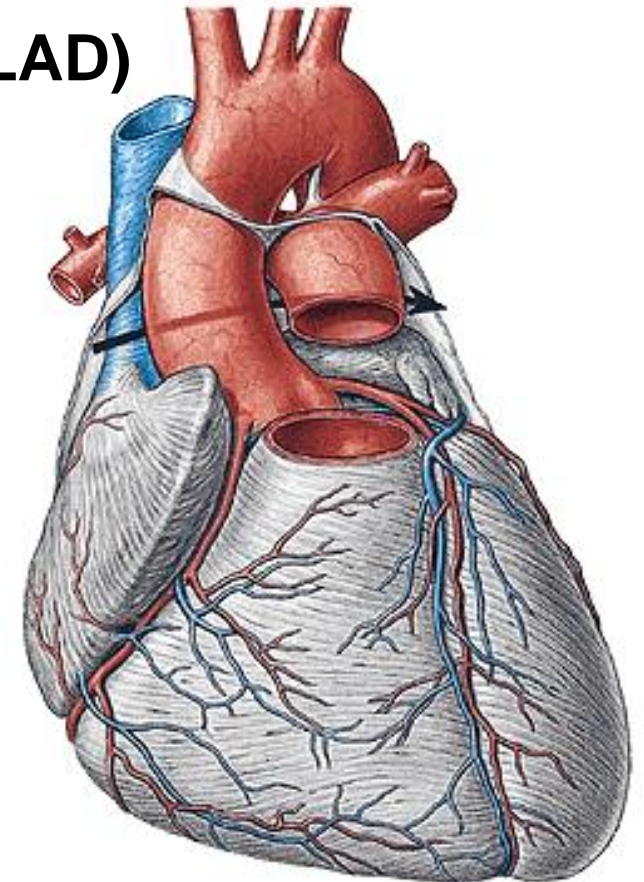
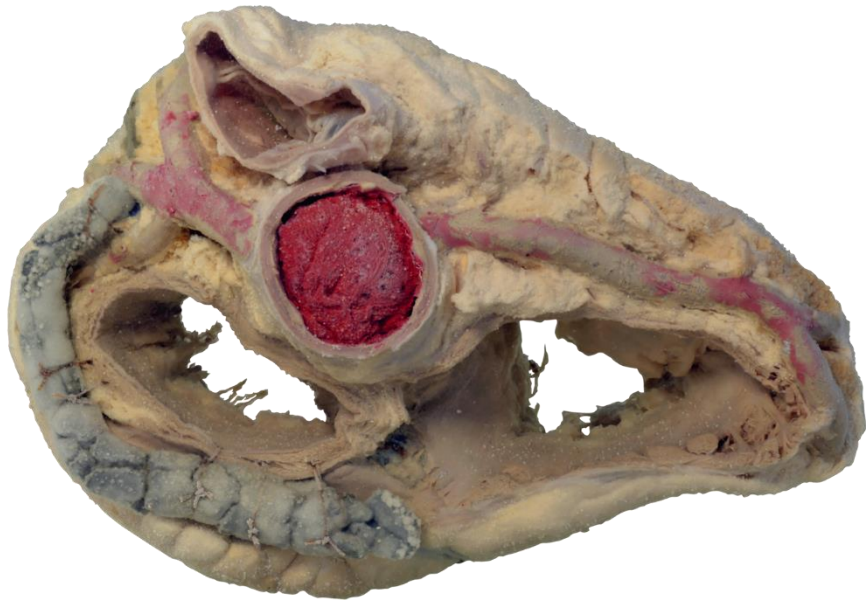

A. coronaria cordis dx. - rr. atriales

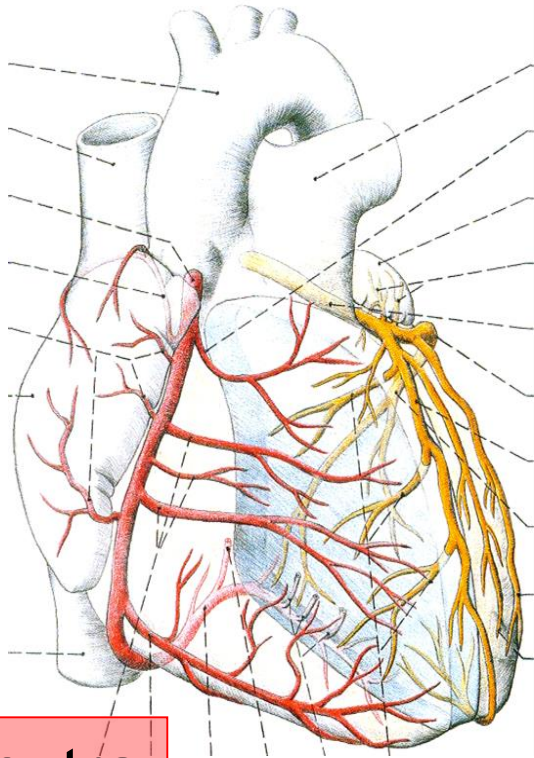
- rr. ventriculares
- r. marginalis dx.
- r. coni arteriosi
- r. nodi sinuatrialis
- r. nodi atrioventricularis
- **r. interventricularis post.**

A. coronaria cordis sin. - r. interventricularis ant. (LAD)

- **r. circumflexus**



A.c.c. sinistra



A.c.c. dextra

anterior

Arteria coronaria cordis sinistra



posterior

Arteria coronaria cordis dextra

Venae cordis

1. Sinus coronarius cordis

a) v. cordis magna

b) v. cordis media

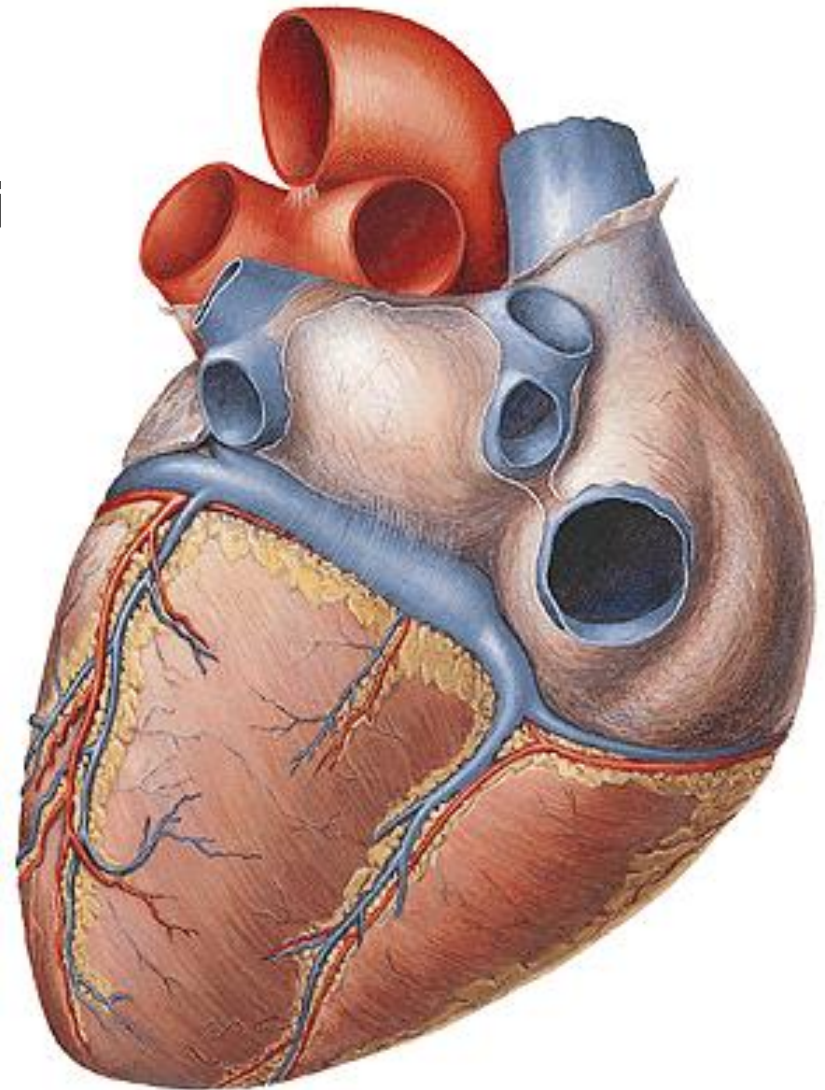
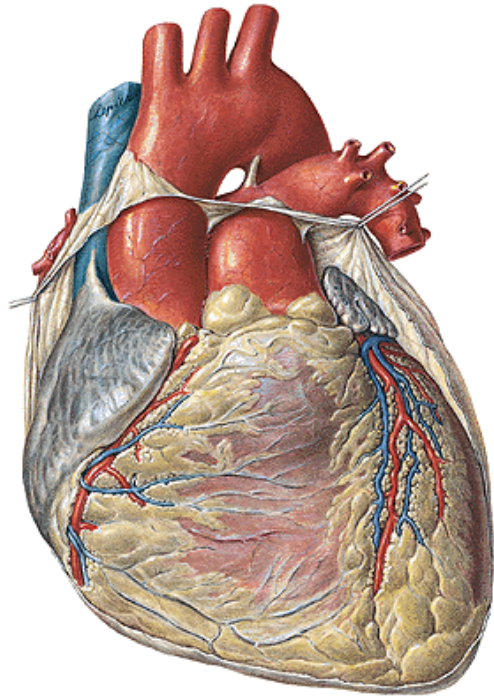
c) v. cordis parva

d) v. obliqua atrii sinistri

e) v. posterior ventriculi sinistri

2. Vv. cordis anteriores

3. Vv. cordis minimae



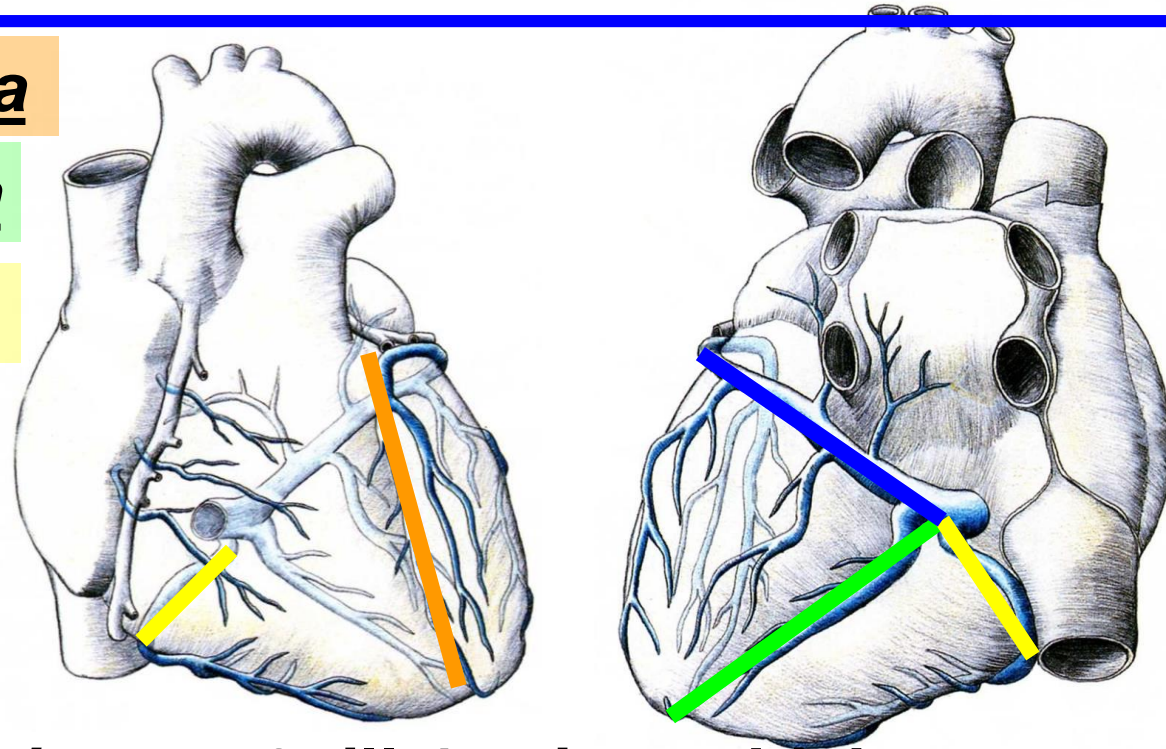
Venae cordis

1) sinus coronarius cordis (60% of the blood), confluence of:

a) vena cordis magna

b) vena cordis media

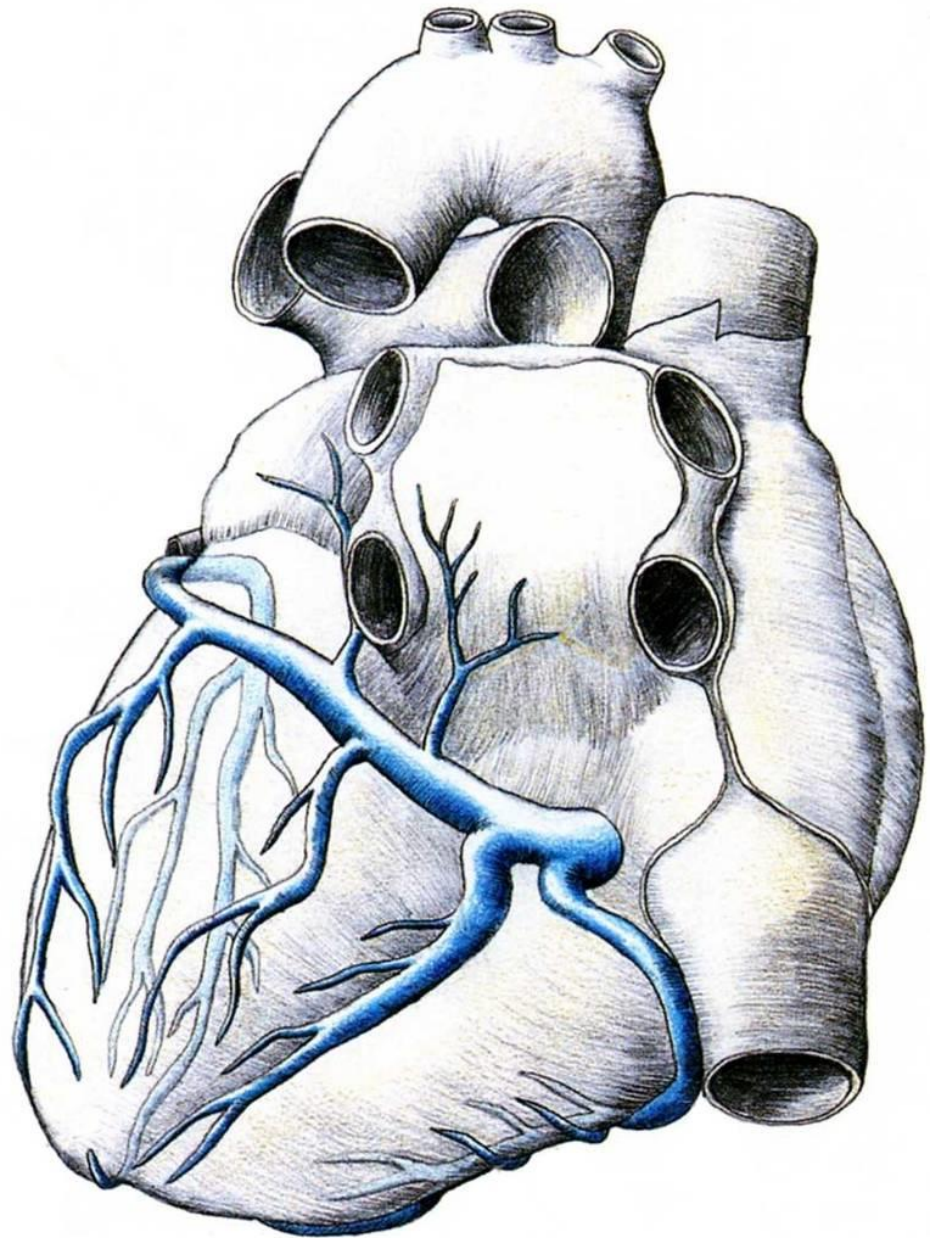
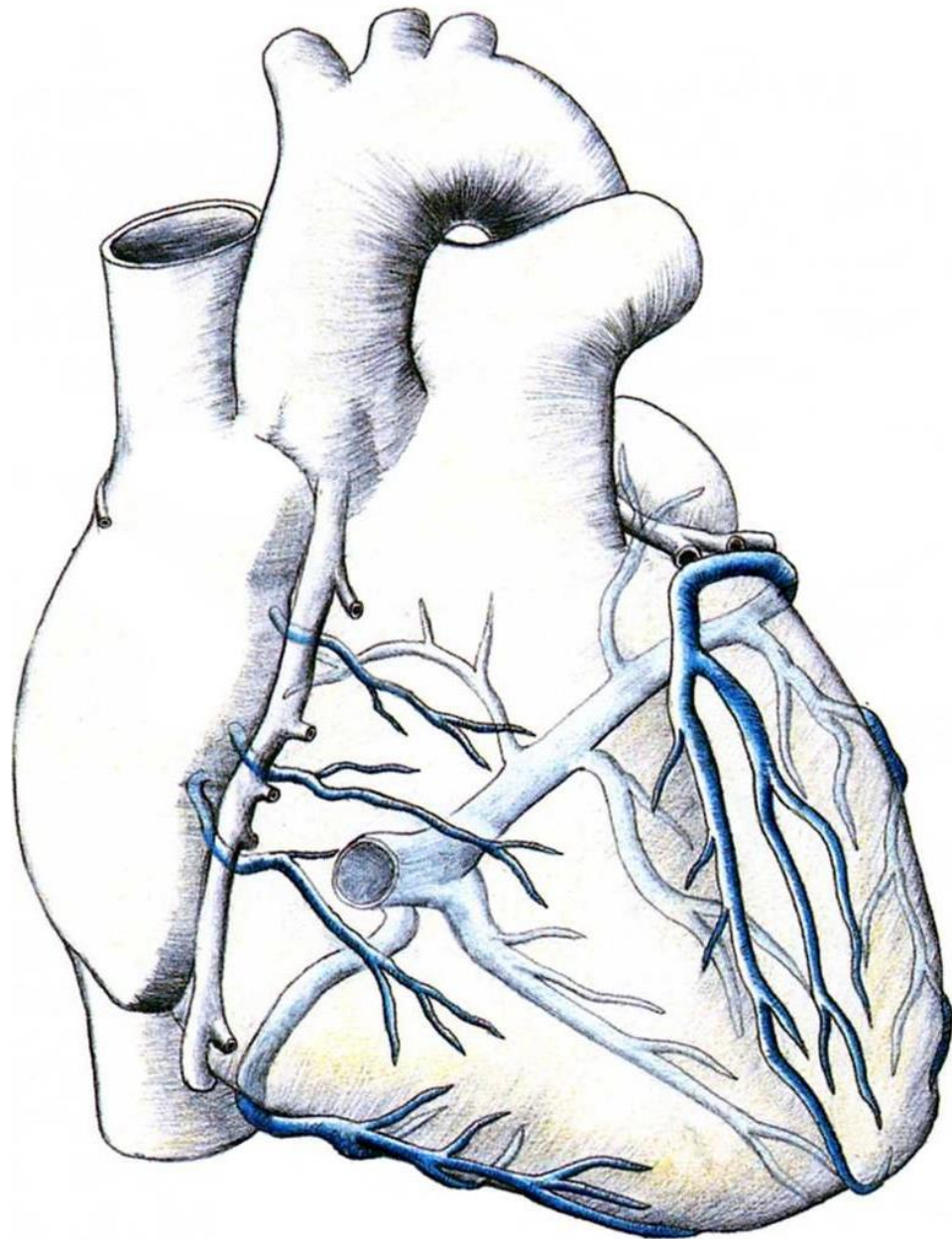
c) vena cordis parva

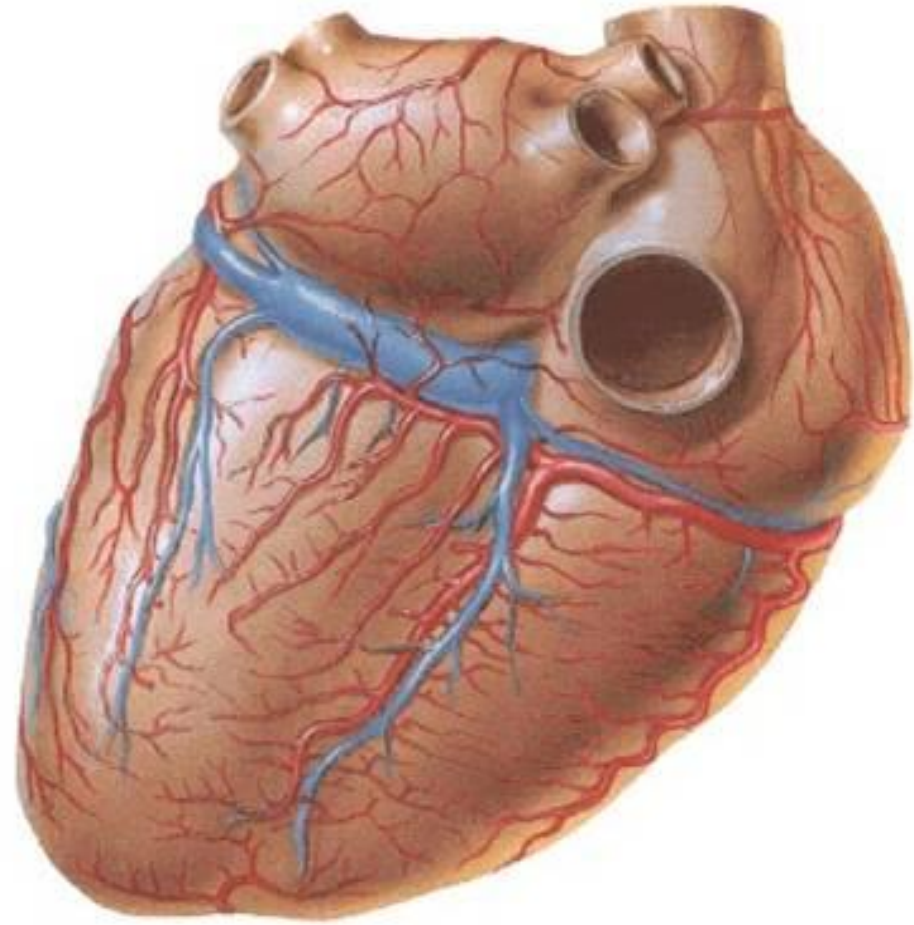
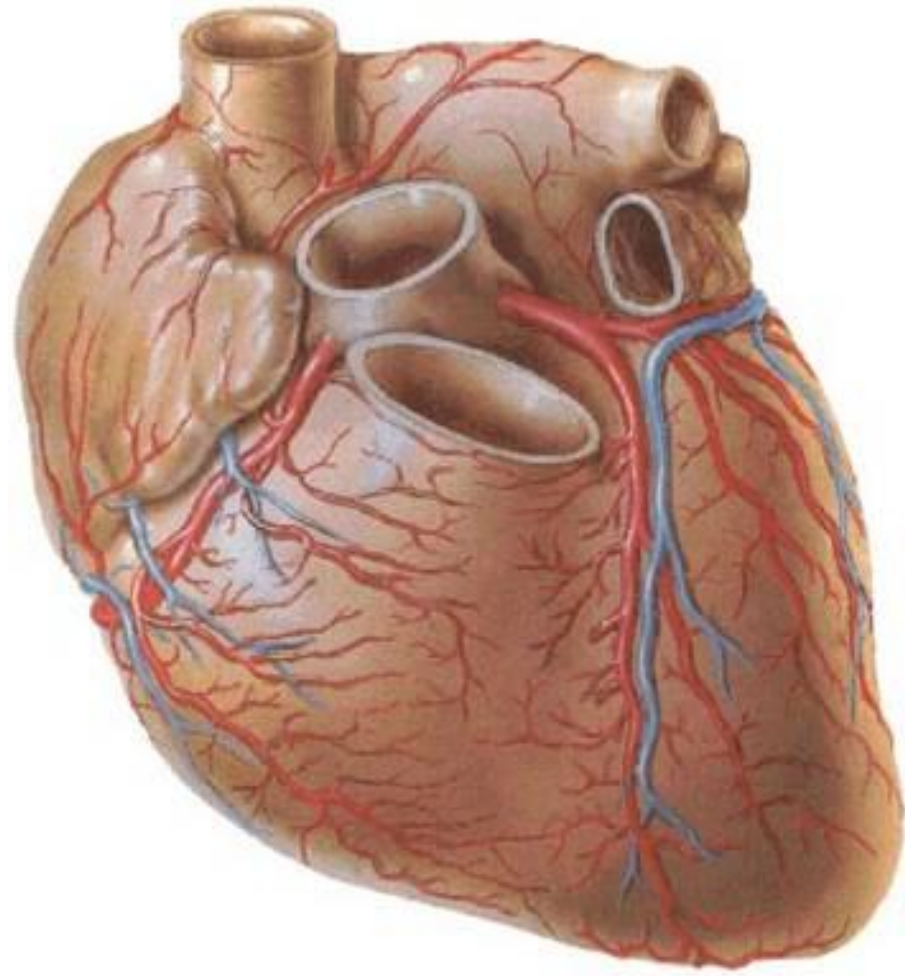


2) venae cordis anteriores – 2 till 4 veins, which collect blood from anterior wall of right ventricle

3) venae cordis minimae – open into cardiac cavities through separate apertures (foramina venarum minimarum)

Venae cordis anteriores at minimae (40% of the blood).





Lymphatics:

They form three lymphatic nets in the cardiac wall:

- subendocardial
- myocardial
- Subepicardial

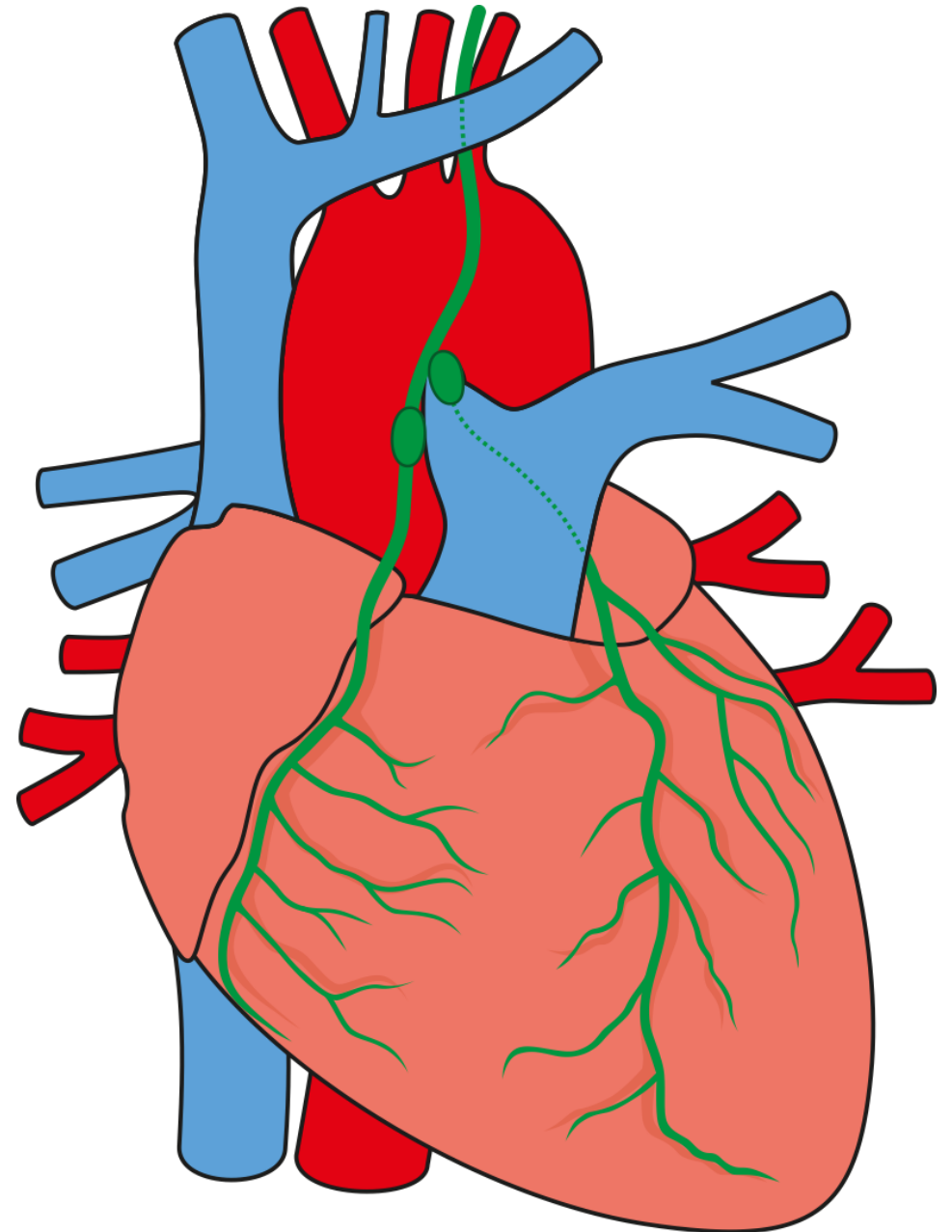
There are two lymphatic trunks draining out the lymph from these nets:

Truncus lymphaticus

**anterior sinister +
truncus lymph. post. –
nodus lymph. retroaorticus –
nodi lymphatici tracheobronchiales**

Truncus lymph. ant. dx. –

**nodus lymph. prae-aorticus –
*nodi lymphatici mediastinales anteriores***



Nerves:


ANS (sympathetic and parasympathetic nerve fibres), which influence conductive system (changes of cardiac rhythm) and wall of coronary vessels

Nn. cardiaci (symp., truncus sympathicus)

– accelerantes (acceleration of heart activity + vasodilatation of the cardiac arteries)

Rr. cardiaci (parasymp., nn. vagi)

– retardantes (deceleration of heart activity, vasoconstriction of coronary arteries)

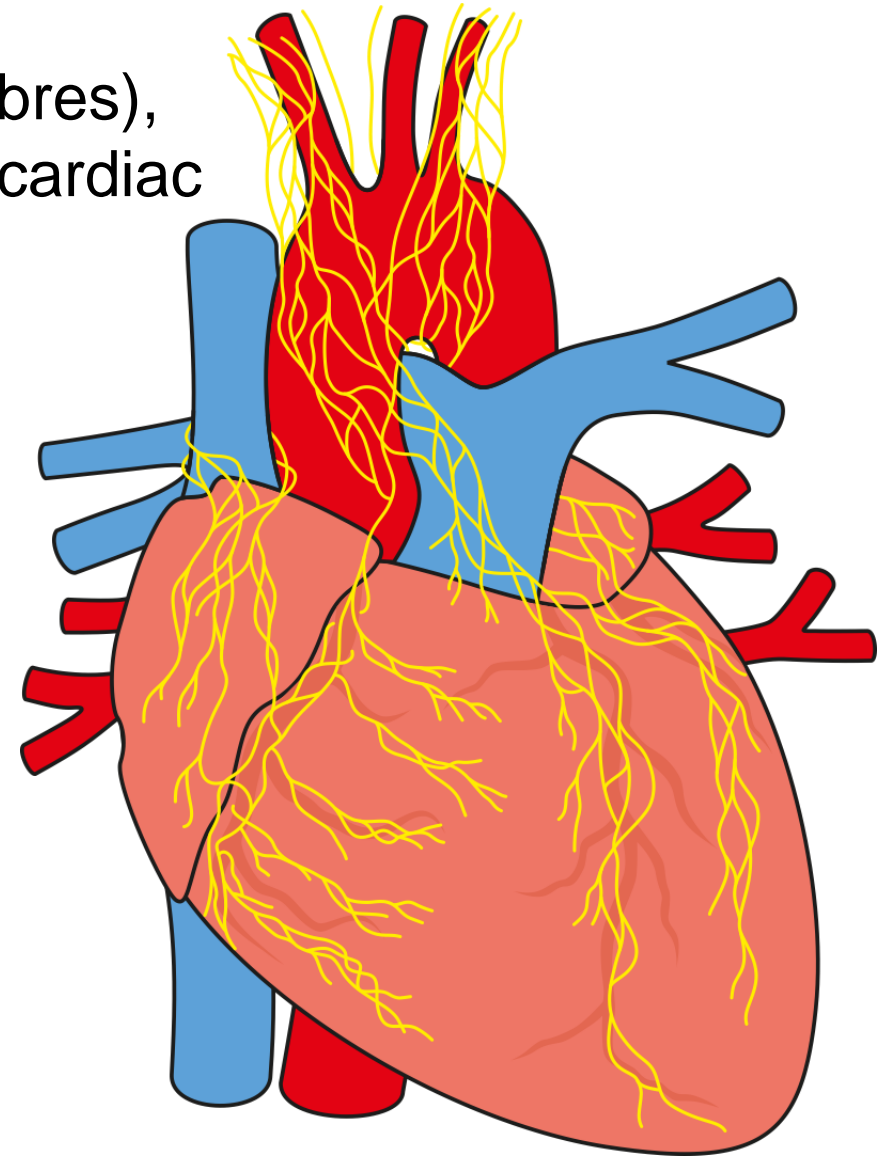


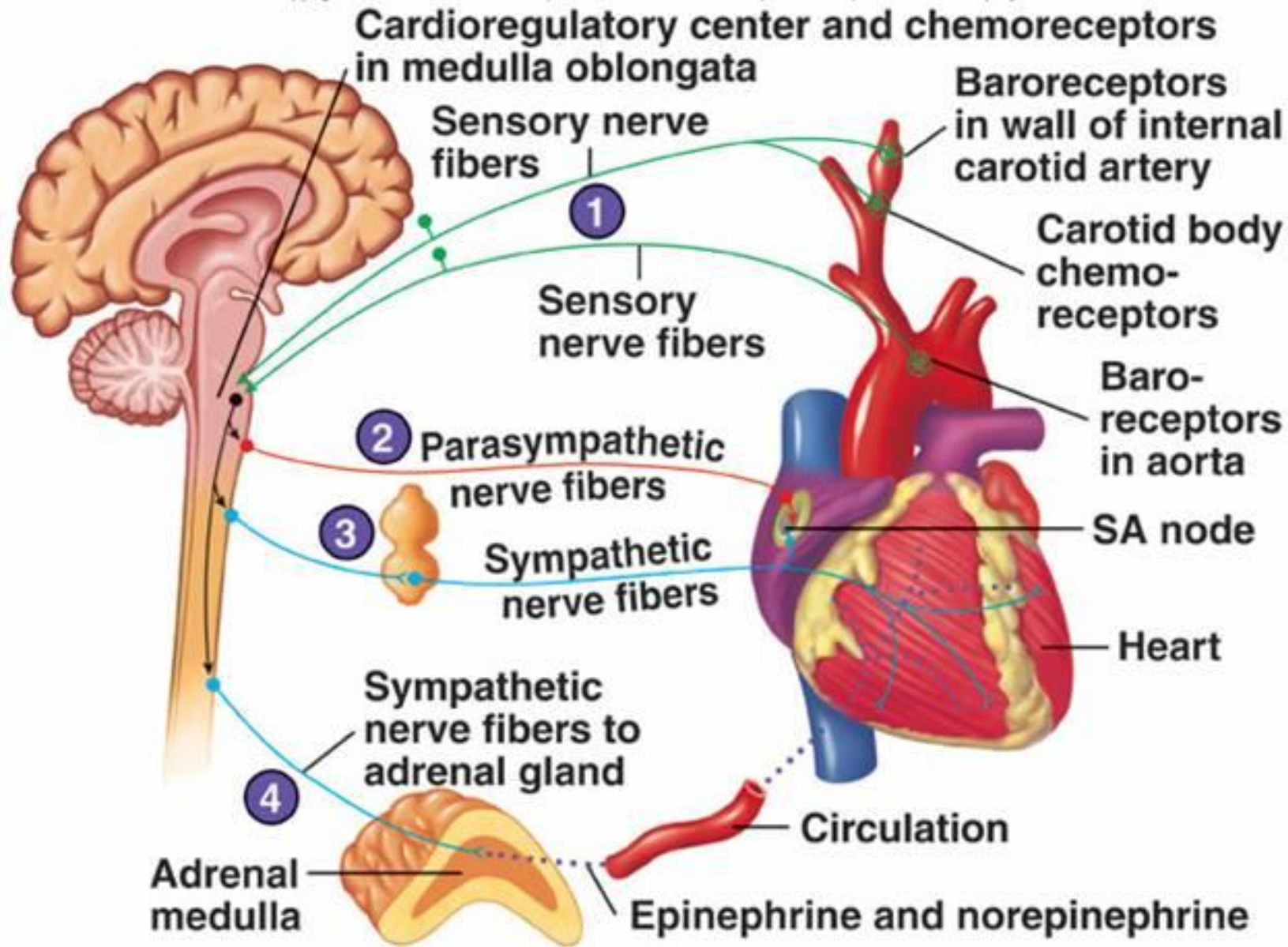
Plexus cardiacus spf.

(ganglion cardiacum)

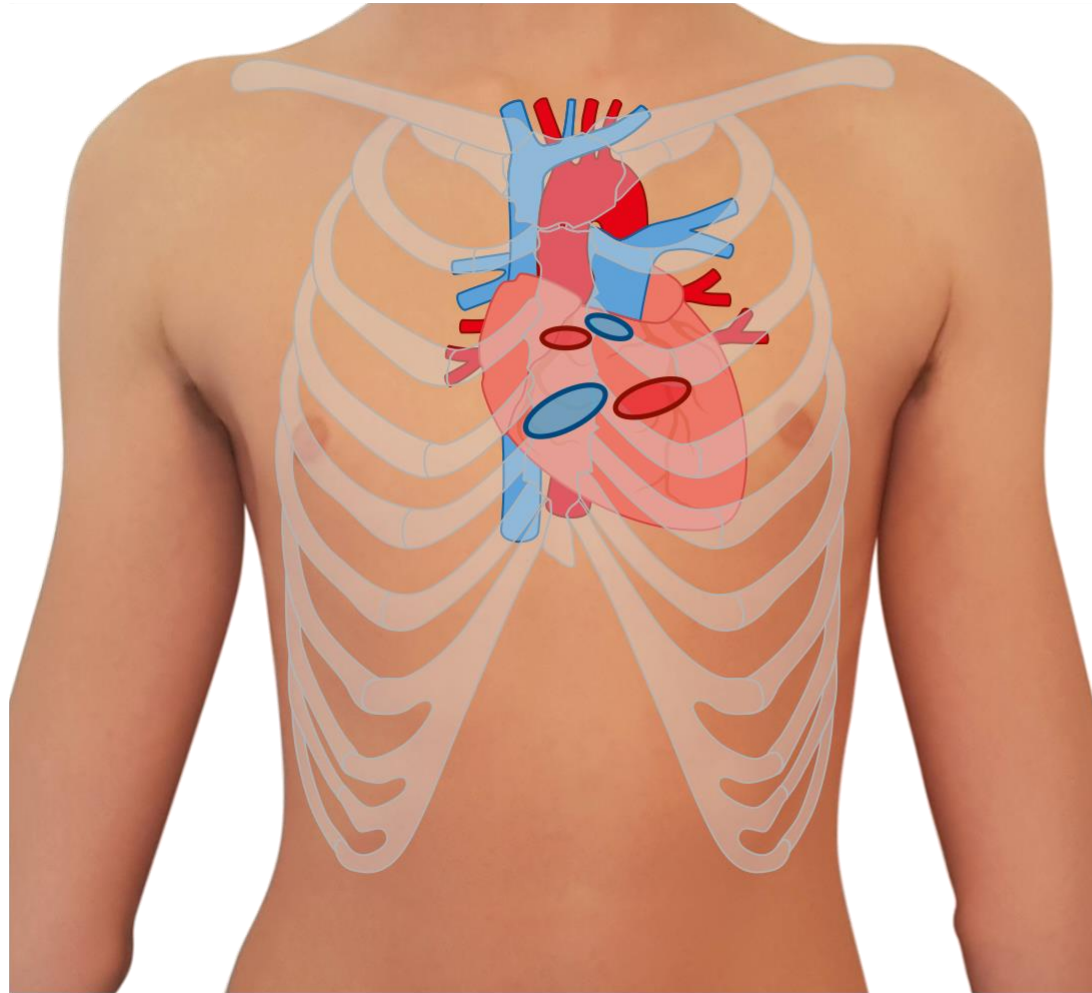
Plexus cardiacus prof.

Plexus coronarius dx. et sin.

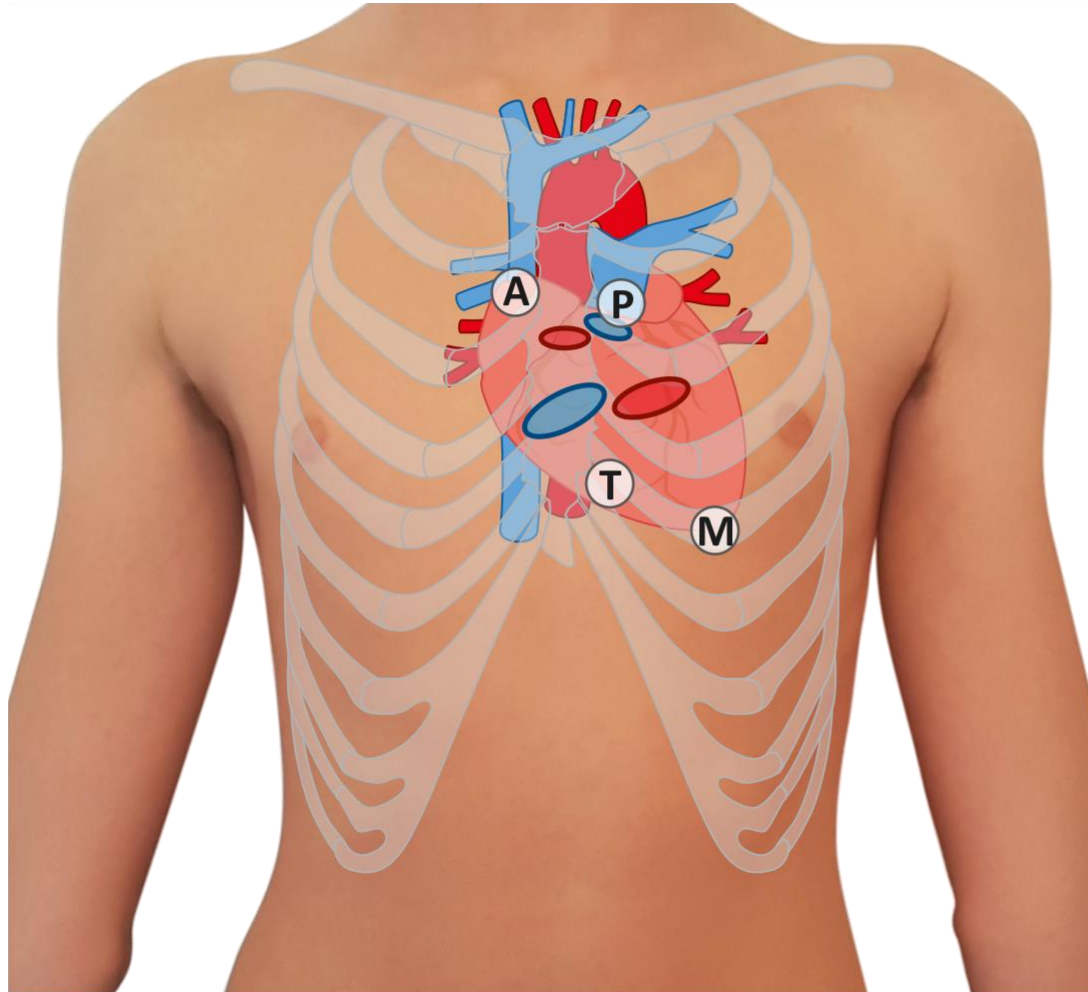




The projection of the heart and auscultation sites

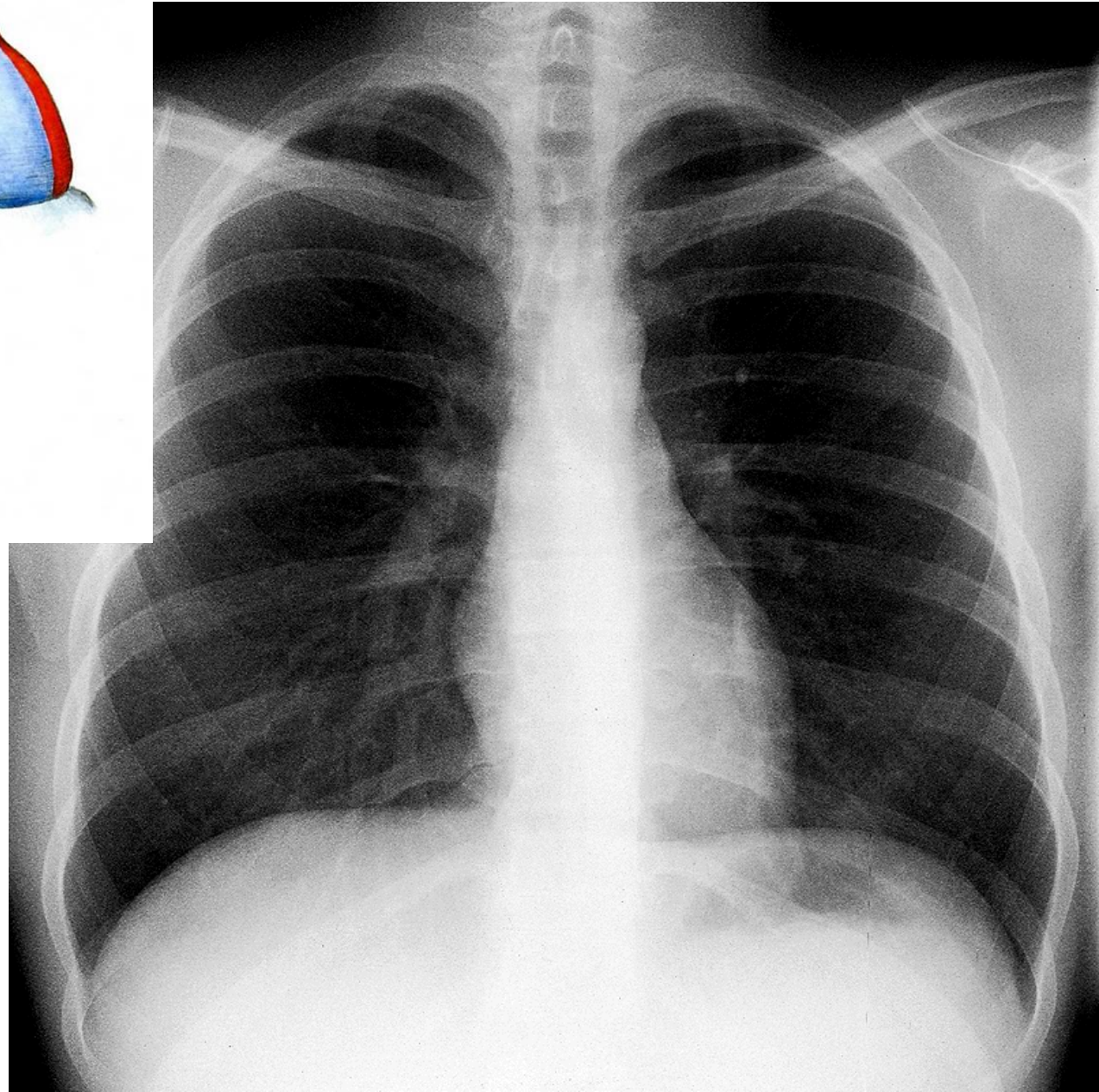
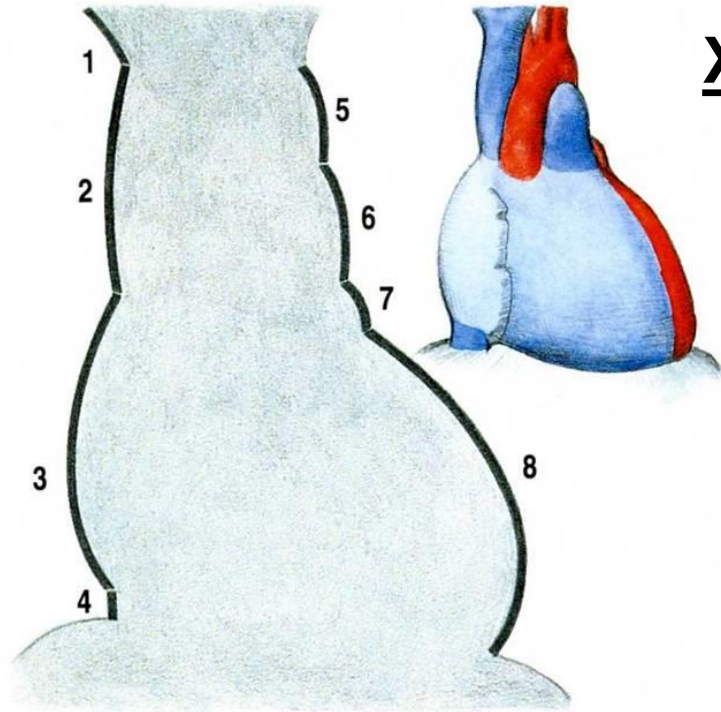


The heart is located in the middle inferior mediastinum.
The projection of the heart on the anterior thoracic wall – it is bordered with 4 auscultation points – heart field.

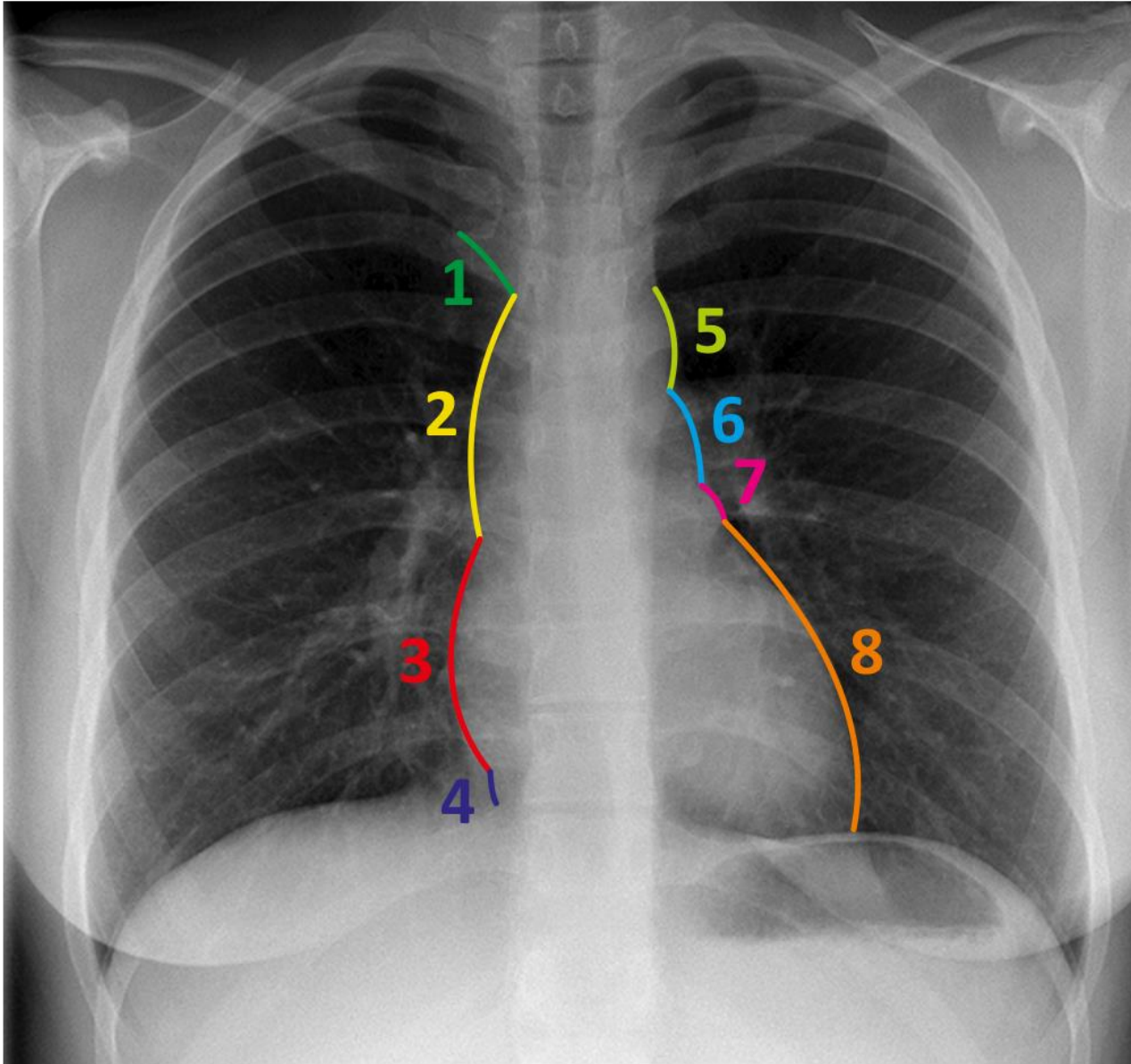


- 1) Point A – 2nd intercostal space, circa 1 cm on the right from the sternal margin – Auscultation Point of valva aortae.
- 2) Point B – 5th intercostal space, at left edge of sternum- AP of valva tricuspidalis.
- 3) Point C – 5th intercostal space, left, medially from medioclavicular line – AP of valva bicuspidalis.
- 4) Point D – 2nd intercostal space, left, circa 2 cm from sternal margin - AP of valva trunci pulmonalis

X – ray (AP projection)



Heart shadow:



1 V. brachiocephalica dx.

2 V. cava sup.

3 Atrium dx.

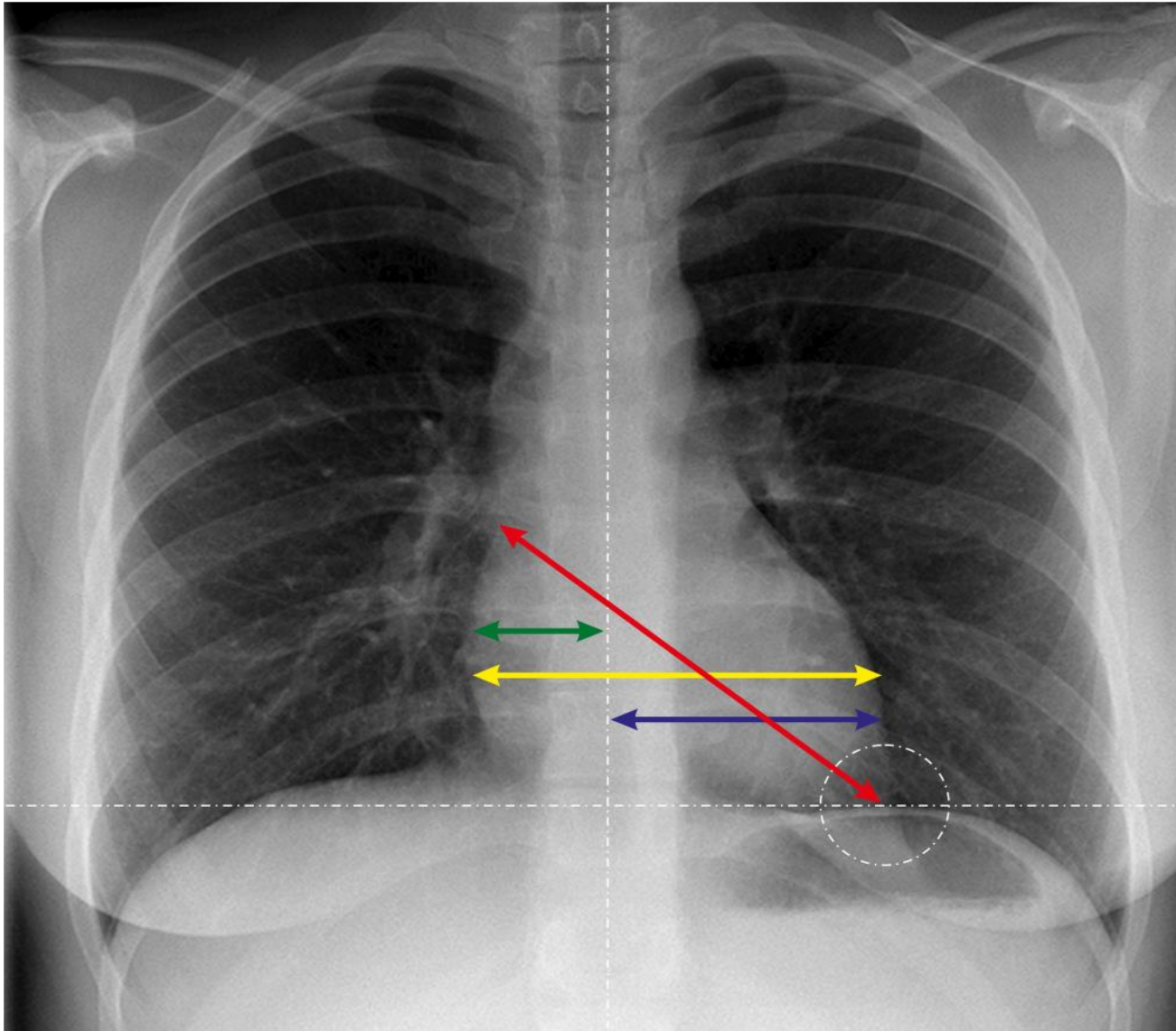
4 V. cava inf.

5 Arcus aortae

6 Truncus pulmonalis

7 Auricula sin.

8 Ventriculus sin.



▶ **Distantia mediodextra**

▶ **Distantia mediosinistra**

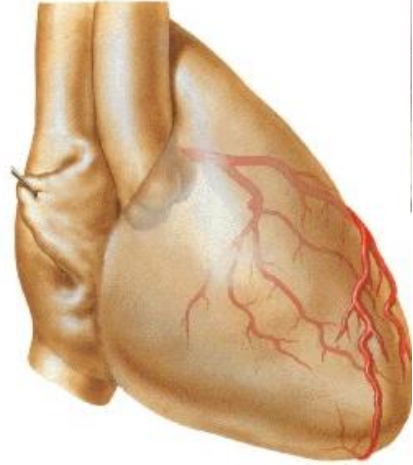
▶ **Transverse line = DMd+DMs**

▶ **Length**

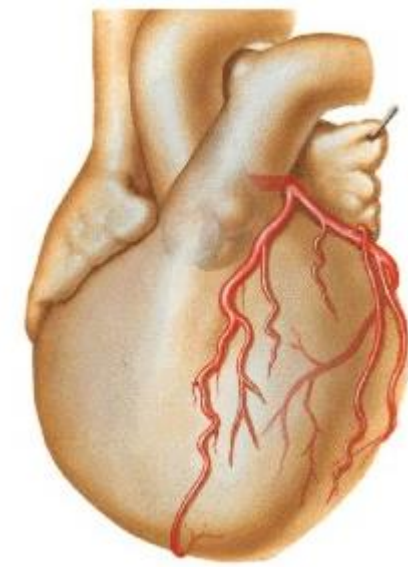
Gradient

Area

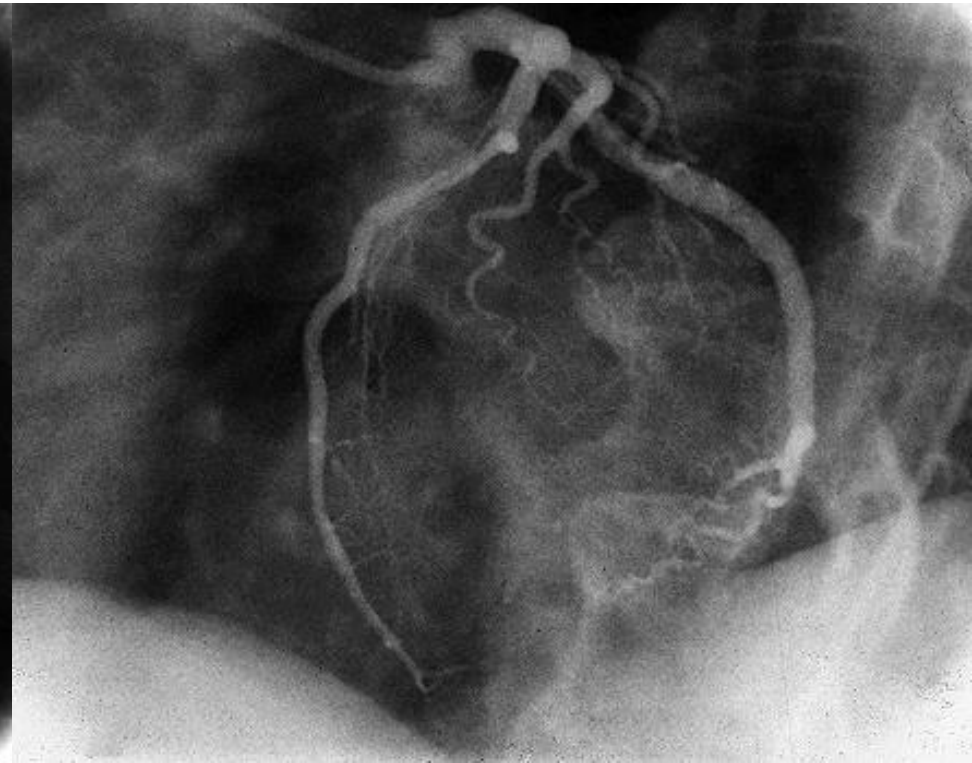
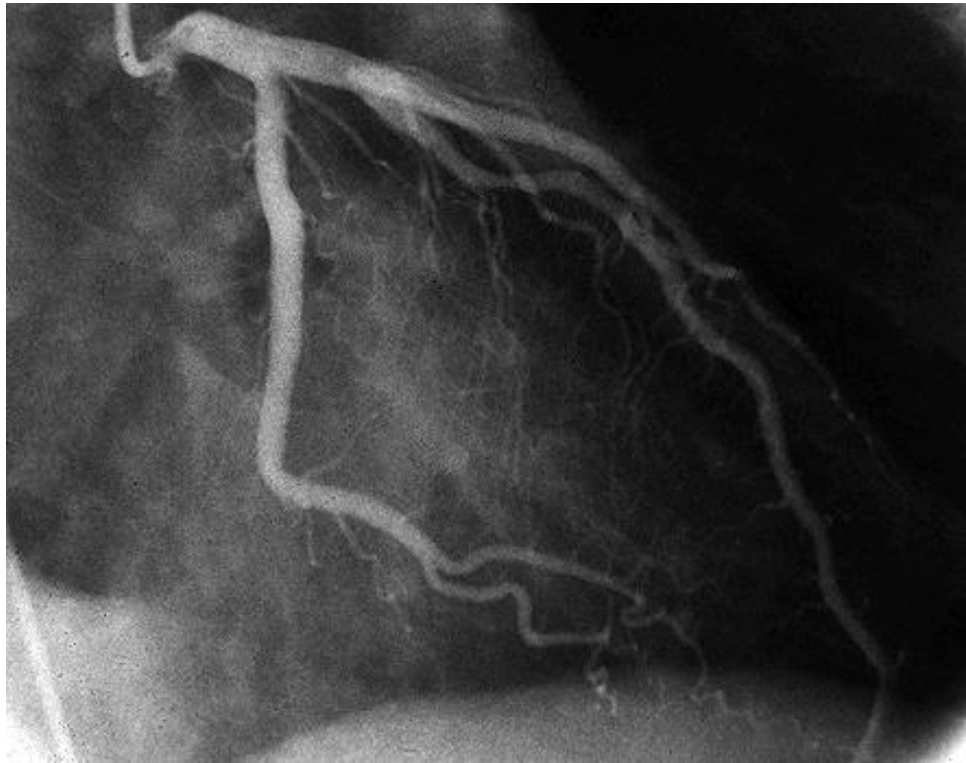
Coronary angiography – left coronary artery



Right anterior oblique projection

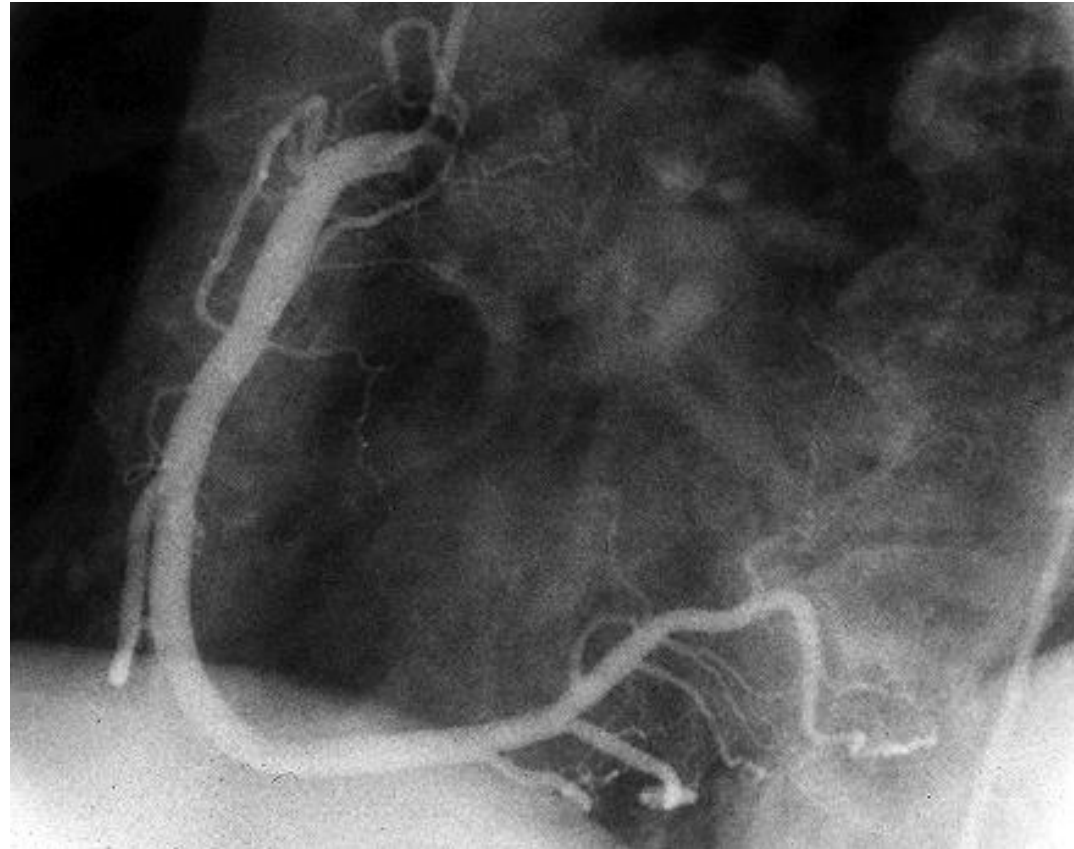
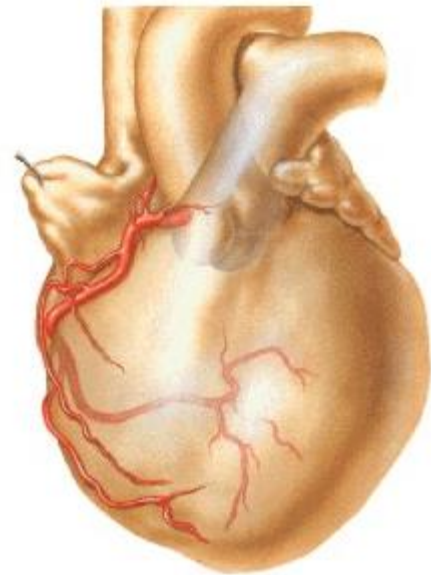


Left anterior oblique projection



Coronary angiography – right coronary artery

Left anterior oblique projection



Illustrations were copied from:

**Atlas der Anatomie des Menschen/Sobotta.
Putz,R., und Pabst,R. 20. Auflage. München:
Urban & Schwarzenberg, 1993**

**Netter: Interactive Atlas of Human Anatomy.
Windows Version 2.0**

**Čihák R: Anatomie 2 (Splanchnologia). Avicenum,
zdravotnické nakladatelství, Praha, 1988.**

Archiv of the lecturer

