



COLOURS IN MEDICAL TERMINOLOGY



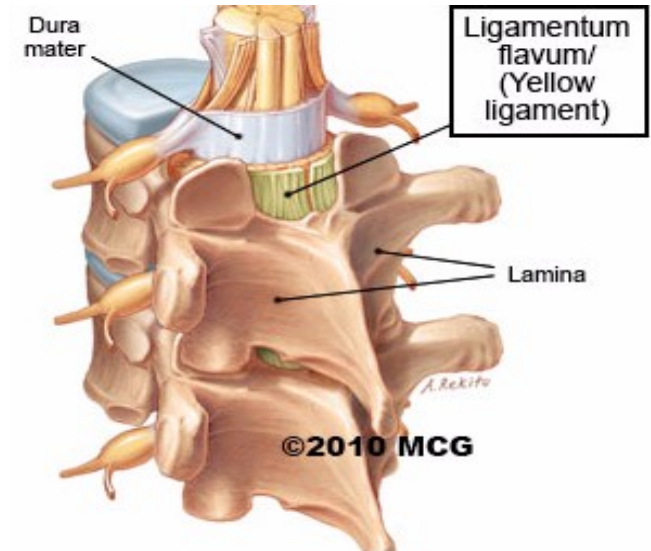
Rahen Hamzaee
And
Warda Umar



General terms

- Colour
- Latin: color, oris, m
- Greek: chroma, chromatis, n.

Case	Singular	Plural
Nominative	Chroma	Chromata
Genitive	Chromatis	Chromatum
Accusative	Chroma	Chromata
Ablative	Chromate	Chromatibus



How colours are used in medical terminology and their significance in clinical medicine.

- Usage of colour adjectives in clinical medicine.
- Synonyms

Adjectives denoting colours and demonstration of their medical use

- **Latin color adjectives behave like 1st and 2nd declension adjectives. They are mostly used in anatomical medicine.**
- **Example: Pallidus, pallida, pallidum (m, f, n). .**

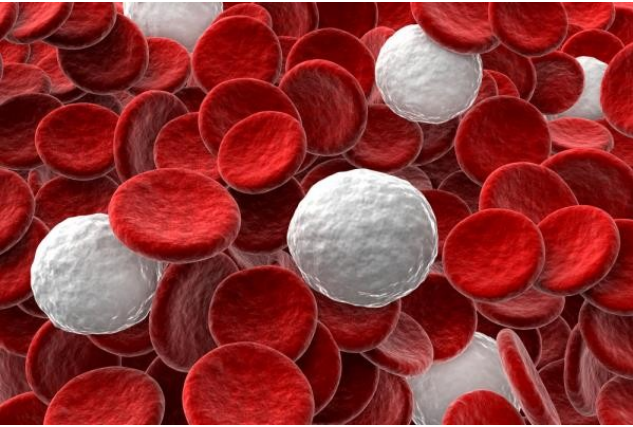
Case	Singular	Plural
Nominative	Pallidus, Pallida, Pallidum	Pallidi, Pallidae, Pallida
Genitive	Pallidi, Pallidae, Pallidi	Pallidorum, Pallidarum
Accusative	Pallidum, Pallidam, Pallidum	Pallidos, Pallidas, Pallida
Ablative	Pallido, Pallida, Pallido	Pallidis, Pallidis, Pallidis

- **Greek adjectives are usually forming compound words and are most frequently used in clinical medicine.**
- **Example: Polio-**

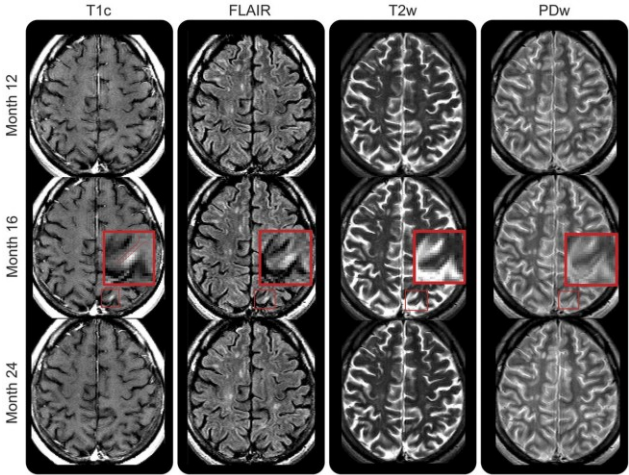
Adjectives denoting colours and demonstration of their medical use

○ L: Albus, a, um

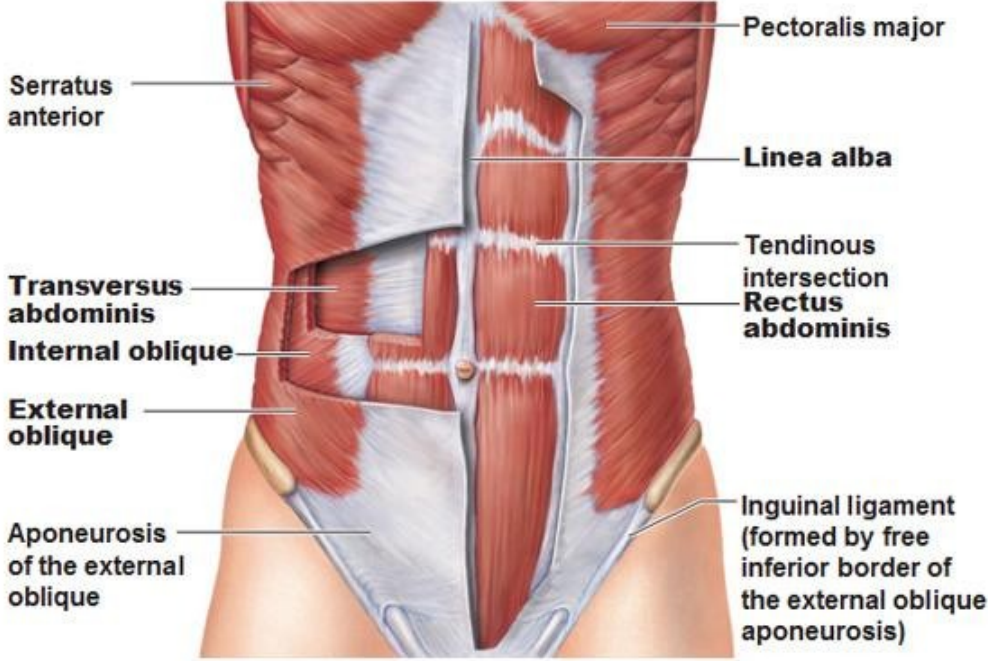
G: Leuko- (G.) = white



Leucaemia
White blood cell cancer.



Leukocortical
Relating to the white matter of the brain.



Linea Alba

Adjectives denoting colours and demonstration of their medical use

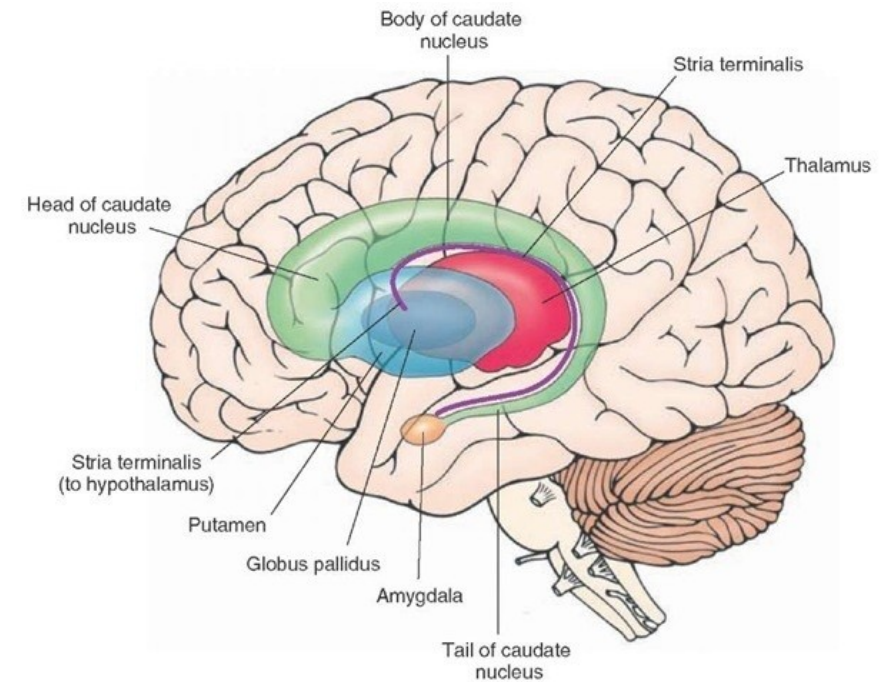
- L: pallidus, a, um = pale



facies pallida



febris pallida

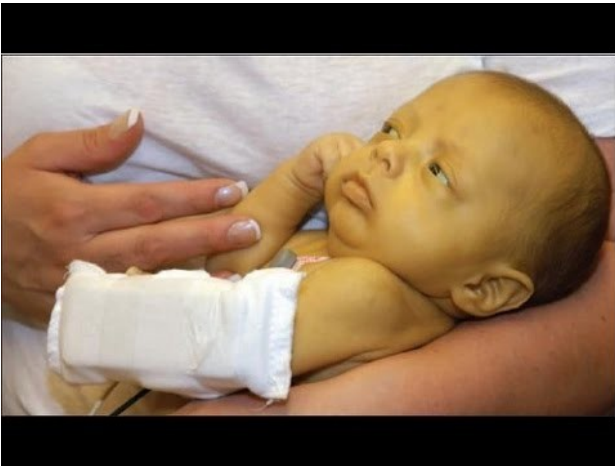

Globus Pallidus

sub-cortical structure of the brain

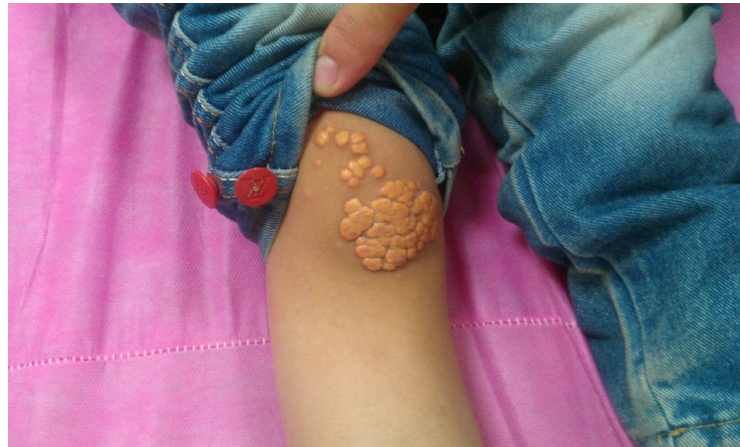Adjectives denoting colours and demonstration of their medical use

- L: flavus/luteus, a, um G: xantho-/cirrho-
- Yellow



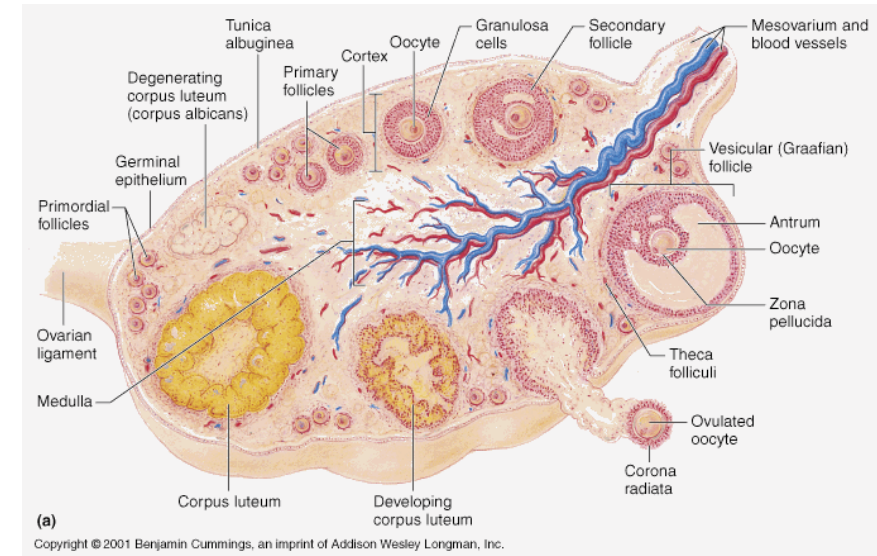
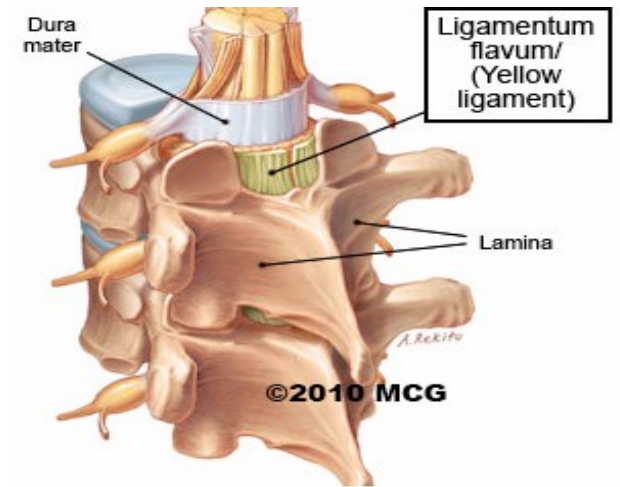
febris flava

acute viral haemorrhagic disease transmitted by infected mosquitoes



Xanthoma

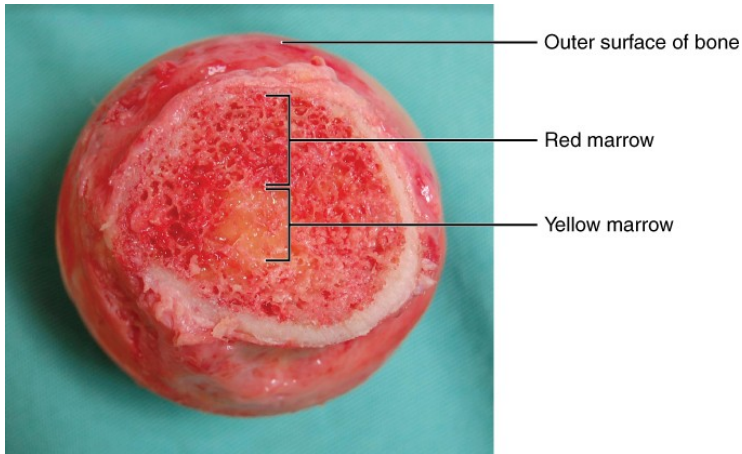
Irregular yellow patch in the skin.



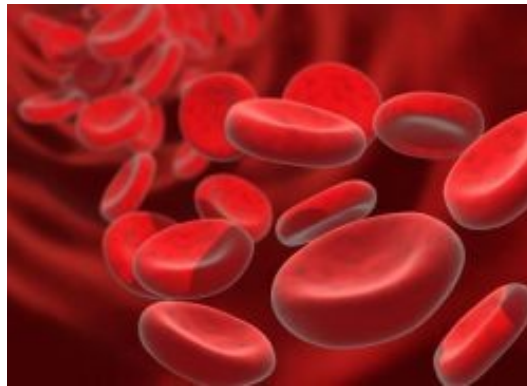
corpus luteum

Adjectives denoting colours and demonstration of their medical use

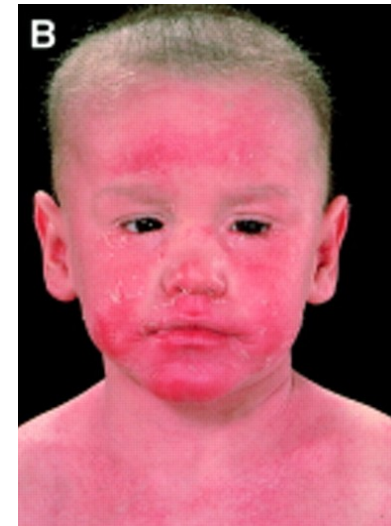- L: ruber, a, um G: erythro-
- Red



medulla ossium rubra
Red bone marrow



Erythrocytus
Red blood cells

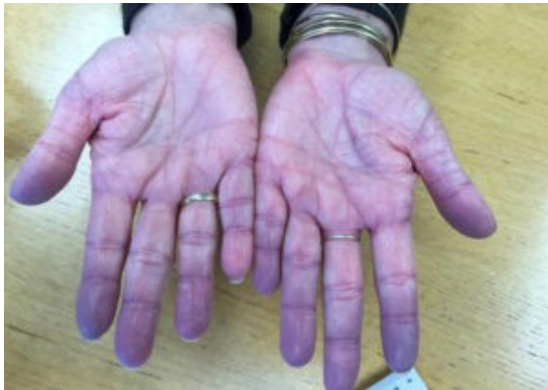

Erythroderma
Skin disease causing redness

Adjectives denoting colours and demonstration of their medical use

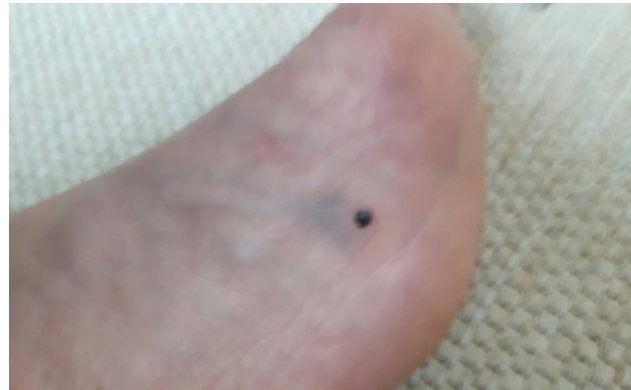- L: caeruleus, a, um G: cyano-
- blue/blue-black

Case	Singular	Plural
Nominative	Caeruleus, Caerulea, Caeruleum	Caerulei, Caeruleae, Caerulea
Genitive	Caerulei, Caeruleae, Caerulei	Caeruleorum, Caerulearum
Accusative	Caeruleum, Caeruleam, Caeruleum	Caeruleos, Caeruleas, Caerulea
Ablative	Caeruleo, Caerulea, Caeruleo	Caeruleis, Caeruleis, Caeruleis



Cyanosis

Condition where the skin turns blue due to bad circulation



naevus caeruleus

Tumor containing nervous cells



Cyanobacteria

Photosynthetic bacteria

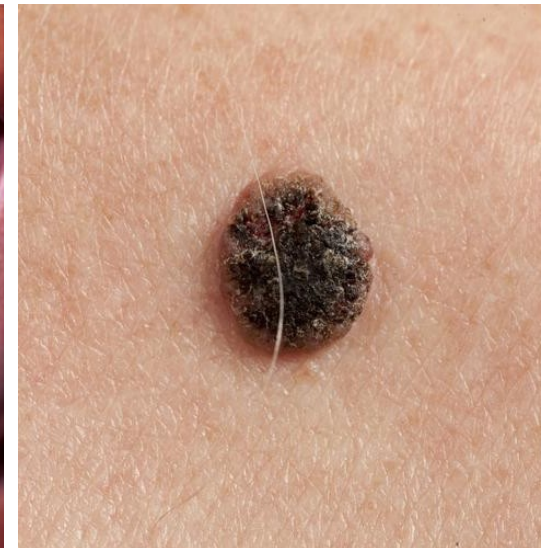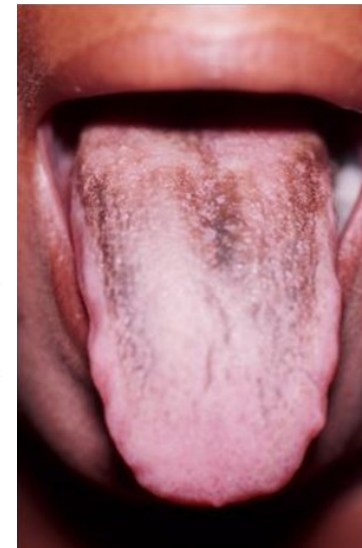
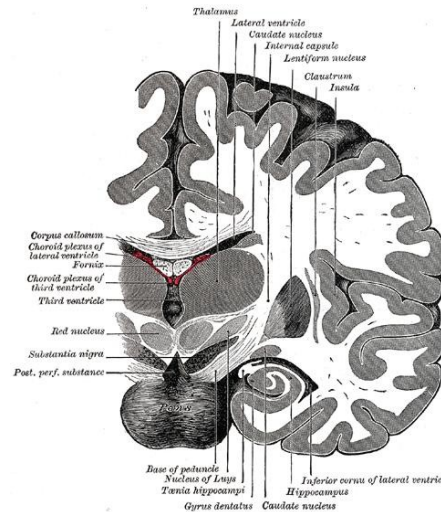
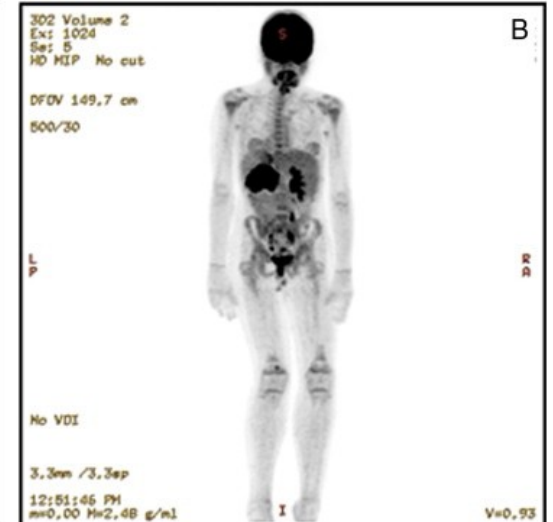
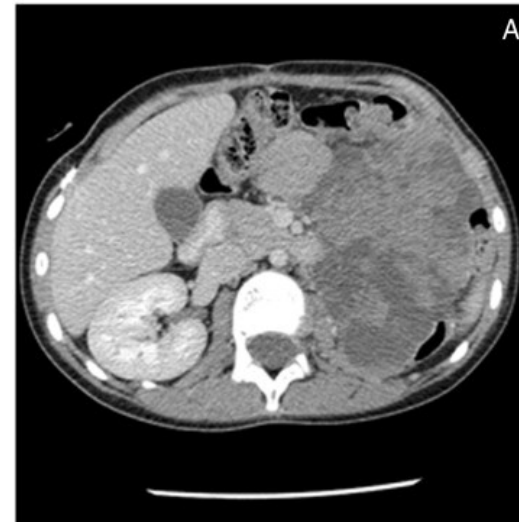Adjectives denoting colours and demonstration of their medical use

L: Niger, a, um

- Lingua villosa nigra
- Substantia nigra

G: Melano and antraco

- Melanosis
- Melanoma
- Melanomatosis – metastasis
- Aggressive peritoneal cancer.
- Anthracosis → anthracofibrosis.



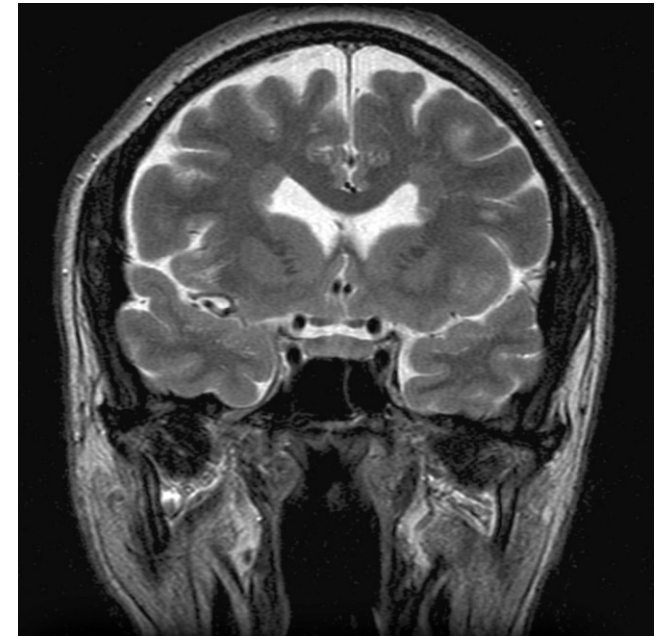
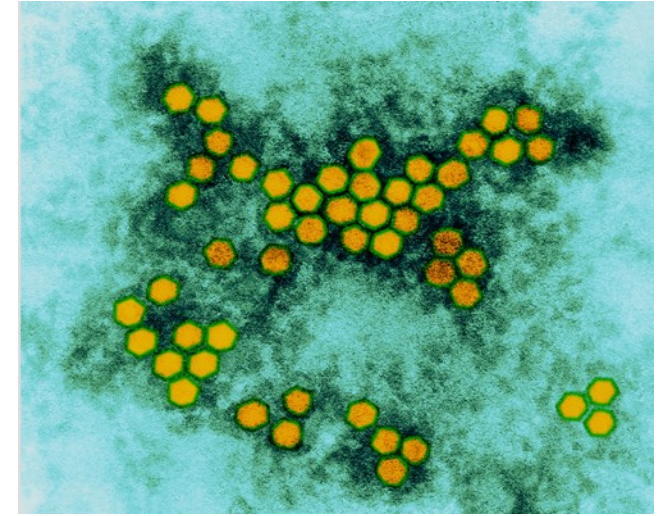
Adjectives denoting colours and demonstration of their medical use

L: Griseus, a, um

- Substantia grisea
- Ramus communicans griseus

G: Polio-

- Poliomyelitis:
- Myel- (myelos) = bone marrow, spinal cord.
- Poliovirus



Compound words

COLOR (eng.)	GREEK STEM	CLINICAL EXAMPLES	LATIN equivalent
Black	melano- anthraco-	Melano-sis Anthraco-sis	Niger, a, um
Grey	polio-	Poliomyel-itis; poliovirus	griseus
Green-blue	glauco-	glaucoma	-
Vari-colored	poikilo-	Poikiloderma	Versicolor, oris
Red	Erythro-	Erythro-derma	Ruber,Rubra,Rubrum
Yellow	Xanth-	Xanth-oma	Flavus,a,um

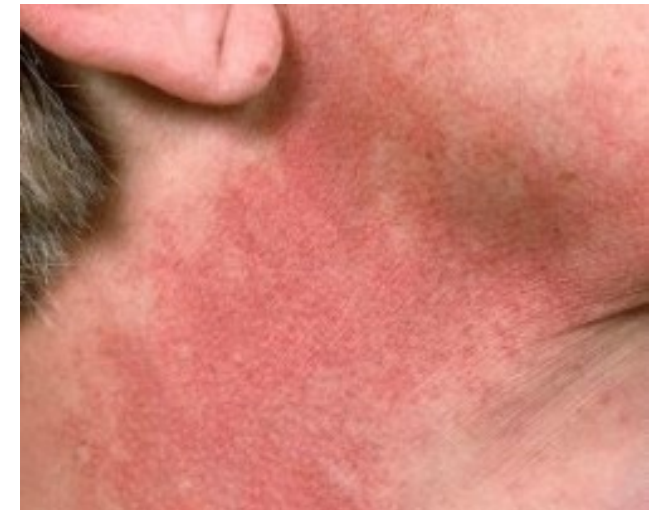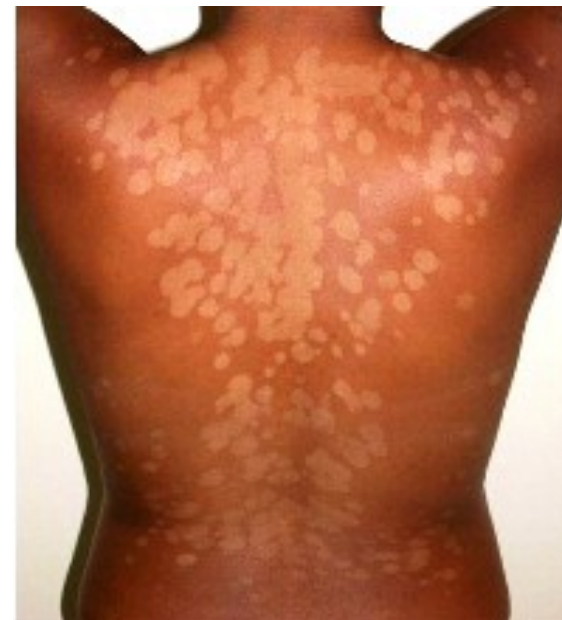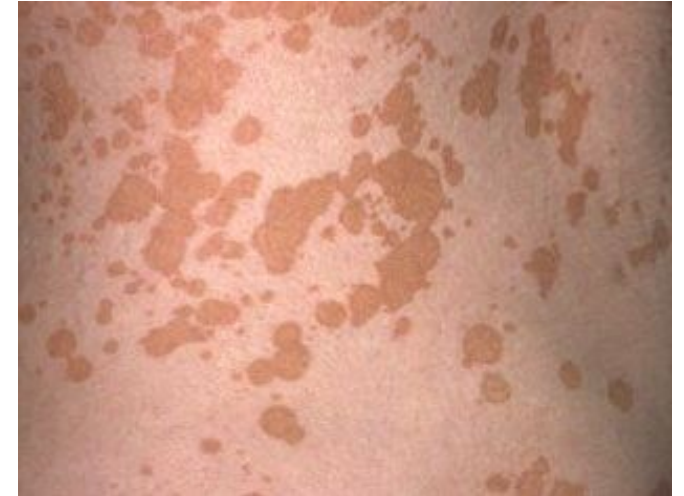Adjectives denoting colours and demonstration of their medical use

L: Versicolor, versicoloris

- Vari-coloured

G: Poikilo-

- Pityriasis versicolor / Tinea
 - Versicolor – overgrowth of a yeast that is naturally found in the skin.
 - Fungal infection leading to discolouration.
- Poikiloderma; -derma.
 - Caused by sun damage, reddish hyperpigmentation.



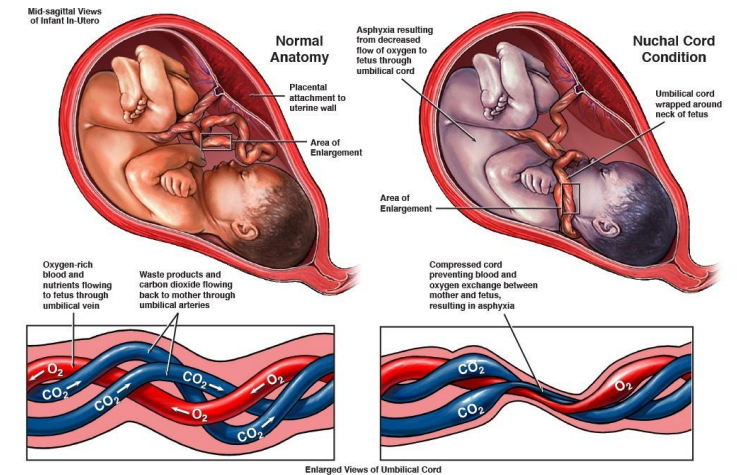
Adjectives denoting colours and demonstration of their medical use

L: Lividus, a, um

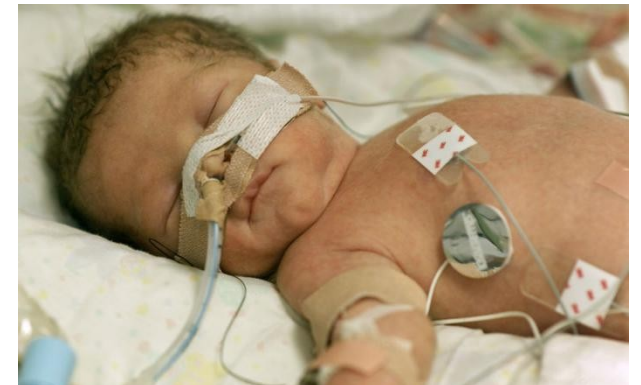- Livid, discoloured, bluish

Clinical example:

- Asphyxia livida
- Diagnoses:
 - Asphyxia neonatalis gravis
 - Asphyxia neonatalis levis
 - In utero
- The International Classification of Diseases (ICD) – 10 used to classify the degrees of severity.
- Funiculus umbilicus circum collum fetus semel/bis/ter in grav. hebd. 42+3
- Repetition:
 - Numeral adverbs → semel, bis, ter, quater etc.



Reiter & Walsh, P.C. | Purchased from: ©2016, Nucleus Medical Media. All rights reserved. www.nucleusinc.com



How many colours can you remember?

How many colours can you remember?

Albus, a, um	Leuko- (G.) = white
flavus/luteus, a, um	xantho-/cirrho
ruber, a, um	erythro
caeruleus, a, um	cyano
niger, a, um	melano-/anthraco-
griseus, a, um	polio-
versicolor, oris	poikilo-

References

Literature:

- Asphyxia - http://clin.au.dk/fileadmin/www.ki.au.dk/forskning/forskningsenheder/gyn_kologisk-obstetrisk_afd_y/logistics/sandbjerg_m_der/sandbjerg_2009/acidose.pdf
- <http://www.who.int/topics/poliomyelitis/en/>
- <https://www.ncbi.nlm.nih.gov/pubmed/22498396>
- <https://en.wikipedia.org/wiki/Xanthoma>
- <https://www.cambridge.org/core/books/progressive-brain-disorders-in-childhood/neurodegenerative-and-other-progressive-disorders-in-childhood/1A5C1105BDE151435CA114233AD96F52/core-reader>

Images:

- <https://www.ncbi.nlm.nih.gov/pubmed/26433132>
- https://www.google.cz/search?q=hostesaft&source=lnms&tbn=isch&sa=X&ved=0ahUKEwjtpory0u7ZAhXEL8AKHQj-B8EQ_AUICigB&biw=1440&bih=763#imgsrc=KY86H-Oi68oa-M
- [https://www.augustahealth.org/spine/spine-glossary/spine-glossary-ligamentum-flavum-\(yellow-ligament\)](https://www.augustahealth.org/spine/spine-glossary/spine-glossary-ligamentum-flavum-(yellow-ligament))
- <http://adc.bmj.com/content/79/2/186>

Gratias pro audientia agenus