

Preclinical periodontology

Periodontology

- Periodontal tissues
 - alveolar bone
 - cementum
 - periodontal ligament
 - gingiva

Morfology

■ Periodontal tissues

Of epithelium origin

- Gingiva-
- Attachement

Of mesenchymal origin

- Periodontal ligaments
- Bone
- Cementum

Supportive tissues

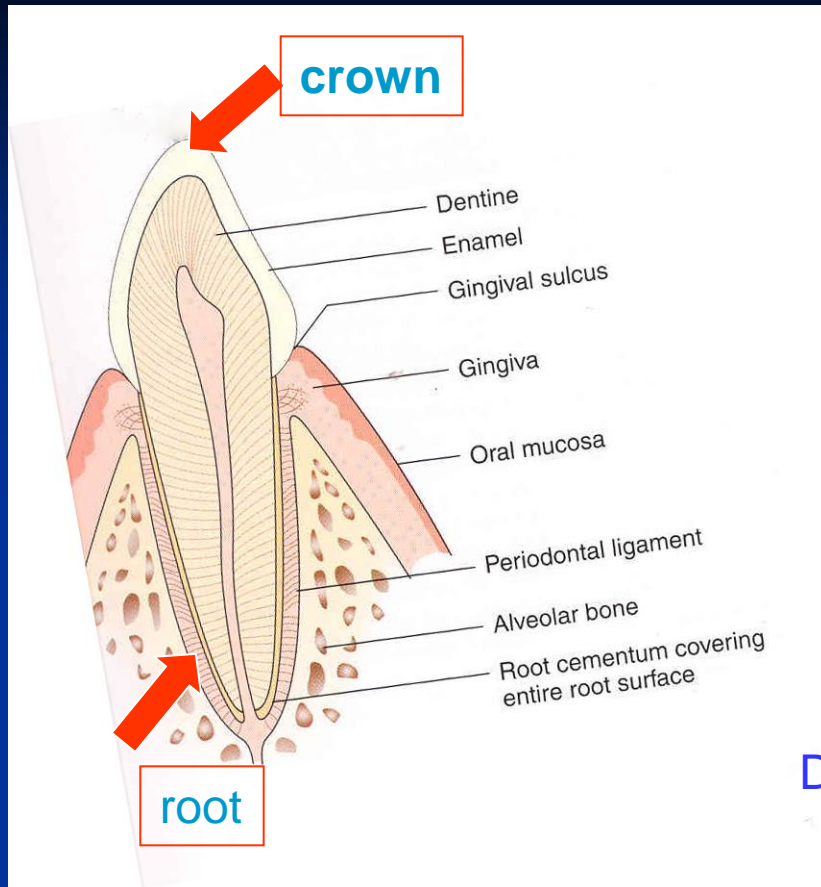
- Alveolar bone

- Cementum

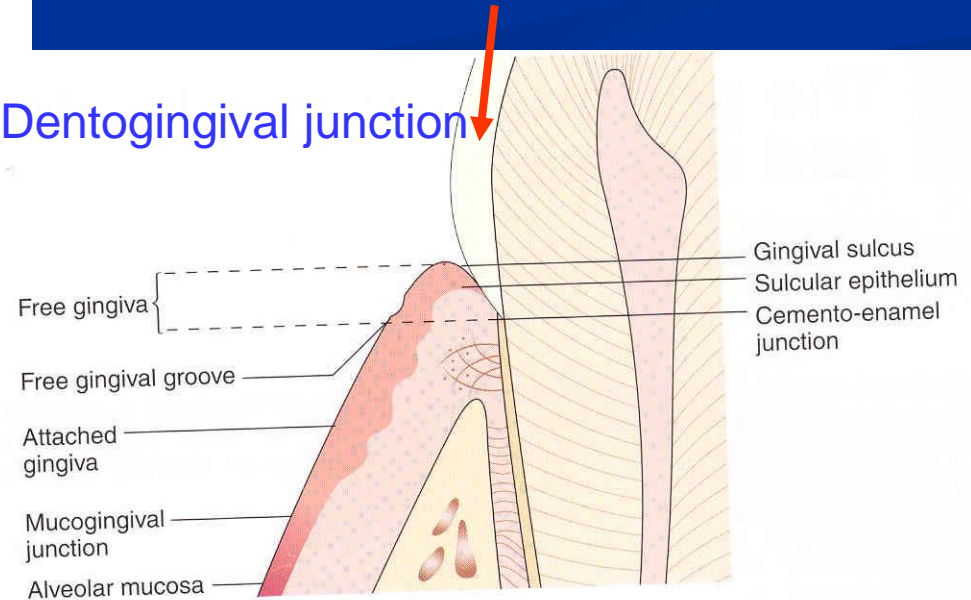
- insertion of periodontal ligaments

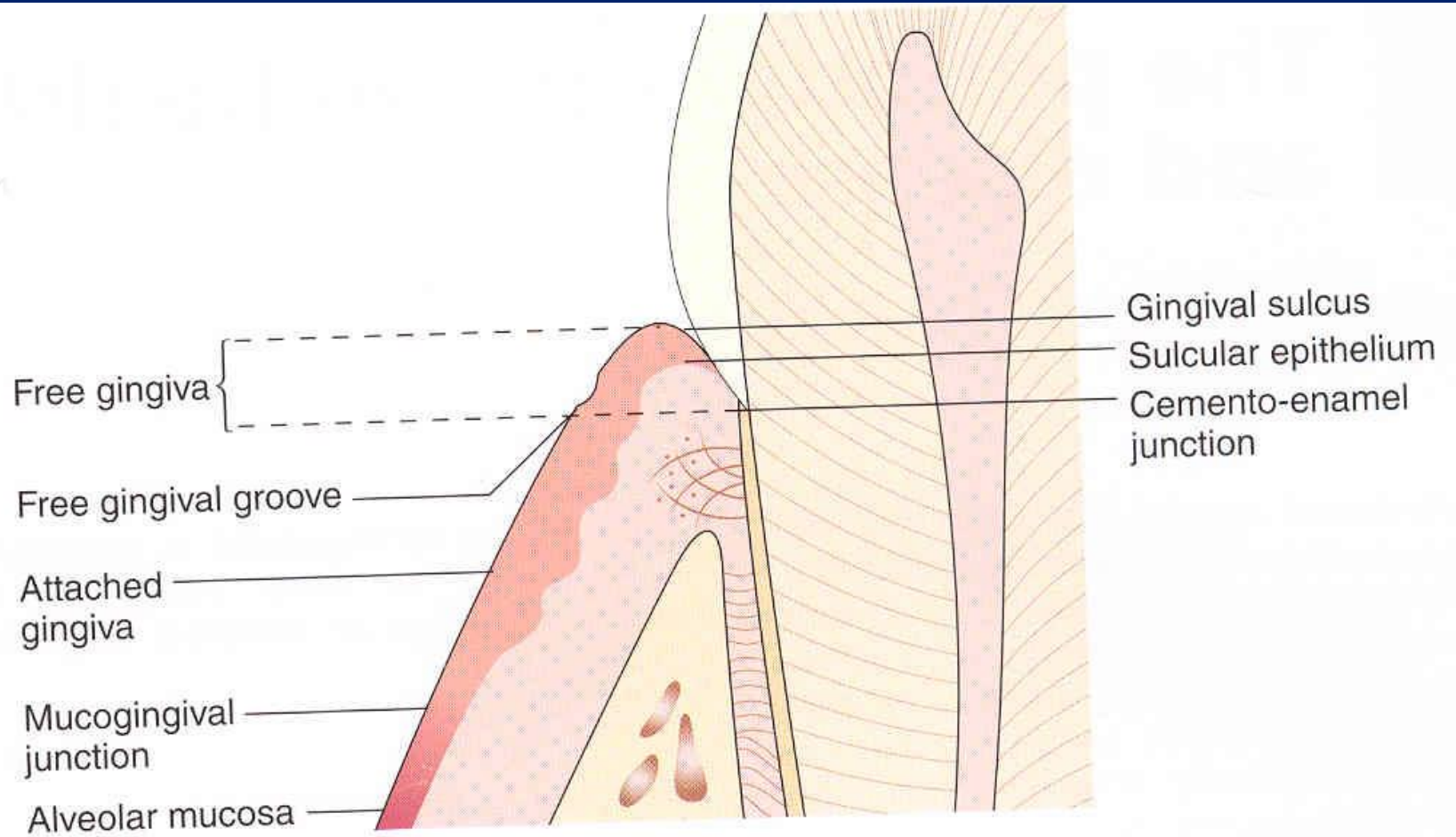
Morphology

Supportive tissues



Dentogingival junction



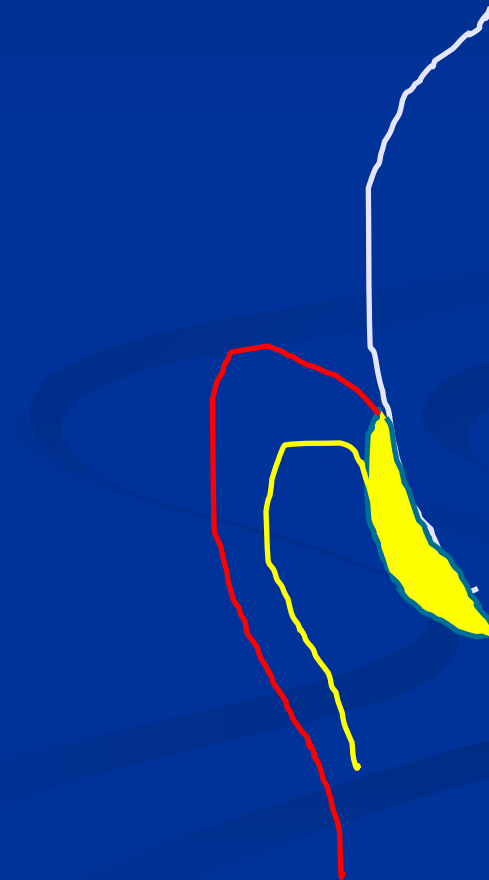


Dentogingival junction

- Attachement - epithelium

Two layers:

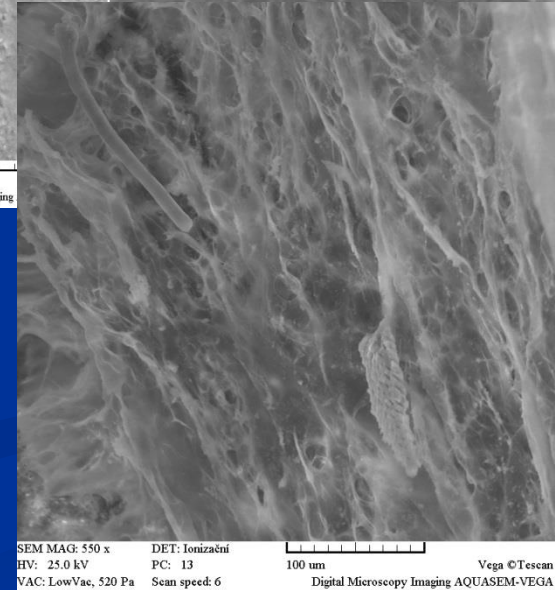

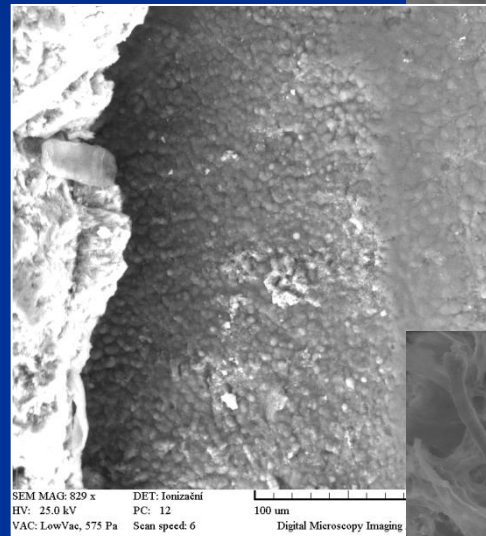
- Stratum basale
- Stratum suprabasale



Cementum

On the root surface
Approx 50% inorganic
material

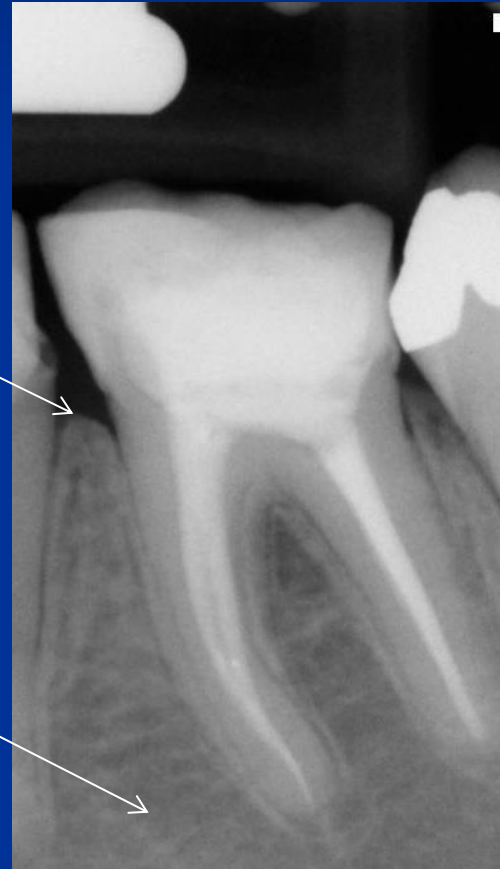Insertion of collagen
fibers



Alveolar bone

Compact bone – lamina dura

Spongise



Periodontal ligament

- In periodontal space

(width 0,4 – 1,5 mm) 20 – 35 %.

Interfibrilar substance with cells, nerves, blood vessels

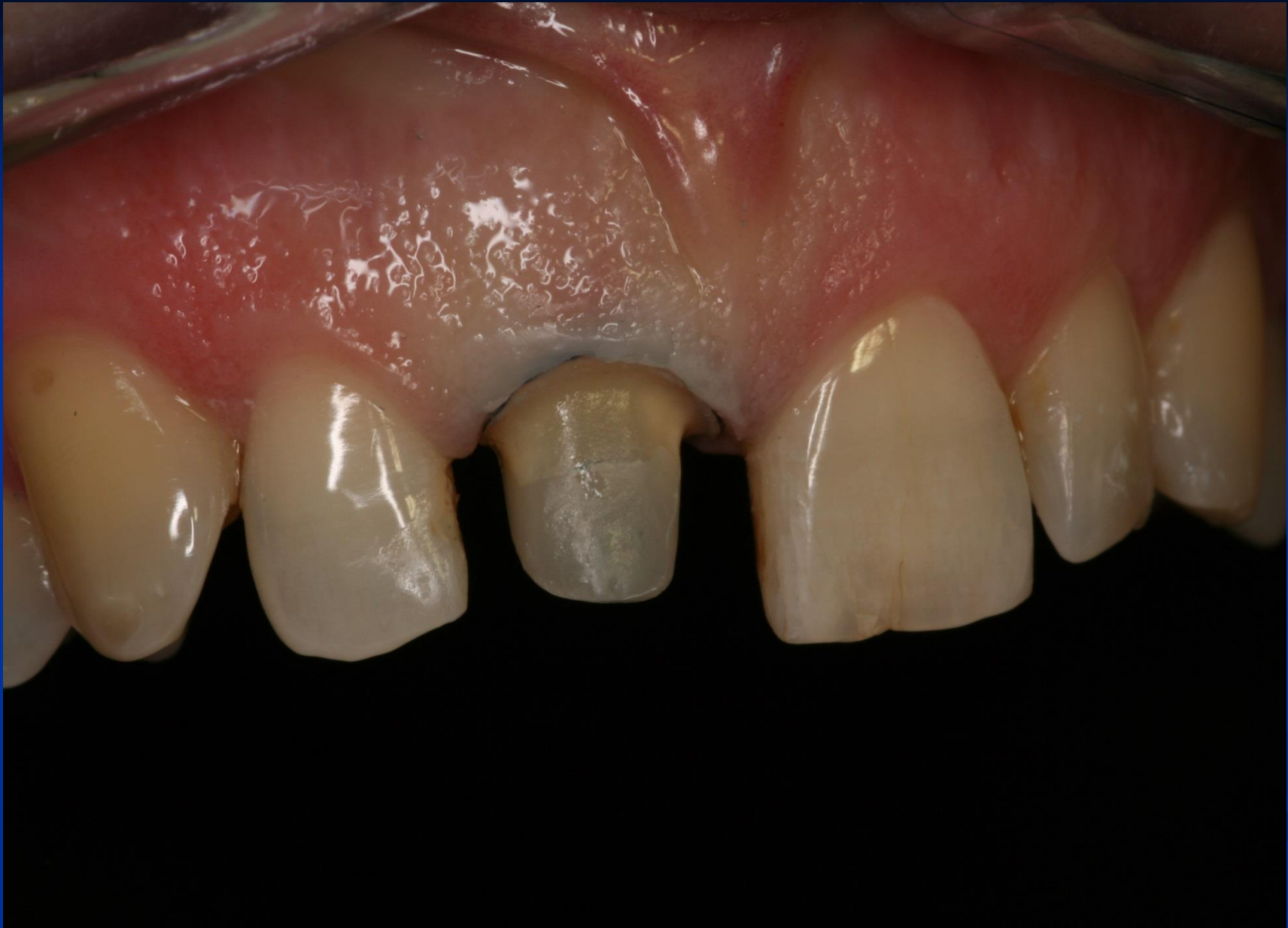Periodontal ligaments

- Supraalveolar ligaments

In various directions.

- Intraalveolar ligaments (Sharpey's fibers)

- Horizontal
- Oblique
- Apical
- Crestal
- Interradicular



Paeriodontal diseases - classification

- Inflammation – gingivitis
- Inflammation of deeper structures – periodontitis
- Non inflammatory diseases
 - gingival recessions

Aethiology

- Local factors

Dental biofilm

Dental calculus

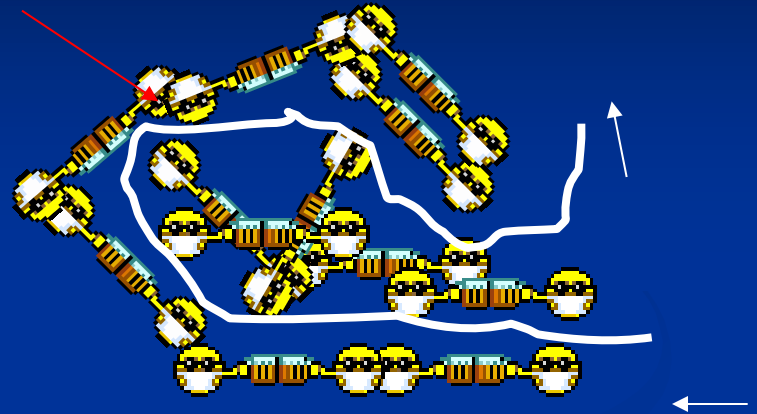

Iatrogenic diseases

Mucogingival disorders (frenulum breve)

Trauma a traumatizace

Dental plaque = biofilm

■ Community



■ Primitive circulation



More species

Higher metabolic activity

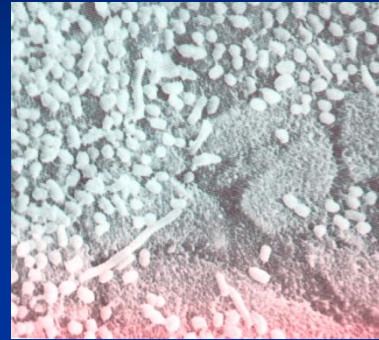
Higher resistance

(*S. sobrinus* CHX 300x, AF 75x)

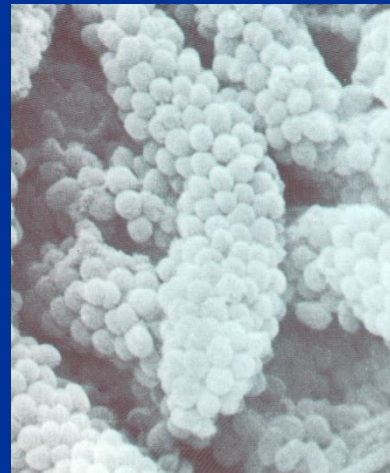
} better conditions to survive
higher virulence

Biofilm

- Adherence

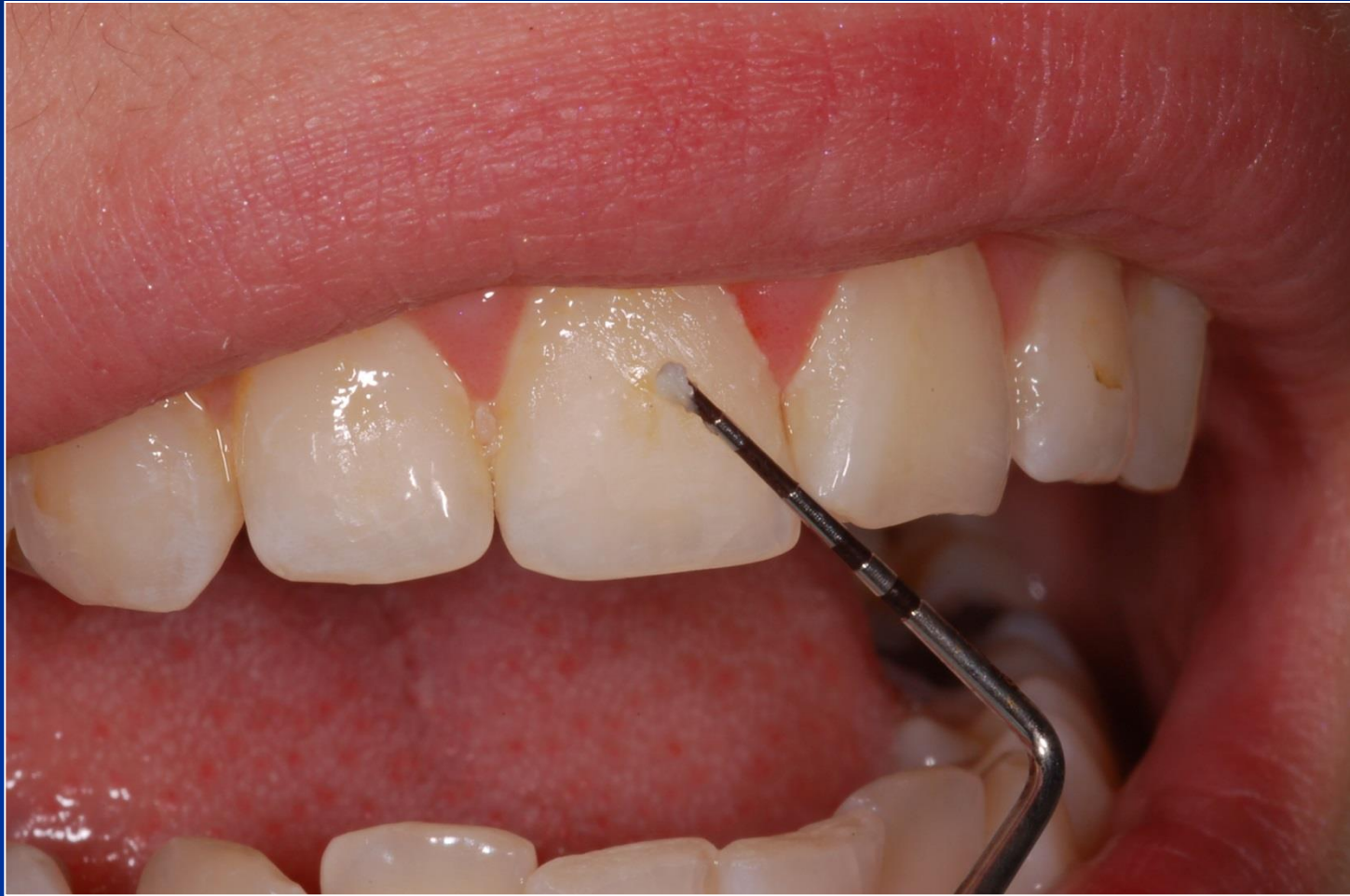

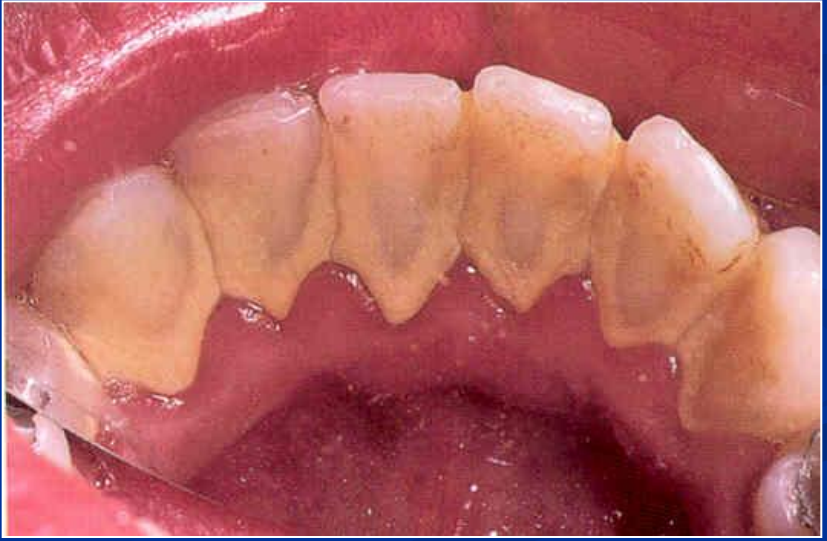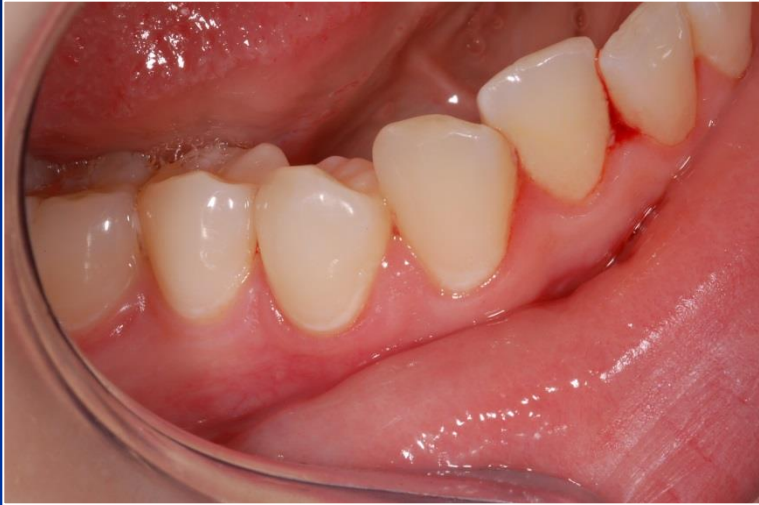- Colonisation



- Maturation

Can it be recognised and removed easily?





Aethiology

■ Systemic factors

Genetic predispositions

Systemic diseases (diabetes mellitus, leukaemia, HIV infection)

Side effects of drugs (cyklosporin A, immunosupresivs, cytostatika, calcium blockers)

Physiologic factors (pregnancy, climacterium, etc).

Periodontal diseases

- Inflammation at most!!!!
- The most important ethiological factor?

 **Dental plaque!!!!** 
BIOFILM

Diagnosis

- History
- Clinical examination
- Imaging methods (radiography)

Diagnosis and treatment plan



Patient's history

- Contemporary troubles
- Oral history
- Hygienic habits
- Professional and social situation
- Smoking
- Family history

Patient's history

- Diseases:

Hypertension

Cardiovascular diseases

Diabetes

Allergy

Rheumatism

... Others

- Farmakotherapy

Clinical examination

- Examination of oral hygiene
- Screening examination
- Complex check
- Special examination
- Status of oral hygiene
- Mucogingival diseases
- Imaging methods - radiogram

Inspection, probing

Examination of depth of gingival sulcus
(periodontal pocket)

in 4 points – mesiobuccally, buccally,
distobuccally, orally

Or in 6 points

Also mesioorally and distoorally

Pressure – 0,25 N (gentle probing)

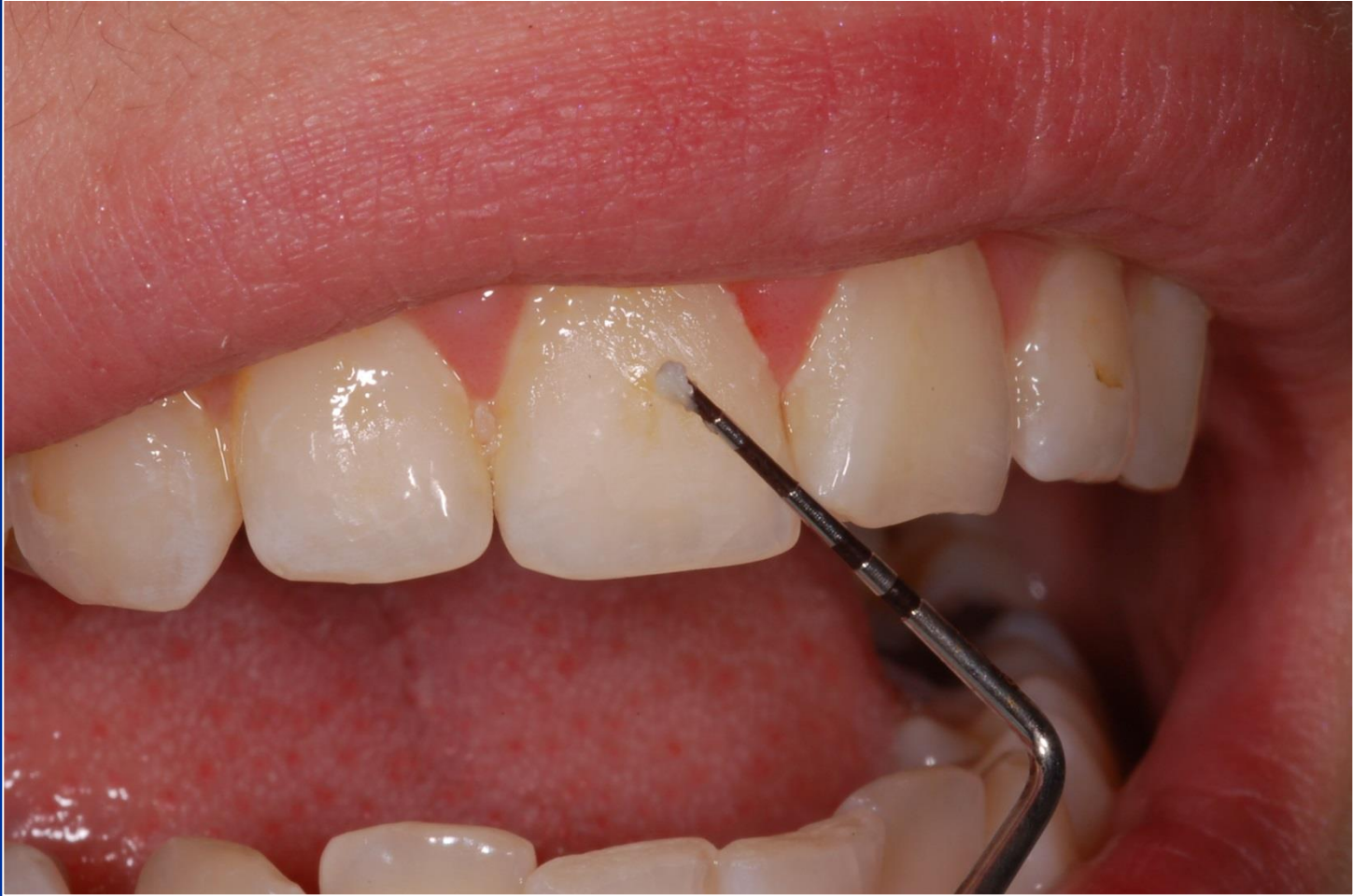Periodontal probes

- WHO probe
- Williams probe
- Nabers probe (for furcation)

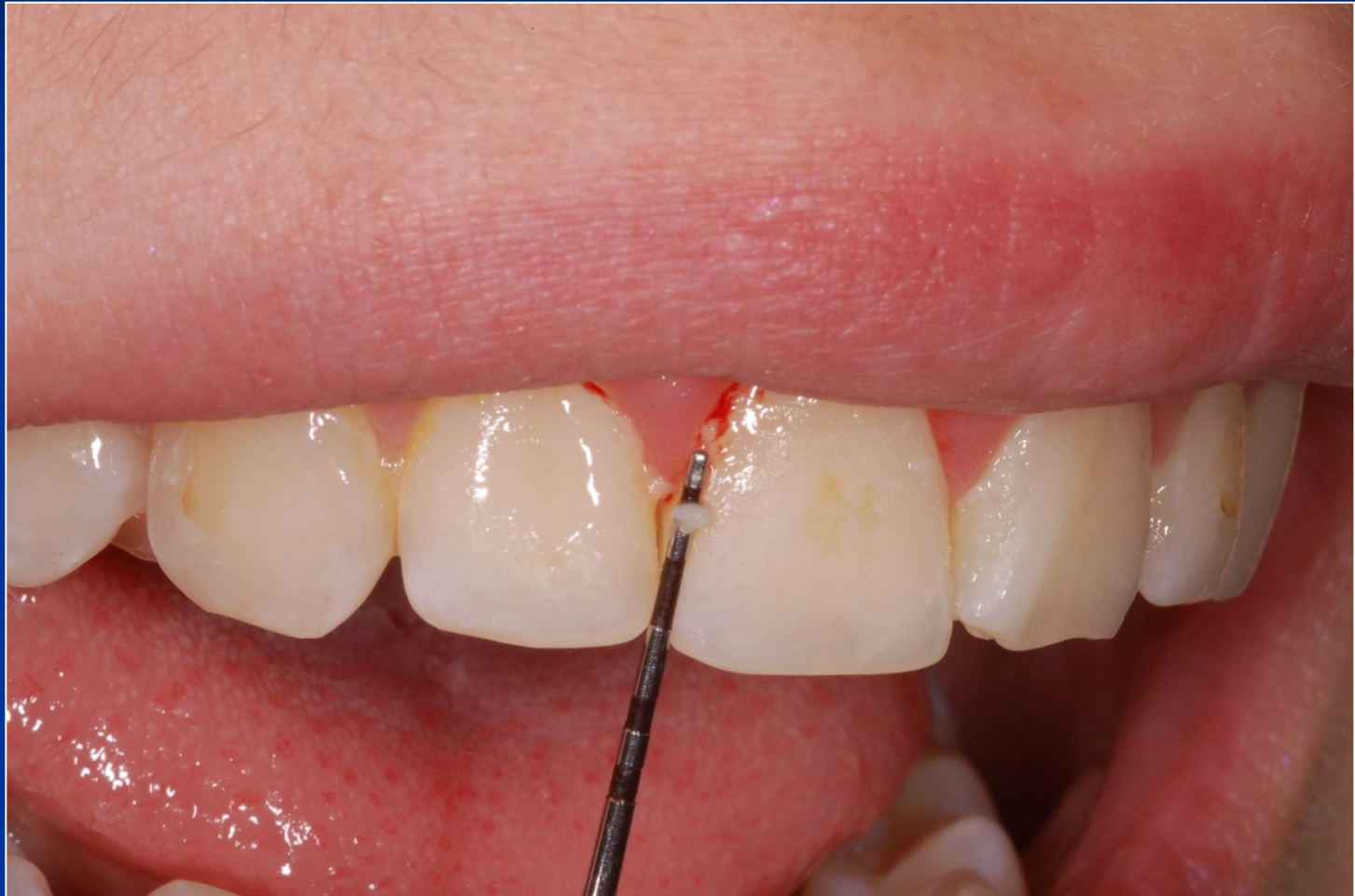Visualisation of dental plaque

- Sonda
- Barviva
- Tablety

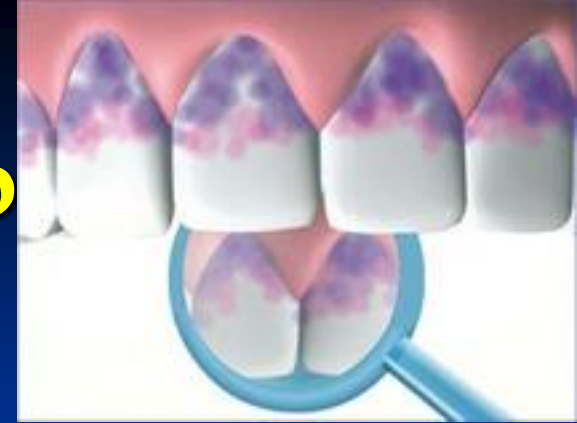Plaque



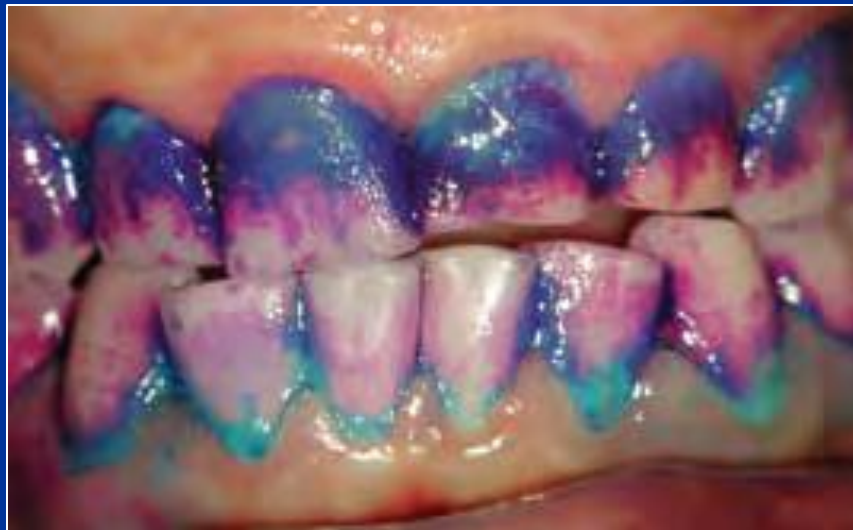Plaque induced inflammation



Detection of dental p



- Special dyes
- E.g. Tri Plague ID gel
- Blue- old plaque (48hours), red – fresh plaque, light blue – high risk (pH 4,5 – 5,5)



Indexes

- K vyšetření orálního zdraví (ve vztahu ke kazu a onemocněním parodontu)
- Ke kontrolám terapeutických opatření

U všech zubů nebo u 16,21,24,36,41,44.

Skóre se dělí počtem vyšetřených míst

Gravimetrické a planimetrické testy

Indexes – special figures

- Level of oral hygiene
- Stage of inflammation
- Treatment needs ...

Plaque-index (Quigley, Hein)

- 0: No plaque
- 1: isolated regions
- 2: line of plaque along the gingival border
- 3: plaque in cervical third of the crown
- 4: plaque in the middle third of the crown
- 5: plaque in coronal third of the crown

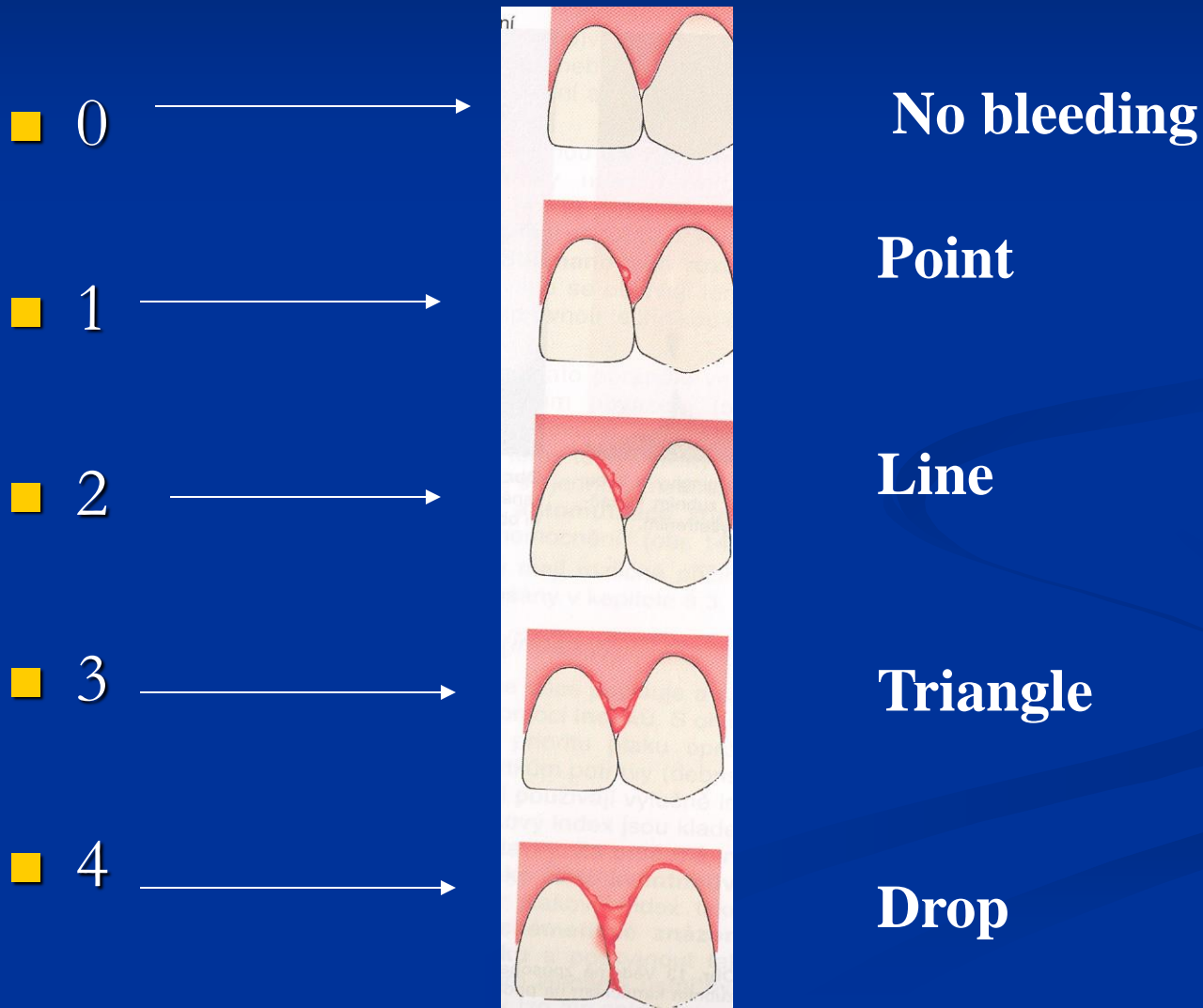
Approximal Plaque-Index (API)(Lange)

- Yes (1) or no (0)
- $API = (\text{sum of positive findings} / \text{sum of investigated approximal spaces}) \times 10$
(multiplied by 10).

Plaque-Index (API)(Lange)

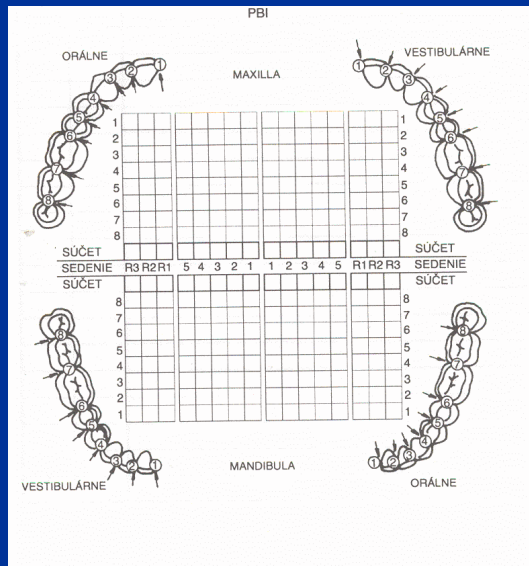
- API 25 % optimal OH
- API 25–39 % good OH
- API 40–69 % wears OH
- API 70–100 % insufficient OH

PBI (papilla bleeding) index



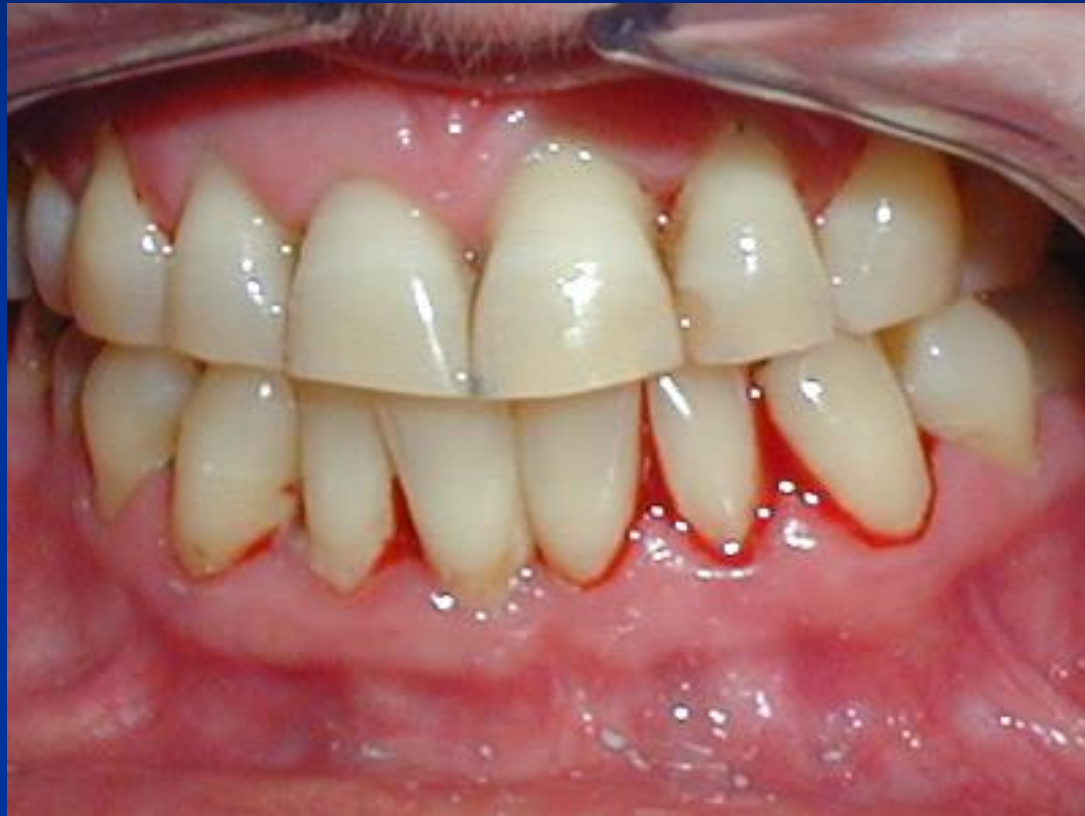Measurement and assesment

- Sume or sume divided by number of investigated papillas



1 2
 3 2
 3 1
 2 2
 1 0
 0 2
 2 3
12 14
 1 1
 2 2
 0 4
 0 3
 3 4
 2 3
 1 0
9 17

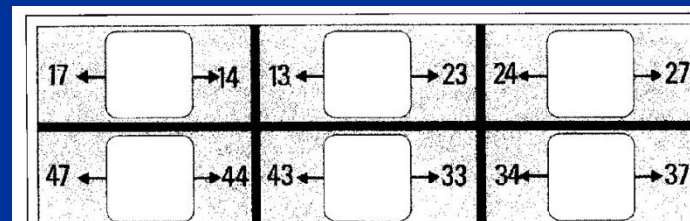

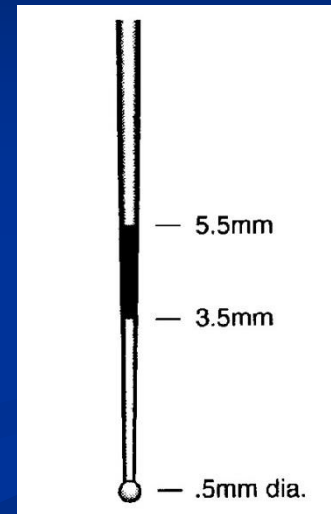
$52:28 = 1,8$
 $52/28$



CPITN

(Community periodontal index of treatment needs)

Kód	Nález	Potřeba ošetření
0	normální	0 bez potřeby léčení
1	krvácení po sondování	I hygienická instruktáž
2	supra- nebo subgingivální zubí kámen, iatrogenní marginální dráždění	II I + supra- a subgingivální scaling
3	choboty 3,5–5,5 mm	
4	choboty > 6 mm	III I + II + chirurgická léčba



Depth of periodontal pockets

Status a léčebný plán Datum:

léčebný plán													kyretáž U/O
													protetika
Nález													děha
													furkace F1 F2 F3
													viklavost I II III
													recesy [mm]

10
8
6
4
2

vestibulárně
HČ
orálně

10
8
6
4
2

vitalita + / -

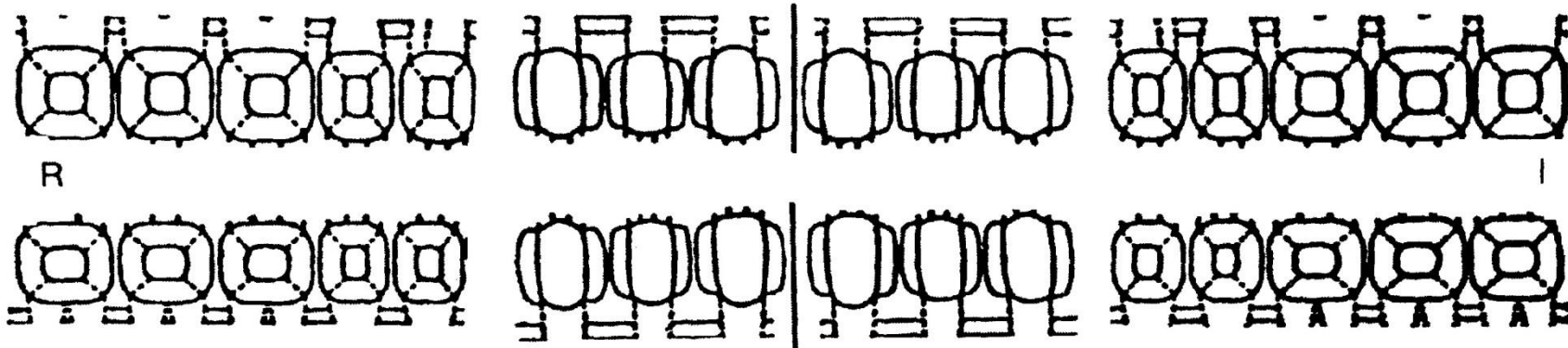
orálně
DČ
vestibulárně

2
4
6
8
10

10
8
6
4
2

vitalita + / -

Nález													recesy [mm]
													viklavost I II III
													furkace F1 F2 F3
													děha
													protetika
													kyretáž U/O



Povlaky

0	<input type="checkbox"/>	málo plaku
1	<input type="checkbox"/>	hodně plaku
2	<input type="checkbox"/>	zubní kámen
3	<input type="checkbox"/>	konkrementy

Převládající hloubka chobotů

0	<input type="checkbox"/>	1–3 mm
1	<input type="checkbox"/>	4–6 mm
2	<input type="checkbox"/>	> 7mm

Převládající viklavost

0	<input type="checkbox"/>	Vikl. 0
1	<input type="checkbox"/>	Vikl. I. st.
2	<input type="checkbox"/>	Vikl. II. st.
3	<input type="checkbox"/>	Vikl. III. st.

Převládající klin. dg.

0	<input type="checkbox"/>	Normální parodont
1	<input type="checkbox"/>	Gingivitis
2	<input type="checkbox"/>	Parodontitis počínající
3	<input type="checkbox"/>	Parodontitis pokročilá

Gingiva

0	<input type="checkbox"/>	Normální
1	<input type="checkbox"/>	Lehký edém
2	<input type="checkbox"/>	Výrazný edém
3	<input type="checkbox"/>	Porucha tvaru

Převládající krvácivost

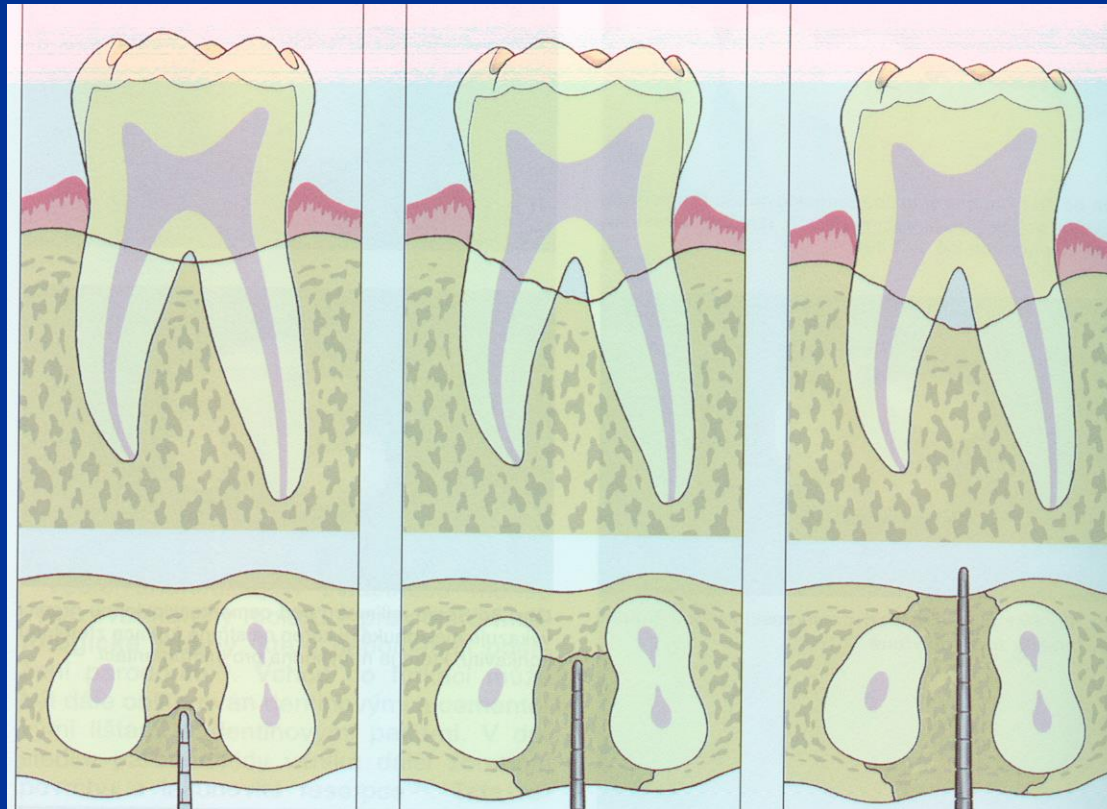0	<input type="checkbox"/>	Žádná
1	<input type="checkbox"/>	Opožděná
2	<input type="checkbox"/>	Spontánní

index pro zubní plak () =

gingivální index () =

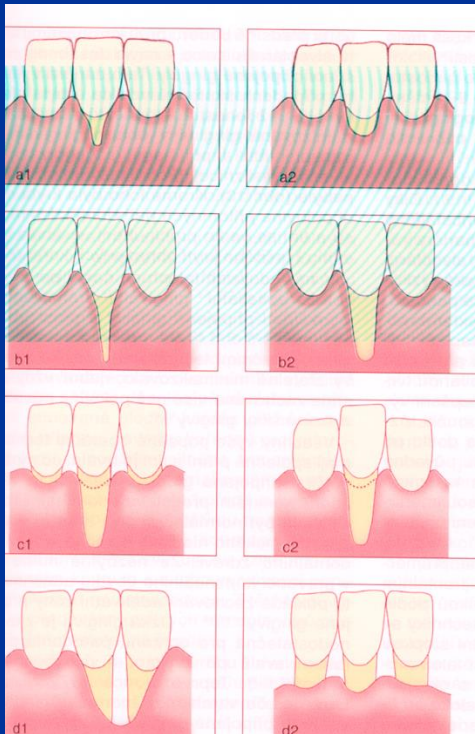
Furcations

- Klasifikace I. – III.



Gingival recessions

■ Classification

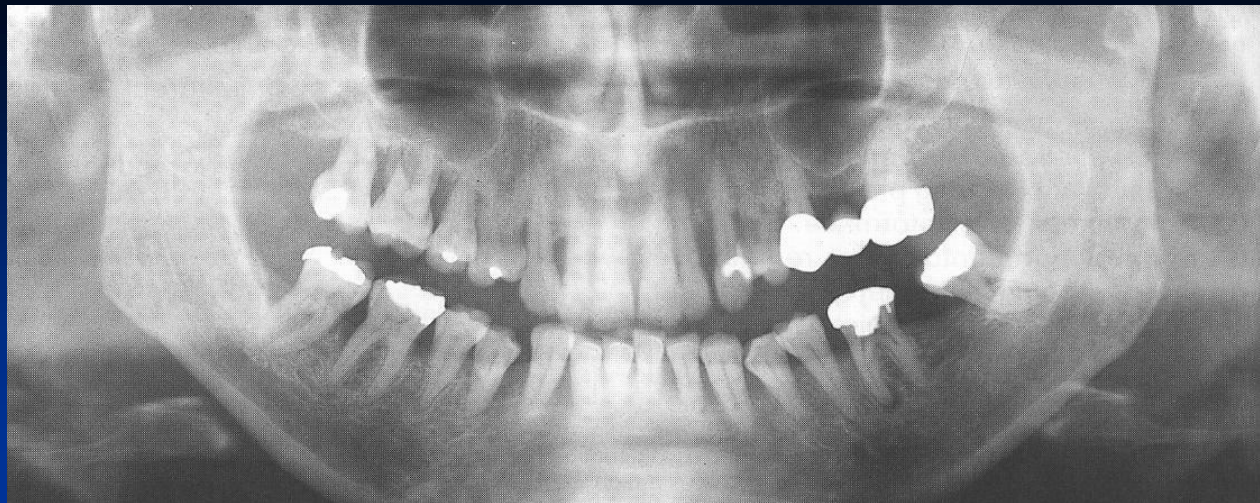

1

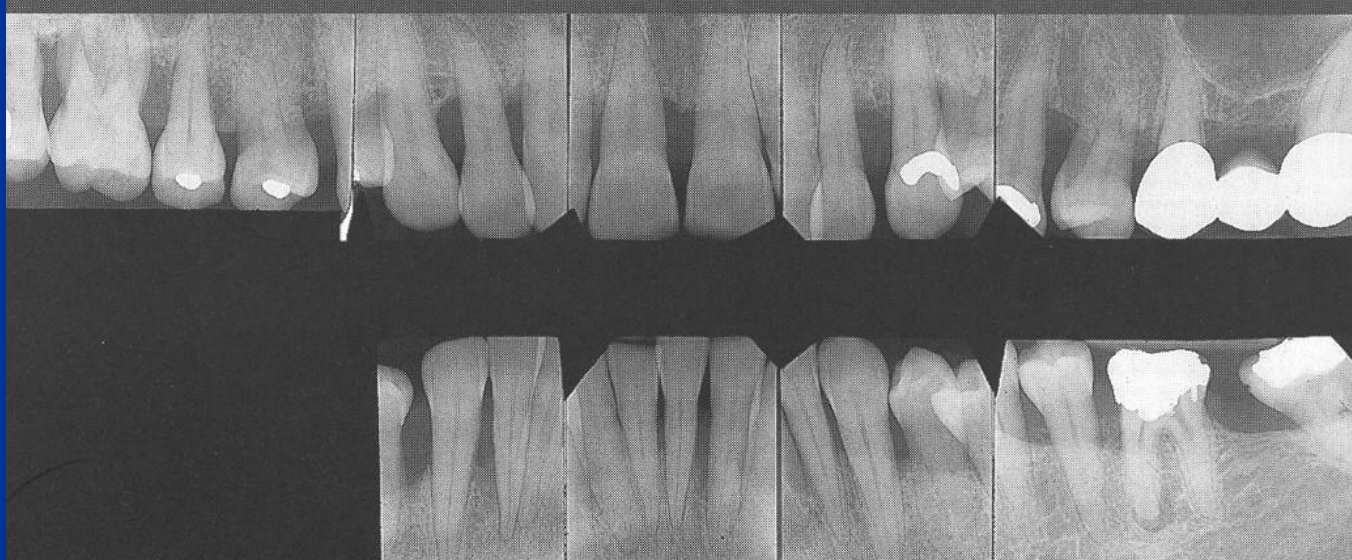
2

3

4



Radiographic investigation



Treatment plan

Initial phase

Oral hygiene— professional and home care

Extractions, fillings RCT.

Subgingival treatment

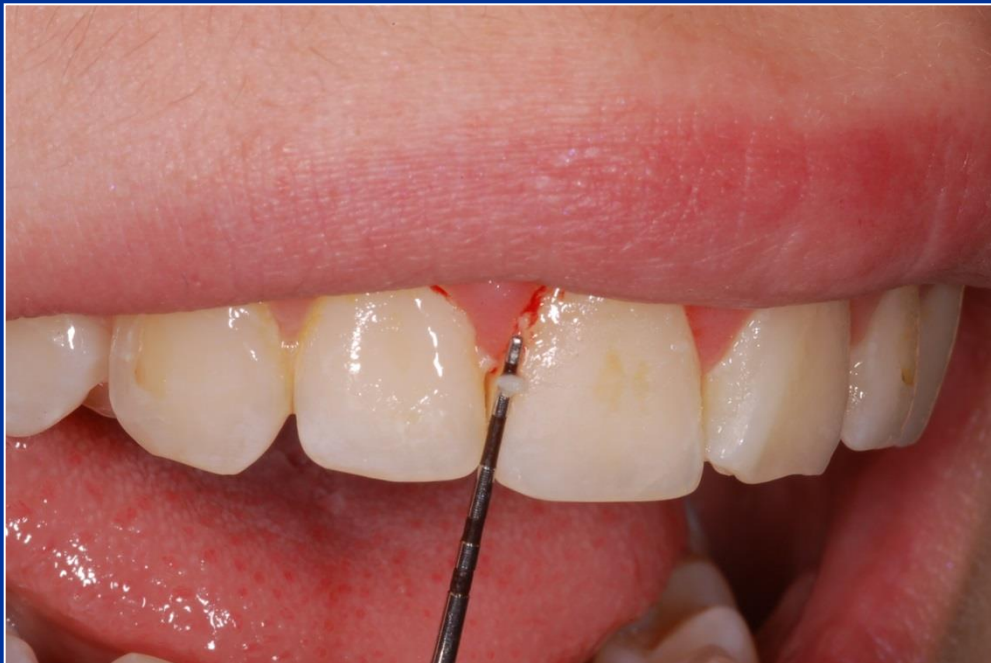Surgical treatment

Prosthetic treatment

Parodontopathies

Gingivitis

■ Plaque associated gingivitis



Chronic form

Erythema

No pain

Easy bleeding

Plaque on the tooth

Acute form

Erythema

Pain

Easy bleeding

Plaque on the
tooth

Parodontopathies

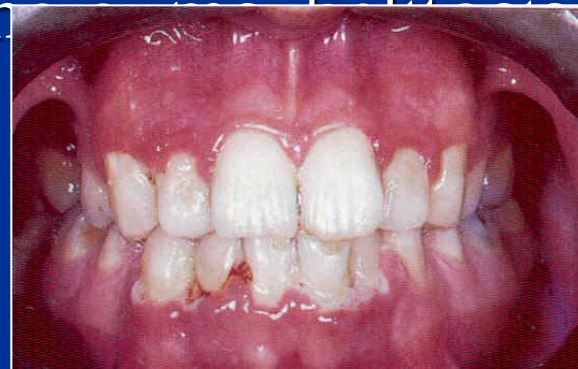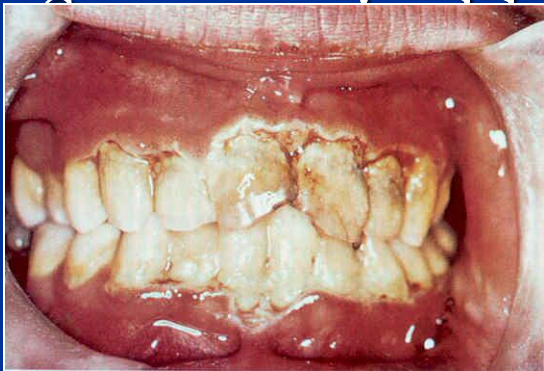Gingivitis

- Plaque modulates gingivitis

Changes on gingiva worsen by dental plaque

The clinical picture

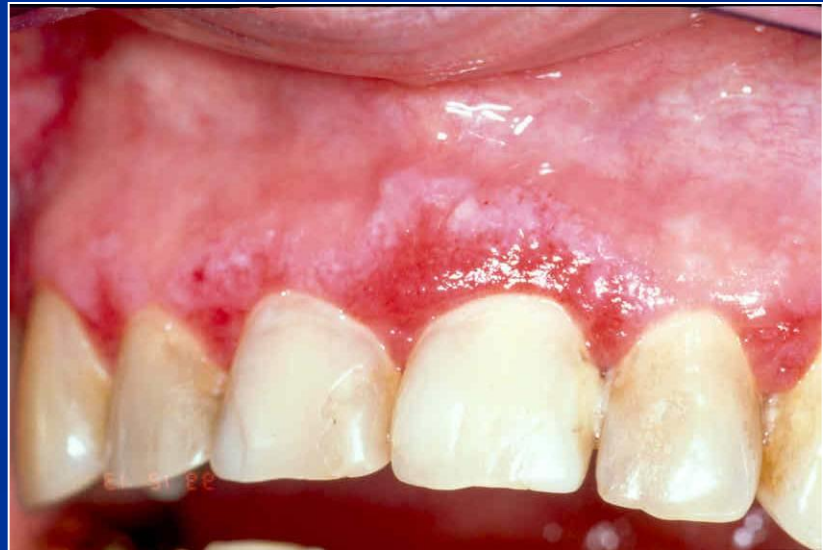- Gingival inflammation and destruction
- ANUG



Atrophic or desquamative gingivitis

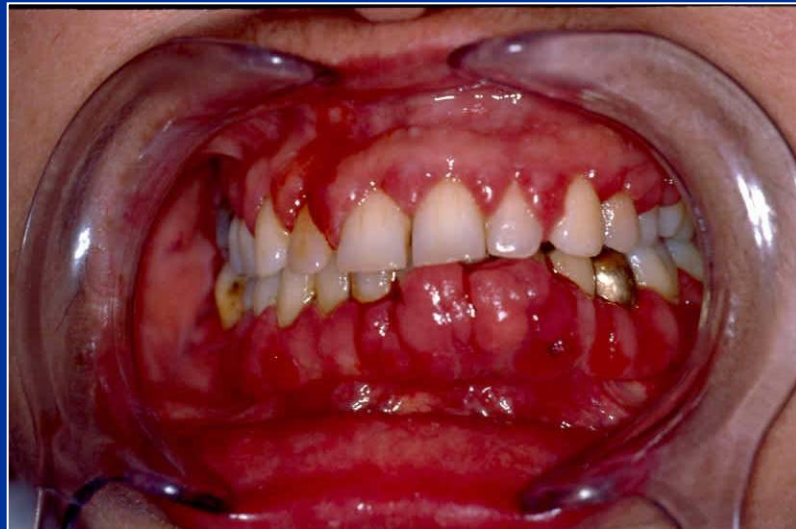
symptoms

- Erythema on free gingiva – loss of the epithelium
- Variety of symptoms: itching, tenderness of eating, burning.



Hyperplastic gingivitis

- High standard of oral hygiene must be achieved!
- Gingivectomy (drugs induced)



Parodontopathies

Periodontitis

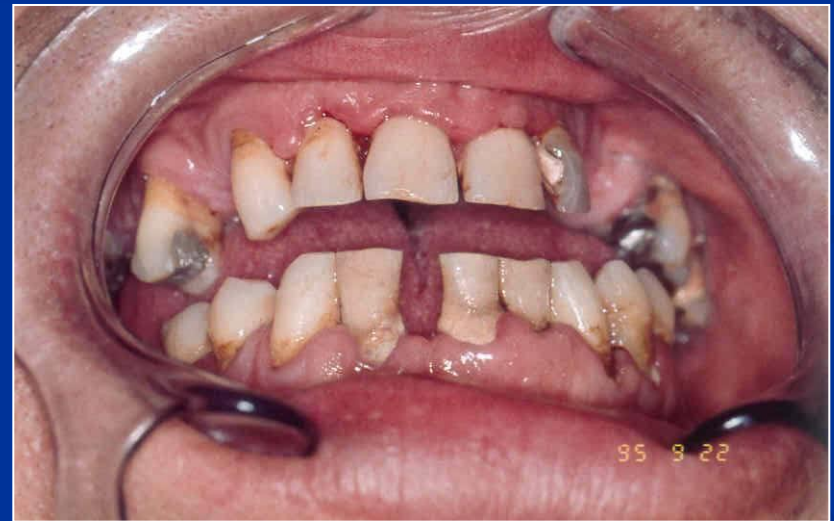- Chronic periodontitis.
- Aggressive periodontitis.
- Periodontitis as a manifestation of systemic disease.
- Necrotizing periodontal diseases.
- Abscesses of the periodontium.
- Periodontitis associated with endodontic lesions.
- Development or acquired deformities and conditions.

Periodontitis

- Inflammation in deeper structures of periodontium

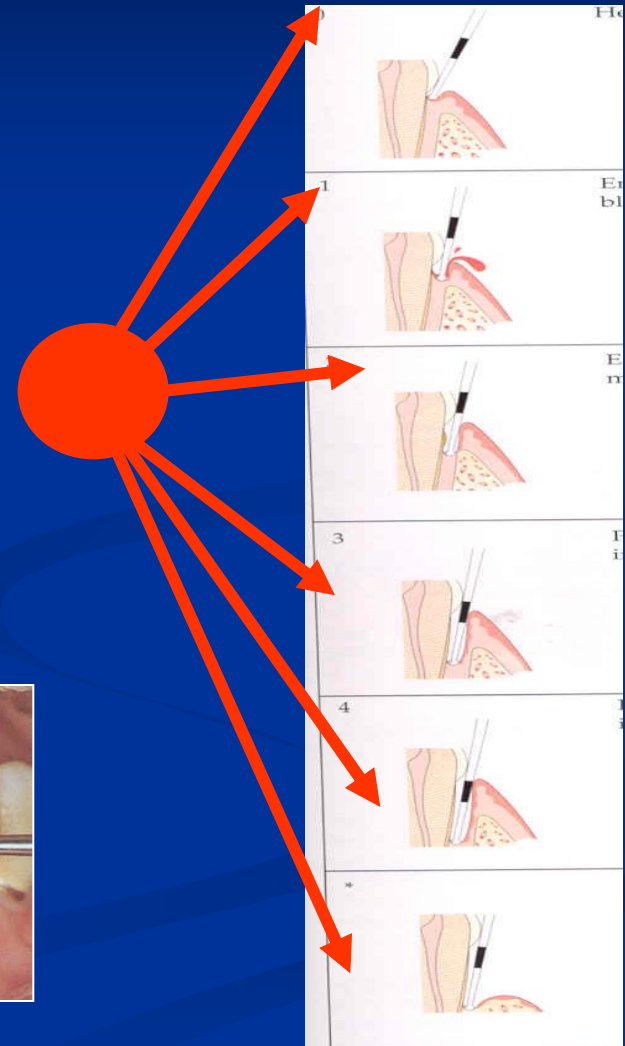
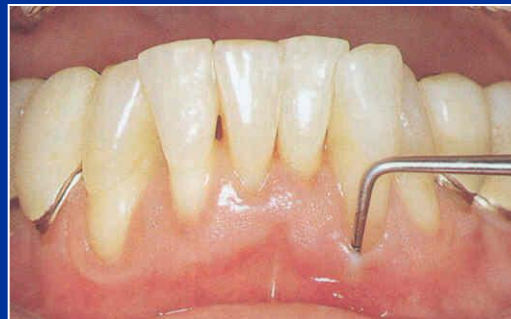Periodontitis

- Gingivitis
- Pocketing
- Loss of alveolar bone
- Drifting and mobility
- Furcation exposures
- Recession



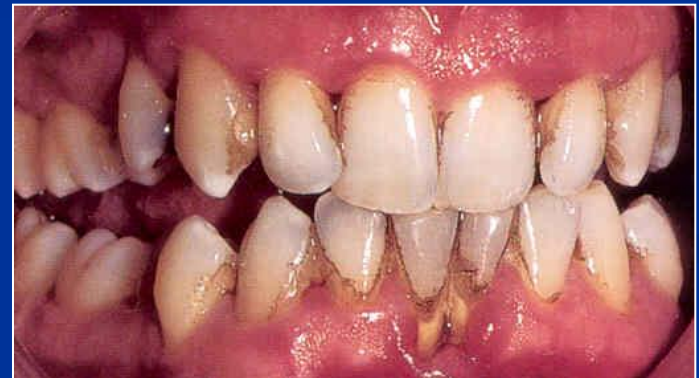Periodontitis

- Gingivitis
- Pocketing
- Loss of alveolar bone
- Drifting and mobility
- Furcation exposures
- Recession



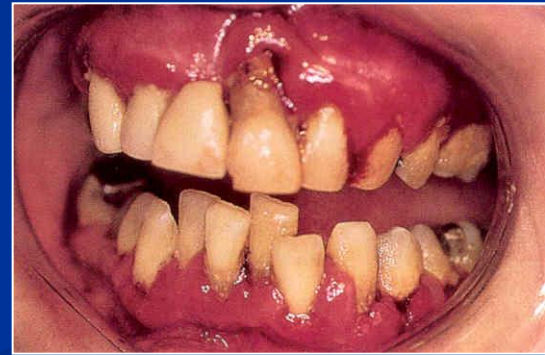Periodontitis

- Gingivitis
- Pocketing
- Loss of alveolar bone
- Drifting and mobility
- Furcation exposures
- Recession



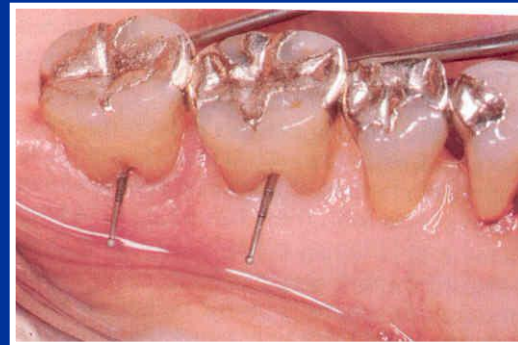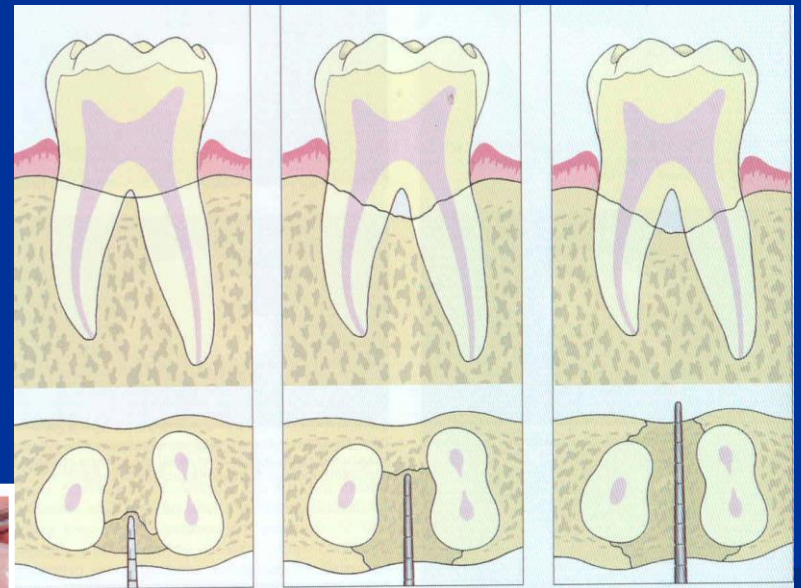

Periodontitis

- Gingivitis
- Pocketing
- Loss of alveolar bone
- Drifting and mobility
- Furcation exposures
- Recession



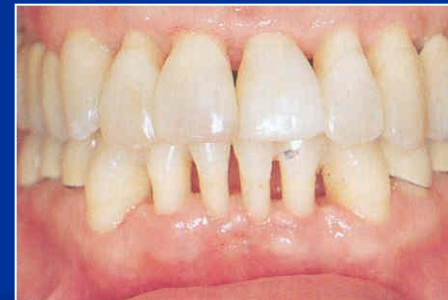Periodontitis

- Gingivitis
- Pocketing
- Loss of alveolar bone
- Drifting and mobility
- Furcation exposures
- Recession



Periodontitis

- Gingivitis
- Pocketing
- Loss of alveolar bone
- Drifting and mobility
- Furcation exposures
- Recession

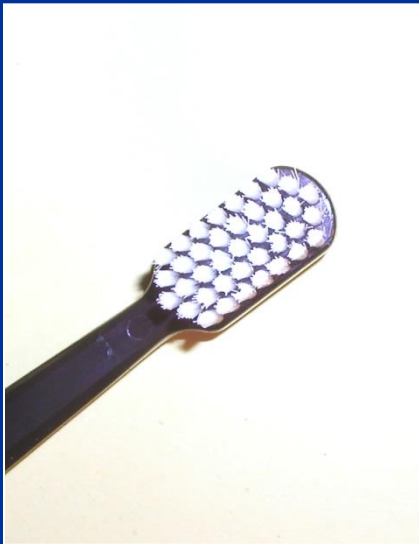

Periodontitis

- Chronic adult periodontitis
- Aggressive periodontitis
- Early onset periodontitis

Therapy

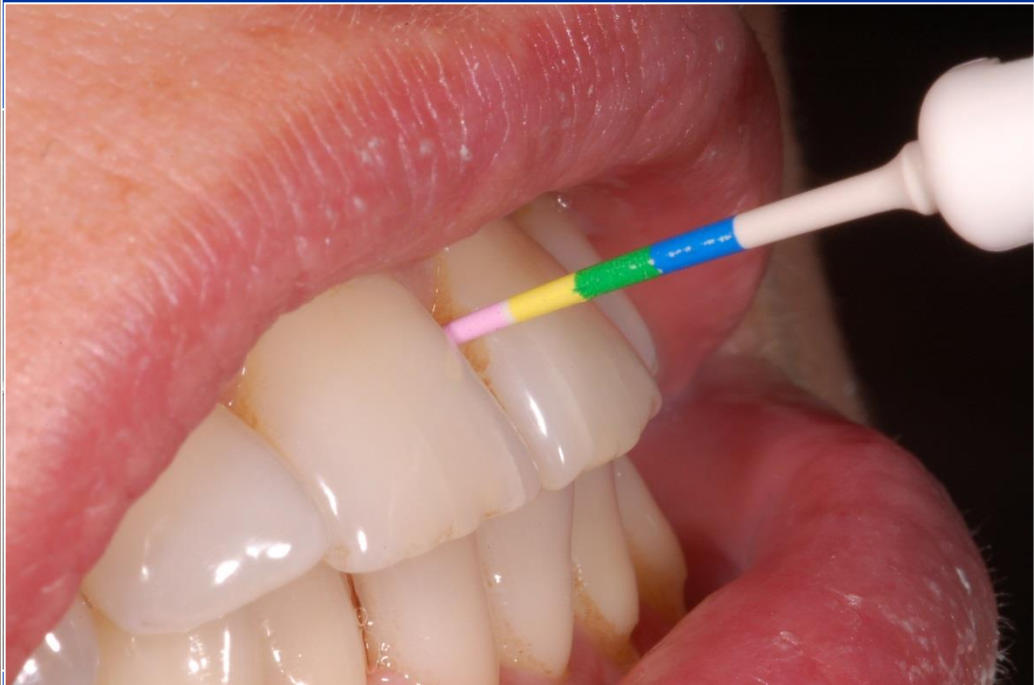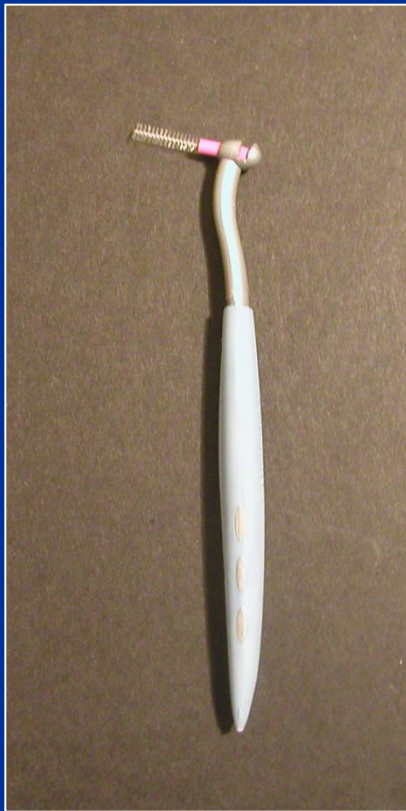- 1. Oral hygiene - professional, home care
INDIVIDUAL



Therapy

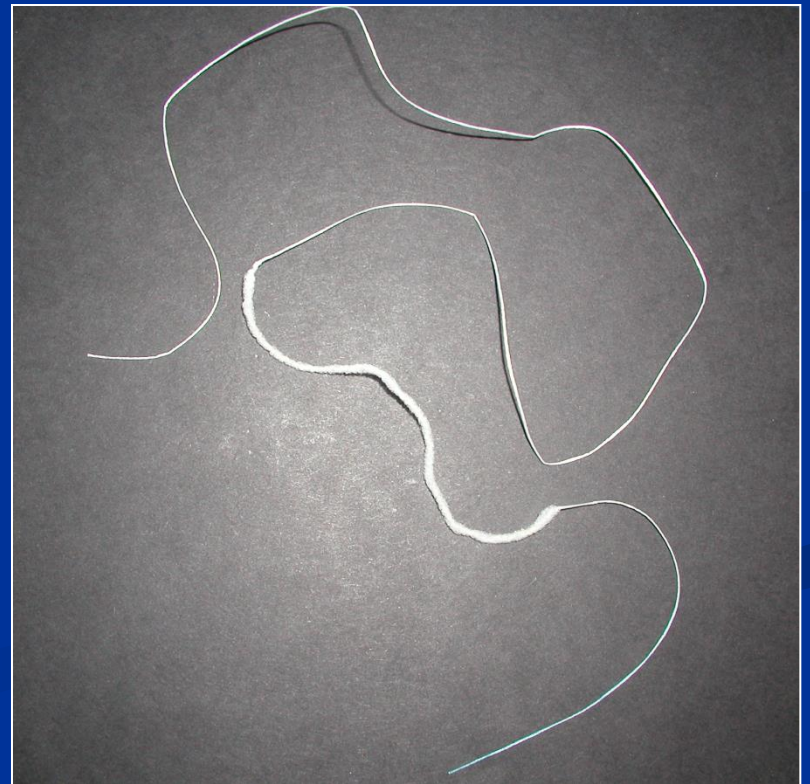

- 1. Oral hygiene - professional, home care

INDIVIDUAL

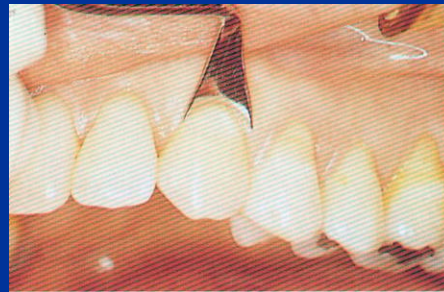
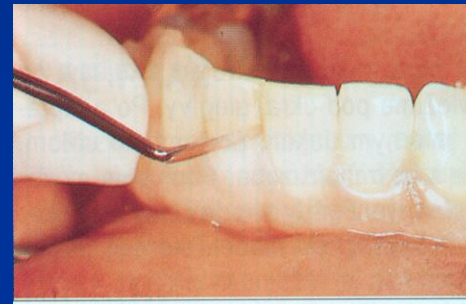
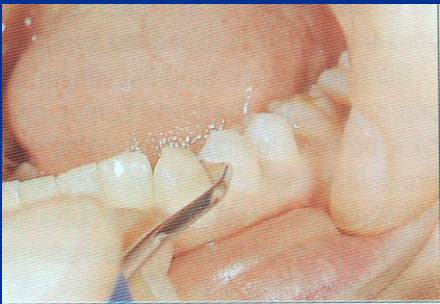

Therapy

- 1. Oral hygiene - professional, home care
INDIVIDUAL

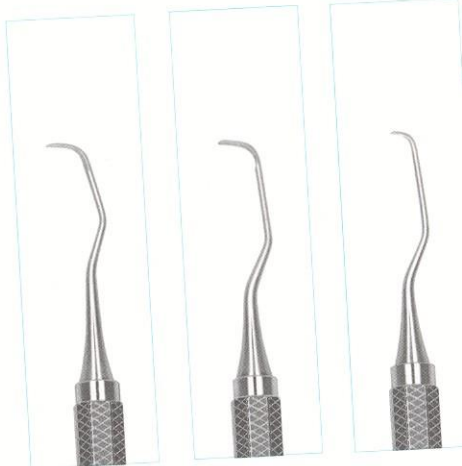
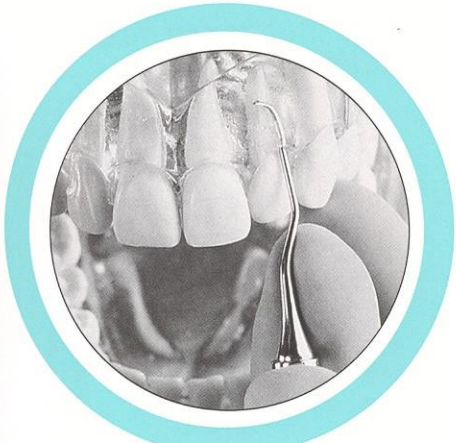
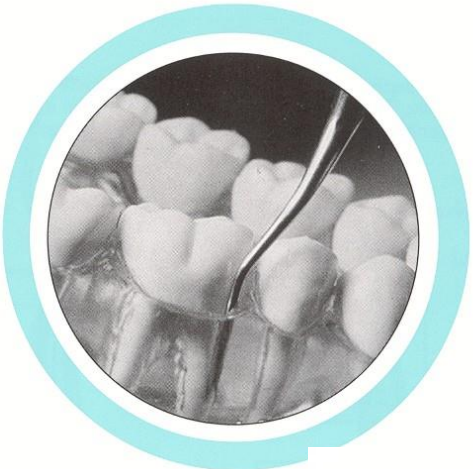
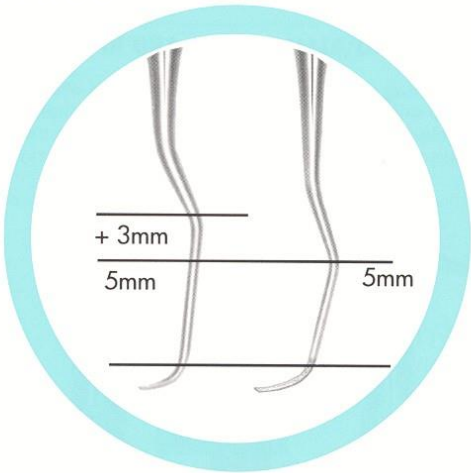
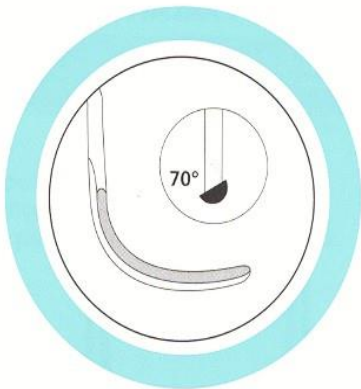
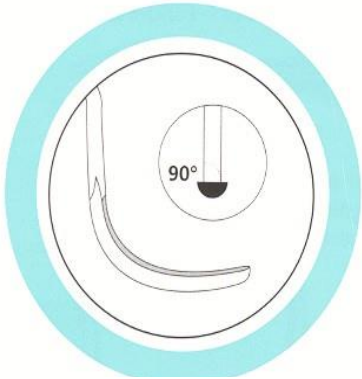
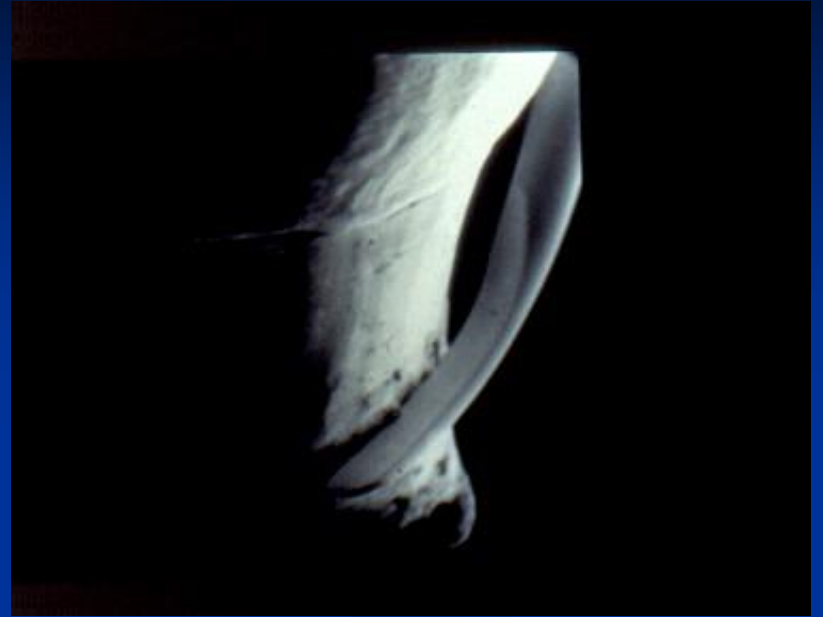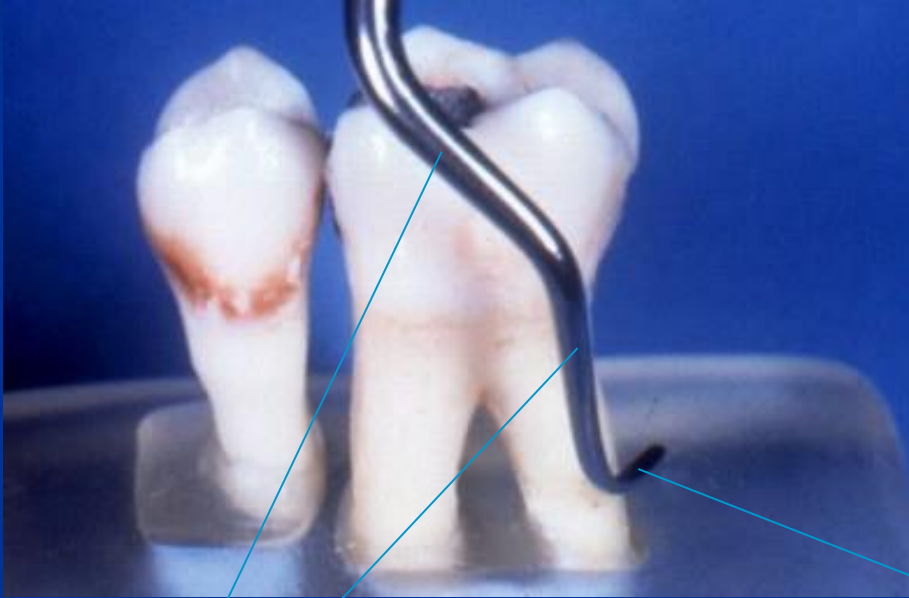Scalers – sharp pointed instruments for removal of supragingival calculus



Curretes

Universal Special (Gracey)



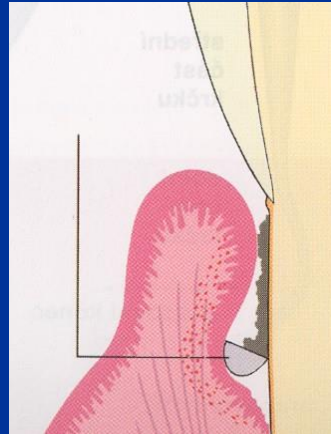
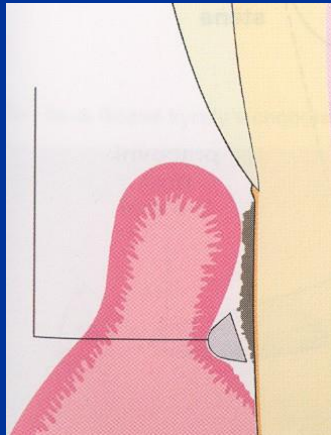


Shank

Edge

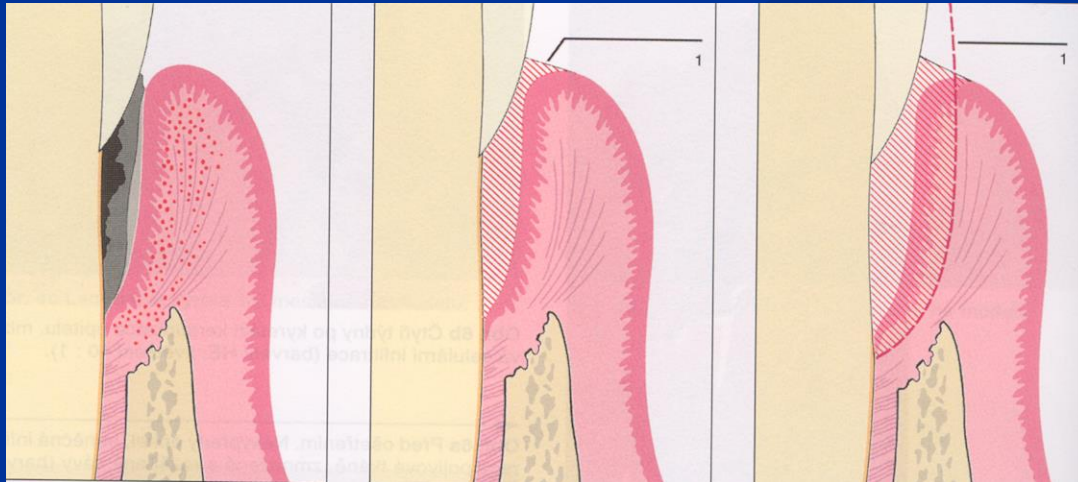

Scaling, root planing

- Gracey curretes, cleaning of the root surface



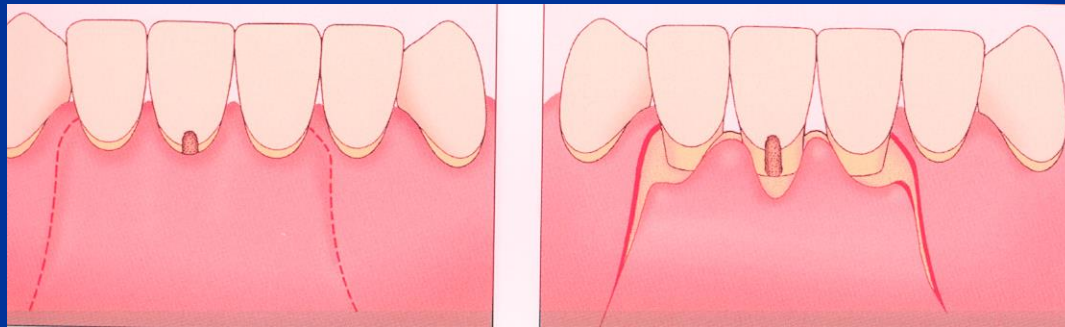
Therapy

- 2. Subgingival treatment – scaling root planing, curettage



Therapy

- 3. Periodontal surgery

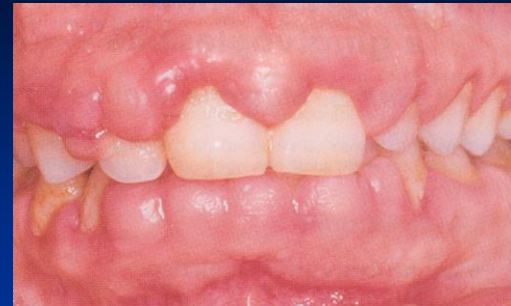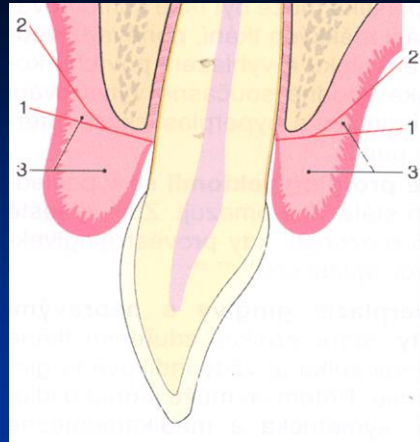


Gingivectomy, gingivoplastic

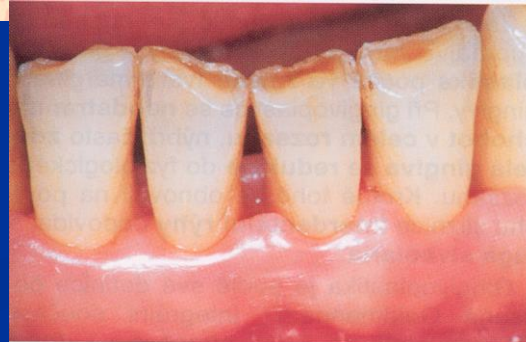
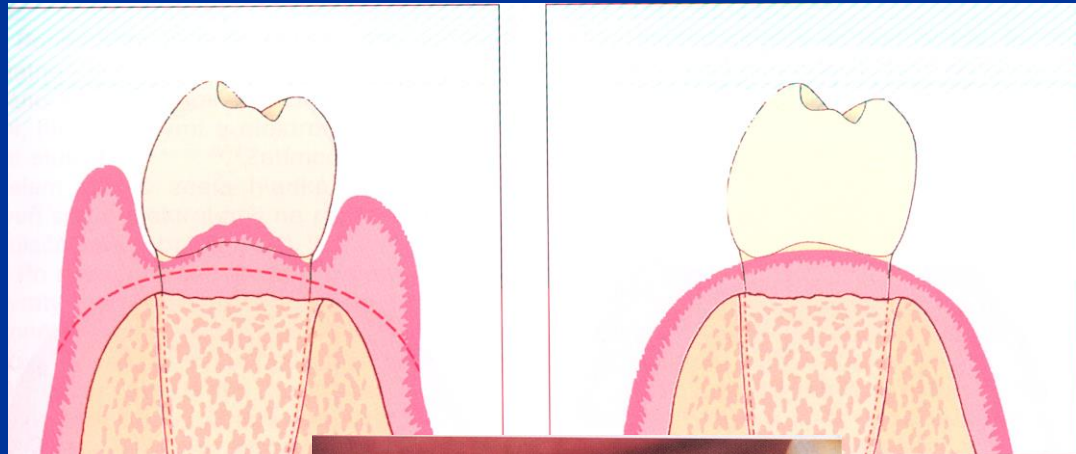
Indications of gingivectomy

- Hyperplasia gingivae (pseudopockets)
- Supraalveolar periodontal pockets with the horizontal bone resorption
- - Bad configuration of the gingival margin or papilla fol. ANUG or extraction.

Gingivectomy

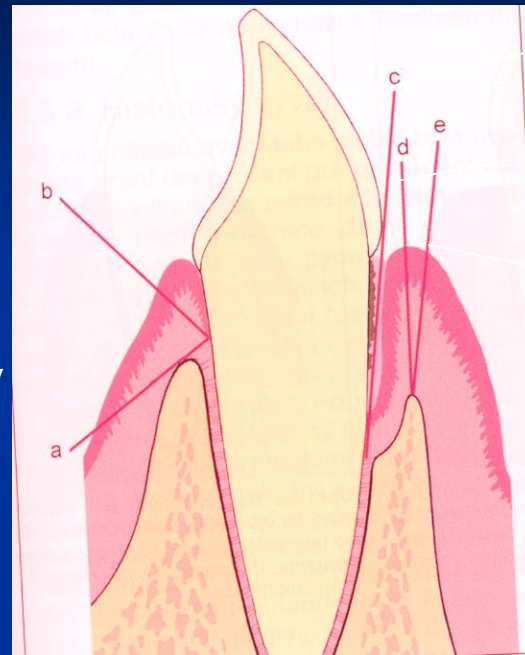


Gingivoplastic



Internal gingivectomy

External gingivectomy



Intrasulcular

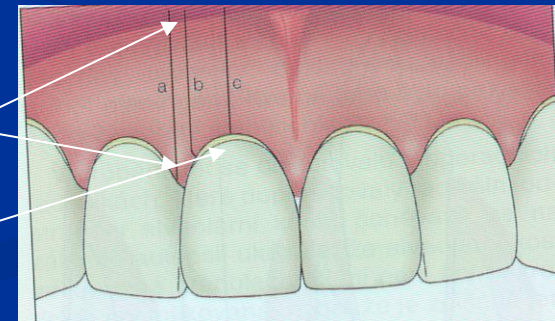
Marginal

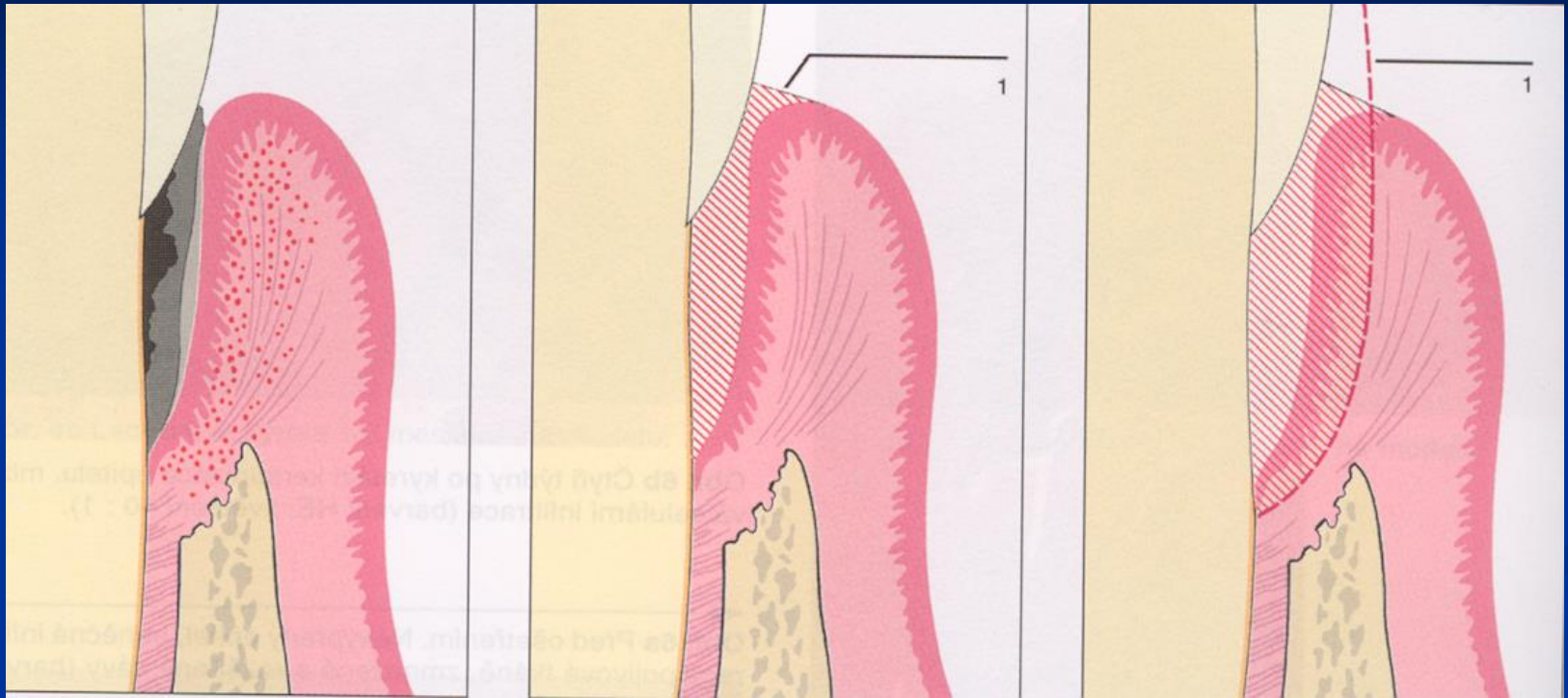
Paramarginal

Papilar

Paramedial

Medial





Closed curettage

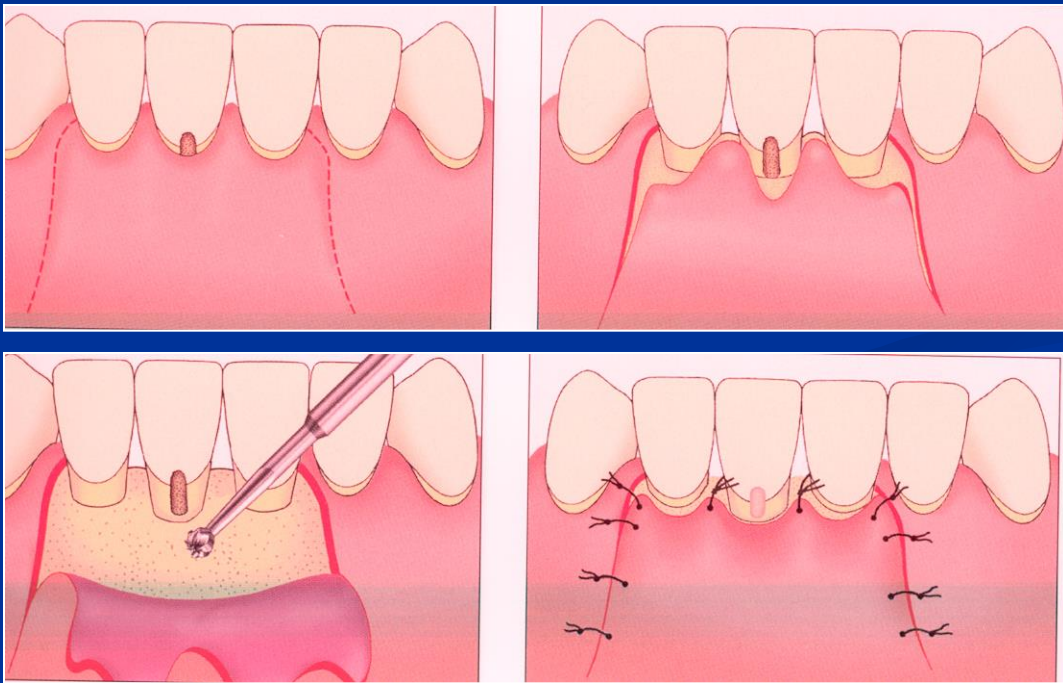
Flap operation

Resective

Regenerative

Apical flap

Replaced flap



Mucogingival surgery

- Enlargement of attached gingiva
 - Frenulectomy
 - Vestibuloplastic

- Plastic of recessus
 - Lateral flap
 - Bridge flap
 - Mucous or mesenchymal grafts

