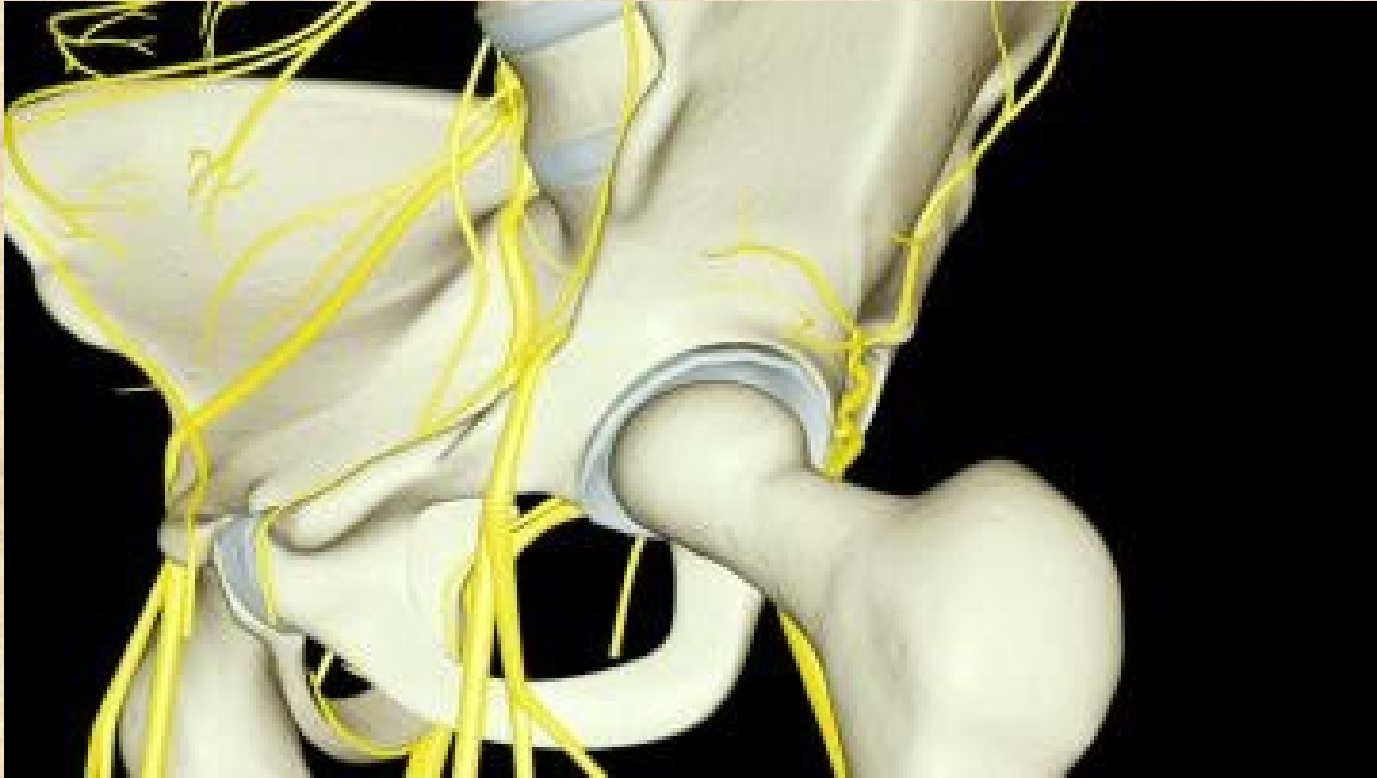


# Plexus lumbalis et sacralis



# Plexus lumbalis L1-L4

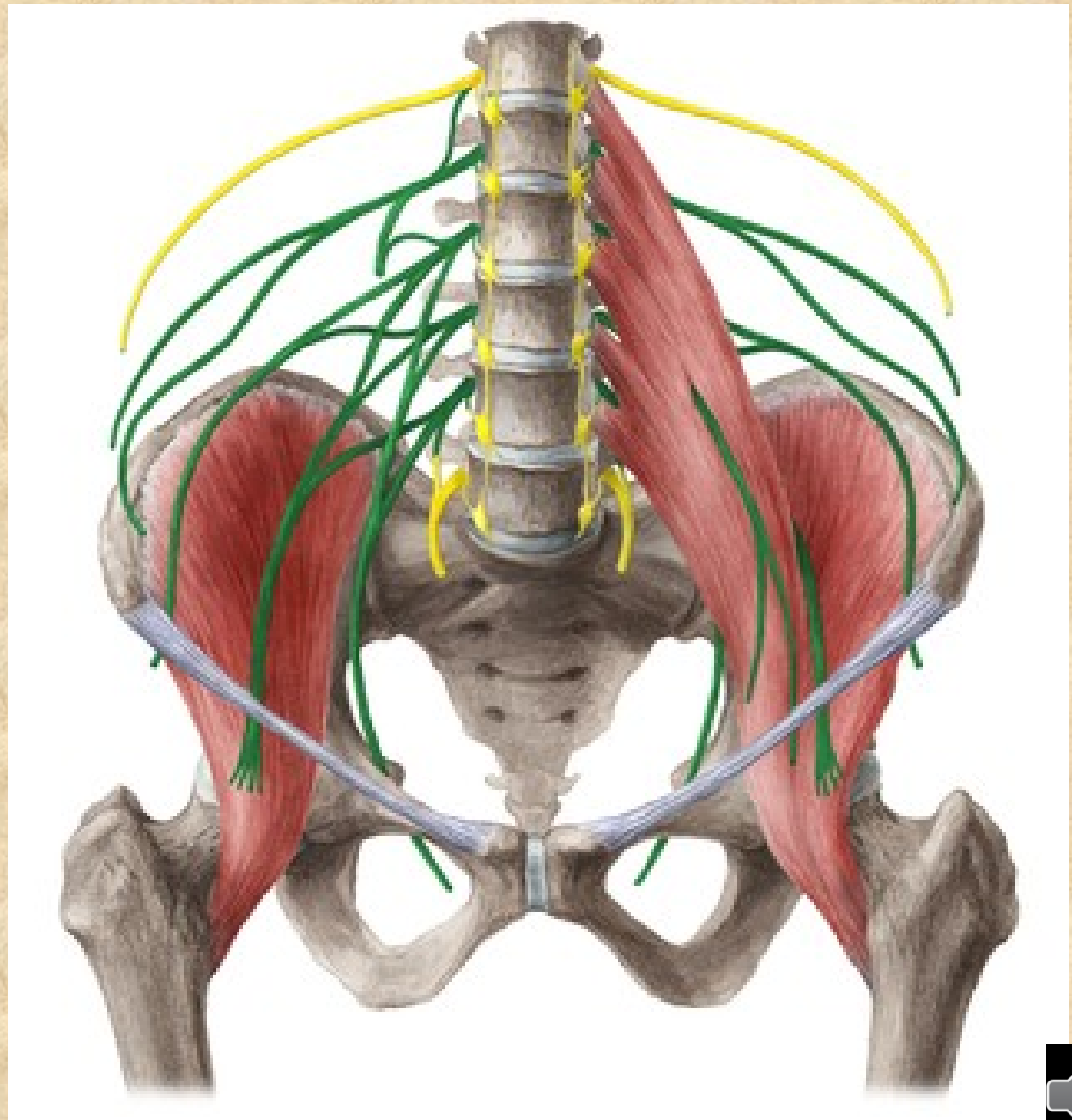
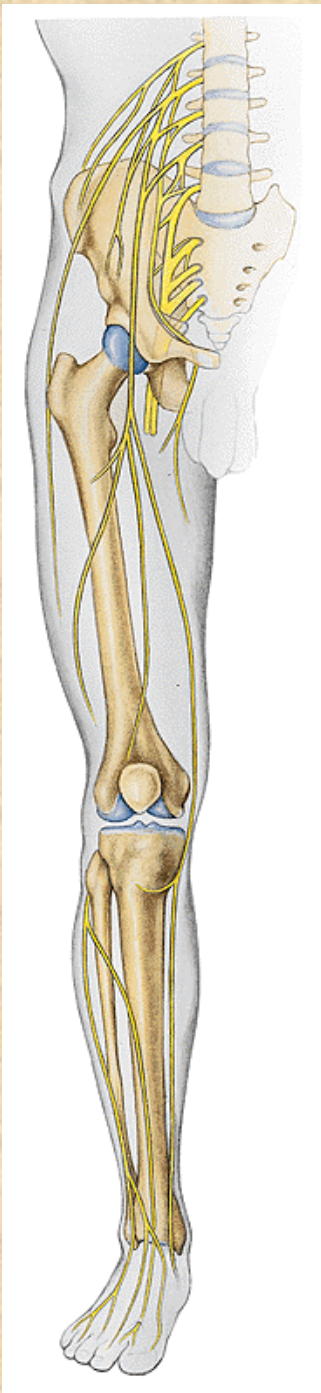
## senzoricky

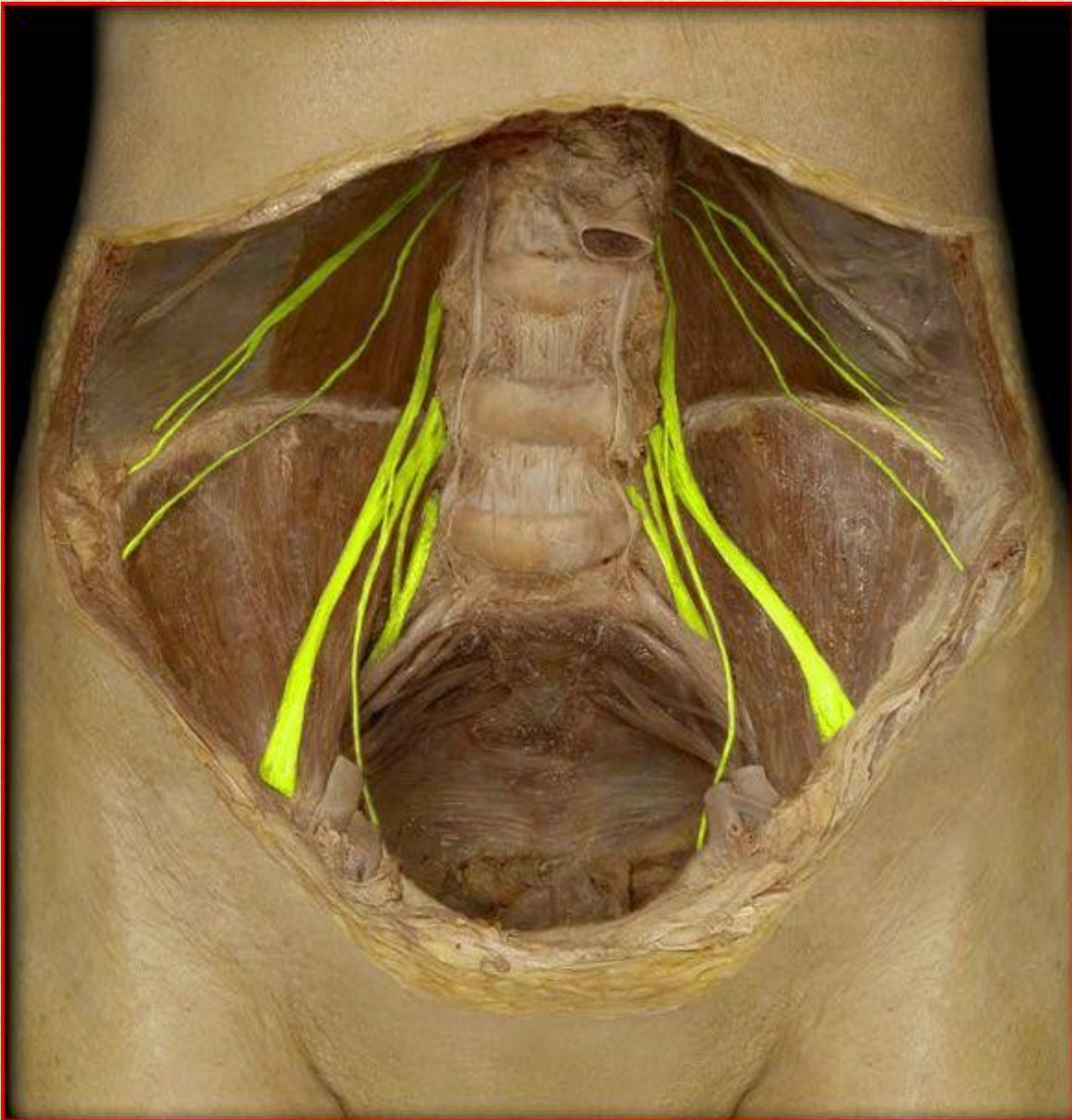
kůži v bederní oblasti a kůži na přední a mediální ploše stehna a bérce

## motoricky

zadní a částečně boční skupinu břišních svalů, dále přední skupinu svalů pánevních a přední a mediální skupinu stehenních svalů

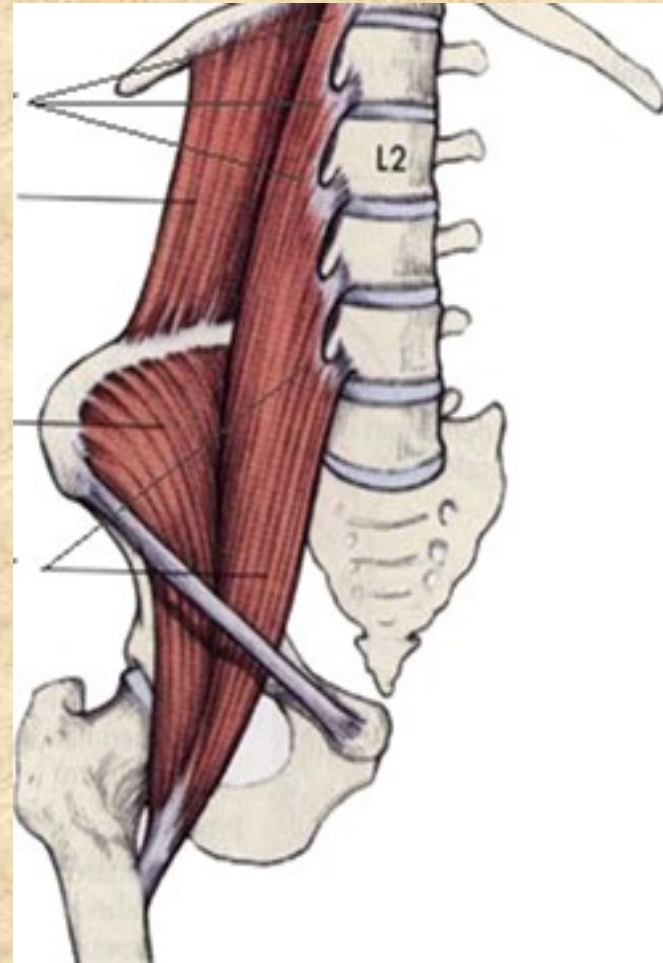




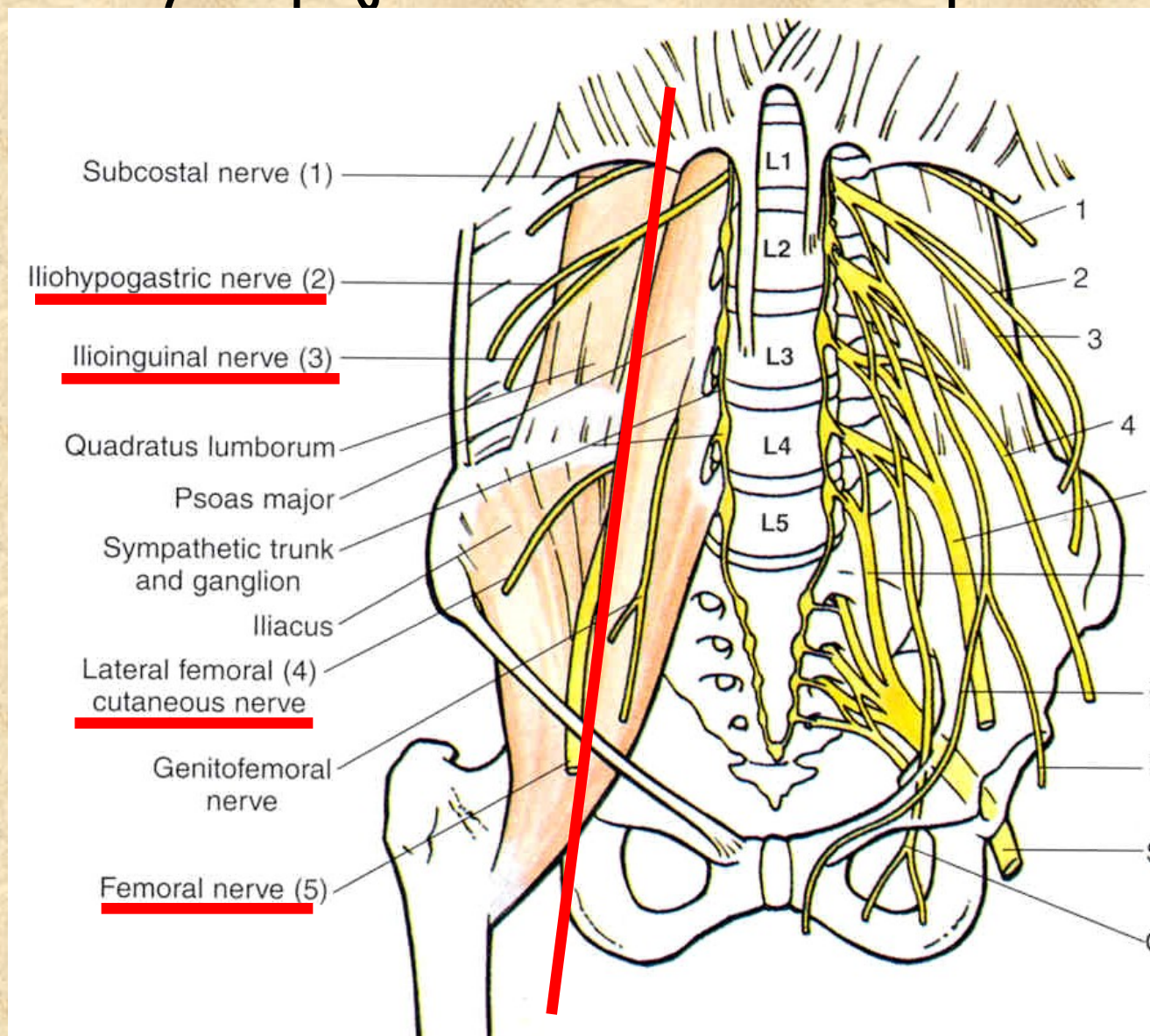


# Větve plexus lumbalis

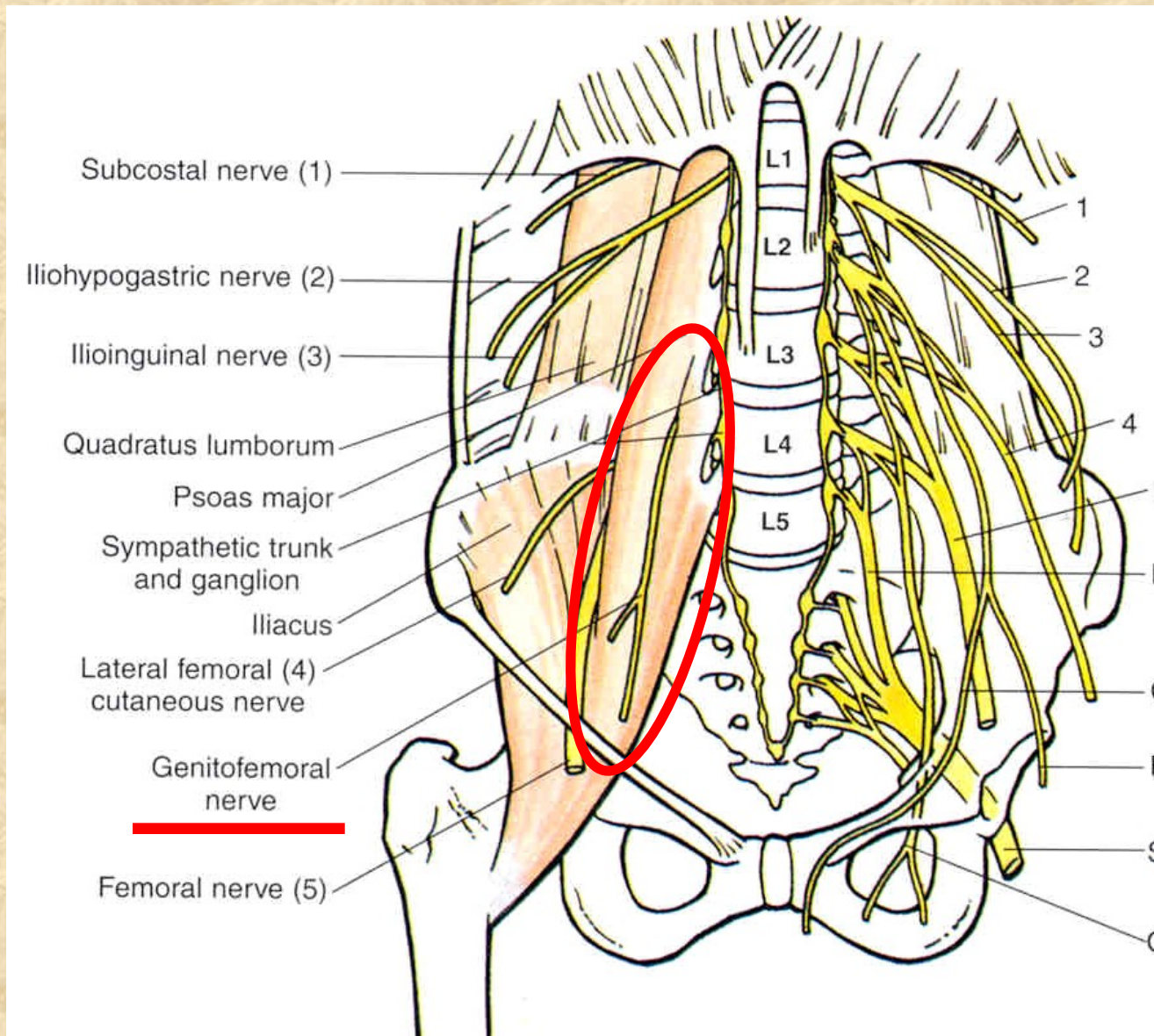
- Rr. musculares (m. psoas major, m. psoas minor, m. quadratus lumborum)



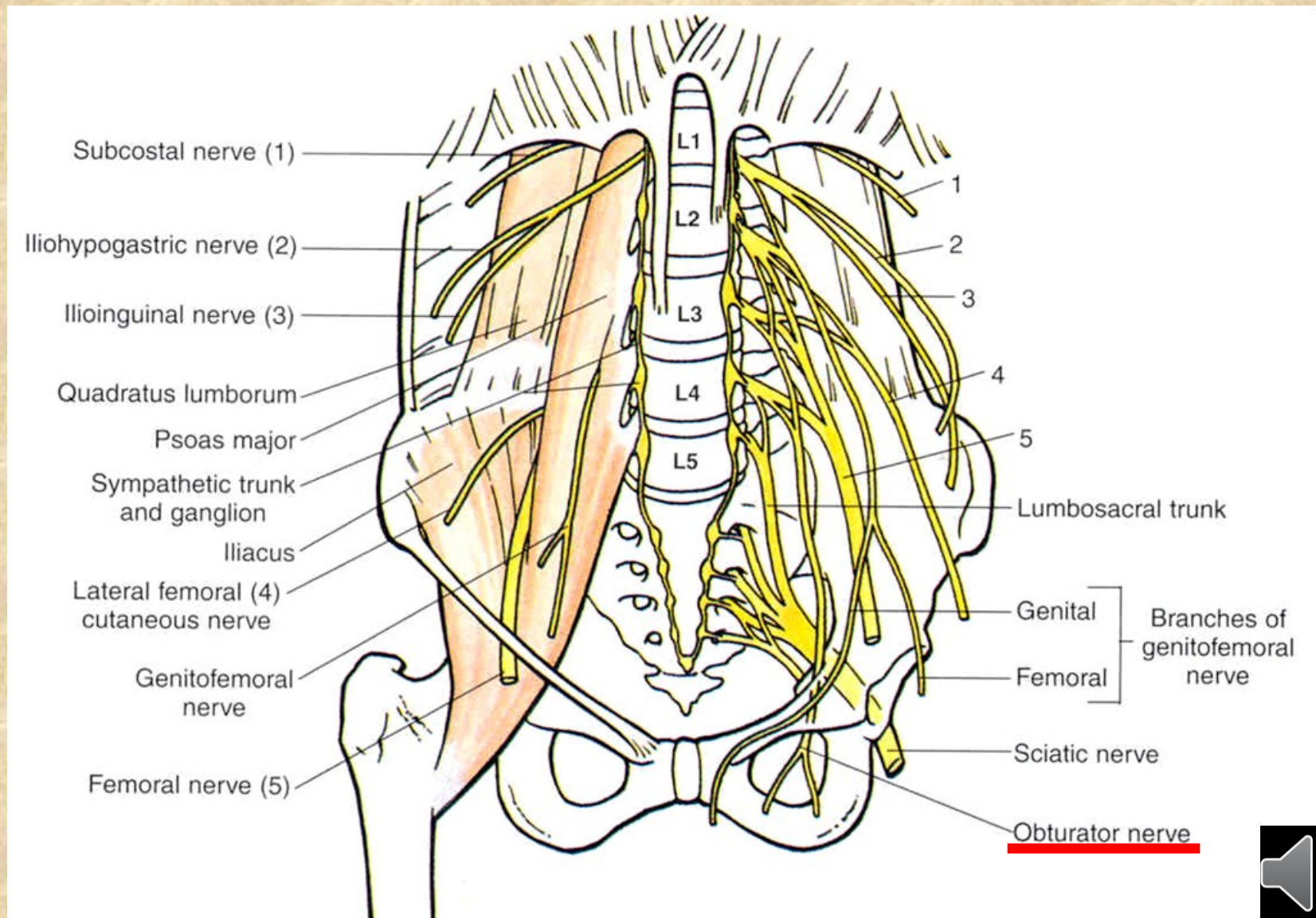
# 1. větve vystupující laterálně od m. psoas major



## 2. větve vystupující skrze m. psoas major



### 3. větve vystupující mediálně od m. psoas major

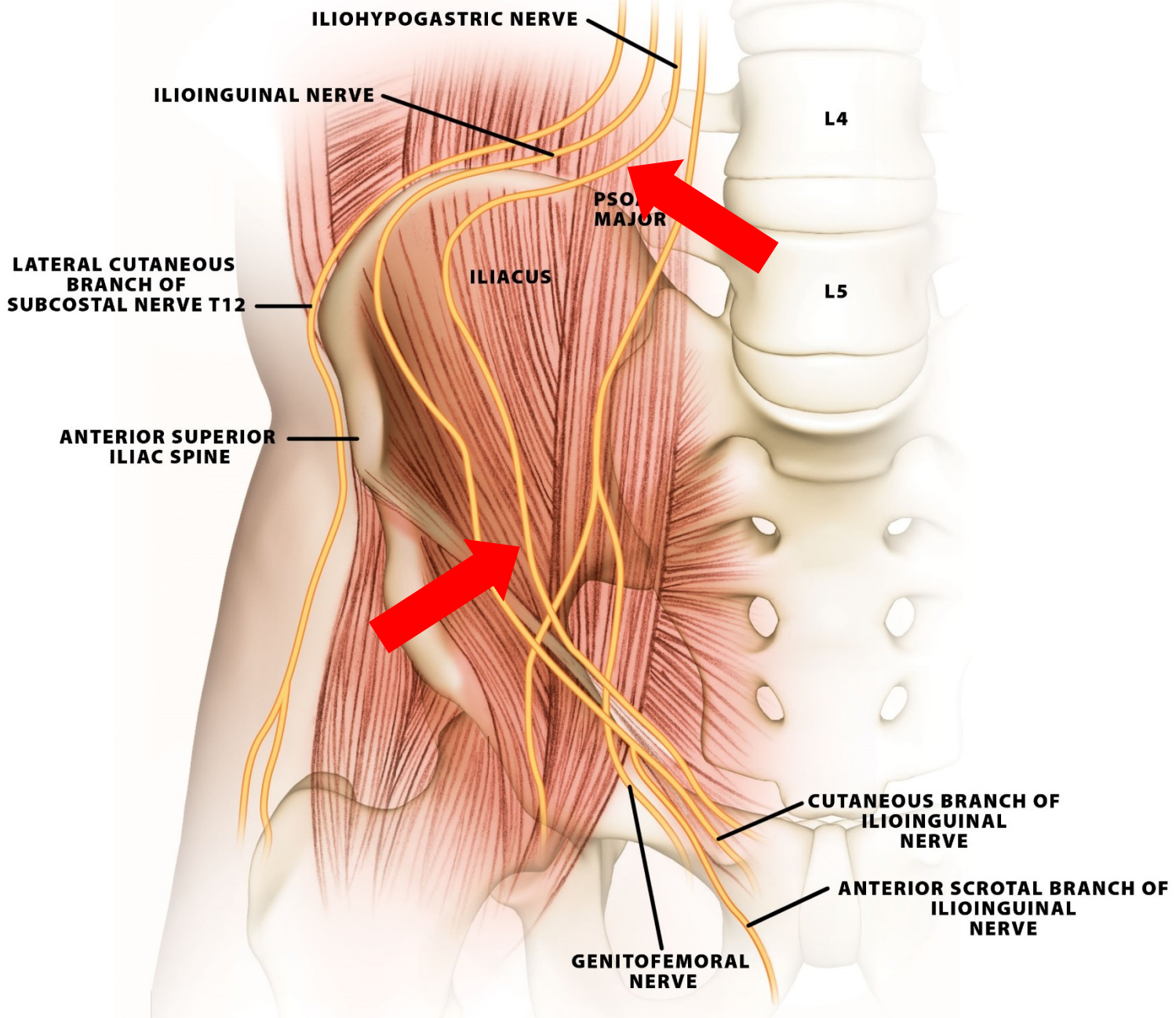


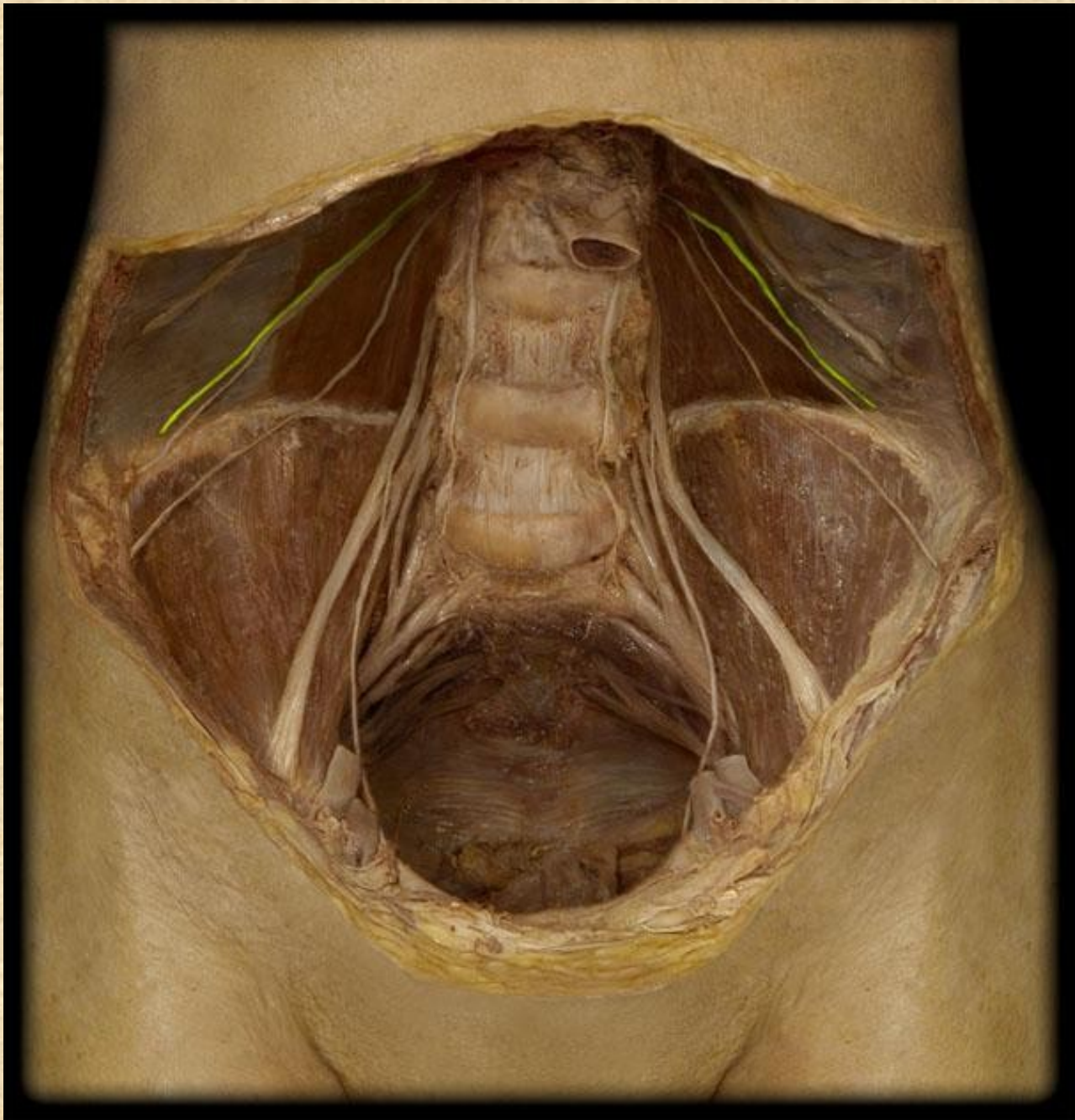


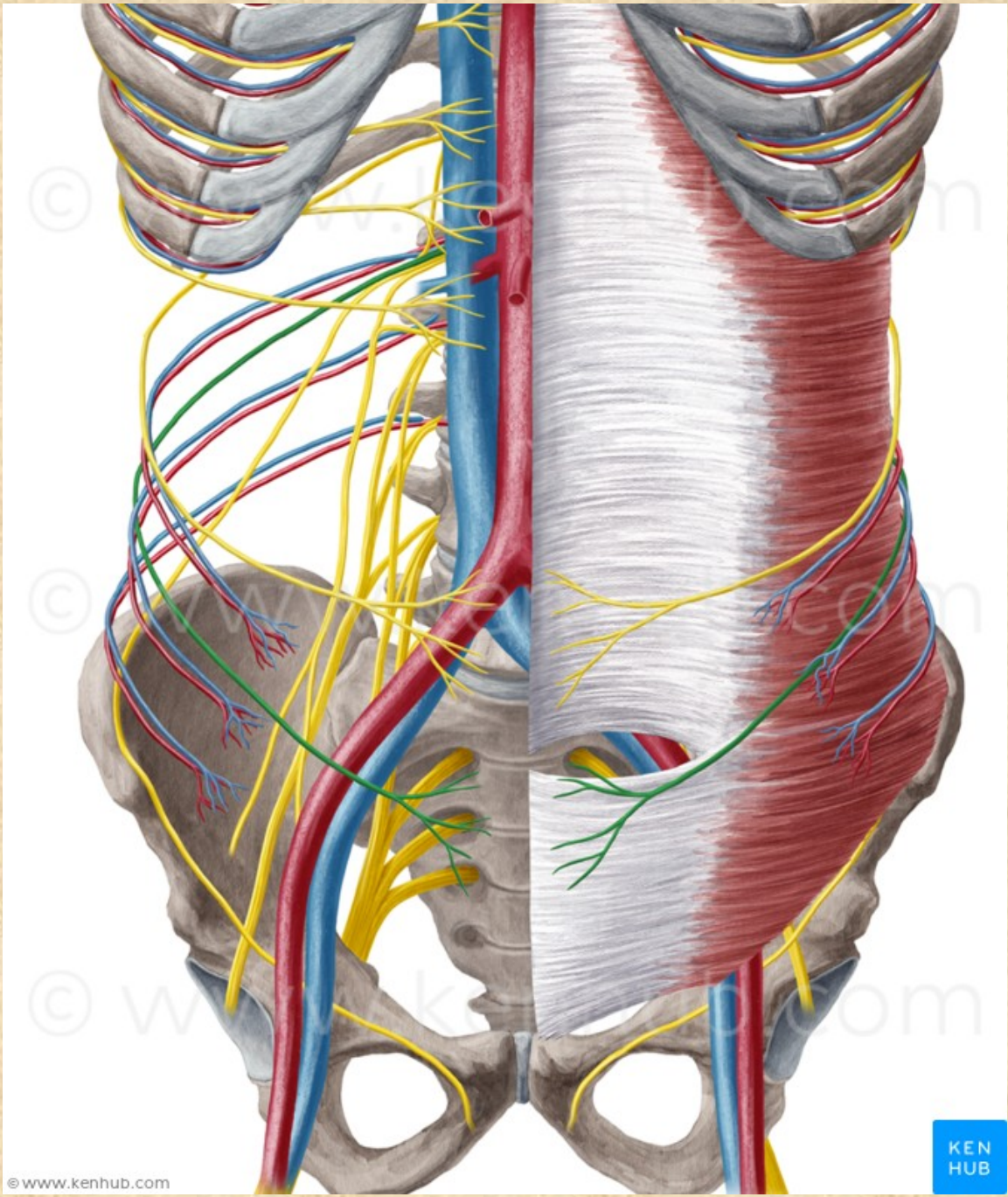
# Nervus iliohypogastricus Th12-L1

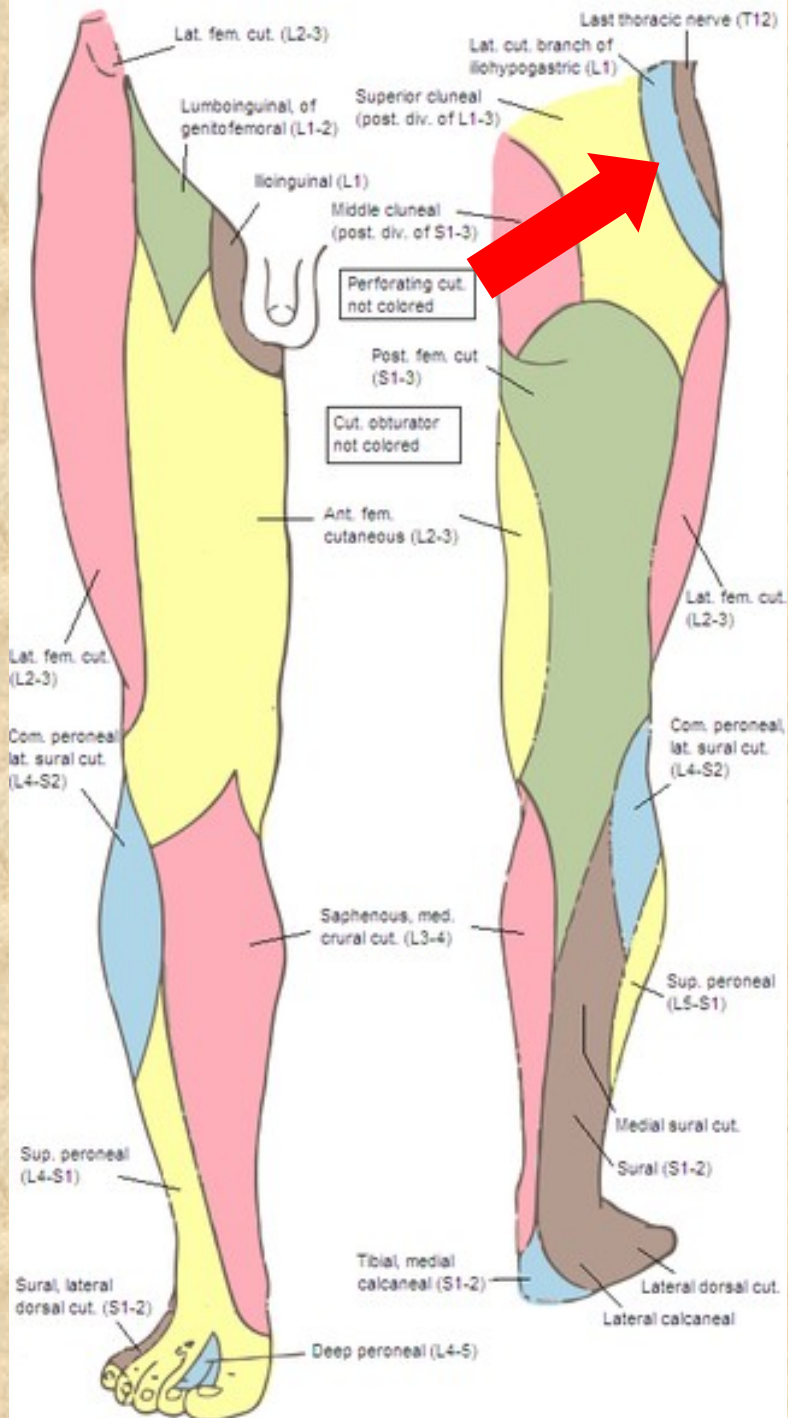
- **rr. musculares** (m.obliquus internus a externus, m. transversus abdominis)
- **r. cutaneus lateralis**  
kůže v oblasti kyčelního kloubu a lig. inguinale
- **r. cutaneus medialis**  
kůže nad lig. inguinale a v regio pubica







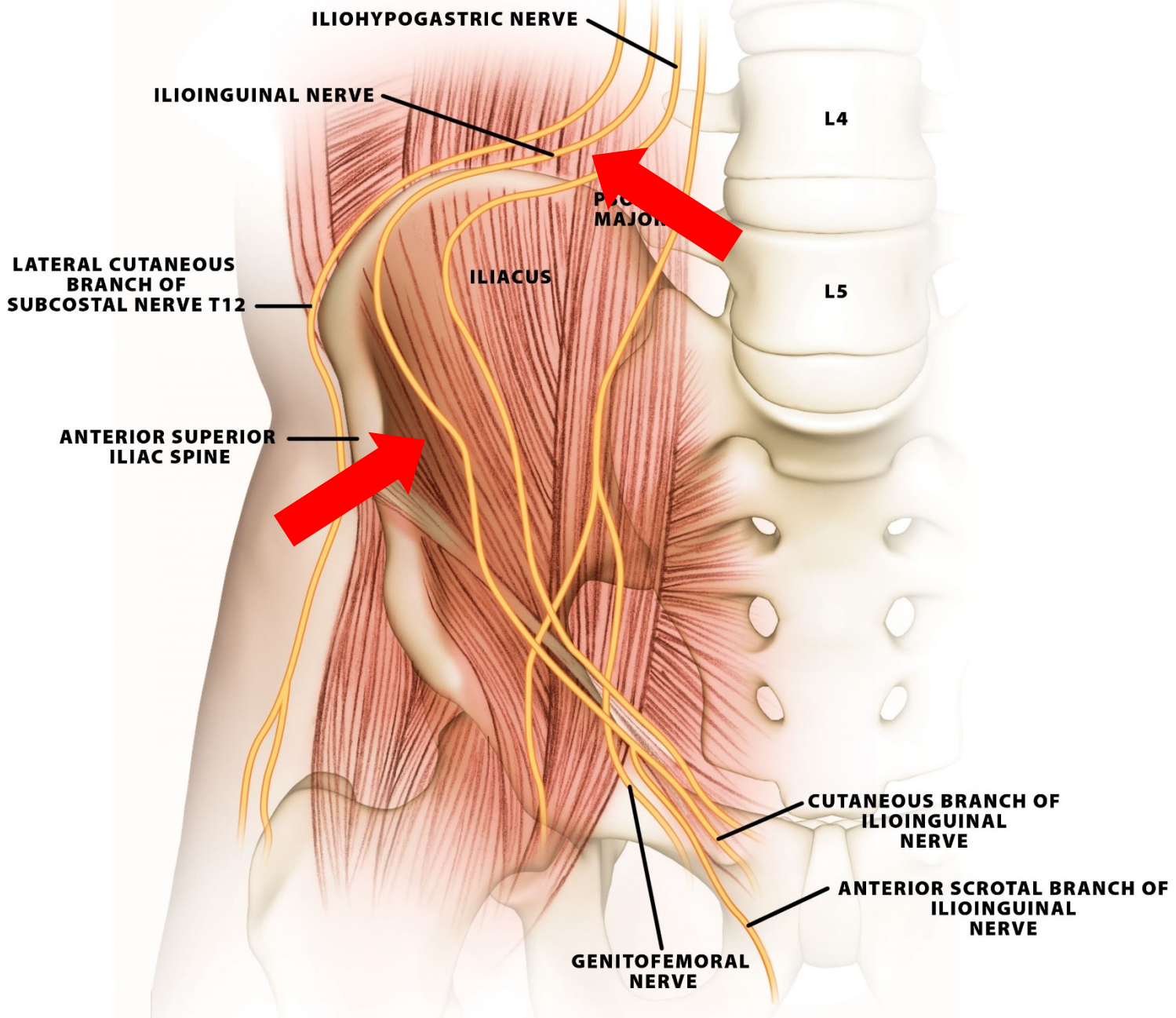


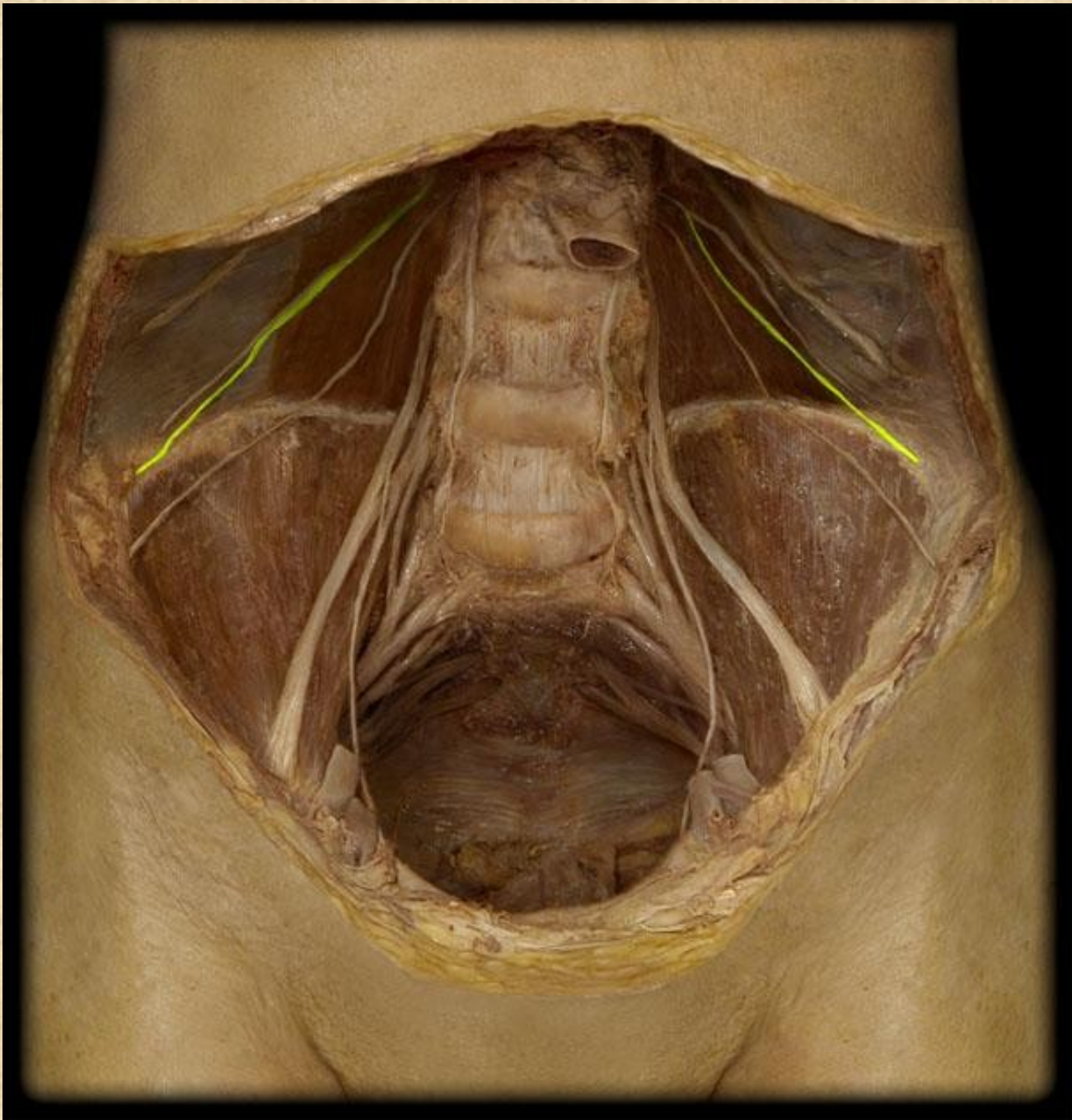


# Nervus ilioinguinalis L1

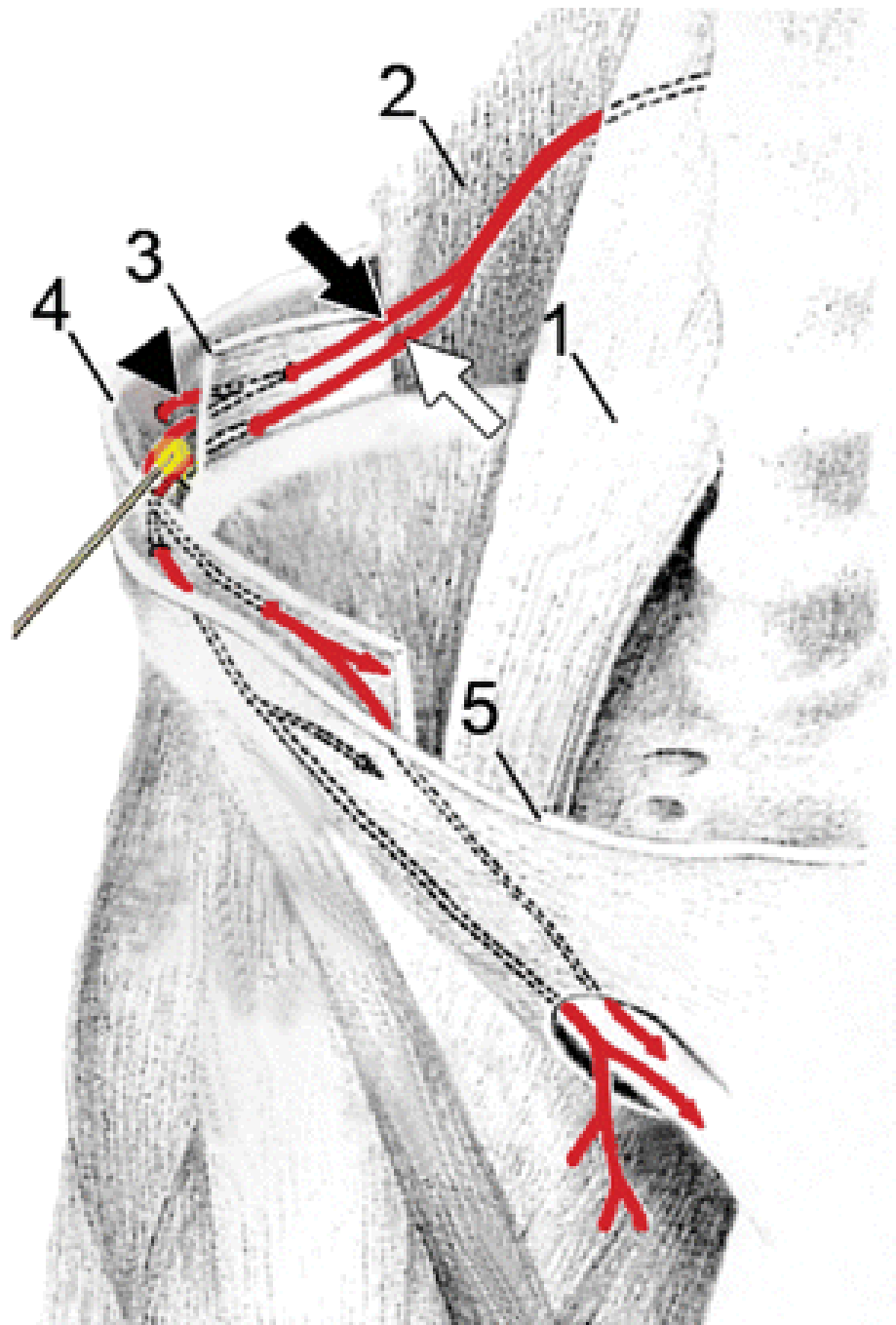
- **rr. musculares** (mm. obliquus internus, m. transversus abdominis, m. cremaster)
- v inguinálním kanálu
- **nn. scrotales (labiales anteriores)**  
kůže tříselné krajiny a zevního genitálu

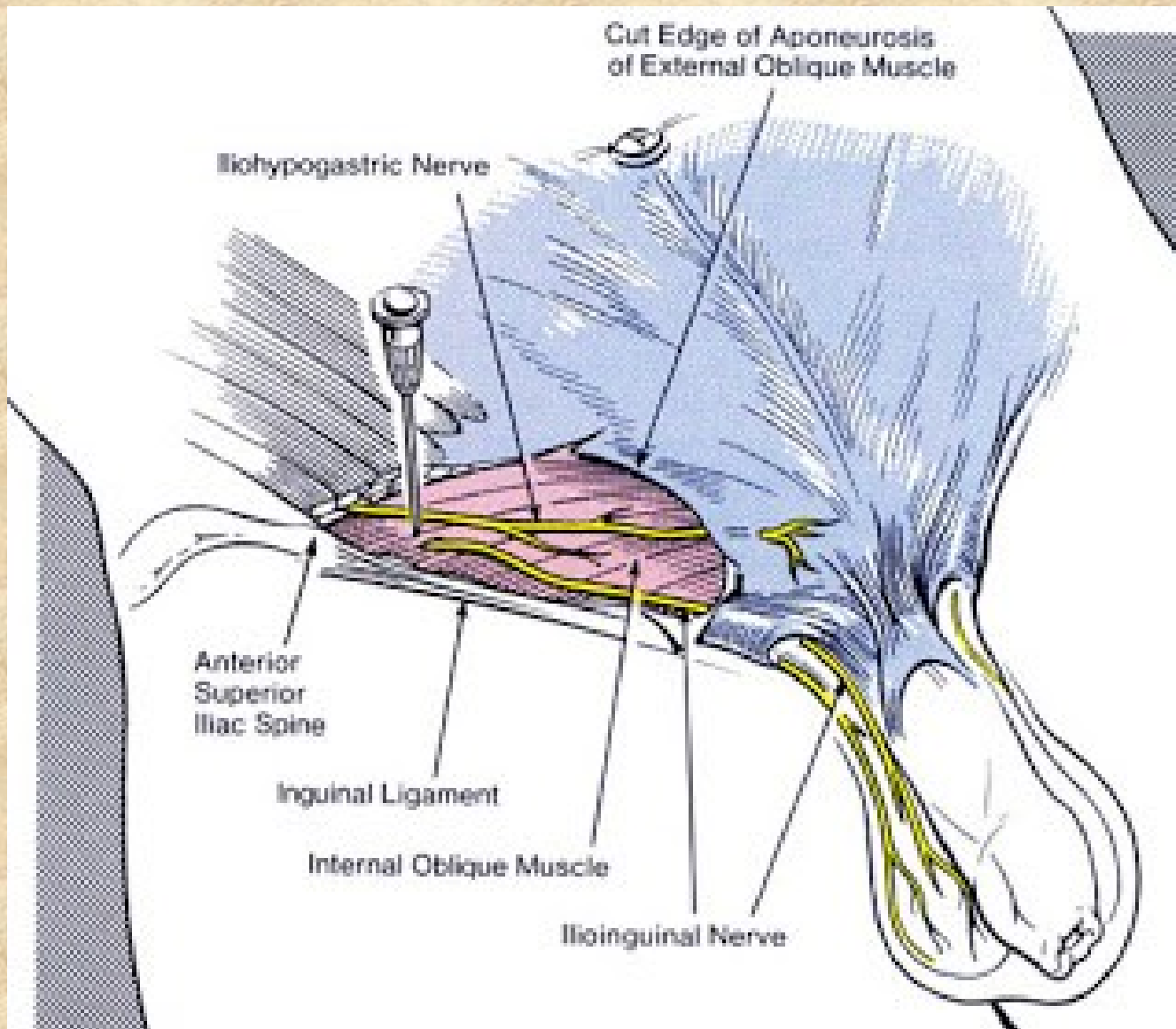




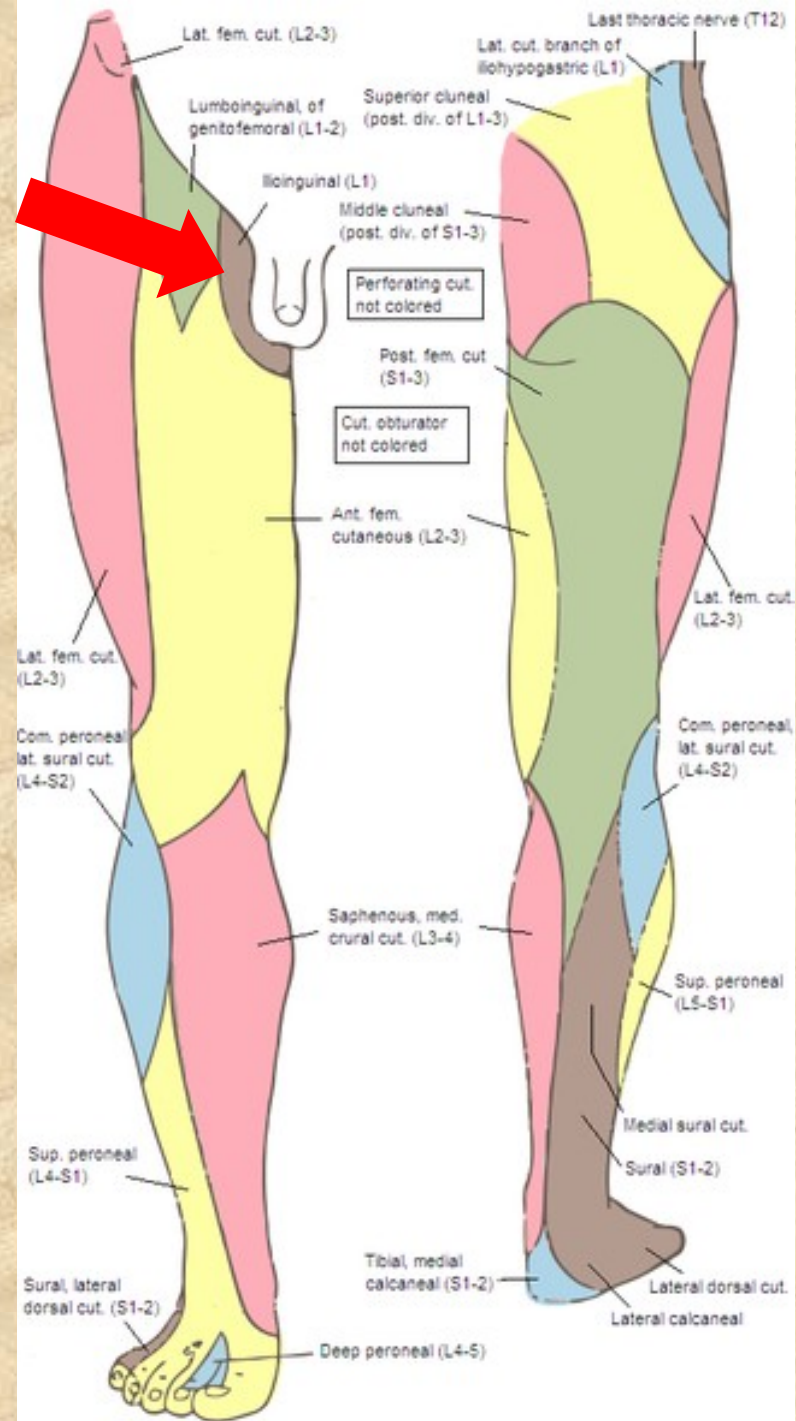








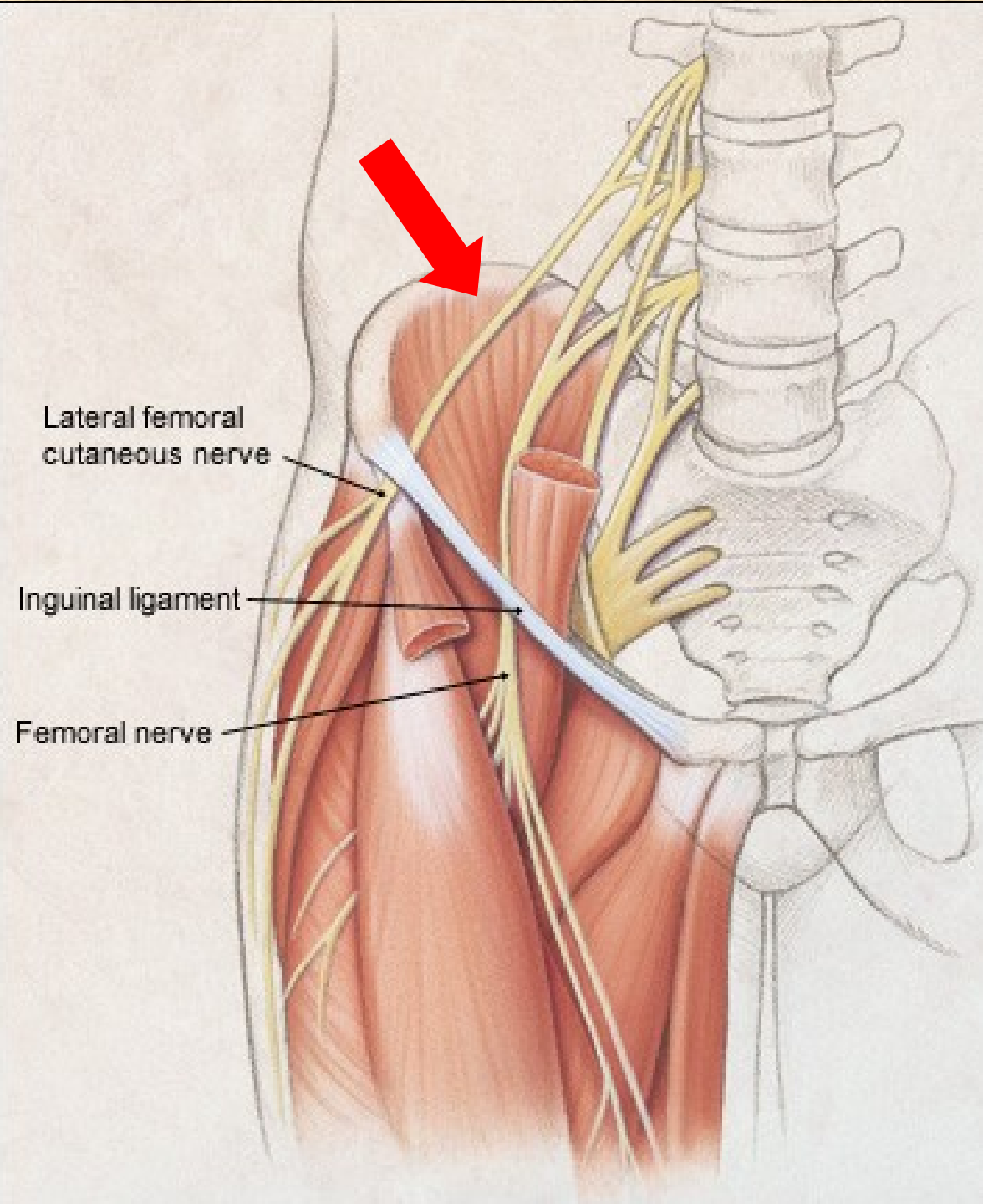




# Nervus cutaneus femoris lateralis L2-L3

- čistě senzorický
- skrze lacuna musculorum, těsně u spina iliaca anterior superior
- kůže laterální strany stehna



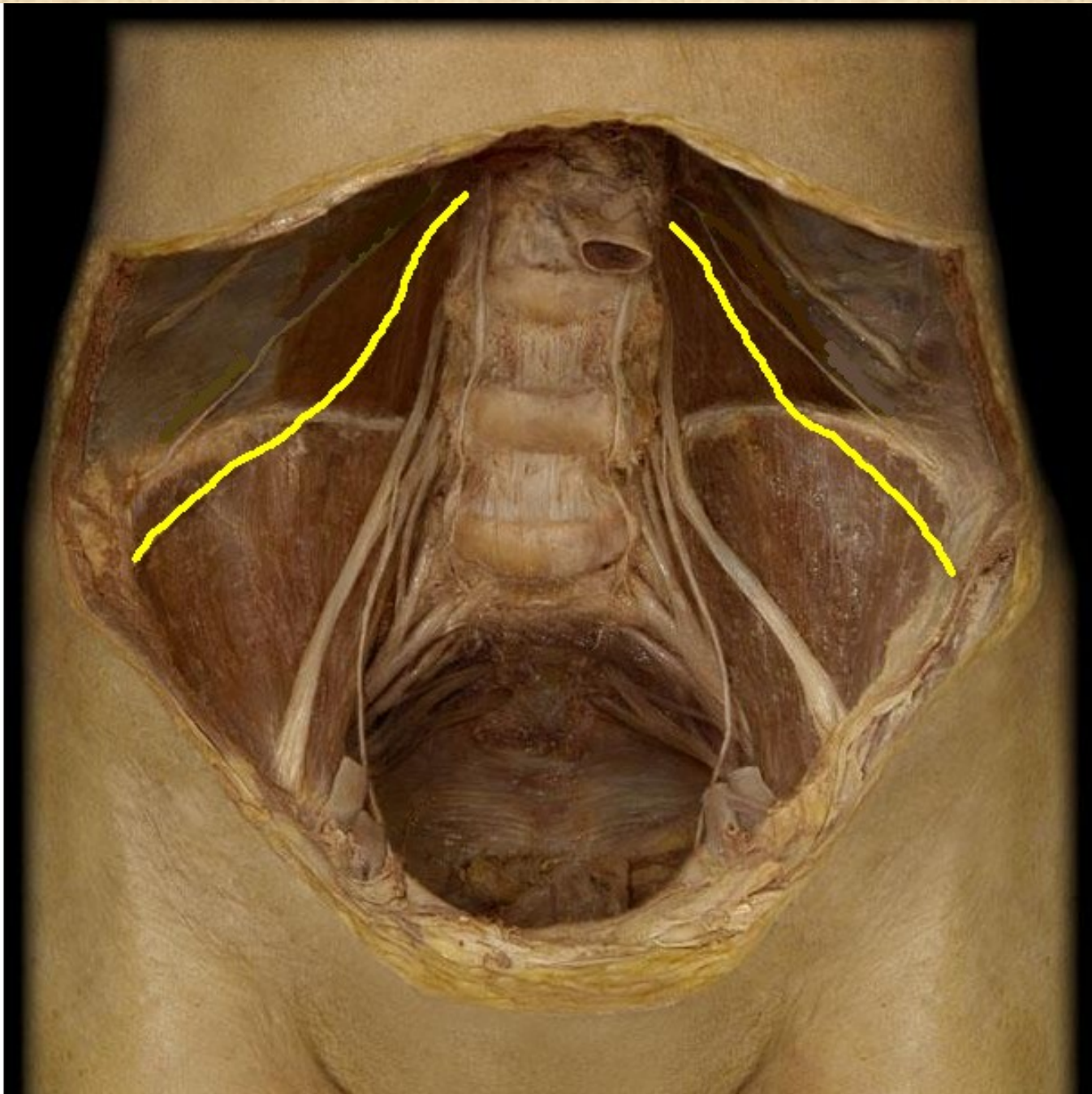


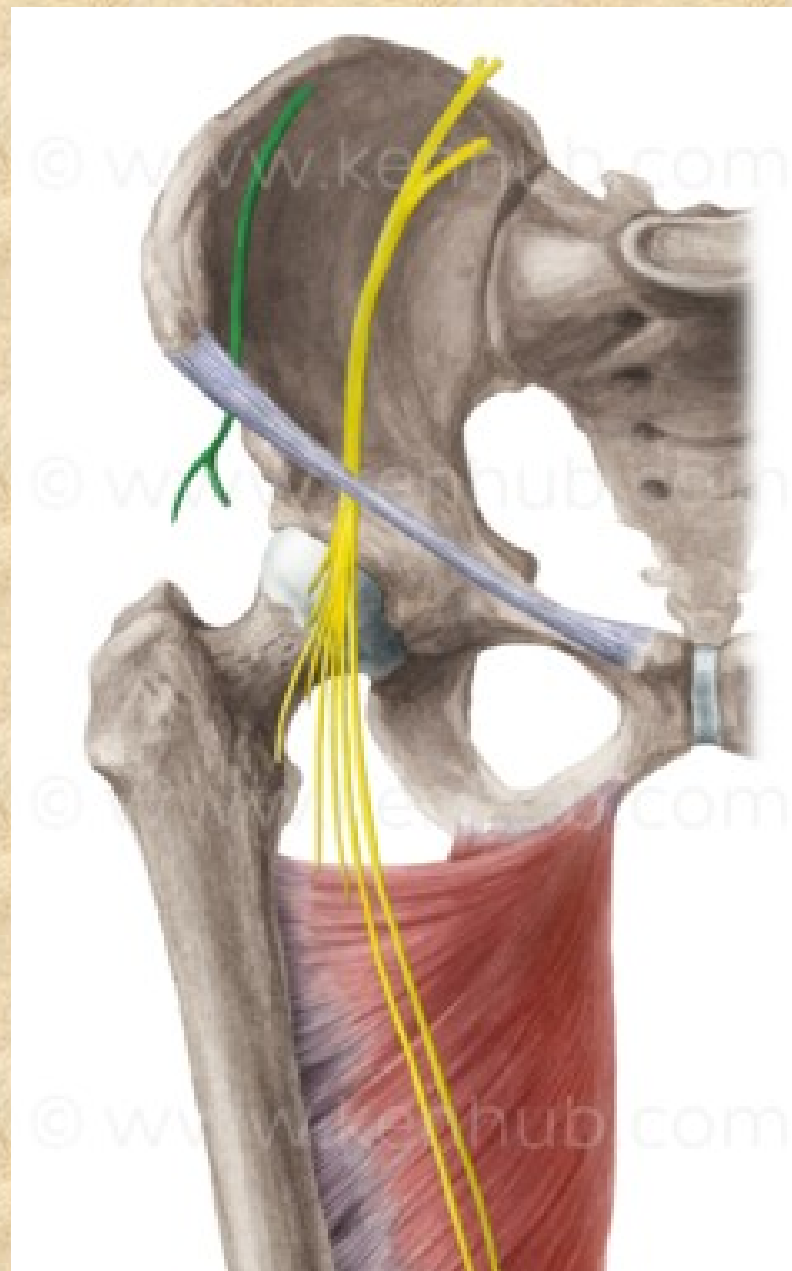
Lateral femoral cutaneous nerve

Inguinal ligament


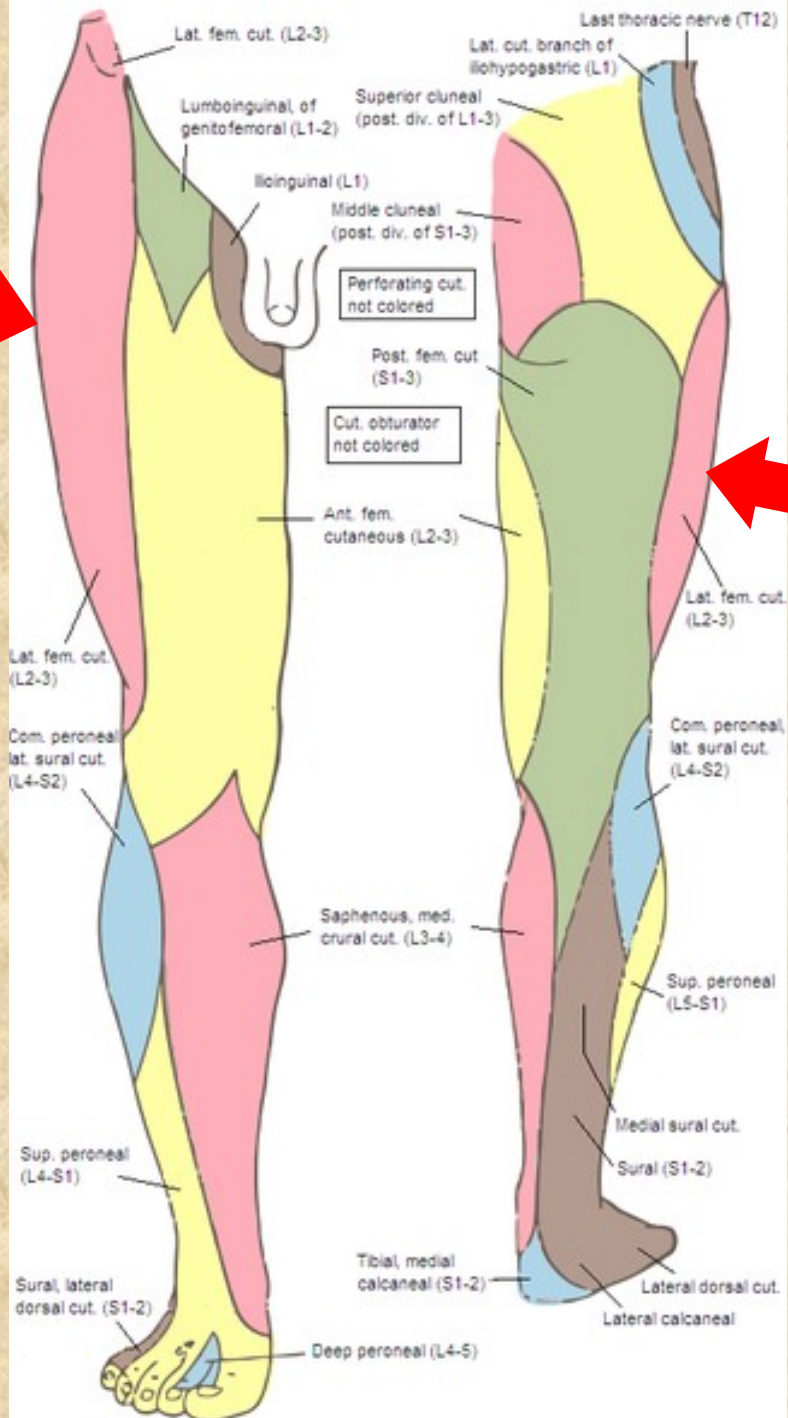
Femoral nerve

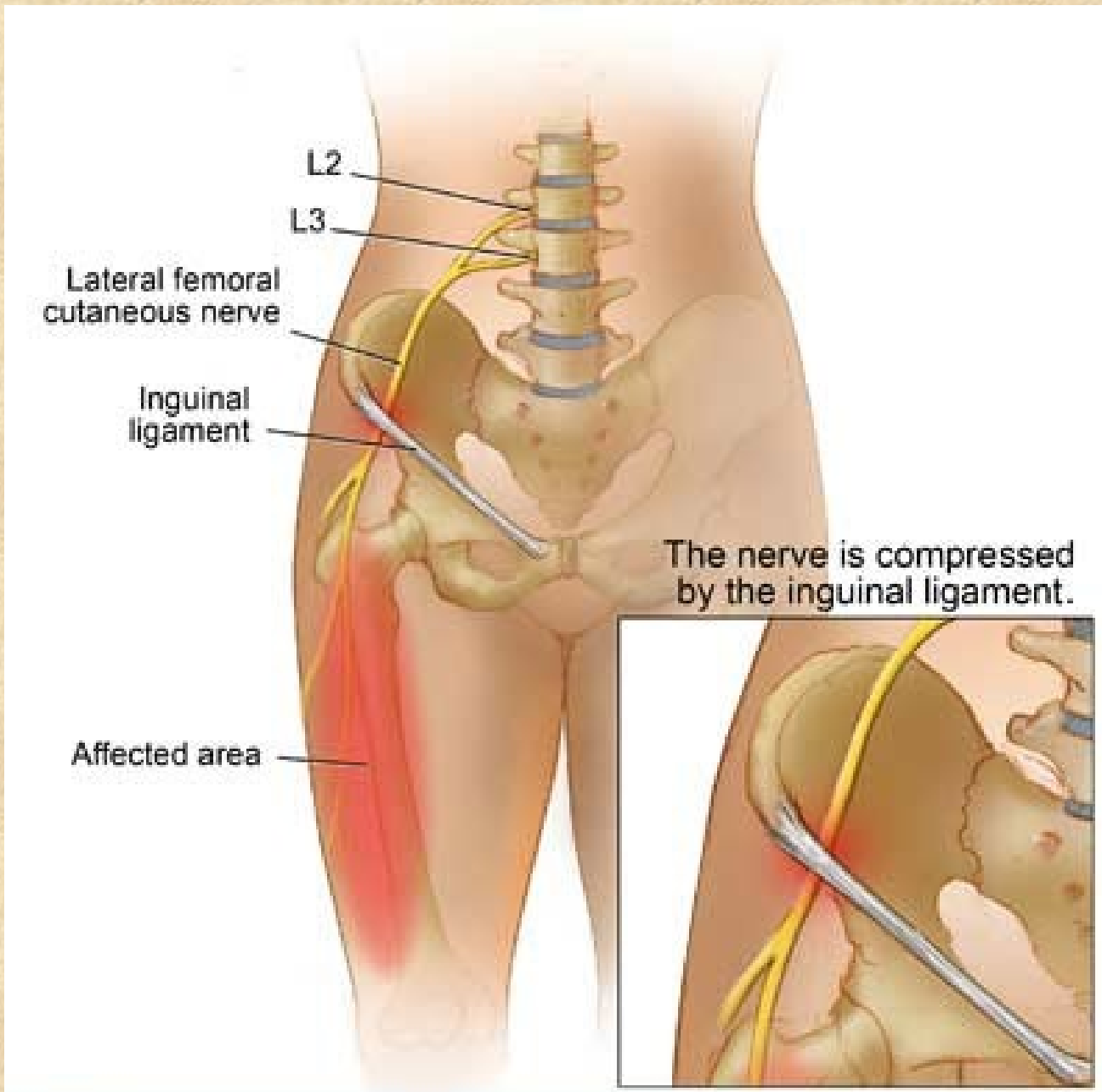












# Nervus femoralis L2-L4

- **rr. musculares**

(m. iliopsoas, m. quadriceps femoris, m. articularis genus, m. sartorius a m. pectineus)

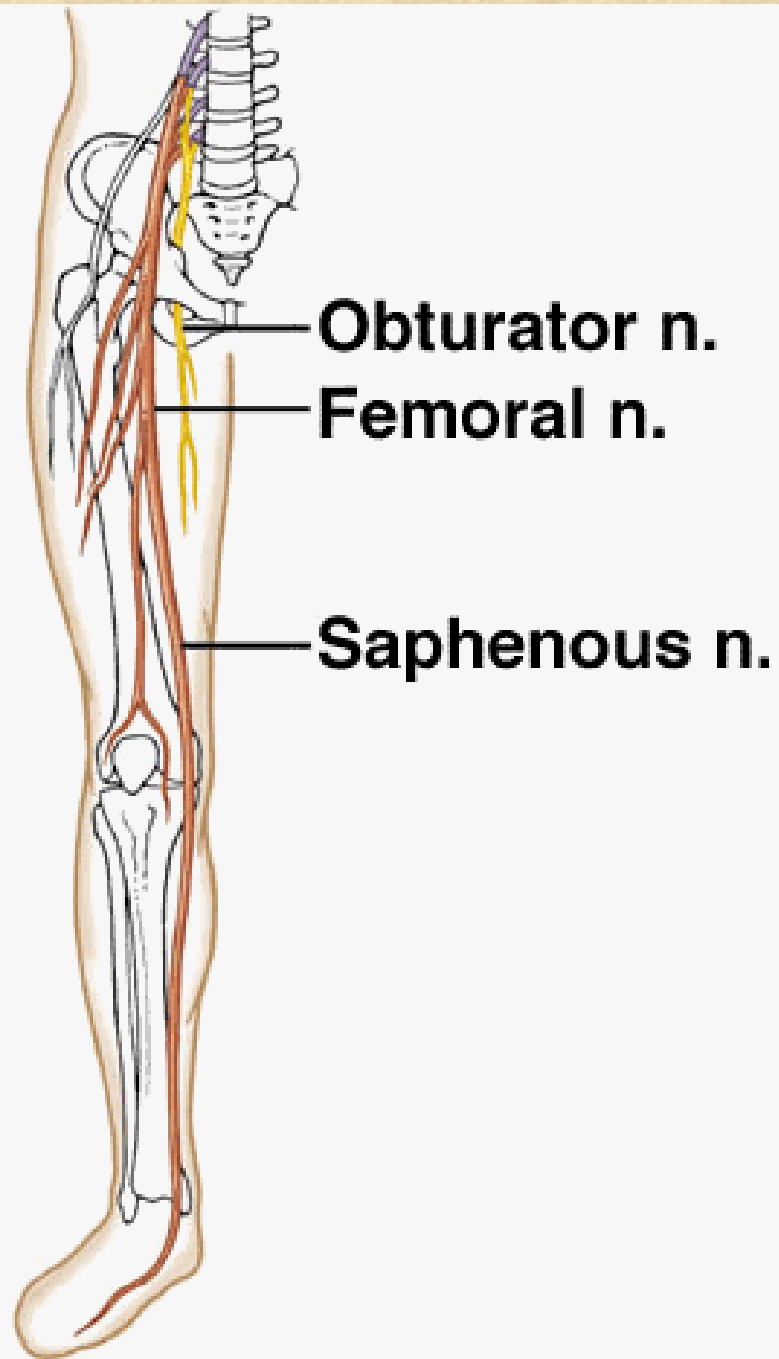
- **rr. cutanei anteriores** přední plocha stehna po patelu

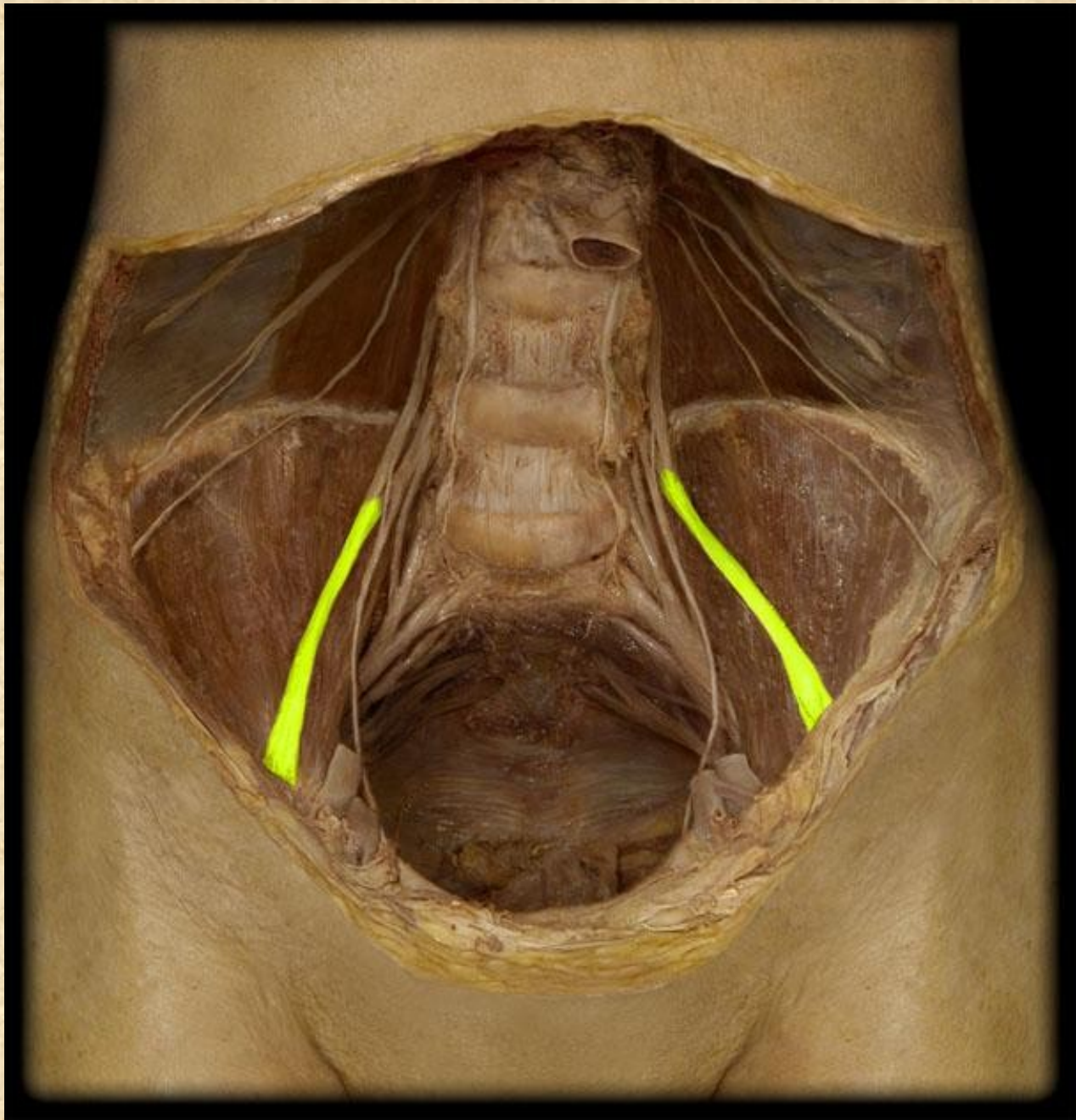
- **n. saphenus**

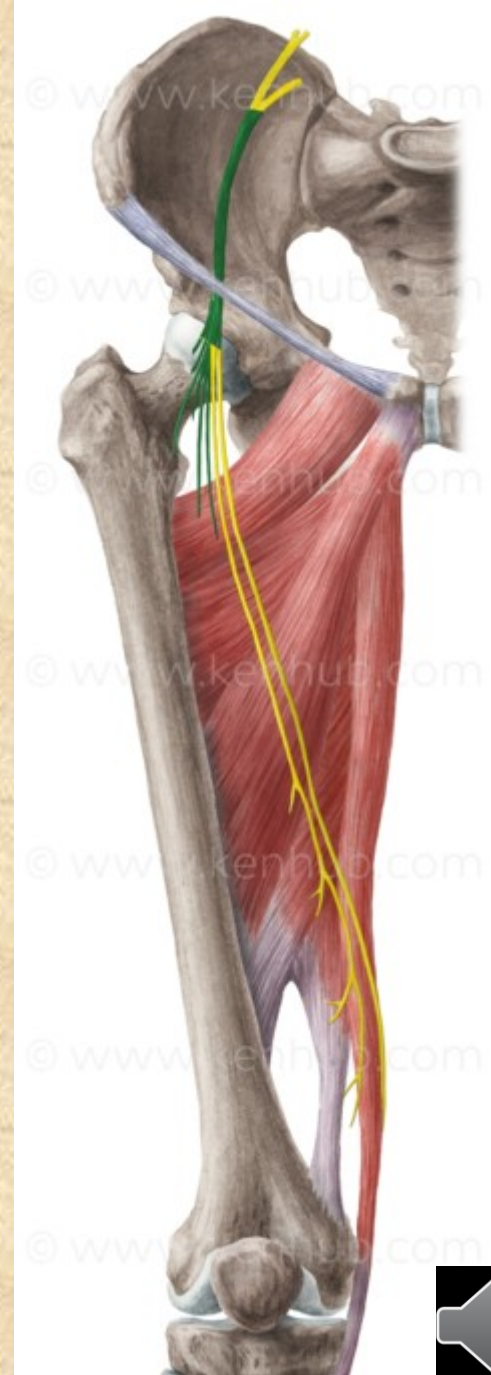
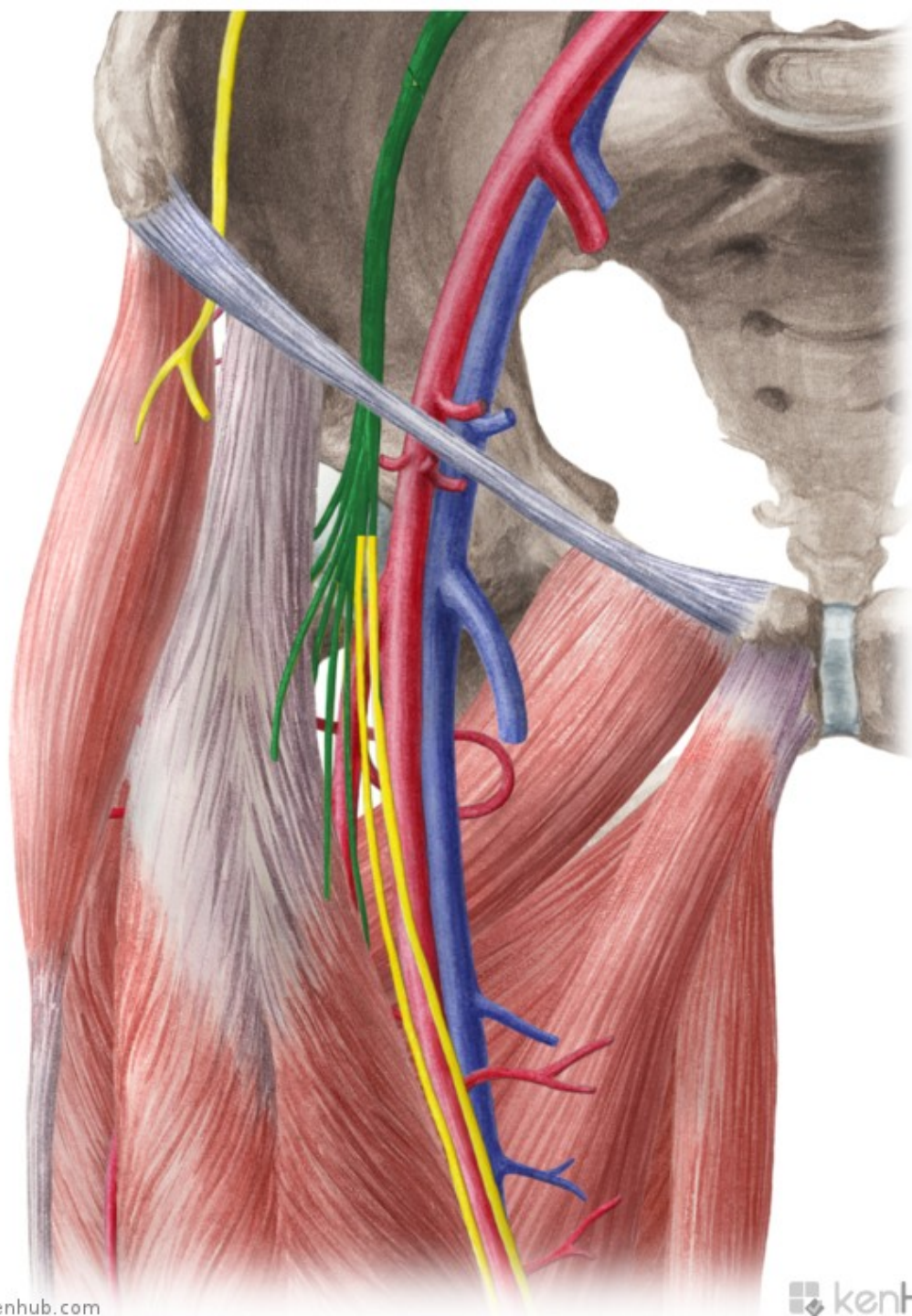
senzitivně kůži vpředu na mediální straně bérce a před mediálním kotníkem

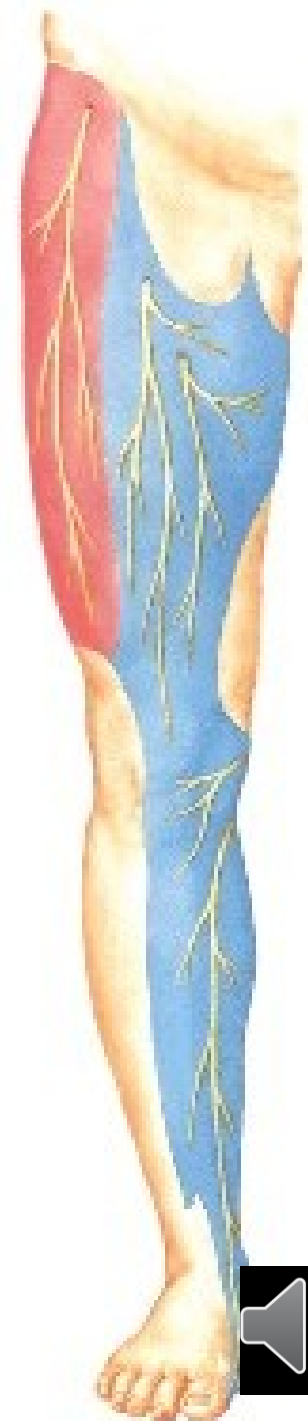
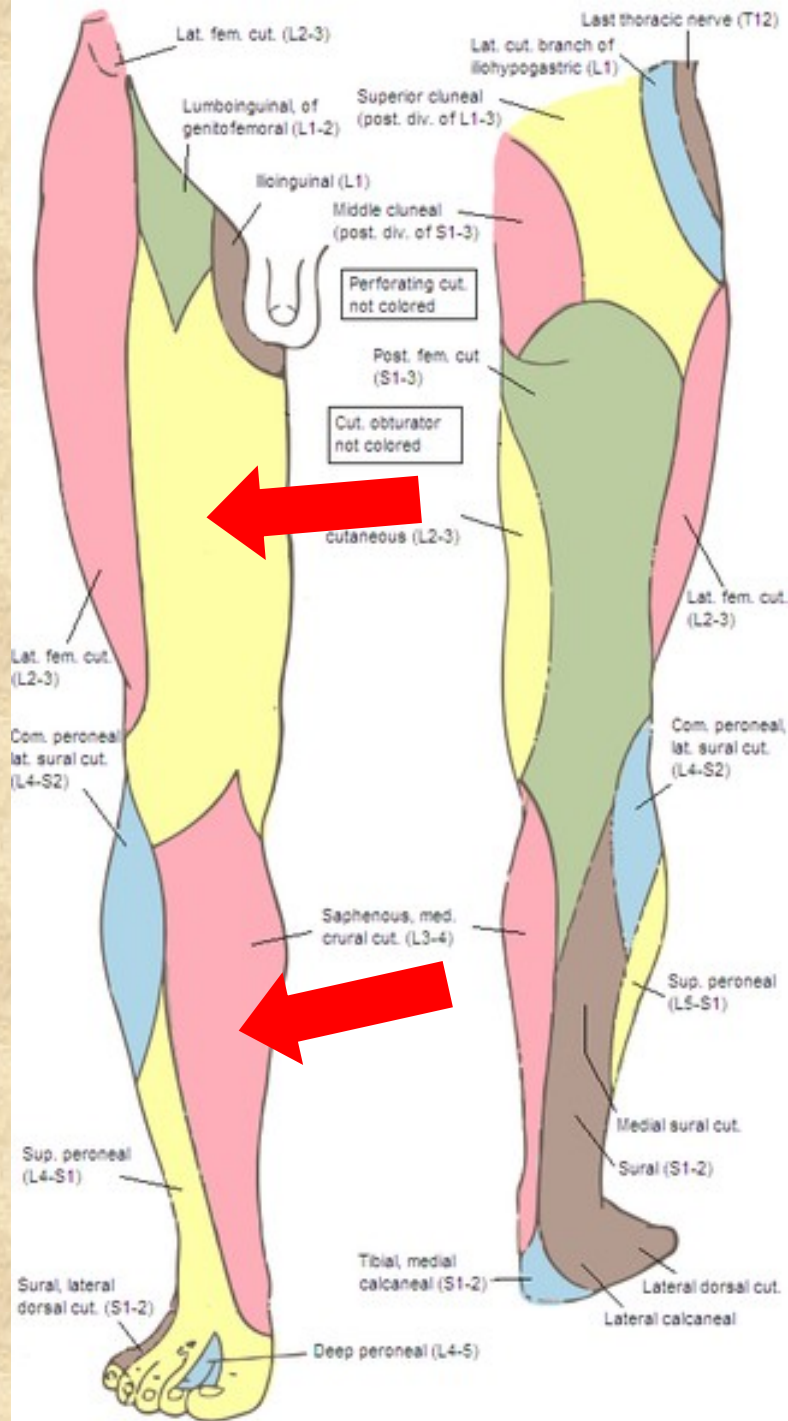
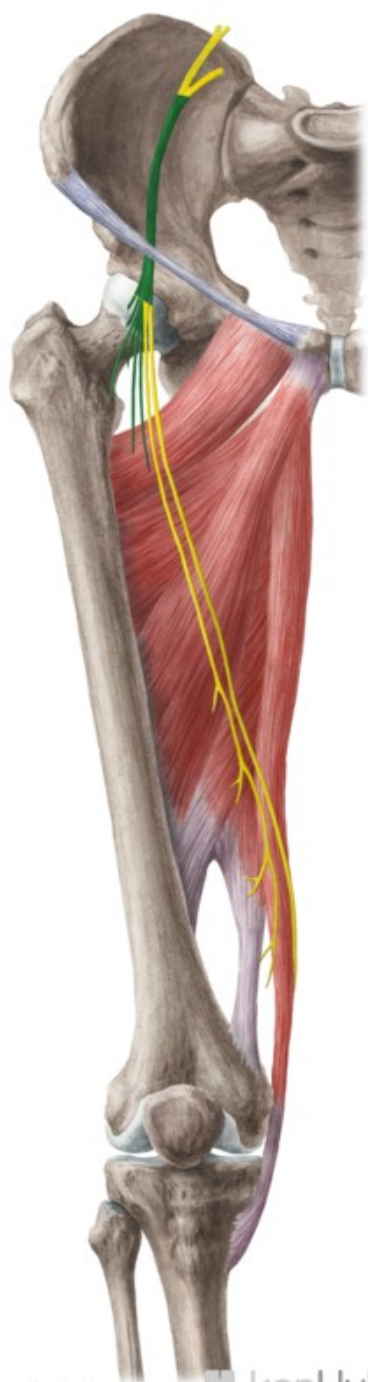






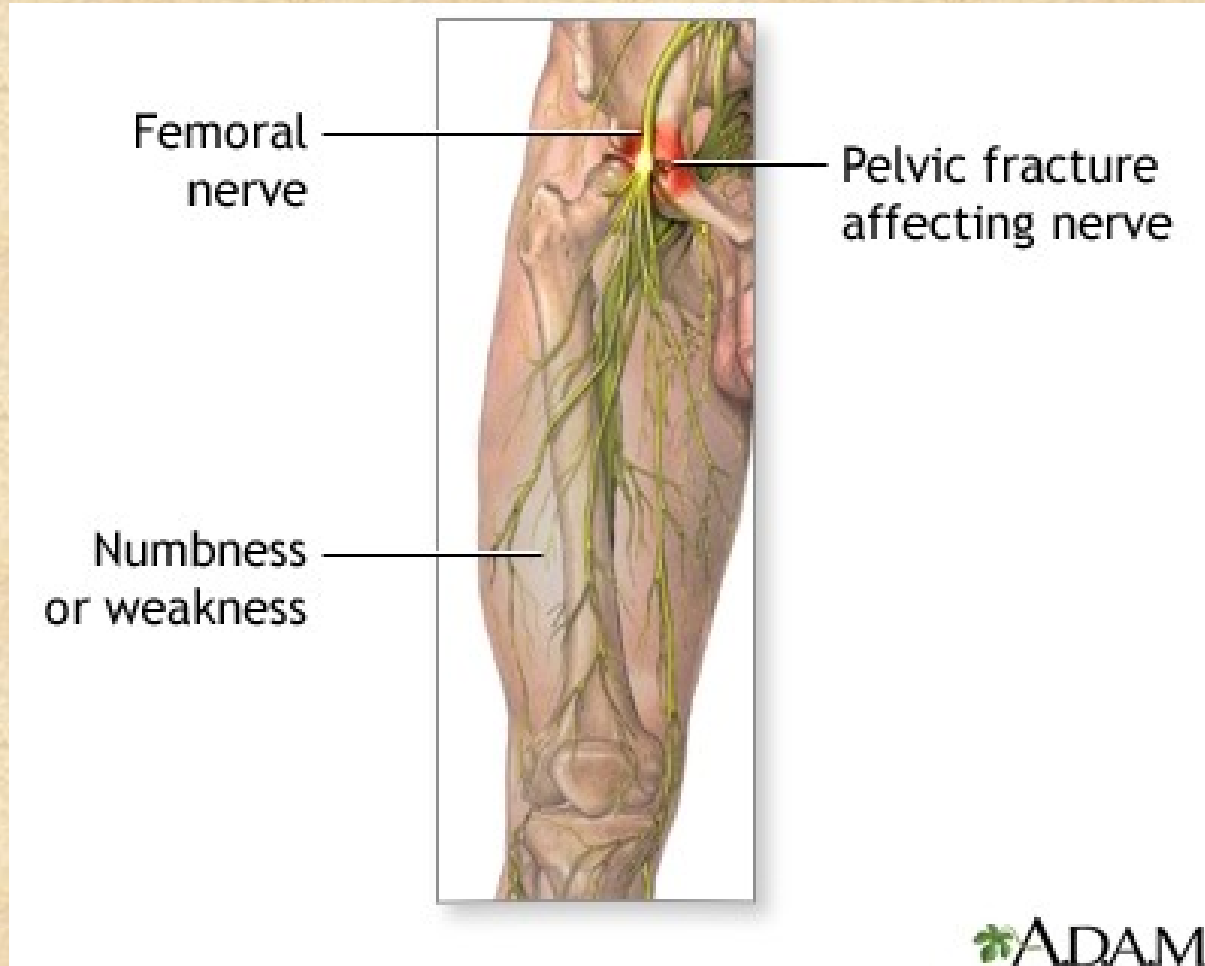








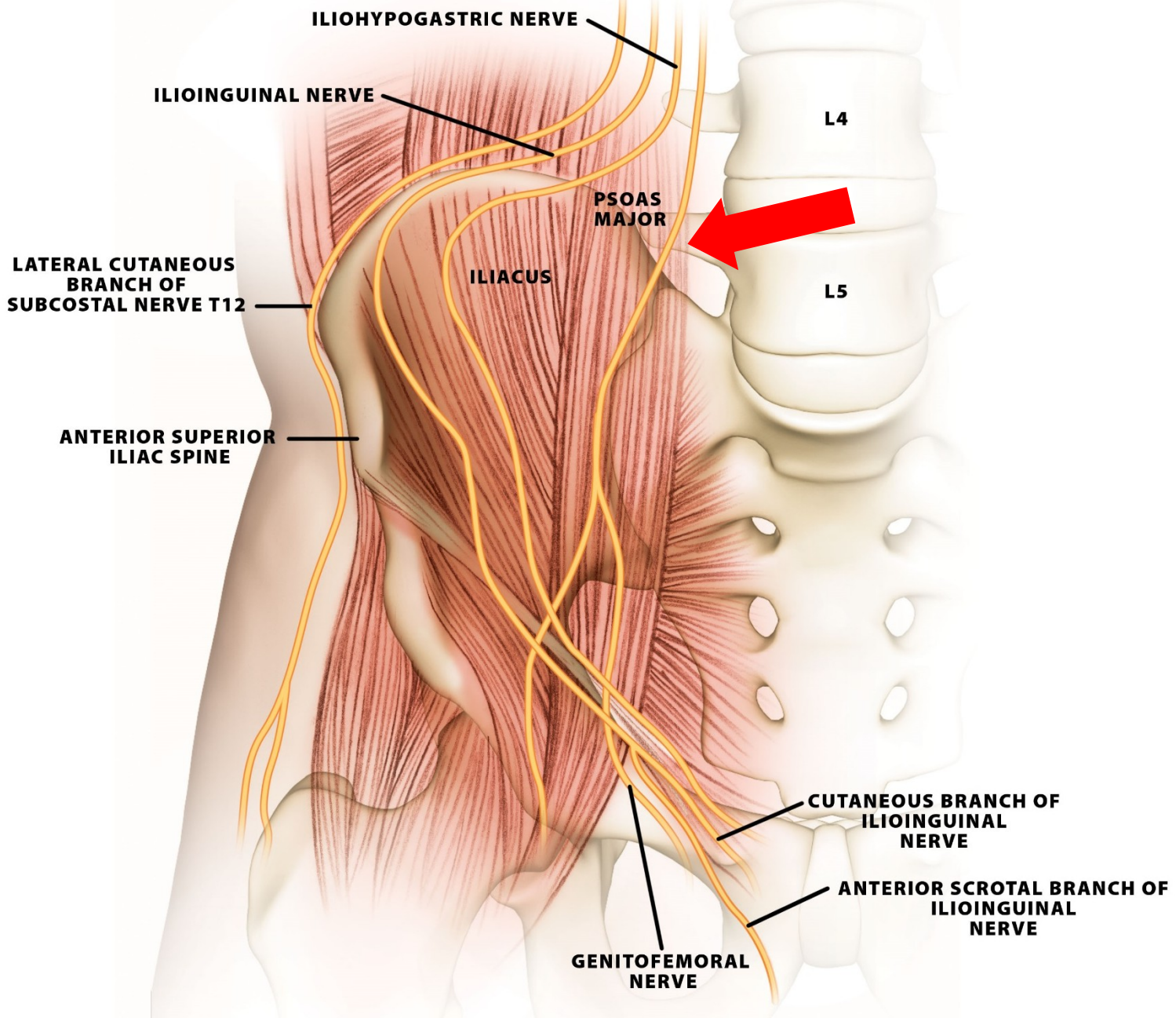
- **Obrna:** neschopnost extenze v kolenním kloubu a flexe v kyčelním kloubu, poruchy citlivosti v inervační oblasti

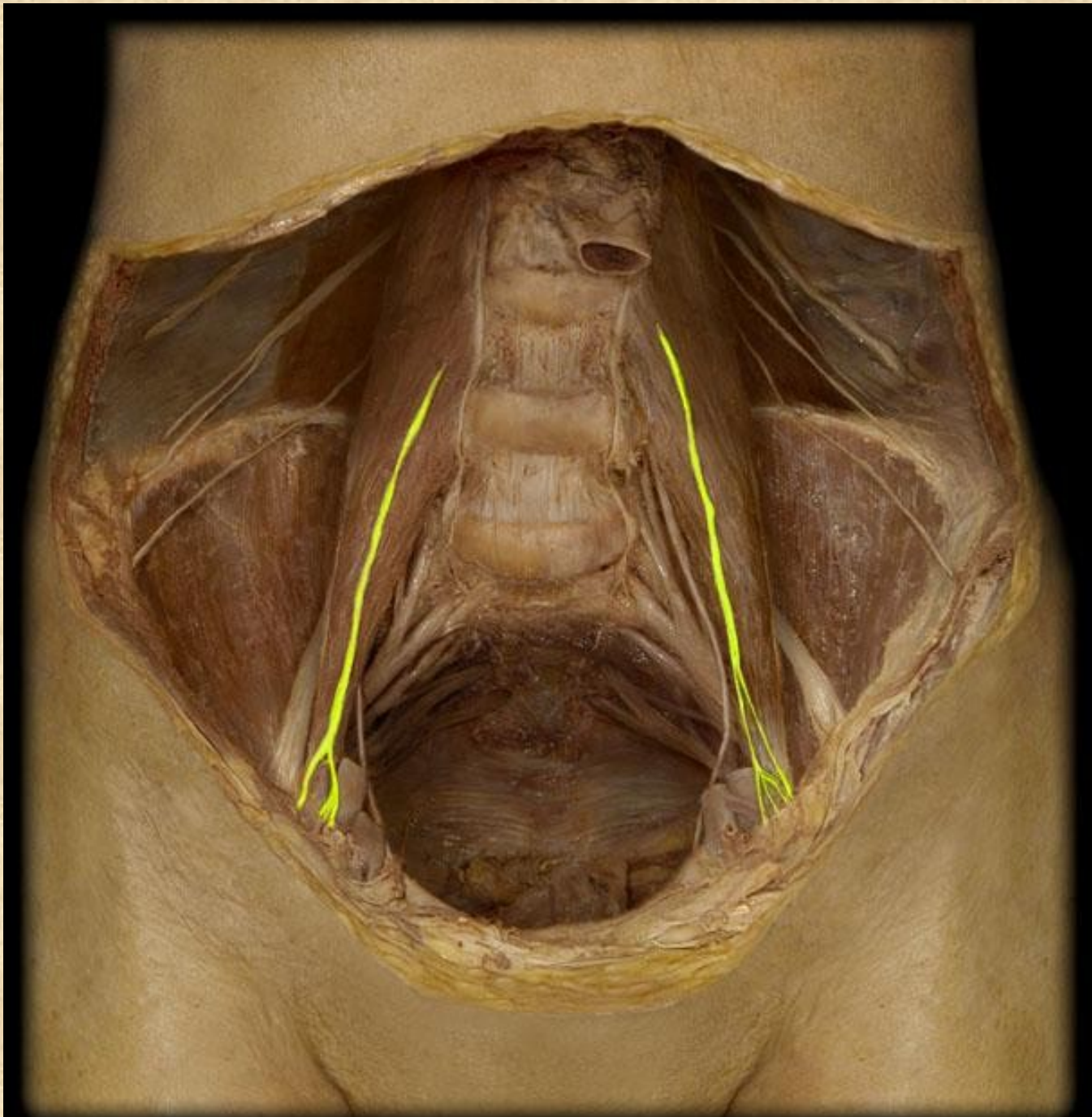


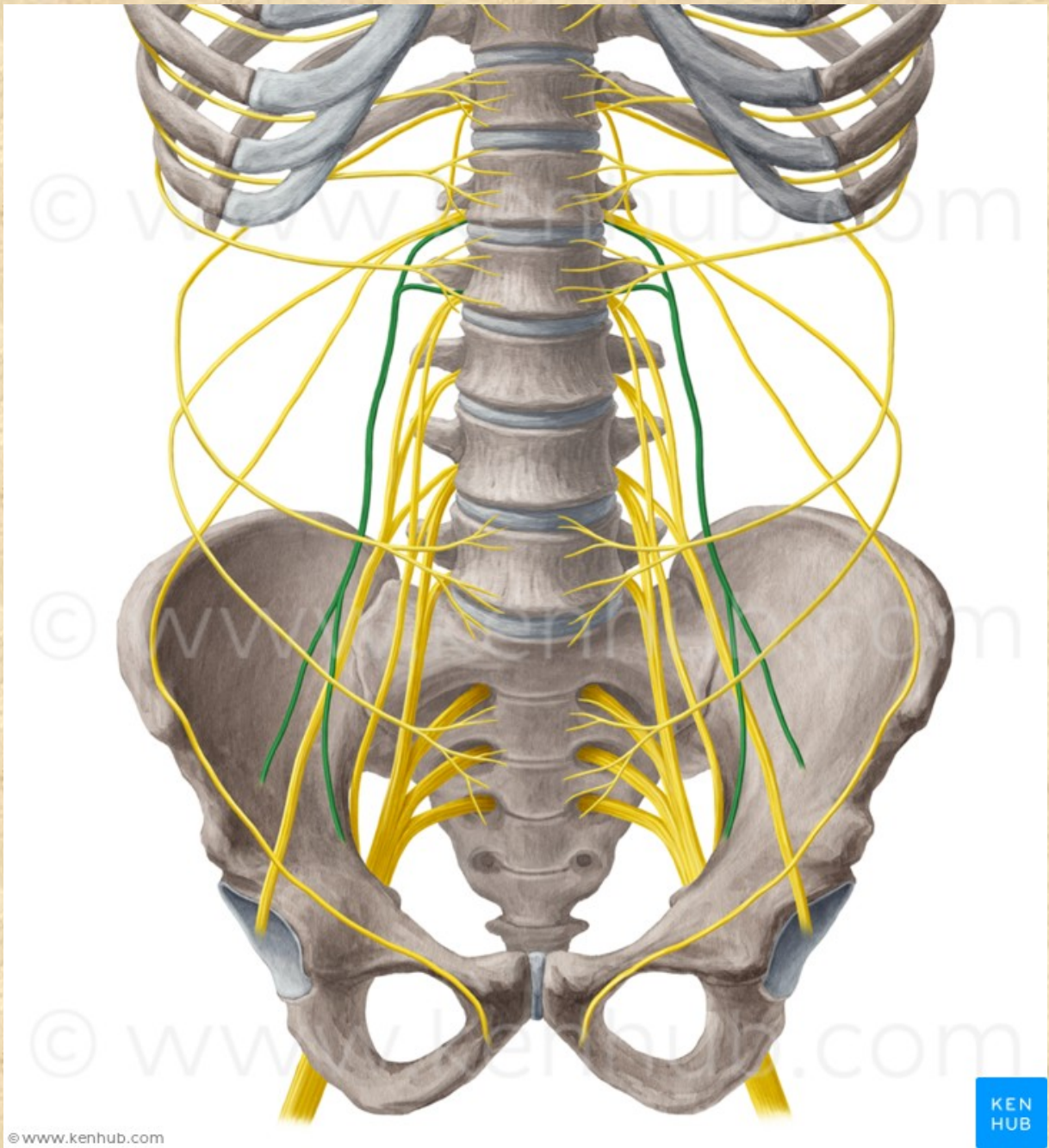
# Nervus genitofemoralis L1-L2

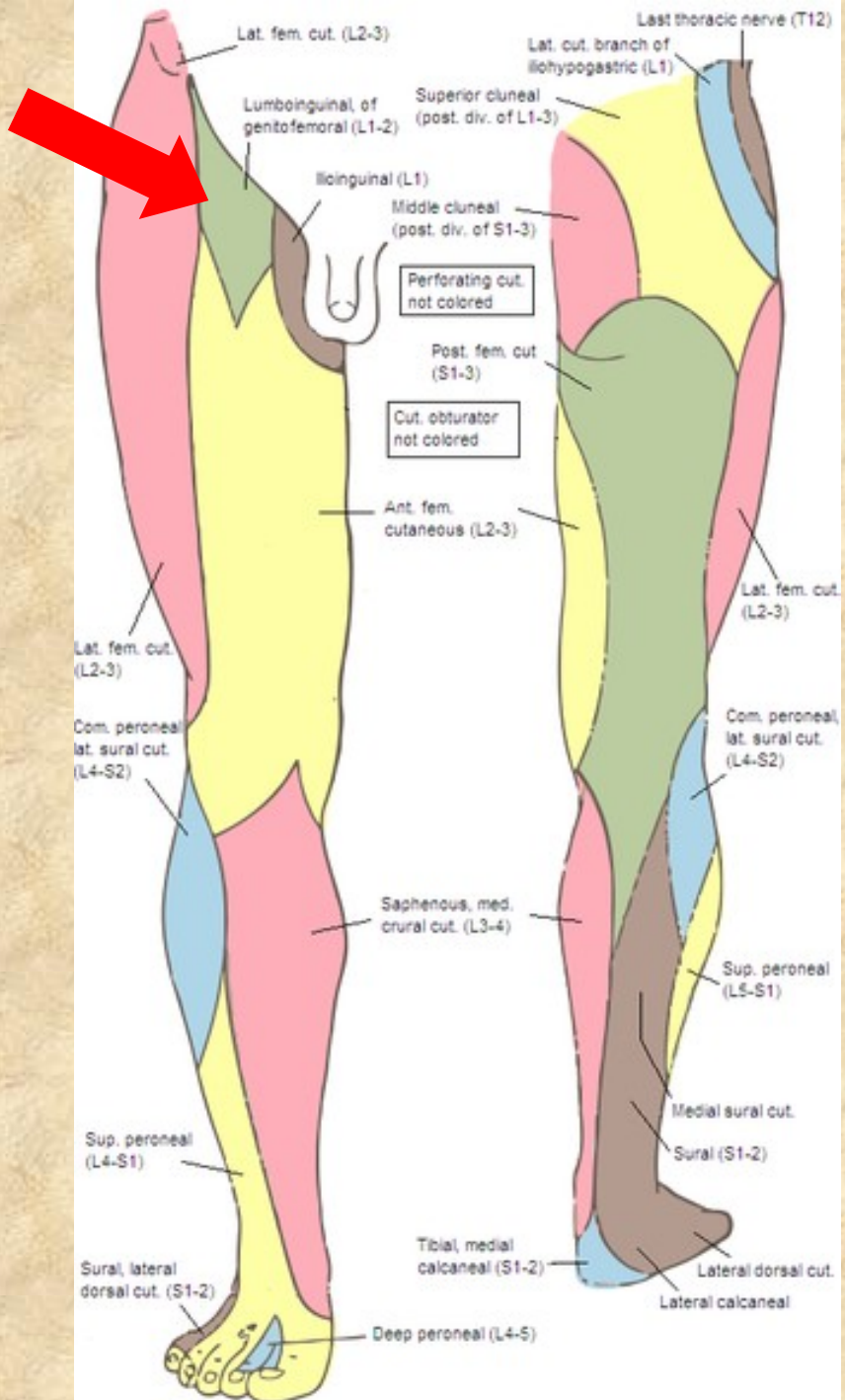
- **r. genitalis** (přes canalis inguinalis), m. cremaster, kůže mediální strany stehna
- **r. femoralis** - (lacuna vasorum) kůže přední plochy stehna (pod tříselným vazem)











# Nervus obturatorius L2-L4

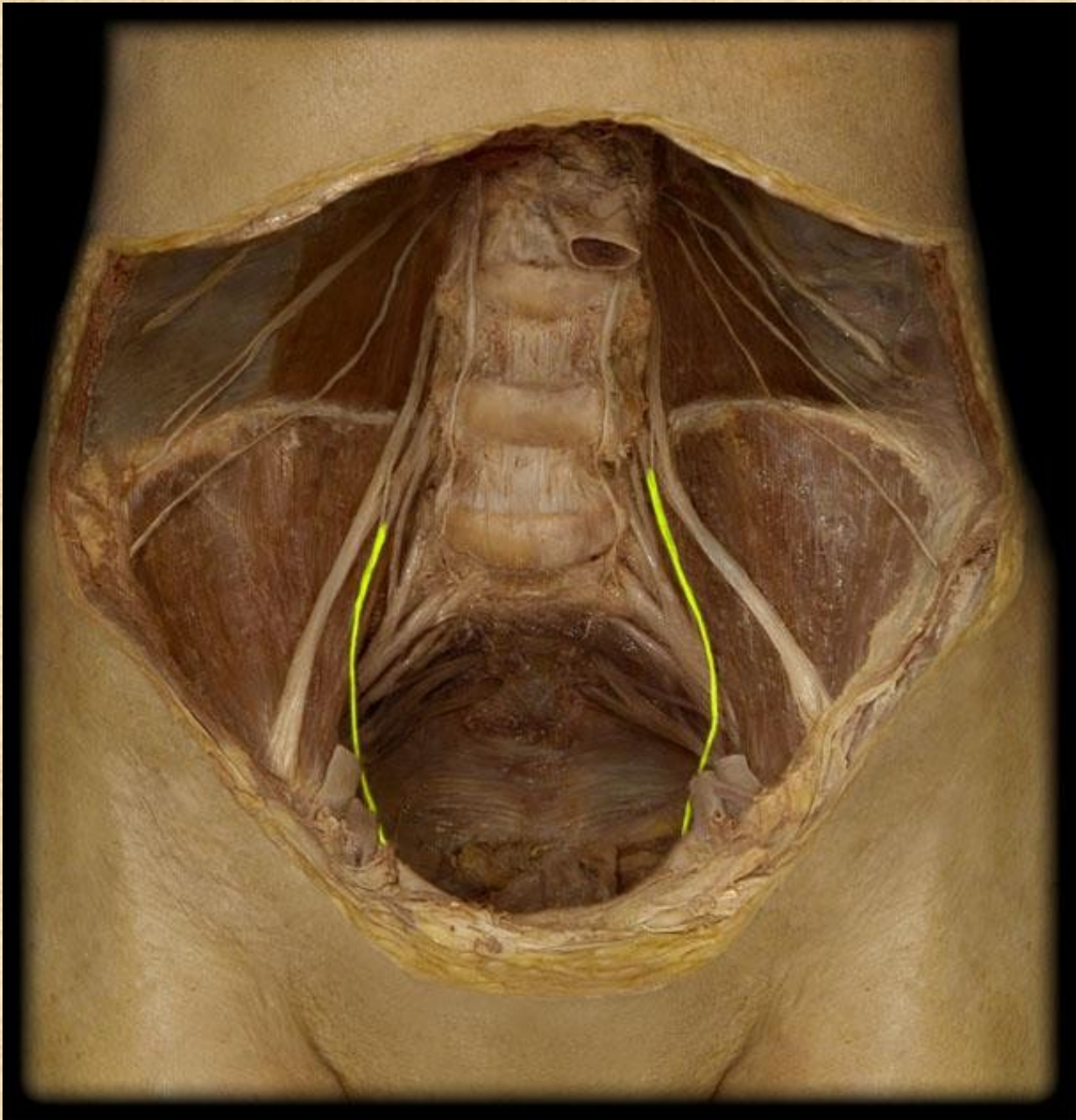
- **r. anterior - r. cutaneus**  
(m. pectineus, m. adductor longus, m. gracilis)
- **r. posterior - r. articularis**  
(m. obturatorius externus, m. adductor magnus, m. adductor brevis)

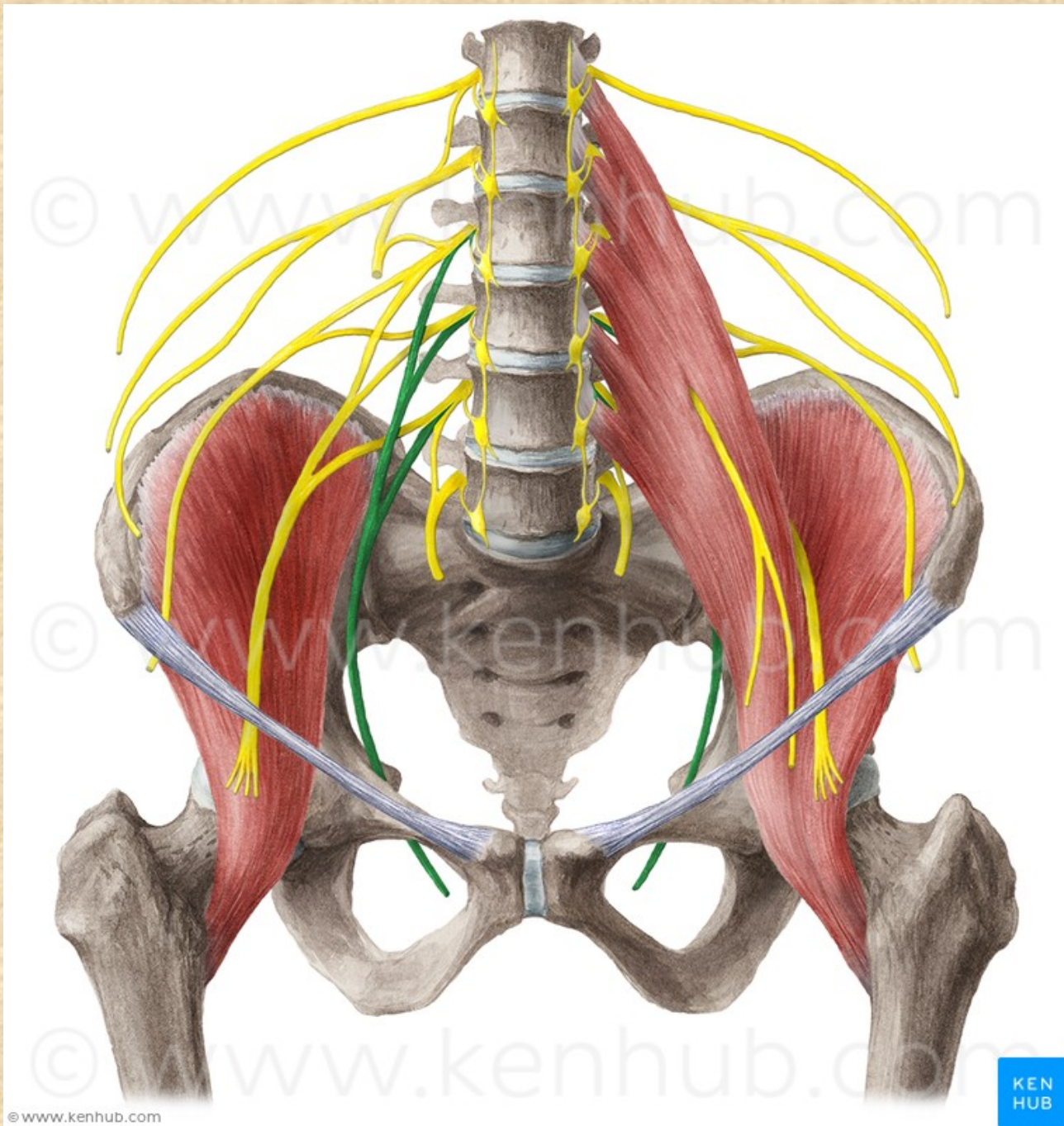
**Obrna:** není možná addukce

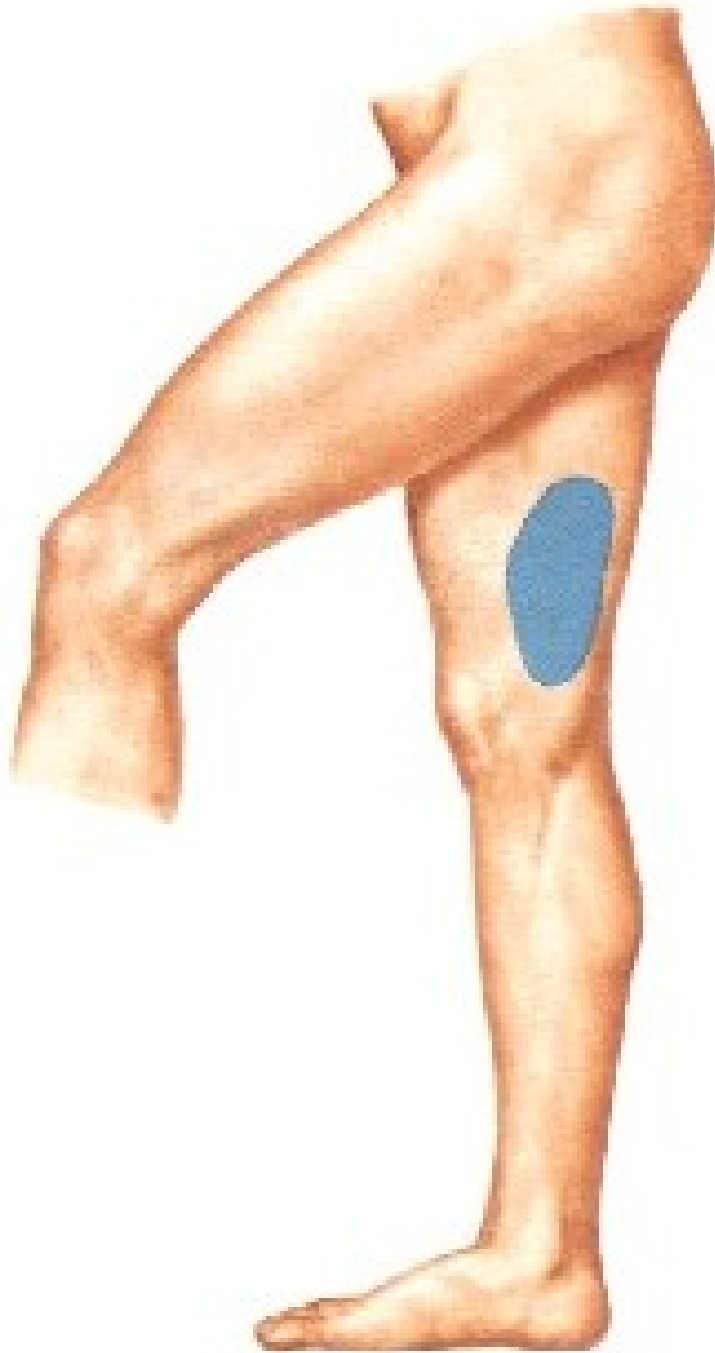











# Plexus sacralis L4-S4 (S5+Co)

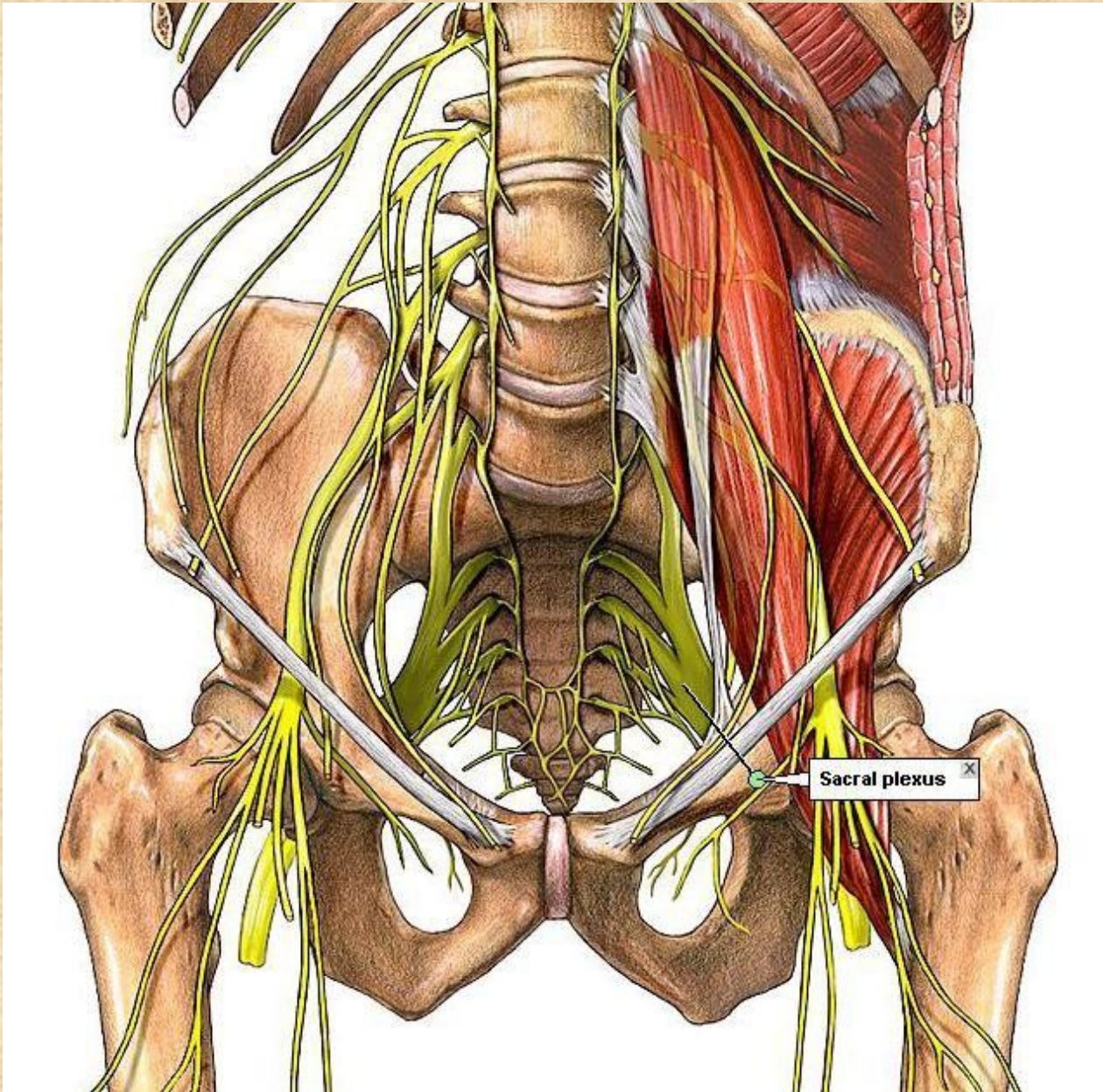
## senzoricky

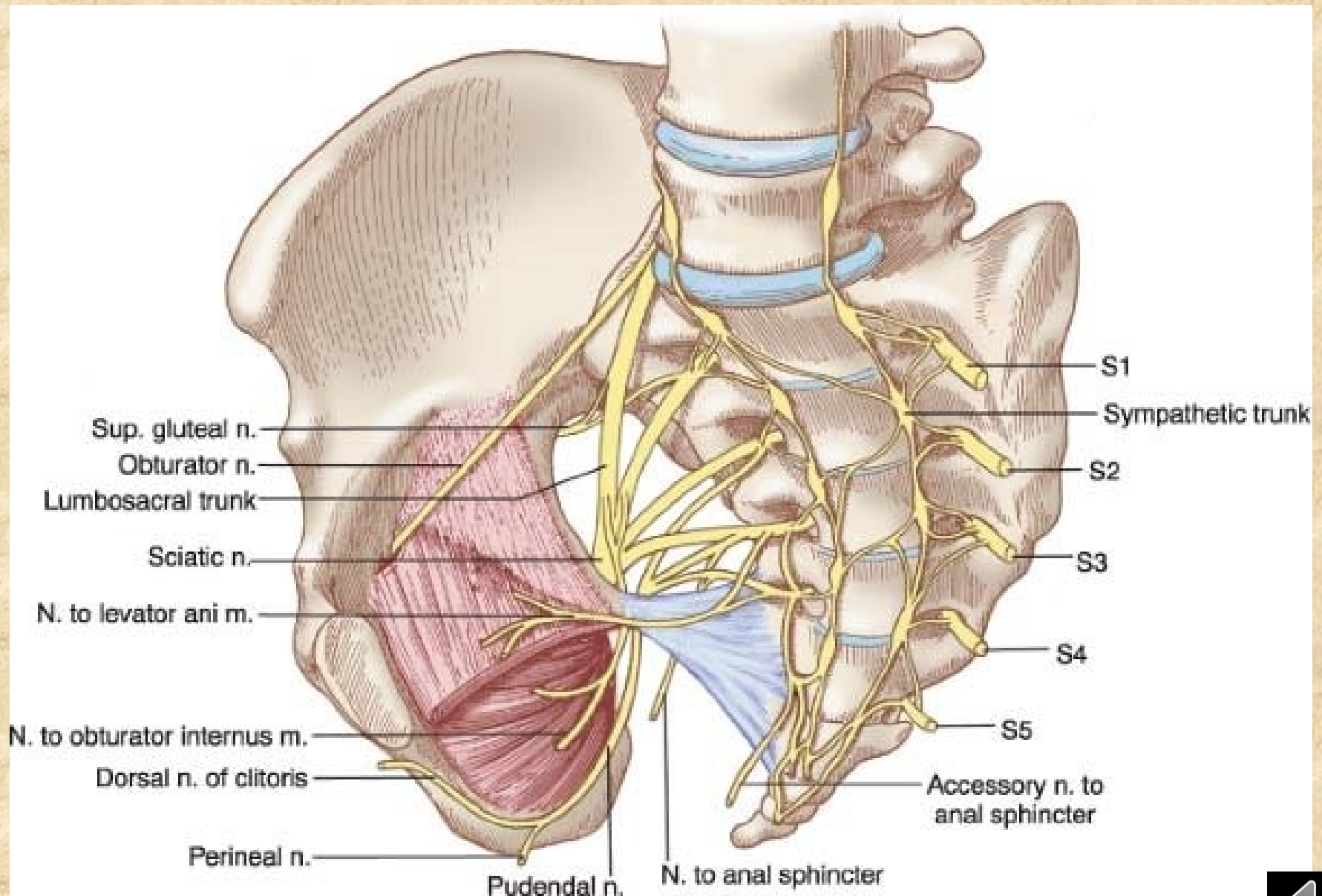
kůži v hýžd'ové oblasti, kůži na zadní ploše stehna a bérce a kůži zevních pohlavních orgánů

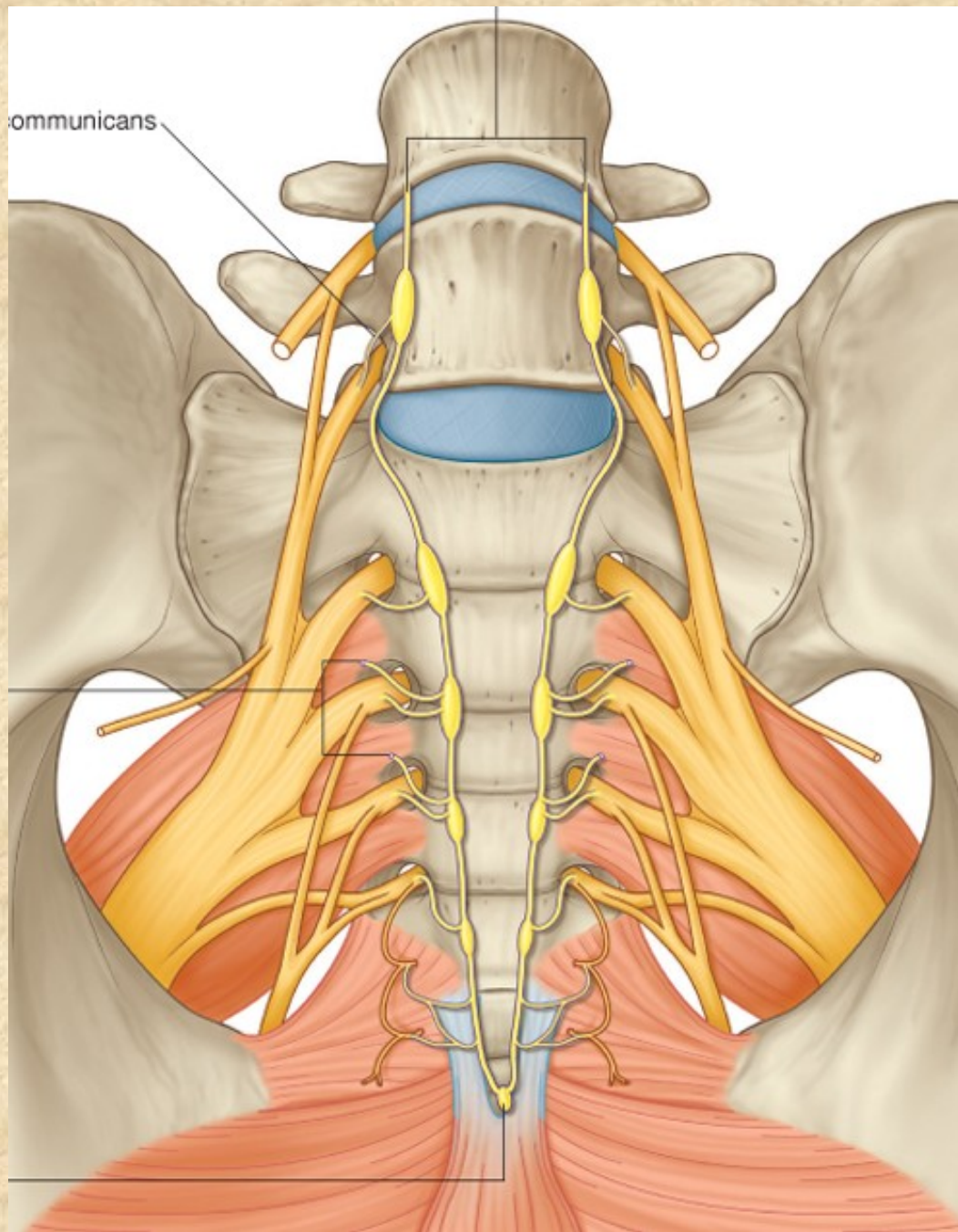
## motoricky

zadní skupinu pánevních a stehenních svalů a svaly bérce a nohy



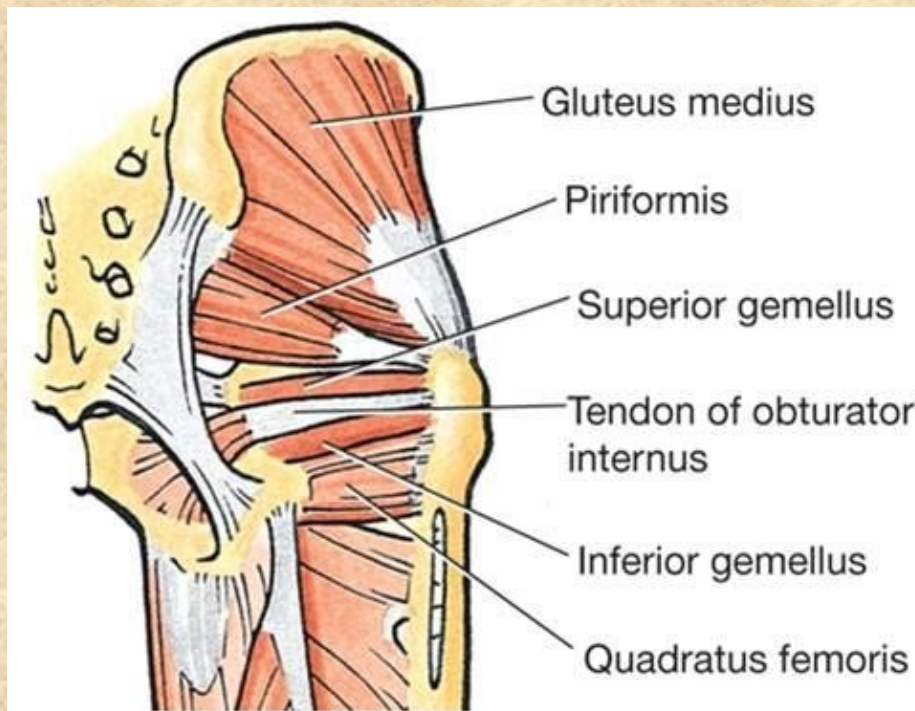






# Větve plexus sacralis

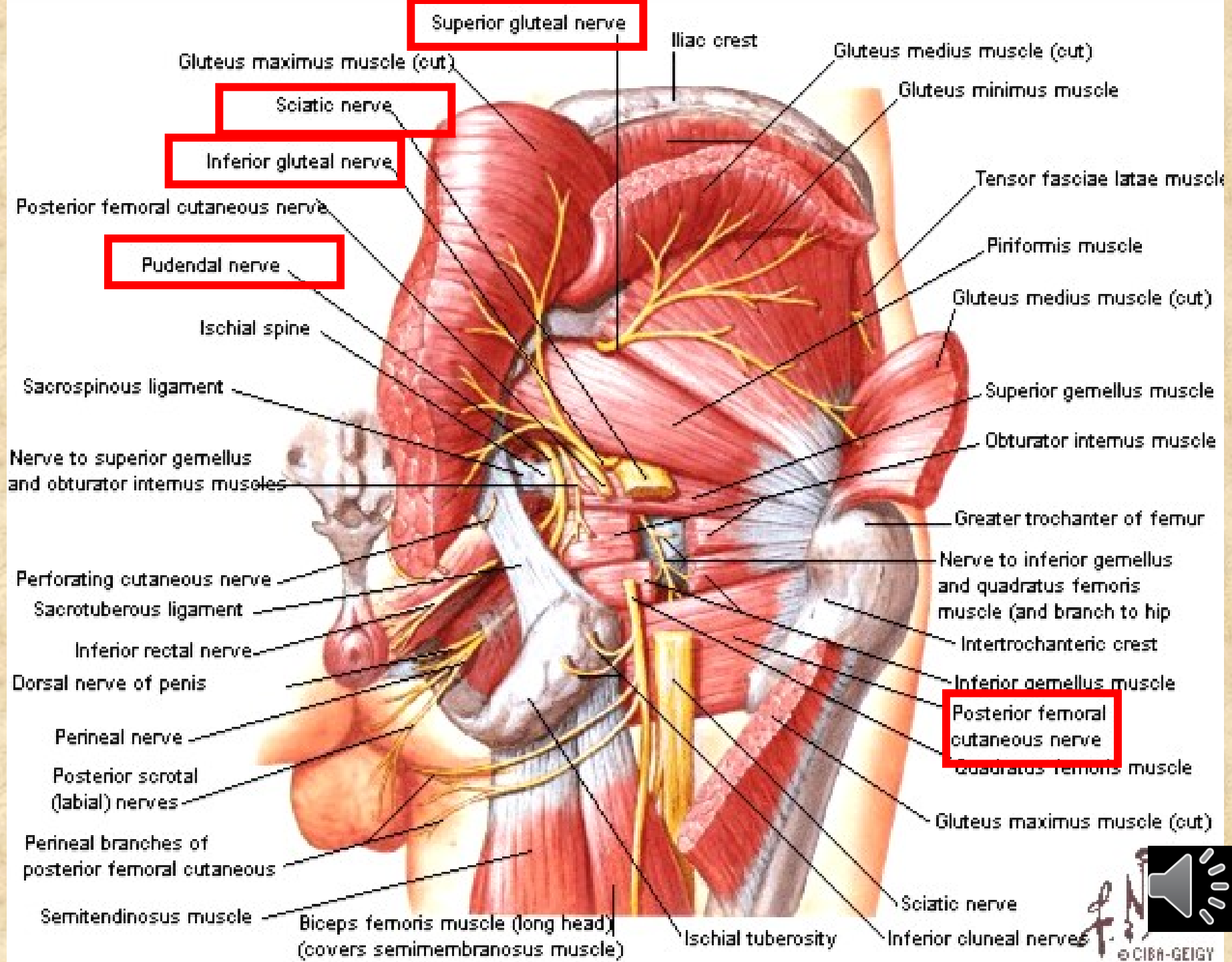
- rr. musculares: m. piriformis, m. obturatorius int., m. quadratus femoris, mm. gemelli



C Posterior view





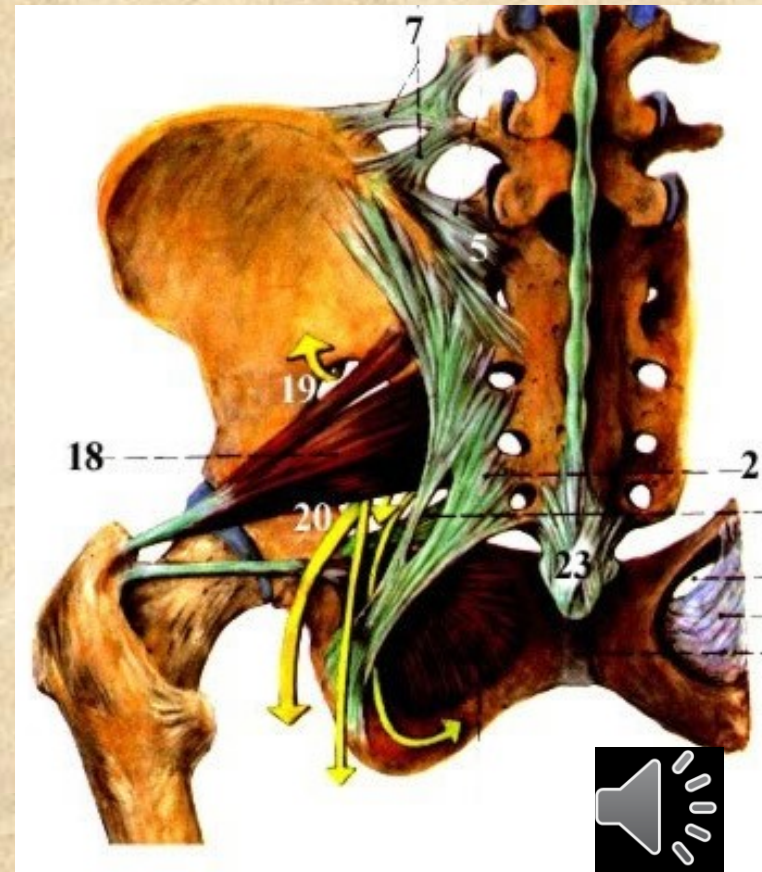


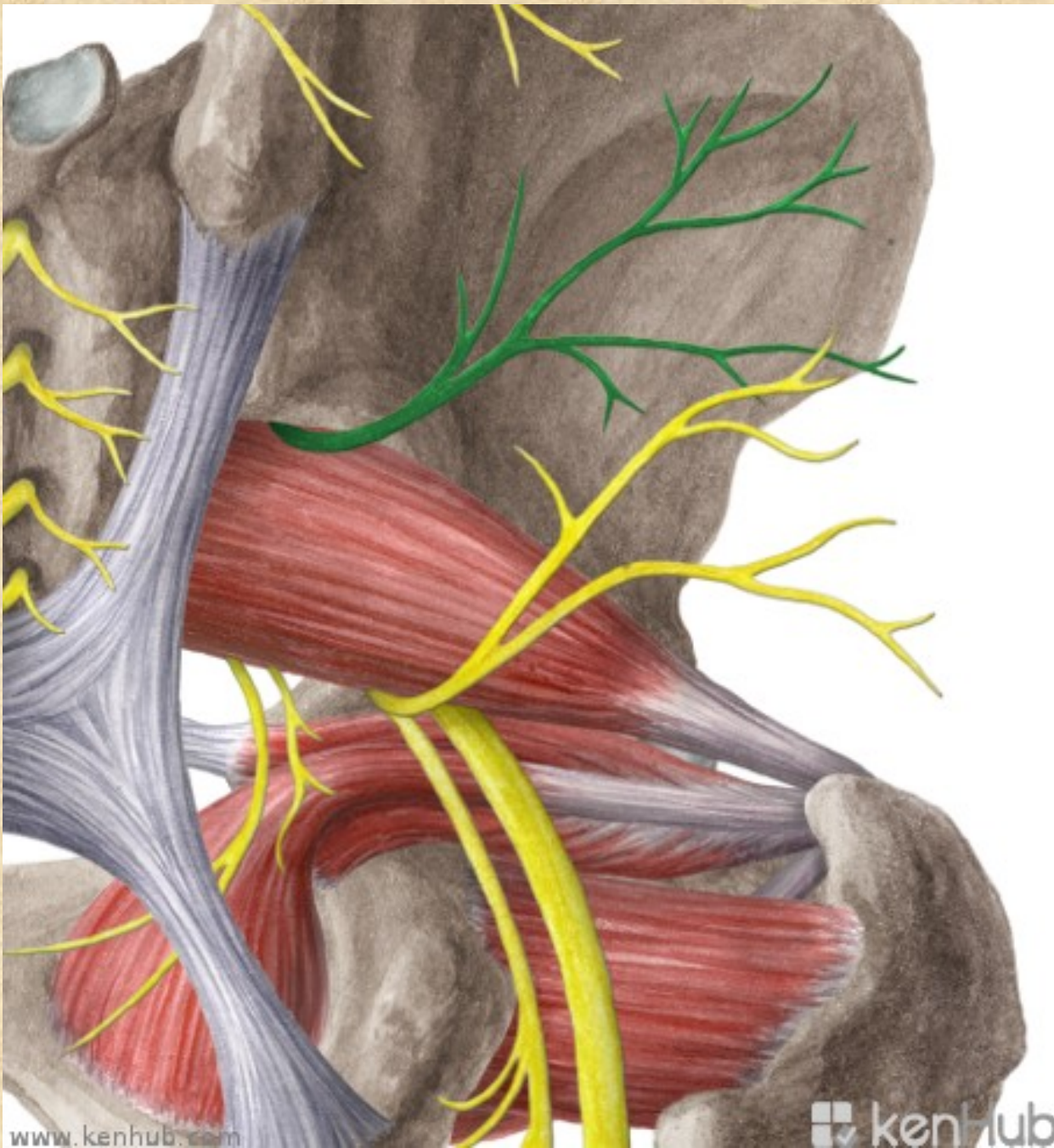
# Nervus gluteus superior L4-S1

- m. gluteus medius et minimus, m. tensor fasciae latae
- foramen suprapiriforme

## Poškození n. gluteus superior

poškození: při porodu tlakem hlavičky,  
abnormální průběh skrze m. piriformis  
oslabení svalů, především abductorů a  
vnitřních rotátorů v kyčli, obrna nervu -  
porucha extenze v kyčli

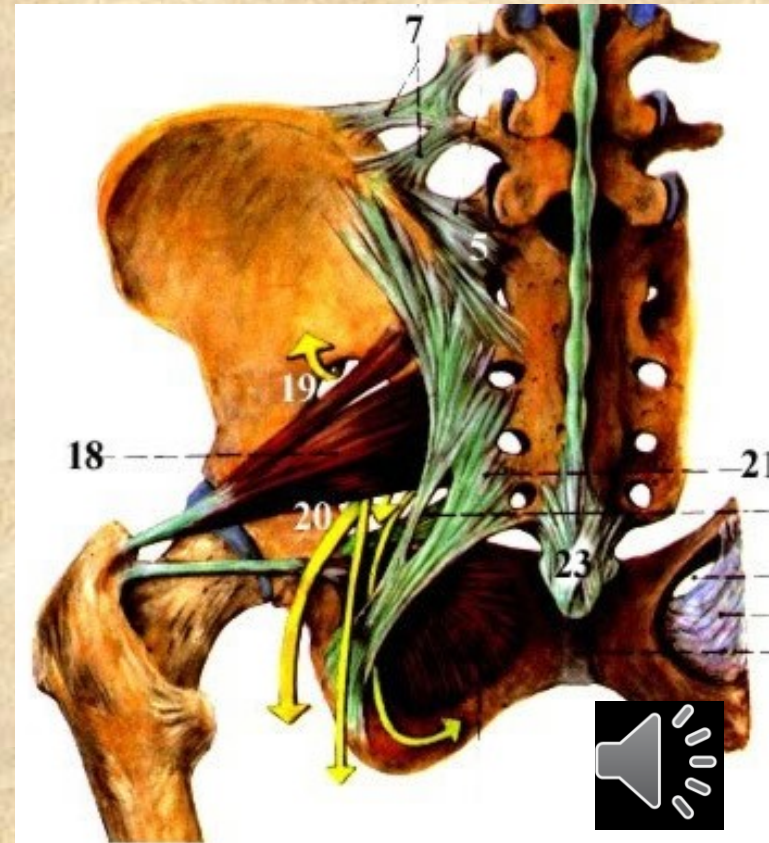


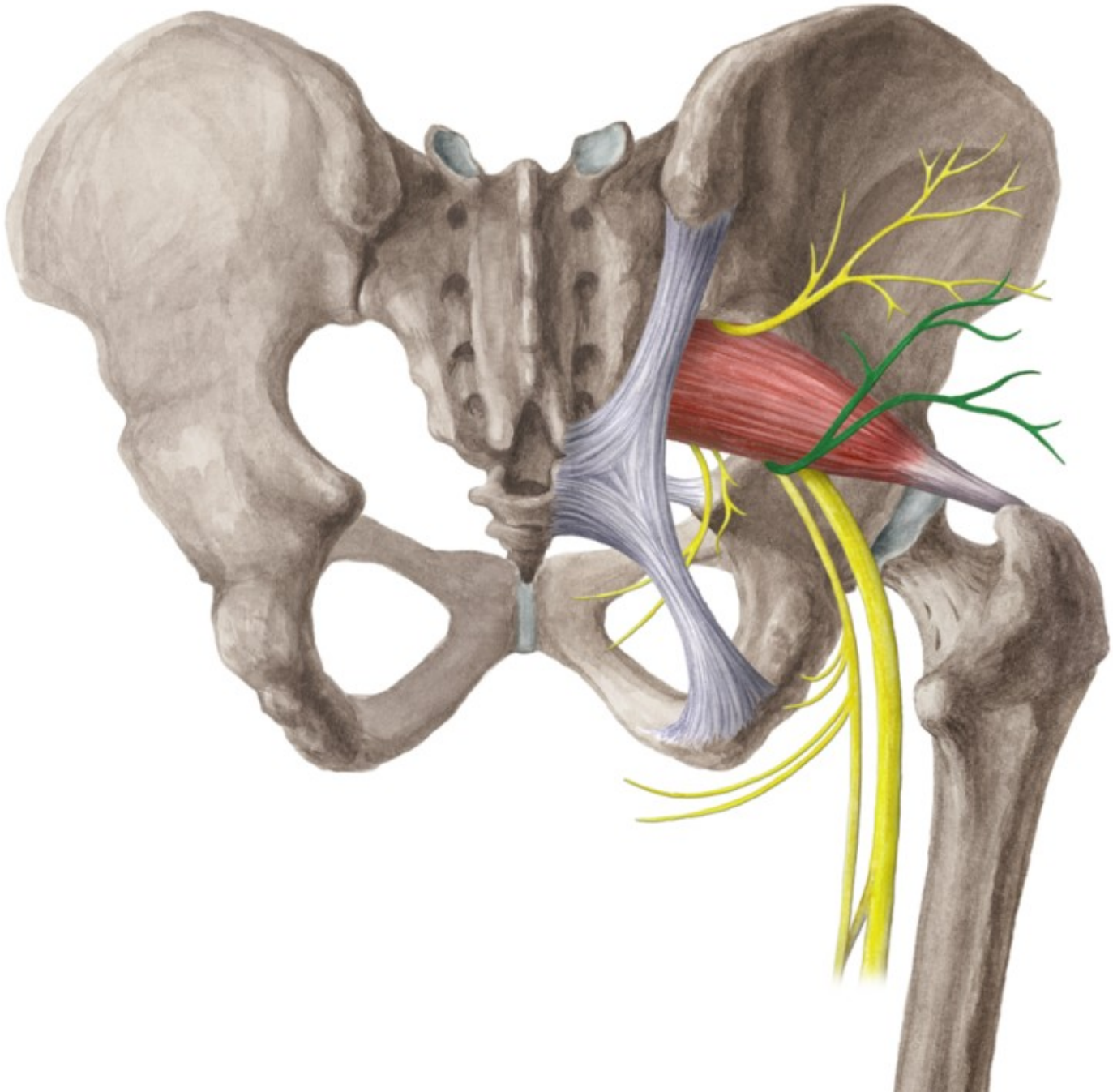


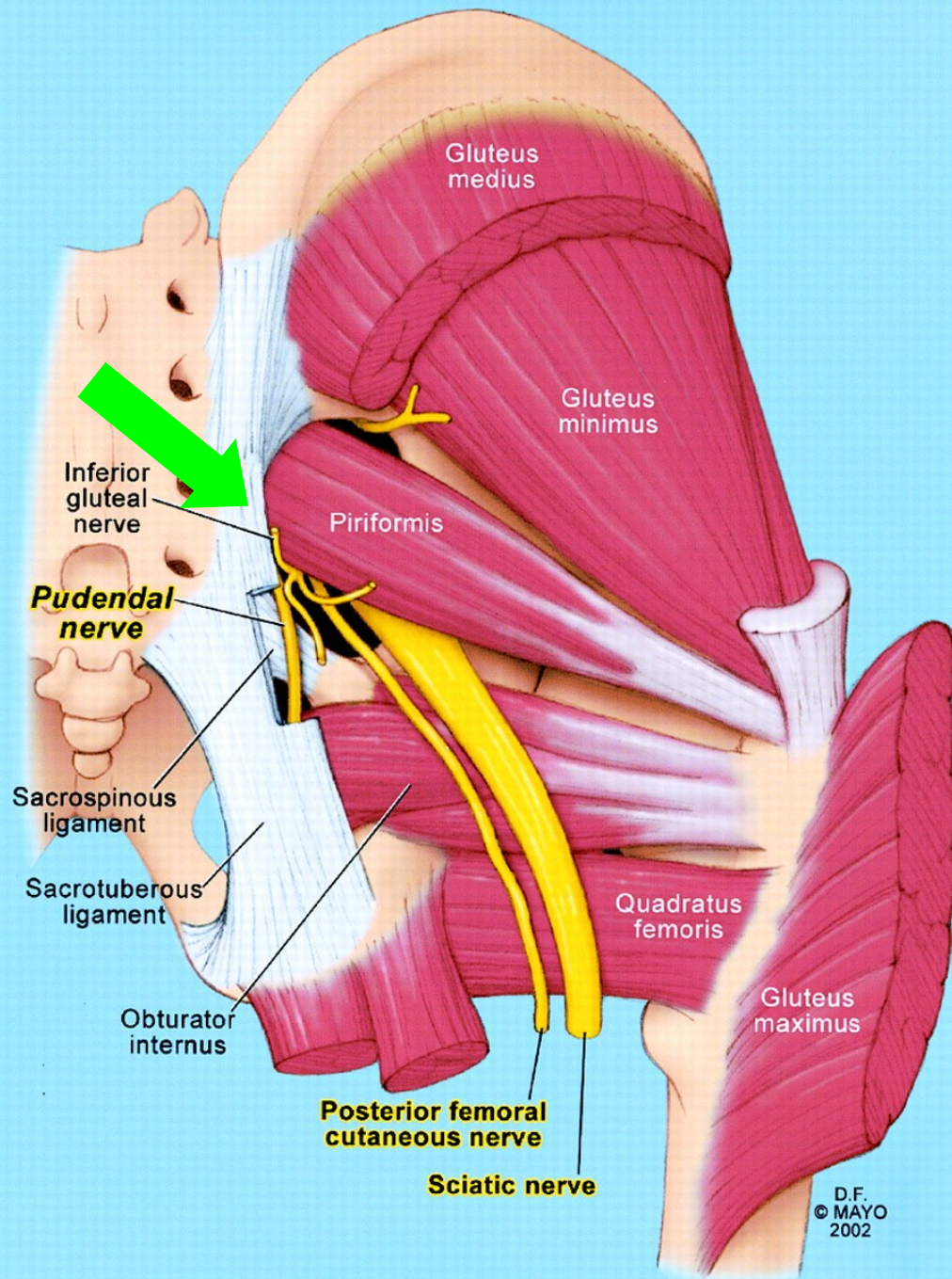
# Nervus gluteus inferior L5-S2

m. gluteus maximus, zadní část pouzdra kyčelního kloubu


foramen infrapiriforme







D.F.  
© MAYO  
2002

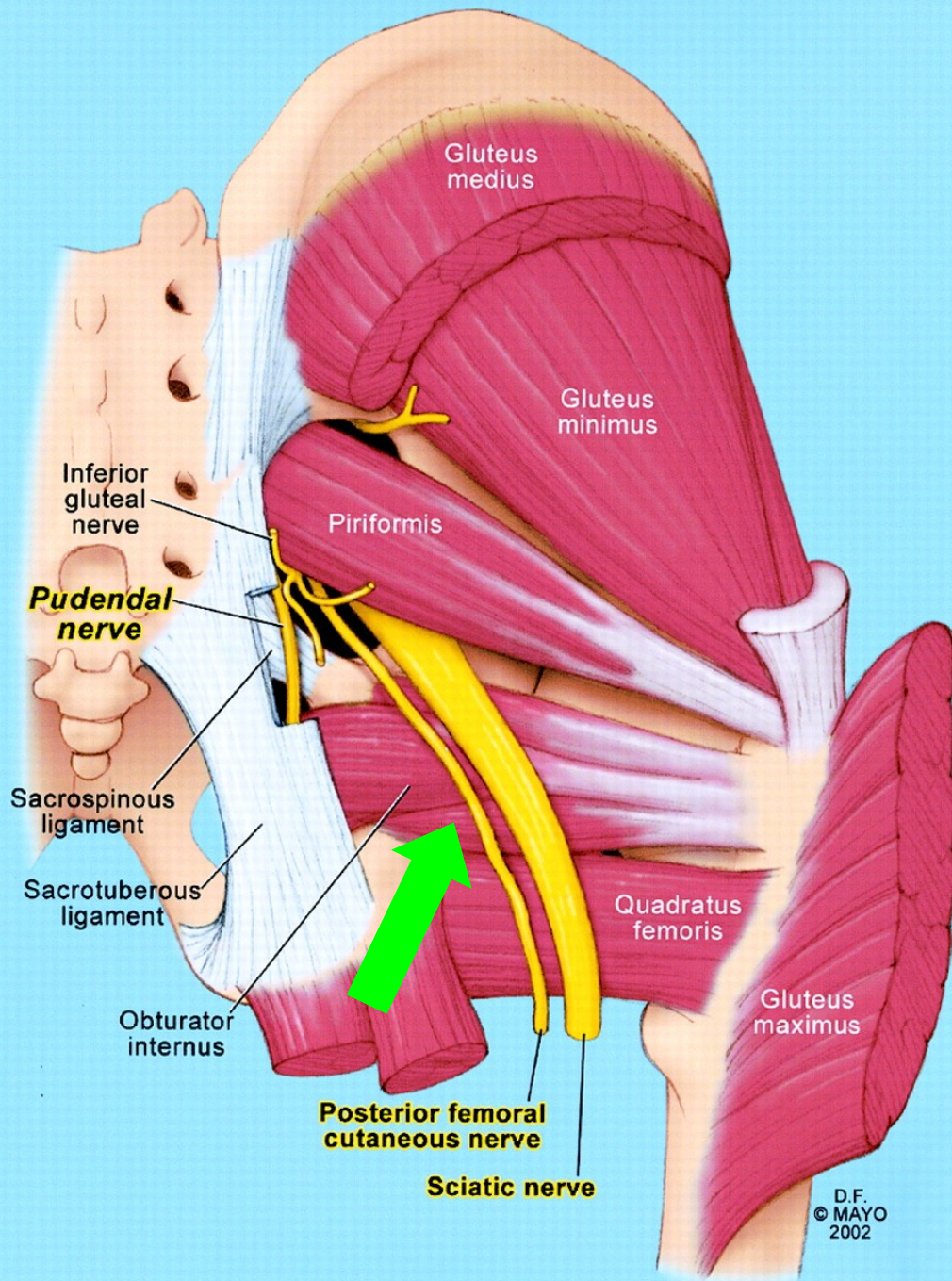


# Nervus cutaneus femoris posterior S1-S3

kůže zadního stehna, jámy zákolenní a proximální části zadního bérce

- **rr. perineales** - ke kůži hráze a scrota (labia majora)
- **nn. clunium inf.** - ke kůži dolní části hýždí
- **rr. cutanei-** ke kůži regio femoris posterior

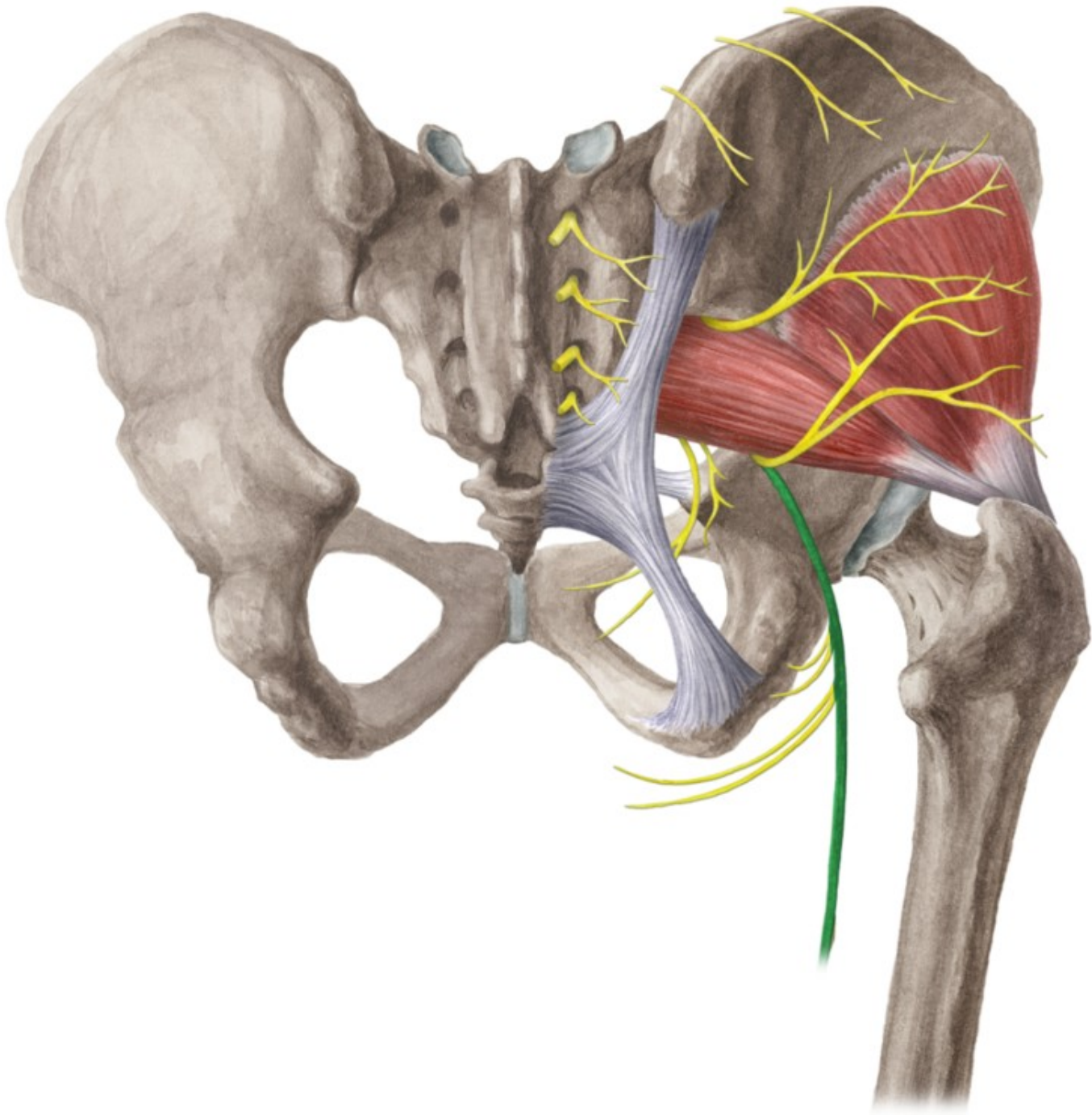


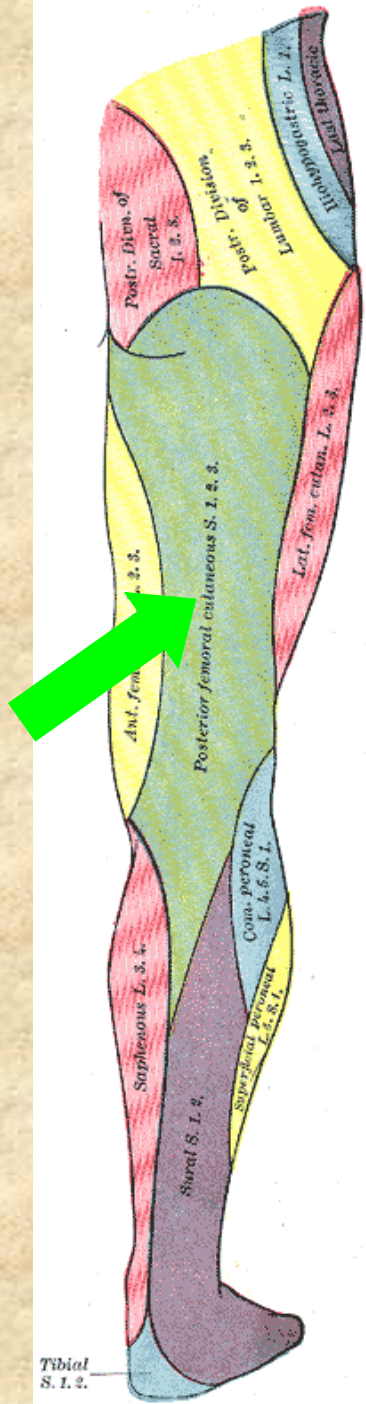


D.F.  
© MAYO  
2002









# Nervus ischiadicus L4-S3

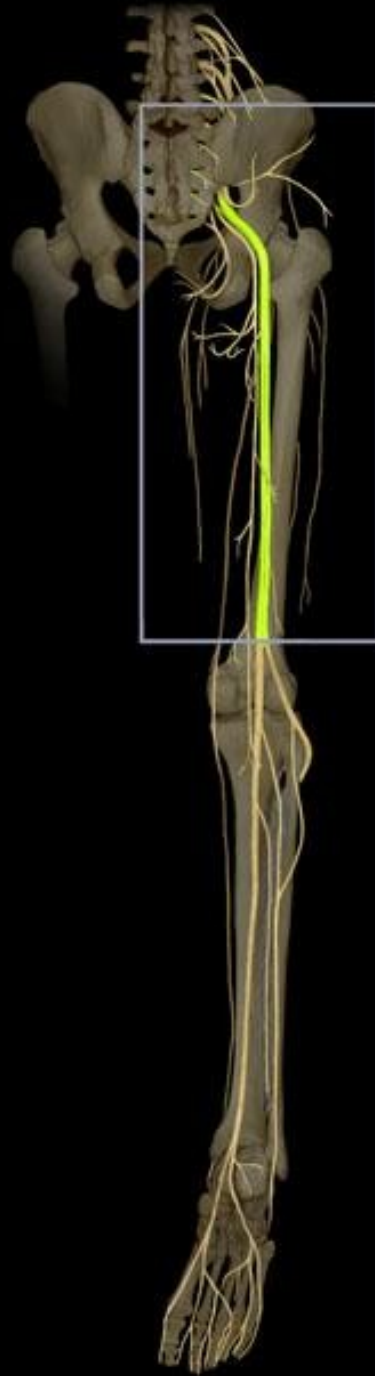
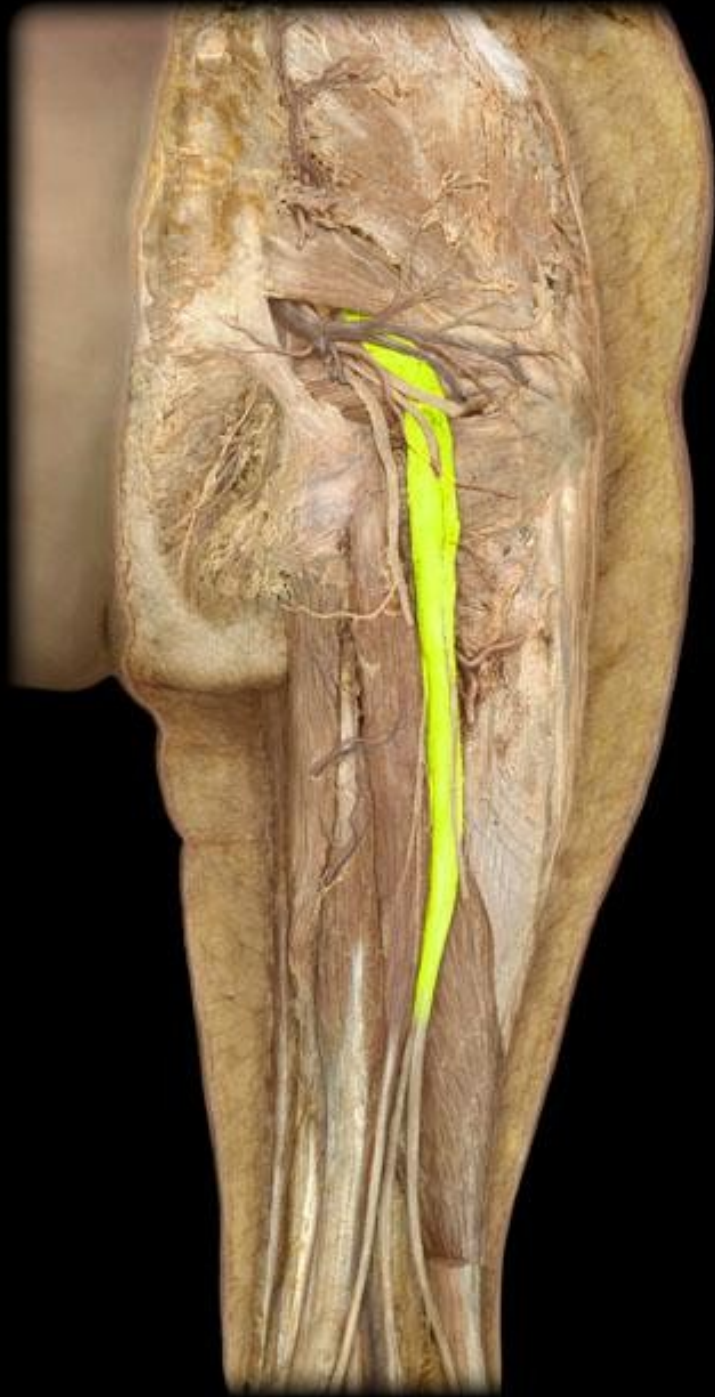nejsilnější periferní nerv v těle

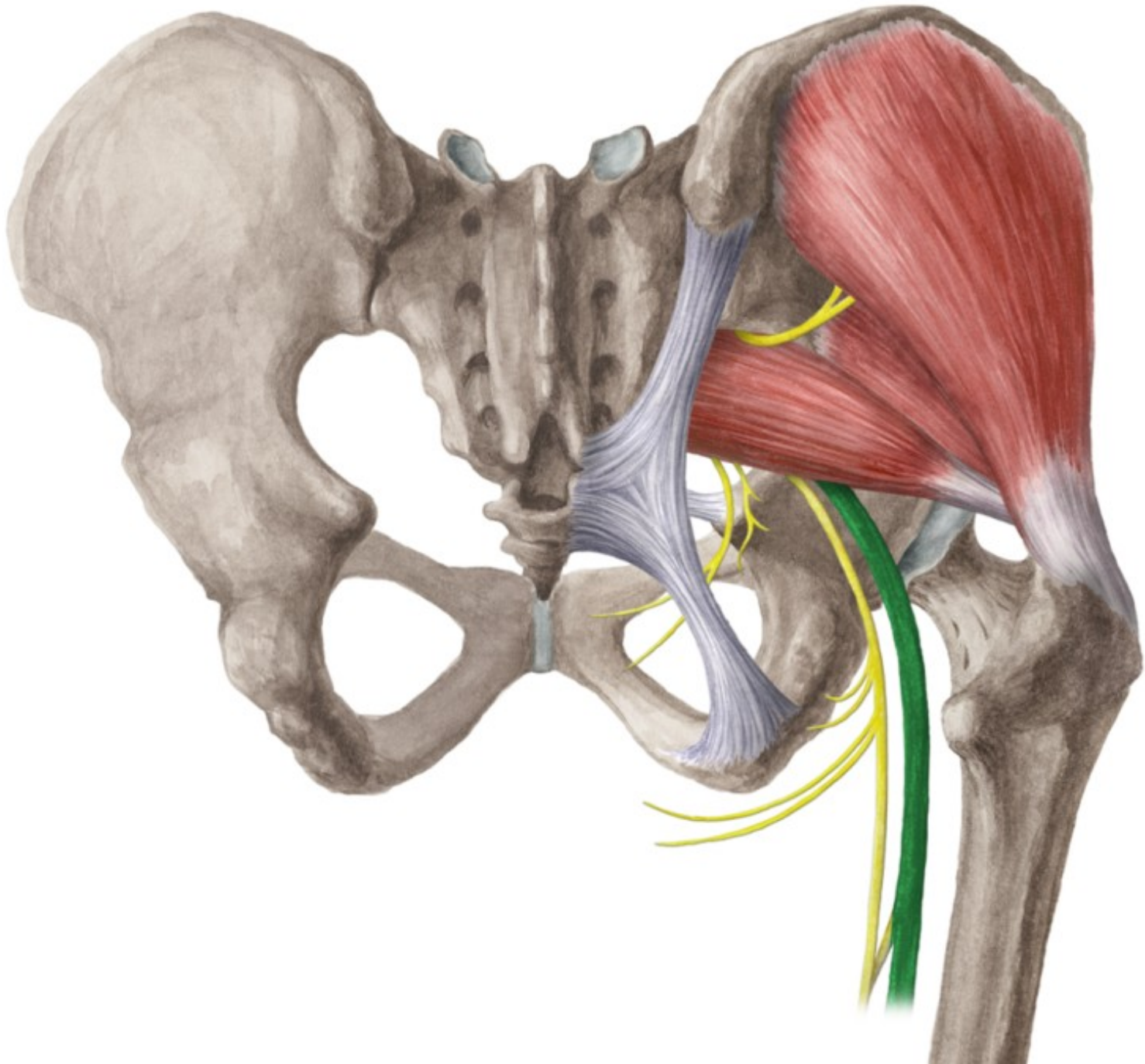
- **rr. musculares (zadní strana stehna + m. adductor magnus)**
- **rr. articulares (art. coxae)**

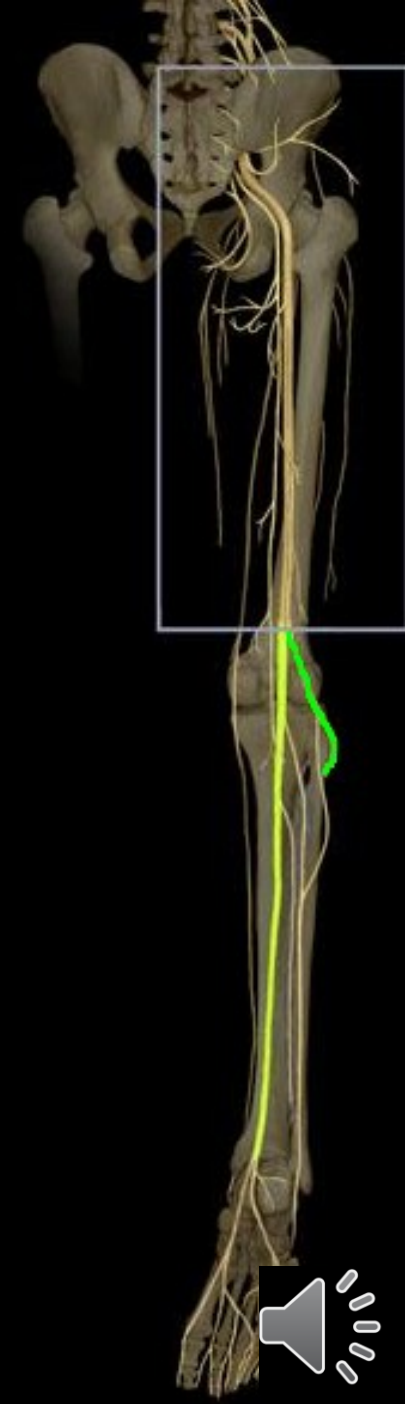
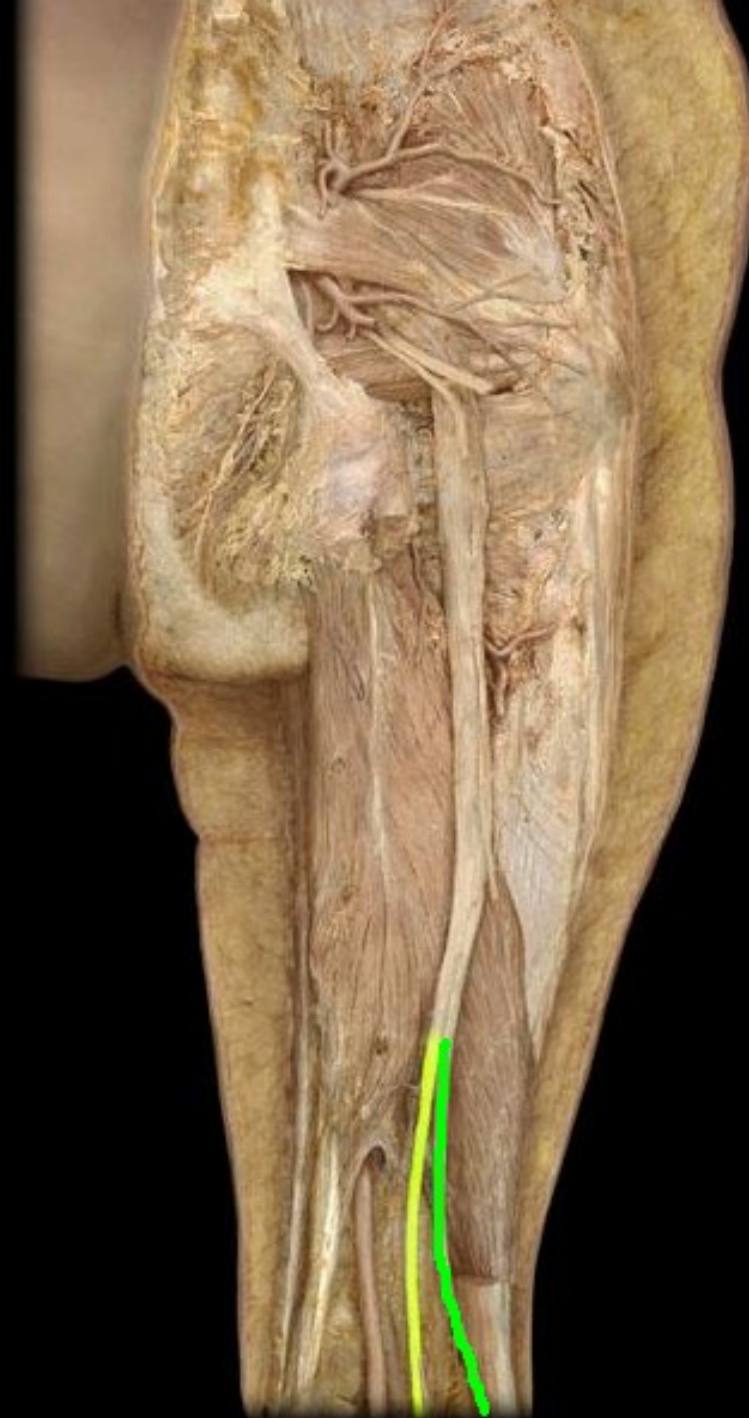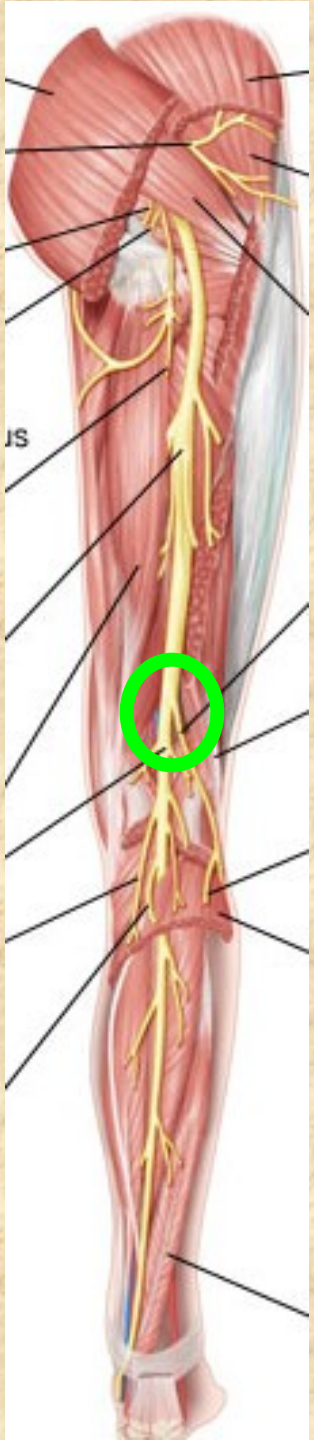
## **Konečné větve:**

- **n. fibularis communis**
- **n. tibialis**









# Nervus tibialis

- přímé pokračování n. ischiadicus (fossa poplitea, pod arcus tendineus m. solei a dále za mediální kotník - canalis malleolaris - do planty)

**n. cutaneus surae medialis** → r. **communicans peronaeus**

**n. suralis**- přilehlá kůže bérce, za zevním kotníkem

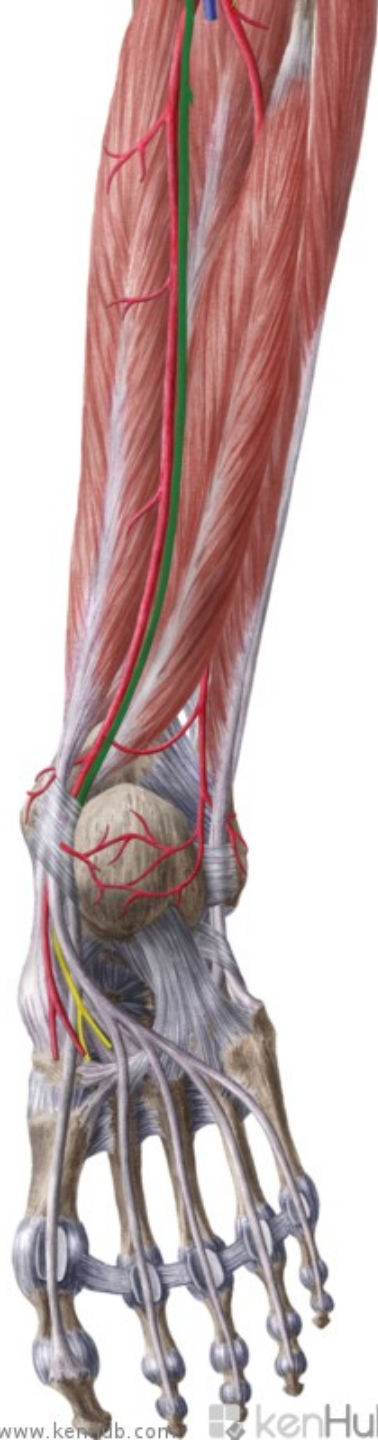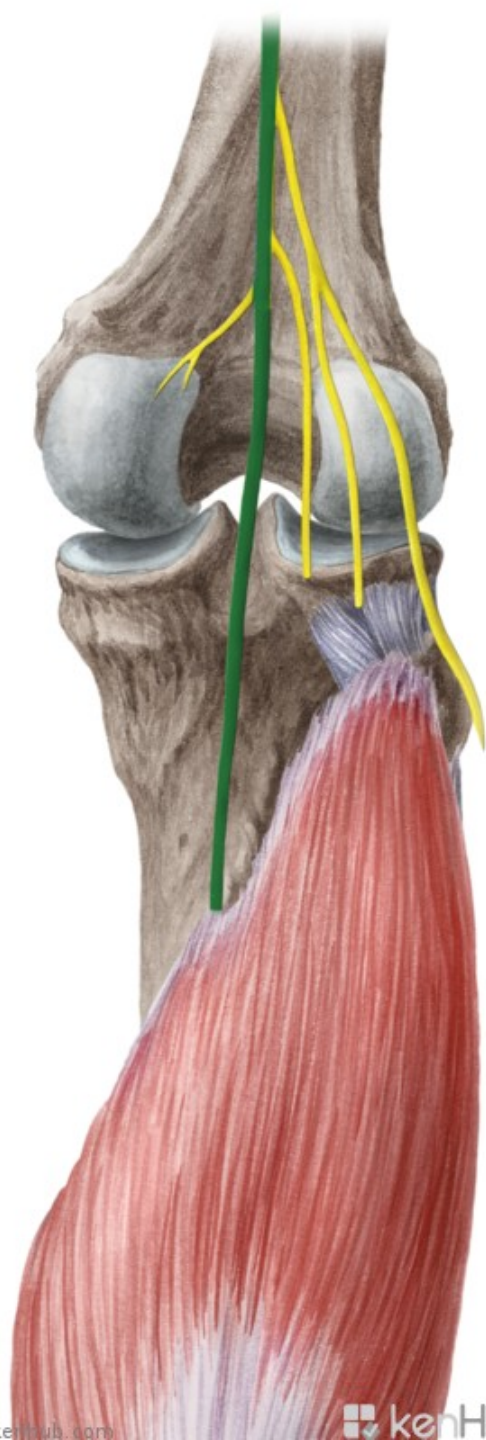
- rr. **calcanei lat.**

- n. **cutaneus dorsalis lateralis**- lat. okraj nohy a malíku

**rr. musculares** svaly zadní skupiny bérce

rr. **calcanei mediales**

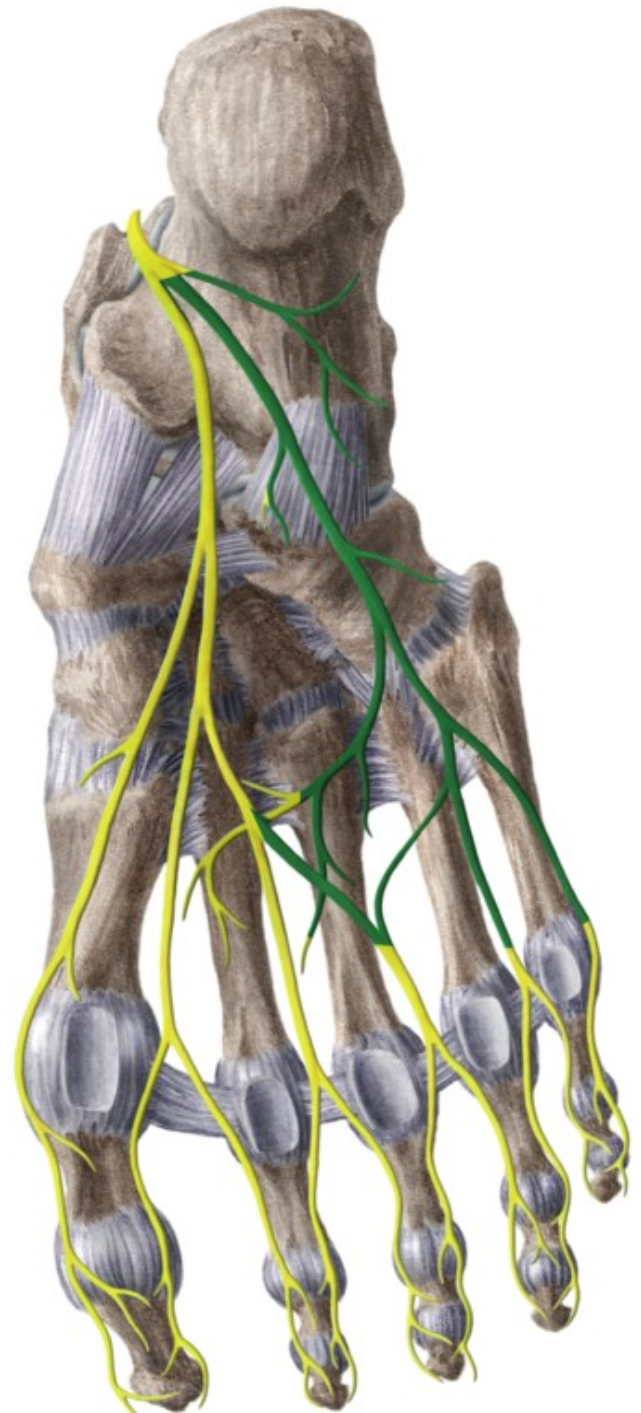
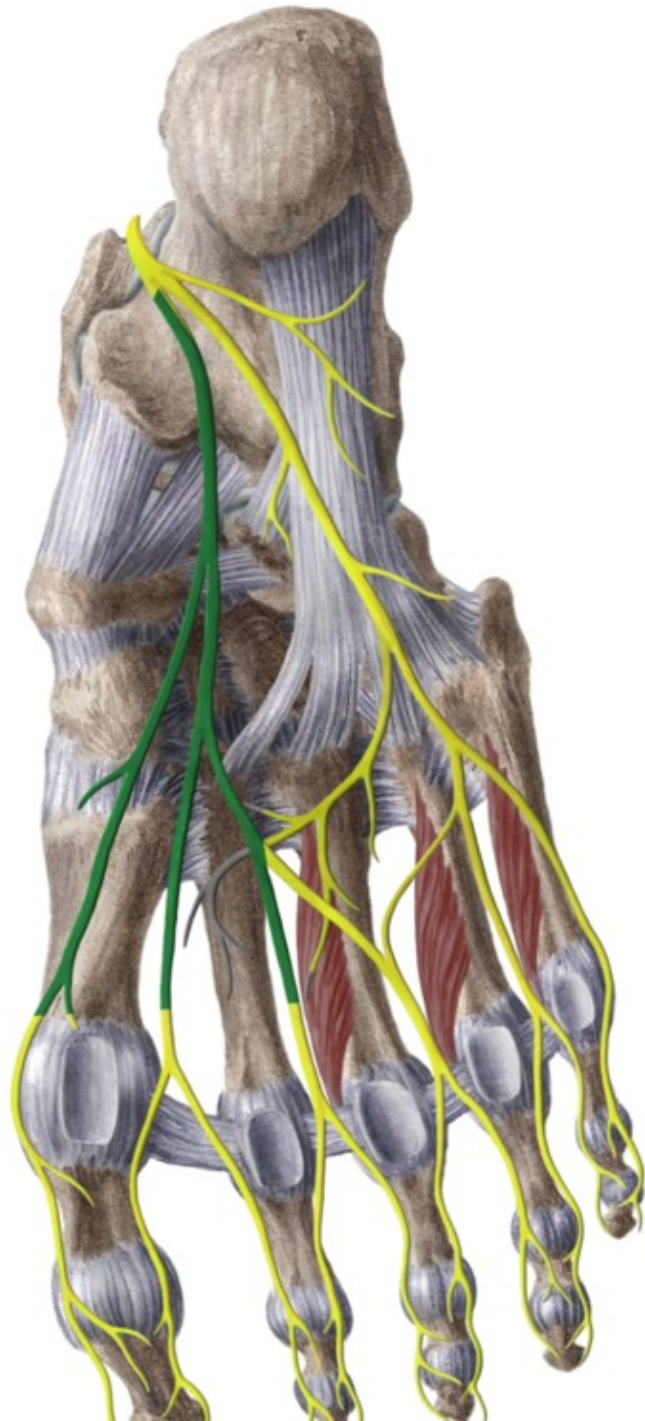


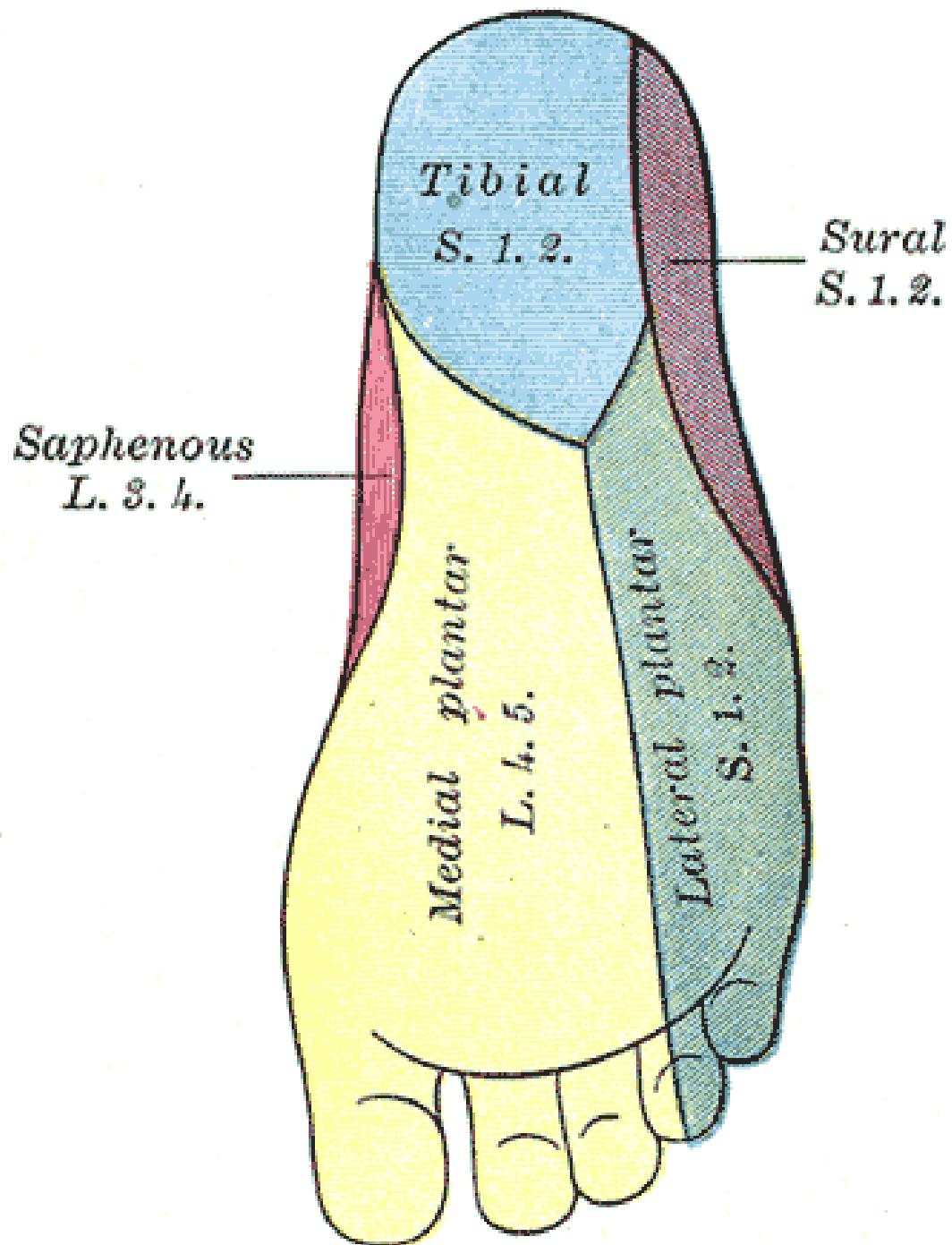




- Konečné větve:
- **n. plantaris medialis**
- **rr. musculares:** m. abductor hallucis, m. flexor hallucis brevis, m. flexor digitorum brevis, I. a II. m. lumbricalis
- **n. plantaris lateralis**
- **rr. musculares:** m. quadratus plantae, m. flexor dig. min., m. abductor digiti minimi, m. opponens a flexor dig. min. brevis, mm. interossei, 3., 4. m. lumbricalis, m. adductor hallucis

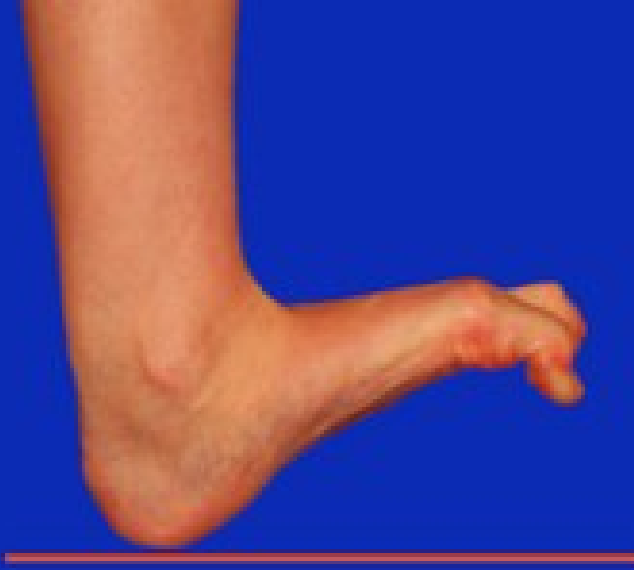



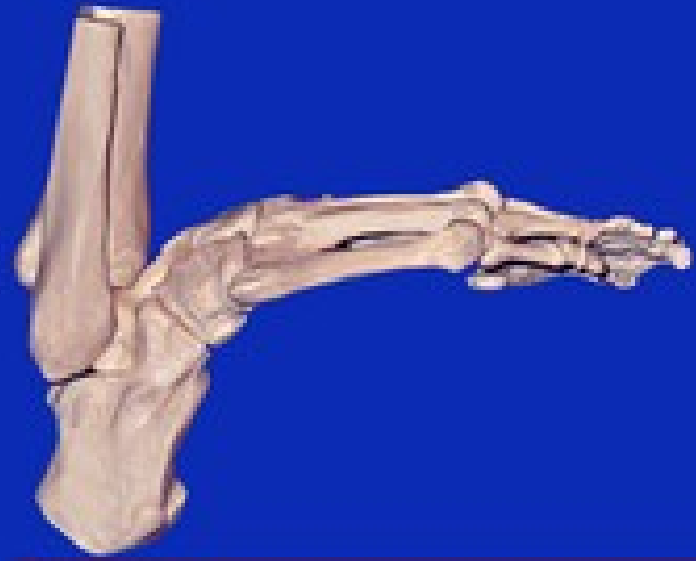


- **Motoricky:** zadní skupiny svalů bérce, svaly planty
- **Senzoricky:** většinu zádní plochy bérce, chodidlo a plantární plochu prstů
- poraněn bývá ve fossa poplitea
- v sulcus malleolaris
- obrna pes calcaneus (převaha extensorů)





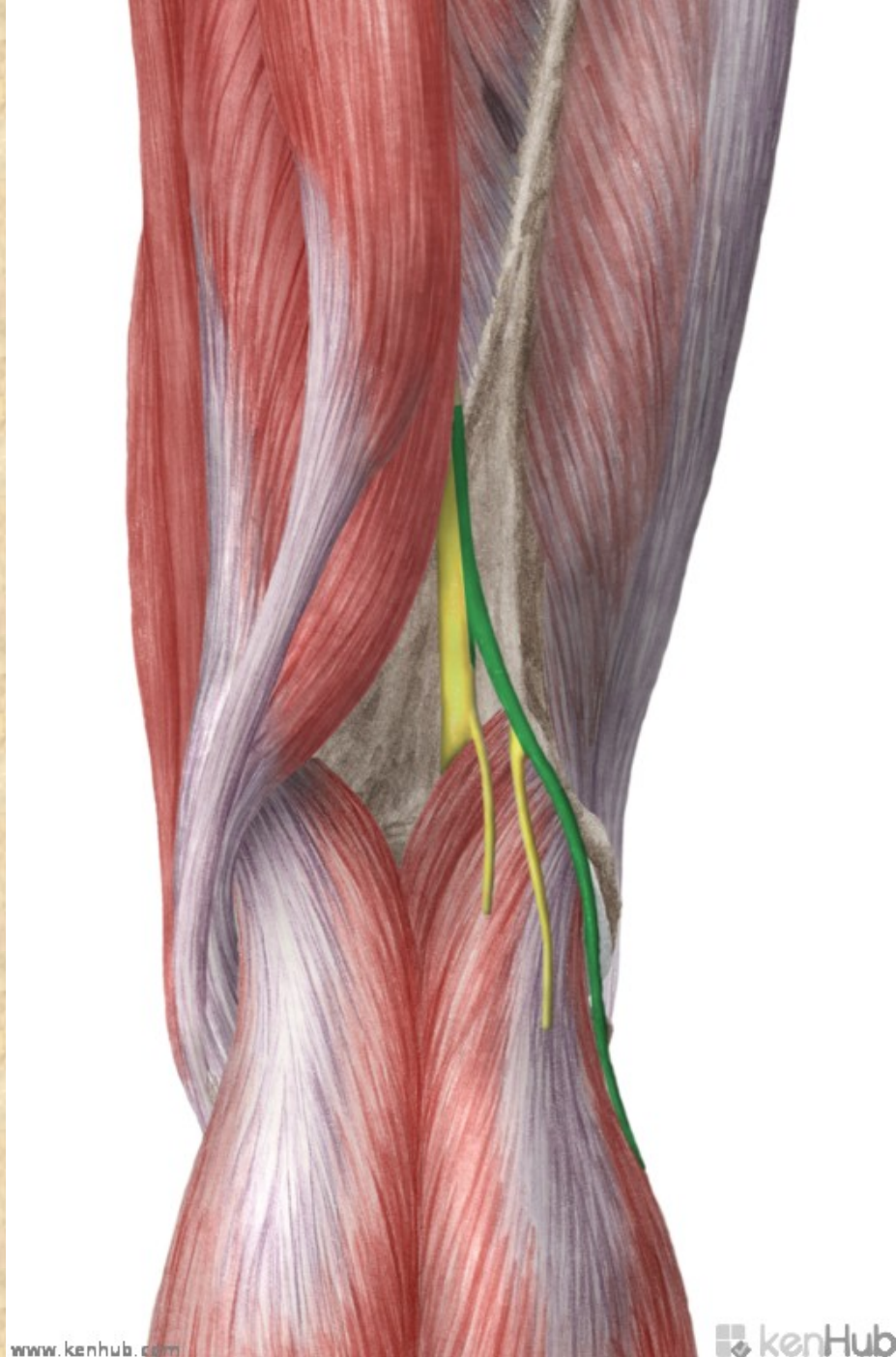
• pes calcaneus

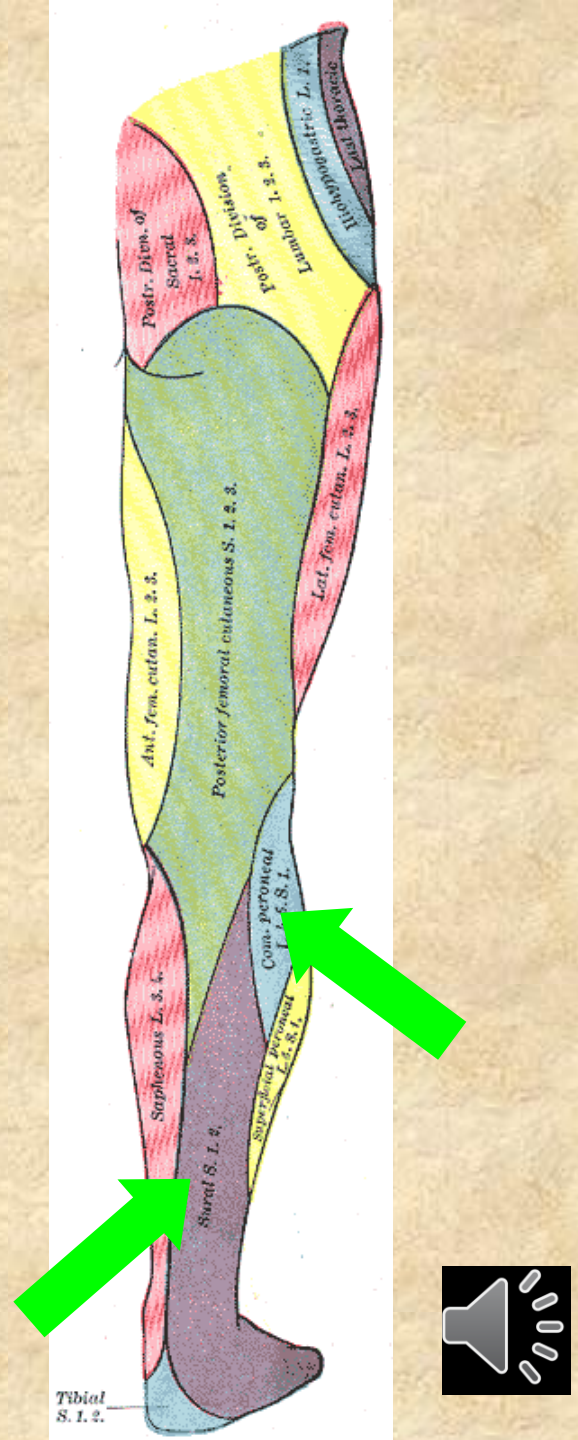
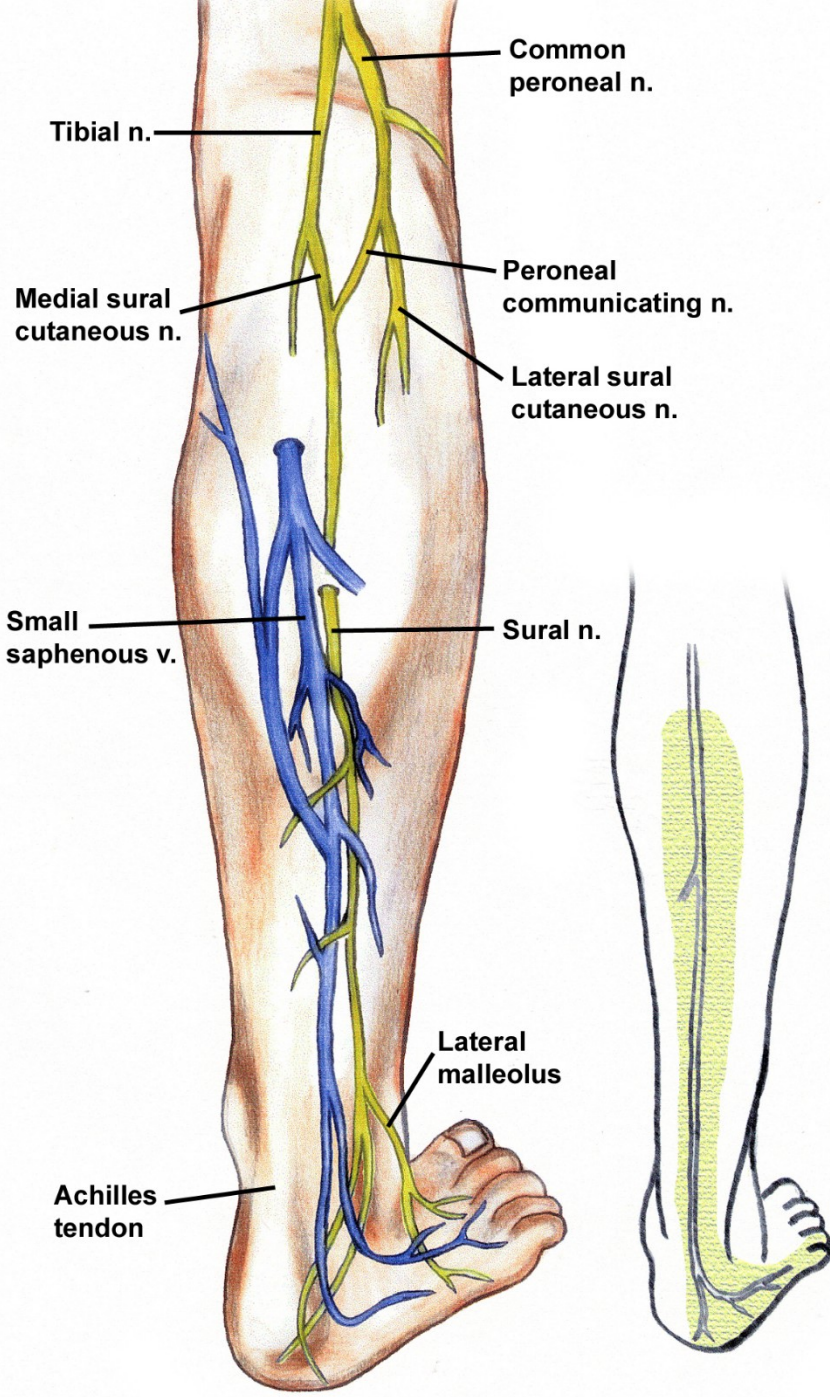


# Nervus fibularis communis

- rr. articulares
- *n. cutaneus surae lat.* - senzit.-kůže na laterální straně lýtka
  - přední větev → kůže dorzolaterálního bérce
  - zadní větev - *r. communicans fibularis* → do n. suralis

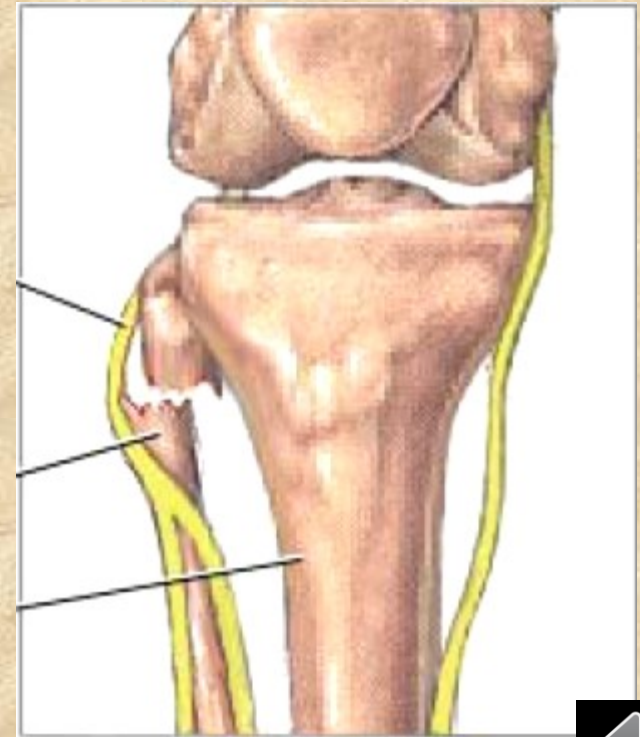








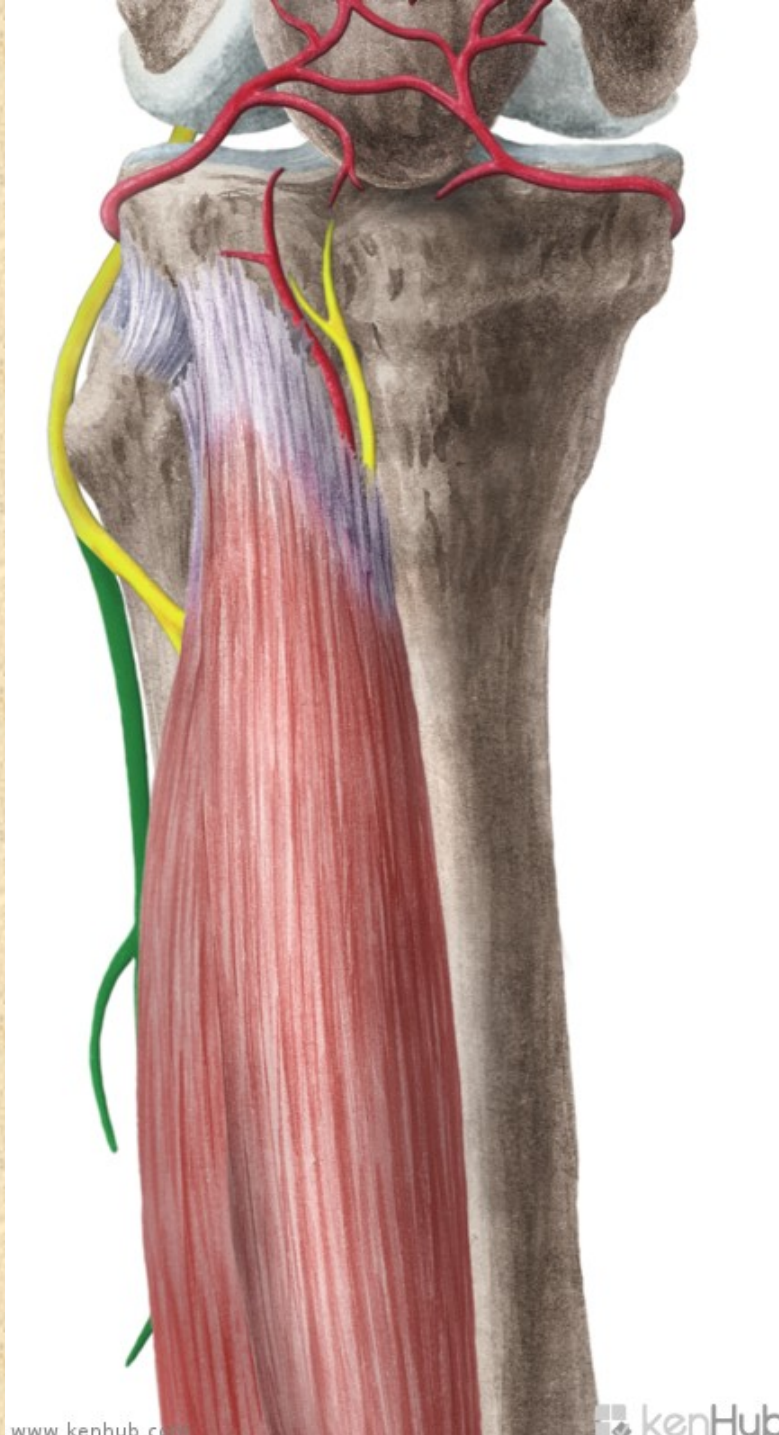
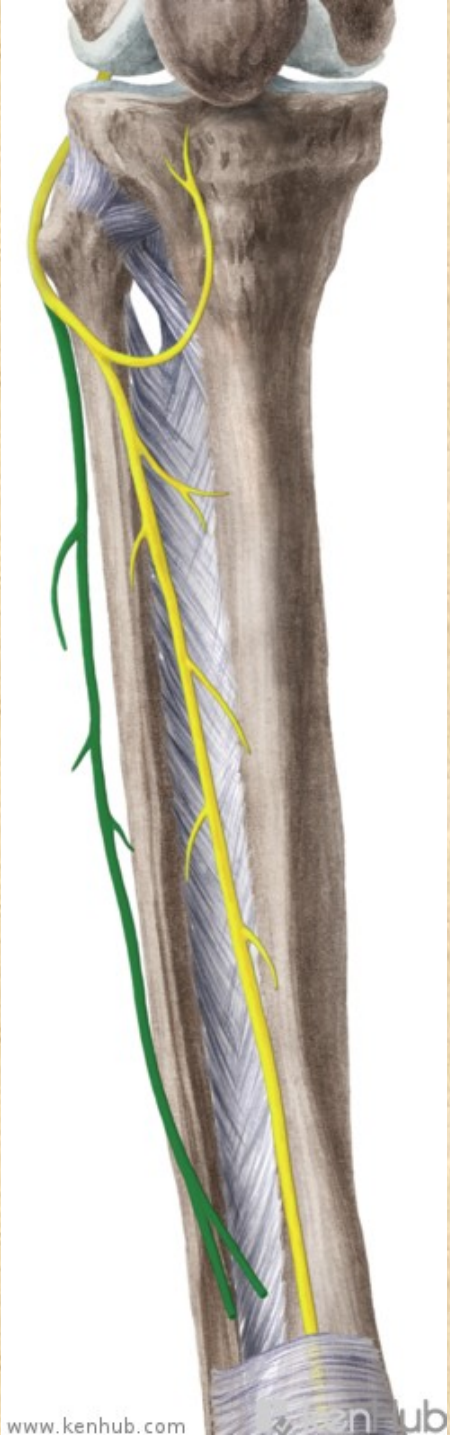
- útlak n. peroneus communis za hlavičkou fibuly
- při obrně plantární přepadávání špičky (zakopávání o špičky)- kompenzace:  
**KOHOUTÍ CHŮŽE**

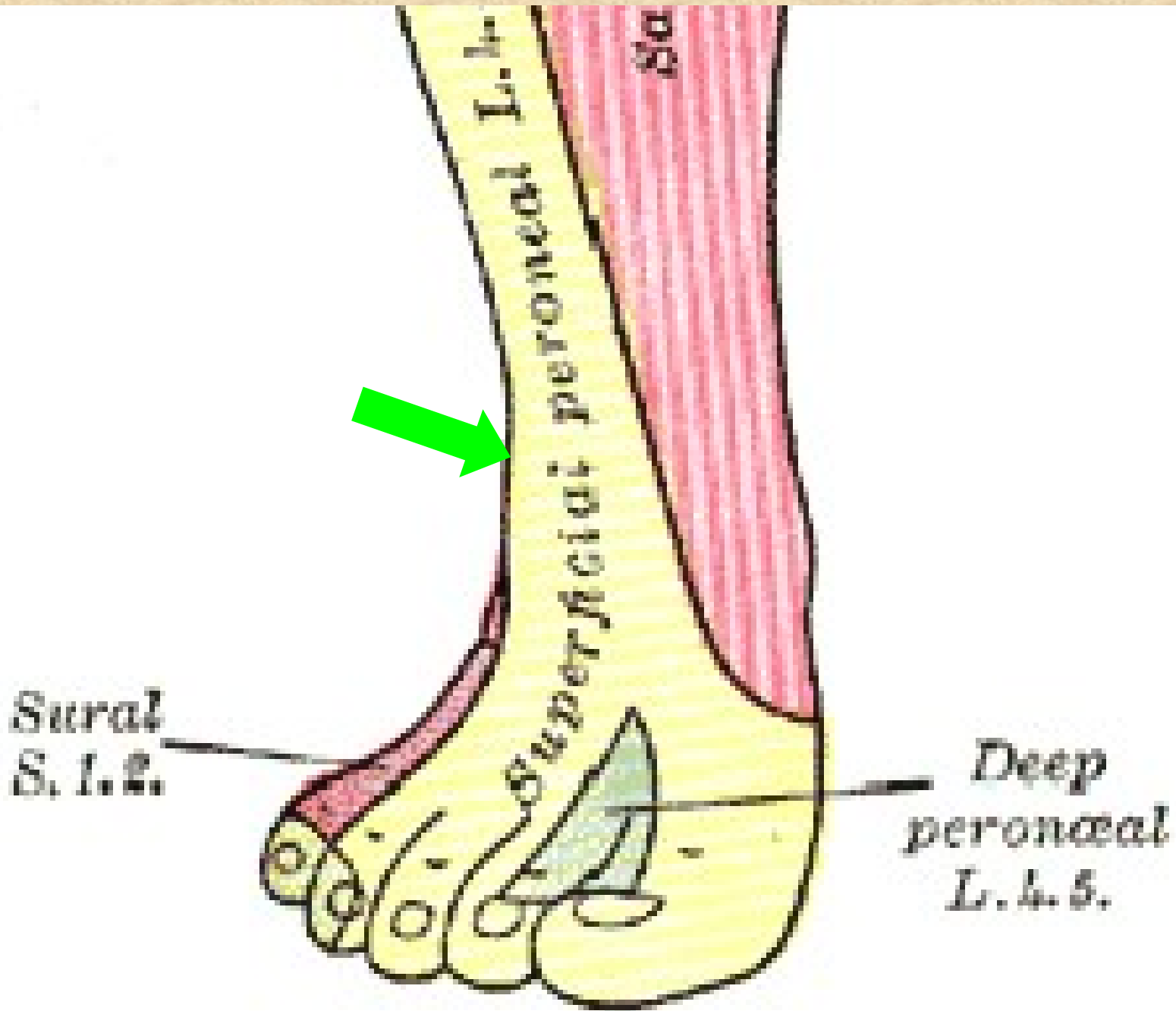


# Nervus fibularis superficialis

- *n. fibularis superficialis*
- rr. musculares - pro mm. fibulares
- n. cutaneus dorsalis medialis - *nn. digitales dors. ped.*
- n. cutaneus dorsalis intermedius - *nn. digitales dors. ped.*



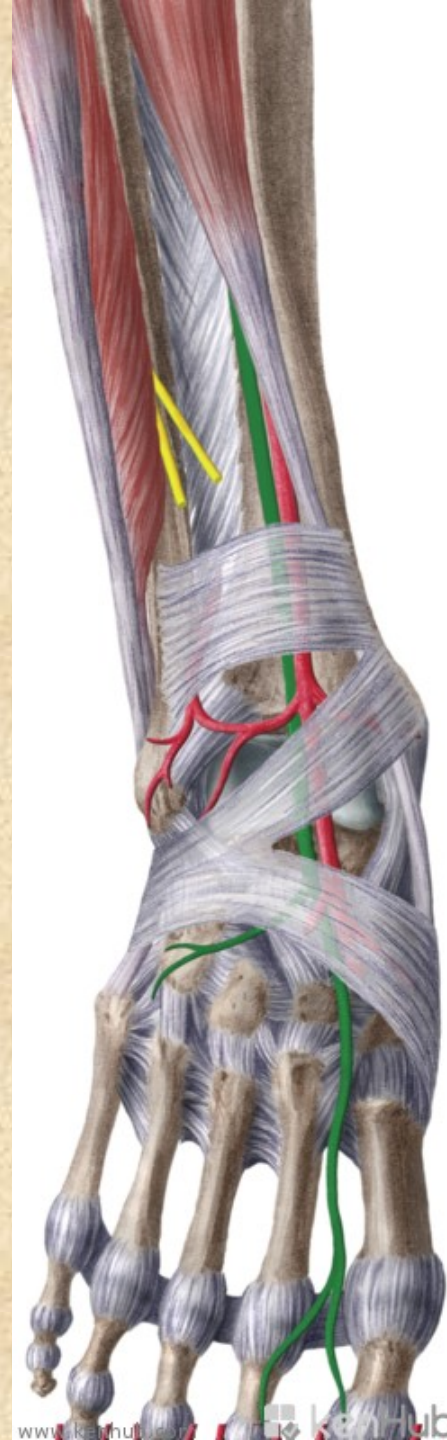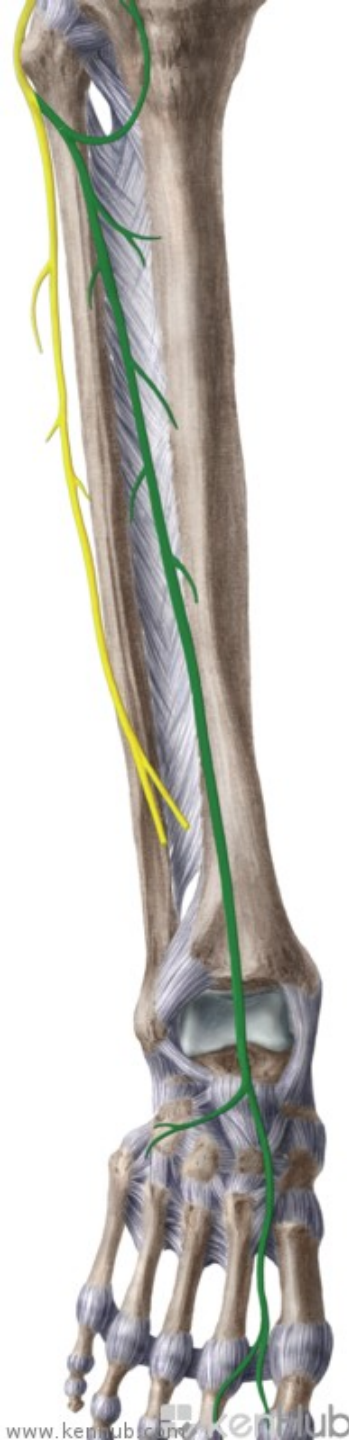




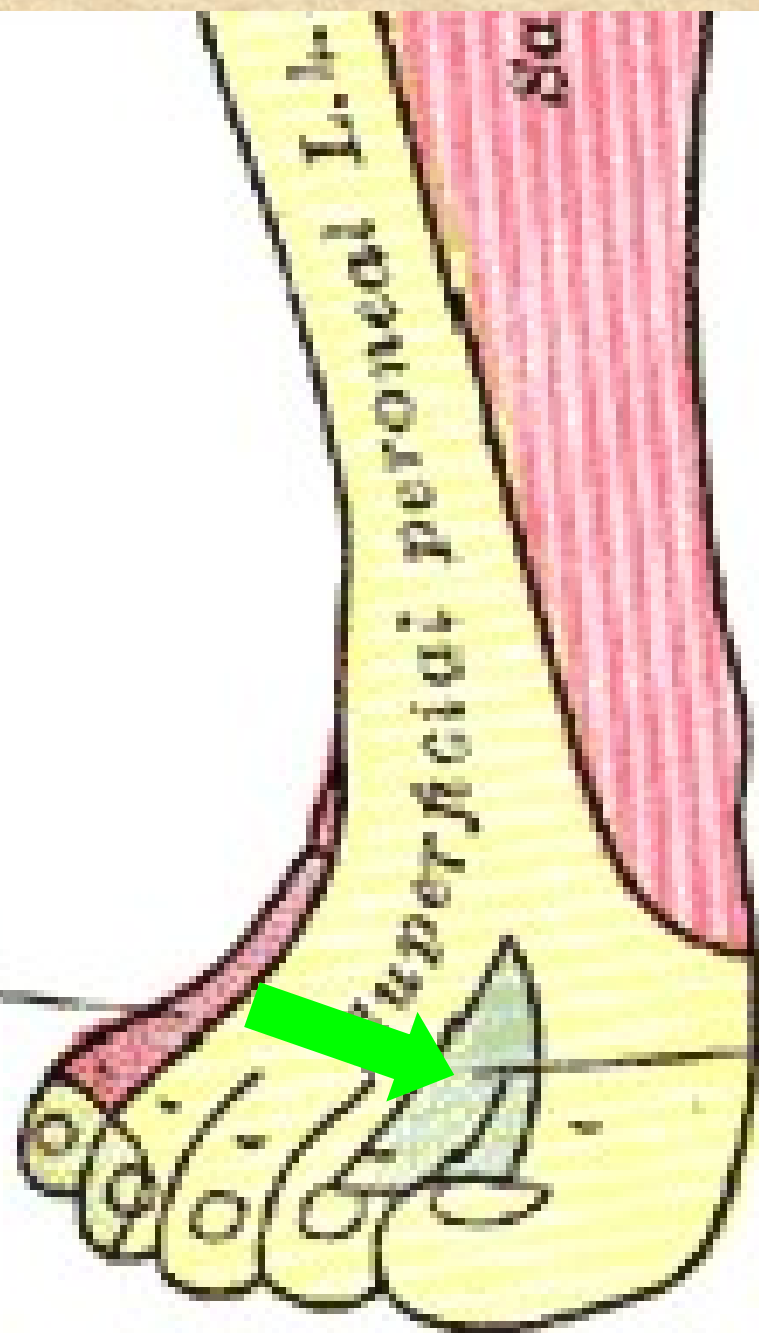
# Nervus fibularis profundus

- n. digitalis dorsalis hallucis lateralis
- n. digitalis dorsalis digiti secundi medialis
- **rr. musculares** pro dlouhé a krátké extenzory






Sural  
S. 1. 2.



Deep  
peroneal  
L. 4. 5.



# Nervus pudendus S1-S5

foramen infrapiriforme (s arterií) obtáčí spina ischiadica → foramen ischiadicum minus → do fossa ischiorectalis → v canalis pudendalis a dosahuje až k symfýze

**nn. rectales inf.** - pro m. sphincter ani ext. a kůži anu

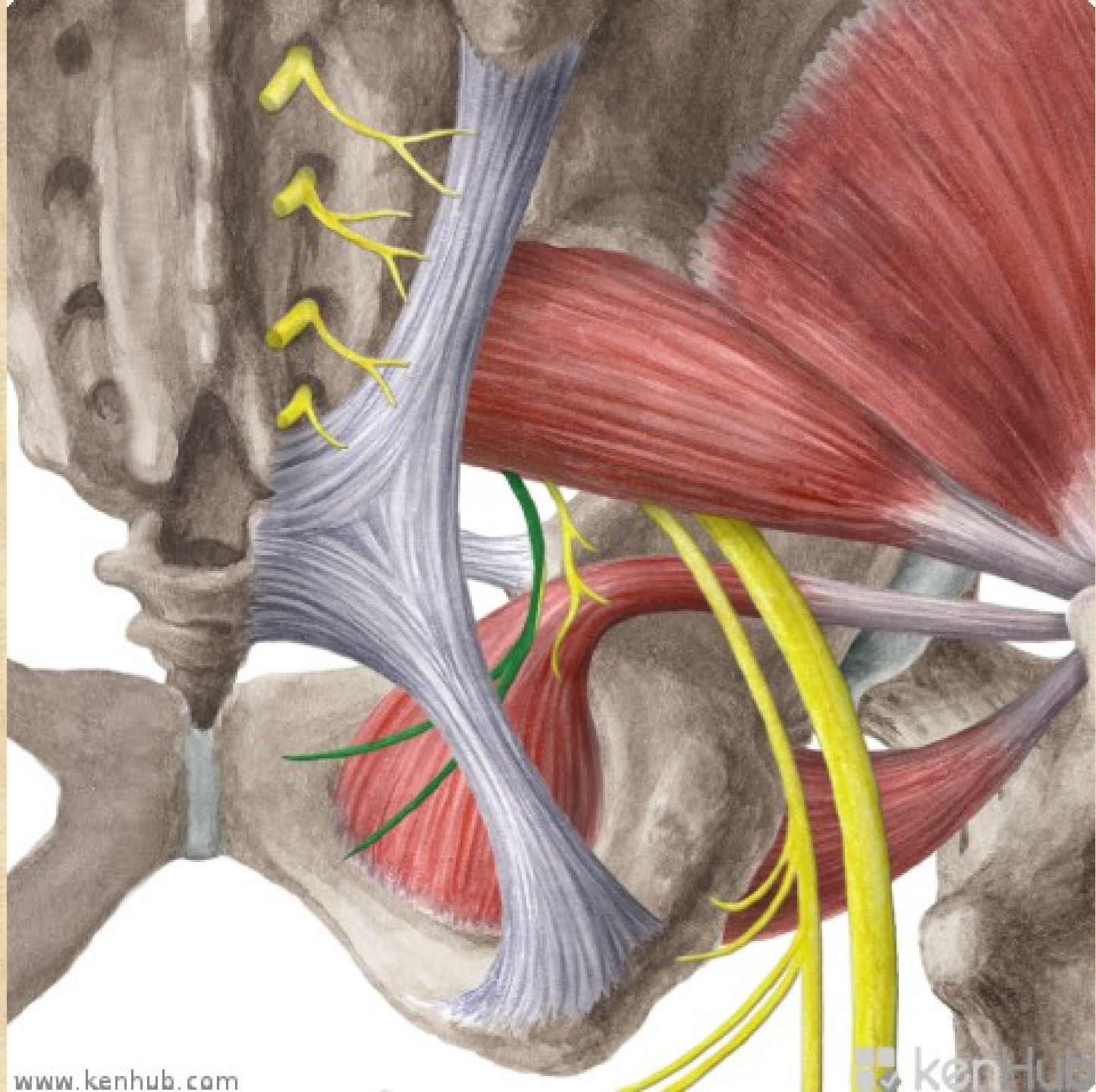
**nn. perineales** - pro kůži hráze a šourku (velkých pysků) - **nn. scrotales (labiales) post.** a pro svaly hráze- m. transversus perinei prof. et superf. , m. bulbospongiosus, m. ischiocavernosus

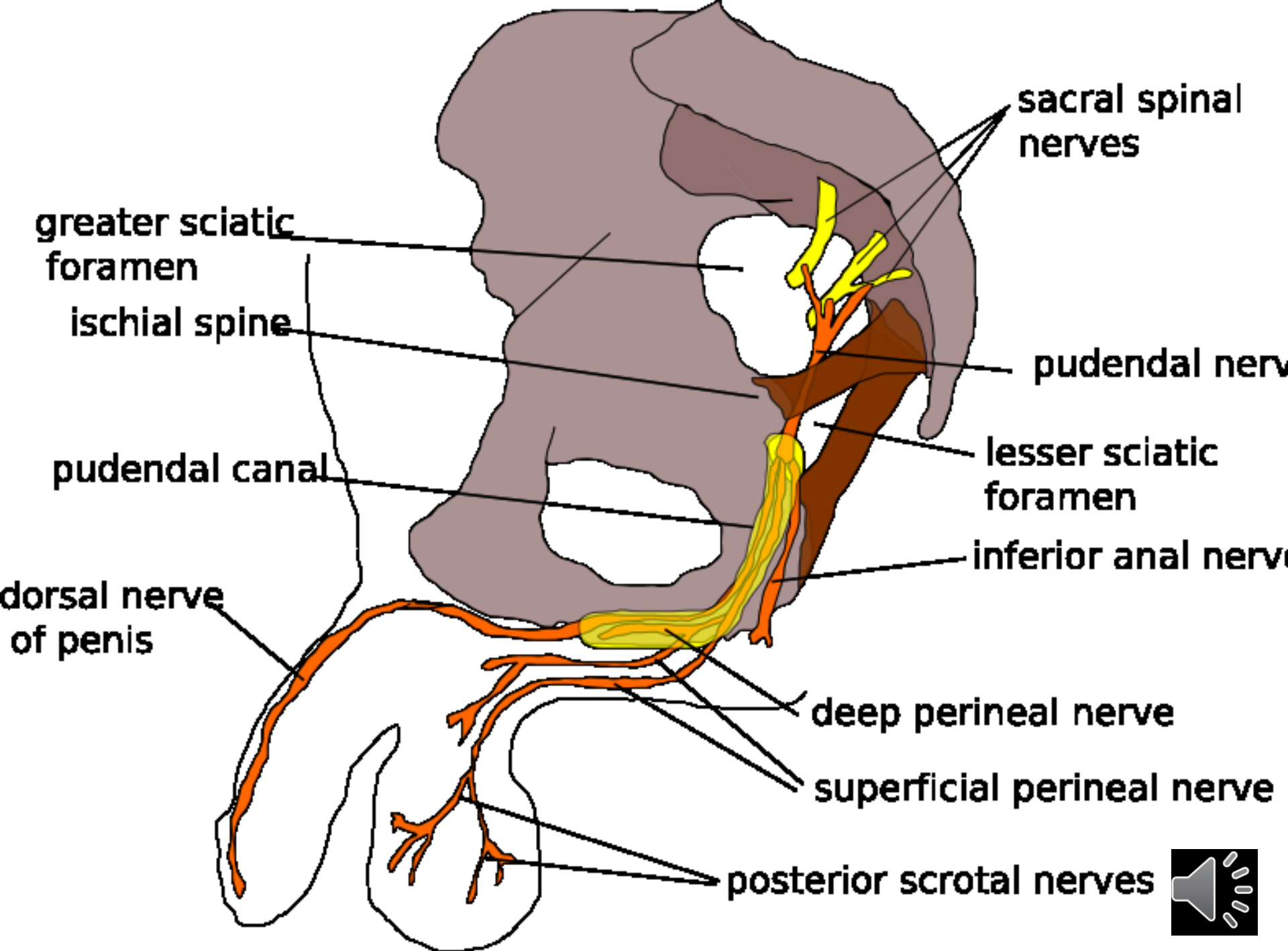
**rr. musculares** - m. levator ani, m. coccygeus

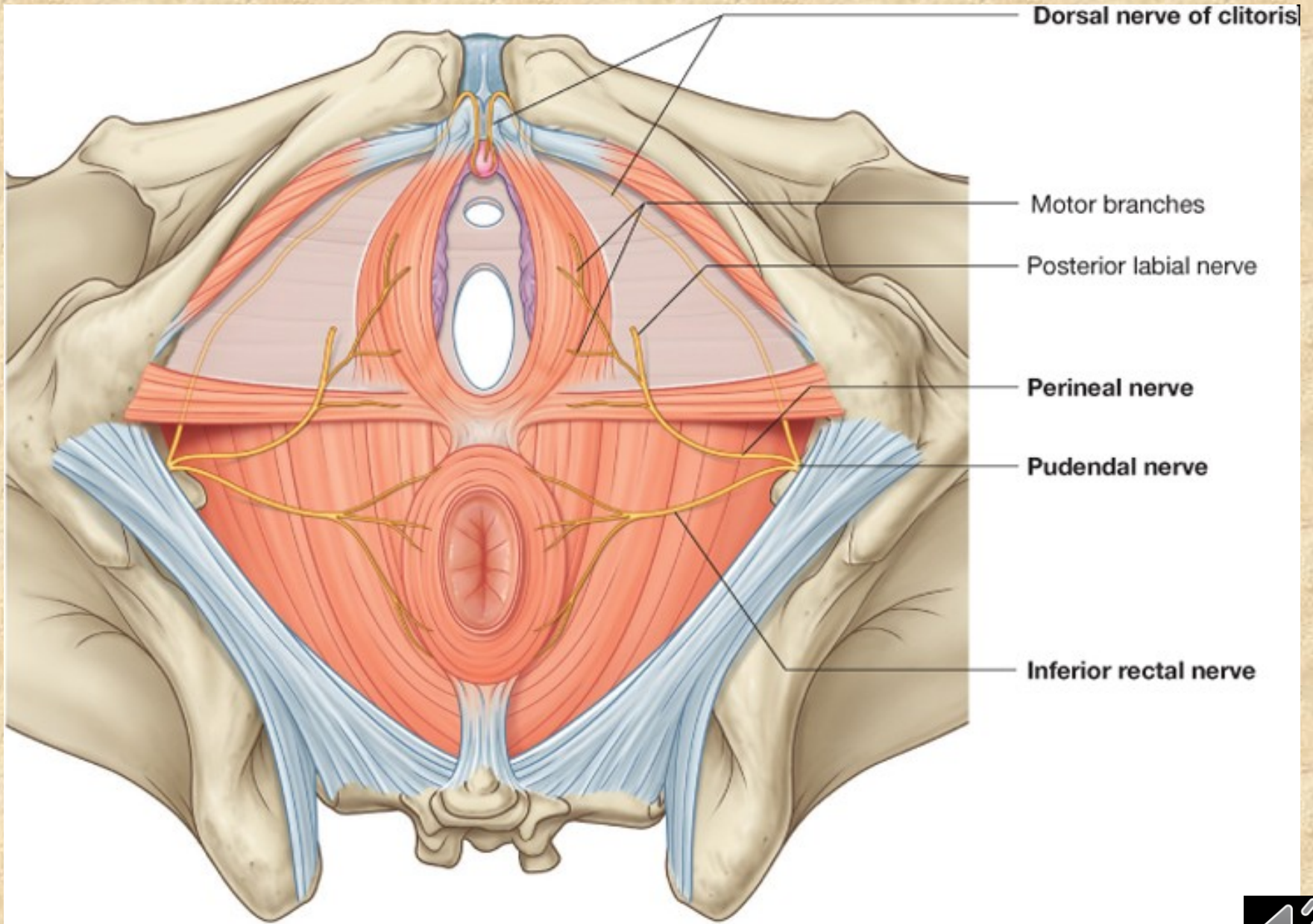
**n. dorsalis penis (clitoridis)** - ke kůži penisu (clitoris) a sliznici močové trubice











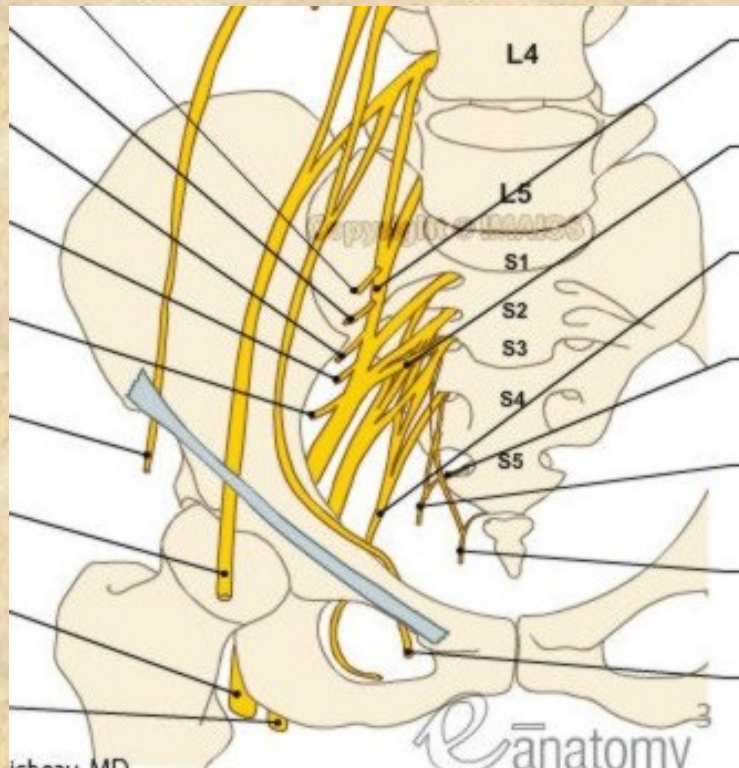
# Plexus coccygeus

Rami ventrales nn. spinalium S4-5, Co

leží na přední ploše m. coccygeus,

**nn. anococcygei** - ke kůži a k zadní části diaphragma pelvis

**rr. musculares** - m. levator ani, m. coccygeus



- **Obrázky:**
- **Atlas der Anatomie des Menschen/Sobotta. Putz,R., und Pabst,R. 20. Auflage. München:Urban & Schwarzenberg, 1993**
- **Netter: Interactive Atlas of Human Anatomy.**
- **Naňka, Elišková: Přehled anatomie. Galén, Praha 2009.**
- **Čihák: Anatomie I, II, III.**
- **Drake et al: Gray's Anatomy for Students. 2010**



• **DĚKUJI ZA POZORNOST!**

