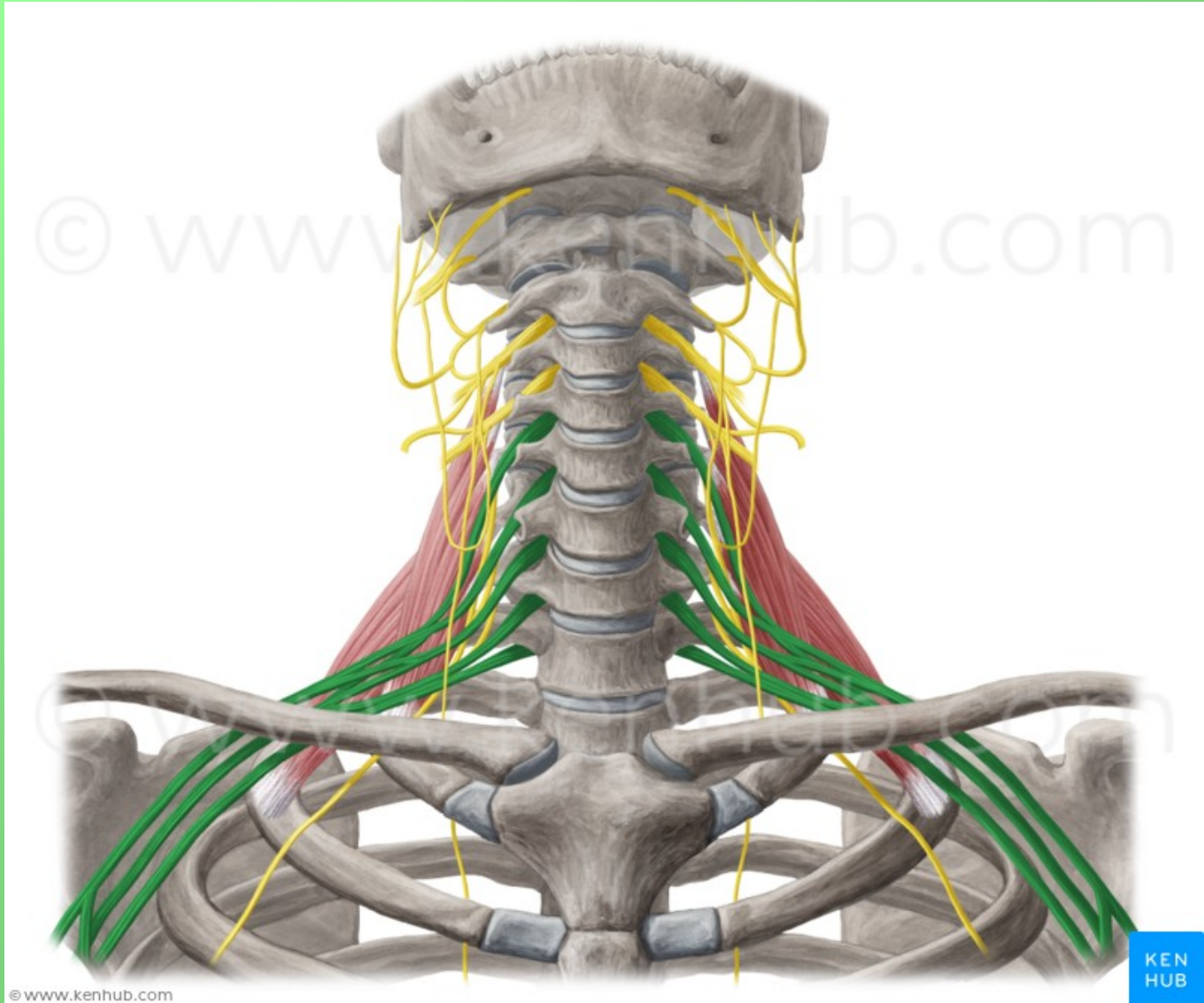
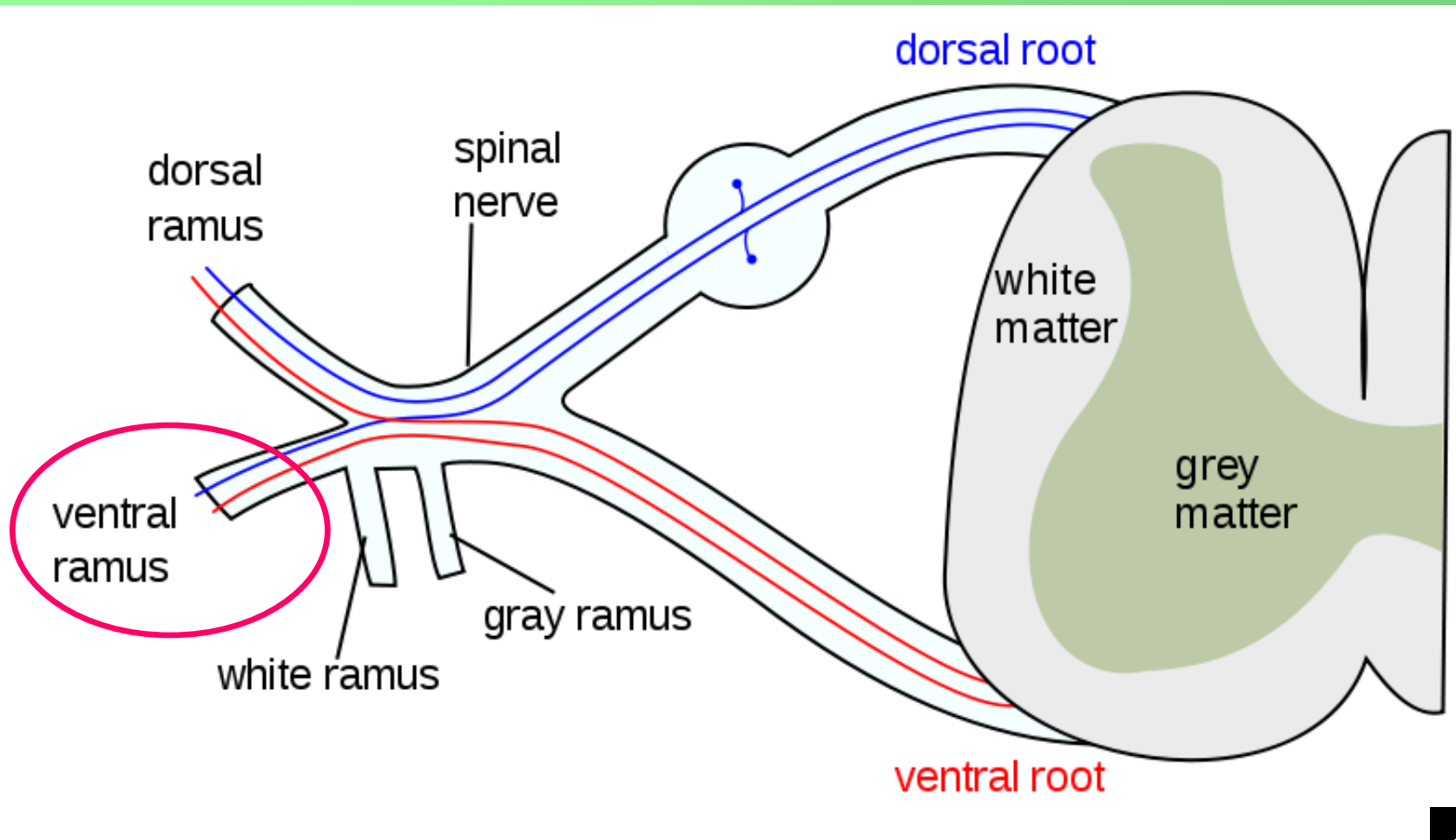


# PLEXUS BRACHIALIS



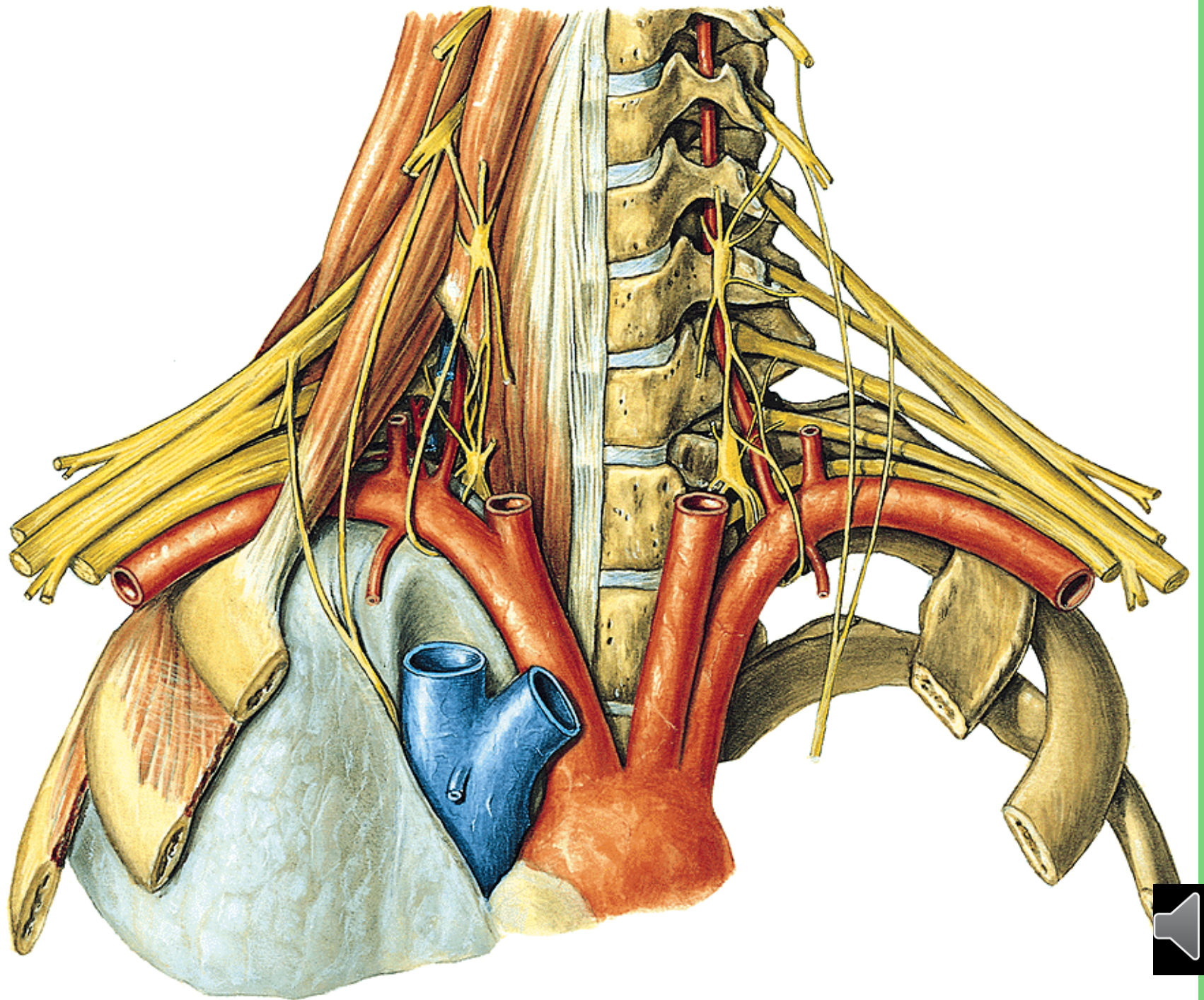
# Nervus spinalis



# Plexus brachialis (C4-Th1)

- ve fissura scalenorum
- senzoricky kůži na horní končetině
- motoricky svaly horní končetiny a také heterochtonní svaly zad a hrudníku





# Plexus brachialis (C4-Th1)

Primární svazky:

Truncus superior (C4) C5+6

Truncus medius C7

Truncus inferior C8+Th1

Sekundární svazky:

**Fasciculus posterior:** spojení všech dorzálních větví

**Fasciculus lateralis:** spojení ventrálních větví truncus superior a medius

**Fasciculus medialis:** ventrální větev truncus inferior

Oddělení jednotlivých nervových kmenů z fascikulů:

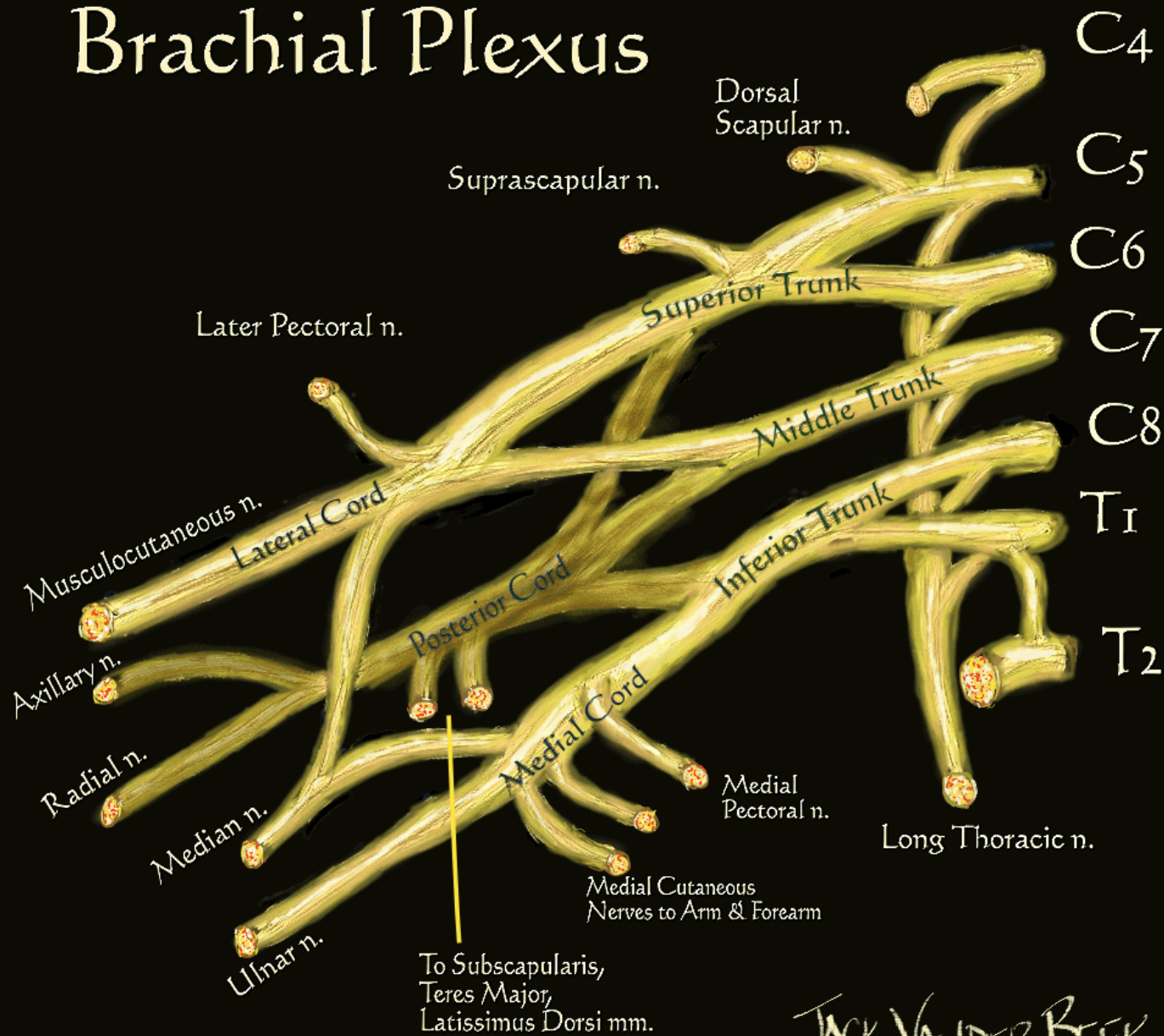
**FP:** n. radialis, n. axillaris

**FL:** n. musculocutaneus + část n. medianus

**FM:** n. ulnaris + část n. medianus



# Brachial Plexus



JACK VANDER BEEK  
 (c) 2005 neuraxiom.com



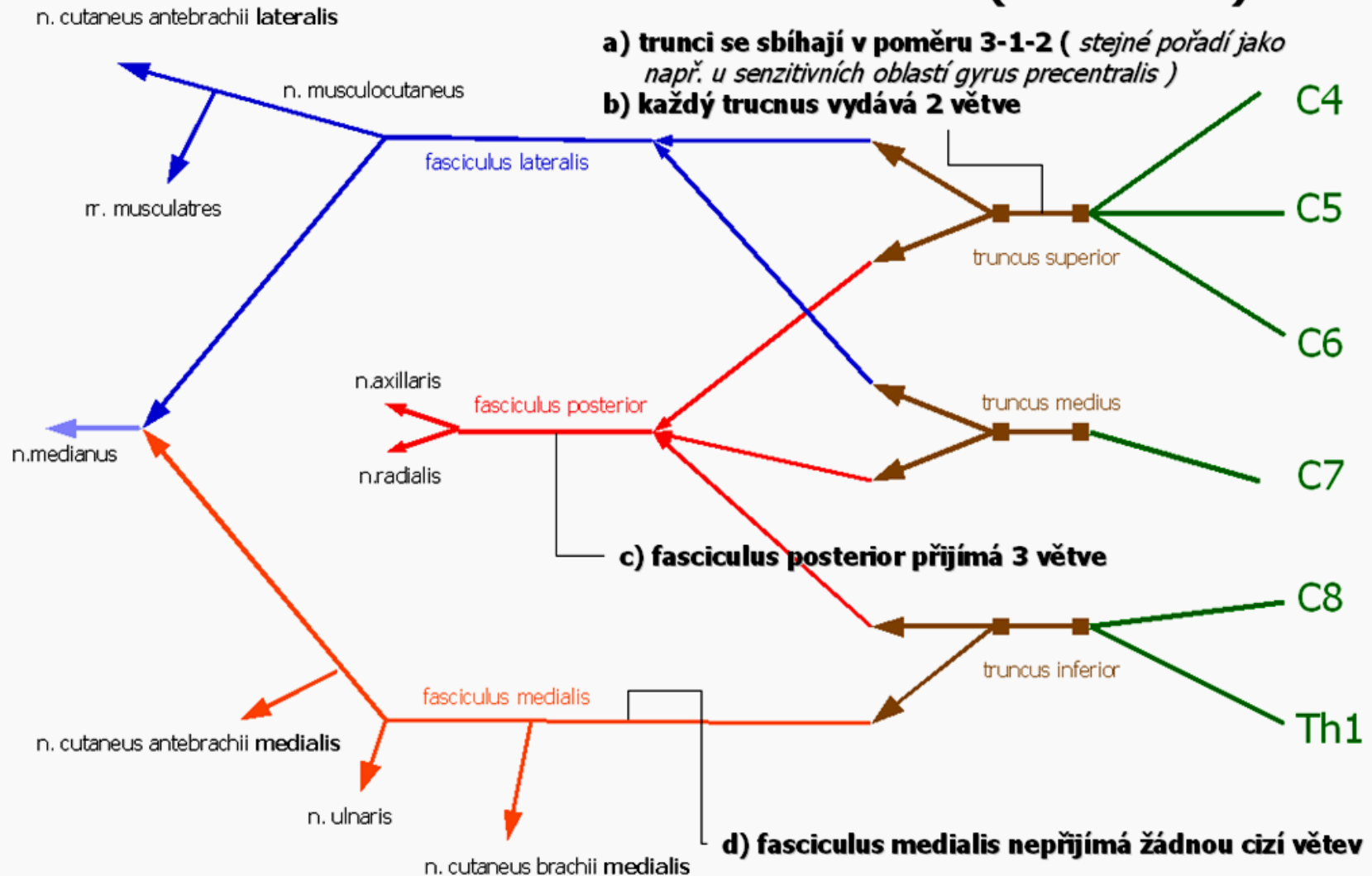
# Plexus brachialis ( C4 – Th1 )

a) trunci se sbíhají v poměru 3-1-2 ( stejné pořadí jako např. u senzitivních oblastí gyrus precentralis )

b) každý truncus vydává 2 větve

c) fasciculus posterior přijímá 3 větve

d) fasciculus medialis nepřijímá žádnou cizí větev

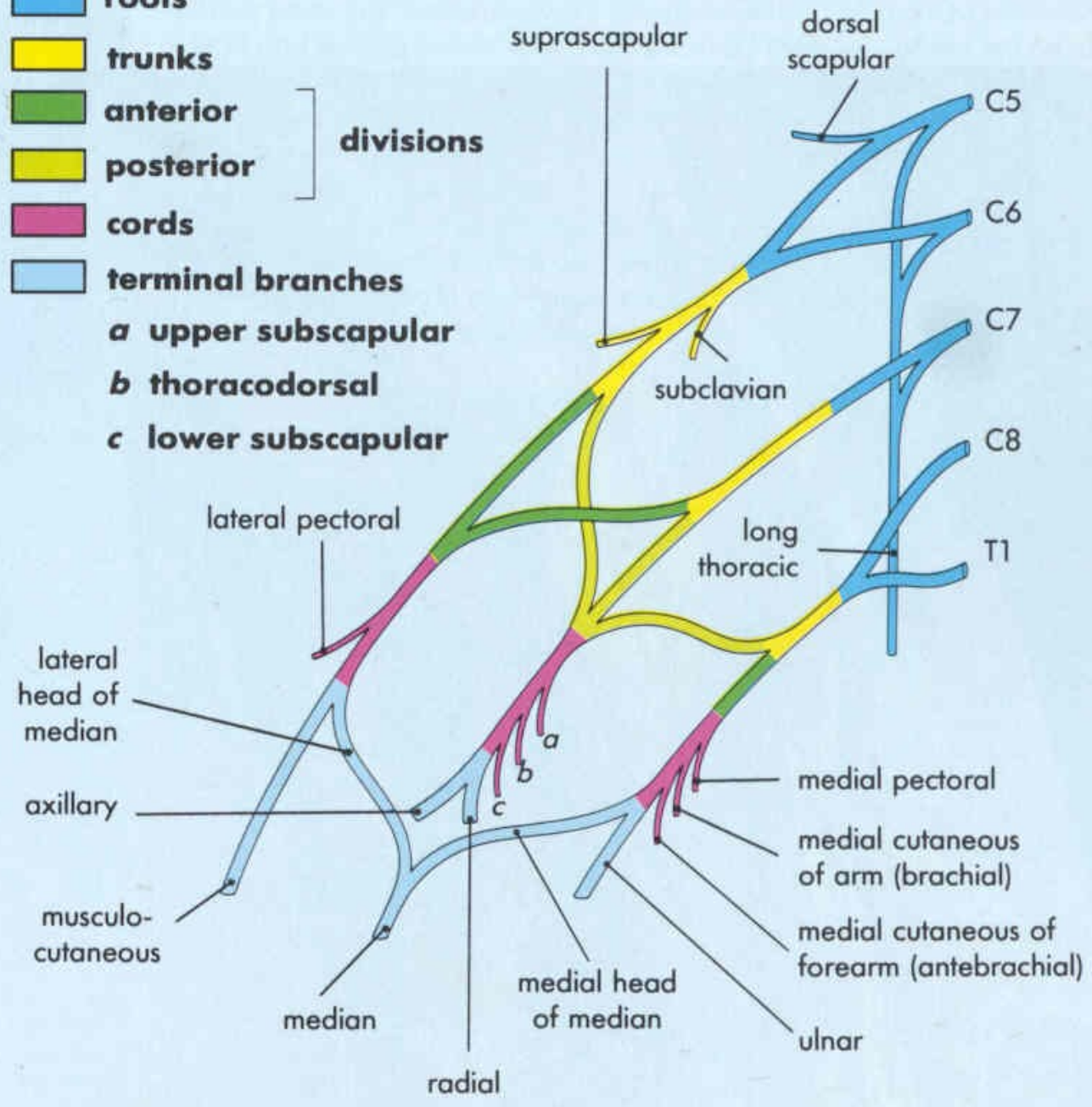


Důsledek: v jednom nervovém kmene jsou obsaženy axony z více segmentů - při porušení kořene obrna více svalů



- roots**
- trunks**
- anterior**
- posterior**
- divisions**
- cords**
- terminal branches**

- a** upper subscapular
- b** thoracodorsal
- c** lower subscapular



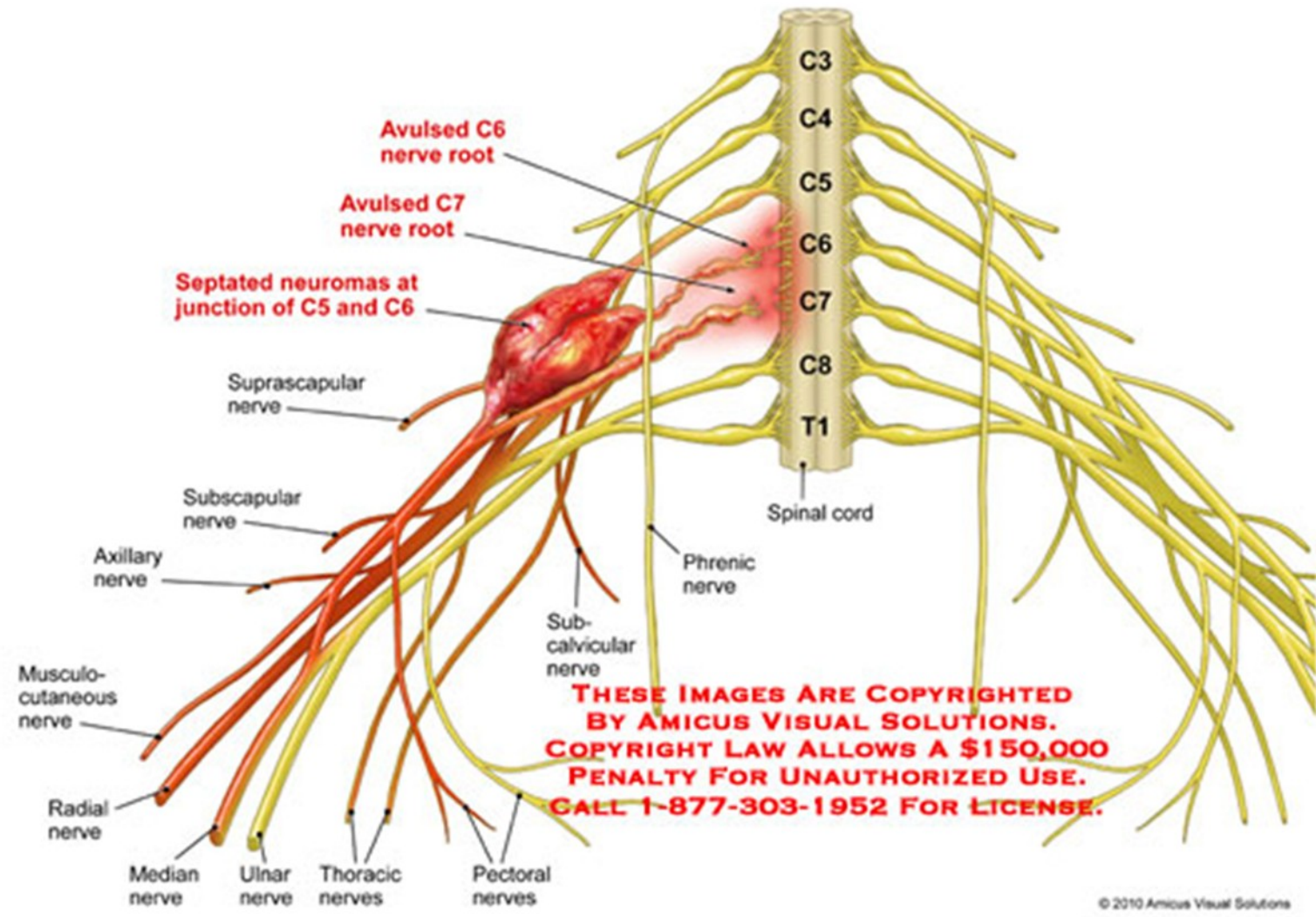


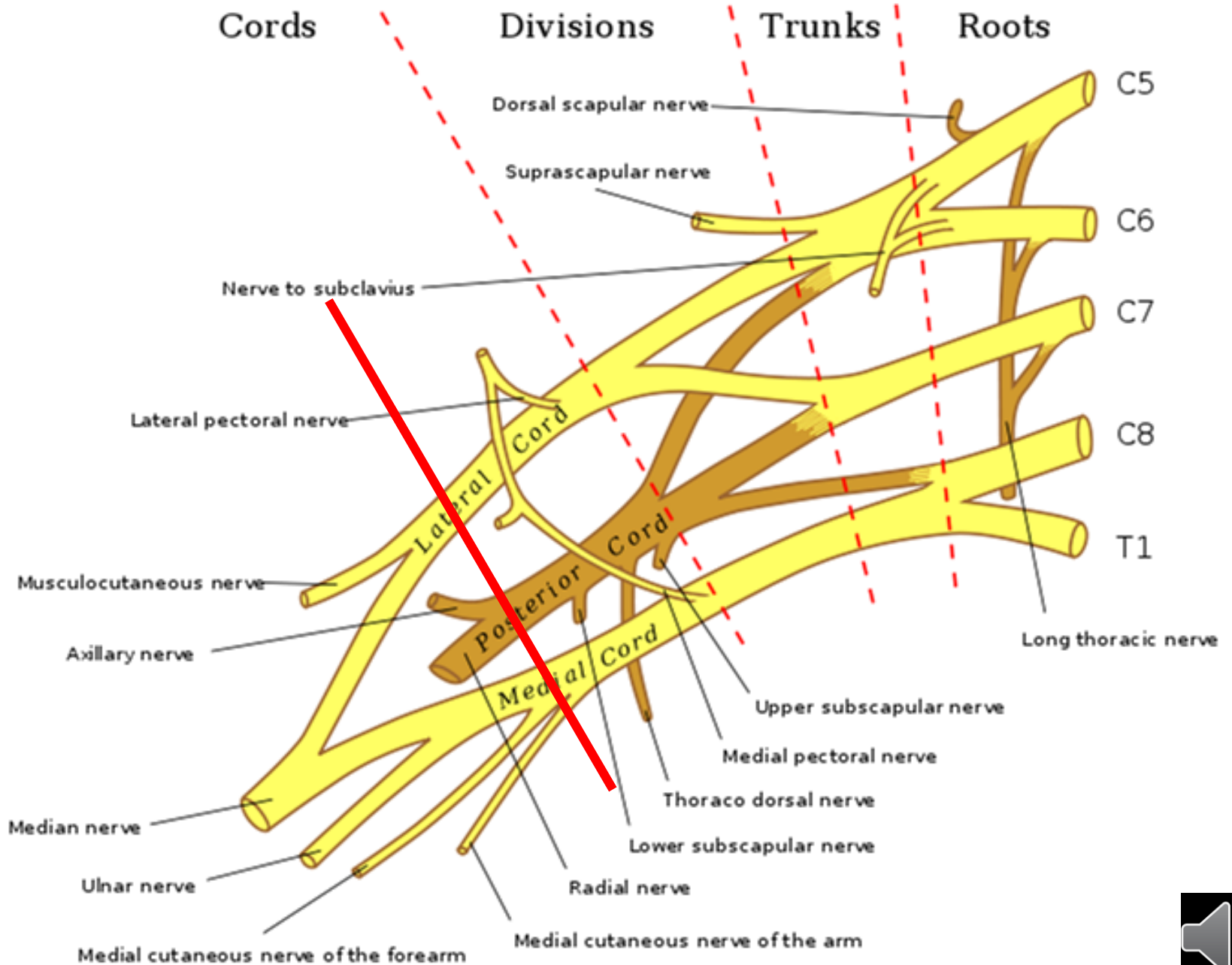
• skalenový syndrom (fissura scalenorum)

- sy
- av

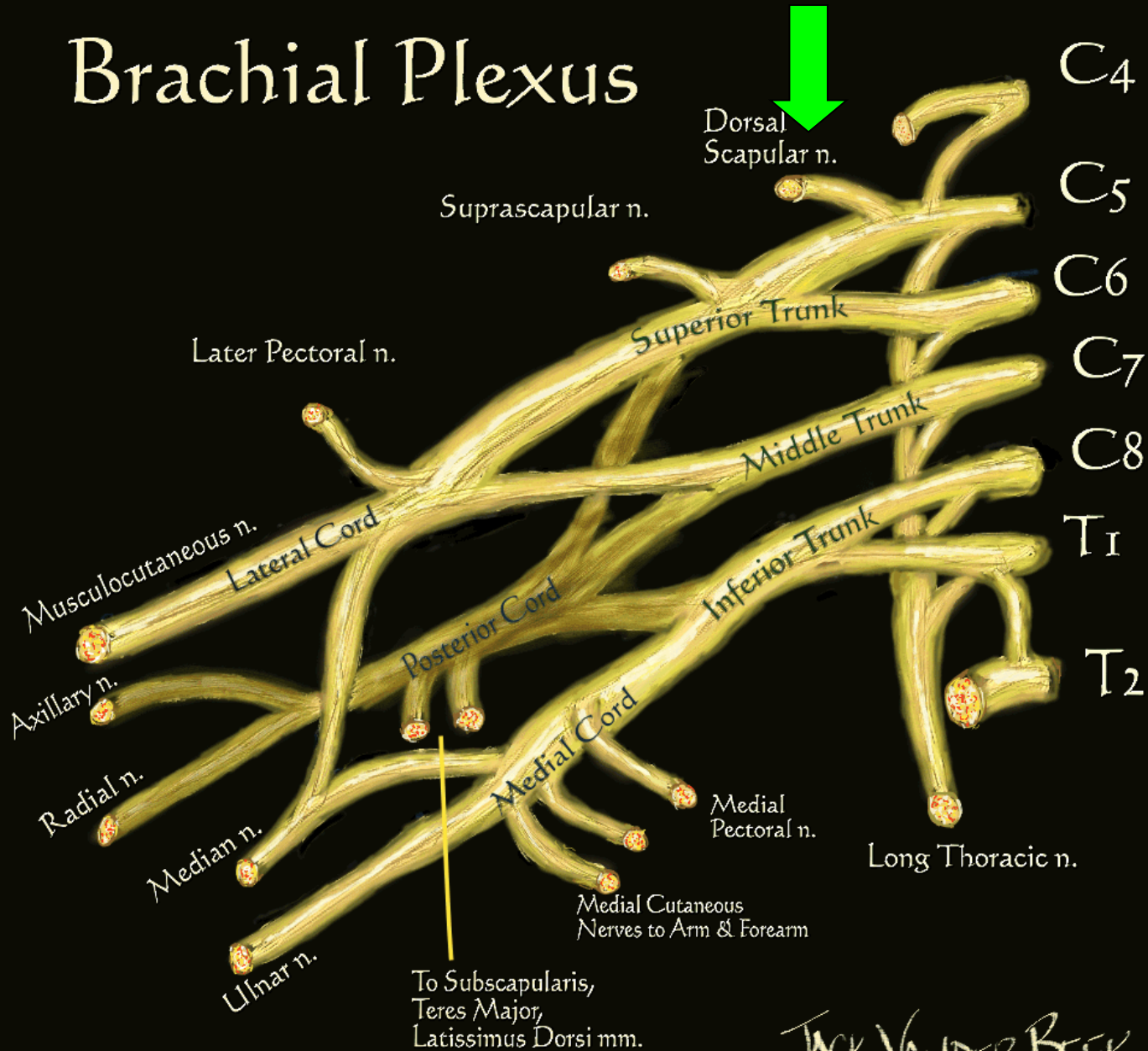
ula)

██████████'s Brachial Plexus Injuries



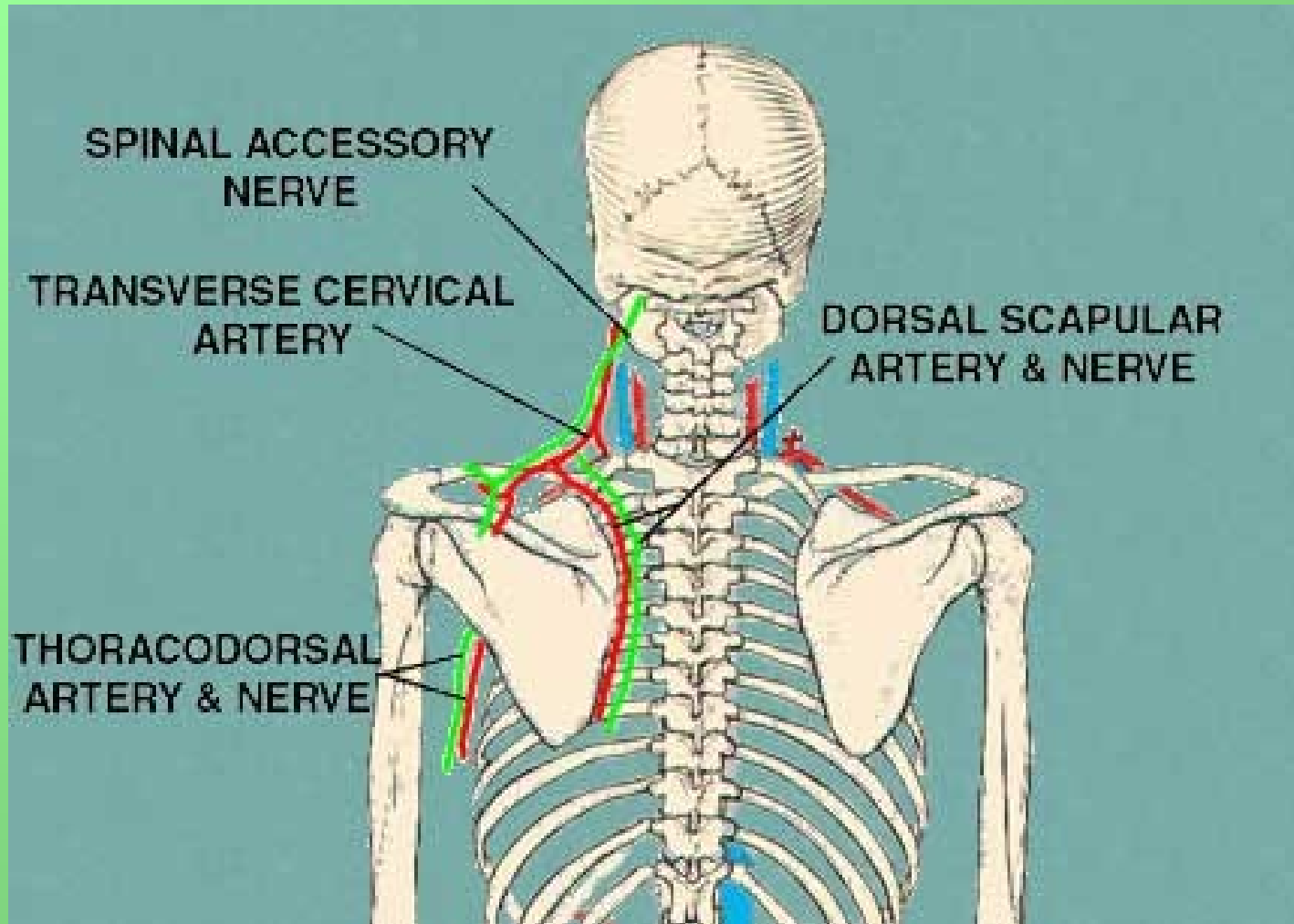


# Brachial Plexus



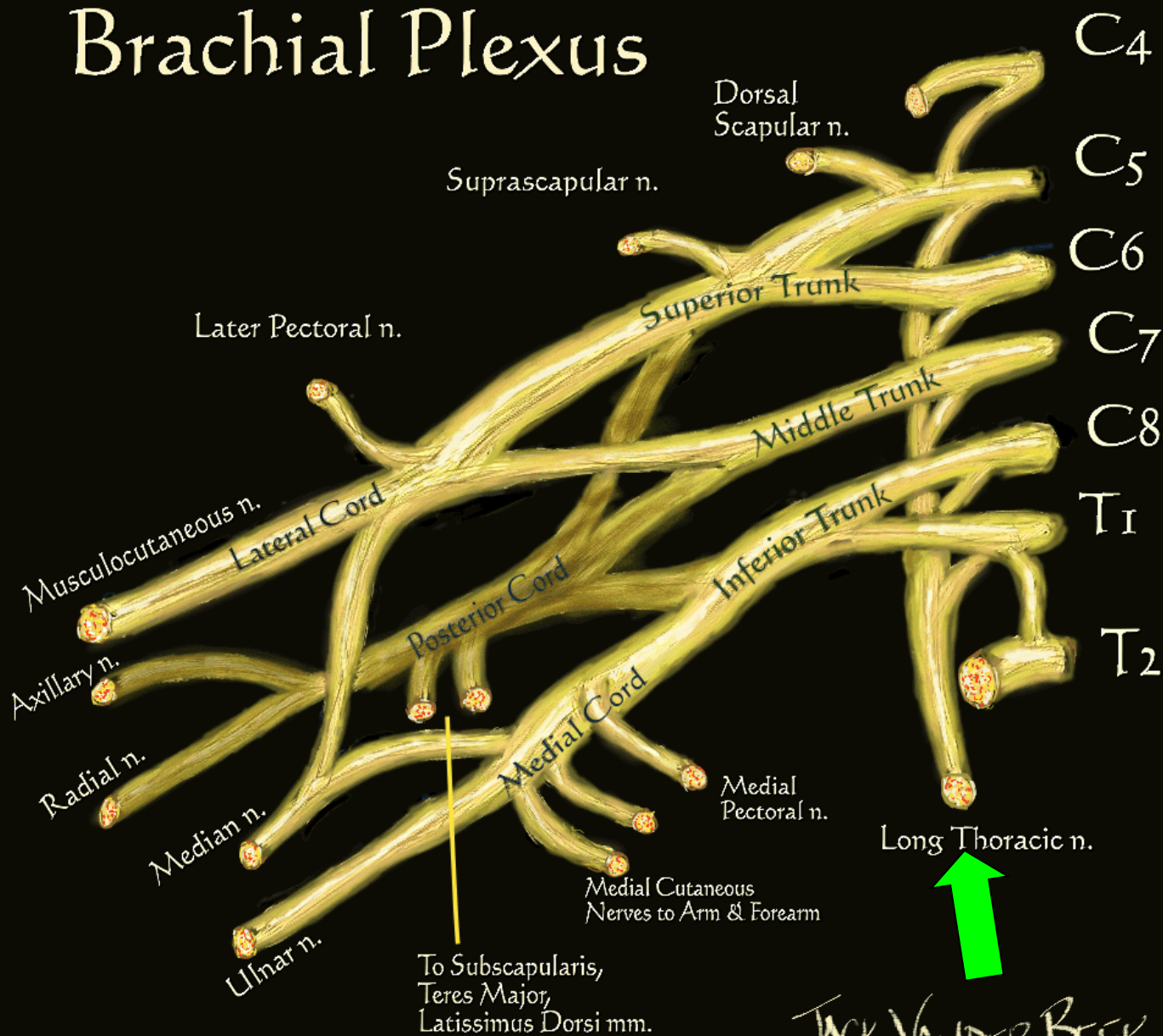
JACK VANDER BEEK  
 (c) 2005 neuraxiom.com





# Brachial Plexus

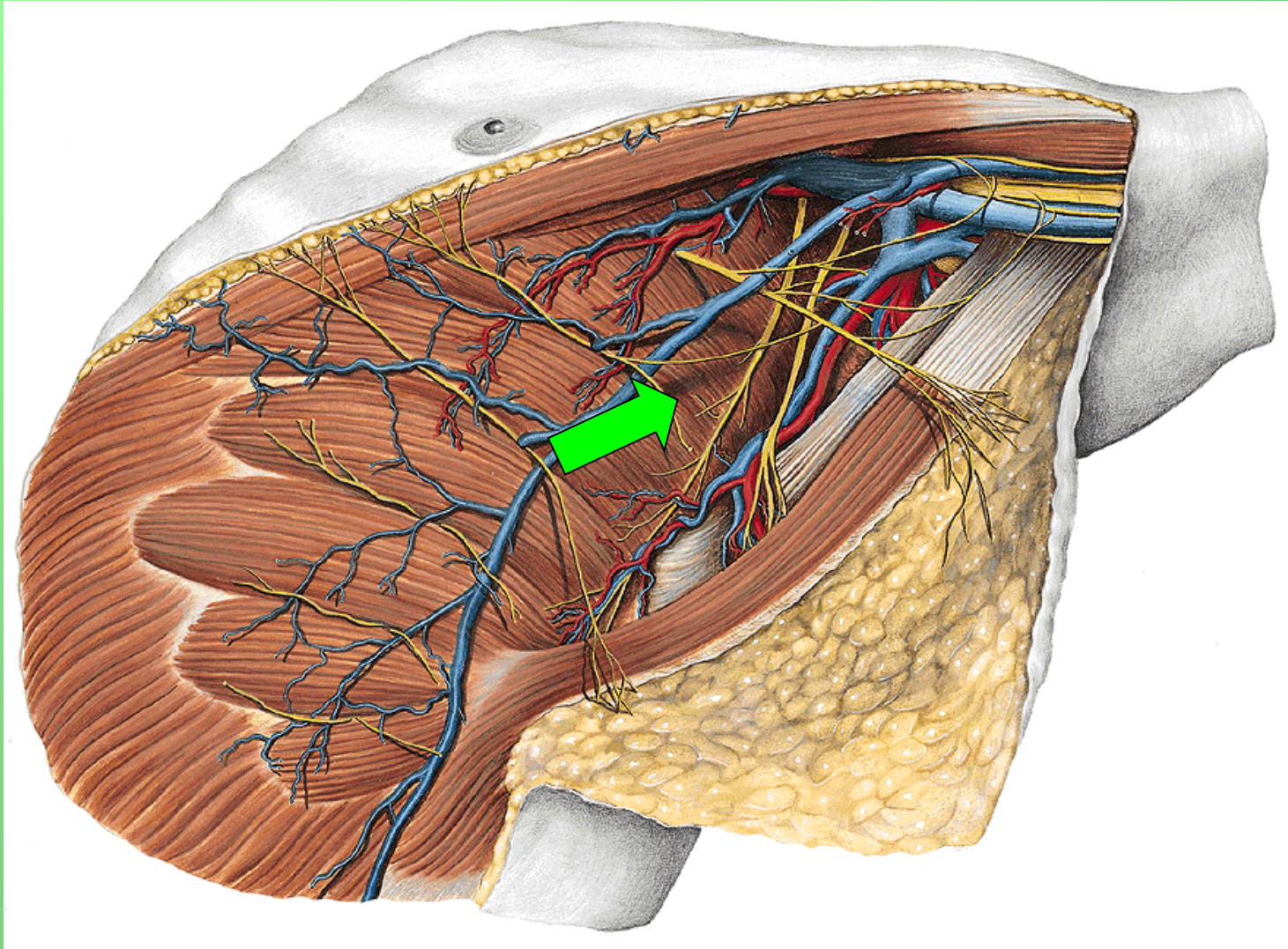
• m



JACK VANDER BEEK  
(c) 2005 neuraxiom.com

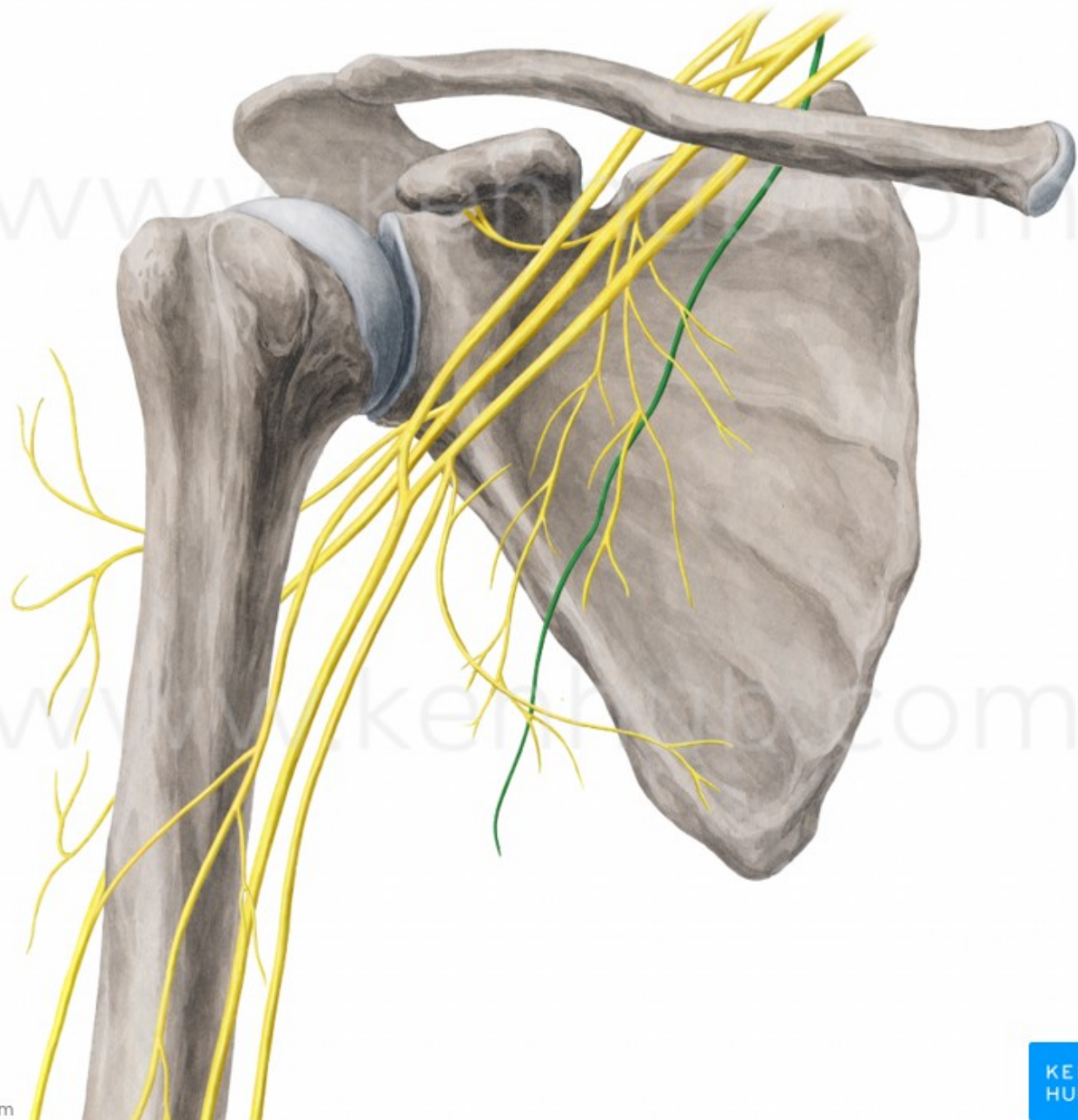


# nervus thoracicus longus (C5-7)



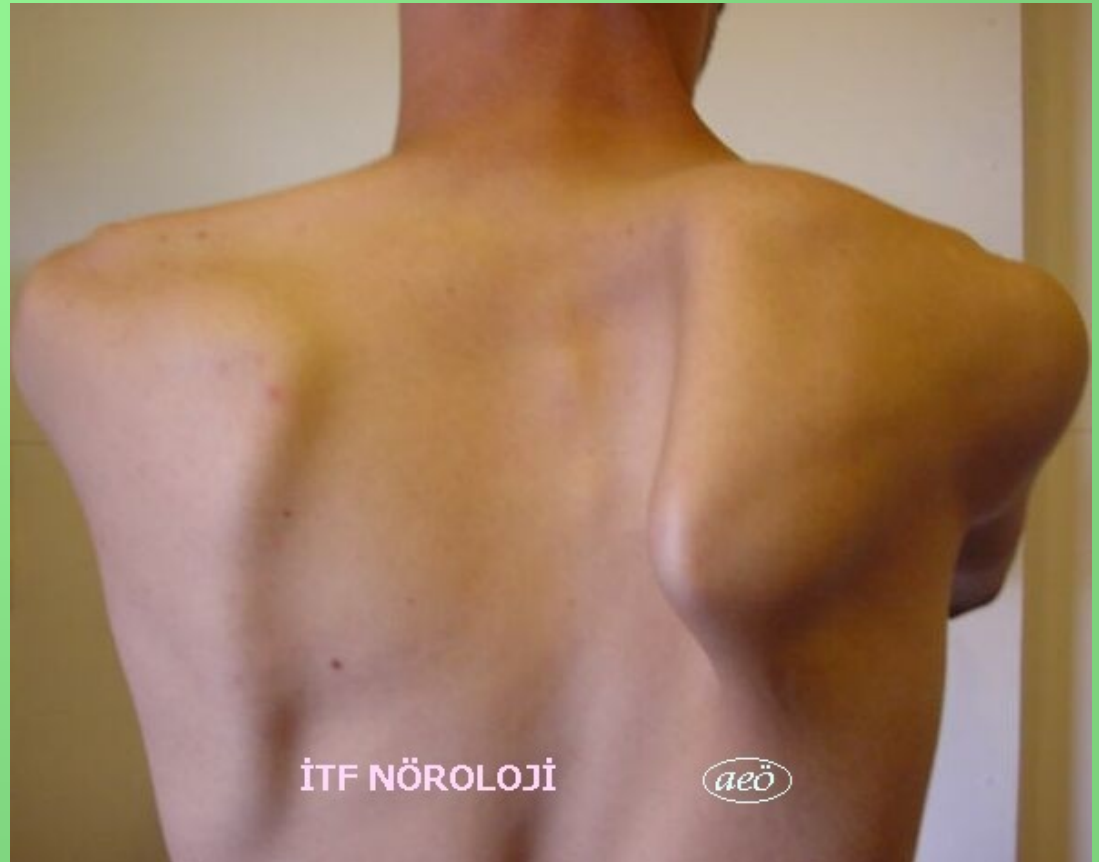© www.kenhub.com

© www.kenhub.com



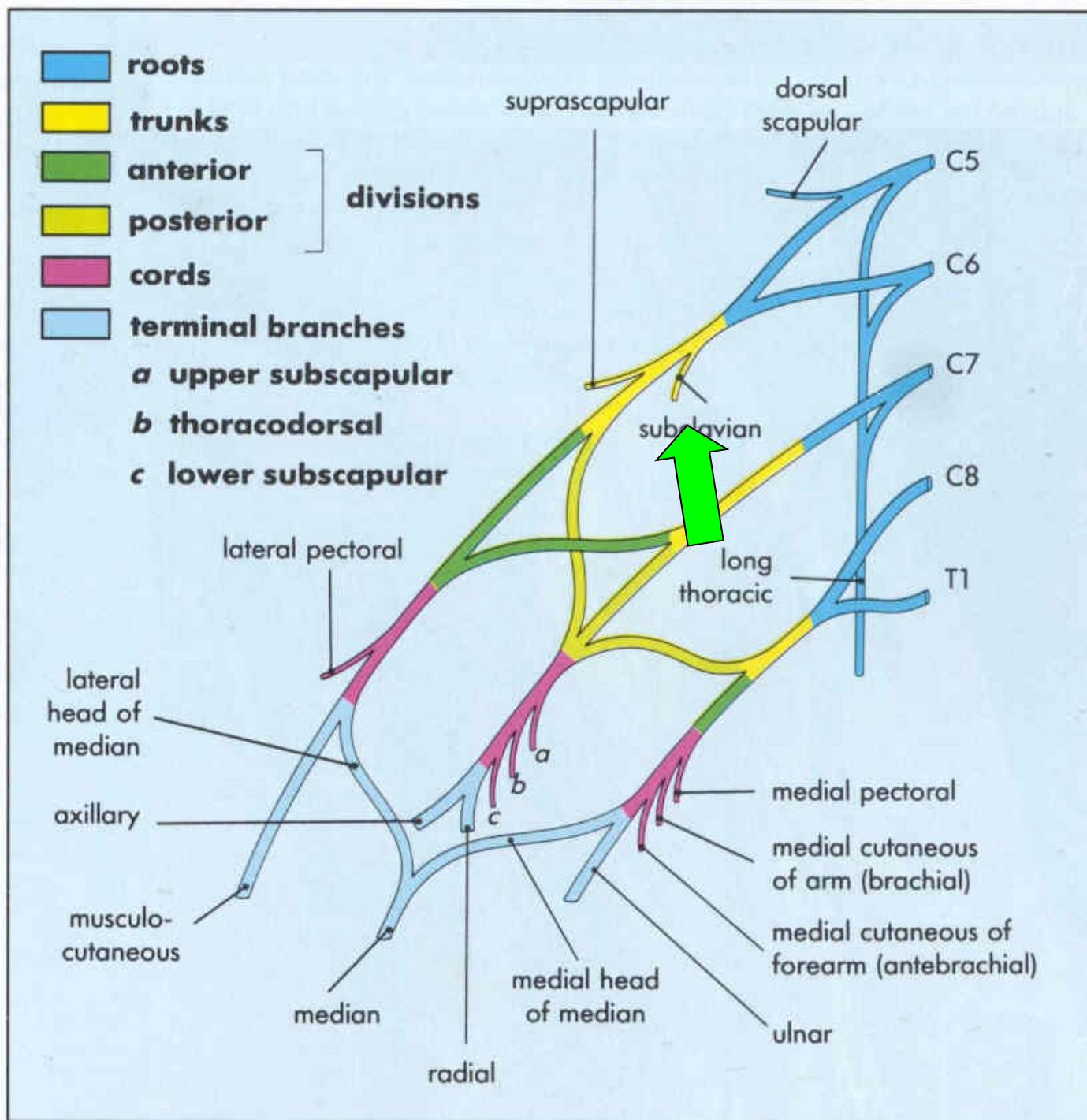
# nervus thoracicus longus (C5-7)

- scapula alata



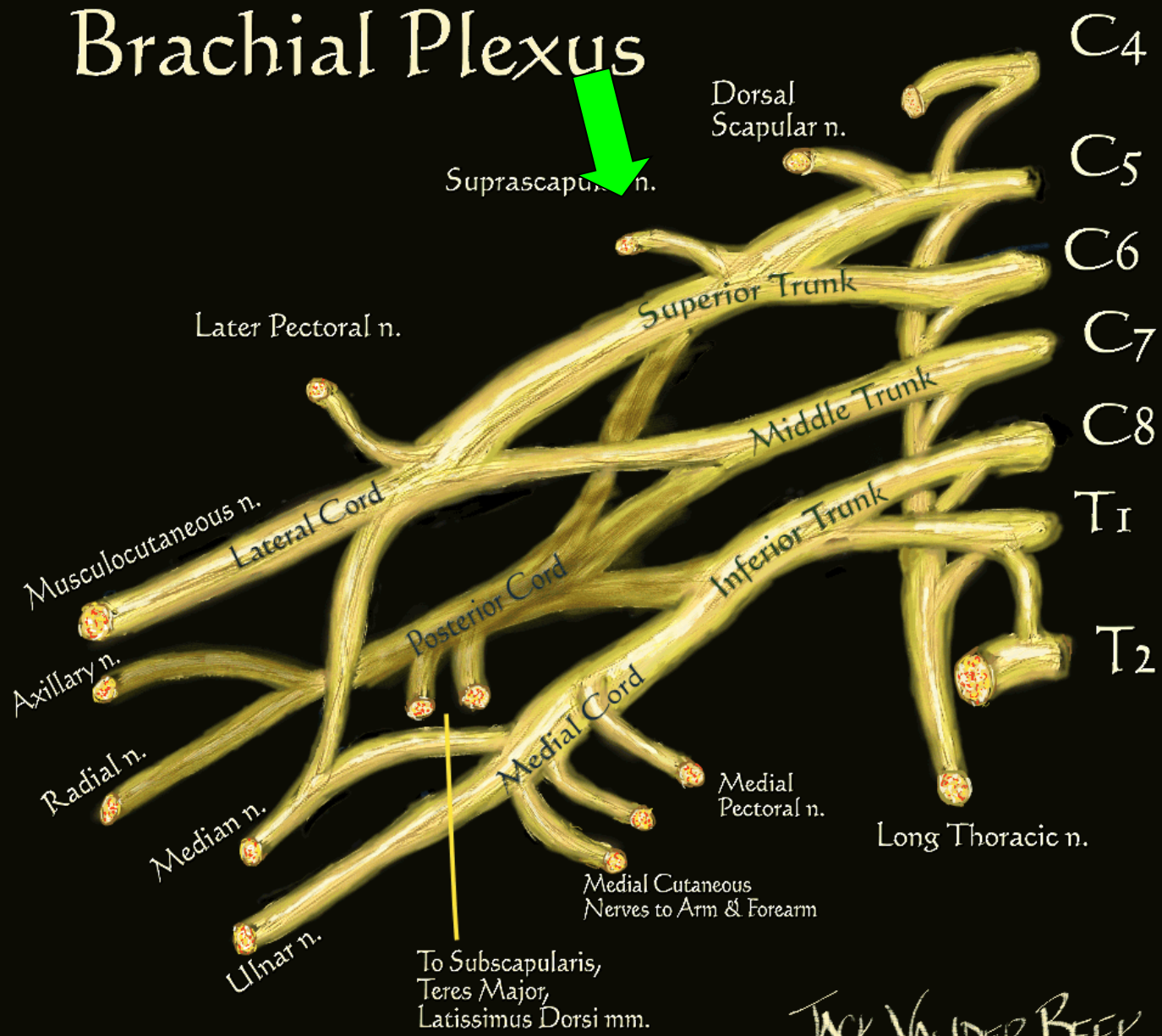


• m



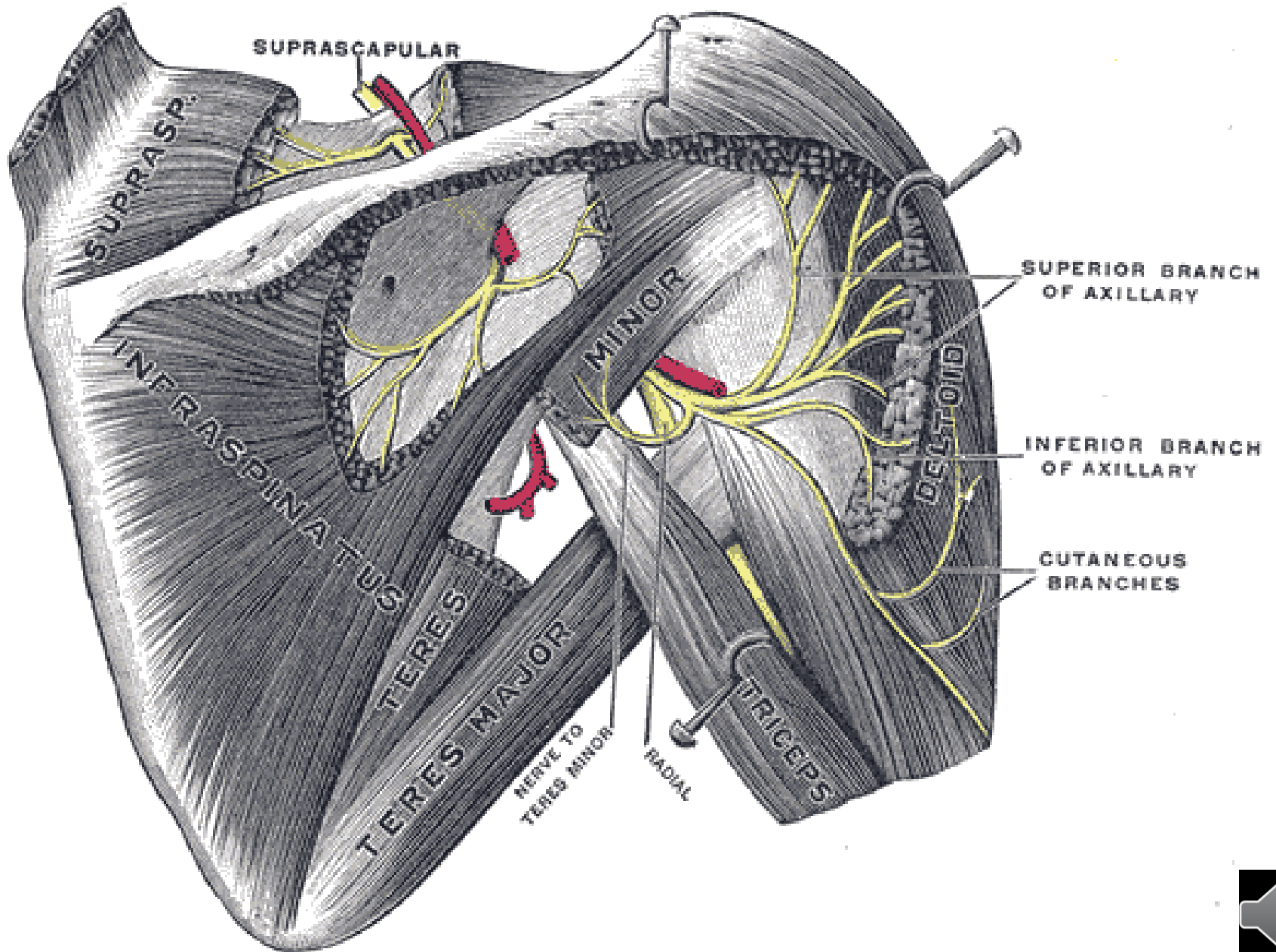
# ne Brachial Plexus

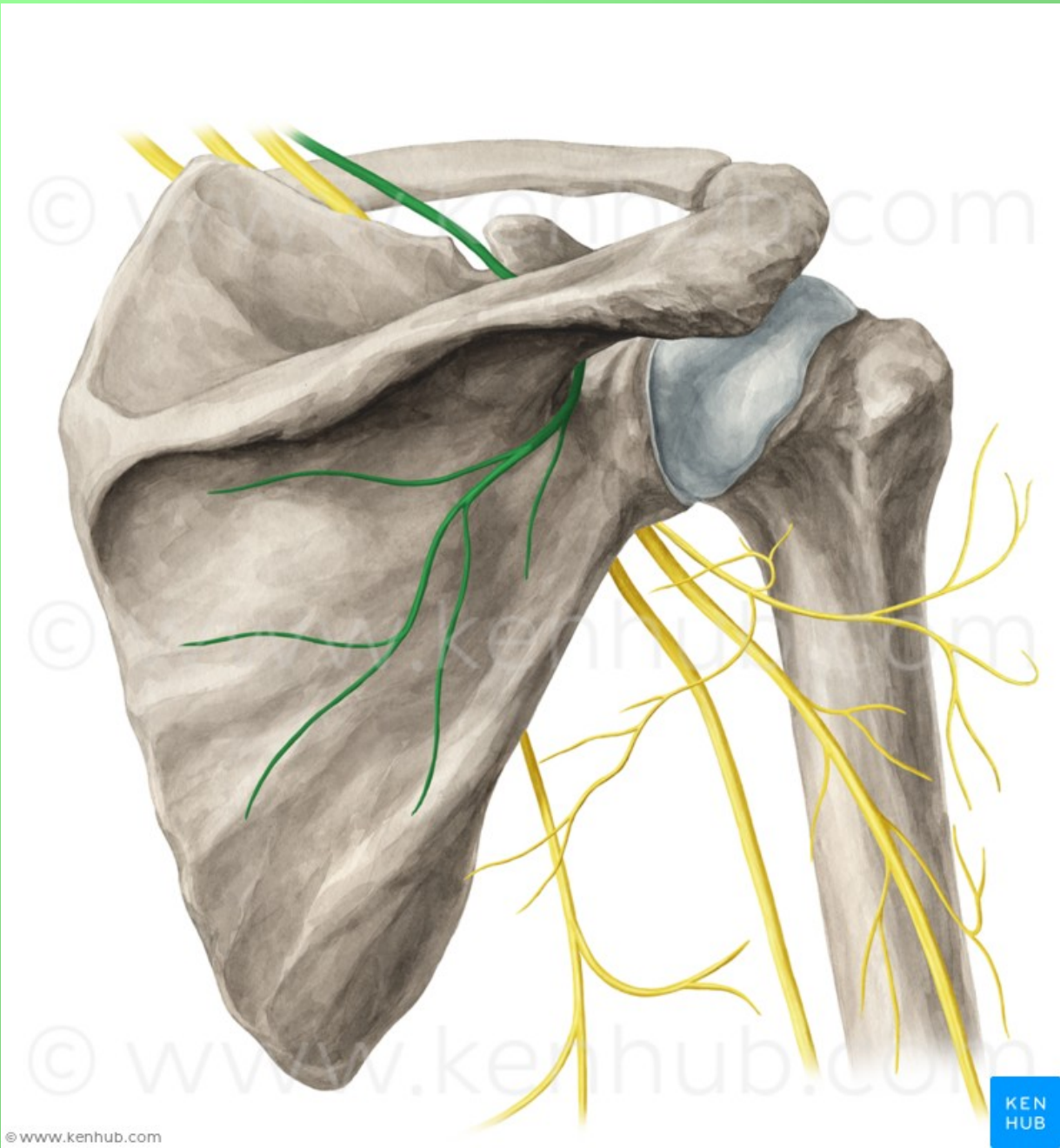
- m
- s



6)

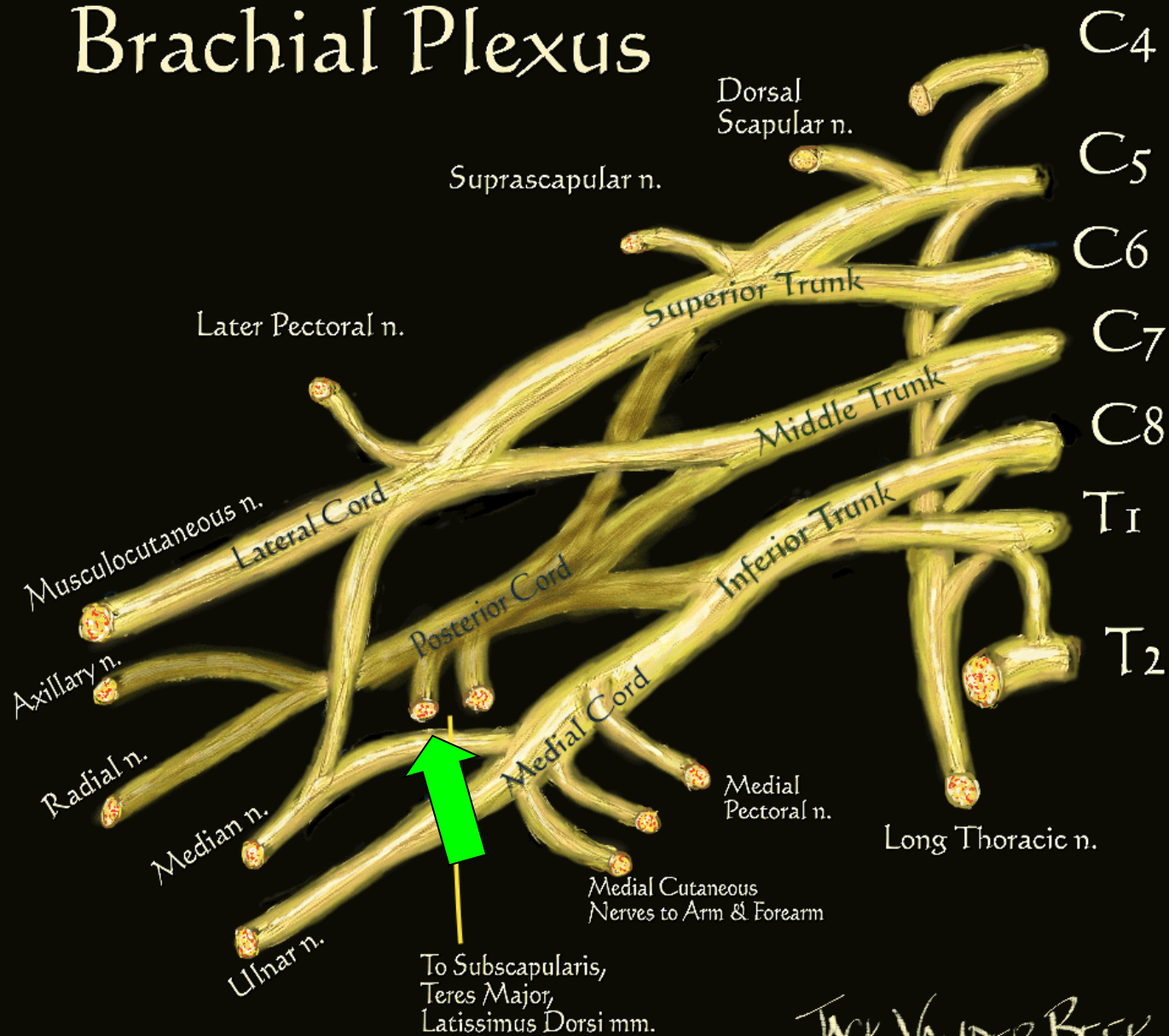






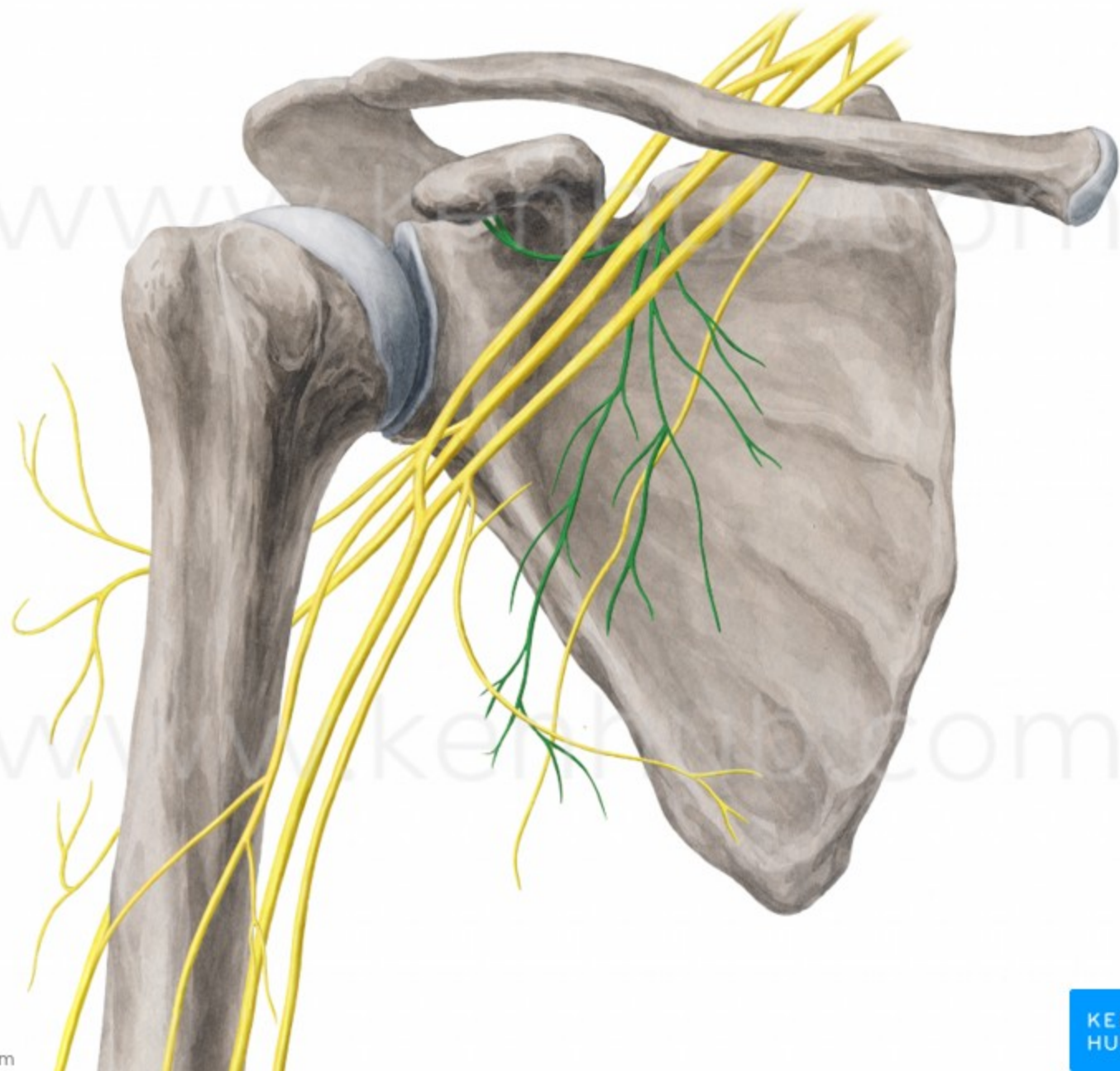
# Brachial Plexus

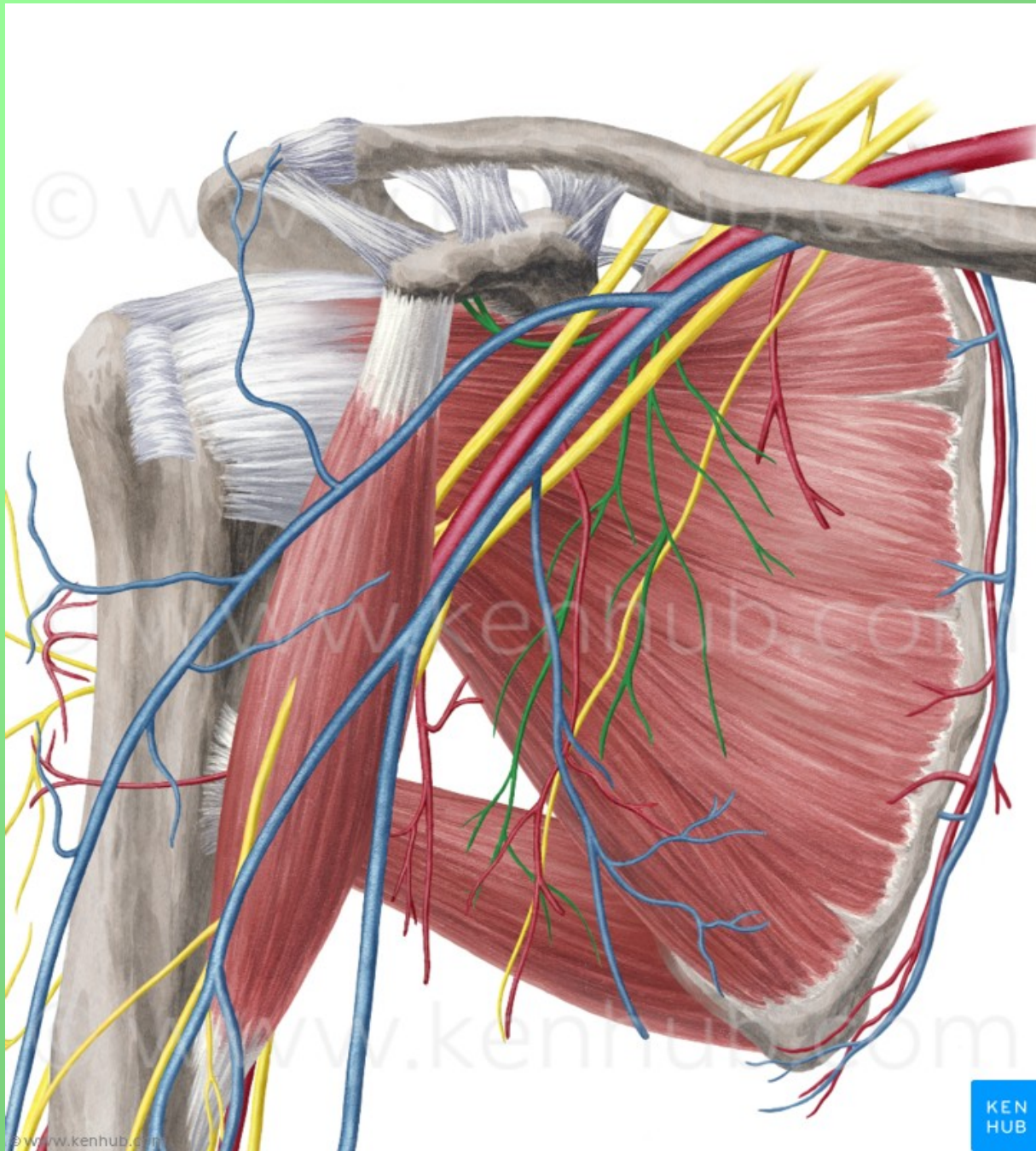
• m



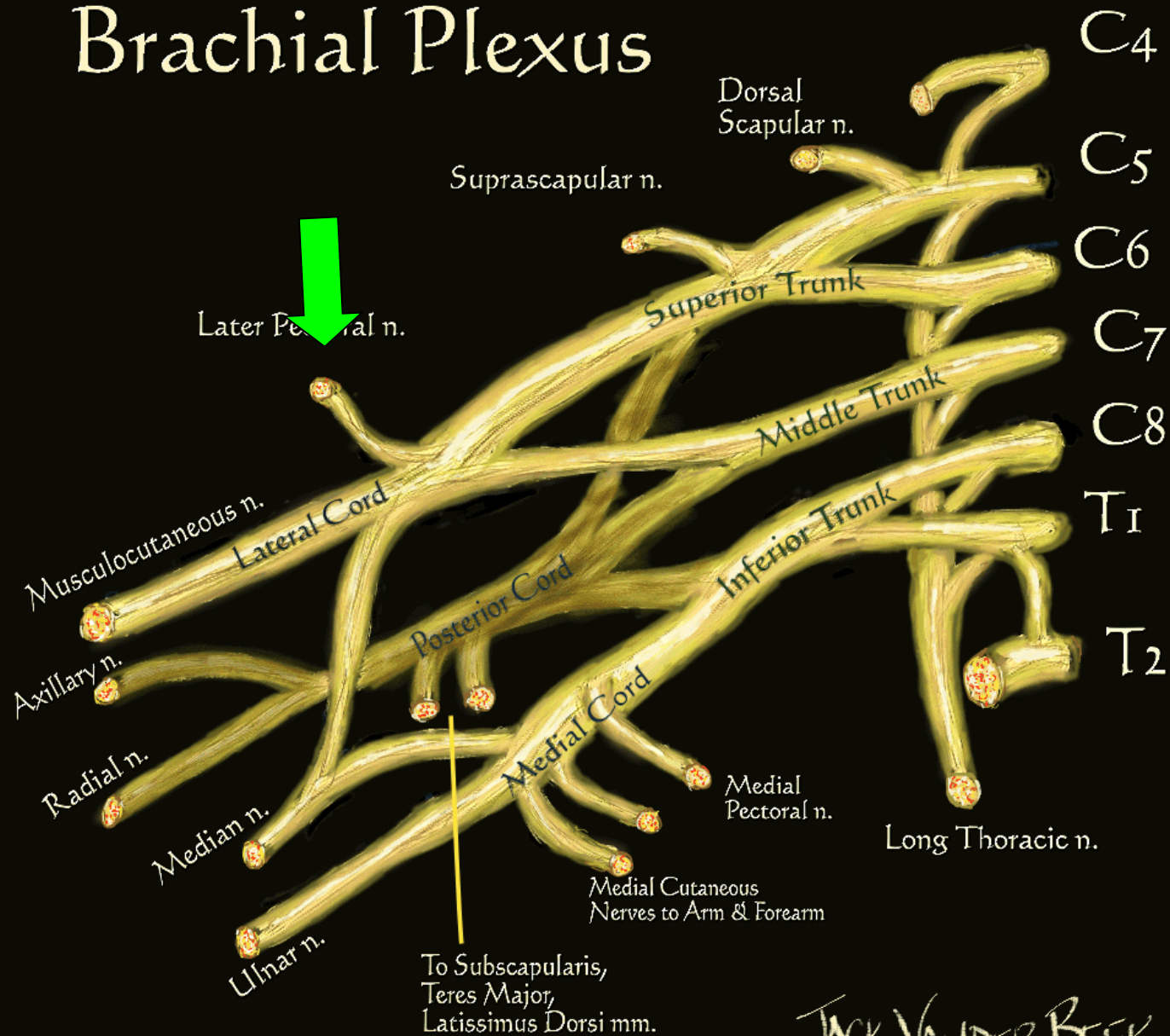
JACK VANDER BEEK  
 (c) 2005 neuraxiom.com







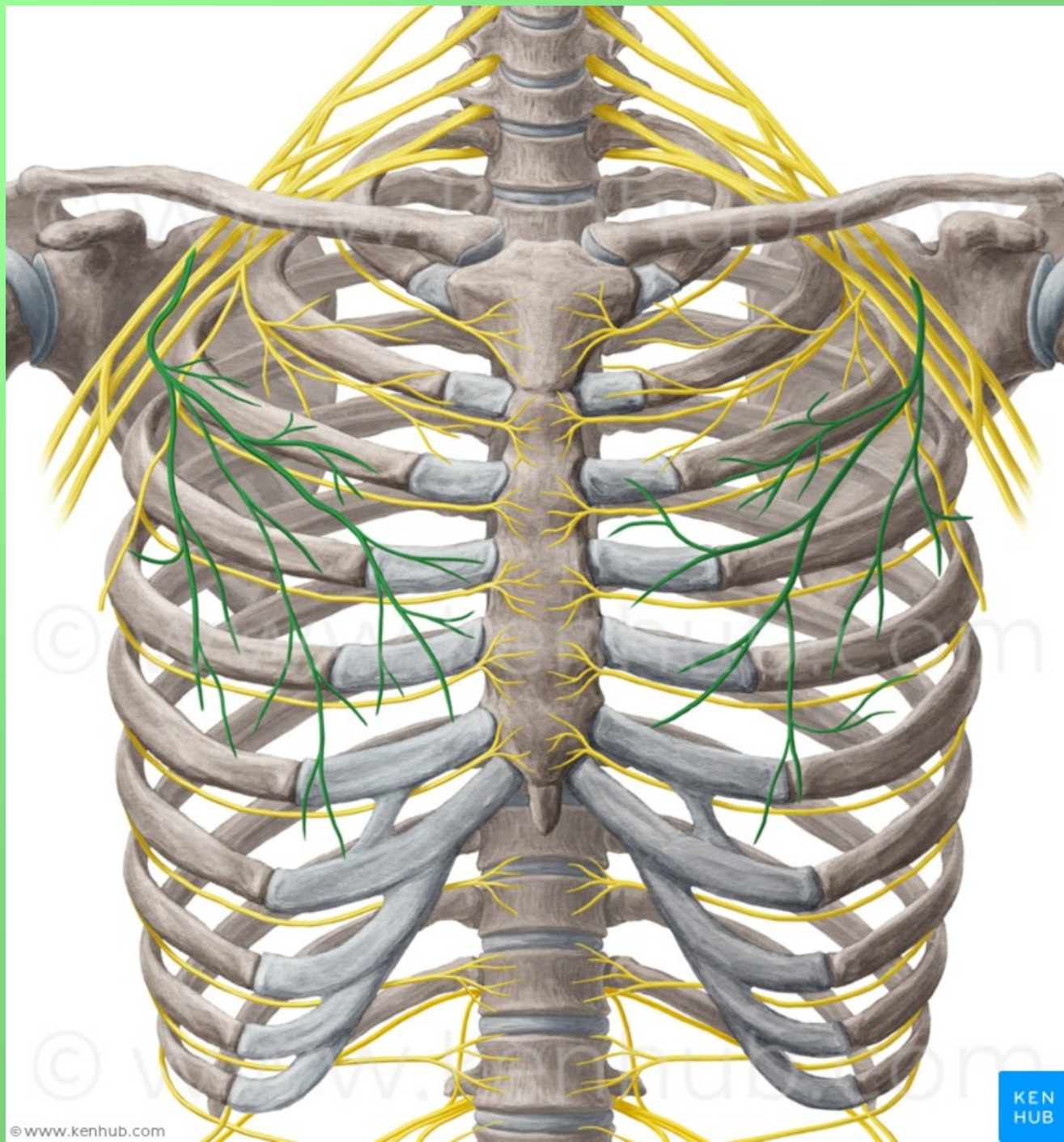
# Brachial Plexus

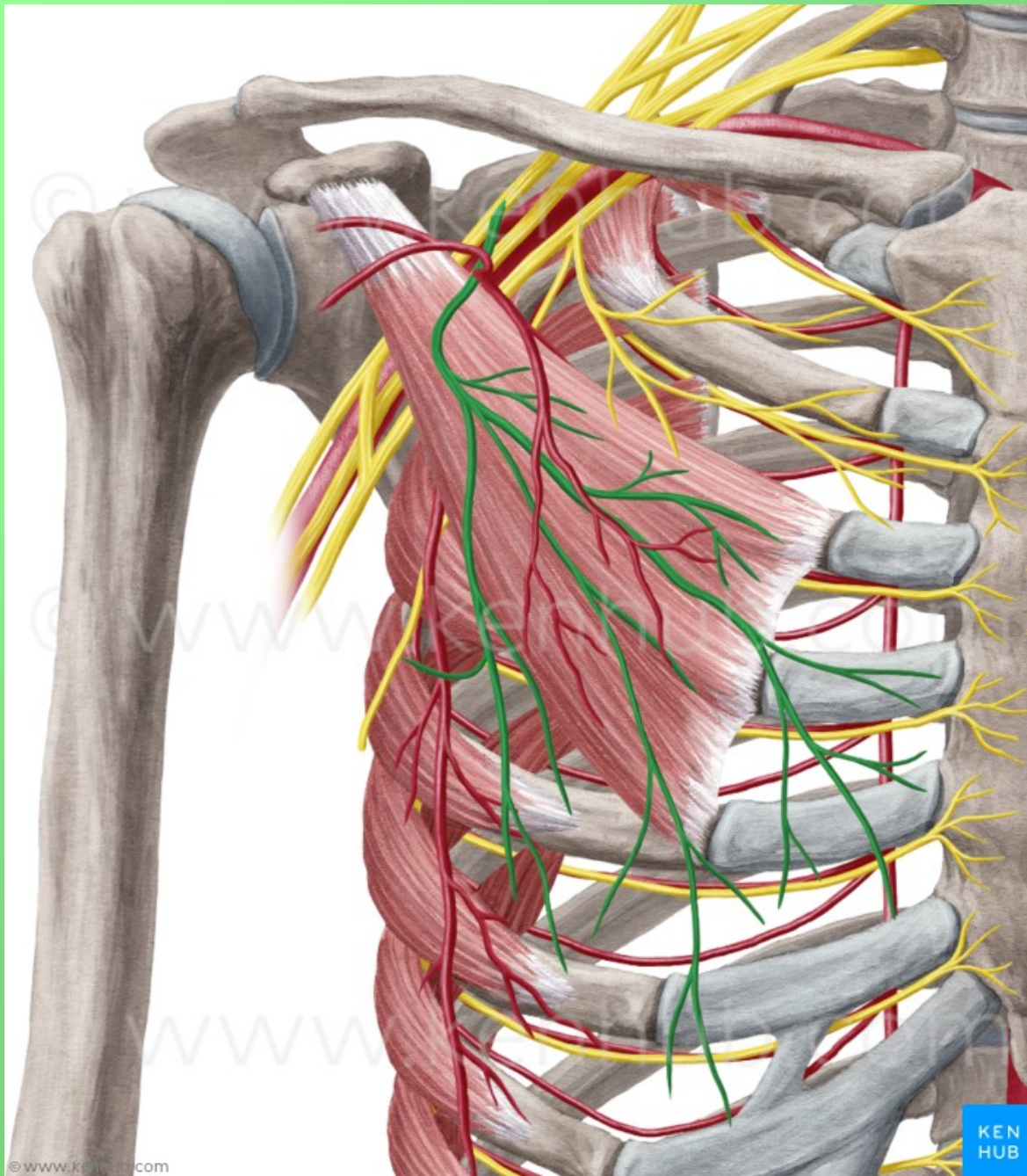


-7



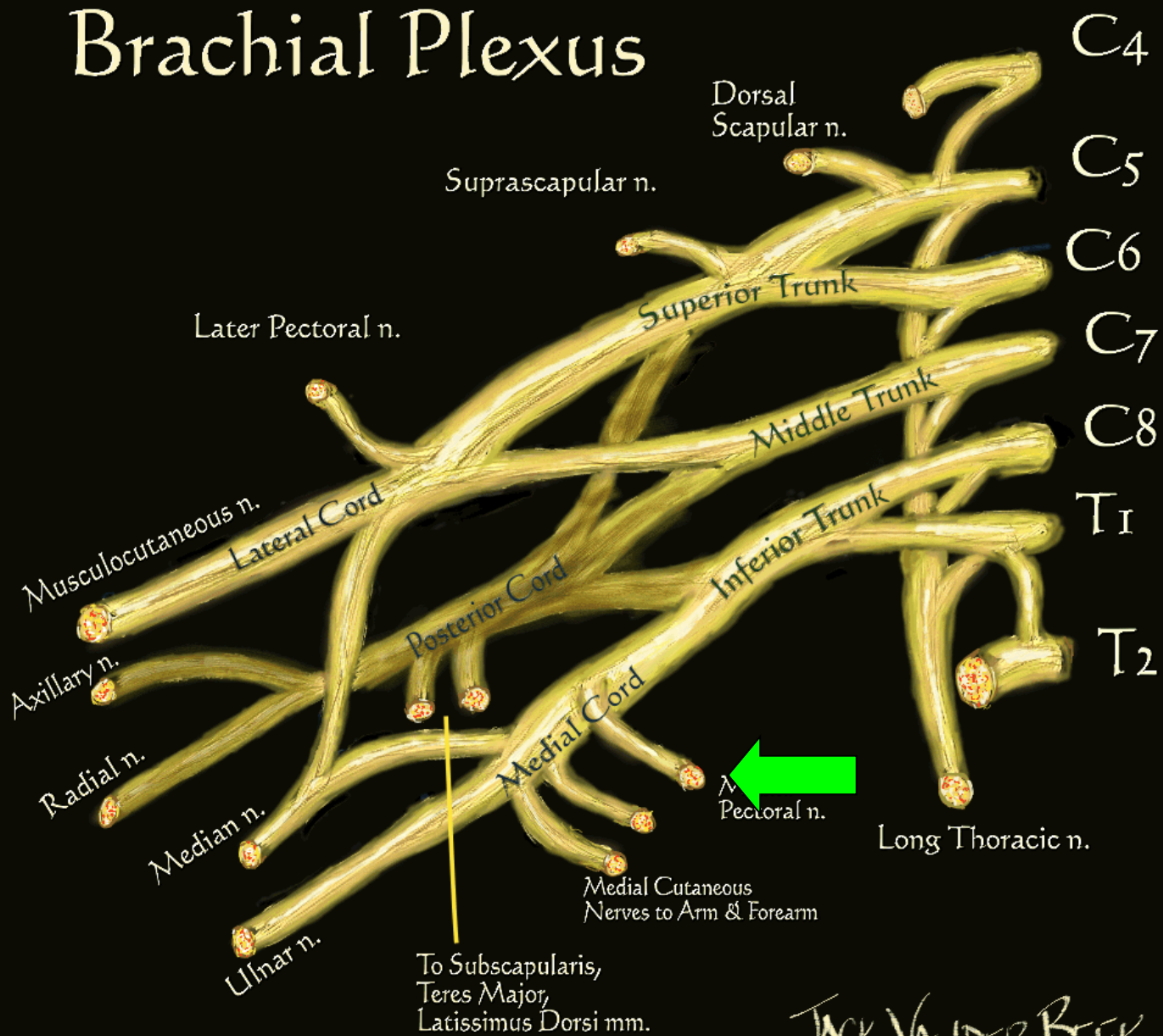






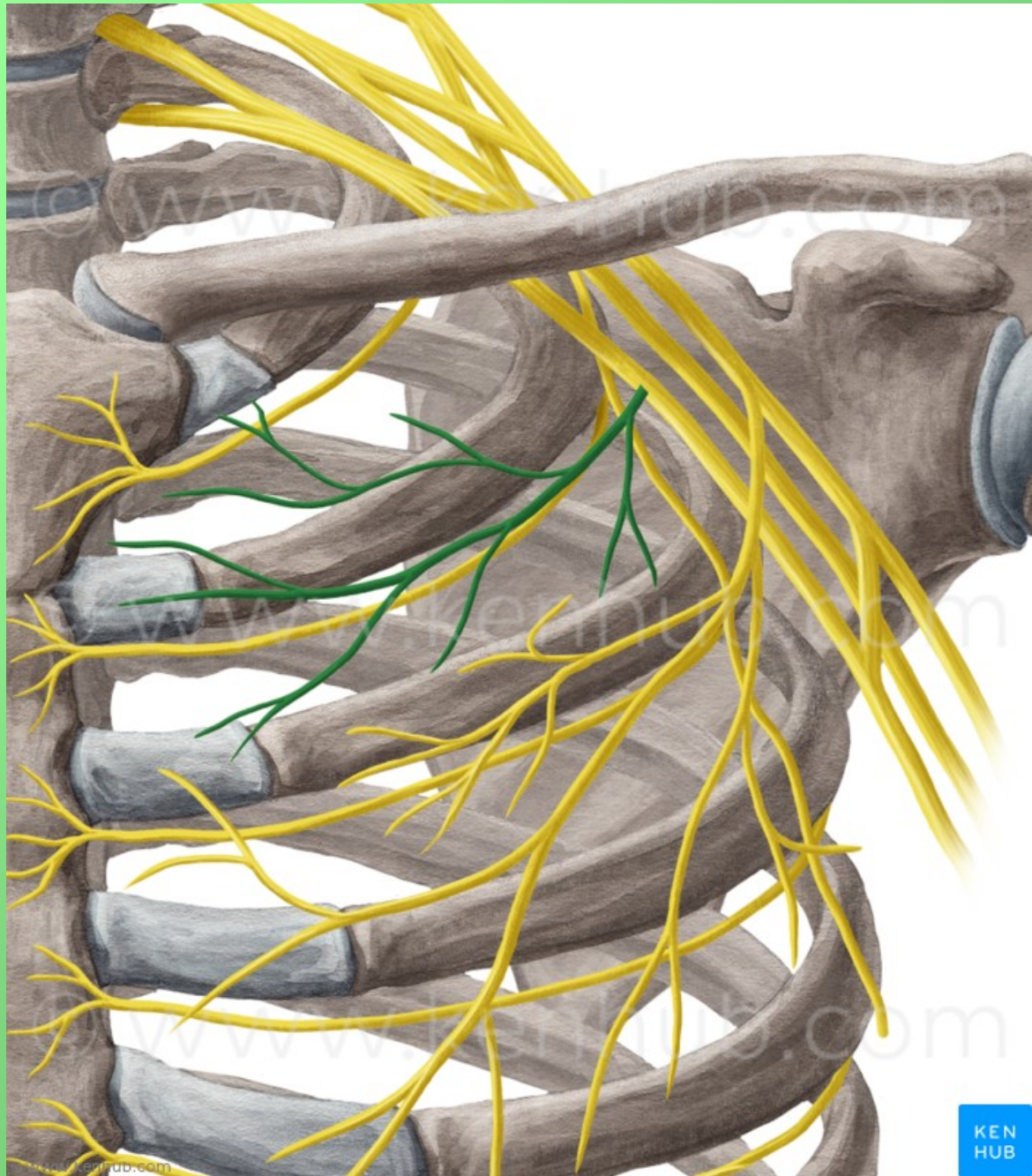
# Brachial Plexus

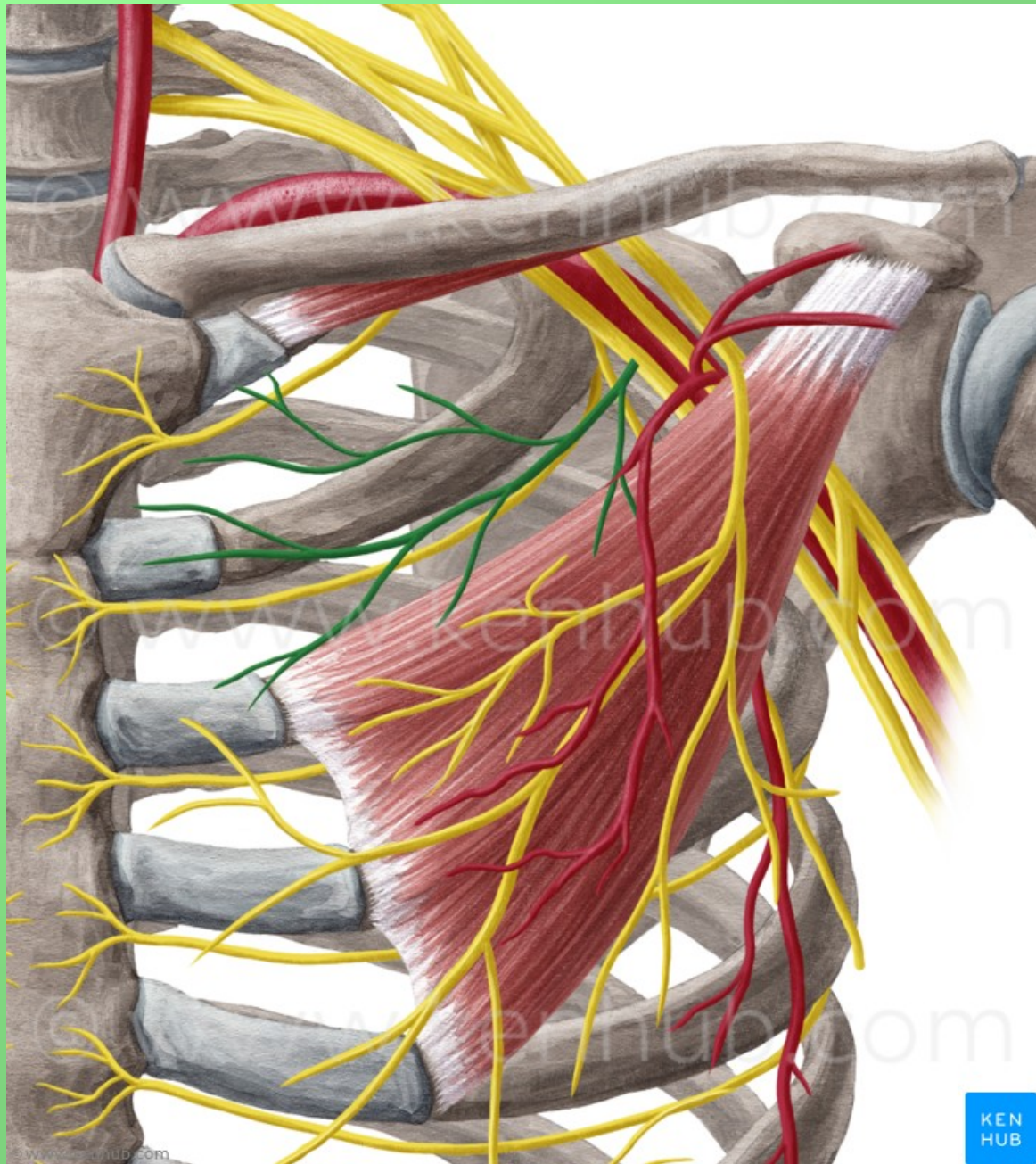
• m



h1



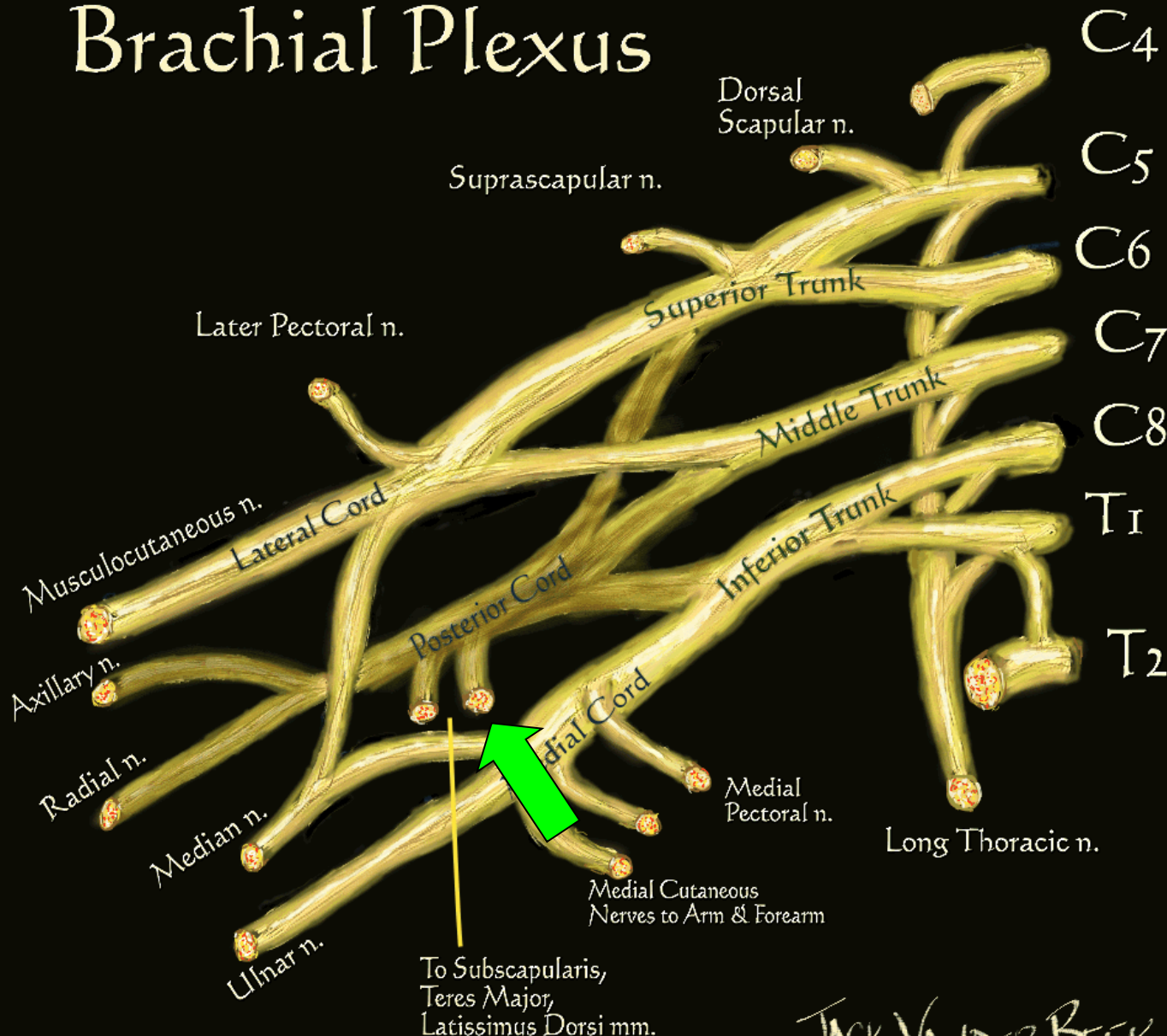




KEN  
HUB

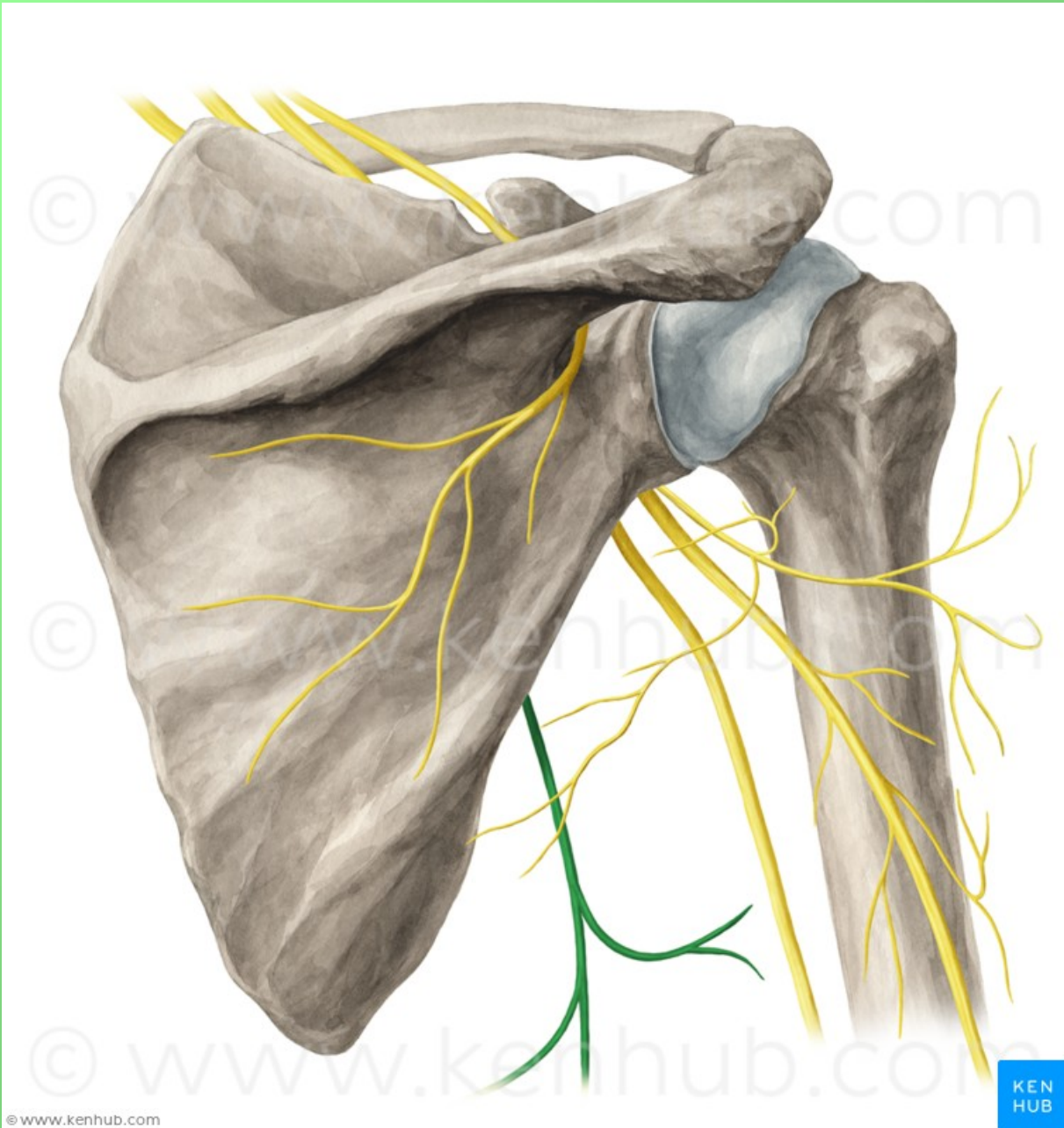


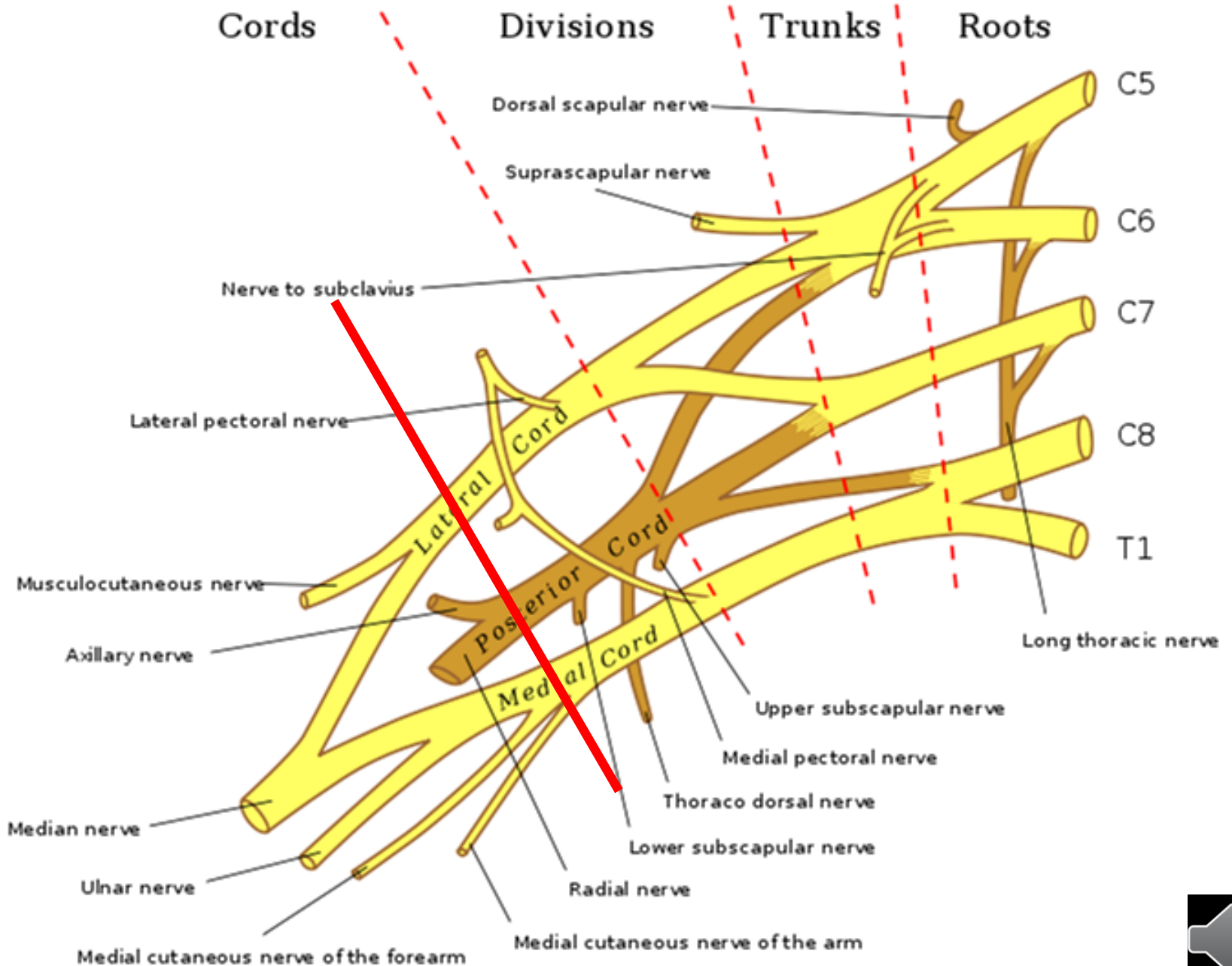
# Brachial Plexus



JACK VANDER BEEK  
(c) 2005 neuraxiom.com



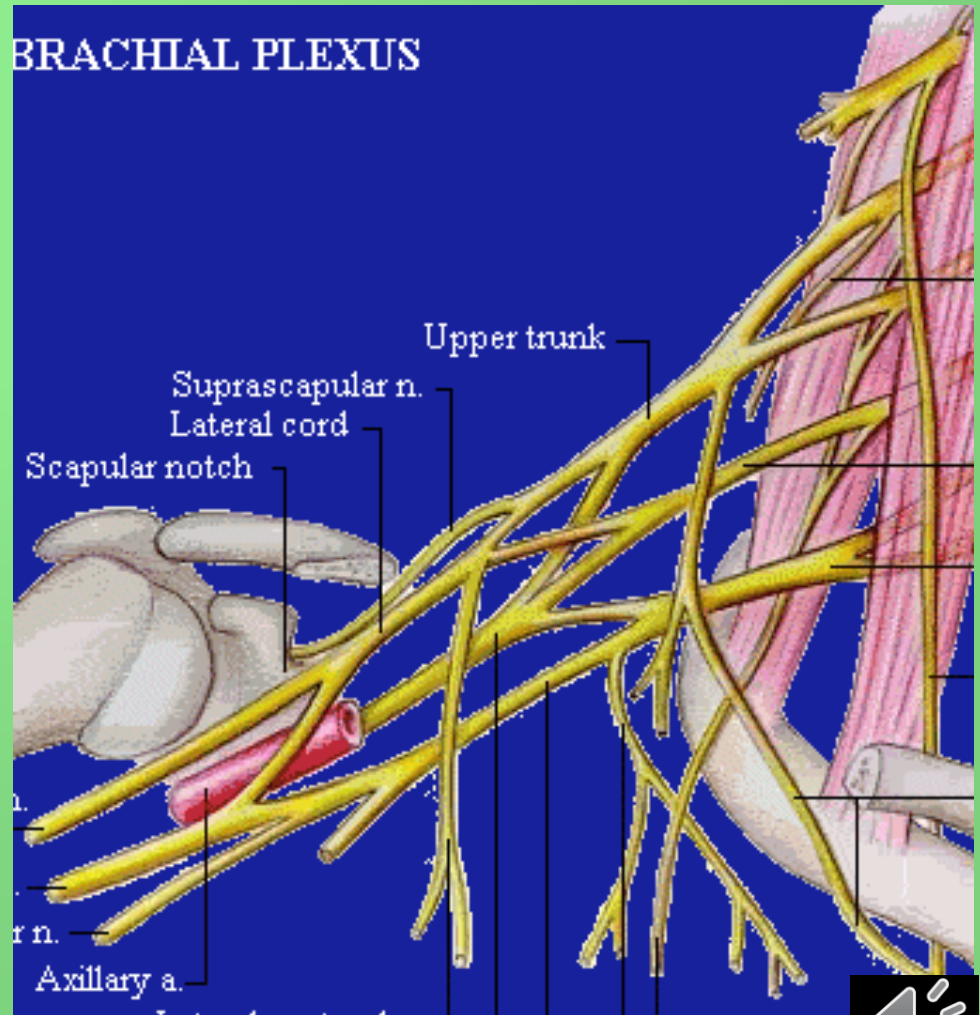


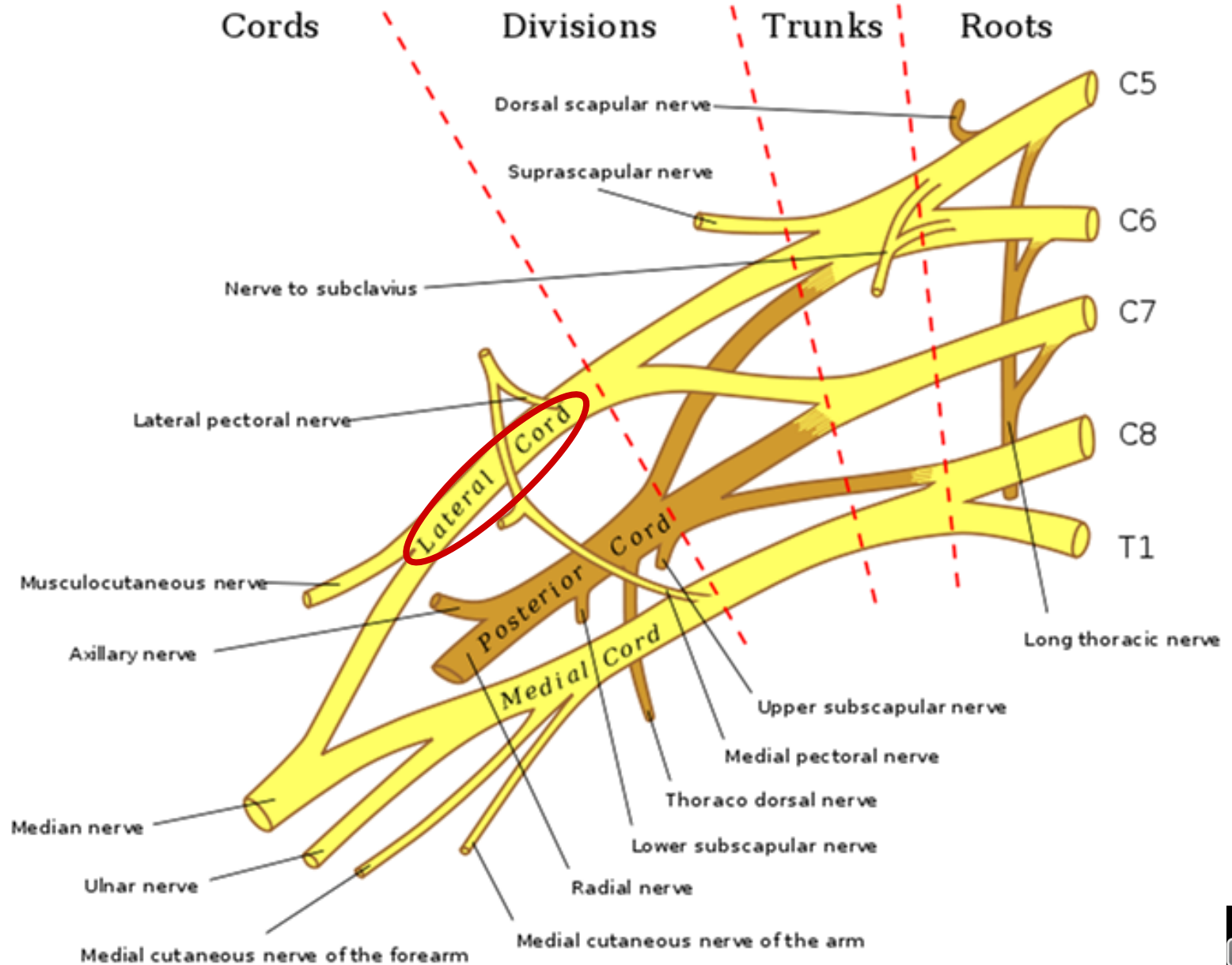




# Pars infraclavicularis plexus brachialis

- fasciculus lateralis
- fasciculus medialis
- fasciculus posterior





# Fasciculus lateralis

## n. musculocutaneus

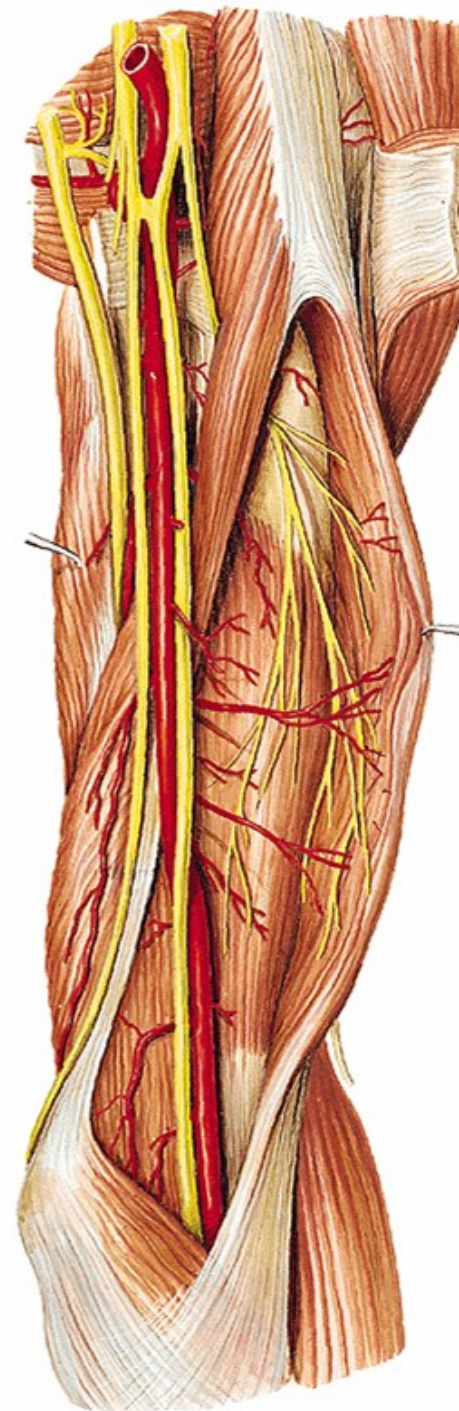
(smíšený) (C5-7)

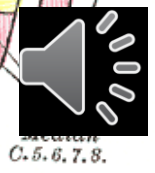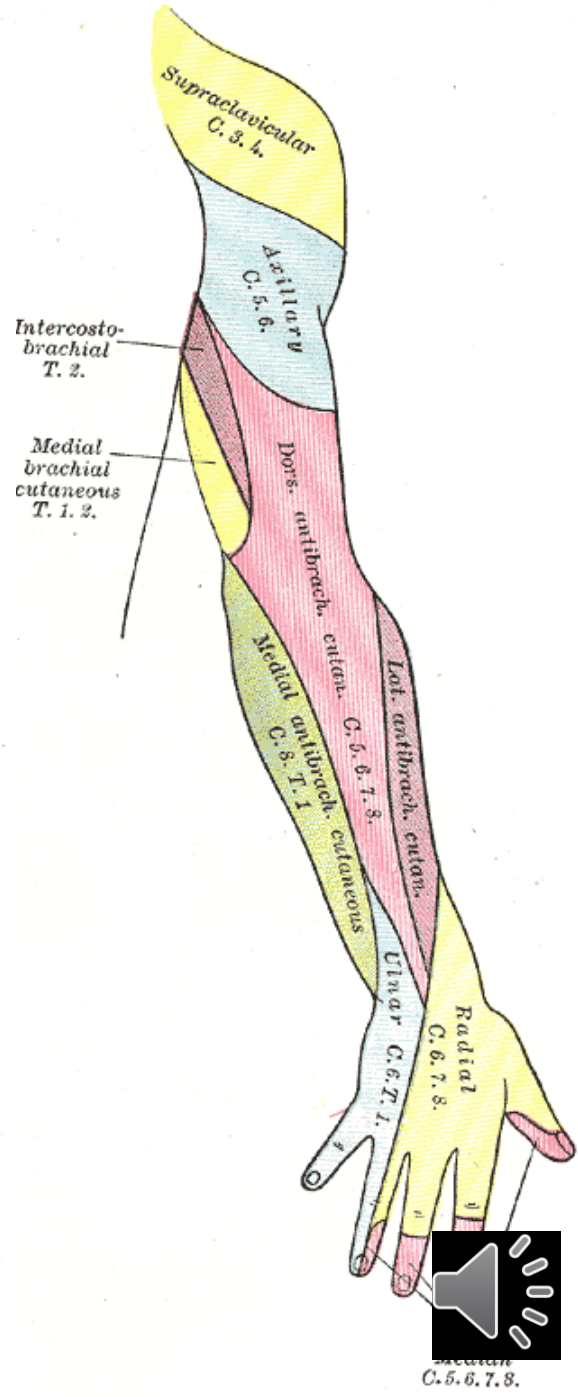
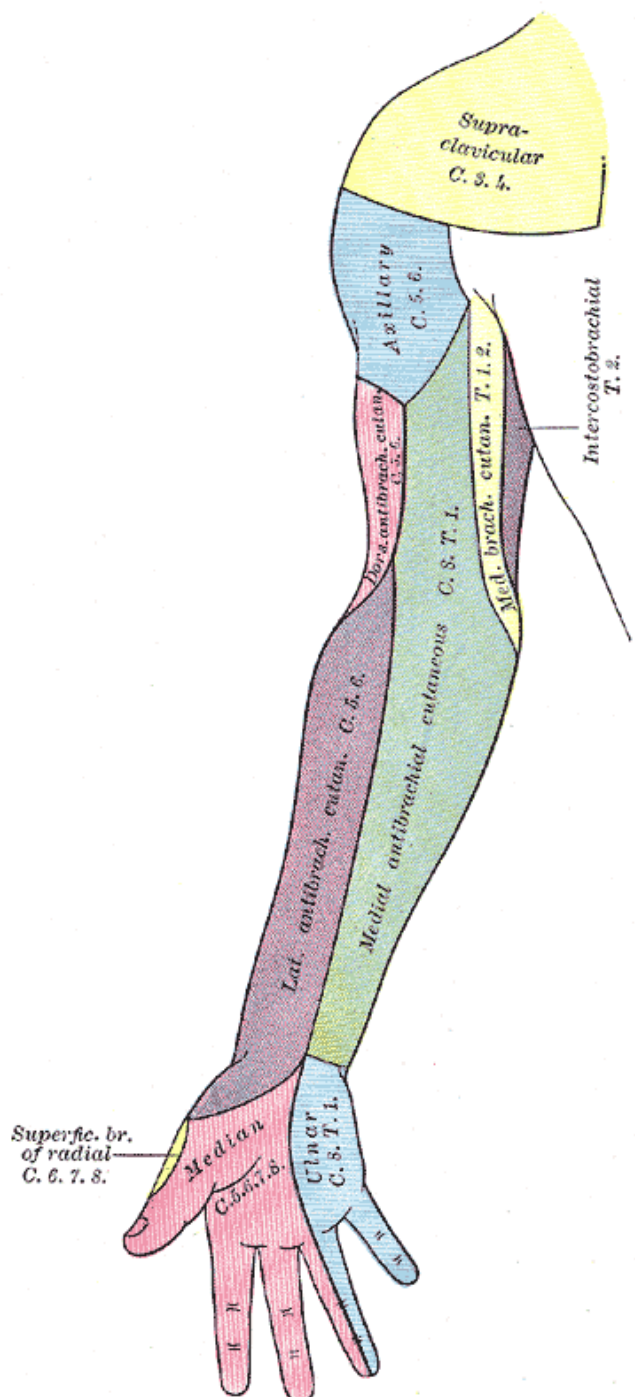
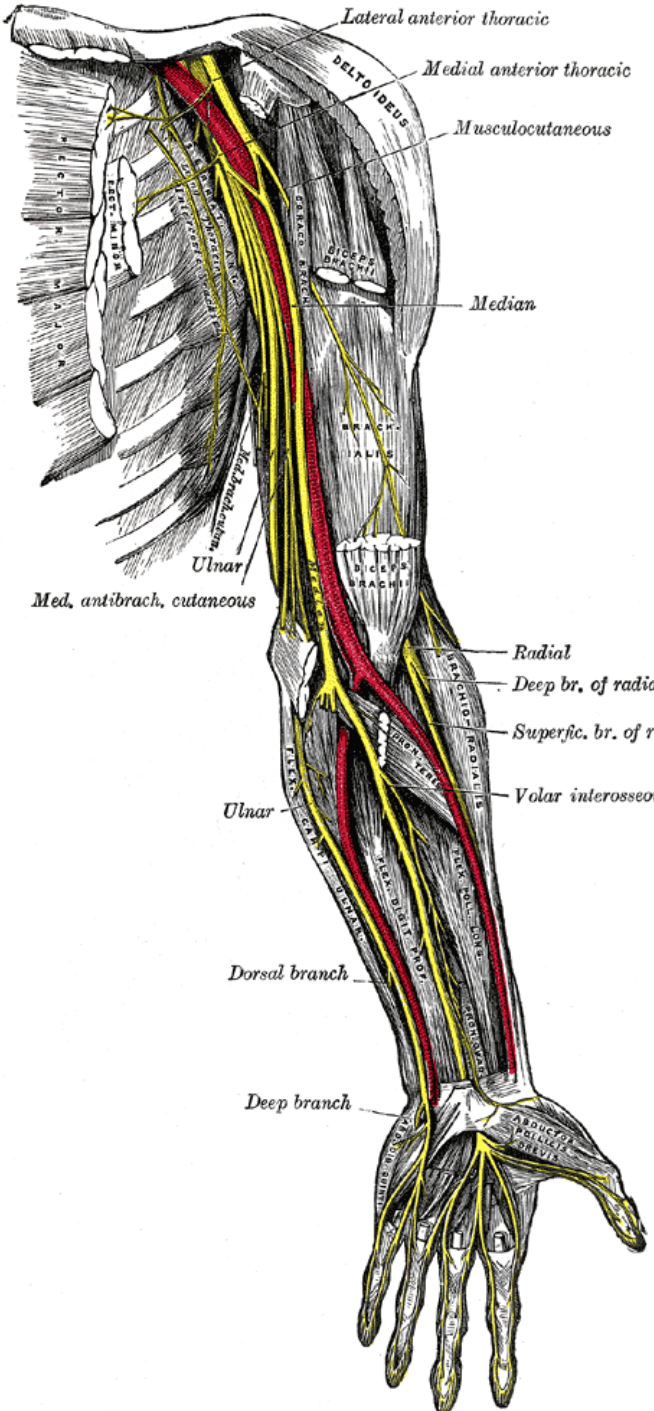
rr. musculares (m. coracobrachialis,  
m. biceps brachii, m. brachialis)

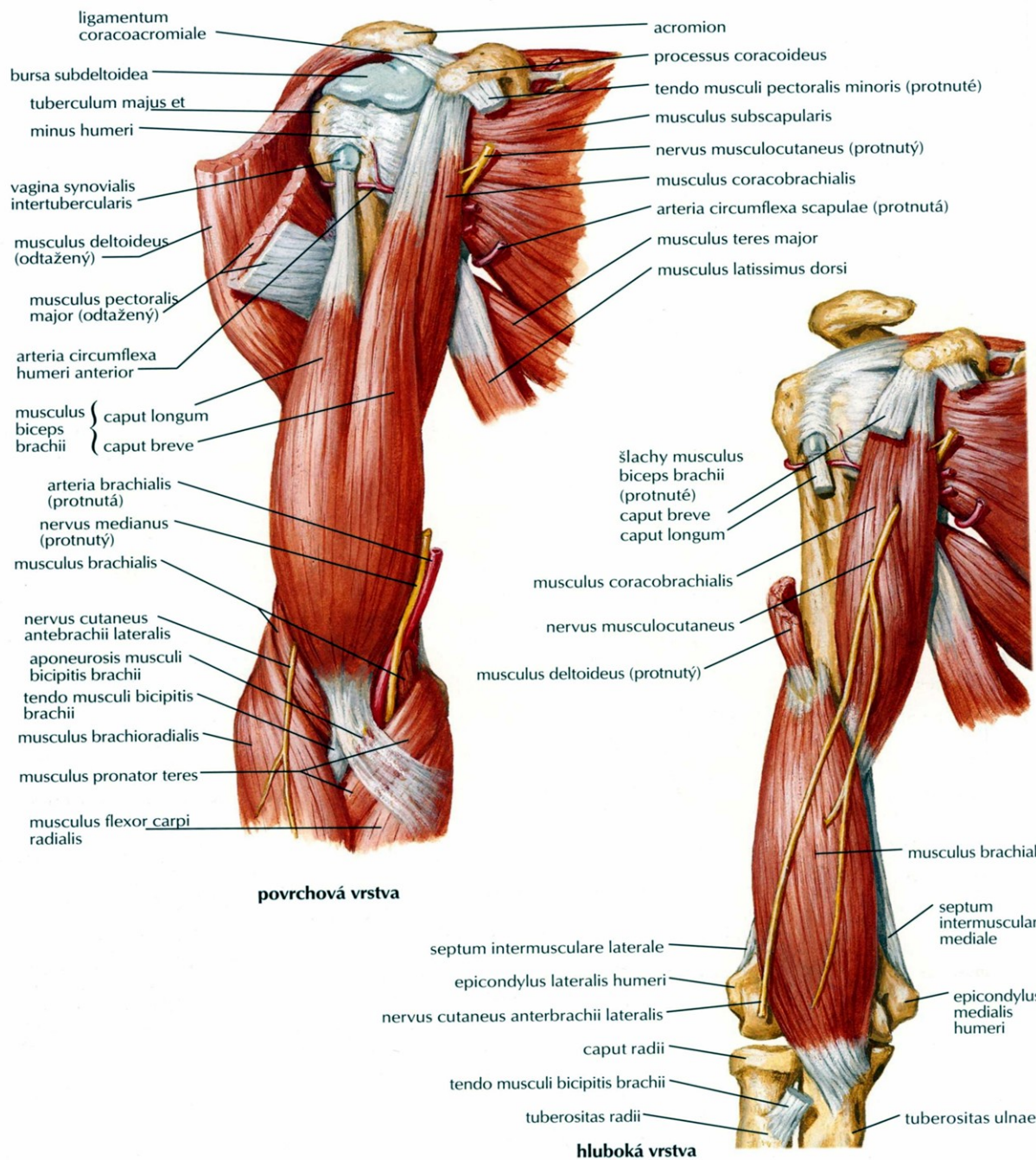
n. cutaneus antebrachii lateralis

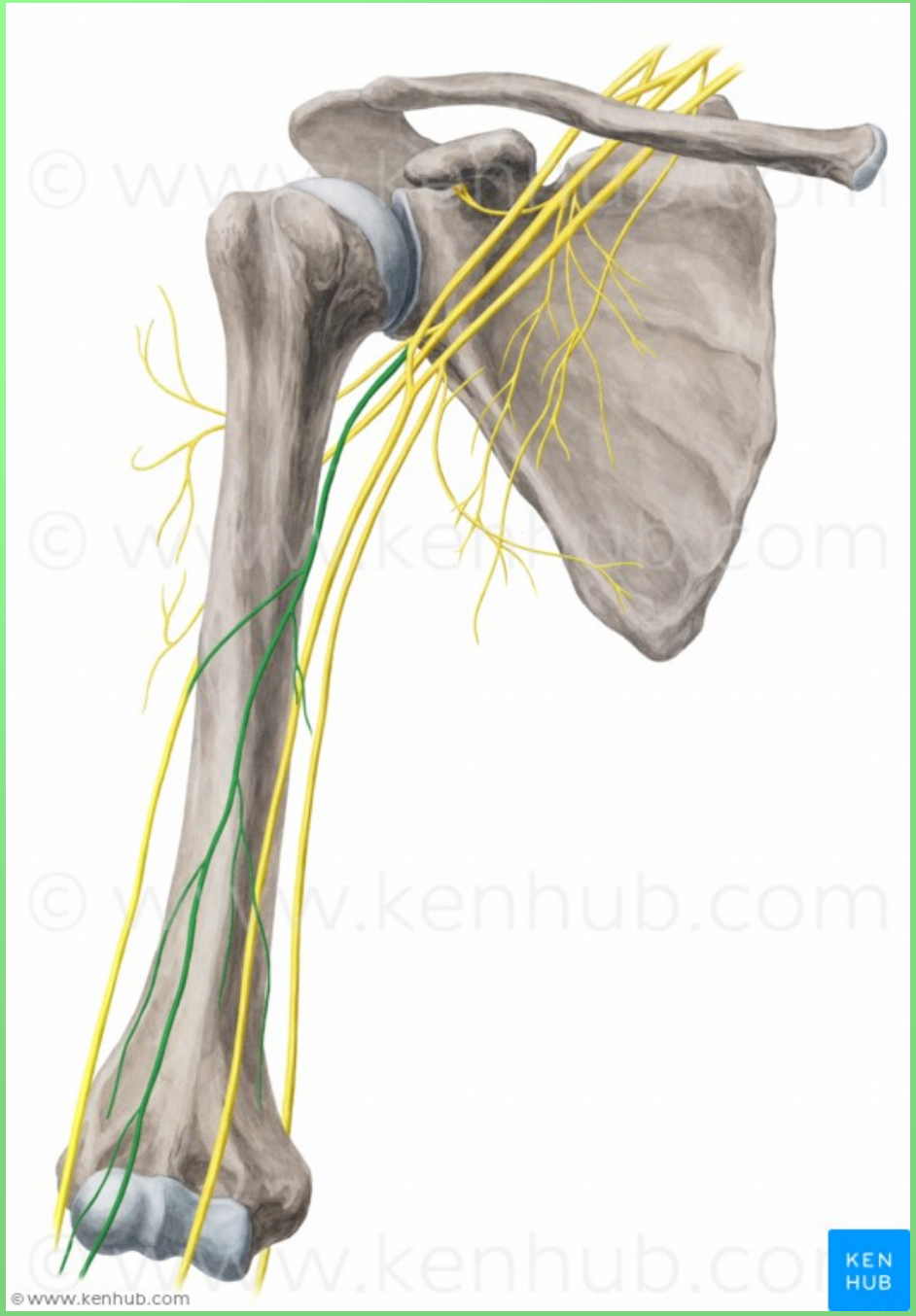
vulnerabilní místo - fossa cubiti

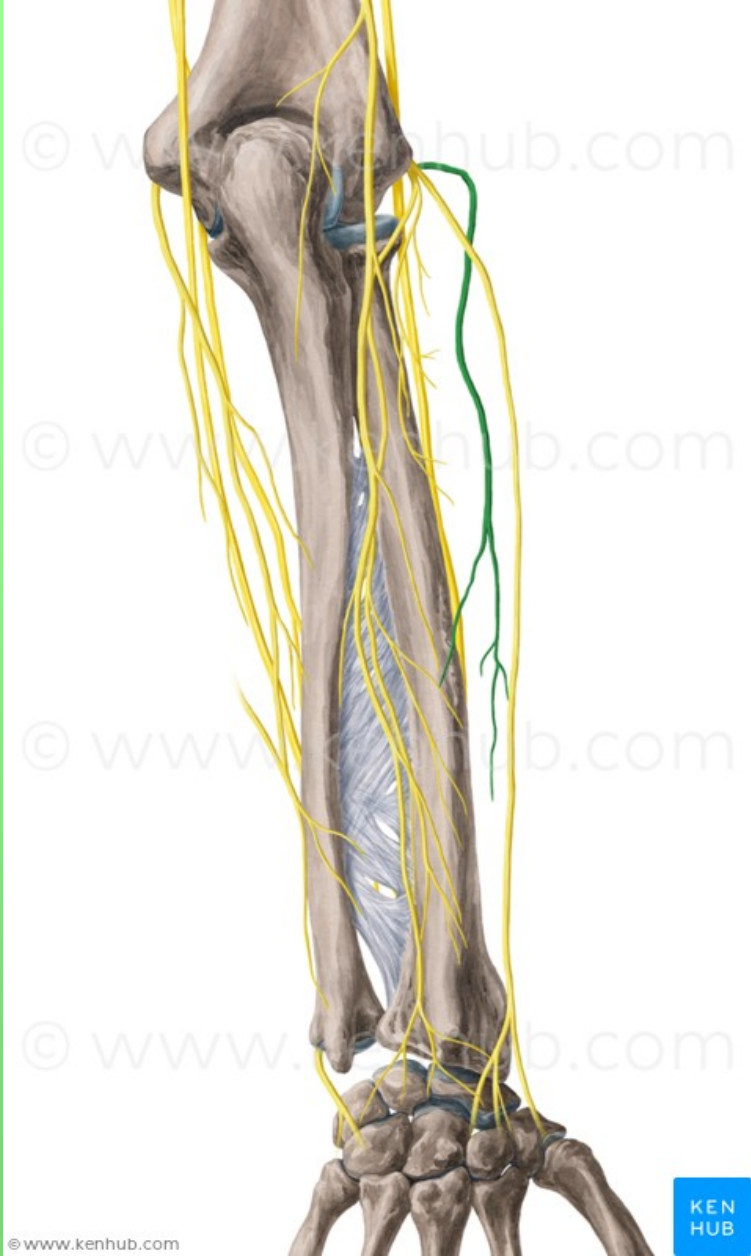
## radix lateralis n. mediani







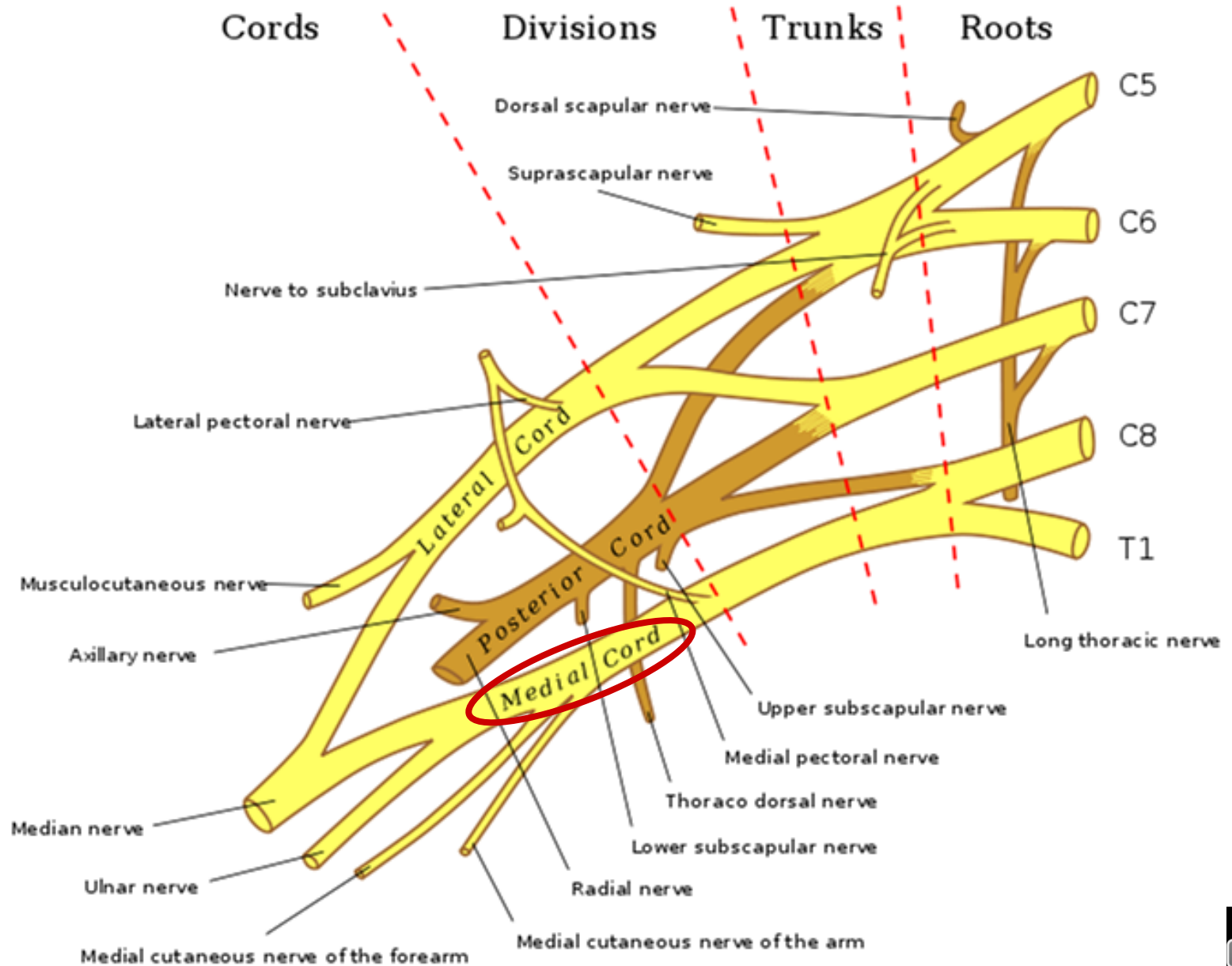




© www.kenhub.com

KEN  
HUB







# Fasciculus medialis

## radix medialis n. mediani

## n. cutaneus brachii medialis (C8–Th1)

- spojky s nn. intercostales II., (III.) – **nn. intercostobrachiales**

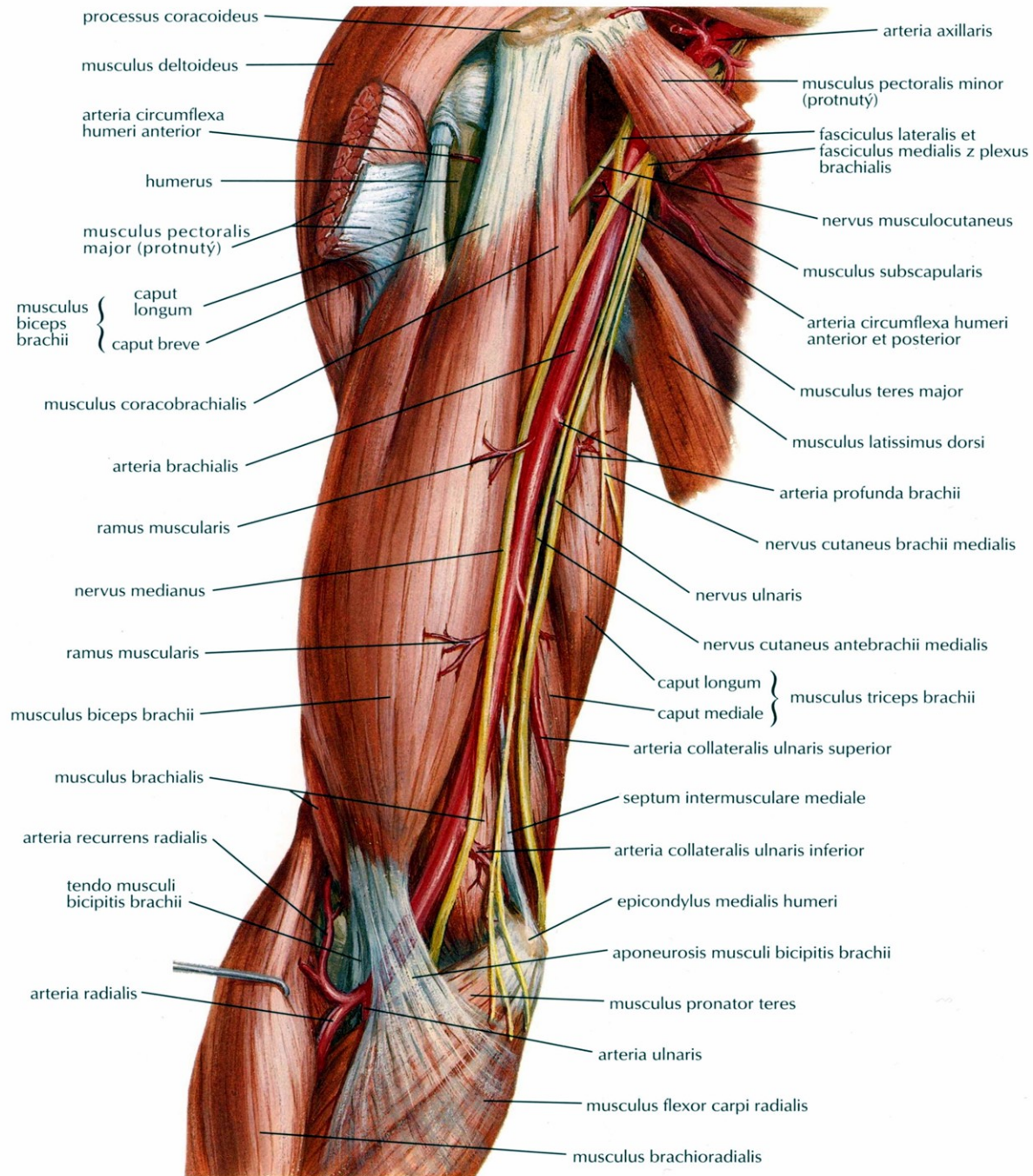
## n. cutaneus antebrachii medialis (C8–Th1)

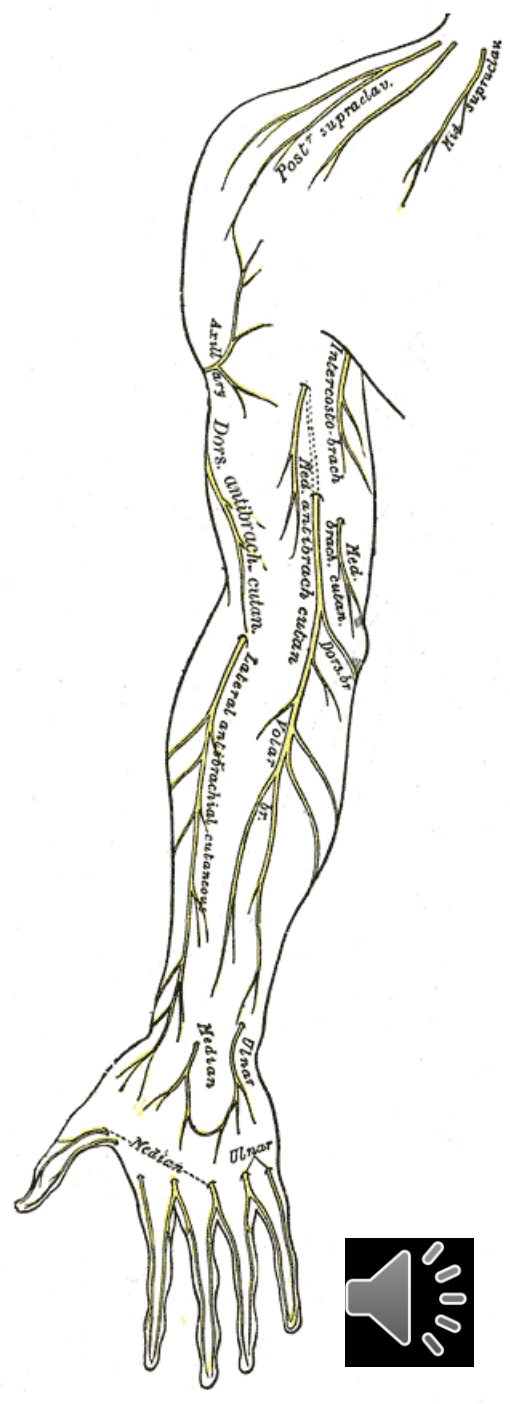
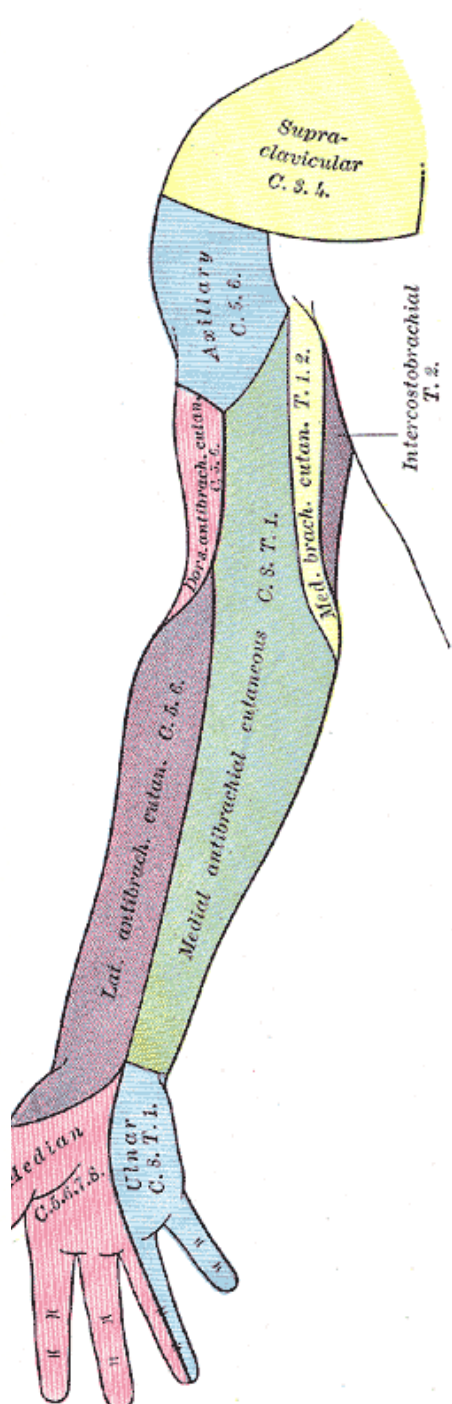
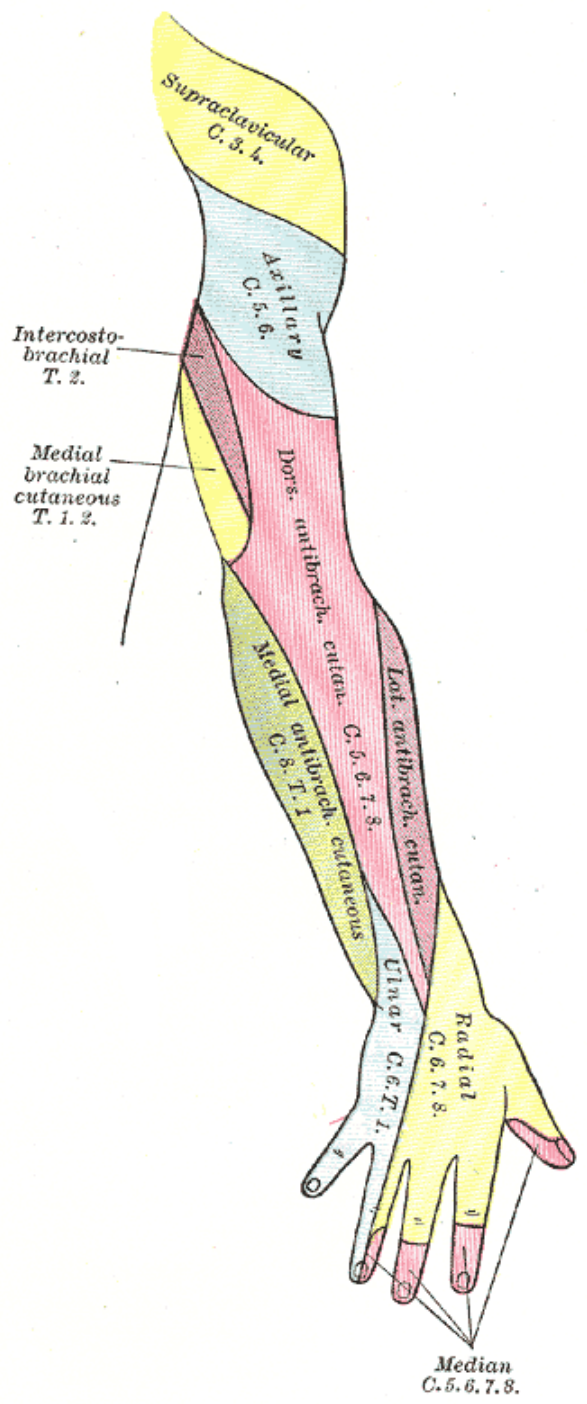
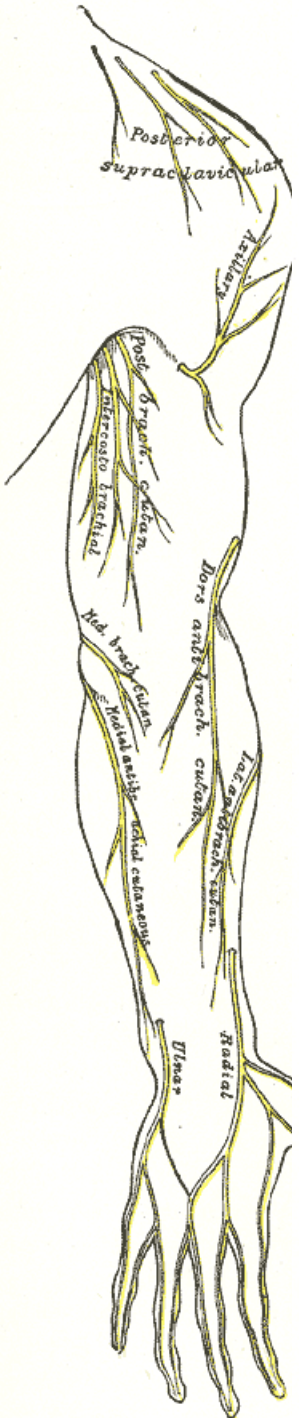
(skrže hiatus basilicus do podkoží a jde distálně po předloktí)

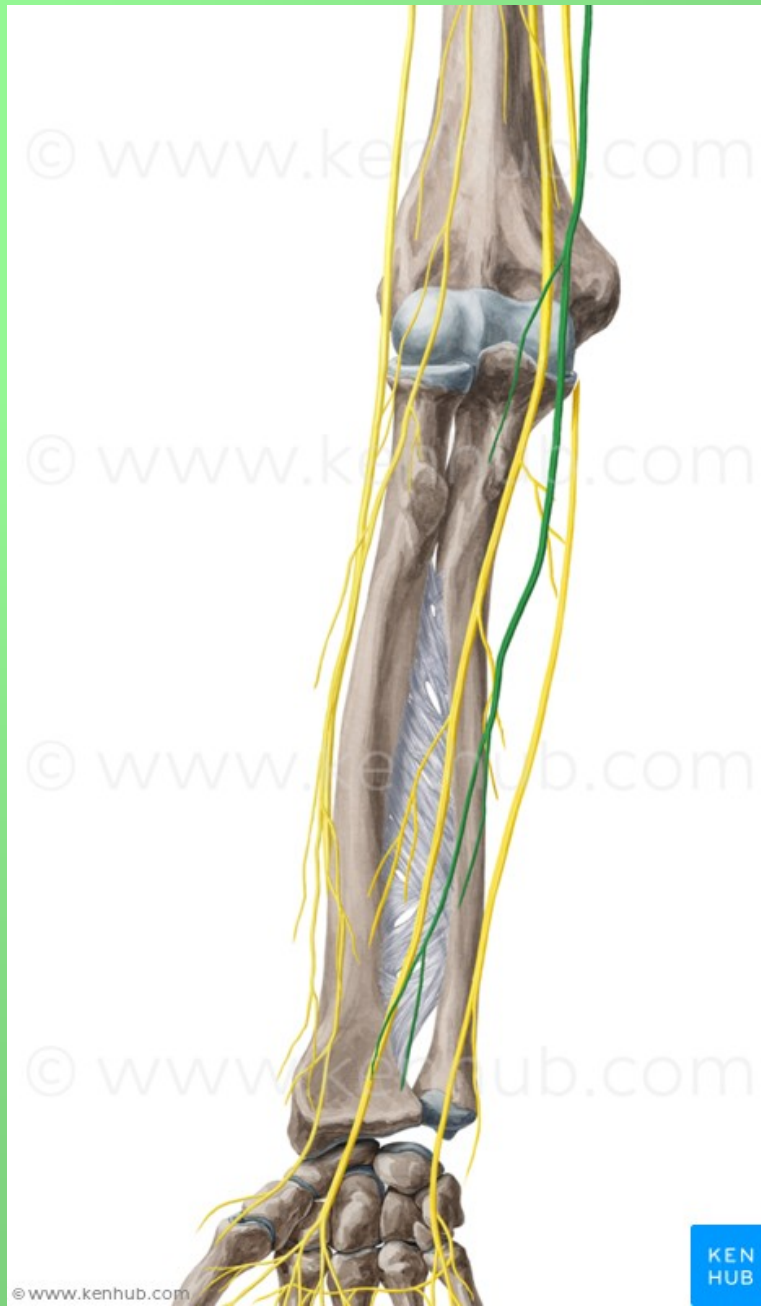
**r. anterior et r. ulnaris**

## n. ulnaris









## n. ulnaris - (smíšený) (C8–Th1)

- po paži mediálně od n. medianus, sulcus nervi ulnaris, mezi m. flexor carpi ulnaris a m. flexor digitorum profundus s a. ulnaris a do dlaně na povrchu retinaculum flexorum

- **rr. articulares**

- **rr. musculares**

- **r. dorsalis n. ulnari**

  - nn. digitales dorsales

- **r. palmaris n. ulnaris**

Kmen n. ulnaris se v dlani větví na:

- r. superficialis

  - r. muscularis (m. palmaris brevis)

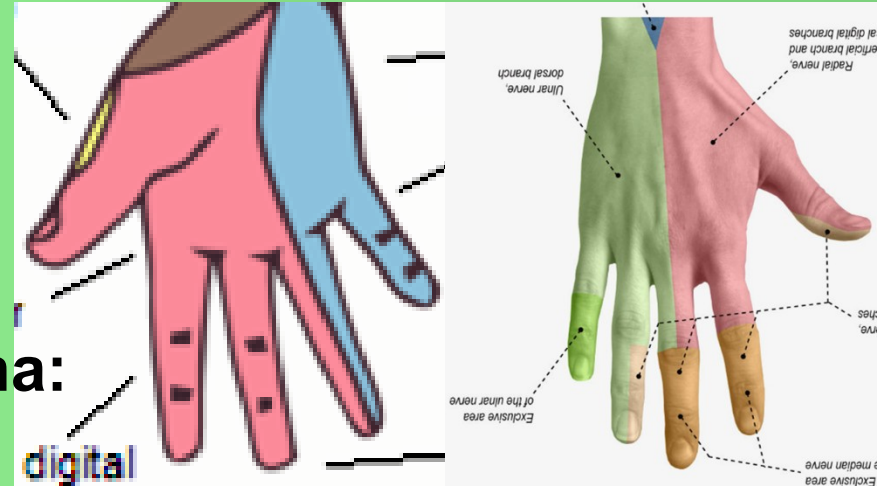
  - 2 nn. digitales palmares communes et proprii

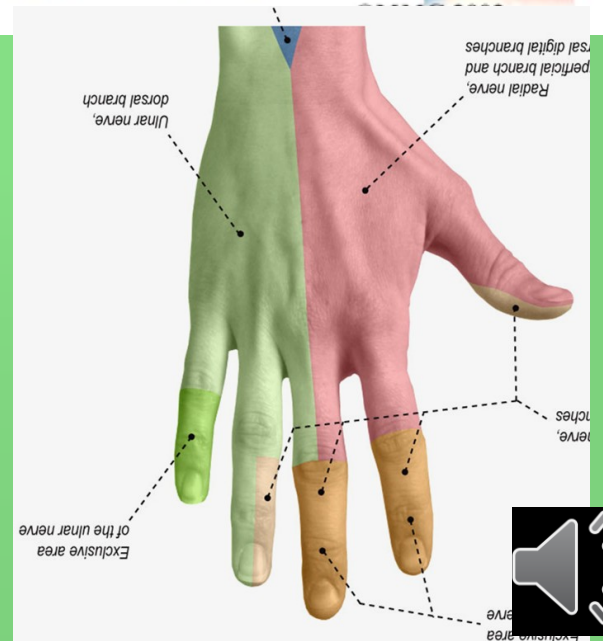
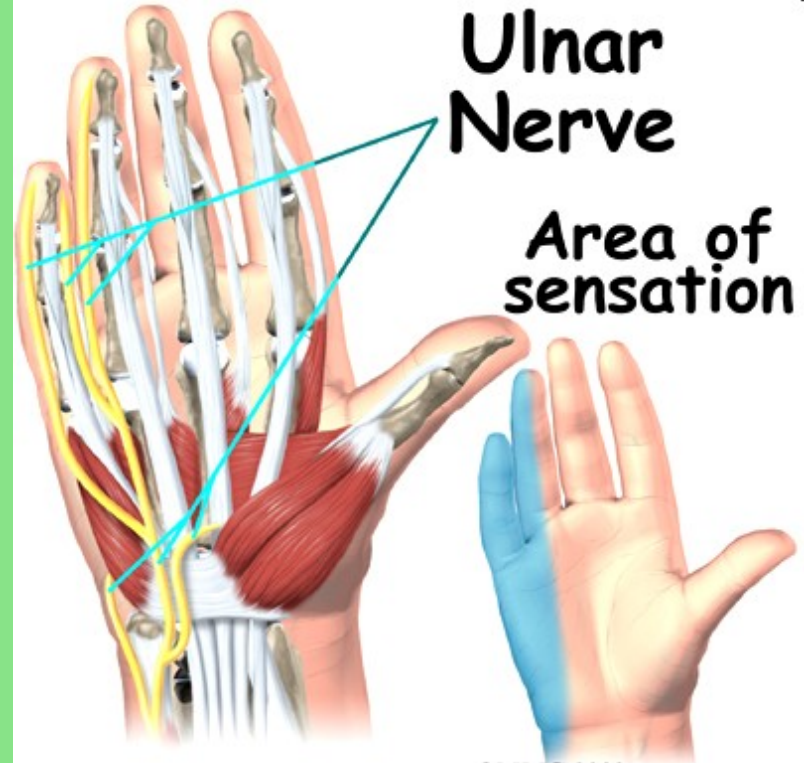
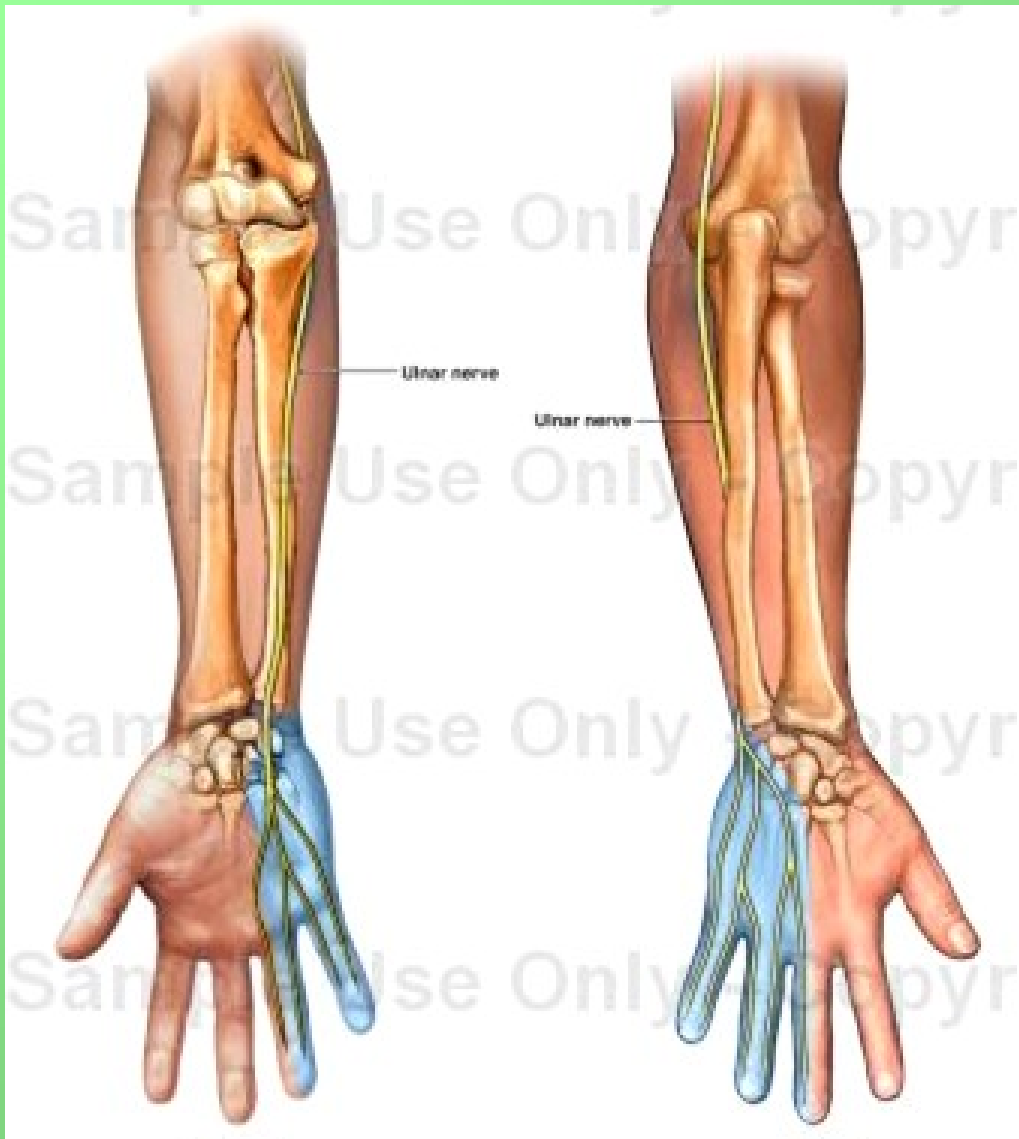
- r. profundus - rr. musculares

**Motoricky:** m. flexor carpi ulnaris, m. flexor digitorum profundus (4. a 5. prst), svaly hypothenaru, m. adductor pollicis a m. flexor pollicis brevis (caput profundum), mm. interossei, mm. lumbricales (III. a IV.)

**Senzoricky:** palmárně: 5. a polovinu 4. prstu

dorsálně: 5., 4., a polovinu 3. prstu





ANTERIOR

POSTERIOR

Supra-clavicular (C3-4)

Axillary, sup. lat. cut. (C5-6)

Intercostobrachial (T2)

Medial brachial cut. (T1-2)

Medial brachial cut. (C8-T1)

Ulnar (C8-T1)

Palmar Dorsal

Palmar, digital

Proper palmar digital

Median (C5-8)

Radial, dors. antebrach. cut. (C5-6)

Lateral antebrachial cutan. (C5-6)

Radial, superficial (C6-8)

Palmar

Palmar, digital

Post. brach. cut.

Inf. lat. cut.

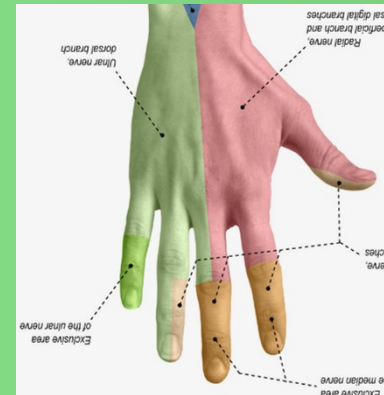
Post. antebrach. cut.

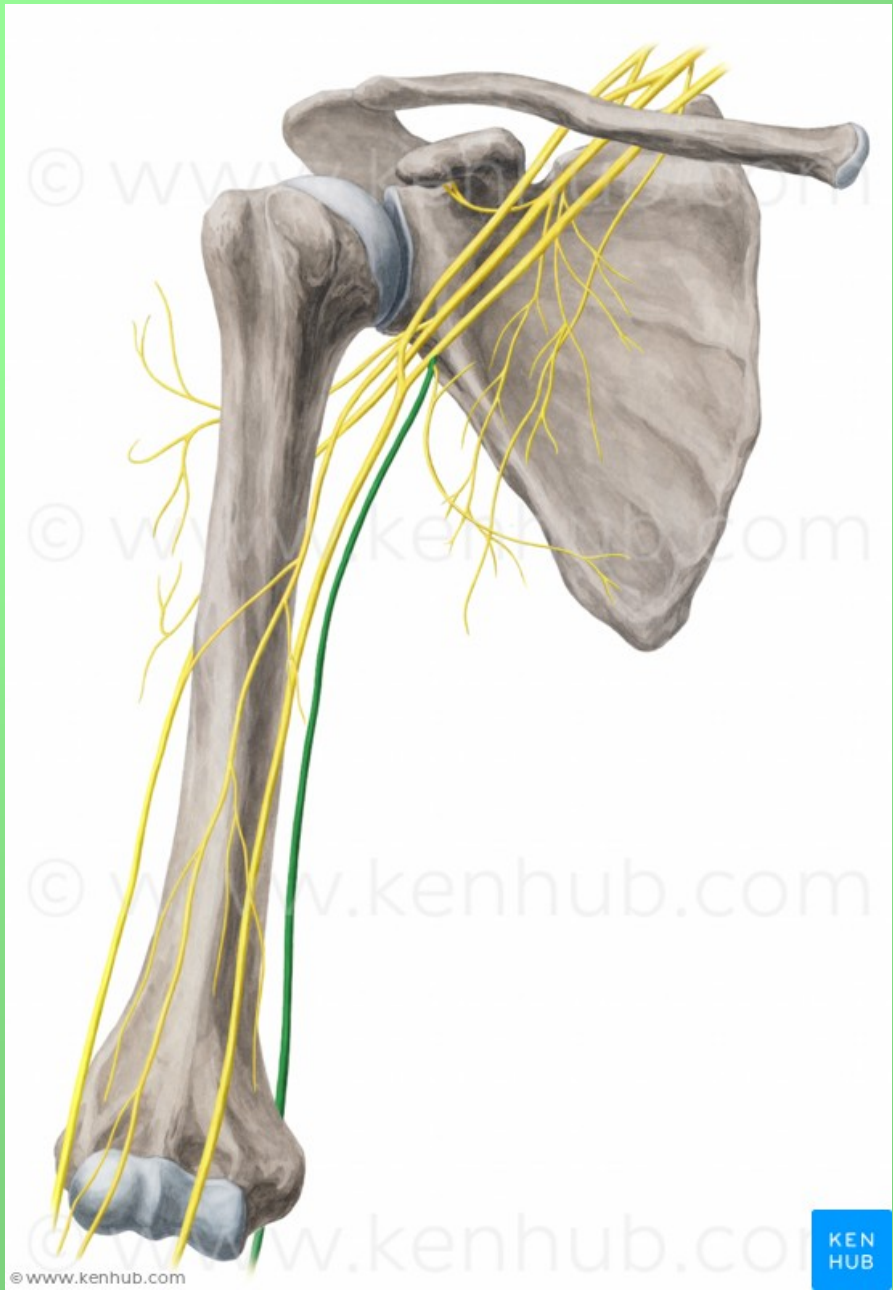
Lateral antebrachial cutan. (C5-6)

Radial, superficial (C6-8)

Dorsal digital

Proper palmar digital



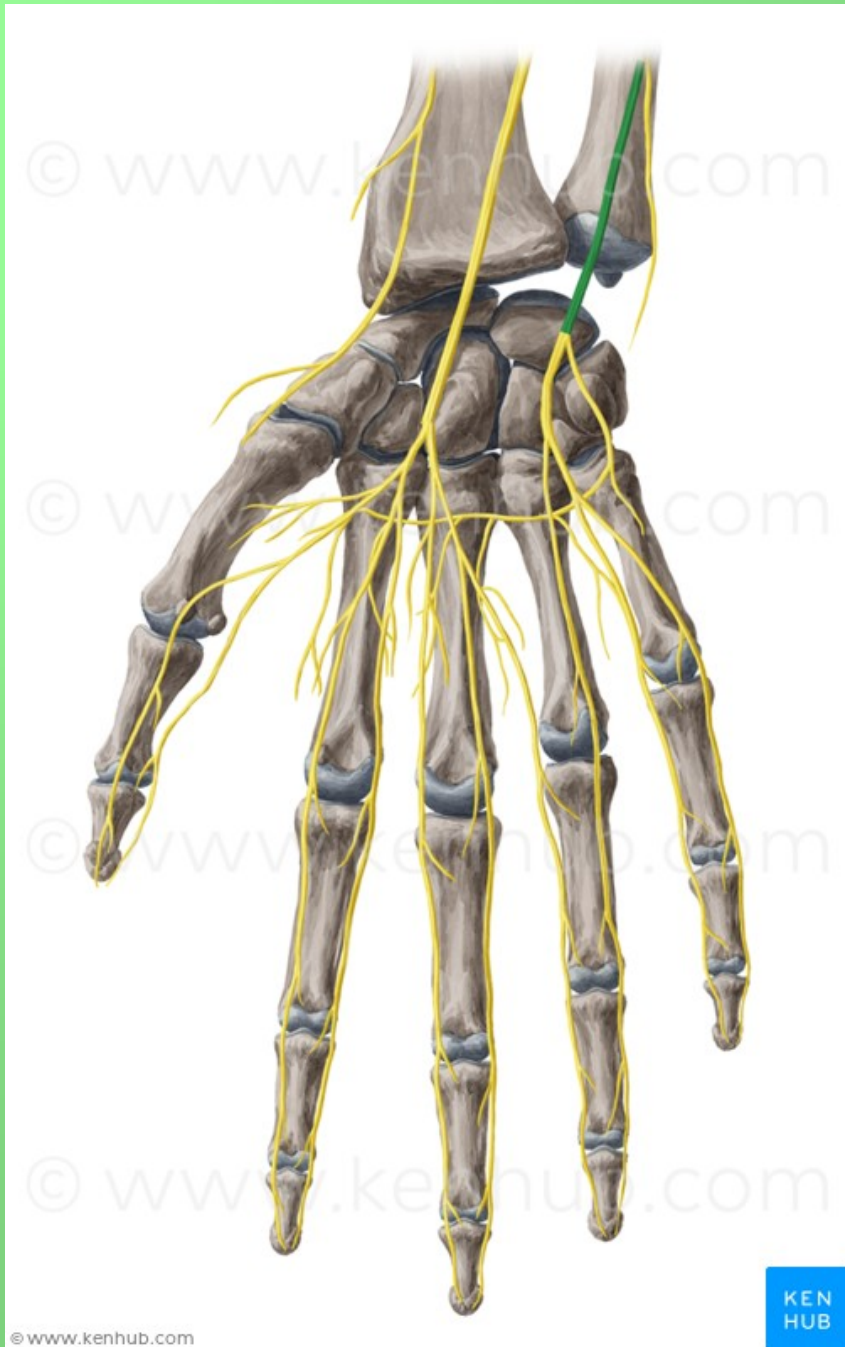

© www.kenhub.com

KEN  
HUB





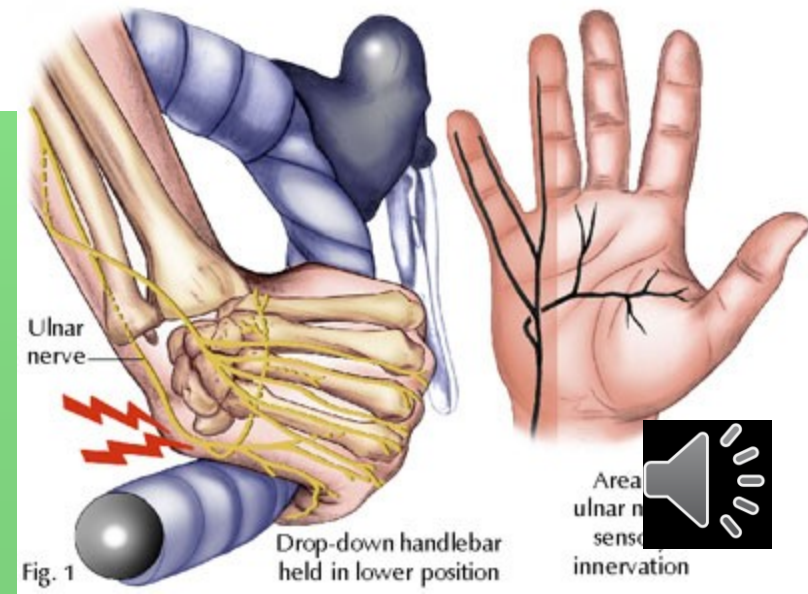
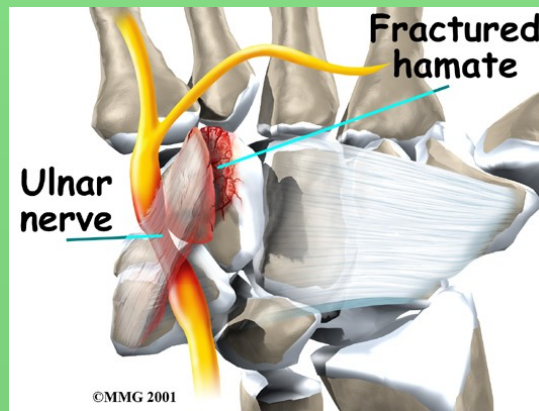
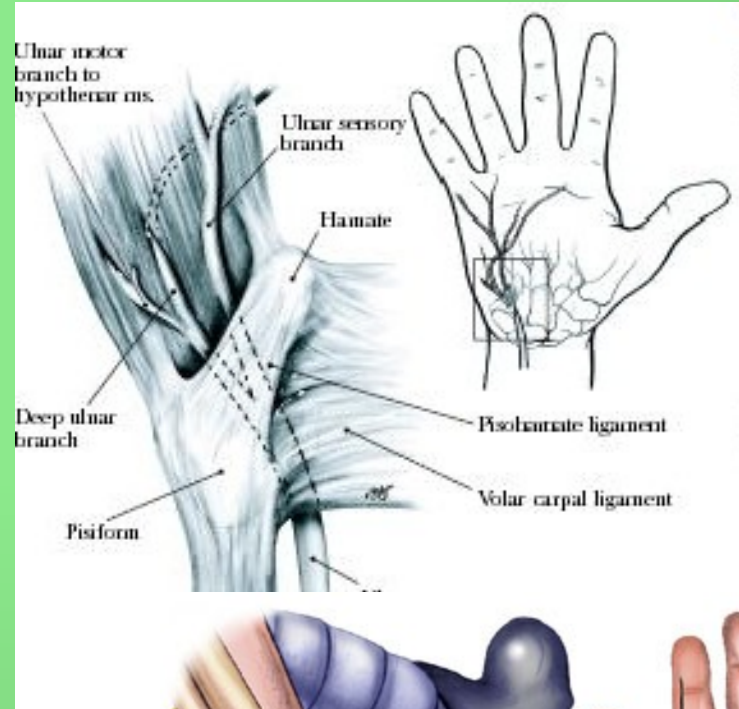
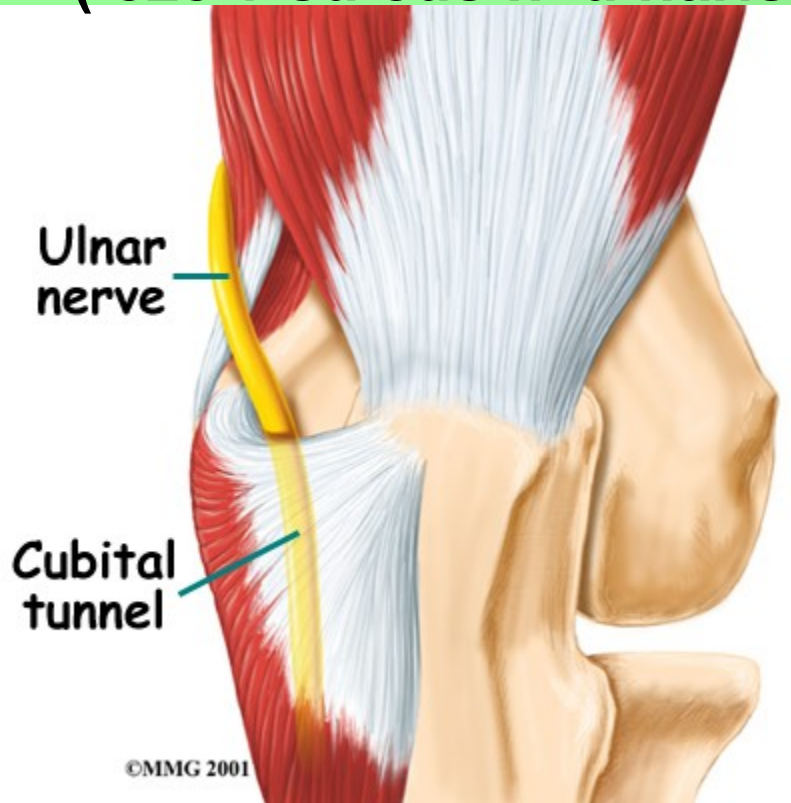


# Canalis cubitalis

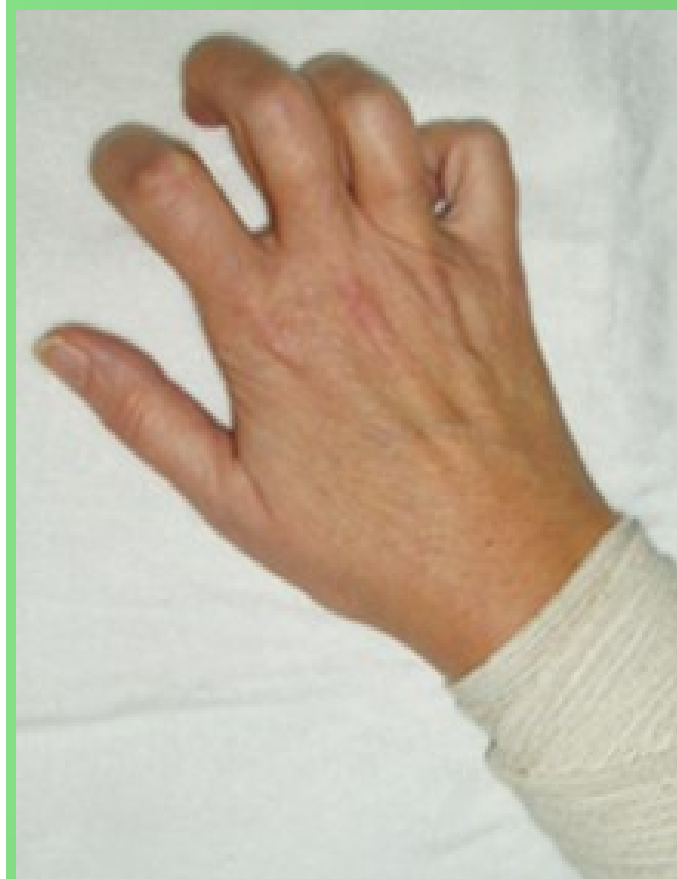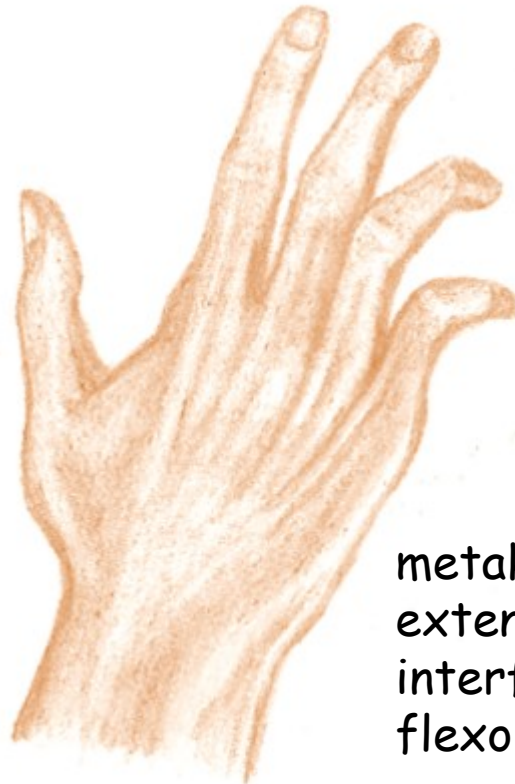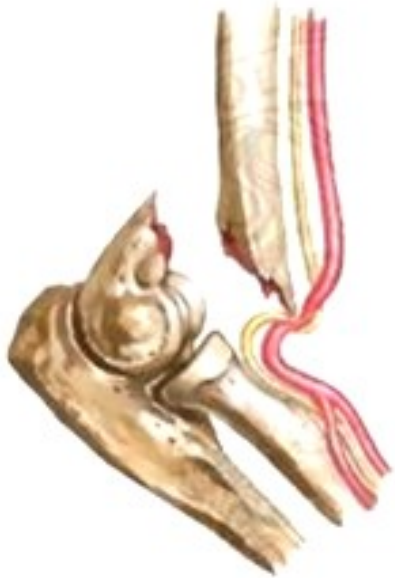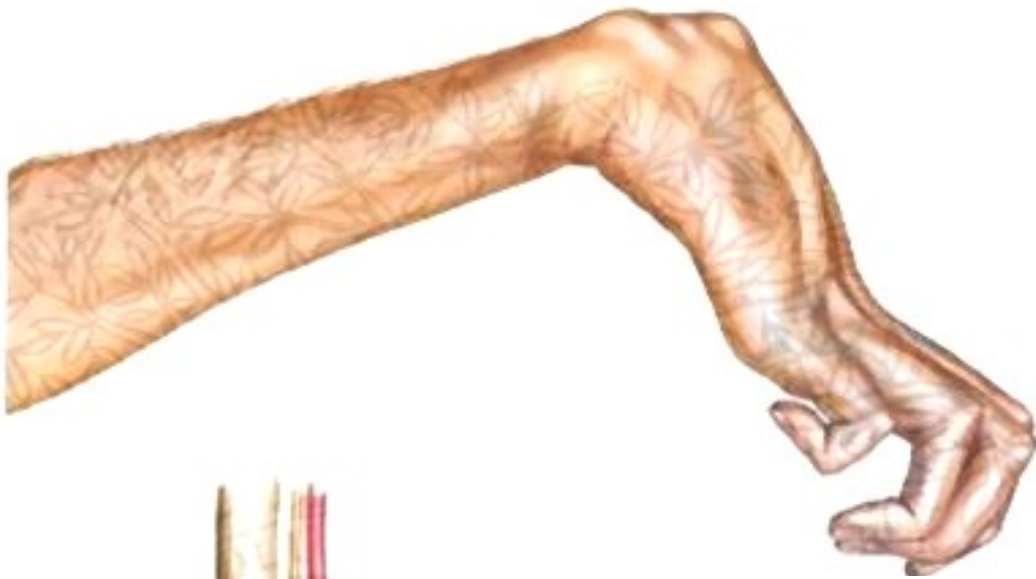-kubitální syndrom  
(léze v sulcus n. ulnaris)

# Guyonův kanálek

(mezi os pisiforme a hamulus ossis hamati)



# Dráповitá ruka



metakarpofalangeální klouby  
extendovány (převaha extenzorů),  
interfalangeální klouby ve flexi (převaha  
flexorů), palec abdukován.





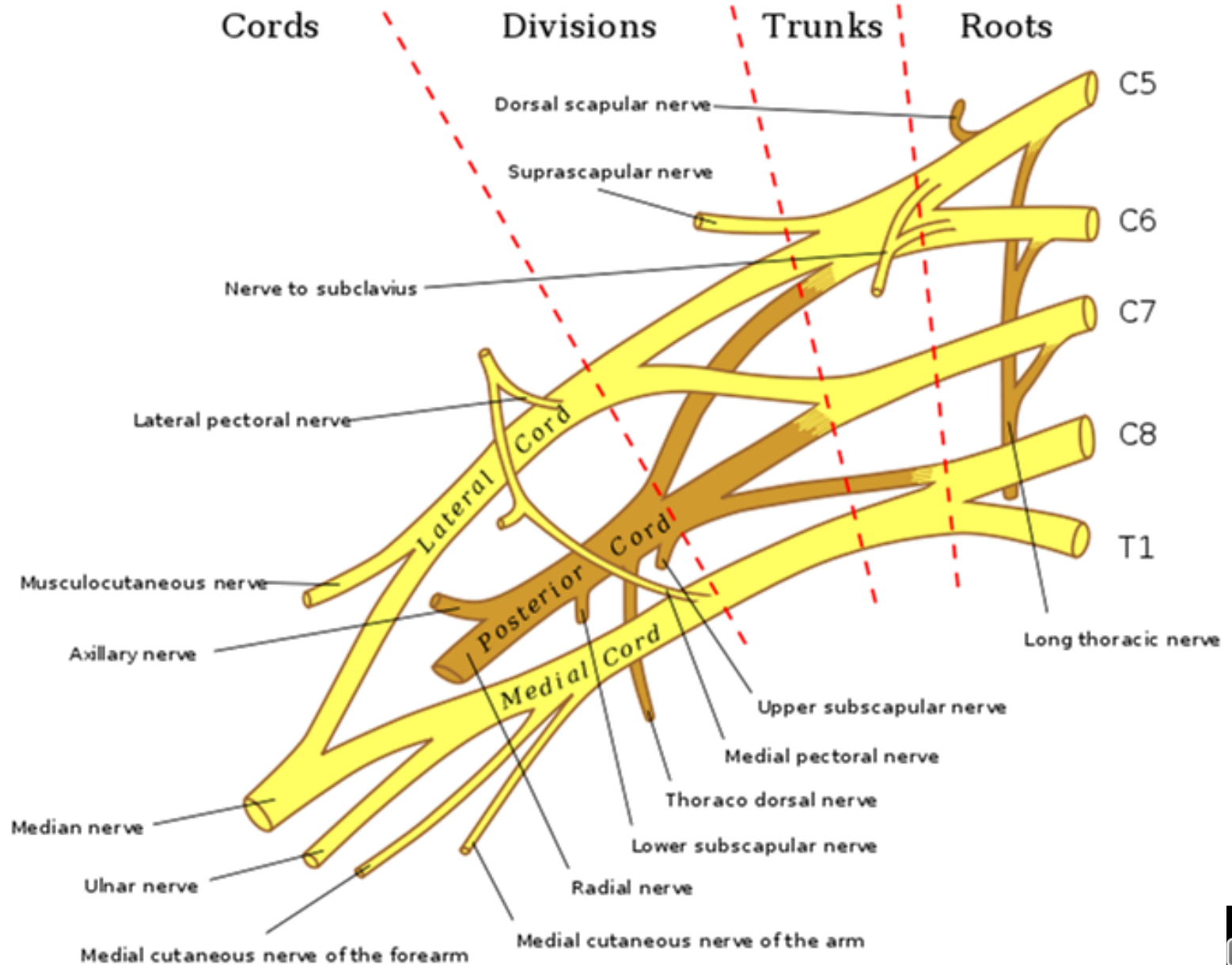
1 cm

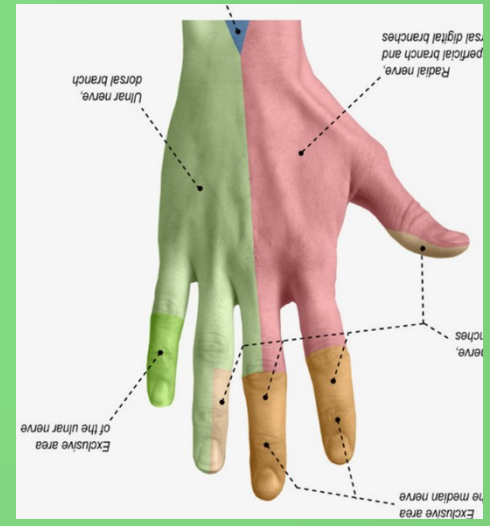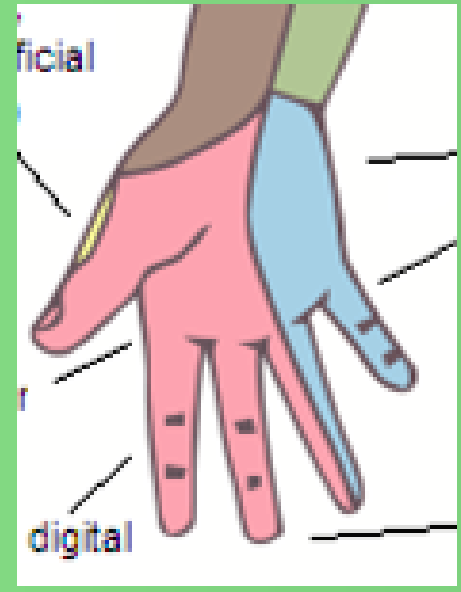
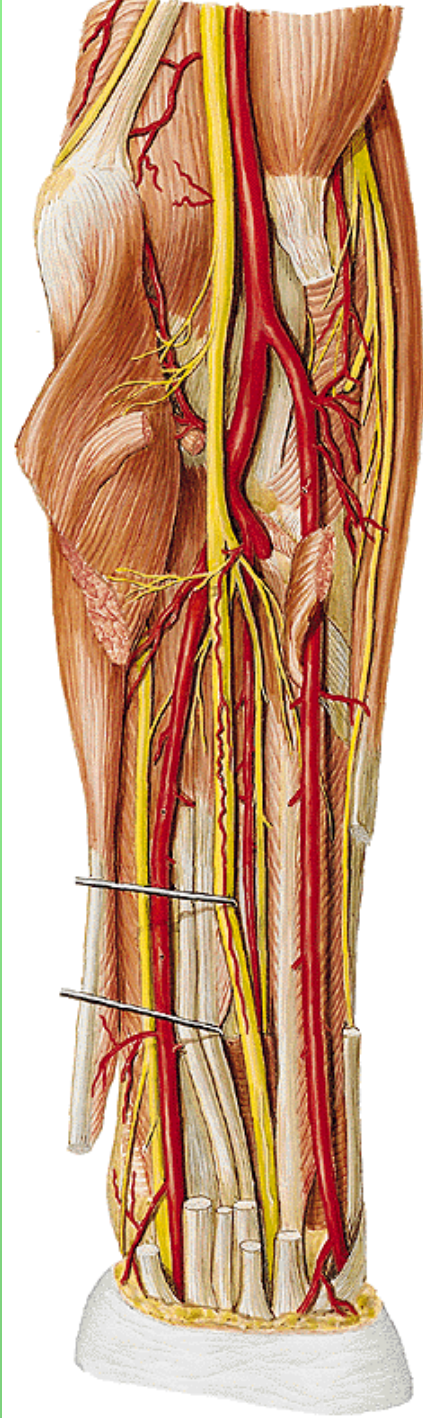
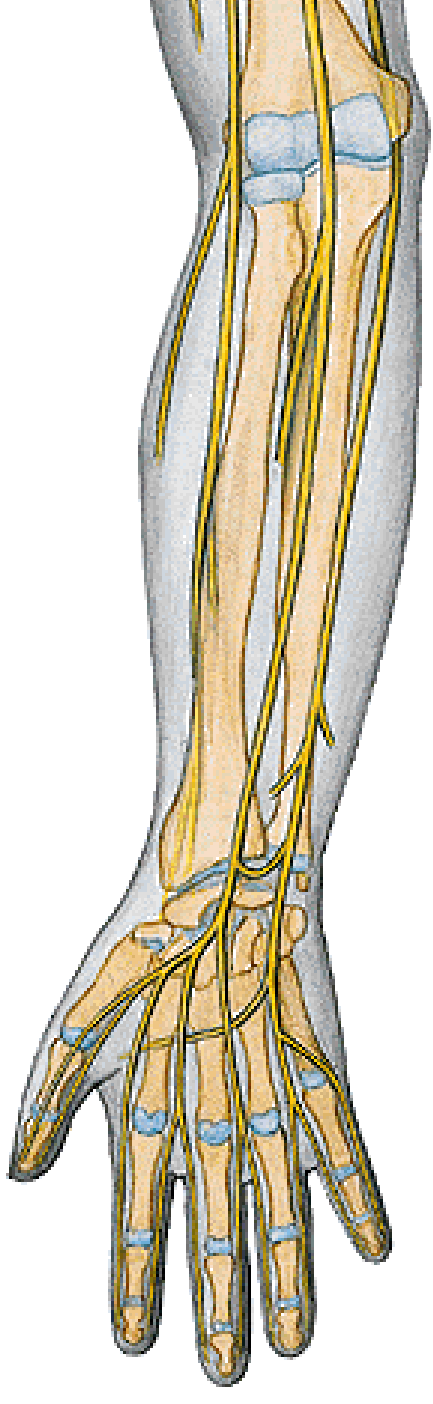
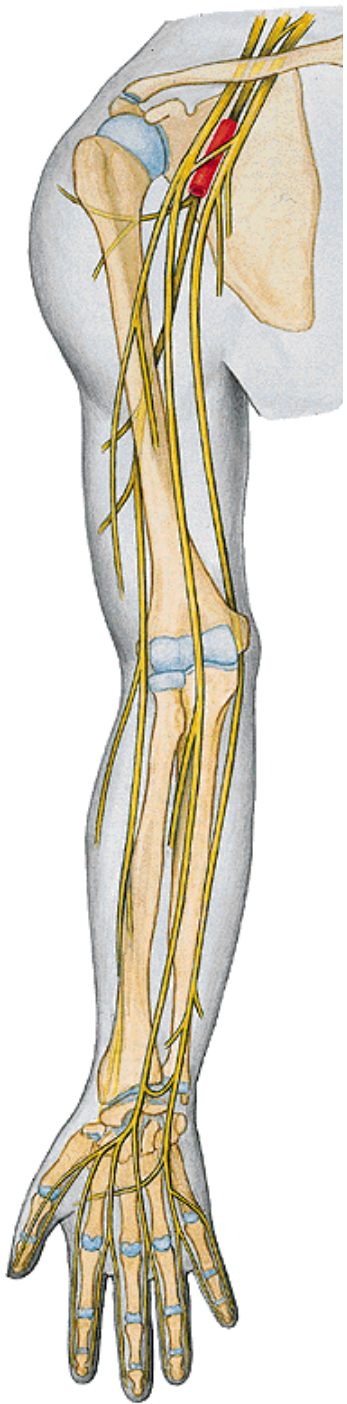
**HH**

**UH**

**NM**

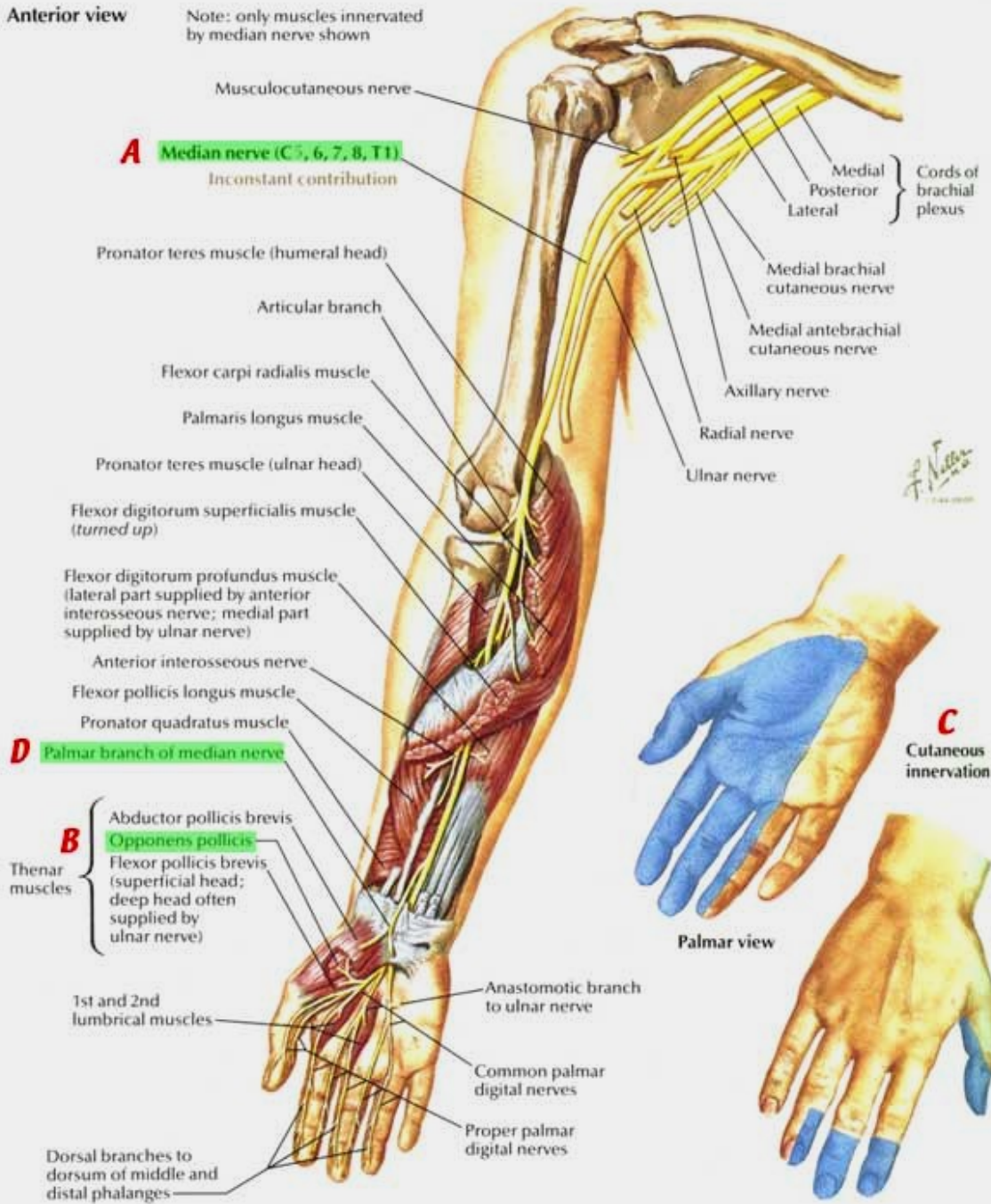


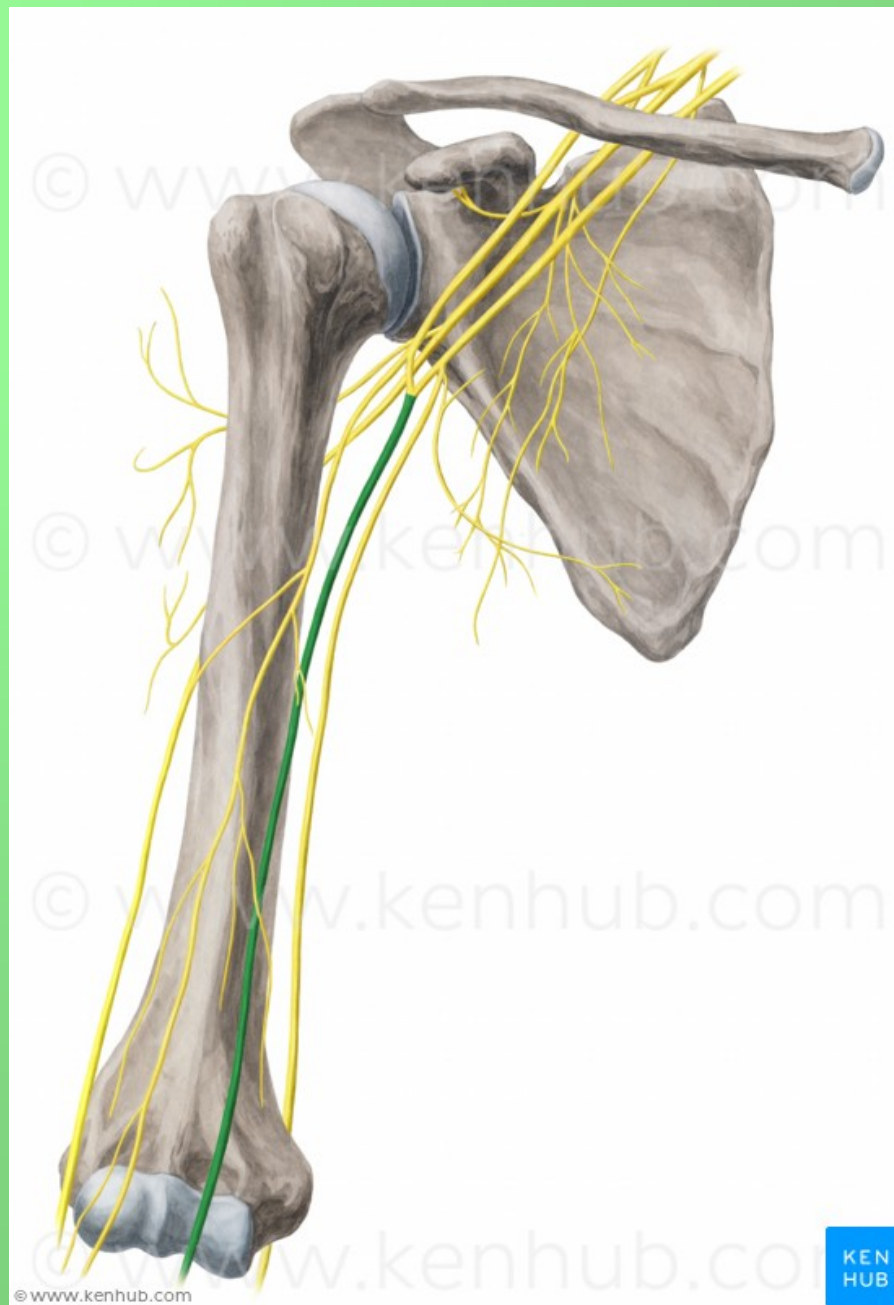




**Anterior view**

Note: only muscles innervated by median nerve shown



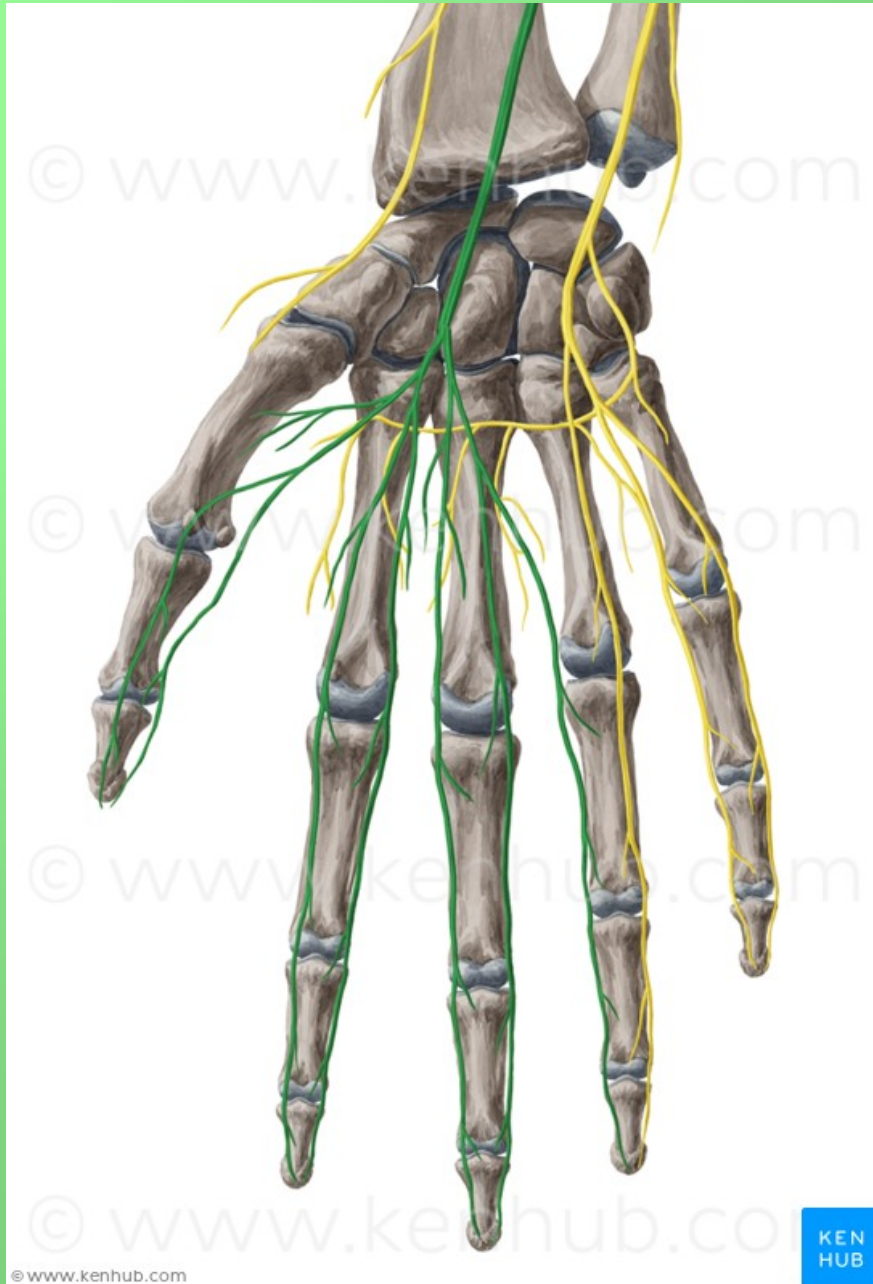


© www.kenhub.com

KEN  
HUB

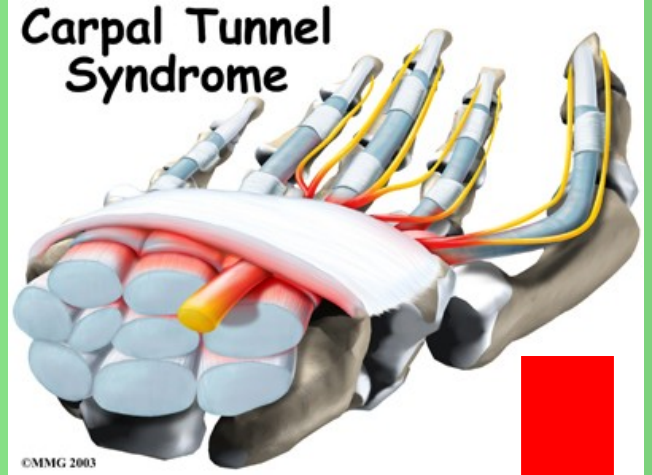




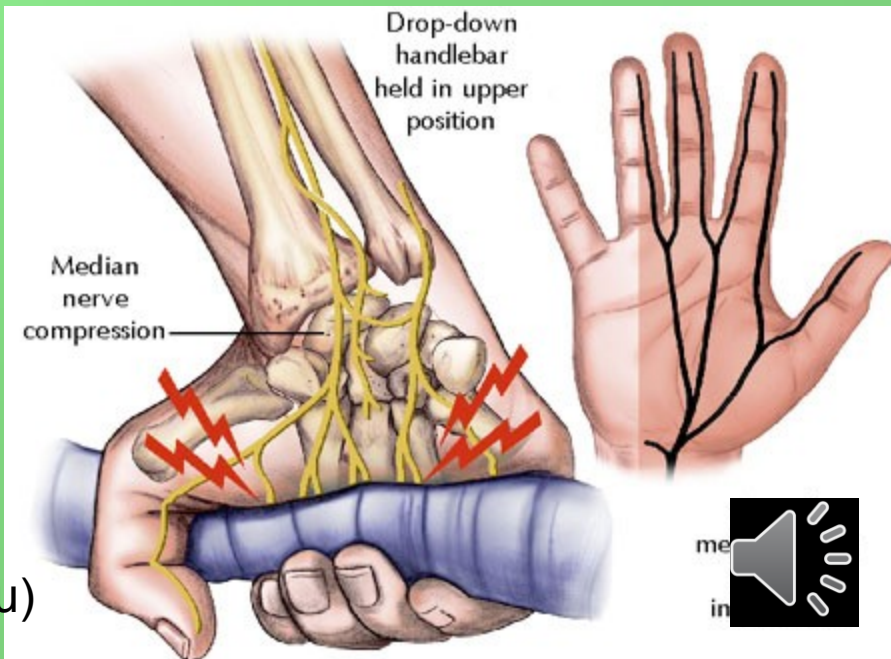
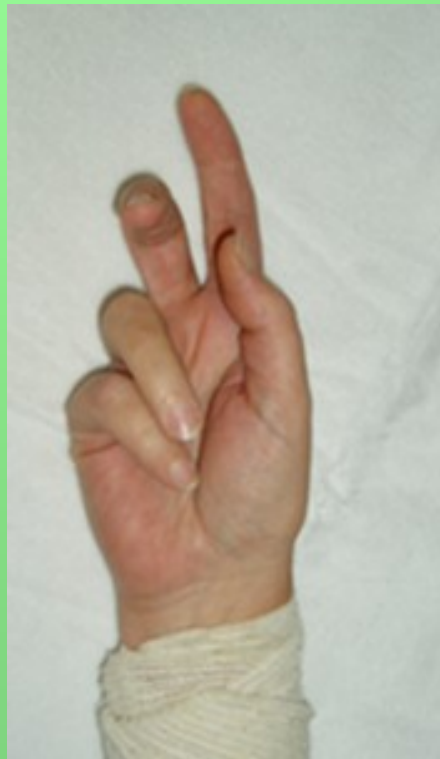
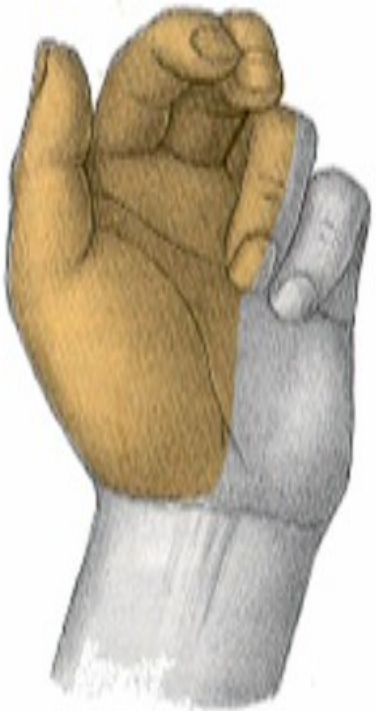
# Poškození nervu:

- sebevražedné pokusy (řezné poranění)
- patologické změny v karpálním tunelu
- chybí úchopový pohyb (opozice palce, zaškrábání ukazovákem)



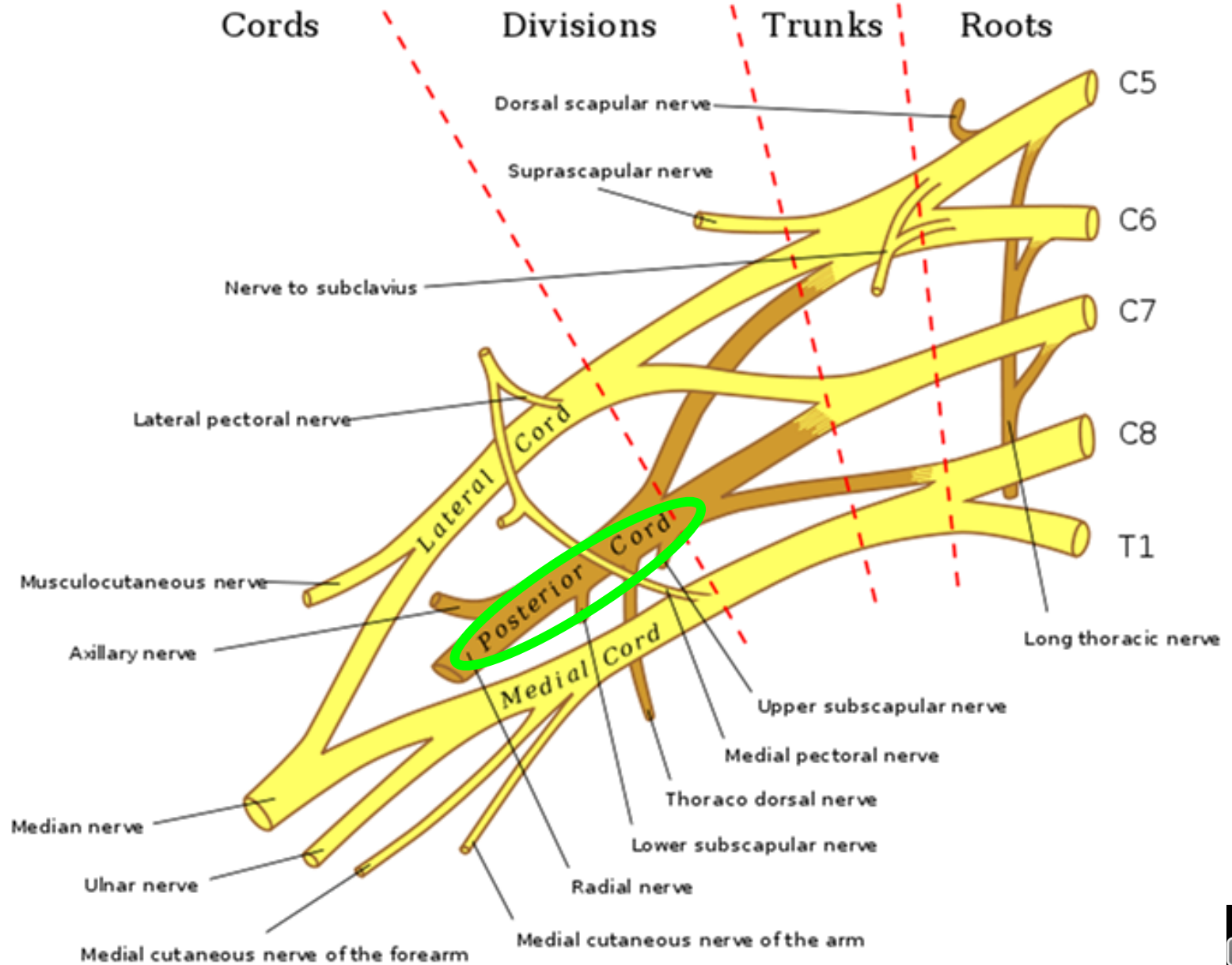
## Syndrom opičí ruky - vážne opozice palce



## Přísahající ruka

(neschopnost opozice palce a flexe 2. a 3. prstu)



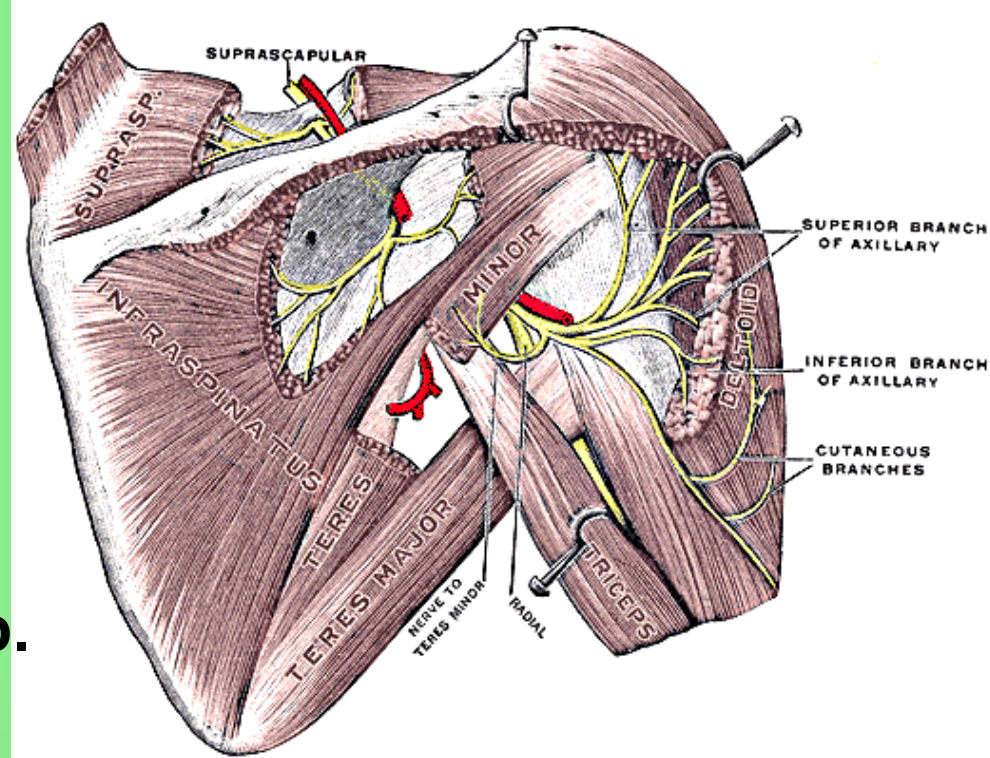


# Fasciculus posterior

## n. axillaris

foramen humerotricipitale  
(smíšený) (C5–6)

- rr. musculares
- rr. articulares
- n. cutaneus brachii lat. sup.



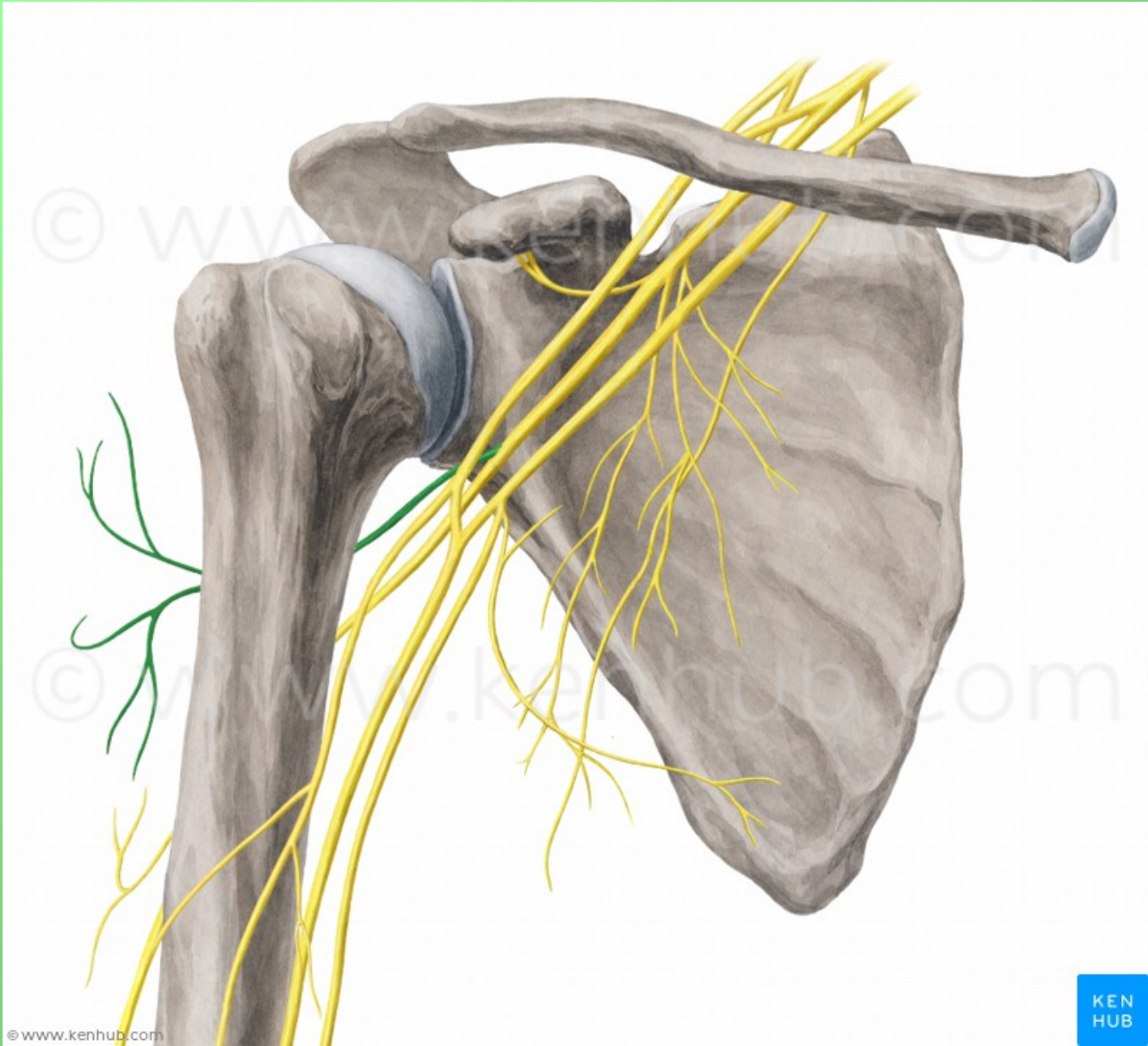
**Motoricky:** m. deltoideus, m. teres minor

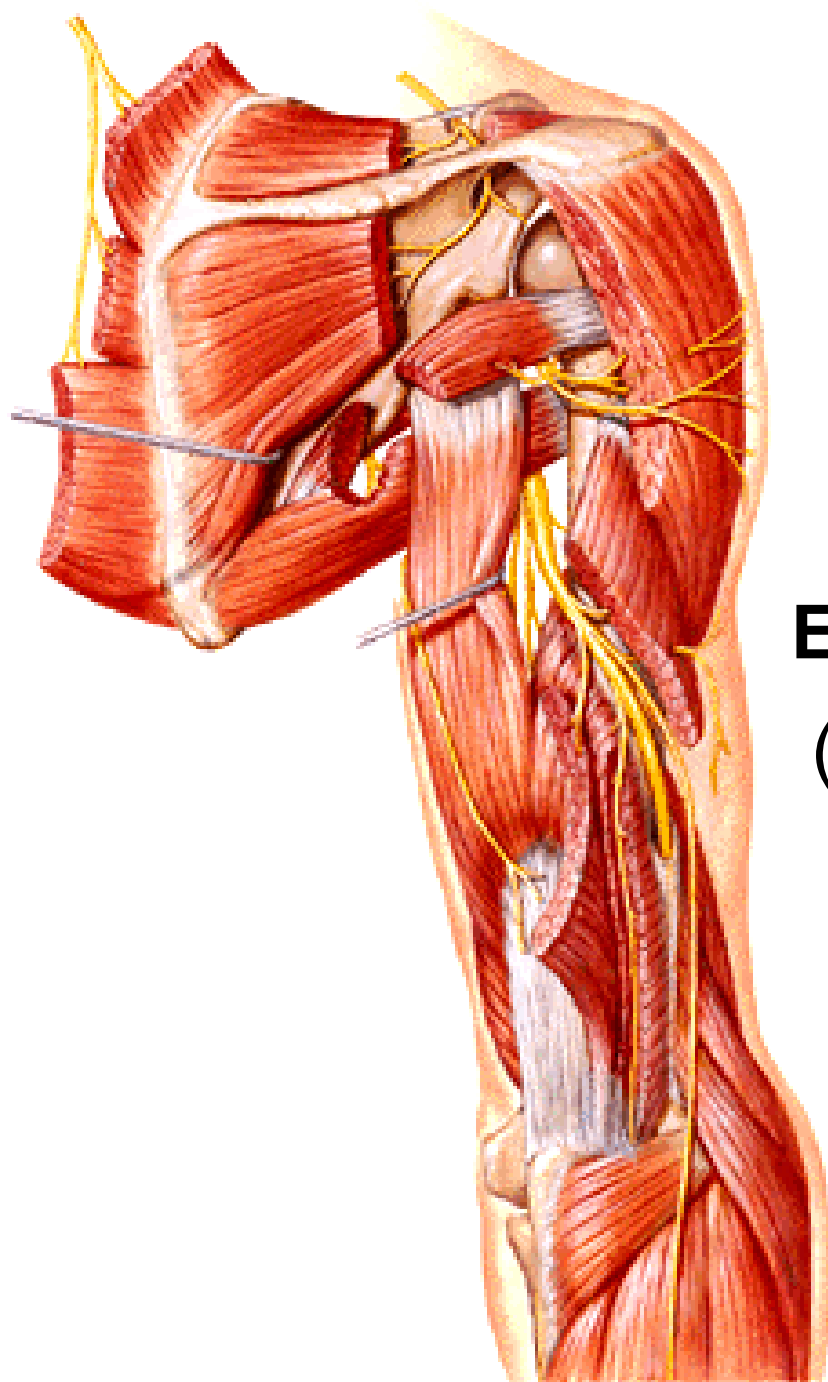
**Senzoricky:** oblast ramene

**Poškození nervu** (luxace, zlomenina v collum chirurgicum)

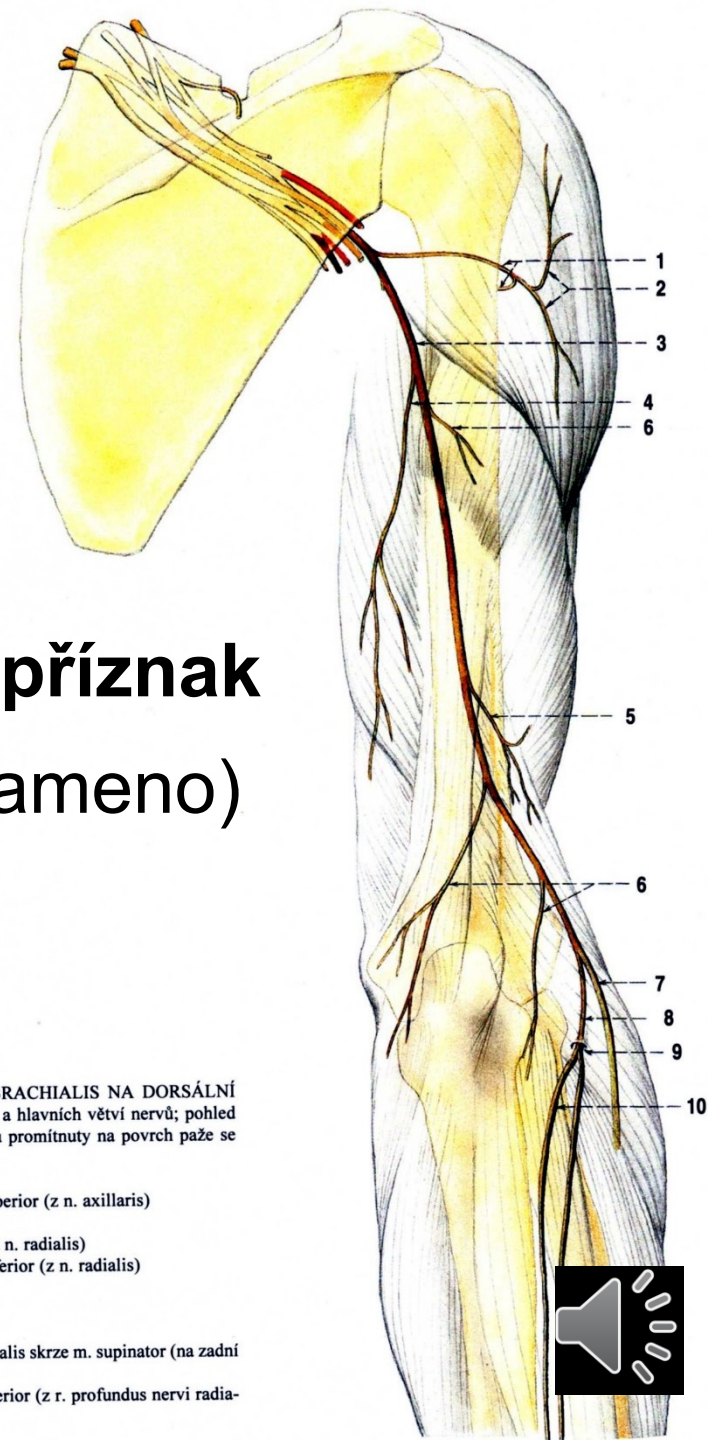
- chybí zevní rotace a abdukce paže do horizontály








## Epoletový příznak (pokleslé rameno)



Obr. 292. NERVY Z PLEXUS BRACHIALIS NA DORSÁLNÍ STRANĚ PAŽE; schéma průběhu a hlavních větví nervů; pohled zezadu na pravou paži; nervy jsou promítnuty na povrch paže se znázorněným skeletem

- 1 n. axillaris
- 2 n. cutaneus brachii lateralis superior (z n. axillaris)
- 3 n. radialis
- 4 n. cutaneus brachii posterior (z n. radialis)
- 5 n. cutaneus brachii lateralis inferior (z n. radialis)
- 6 rr. musculares (nervi radialis)
- 7 r. superficialis nervi radialis
- 8 r. profundus nervi radialis
- 9 průchod r. profundus nervi radialis skrze m. supinator (na zadní stranu předloktí)
- 10 n. interosseus antebrachii posterior (z r. profundus nervi radialis)



# n. radialis

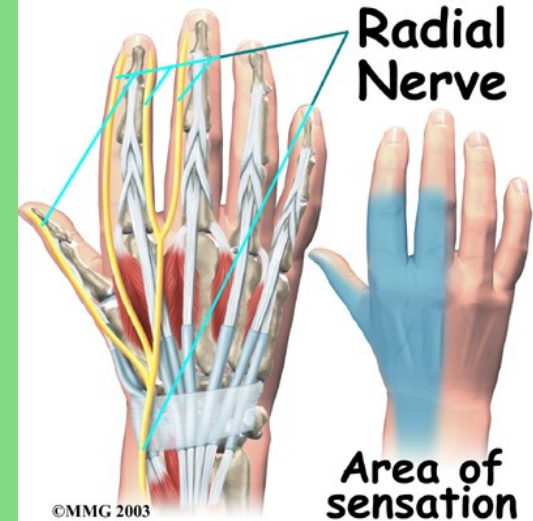
(smíšený) (C5–Th1)

- n. cutaneus brachii posterior
- n. cutaneus brachii lateralis inferior
- rr. musculares

- n. cutaneus antebrachii posterior

Větvení v oblasti lokte (mezi m. brachialis a m. brachioradialis)

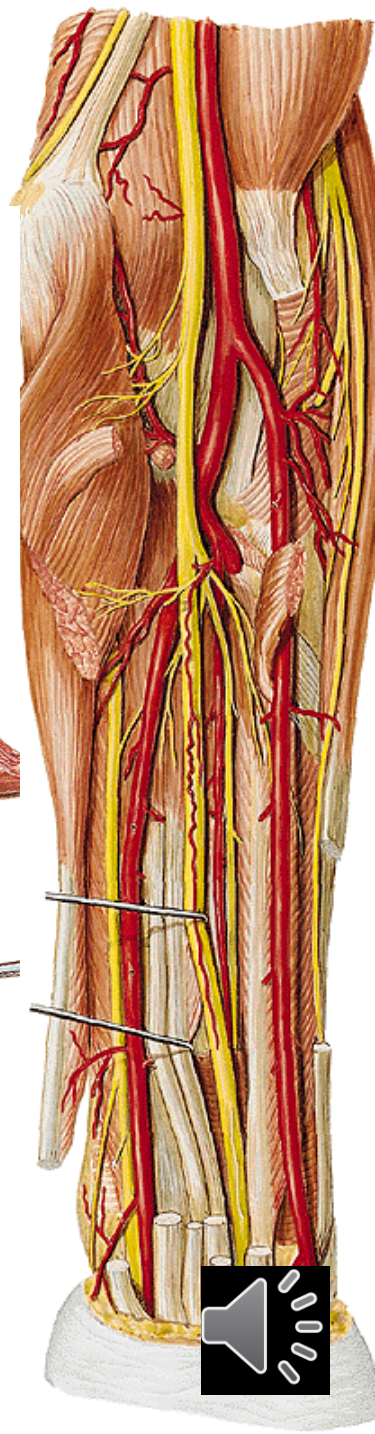
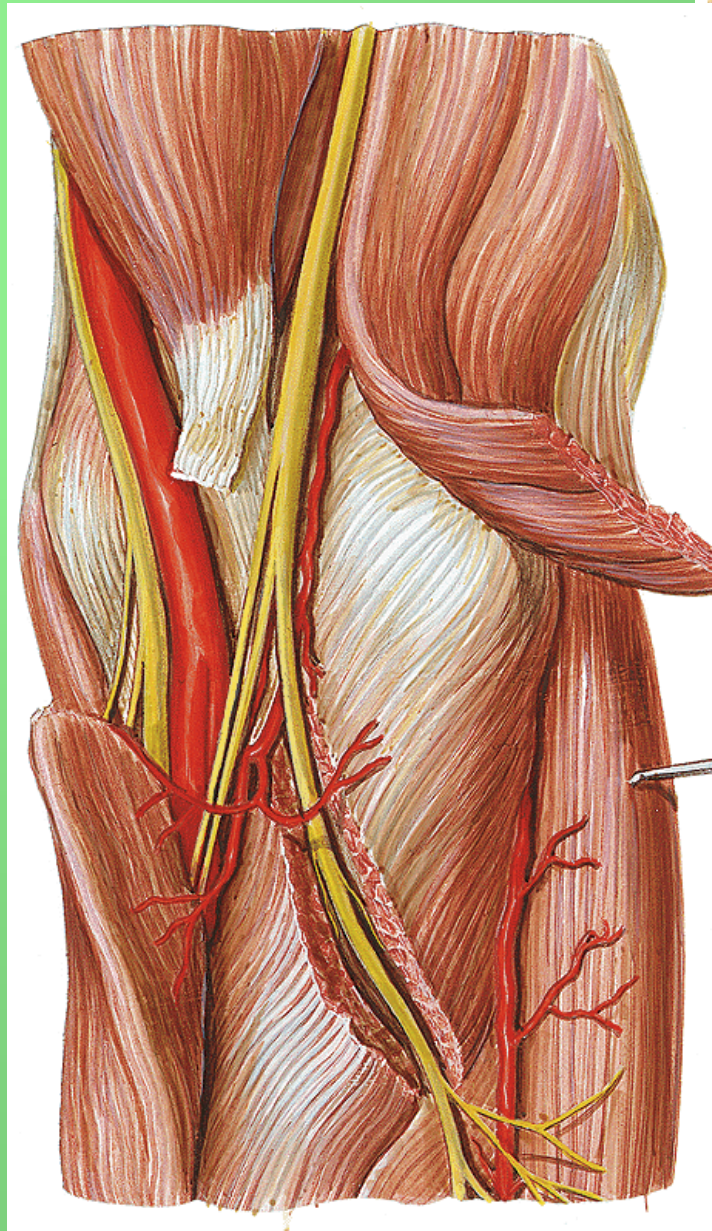
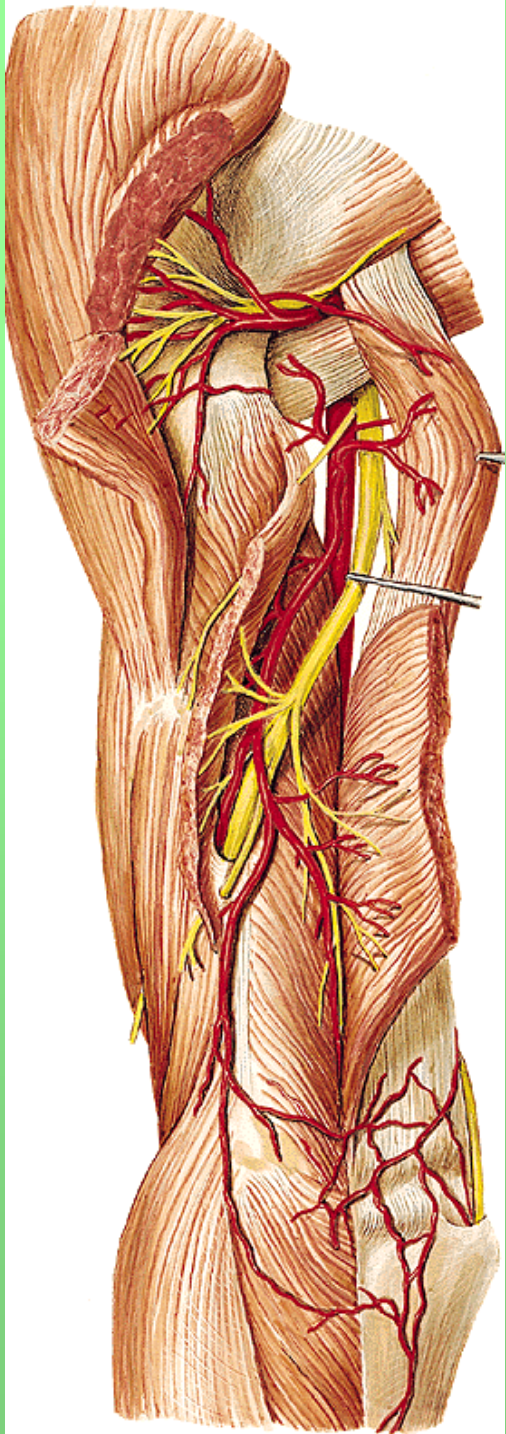
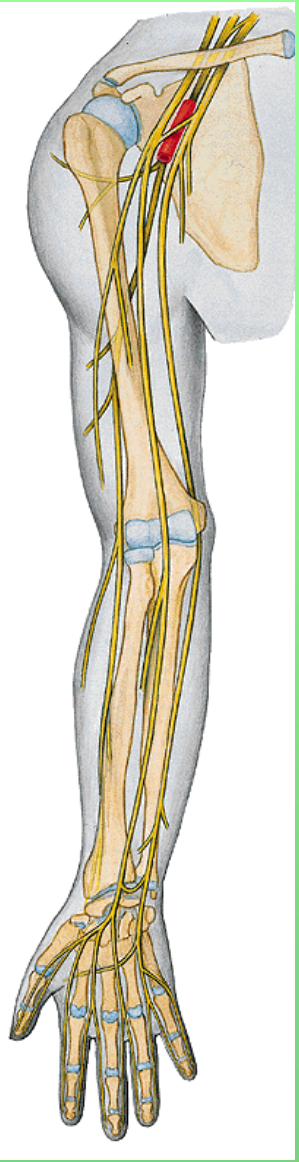
- r. profundus (svaly dorsální skupiny předloktí)
  - n. interosseus antebrachii posterior (senzitivní nerv)
- r. superficialis (pod m. brachioradialis na hřbet ruky)
  - nn. digitales dorsales



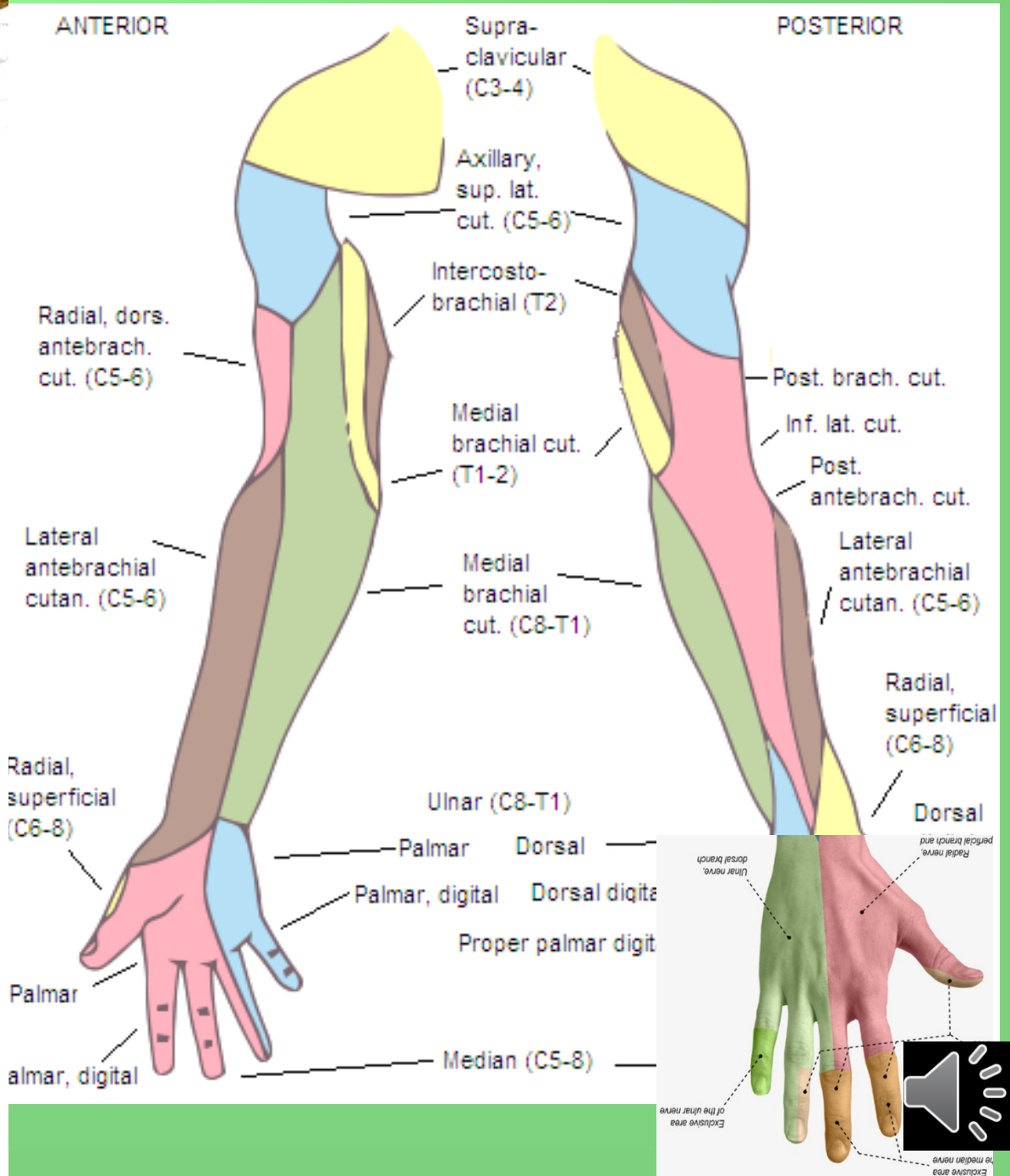
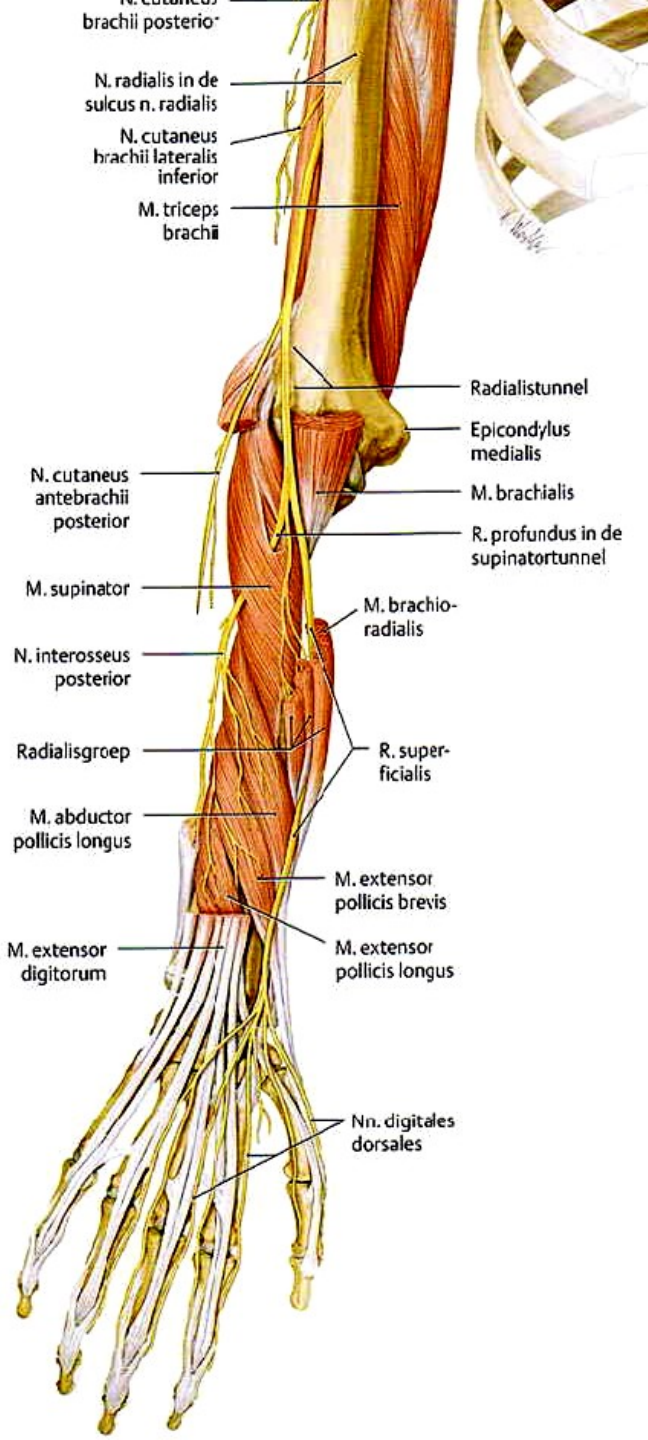
**Motoricky:** m. triceps brachii, laterální skupinu svalů předloktí, m. supinator, svaly zadní skupiny předloktí

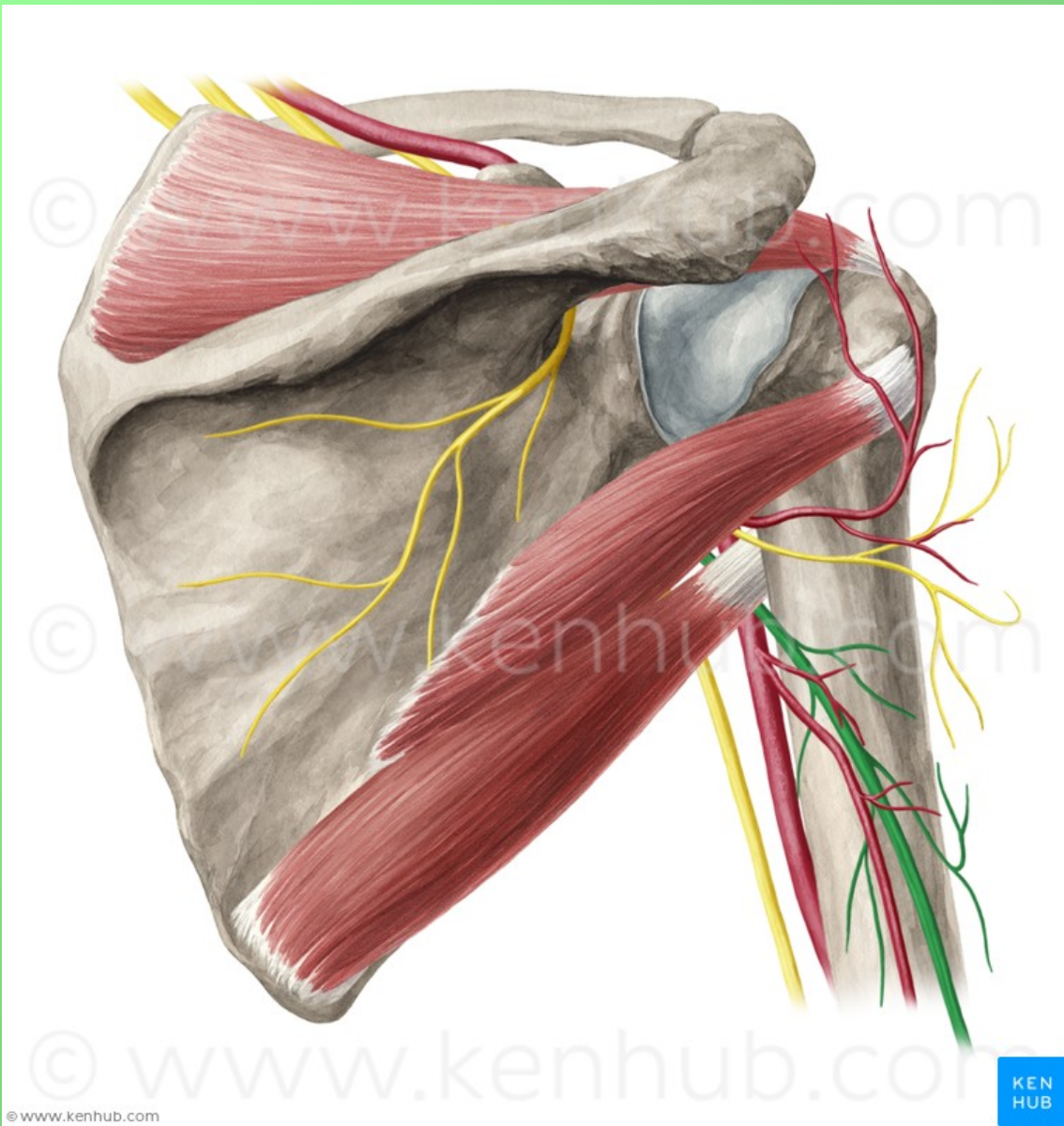
**Senzoricky:** hřbetní plocha zápěstí a 1., 2. a polovinu 3. prstu











© www.kenhub.com

KEN  
HUB



© www.kenhub.com

© www.kenhub.com

© www.kenhub.com

© www.kenhub.com

© www.kenhub.com

KEN  
HUB



© www.kenhub.com

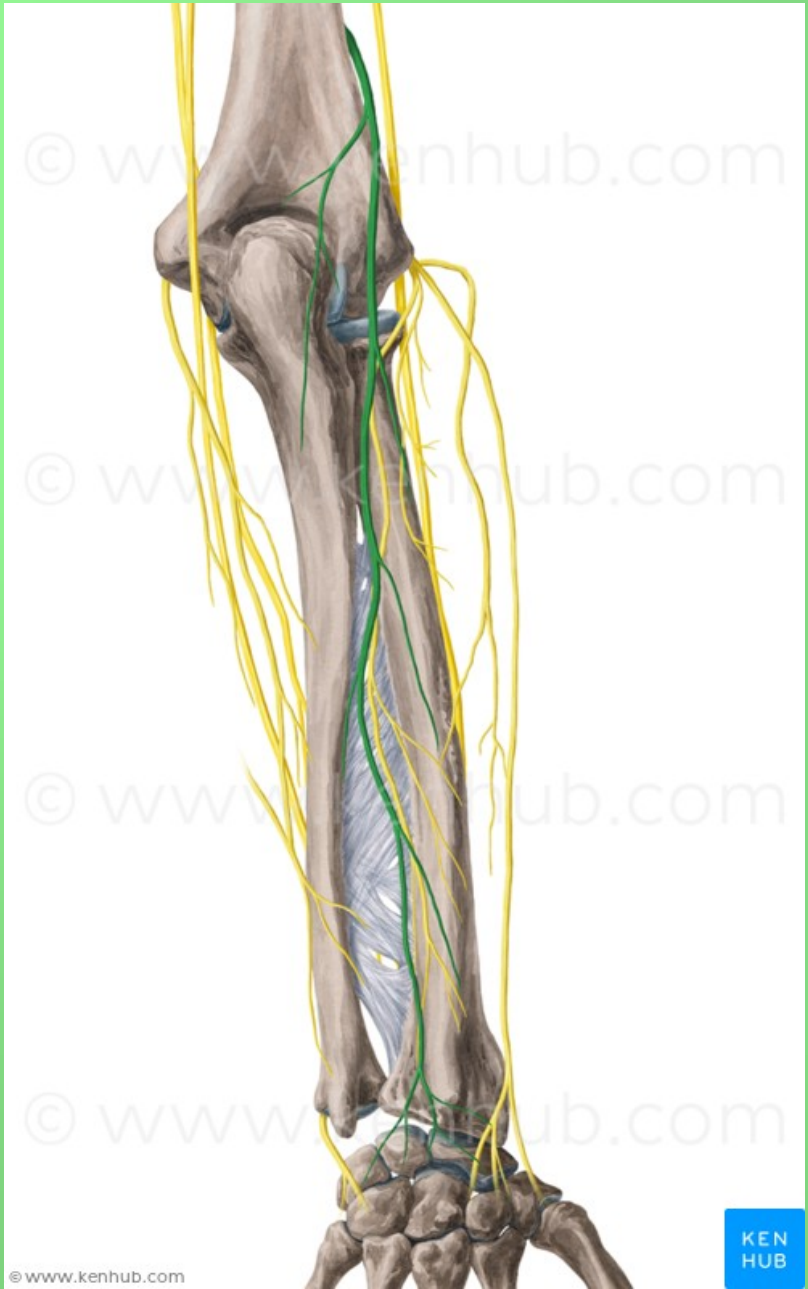
© www.kenhub.com

© www.kenhub.com

© www.kenhub.com

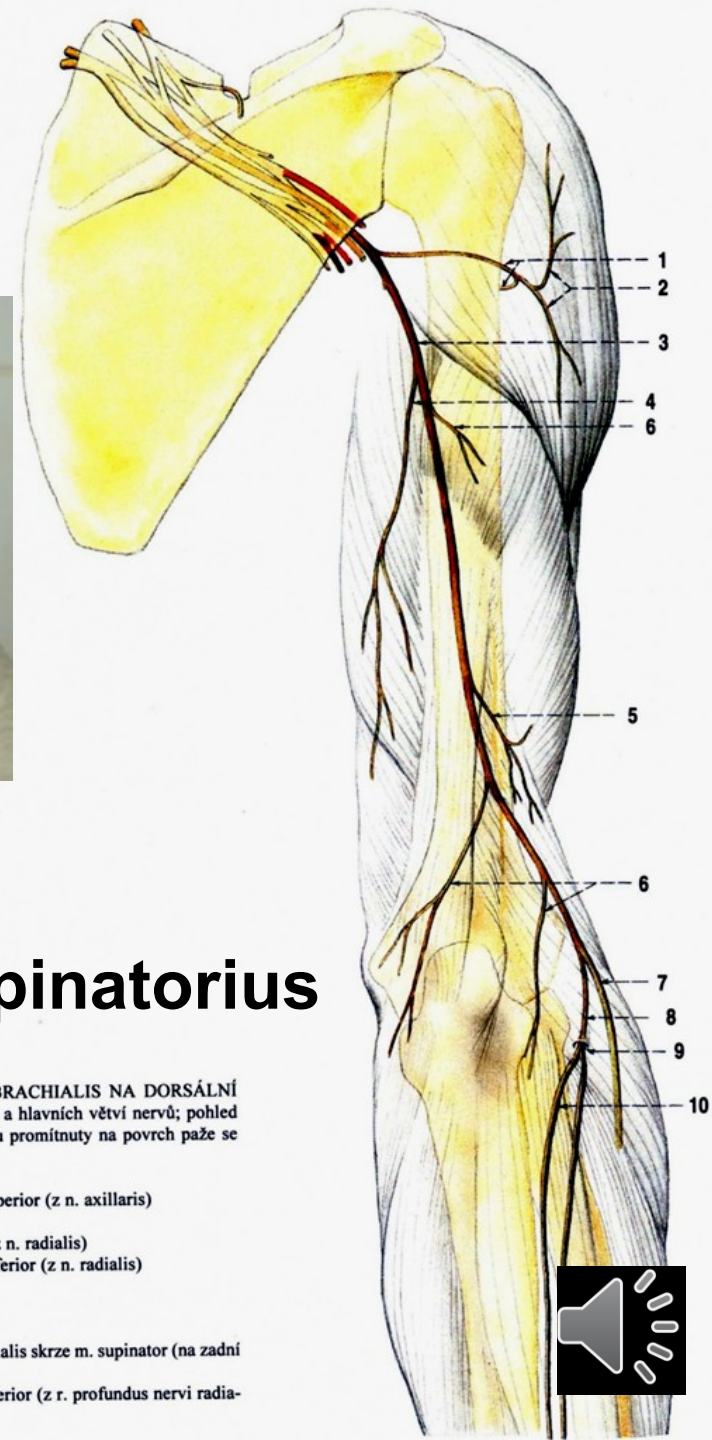
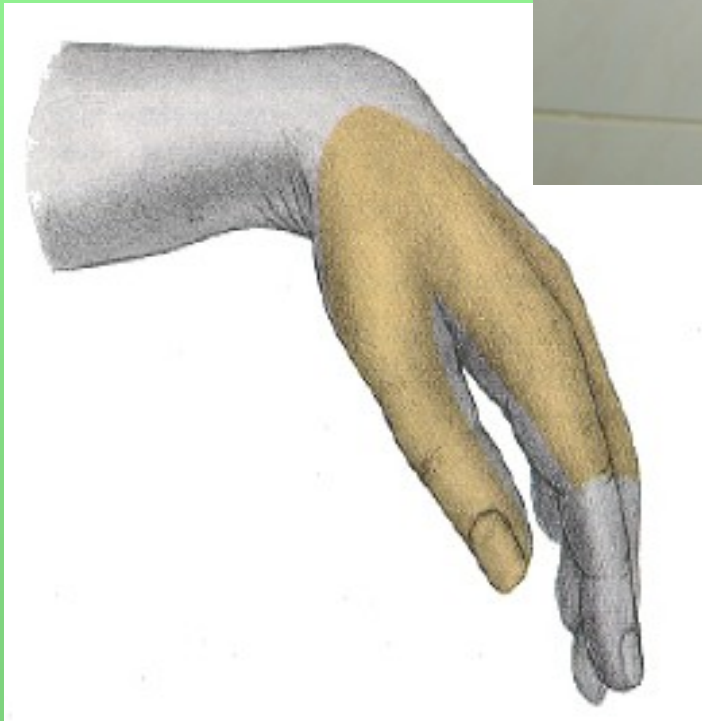
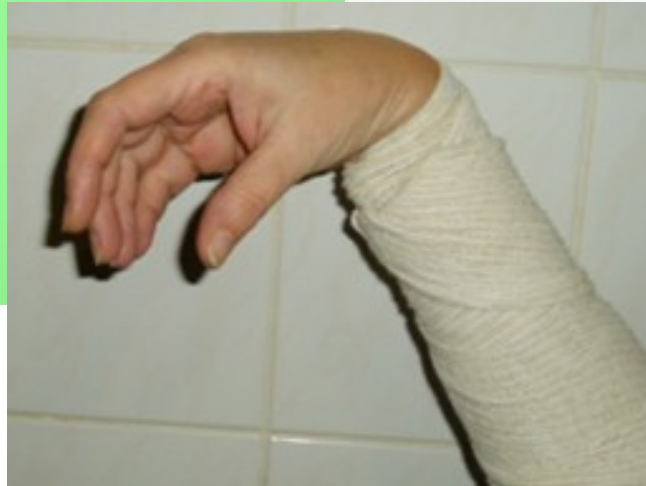© www.kenhub.com

KEN  
HUB



# Poranění nervu: na paži (zlomeniny)


- obrna extensorů ruky přepadá palmárně



## Canalis supinatorius

Obr. 292. NERVY Z PLEXUS BRACHIALIS NA DORSÁLNÍ STRANĚ PAŽE; schéma průběhu a hlavních větví nervů; pohled zezadu na pravou paži; nervy jsou promítnuty na povrch paže se znázorněným skeletem

- 1 n. axillaris
- 2 n. cutaneus brachii lateralis superior (z n. axillaris)
- 3 n. radialis
- 4 n. cutaneus brachii posterior (z n. radialis)
- 5 n. cutaneus brachii lateralis inferior (z n. radialis)
- 6 rr. musculares (nervi radialis)
- 7 r. superficialis nervi radialis
- 8 r. profundus nervi radialis
- 9 průchod r. profundus nervi radialis skrze m. supinator (na zadní stranu předloktí)
- 10 n. interosseus antebrachii posterior (z r. profundus nervi radialis)

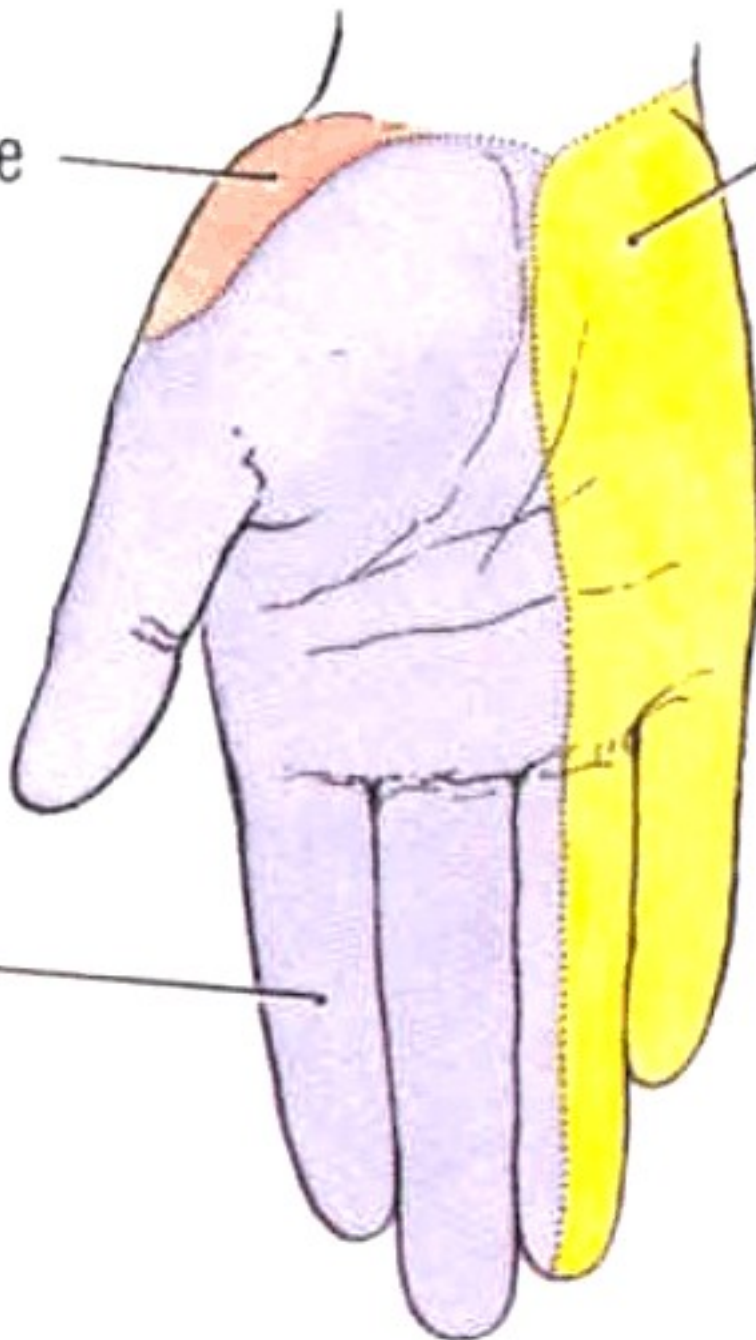


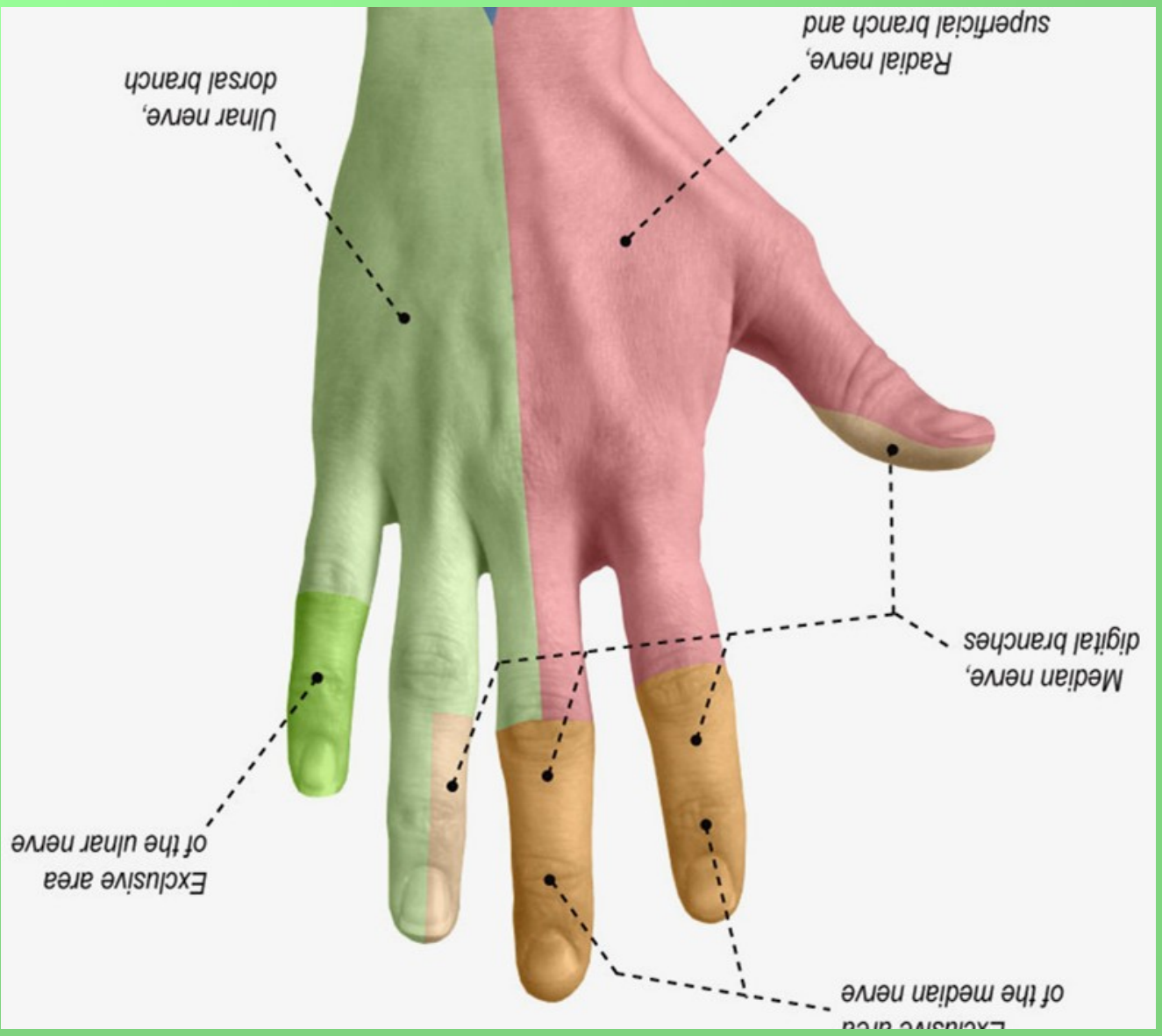
Syndrom labutí šíje

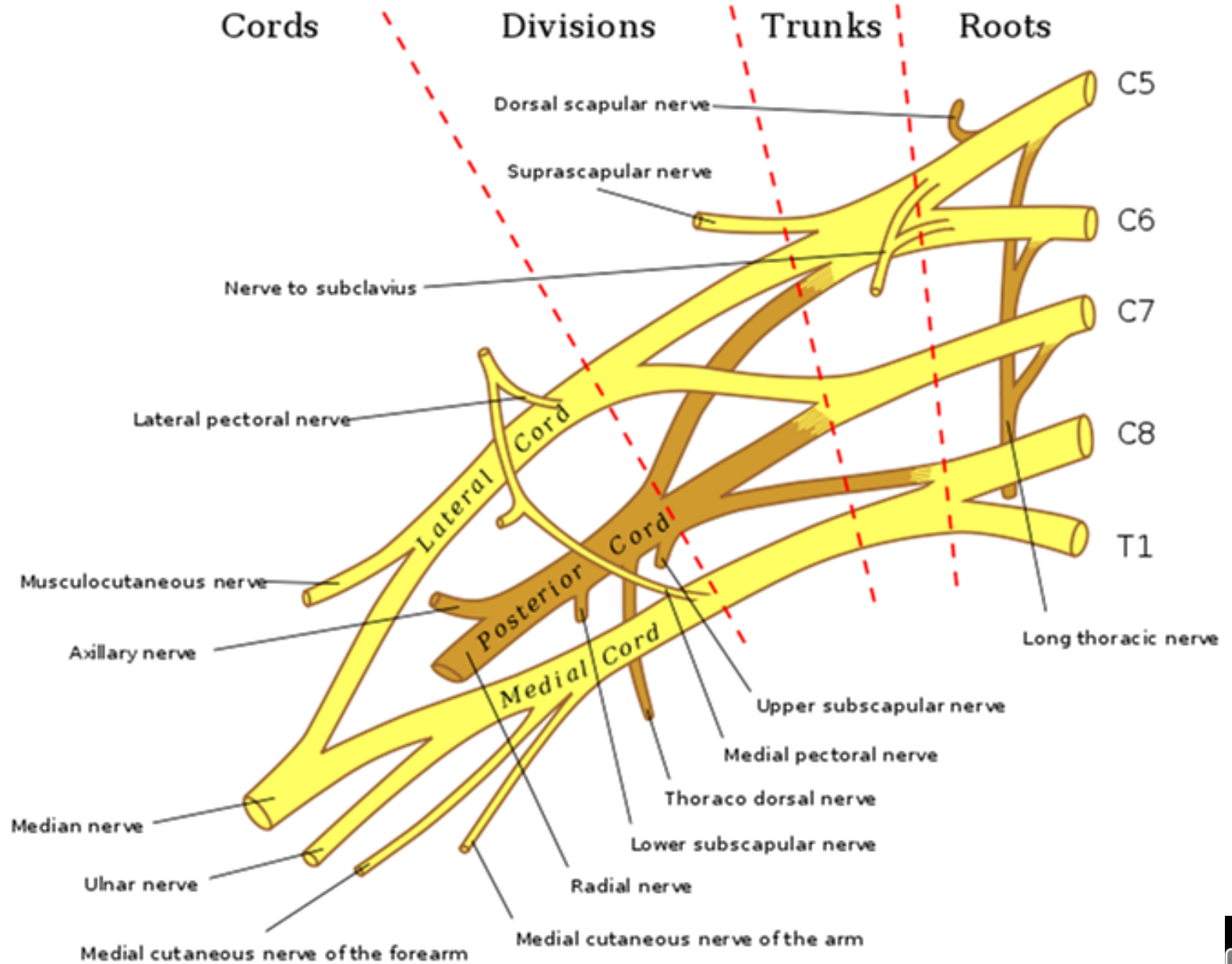
Radial nerve

Ulnar nerve

Median nerve



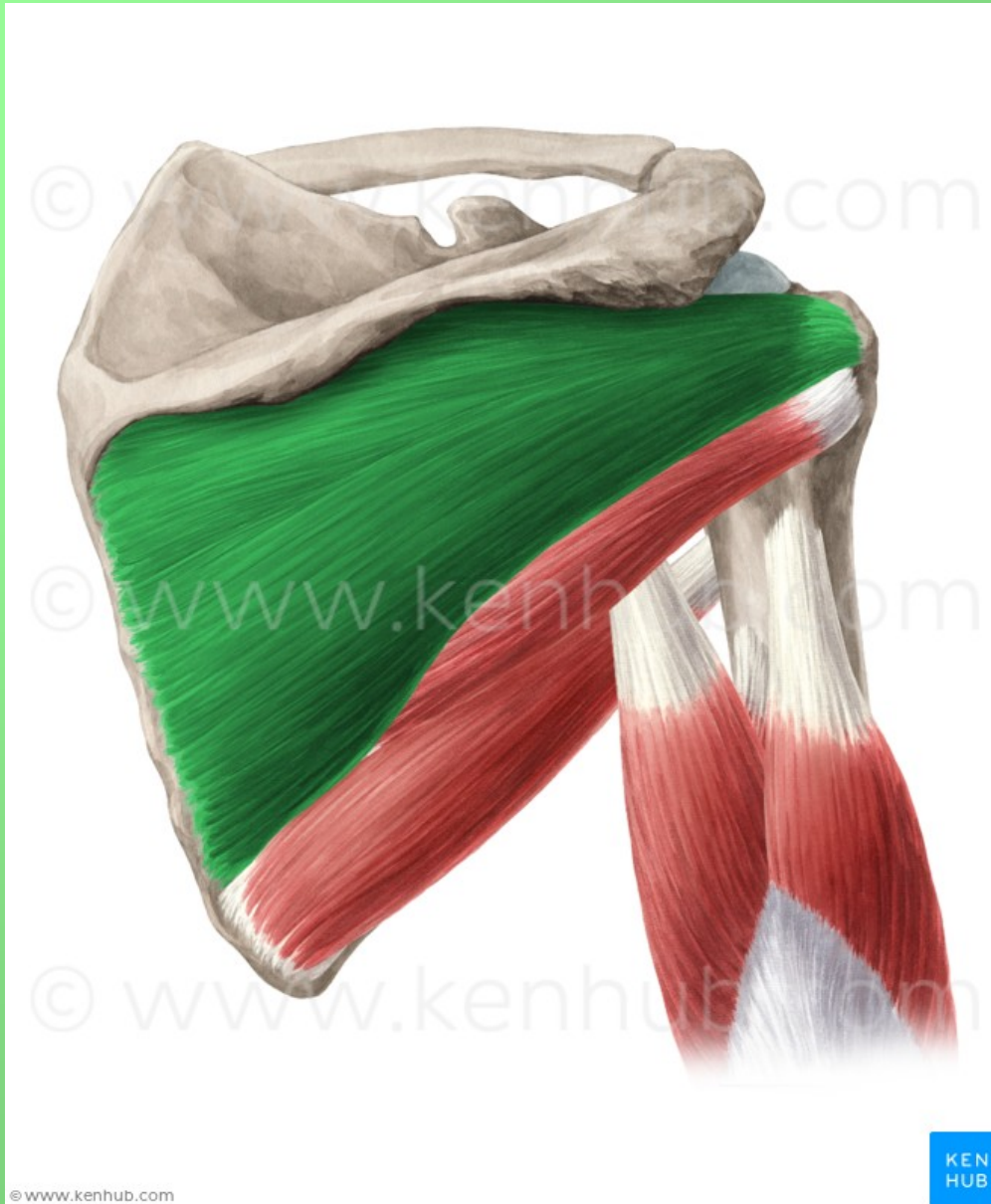


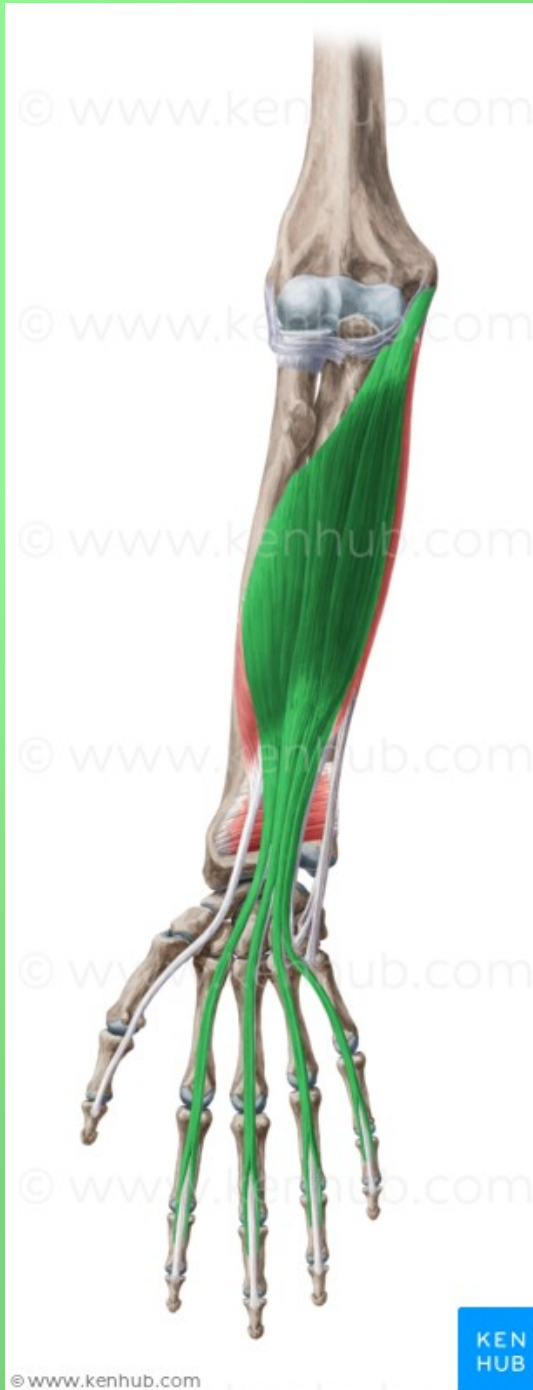



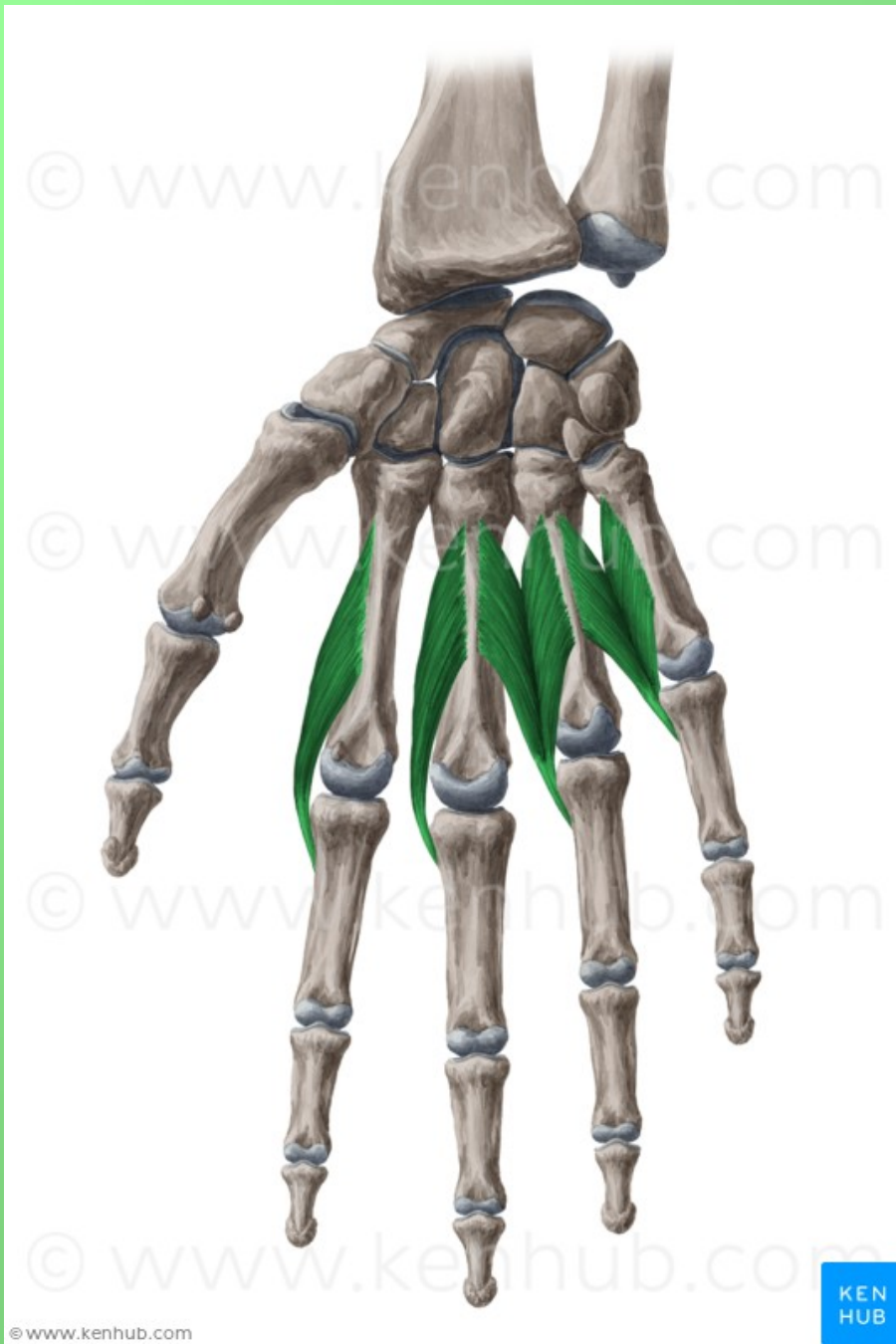
- **Obrázky:**
- **Atlas der Anatomie des Menschen/Sobotta. Putz,R., und Pabst,R. 20. Auflage. München:Urban & Schwarzenberg, 1993**
- **Netter: Interactive Atlas of Human Anatomy.**
- **Naňka, Elišková: Přehled anatomie. Galén, Praha 2009.**
- **Čihák: Anatomie I, II, III.**
- **Drake et al: Gray's Anatomy for Students. 2010**



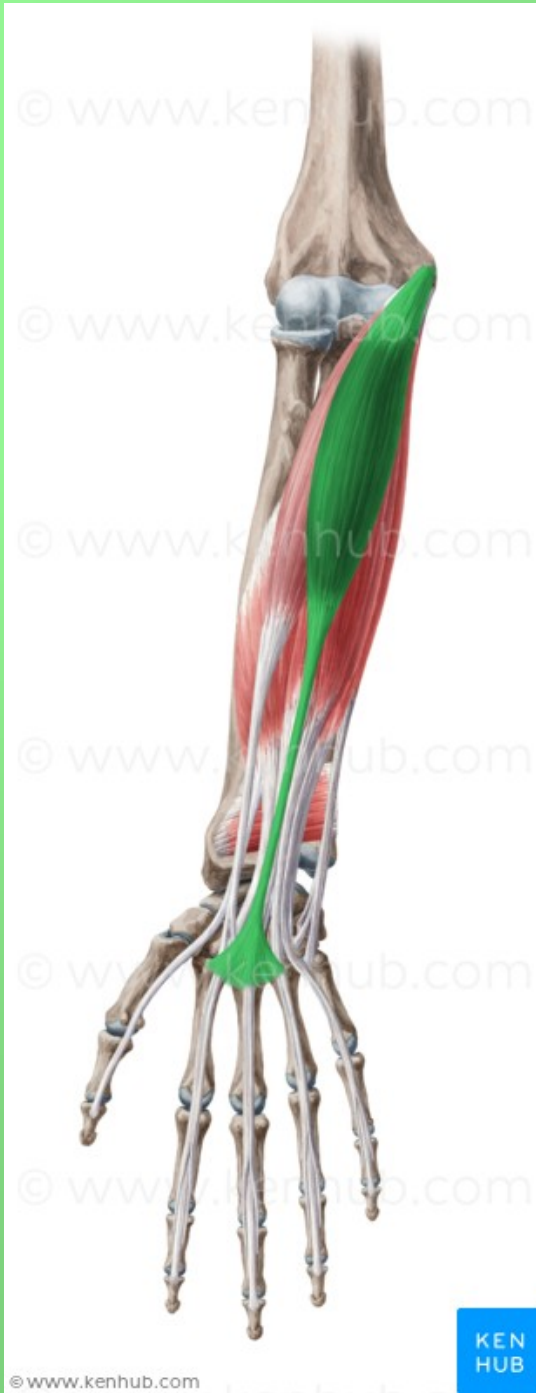

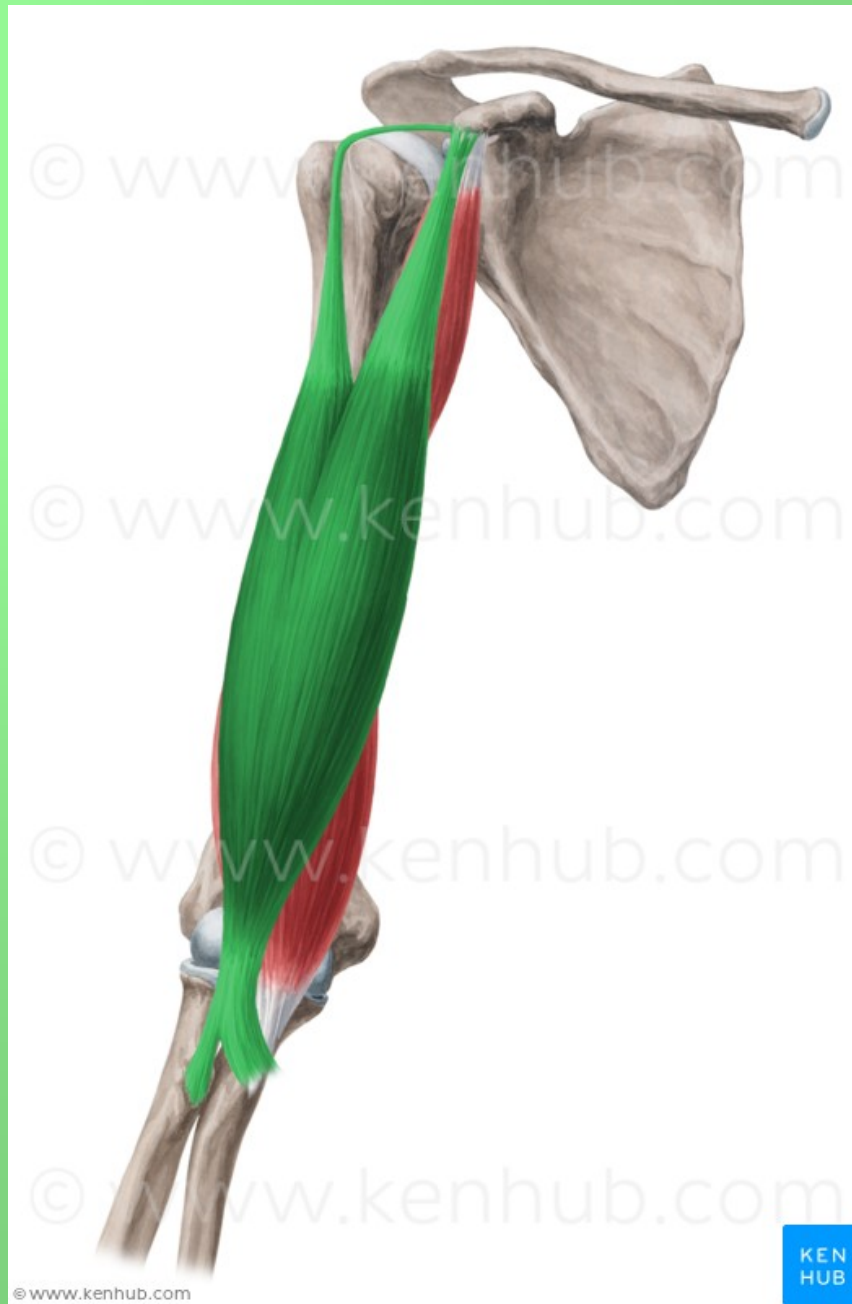


2

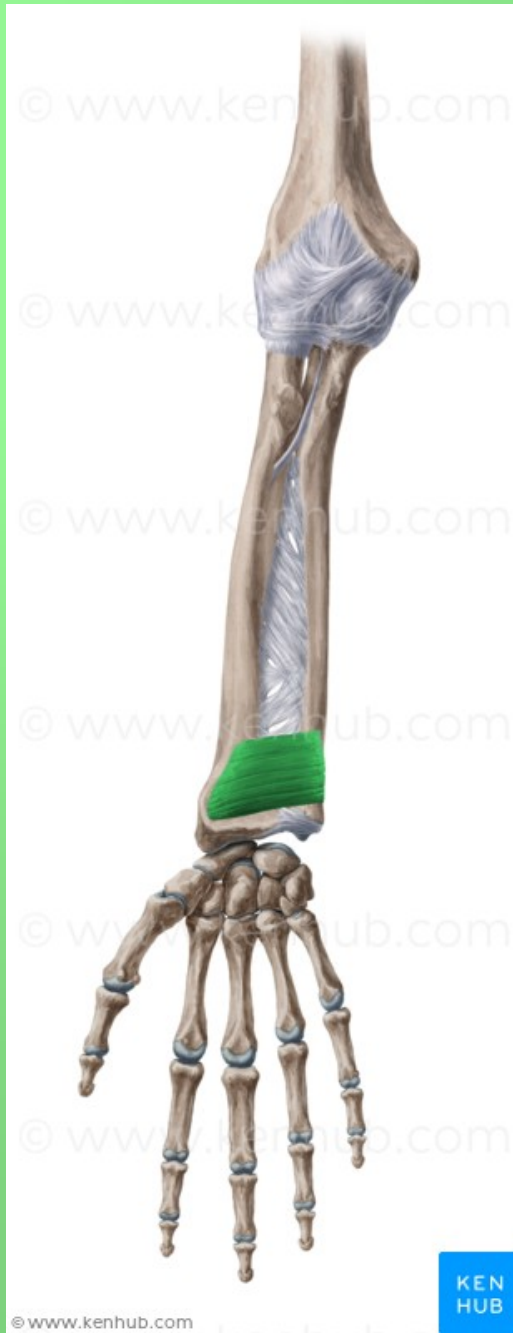

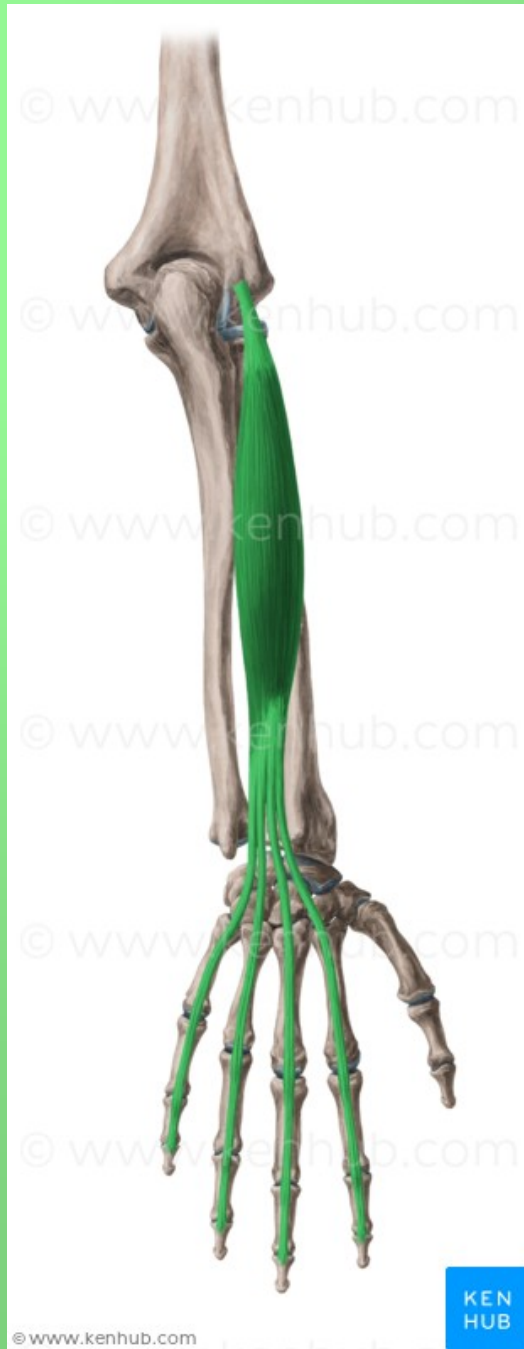3





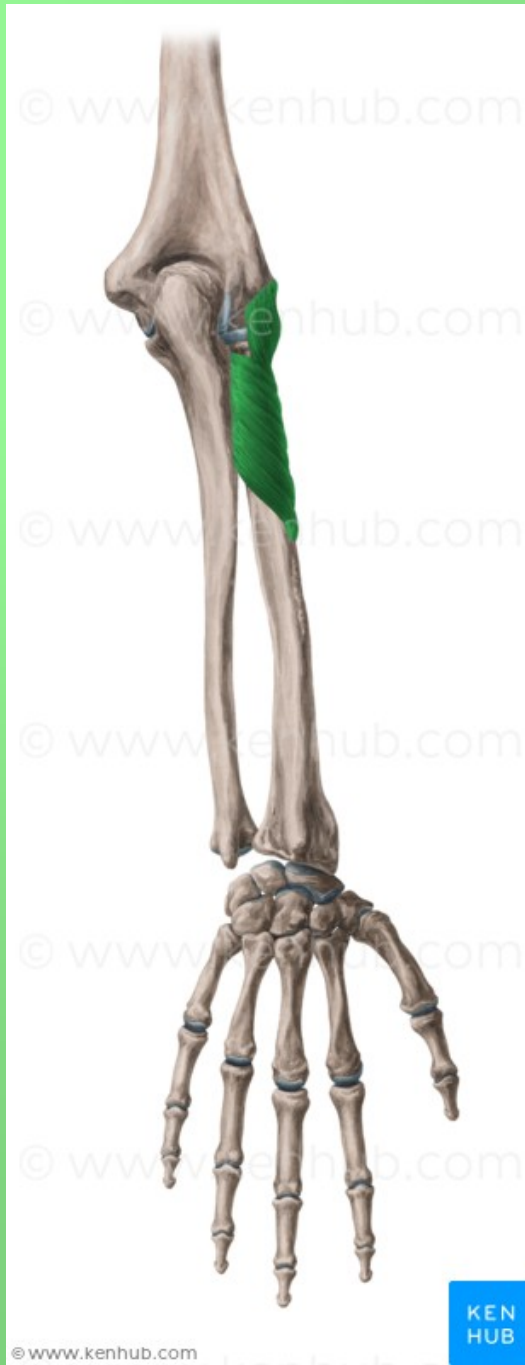5

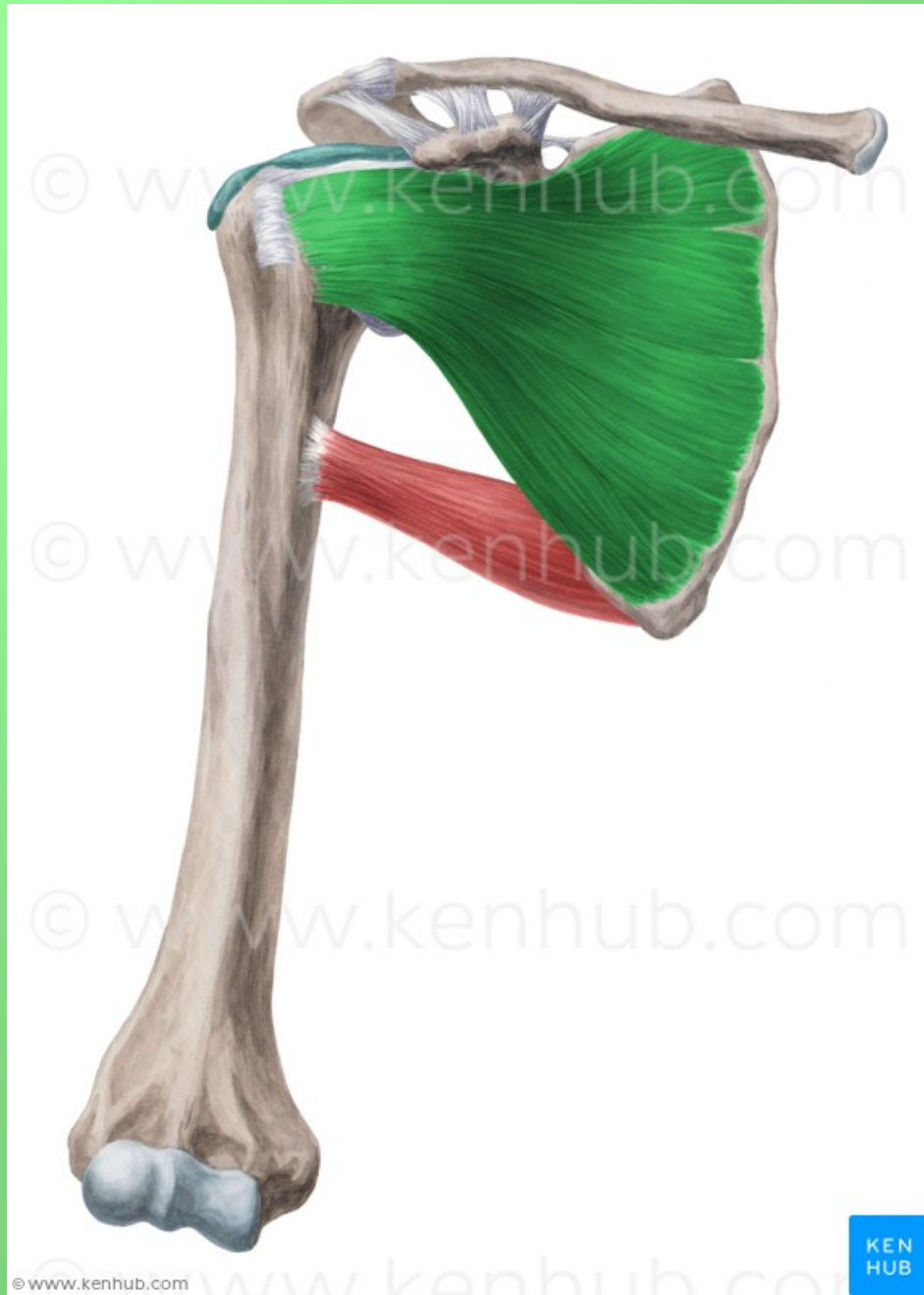




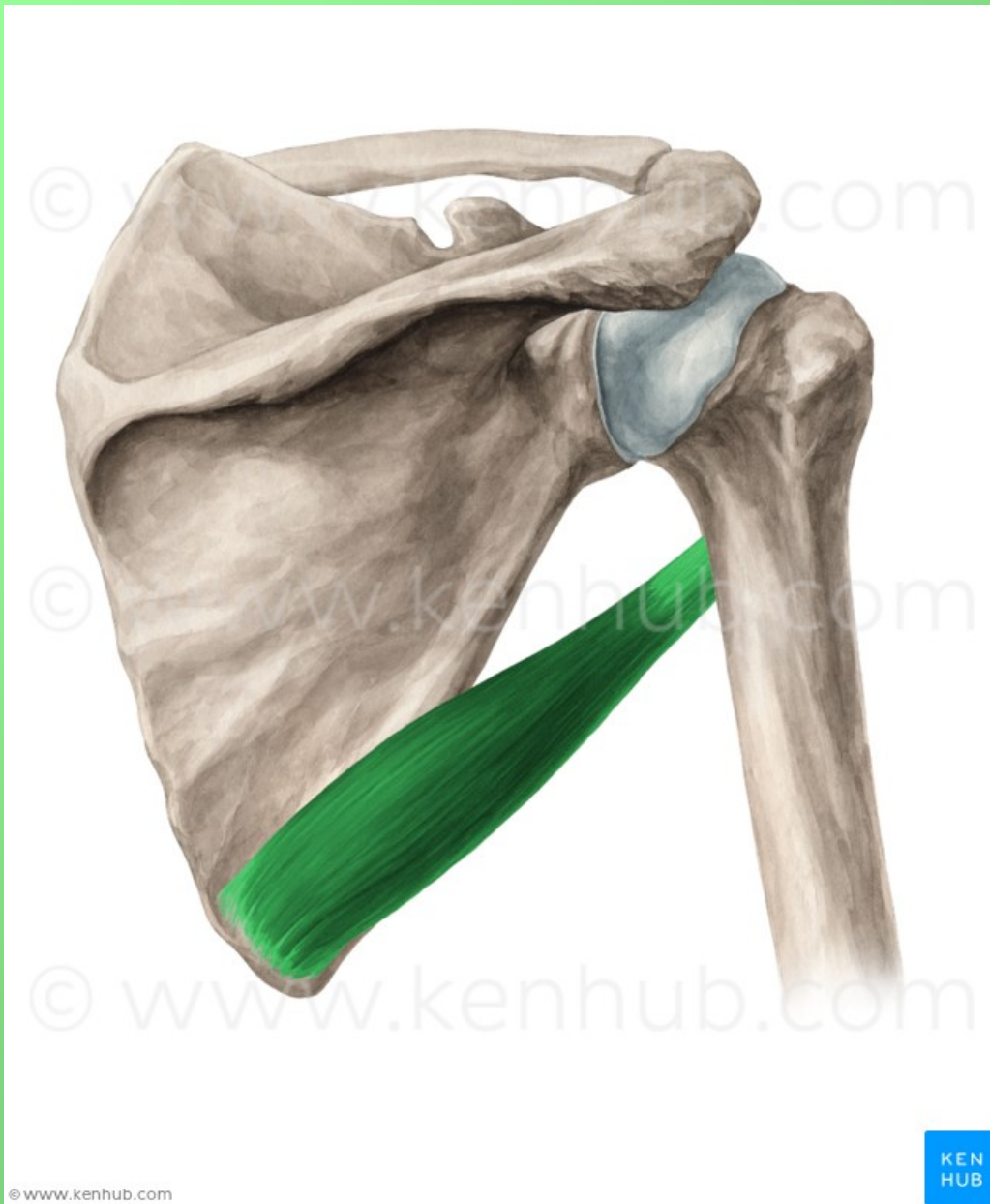
7



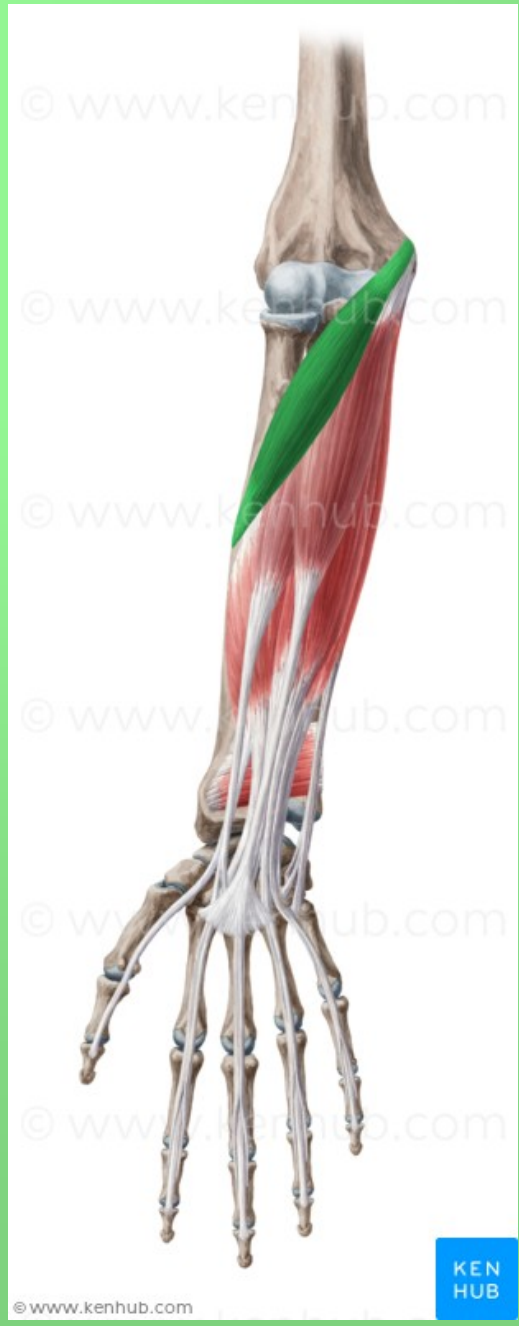



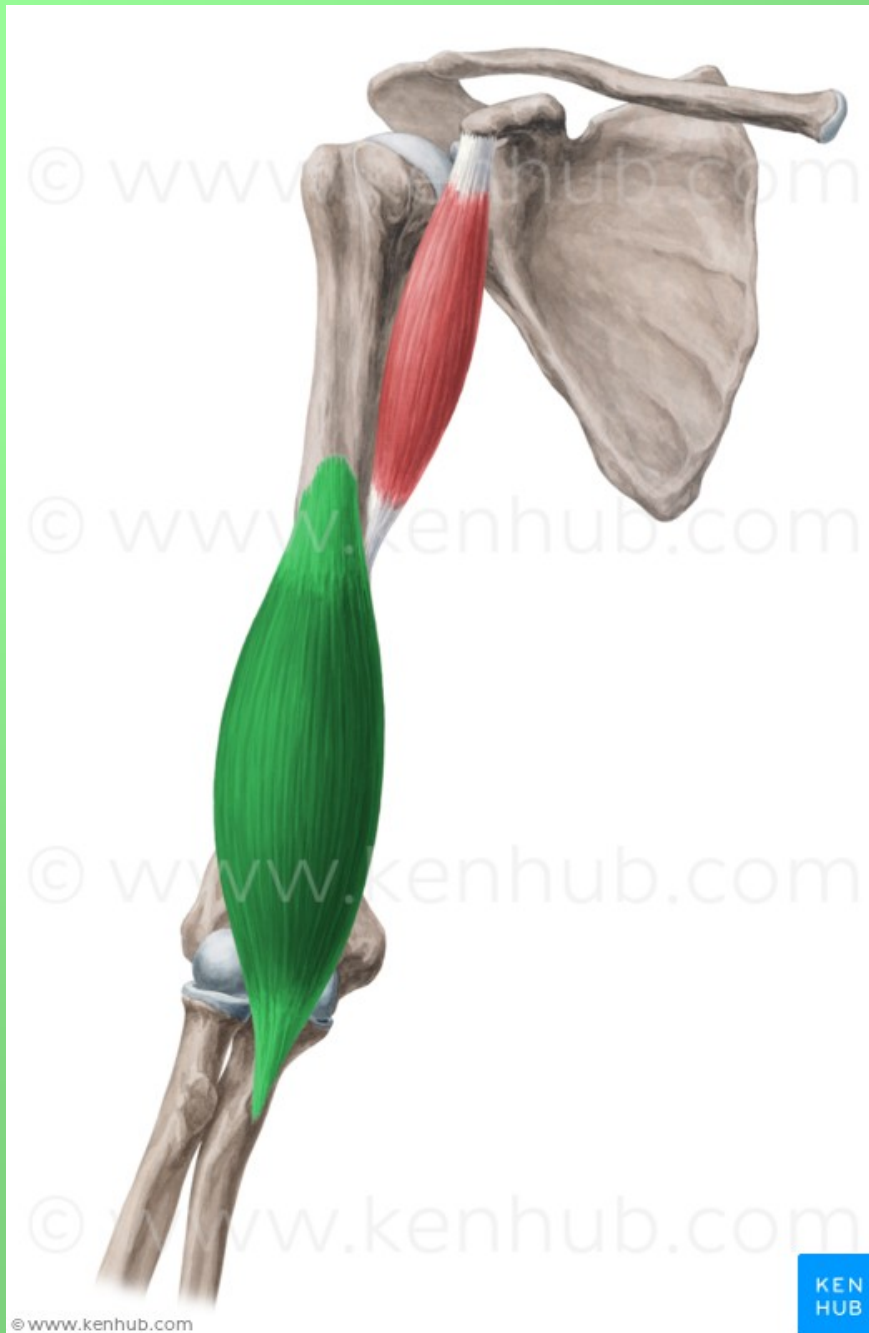
9



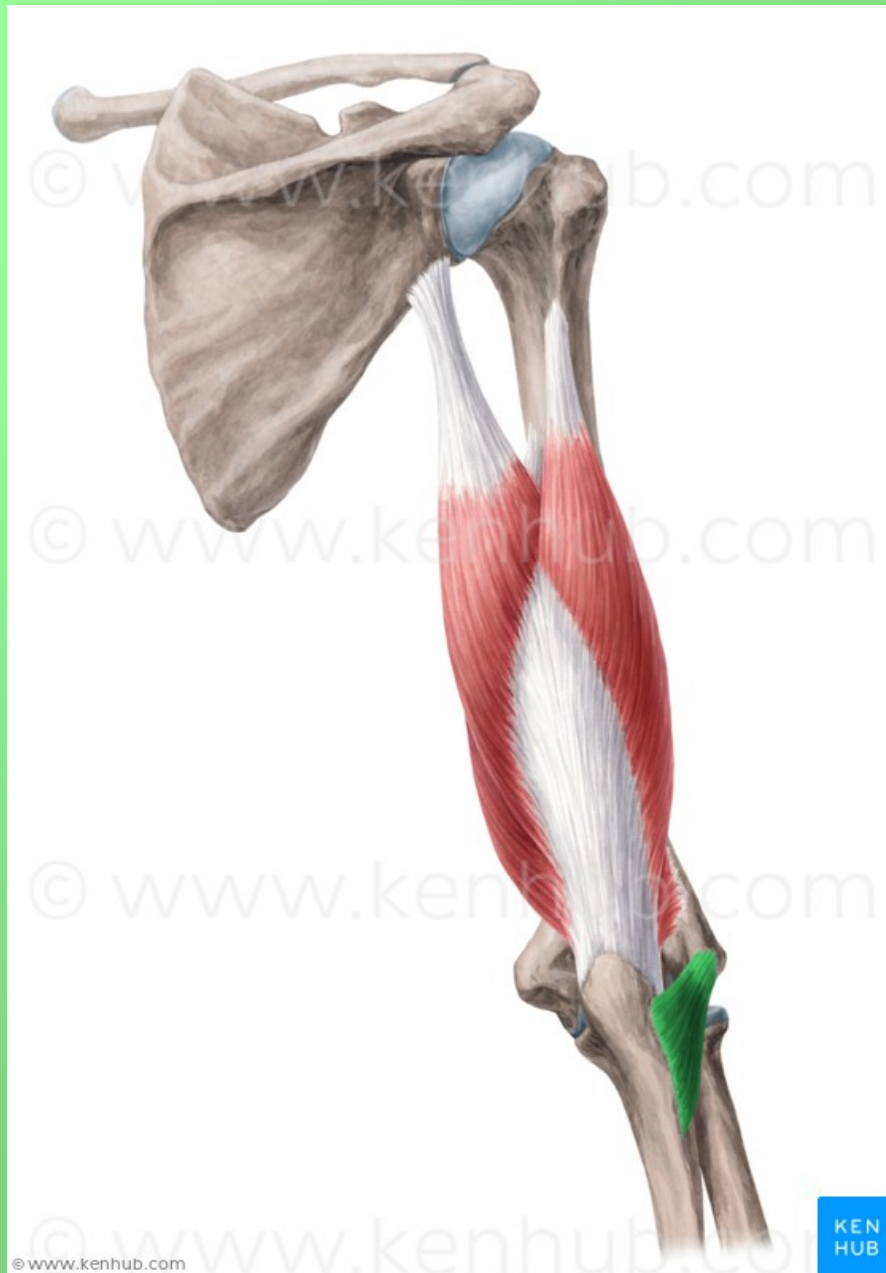
10



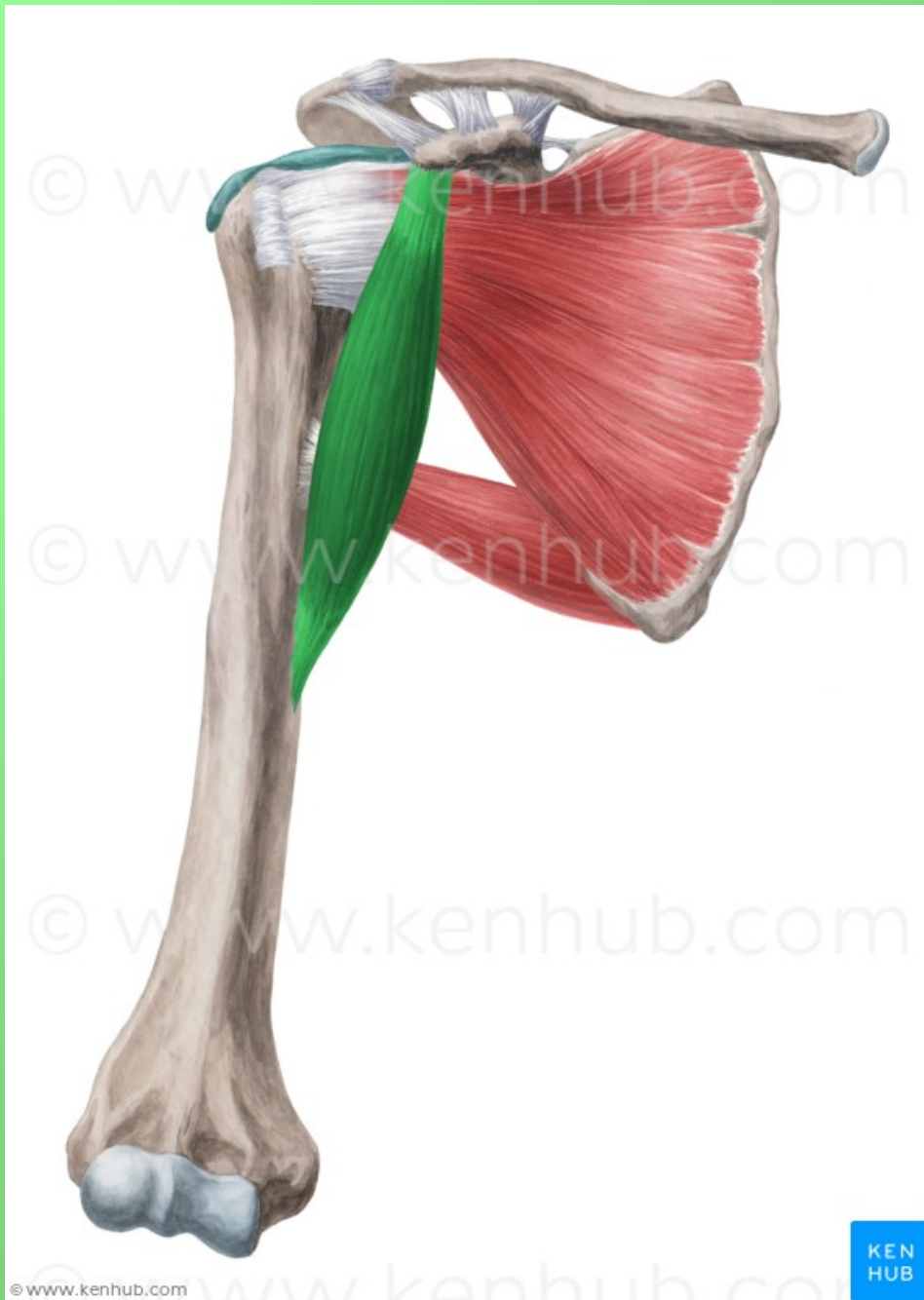
11



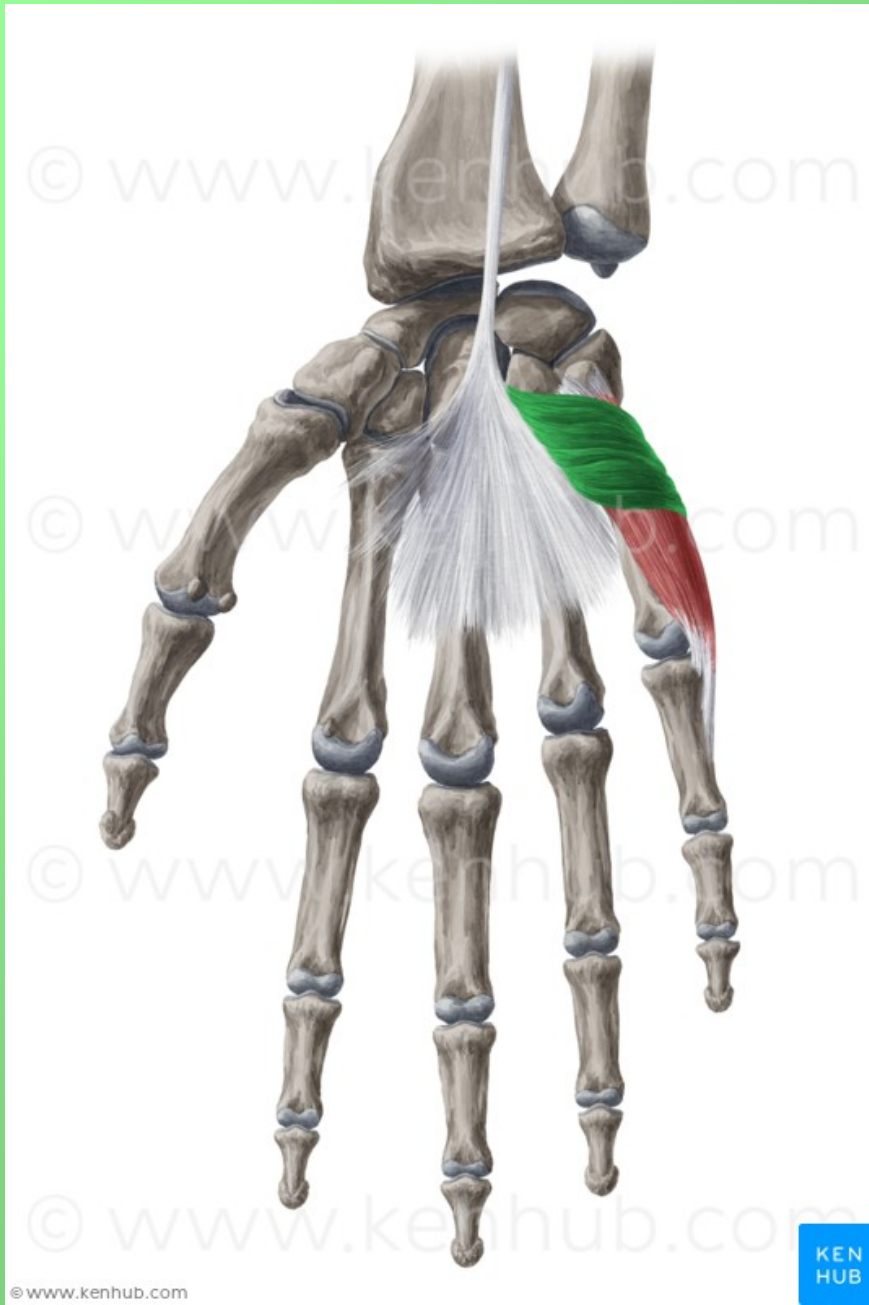12



13

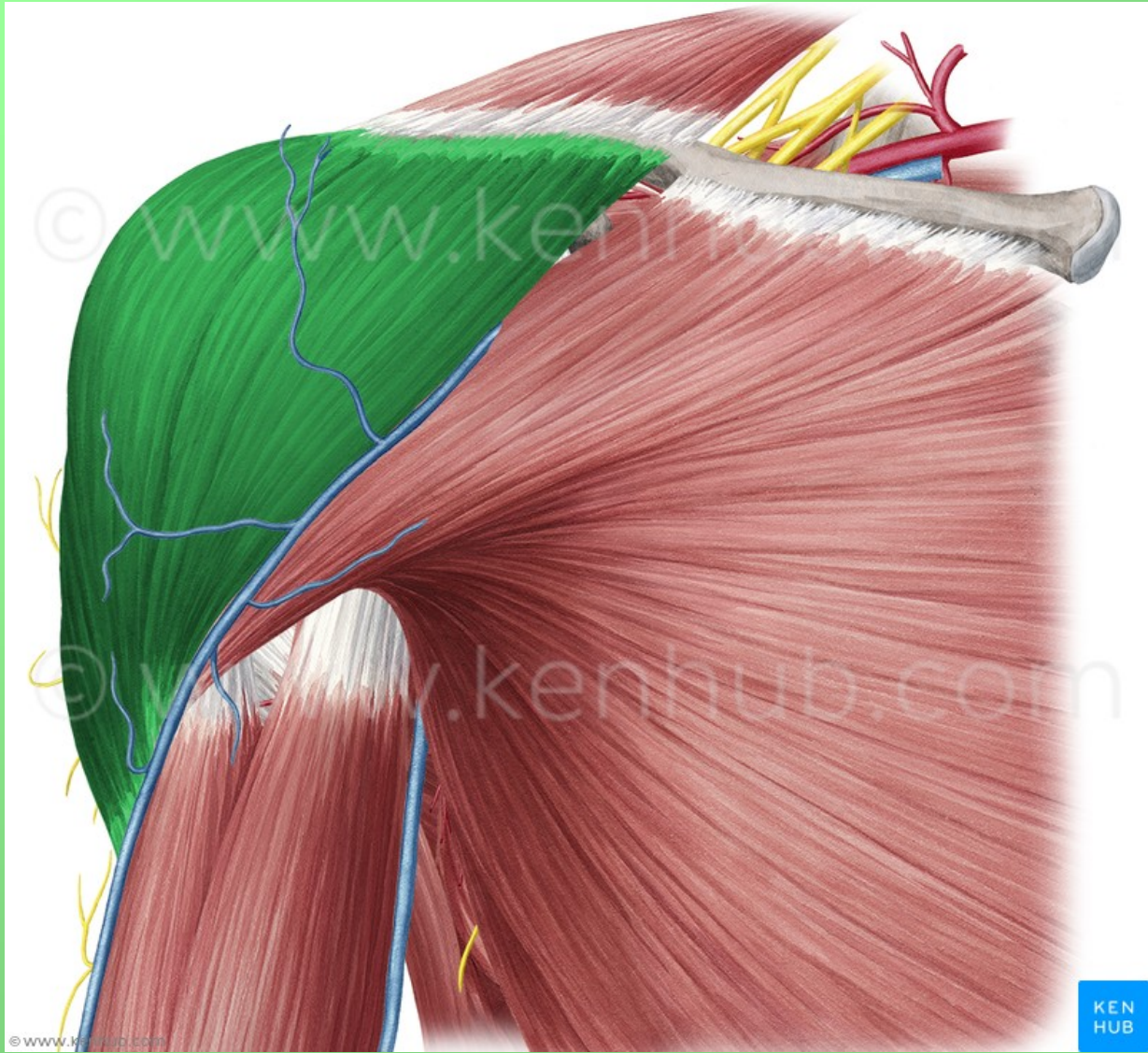


14

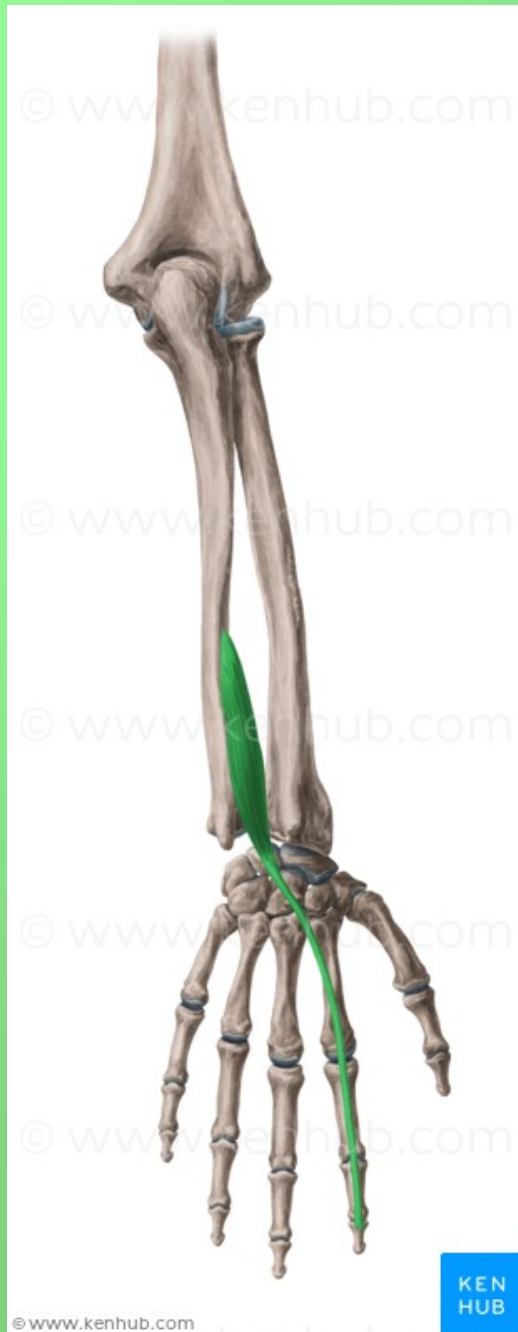

15

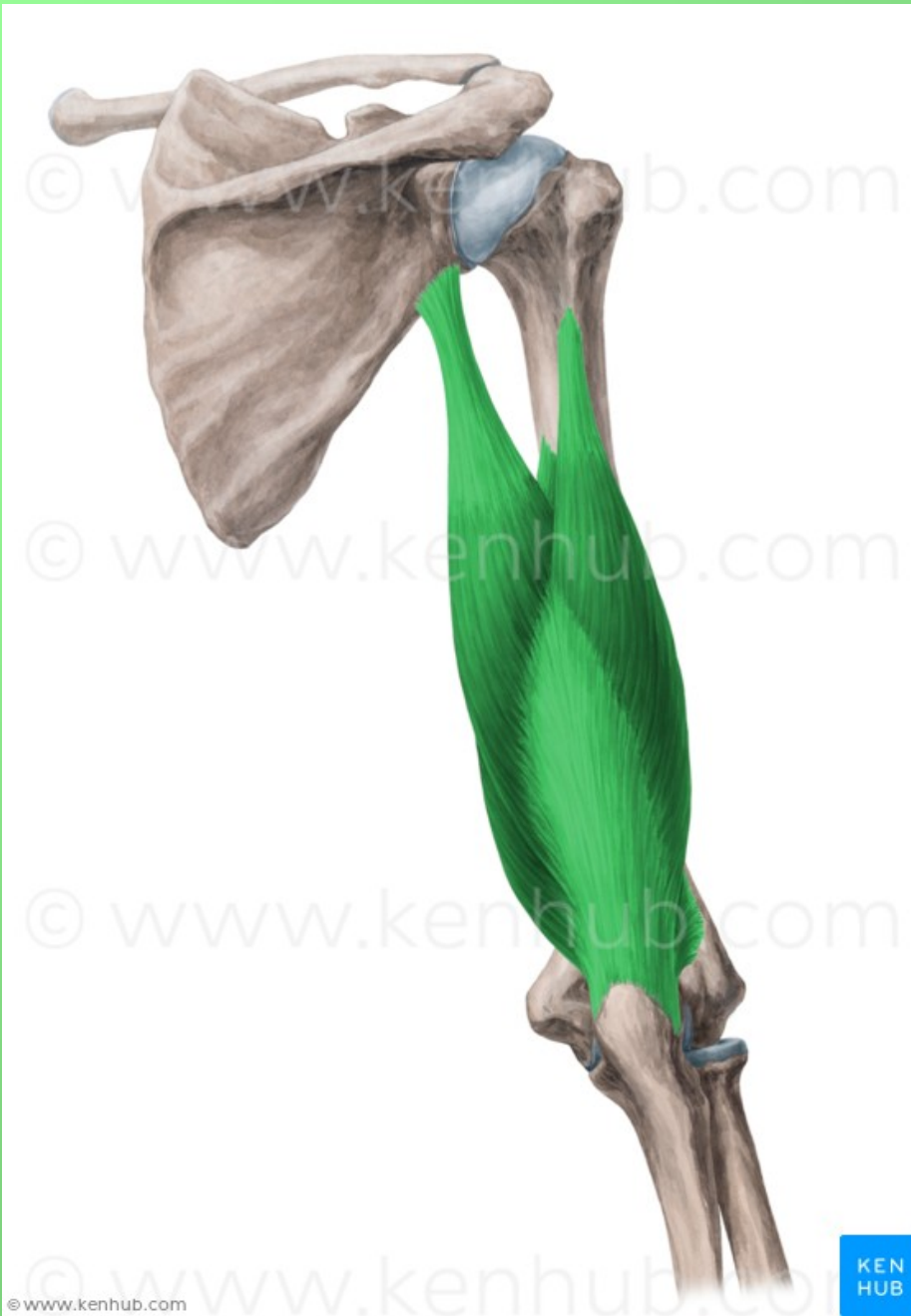




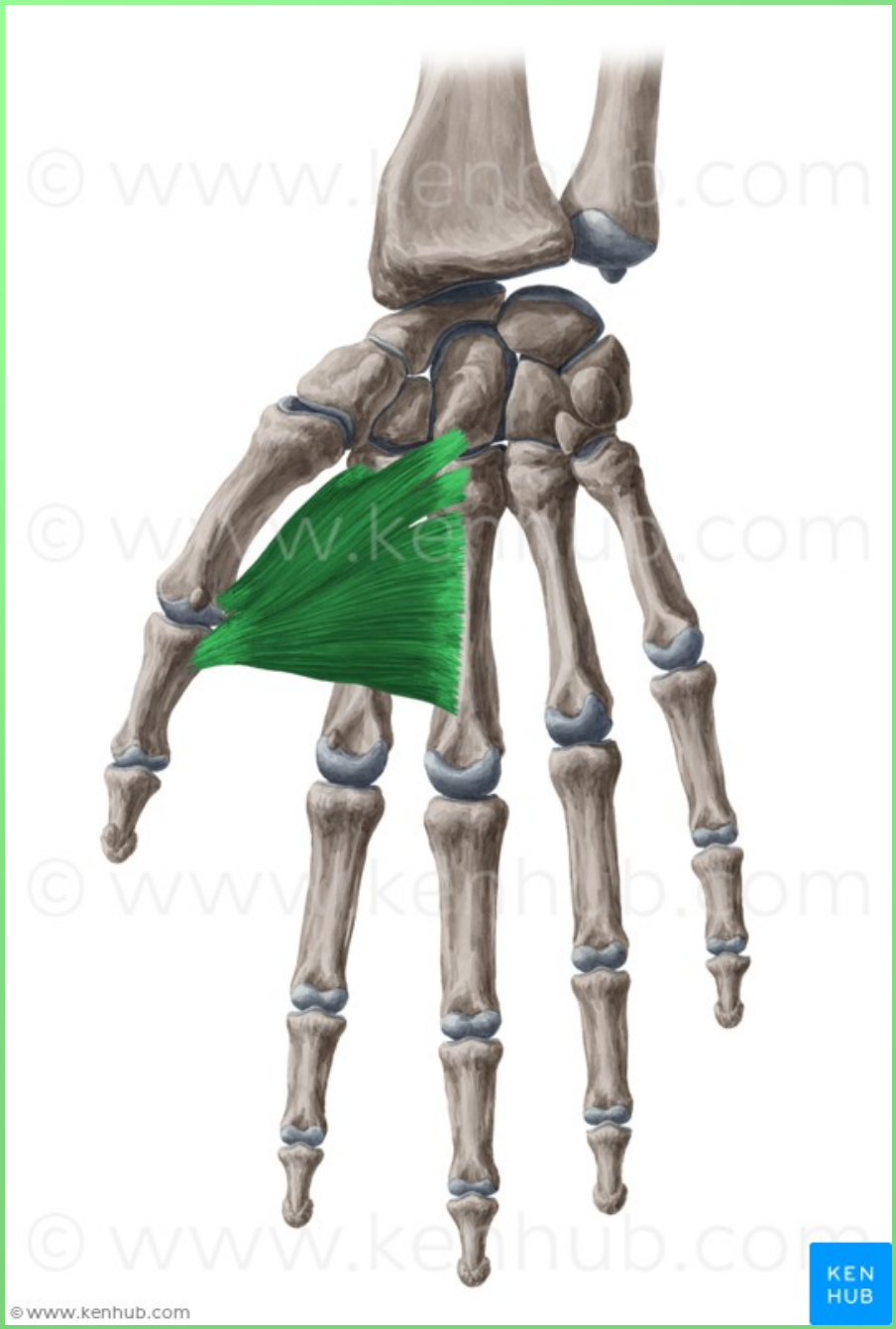
16



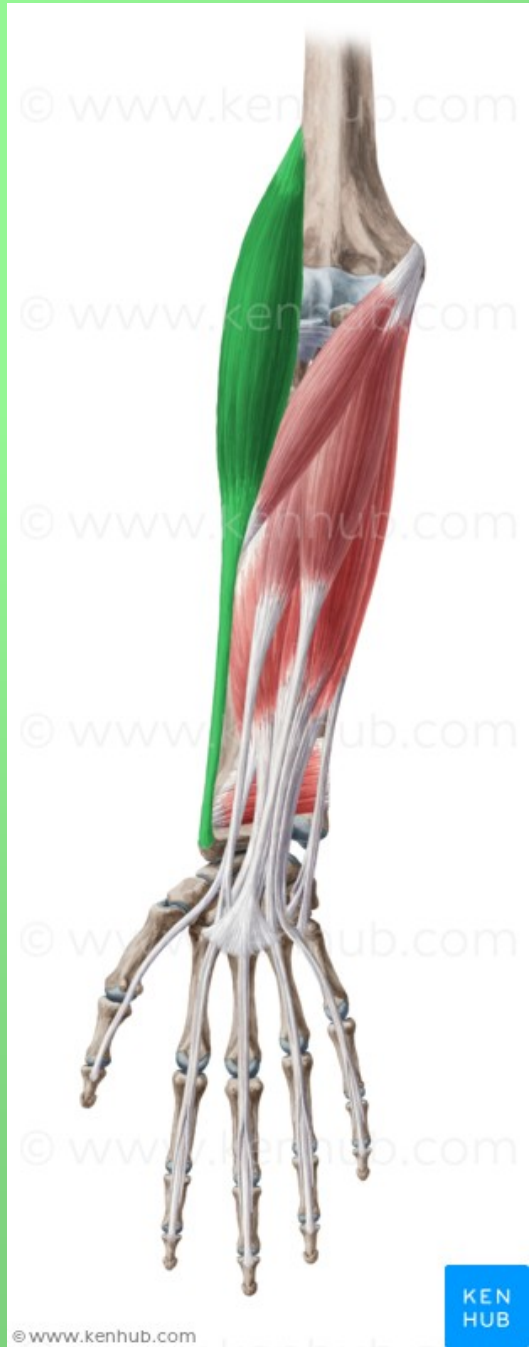17



18



19



20

- 1) m. infraspinatus
- 2) m. flexor digitorum superficialis
- 3) mm. lumbricales
- 4) m. palmaris longus
- 5) m. biceps brachii
- 6) m. pronator quadratus
- 7) m. extensor digitorum communis
- 8) m. supinator
- 9) m. subscapularis
- 10) m. teres major

- 11) m. pronator teres
- 12) m. brachialis
- 13) m. anconaeus
- 14) m. coracobrachialis
- 15) m. palmaris brevis
- 16) m. deltoideus
- 17) m. extensor indicis
- 18) m. triceps brachii
- 19) m. adductor pollicis
- 20) m. brachioradialis

*Děkuji za pozornost!*

