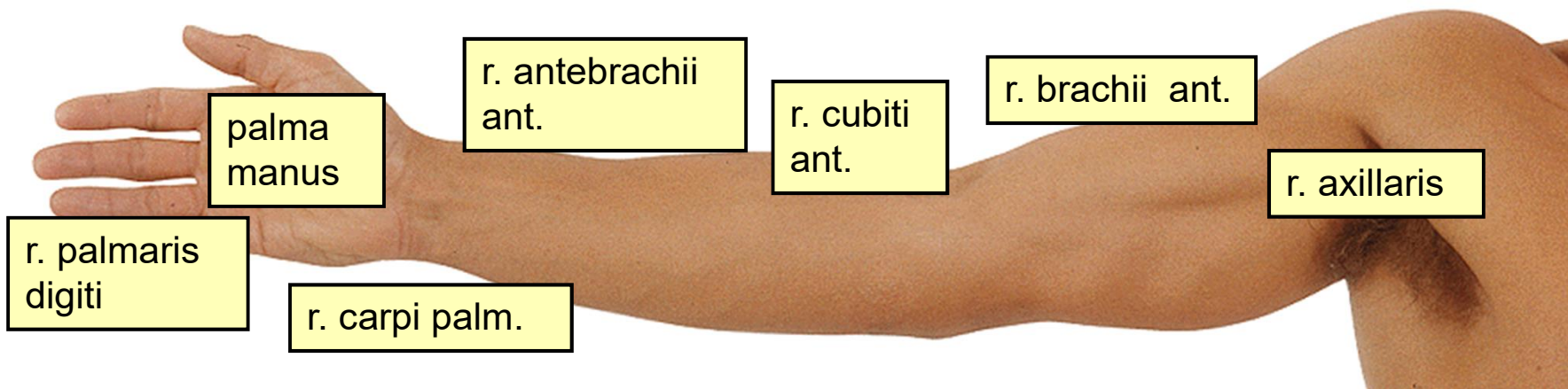
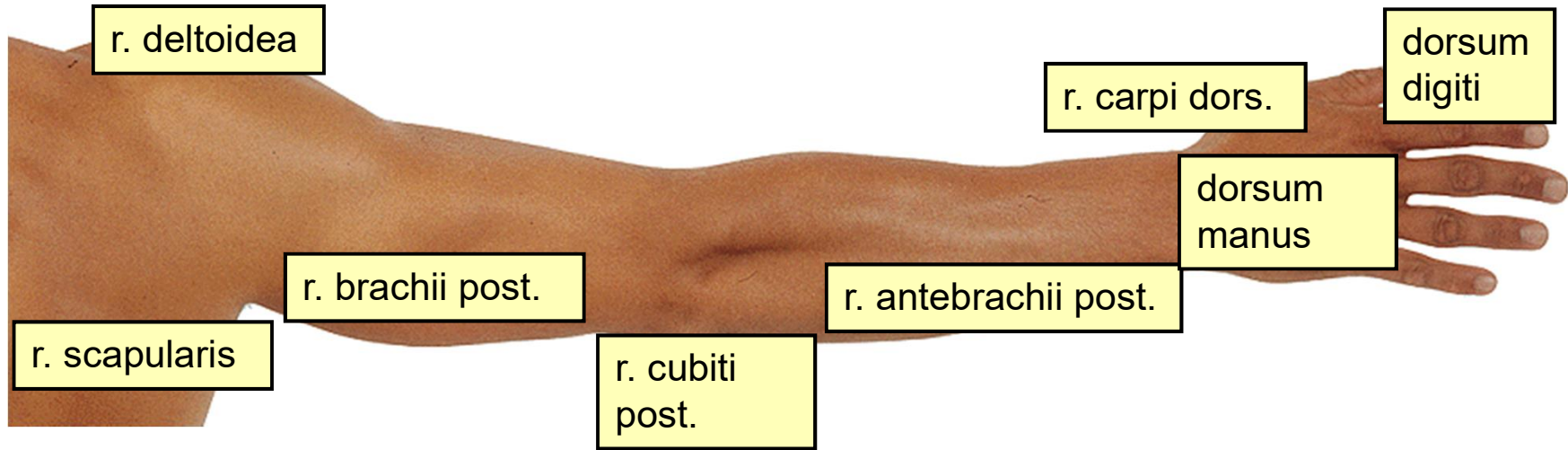


Topografická anatomie HK







r. deltoidea

r. scapularis

r. brachii post.

r. cubiti
post.

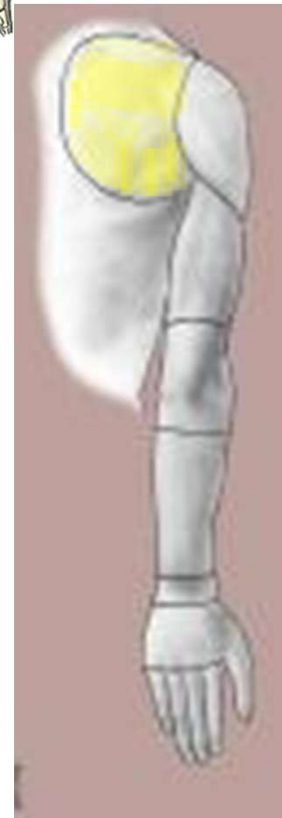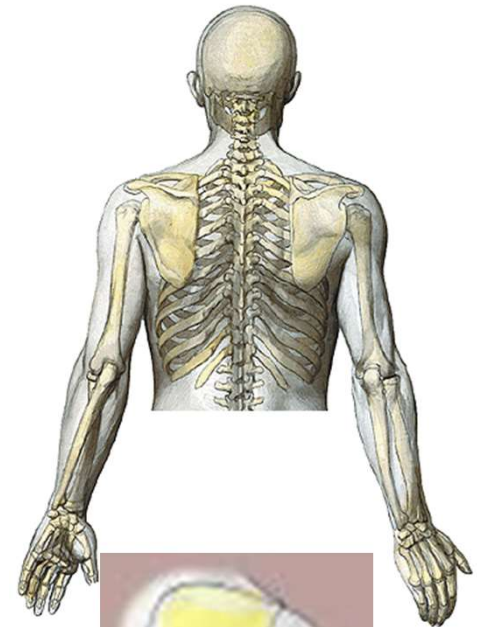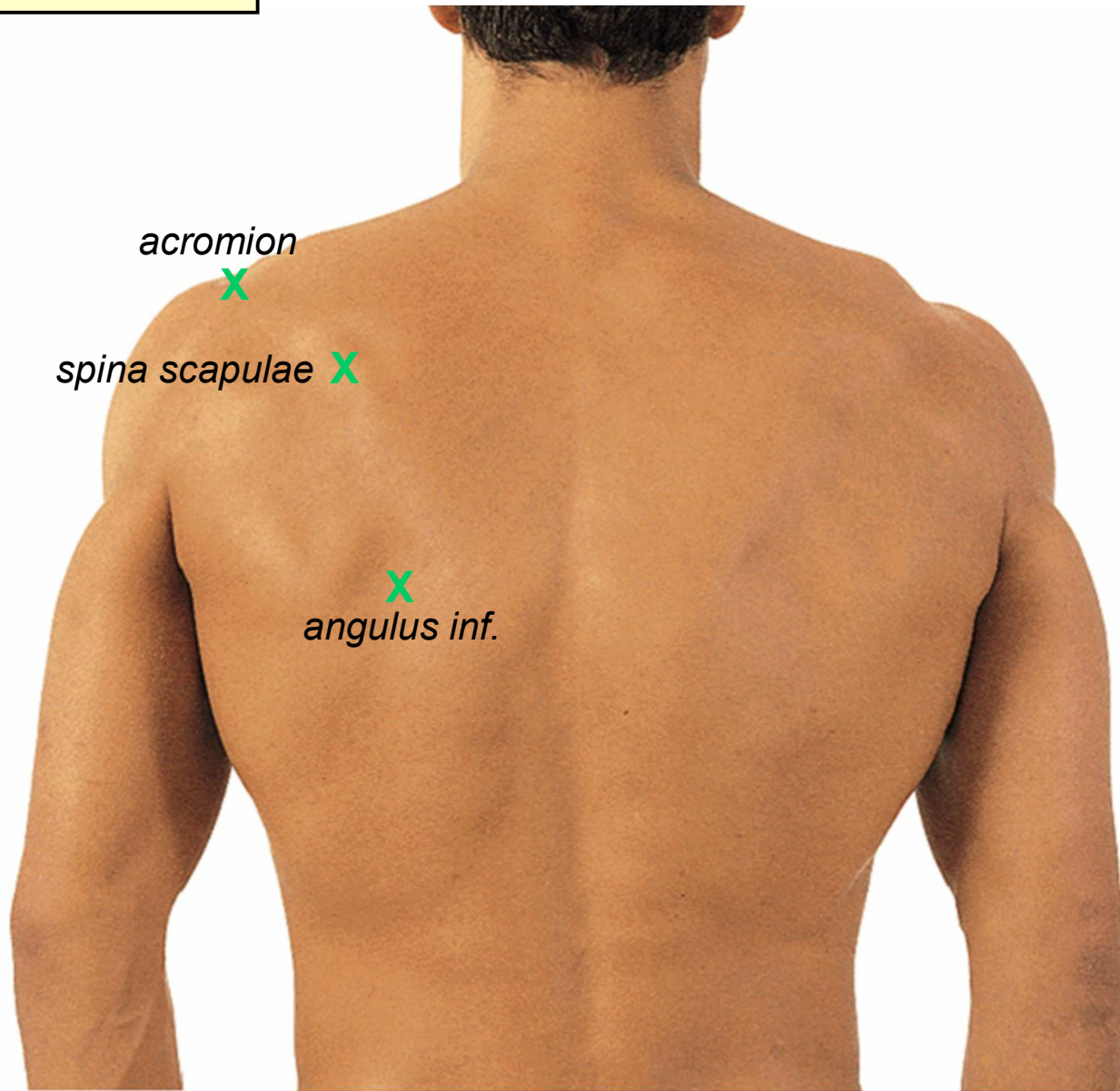
r. antebrachii post.

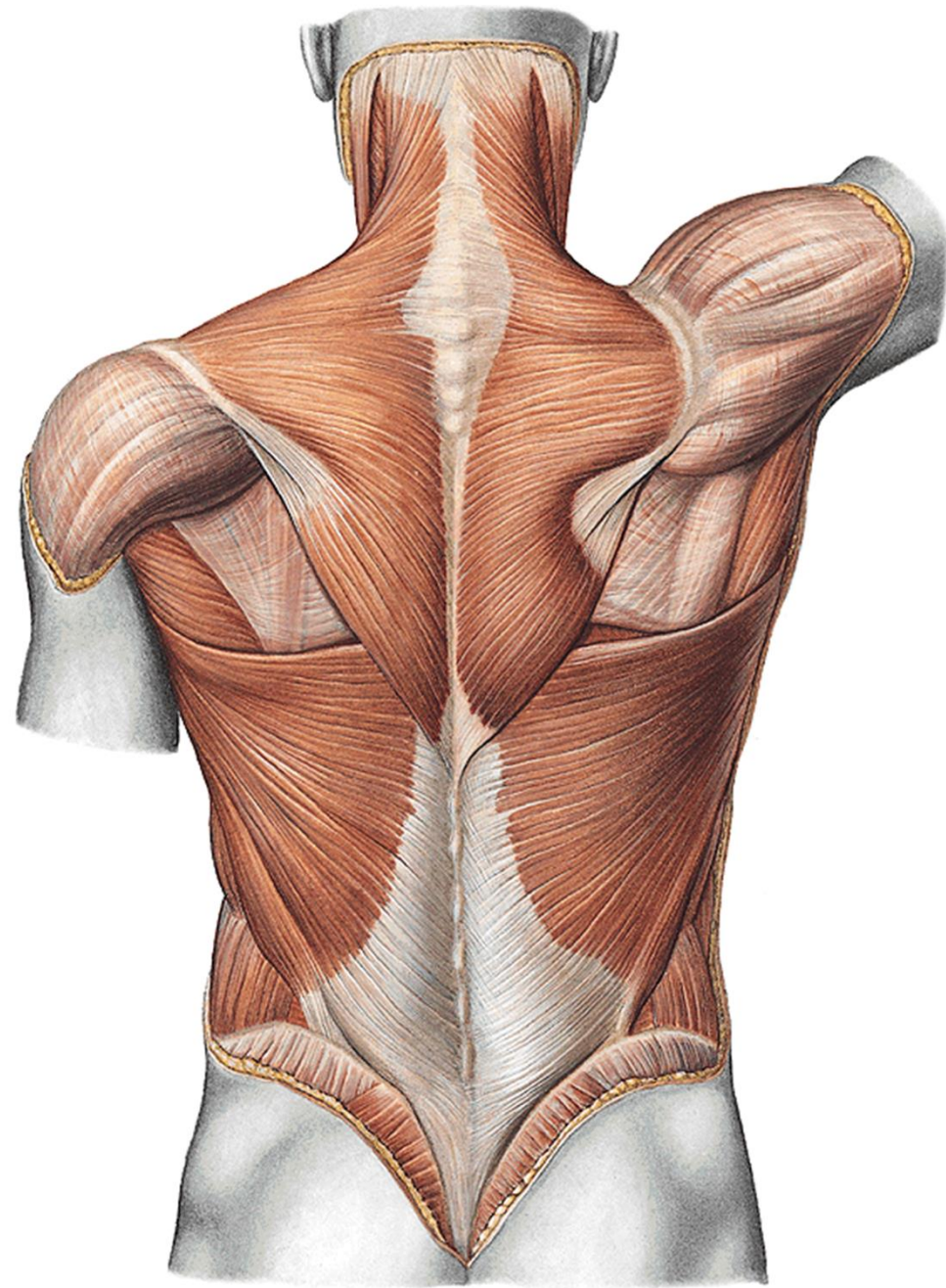
r. carpi dors.

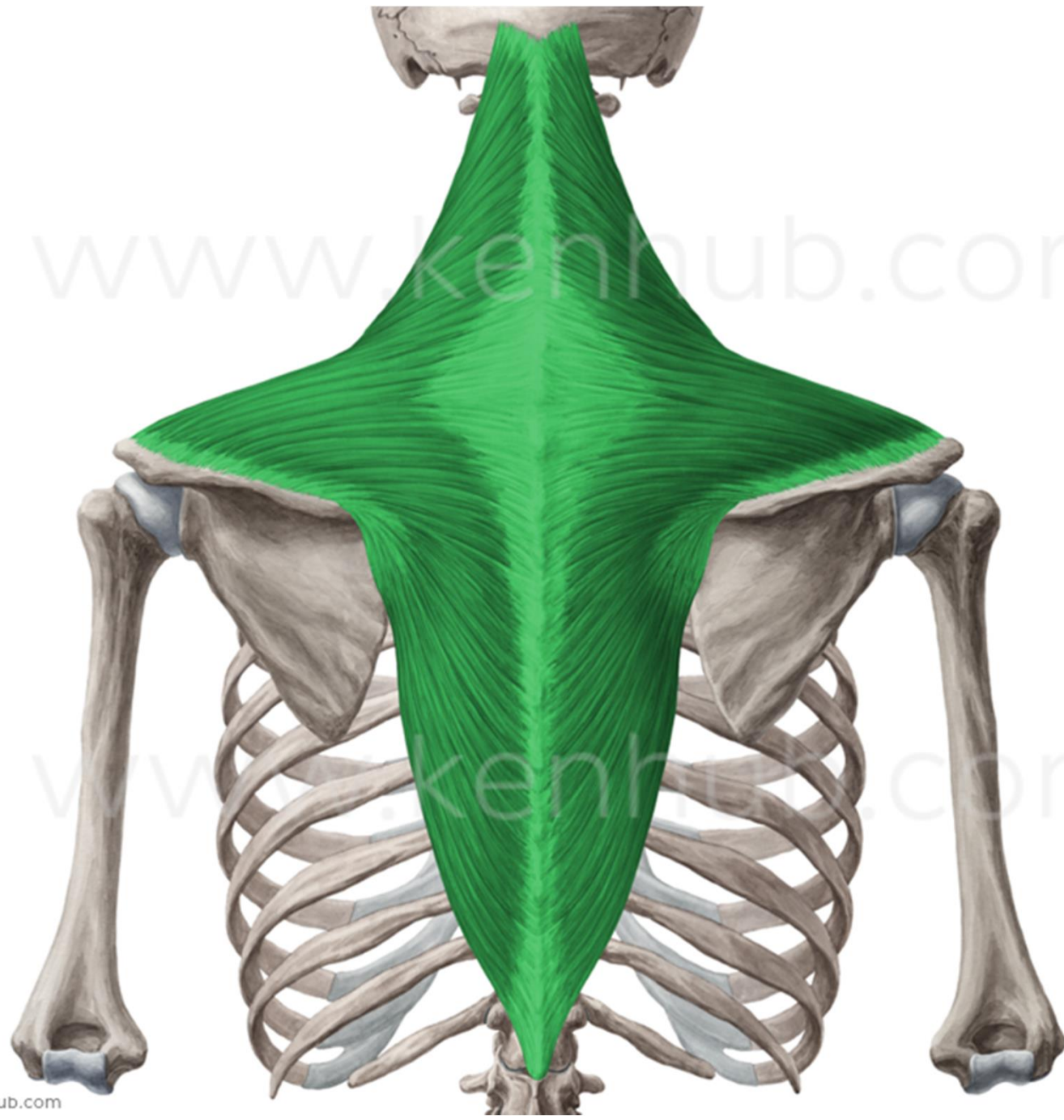
dorsum
manus

dorsum
digiti

r. scapularis

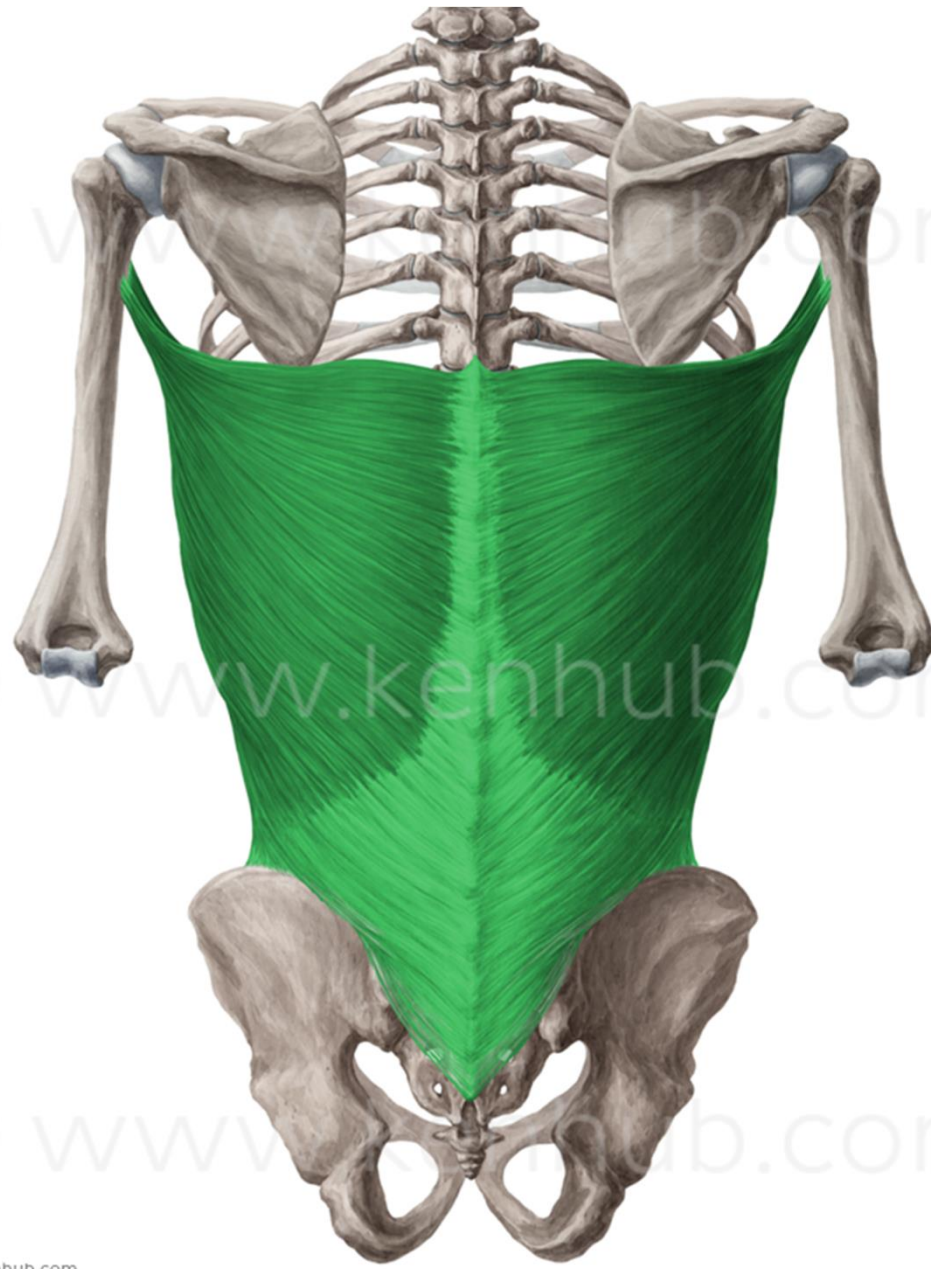


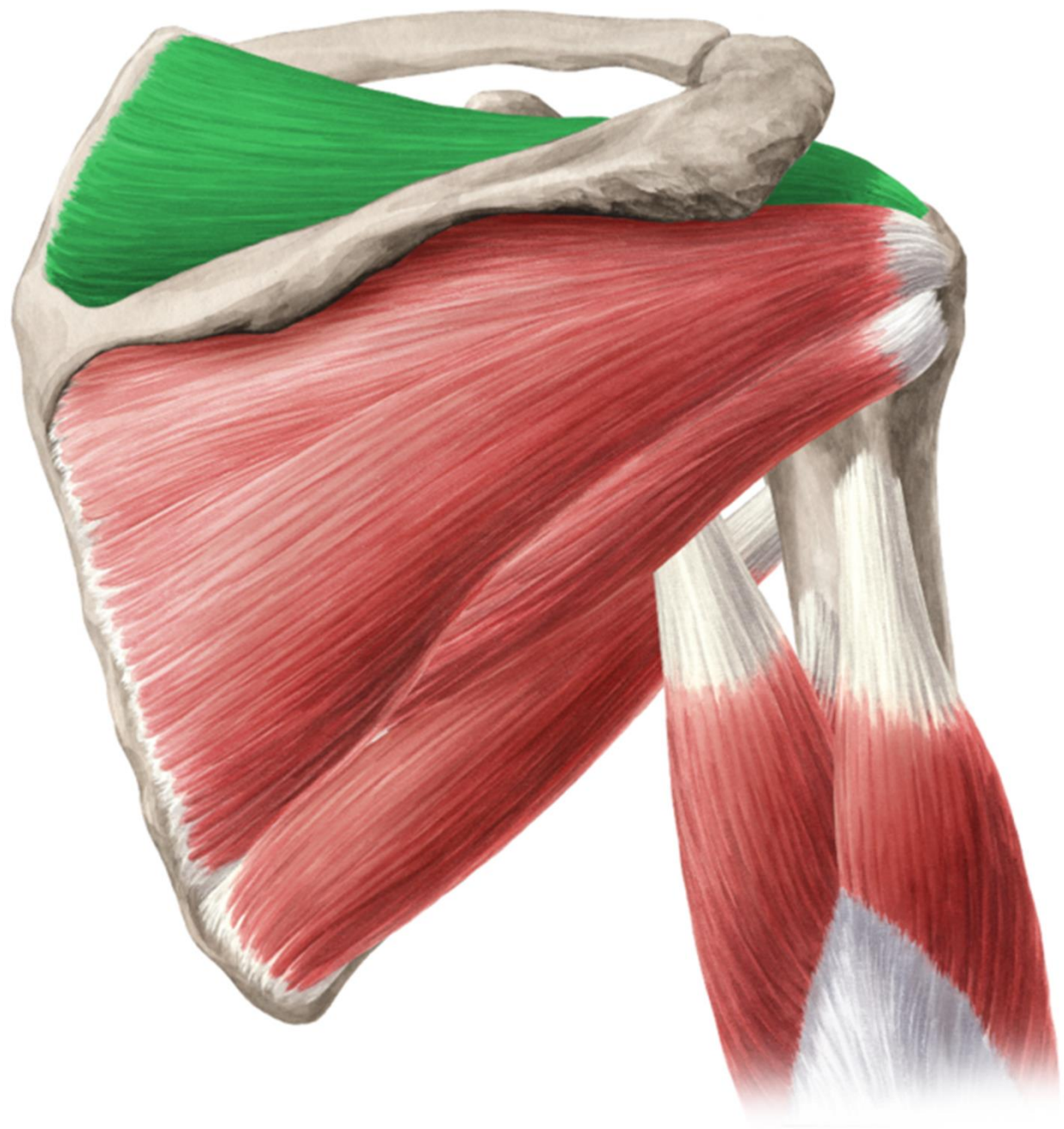


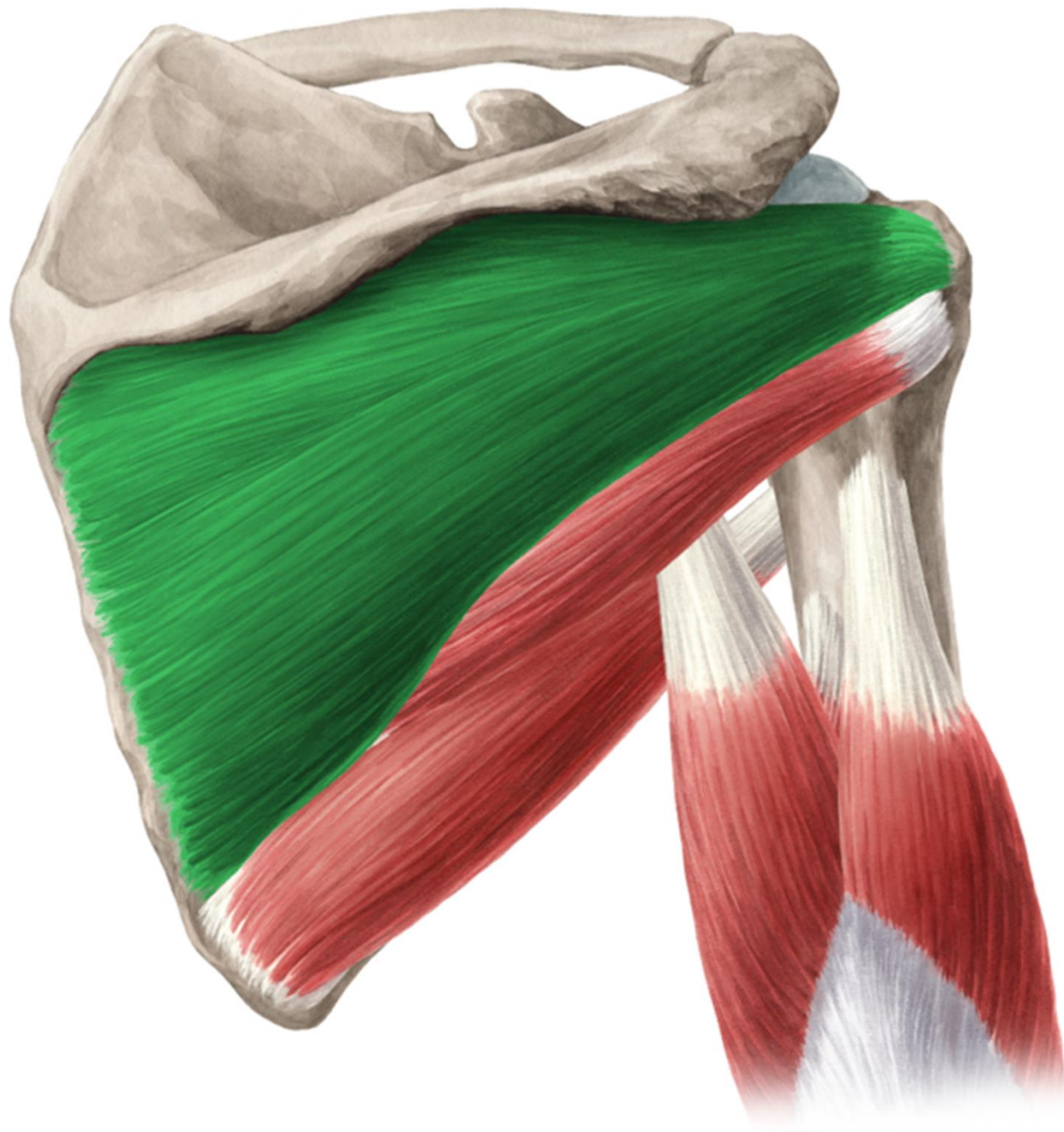


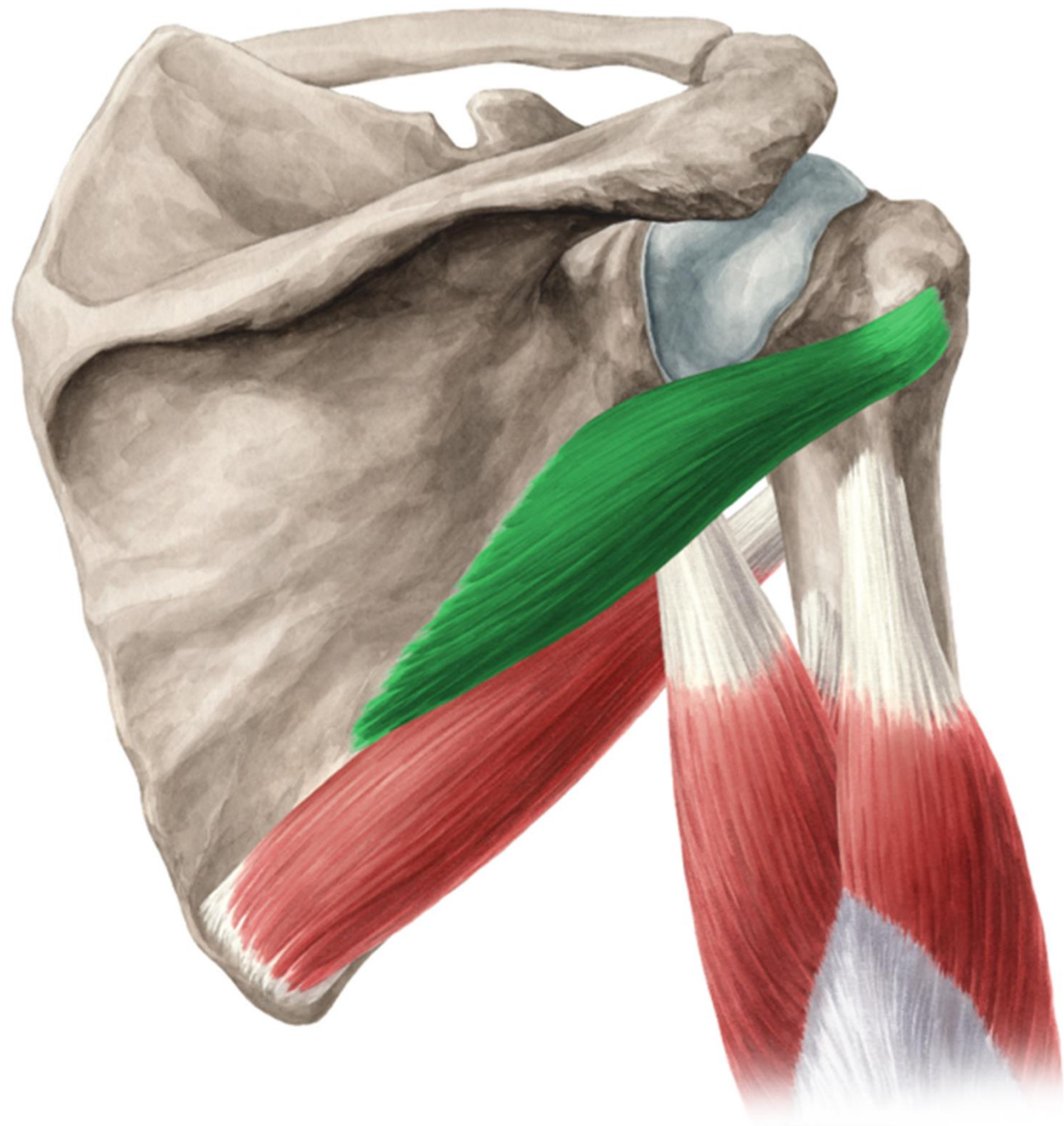
© www.kenhub.com

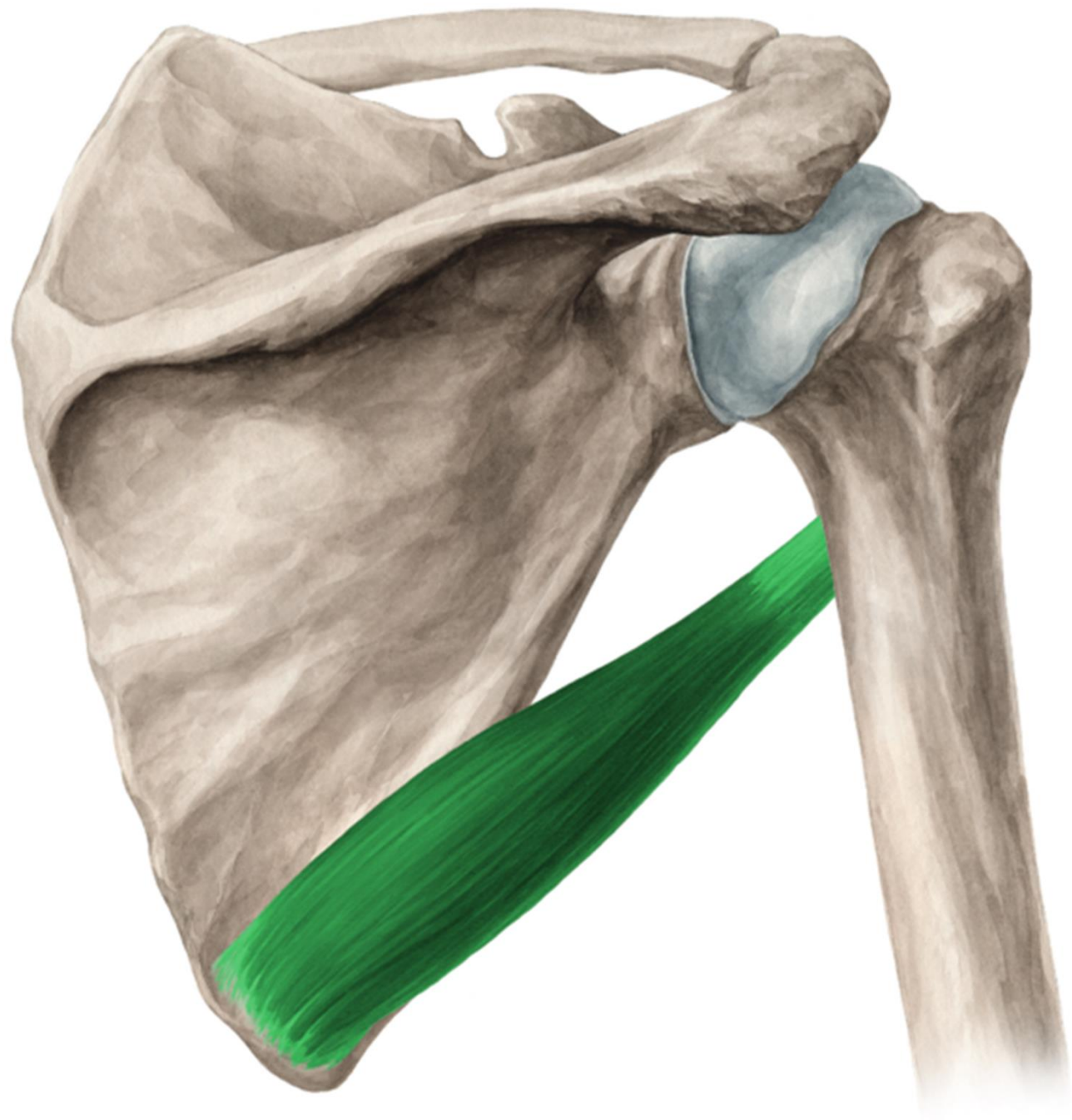
© www.kenhub.com

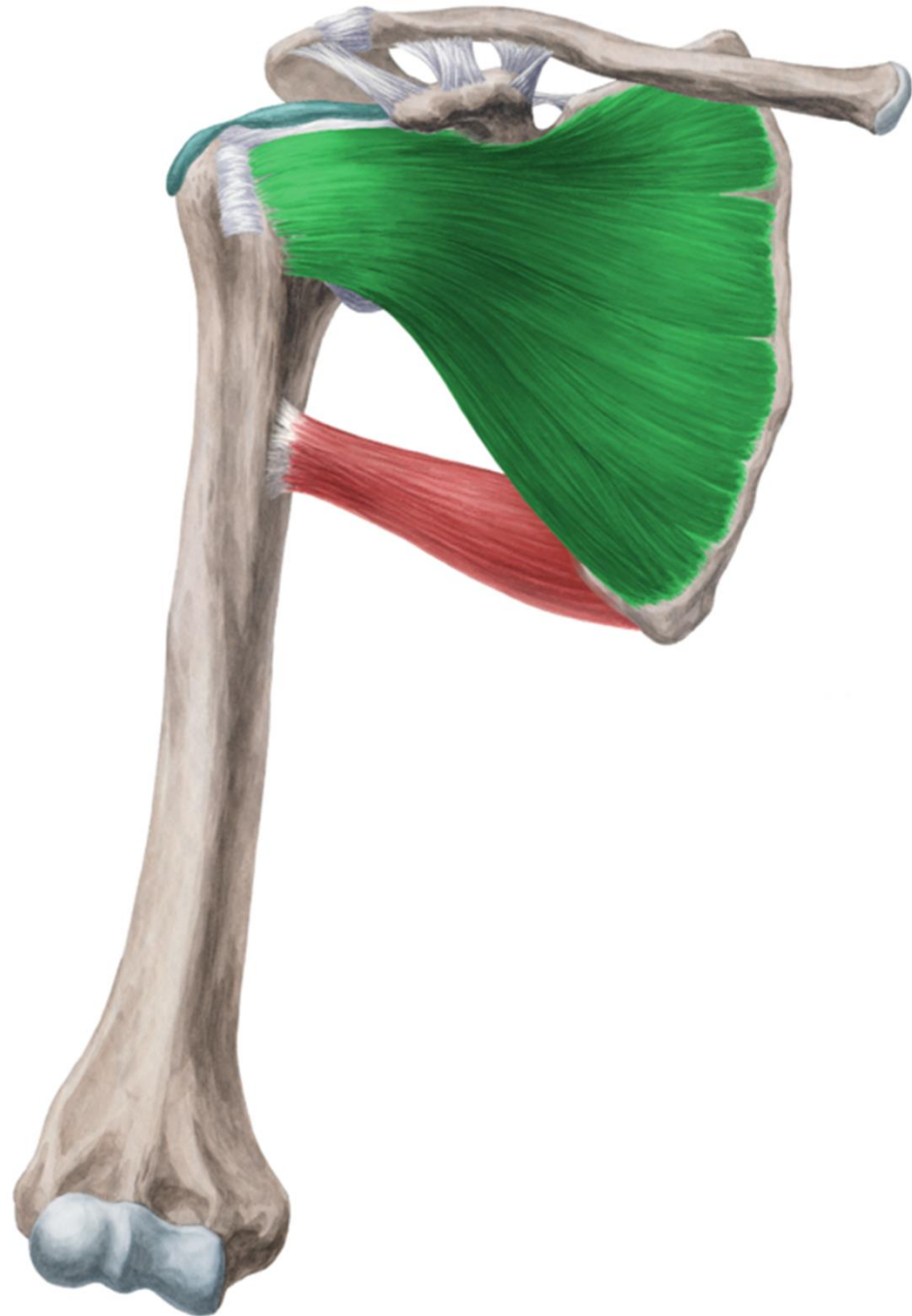

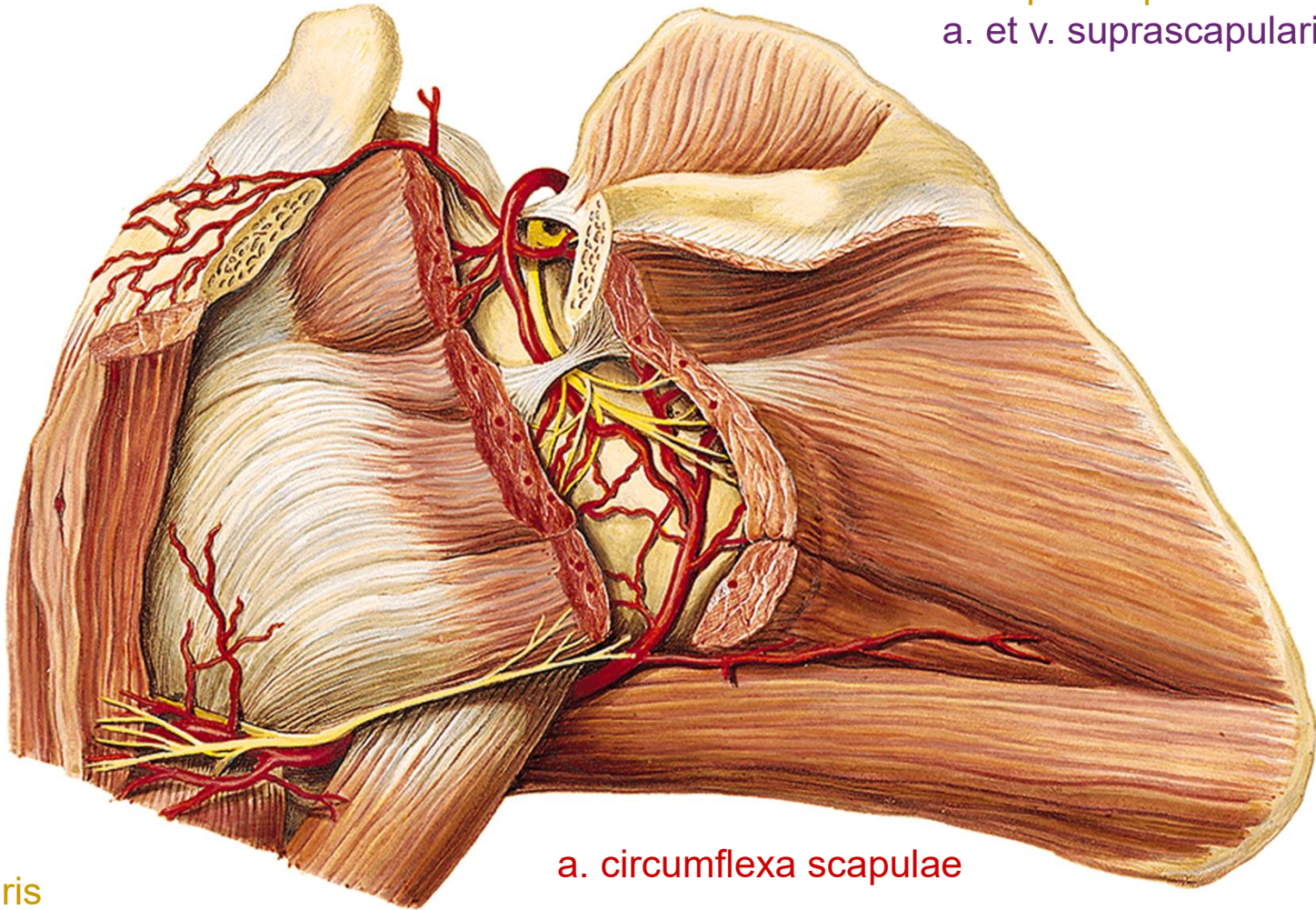










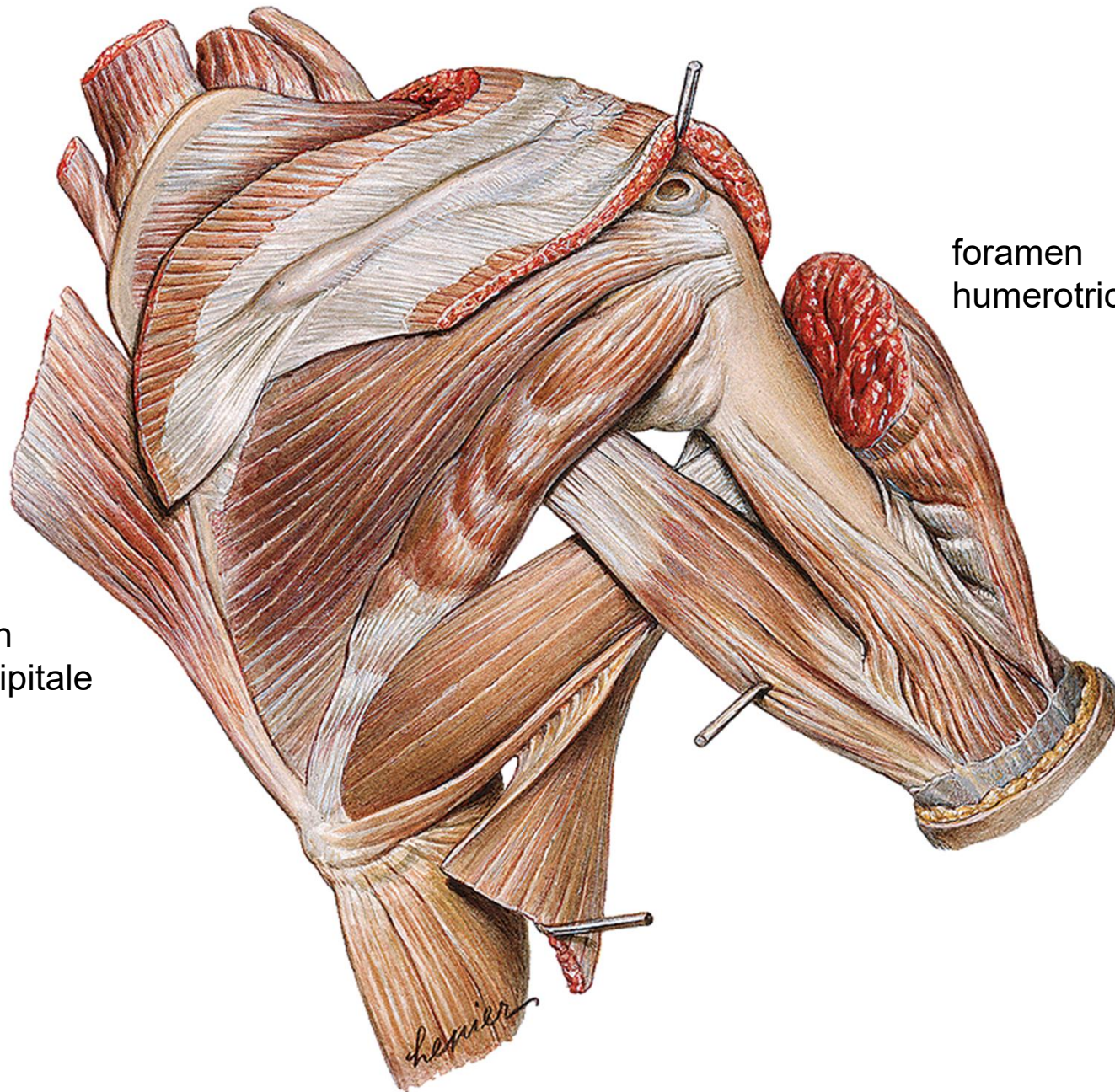


n. suprascapularis
a. et v. suprascapularis

n. axillaris
a. et v. circumflexa humeri post.

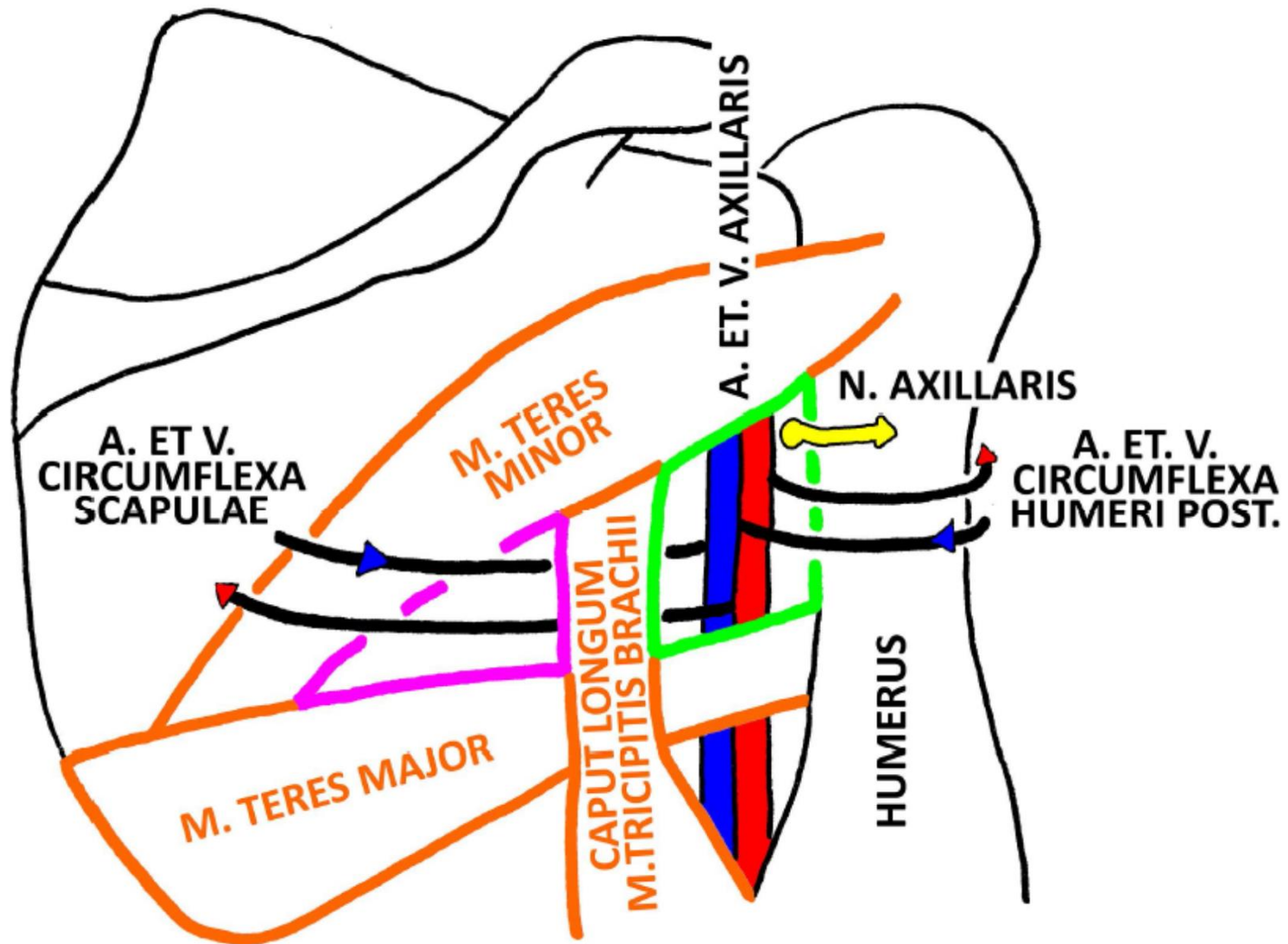
a. circumflexa scapulae

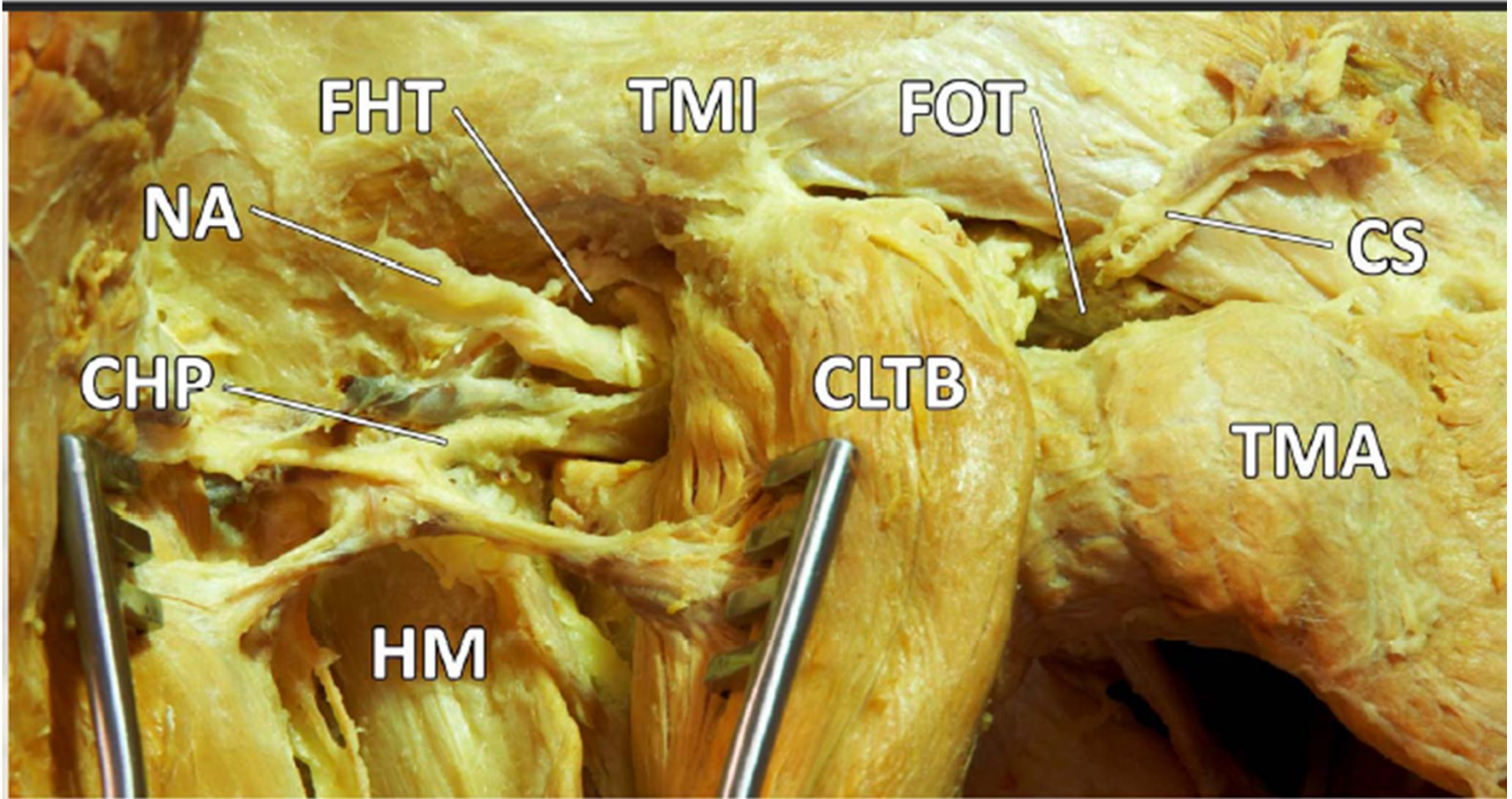
foramen
omotricipitale

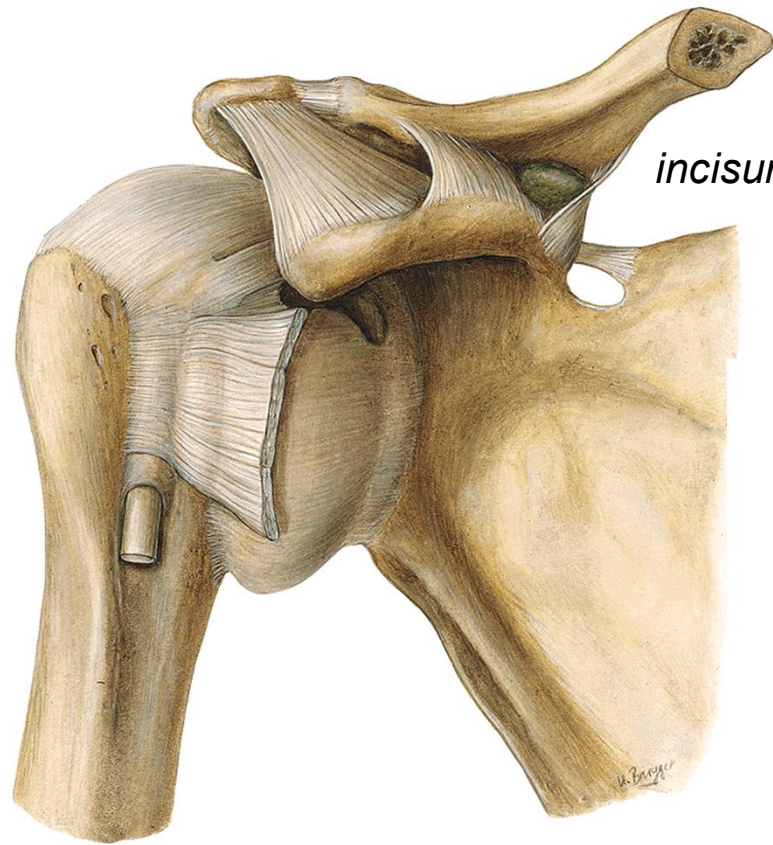


foramen
humerotricipitale

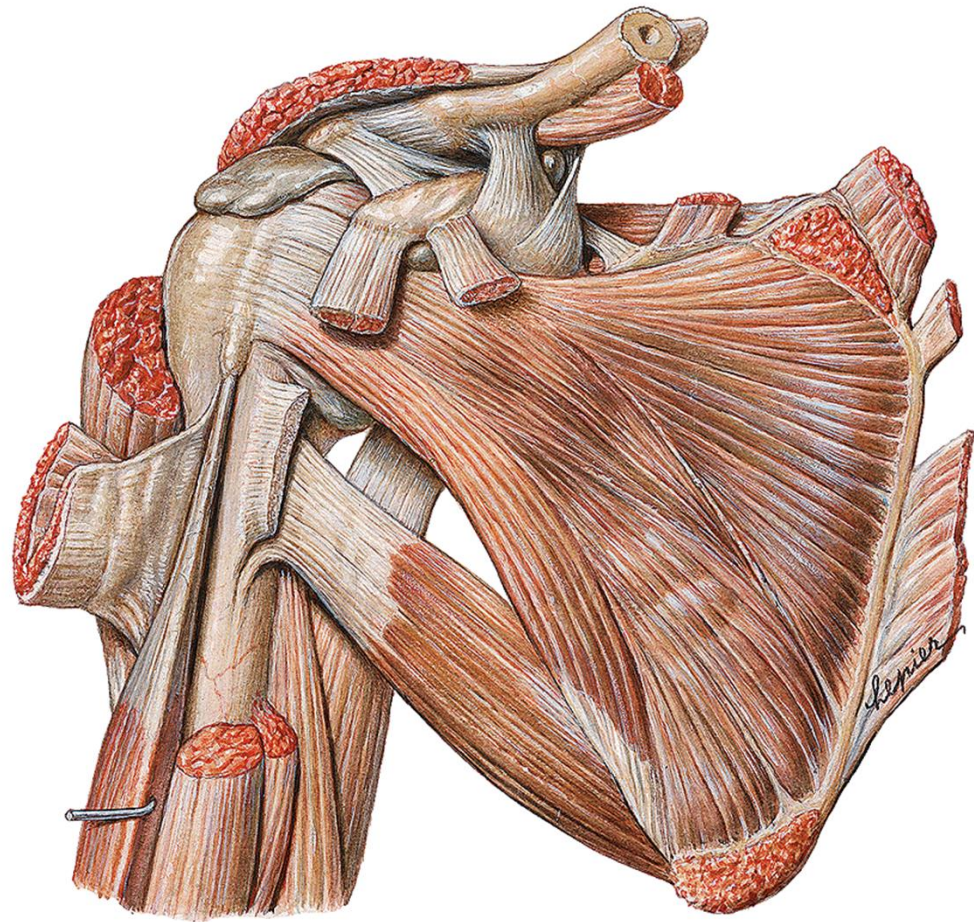
FORAMEN OMOTRICIPITALE ET HUMEROTRICIPITALE

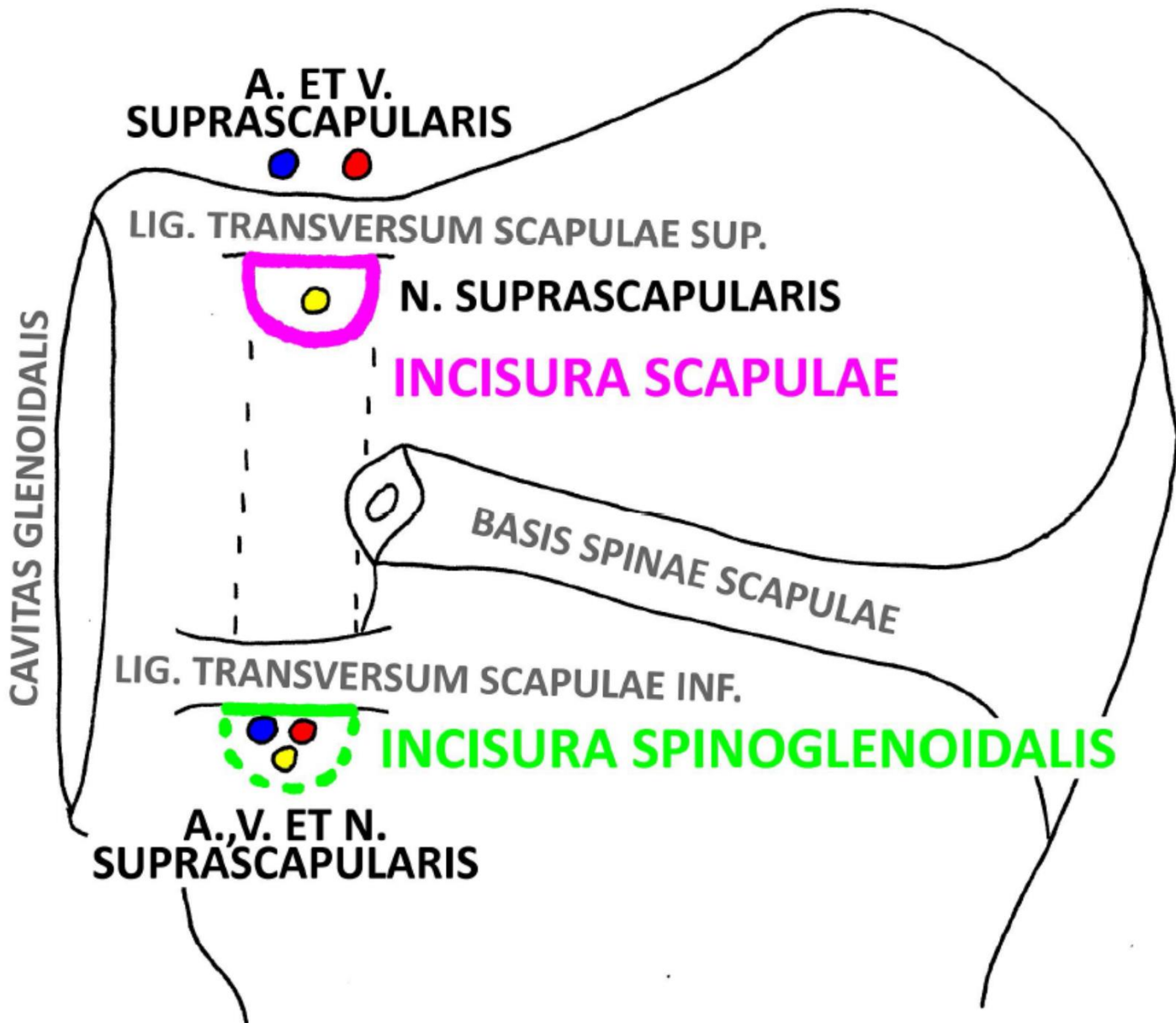






incisura scapulae





A. ET V.
SUPRASCAPULARIS

LIG. TRANSVERSUM SCAPULAE SUP.

N. SUPRASCAPULARIS

INCISURA SCAPULAE

BASIS SPINAE SCAPULAE

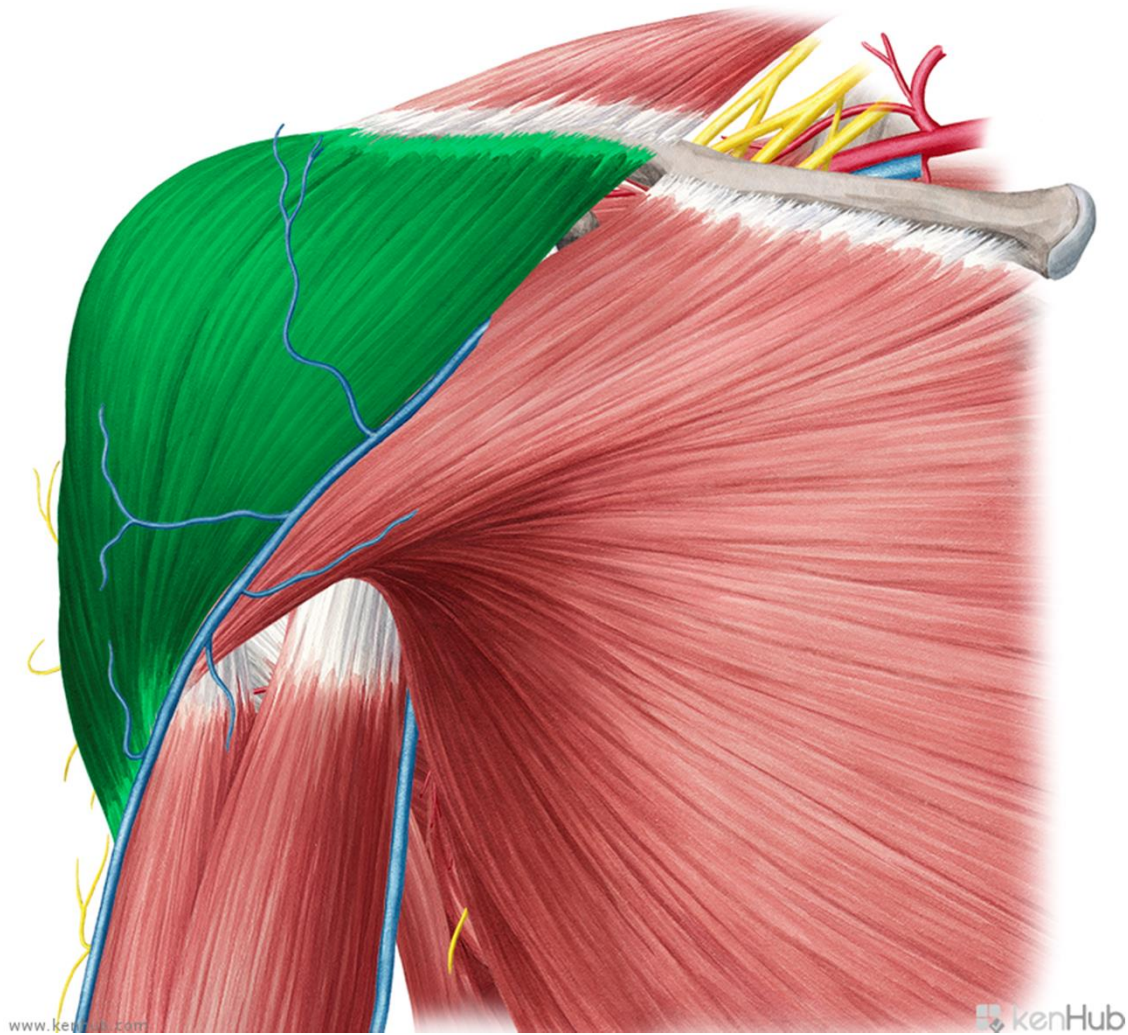
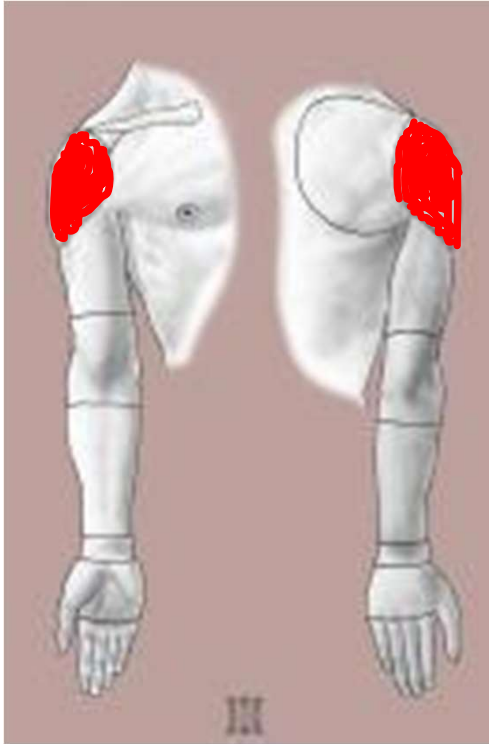
LIG. TRANSVERSUM SCAPULAE INF.

INCISURA SPINOGLENOIDALIS

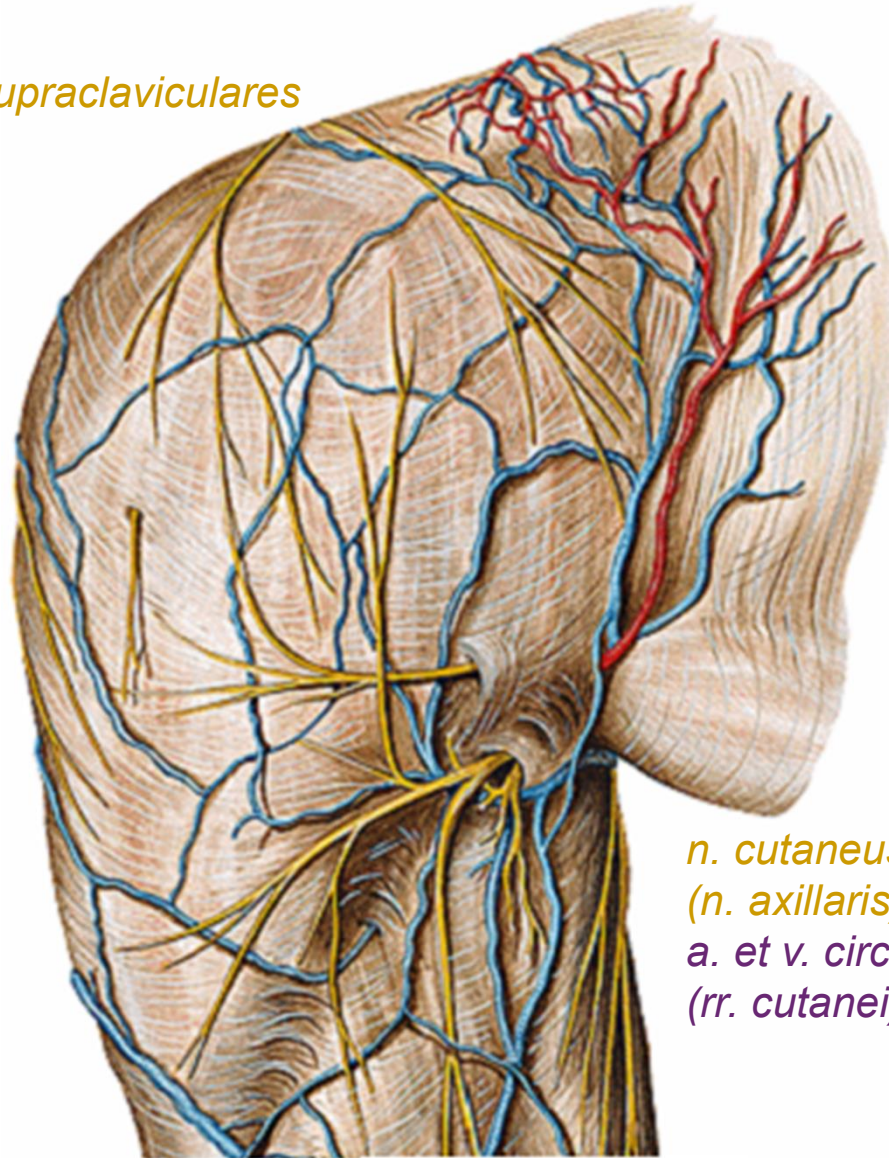
A., V. ET N.
SUPRASCAPULARIS

CAVITAS GLENOIDALIS

r. deltoidea

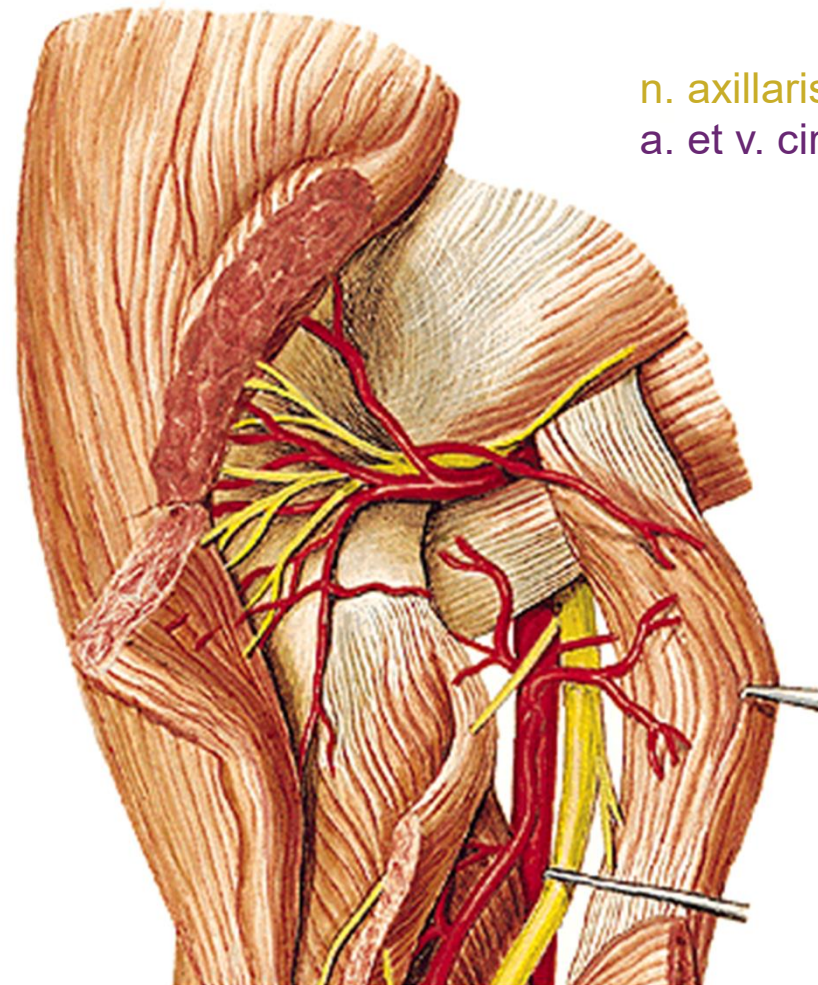


nn. supraclaviculares



*n. cutaneus brachii lat. sup.
(n. axillaris)
a. et v. circumflexa humeri post.
(rr. cutanei)*

*levá končetina
dorsálně*

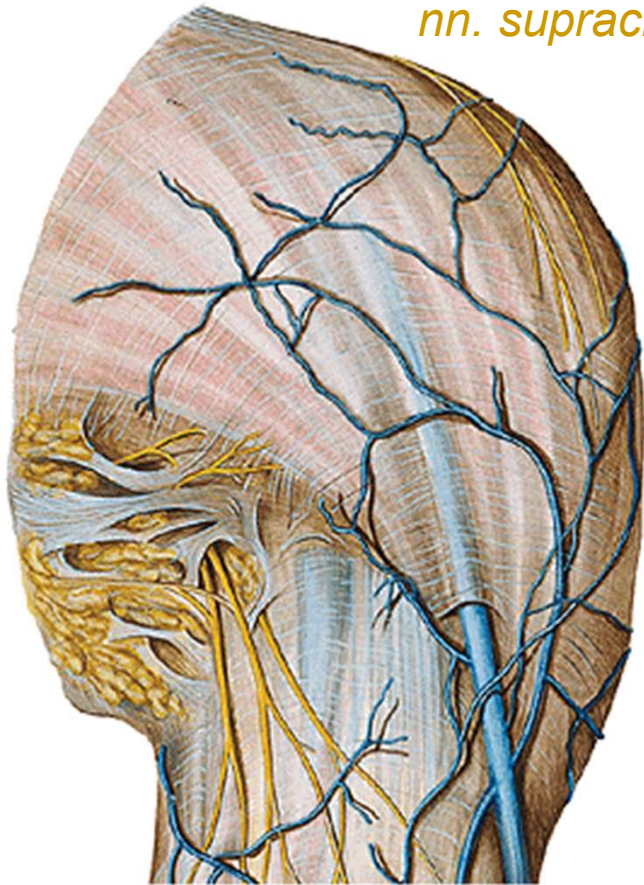


n. axillaris

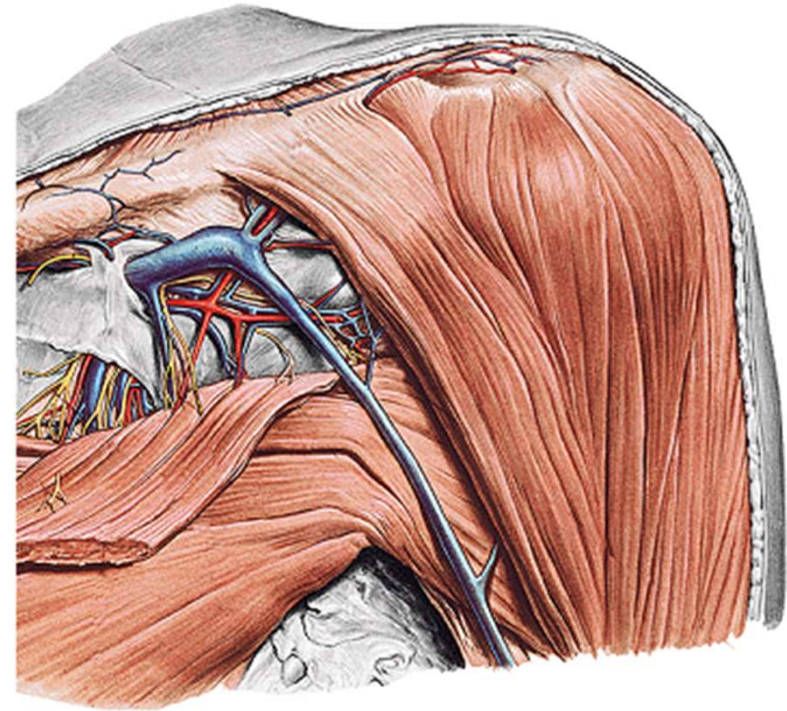
a. et v. circumflexa humeri post.

dorsálně

nn. supraclaviculares

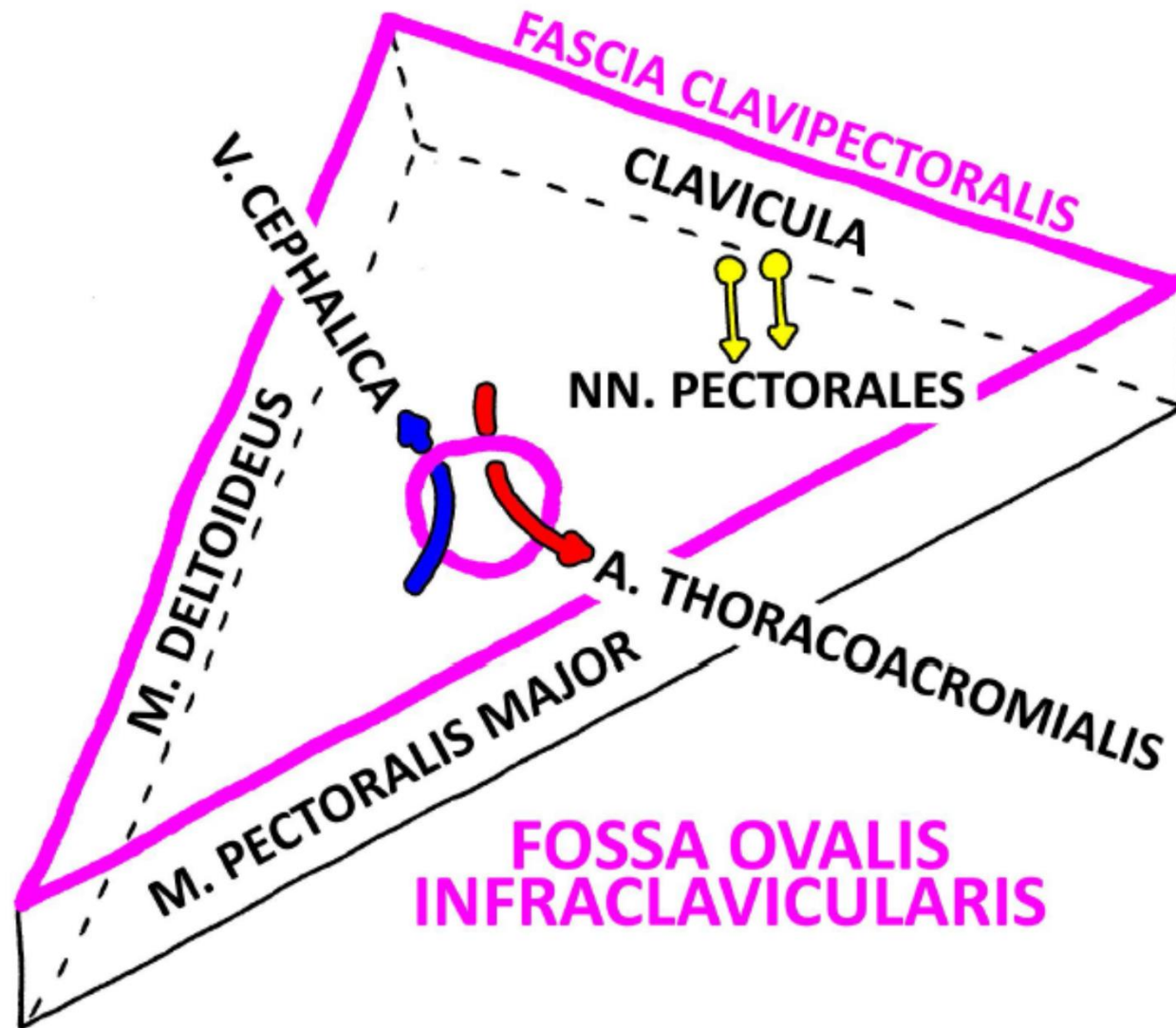


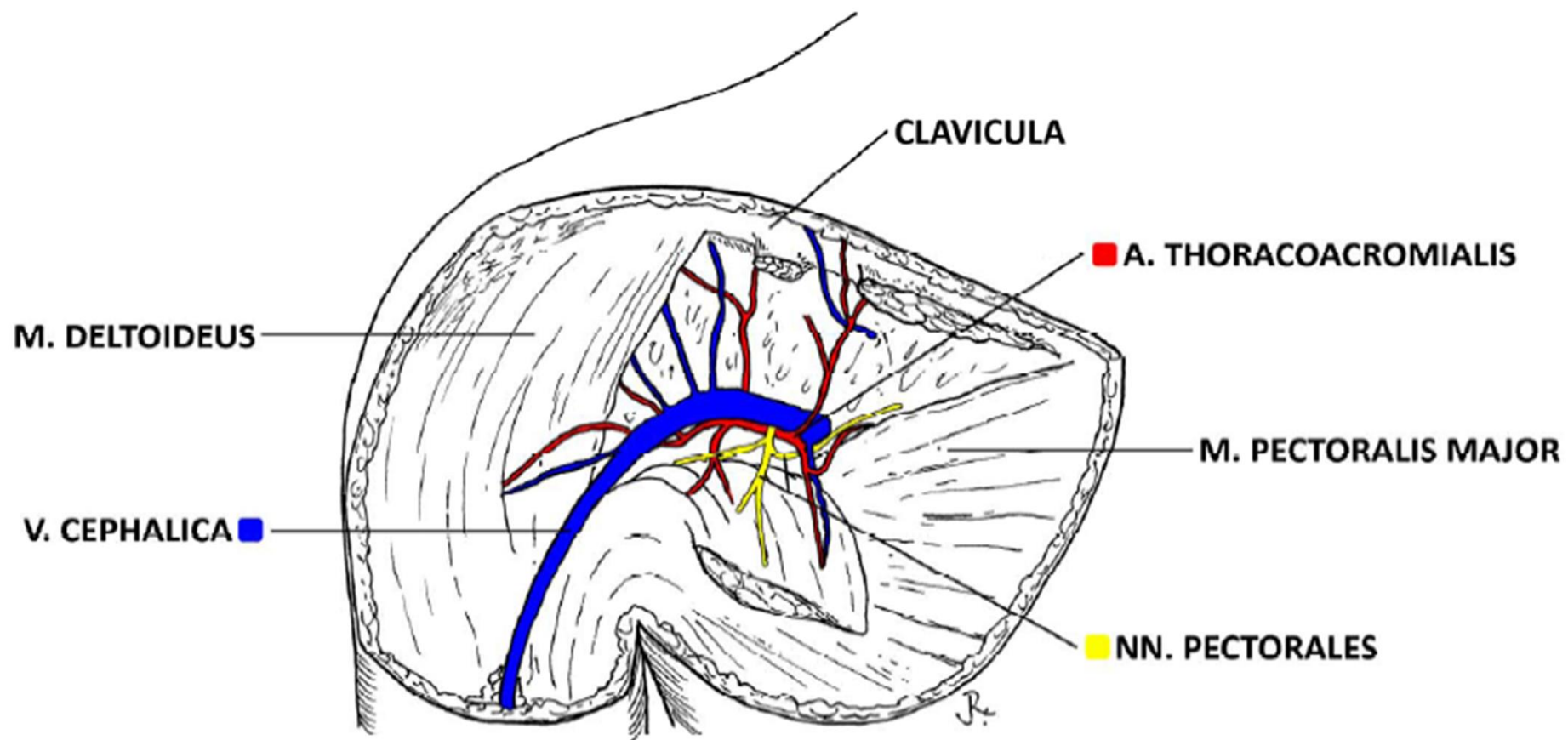
ventrálně

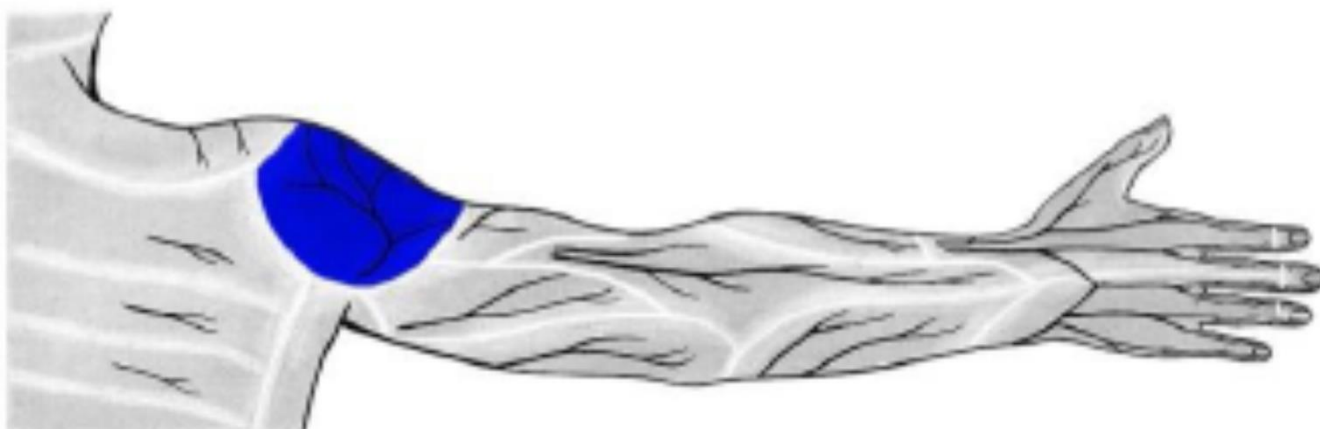
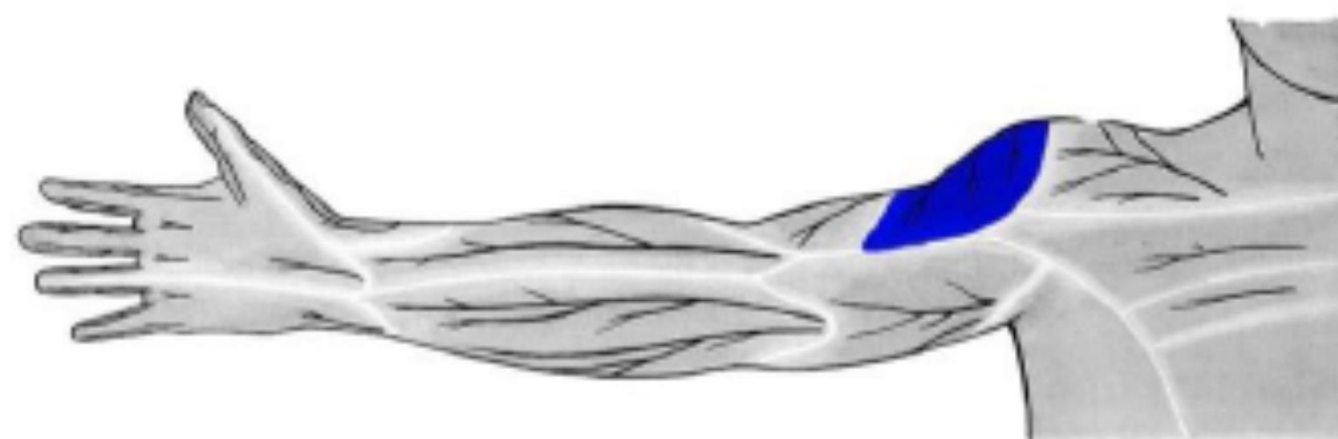


trigonum
deltoideopectorale

TRIGONUM CLAVIPECTORALE DX.

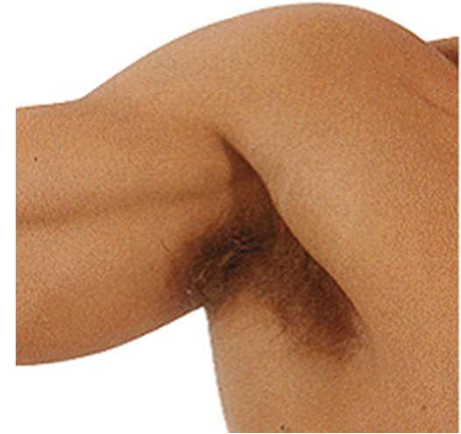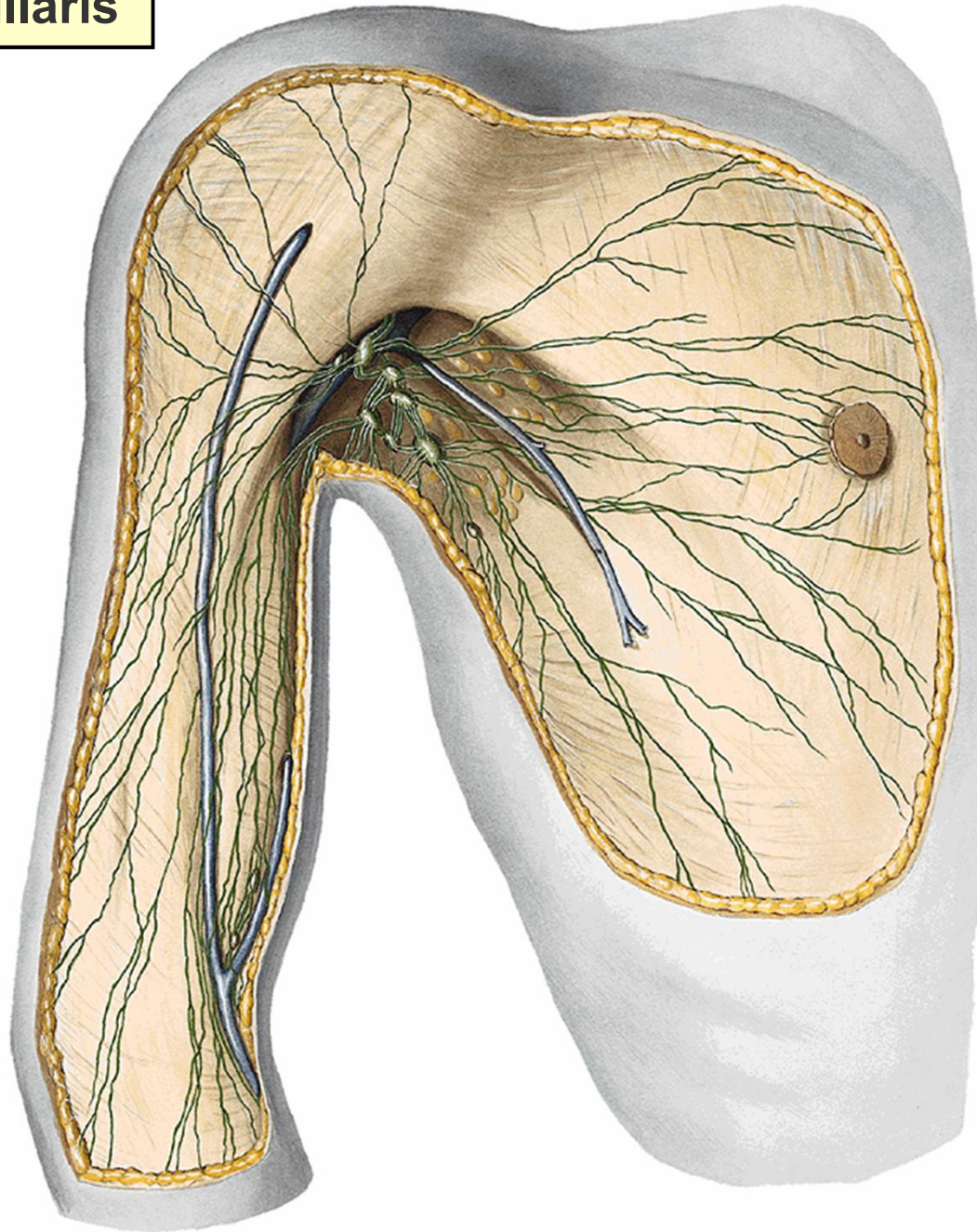




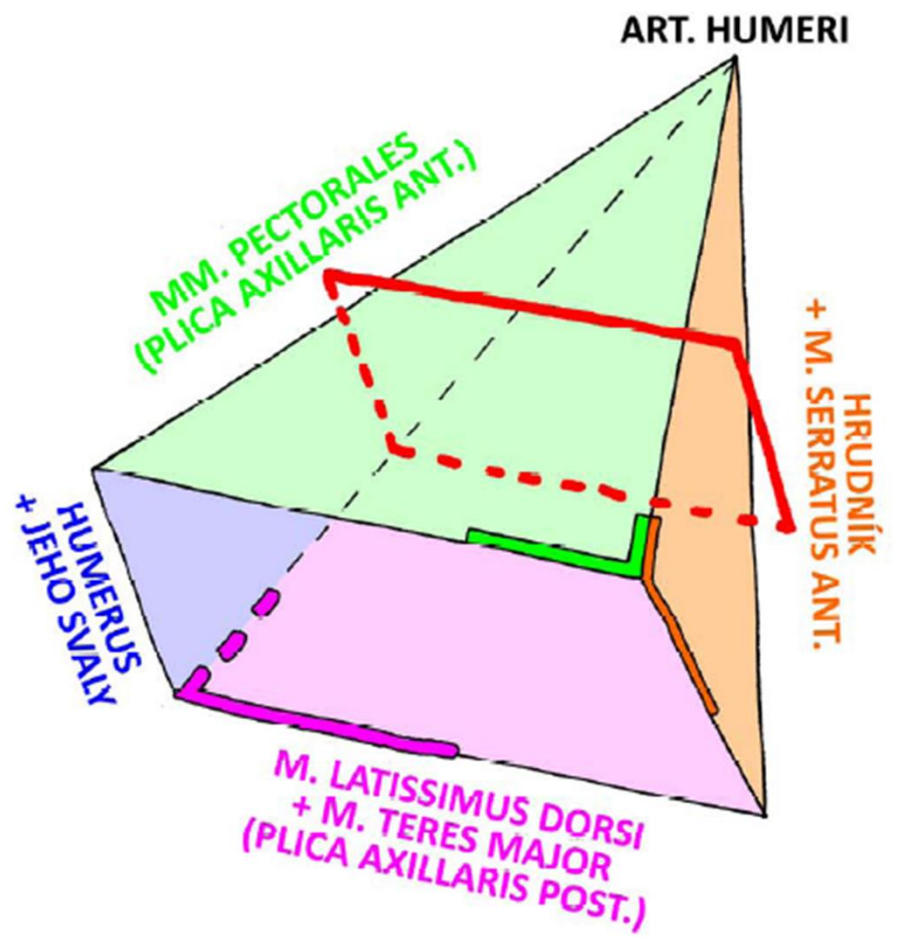

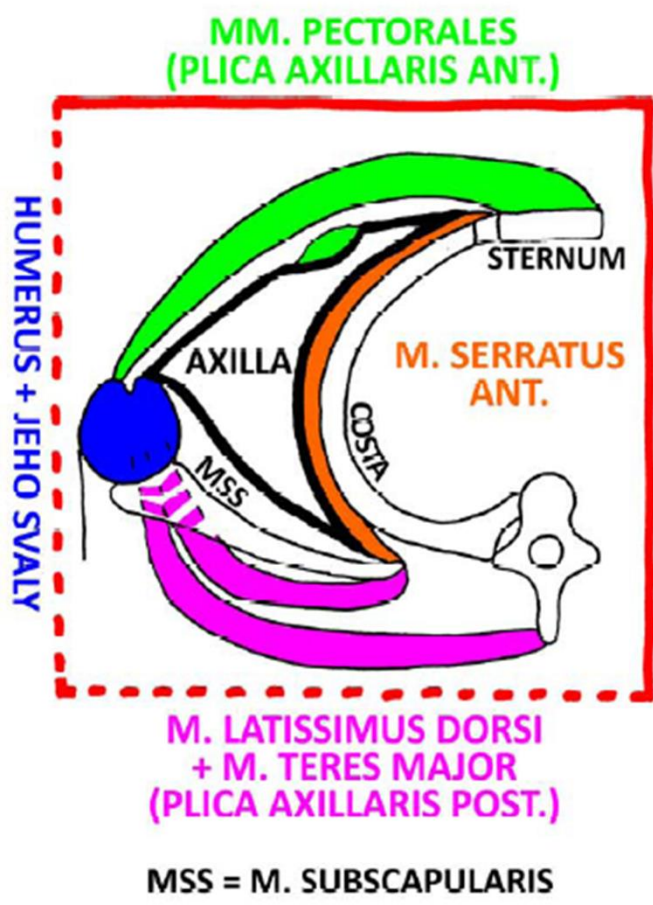
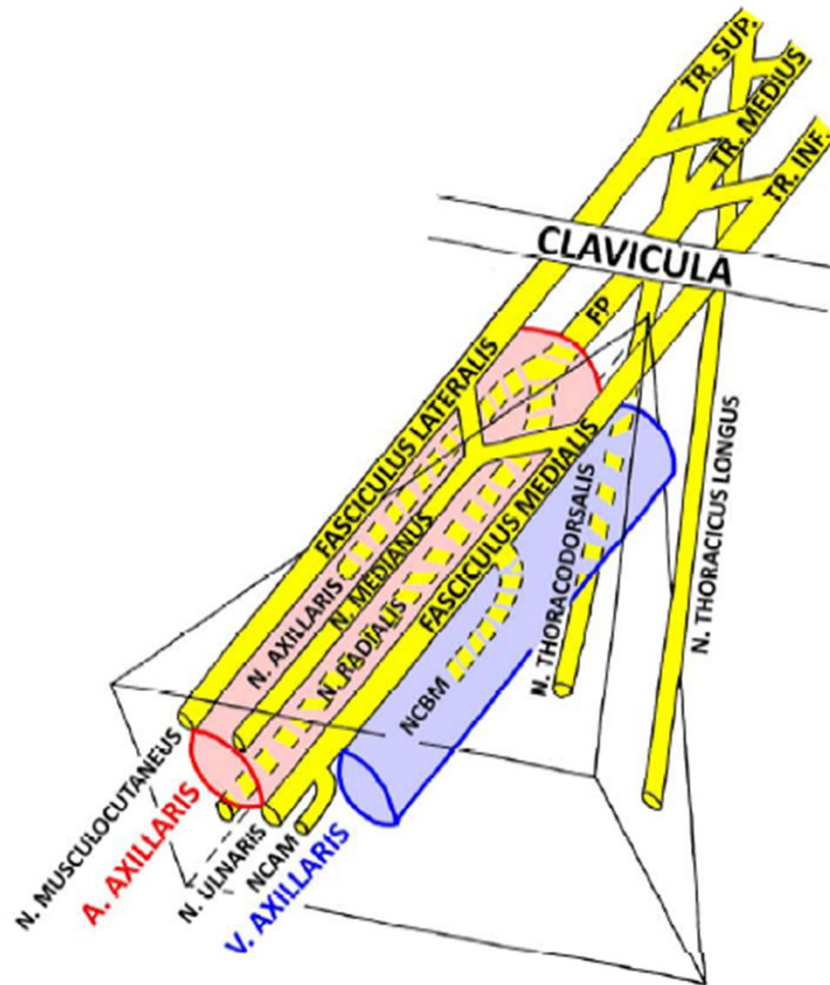
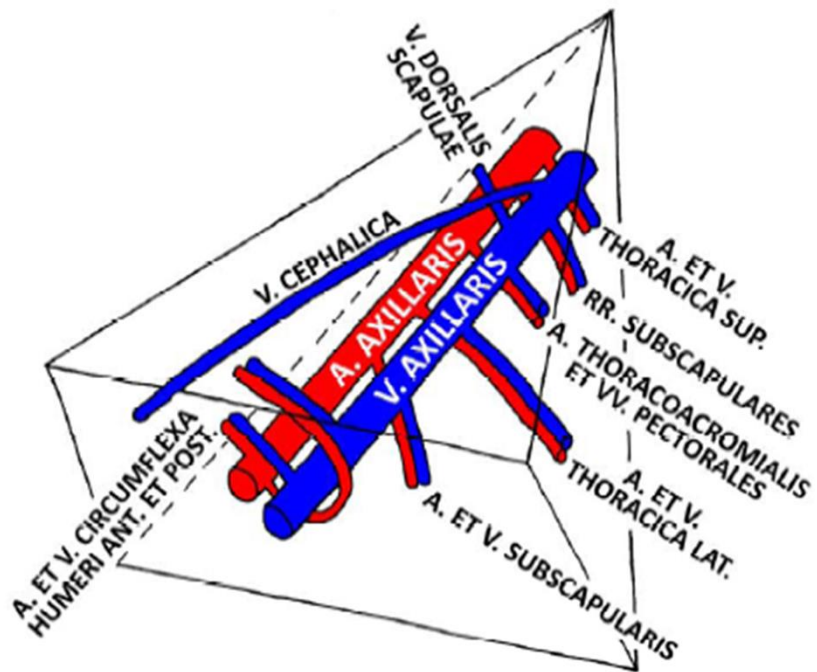
n. cutaneus brachii lat. sup. (z *n. axillaris*)

fossa axillaris

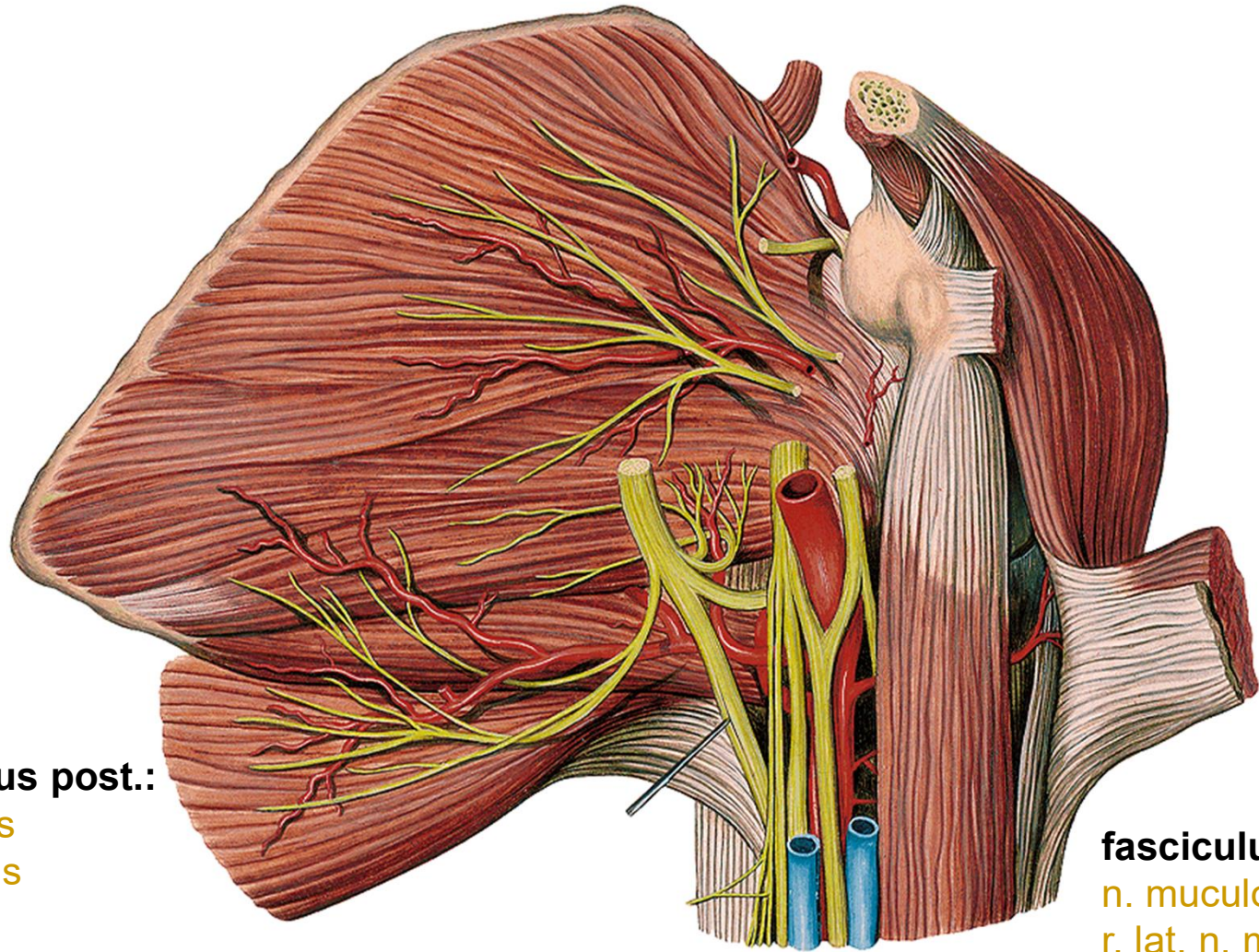


v. thoracoepigastrica
mízní cévy





FP = FASCICULUS POSTERIOR
 NCBM = N. CUTANEUS BRACHII MEDIALIS
 NCAM = N. CUTANEUS ANTEBRACHII MEDIALIS



fasciculus post.:

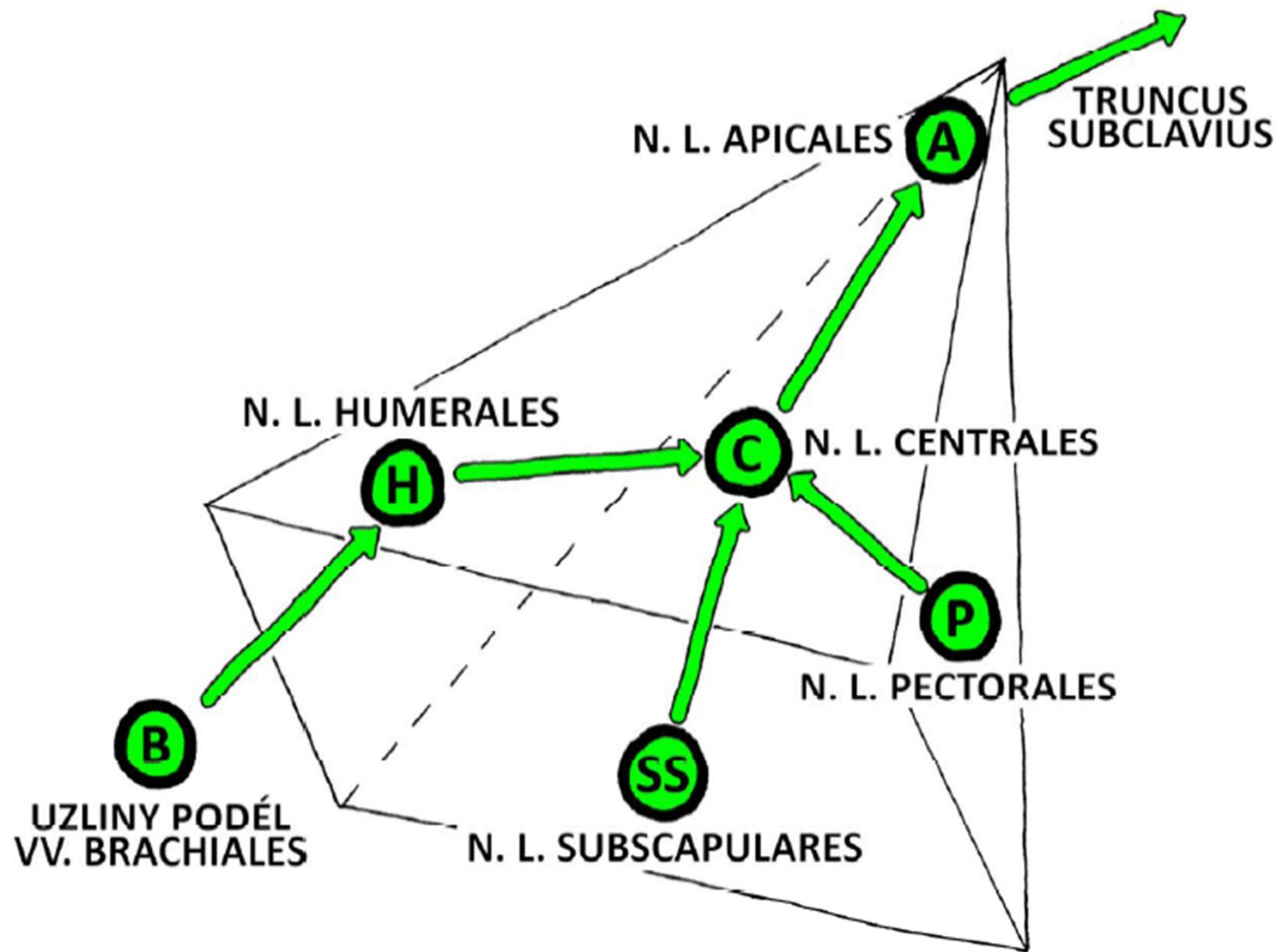
n. radialis
n. axillaris

fasciculus lat.:

n. musculocutaneus
r. lat. n. mediani

fasciculus med.:

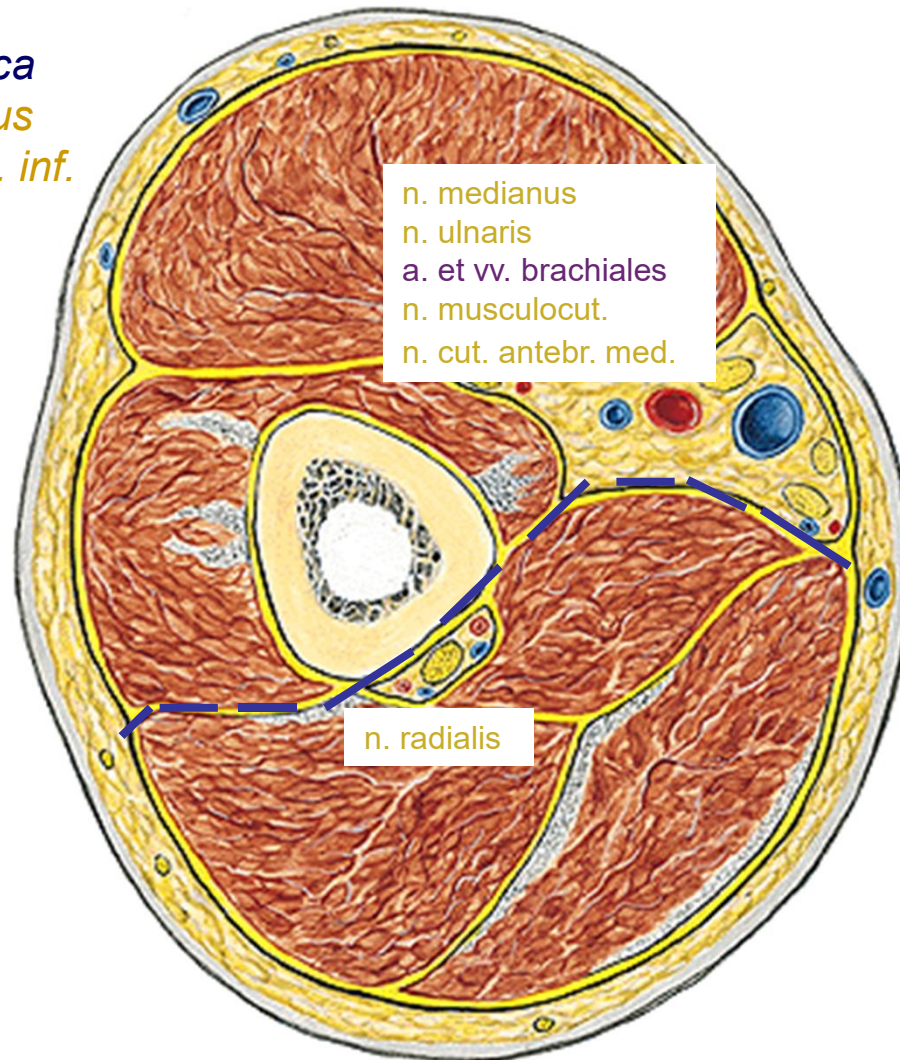
med. n. mediani
n. ulnaris
n. cutaneus brachii med.
n. cutaneus antebrachii med.



r. brachii

pravá, zespodu

v. cephalica
n. cutaneus
brachii lat. inf.

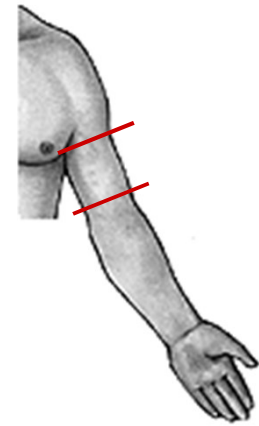


n. medianus
n. ulnaris
a. et vv. brachiales
n. musculocut.
n. cut. antebr. med.

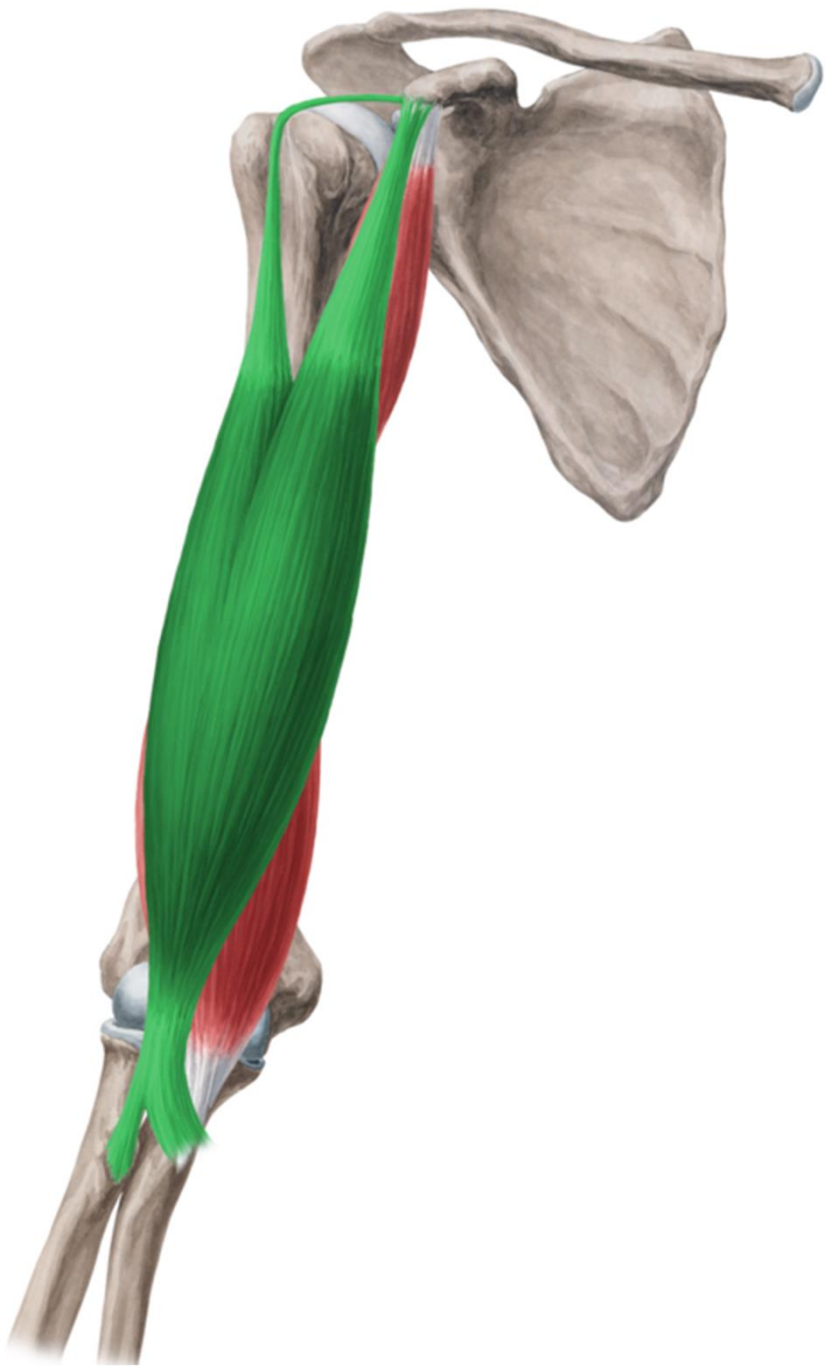n. radialis

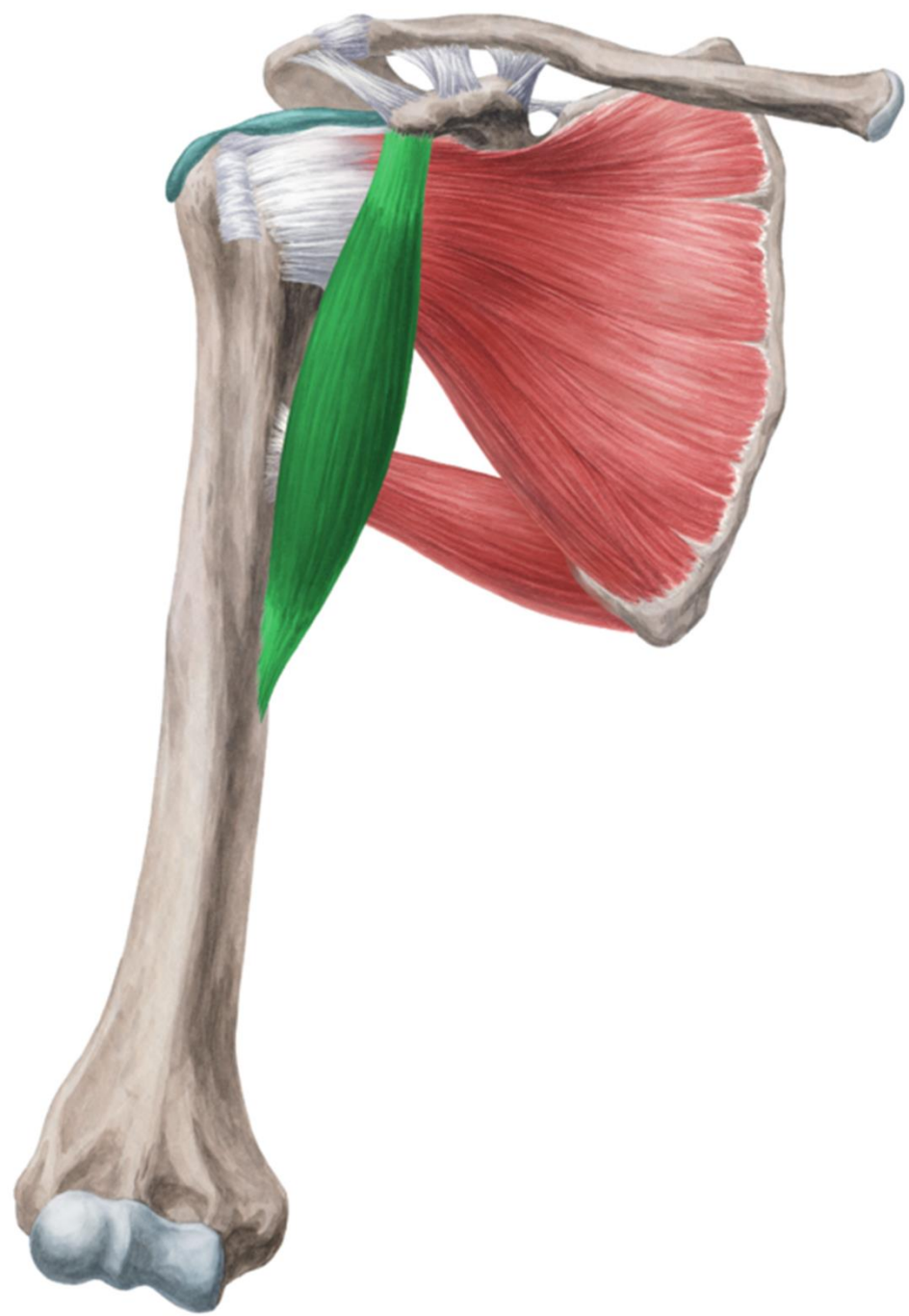
n. cutaneus brachii
post.

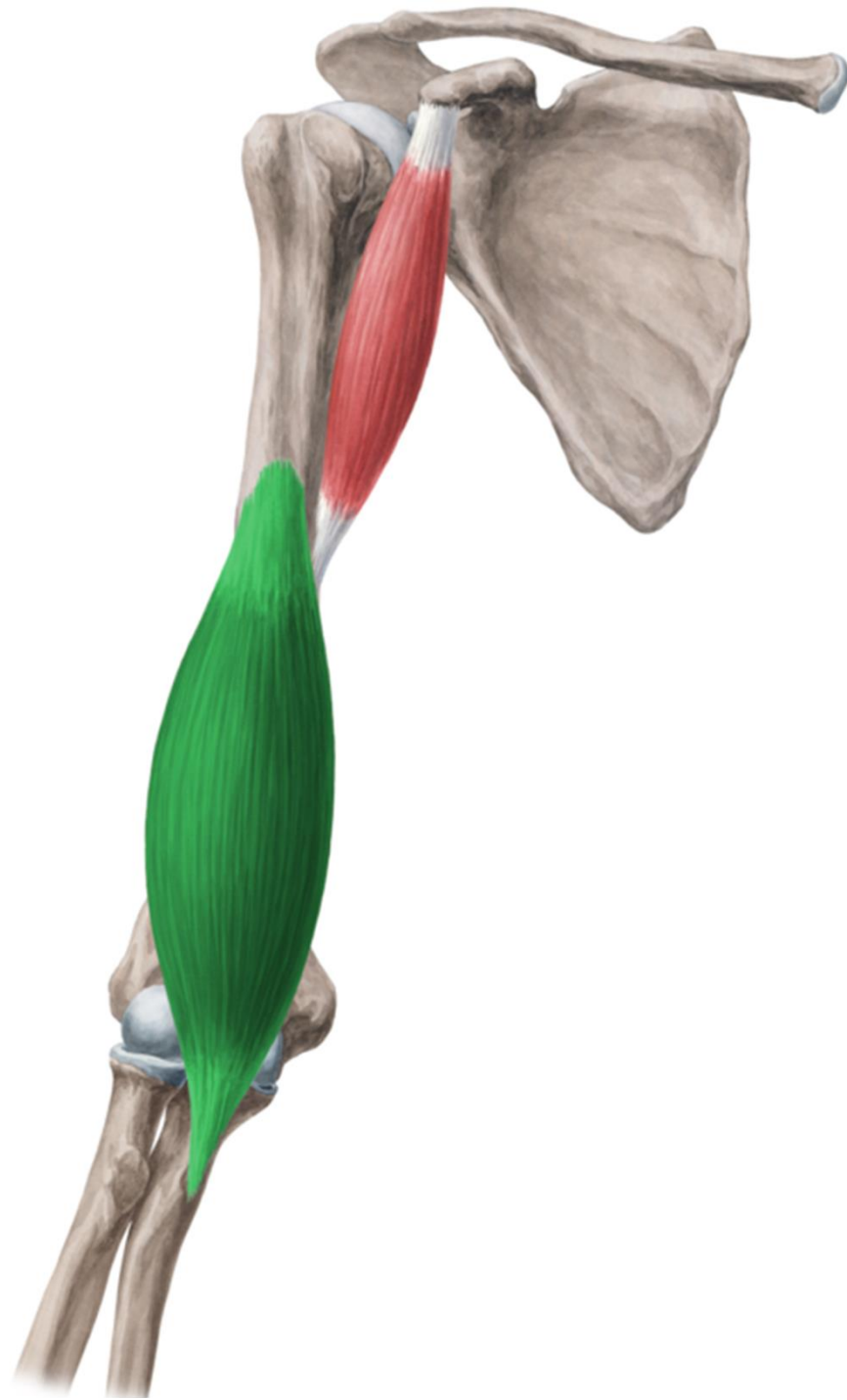
v. basilica
n. cutaneus
brachii med.



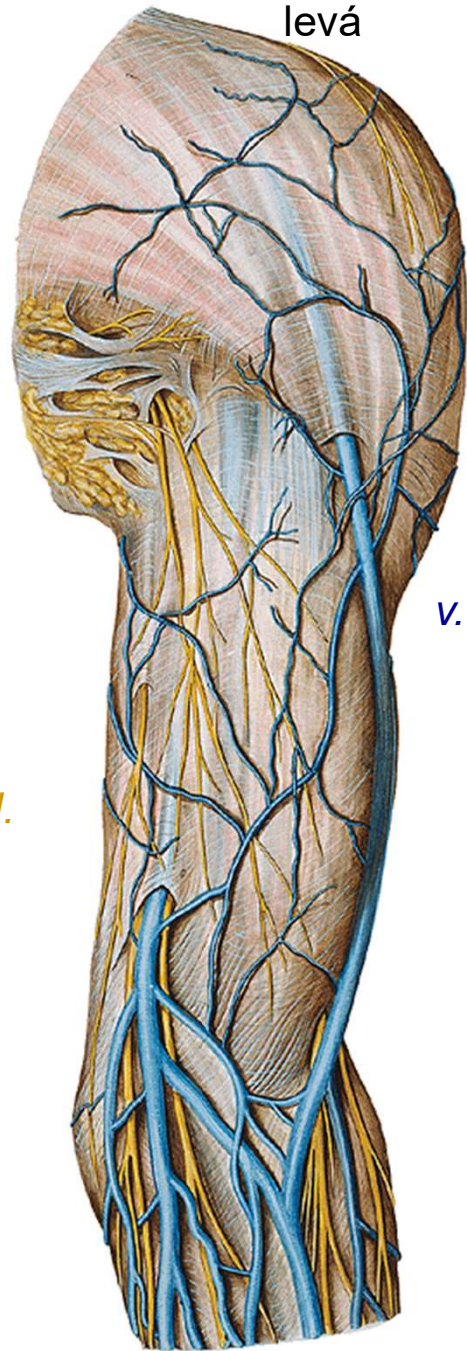
r. brachii ant.







levá

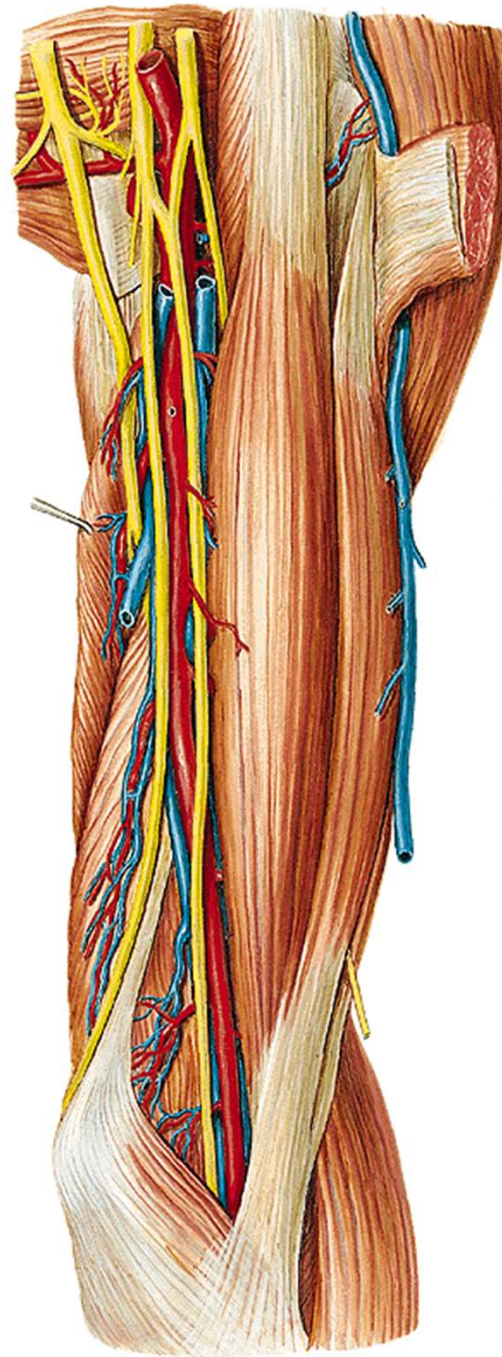


n. cutaneus brachii med.

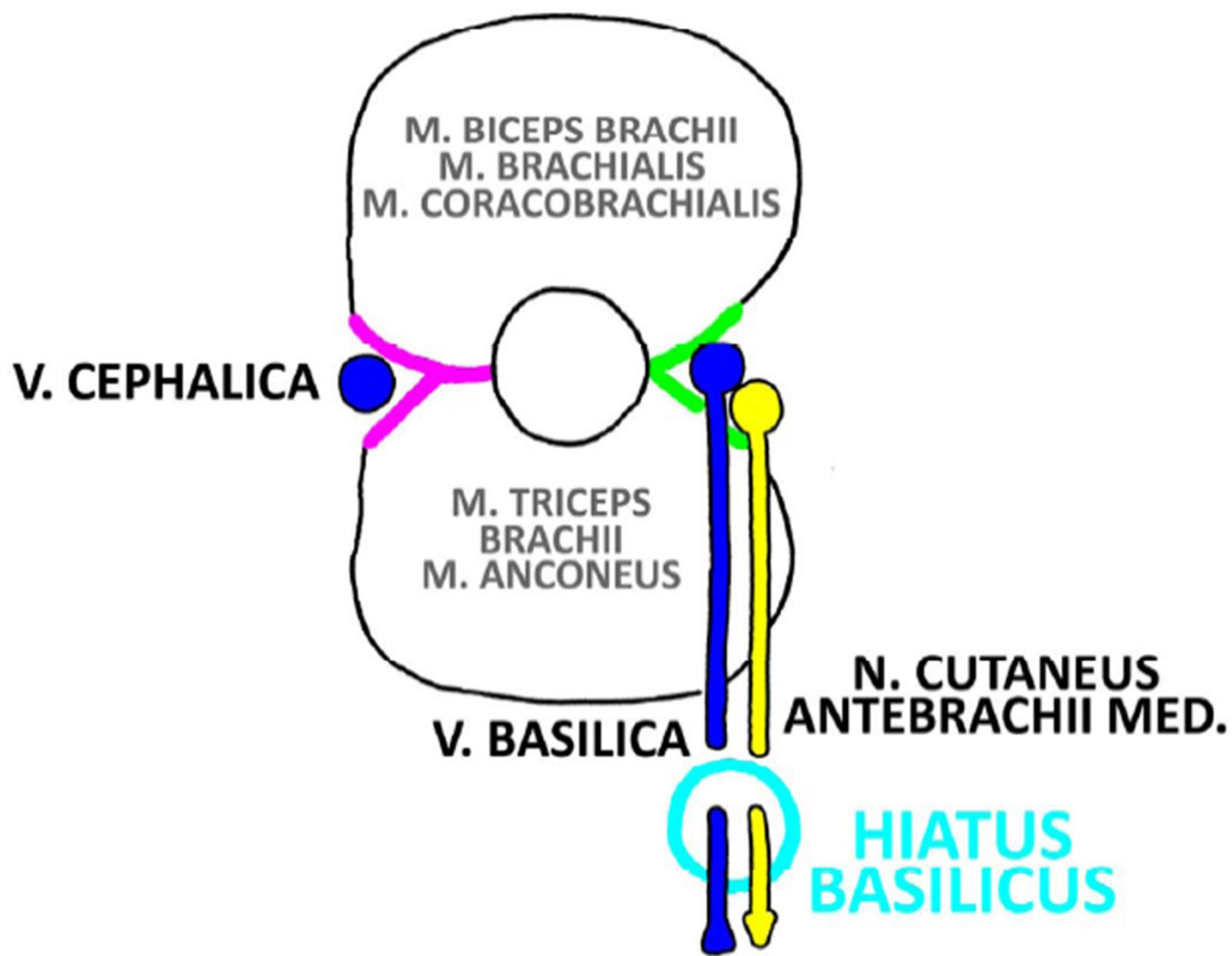
v. cephalica

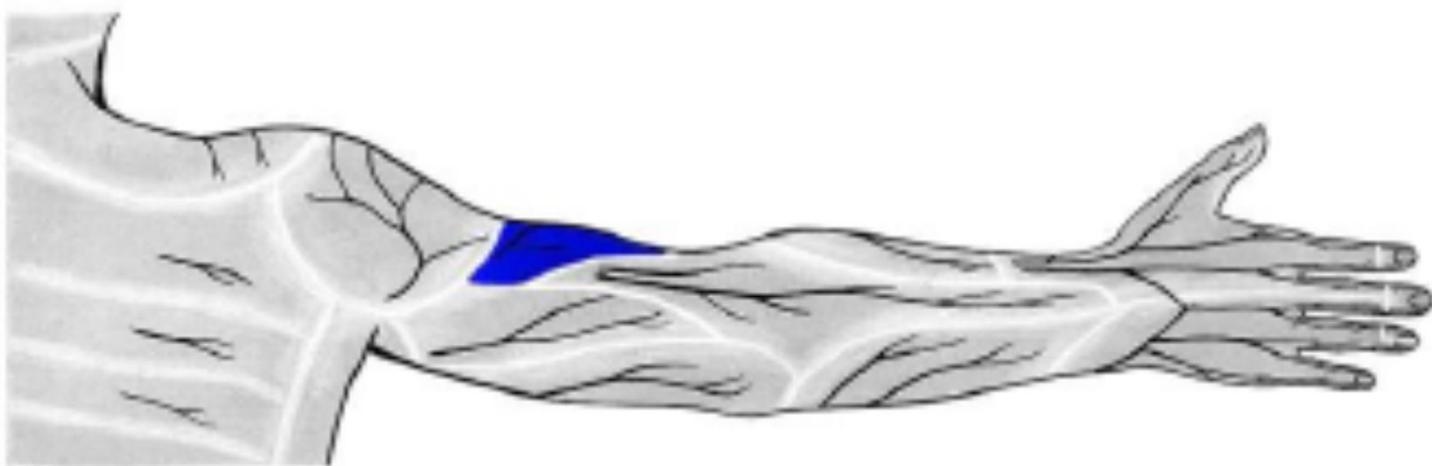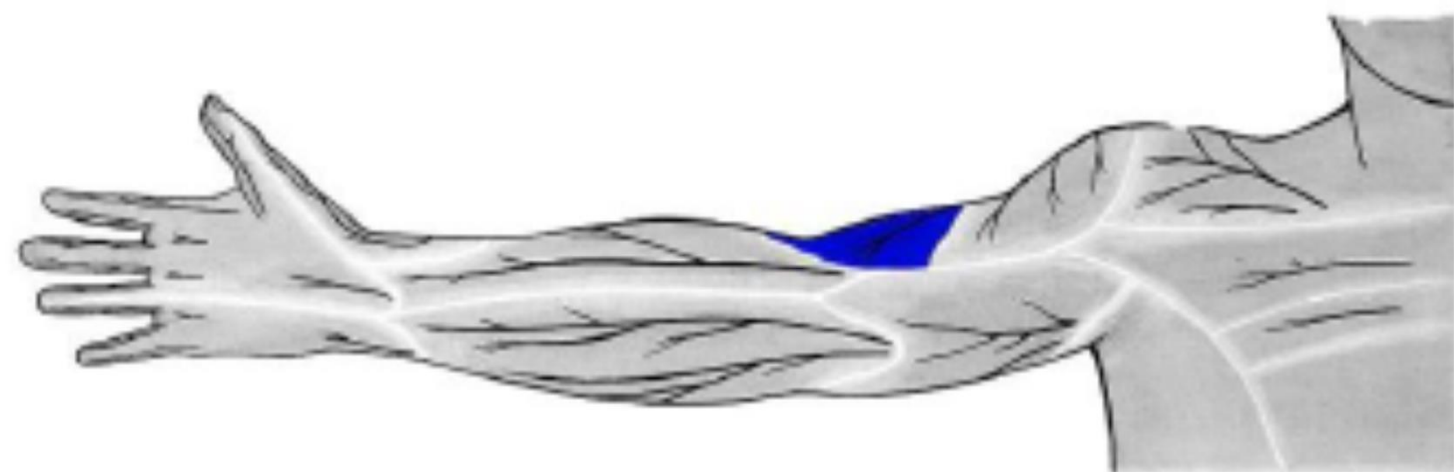n. cutaneus antebrachii med.
v. basilica

a. et. v. brachialis
n. musculocutaneus
n. medianus
n. ulnaris




SULCUS BICIPITALIS MEDIALIS ET LATERALIS



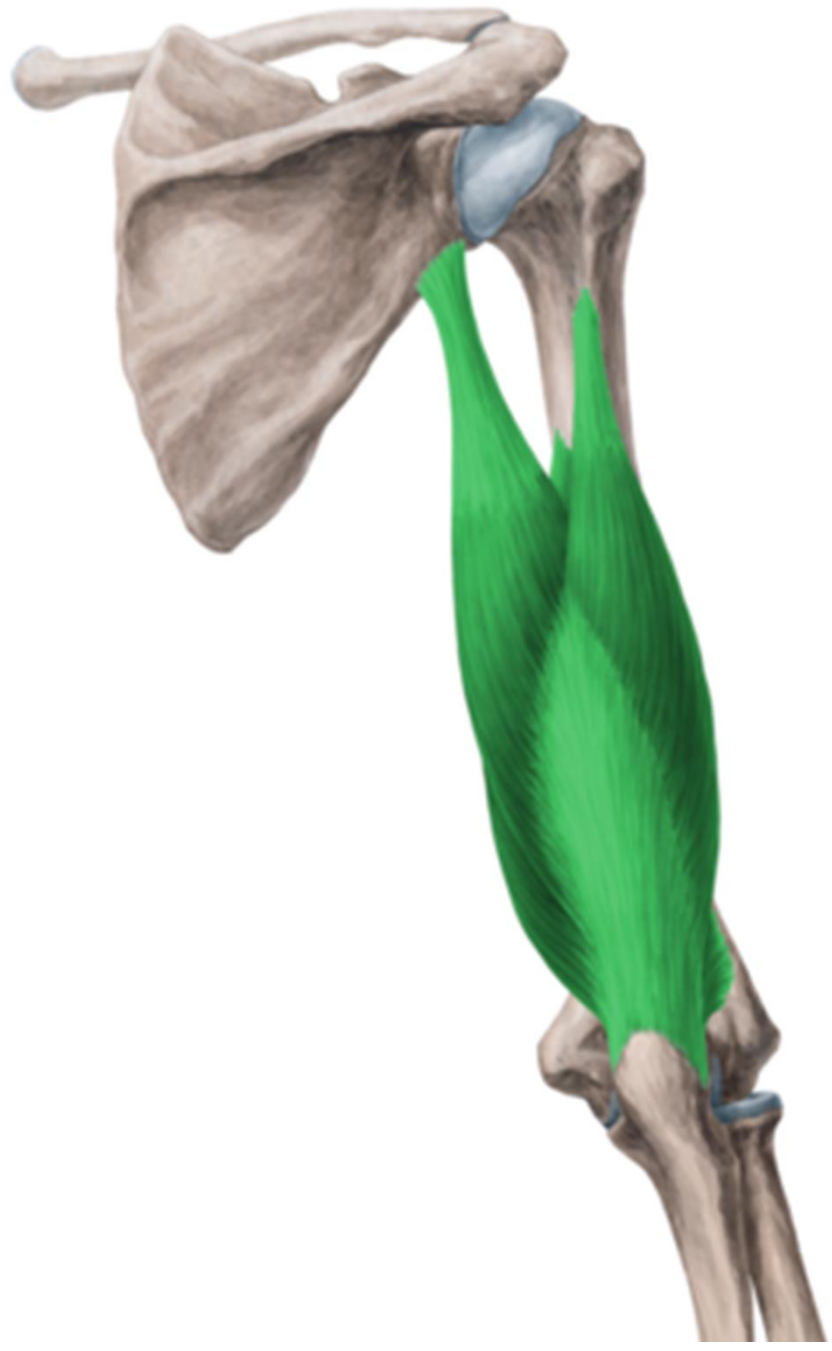

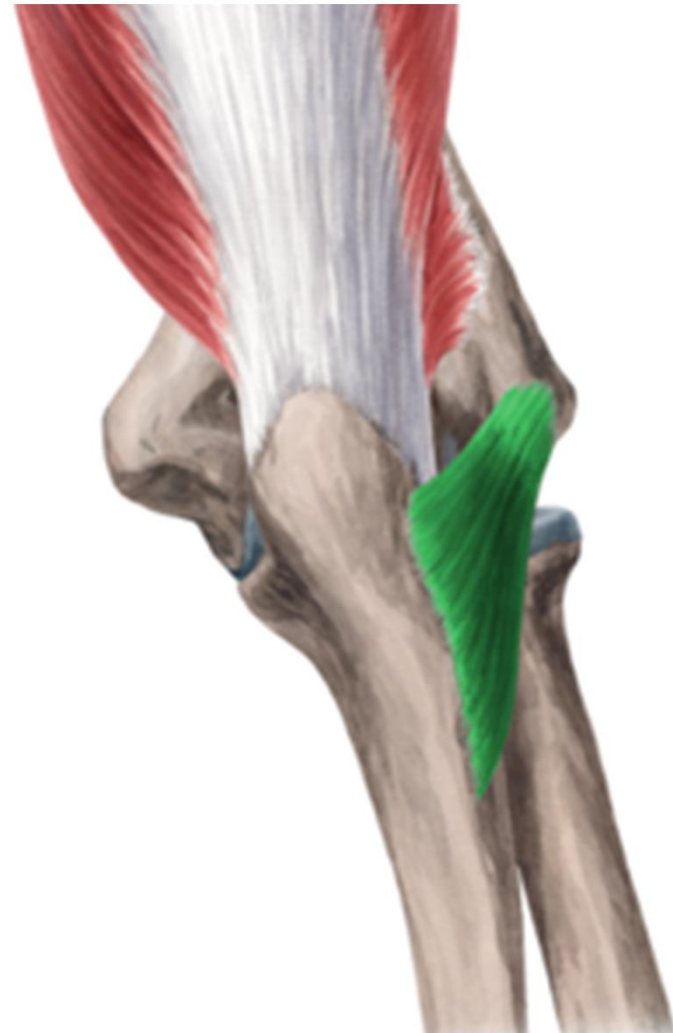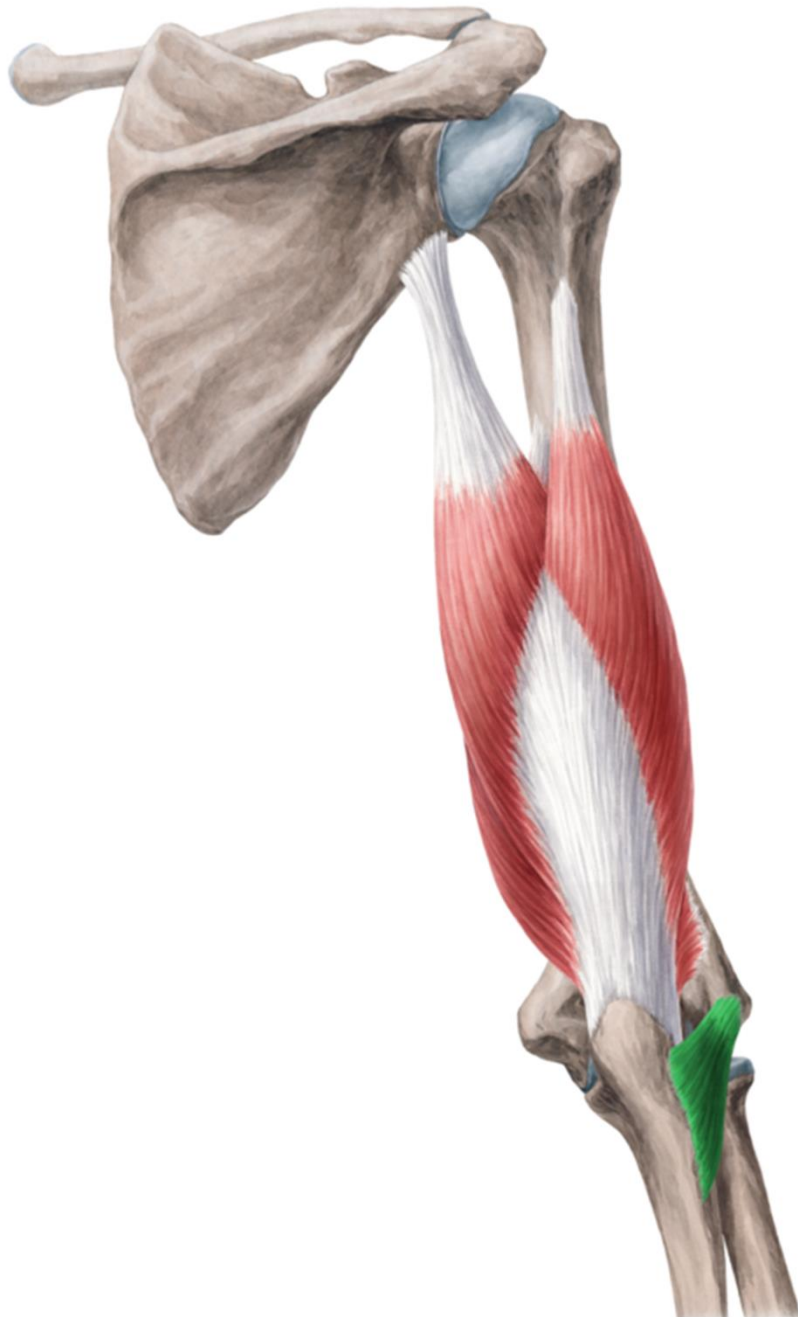n. cutaneus brachii lat. inf. (z *n. radialis*)



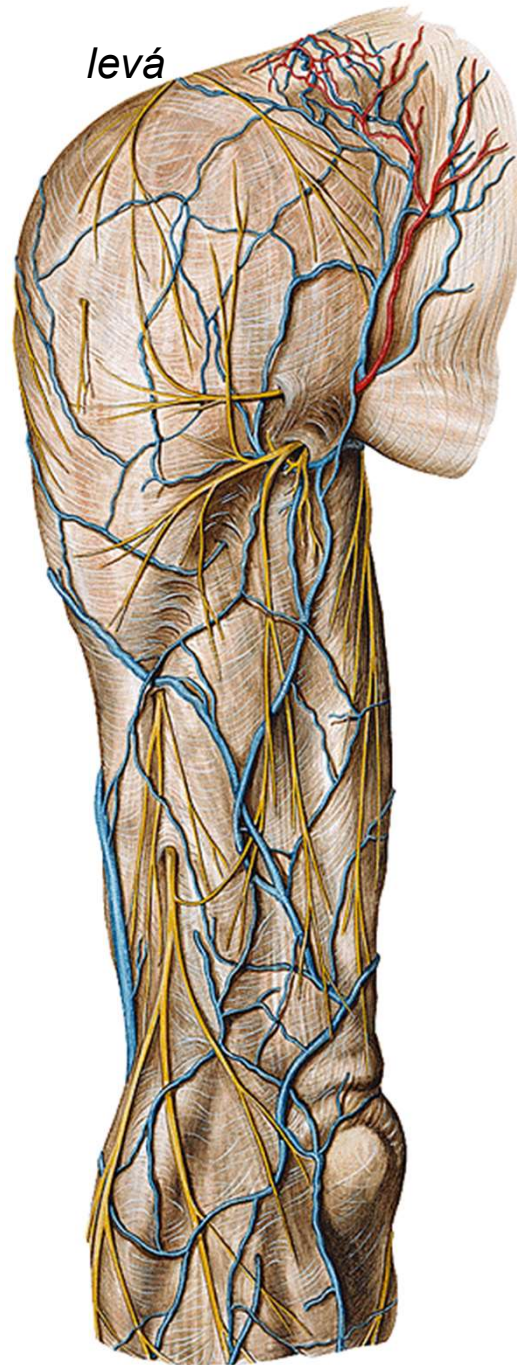
n. cutaneus brachii med.
(z *fasciculus medialis*)

r. brachii post.





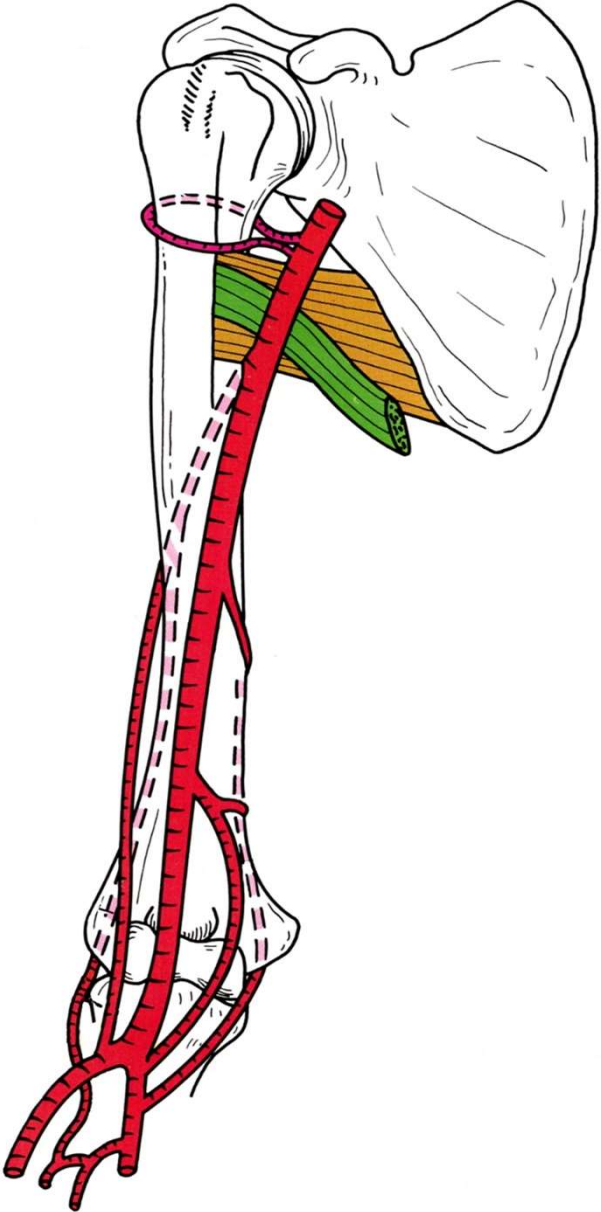
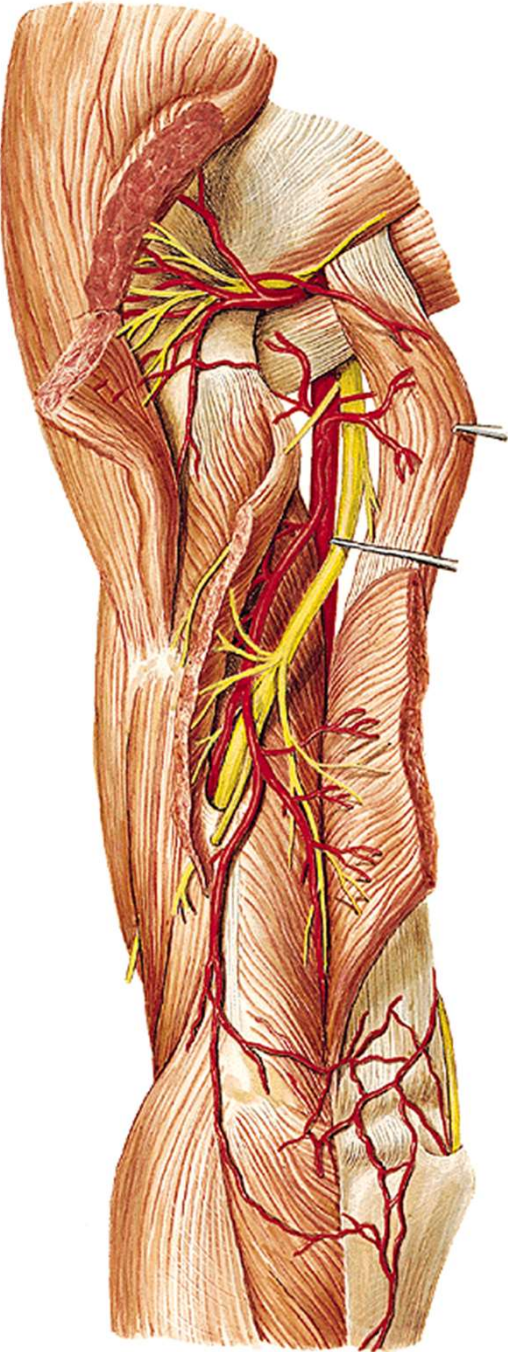
levá



n. cutaneus brachii lat. sup.
(*n. axillaris*)

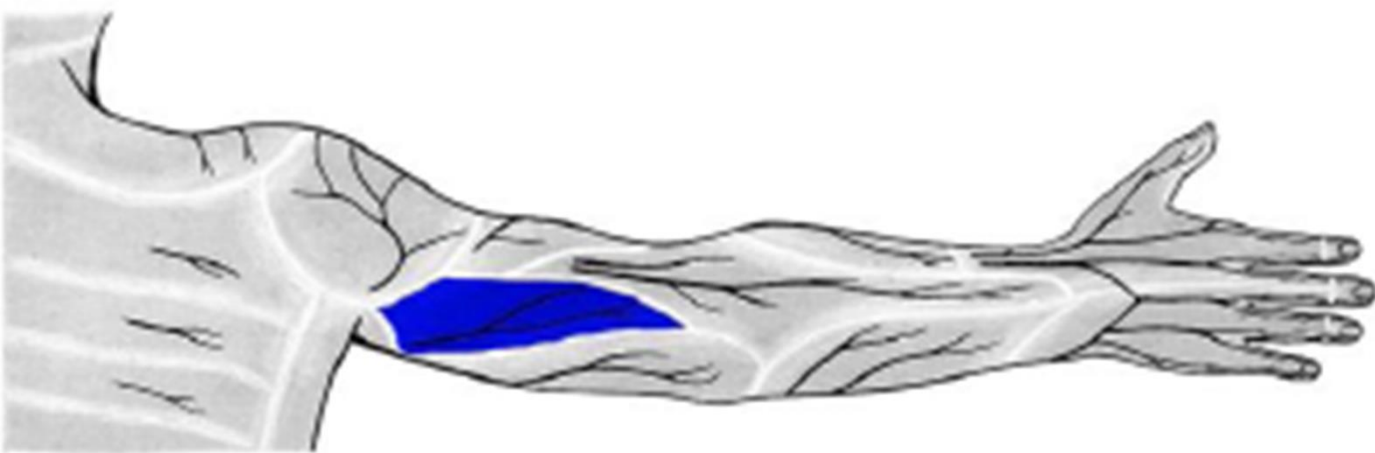
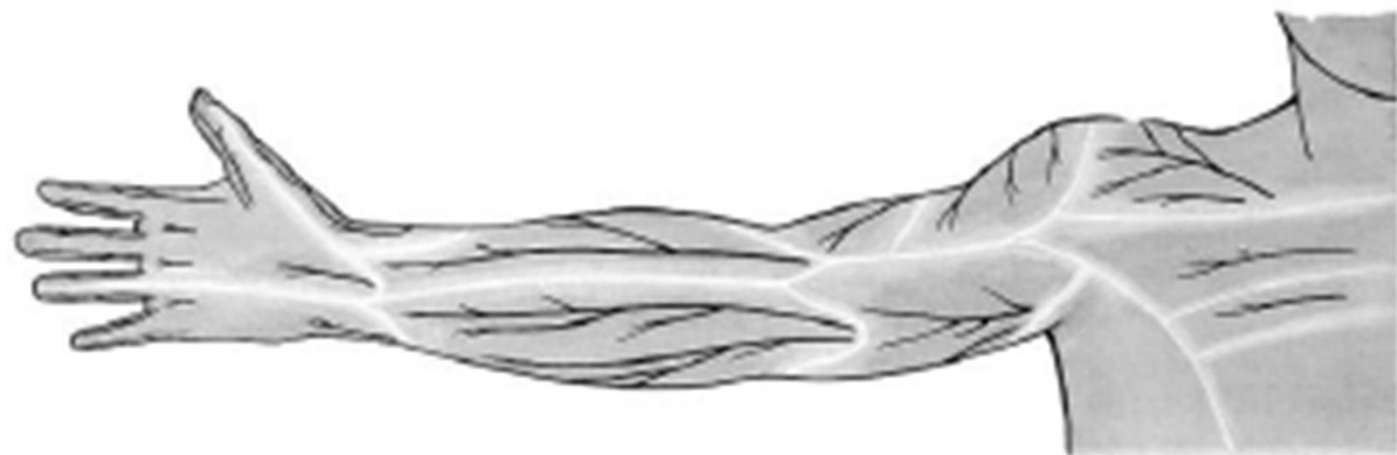cutaneus brachii lat. inf.
n. cutaneus brachii post.
n. cutaneus antebrachii post.
(*n. radialis*)

n. radialis
a. et. v. profunda brachii

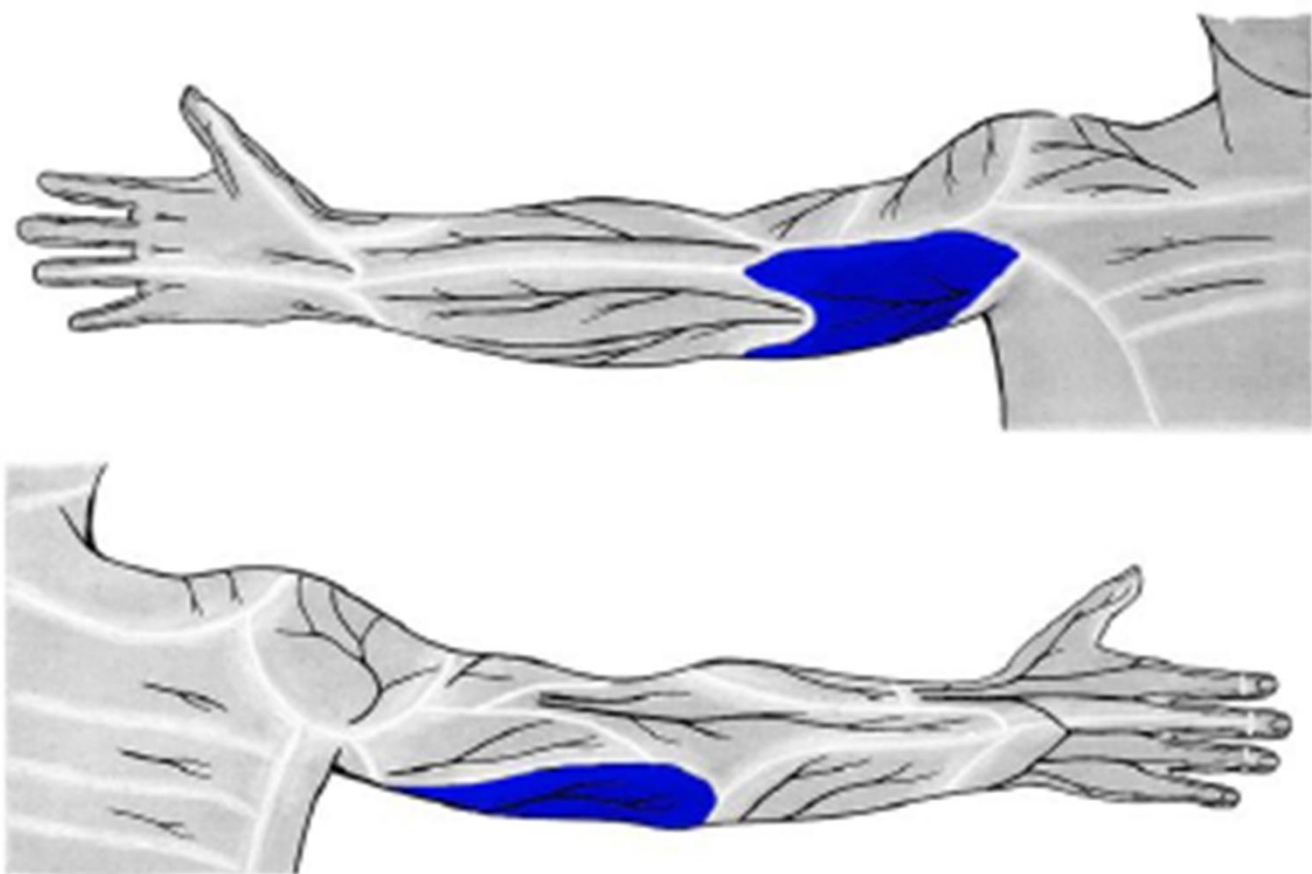




n. cutaneus brachii lat. inf. (z *n. radialis*)

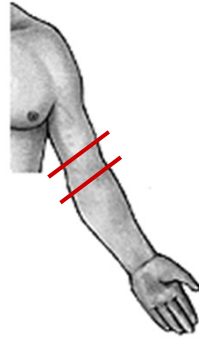


n. cutaneus brachii post. (z n. radialis)

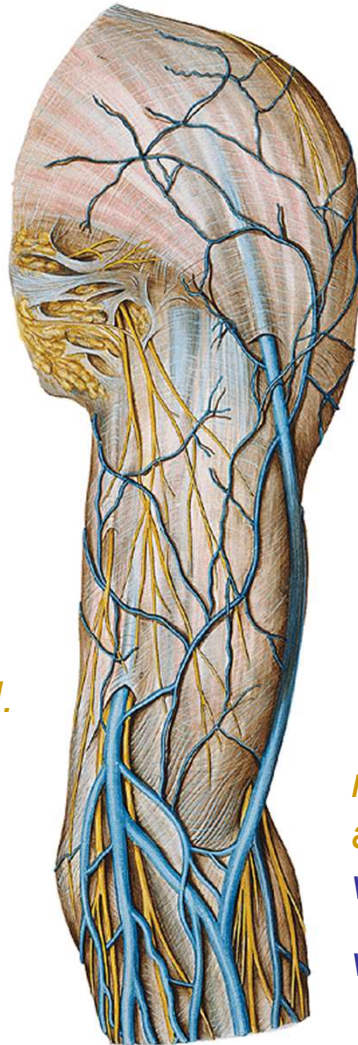

n. cutaneus brachii med.
(z *fasciculus medialis*)

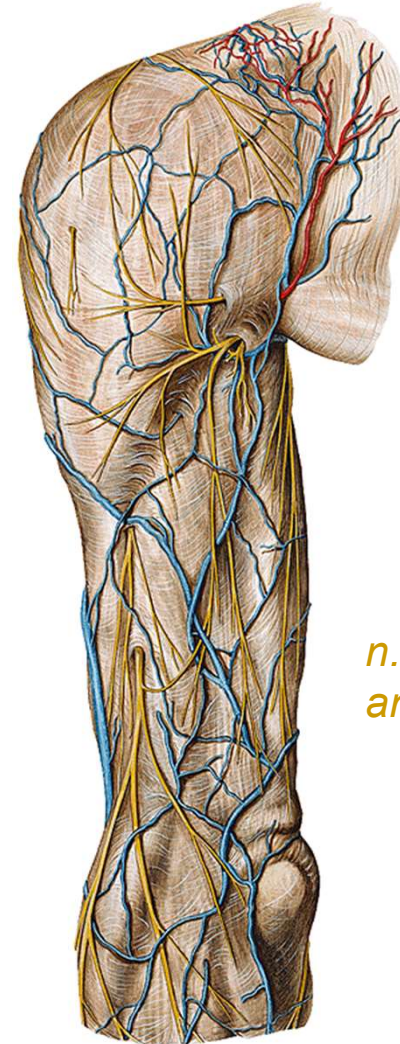
r. cubiti



*n. cutaneus
antebr. med.
v. basilica*

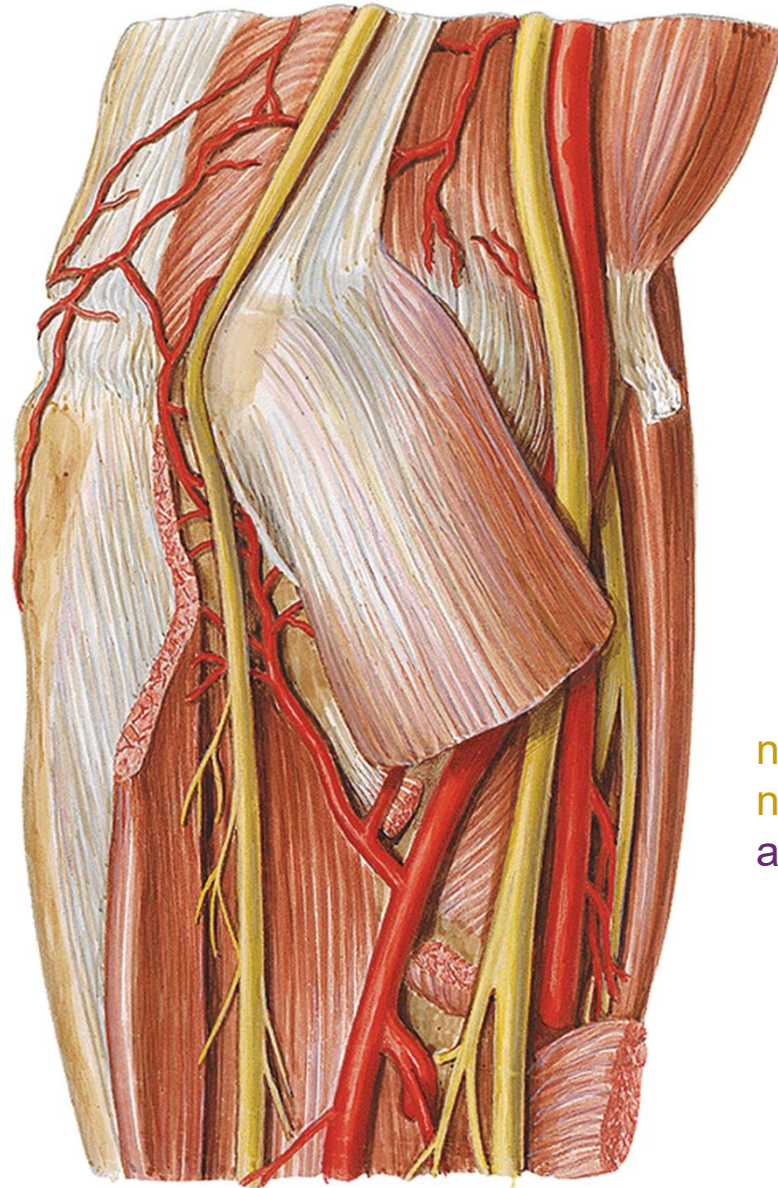


*n. cutaneus
antebr. lat.
v. cephalica
v. mediana cubiti*



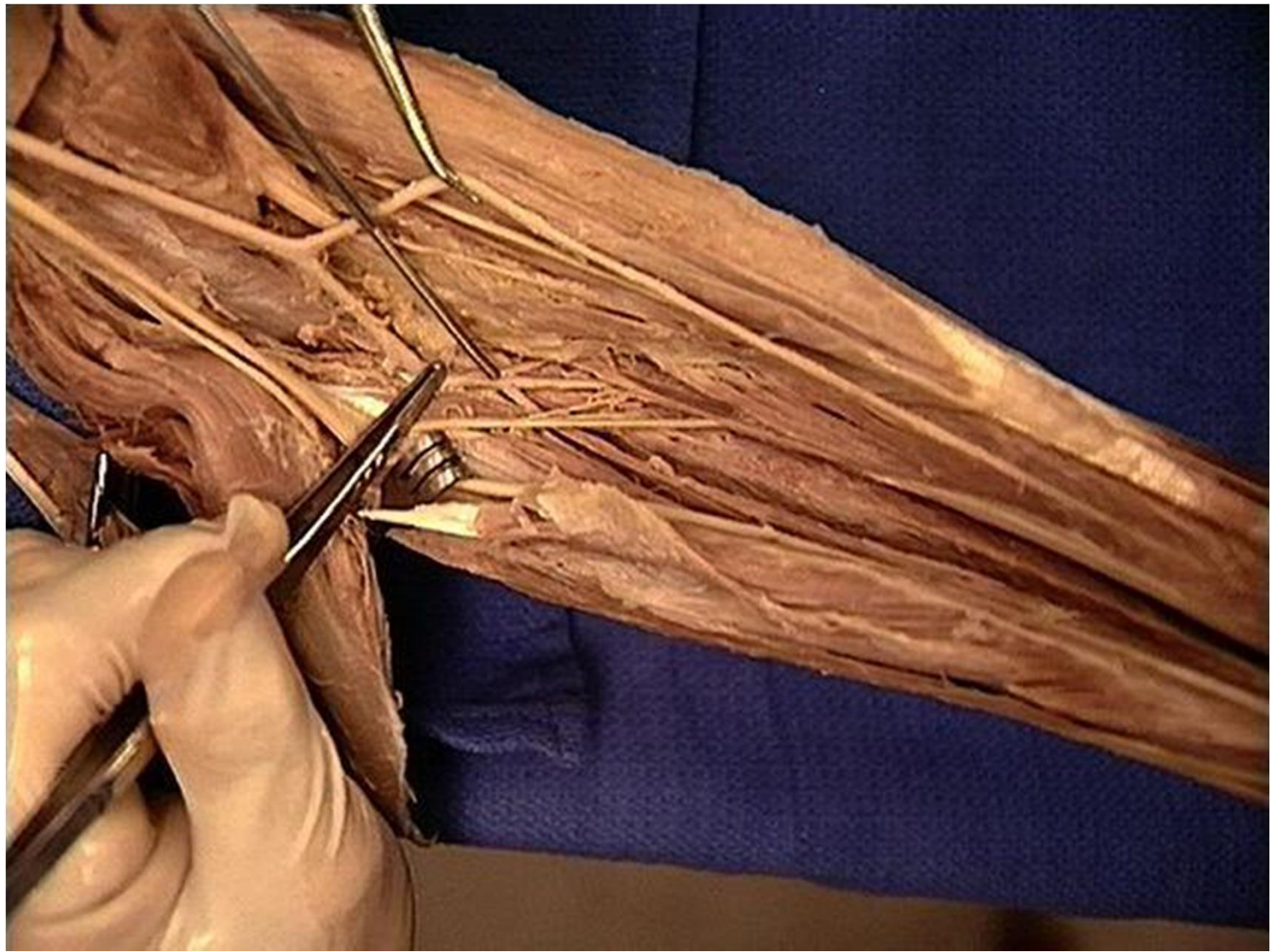
*n. cutaneus
antebr. post.*

pohled med.

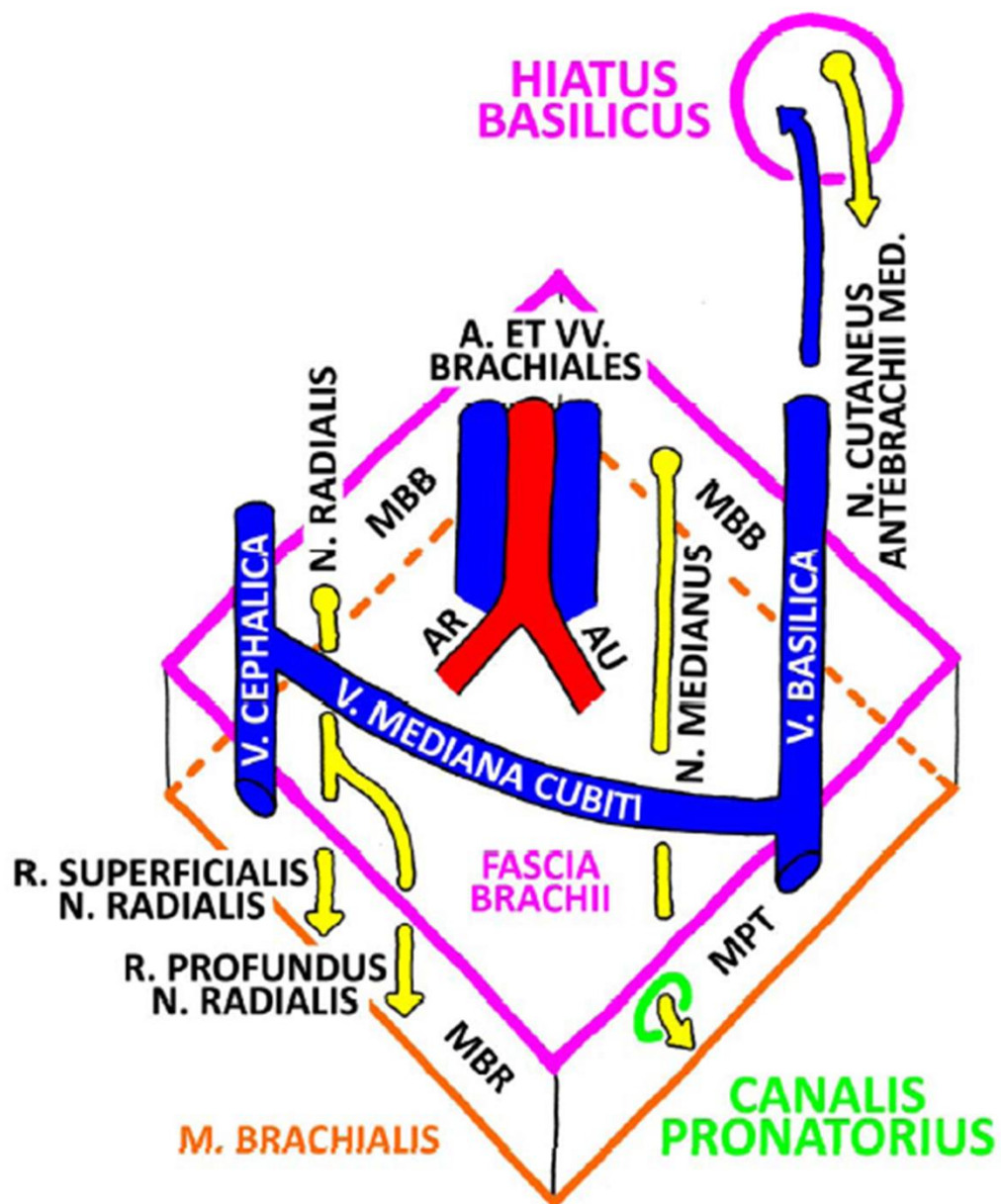


n. ulnaris
a. et v. ulnaris

n. medianus
n. radialis (r. superf.)
a. et v. radialis

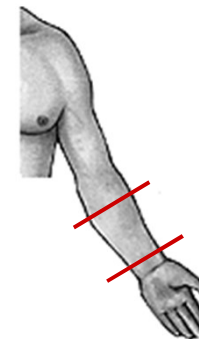


FOSSA CUBITALIS DX.



r. antebrachii

pravá, pohled zdola



n. cut. antebr. lat. v. cephalica

*n. ulnaris
a. et v. ulnaris*

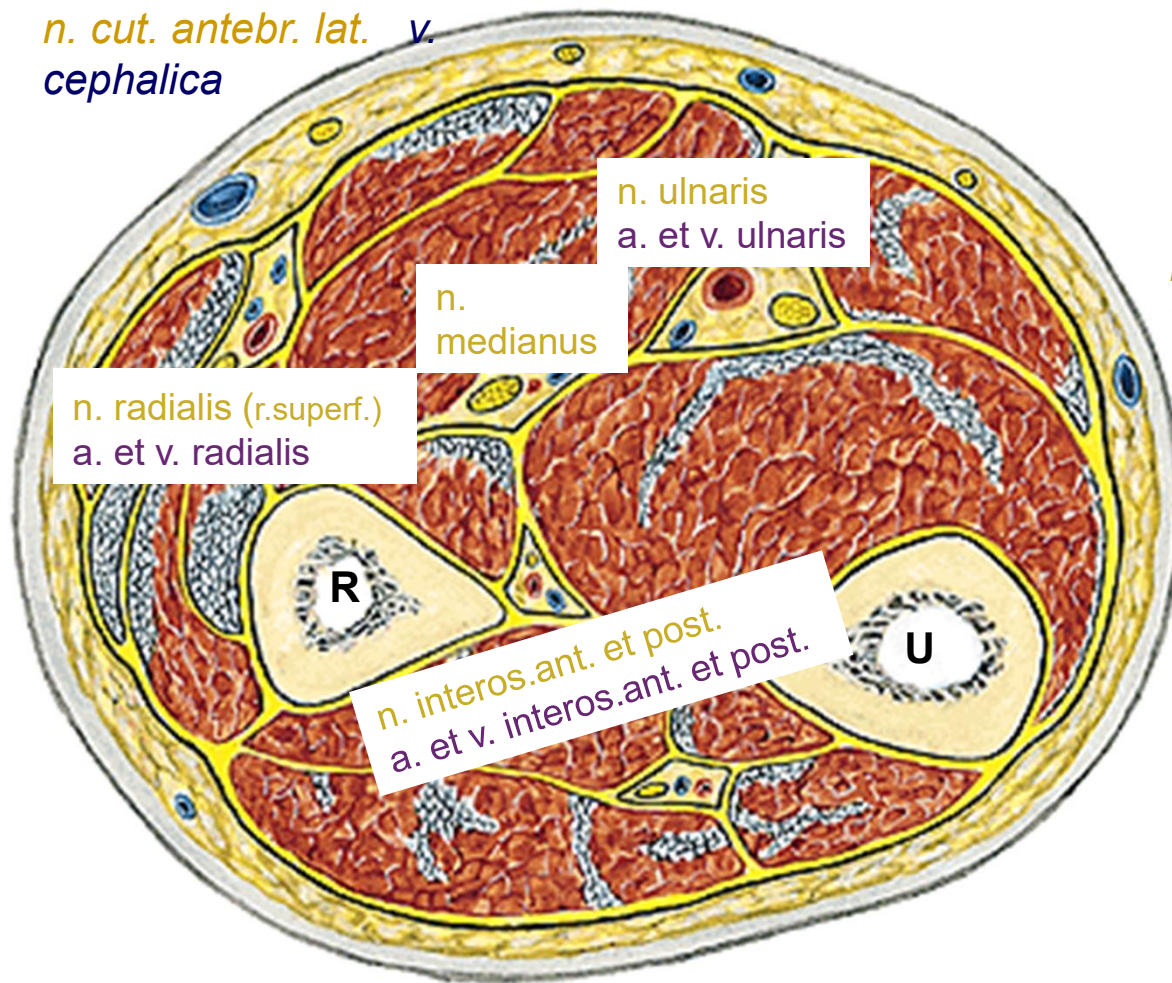
*n.
medianus*

*n. radialis (r.superf.)
a. et v. radialis*

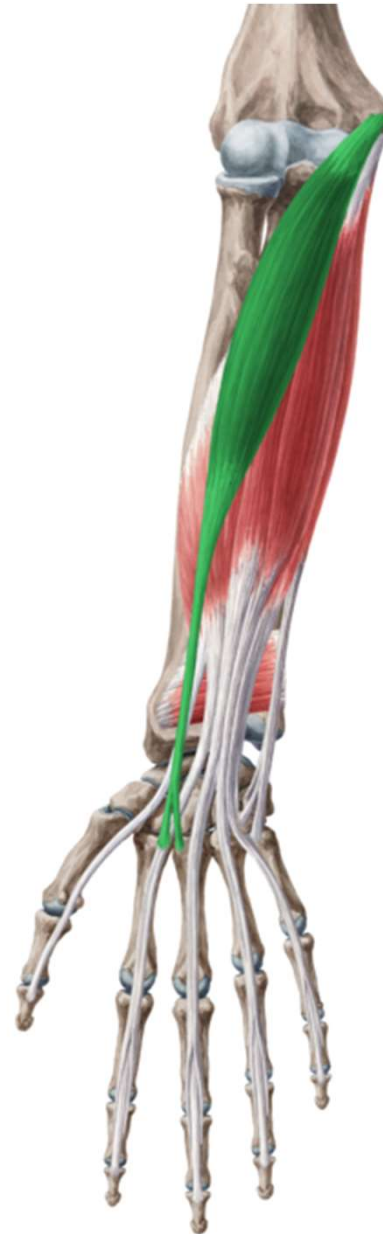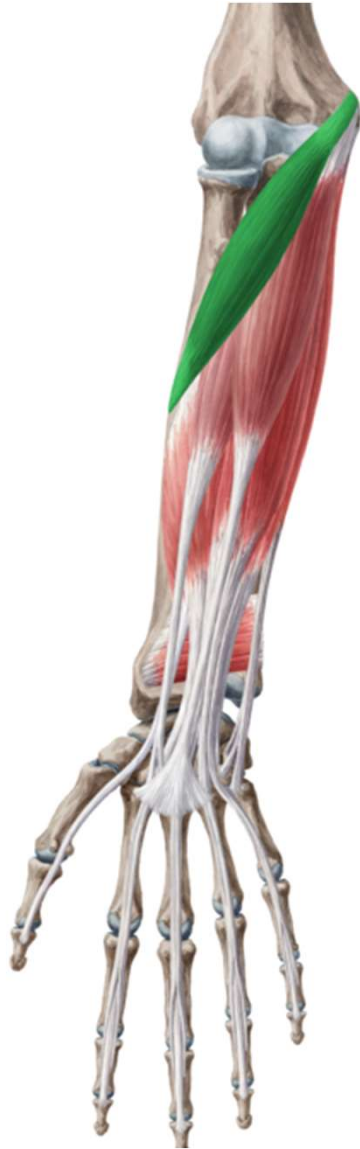*n. cut. antebr. med.
v. basilica*

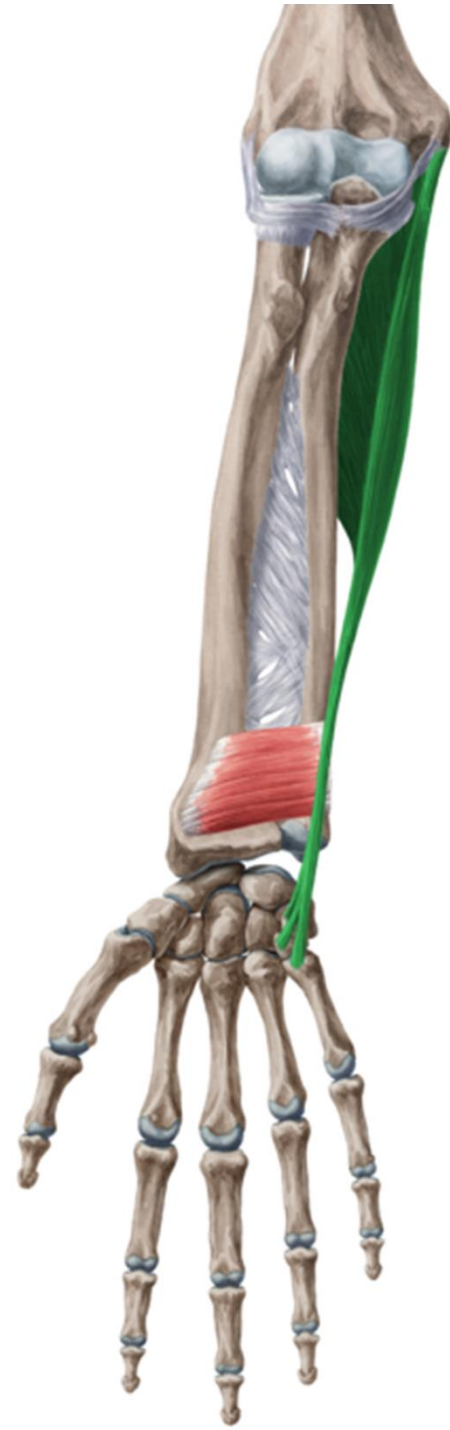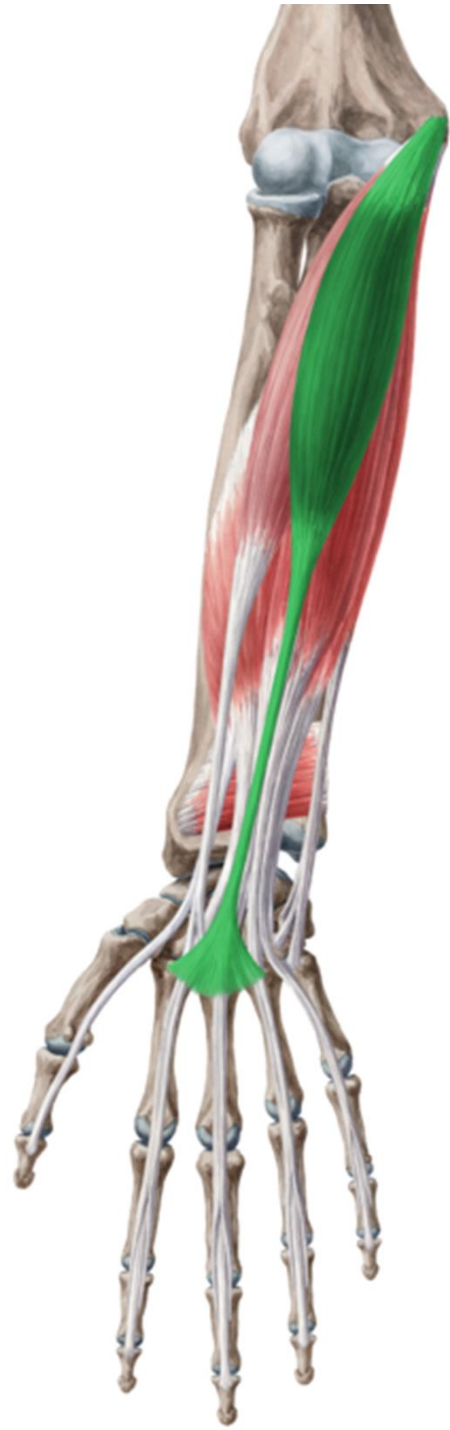*n. interos.ant. et post.
a. et v. interos.ant. et post.*

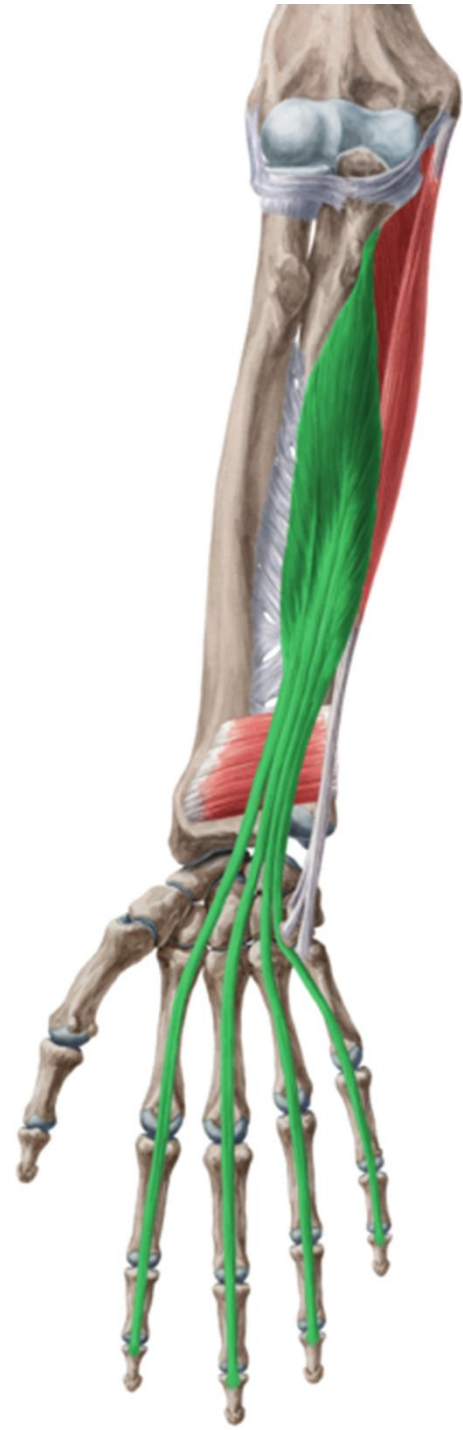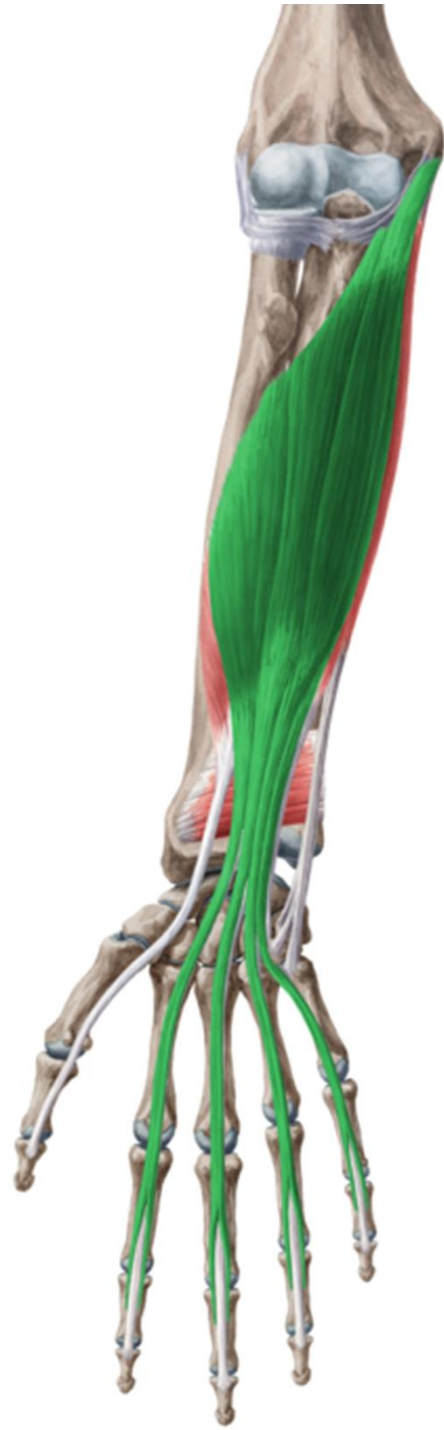n. cut. antebr. post.

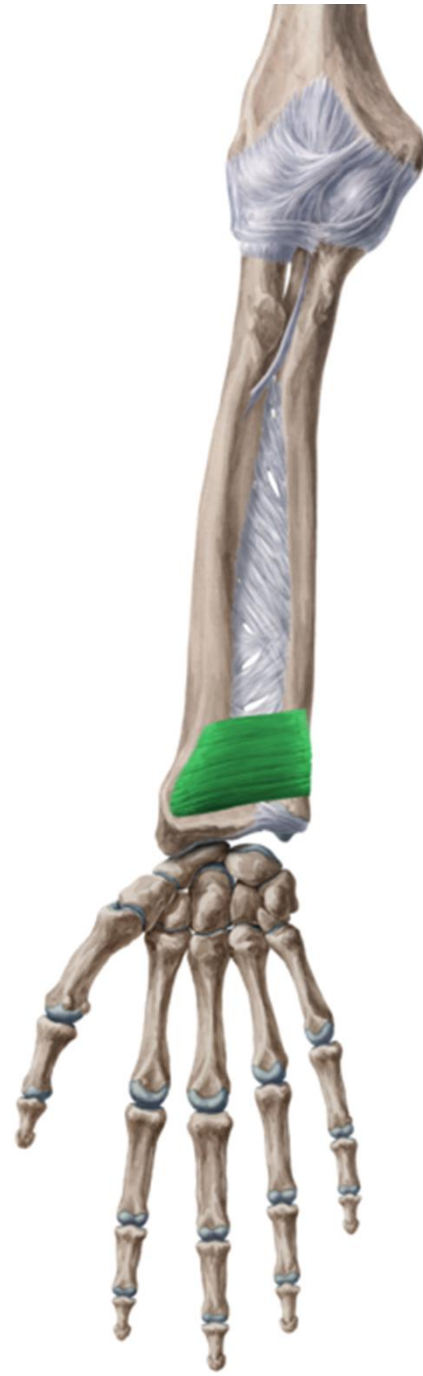
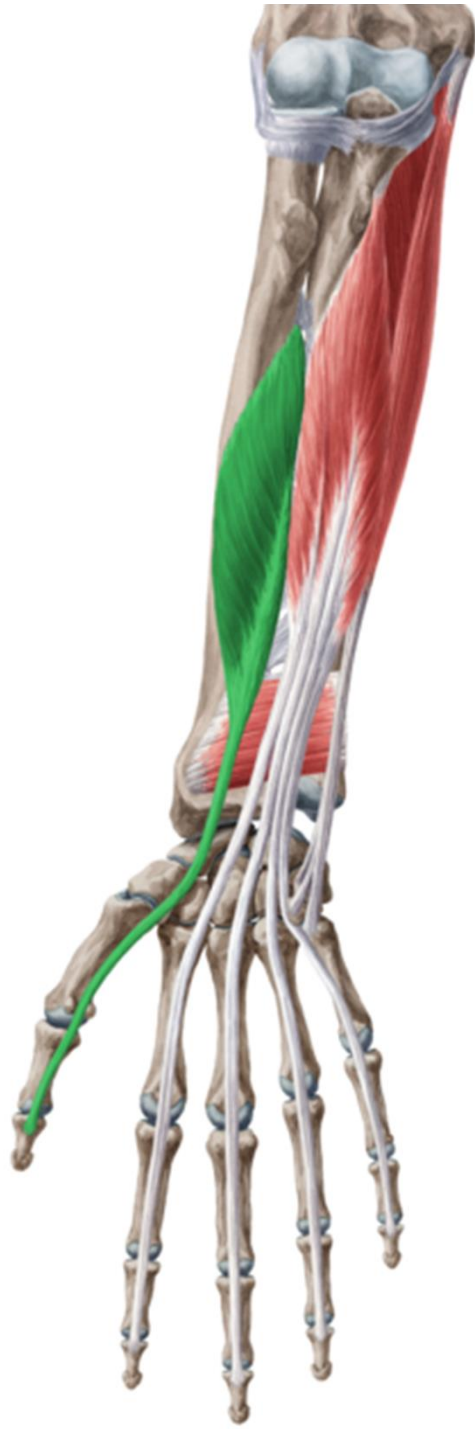
r. antebrachii ant.

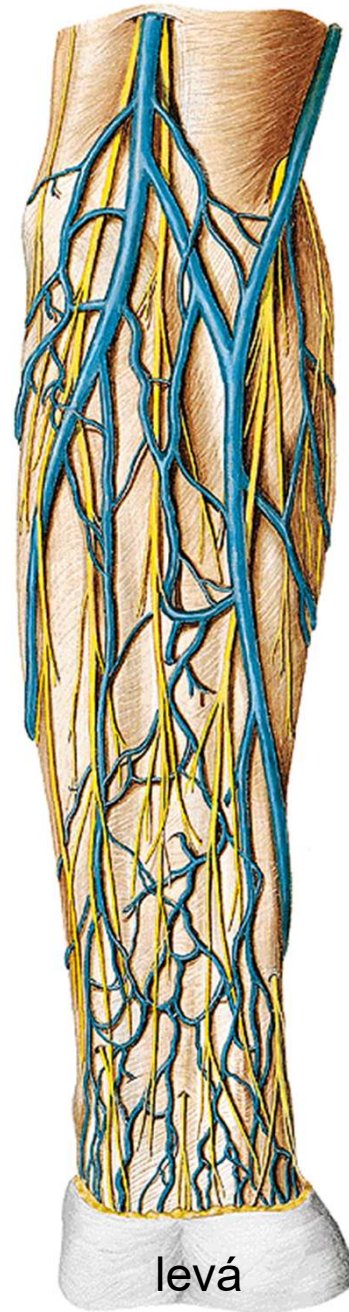






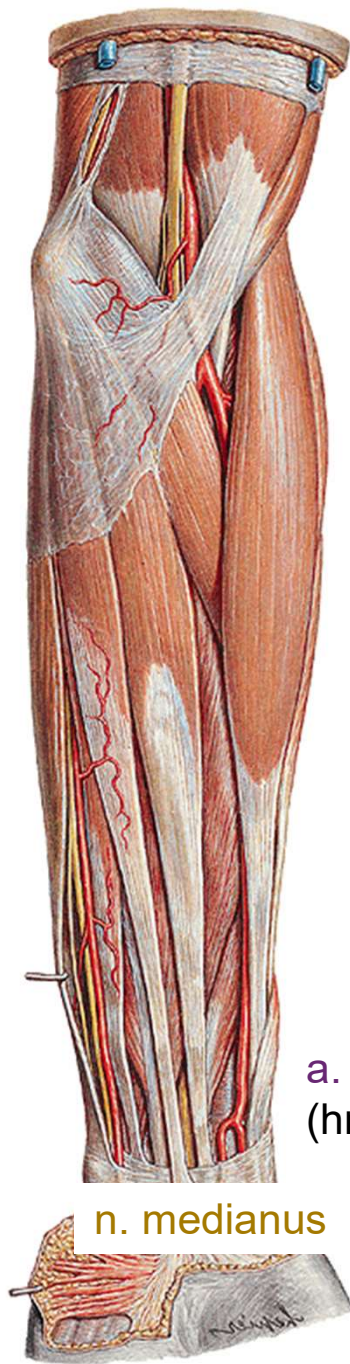

n. cutaneus antebr. med.
v. basilica



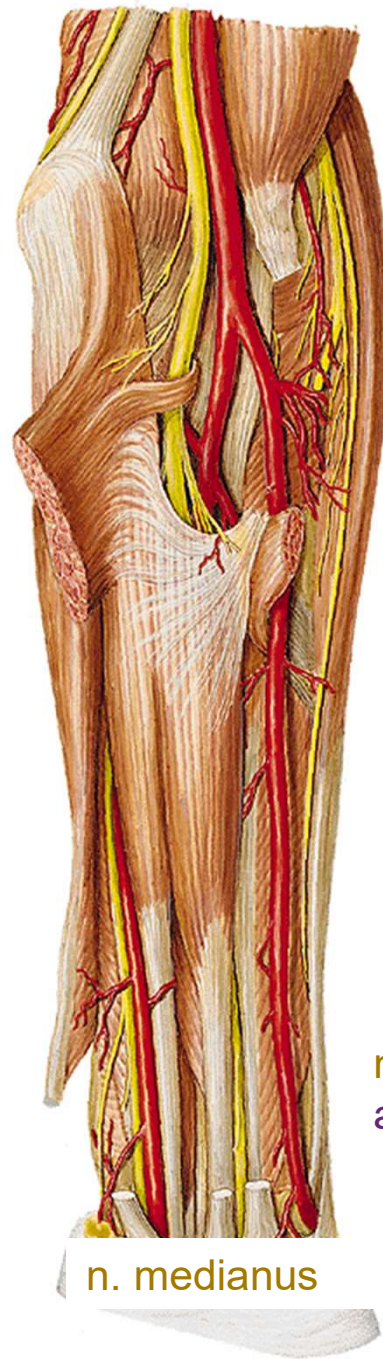n. cutaneus antebr. lat.
v. cephalica

levá



a. et v. radialis
(hmatný tep)

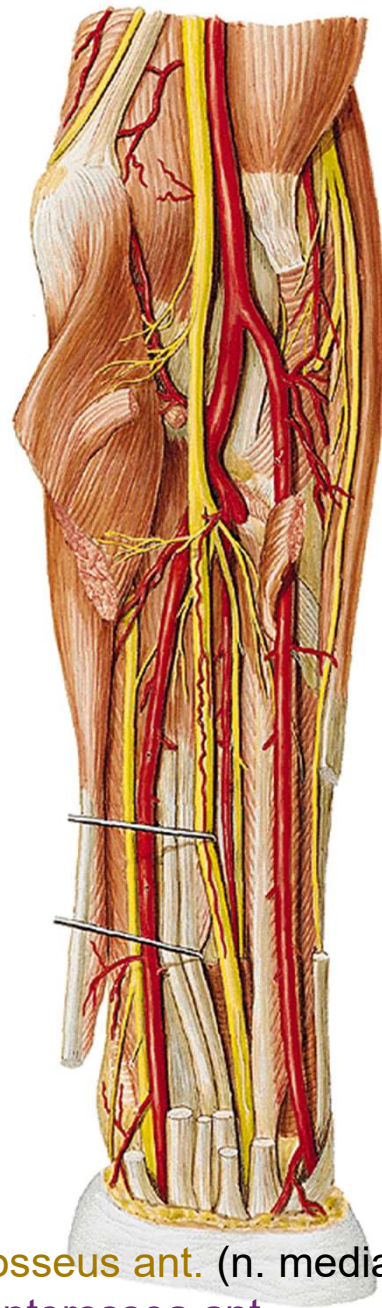
n. medianus



n. ulnaris
a. et v. ulnaris

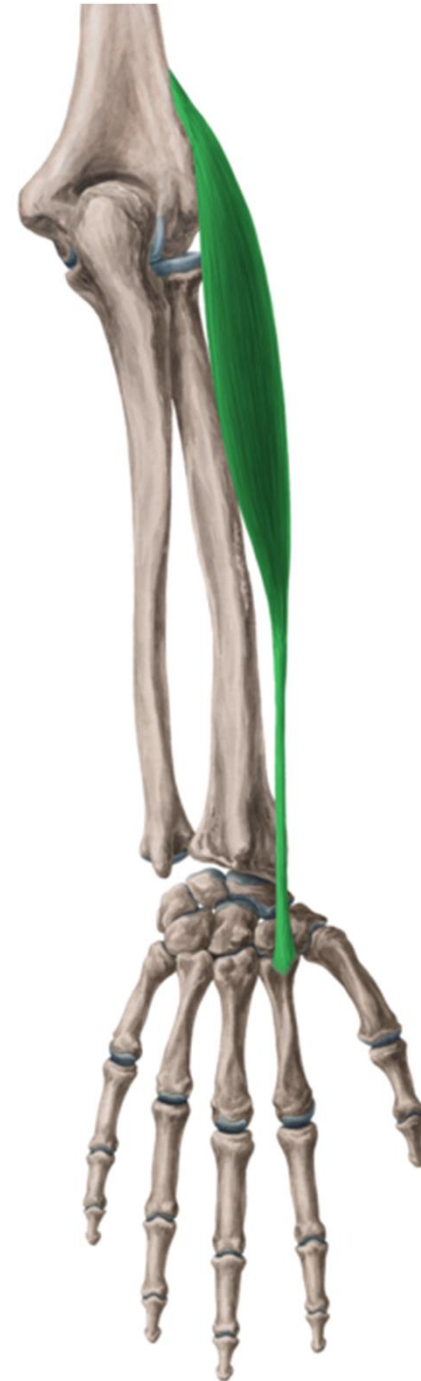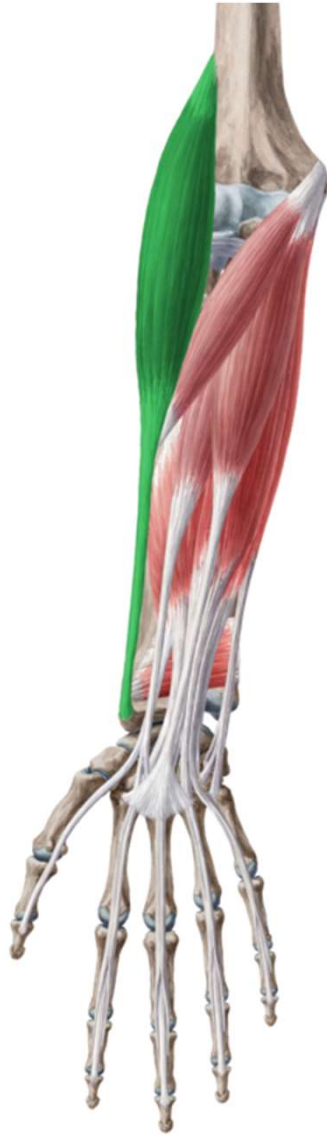n. radialis (r. superf.)
a. et v. radialis

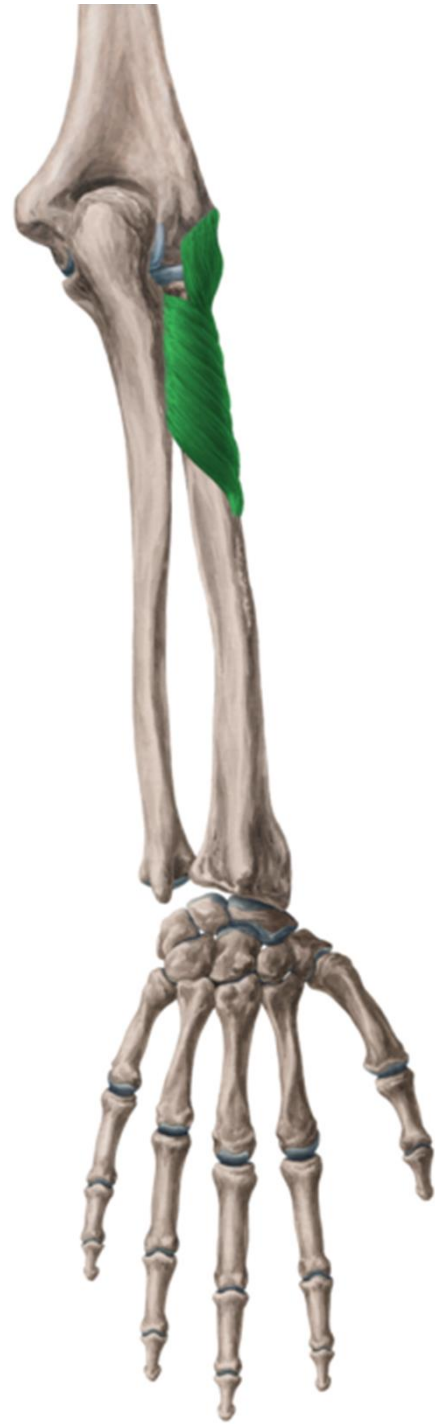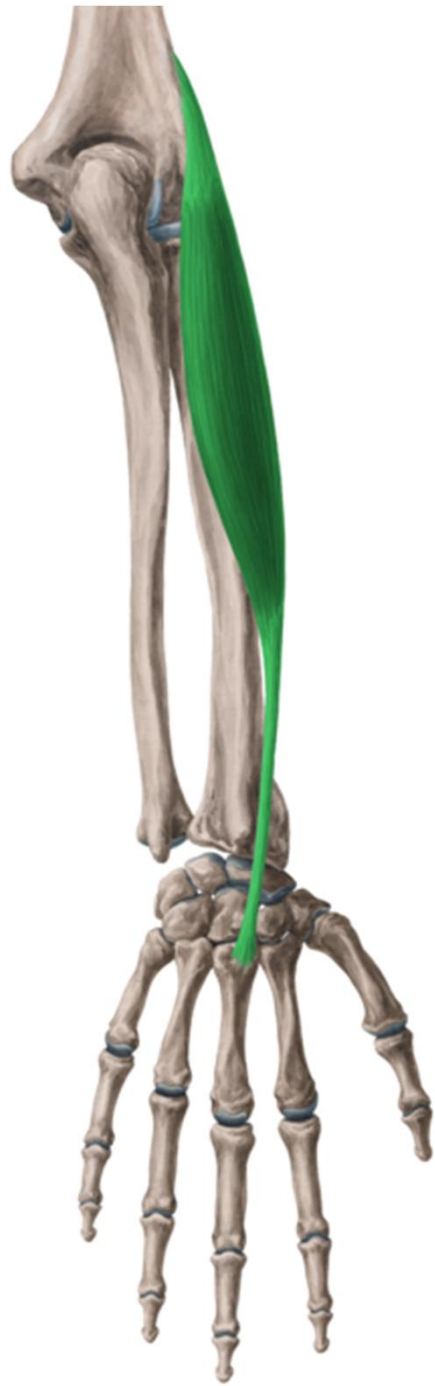n. medianus

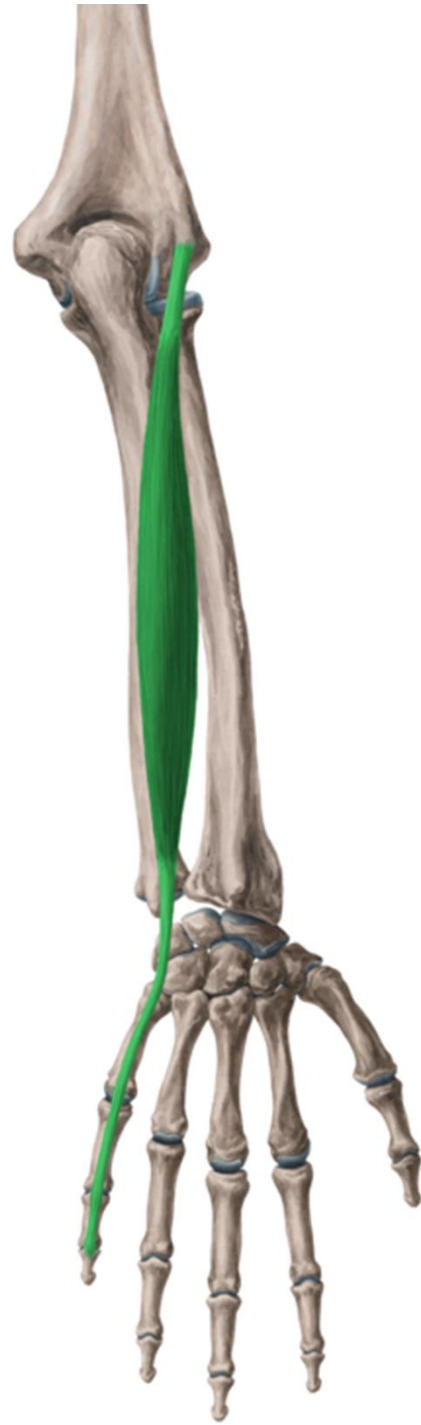
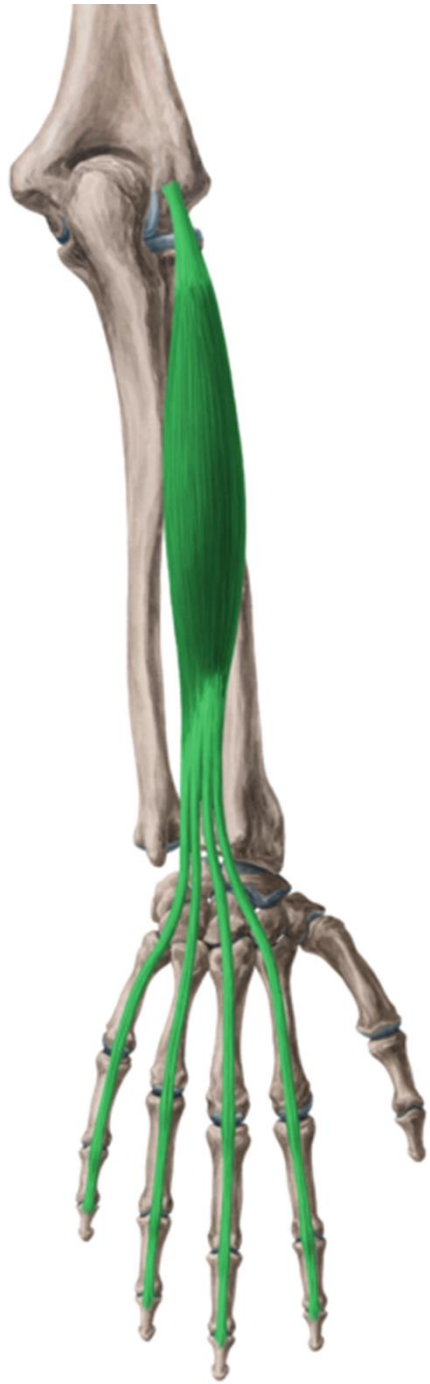
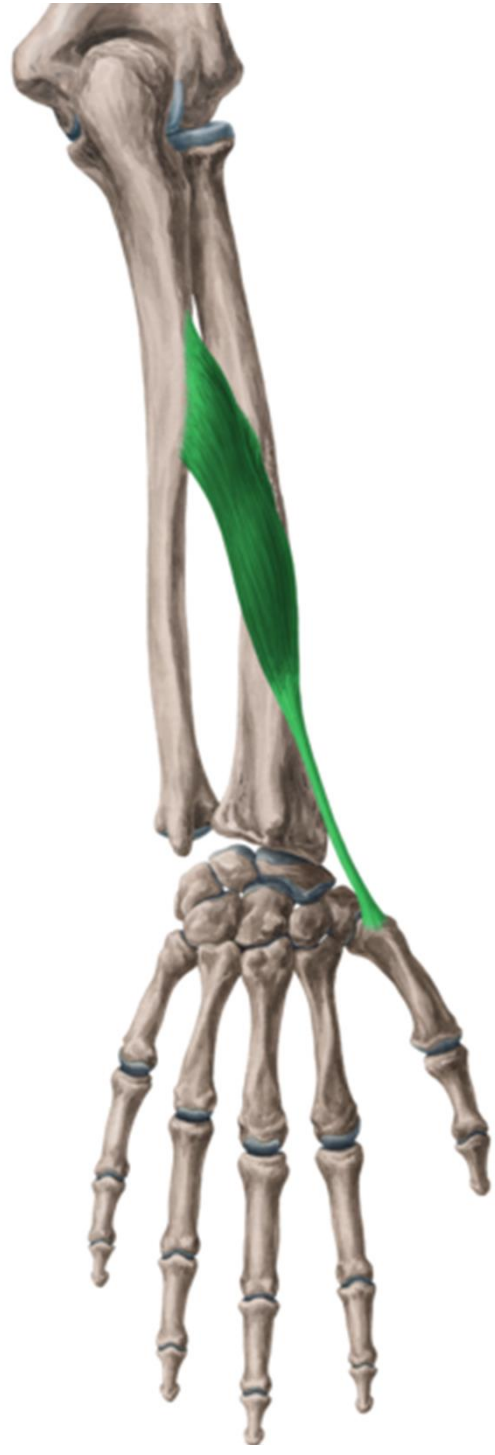
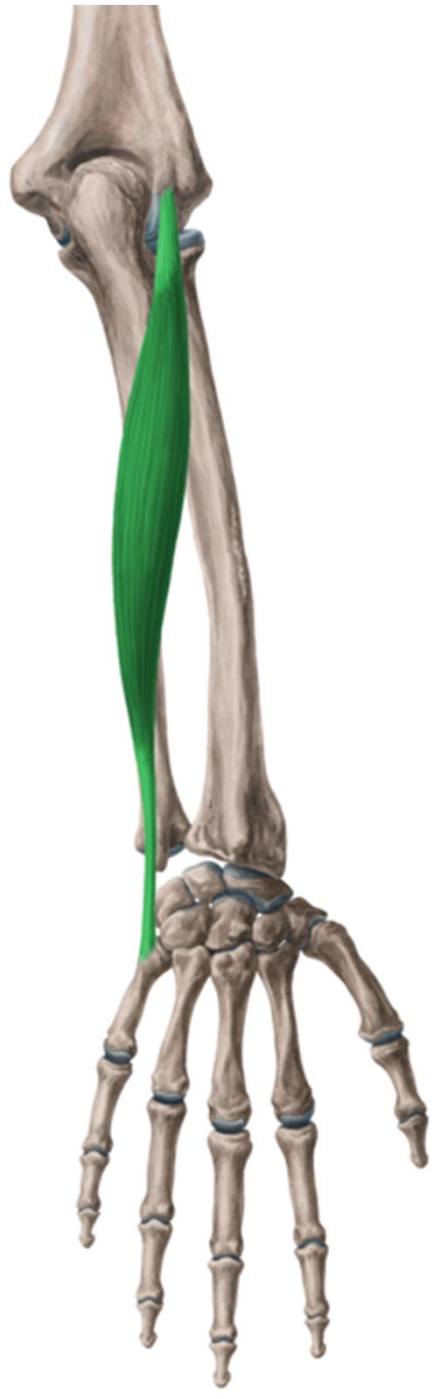n. interosseus ant. (n. medianus)
a. et v. interossea ant.

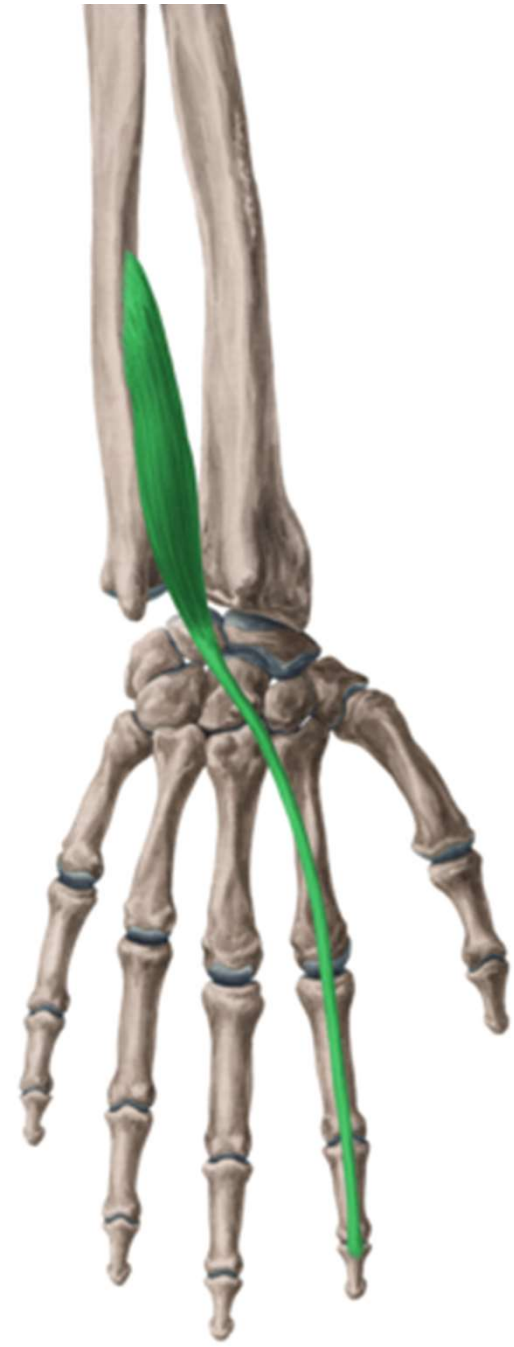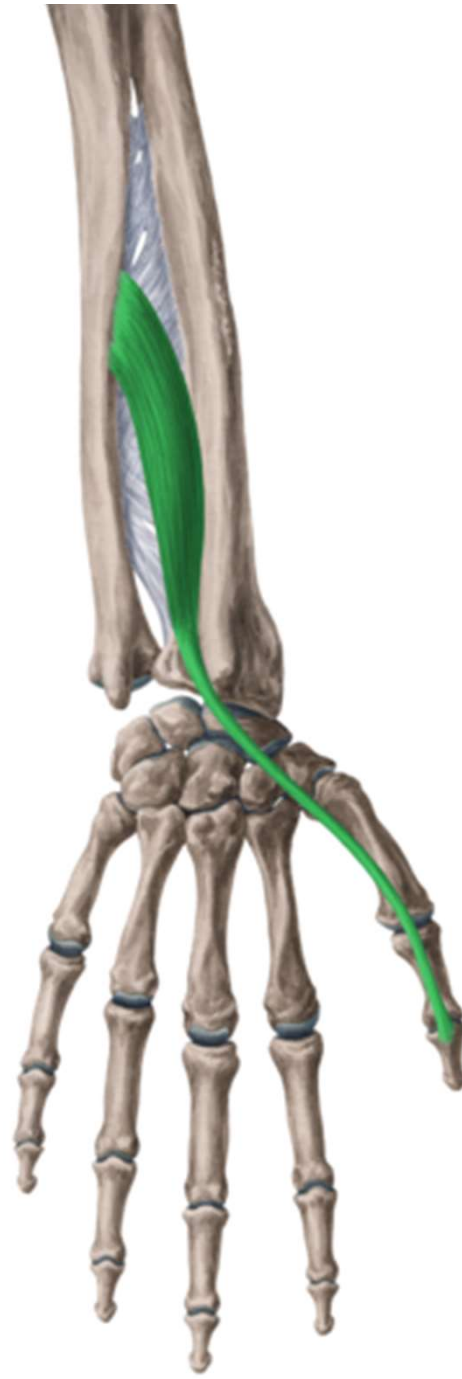
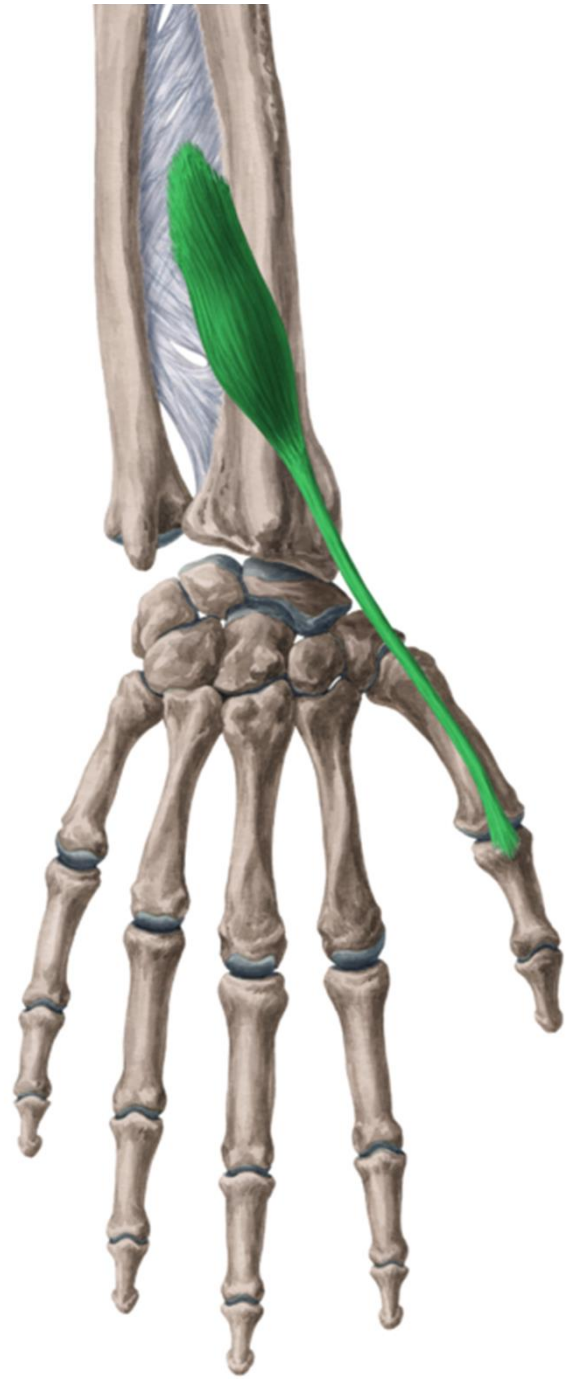
r. antebrachii post.



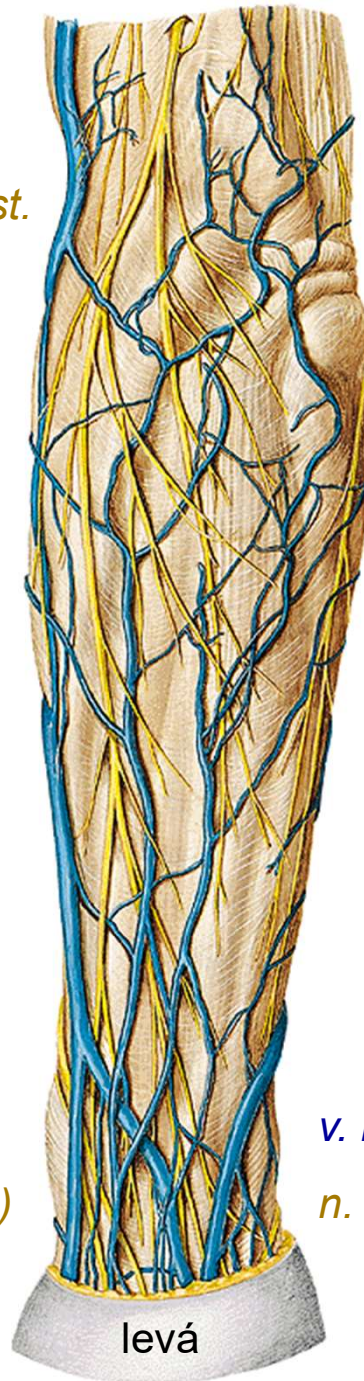







n. cutaneus antebrachii post.



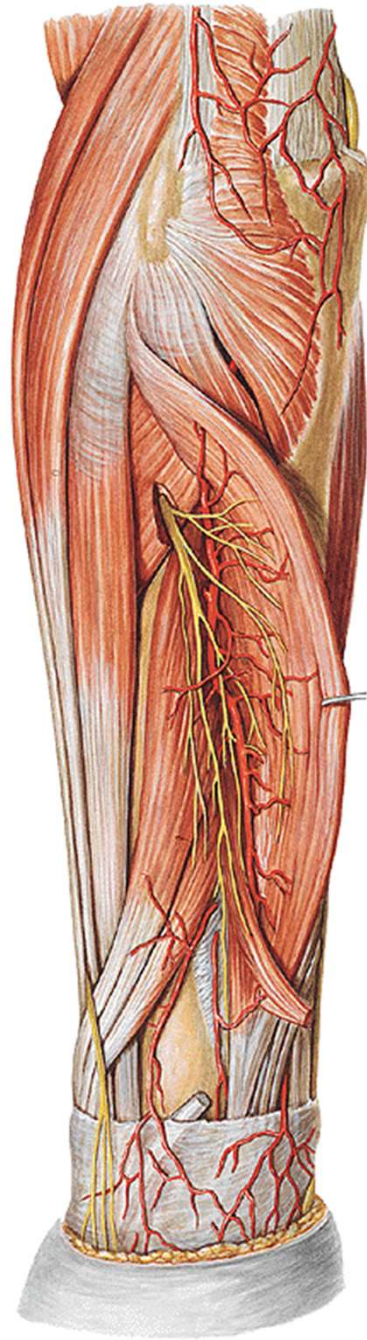
v. cephalica

n. radialis (r. superf.)

v. basilica

n. ulnaris (r. dorsalis)

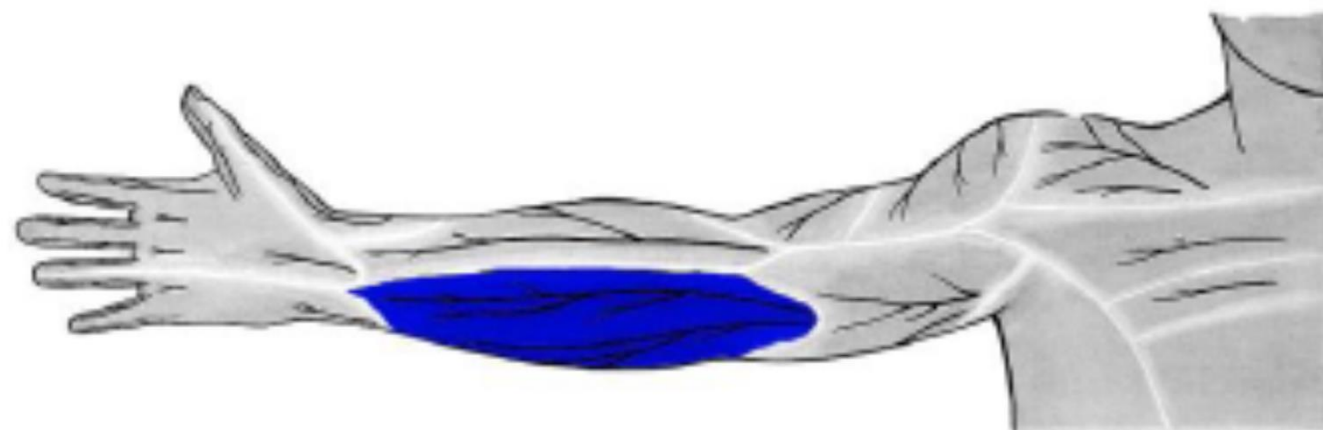
levá



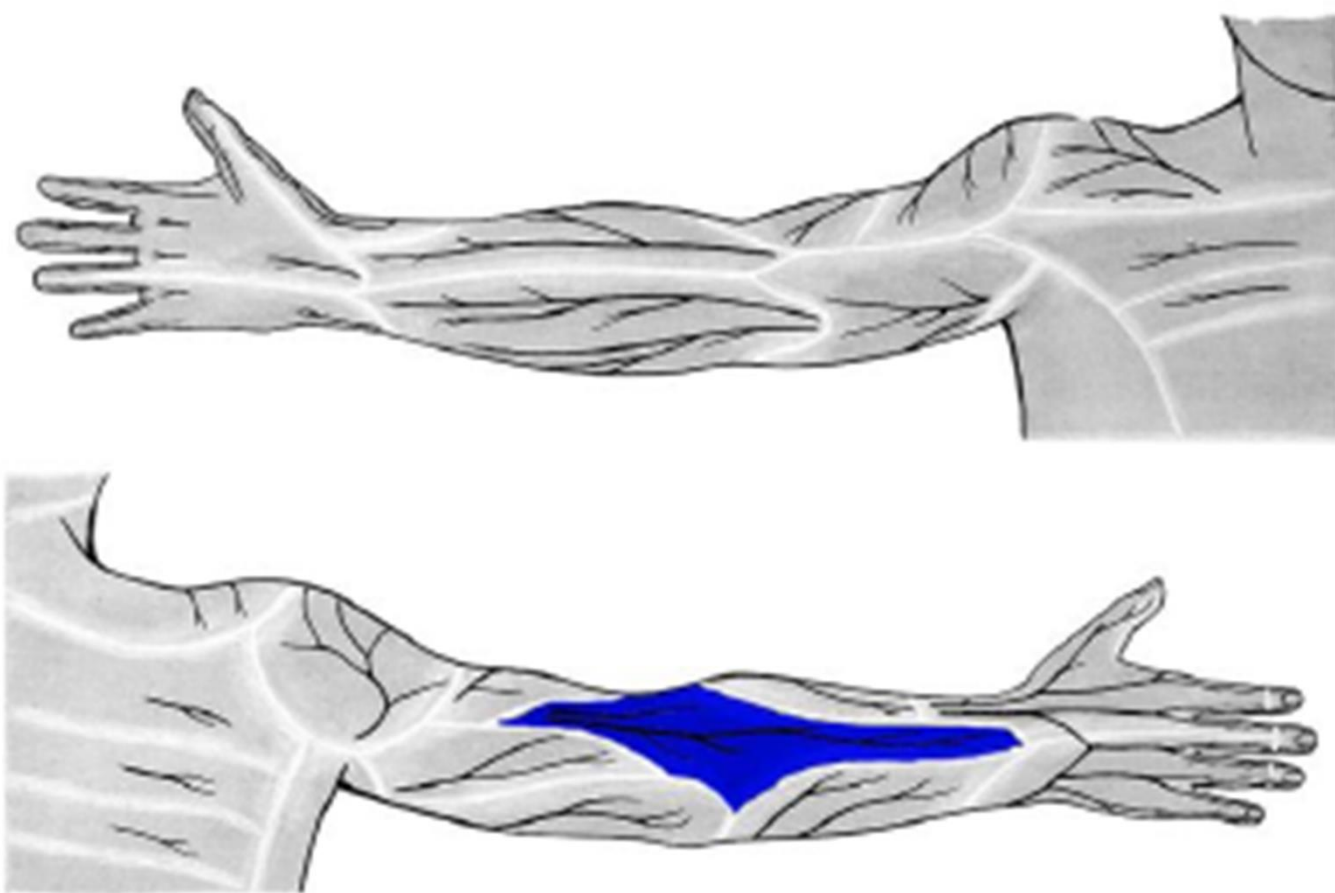
n. radialis

(r. prof., n. interosseus post.)

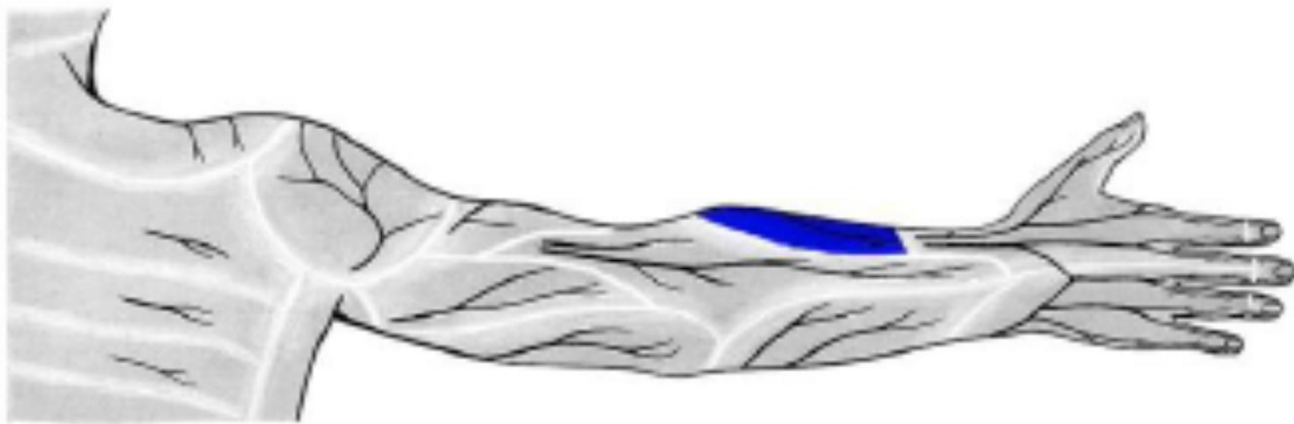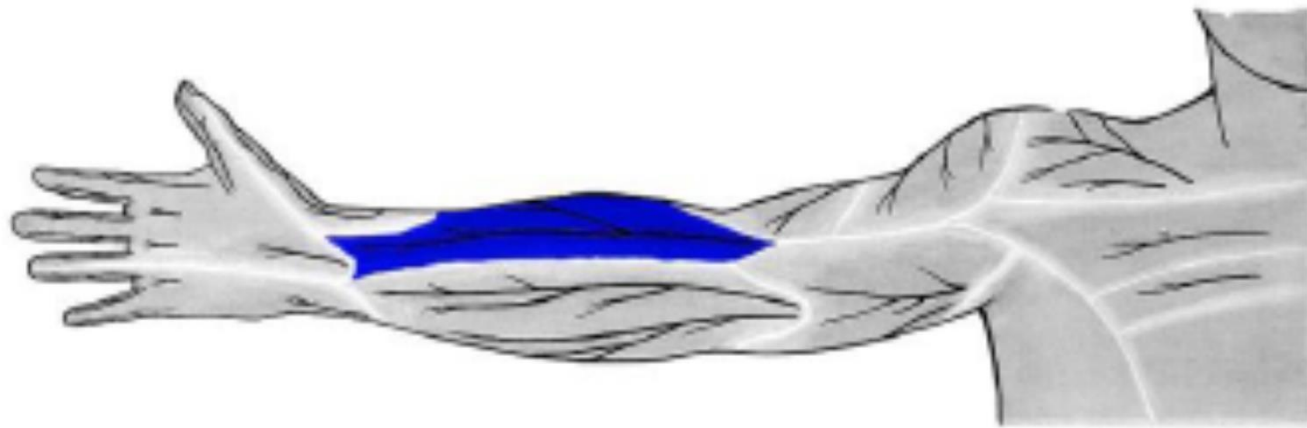
a. et v. interossea post.



n. cutaneus antebrachii med.
(z fasciculus medialis)

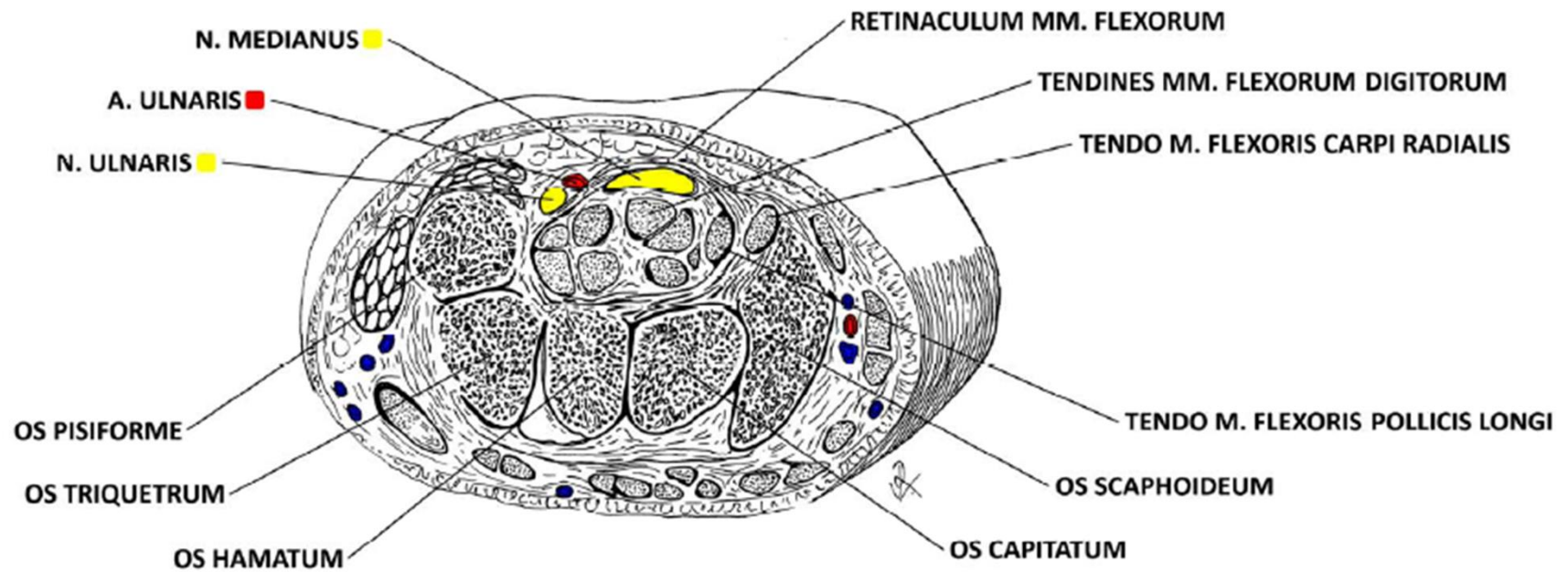


n. cutaneus antebrachii post.
(z. n. radialis)

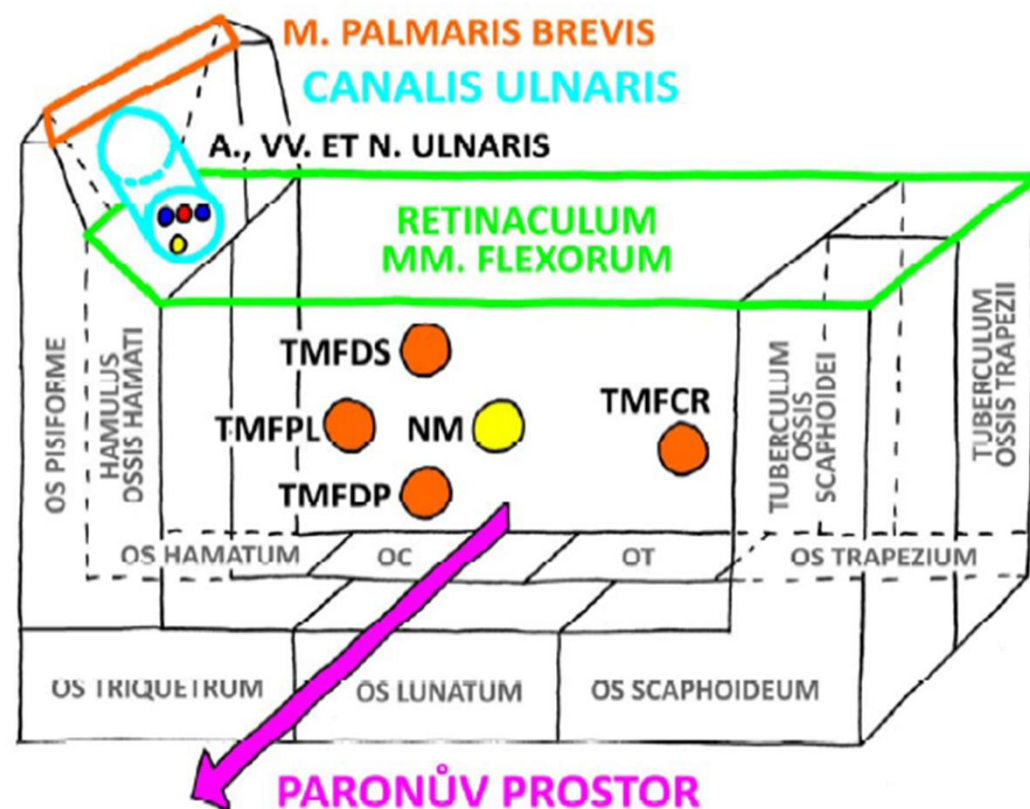


n. cutaneus antebrachii lat.
(z *n. musculocutaneus*)

r. carpi palm.



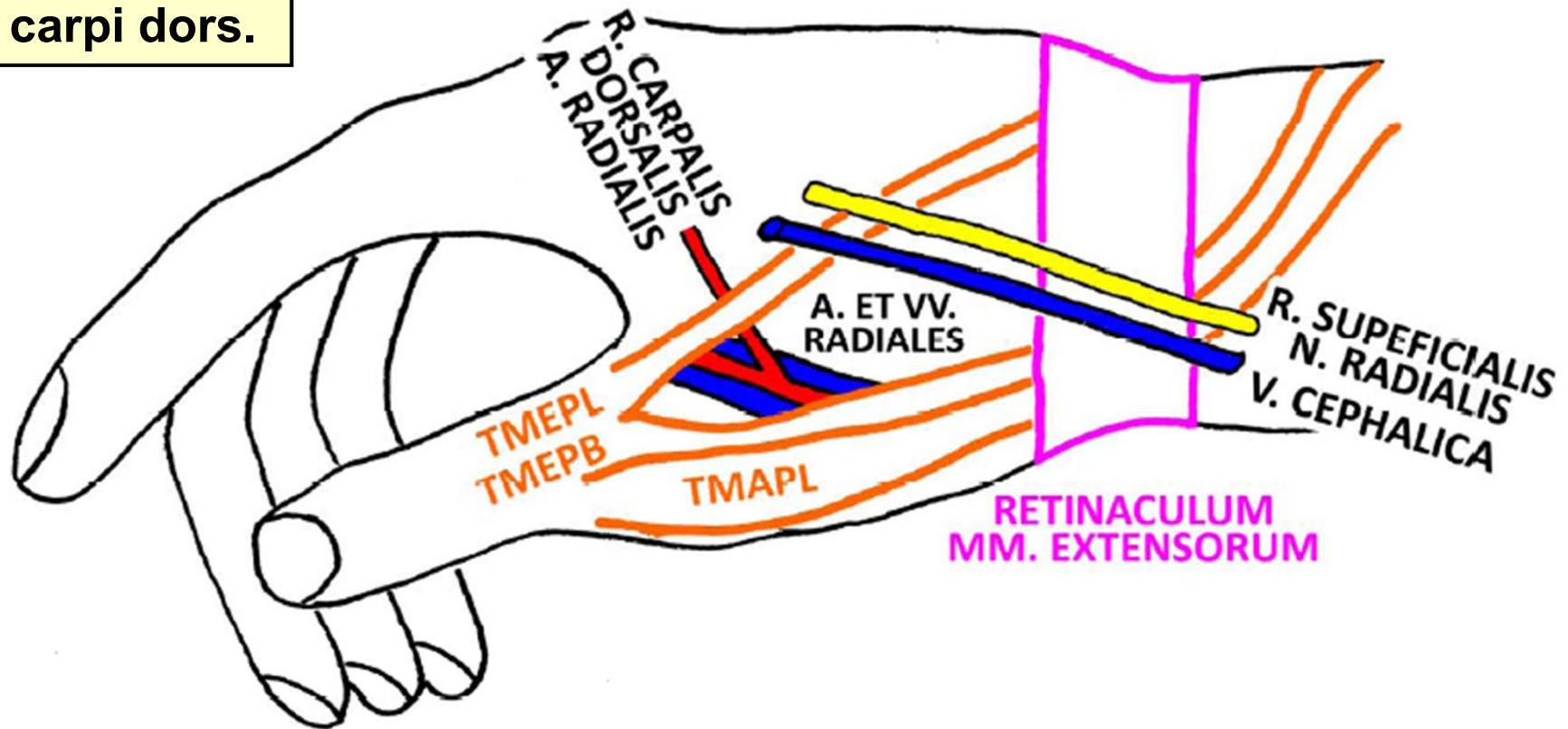
CANALIS CARPI DX.



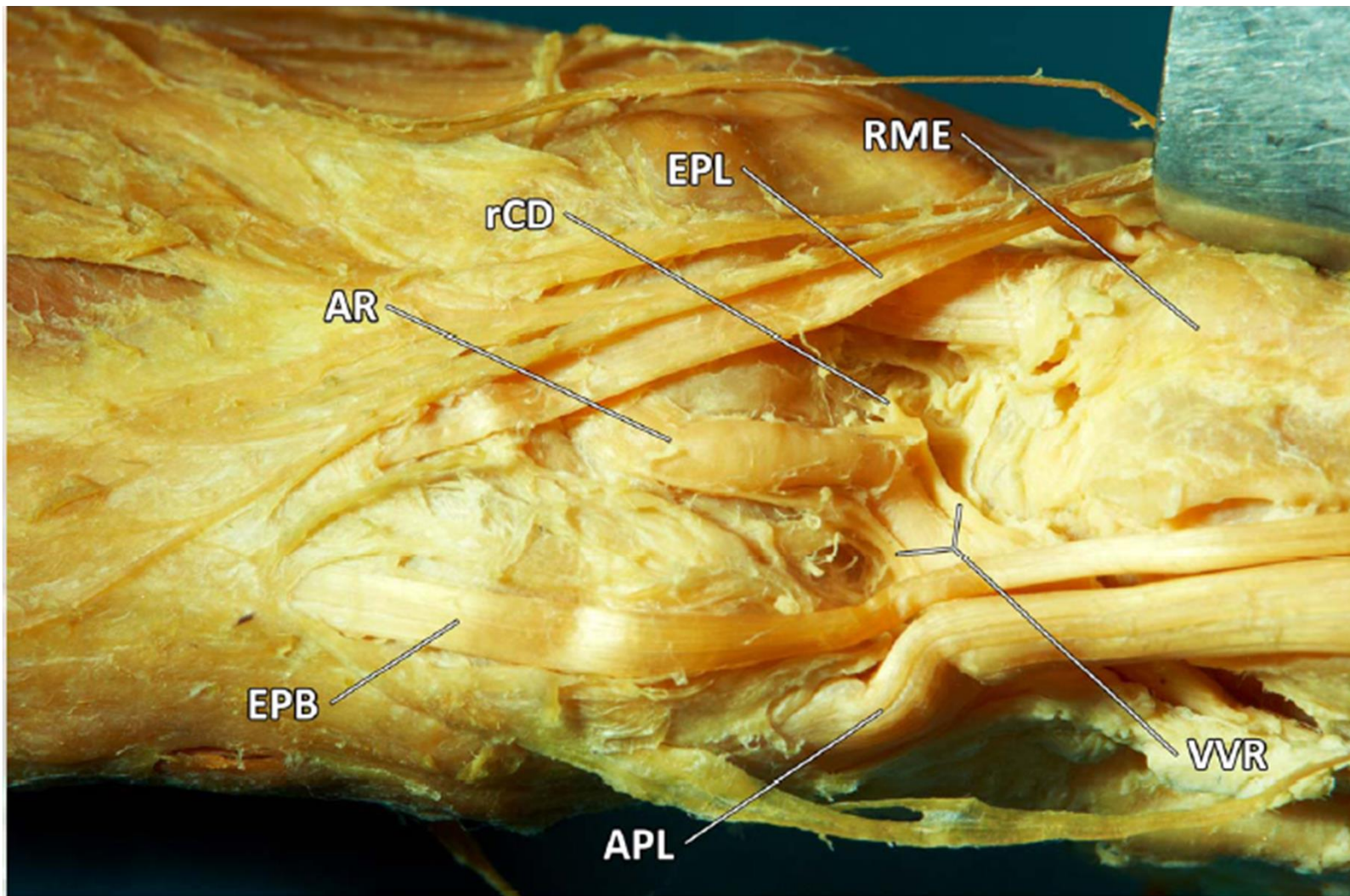
- TMFDS = TENDO M. FLEXORIS DIGITORUM SUPERFICIALIS
- TMFPL = TENDO M. FLEXORIS POLLICIS LONGI
- NM = N. MEDIANUS
- TMFDP = TENDO M. FLEXORIS DIGITORUM PROFUNDI
- TMFCR = TENDO M. FLEXORIS CARPI RADIALIS
- OC = OS CAPITATUM
- OT = OS TRAPEZOIDEUM

FOVEOLA RADIALIS DX.

r. carpi dors.



TMEPL = TENDO M. EXTENSORIS POLLICIS LONGI
TMEPB = TENDO M. EXTENSORIS POLLICIS BREVIS
TMAPL = TENDO M. ABDUCTORIS POLLICIS LONGI



AR - A. RADIALIS

rCD - R. CARPALIS DORSALIS A. RADIALIS

EPL - TENDO M. EXTENSORIS POLLICIS LONGI

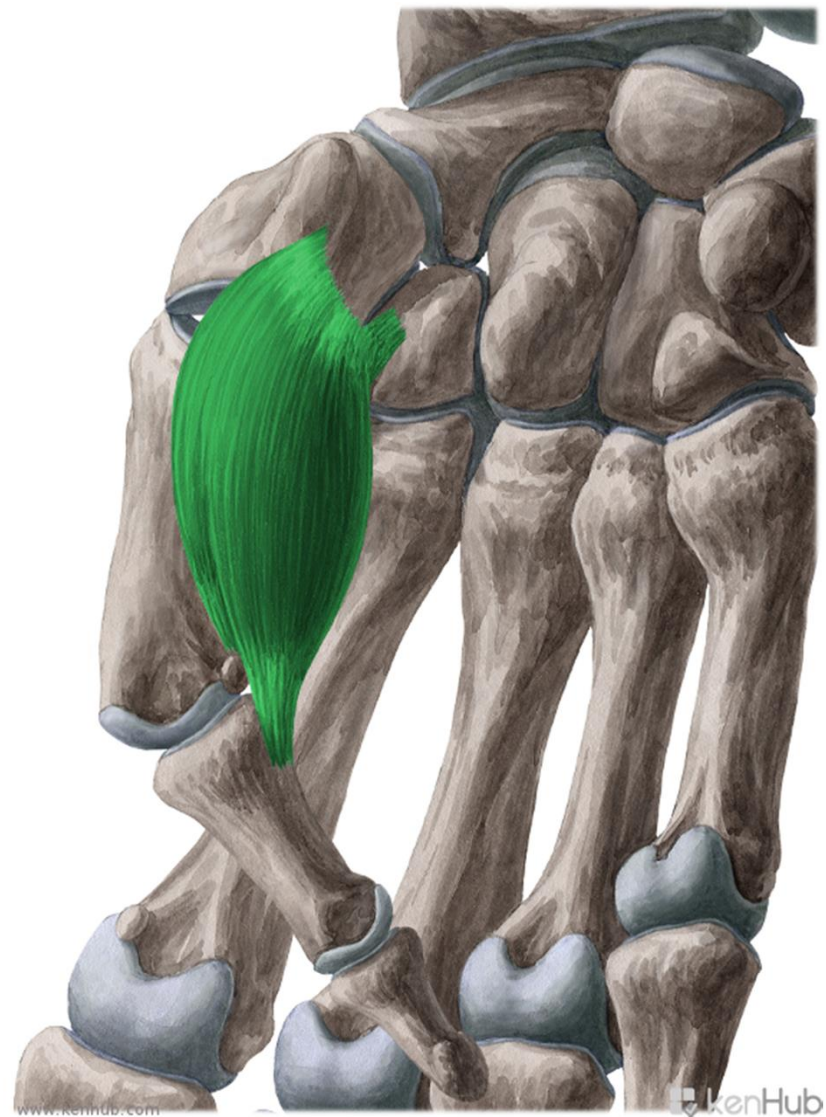
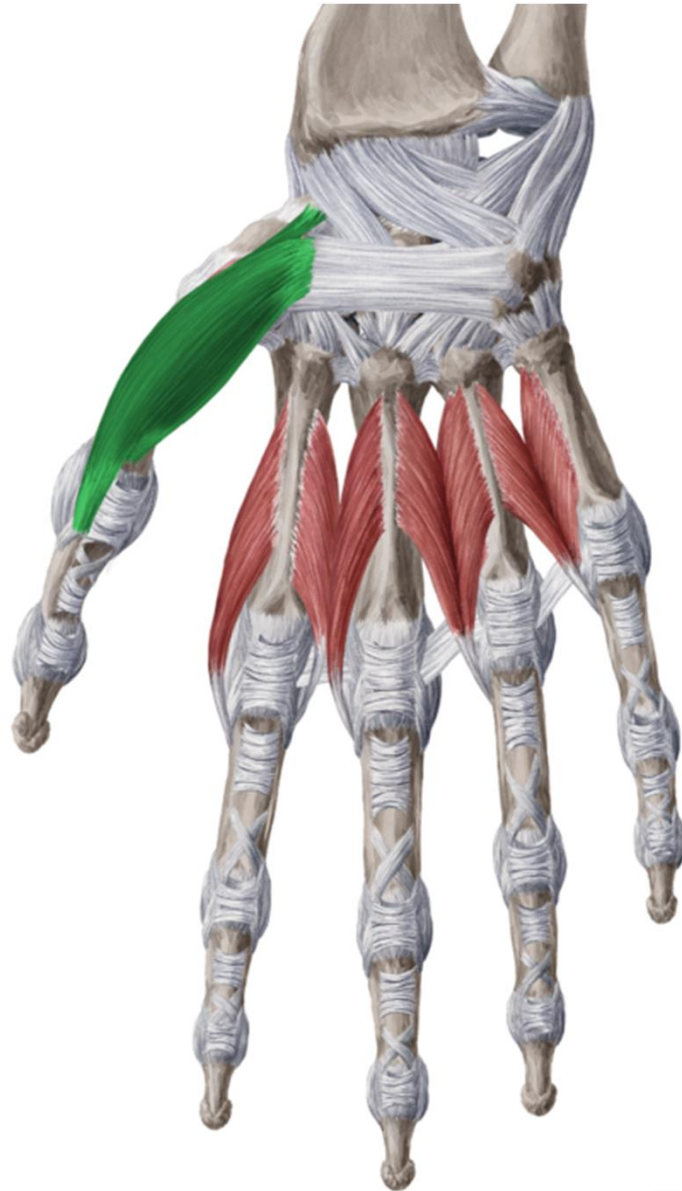
RME - RETINACULUM MM. EXTENSORUM

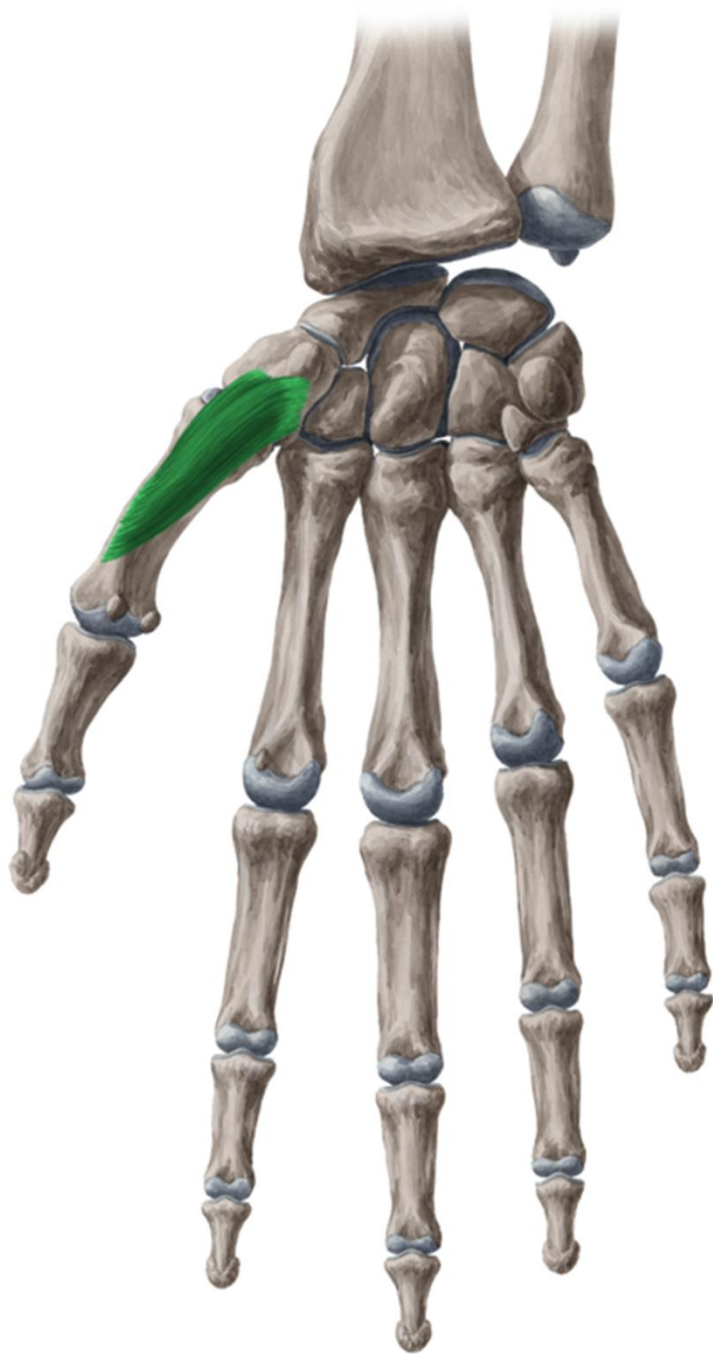
VVR - VV. RADIALES

APL - TENDO M. ABDUCTORIS POLLICIS LONGI

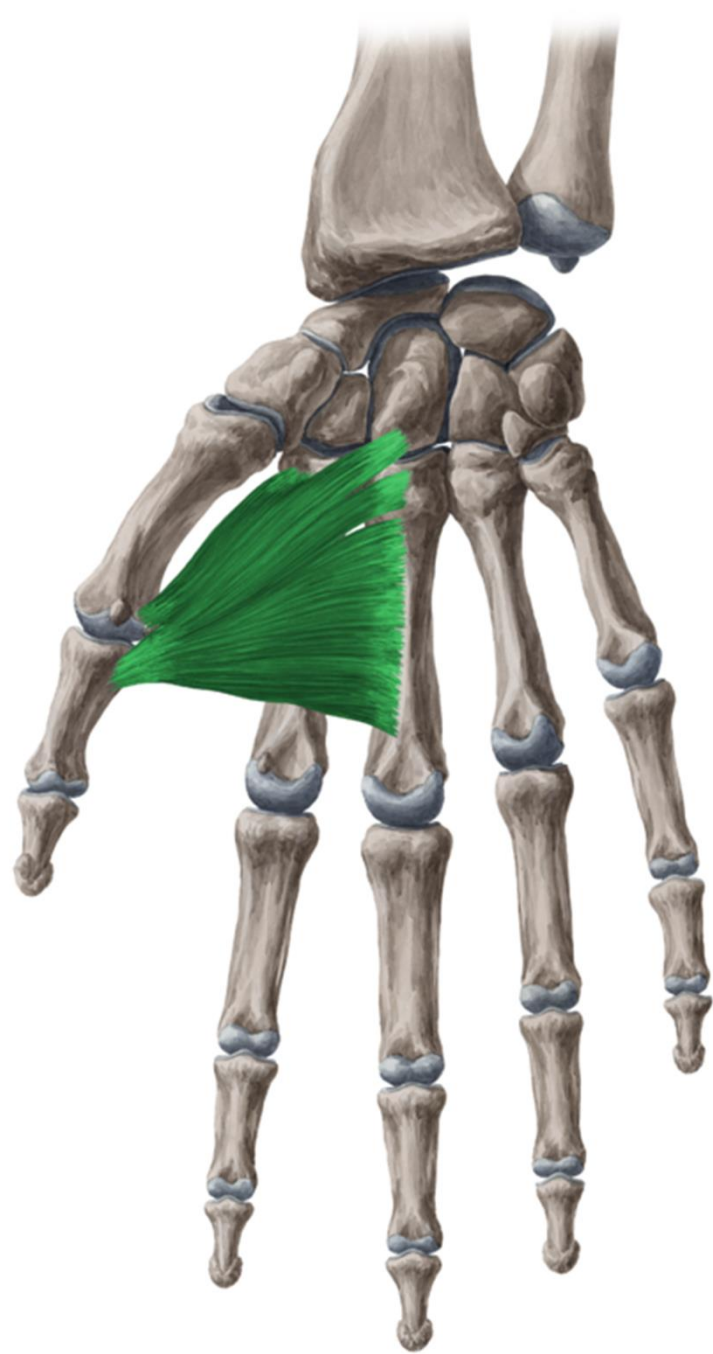
EPB - TENDO M. EXTENSORIS POLLICIS BREVIS

palma manus

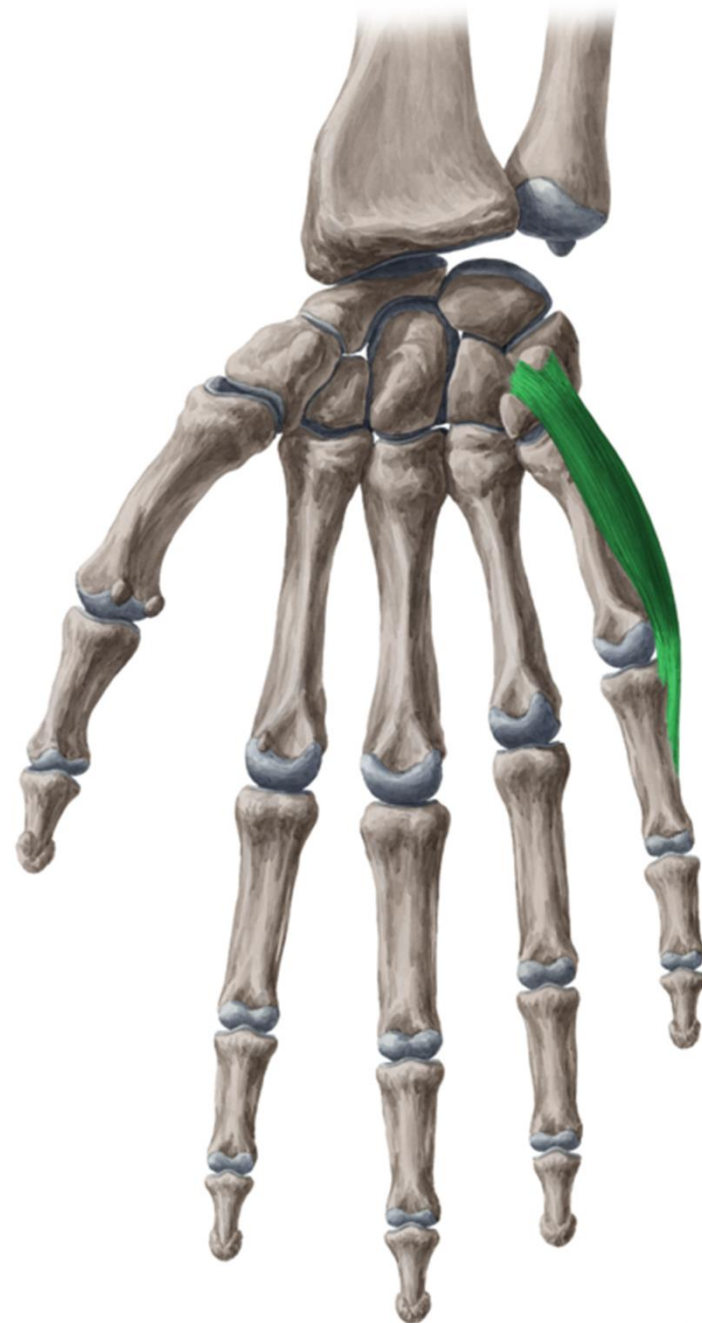
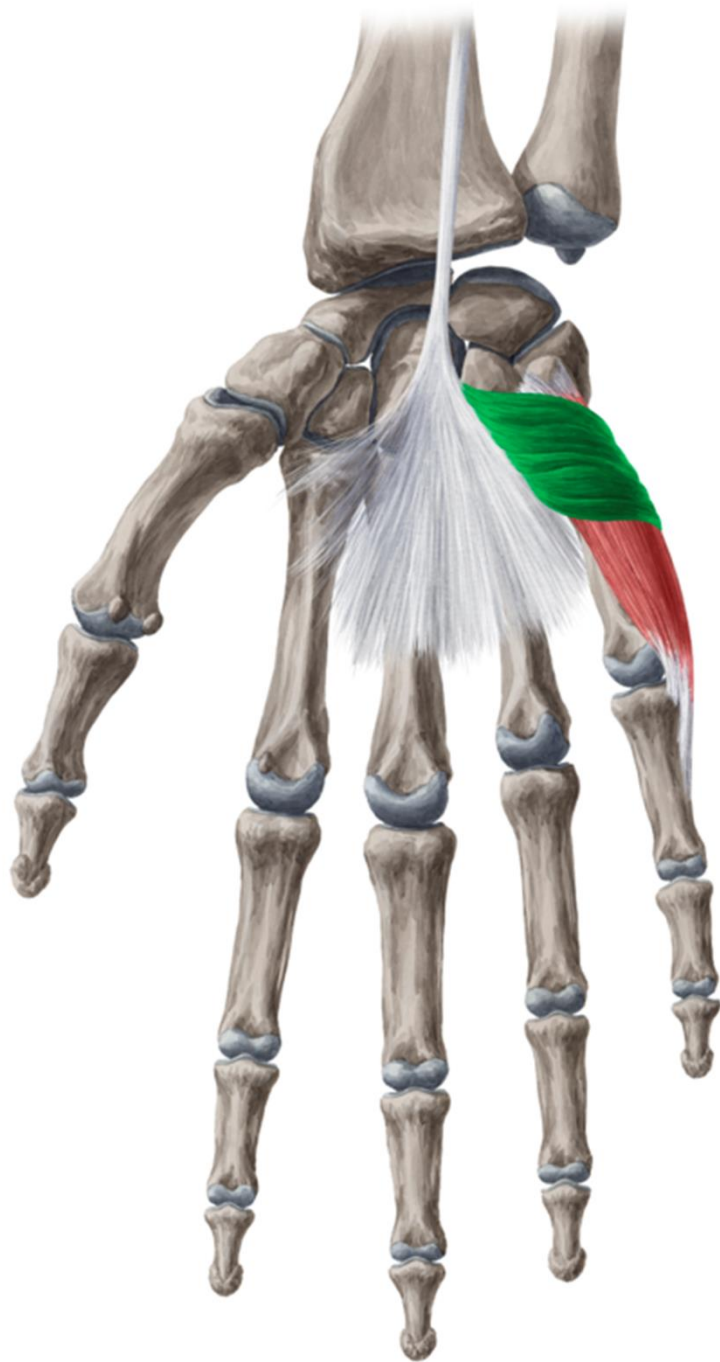


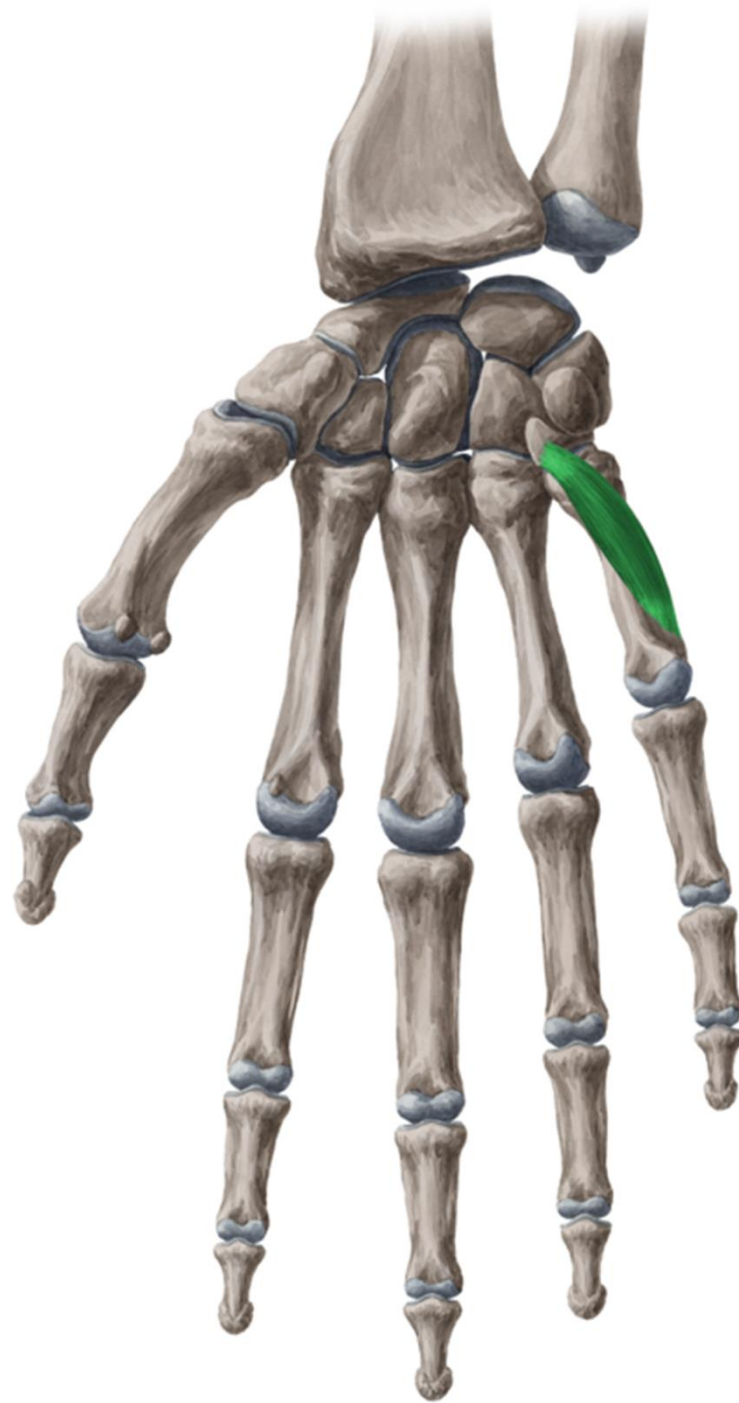
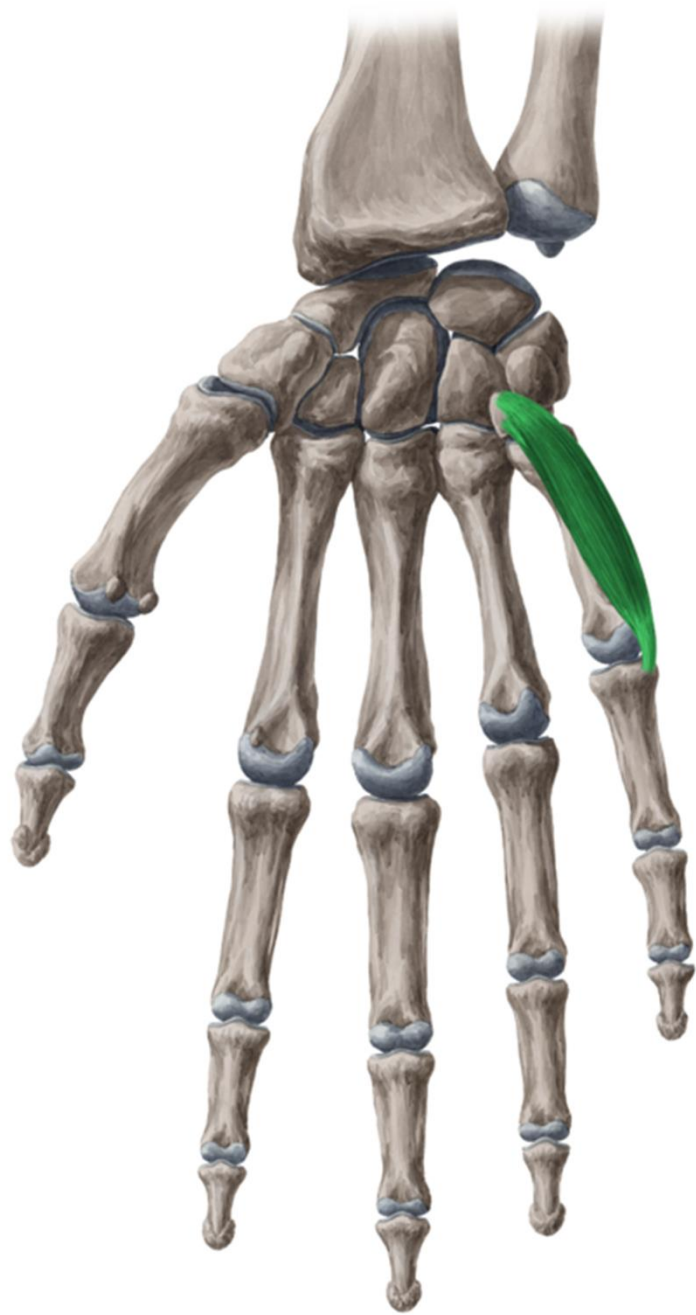


— 1 —



— 2 —





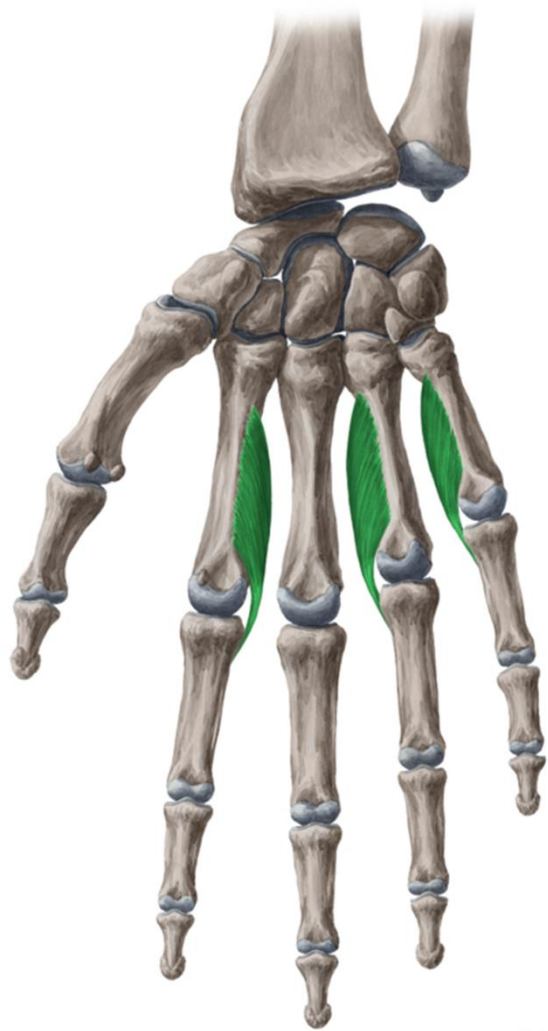


Figure 1.1.1

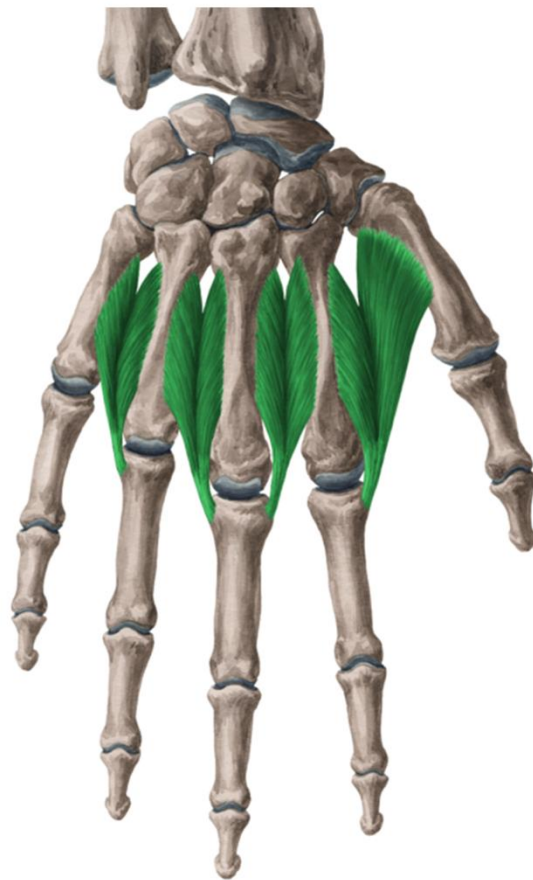
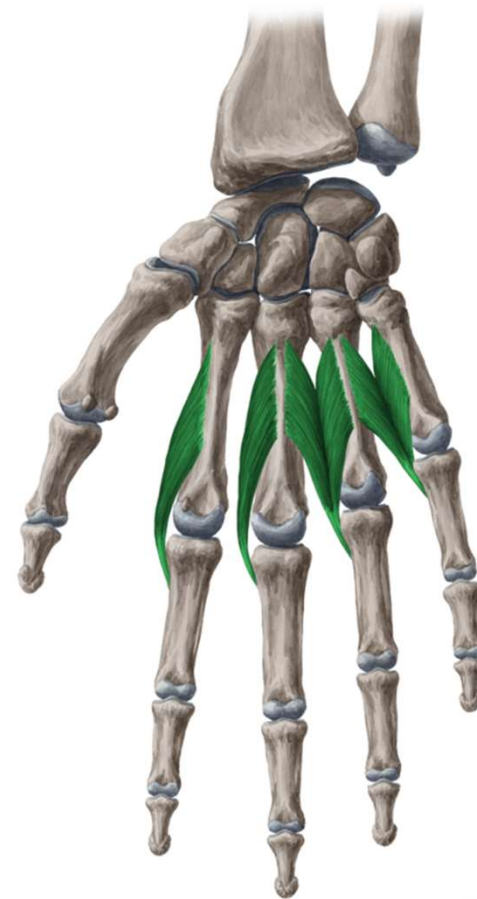


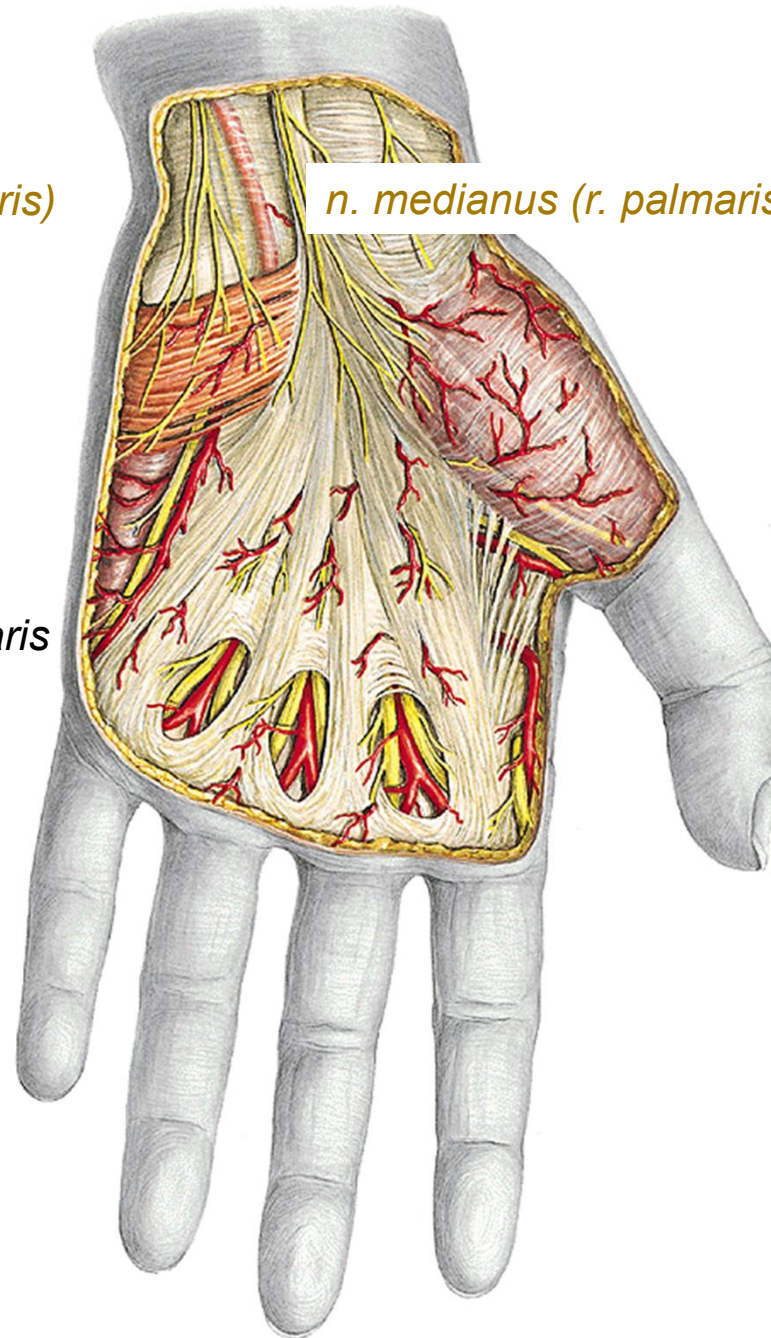
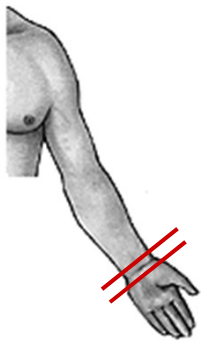
Figure 1.1.2

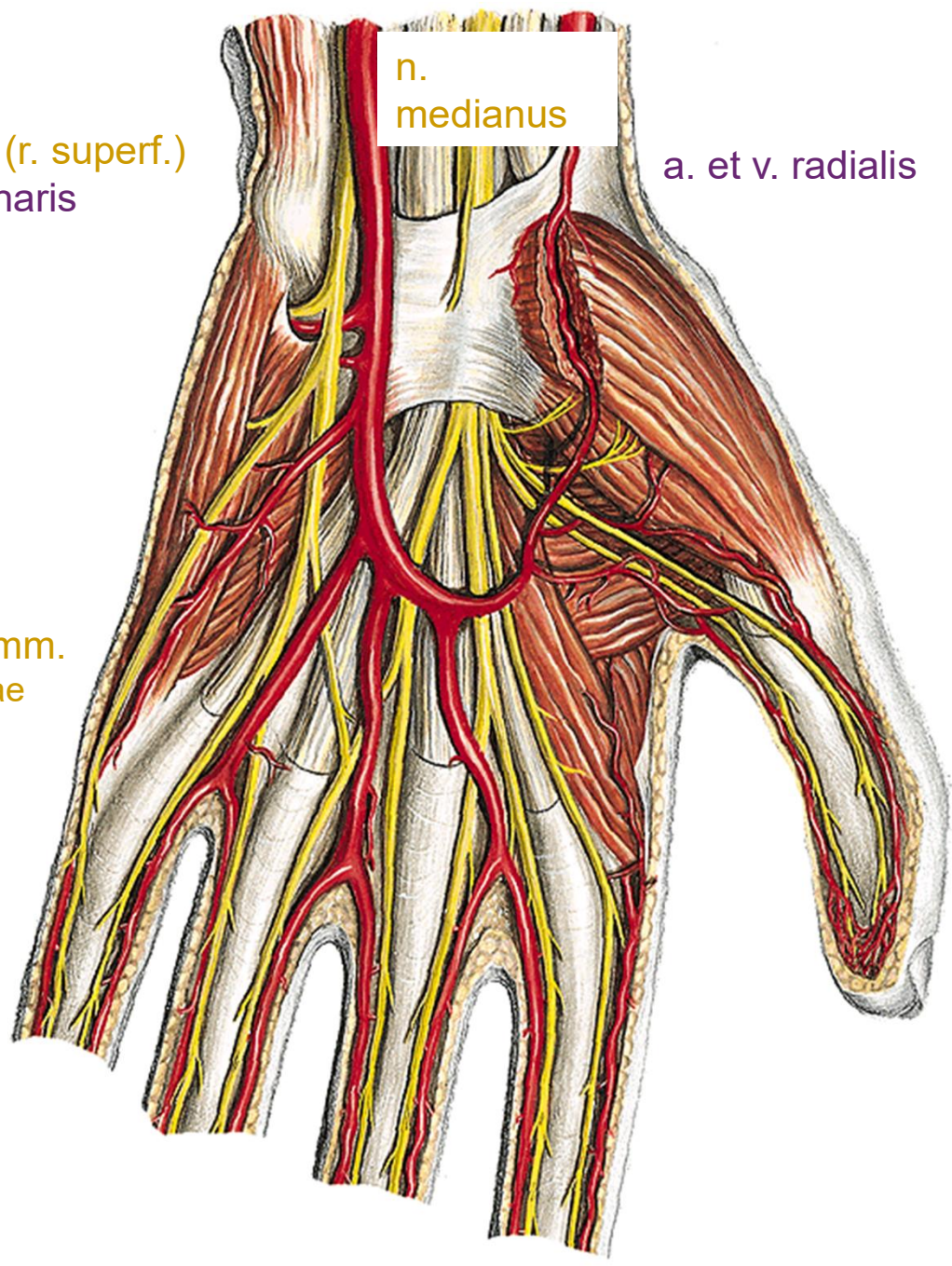


n. ulnaris (r. palmaris)

n. medianus (r. palmaris)

povrchové žíly
aponeurosis palmaris





n.
medianus

n. ulnaris (r. superf.)
a. et v. ulnaris

a. et v. radialis

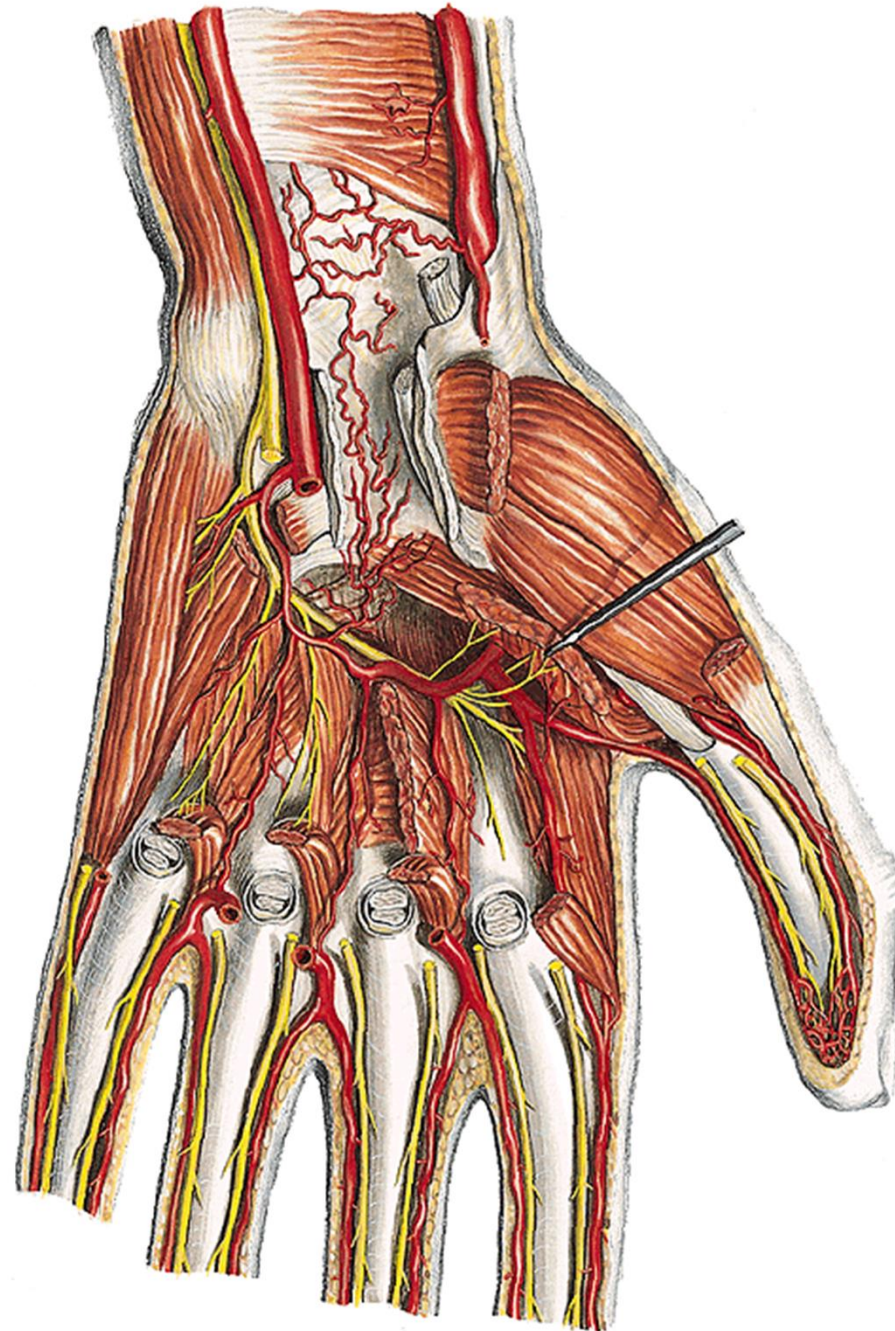
arcus palmaris superf.

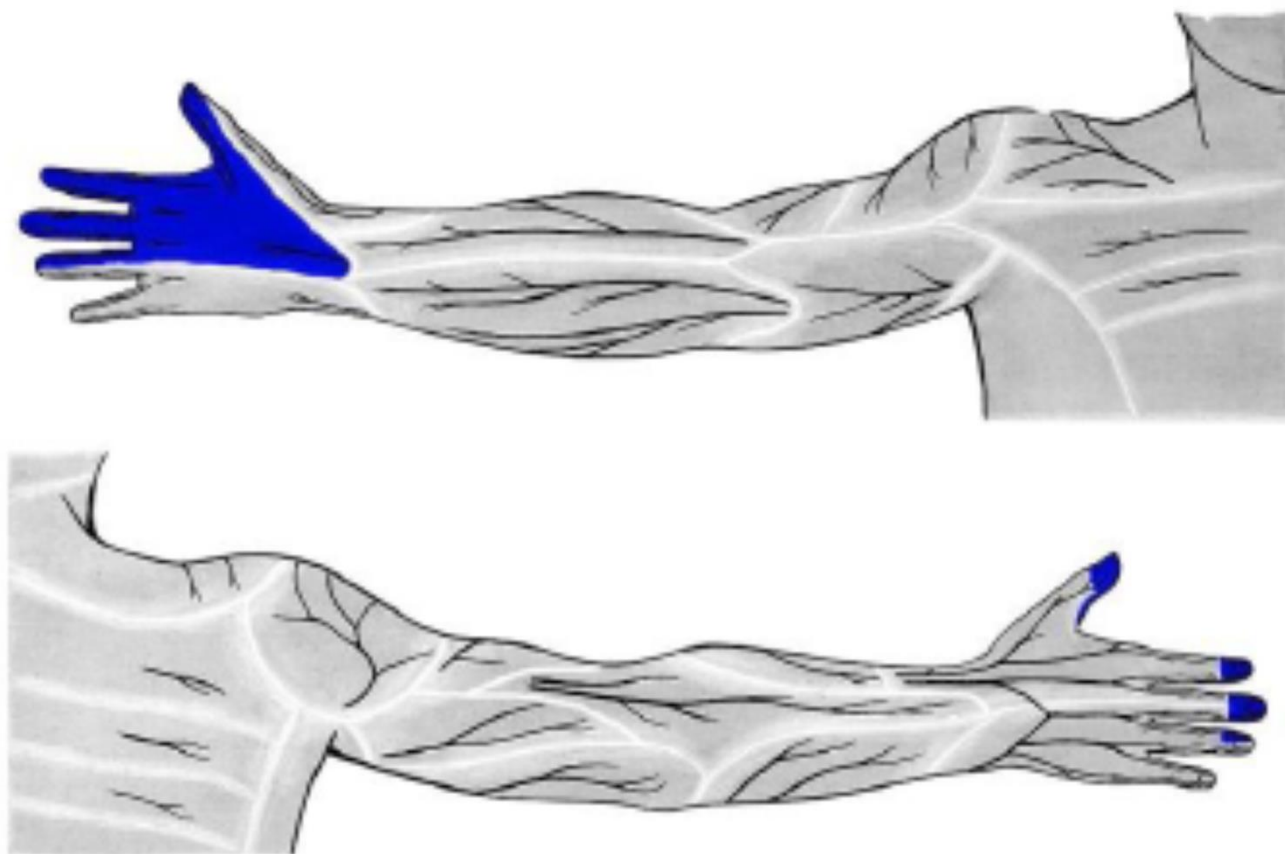
- aa. digitales palm. comm.
- aa. digitales palm. propriae

- nn. digitales palmares comm.
- nn. digitales palmares propriae

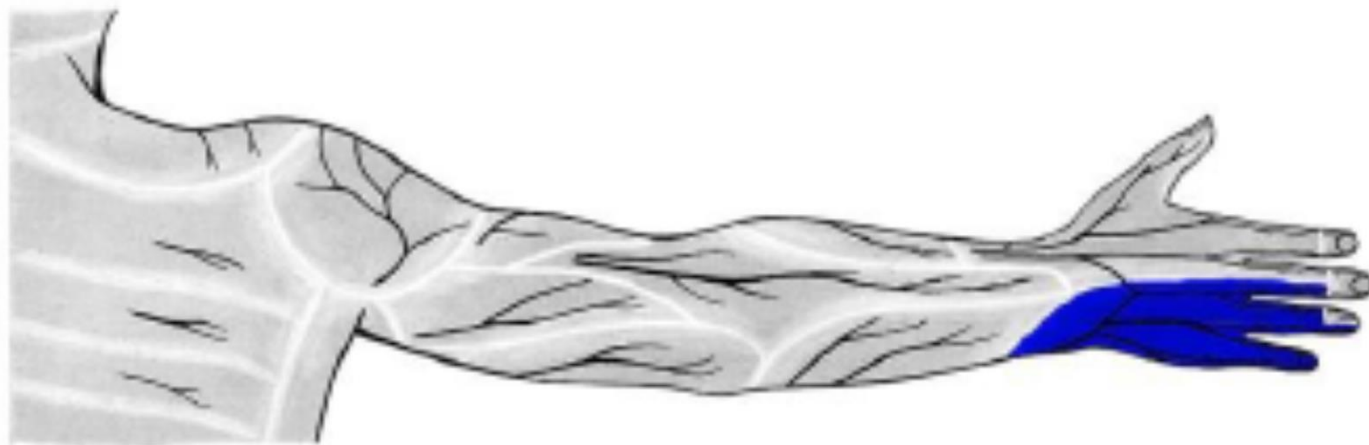
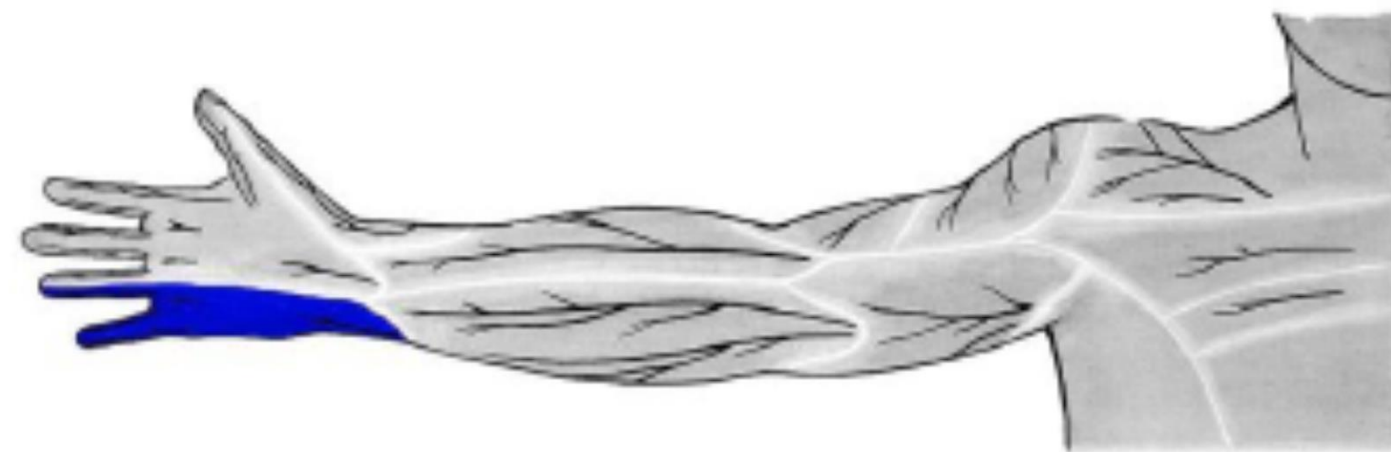n. ulnaris (r. prof.)

arcus palmaris prof.
aa. metacarpeae palm.





n. medianus



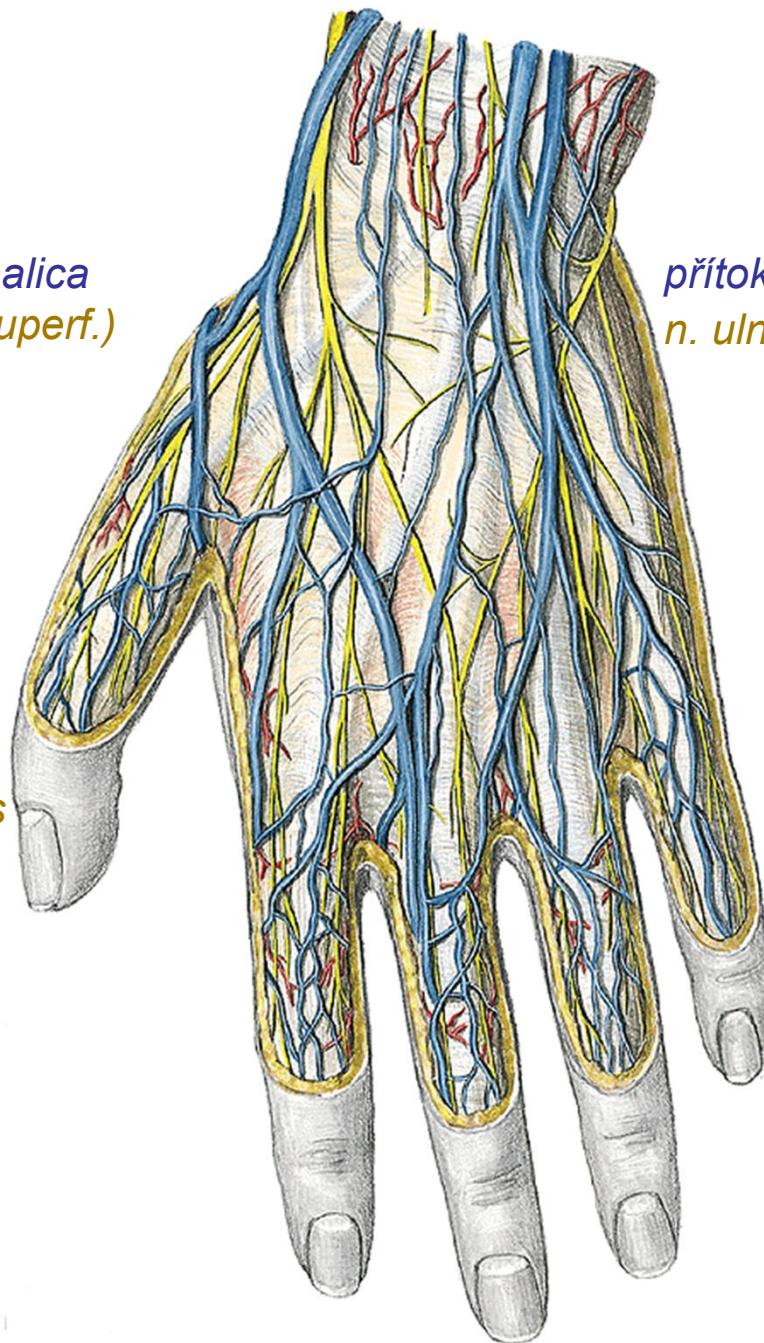
n. ulnaris

přítoky v. cephalica
n. radialis (r. superf.)

přítoky v. basilica
n. ulnaris (r. dorsalis)

dorsum manus

rete venosum
nn. digitales dorsales

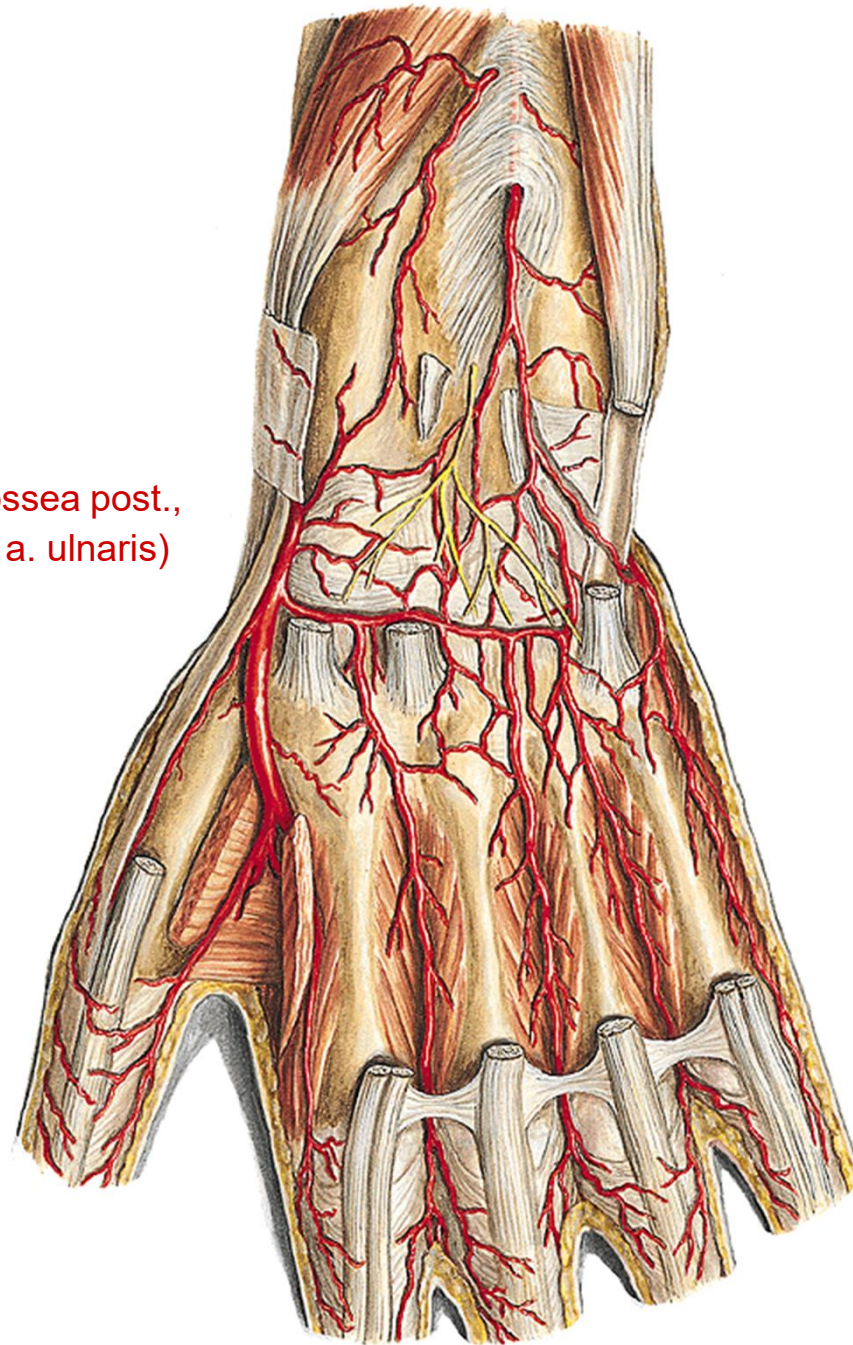


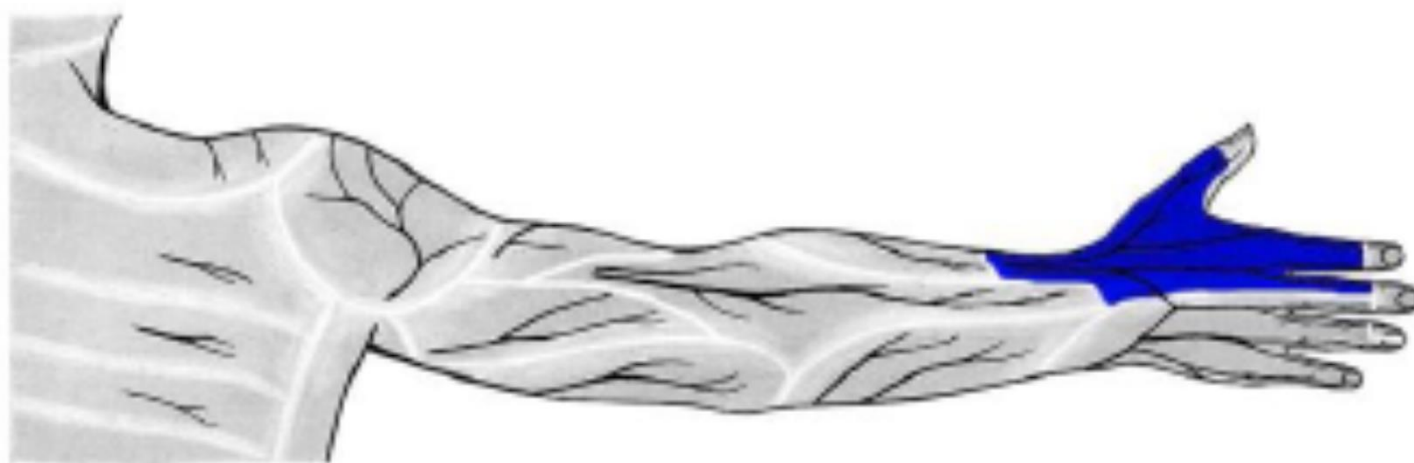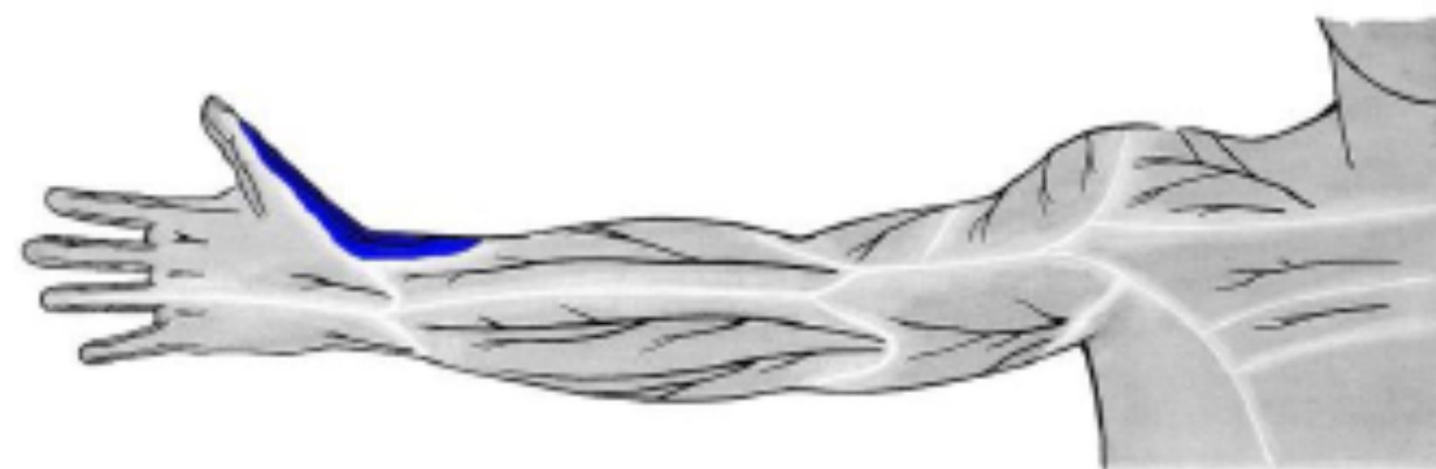n. interosseus post.

rete carpi dorsale

(a. interossea ant., a. interossea post.,
r. carpeus dors a. radialis et a. ulnaris)

aa. metacarpeae dors.





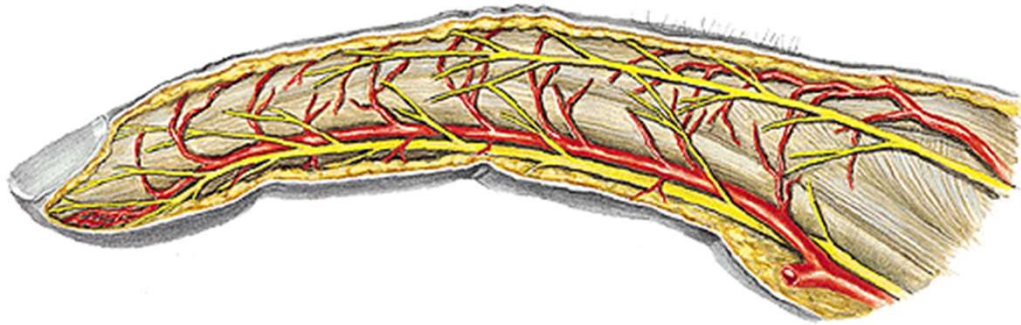
n. radialis



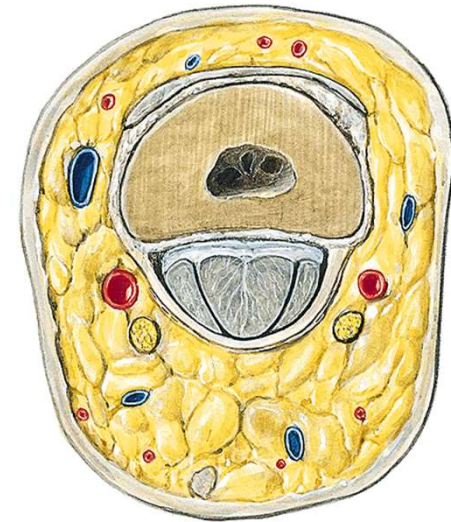
n. ulnaris

digiti manus

nn. digitales dors. (n. radialis et n. medianus)
aa. digitales dors.

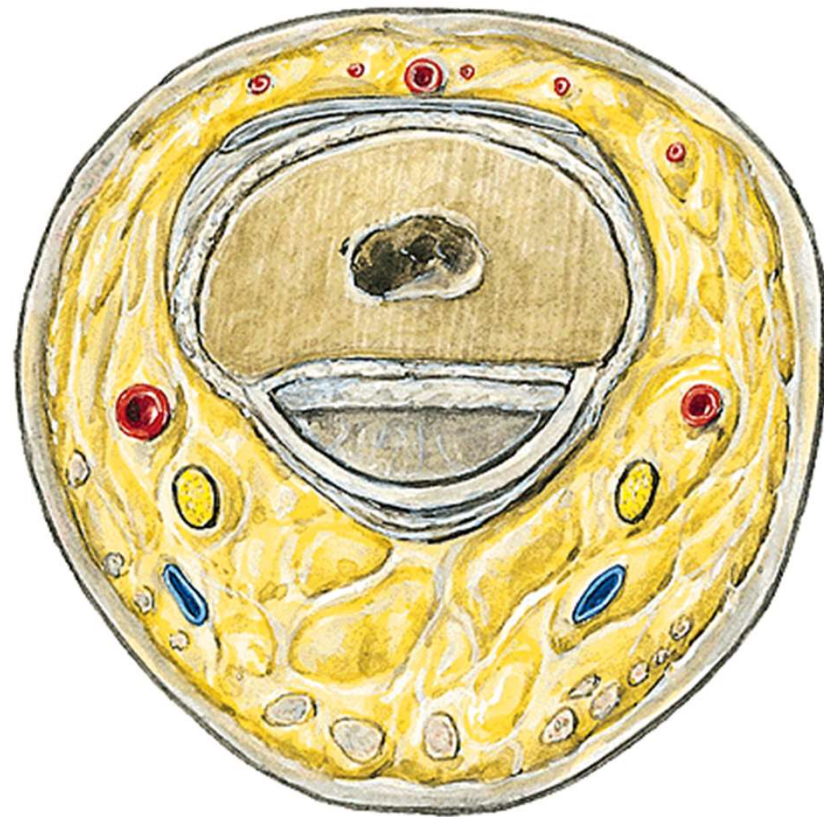

nn. digitales palm. propr. (n. medianus et n. ulnaris)
aa. digitales palm. propr.



phalanx proximalis

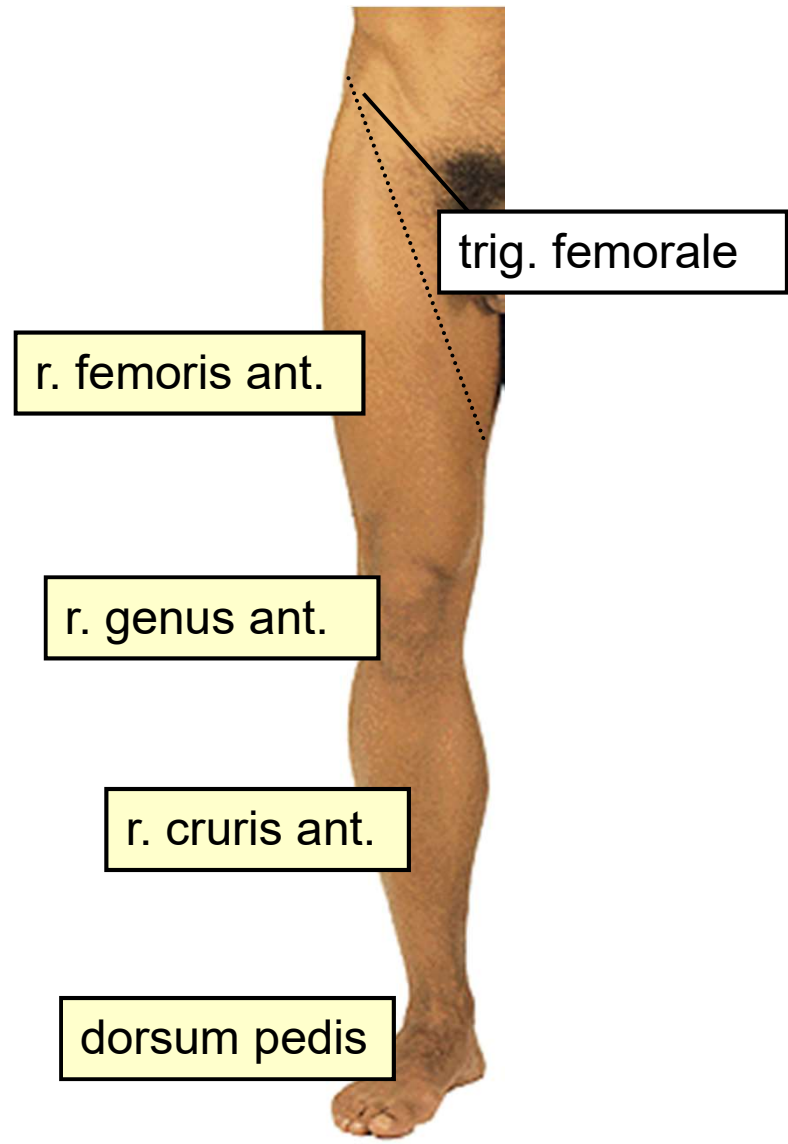
dorsálně



phalanx media

Topografická anatomie DK





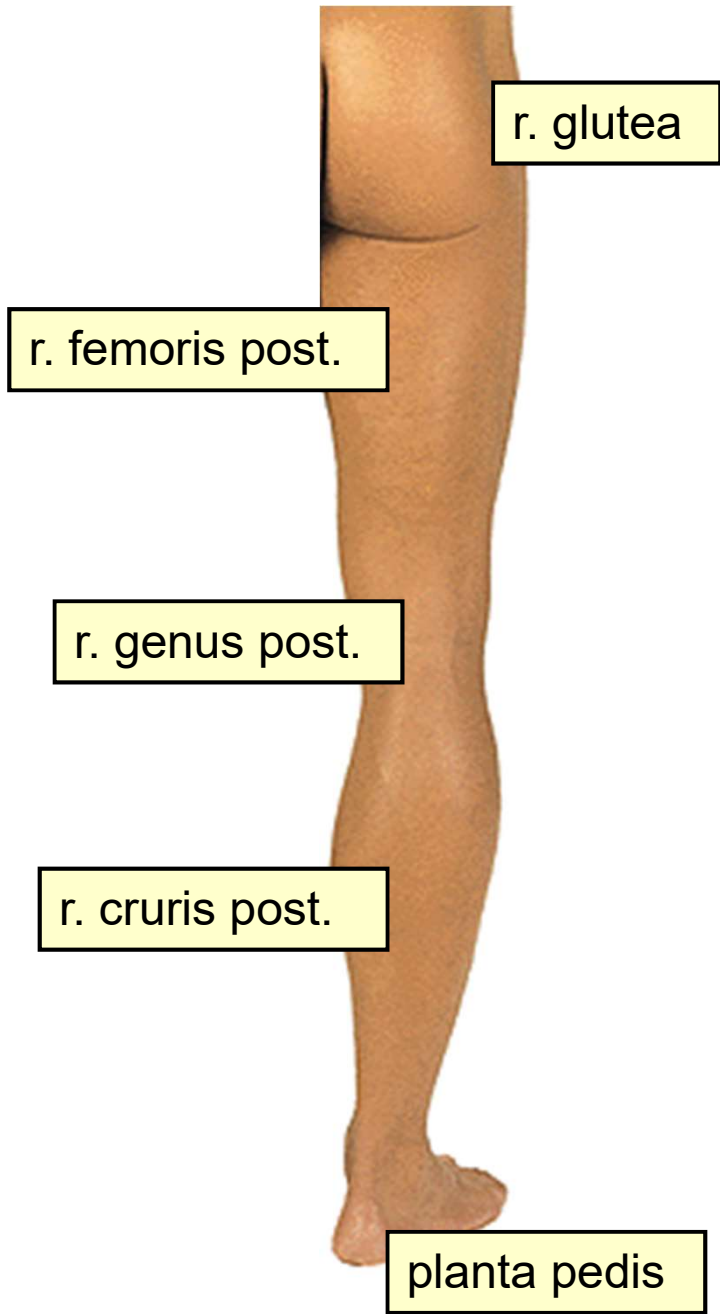
trig. femorale

r. femoris ant.

r. genus ant.

r. cruris ant.

dorsum pedis



r. glutea

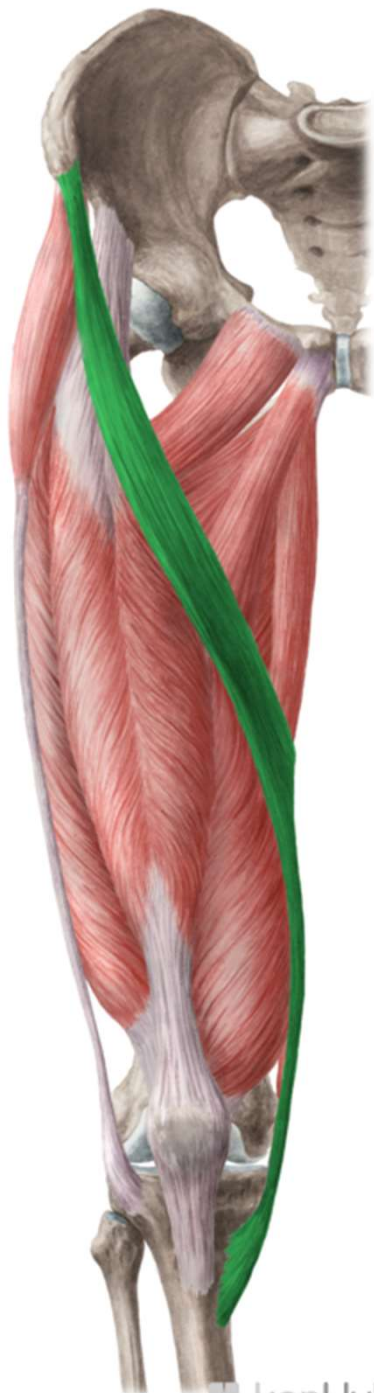r. femoris post.

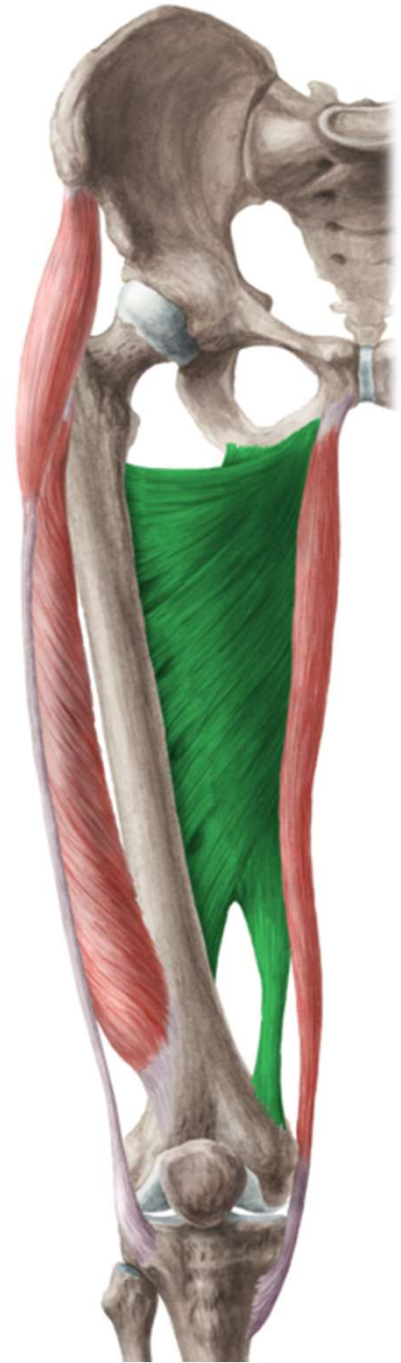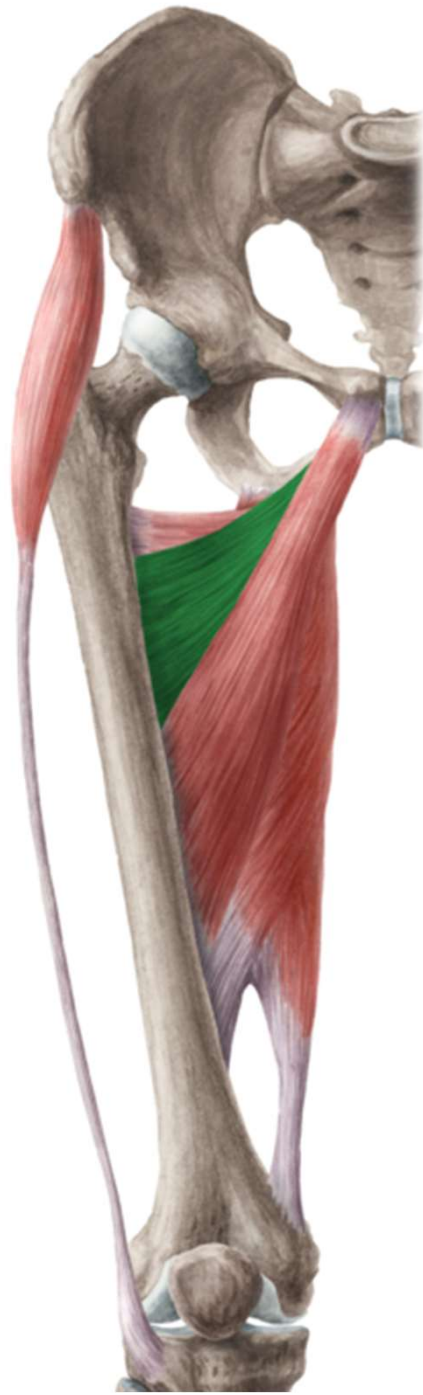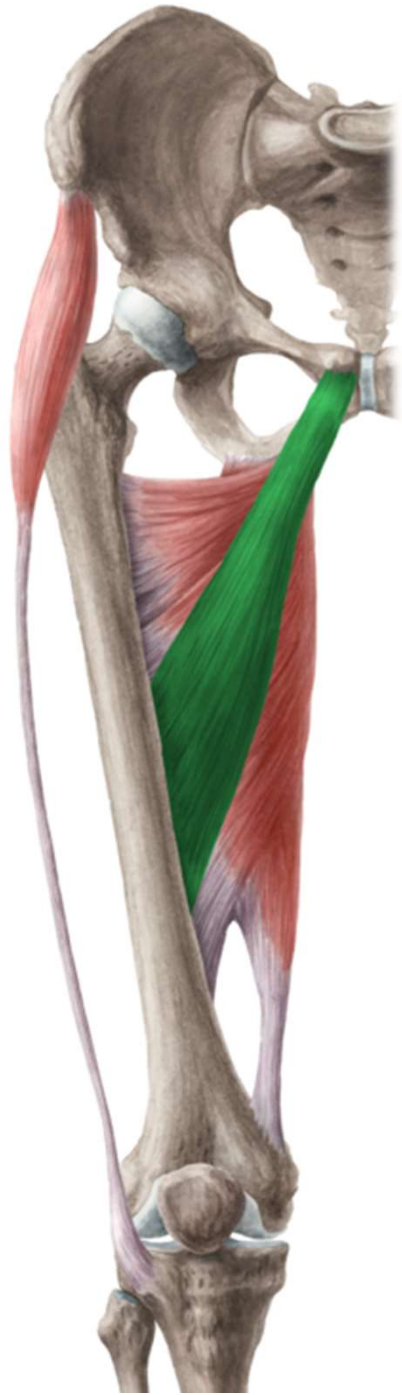r. genus post.

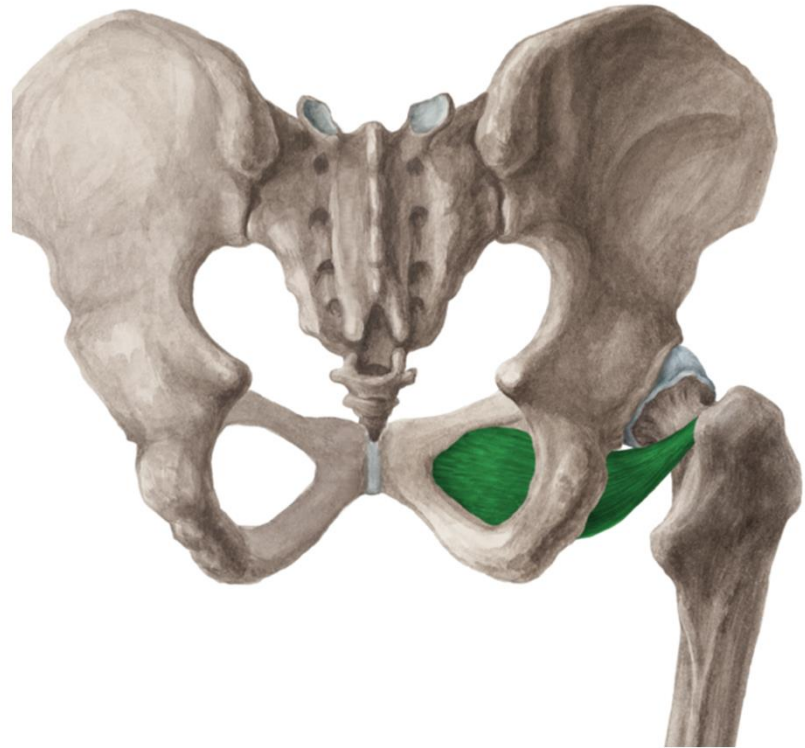
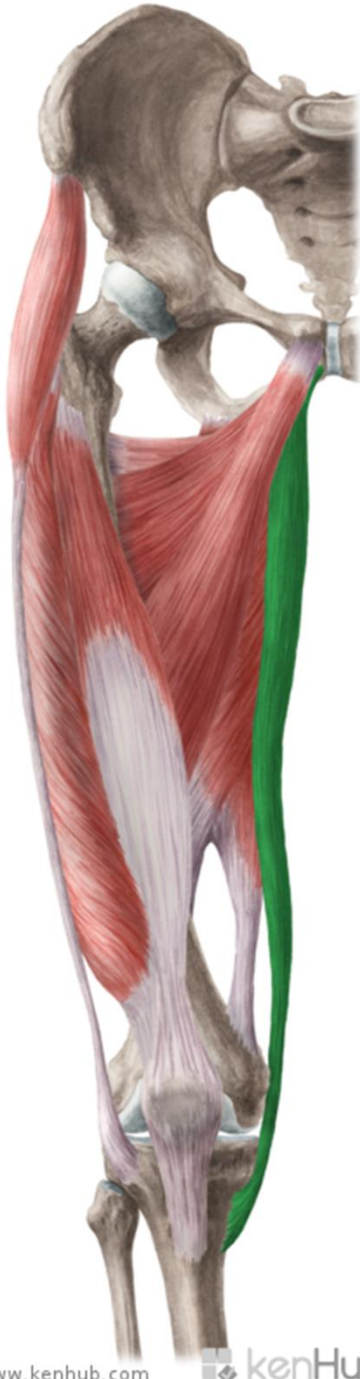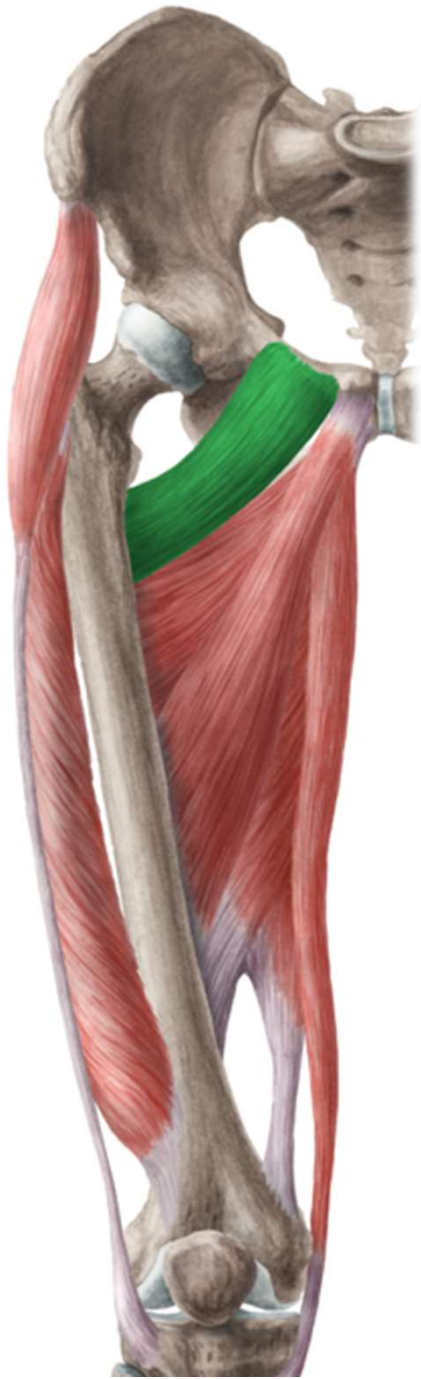r. cruris post.

planta pedis

**r. femoris
ant.**

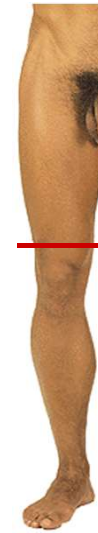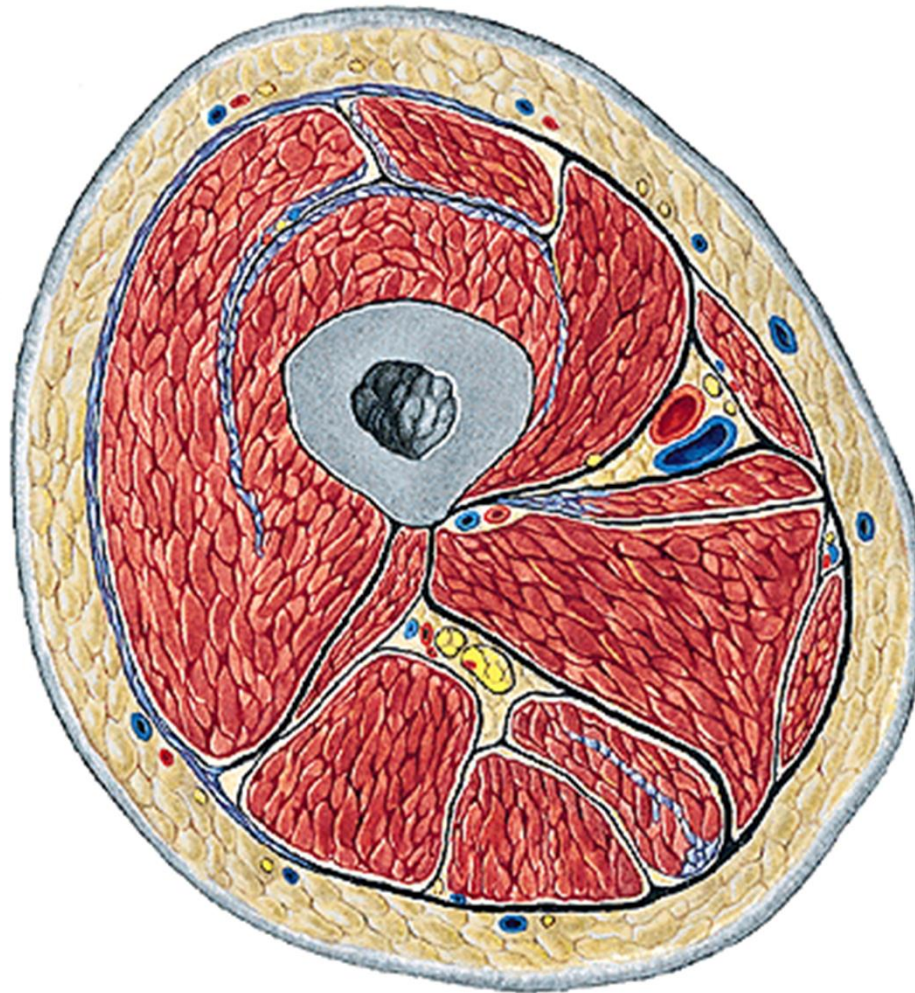






v. saphena magna + přítoky
n. cutaneus femoris lat.
n. cutaneus femoris post.
rr. cutanei ant. (z n. femoralis)
r. cutaneus (z n. obturatorius)

n. femoralis → n. saphenus
a. et v. femoralis
n. obturatorius
a. et v. obturatoria
n. ischiadicus



r. femoris ant.

v. saphena magna + přítoky

a. epigastrica superf.

a. circumflexa ilium superf.

aa. pudendae ext.

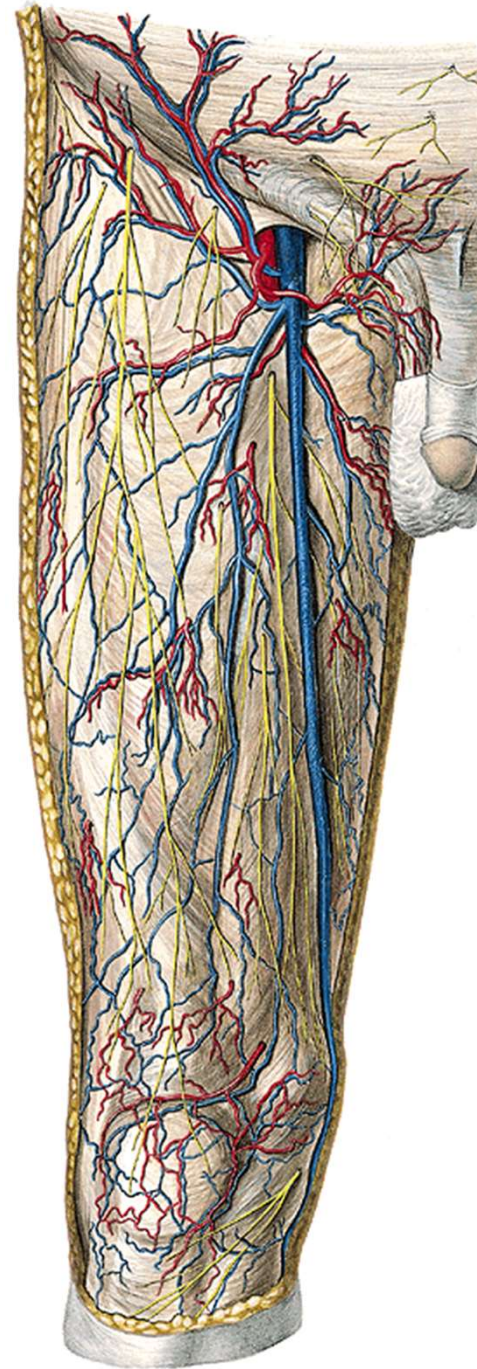
n. cutaneus femoris lat.

r. femoralis (z n. genitofemoralis)

rr. cutanei ant. (z n. femoralis)

r. cutaneus (z n. obturatorius)

nll. inguinales superf.



trig. femorale

m. sartorius, lig. inguinale, m. adductor longus

v. saphena magna

v. saphena accessoria

v. epigastrica superf. a. epig. superf.

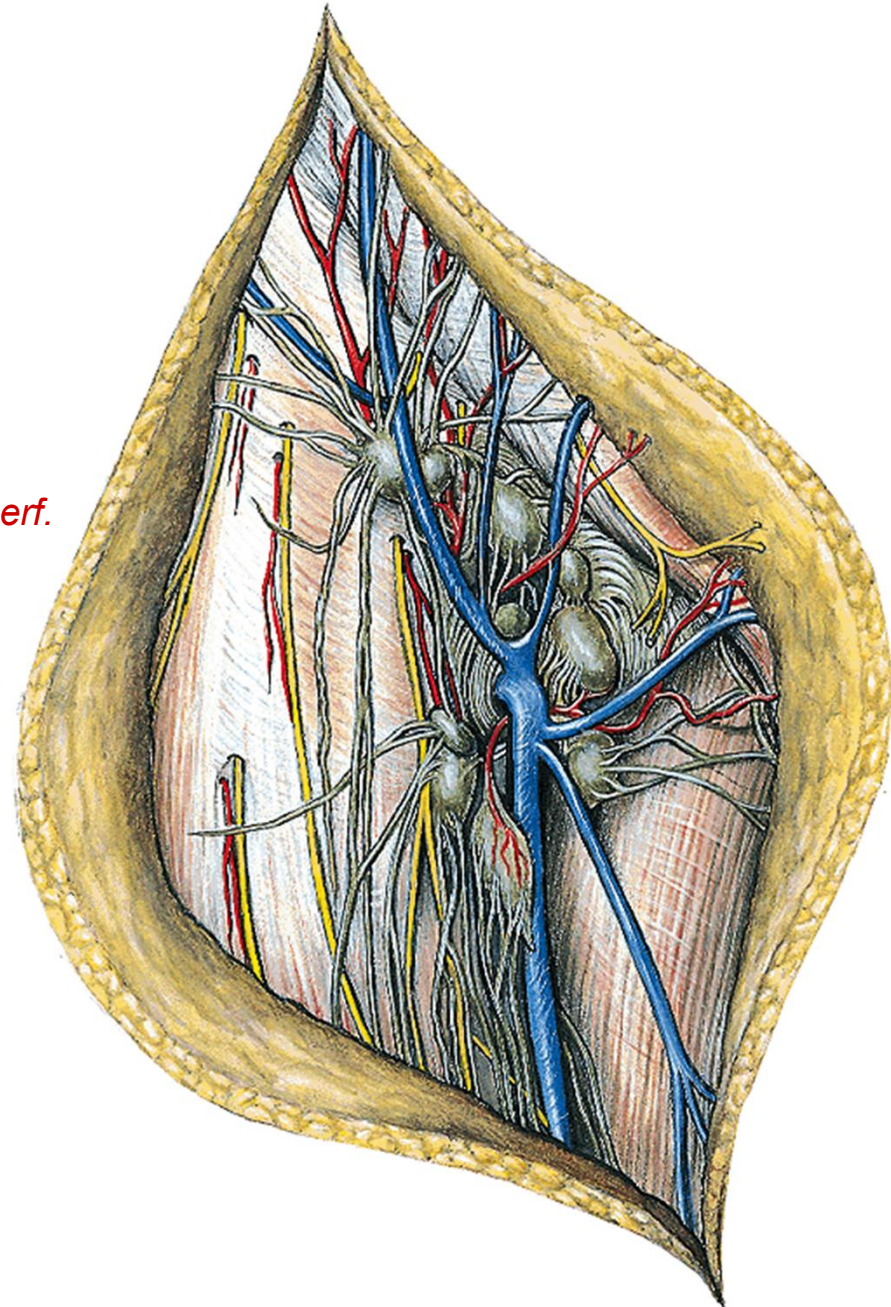
v. circumfl. ilium superf. a. circumfl. ilium superf.

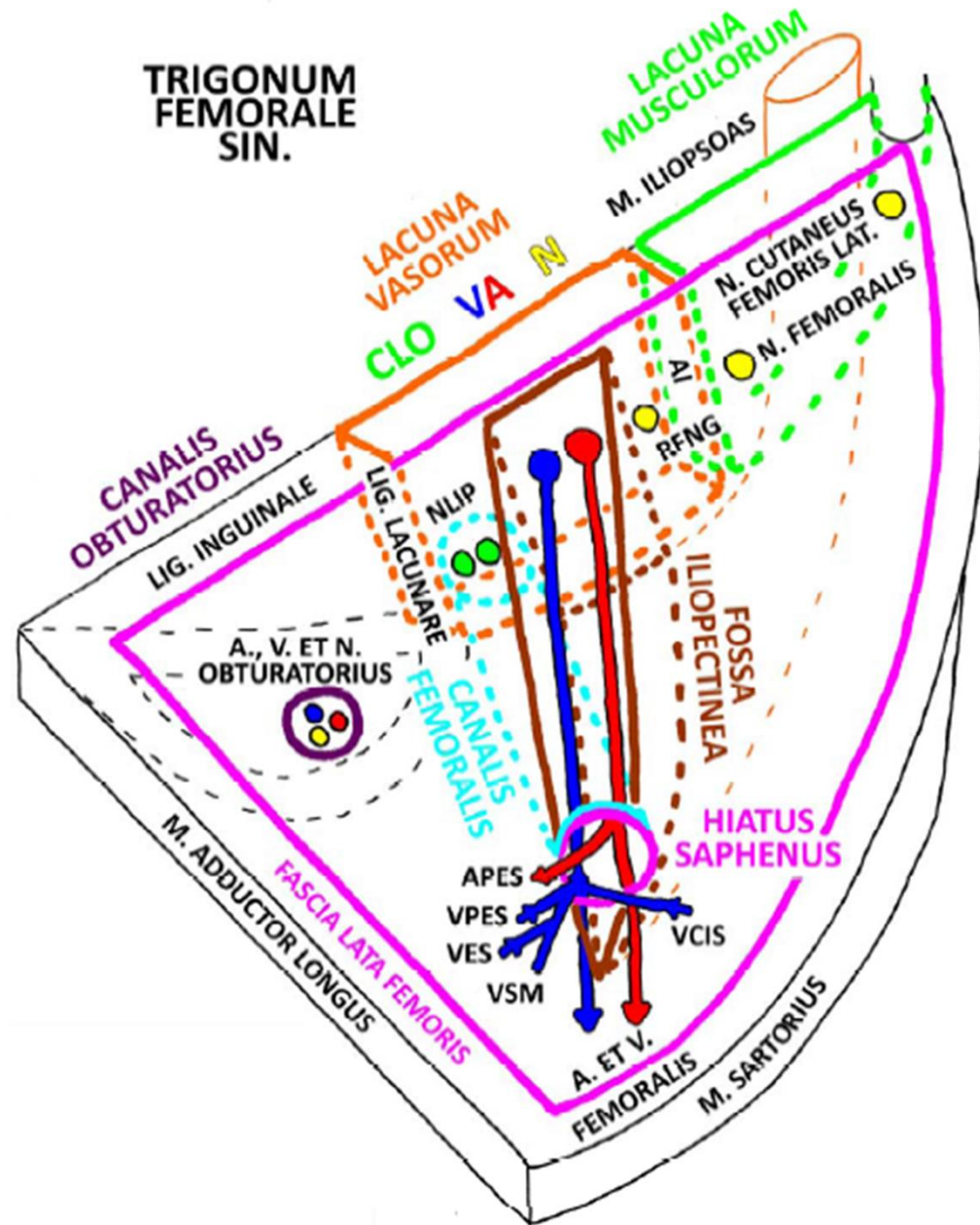
vv. pudendae ext. aa. pudendae ext.

nl. inguinales superf.

n. ilioinguinalis

n. genitofemoralis (r. femoralis)



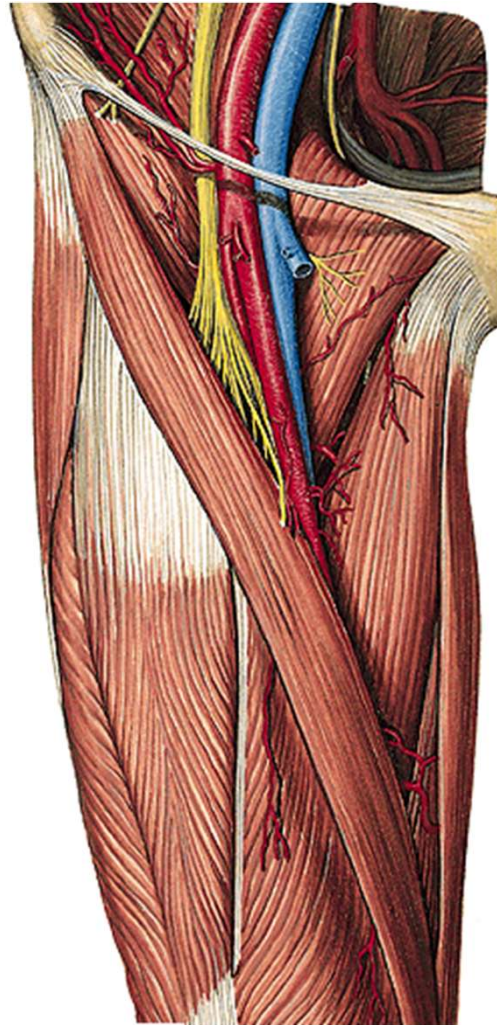


fossa
iliopectinea

a. et v. femoralis

n. femoralis

nll. inguinales prof.



FOSSA ILIOPECTINEA



lacuna musculorum:

m. iliopsoas

n. femoralis

lacuna vasorum:

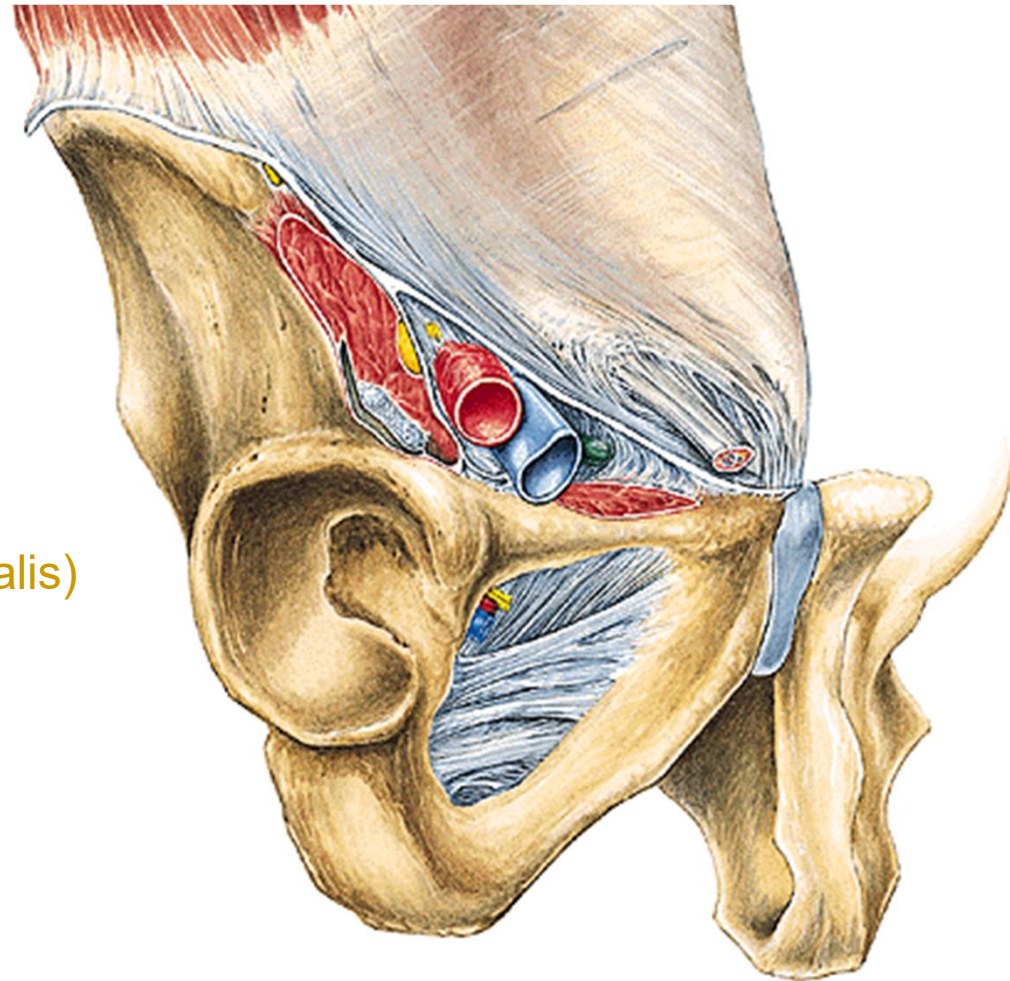
n. genitofemoralis (r. femoralis)

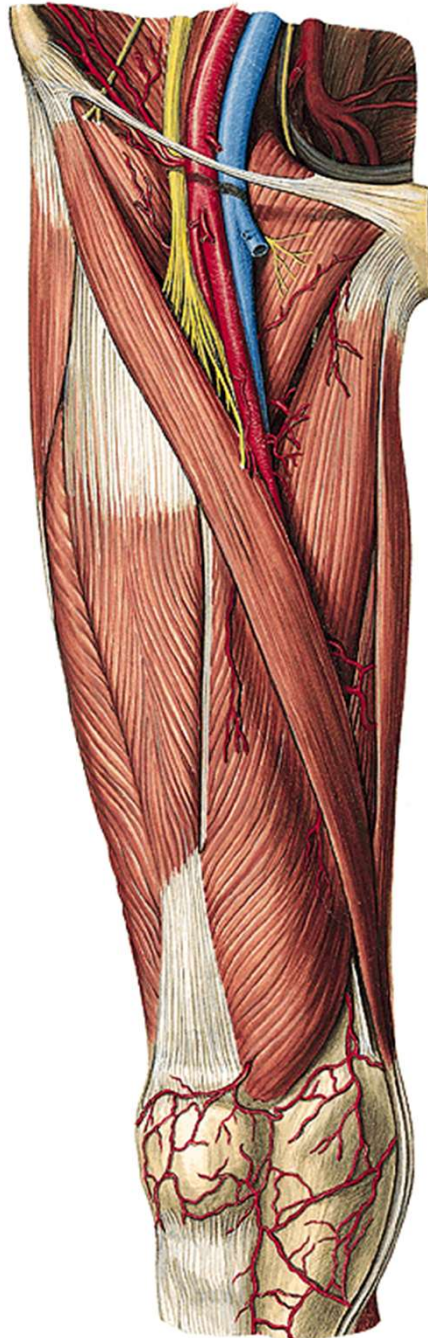
a. femoralis

v. femoralis

nl. Cloqueti

femorální hernie





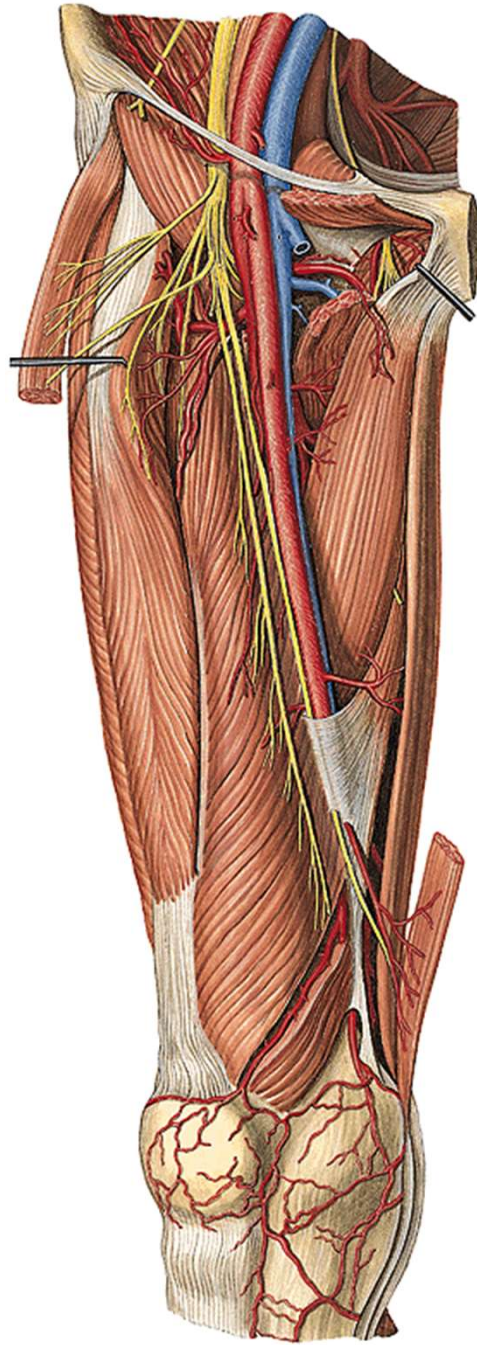
canalis adductorius

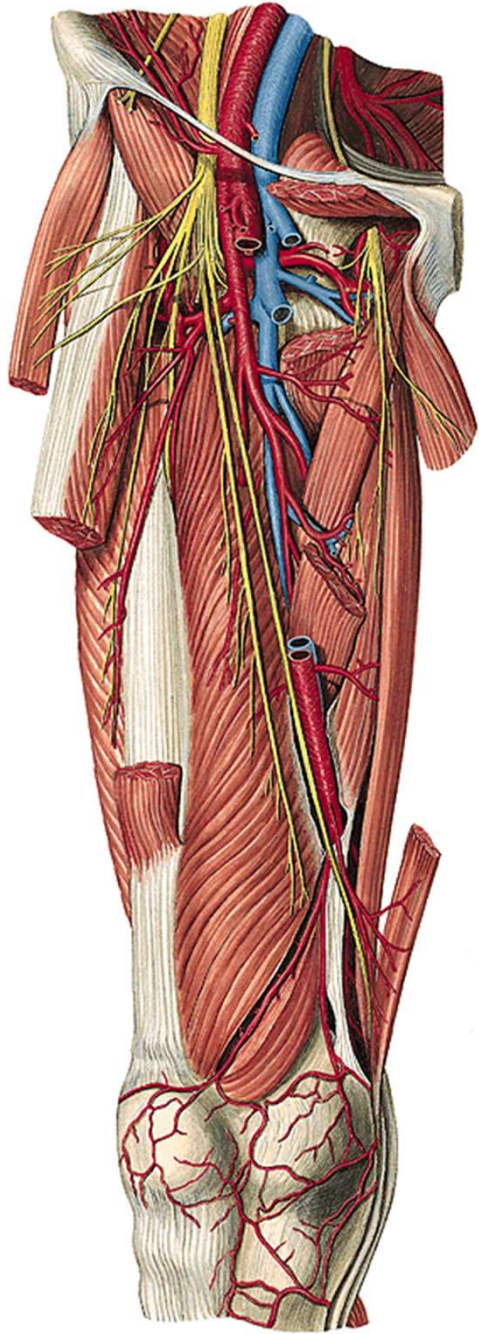
(m. vastus med. a m. adductor magnus)

a. et v. femoralis

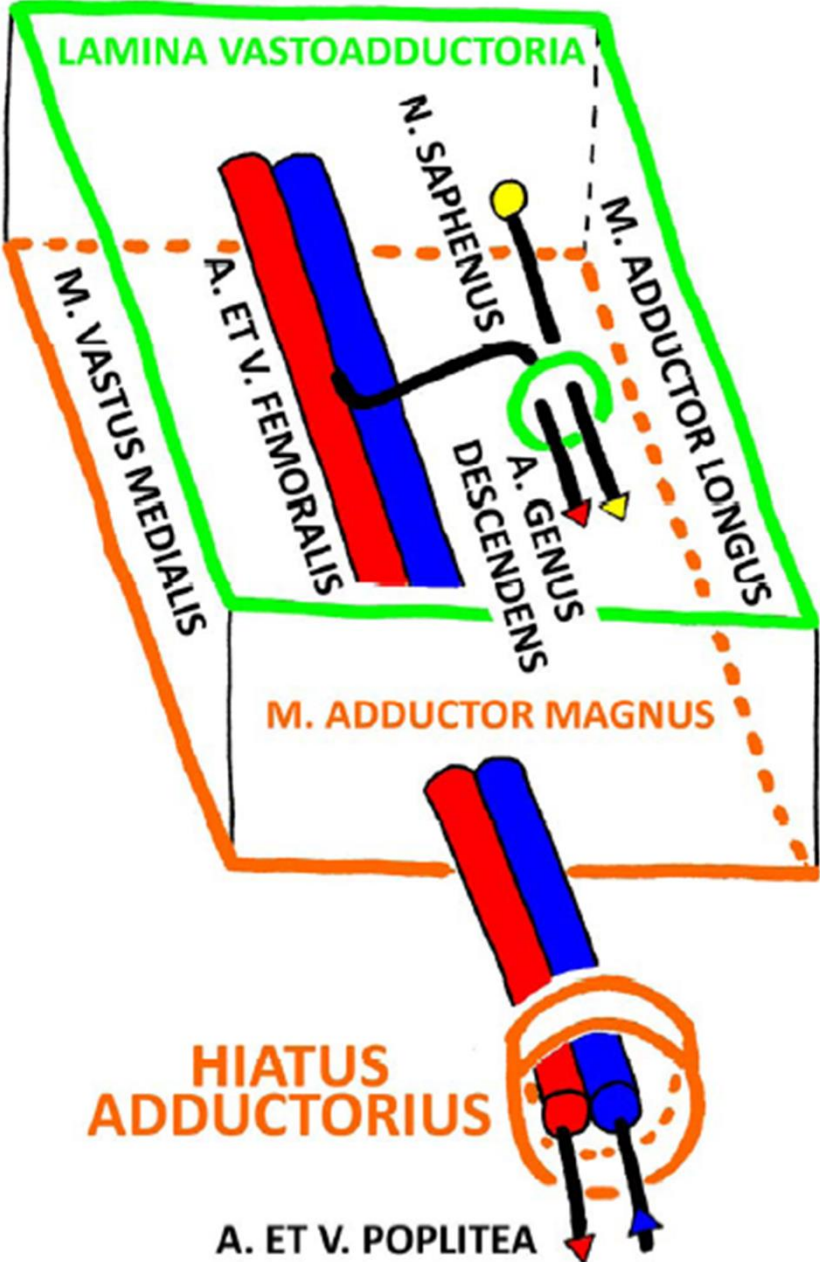
n. saphenus

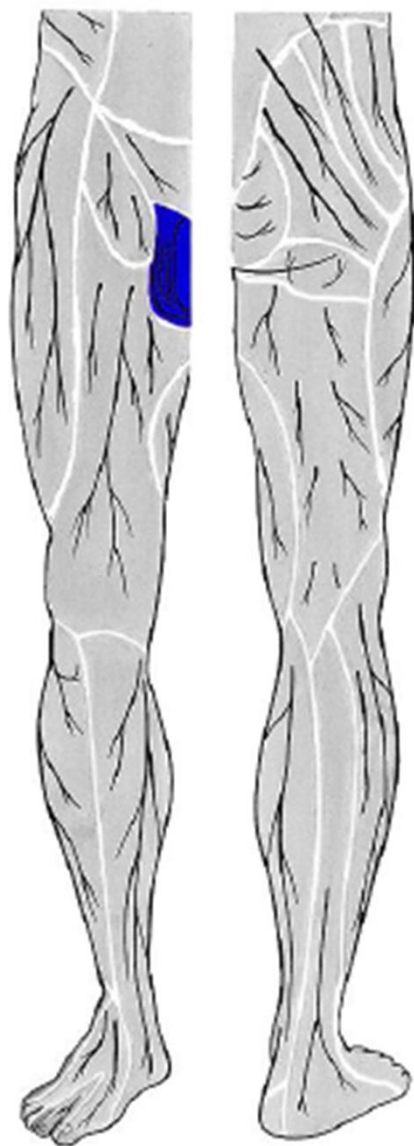
hiatus tendineus



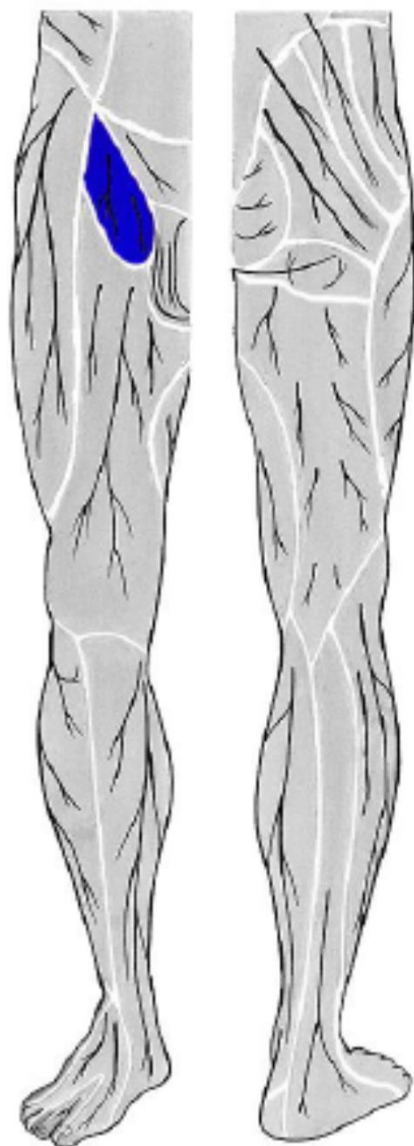


CANALIS ADDUCTORIUS DX.

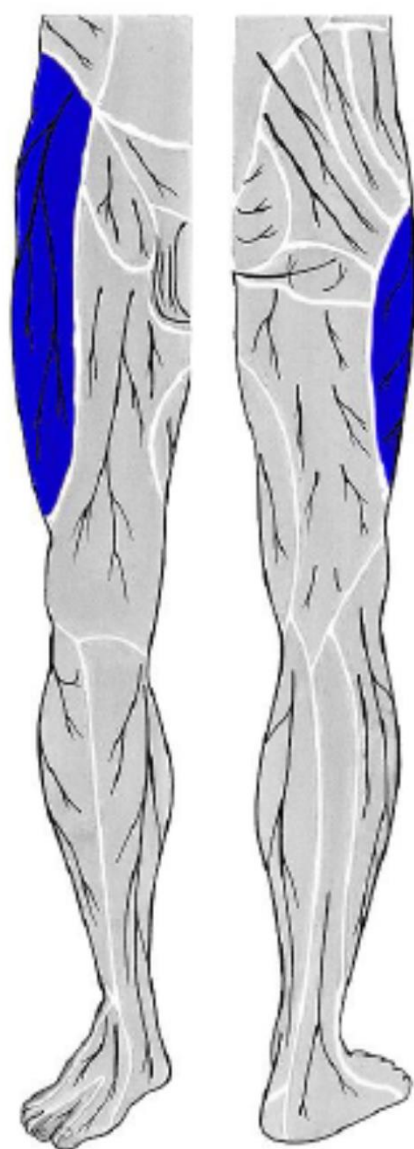




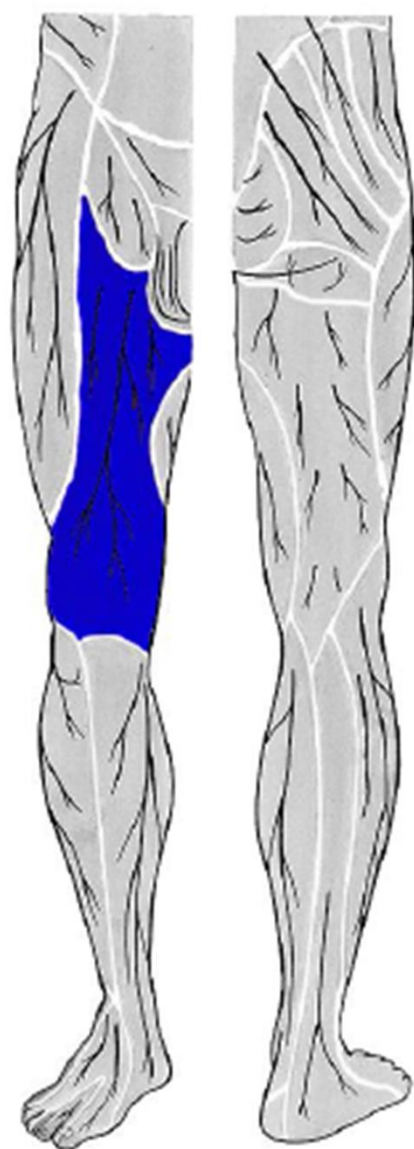
n. ilioinguinalis



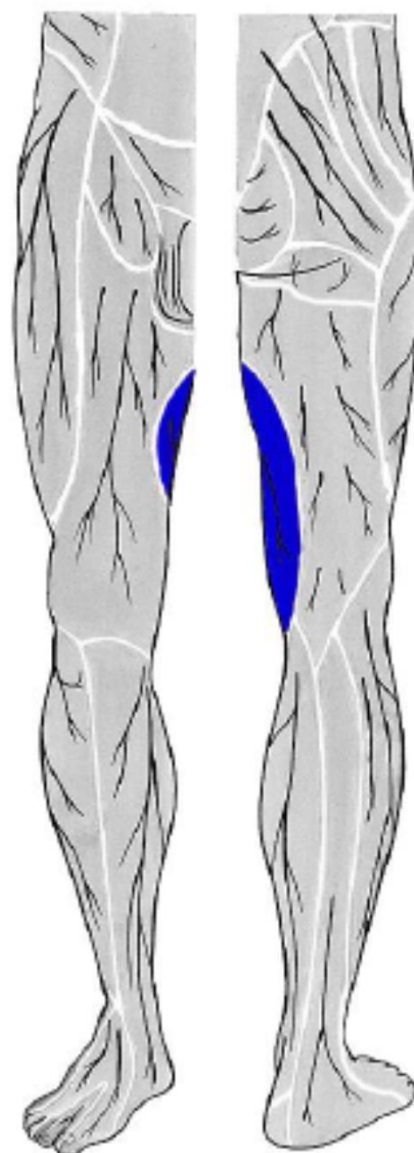
n. genitofemoralis



**n. cutaneus femoris
lateralis**

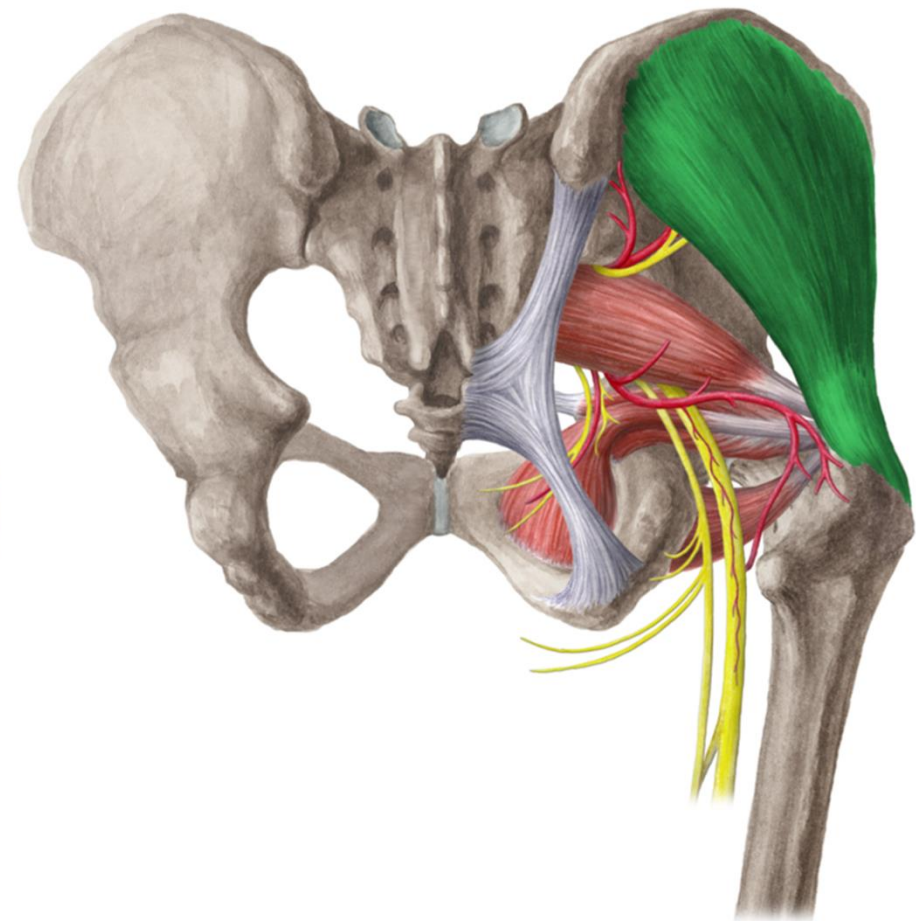
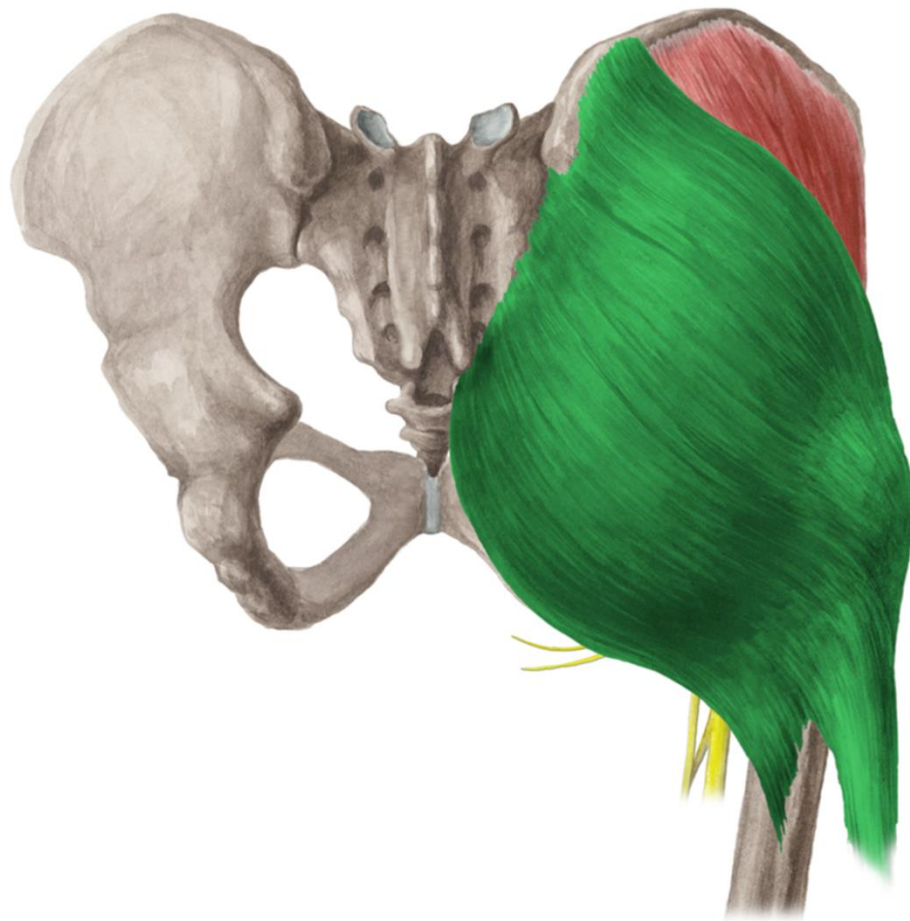

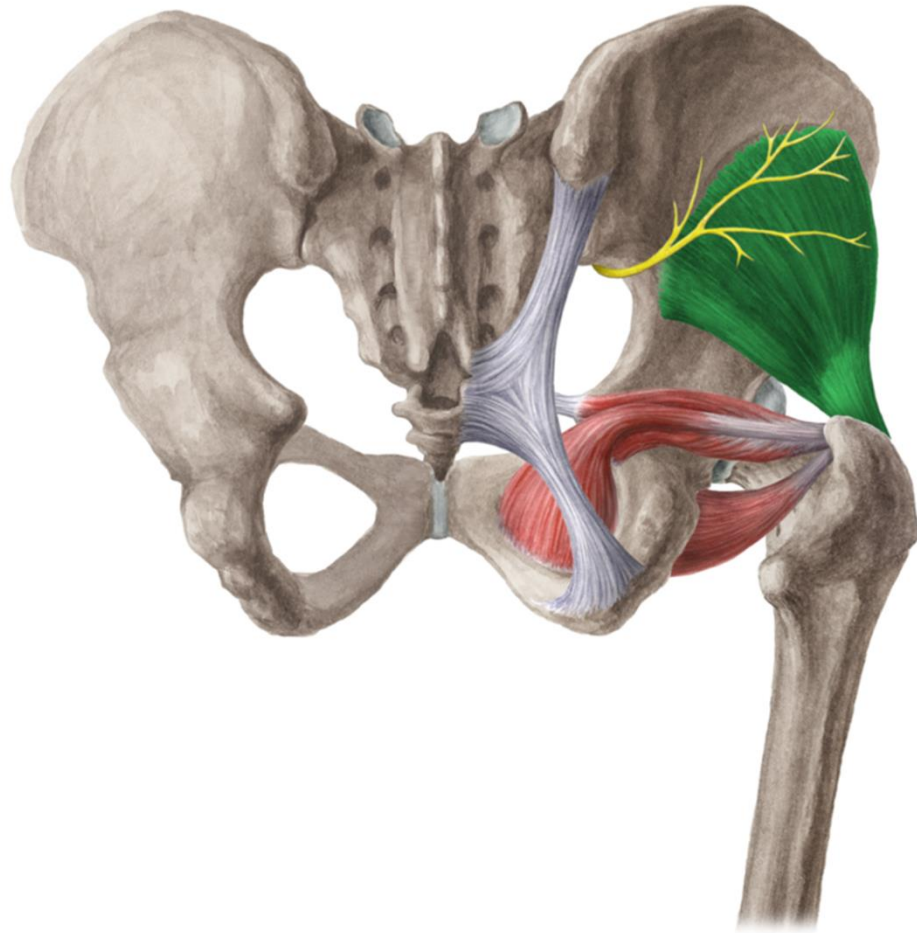
**rr. cutanei ant. femoris
(z n. femoralis)**



**r.cutaneus n. obturatorii
(z n. obturatorius)**

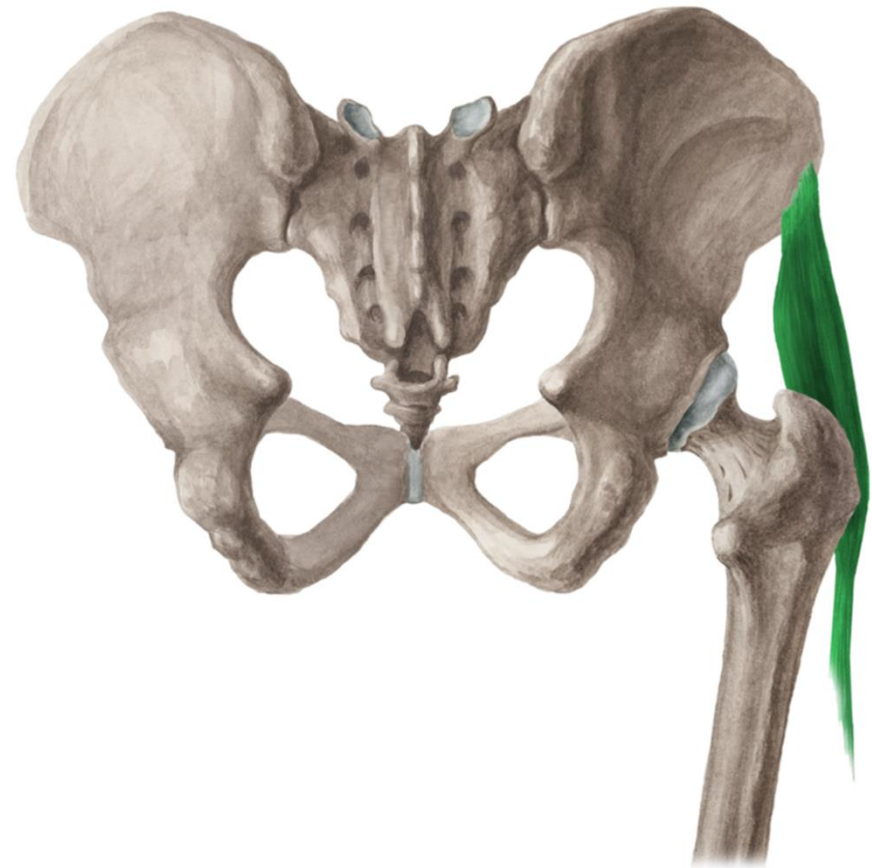
r. glutea
r. femoris post.





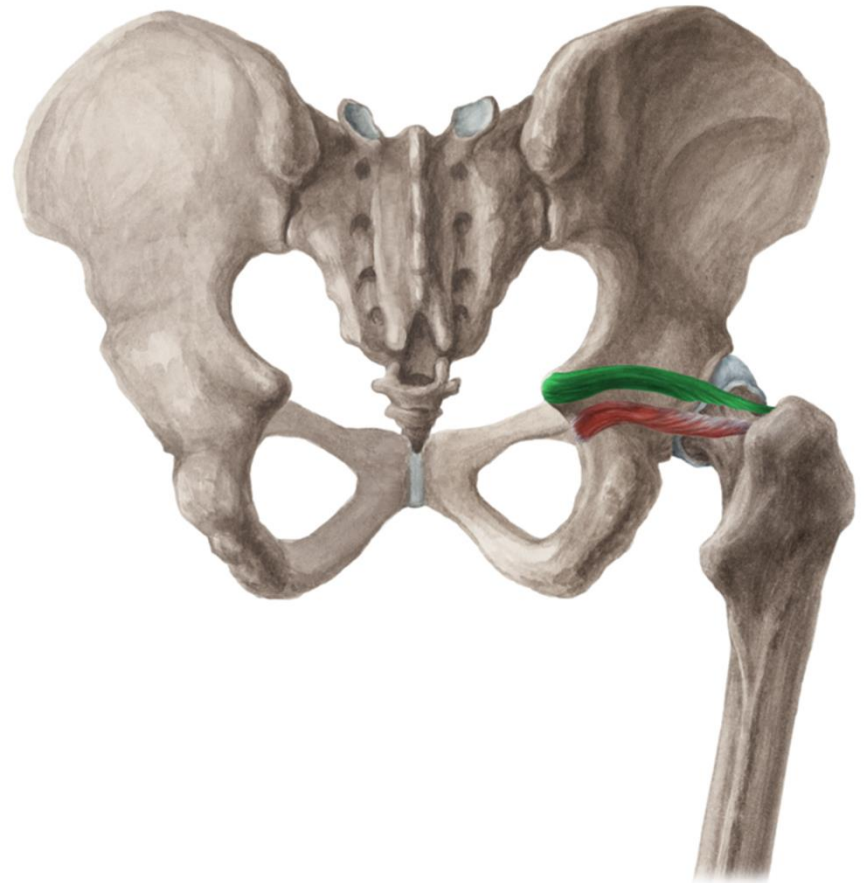
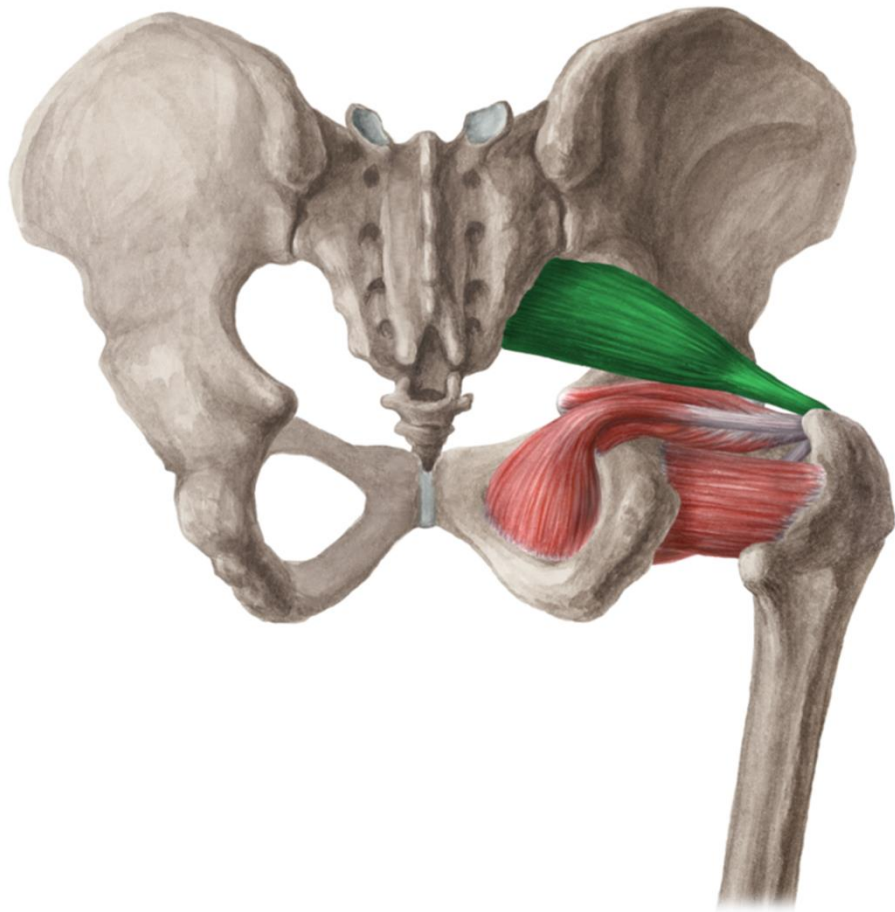
www.kenhub.com

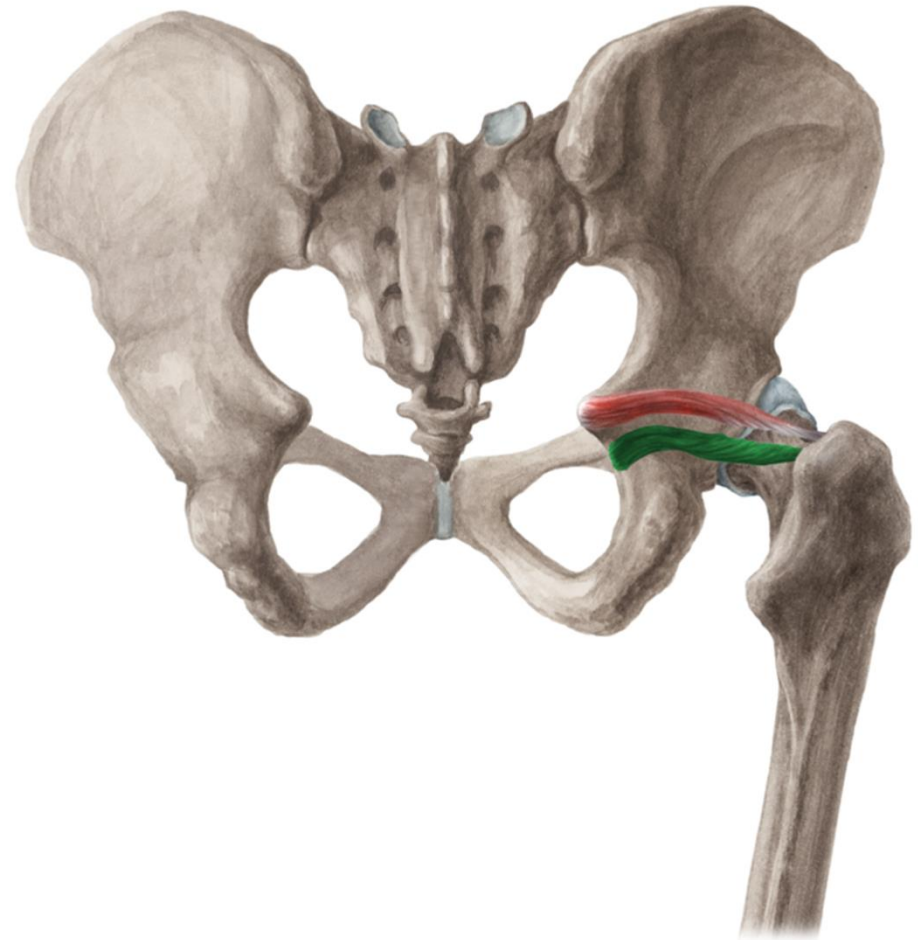
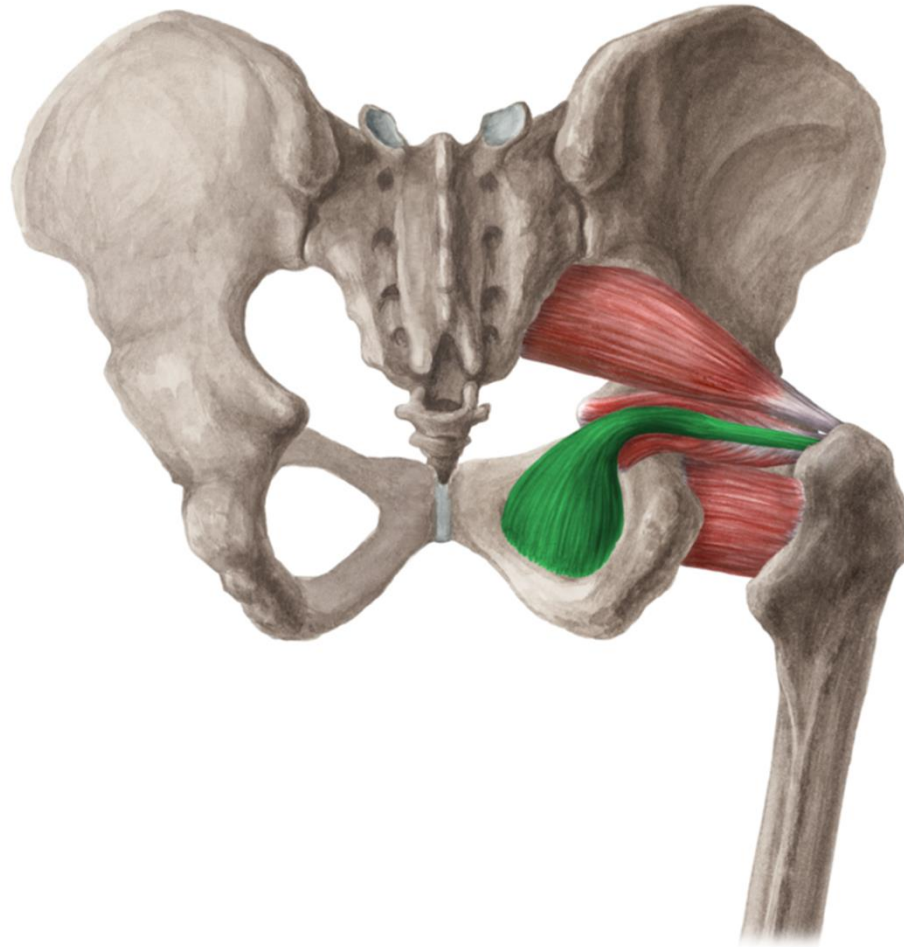
kenHub

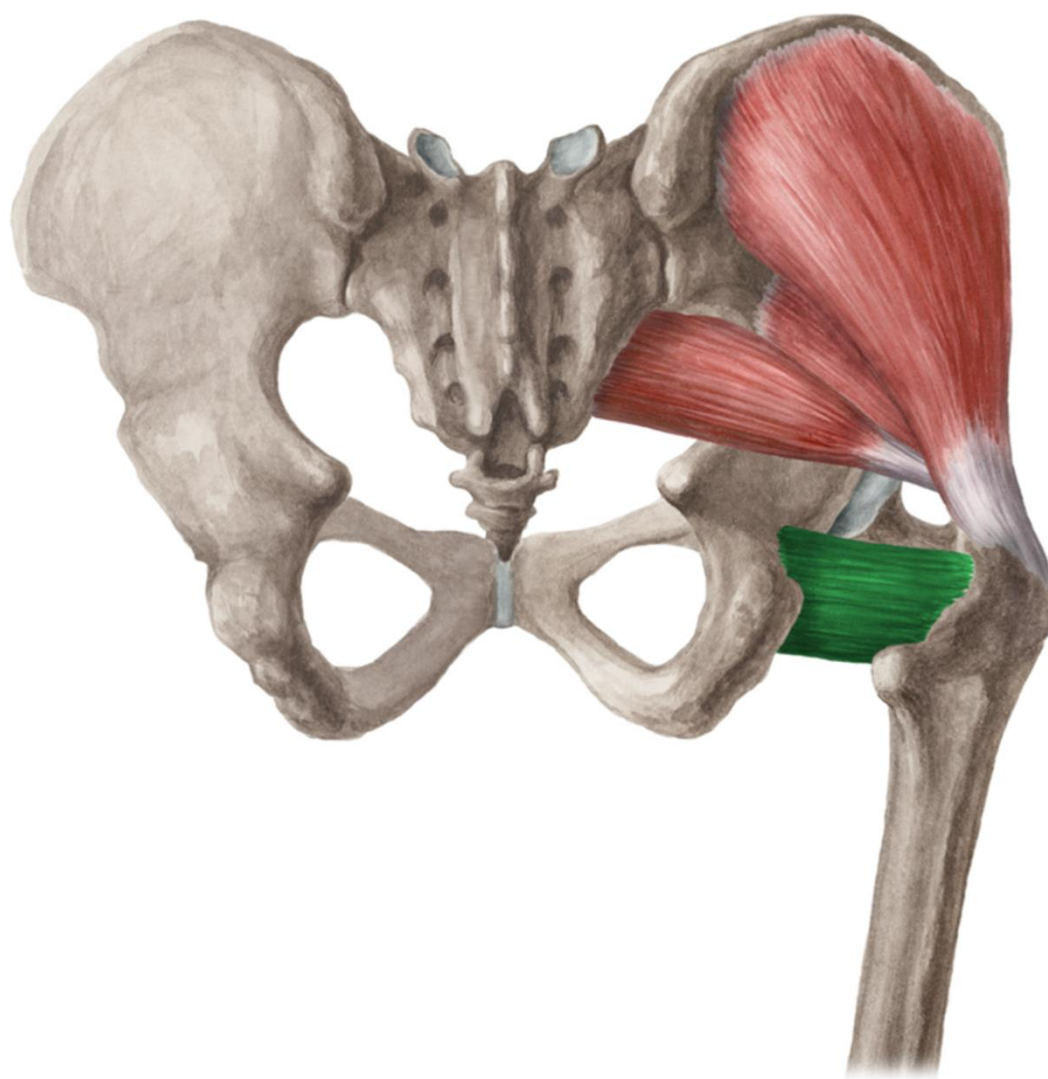


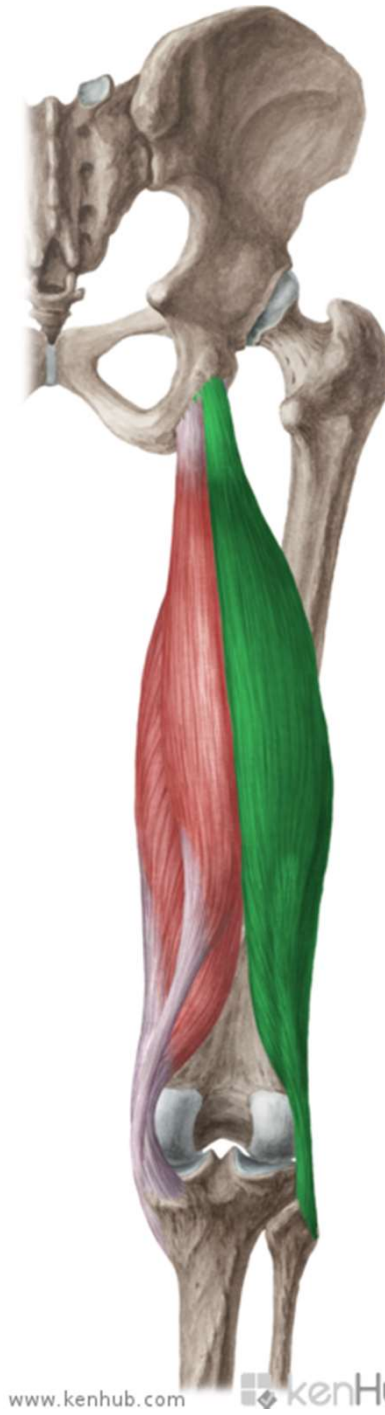
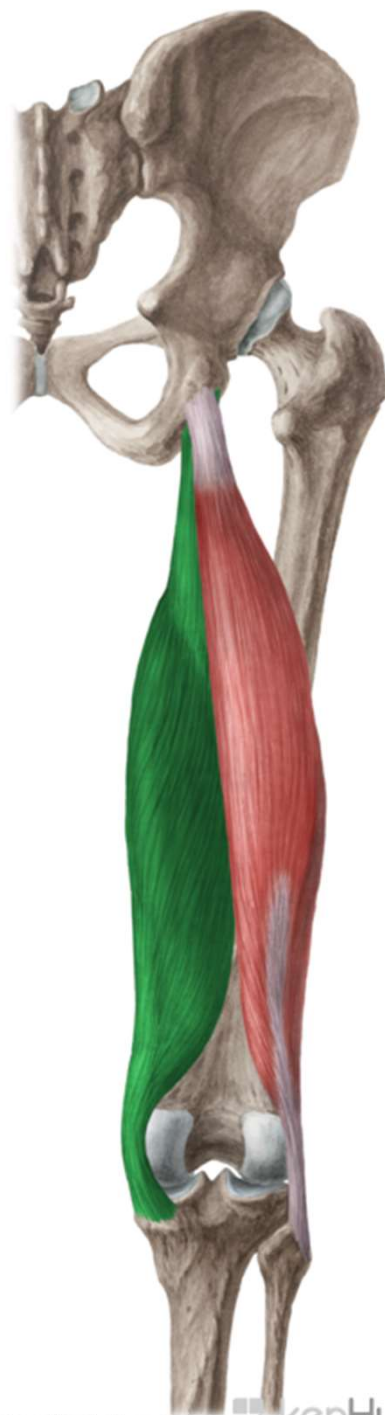
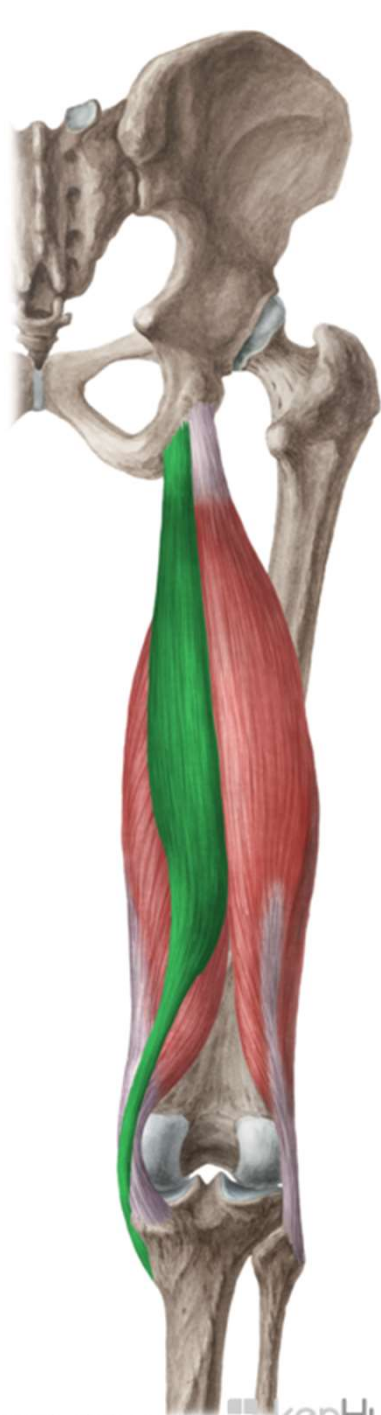
www.kenhub.com

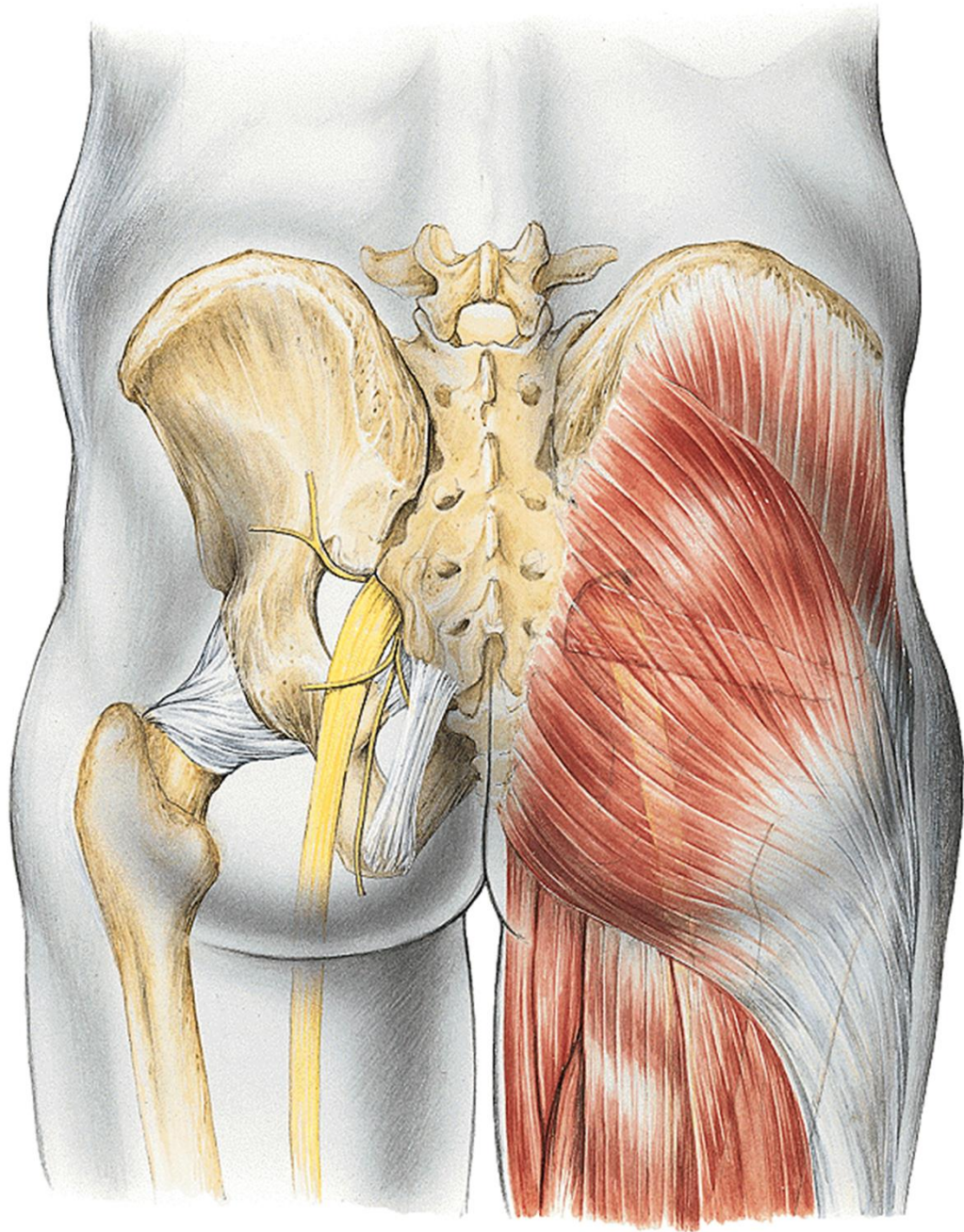
kenHub





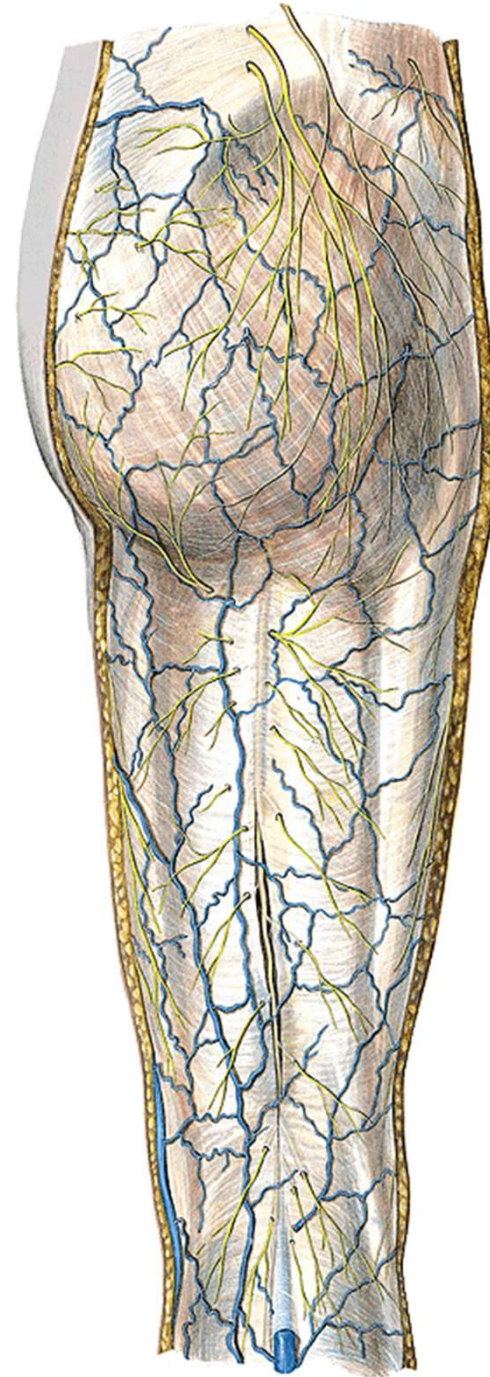


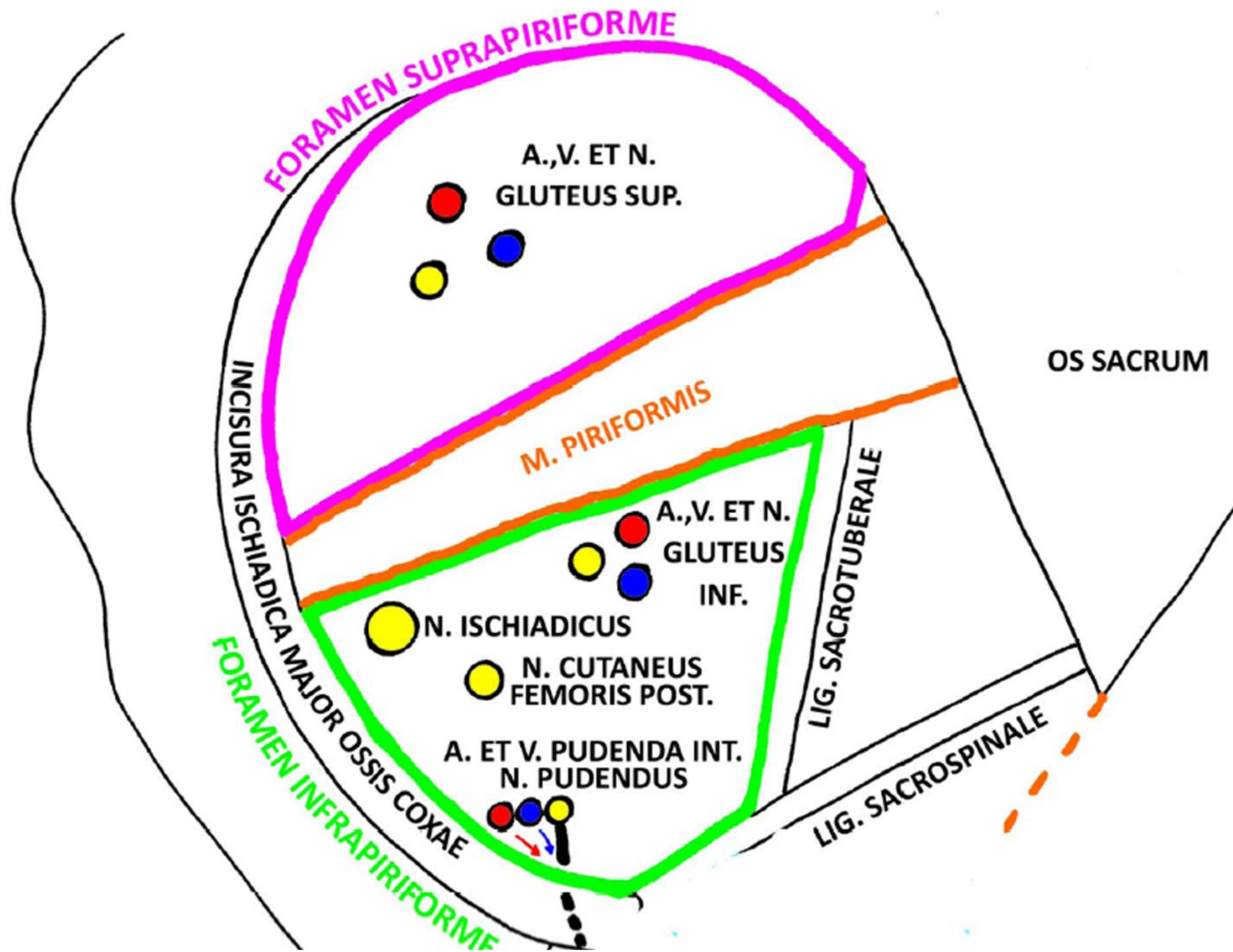




nn. clunium sup.
nn. clunium medii } rr. dors. nn. spinalium
nn. clunium inf. (z n. cutaneus fem. post.)

n. cutaneus femoris post.





foramen suprapiriforme

n. gluteus sup.

a. et v. glutea sup.

foramen infrapiriforme

n. gluteus inf.

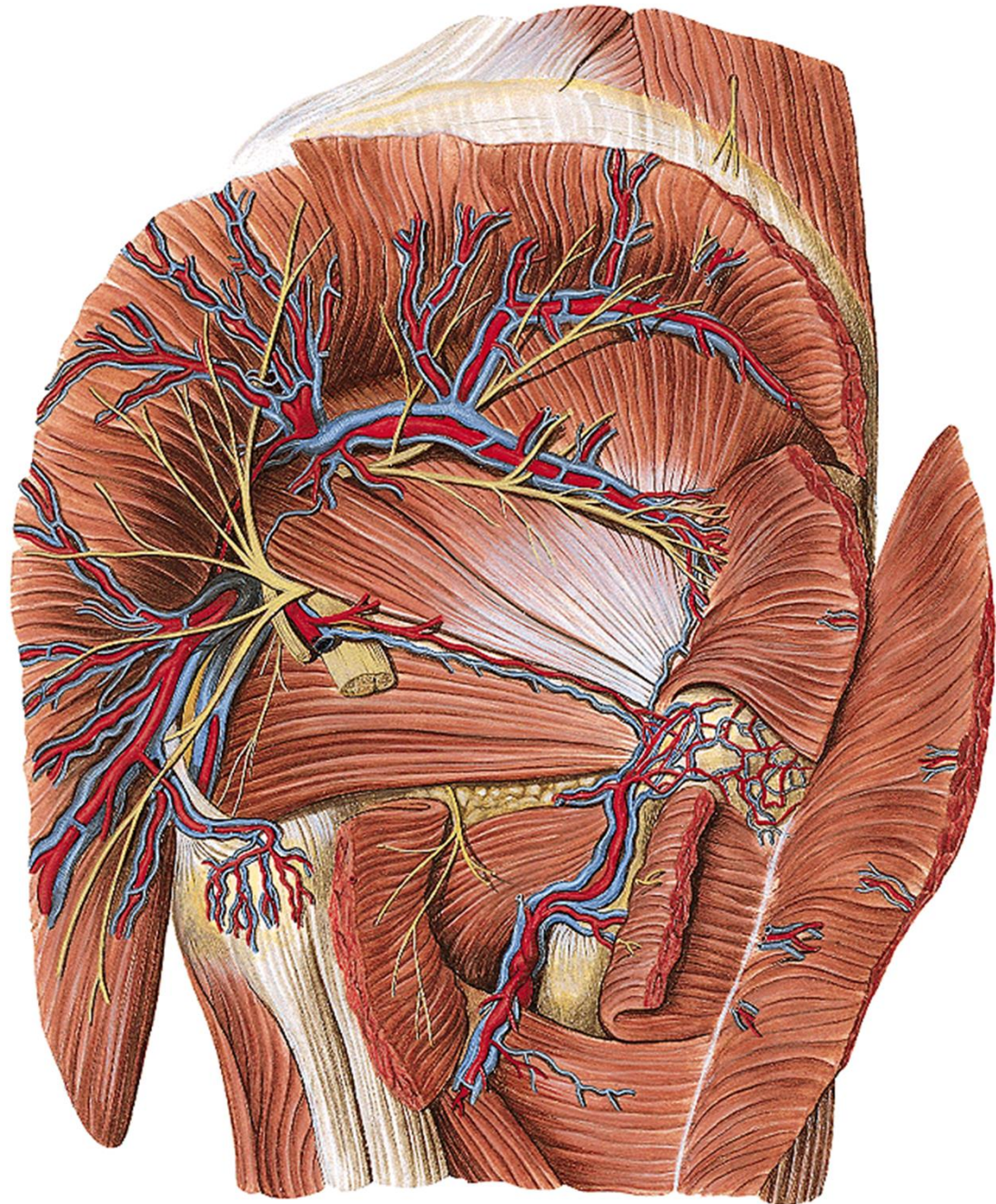
a. et v. glutea inf.

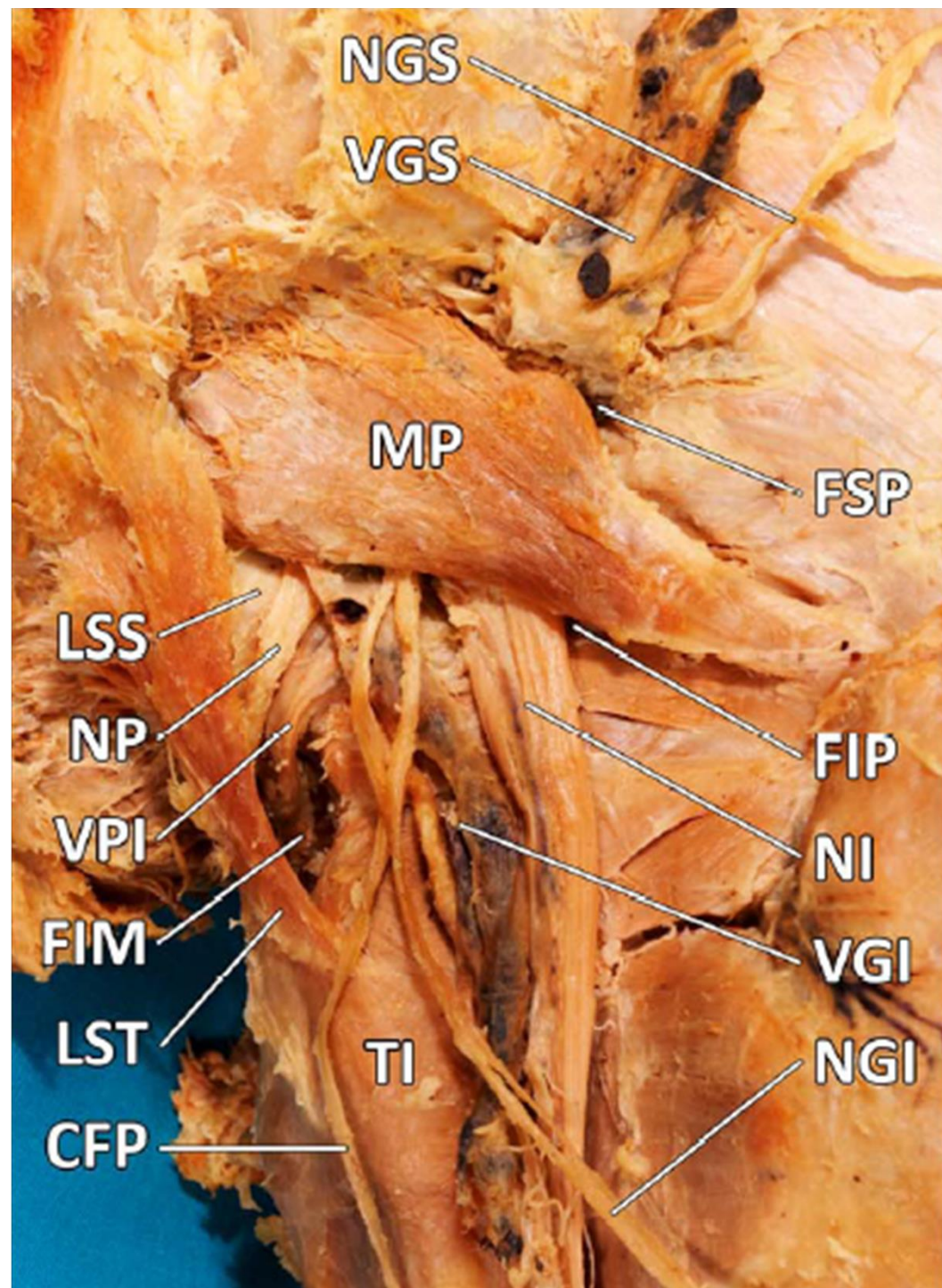
n. pudendus

a. et v. pudenda int.

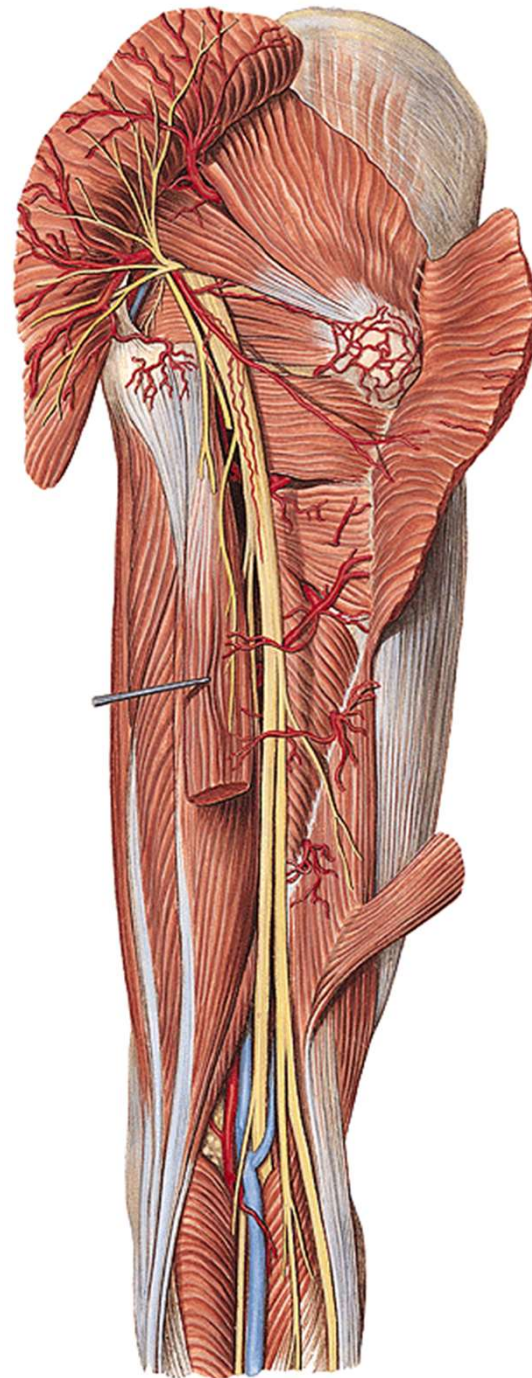
n. cut. femoris post.

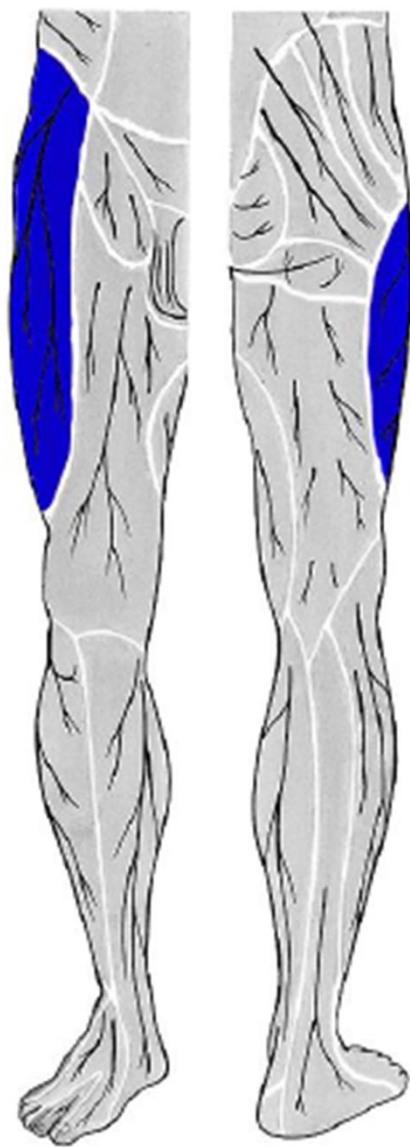
n. ischiadicus



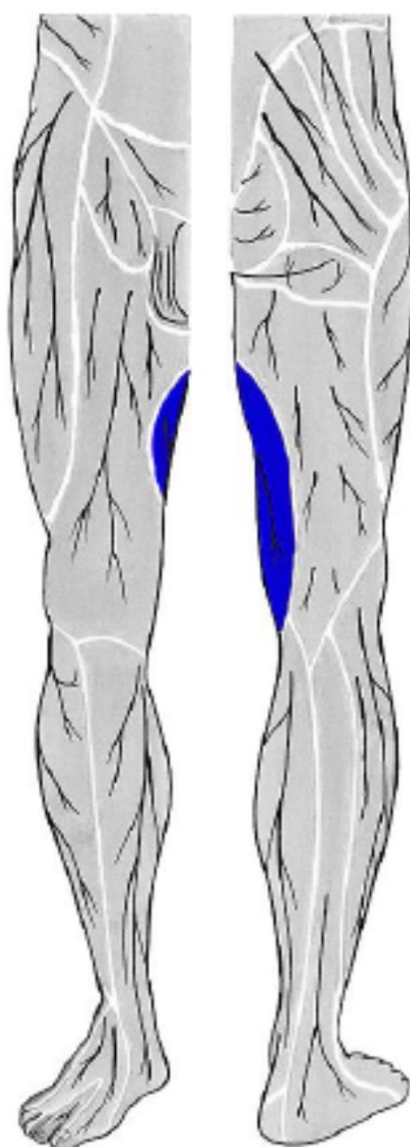


n. ischiadicus
rr. perforantes (z a. prof. femoris)

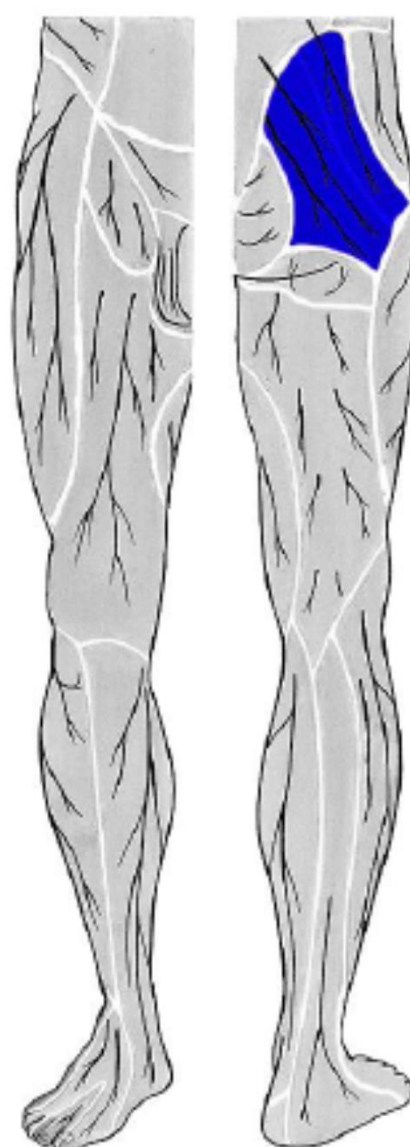




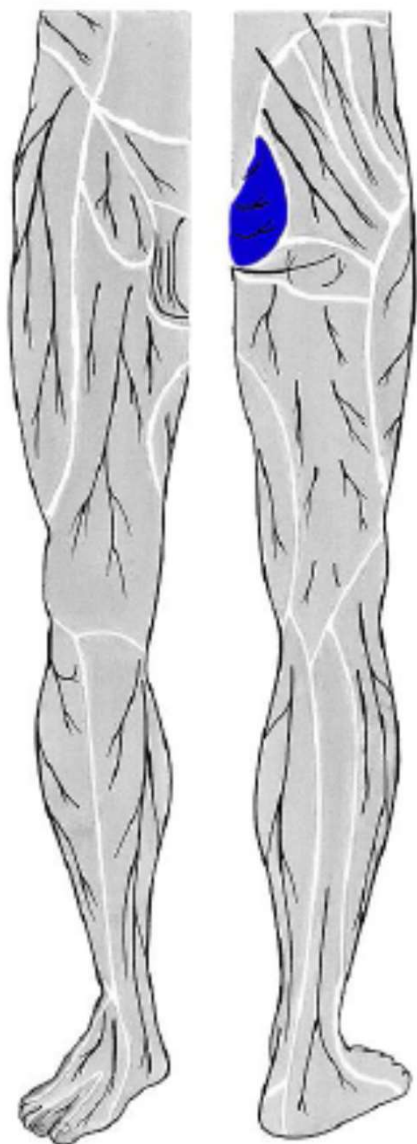
**n. cutaneus femoris
lateralis**



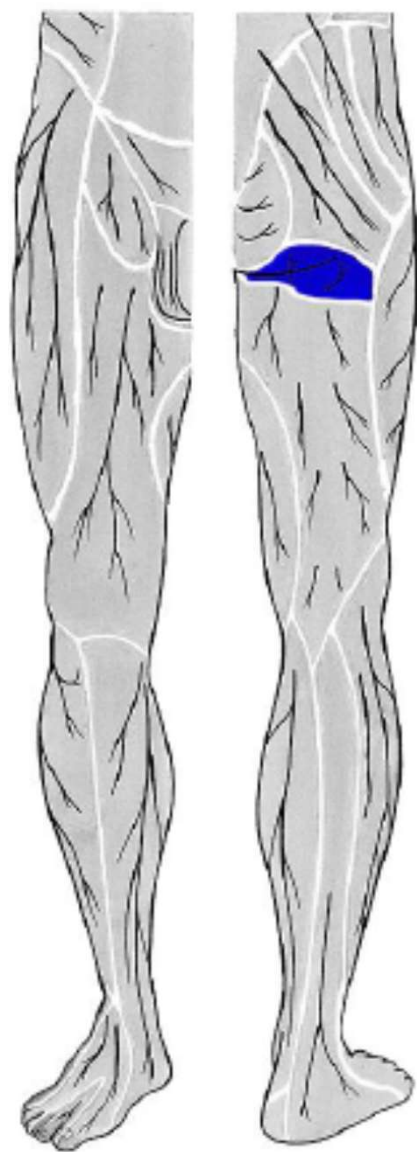
**r.cutaneus n. obturatorii
(z n. obturatorius)**



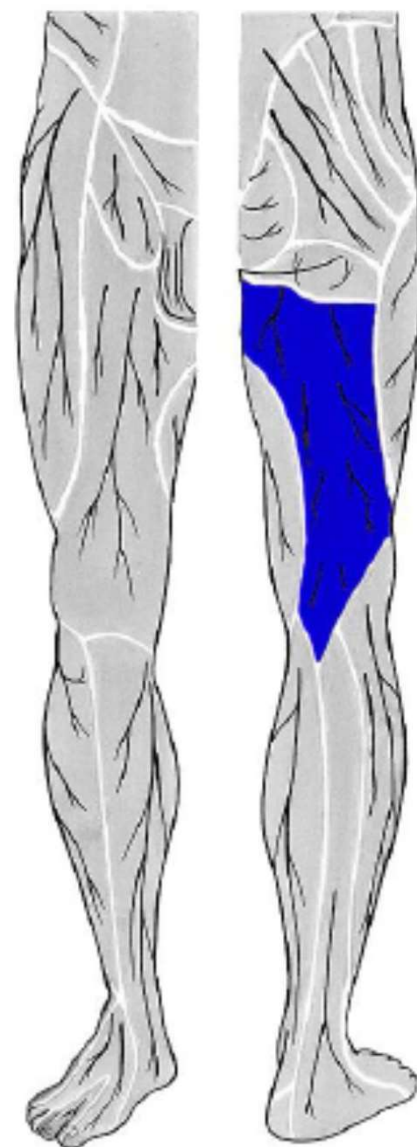
**nn. clunium sup.
(ze segmentů L1 - L3)**



nn. clunium medii
(ze segmentů S1 - S3)

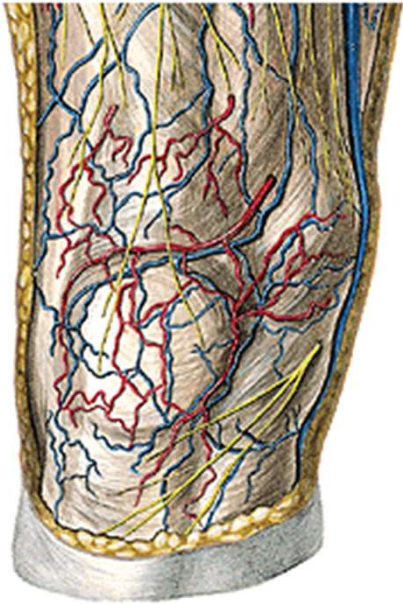


nn. clunium inf.
(z n. cutaneus femoris posterior)

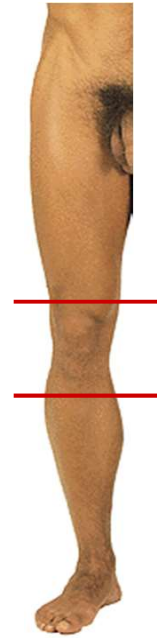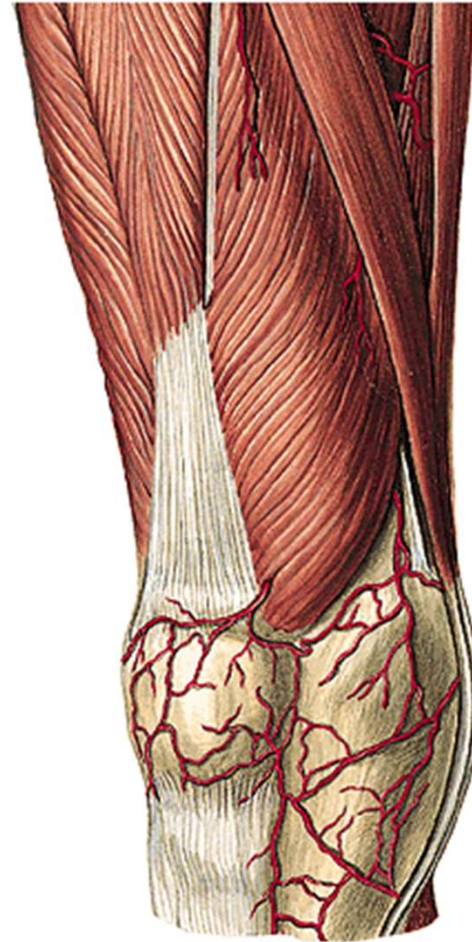


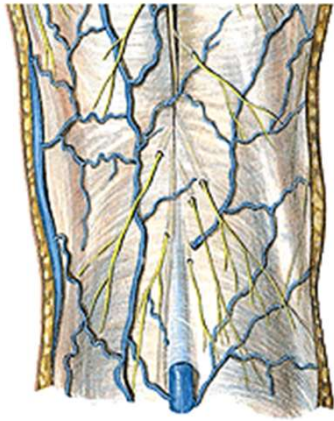n. cutaneus femoris posterior

r. genus

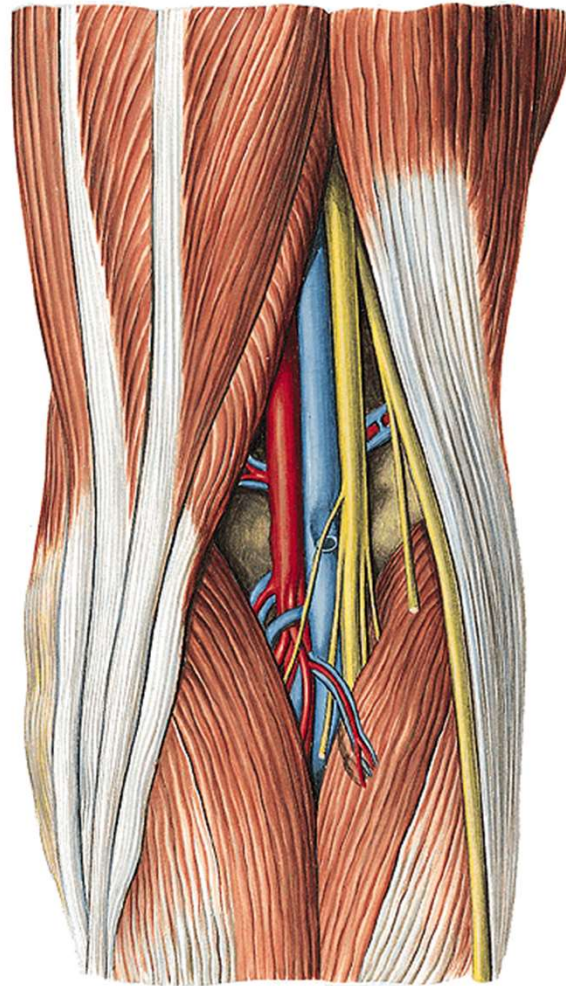


v. saphena magna
n. saphenus
rr. cut. ant. (z *n. femoralis*)

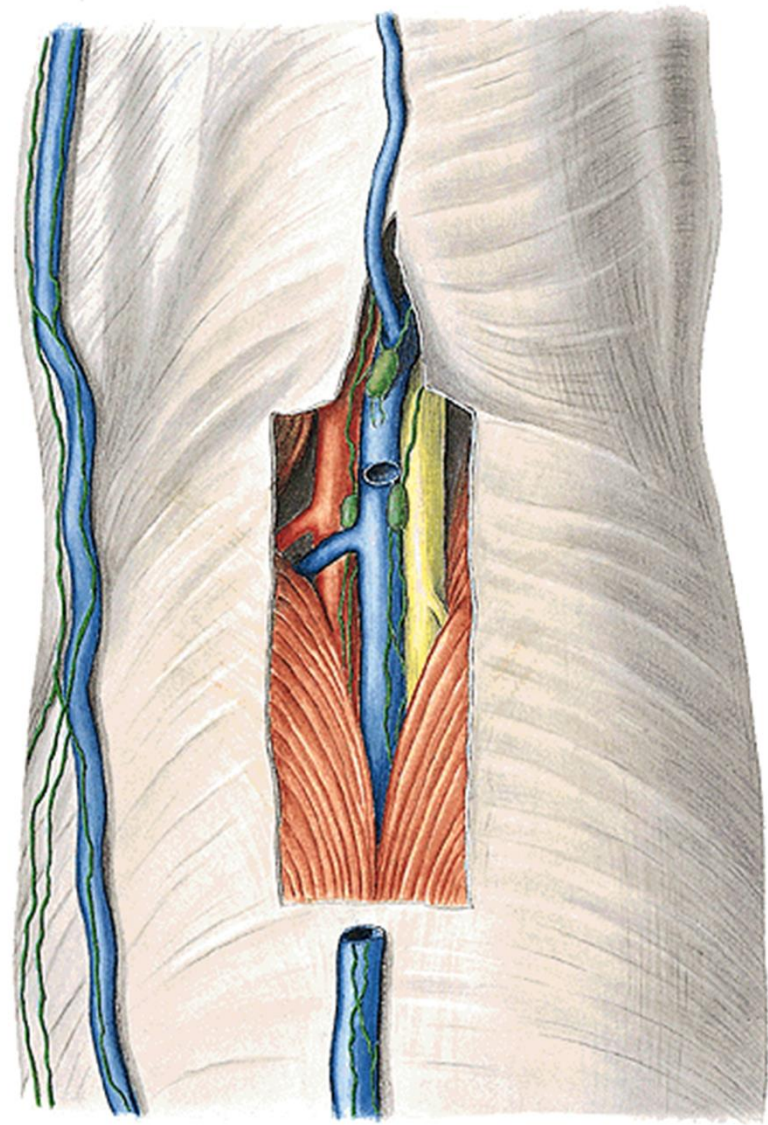


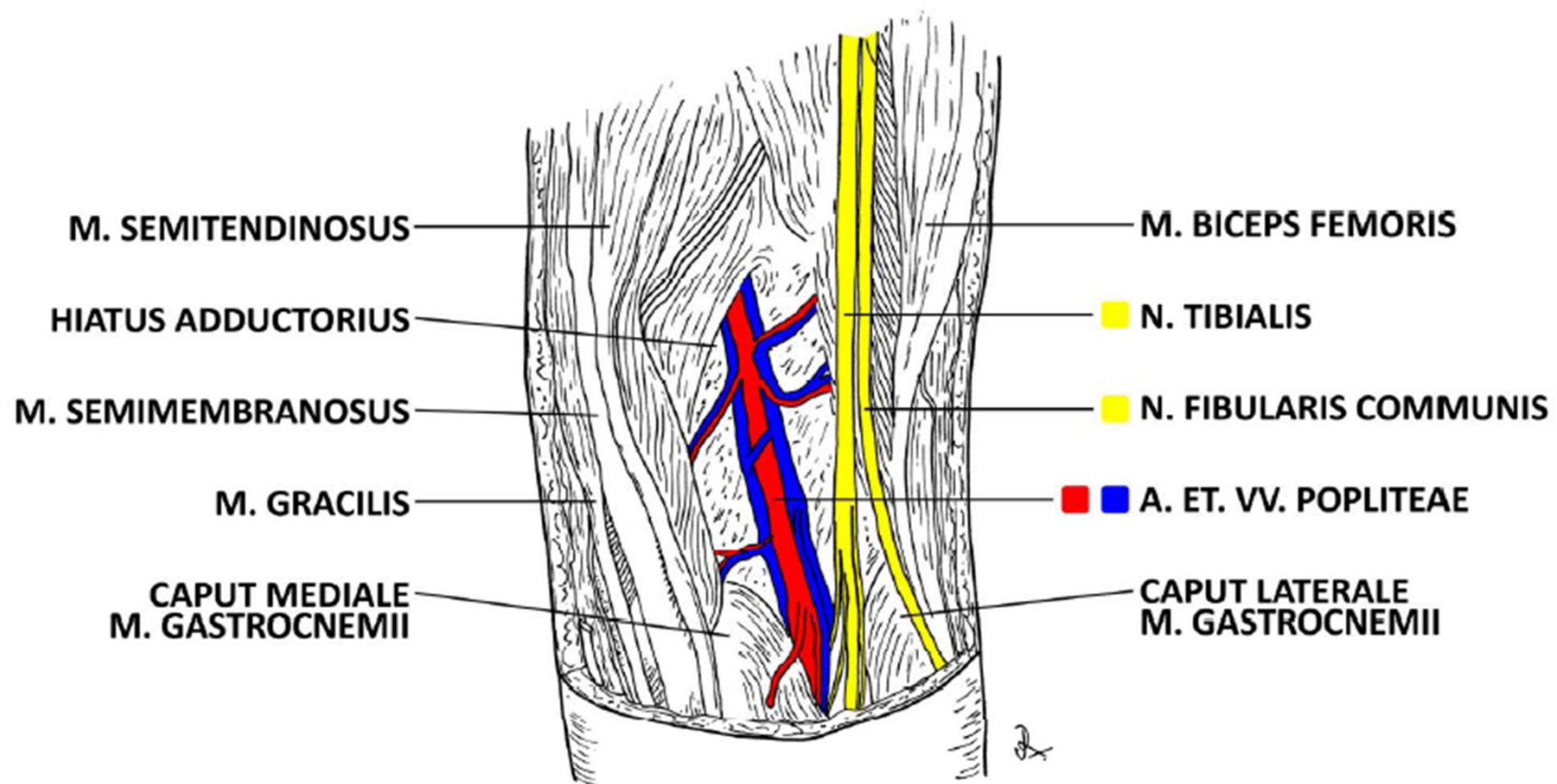


v. saphena parva
(ev. v. femoropoplitea)



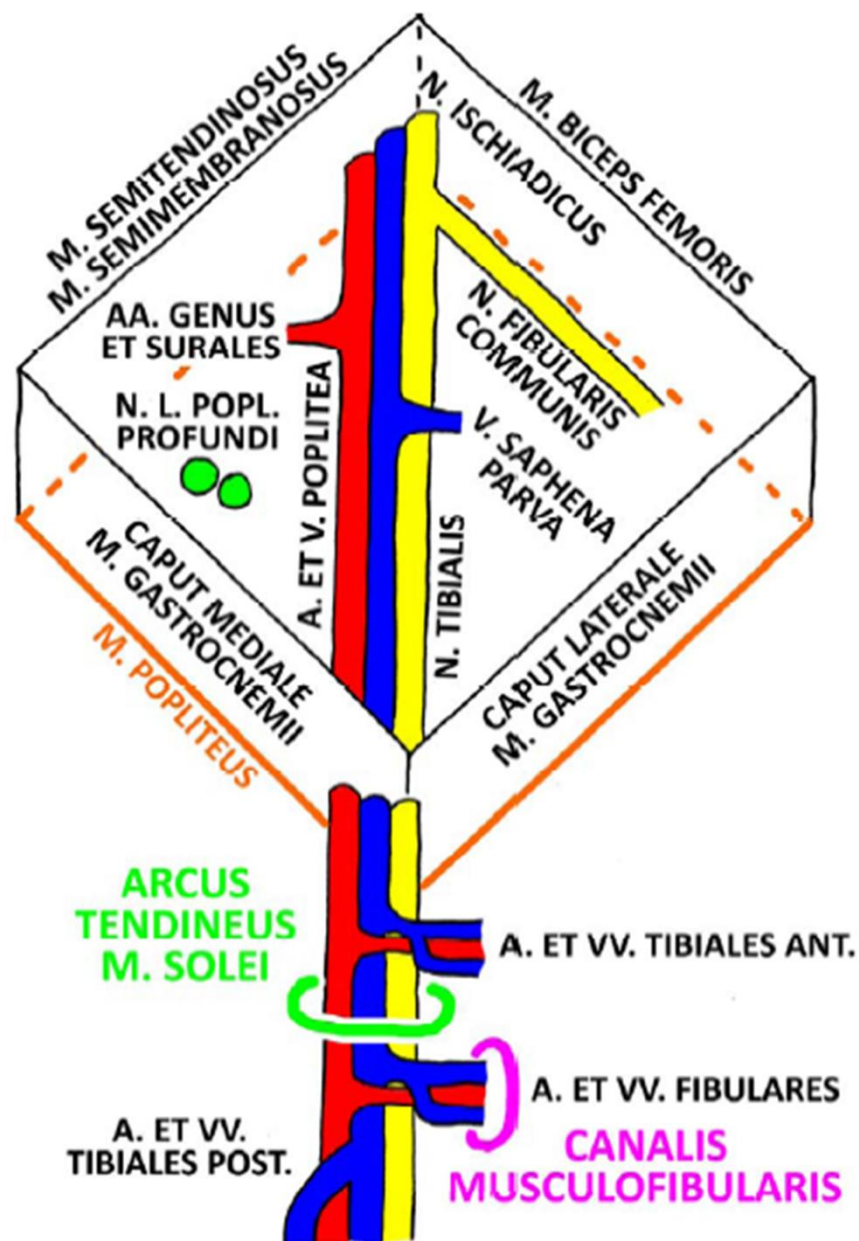
n. tibialis
n. peroneus comm.
a et v. poplitea
nll. poplitei

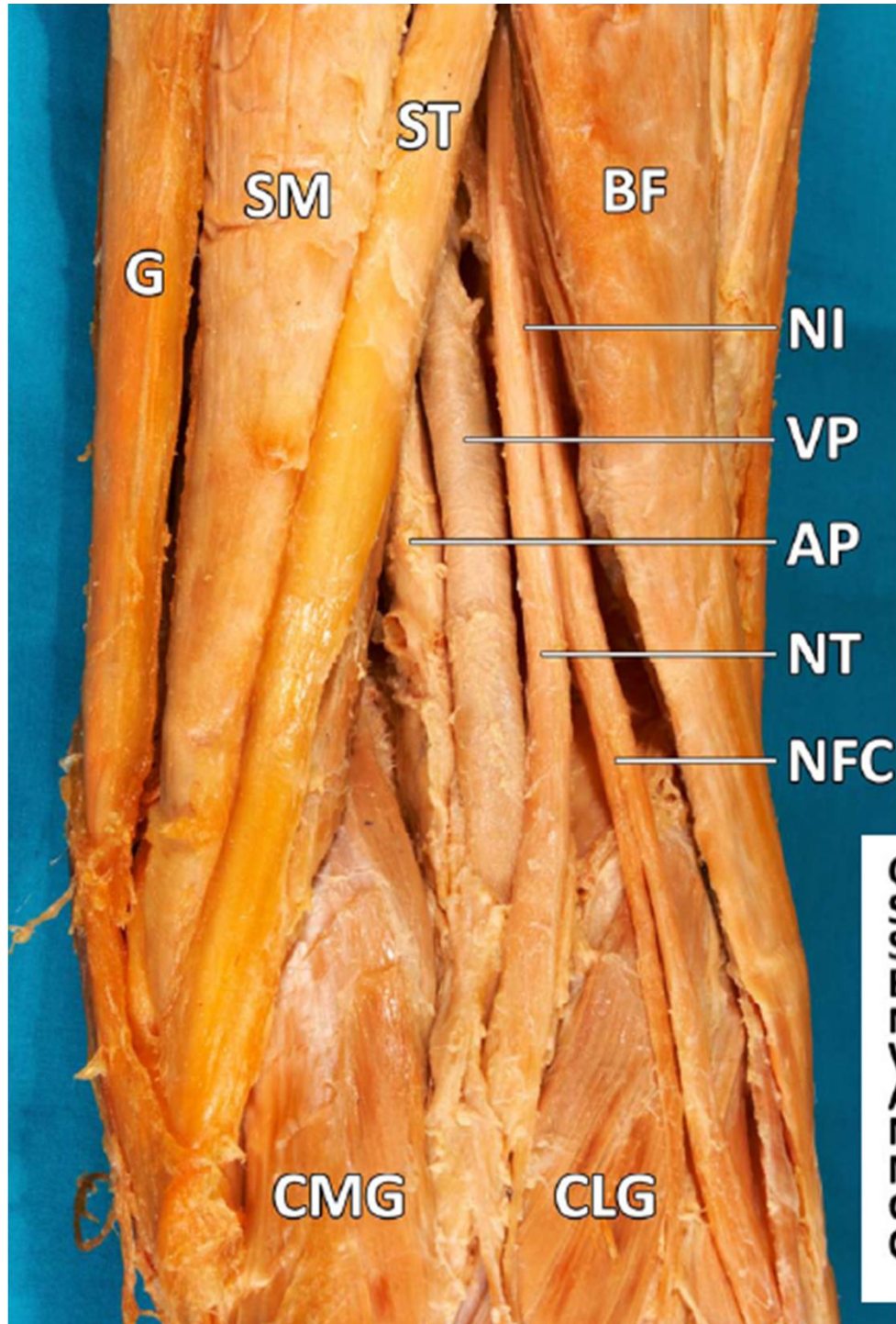




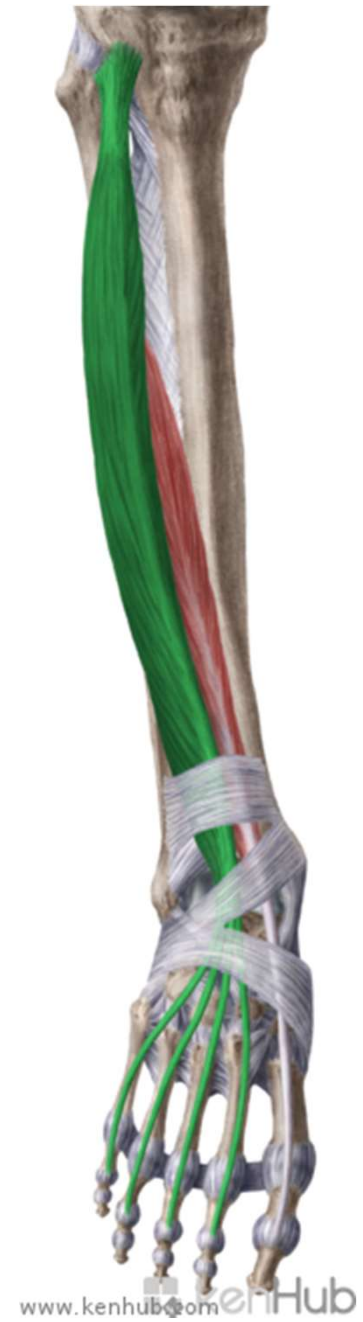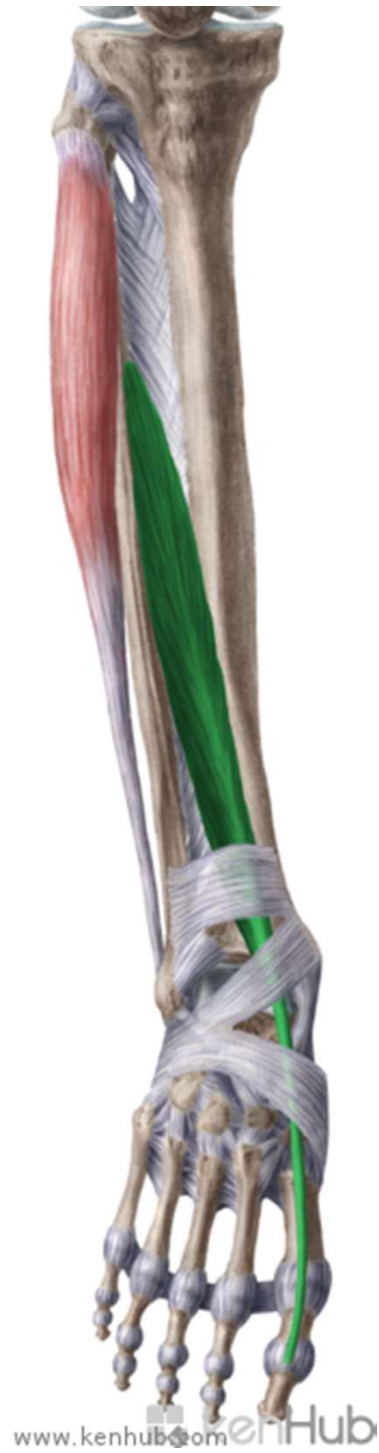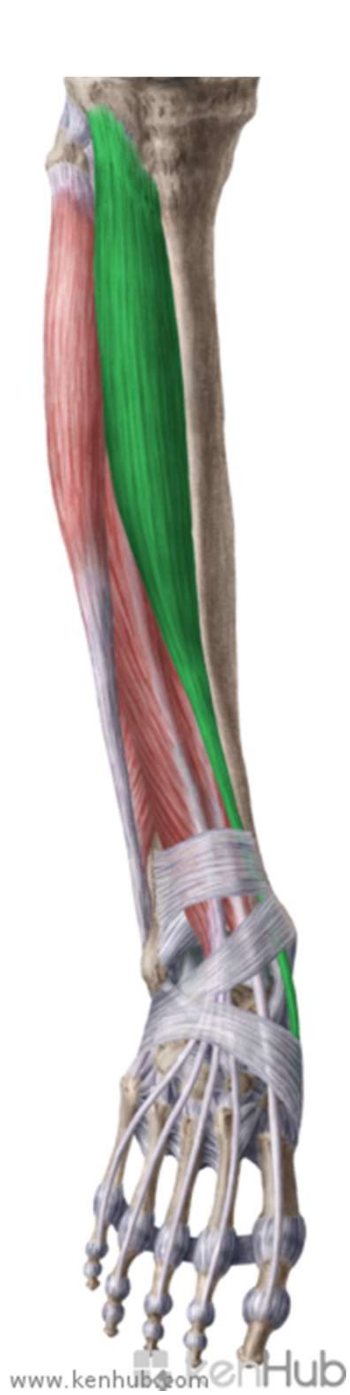FOSSA POPLITEA DX.

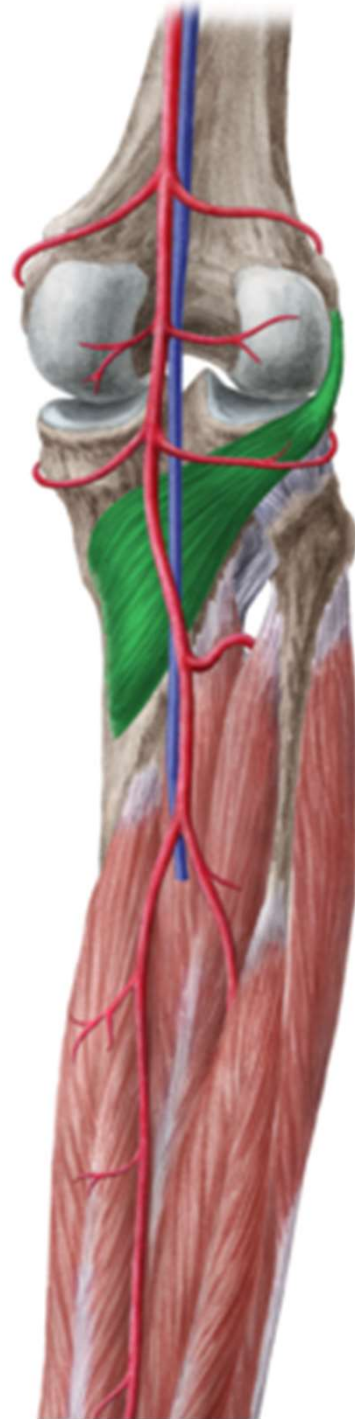
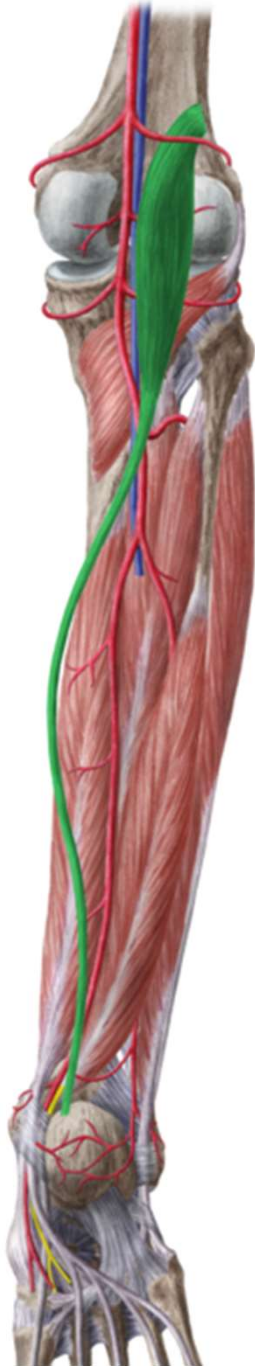
A V E N

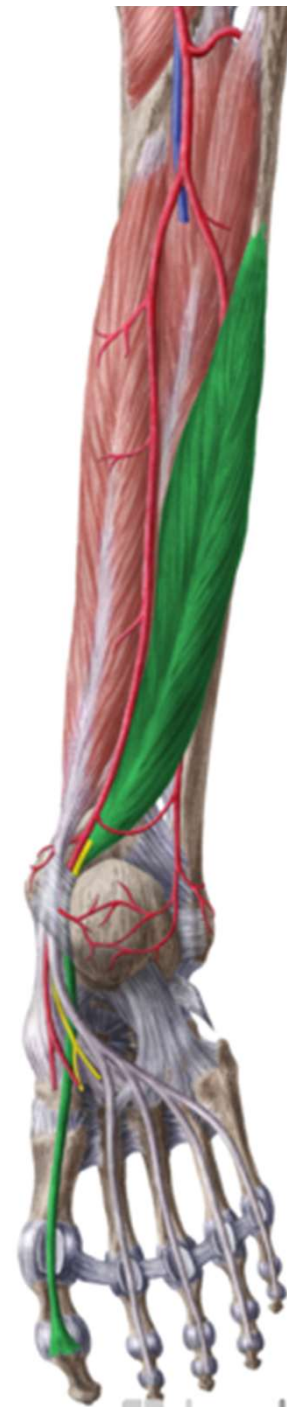
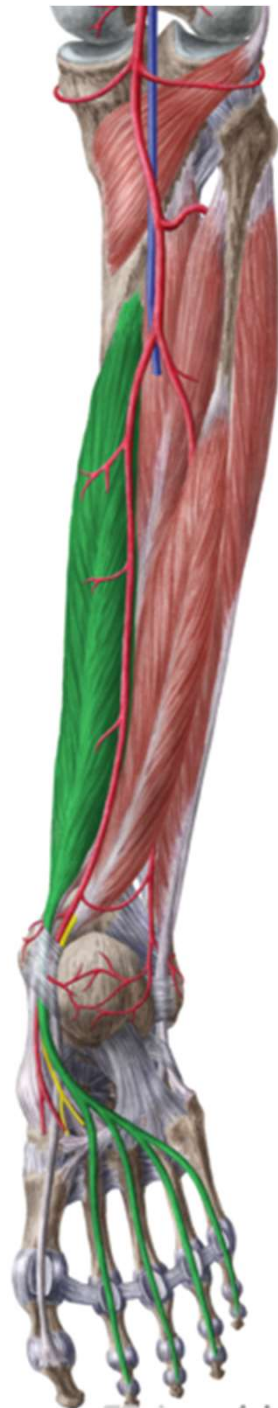


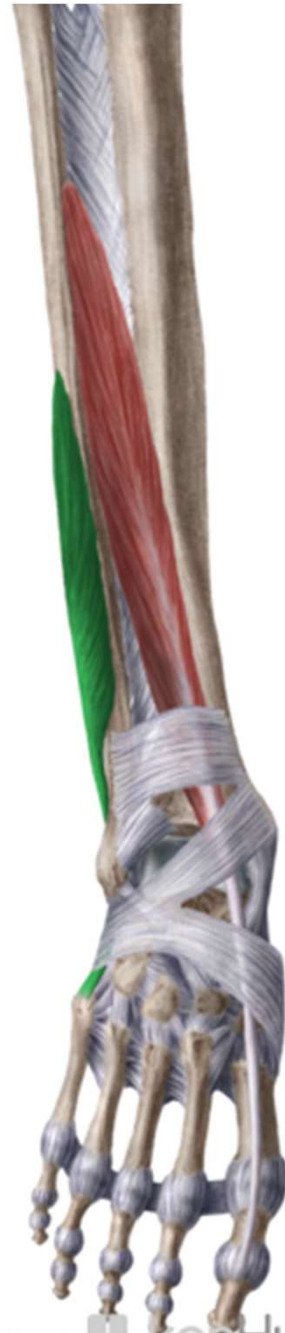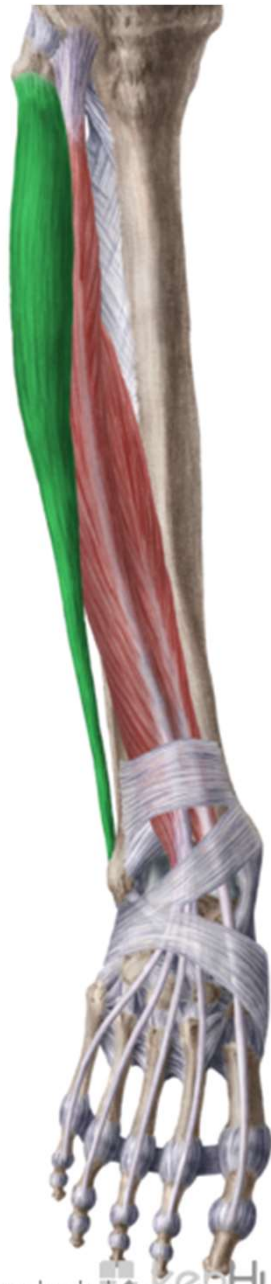r. cruris



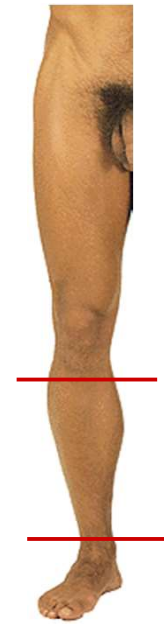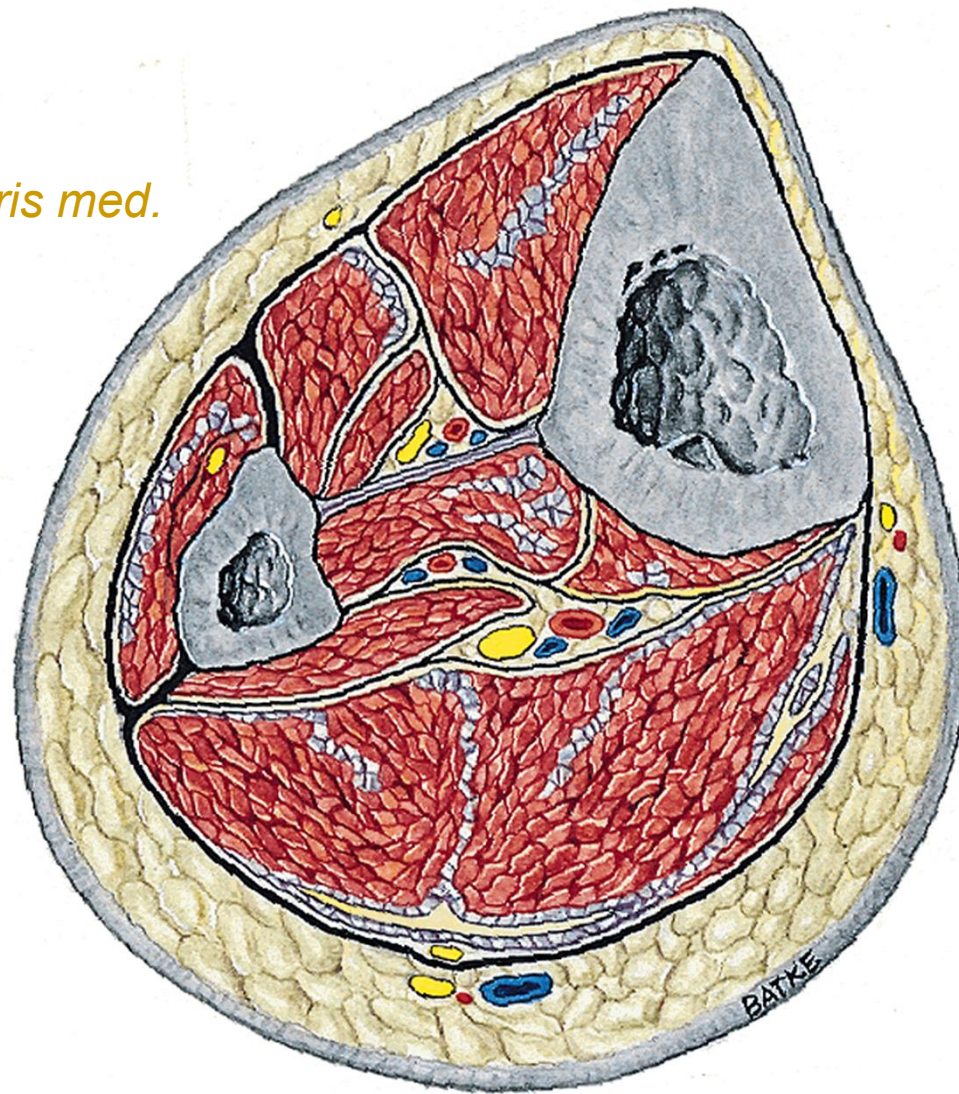


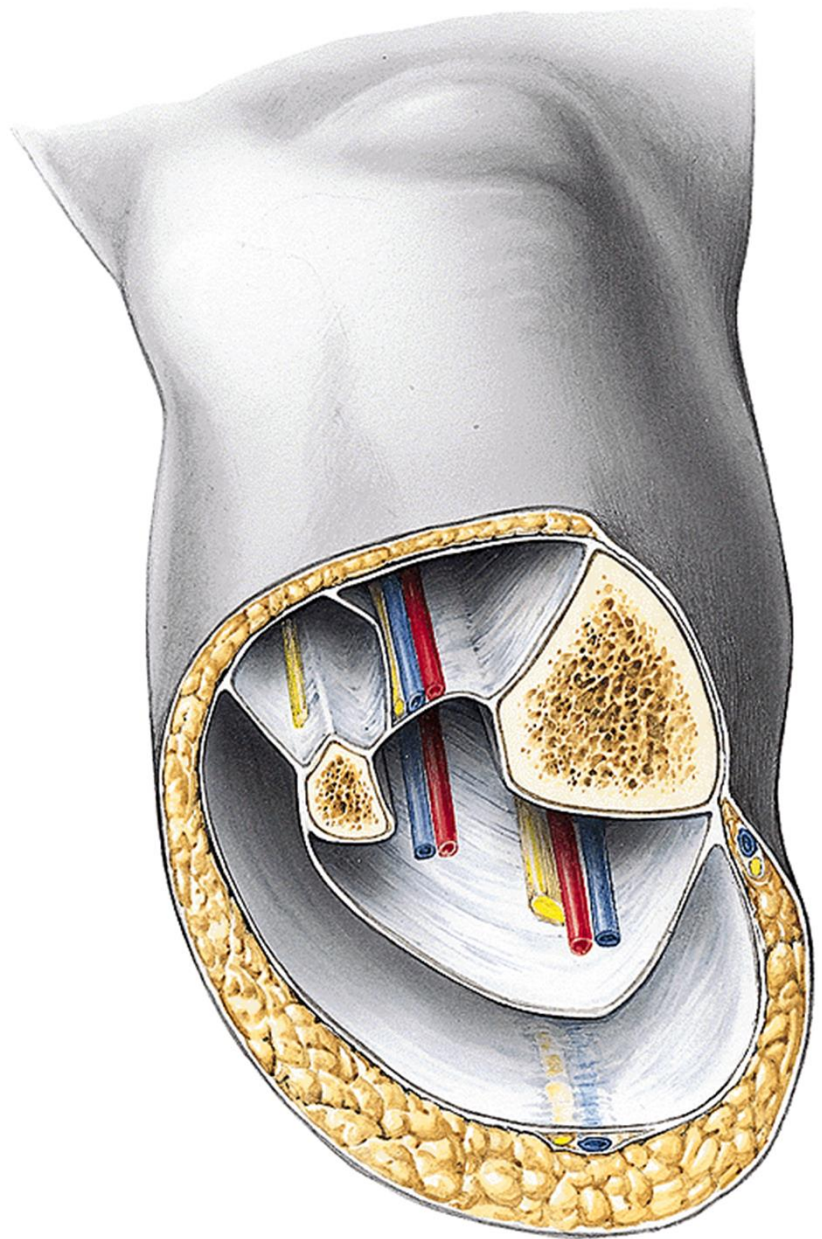




v. saphena magna
n. saphenus → *rr. cut. cruris med.*
v. saphena parva
n. suralis
n. cut. surae lat.
n. cut. surae med.

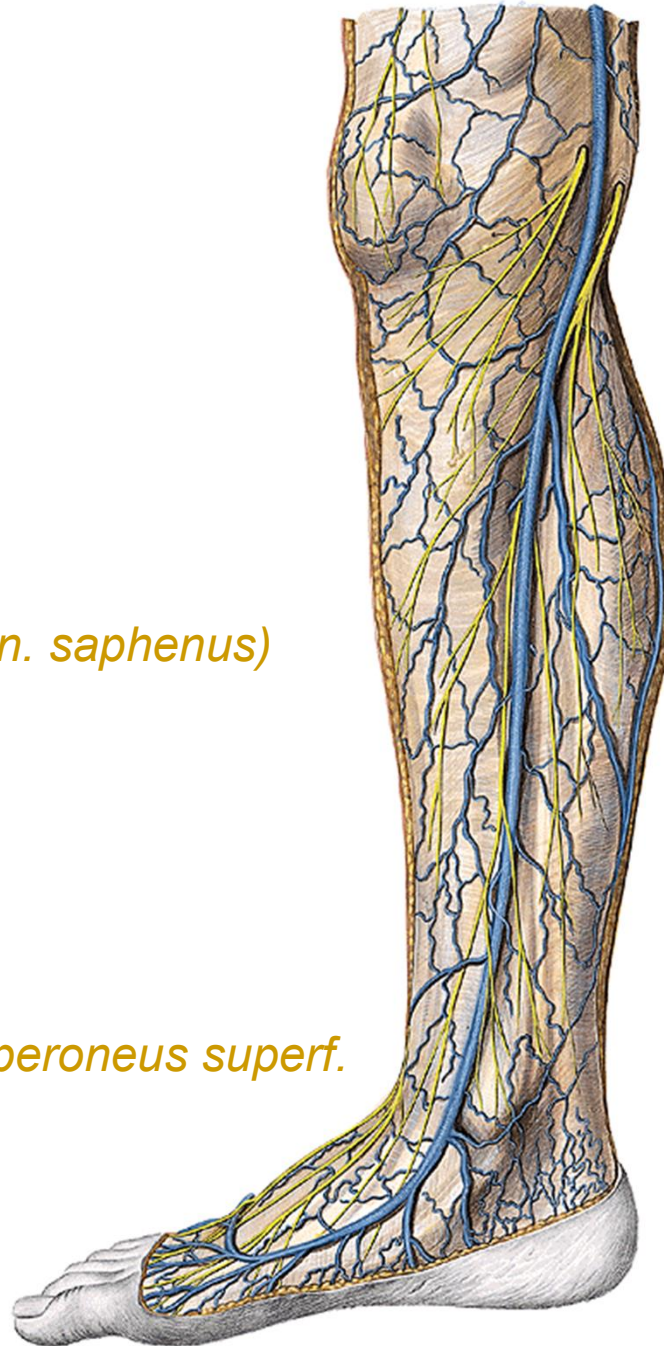n. peroneus superf.
n. peroneus prof.
a. et v. tibialis ant.
n. tibialis
a. et v. tibialis post.



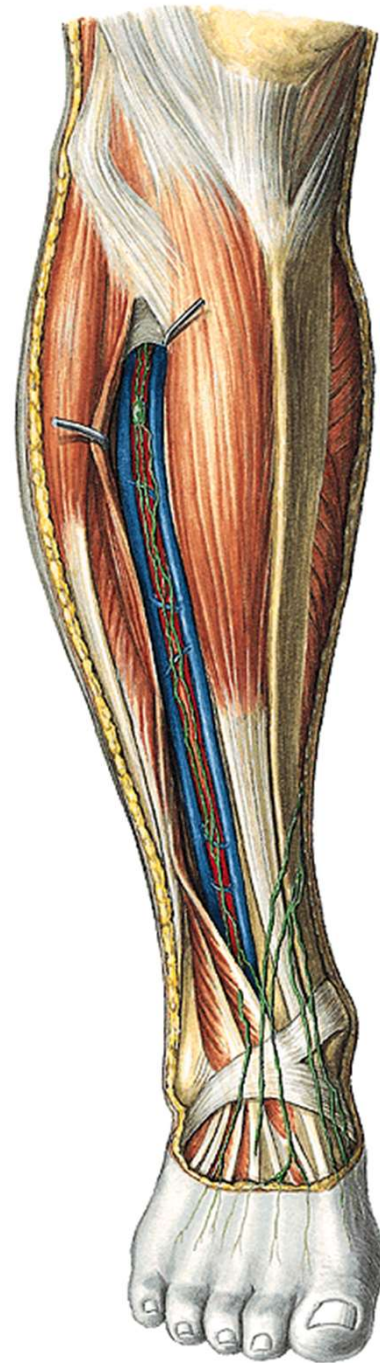


v. saphena magna
rr. cut. cruris med (z n. saphenus)

n. peroneus superf.



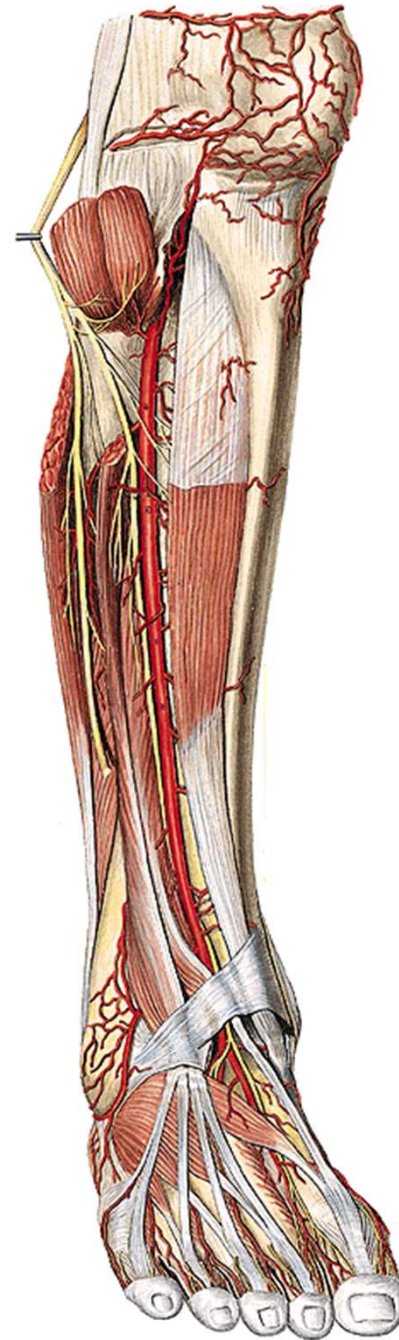
n. peroneus prof.
a. et v. tibialis ant.



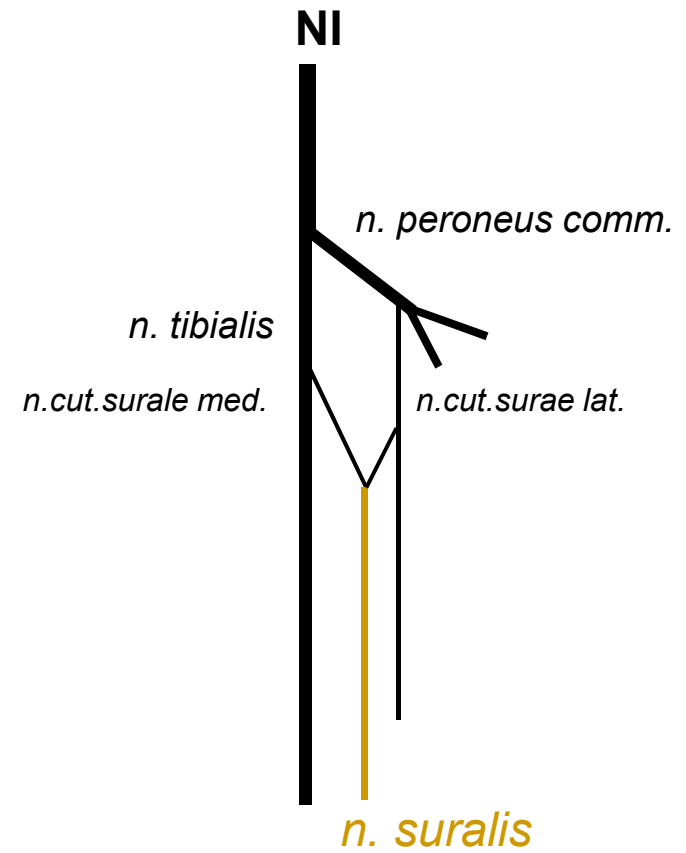
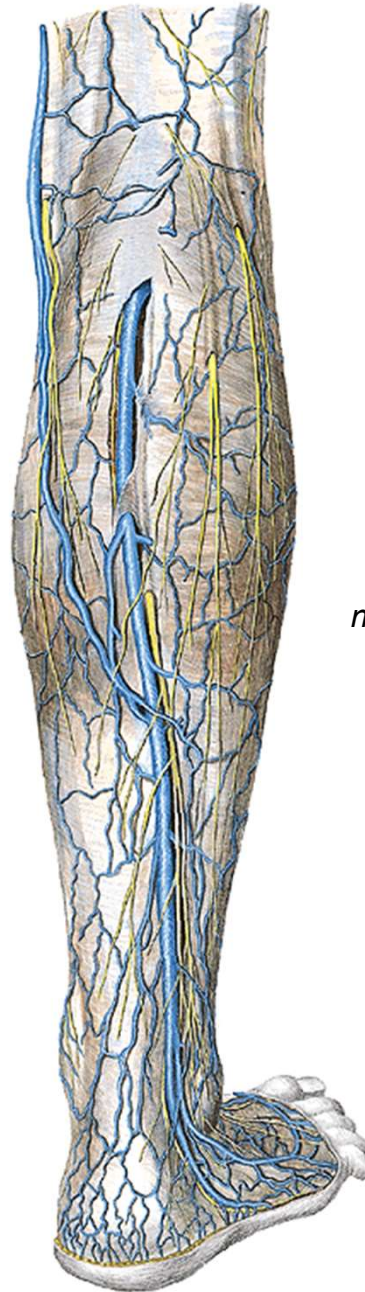
n. peroneus comm.:

n. peroneus prof.

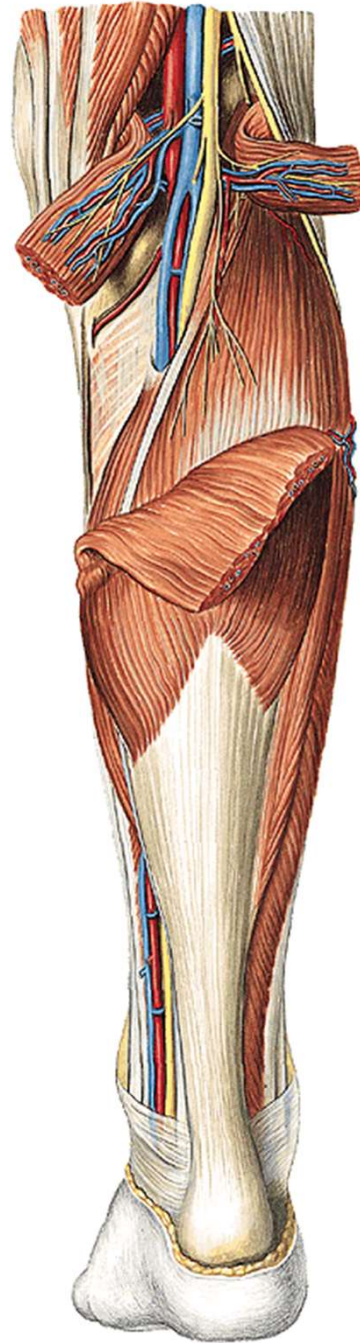
n. peroneus superf.

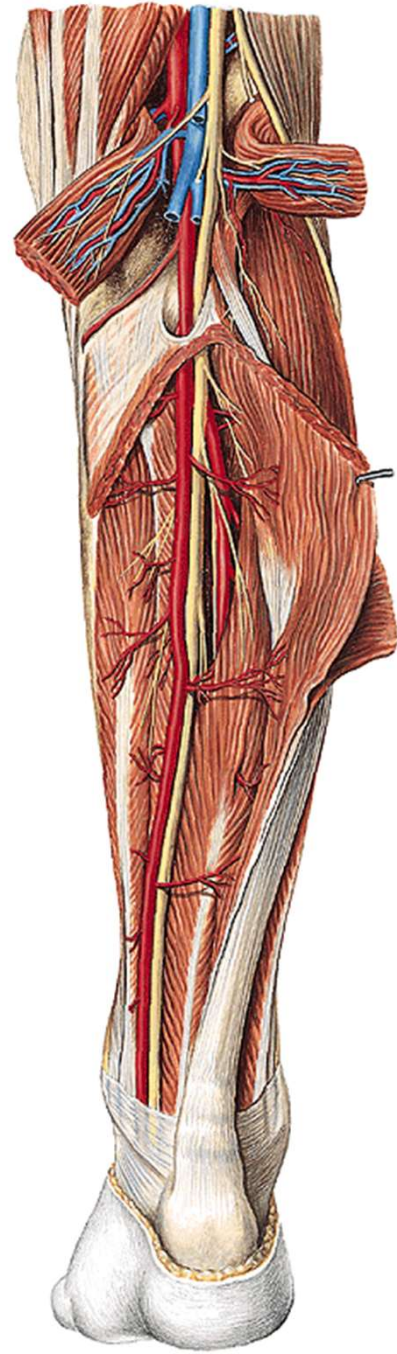


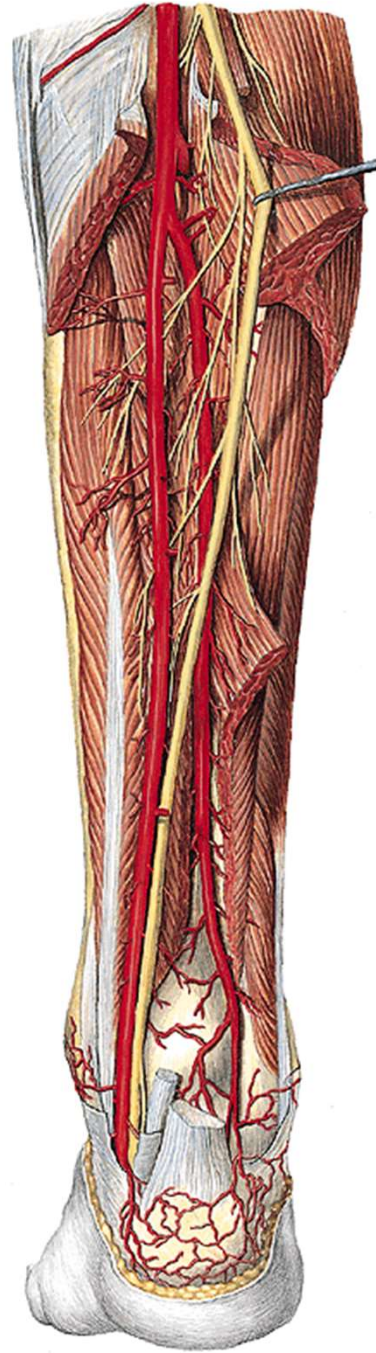v. saphena parva
n. cutaneus surae med.
+ *n. cutaneus surae lat.* =
n. suralis

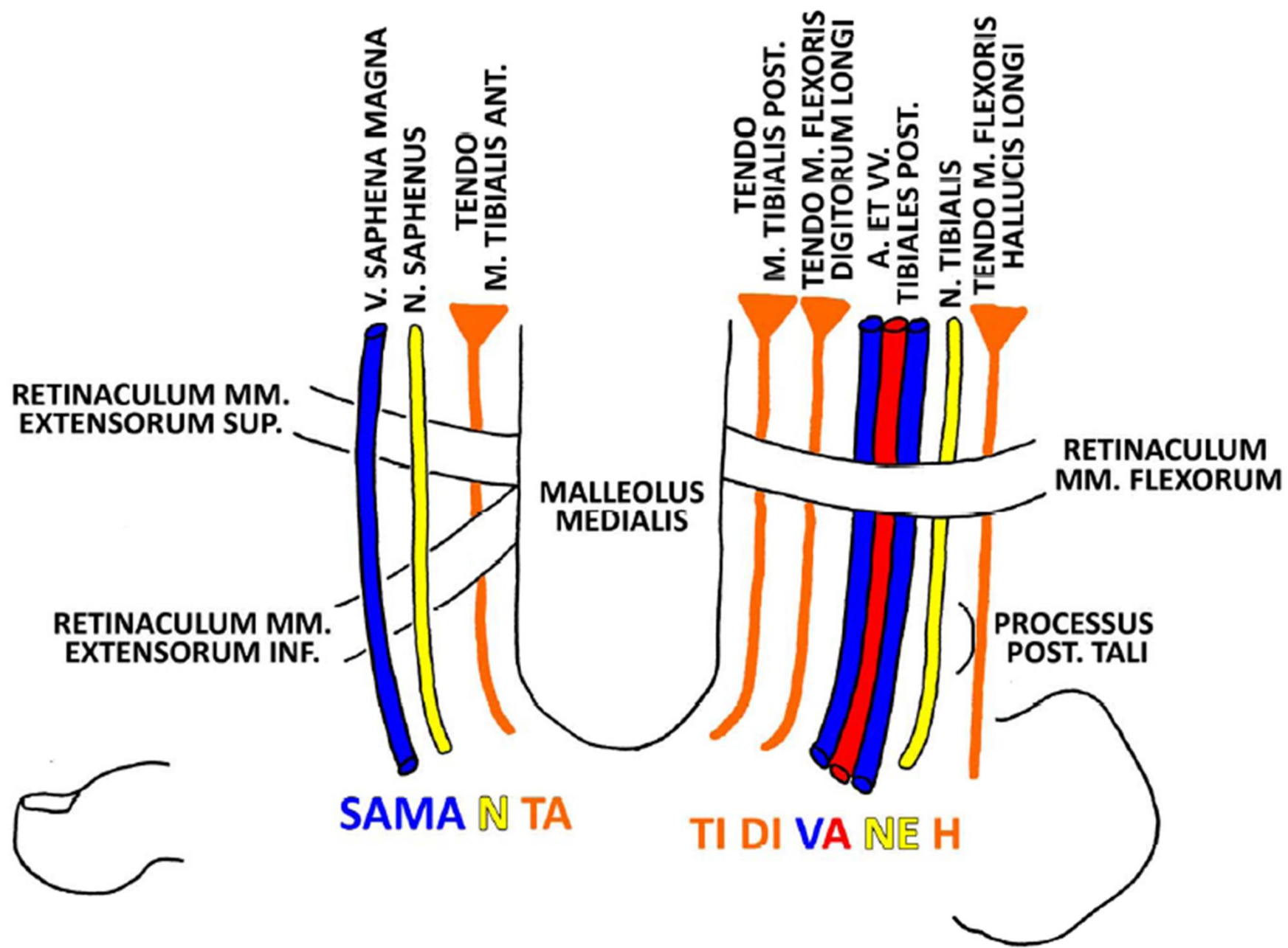


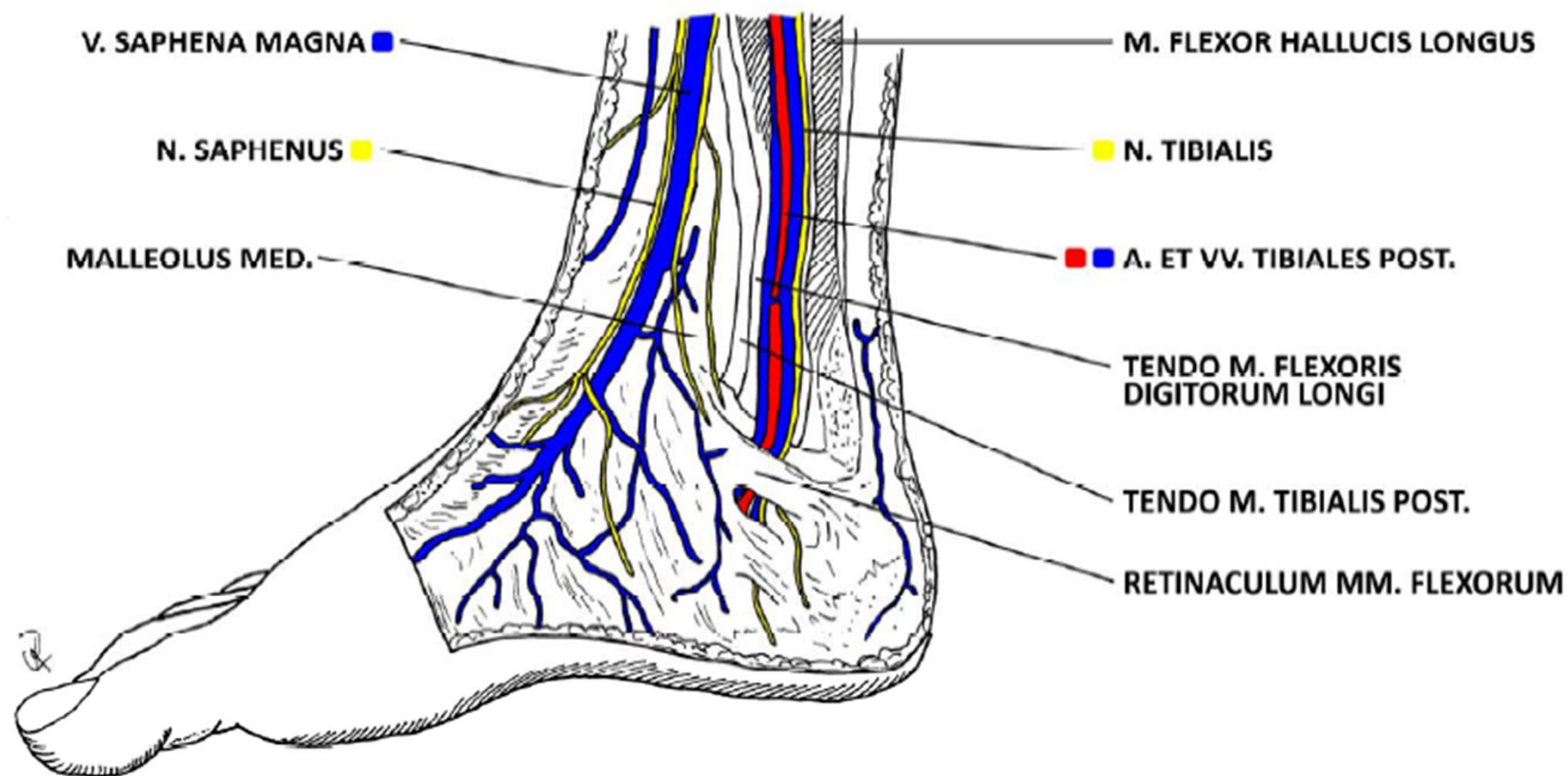
n. tibialis
a. et v. tibialis post.



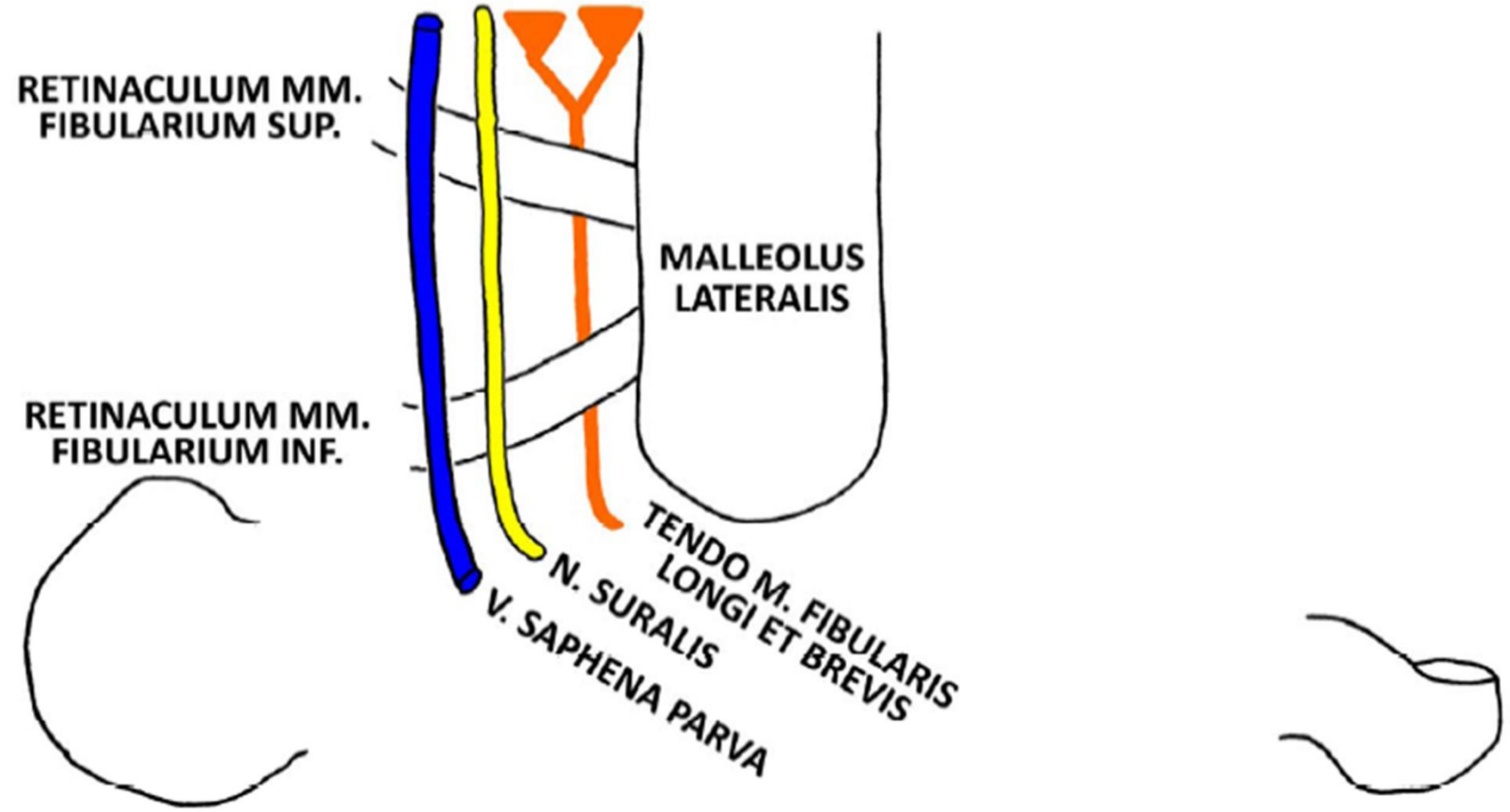


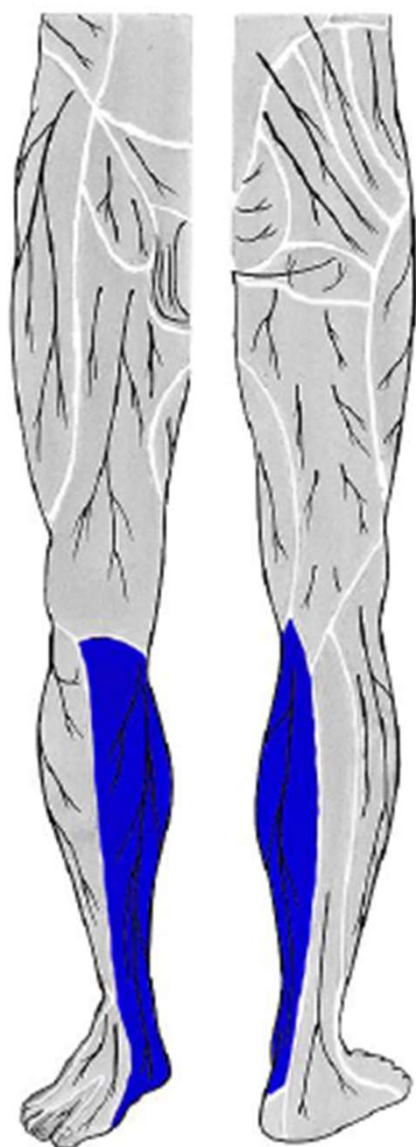




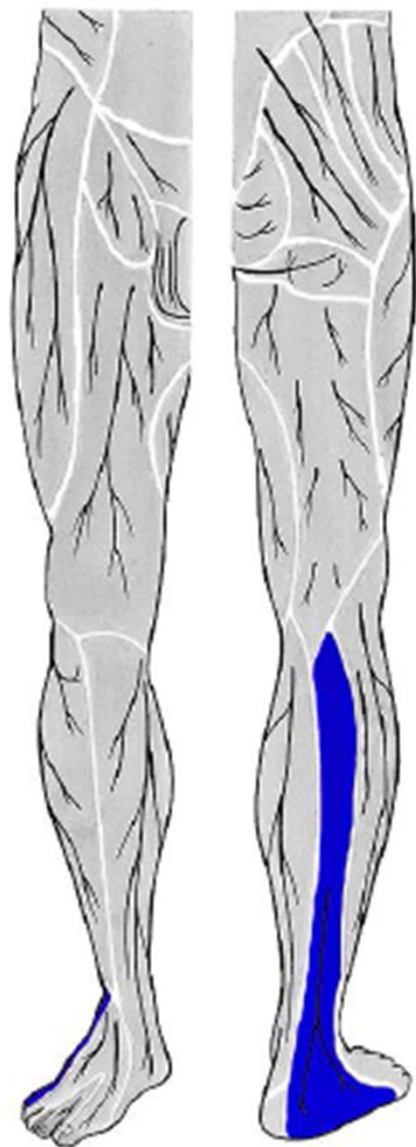


SAPA SU FI

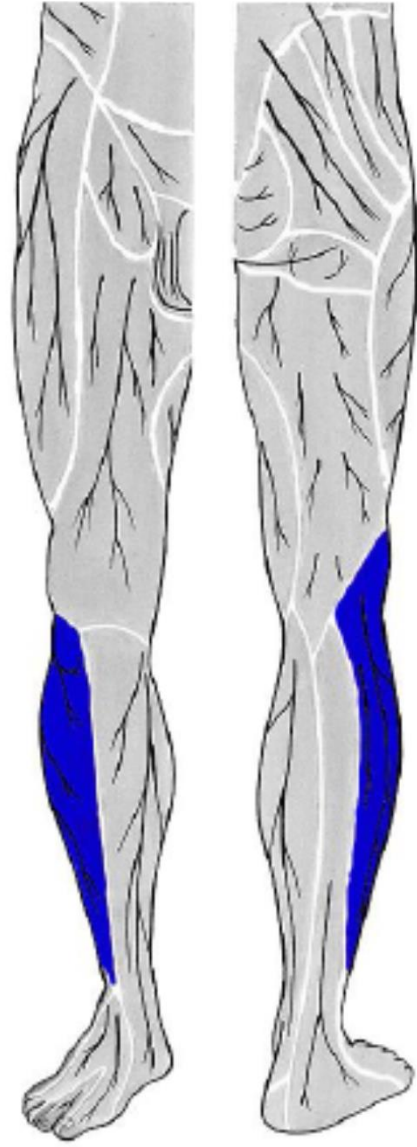




n. saphenus
(z *n. femoralis*)

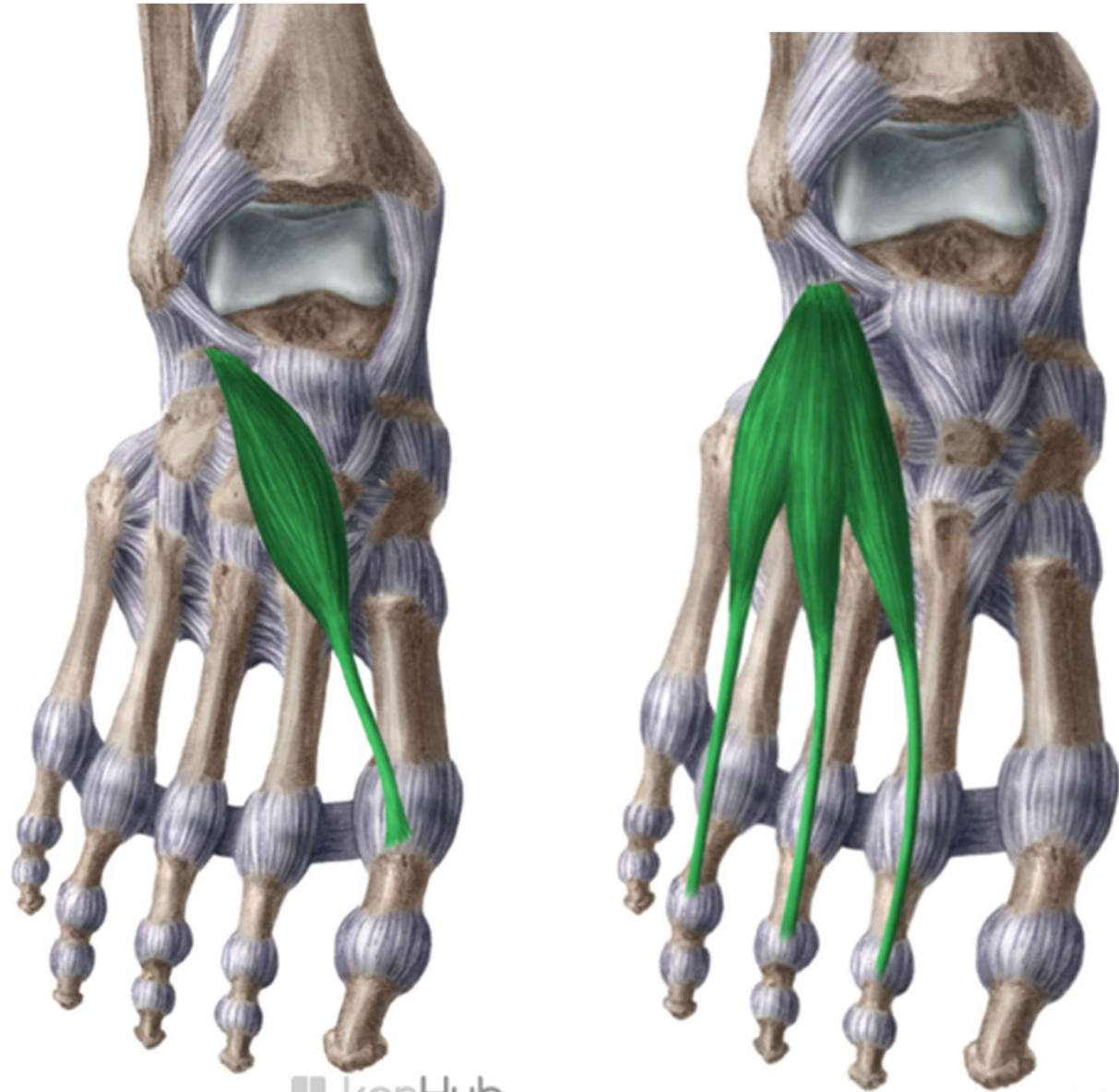


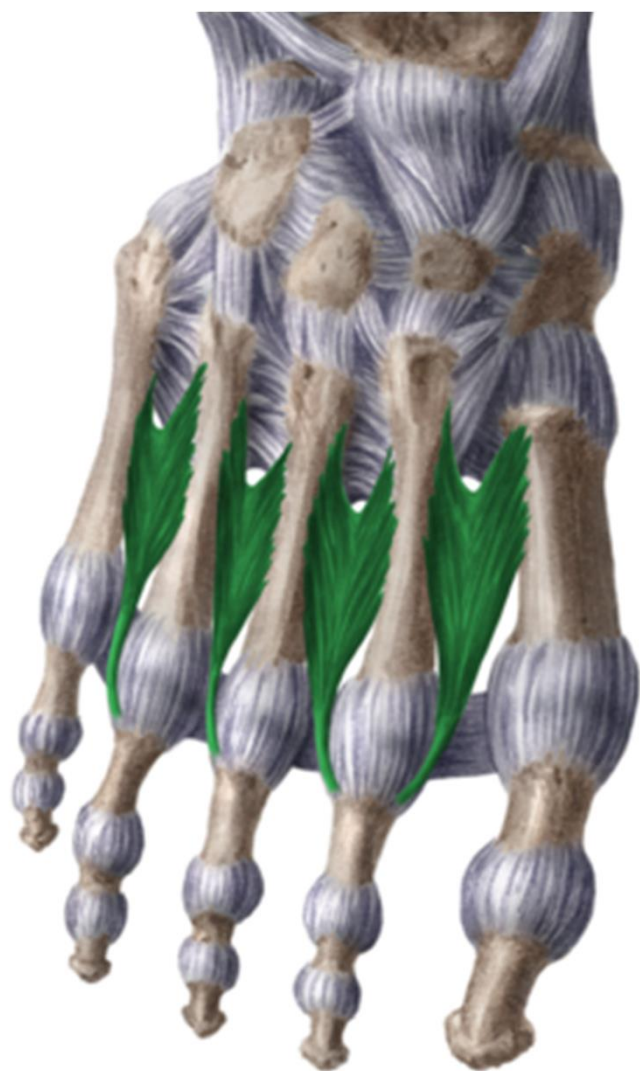n. suralis
(z *n. fibularis communis*
a *n. tibialis*)



n. cutaneus surae lat.
(z *n. fibularis communis*)

dorsum pedis





www.kenhub.com

 kenHub

dorsum pedis

rete venosum dorsale pedis

n. cut. dorsalis med.
n. cut. dors. intermed. } *z n. peroneus superf.*

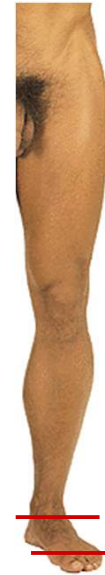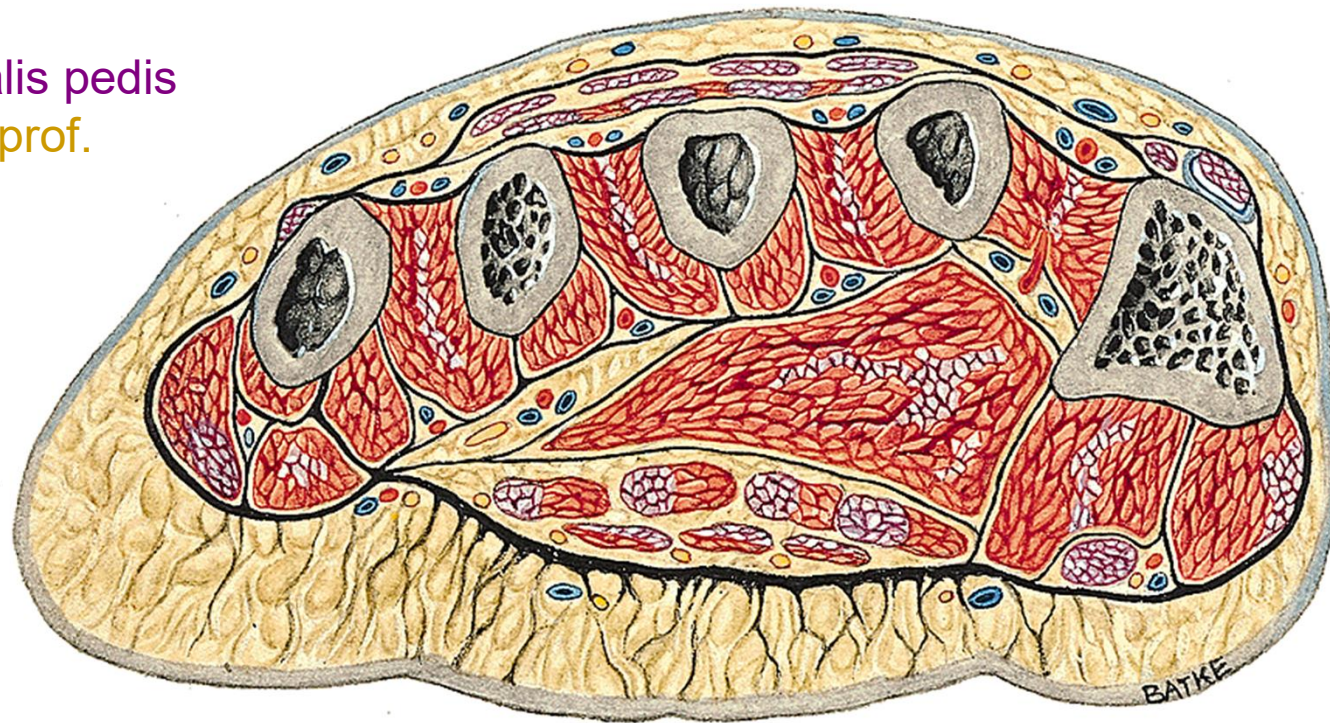n. cut. dors. lat. (z n. suralis)

nn. dig. dors. (z n. peroneus prof.)

fascia dorsalis – retinaculum extensorum

a. et v. dorsalis pedis

n. peroneus prof.



*levá končetina, řez přes metatarsus
pohled zdola*

rete venosum dorsale pedis

v. saphena magna

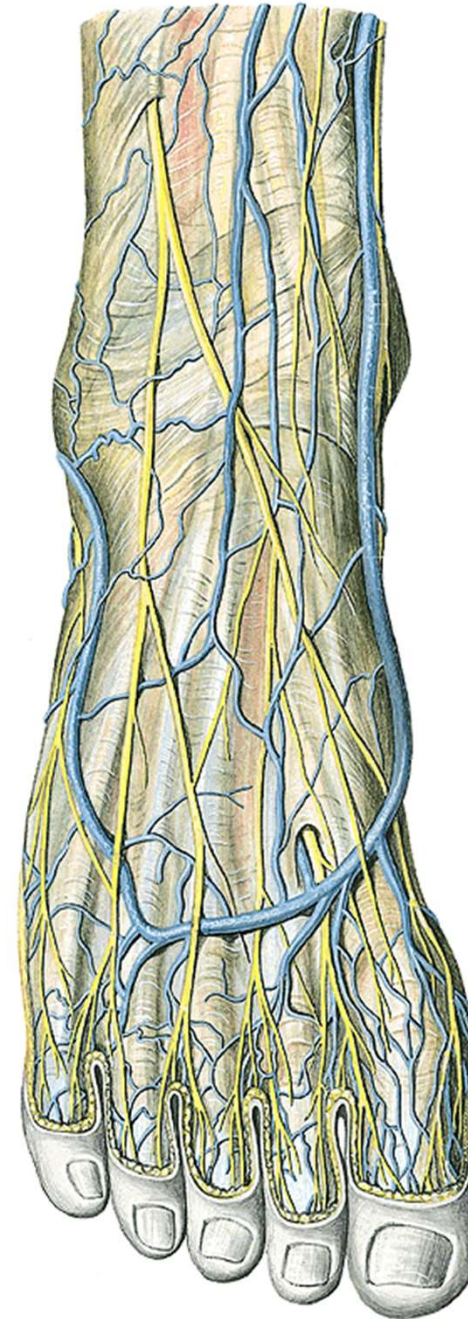
v. saphena parva

n. cut. dorsalis med.

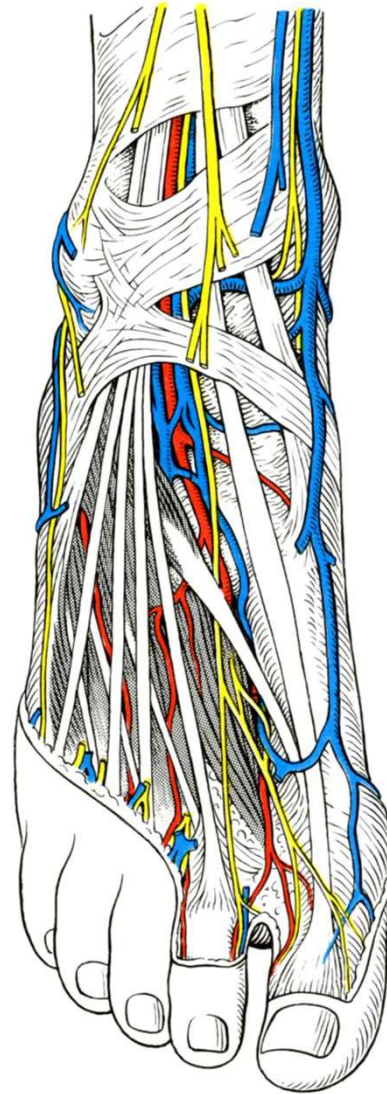
n. cut. dors. intermed. } (*z n. peroneus superf.*)

n. cut. dors. lat. (z n. suralis)

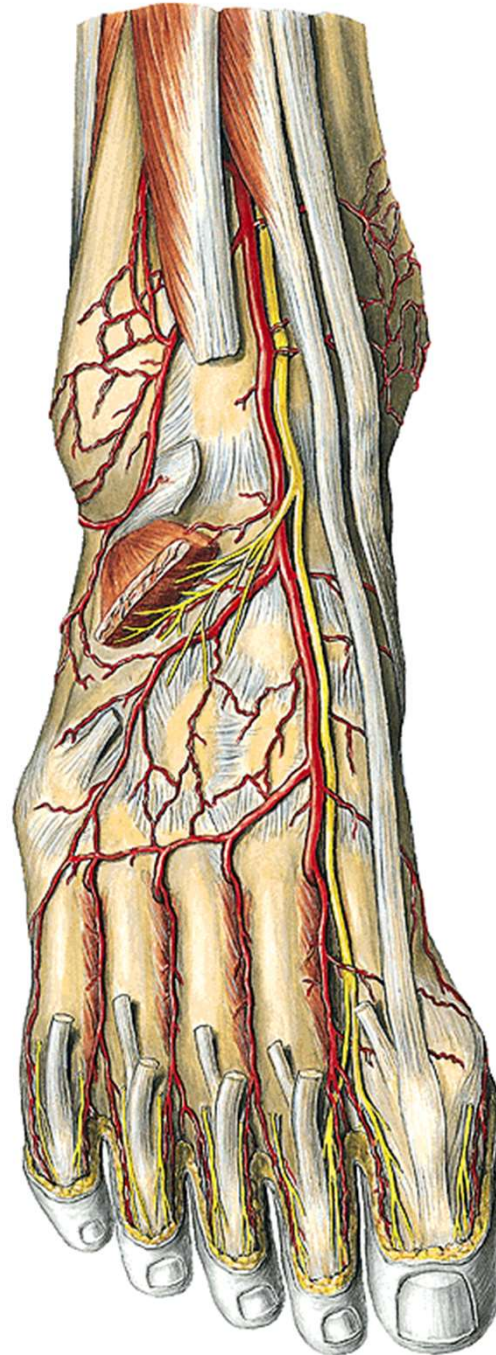
n. peroneus prof.



a. et v. dorsalis pedis
n. peroneus prof.



n. peroneus prof.
a. dorsalis pedis

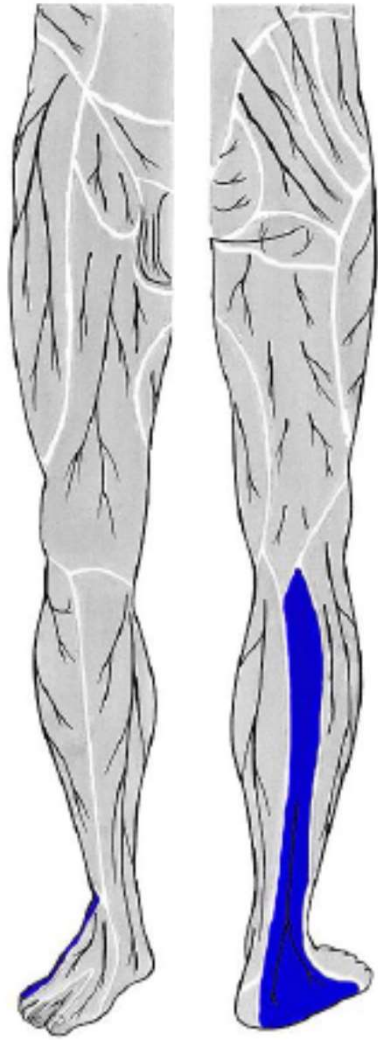


a. arcuata + a. tarsea lat.

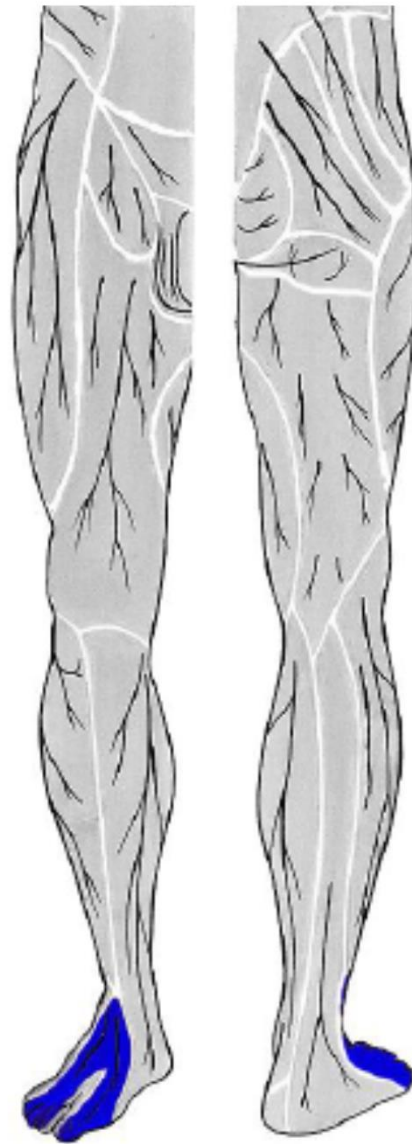
aa. metatarsae dors.

aa. digitales dorsales

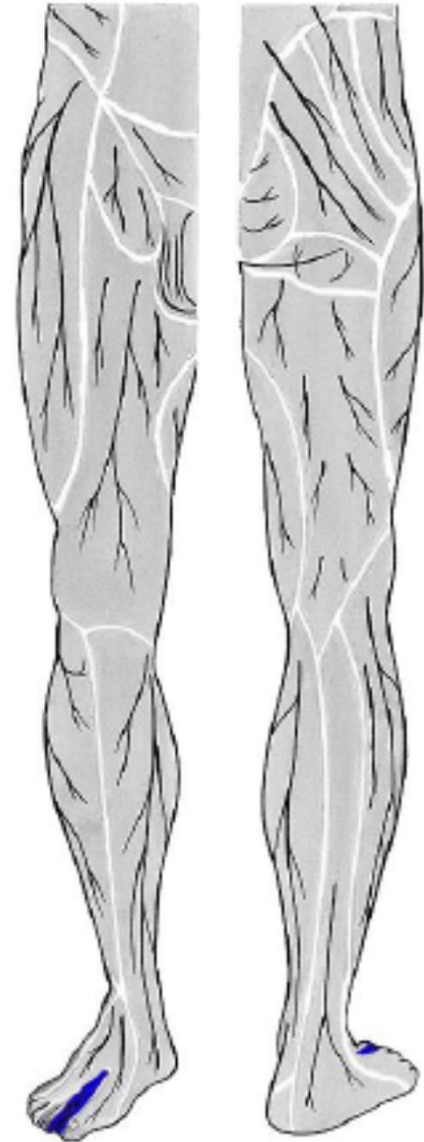
a. metatarsa dors. prima



n. suralis
(z *n. fibularis communis*
a *n. tibialis*)

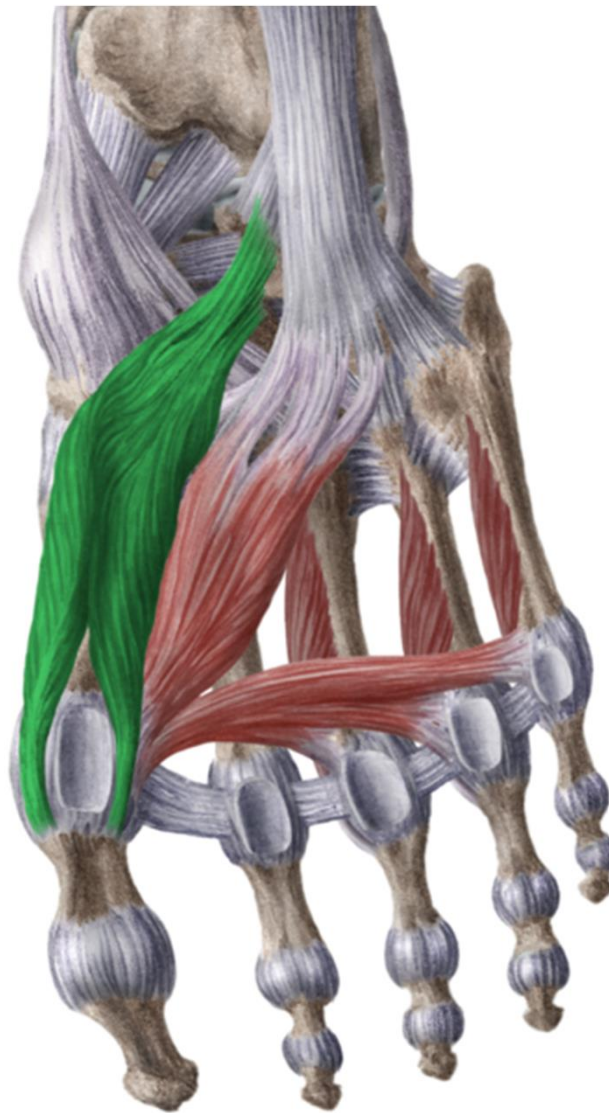
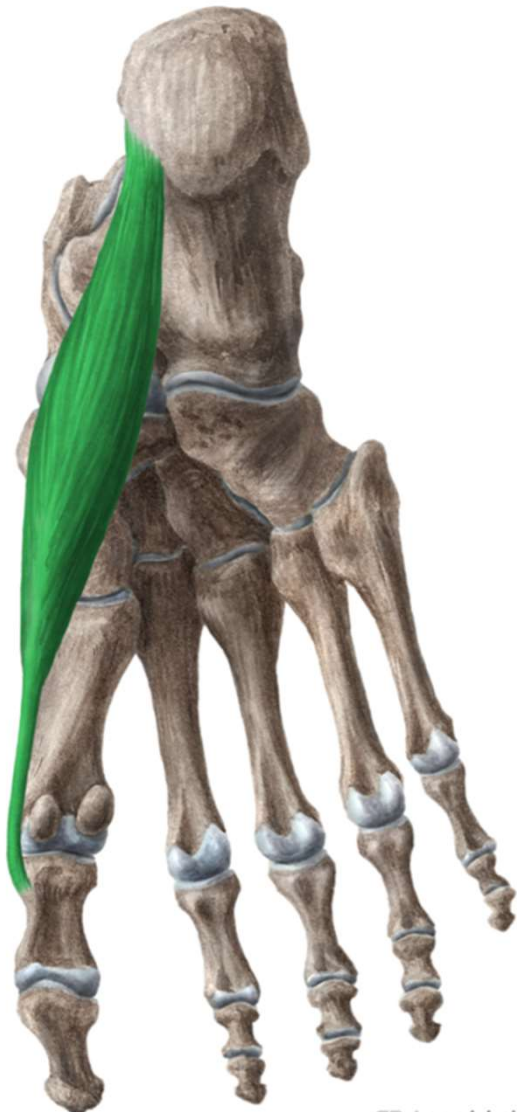


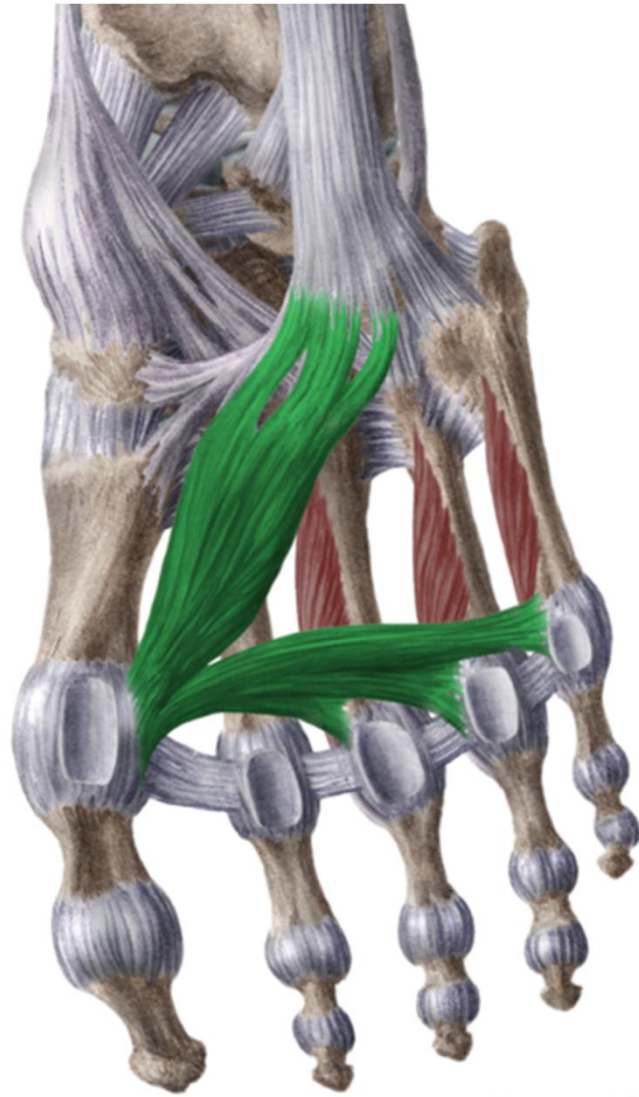
n. fibularis superficialis
(z *n. fibularis communis*)



n. fibularis profundus
(z *n. fibularis communis*)

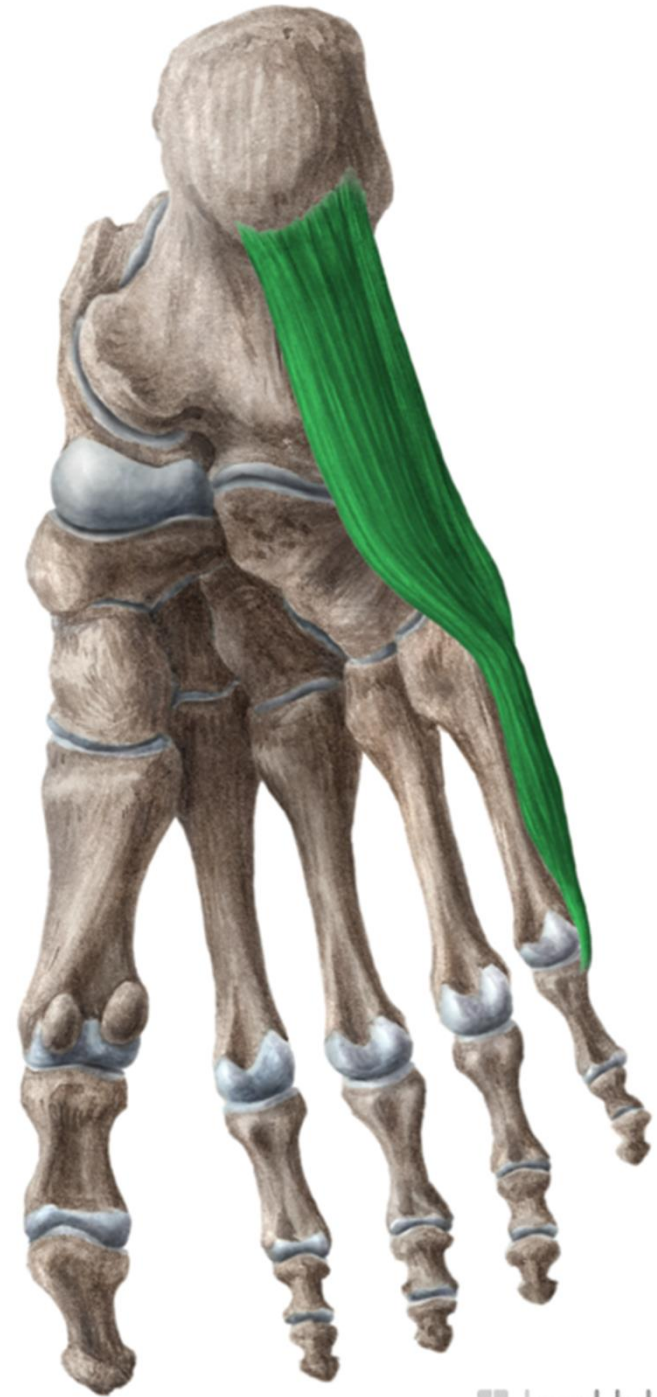
planta pedis





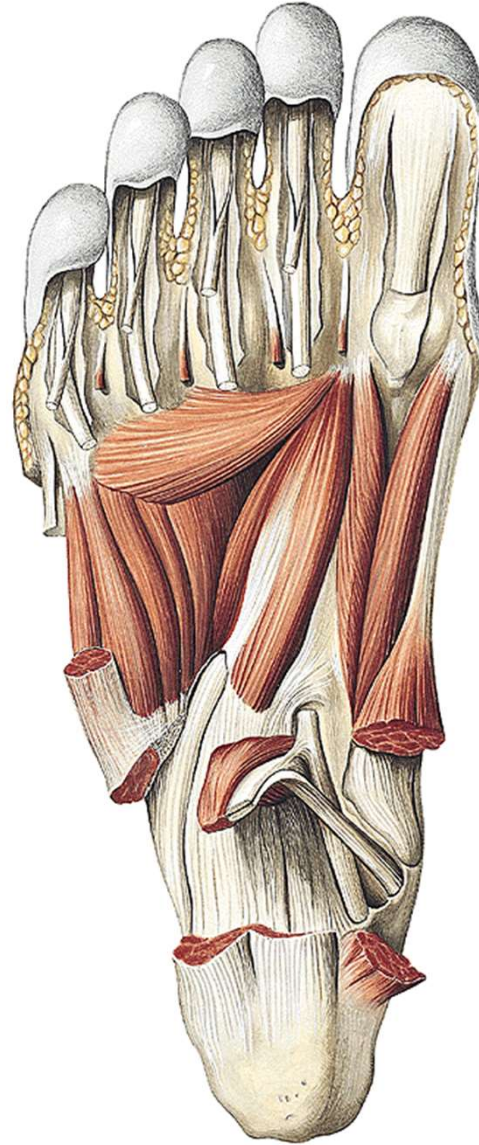
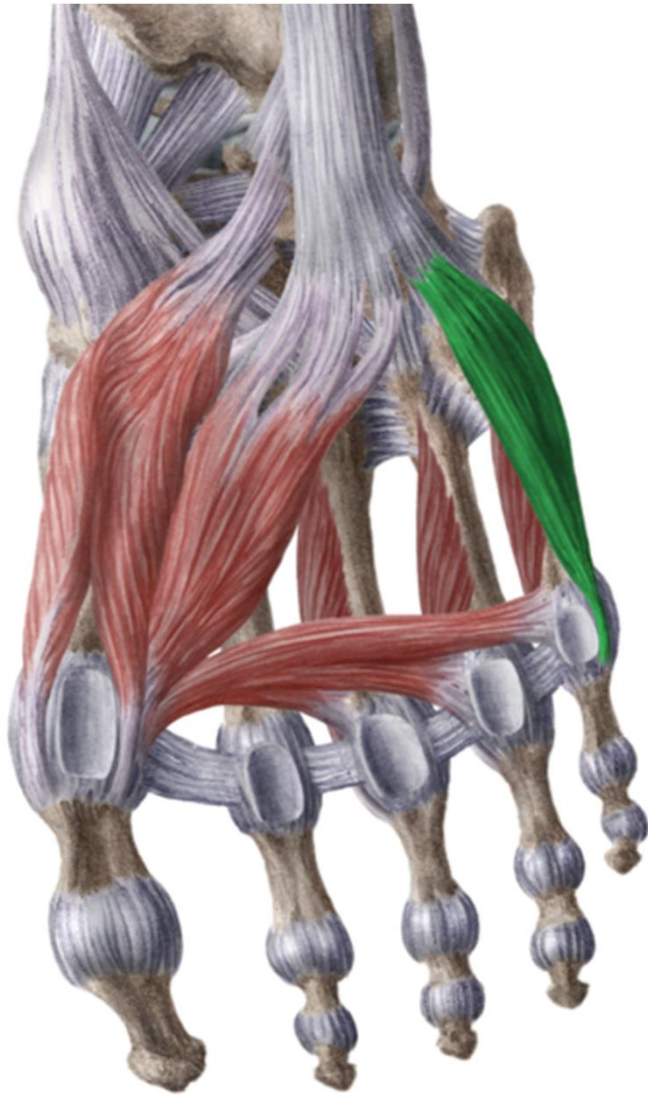
www.kenhub.com

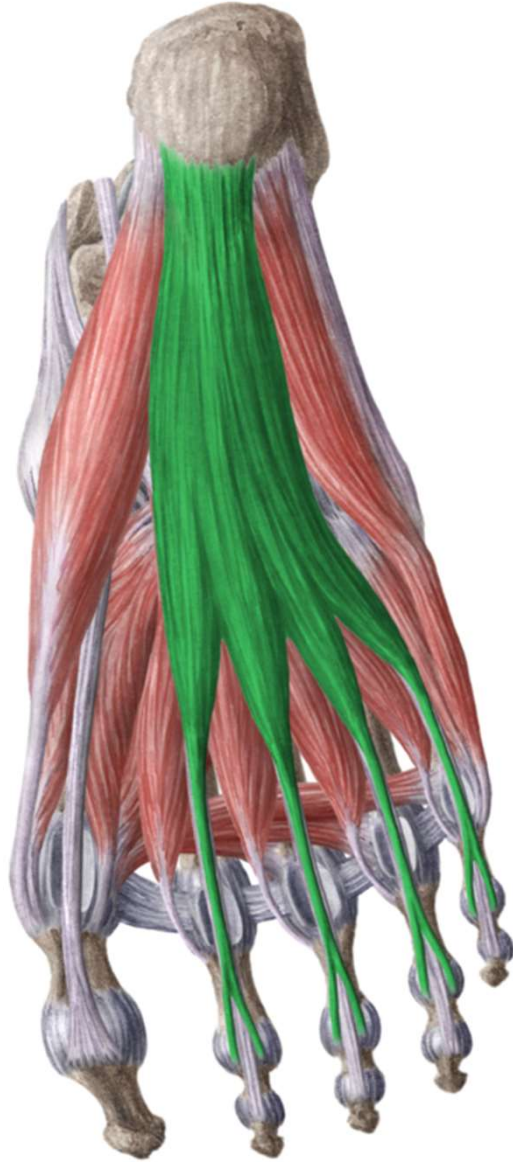
 kenHub



www.kenhub.com

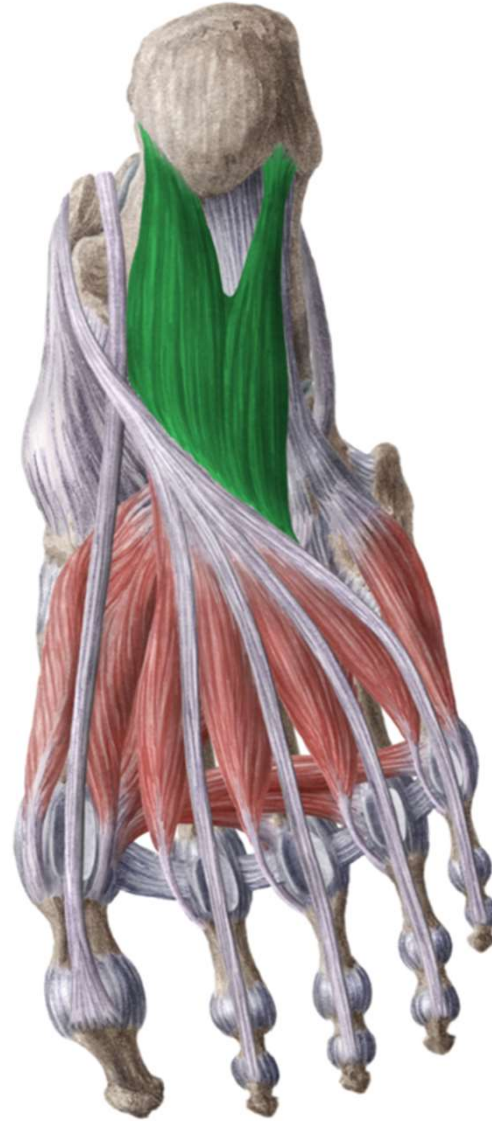
 kenHub





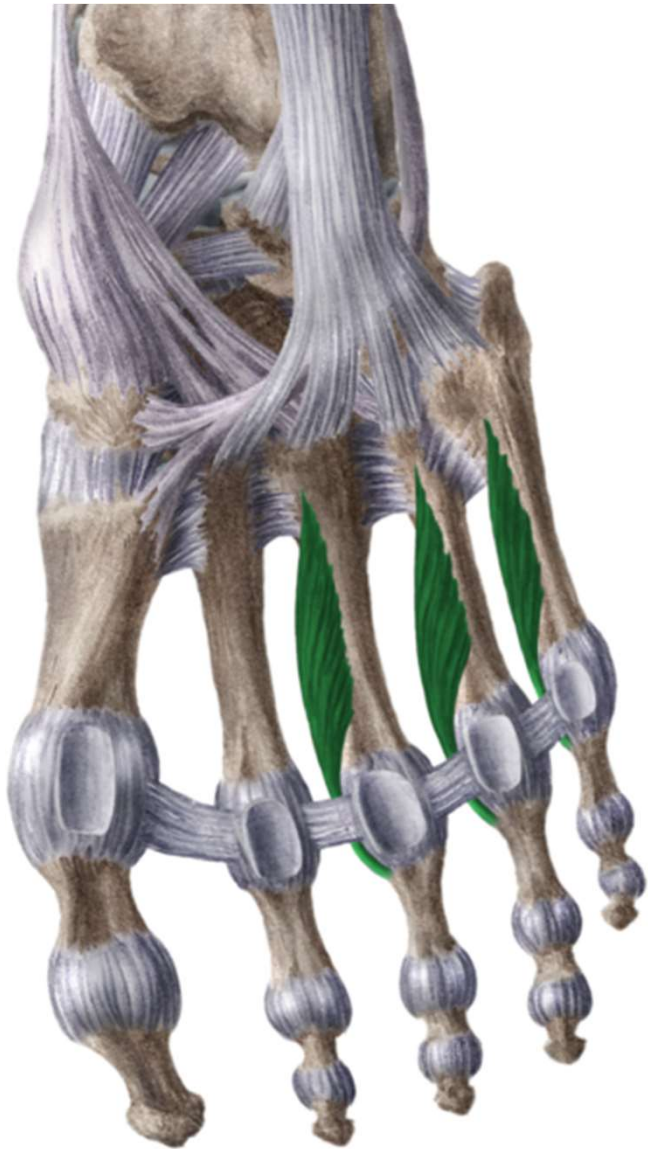
www.kenhub.com

 kenHub

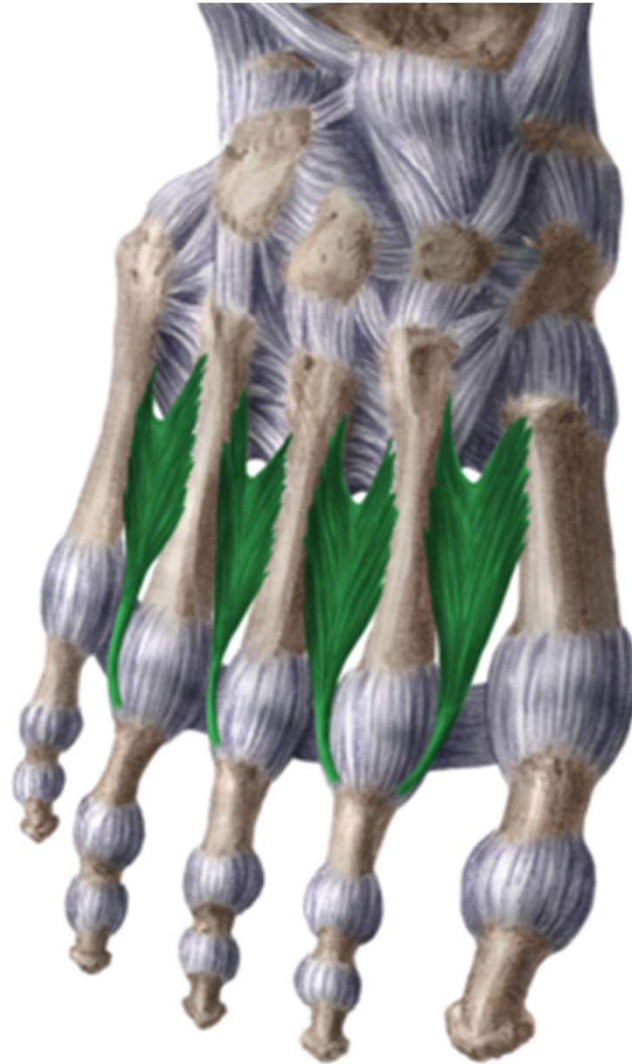

www.kenhub.com

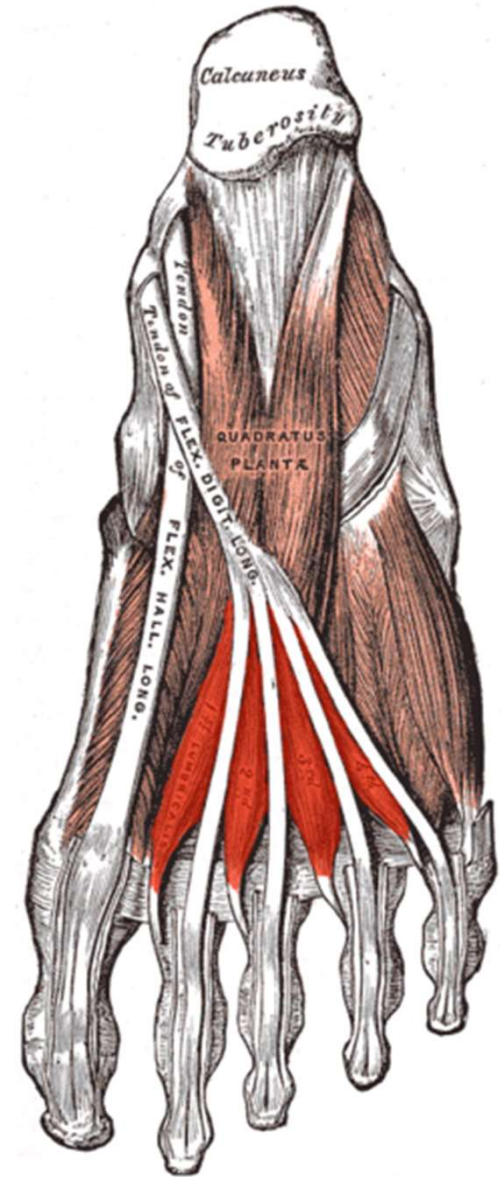
 kenHub



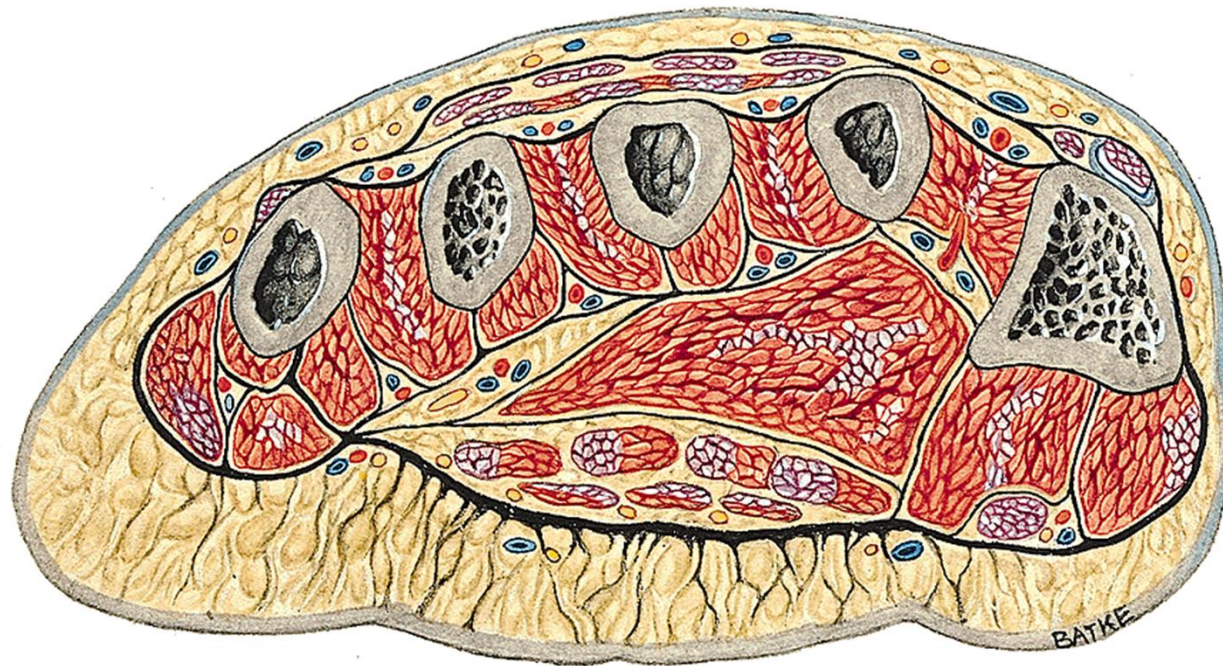
kenhub.com



kenHu w.kenhub.com



kenHu



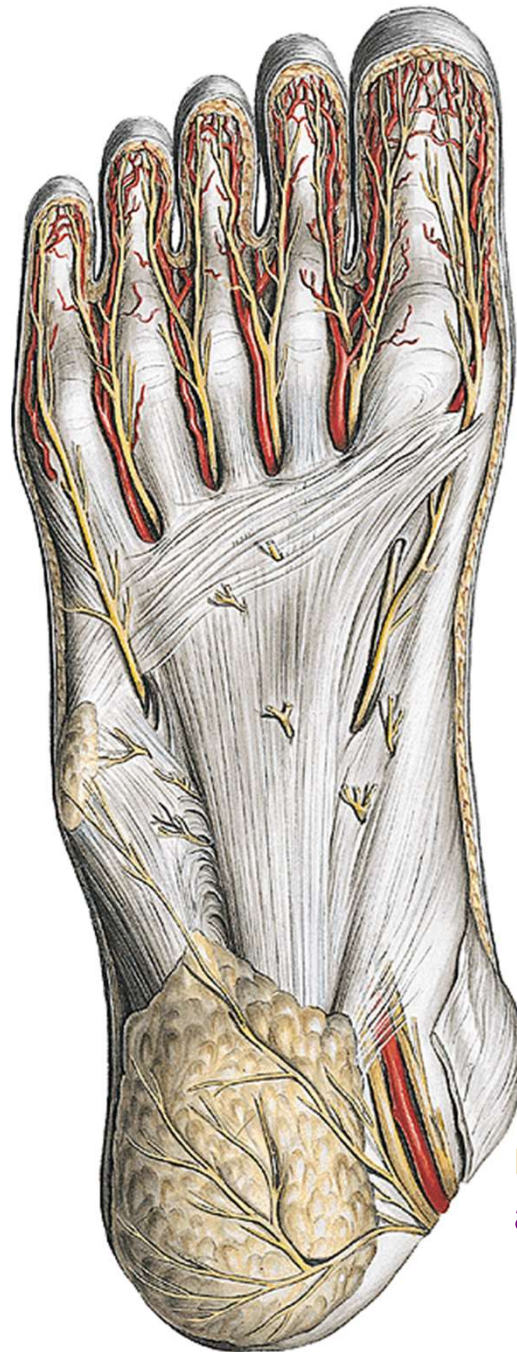aponeurosis plantaris

rr. superf. (z n. plantaris med. et lat.)

rr. superf. (z a. et v. plantaris med.)

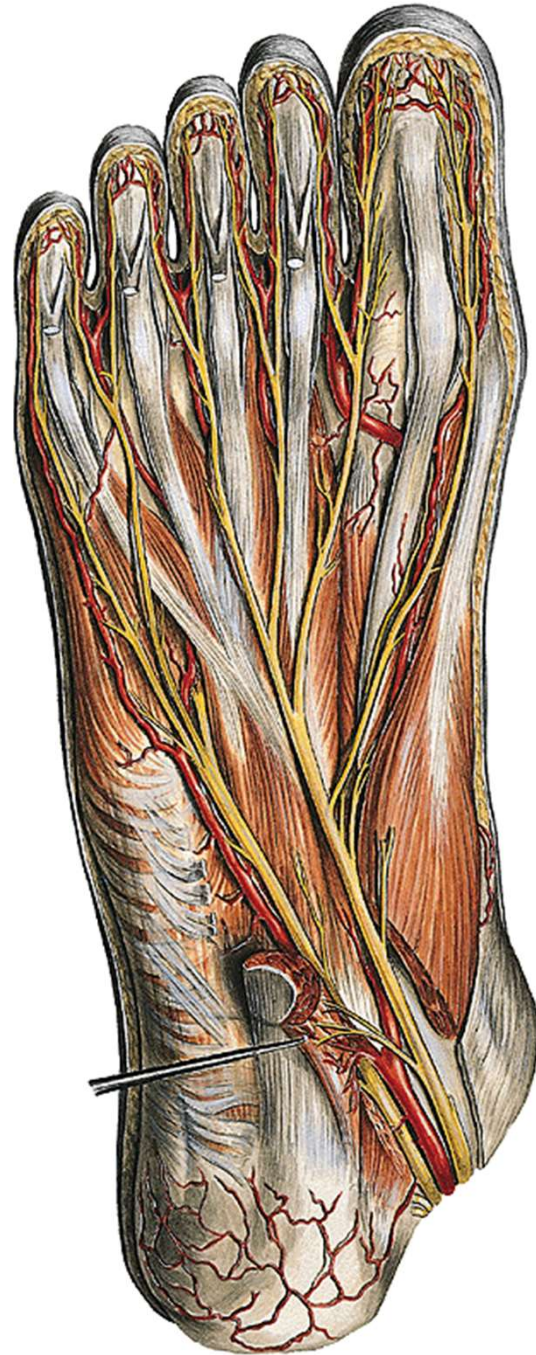
a. et v. plantaris med. et lat.

n. plantaris med. et lat.



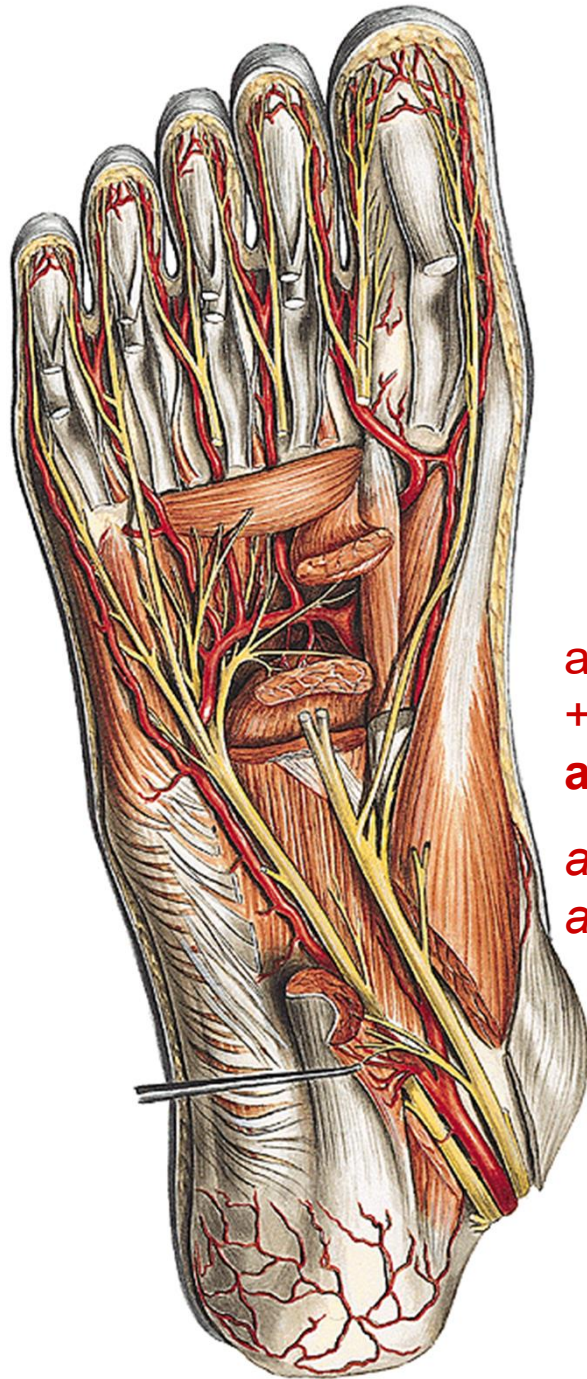
rr. superf. (z n. plantaris med. et lat.)

n. tibialis
a. et v. tibialis



n. plantaris med. et lat.

a. et v. plantaris med. et lat.



a. plantaris lat. + r. plantaris prof (z a. dorsalis pedis)
+ větev z a. plantaris med.

arcus plantaris

aa. metatarsae plant.

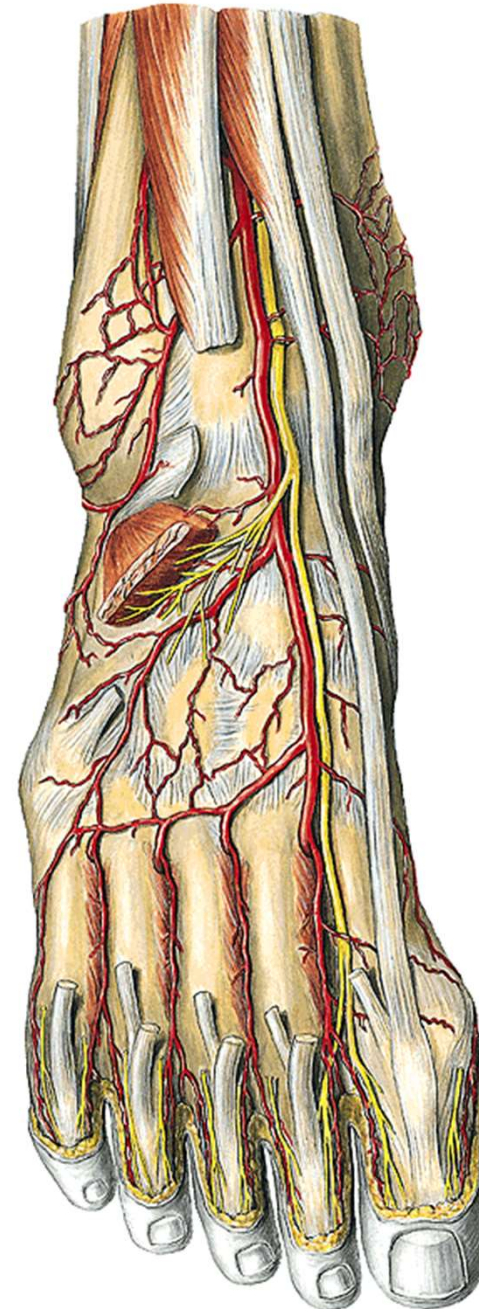
aa. digitales plant.

digiti pedis

dorsální aponeuróza

nn. digitales dorsales

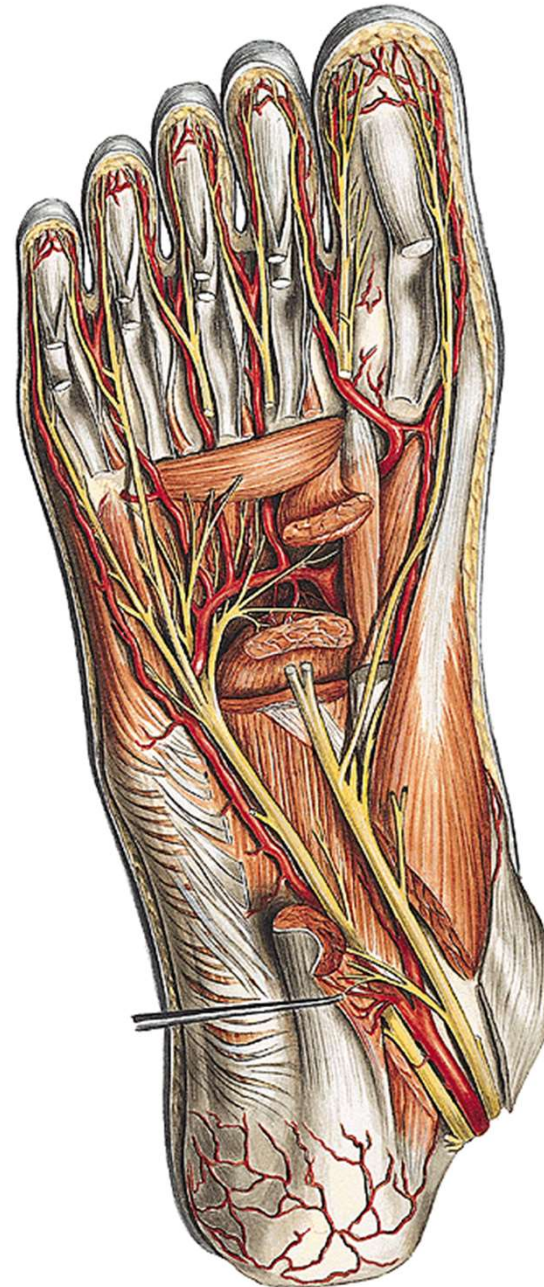
aa. et vv. digitales dorsales

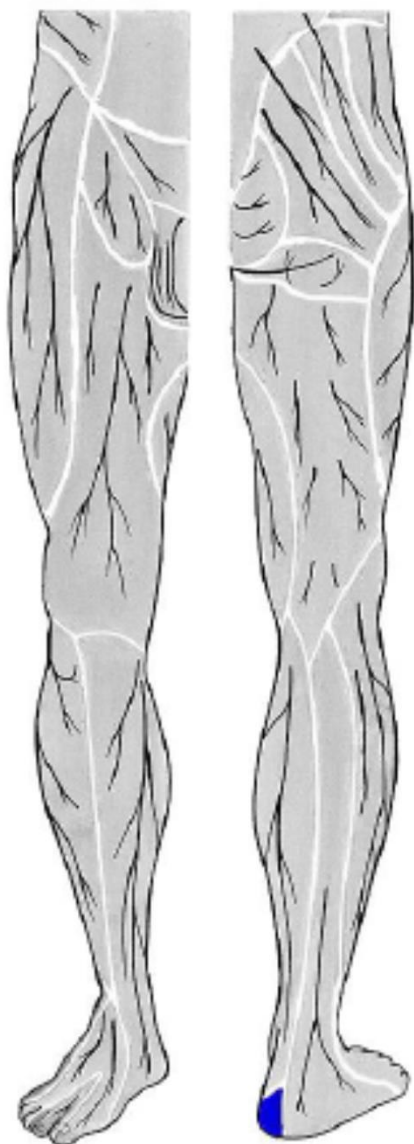


šlachy m. flexor digitorum brevis et longus

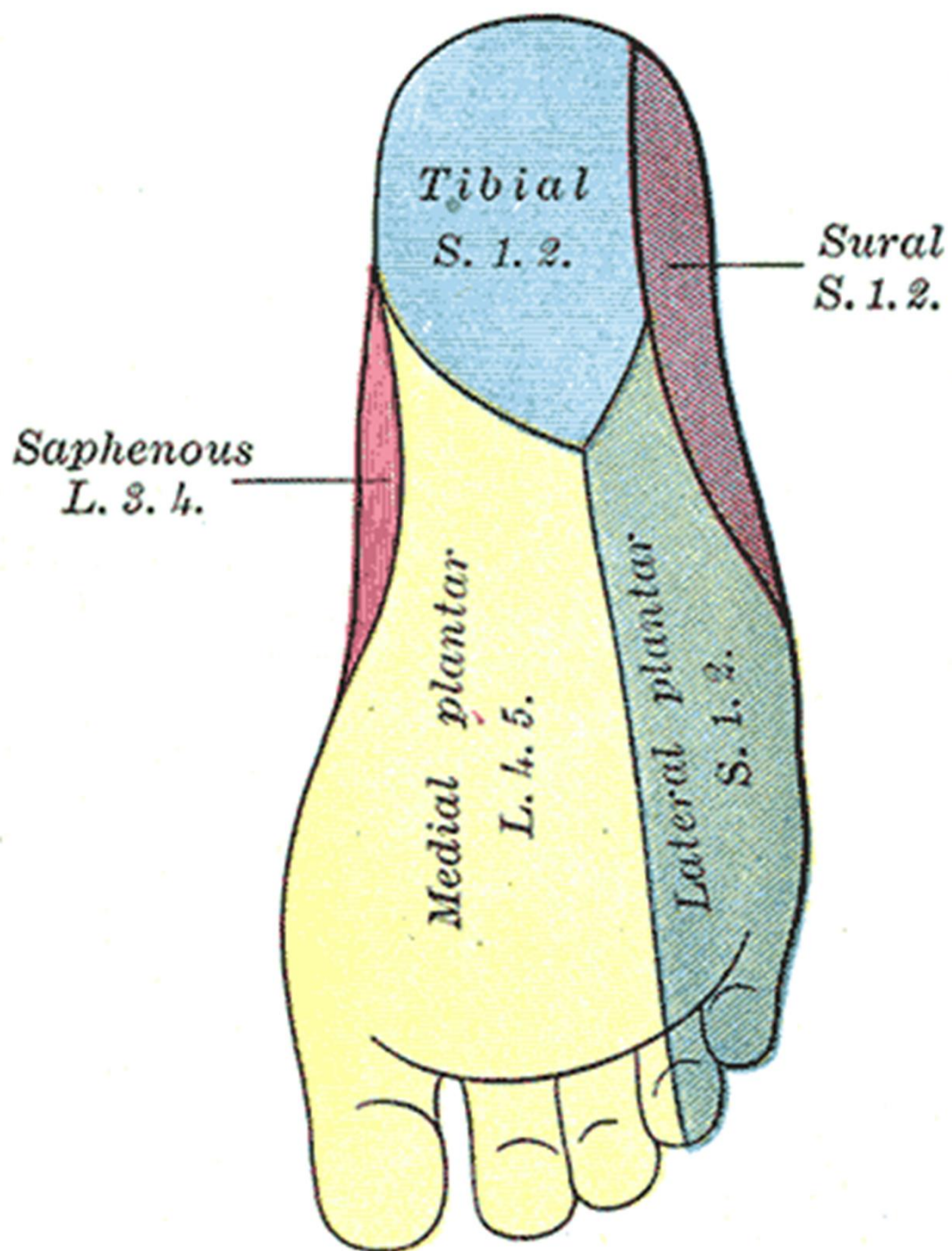
nn. digitales plantares

aa. et vv. digitales plantares



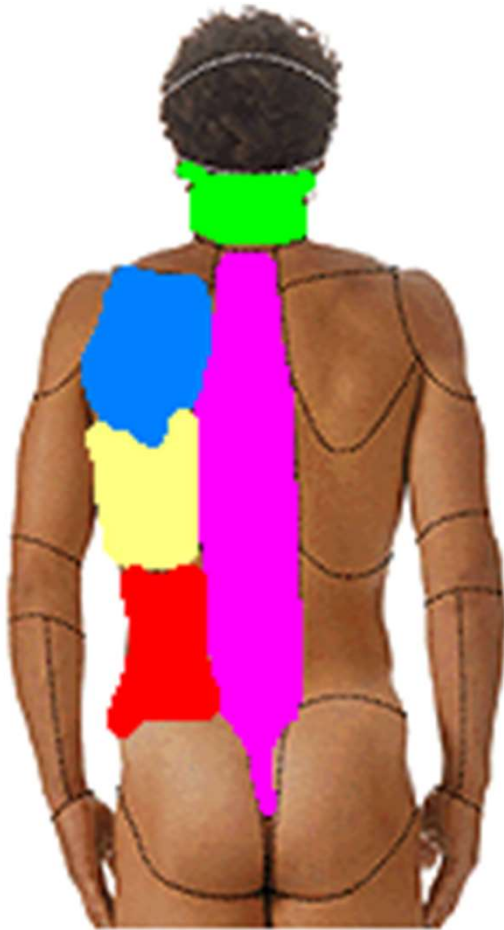


n. plantaris medialis et lateralis:
(z n. tibialis)

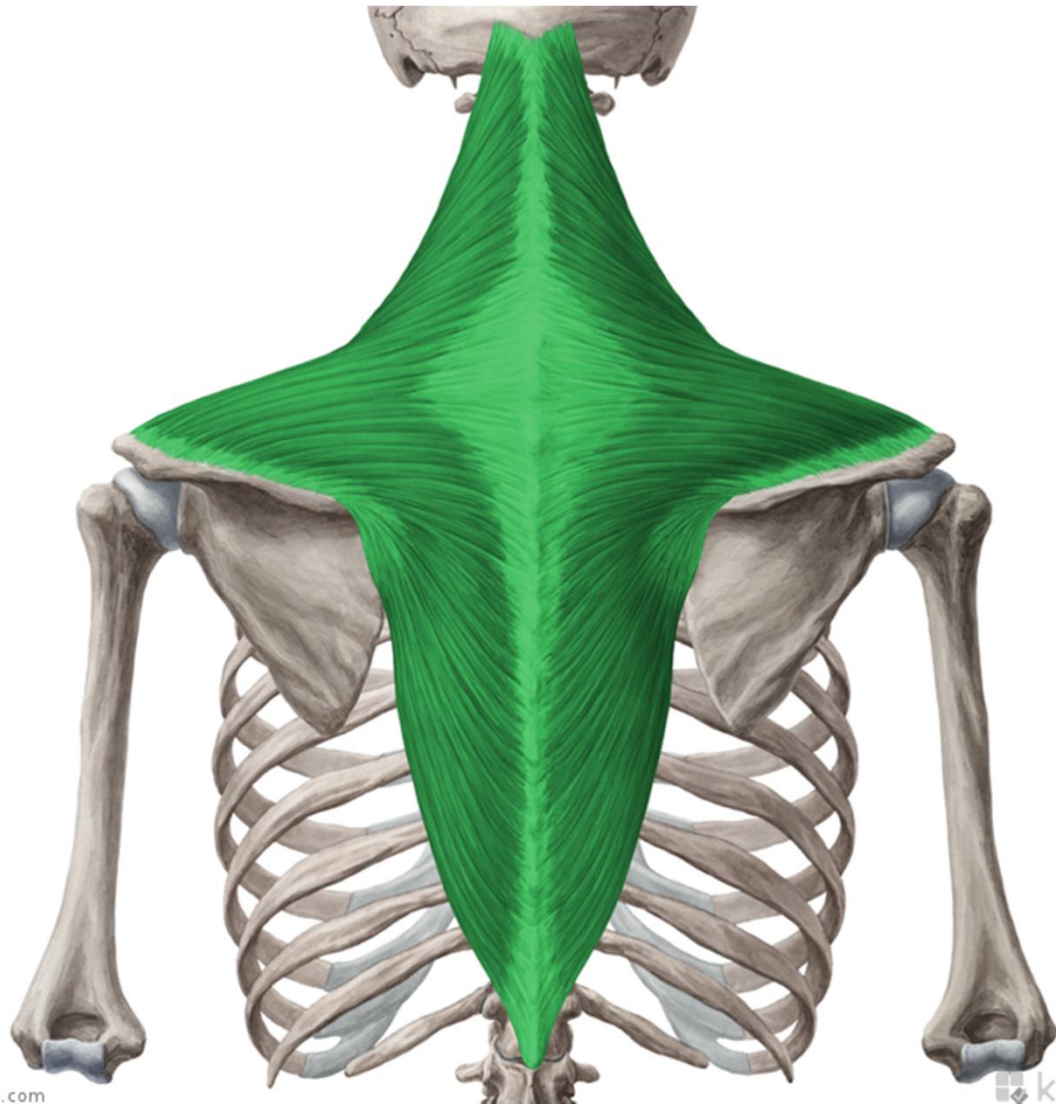


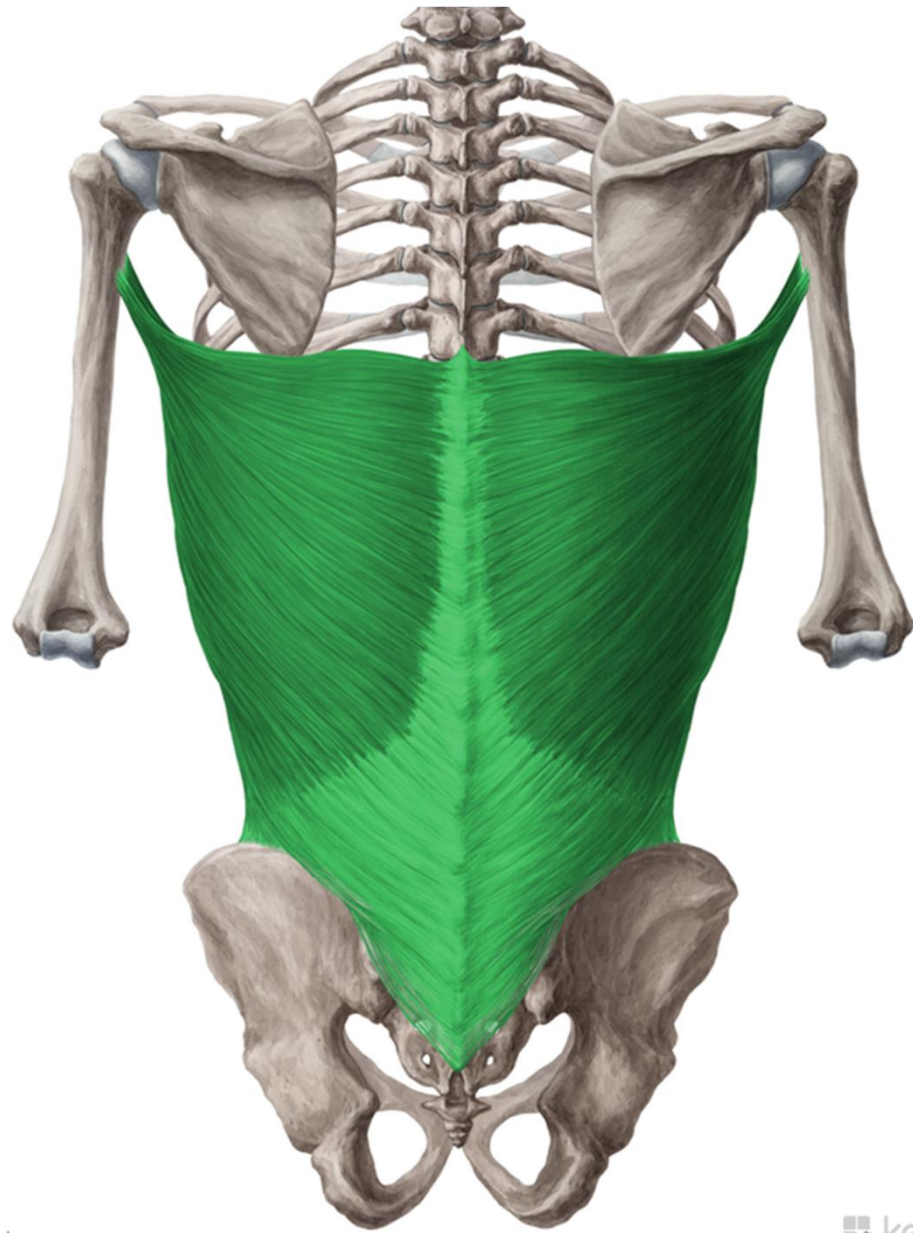
Topografická anatomie zad

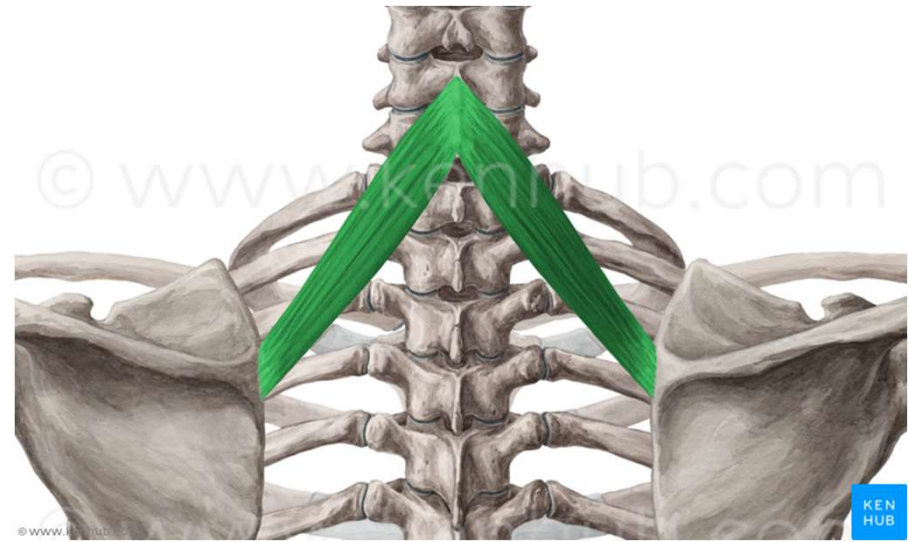
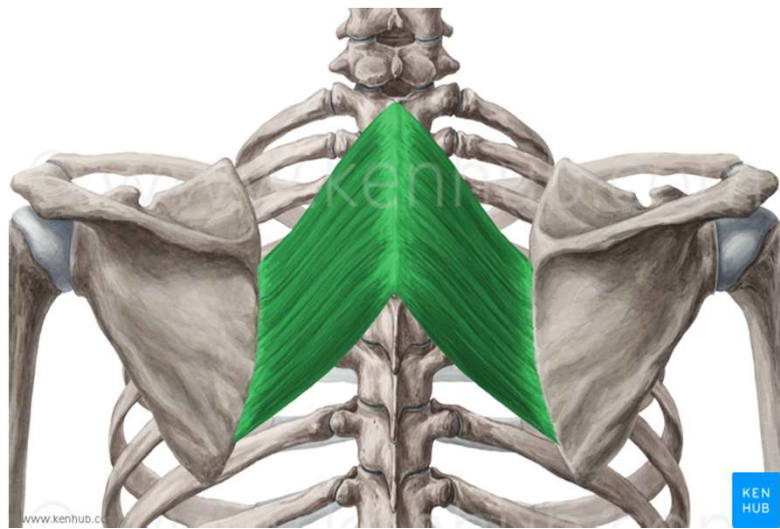
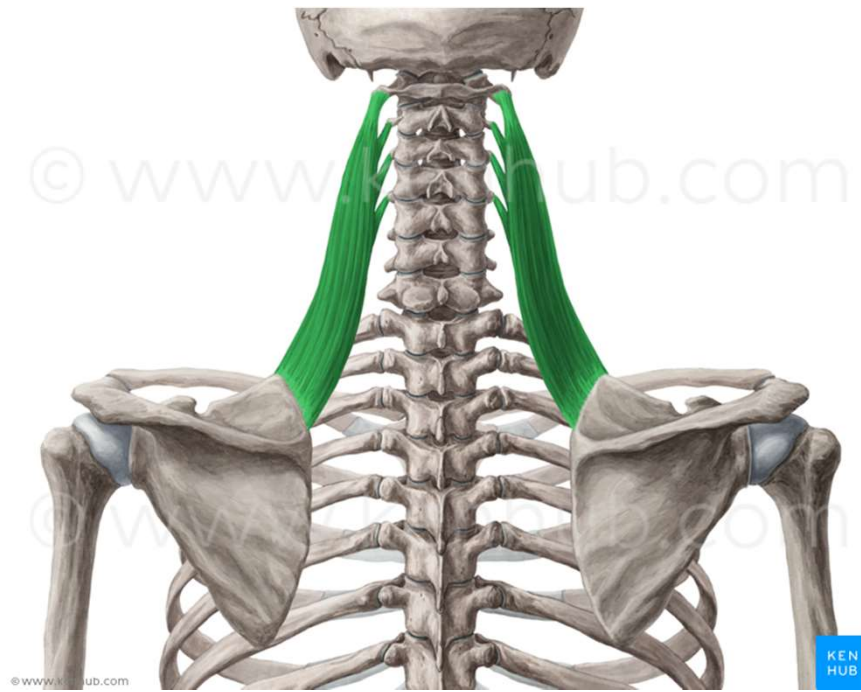


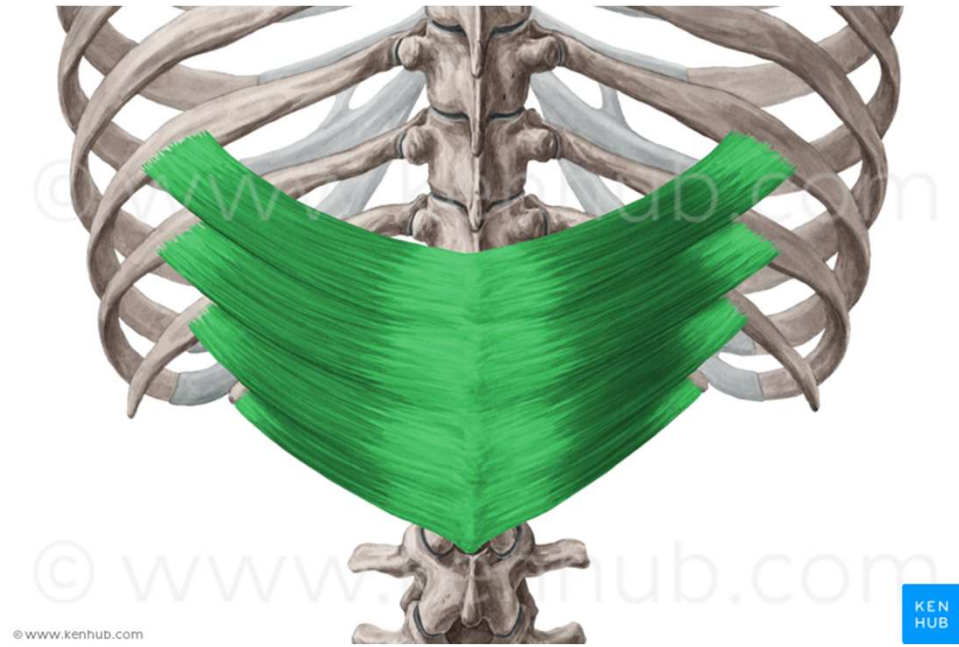
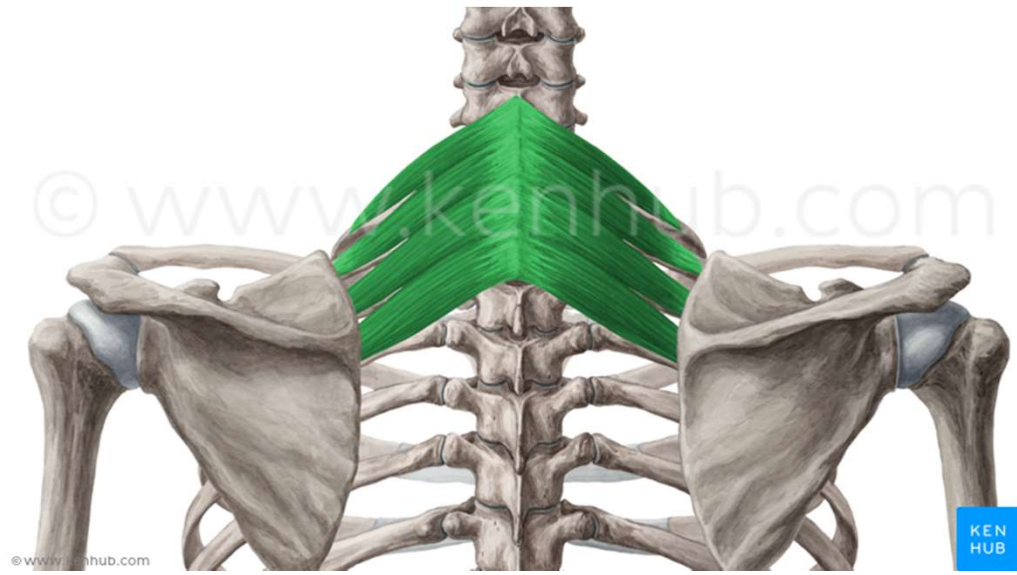


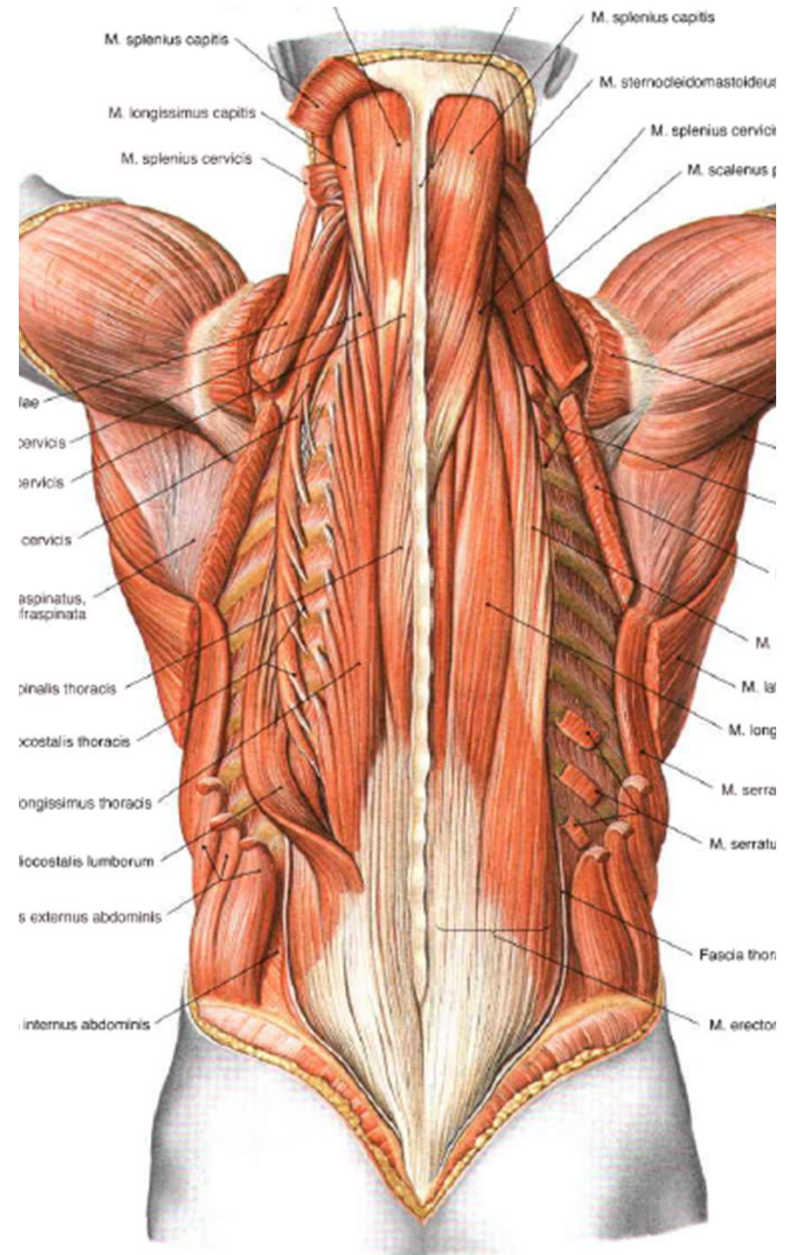
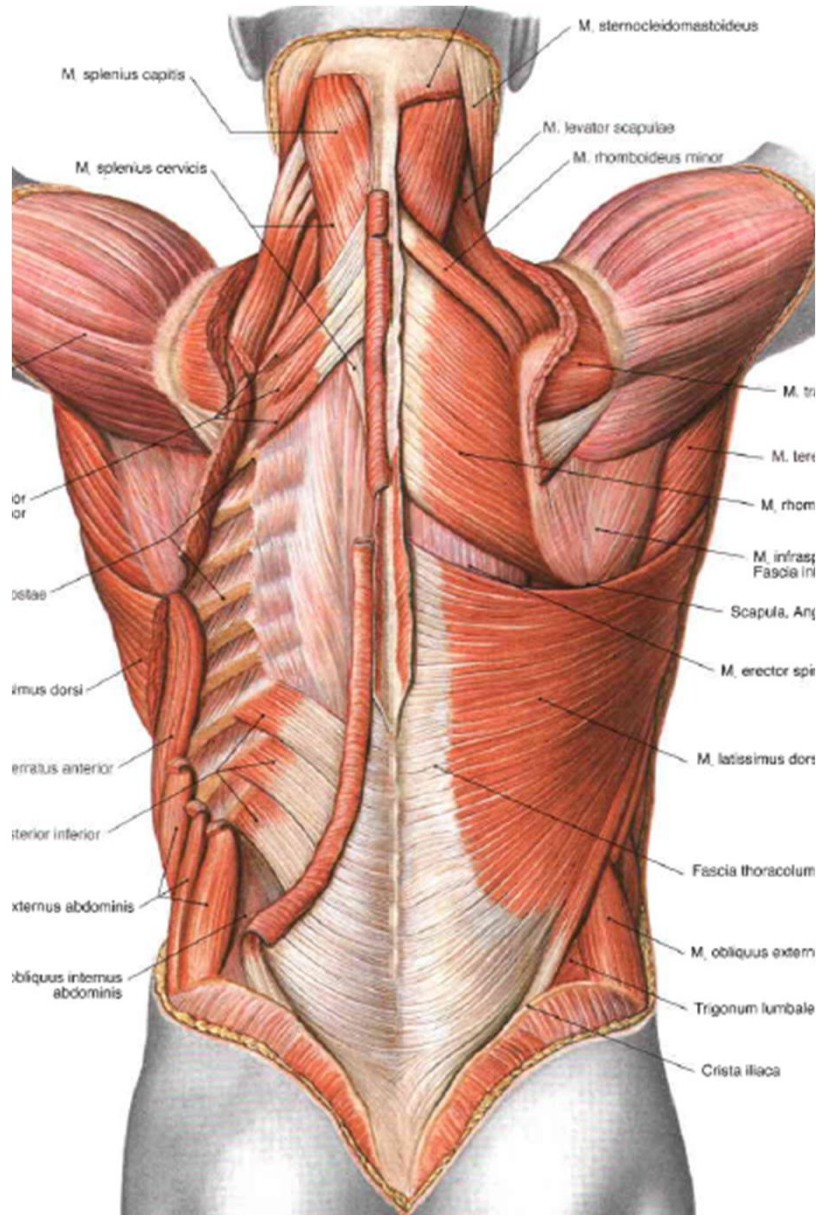
- regio nuchae
- regio vertebralis
- regio infrascapularis
- regio lumbalis



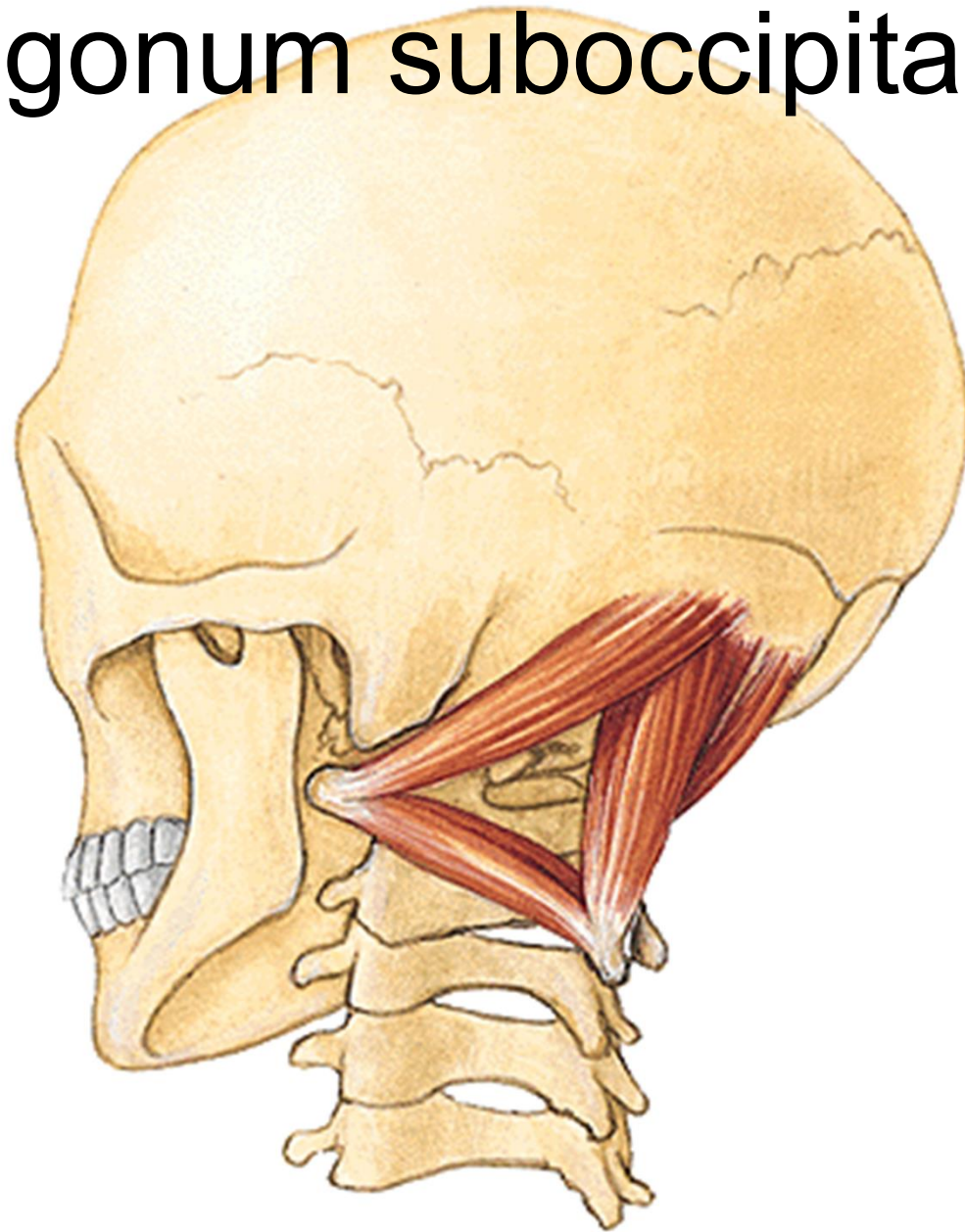


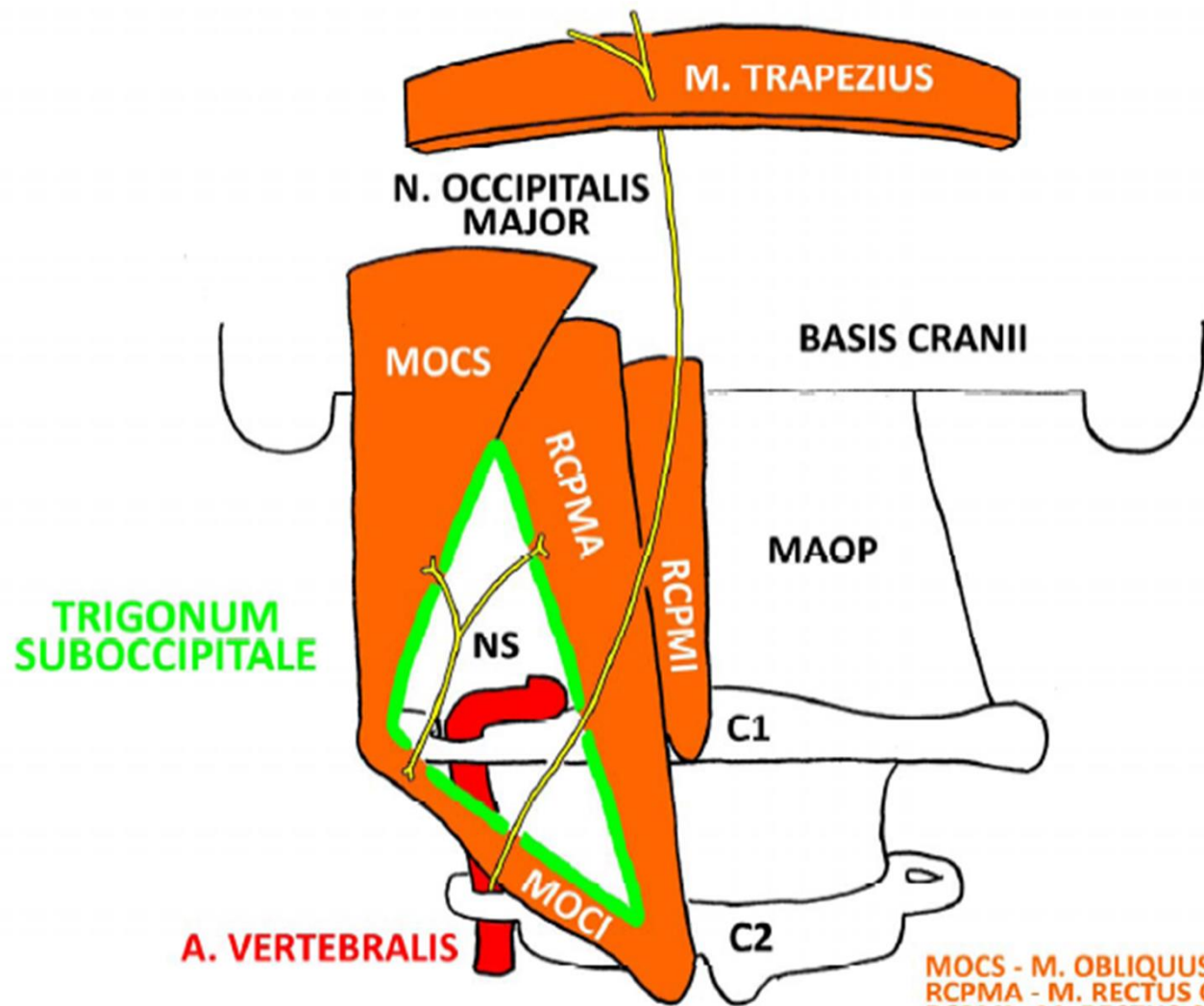







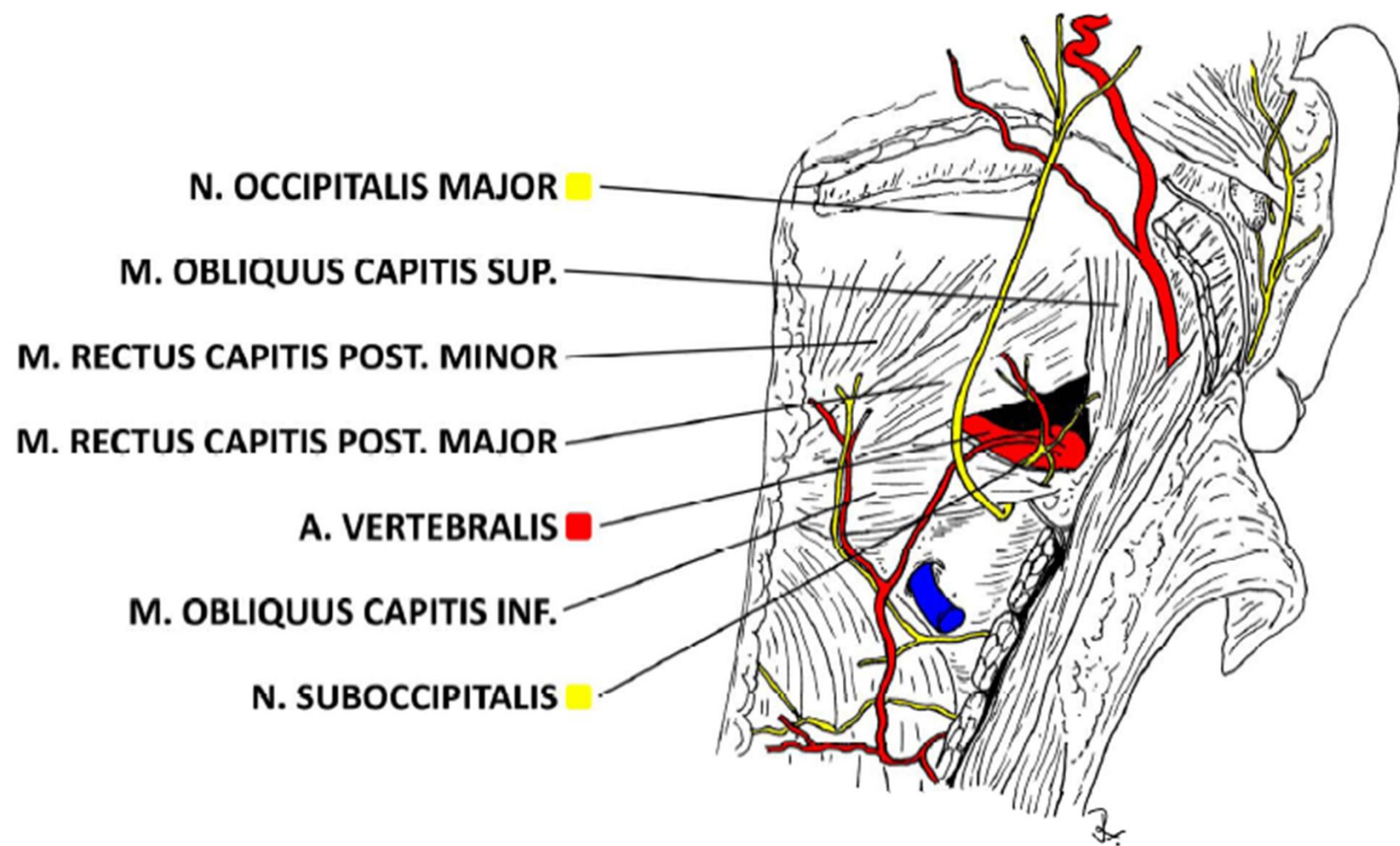
Trigonum suboccipitale



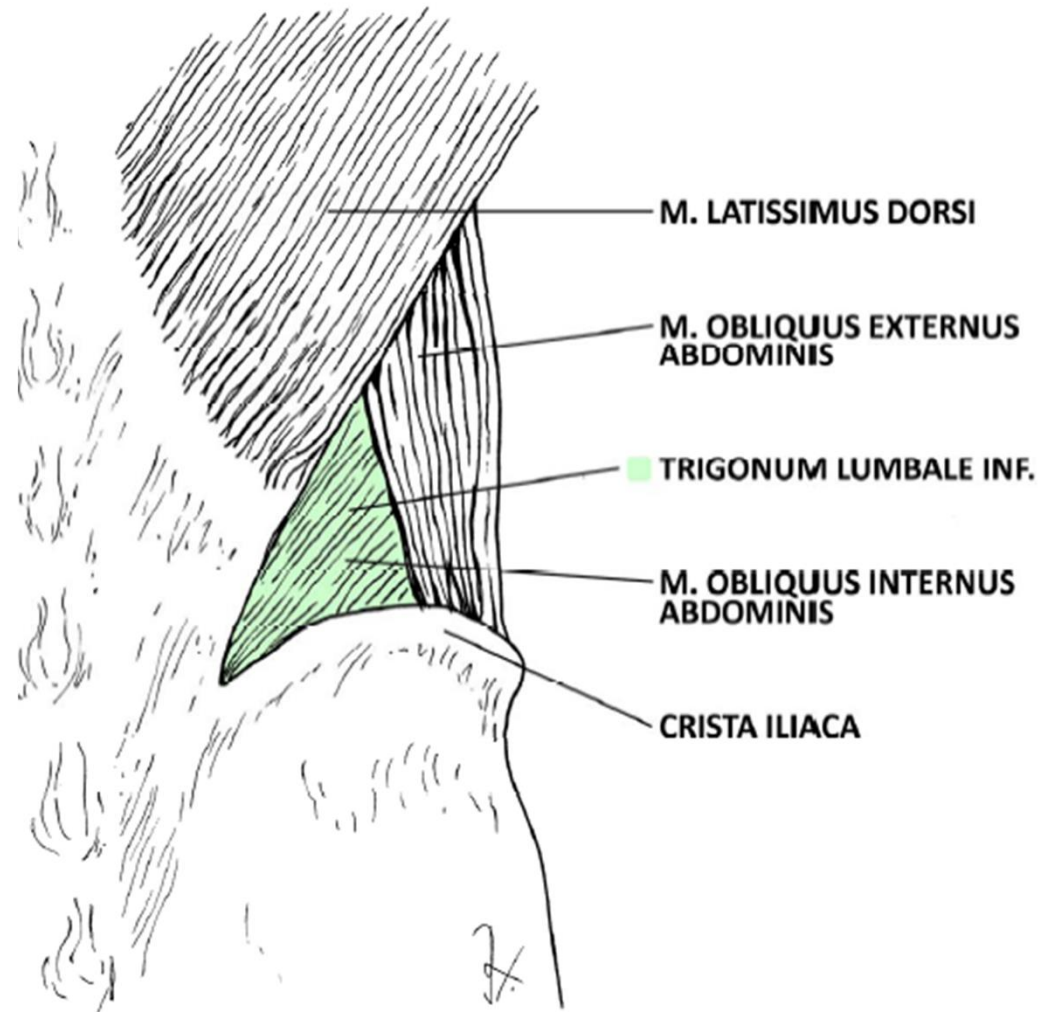


MOCS - M. OBLIQUUS CAPITIS SUP.
RCPMA - M. RECTUS CAPITIS POST. MAJOR
RCPMI - M. RECTUS CAPITIS POST. MINOR
MOCI - M. OBLIQUUS CAPITIS INF.
MAOP - MEMBRANA ATLANTOCCIPITALIS POST.
NS - N. SUBOCCIPITALIS

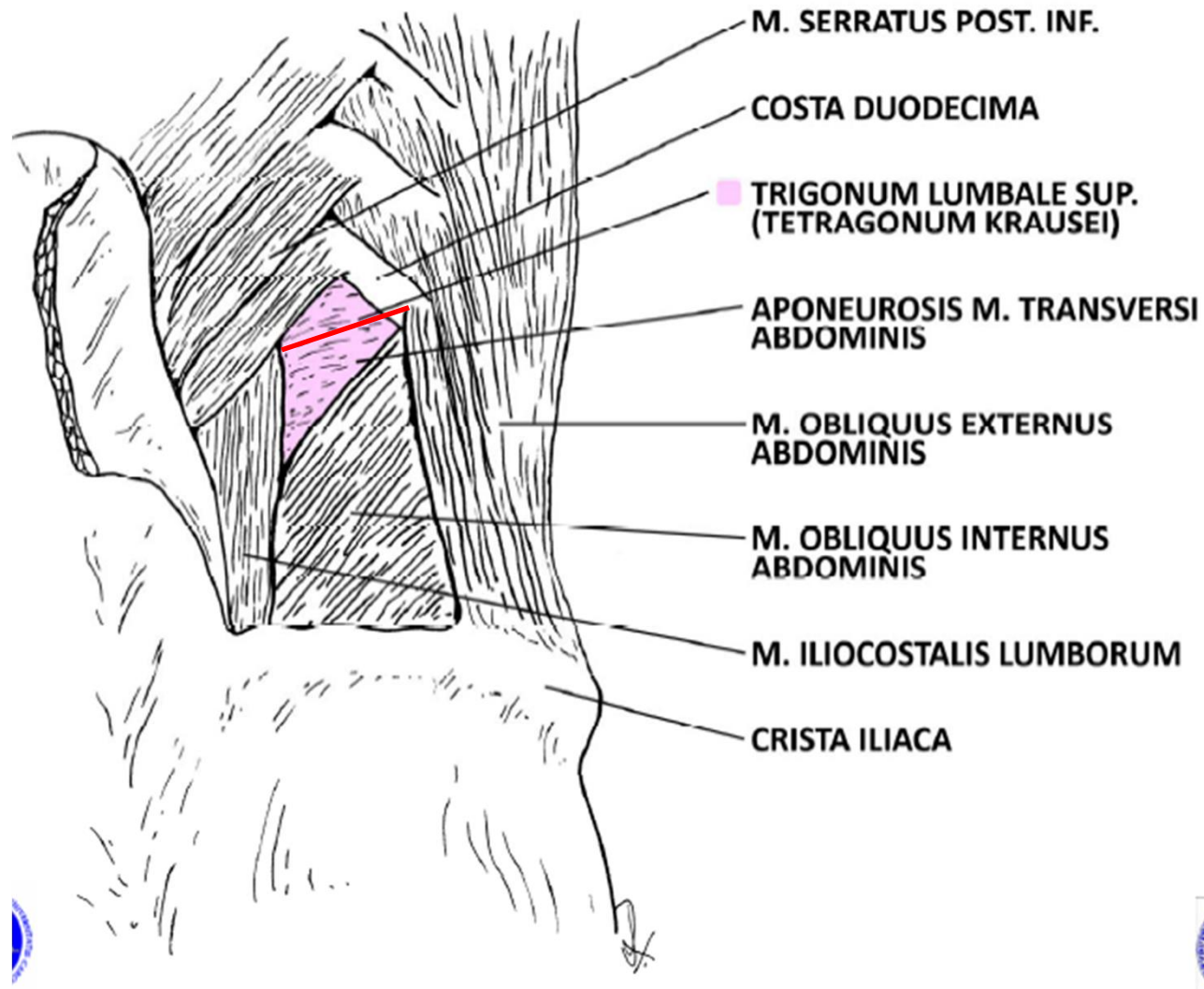




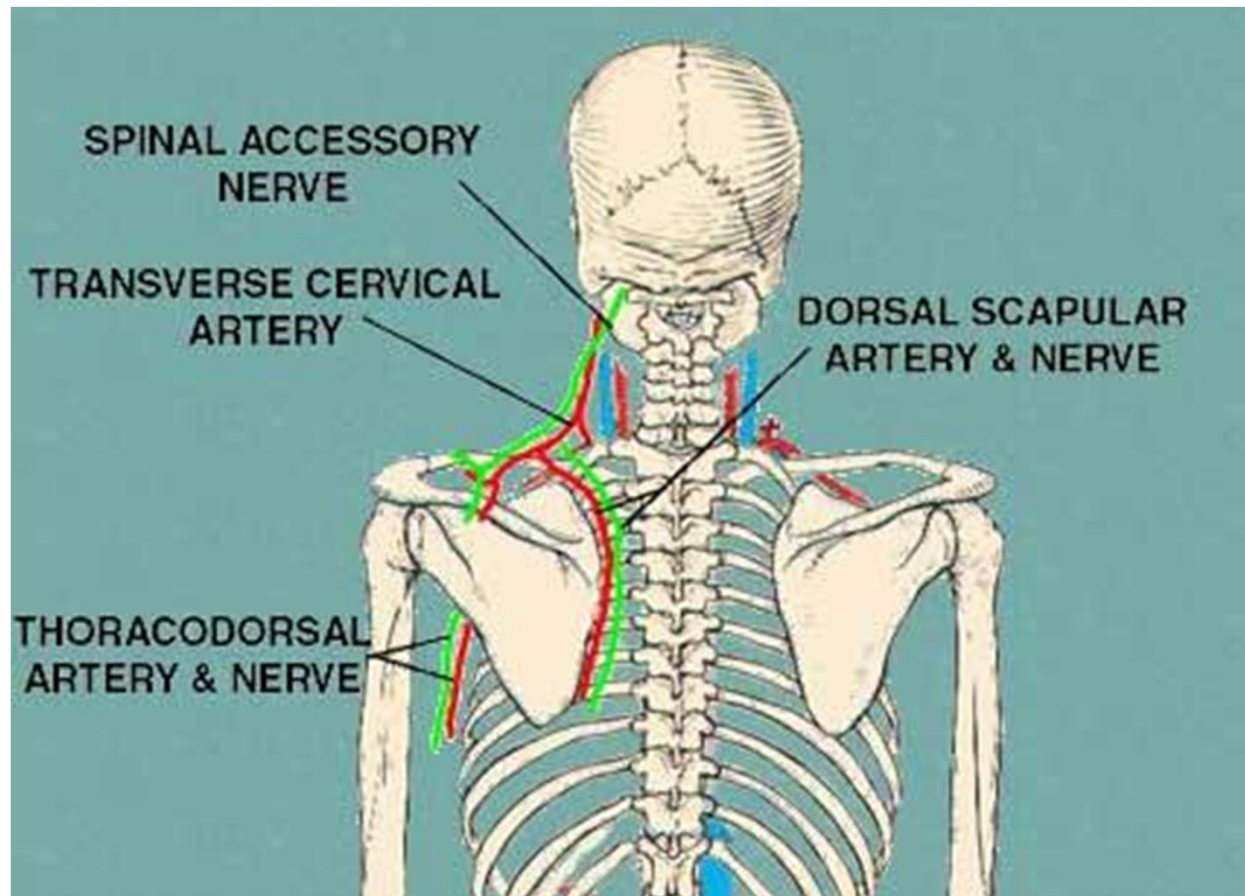
Trigonum lumbale petiti



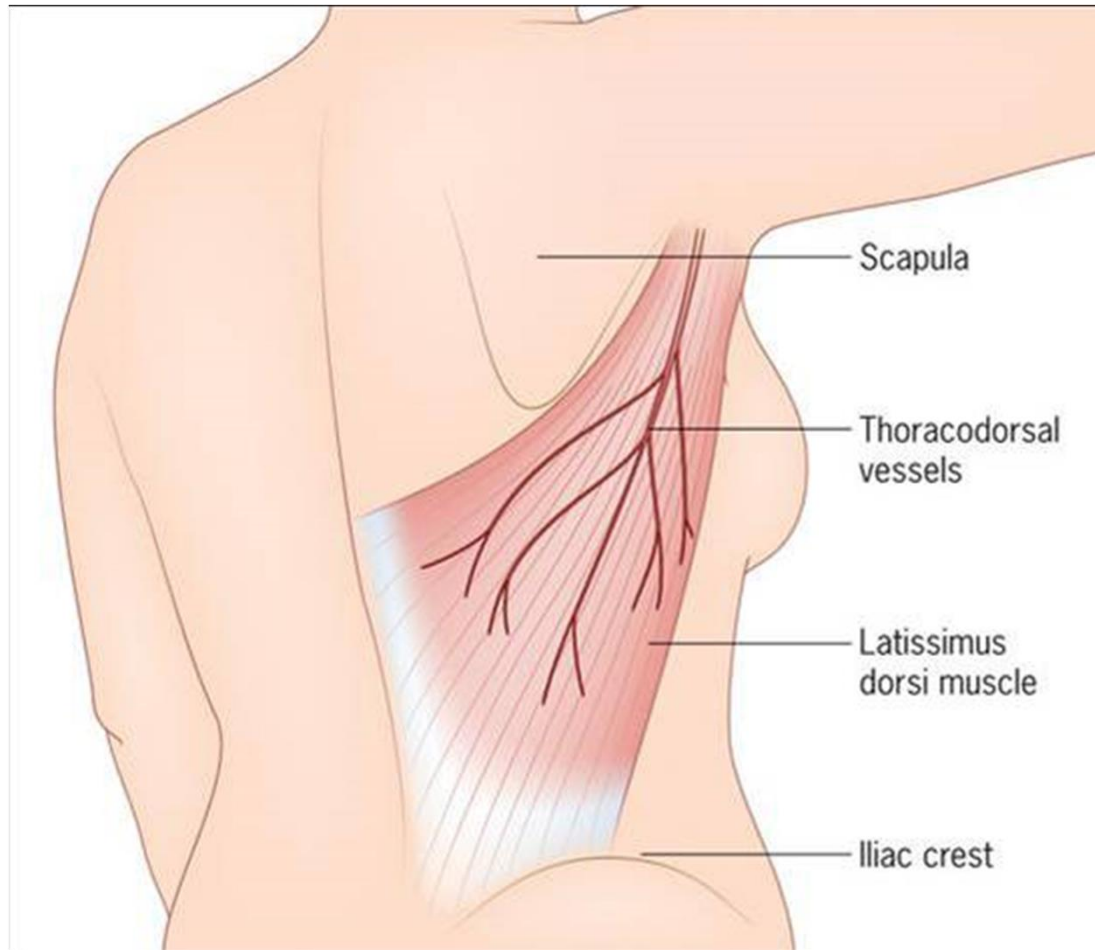
Trigonum Grynfelti/Tetragon Krausei



a. cervicalis profunda, a.
transversa coli, n. dorsalis
scapulae, n. accessorius



a. + n. thoracodorsalis



Děkuji za pozornost.



Obrázky:

- **Atlas der Anatomie des Menschen/Sobotta. Putz,R., und Pabst,R. 20. Auflage. München:Urban & Schwarzenberg, 1993**
- **Netter: Interactive Atlas of Human Anatomy.**
- **Naňka, Elišková: Přehled anatomie. Galén, Praha 2009.**
- **Čihák: Anatomie I, II, III.**
- **Drake et al: Gray's Anatomy for Students. 2010**

