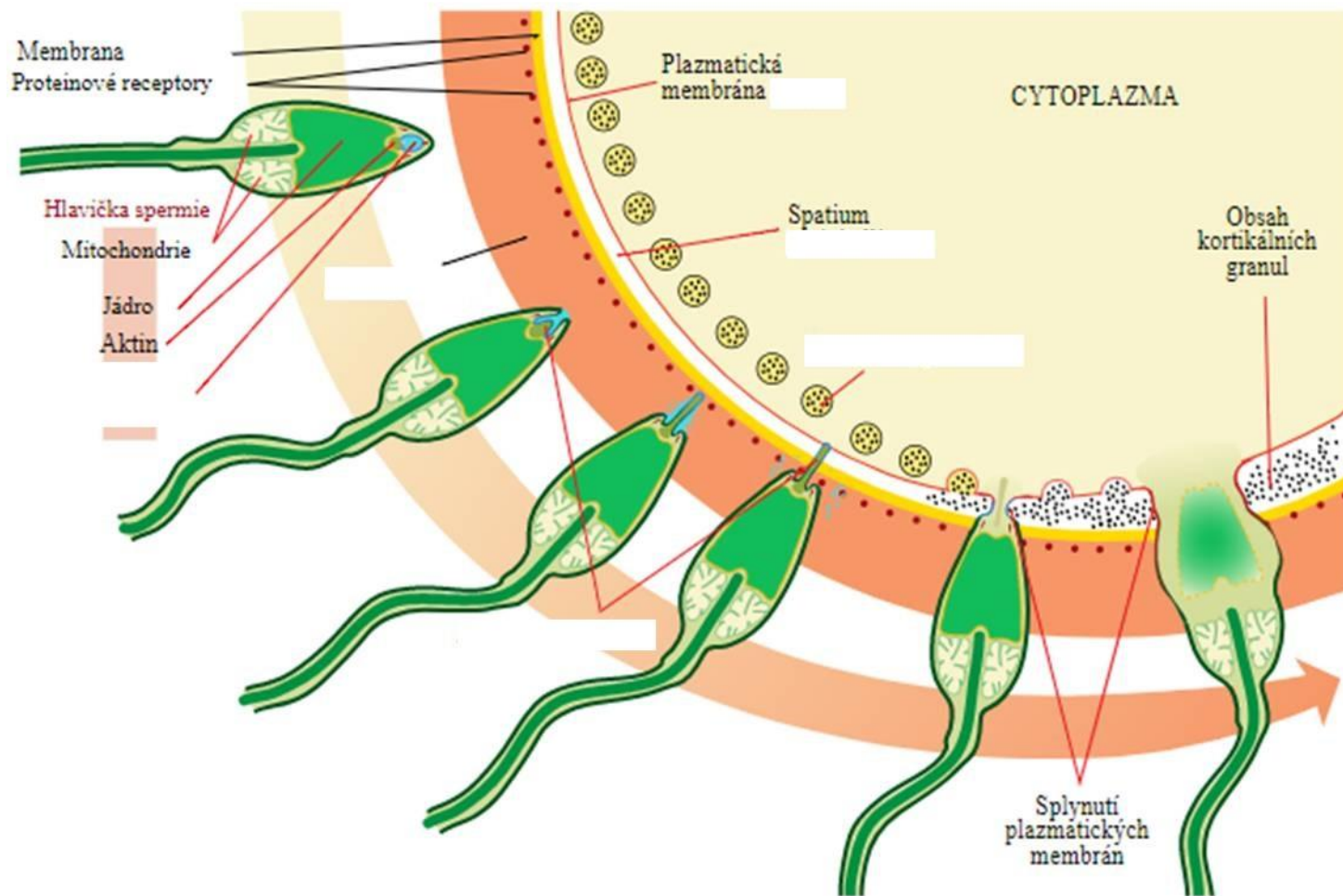
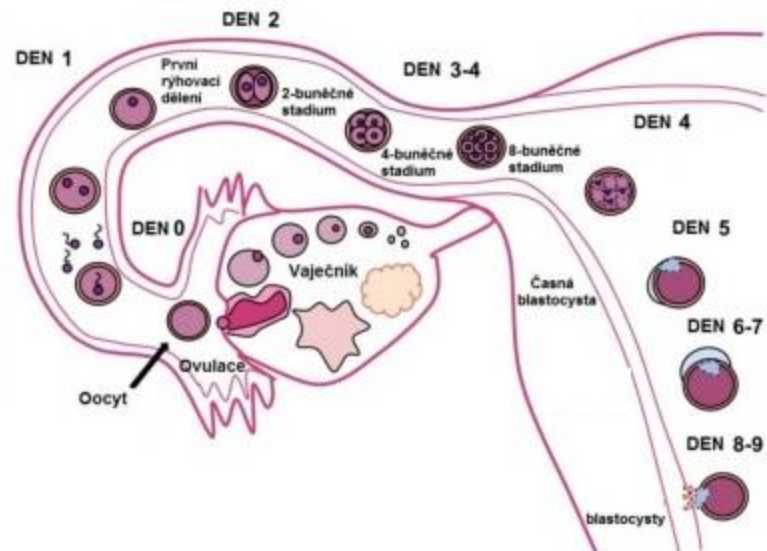
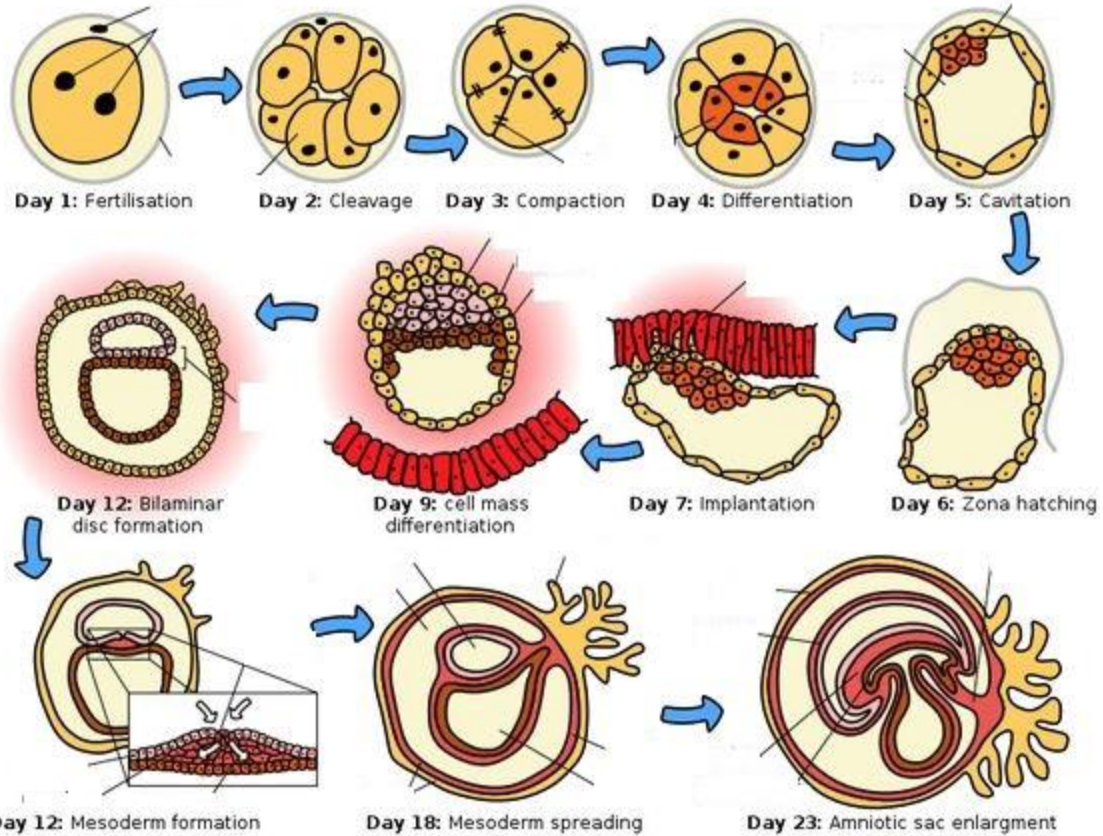


Akrozomová a kortikální reakce

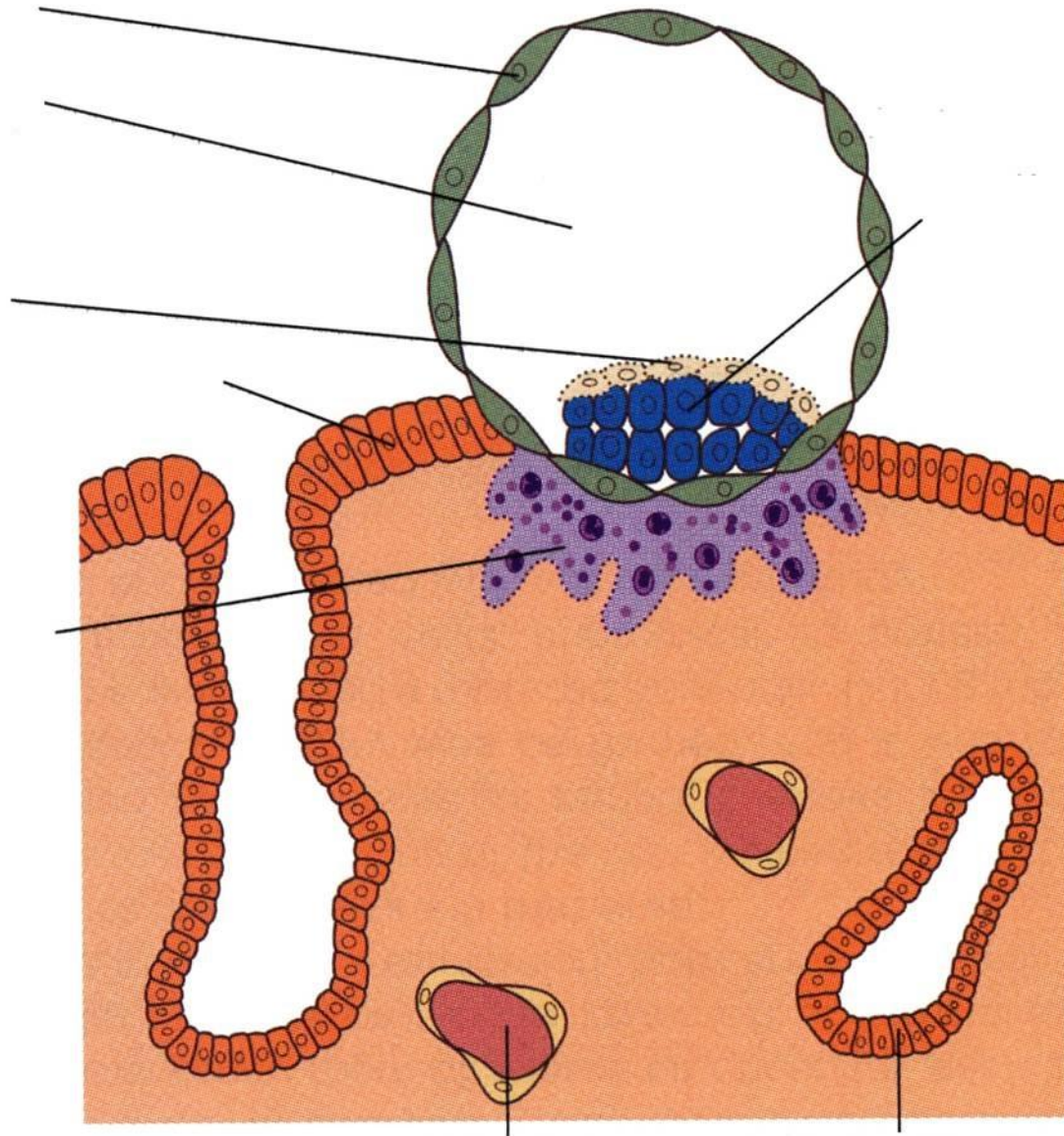


Časný vývoj embra (od ovulace k implantaci)

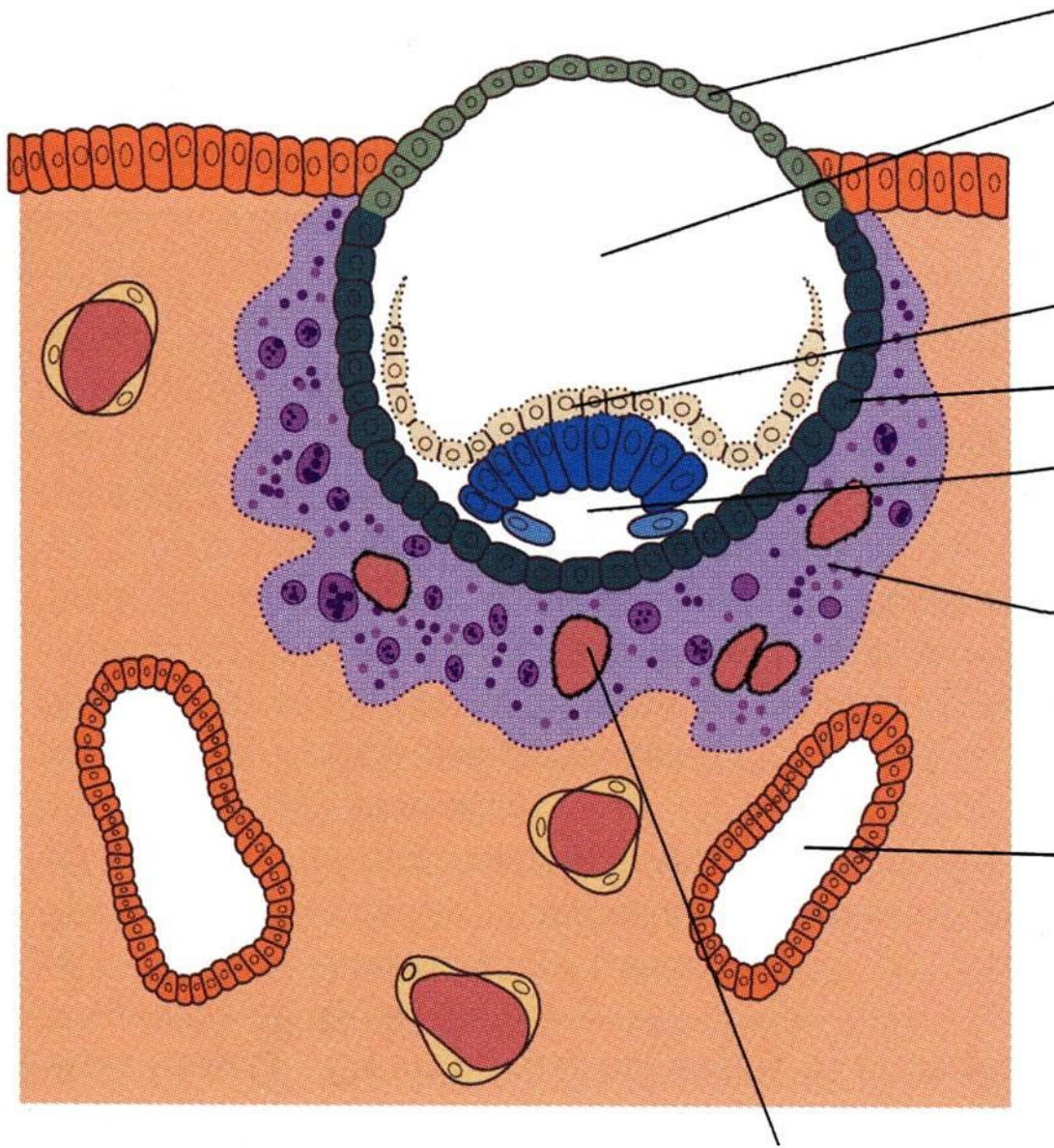




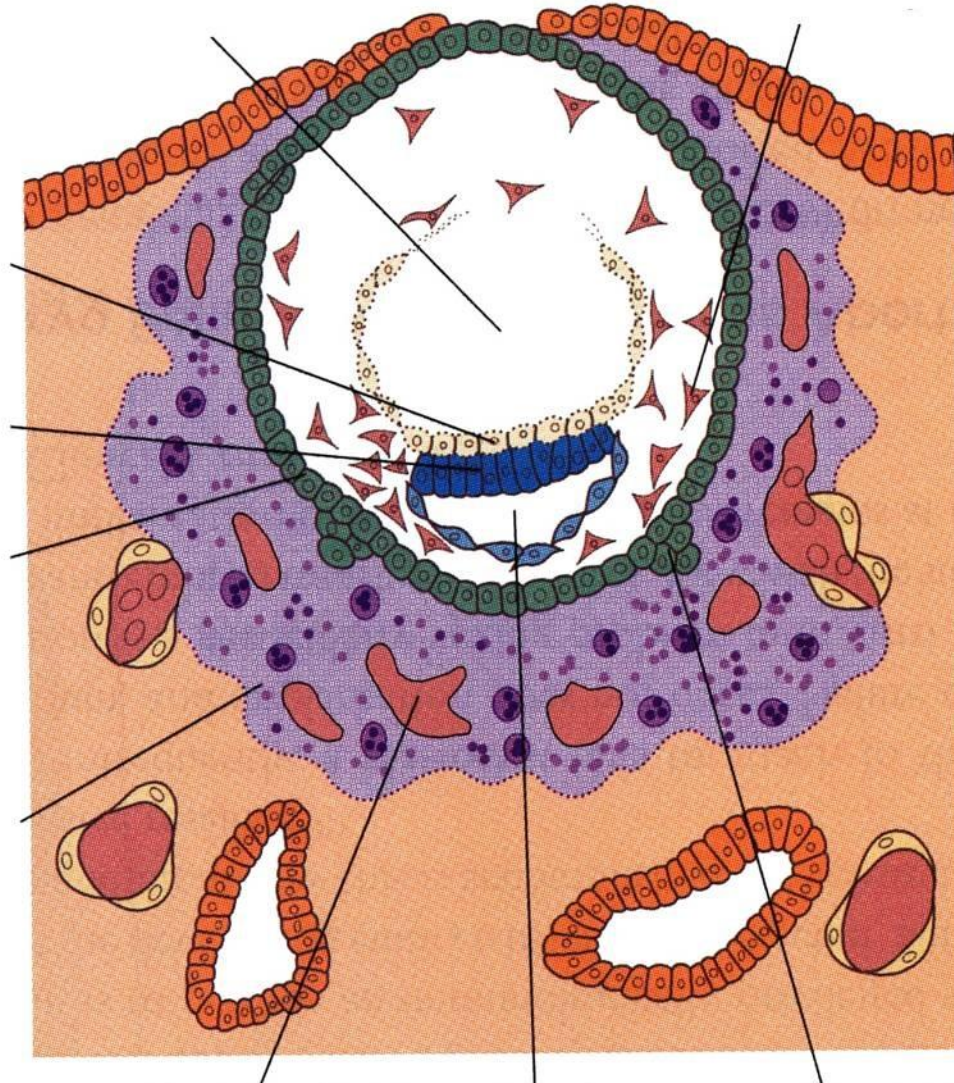
IMPLANTACE - začátek 7. dne



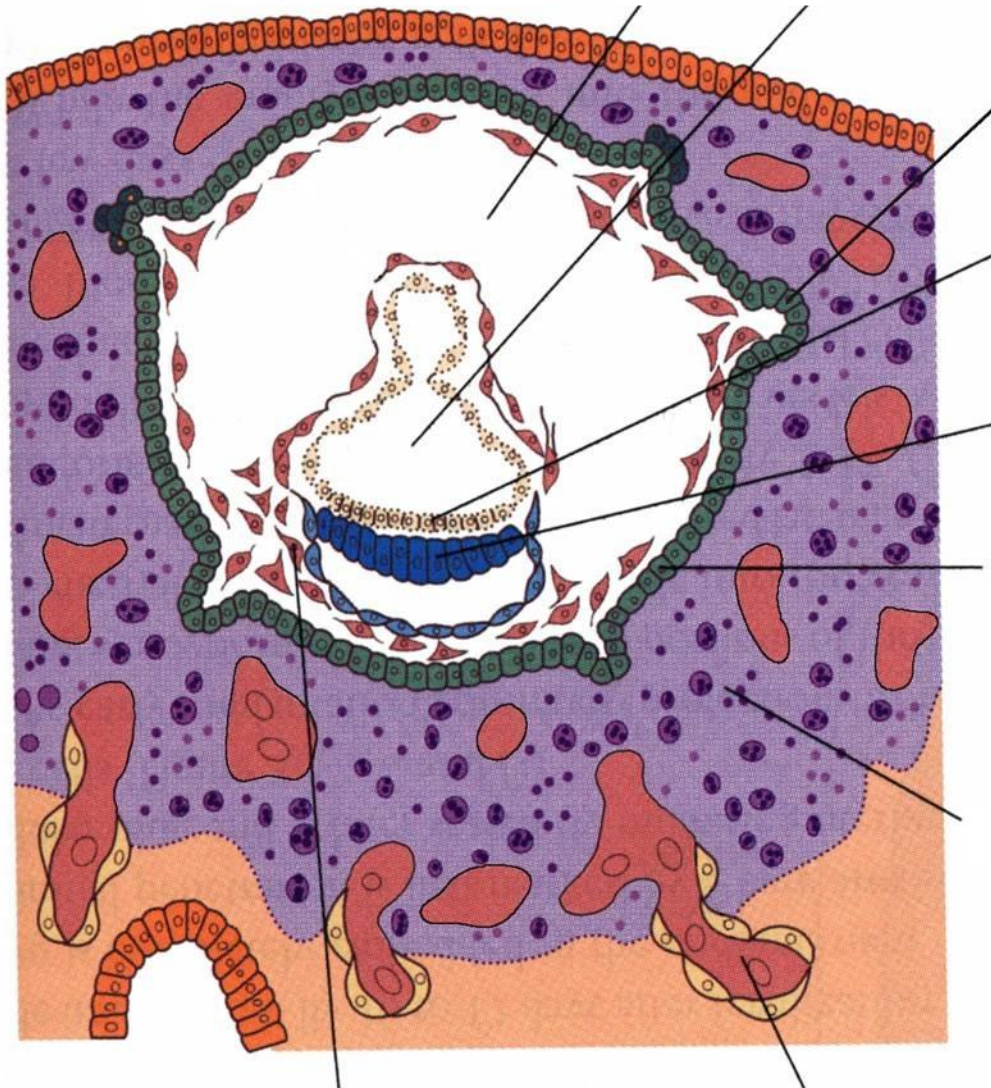
IMPLANTACE - 8 1/2 dne

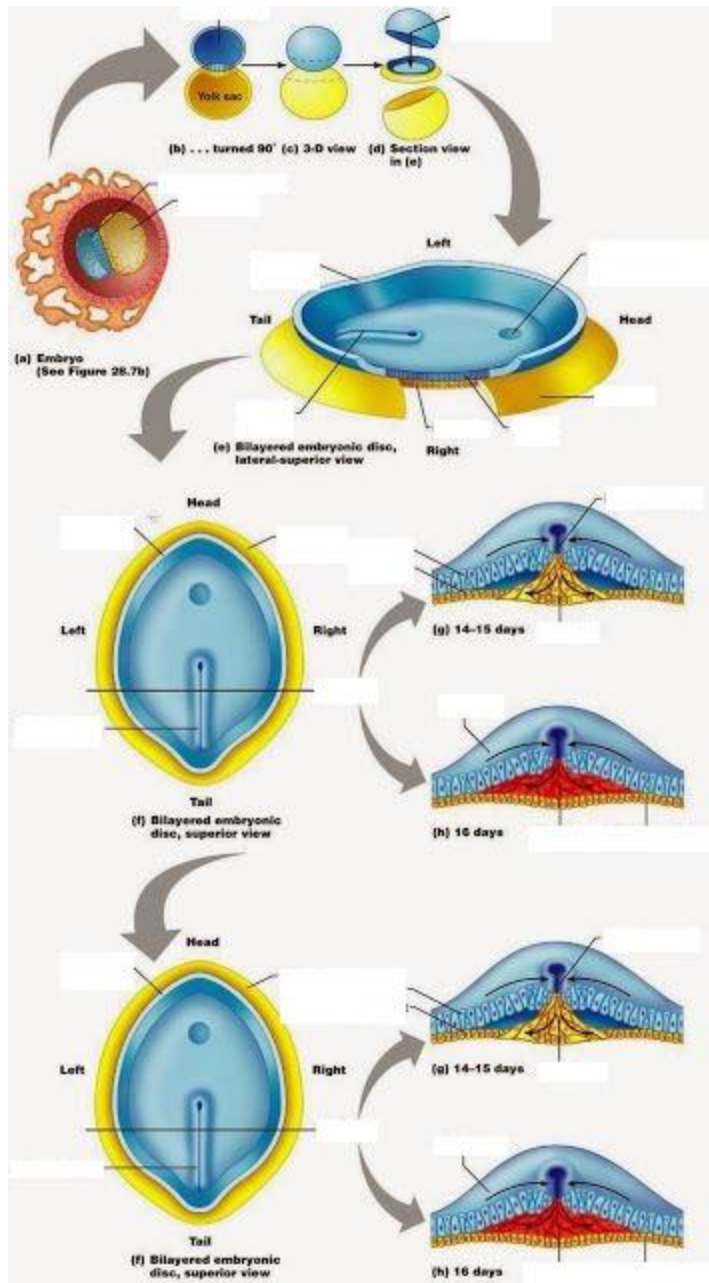


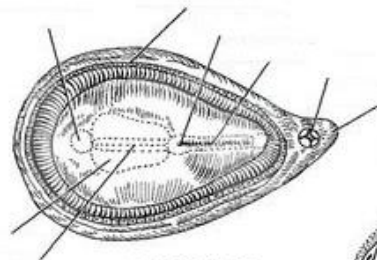
IMPLANTACE - 10. den



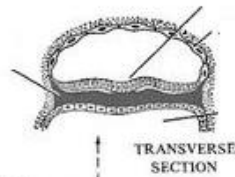
IMPLANTACE - 13. den



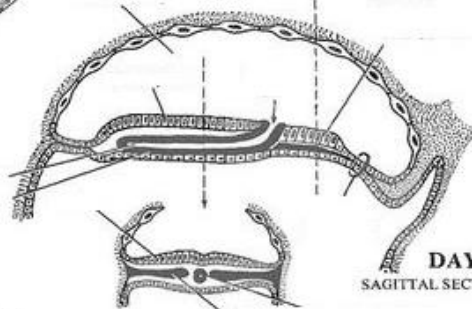




DAYS 17-18
DORSAL VIEW

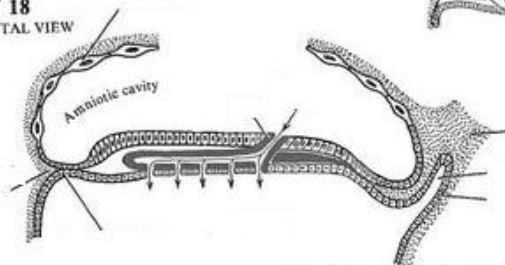


TRANSVERSE SECTION

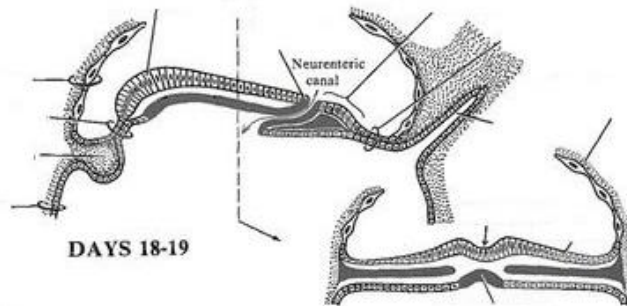


DAY 18
SAGITTAL SECTION

DAY 18
SAGITTAL VIEW



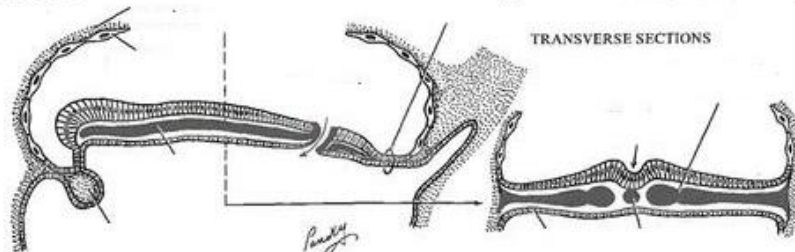
Amniotic cavity



Neurenteric canal

DAYS 18-19

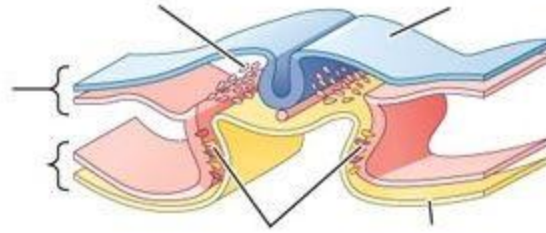
DAYS 19-20



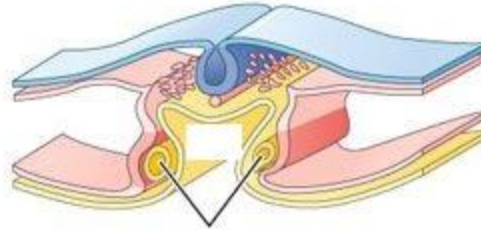
TRANSVERSE SECTIONS

Handwritten signature

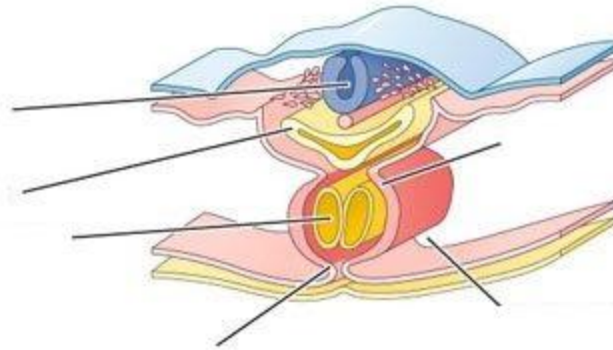
(A)



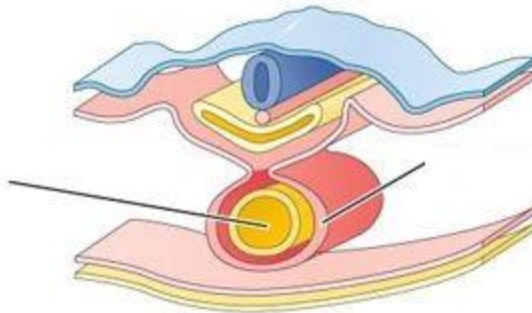
(B)



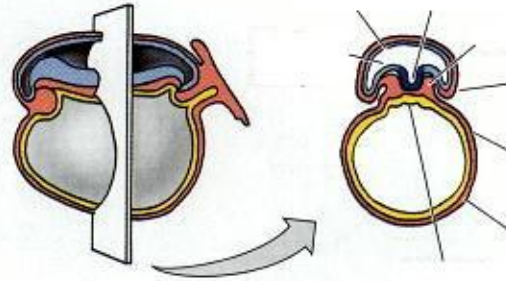
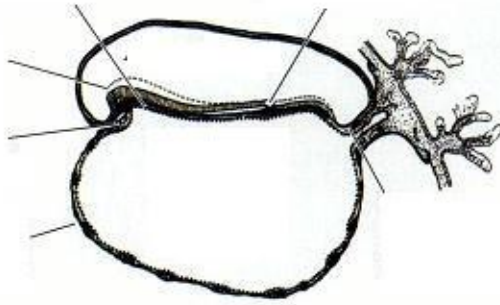
(C)



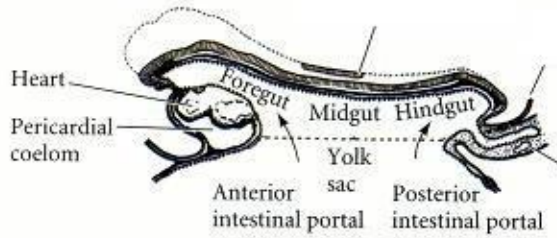
(D)



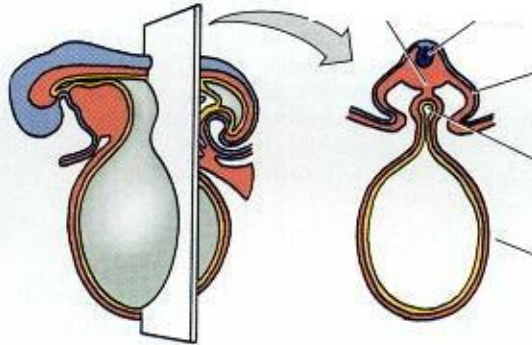
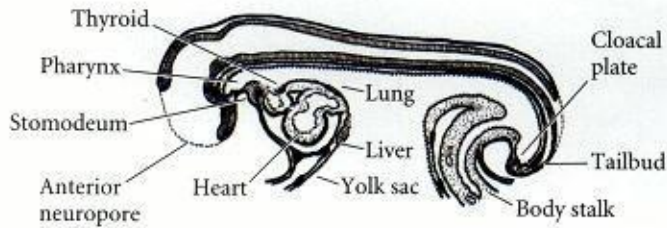
(A) 16 DAYS



(B) 18 DAYS



(C) 22 DAYS



(D) 28 DAYS

