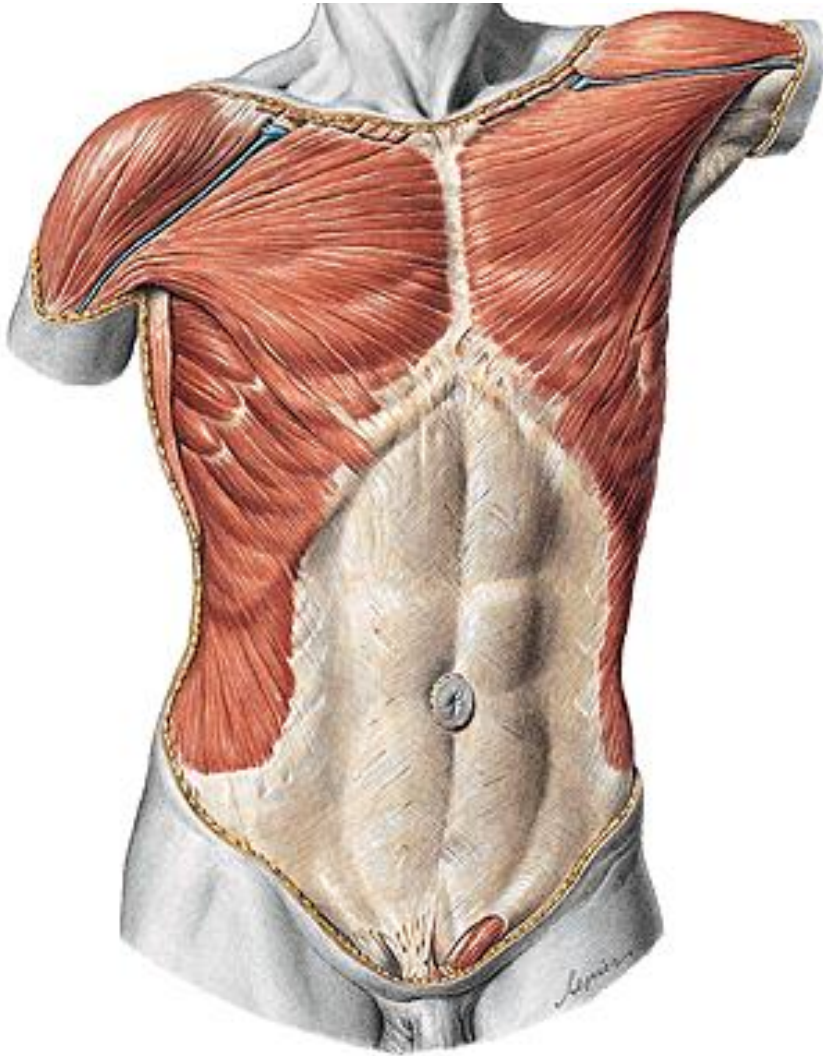
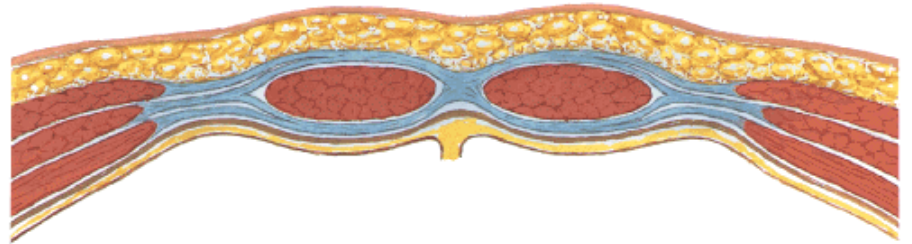


Klinická anatomie břicha

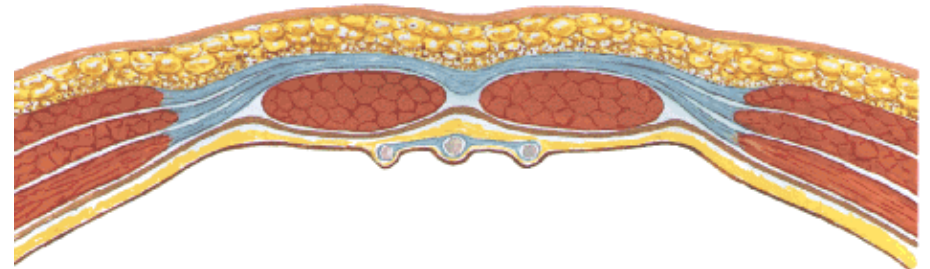
Stavba břišní stěny



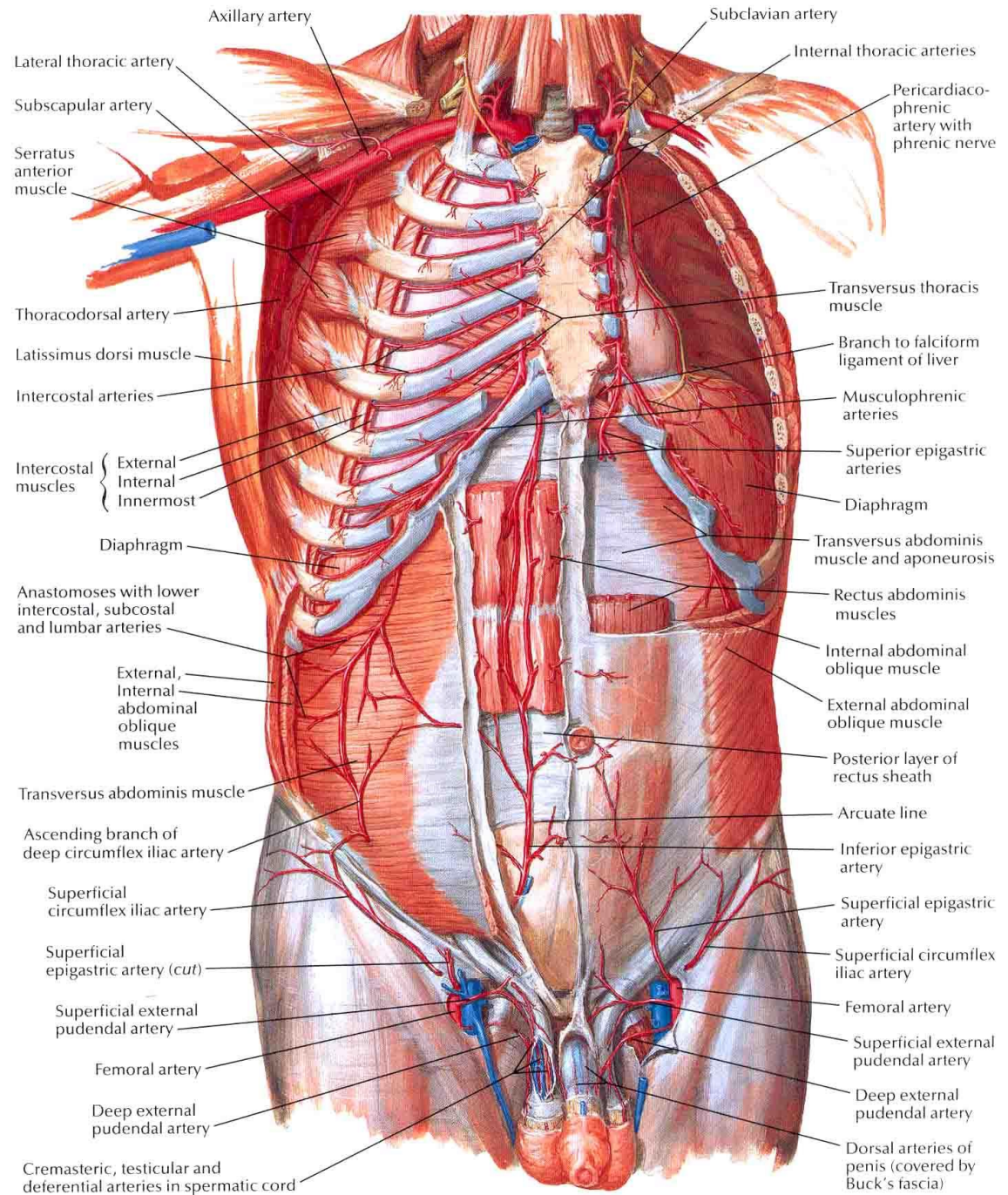
Nad linea semilunaris (horní 2/3)



Pod linea semilunaris (dolní 1/3)



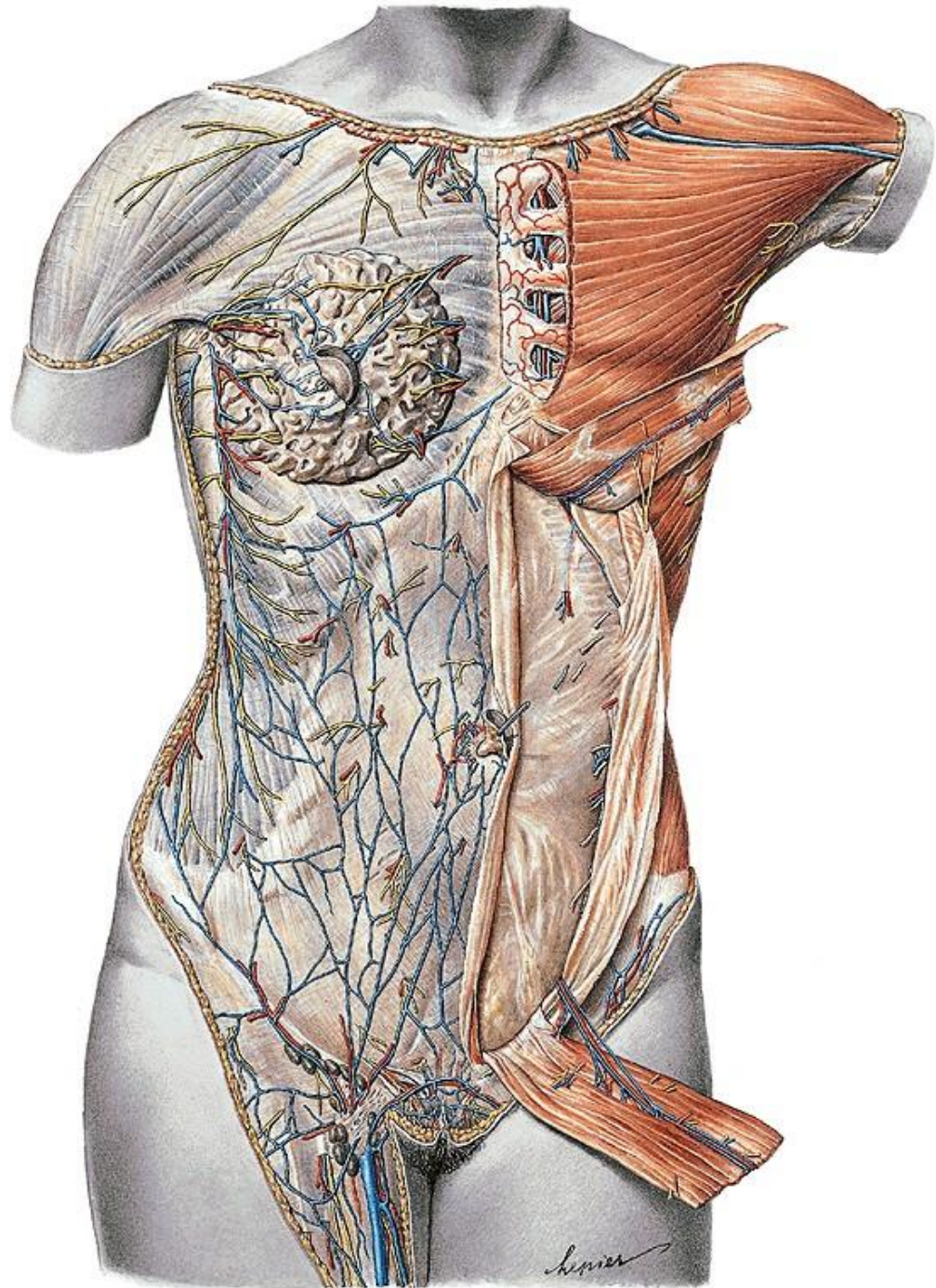
Tepny břišní stěny



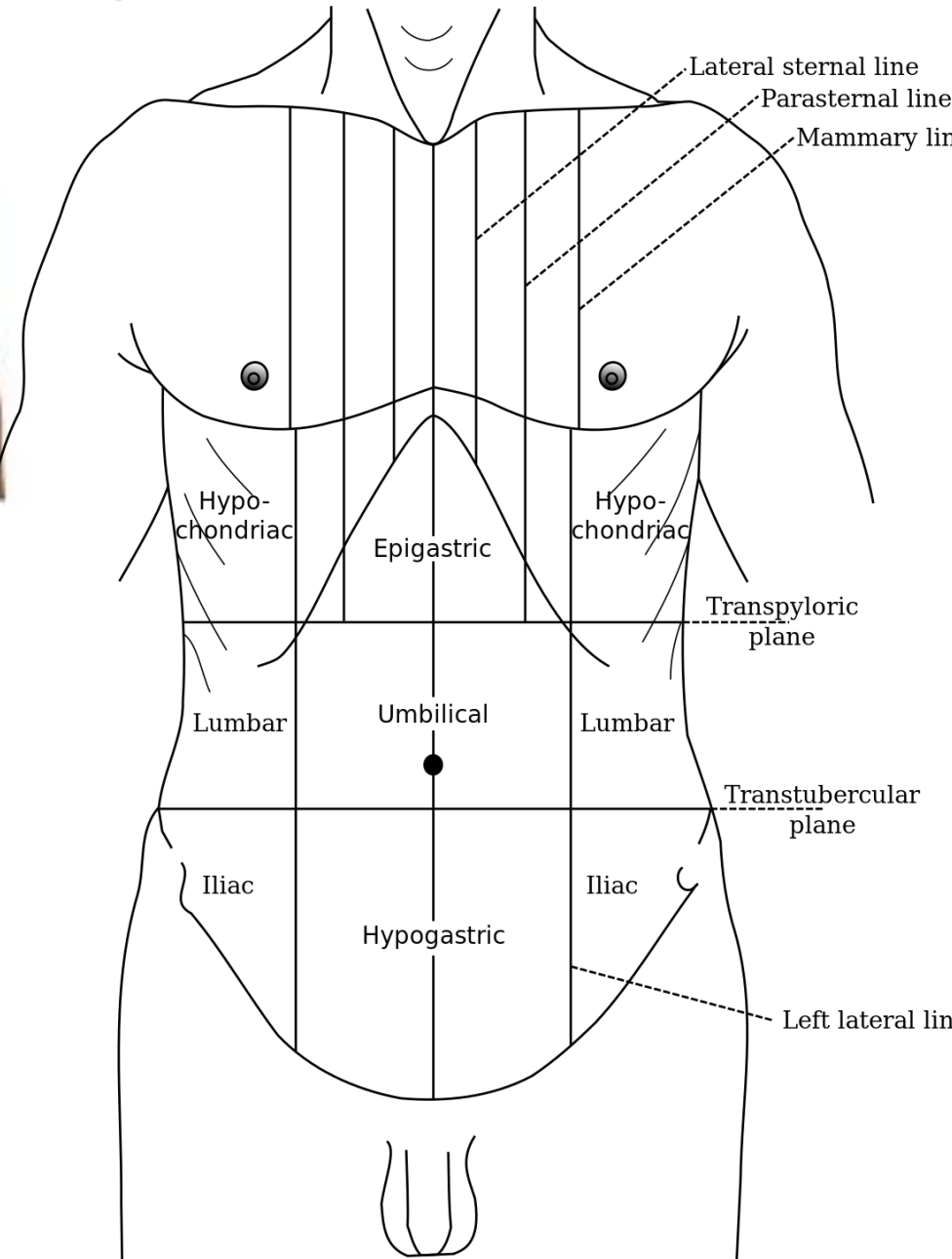
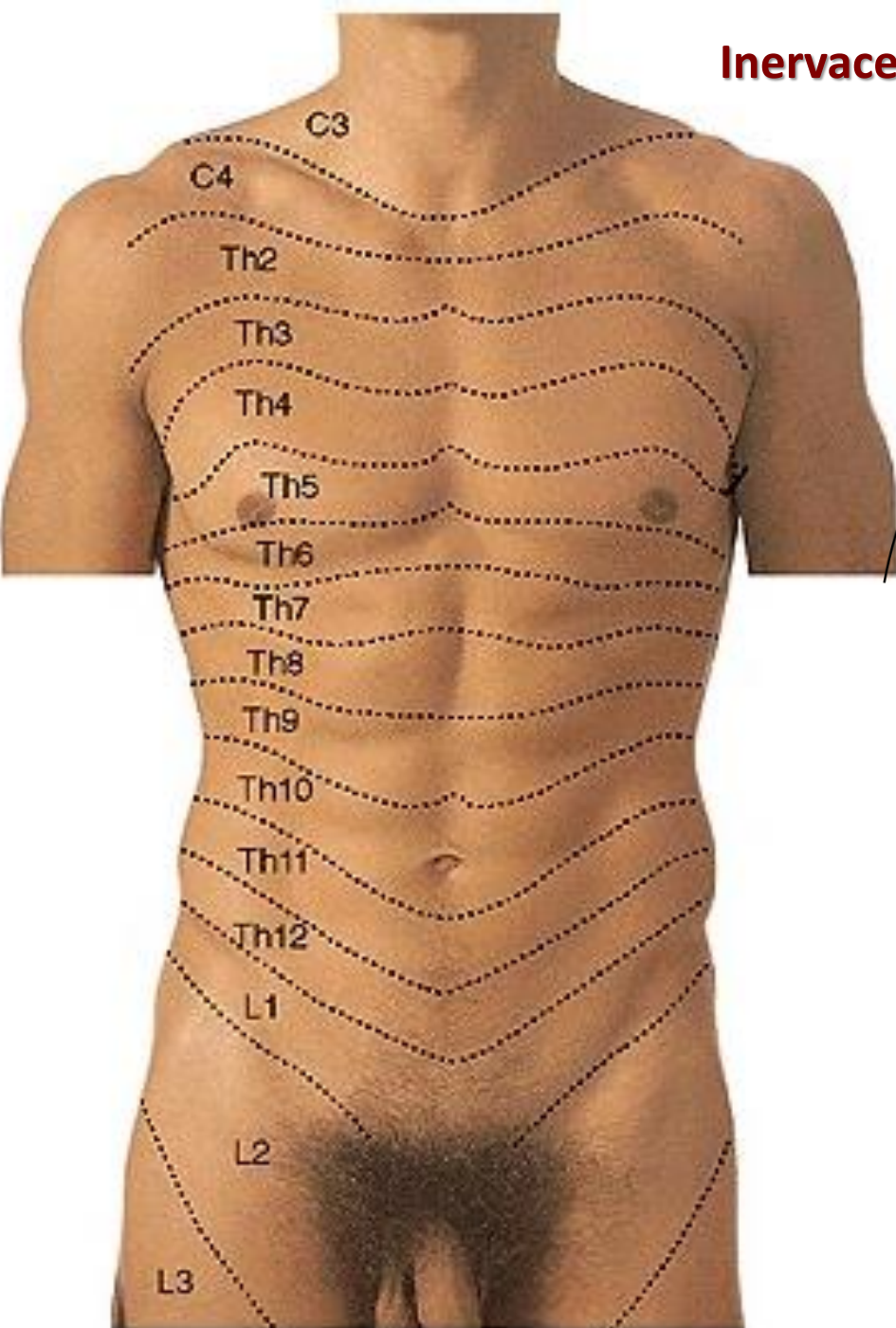
- aa. intercostales
- a. epigastrica spf.
- a. circumflexa ilium spf.
- a. epigastrica sup.
- a. epigastrica inf.

Žíly břišní stěny

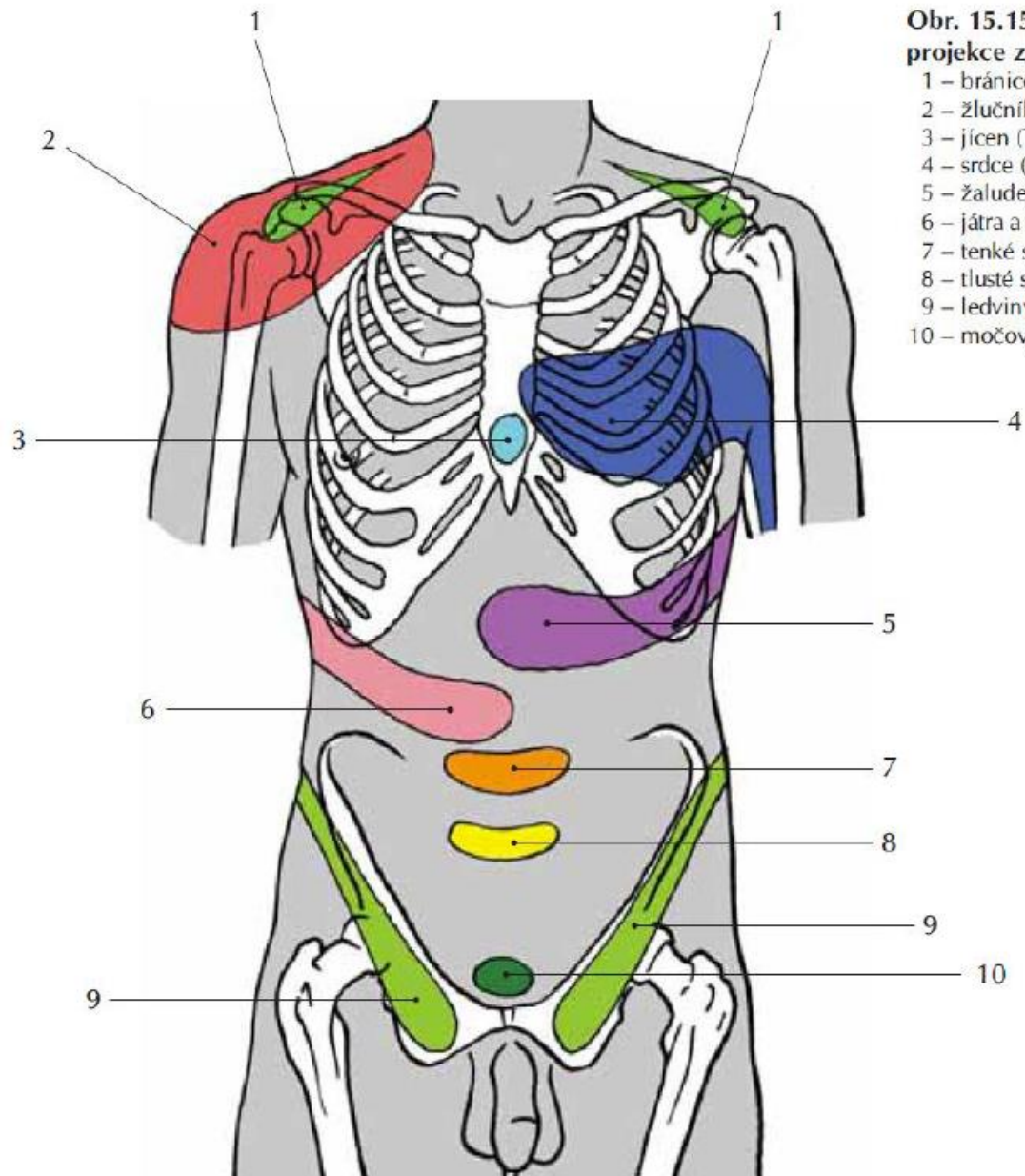
- v. thoracica lateralis
- v. thoracoepigastrica
- vv. paraumbilicales
- v. epigastrica superficialis
- v. circumphlexa ilium spfc.
- Kavo-kavální anastomosisy
- Porto-kavální anastomosisy



Inervace stěny břišní



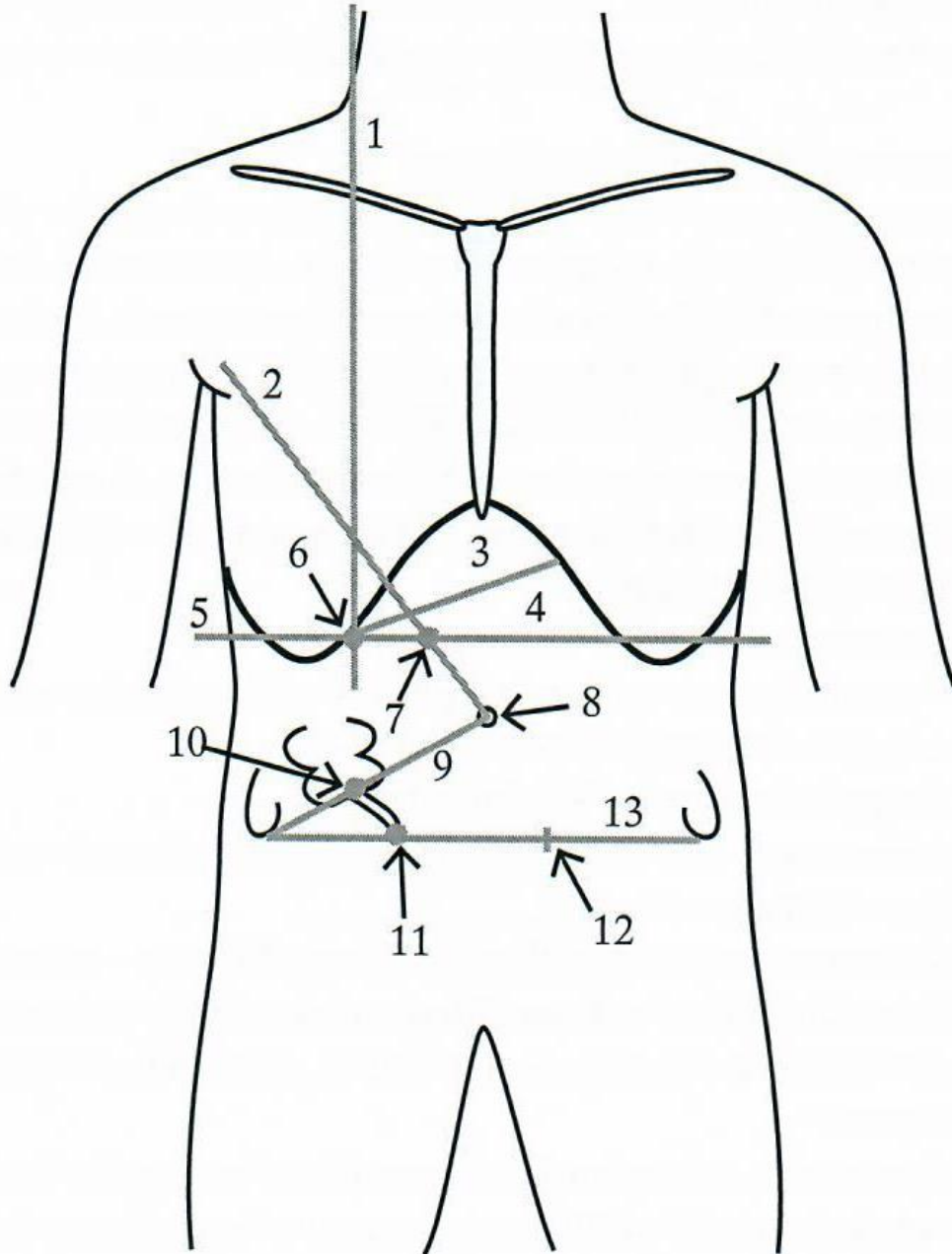
Headovy zóny



Obr. 15.15. Headovy zóny, kožní projekce z vnitřních orgánů

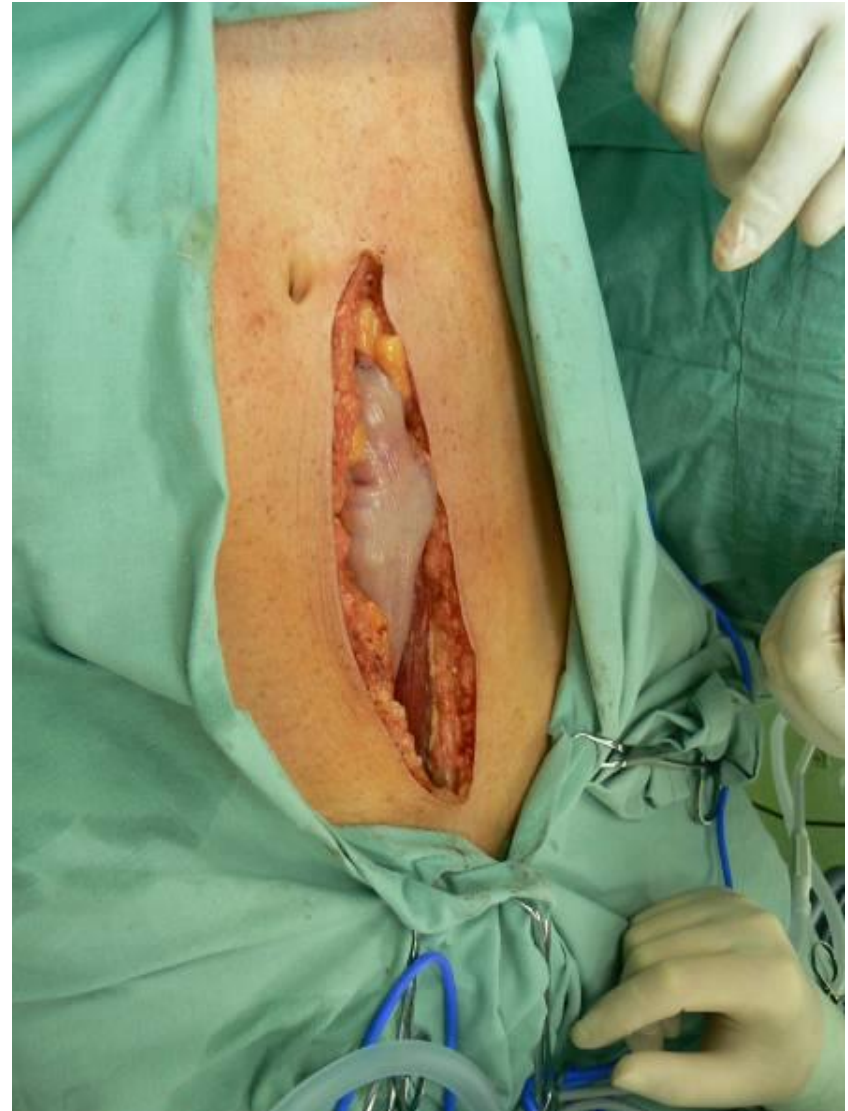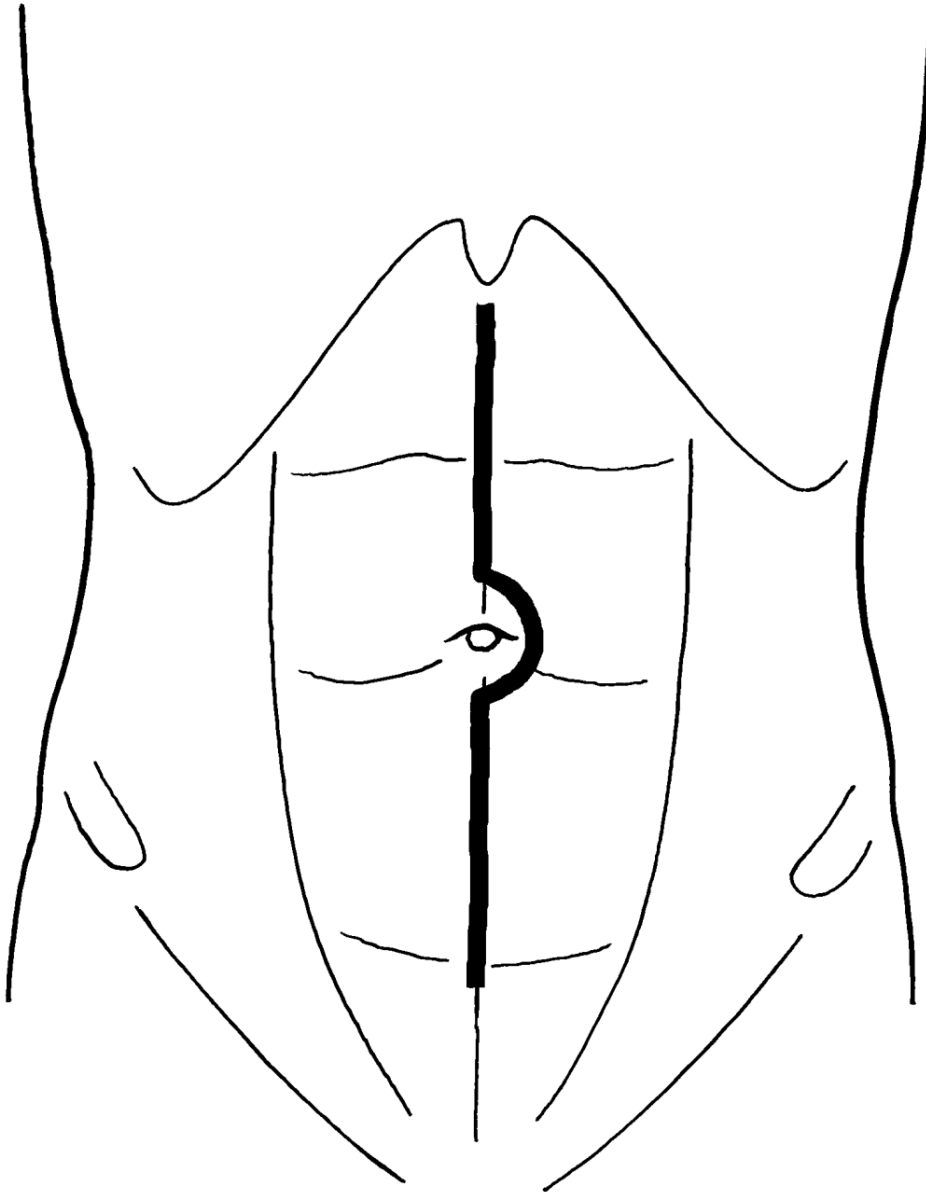
- 1 – bránice (C₄)
- 2 – žlučník (Th₉₋₁₁)
- 3 – jícen (Th₄₋₅)
- 4 – srdce (Th₃₋₄)
- 5 – žaludek (Th₆)
- 6 – játra a žlučové cesty (Th₉₋₁₁)
- 7 – tenké střevo (Th₁₀)
- 8 – tlusté střevo (Th₁₁-L₁)
- 9 – ledviny, varle (Th₁₀-L₁)
- 10 – močový měchýř (Th₁₁-L₁)

Projekce orgánů

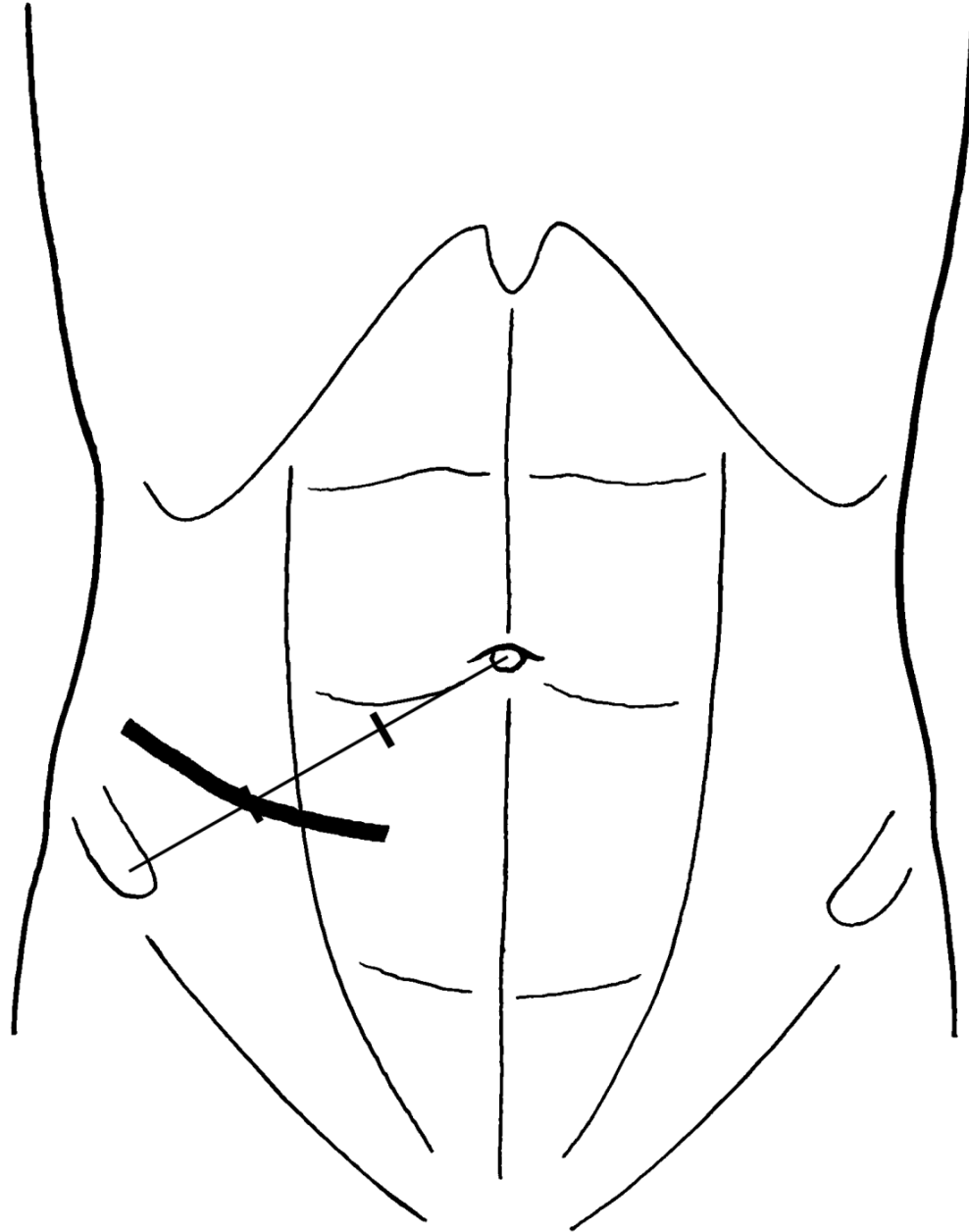


- 1 medioklavikulární čára
- 2 Pravá umbilikoaxilární čára
- 3 Projekce jater
- 4 Labbeův trojúhelník
- 5 Transpylorická čára
- 6 Murphyho bod
- 7 Désjardinsův pankreatický bod
- 8 Umbilicus
- 9 Monroova čára
- 10 MacBurneyův bod
- 11 Lanzův bod
- 13 Bispinální čára

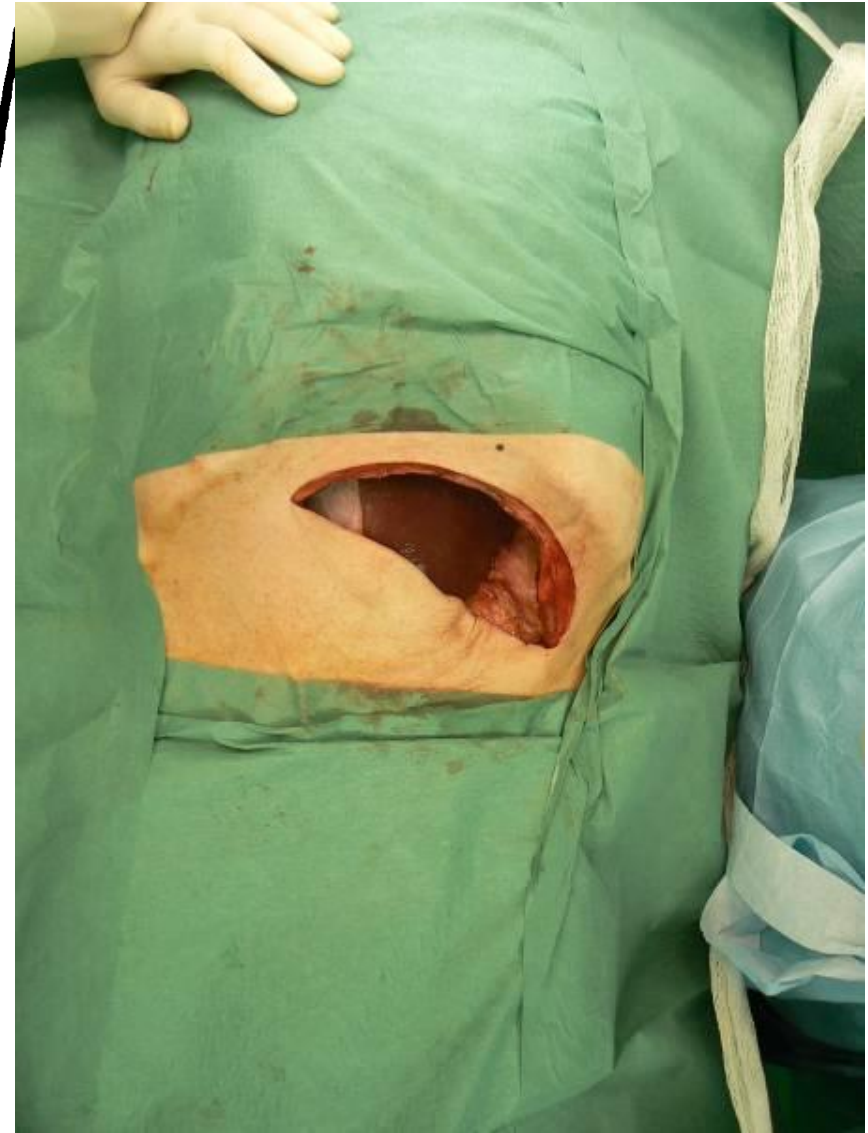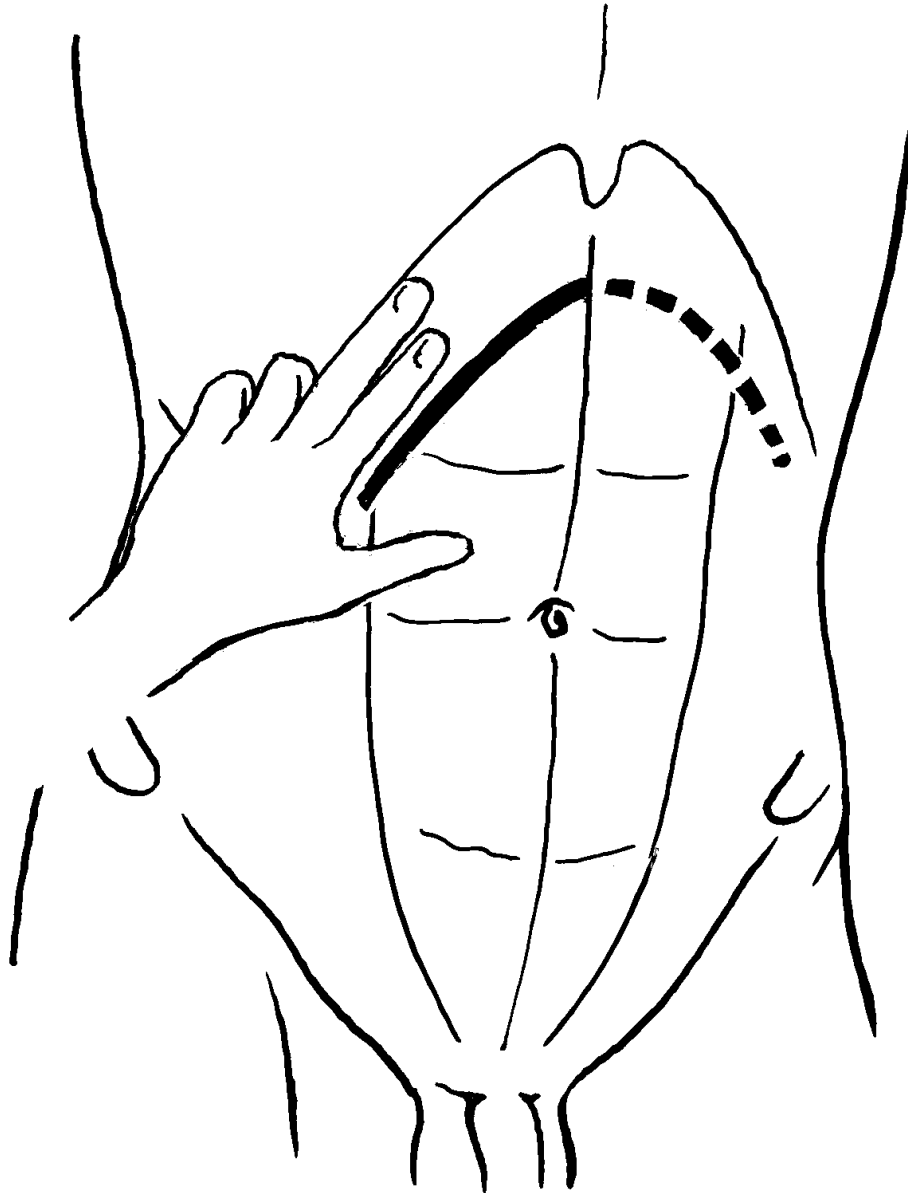
Střední laparotomie a pararektální řez



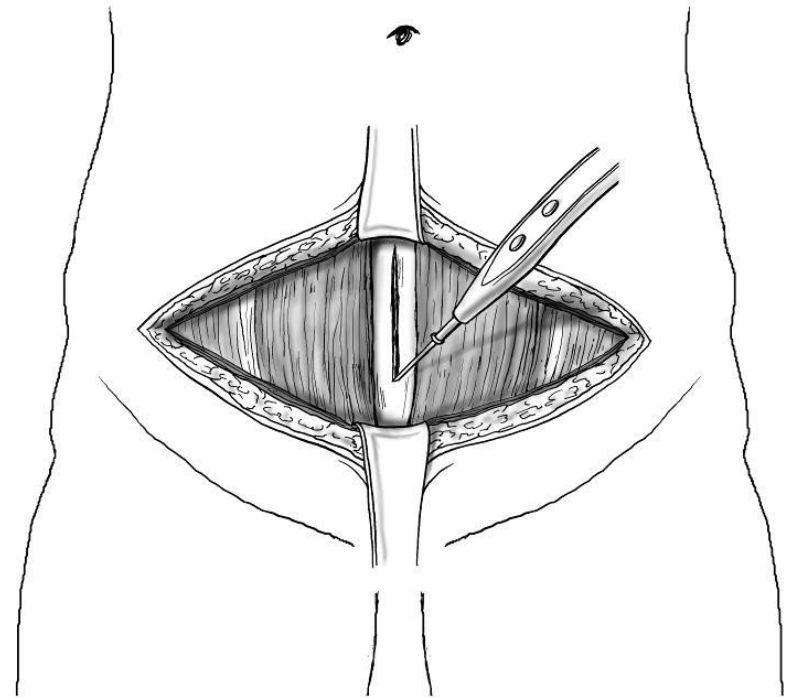
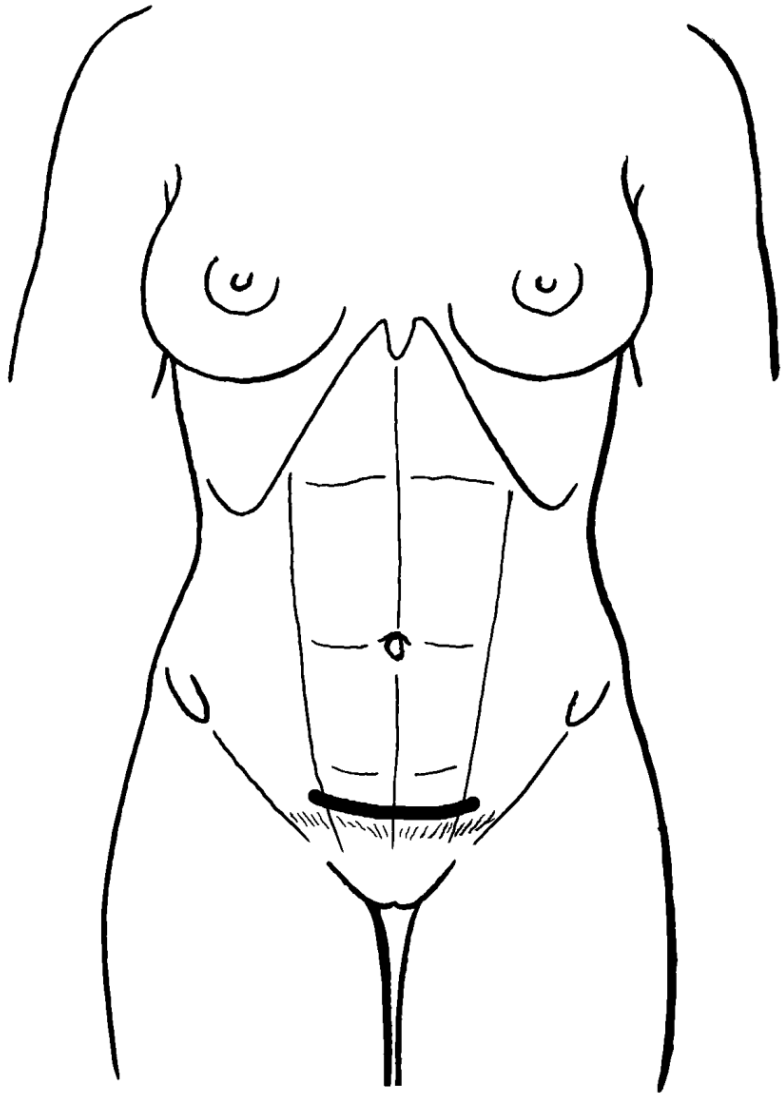
Střídavý řez



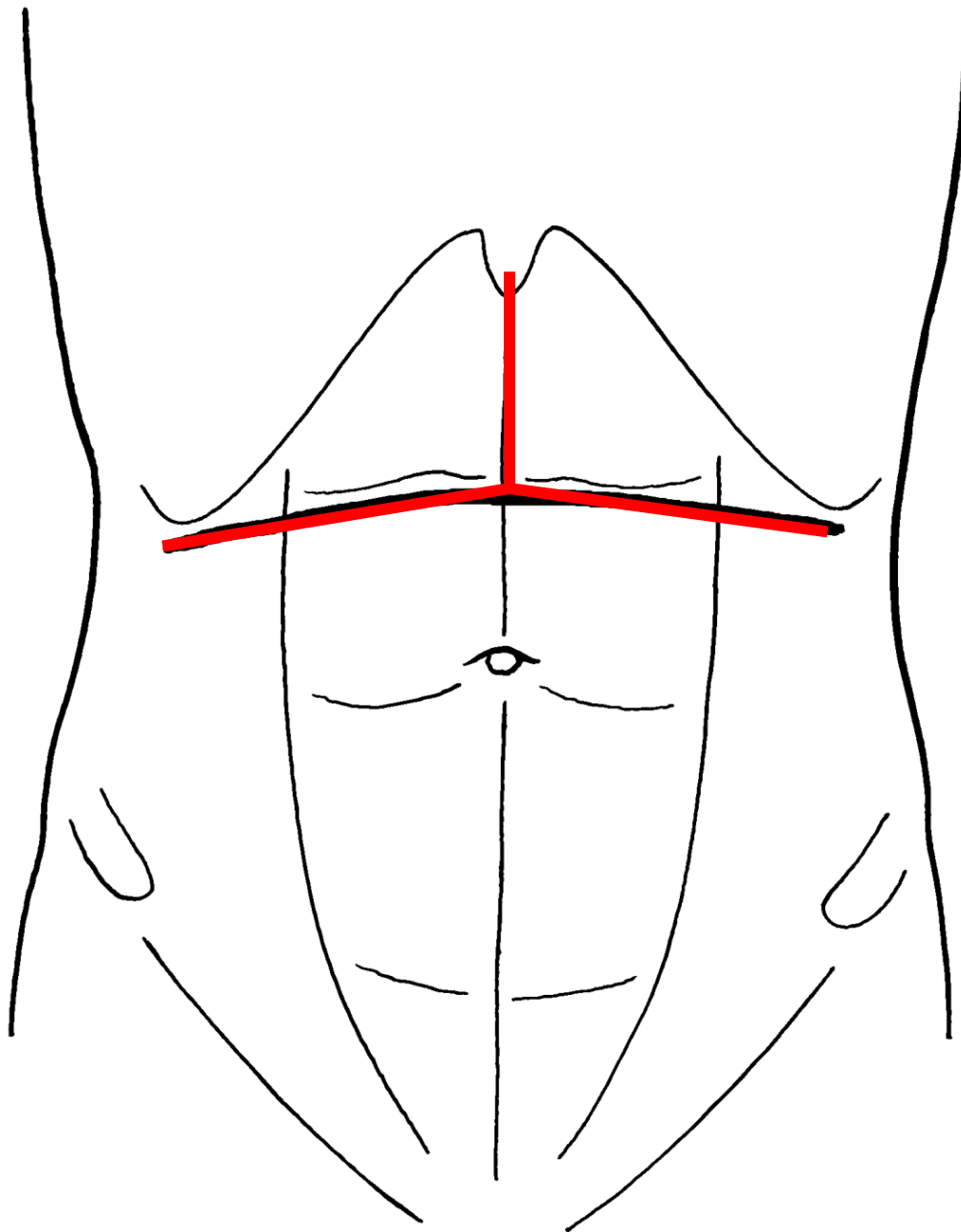
Subkostální řez



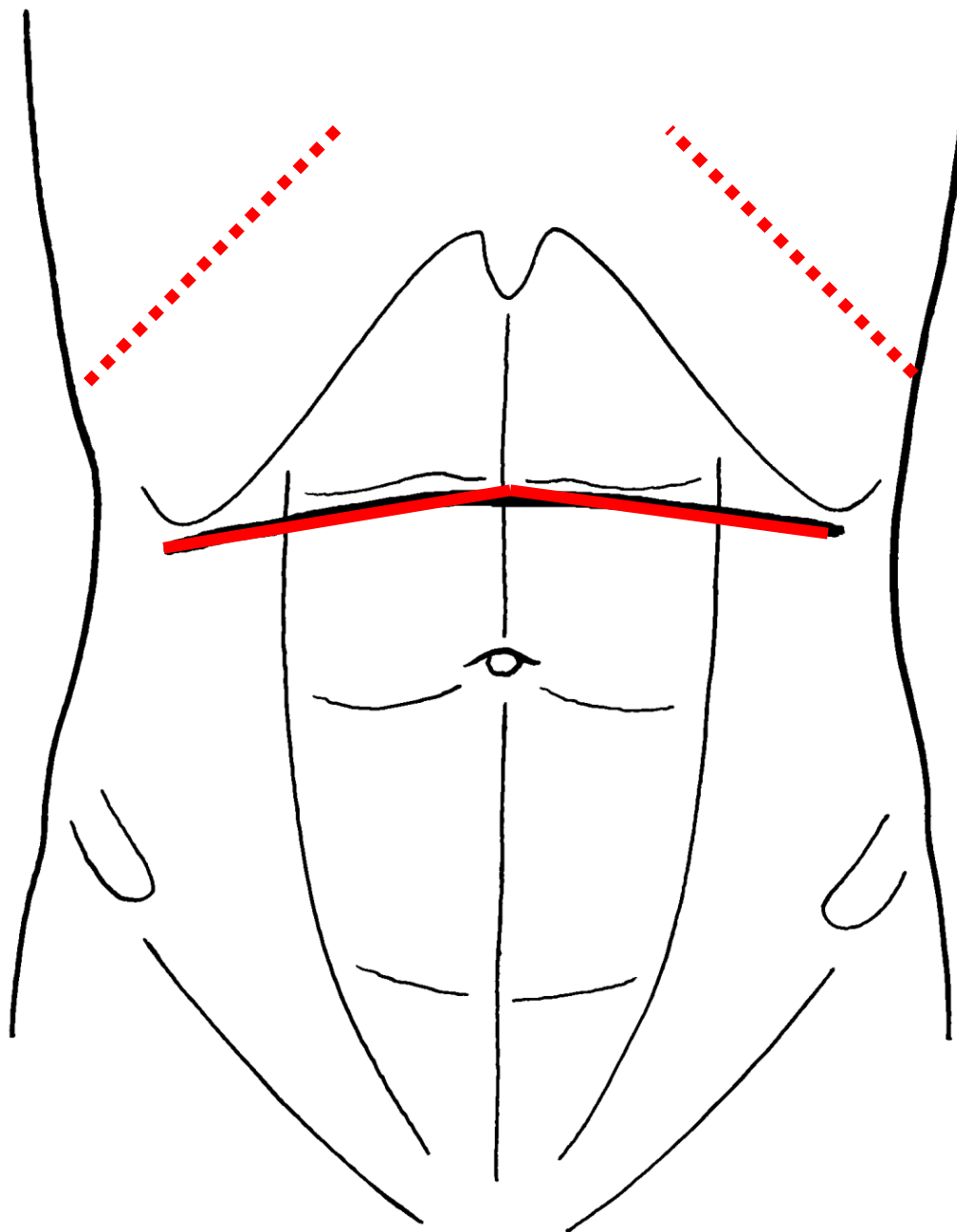
Phannenstiélův řez



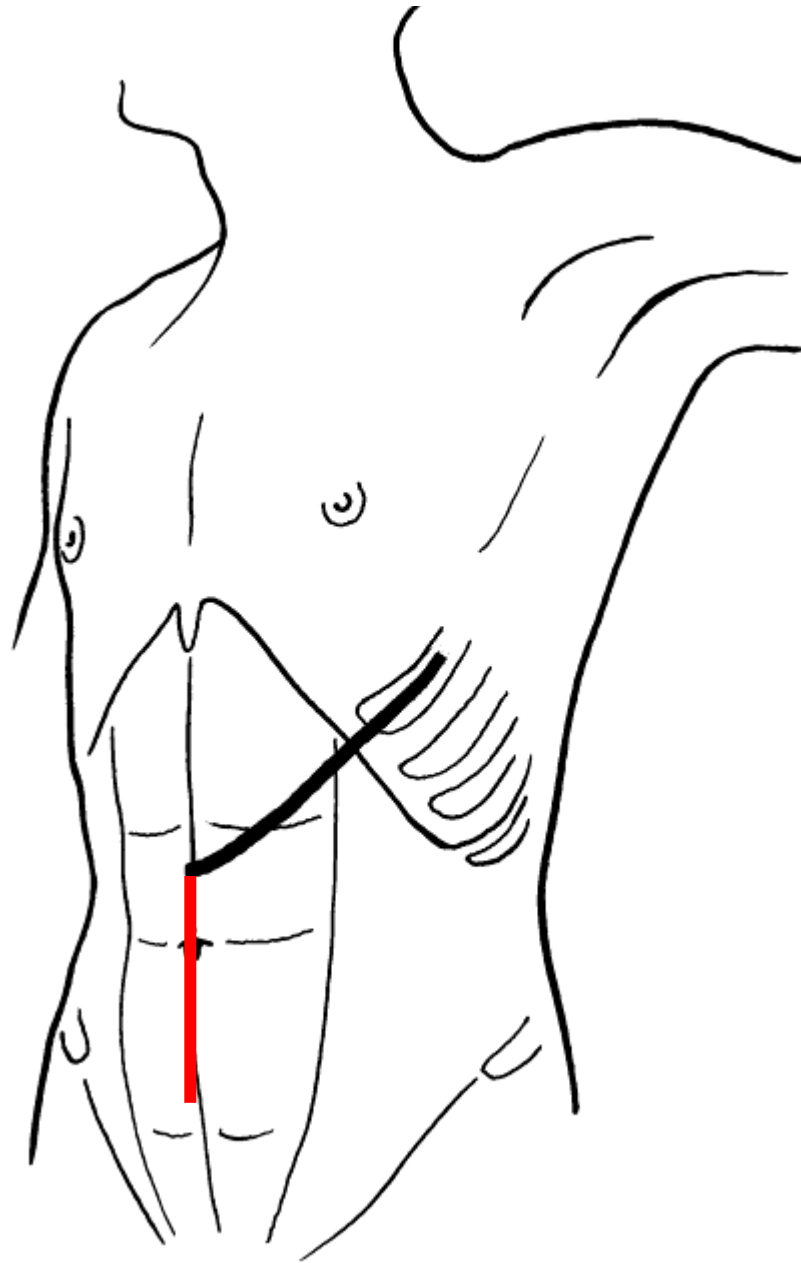
Mercedes-Benz Stern řez



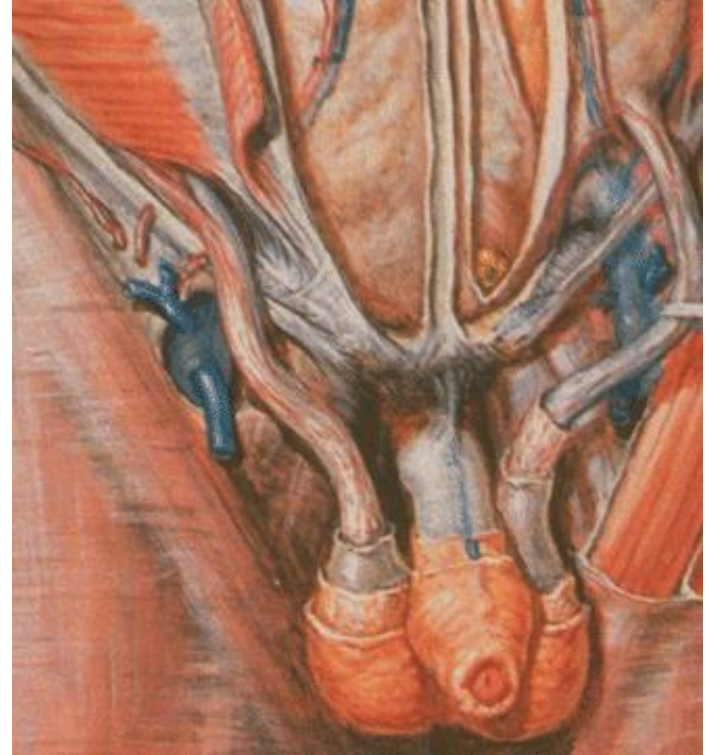
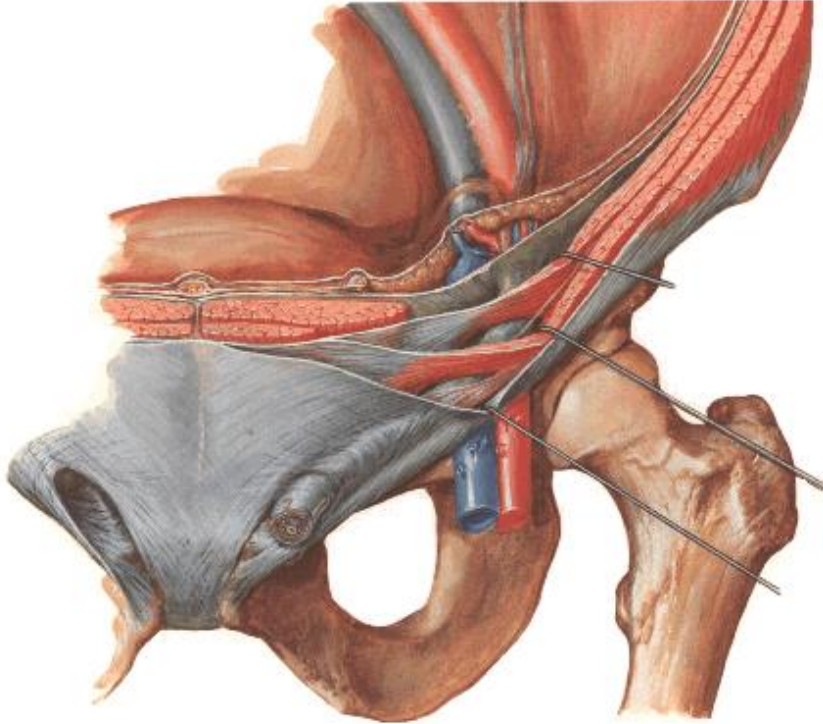
Příčný řez a posterolaterální thorakotomie



Střední laparotomie a frenikotomie



Canalis inguinalis



Přední stěna: aponeuróza m. obliquus externus

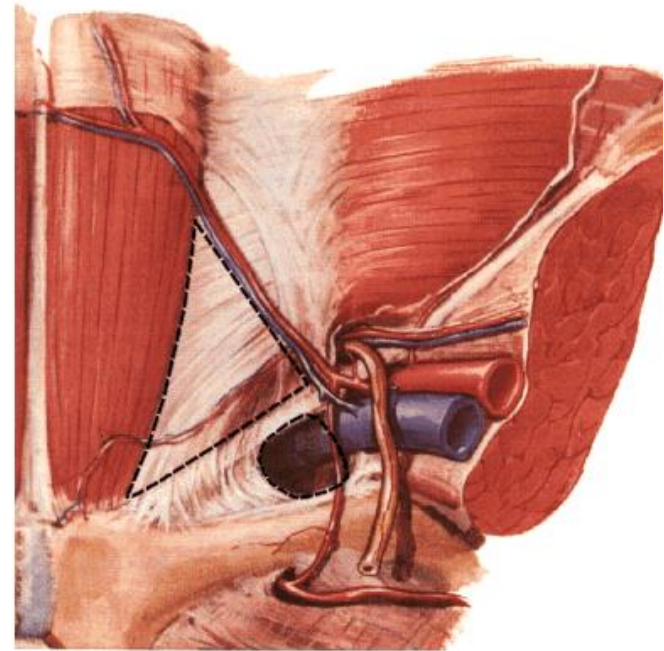
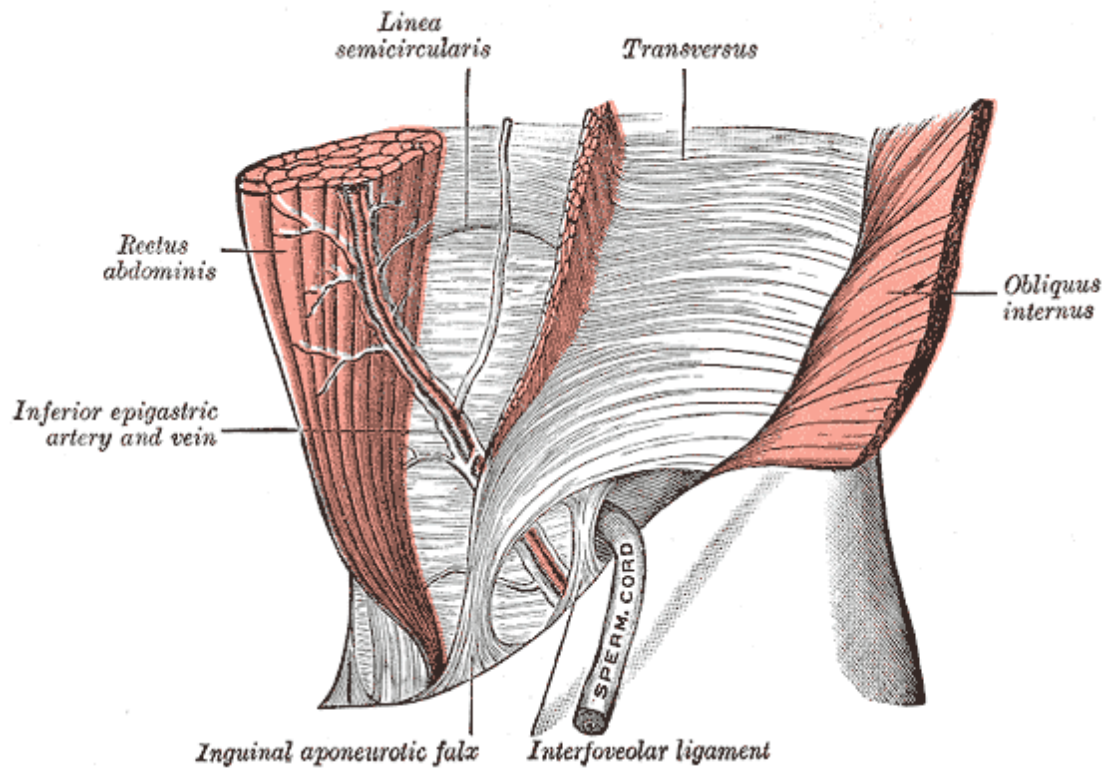
Horní stěna: okraj musculus obliquus int. abdominis a m. transversus abdominis

Dolní stěna: lig. inguinale

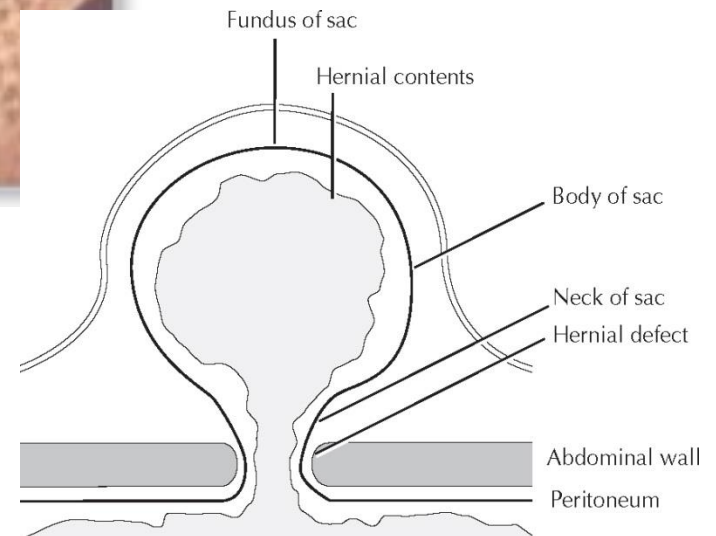
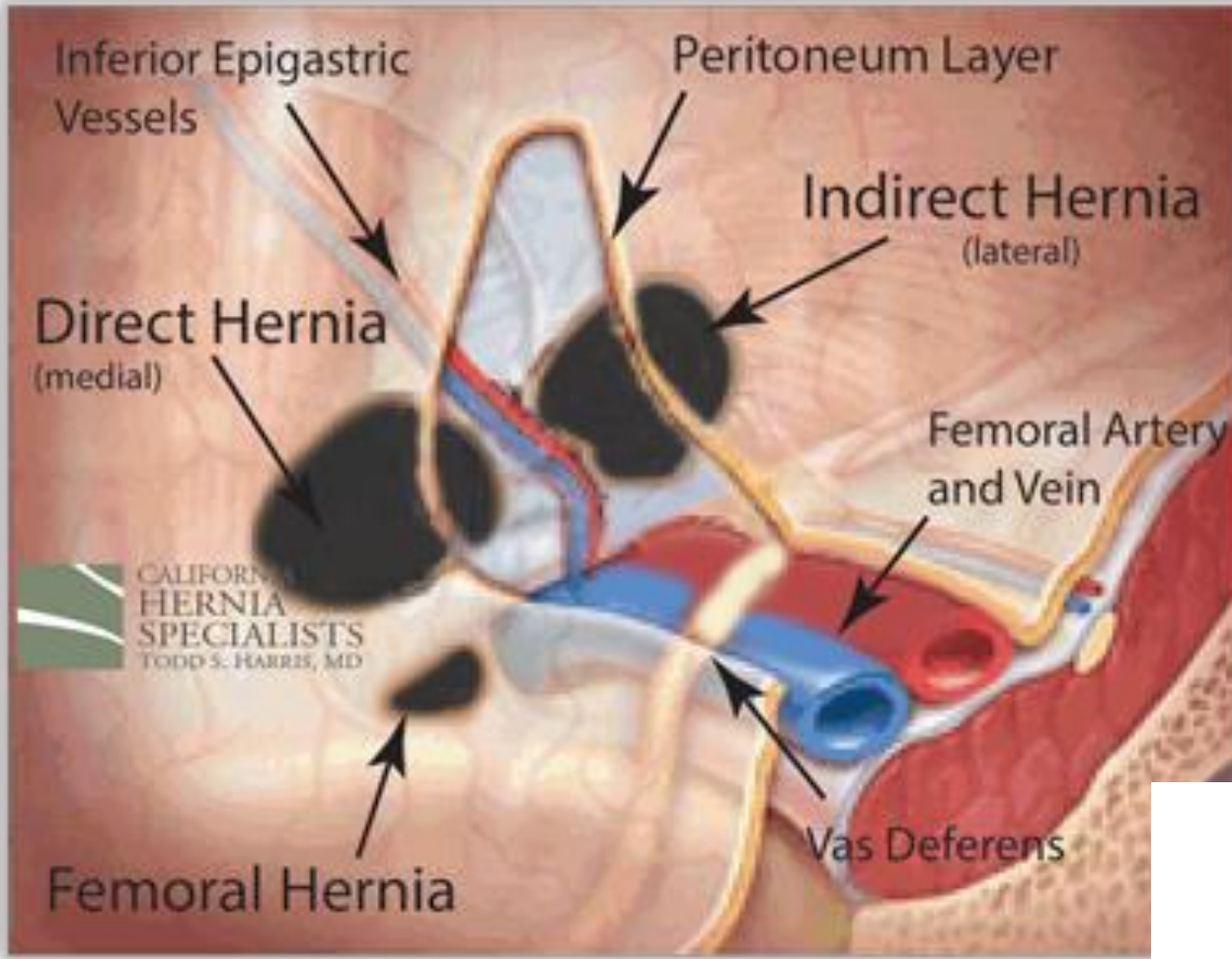
Zadní stěna: falx inguinalis

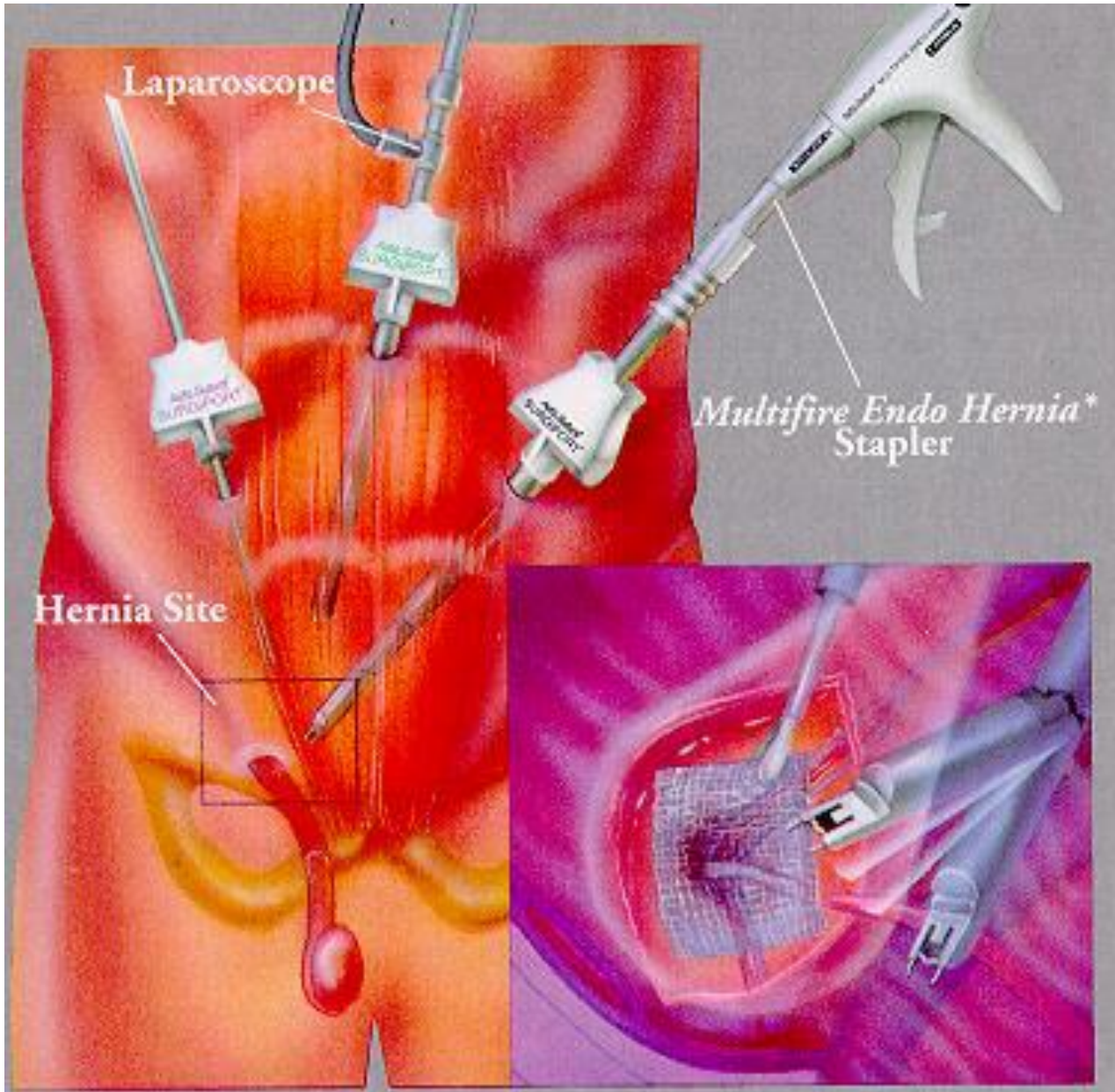lig. interfoveolare

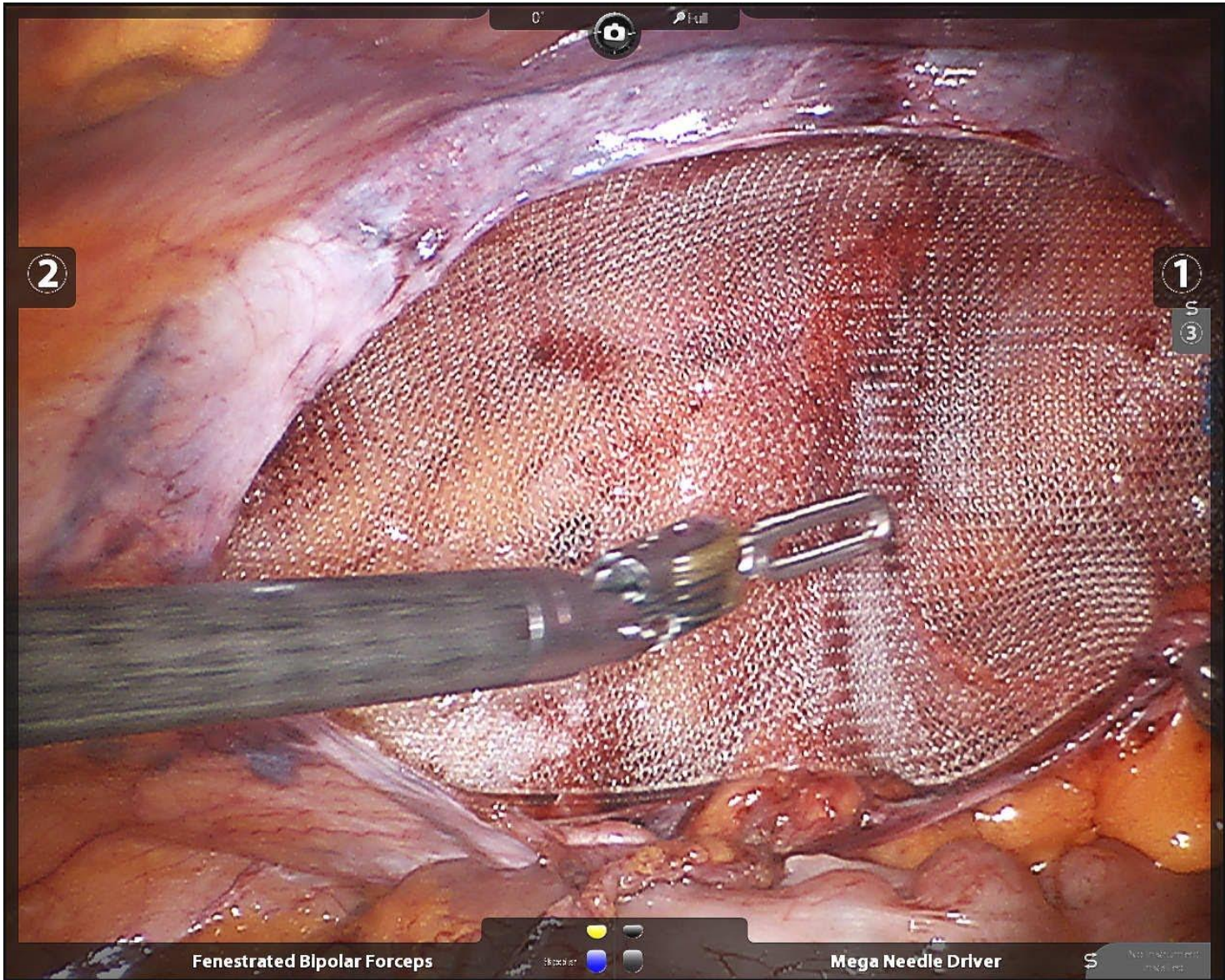
anulus inguinalis profundus



Inguinální hernie







2

1

3

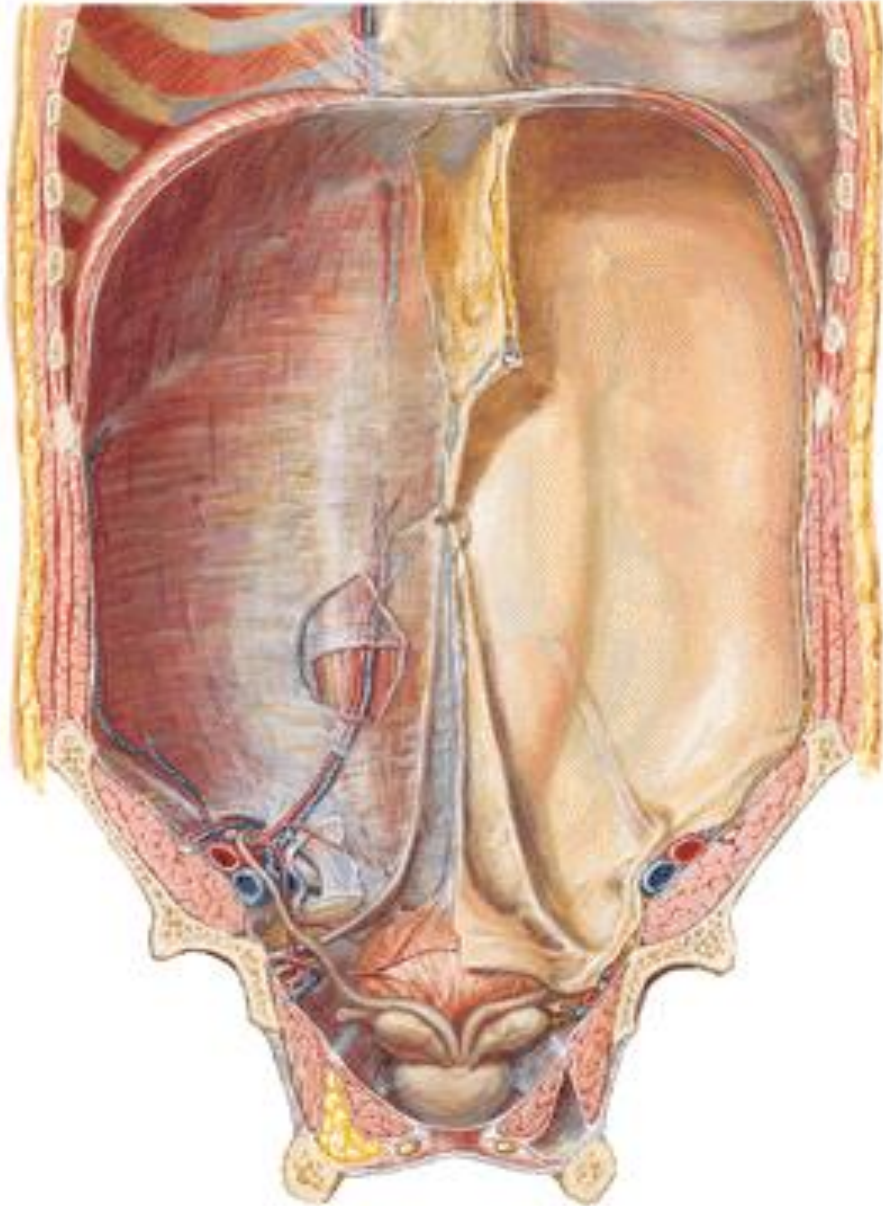
Fenestrated Bipolar Forceps

Skorpion

Mega Needle Driver

No instrument tracked

Umbilicus – pupeční jizva



Funiculus umbilicalis

aa. umbilicales (ligg. umbilicalia lat.)

v. umbilicalis (lig. teres hepatis)

urachus (lig. umbilicale mediale)

ductus omphaloentericus

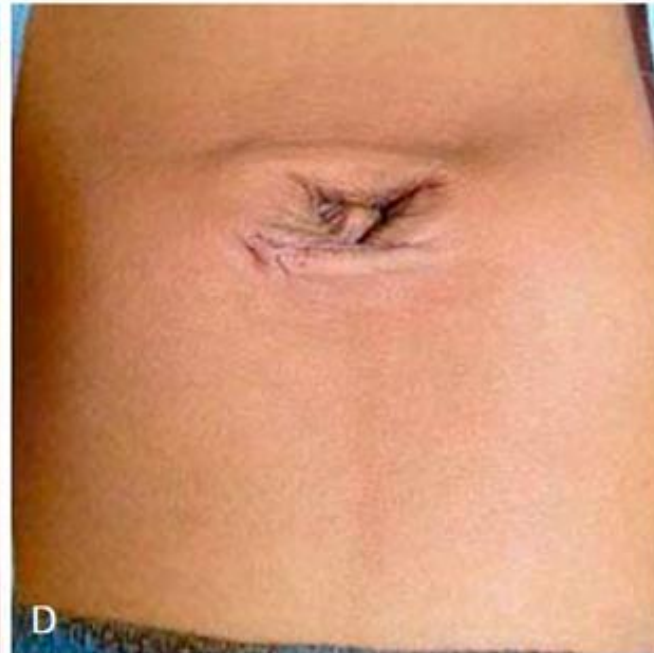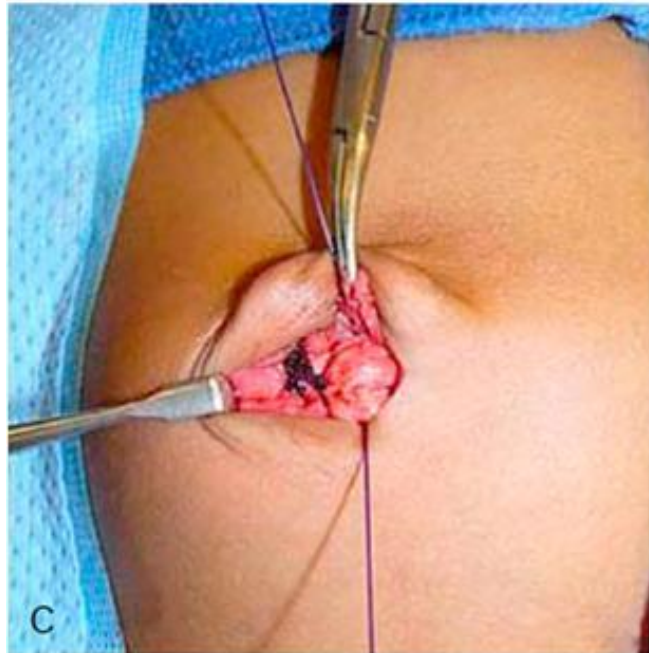
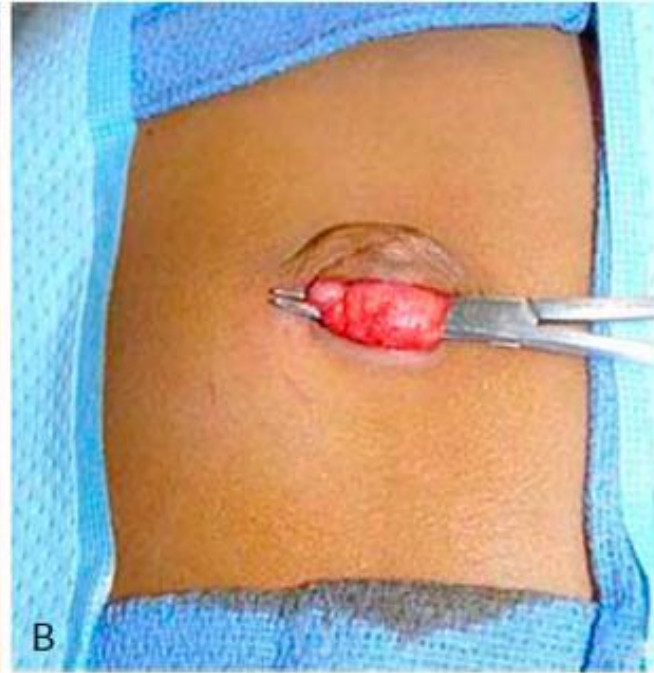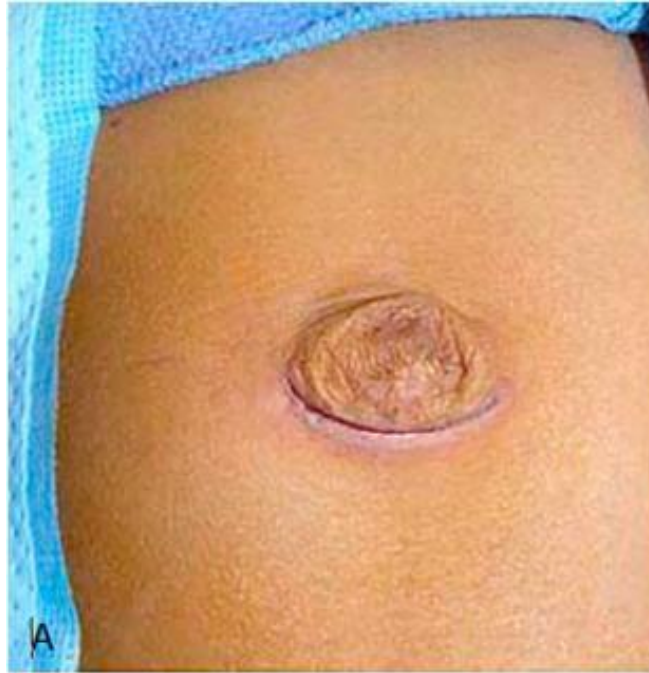**Plica umbilicalis mediana
(lig. umbilicale mediale)**

**Plicae umbilicales mediales
(ligg. umbilicalia lat.)**

**Plicae umbilicales laterales
(ligg. interfoveolaria)**

Fossae supravesicales, inguinales med. et lat.

Hernia umbilicalis



Hernia femoralis

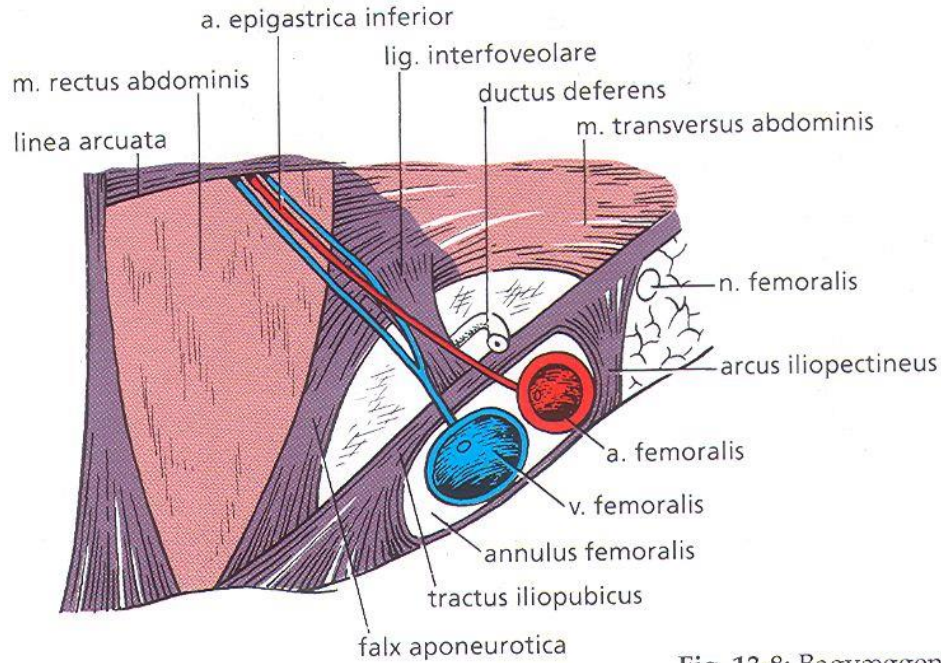
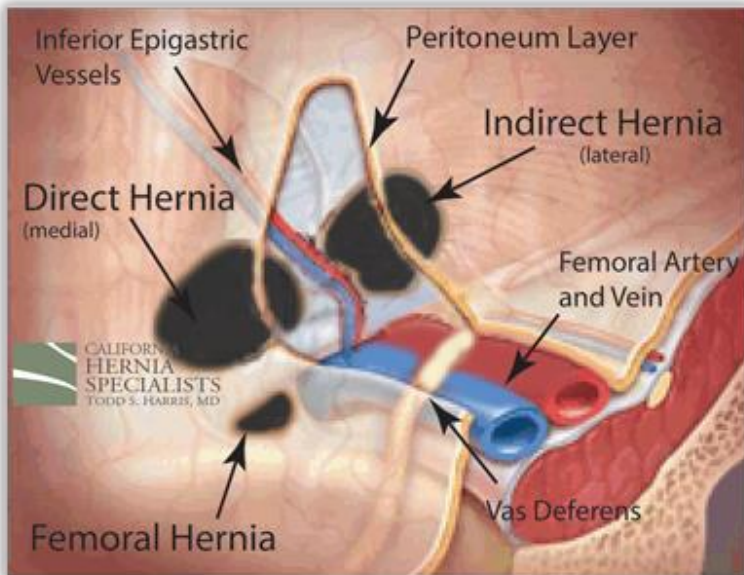
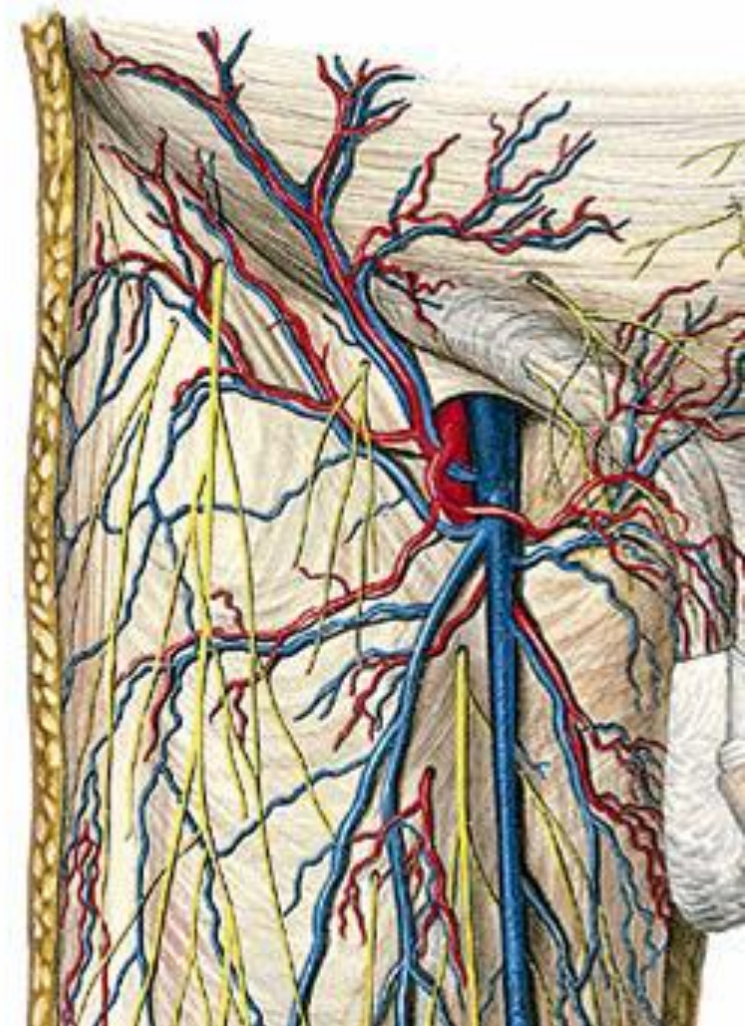
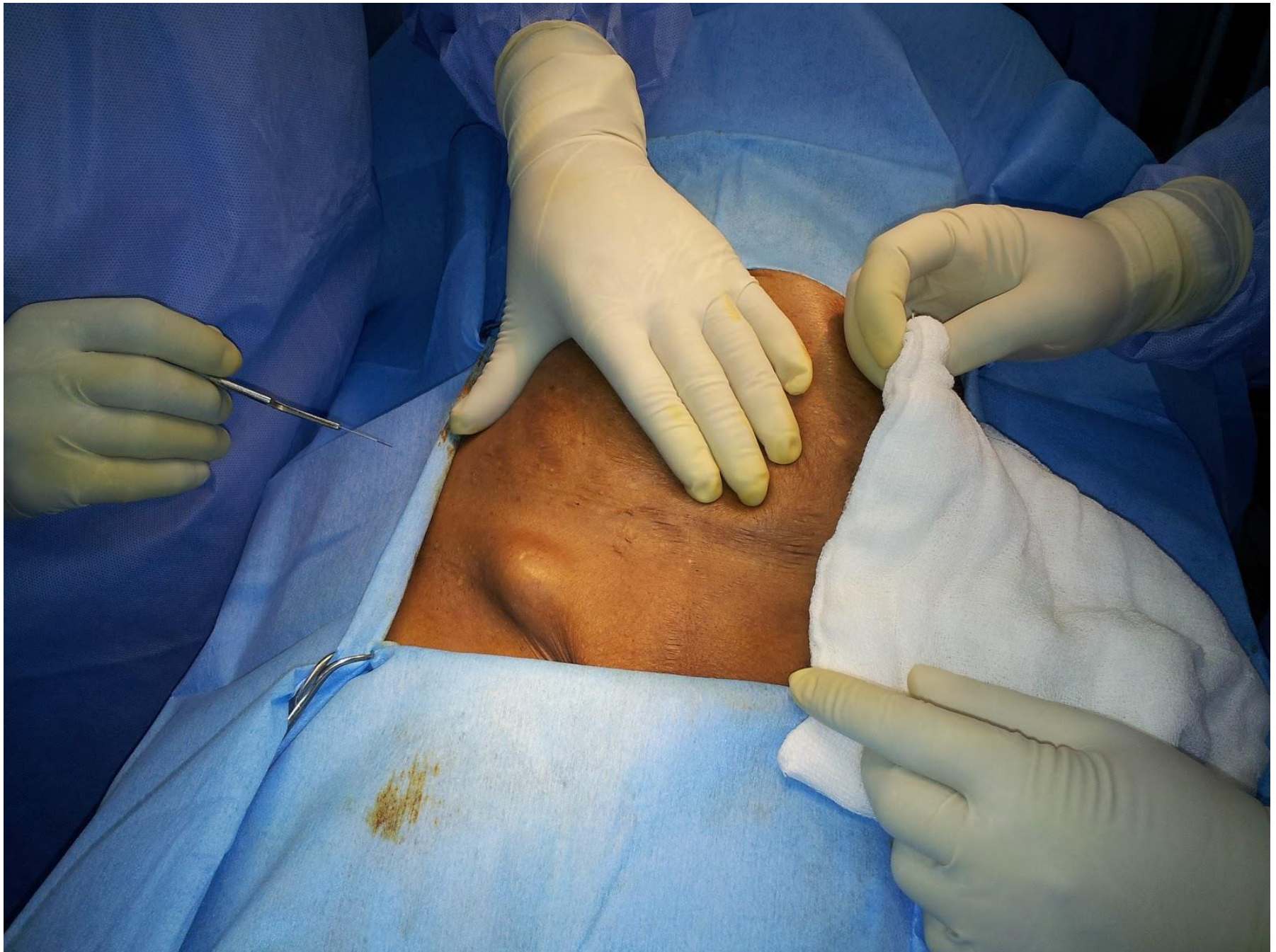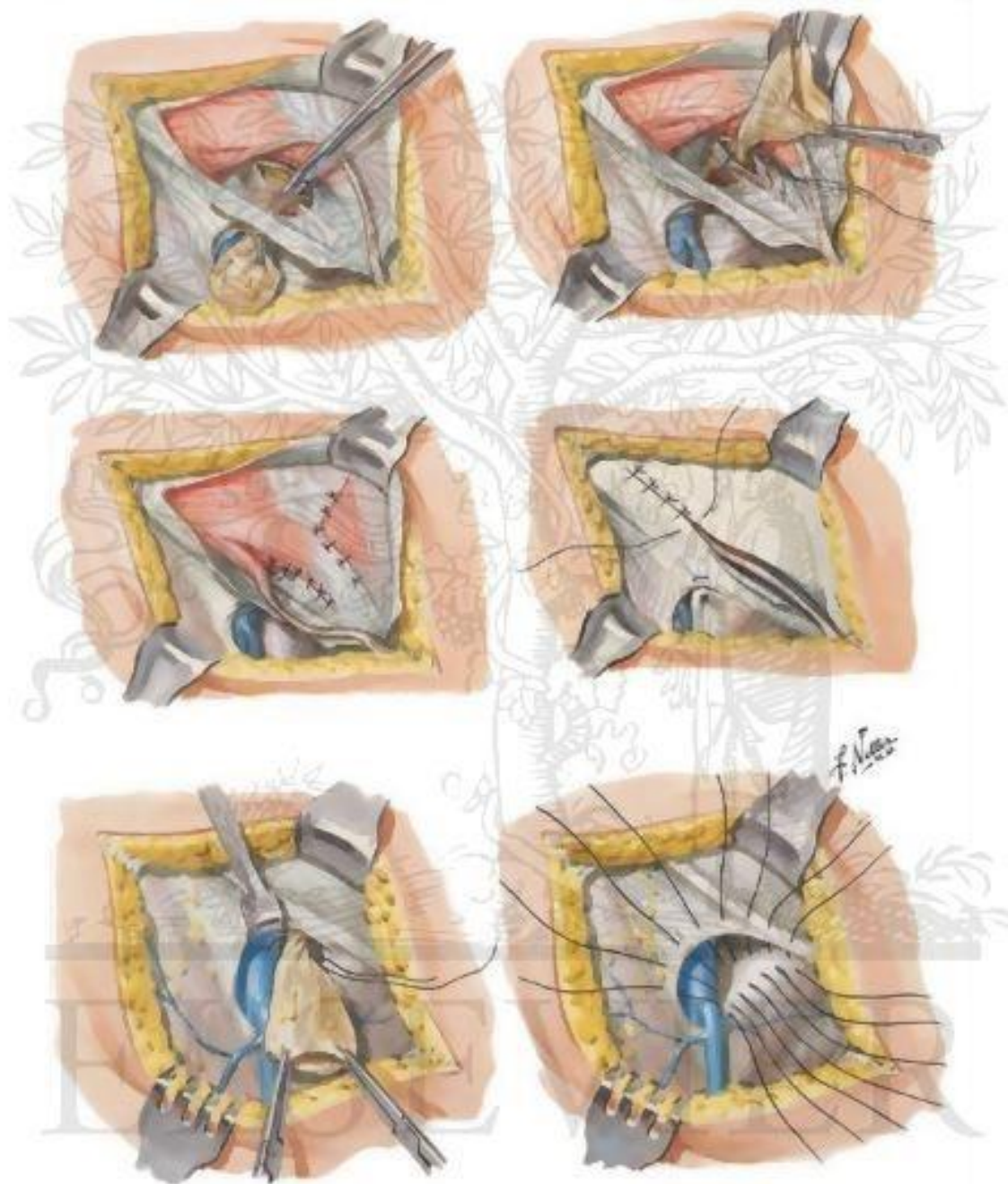


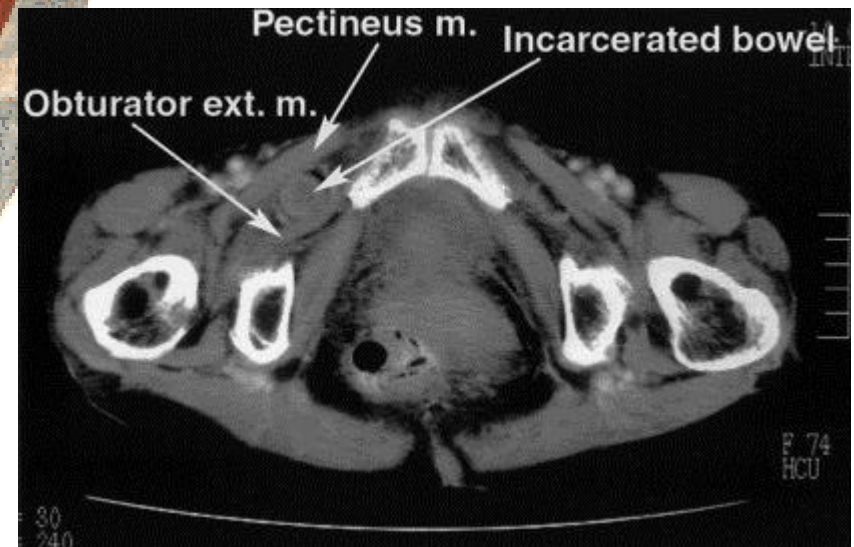
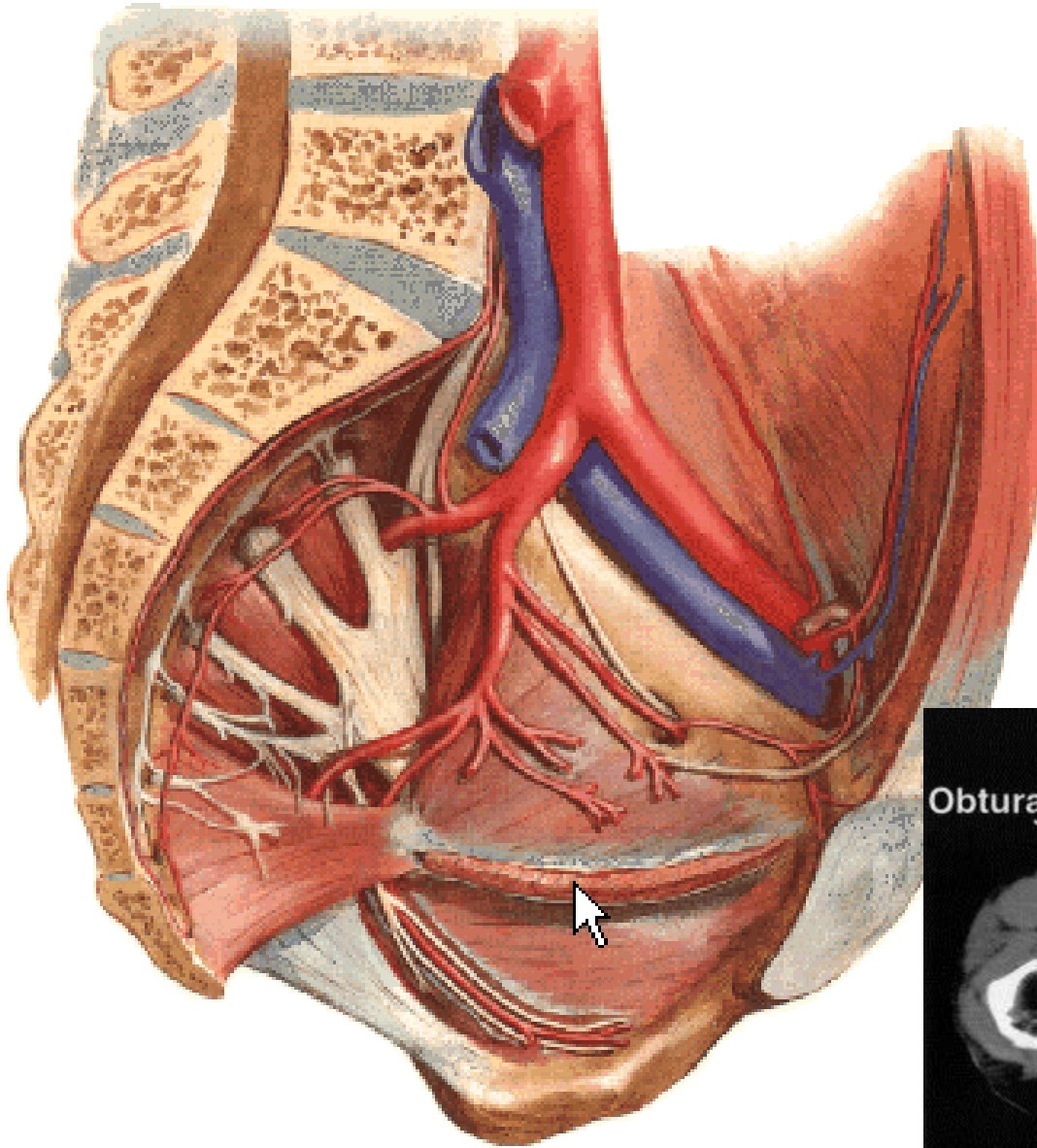
Fig. 13-8: Bagvæggen



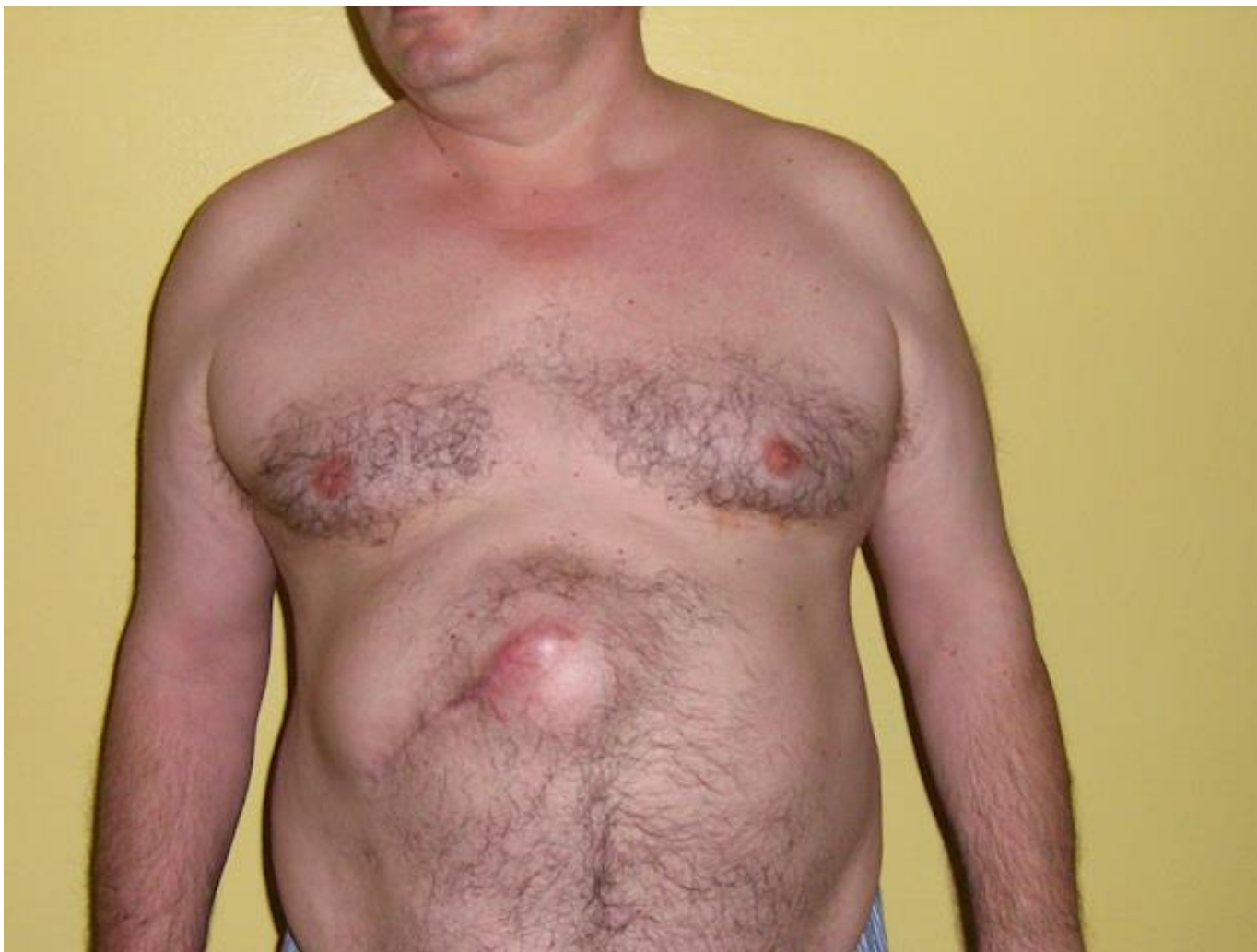



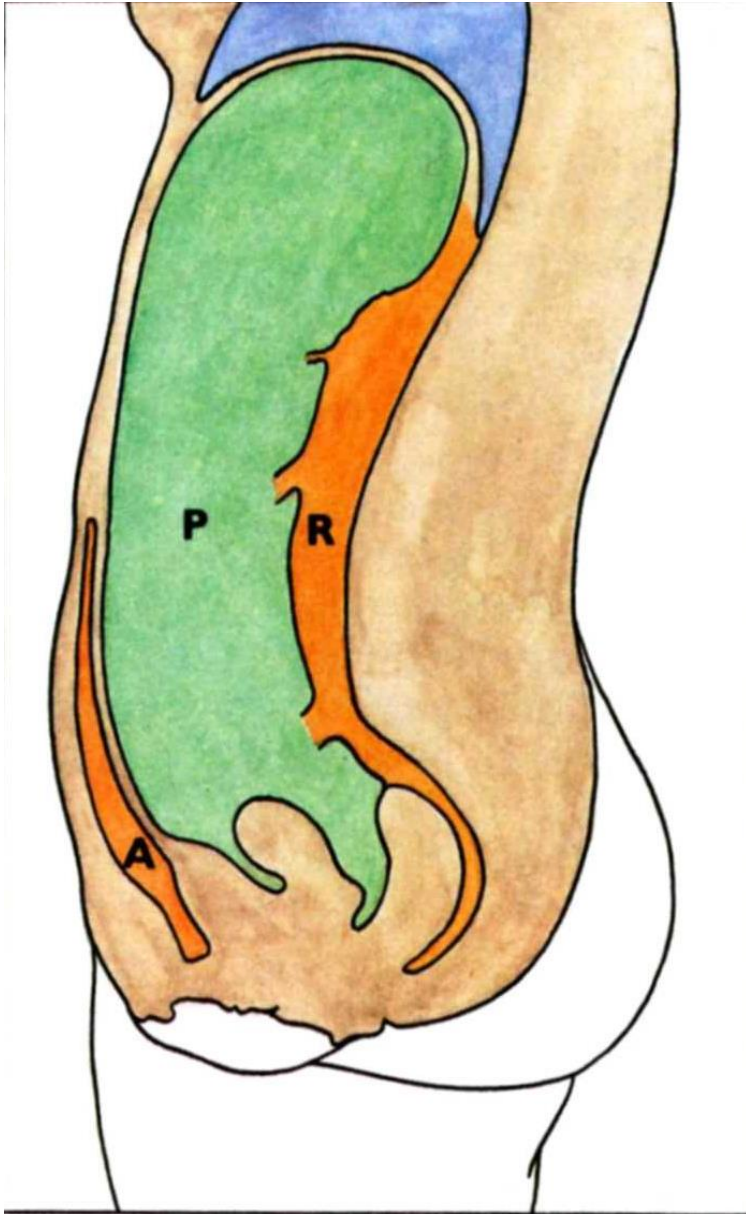
Hernia obturatoria



Kýla v jizvě

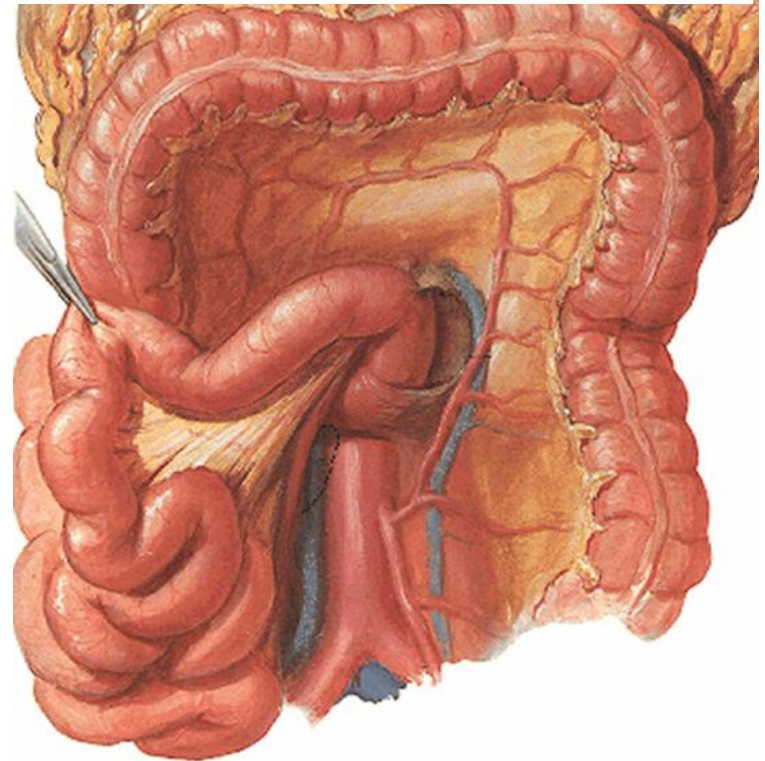
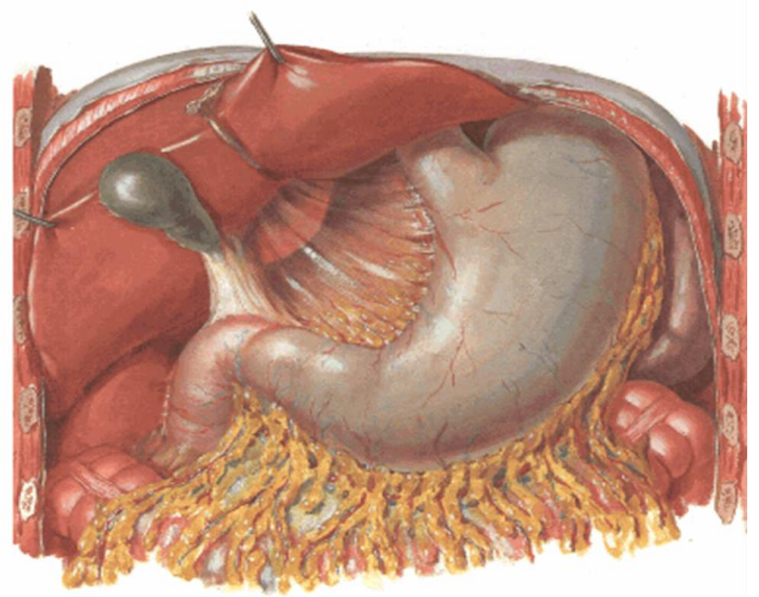
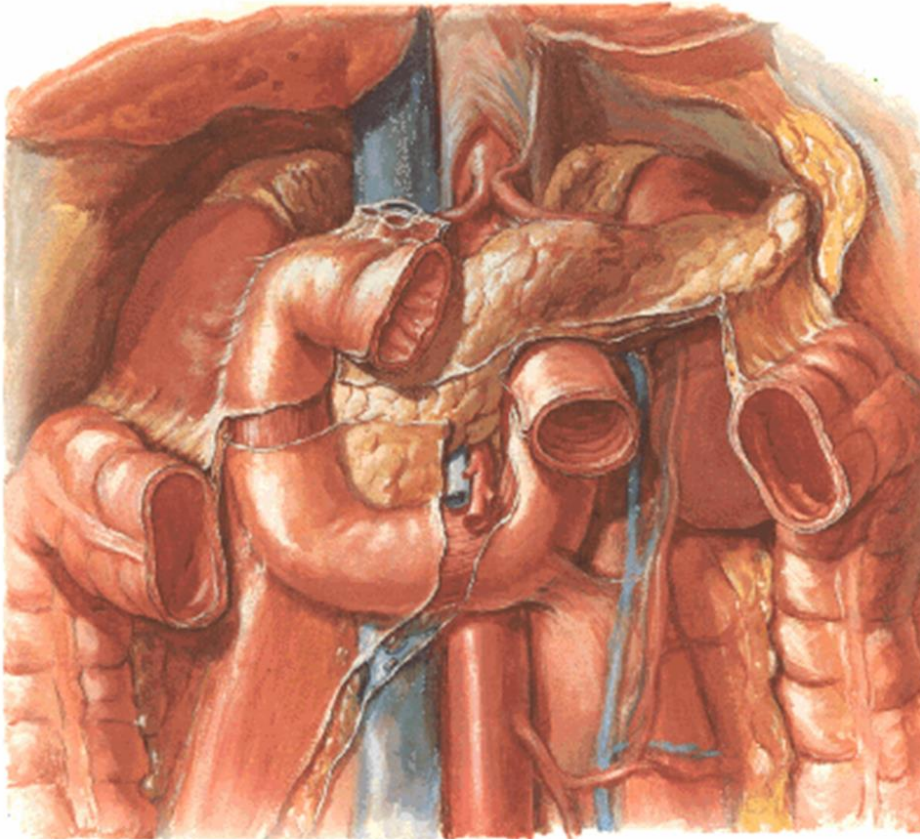


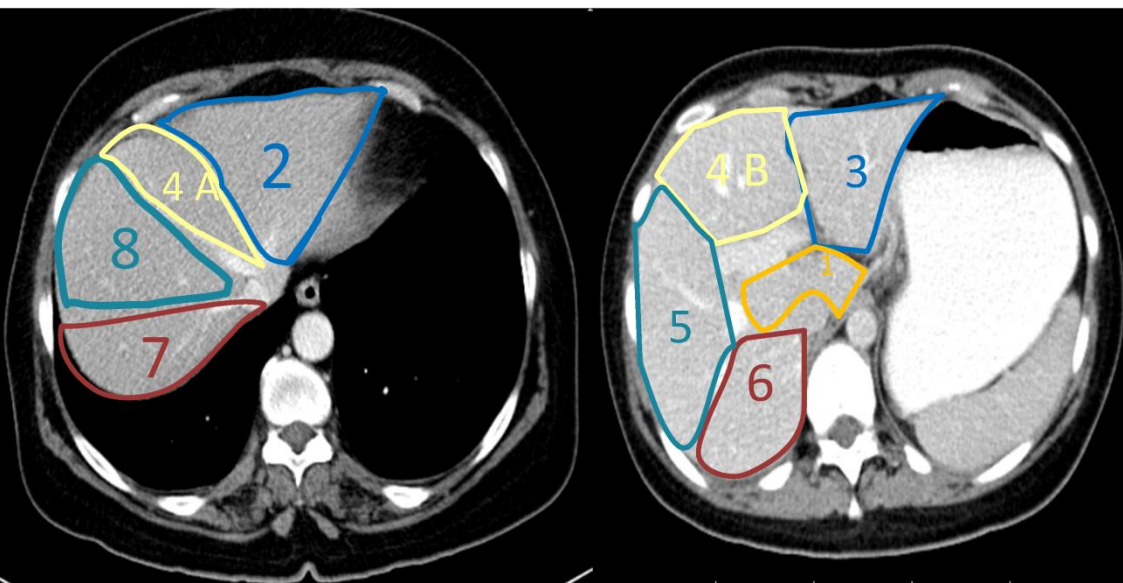
Peritoneum



- Praeperitoneální prostor
- Peritoneální prostor
- Retroperitoneální prostor

Pars supra- et inframesoclica

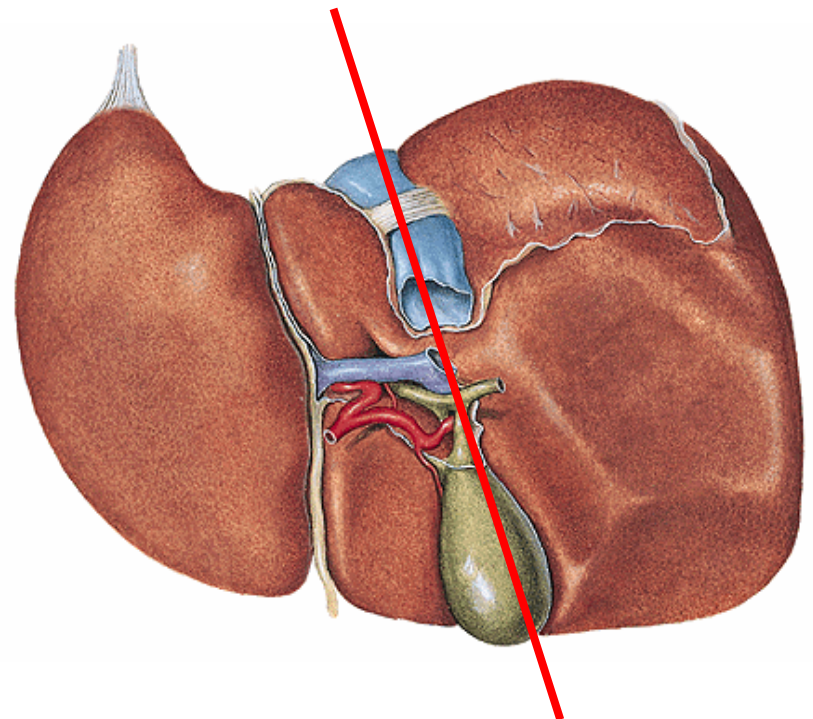
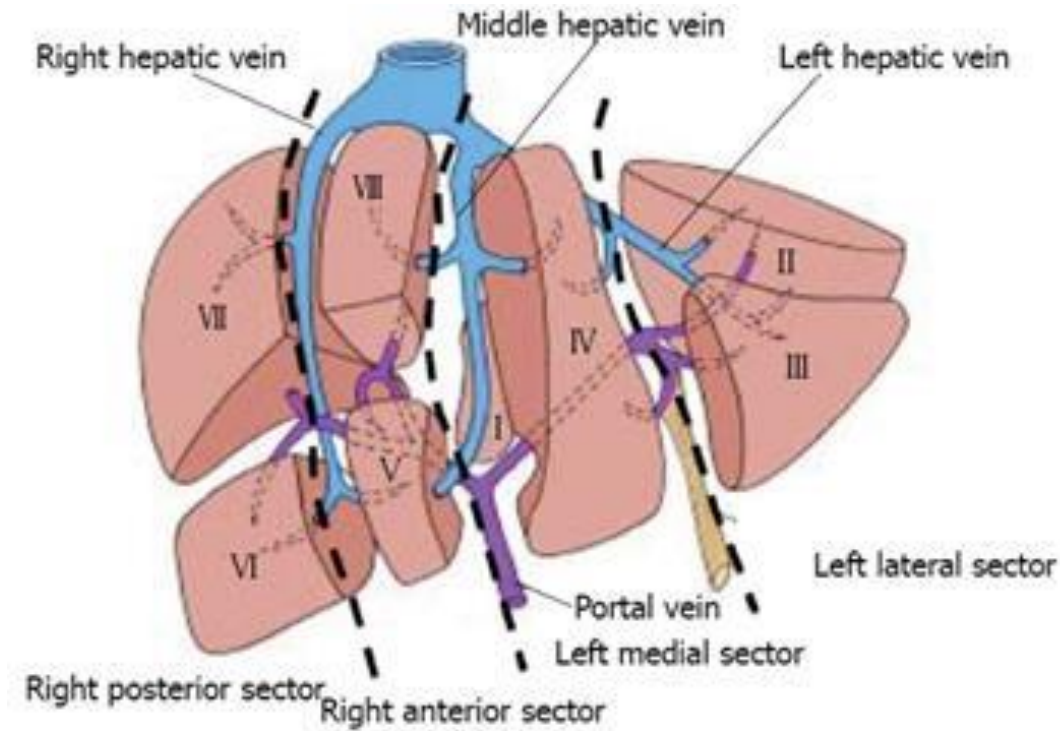




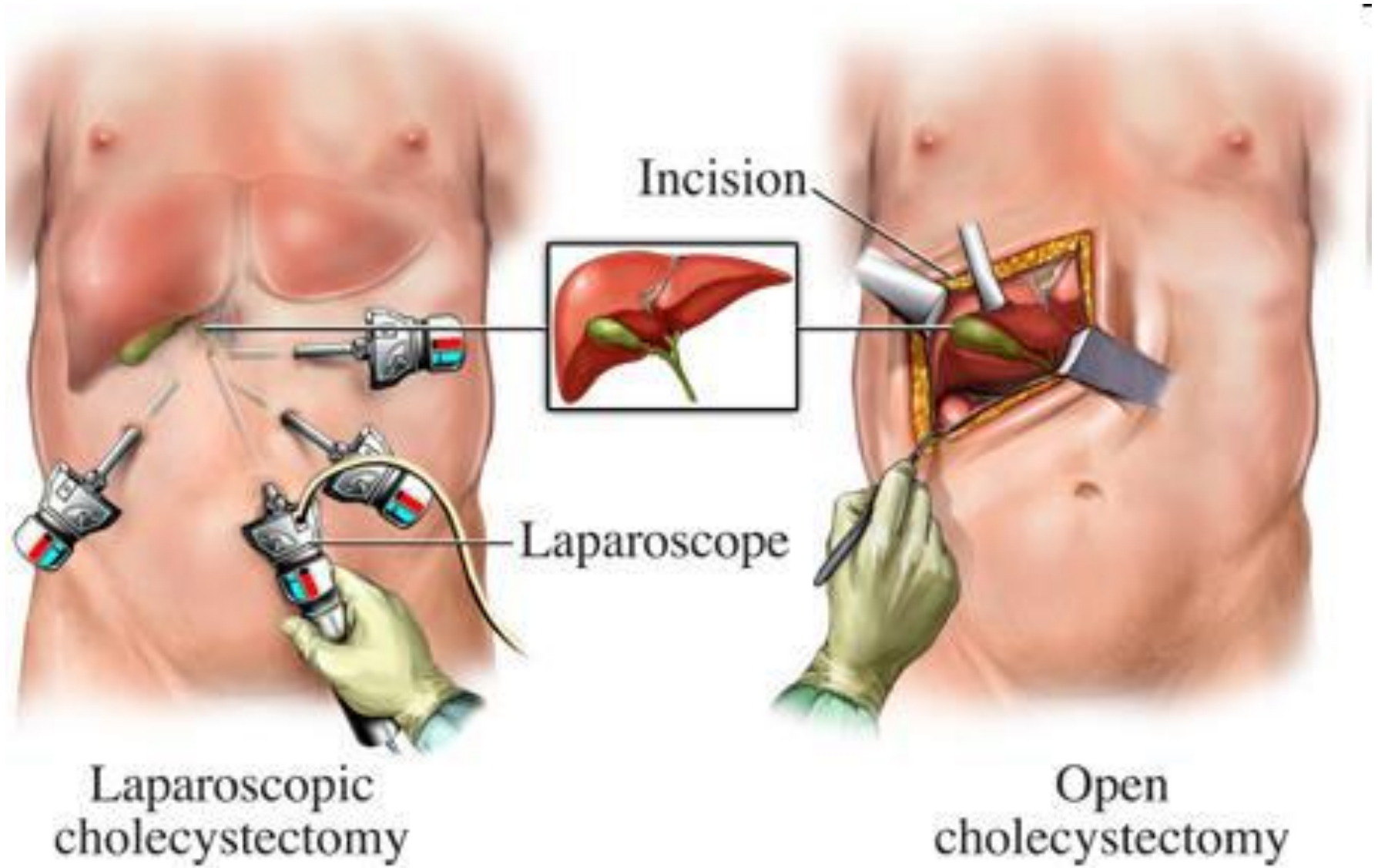
Jaterní segmenty

v. portae, vv. hepaticae

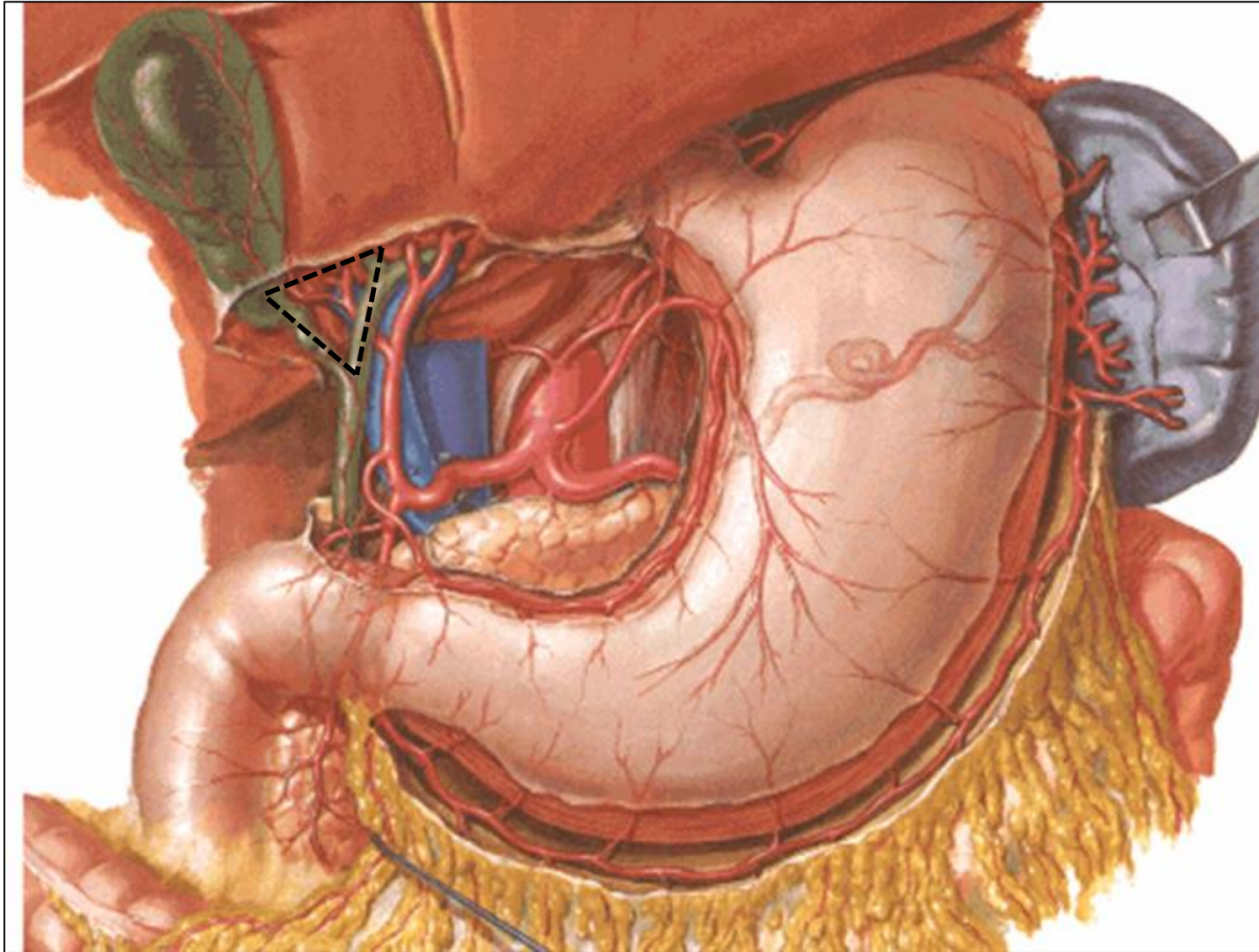
Cantlieova linie



Cholecystektomie

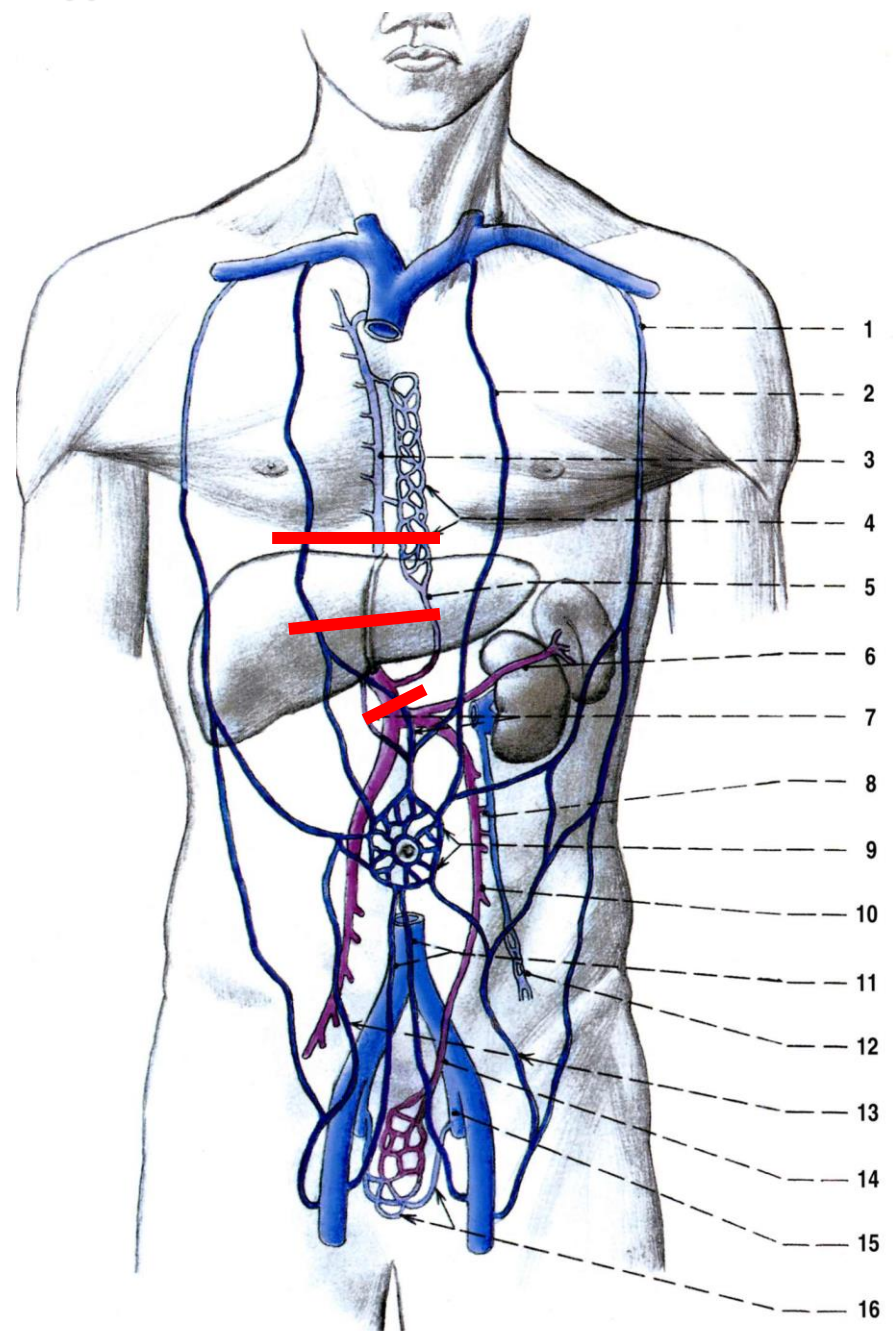
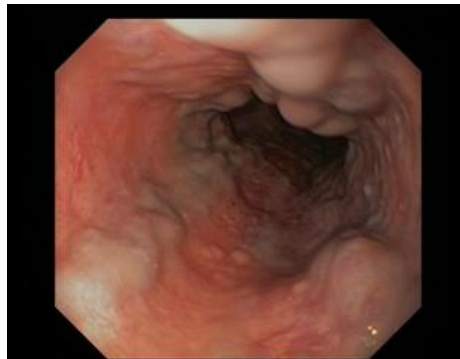
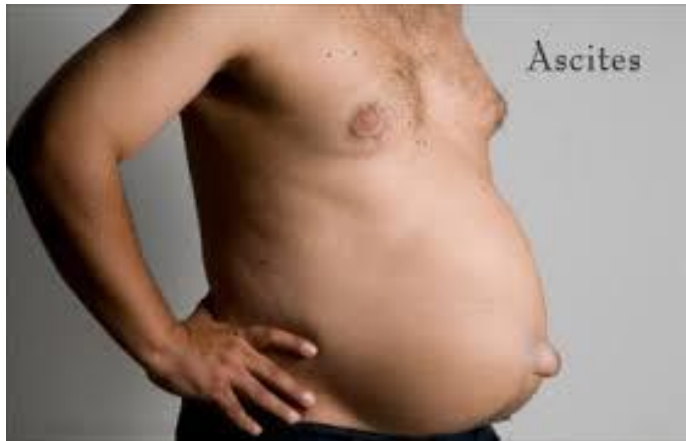
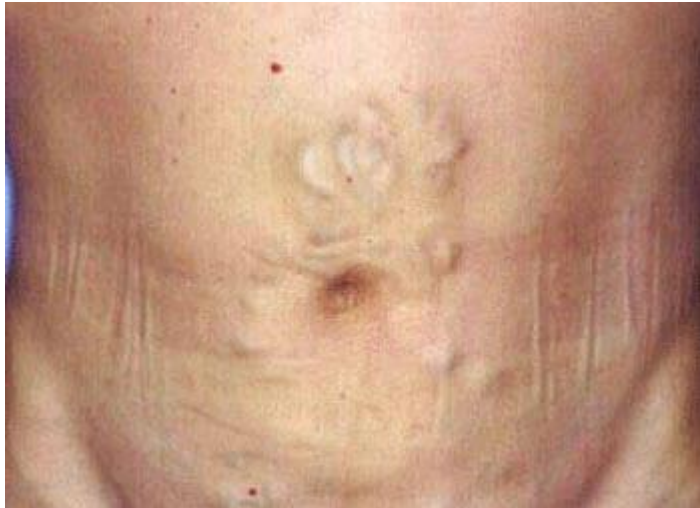Vasa cystica

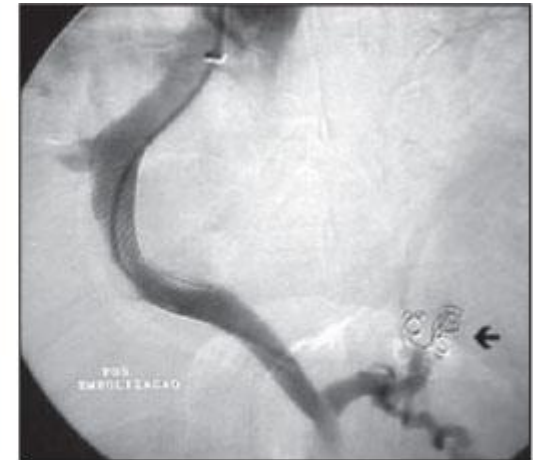
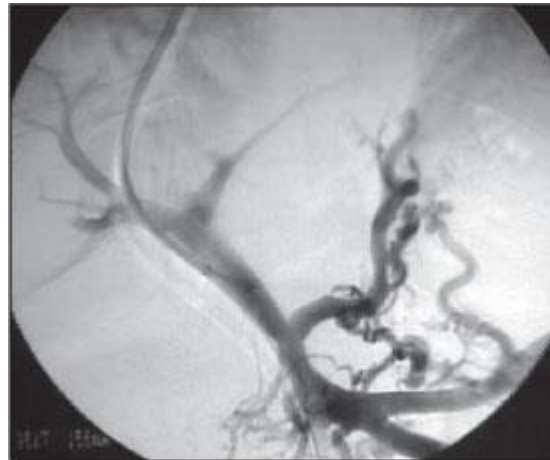
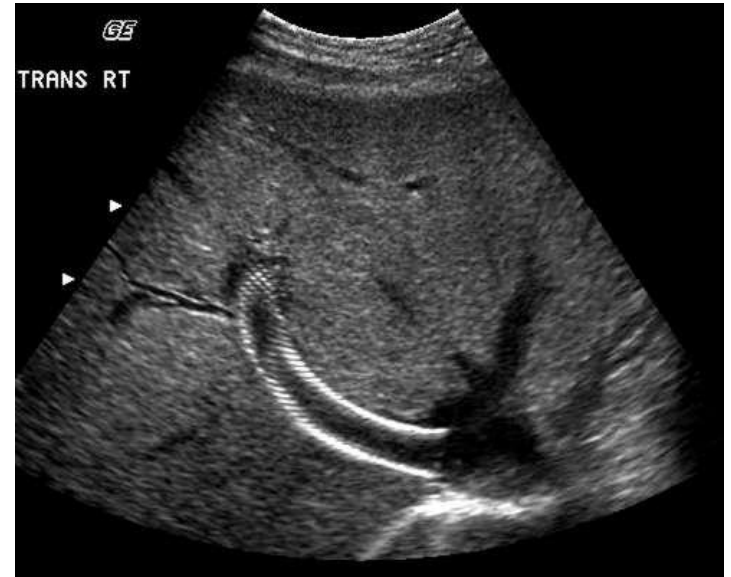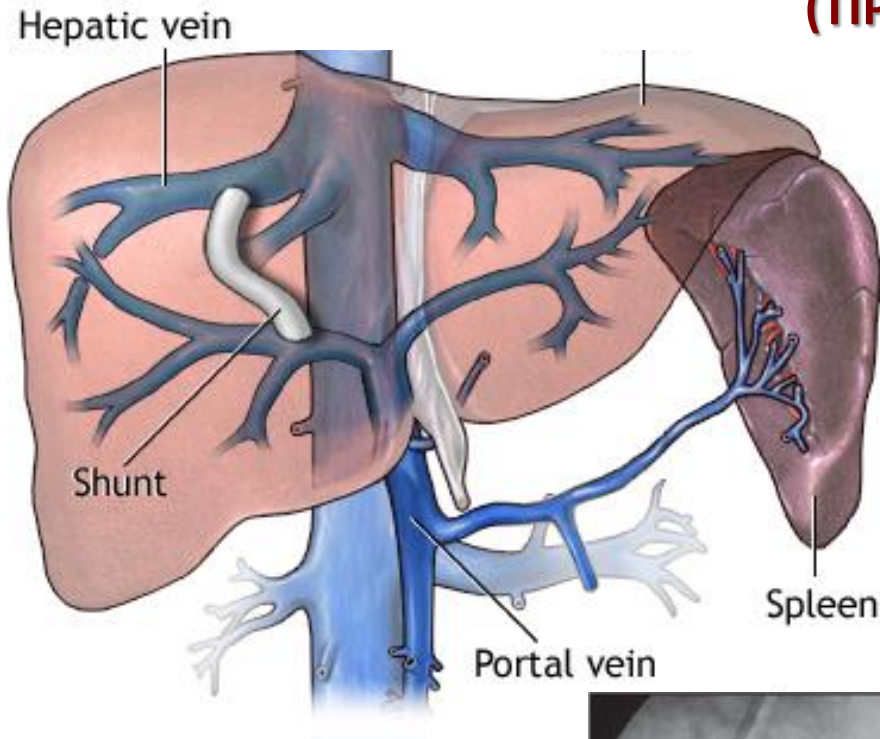


Calotův trojúhelník (*trigonum cystohepaticum*): ductus cysticus, ductus hepaticus communis, lobus quadratus

Portální hypertenze



Transjugulární intrahepatický portosystémový shunt (TIPS)

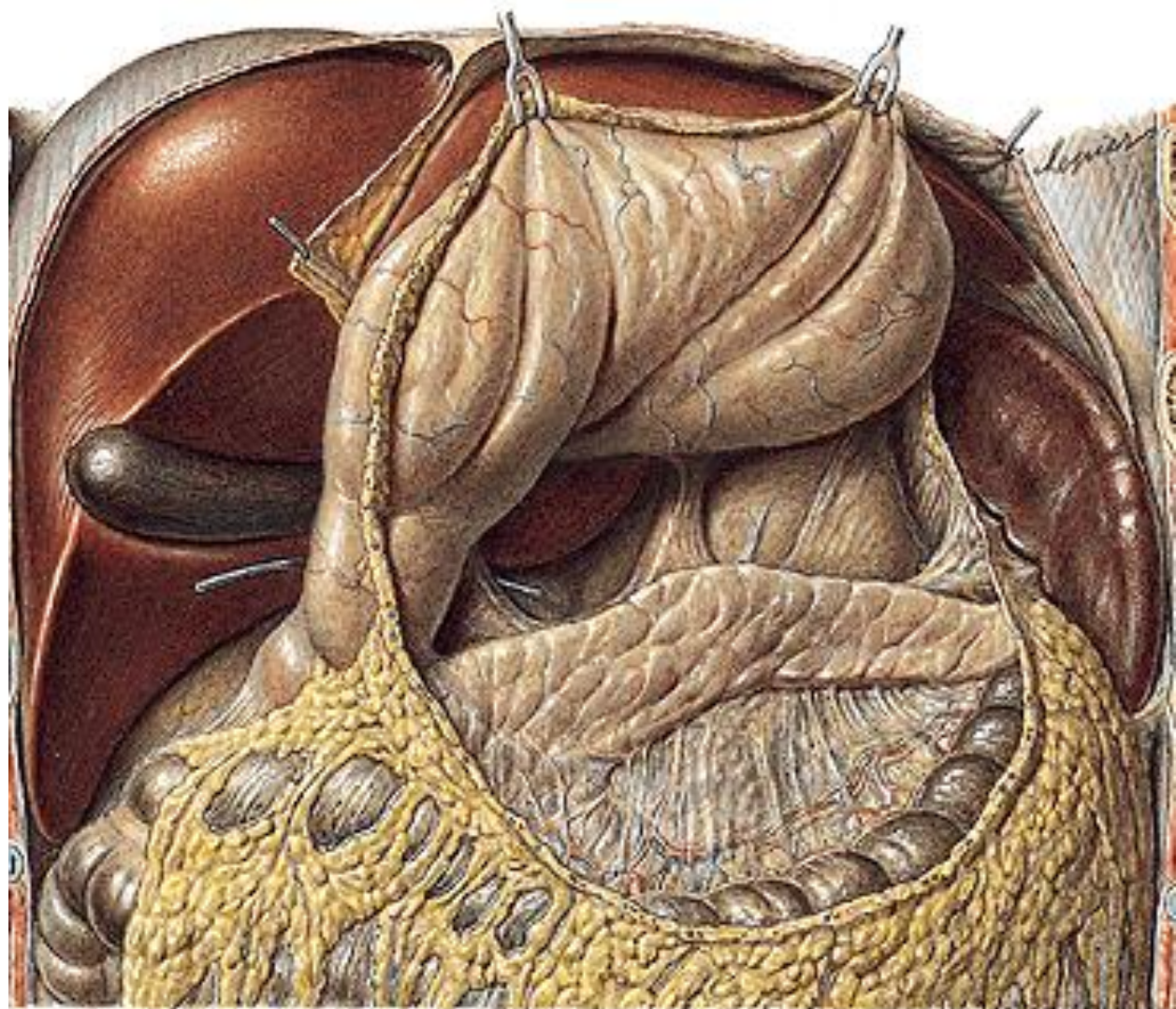
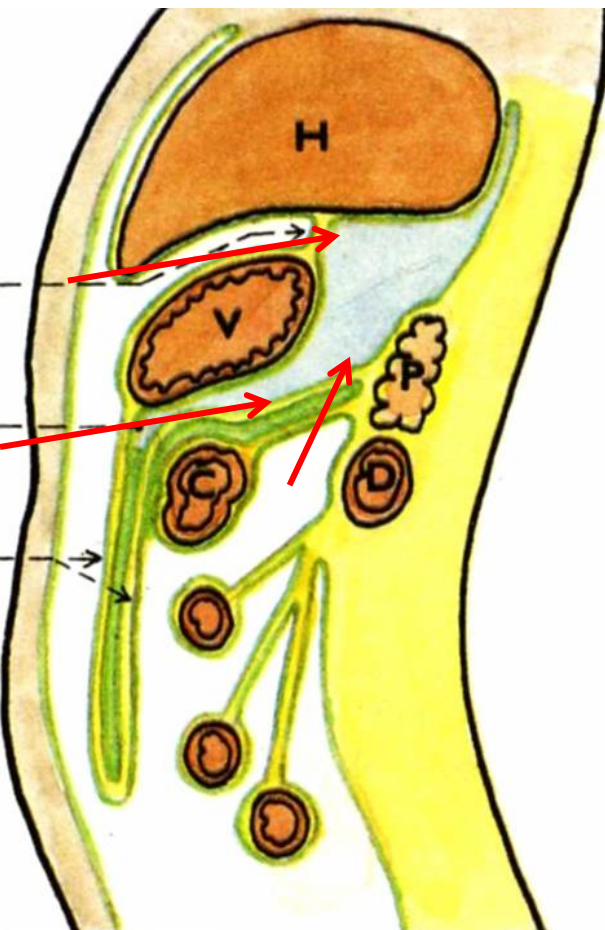


A

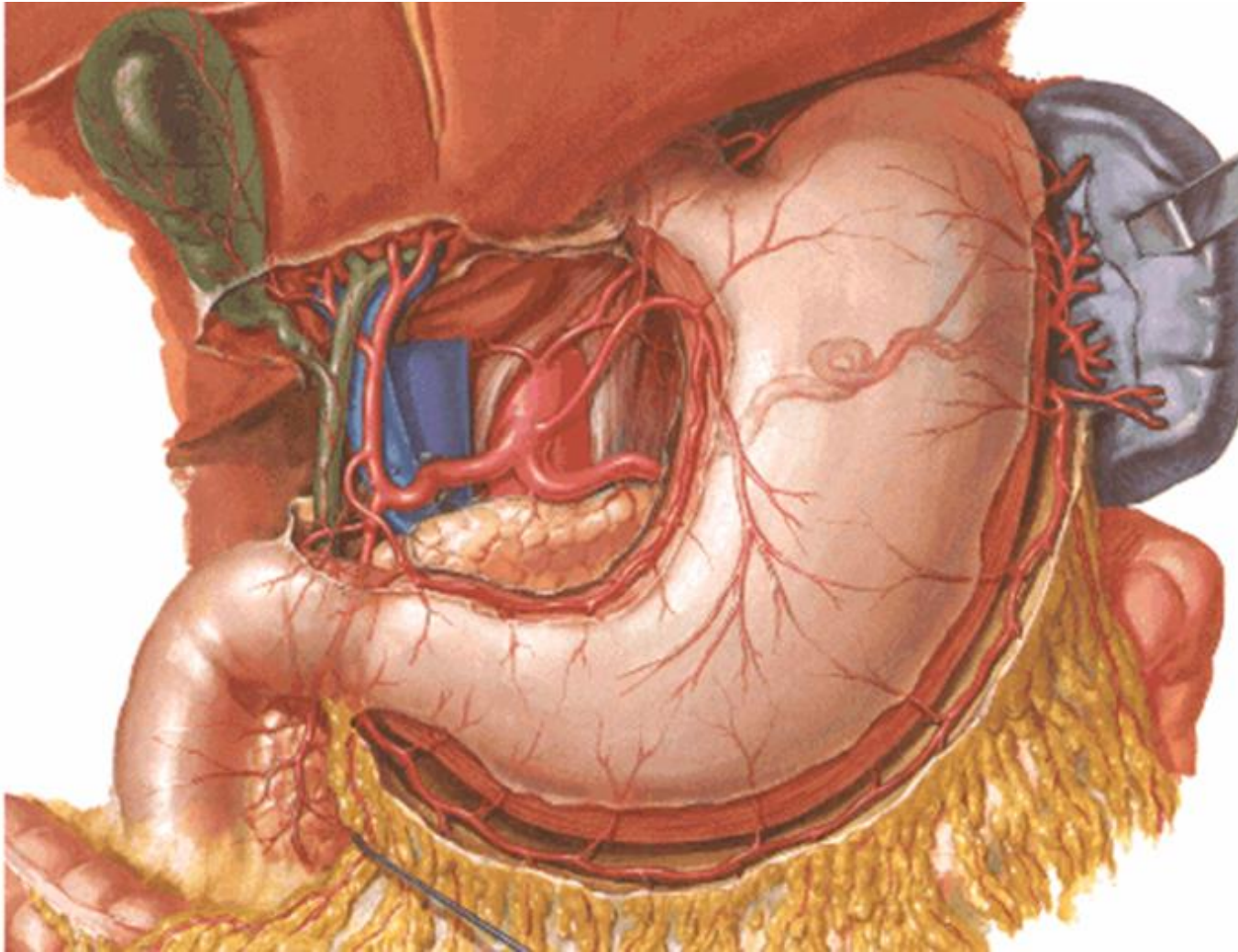
B

Figure 2. Portography by direct transhepatic puncture. **A:** Before TIPS performance, an intense portal reflux through collaterals towards the gastroesophageal transition zone. **B:** As a supplement to TIPS, the collaterals were occluded with metal coils (arrow).

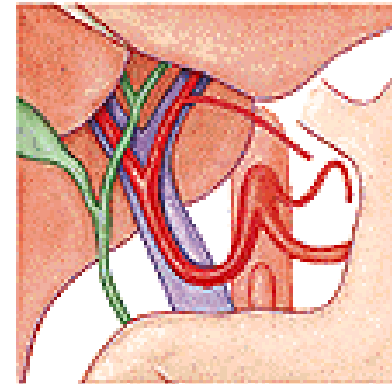
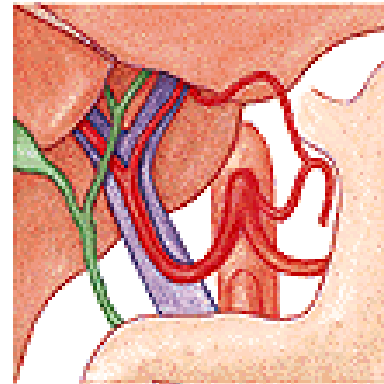
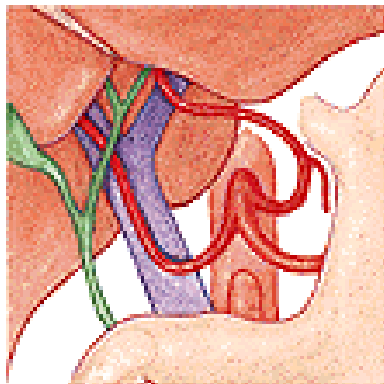
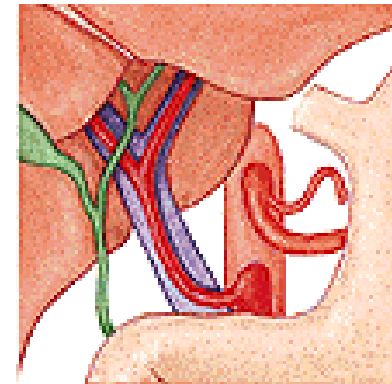
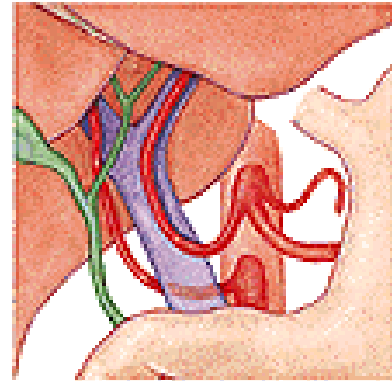
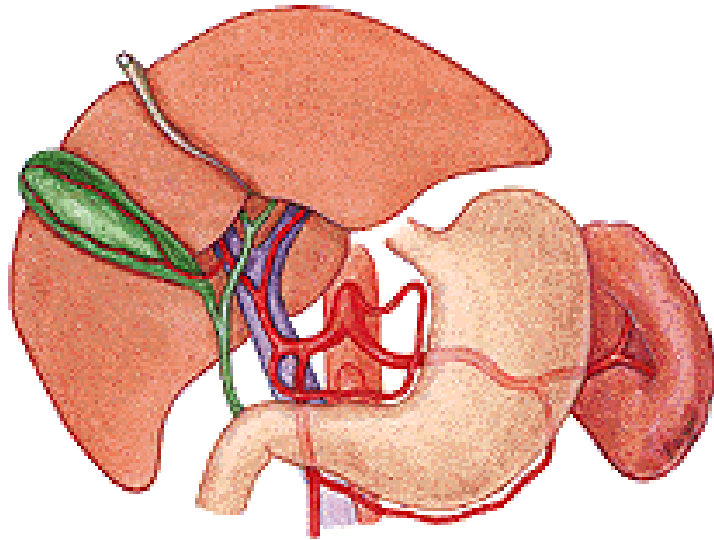
Pankreas – operační přístupy



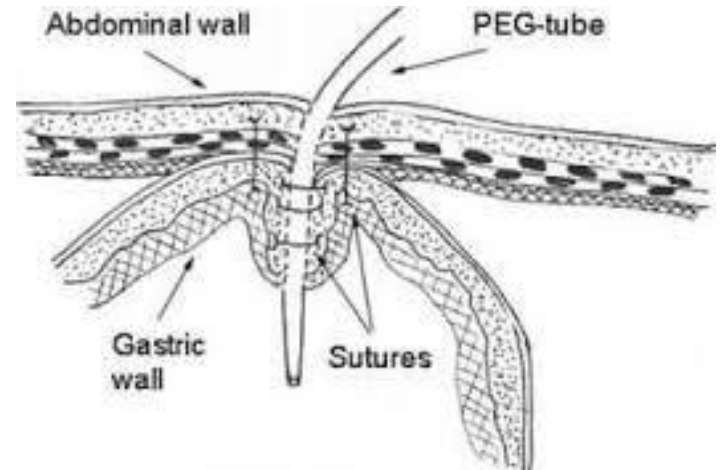
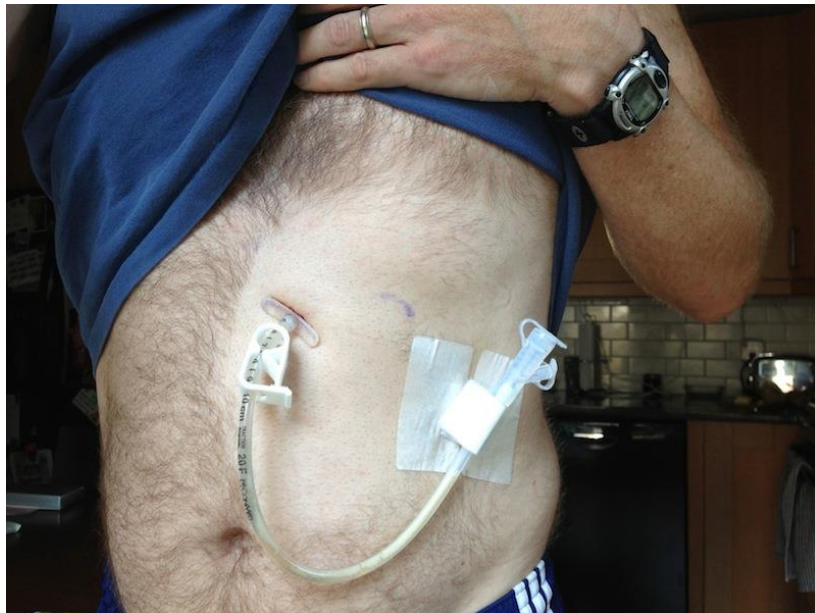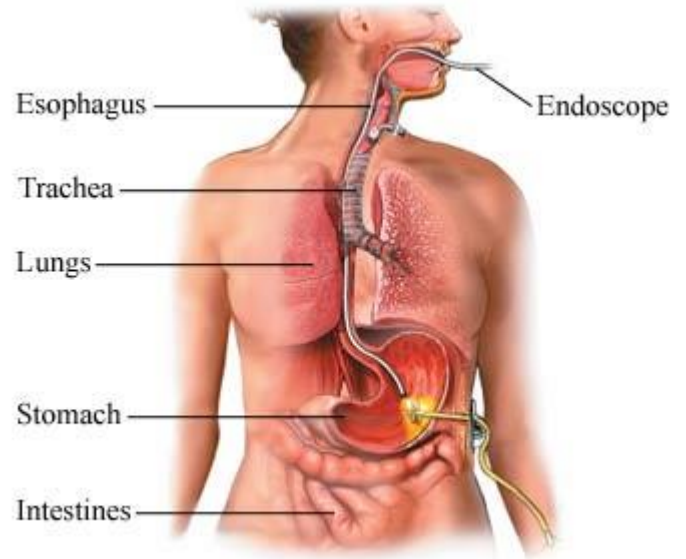
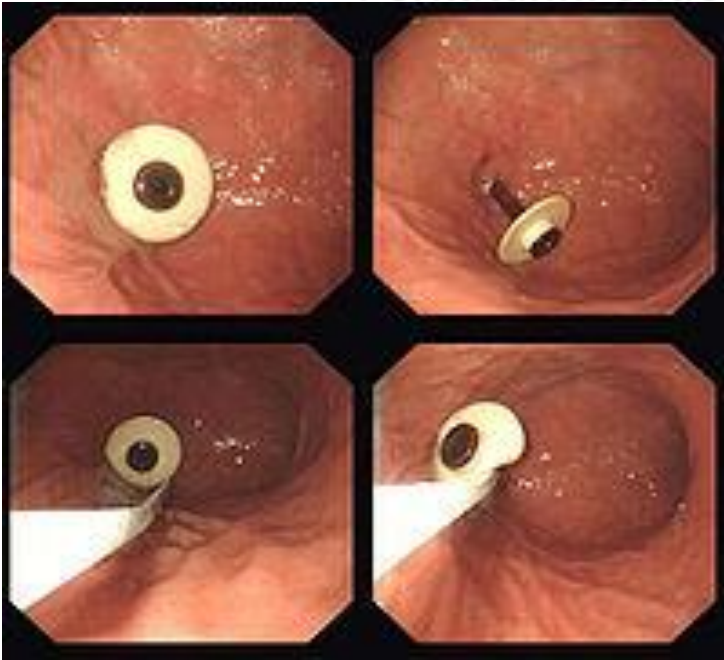Cévní zásobení žaludku



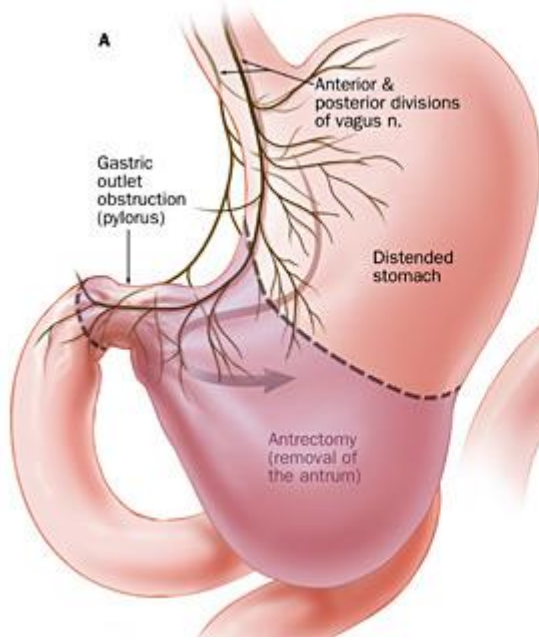
Variablitia truncus coeliacus



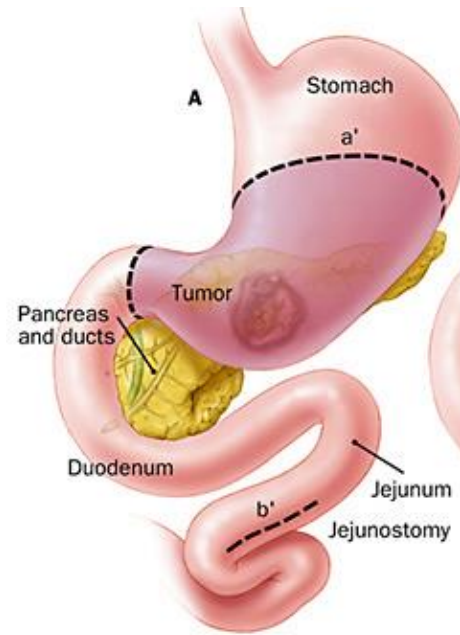
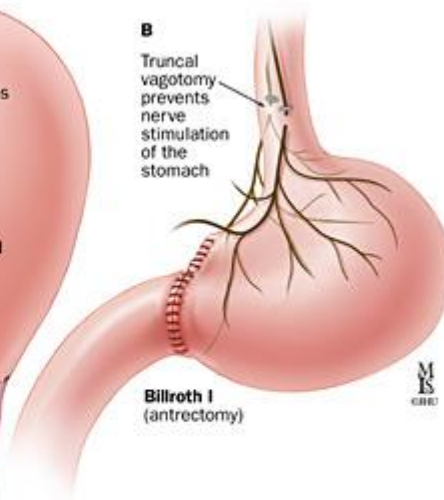
Perkutánní endoskopická gastrostomie (PEG)



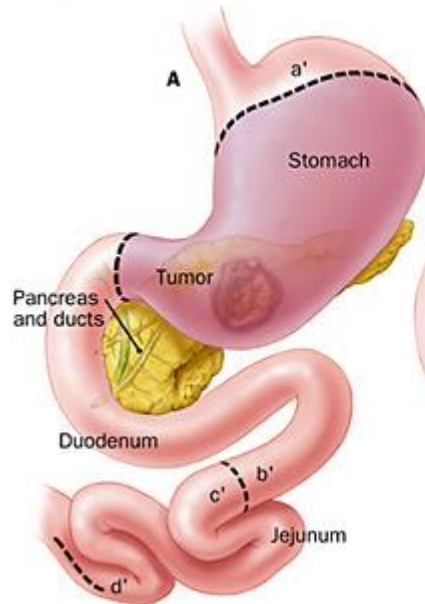
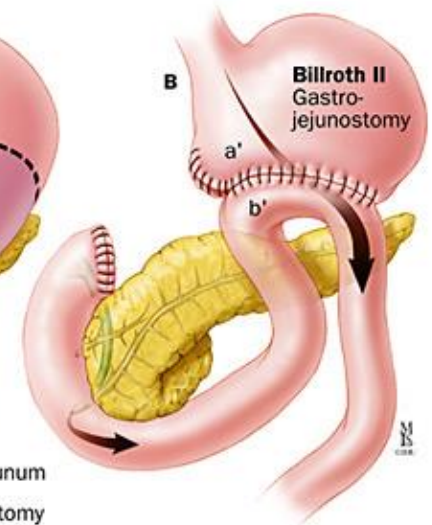
Resekce žaludku



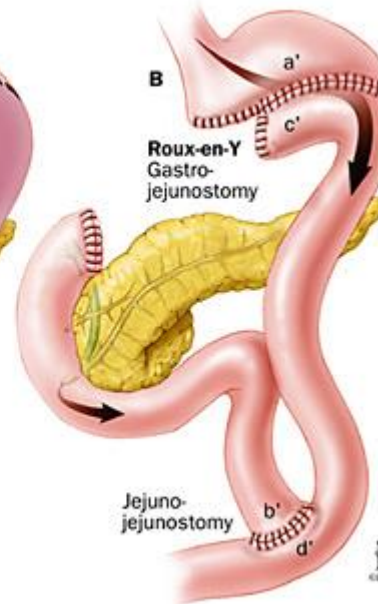
Billroth I



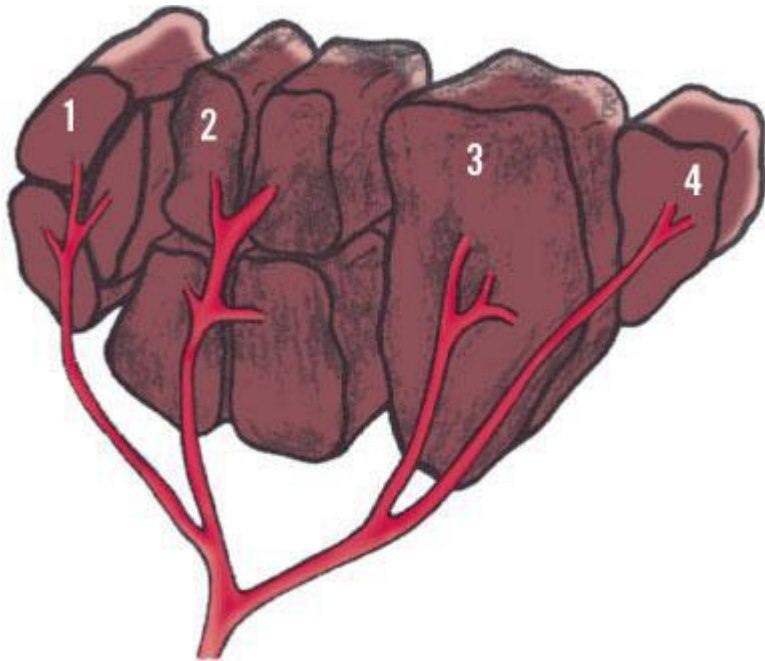
Billroth II



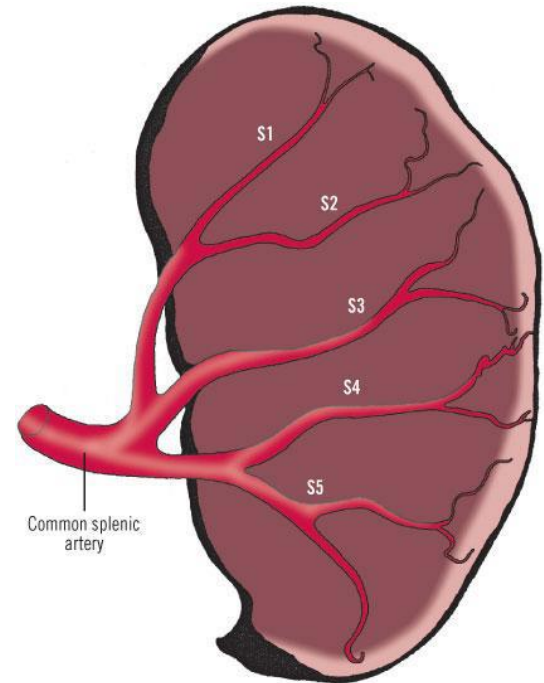
Roux-en-Y



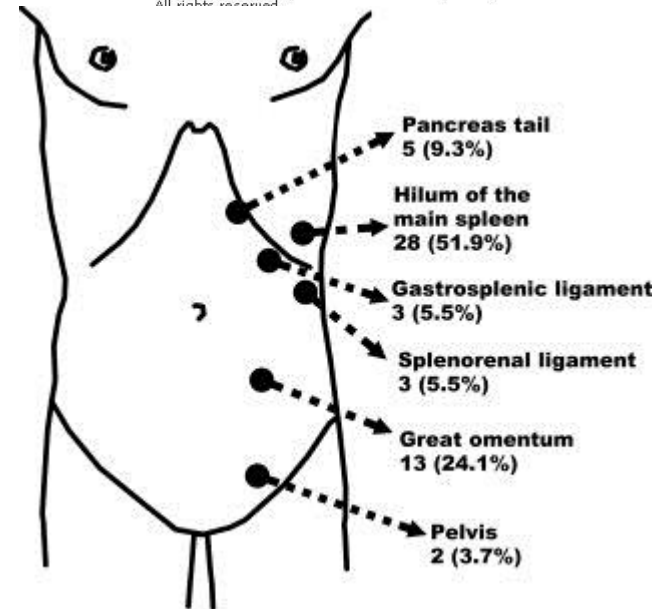
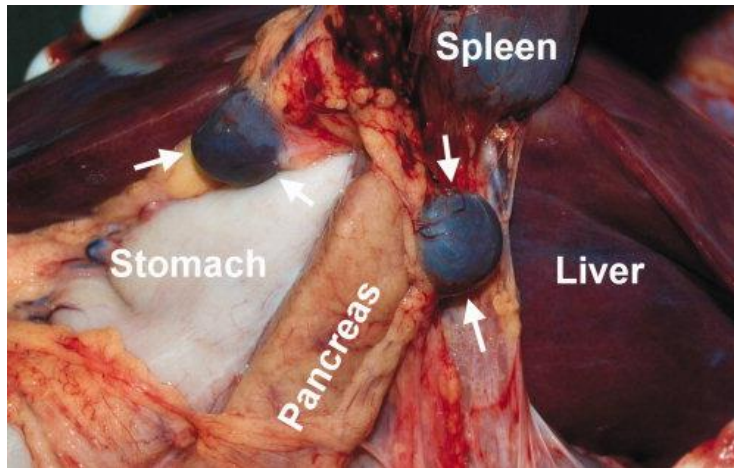
Slezina



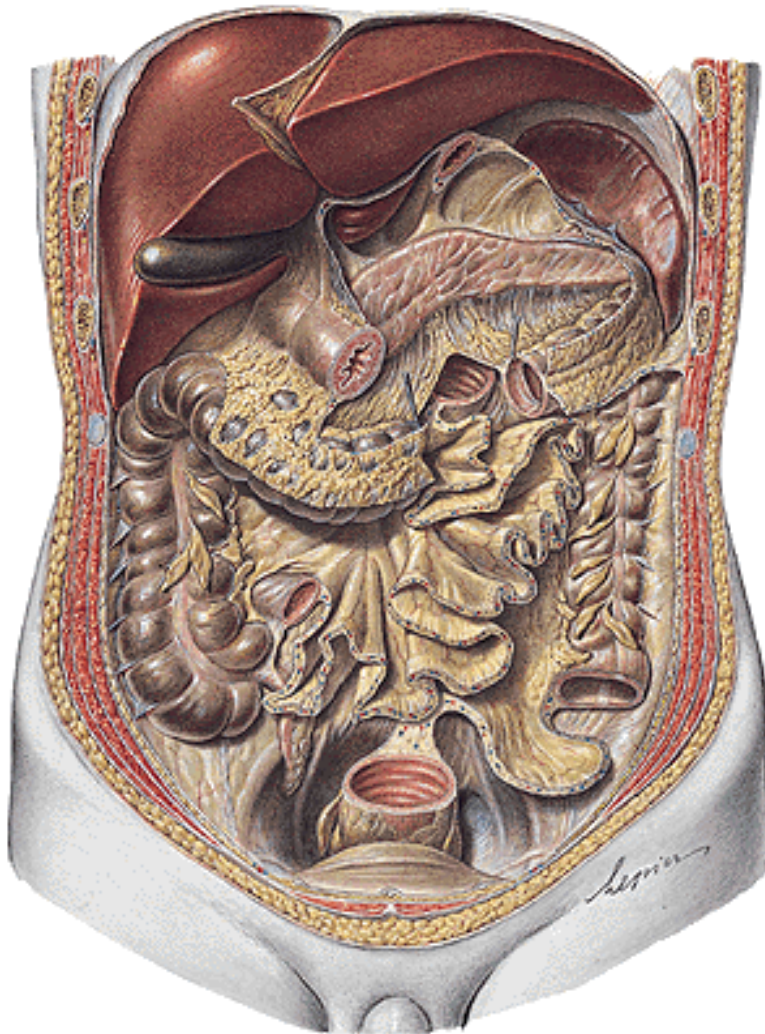Copyright ©2006 by The McGraw-Hill Companies, Inc.
All rights reserved.



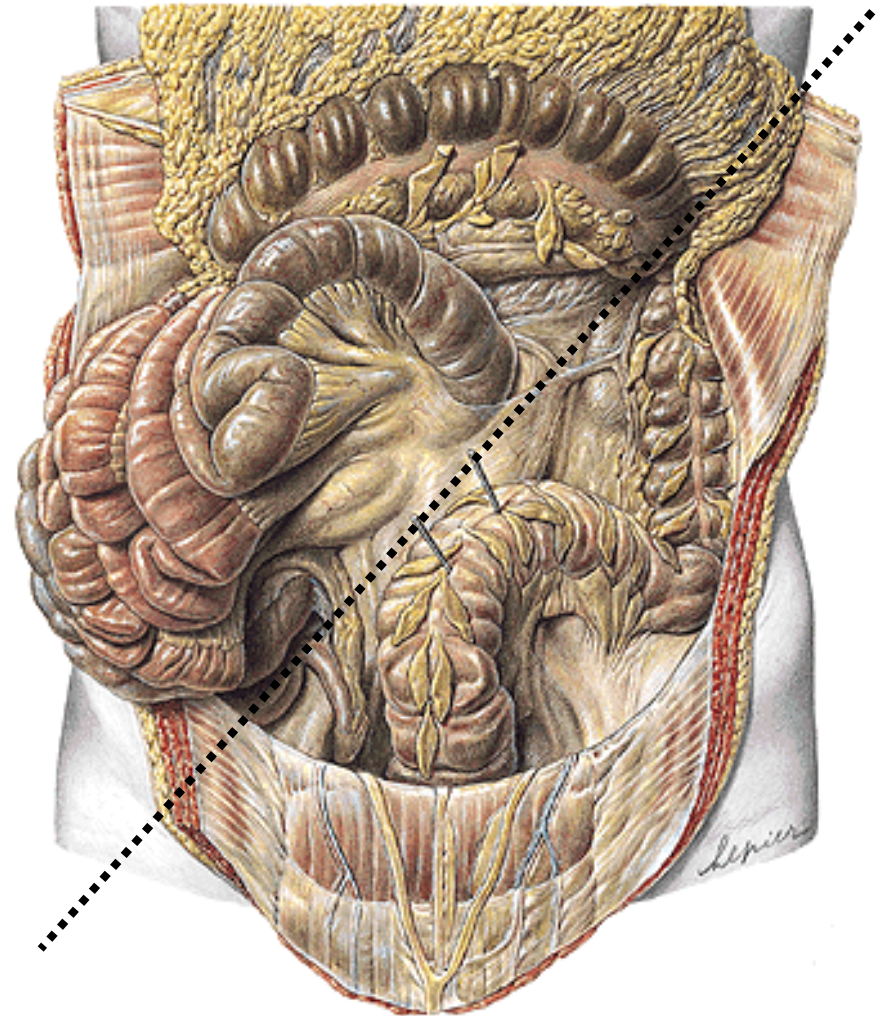
Copyright ©2006 by The McGraw-Hill Companies, Inc.
All rights reserved.



Pars inframesocolica

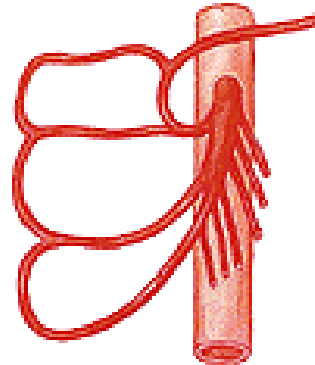
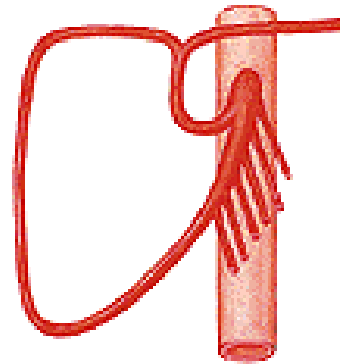
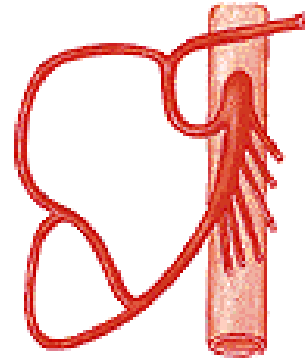
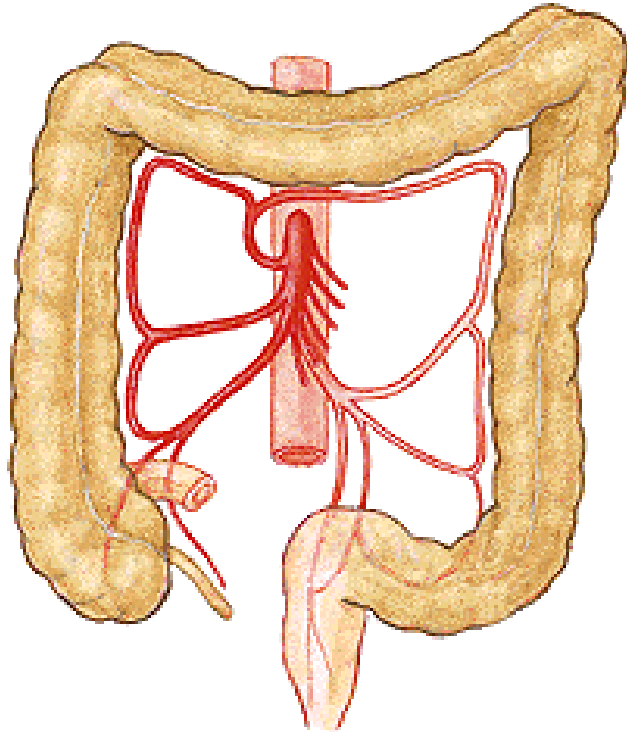



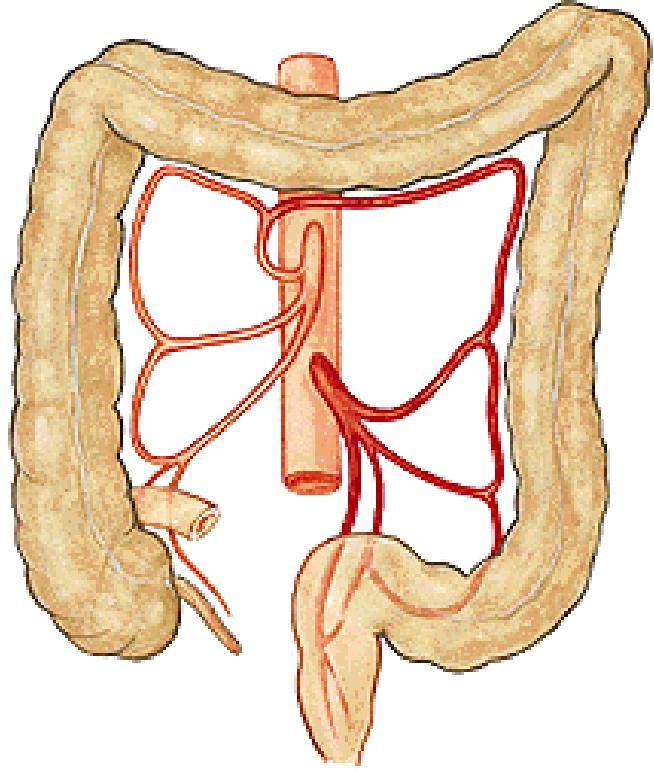
radix mesenterii



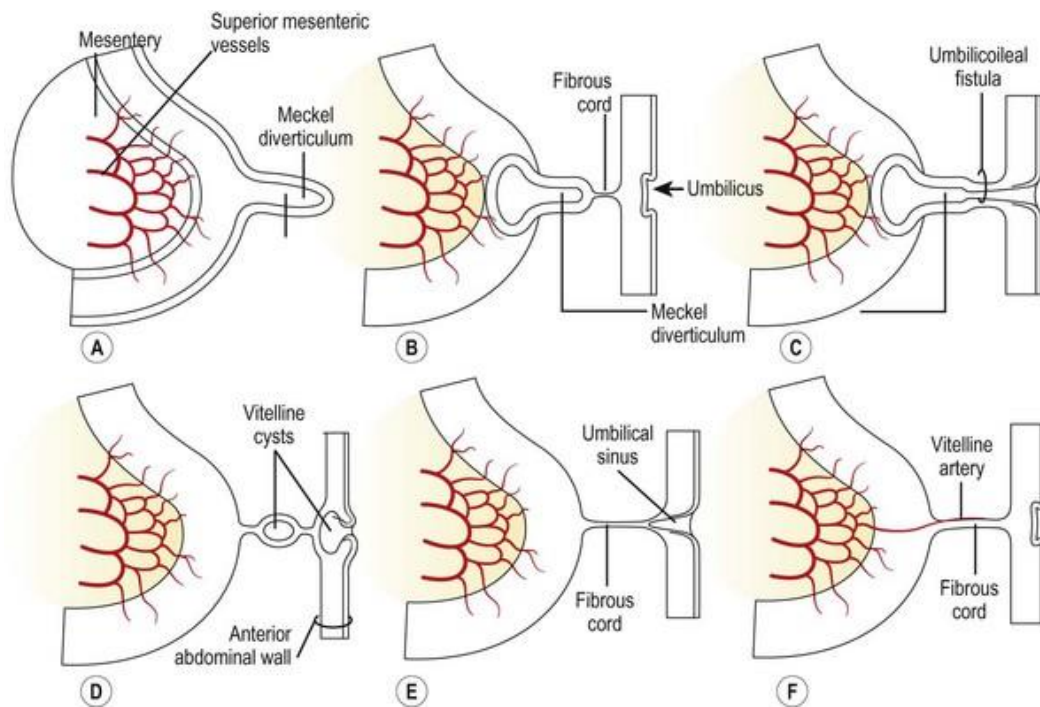
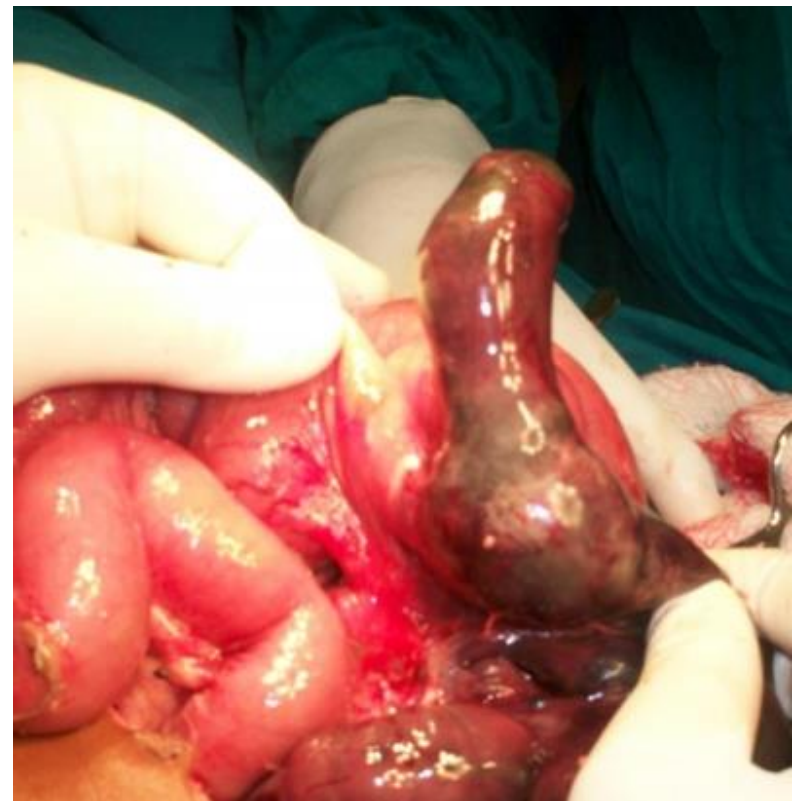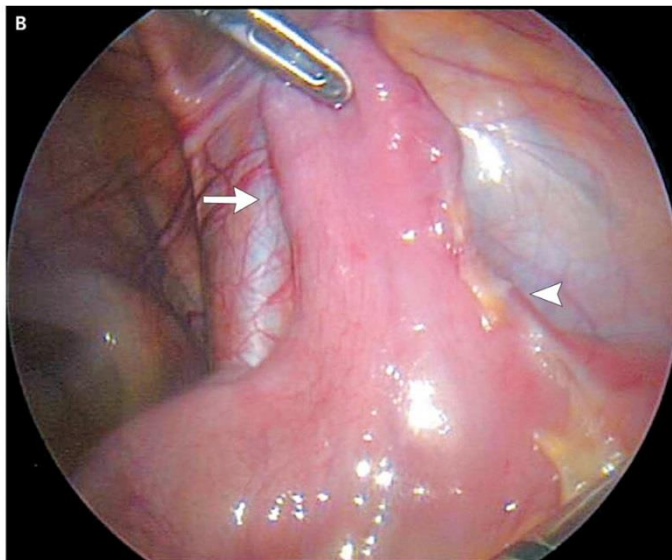
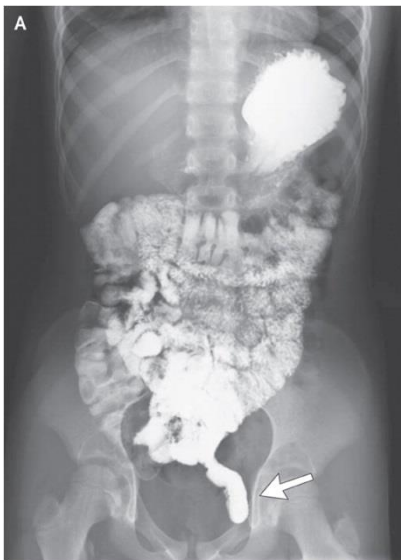Pars inframesocolica dextra et sinistra

Variety tepen





Diverticulum Meckeli (ilei)



Pozůstatek ductus omphaloentericus

Přibližně 100 cm od terminálního ilea

Appendix vermiformis

Positio pelvina (lig. appendiculoovaricum)

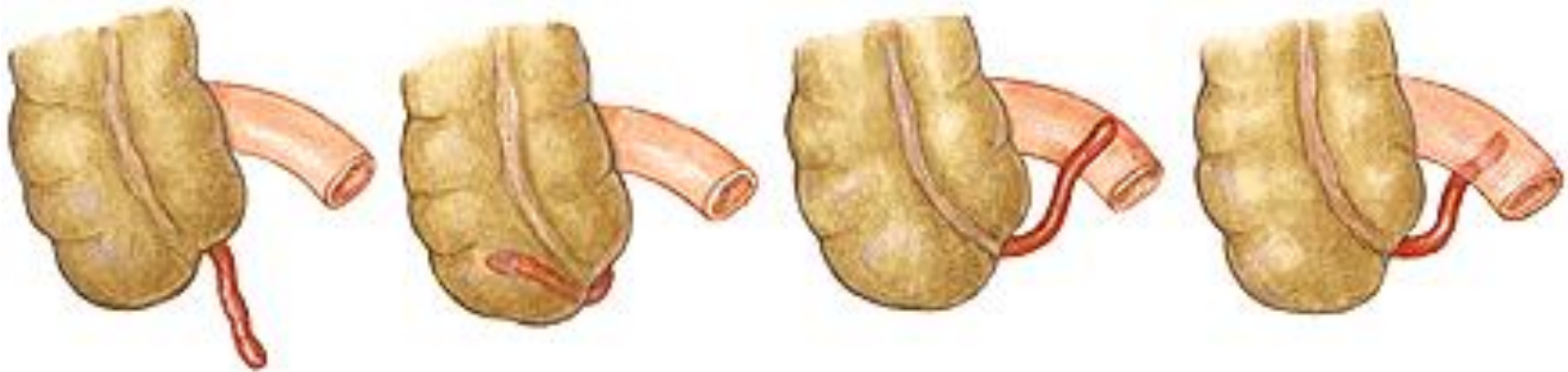
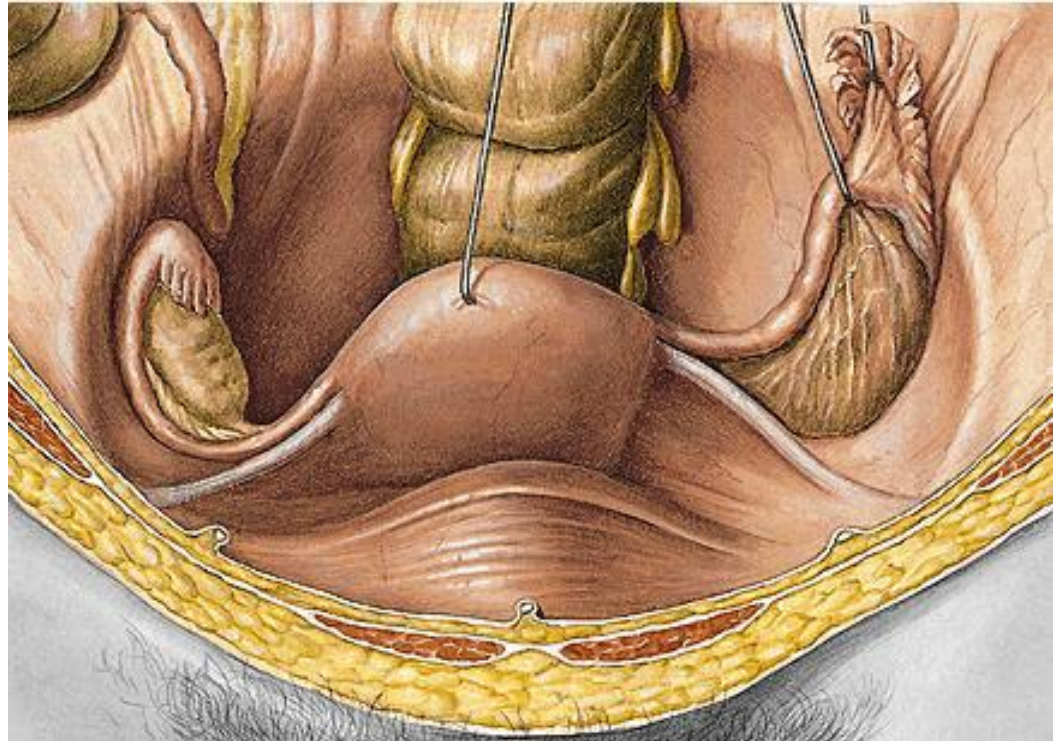
Positio retrocaecalis

Positio ileocaecalis

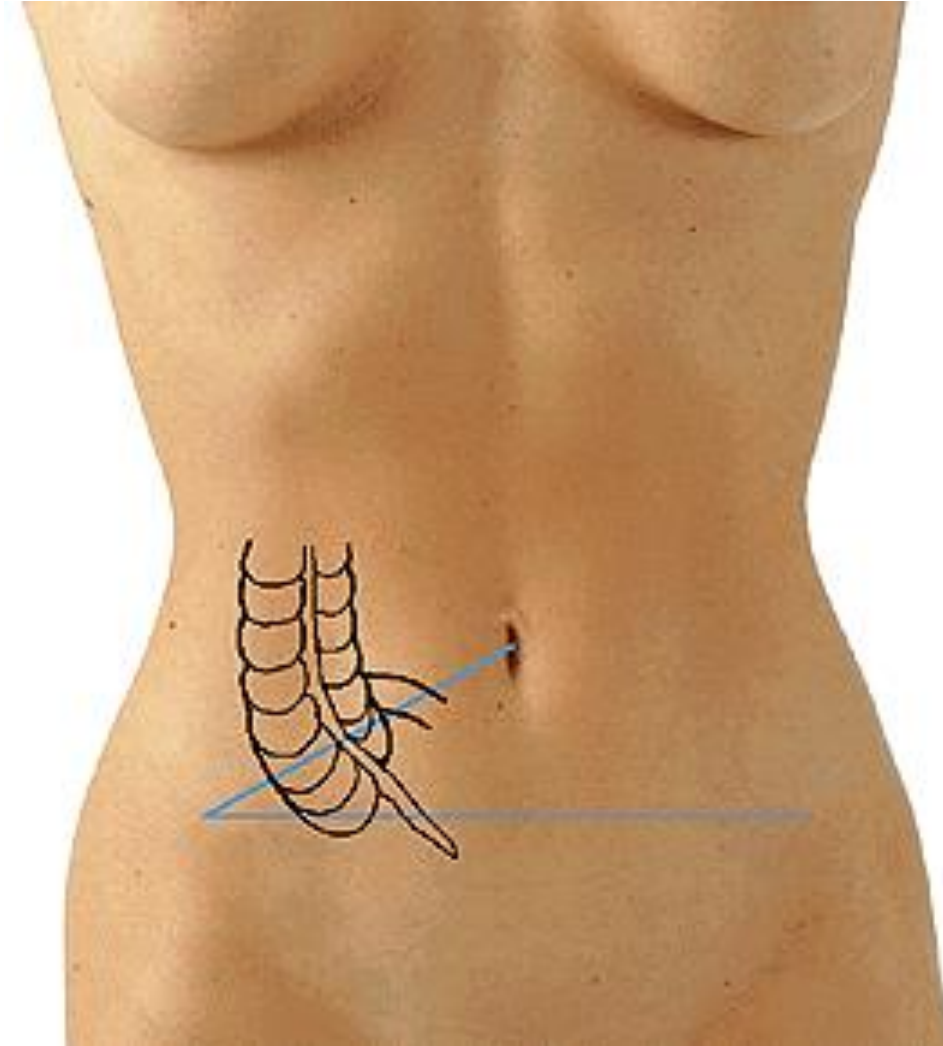
Positio praecaecalis

Positio laterocaecalis

Positio subcaecalis



Monroova čára (linea spinoumbilicalis dextra) – Mac Burneův bod
Linea bispinalis – Lanzův bod



Retroperitoneum

Primárně retroperitoneální (ledviny, nadledviny, pohl. žlázy)

Sekundárně retroperitoneální:

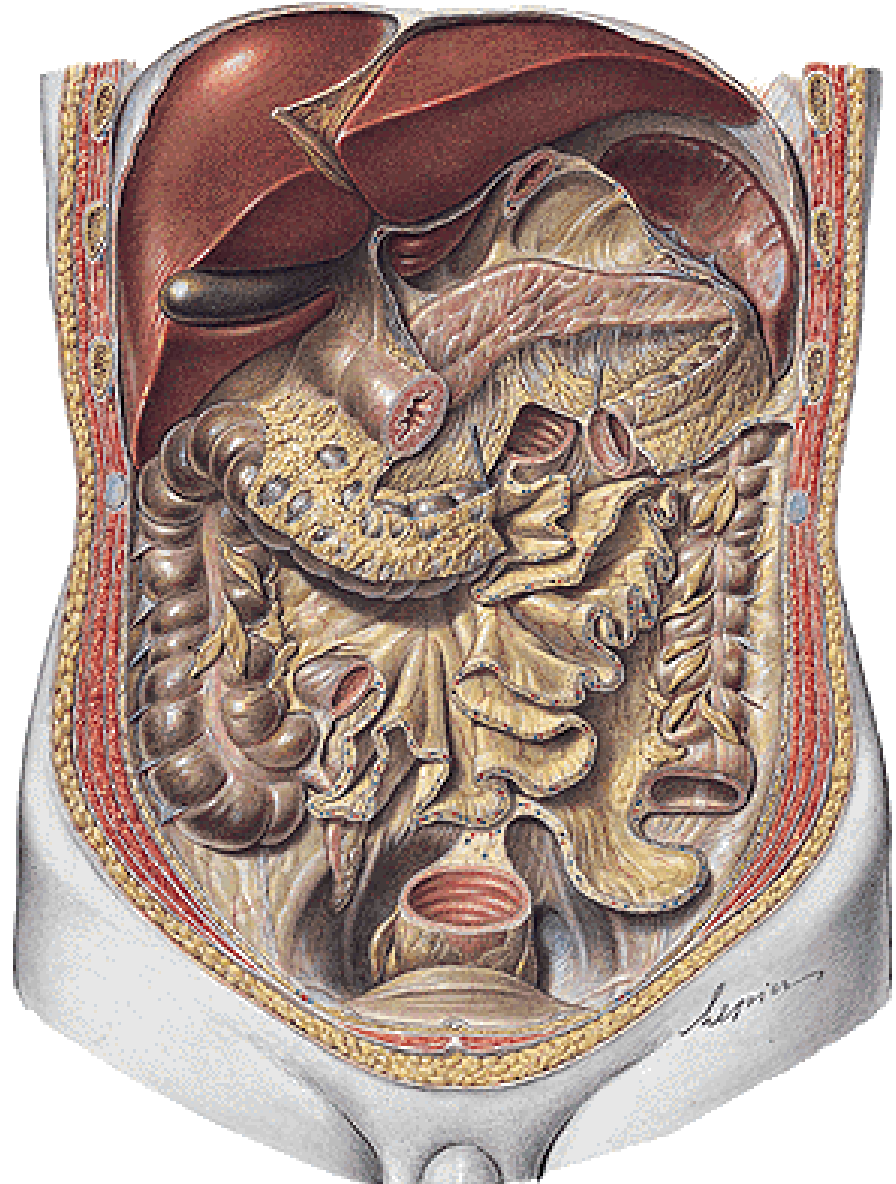
Duodenum (bez pars sup.)

Pancreas

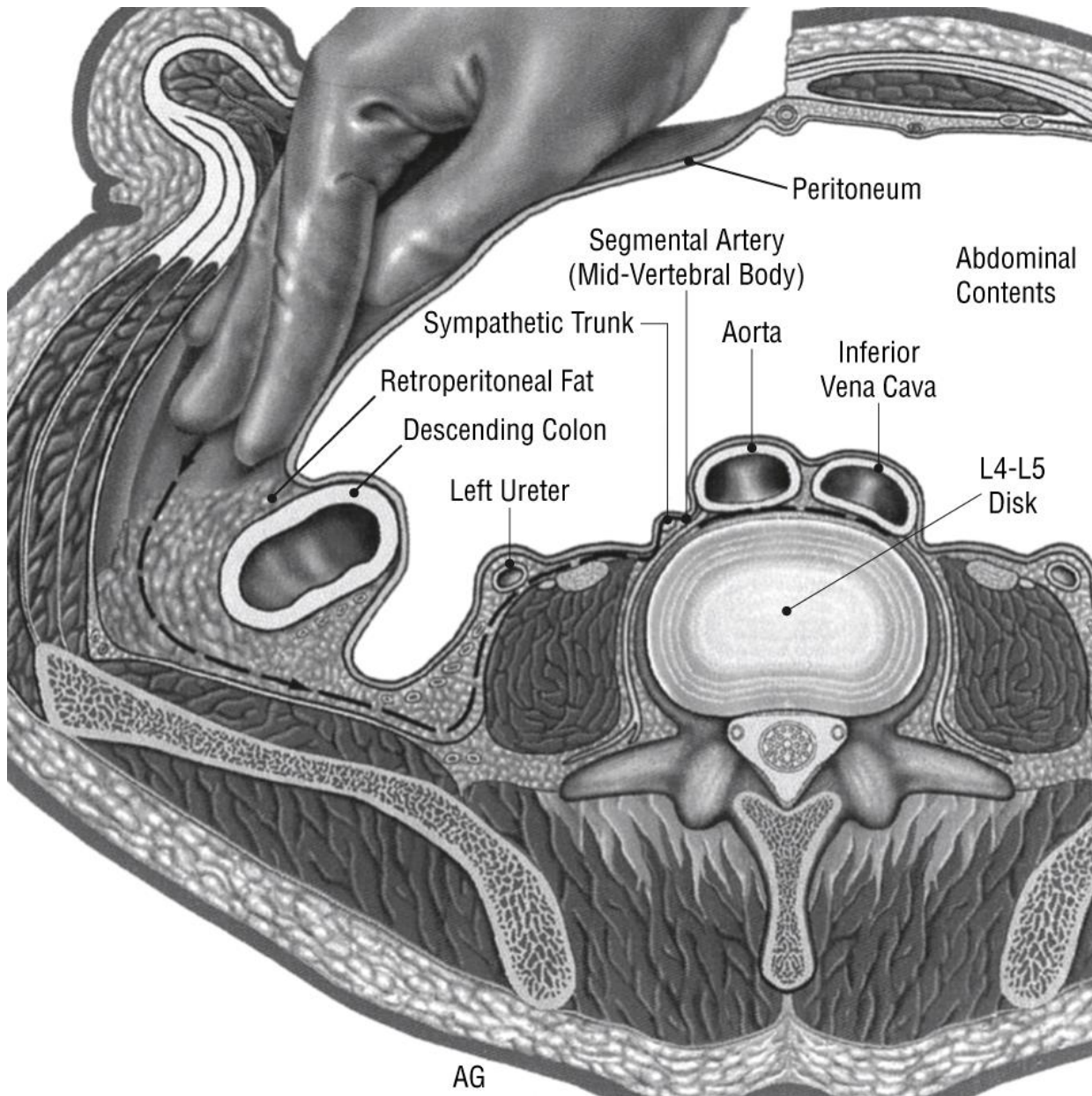
Caecum

Colon ascendens

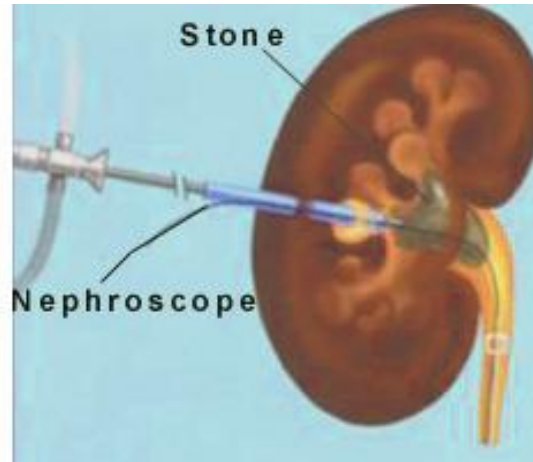
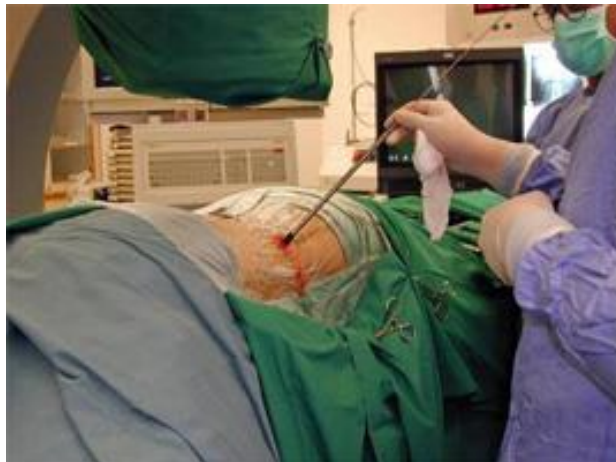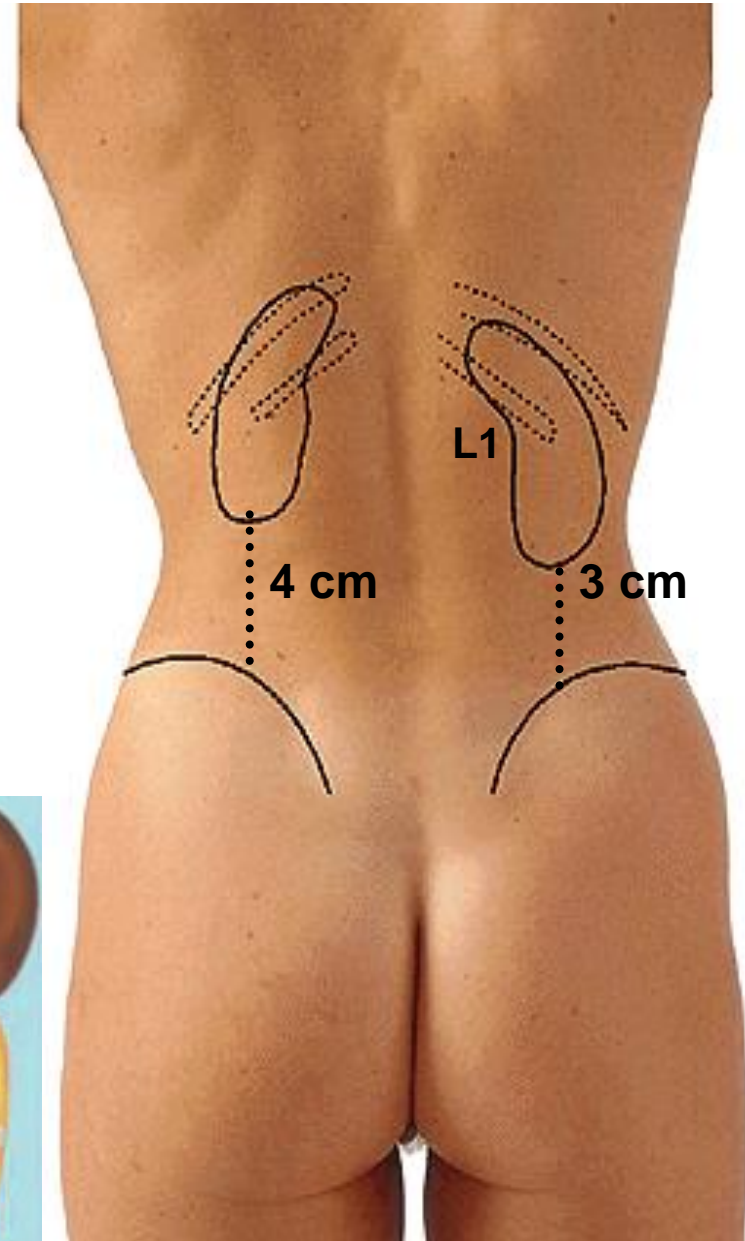
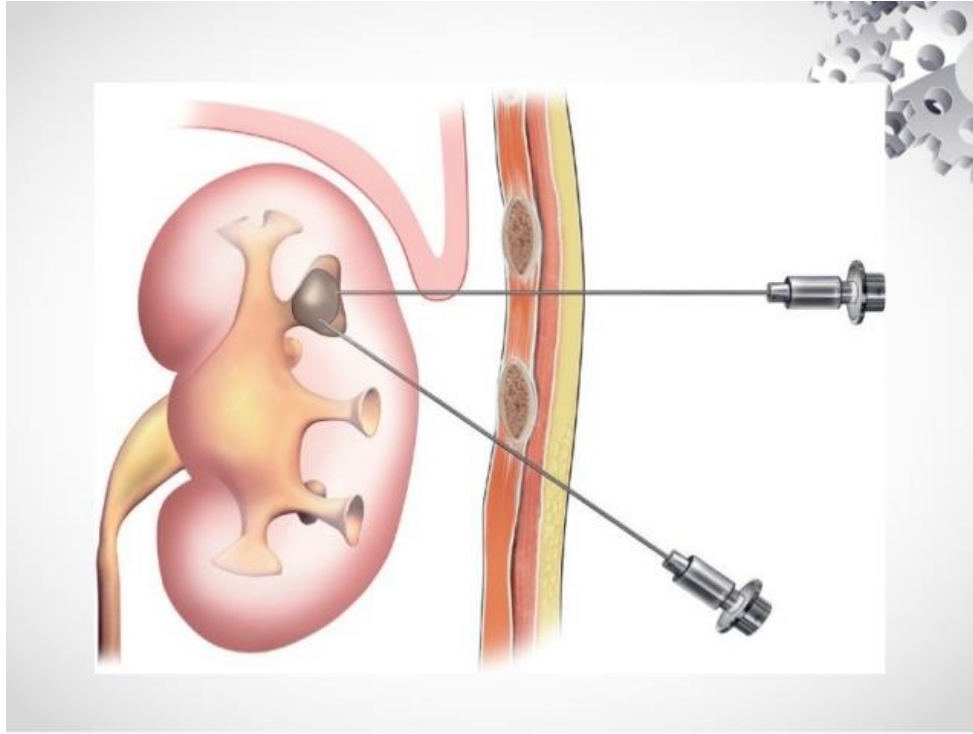
Colon descendens



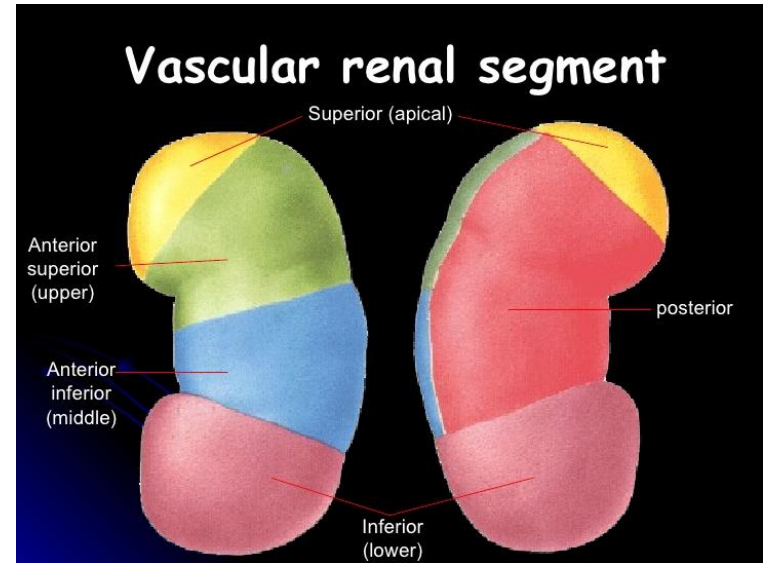
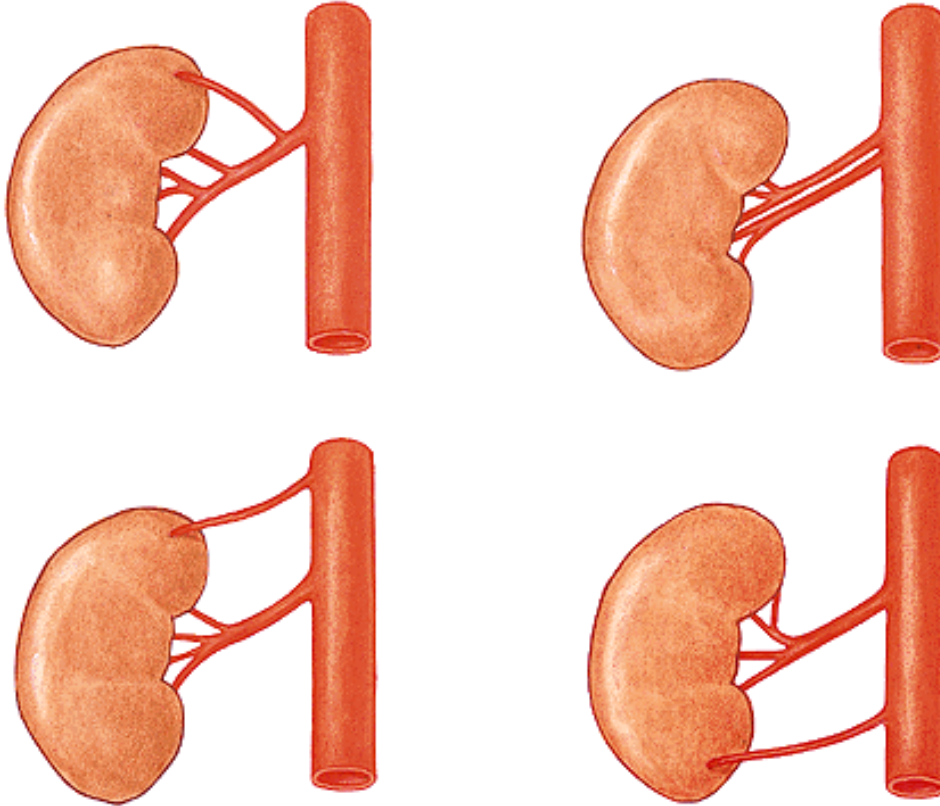
Extraperitoneální přístup



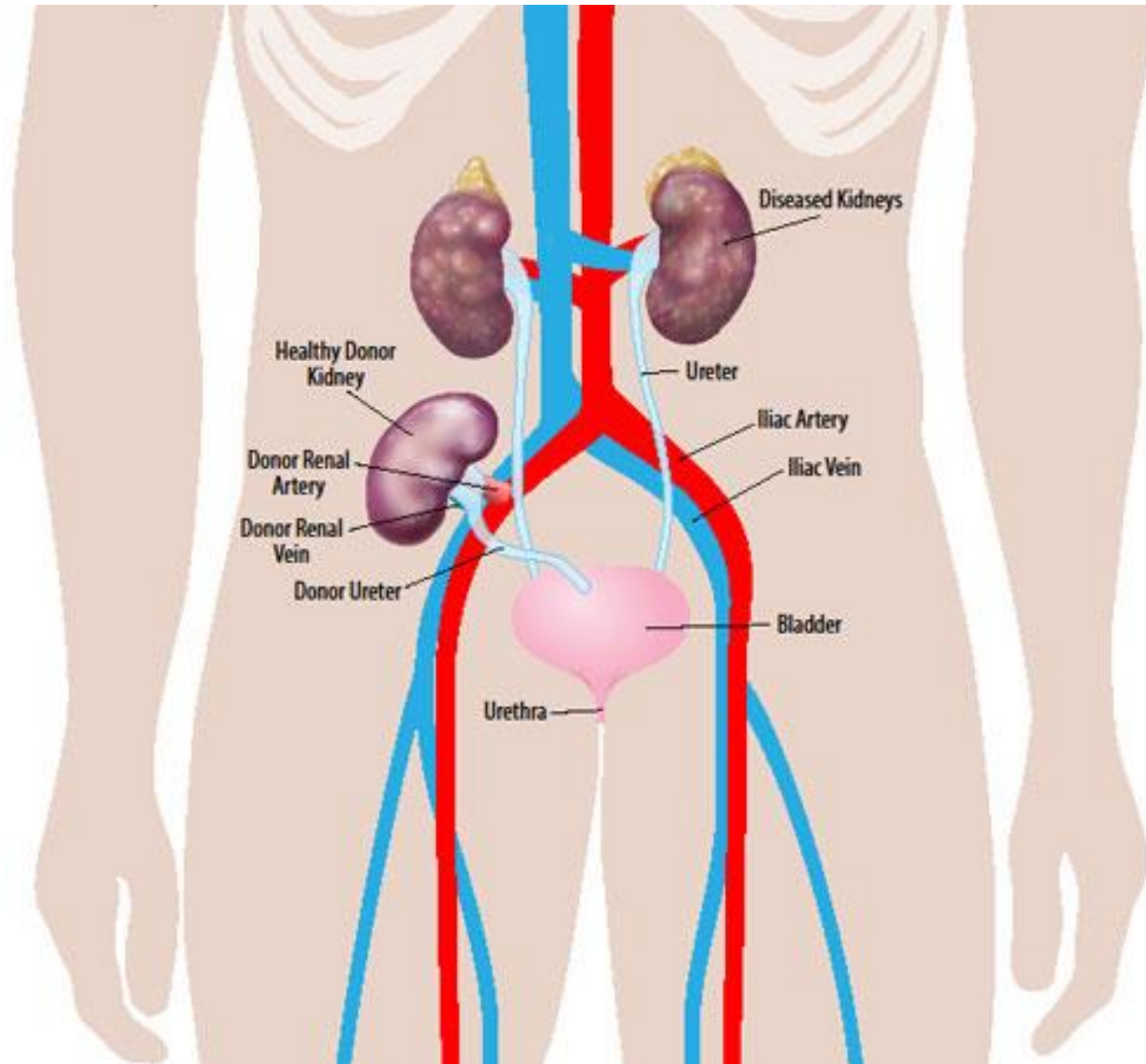
Pozice ledvin a punkce



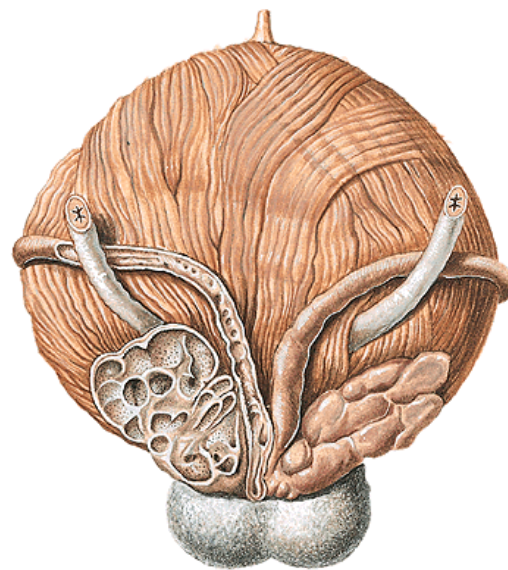
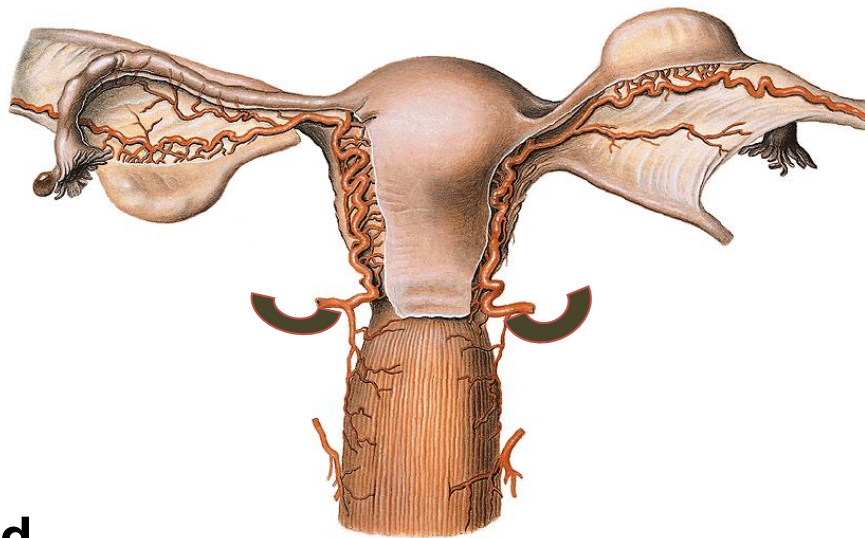
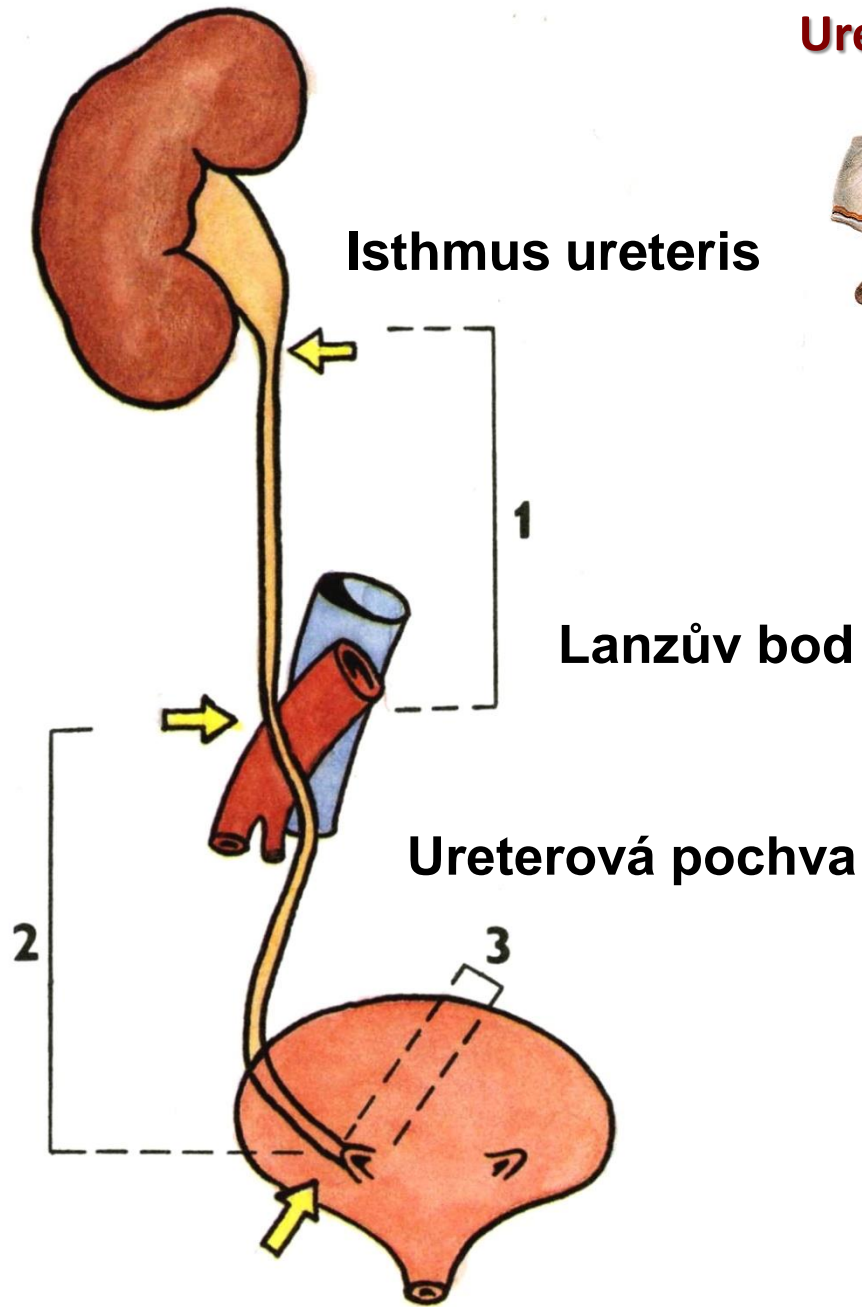
Ledvinné segmenty a cévní zásobení



Transplantace ledvin



Ureter



Aneuryzma abdominální aorty

