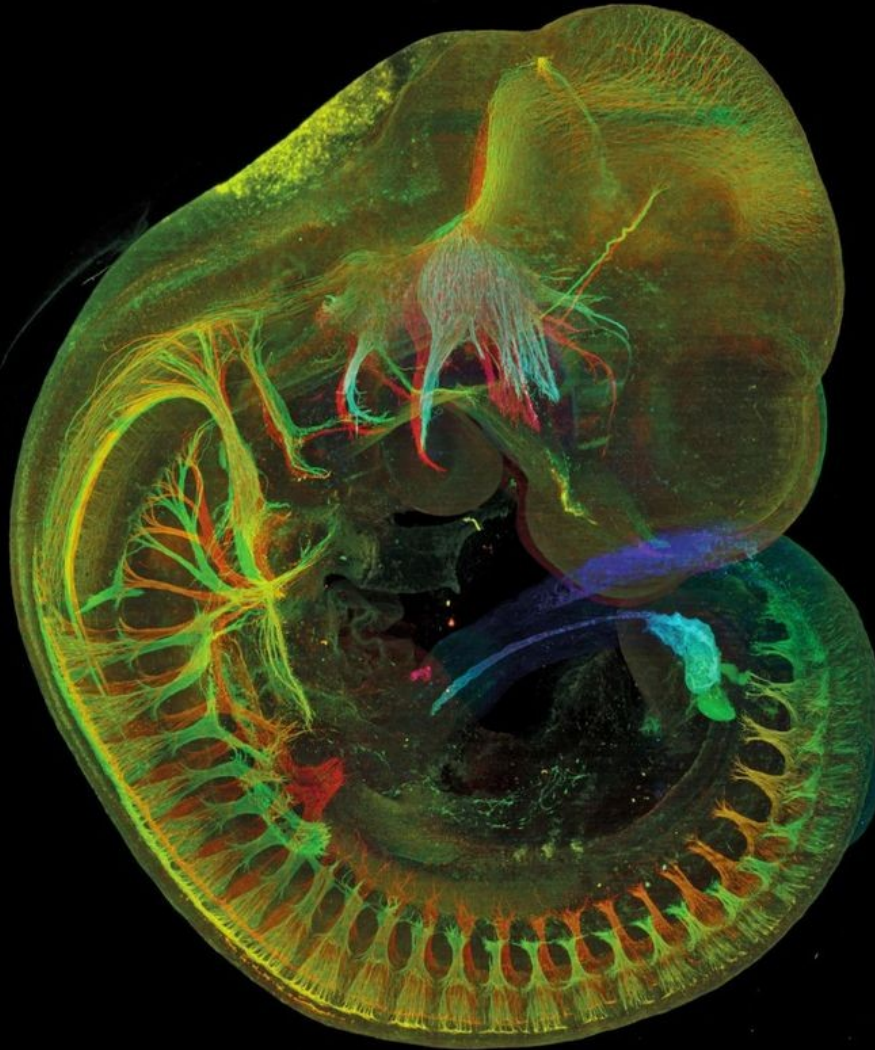

I. Revision of embryonic and fetal development

Petr Vaňhara,
Dept. of Histology and Embryology
LF MU



Gametogenesis

From fertilization to early embryo

Embryogenesis to 8th week

Fetal development

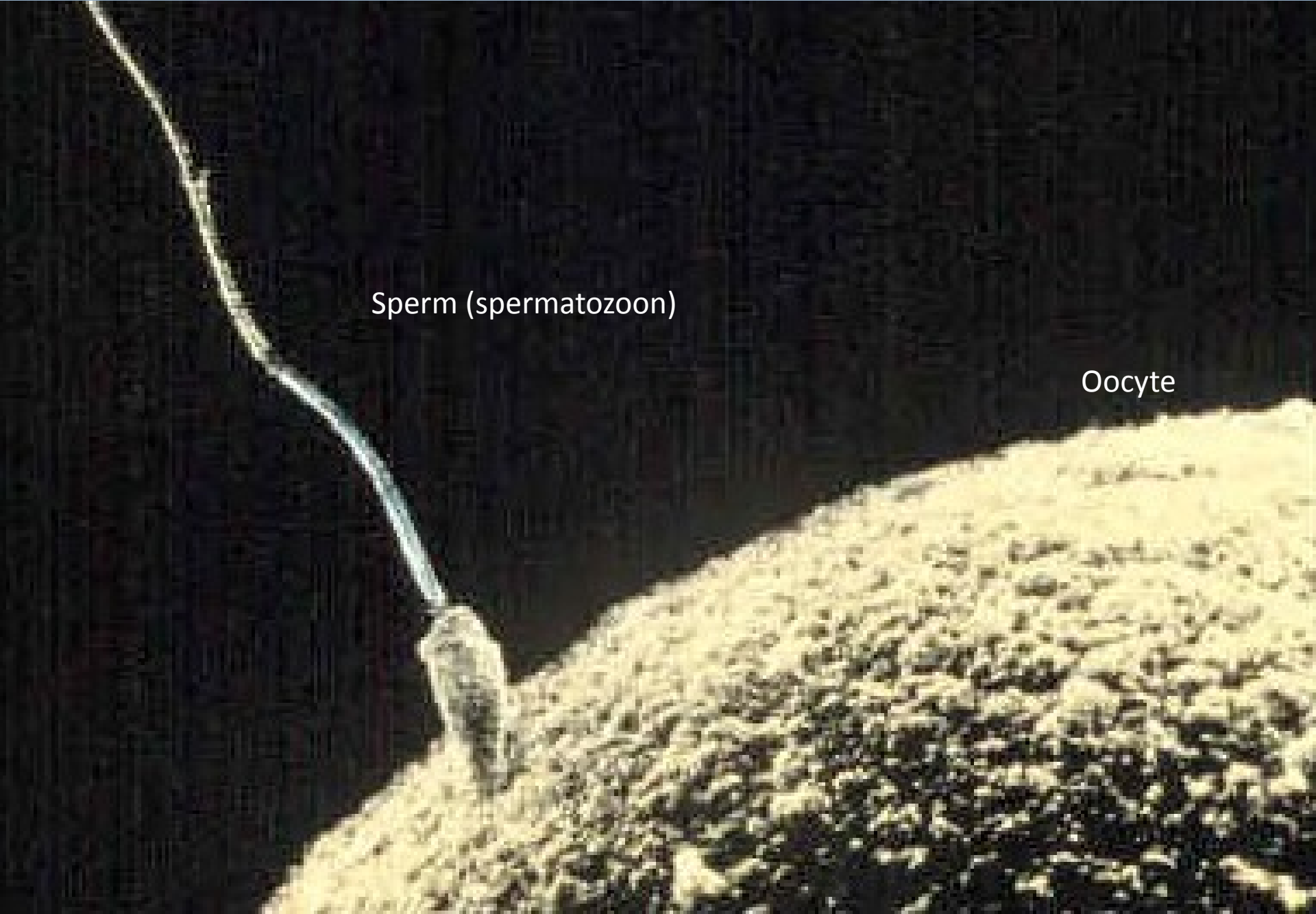
Fetal position in uterus,
hallmarks of newborn

Introduction to teratology and
prenatal diagnostics

GAMETOGENESIS

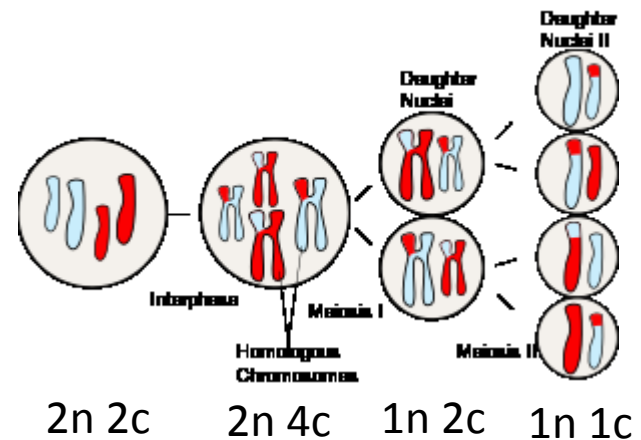
Sperm (spermatozoon)

Oocyte

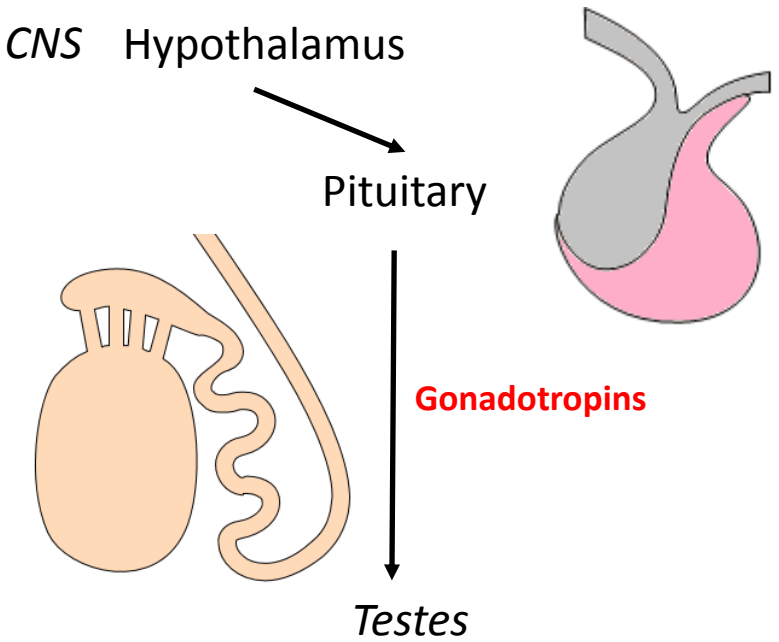


GAMETOGENESIS

- meiosis
- diploid primordial germ cells → haploid gametes
- primordial germ cells
 - extraembryonic origin
 - **spermatogonia** → spermatogenesis and spermiogenesis → **spermatozoon**
 - **oogonia** → oogenesis → **oocyte** (→ ovum)
- gonad
 - unique microenvironment for development of gametes
 - endocrine axis hypothalamus-pituitary gl.
 - important endocrine functions

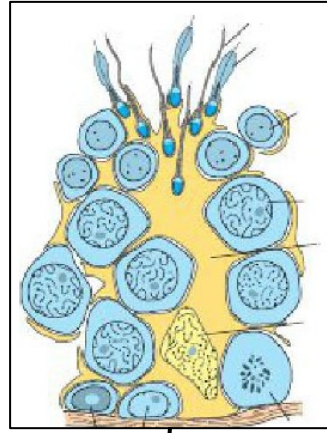


SPERMATOGENESIS AND SPERMIOGENESIS



Spermatozoa

Spermatids



Secondary spermatocyte

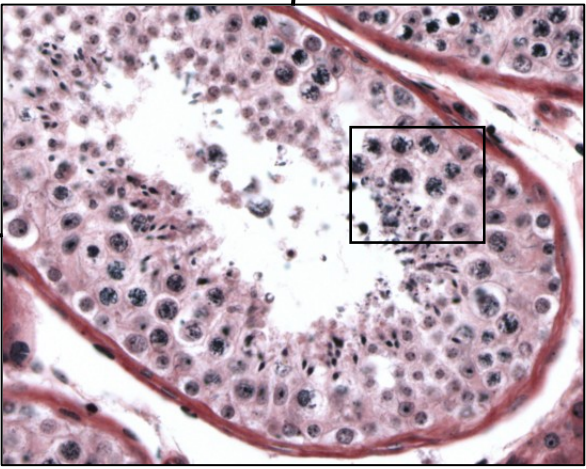
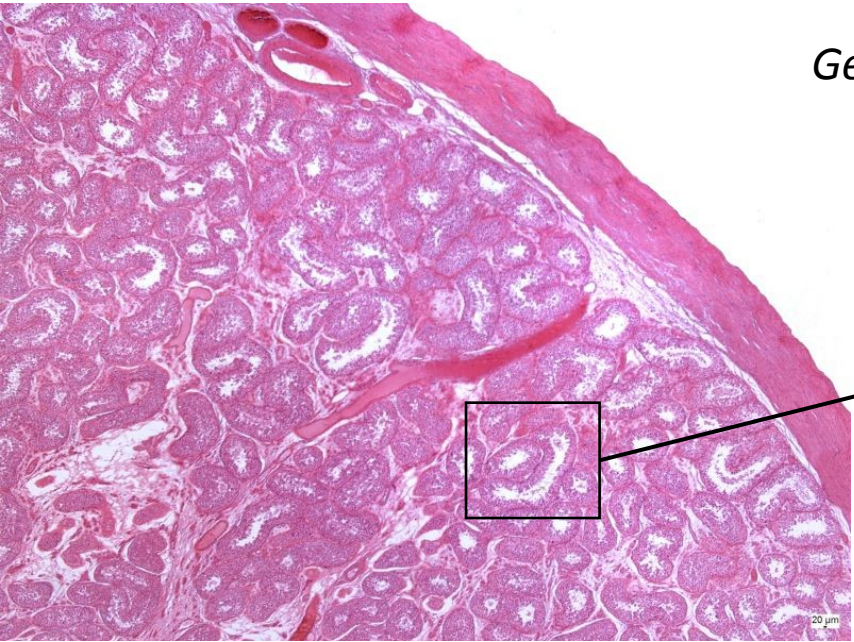
Primary spermatocyte

Cytoplasm of Sertoli cells

Nucleus of Sertoli cell

Spermatogonia

Germinal epithelium



20 μm

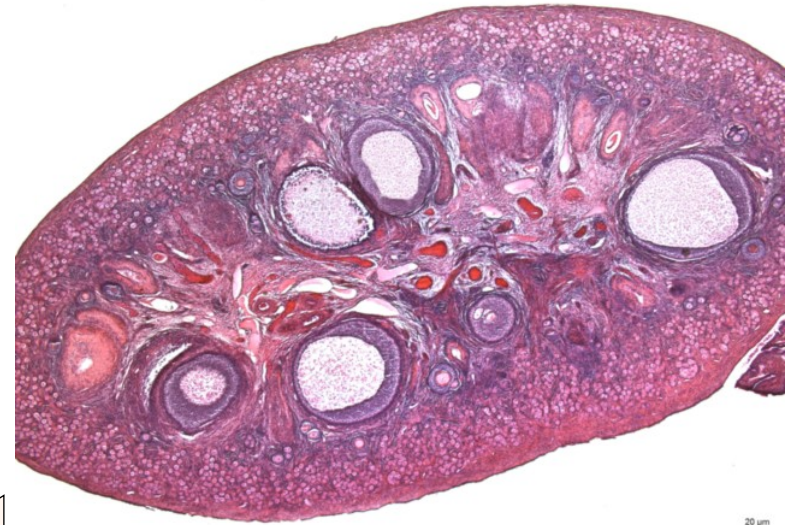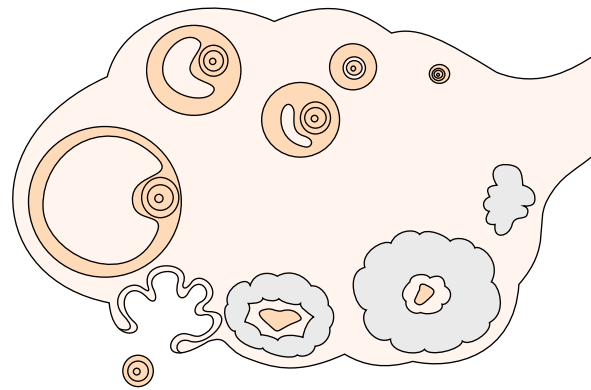
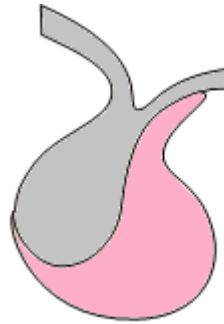OOGENESIS

CNS Hypothalamus

Pituitary

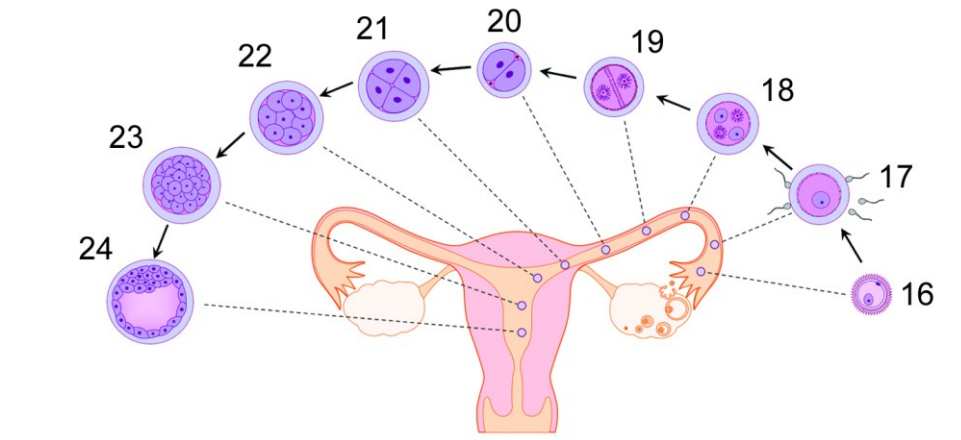
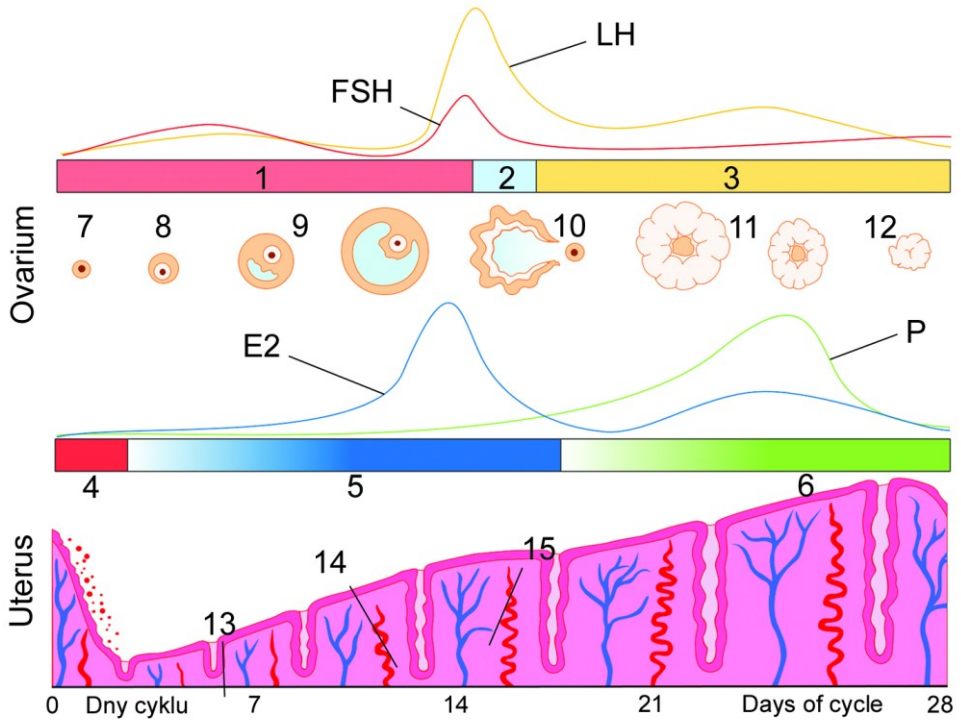
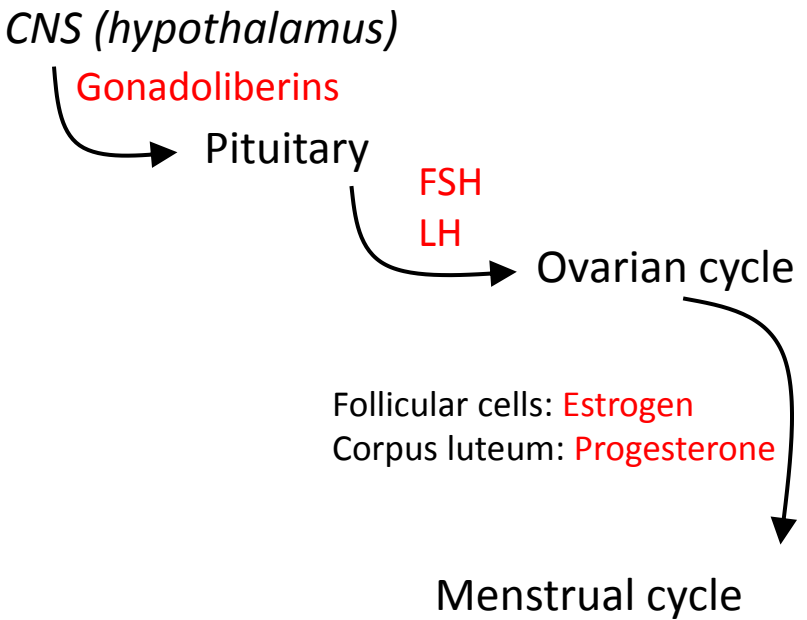
Gonadotropins

Ovarium



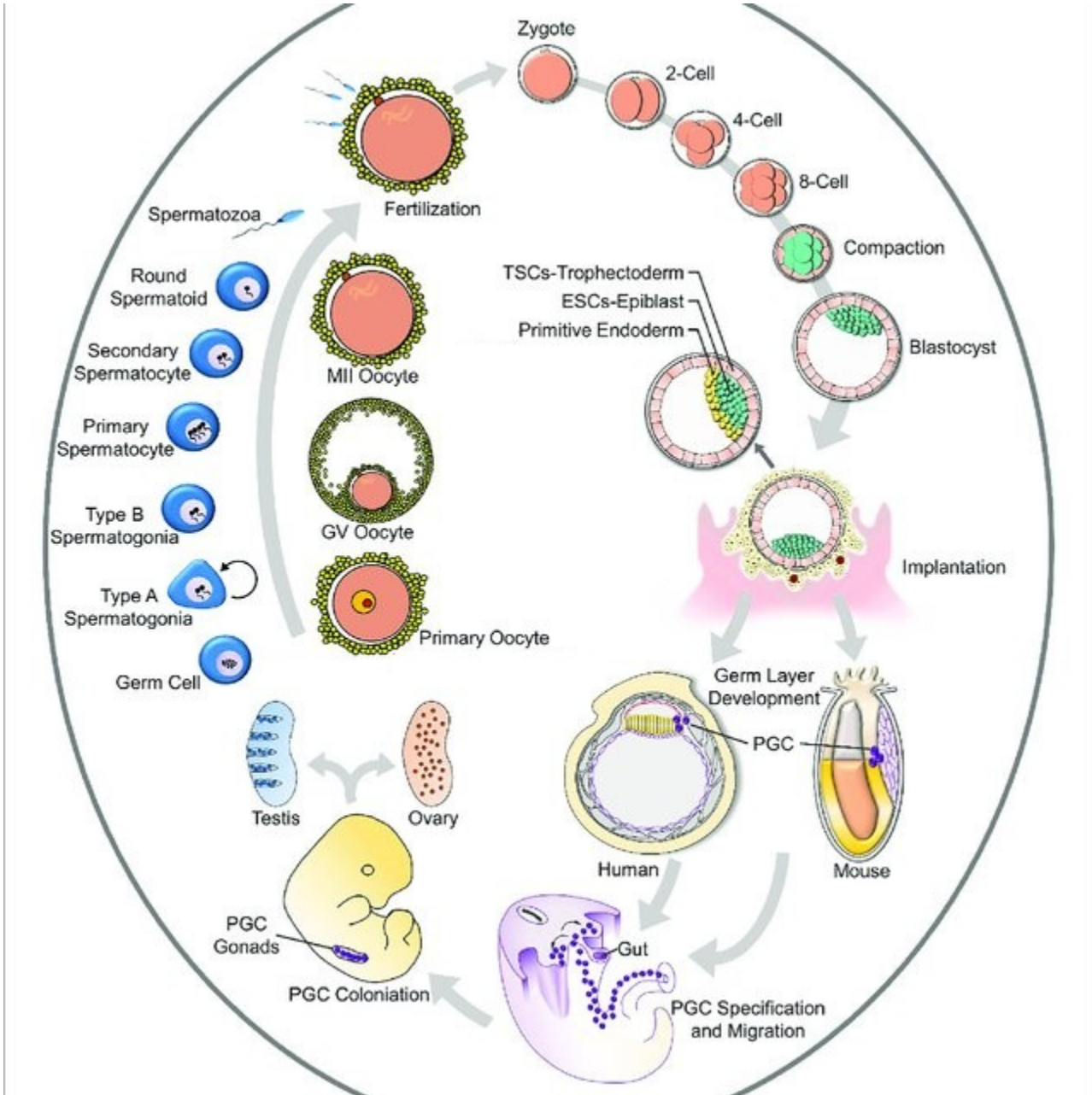
- Oogonia are present only during prenatal development *in utero*
- After birth, only primary oocytes in primordial follicles are present
- Cell cycle of primary oocyte is arrested in dictyotene stage of prophase M I until onset of puberty
- In each ovarian cycle (starting in puberty), a cohort of follicles enters maturation, however, usually only a single follicle reaches ovulation. Atresia of the remaining follicles in cohort.
- Primary oocyte → Secondary oocyte → Ovum (matures after fertilization)
- Primordial follicle → Primary follicle (unilaminar and multilaminar) → Secondary follicle → Graafian follicle (ovulation)
- Luteogenesis (formation of corpus luteum)

OVARIAN AND MENSTRUAL CYCLE



- Synchronization of oogenesis (in ovarium) and readiness of endometrium (uterine lining) to putative implantation.

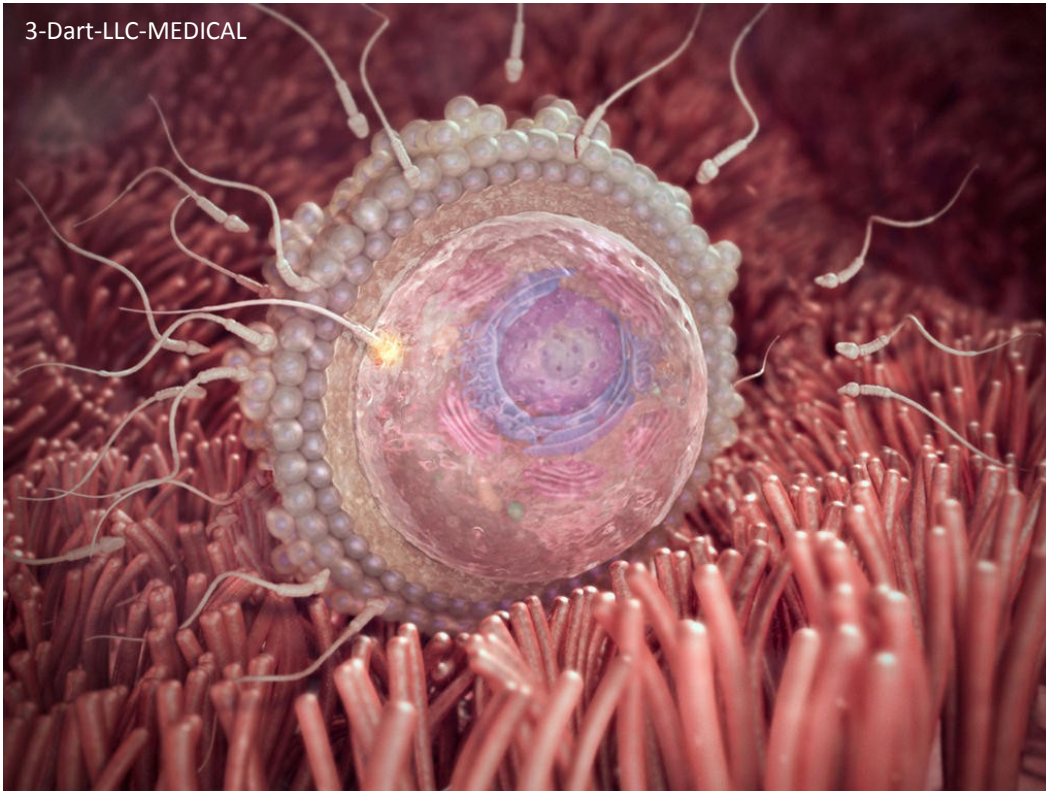
GAMETOGENESIS



FERTILIZATION

300-500×10⁶ sperms → Capacitation
Oocyte in metaphase MII → Ovulation

Ampulla of oviduct (most often)



Contact with *corona radiata*



Acrosomal reaction (acrosin)



Penetration of *zona pellucida*

Contact of sperm and oocyte



Cortical (zonal) reaction
(× polyspermy)



Fusion of oocyte and sperm

Re-entry of oocyte to cell cycle

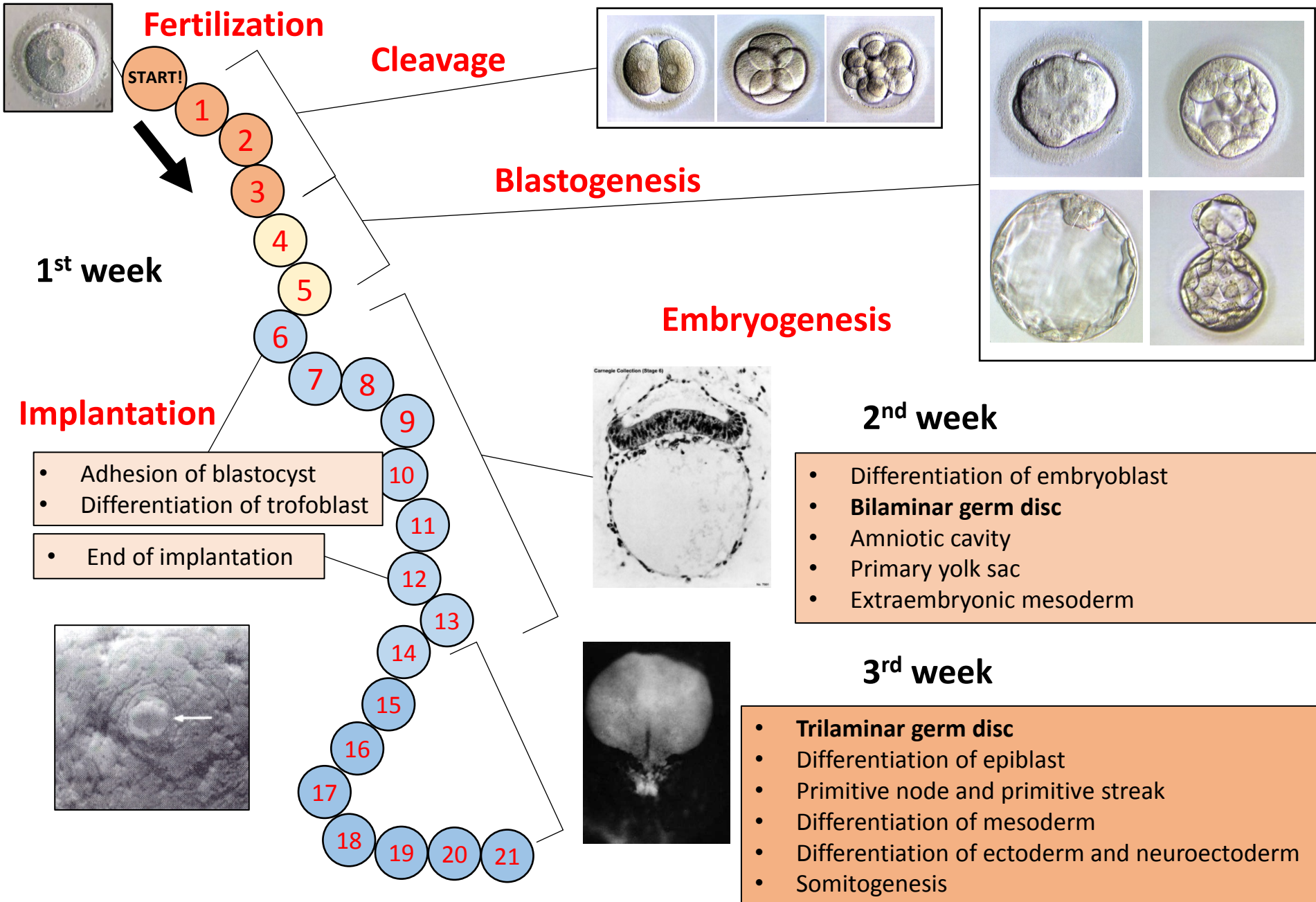
Generation of 2nd polar body

Replication of DNA of pronuclei

Fusion of pronuclei

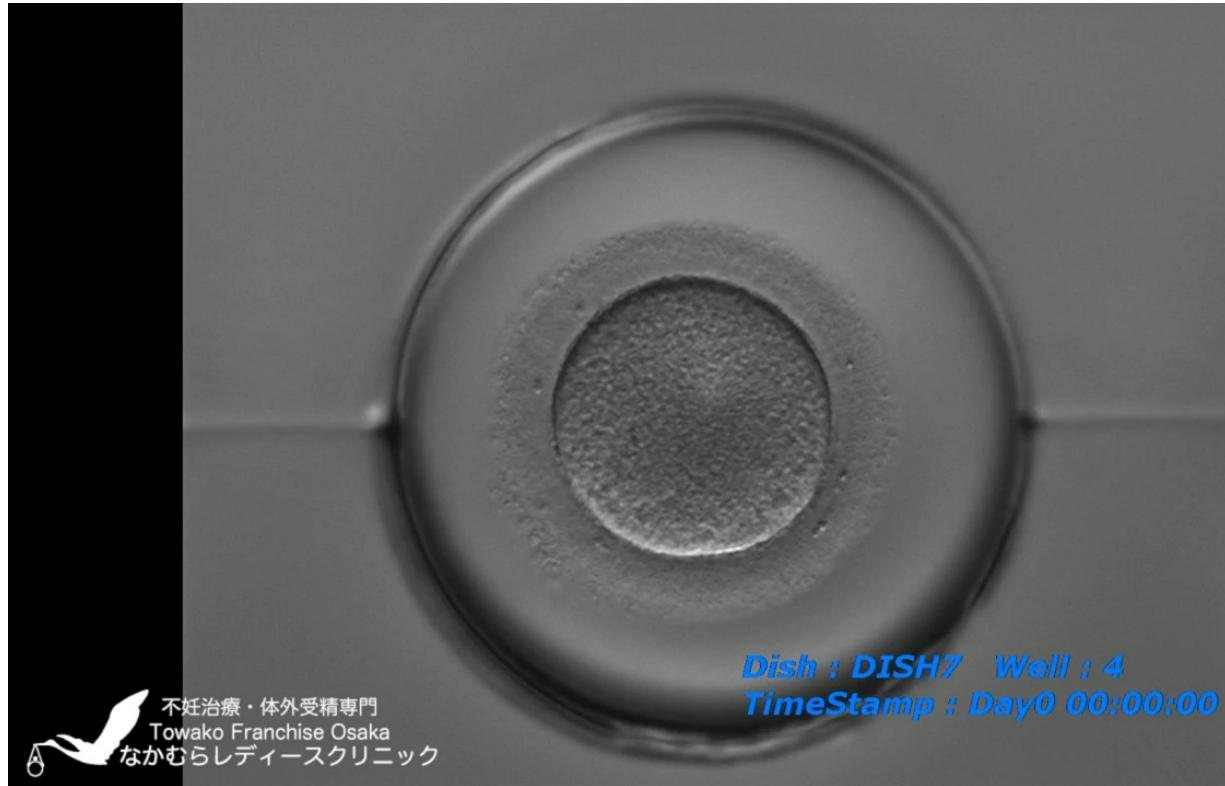
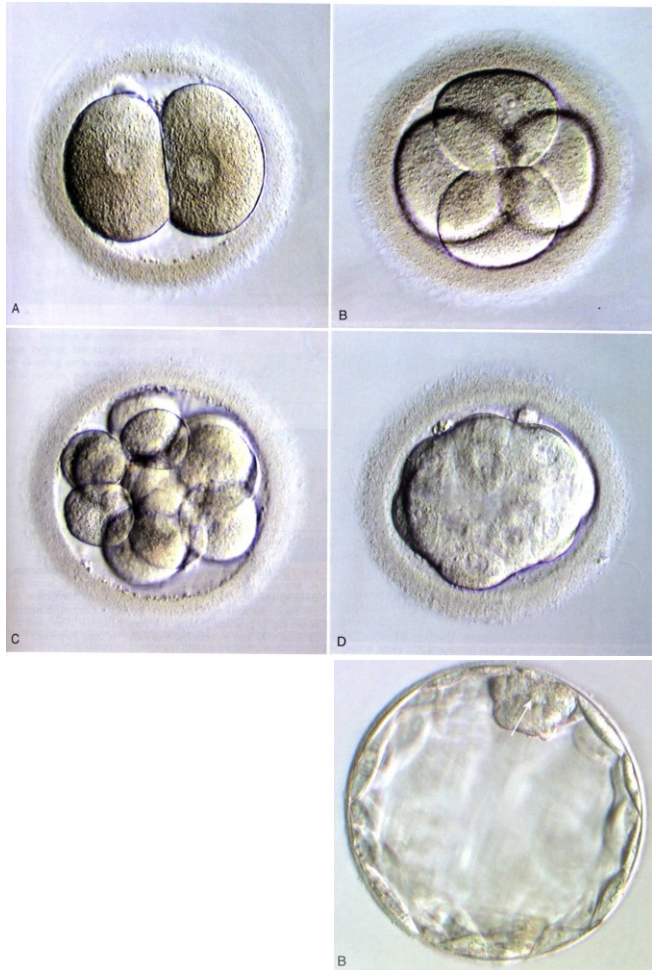
Beginning of cleavage

FIRST EVENTS IN HUMAN LIFE



1st week

WHAT IS DEVELOPMENTAL POTENTIAL OF BLASTOMERES?

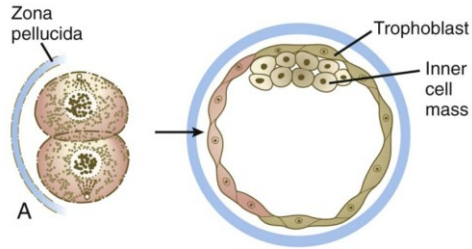


Really?

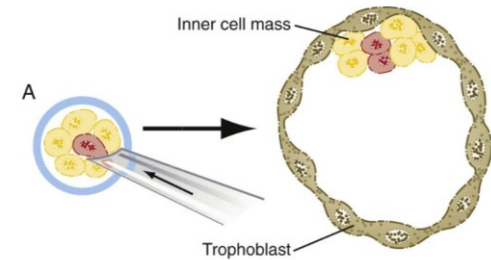
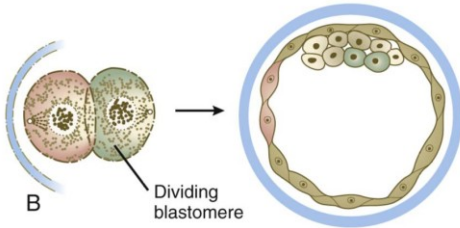
Conclusion: all blastomeres are equal.

1st week

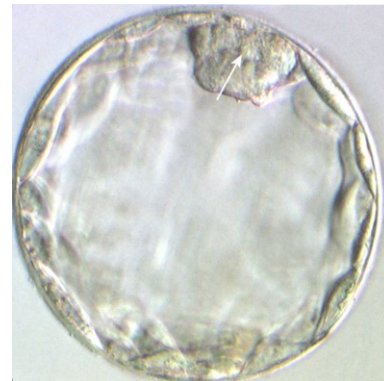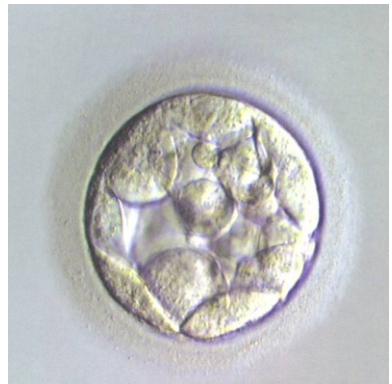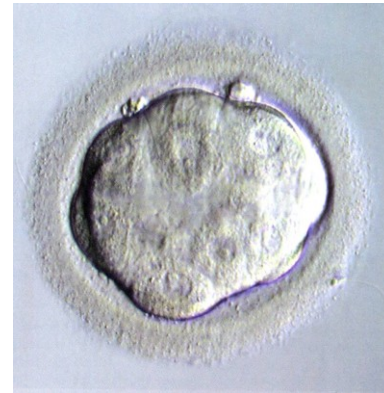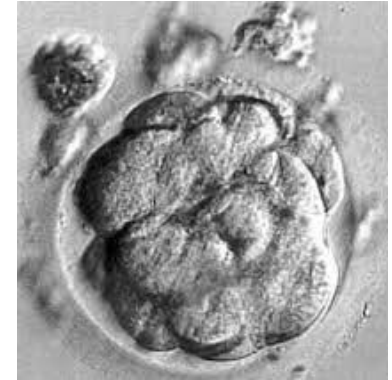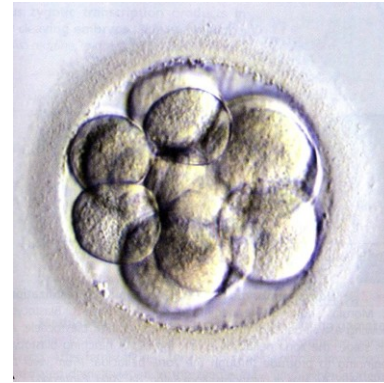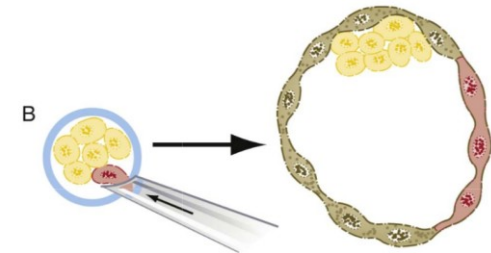
Mechanism of differentiation



„cell polarity“



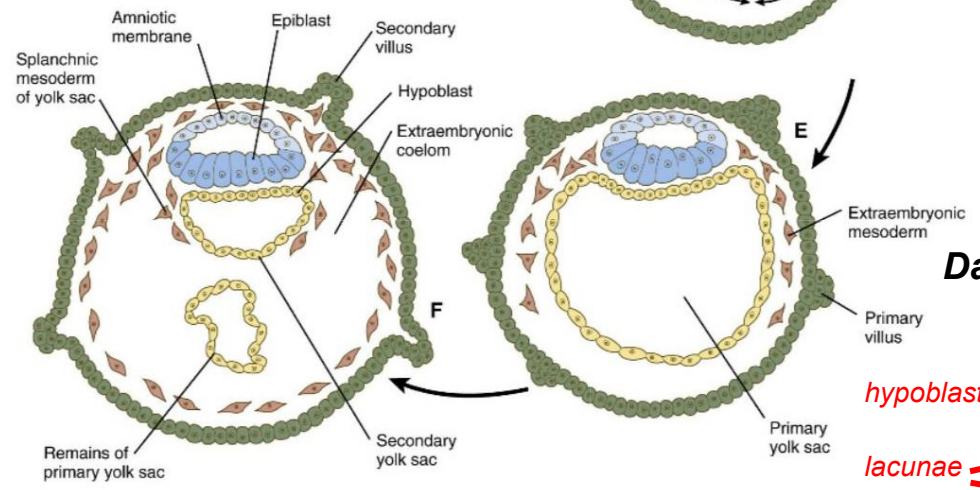
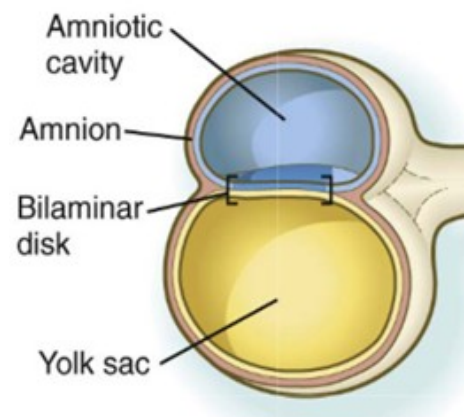
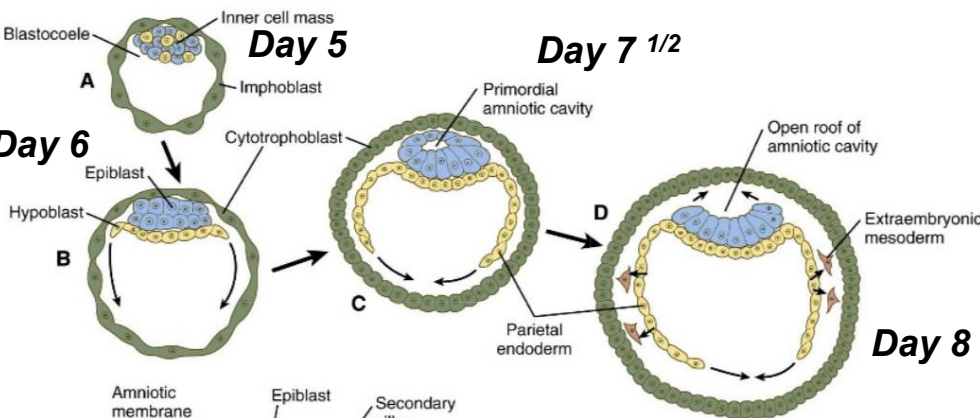
„inside-outside“



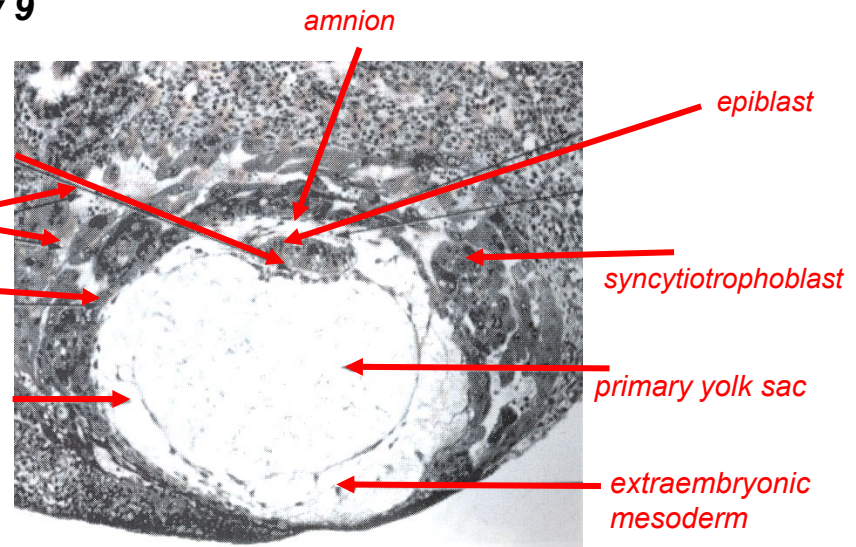
- 16-cell embryo is still totipotent – later (32-cell), it loses the full developmental potential → cell are **determined**.

1st-2nd week

BILAMINAR GERM DISC



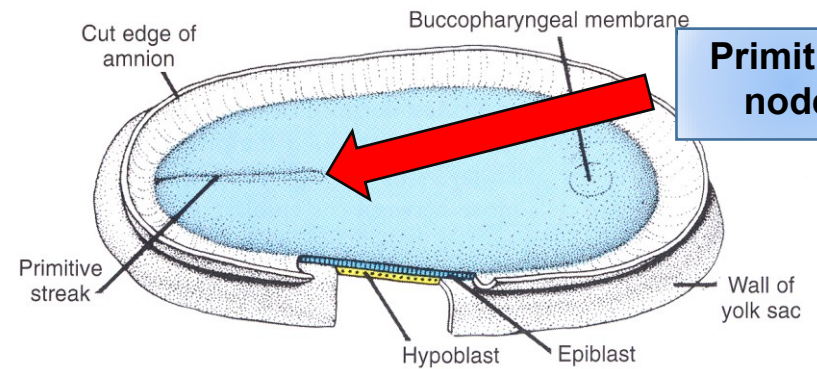
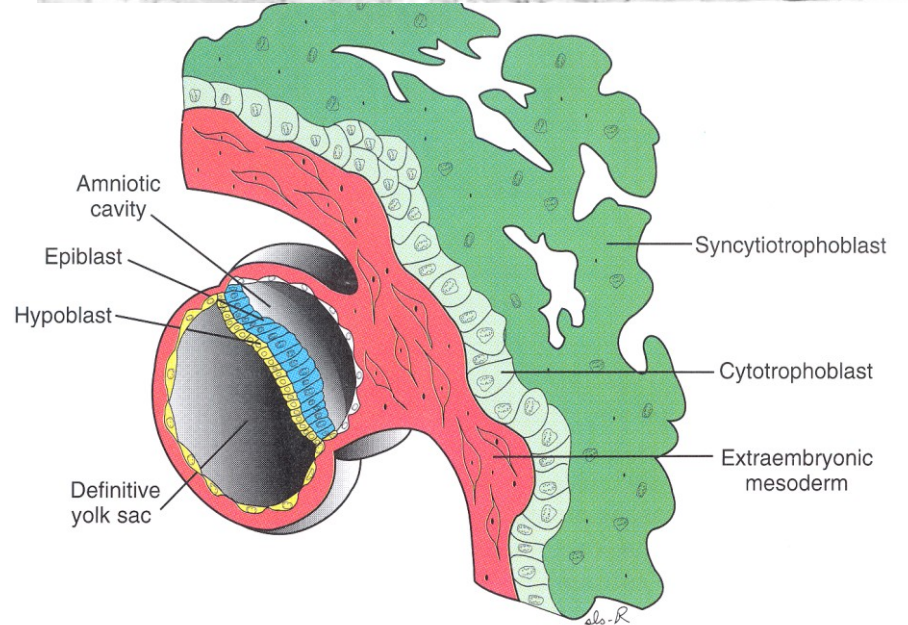
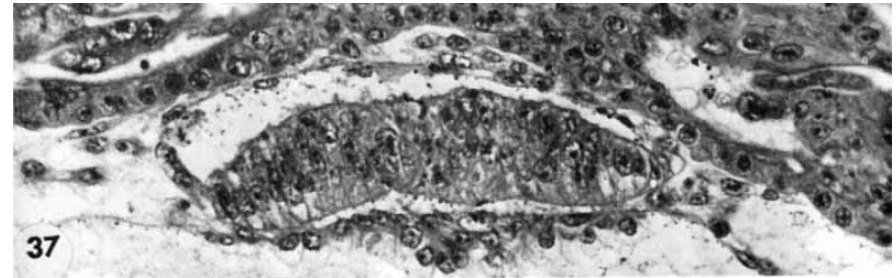
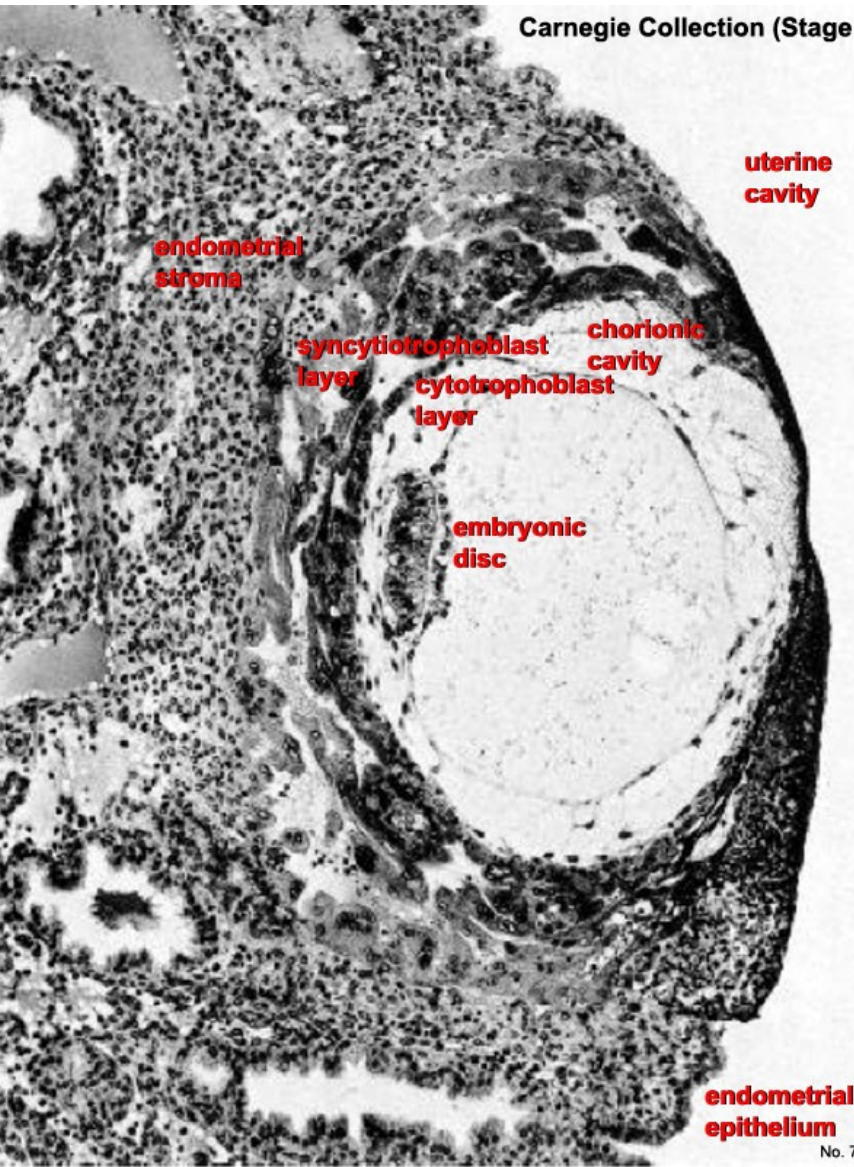
end of 2nd week



ORGANIZER EXISTS IN MAMMALS

BILAMINAR GERM DISC

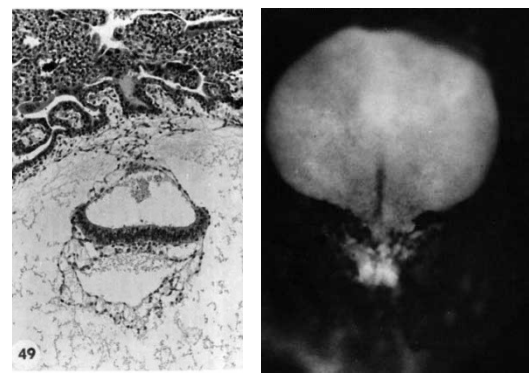
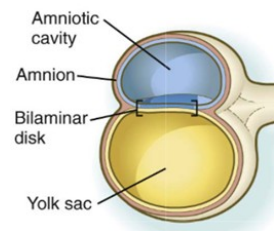
2nd week



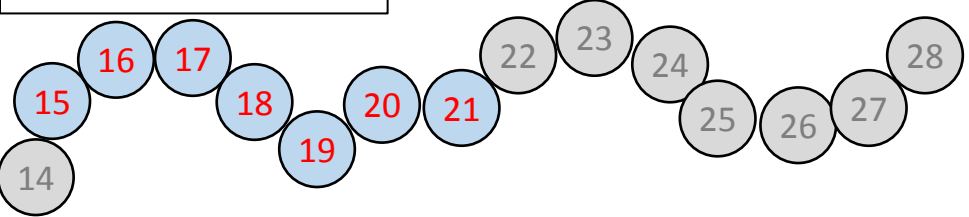
TRILAMINAR GERM DISC

PRIMITIVE STREAK AND PRIMITIVE NODE

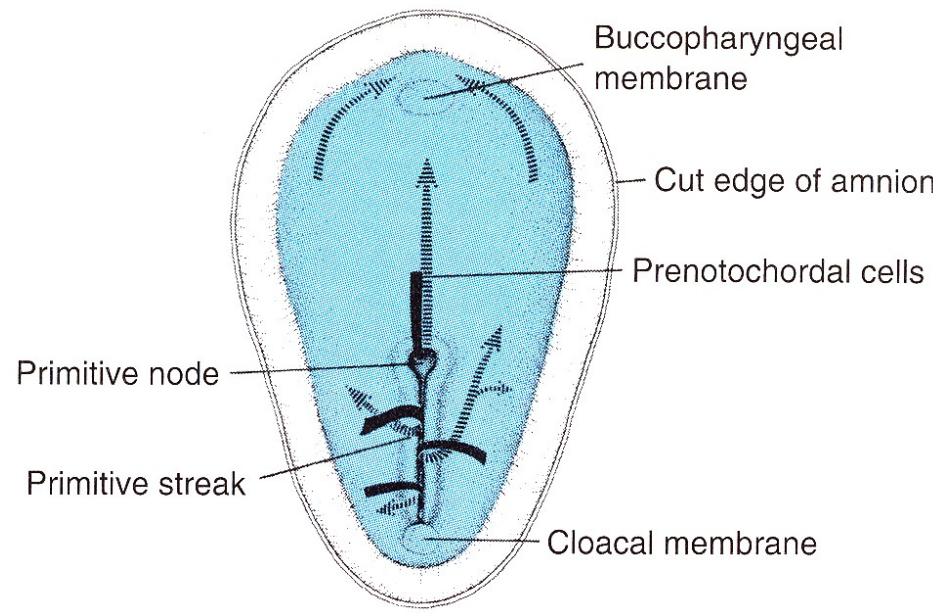
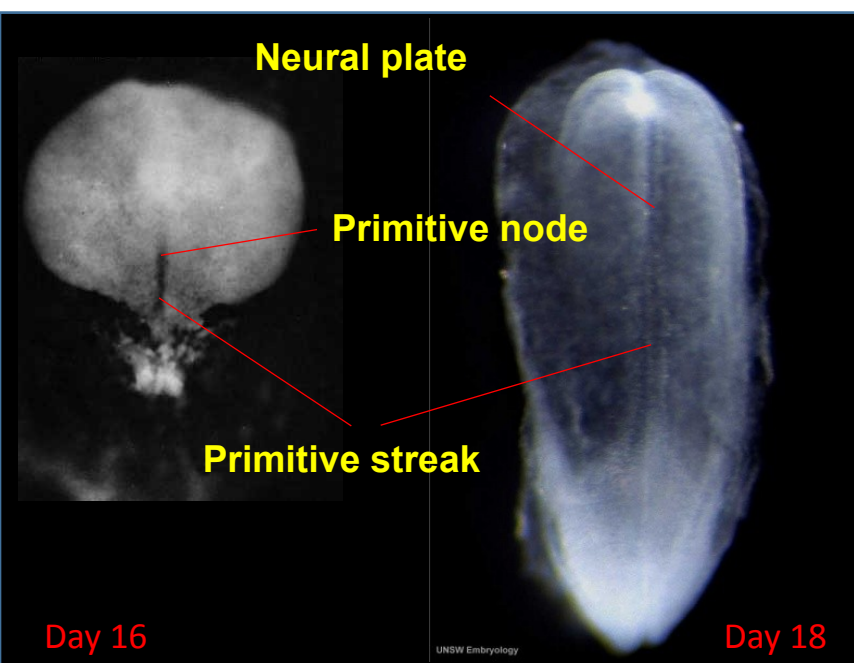
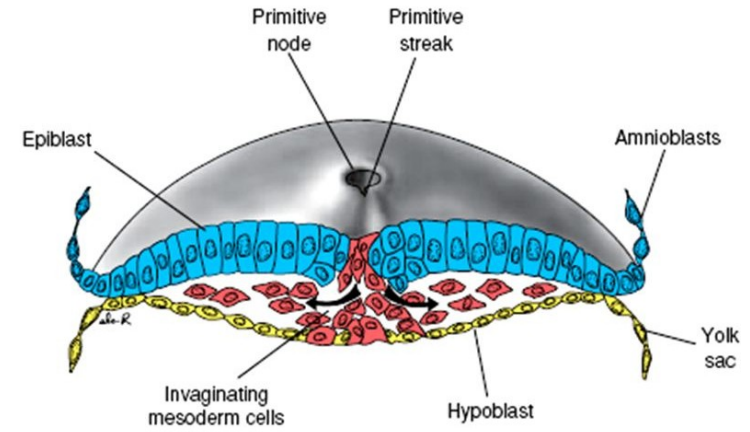
2nd week ends



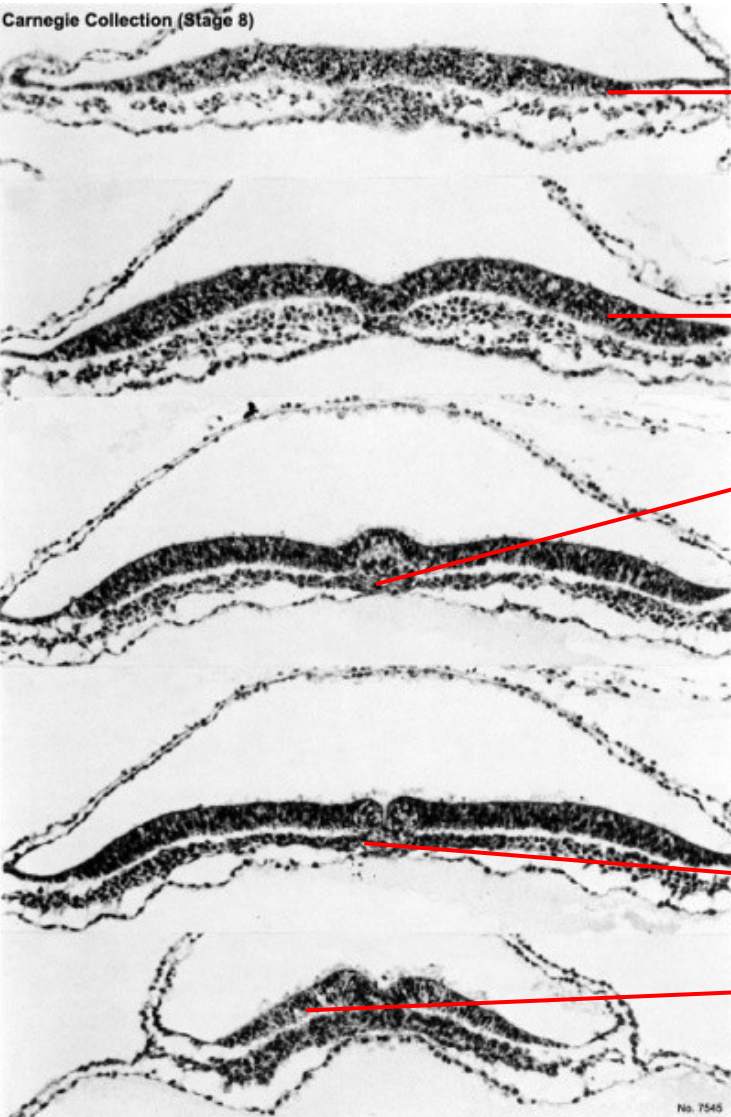
3rd week begins



NEW STRUCTURES



3rd week



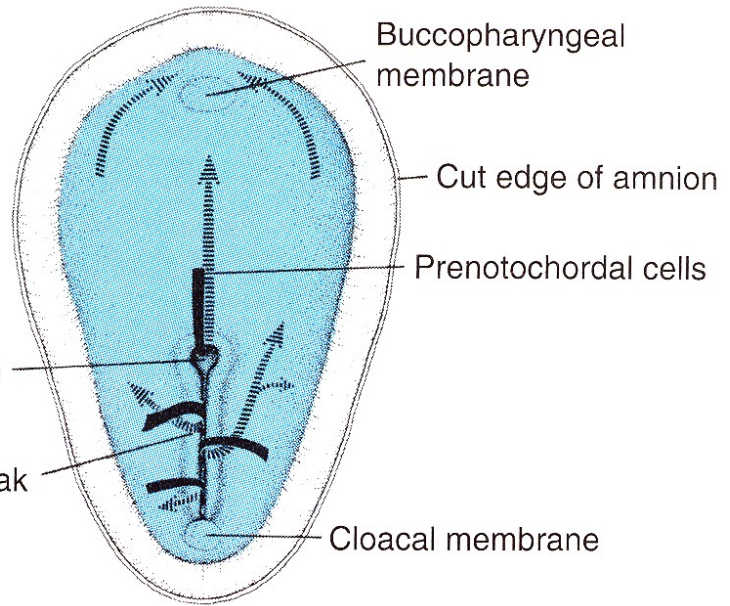
Prechordal plate

Neural plate

Notochordal process

Primitive node

Primitive streak



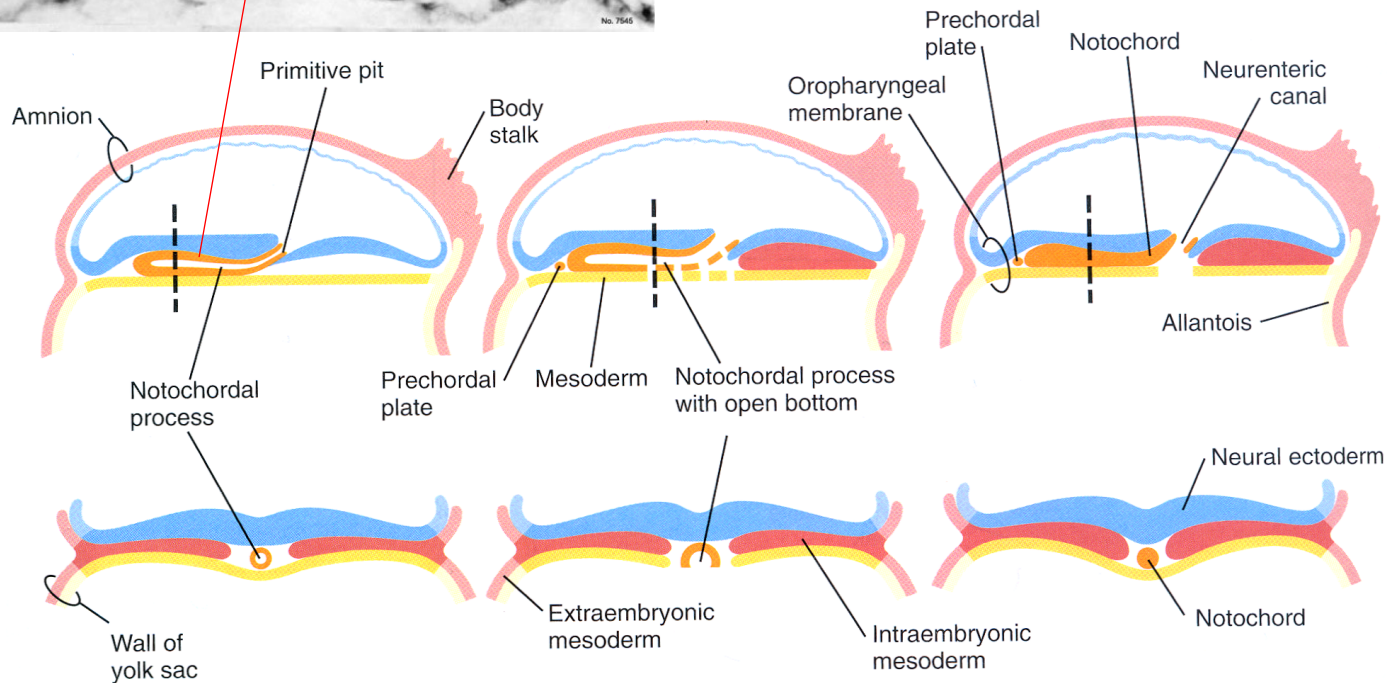
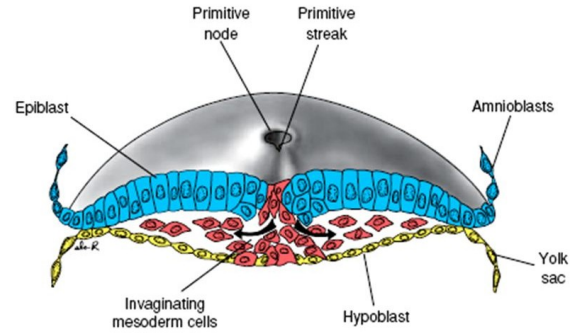
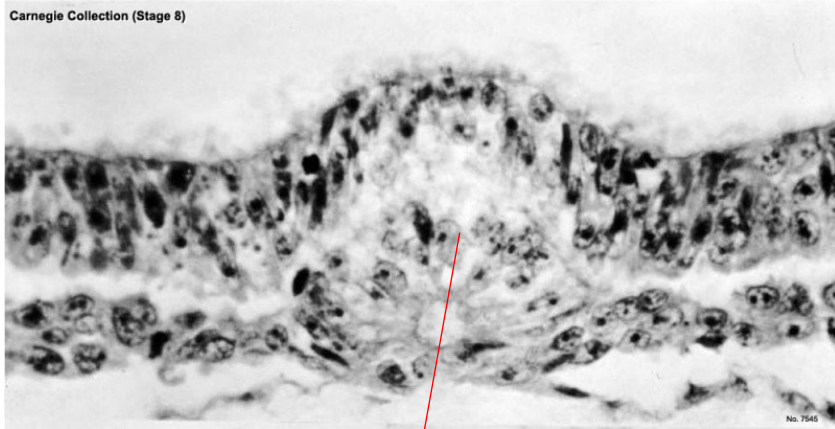
Buccopharyngeal membrane

Cut edge of amnion

Prenotochordal cells

Cloacal membrane

3rd week



Day 17

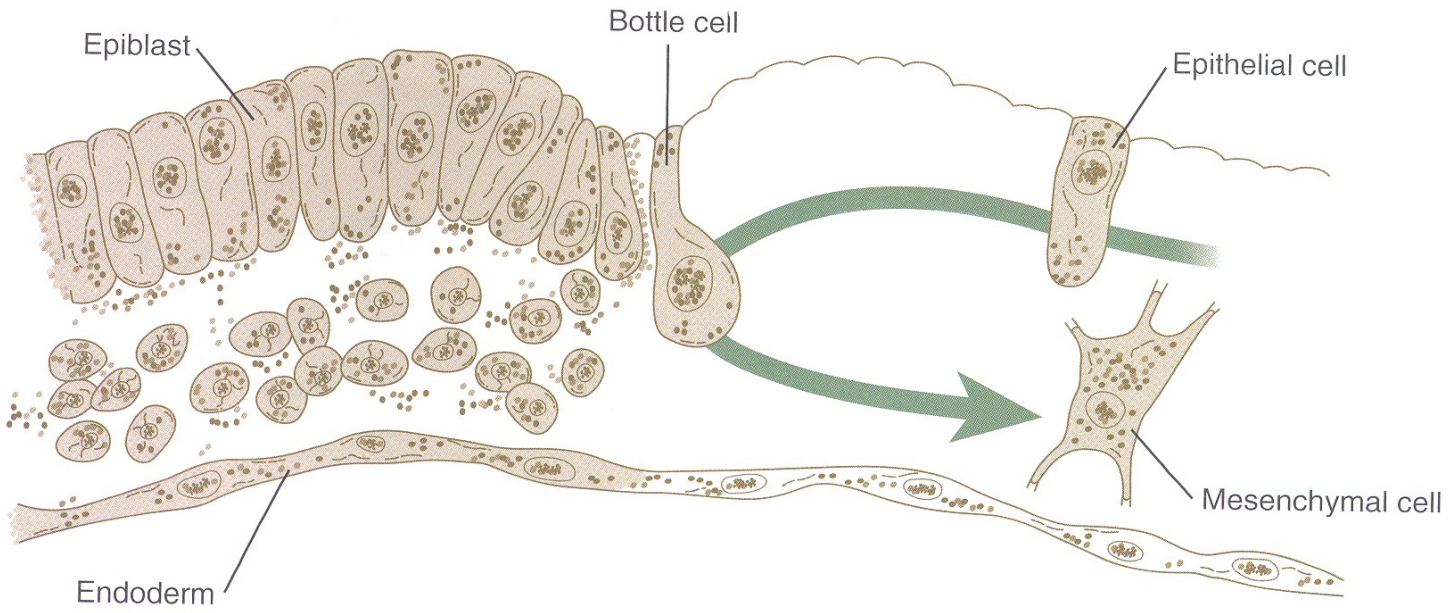
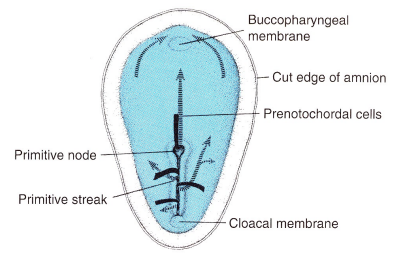
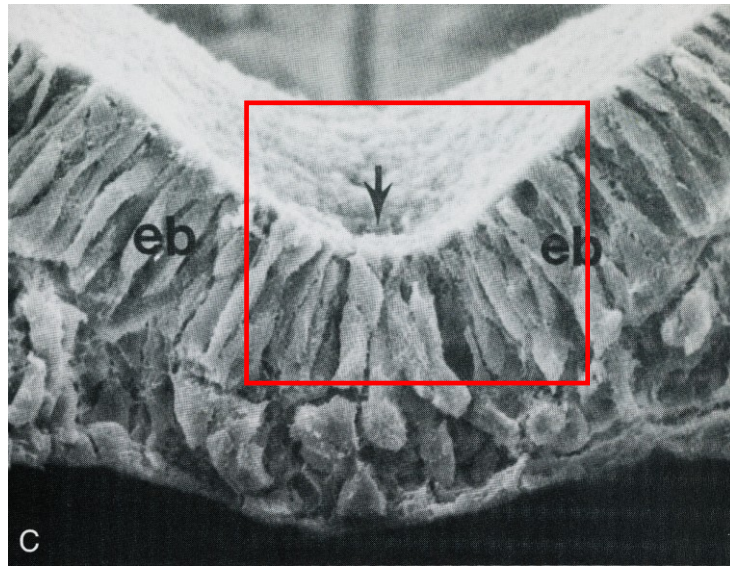
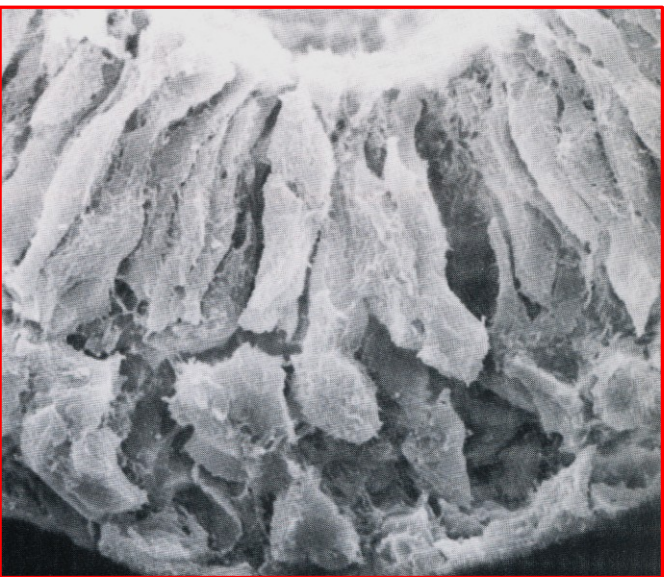
Day 18

Day 19

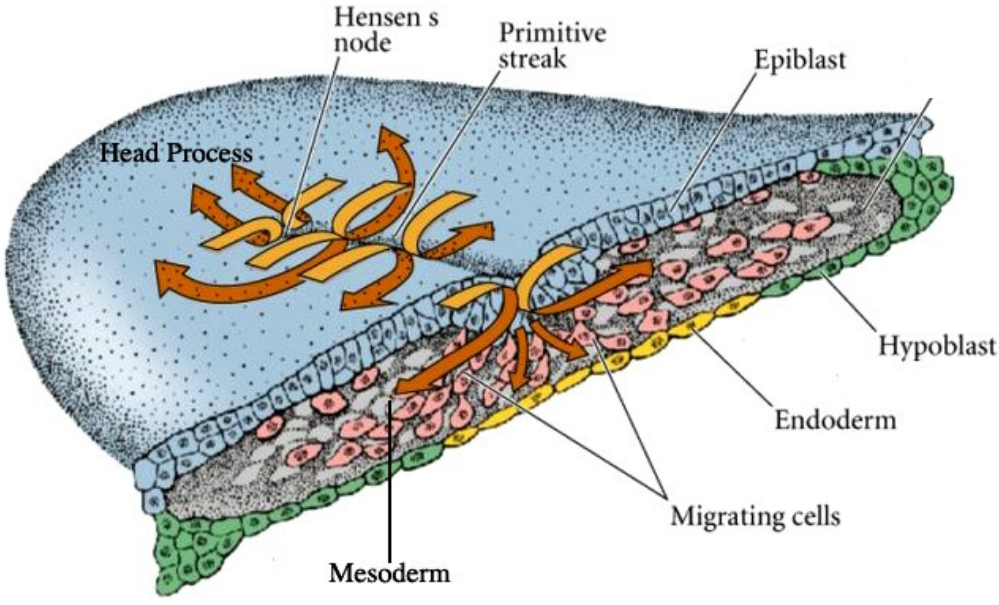
TRILAMINAR GERM DISC

PRIMITIVE STREAK AND PRIMITIVE NODE

3rd week

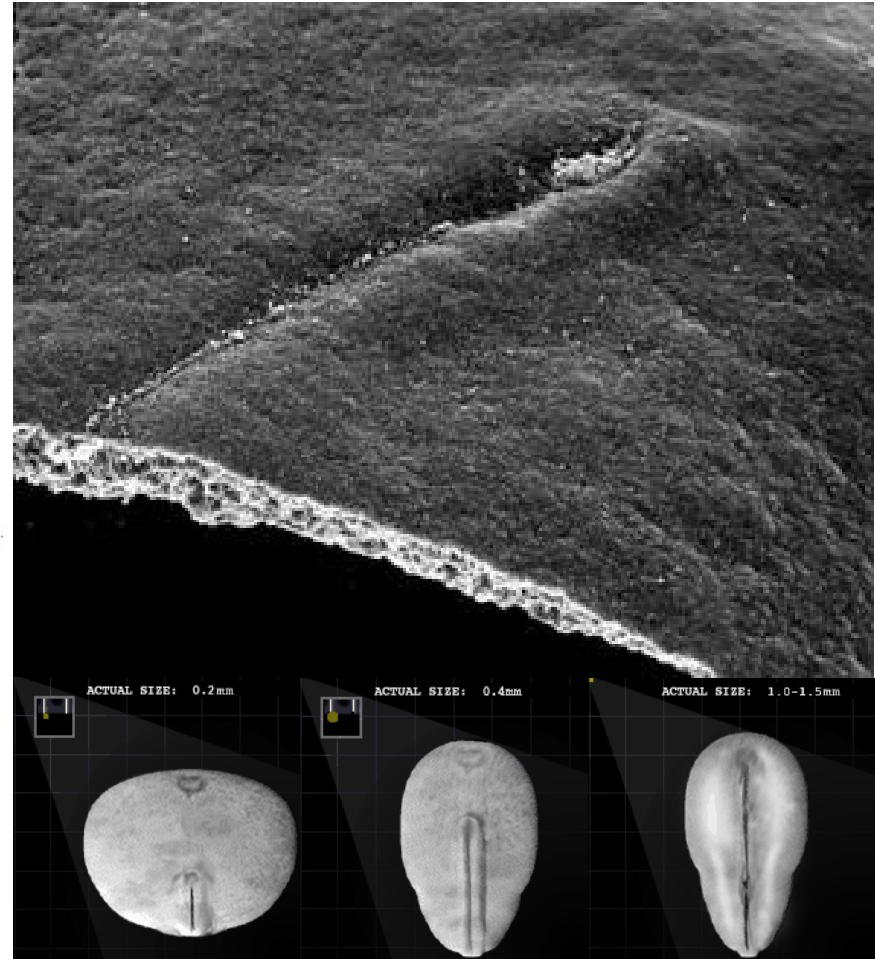


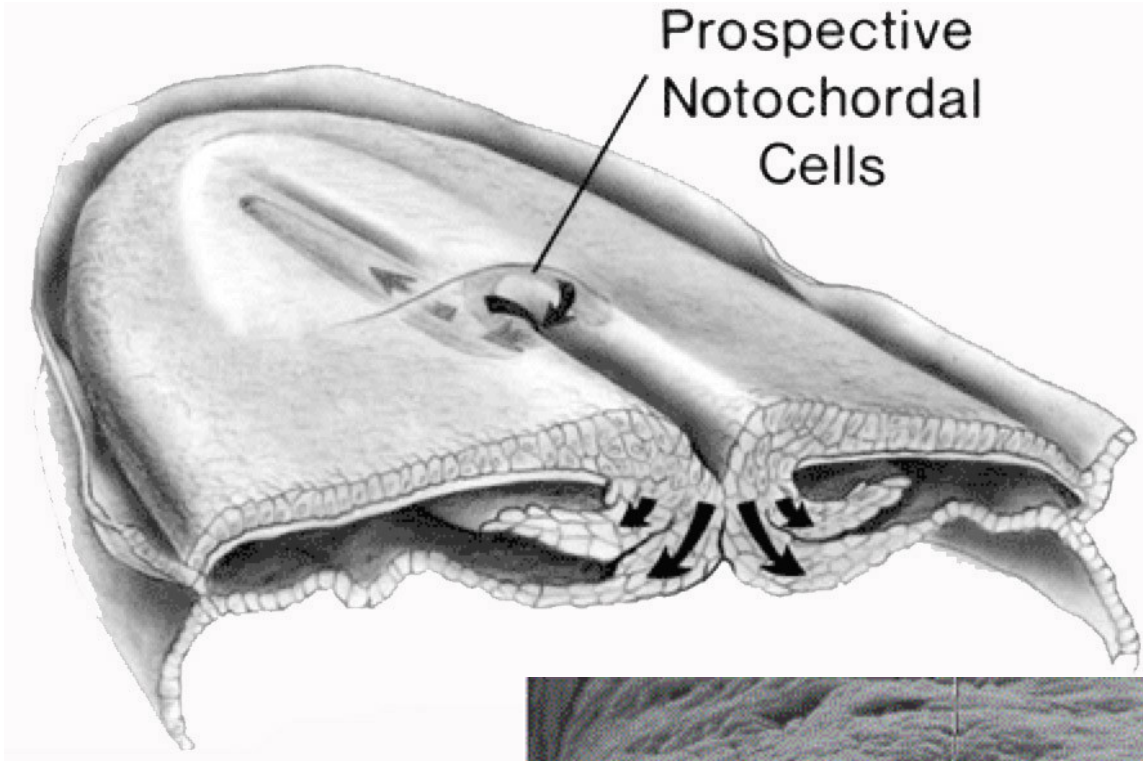
3rd week



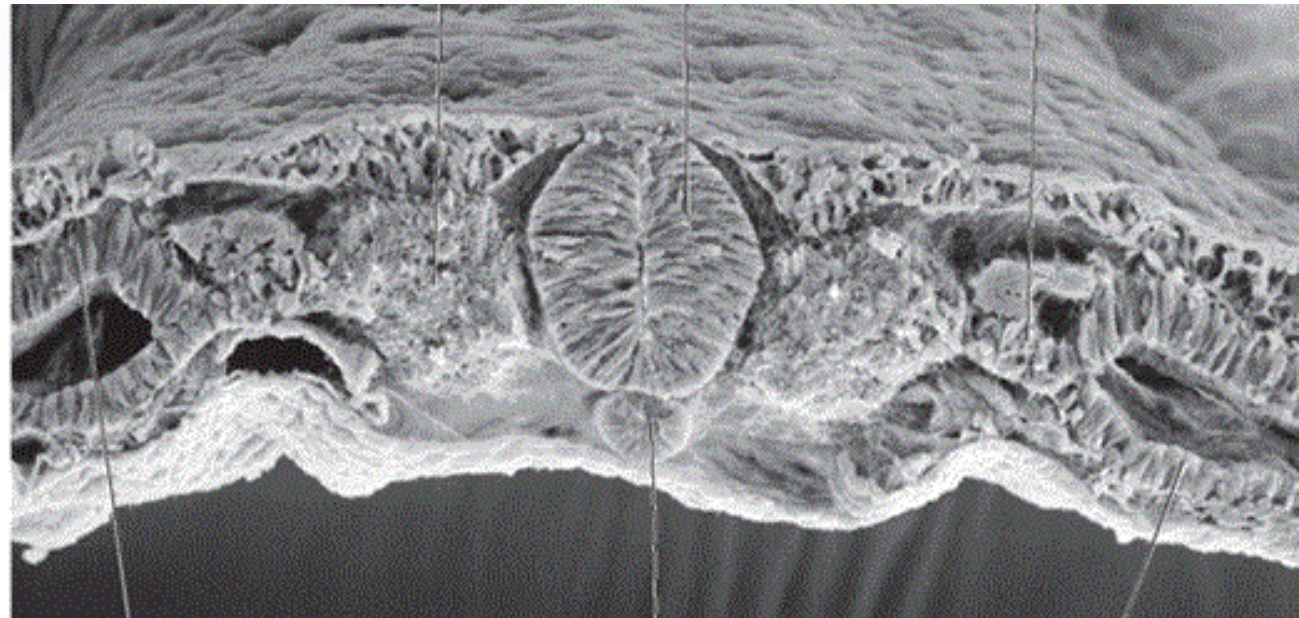
© 2000 Saunders Associates, Inc.

A new cell population appears - MESODERM

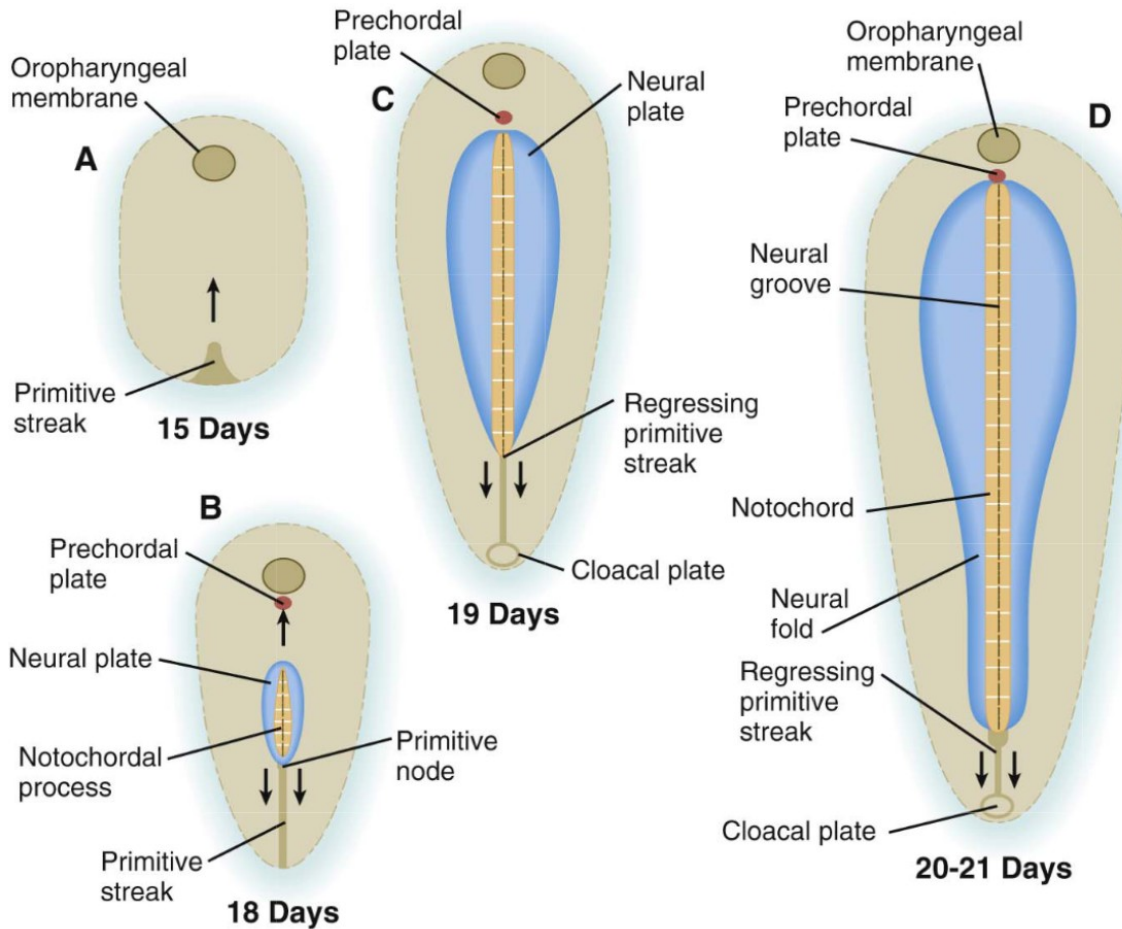




End of 3rd week

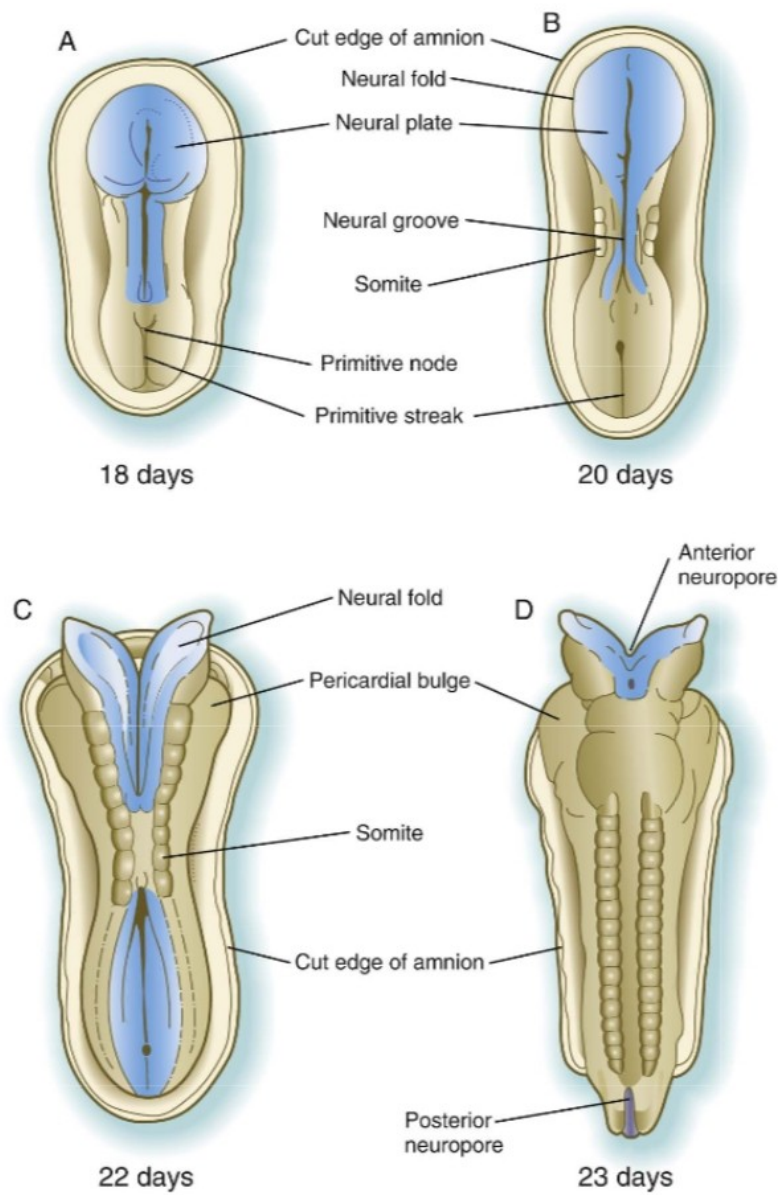


3rd week



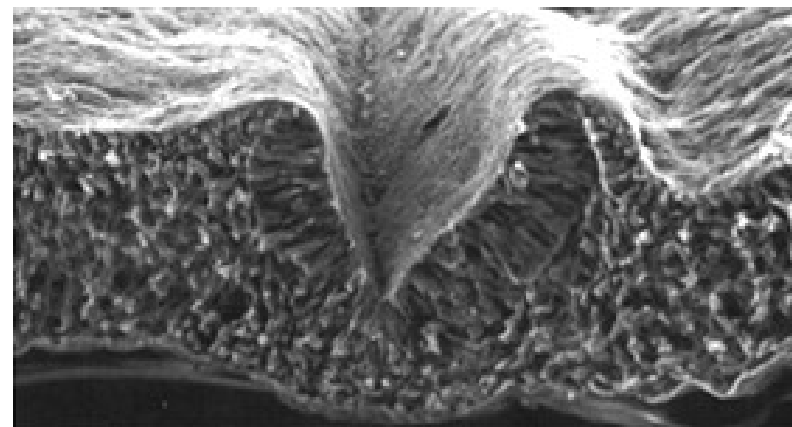
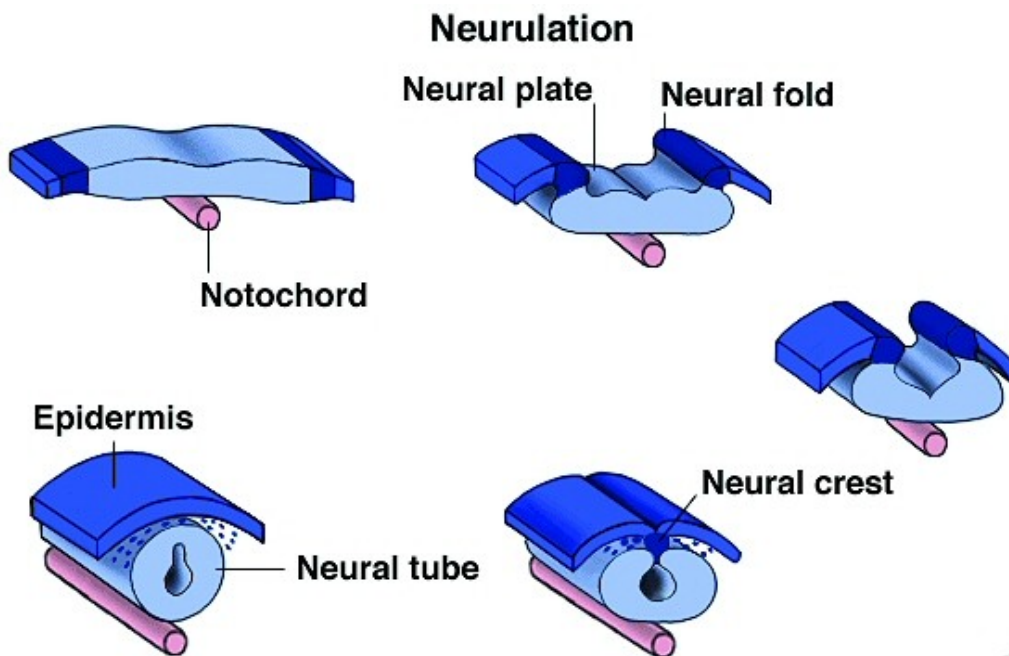
Notochord induces differentiation of ectoderm – cellular basis of nerve system is established – **NEUROECTODERM**

3rd week



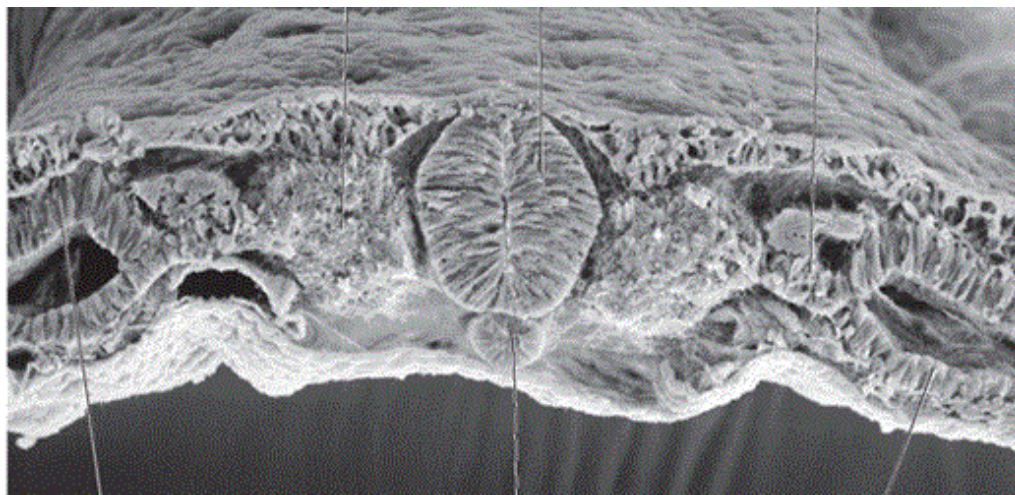
- Neural plate
- Neural folds
- Neural tube
- Neural crest

3rd week



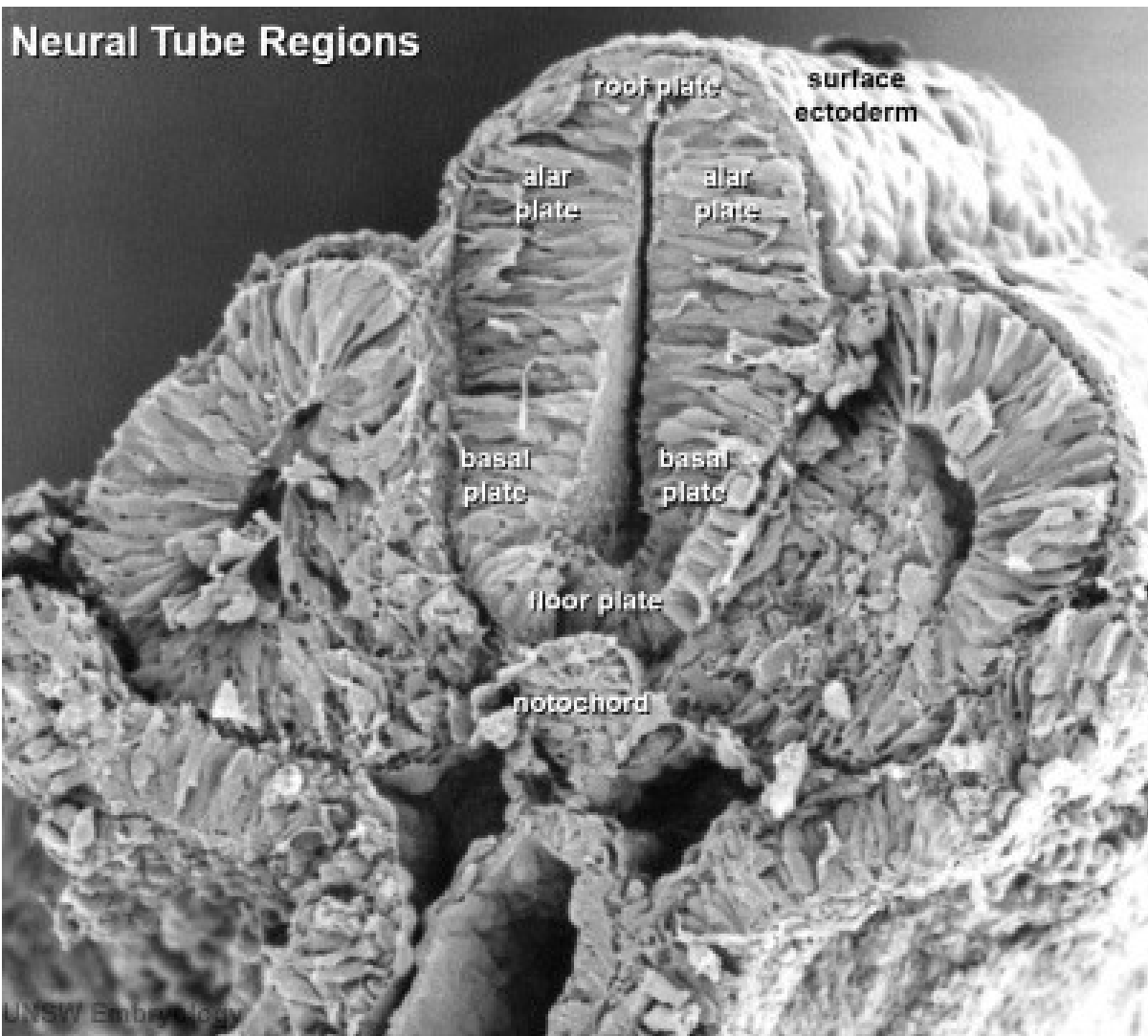
Ectoderm and mesoderm produce BMP4, that induces development of epidermis

Notochord produces inhibitors of BMP4 - noggin, chordin and follistatin (cranially) a wnt3a and FGF (caudally) - ectoderm differentiates into neuroectoderm.

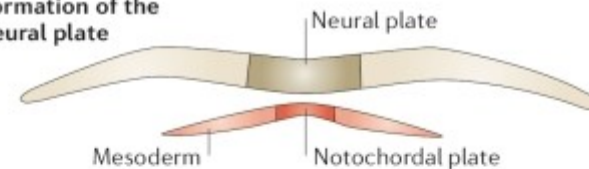


3rd – 4th week

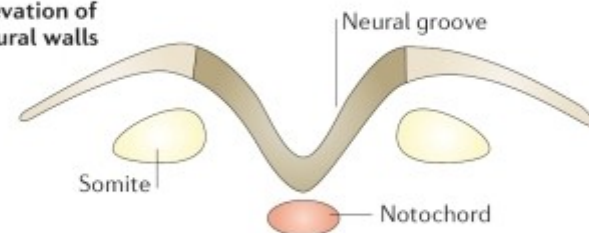
Neural Tube Regions



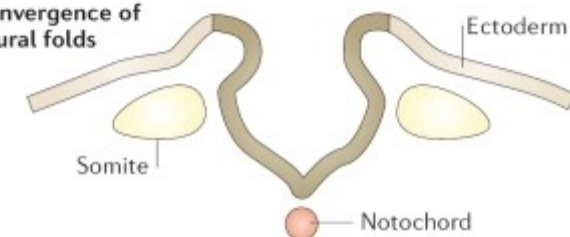
B Formation of the neural plate



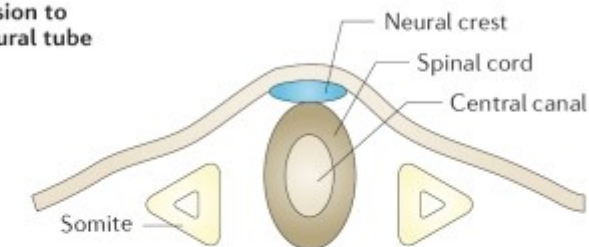
Elevation of neural walls



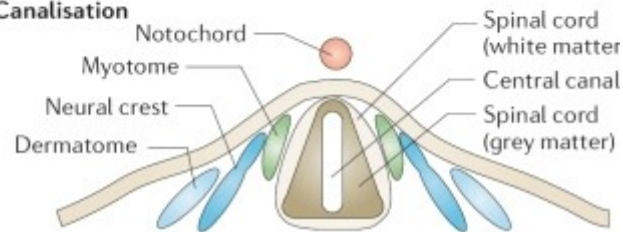
Convergence of neural folds

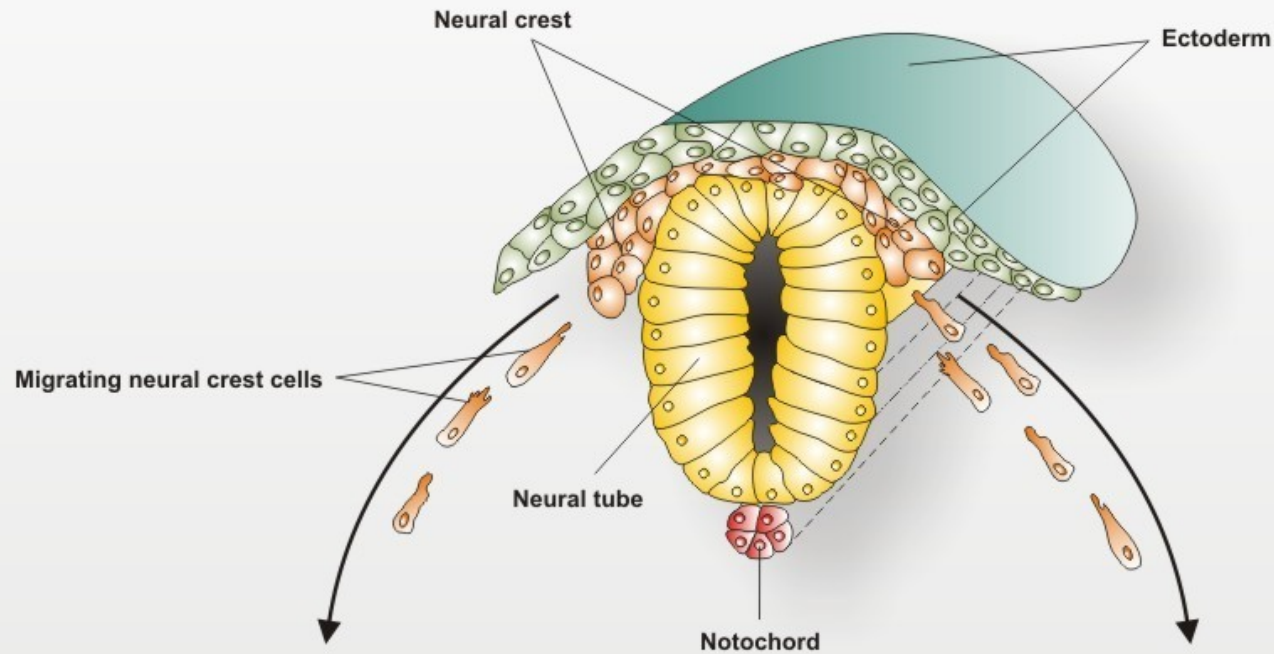


Fusion to neural tube



Canalisation





Mesoderm

Ectoderm




Smooth muscle cells



Osteoblasts
Osteoclasts



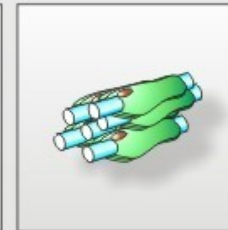
Adipocytes



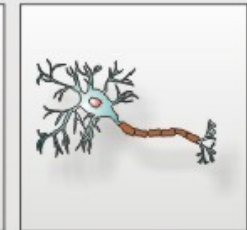Chondrocytes



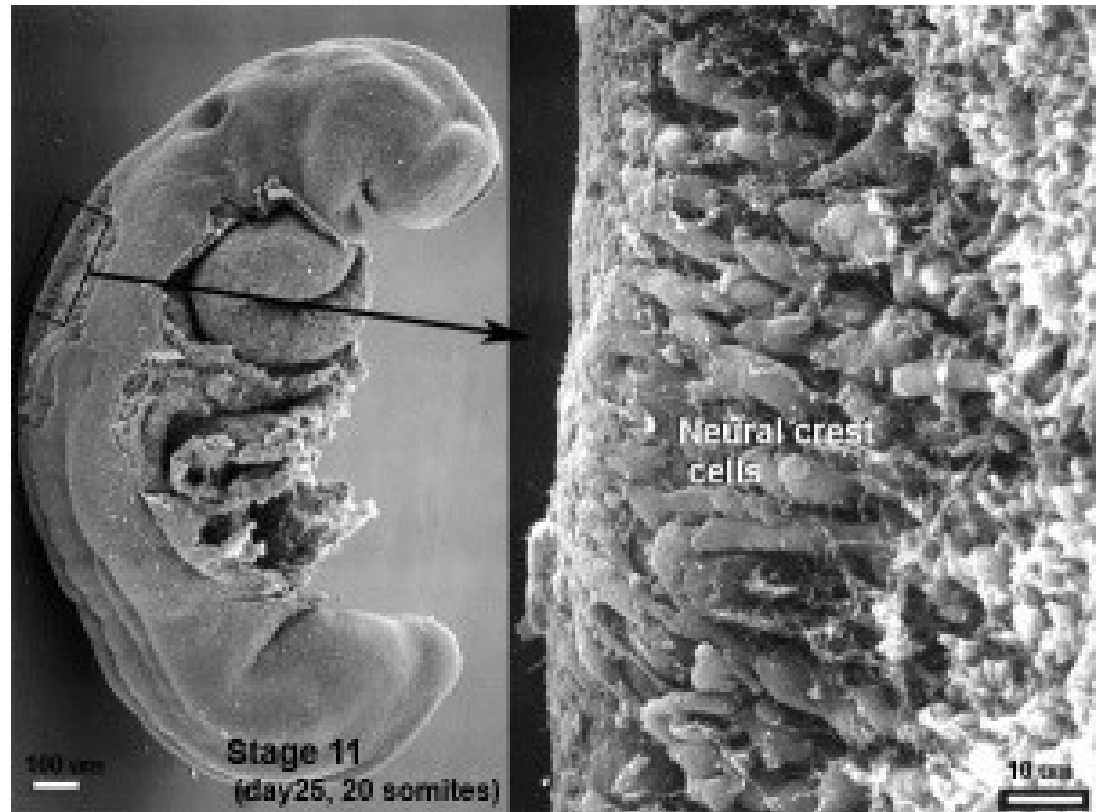
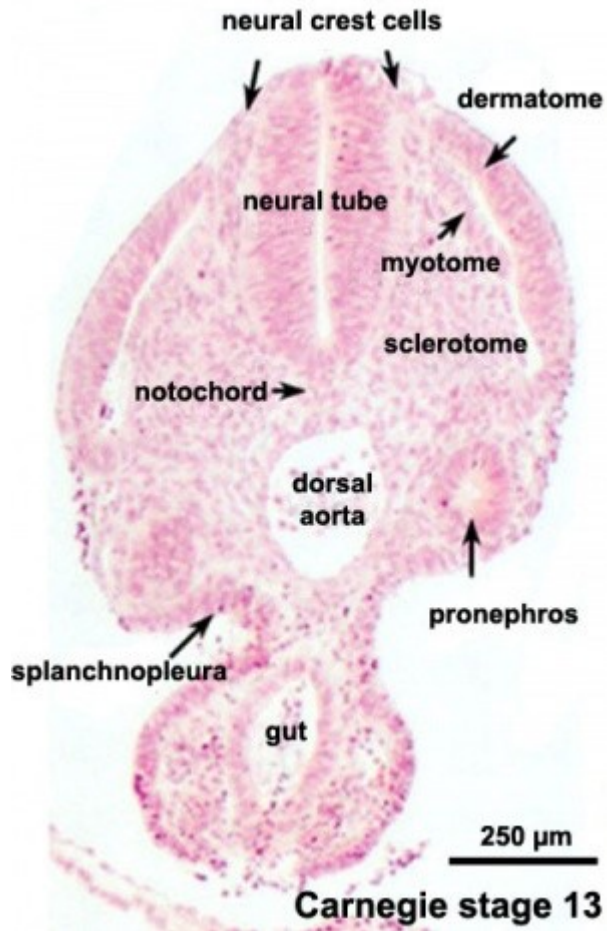
Melanocytes

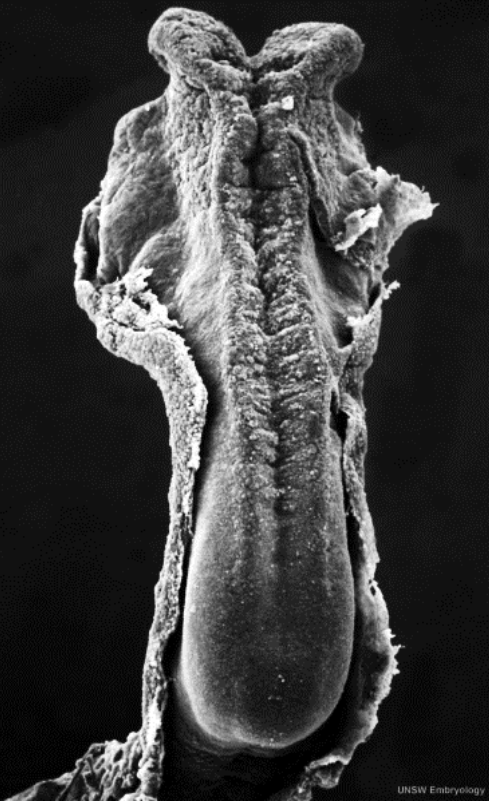

Schwann cells



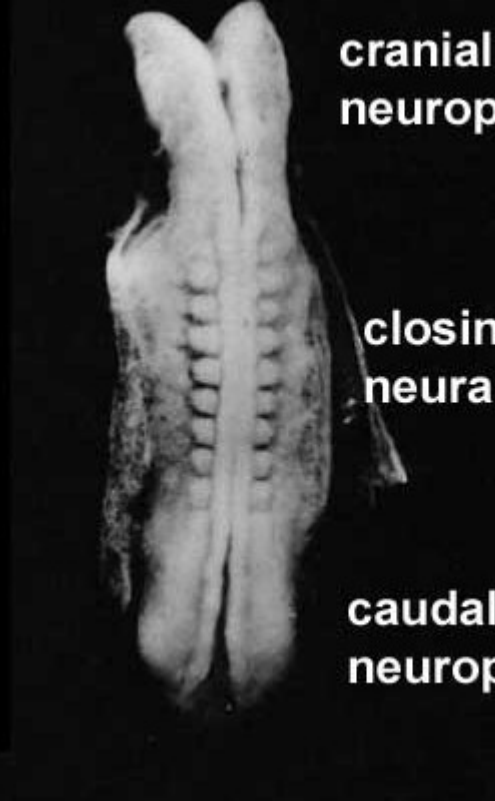
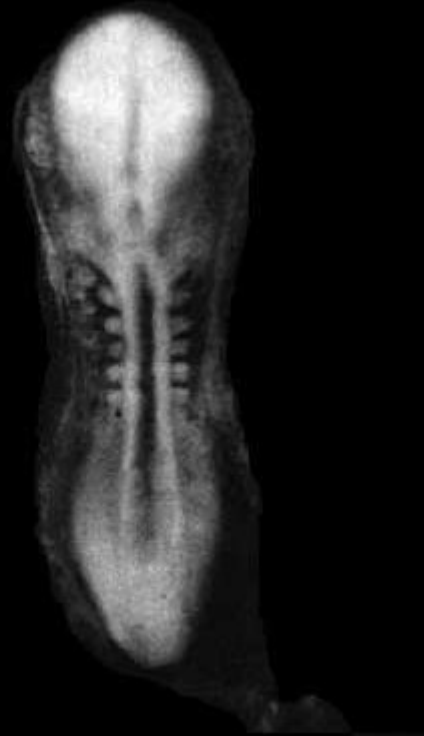Neurons





**brain
fold**

**neural
groove**

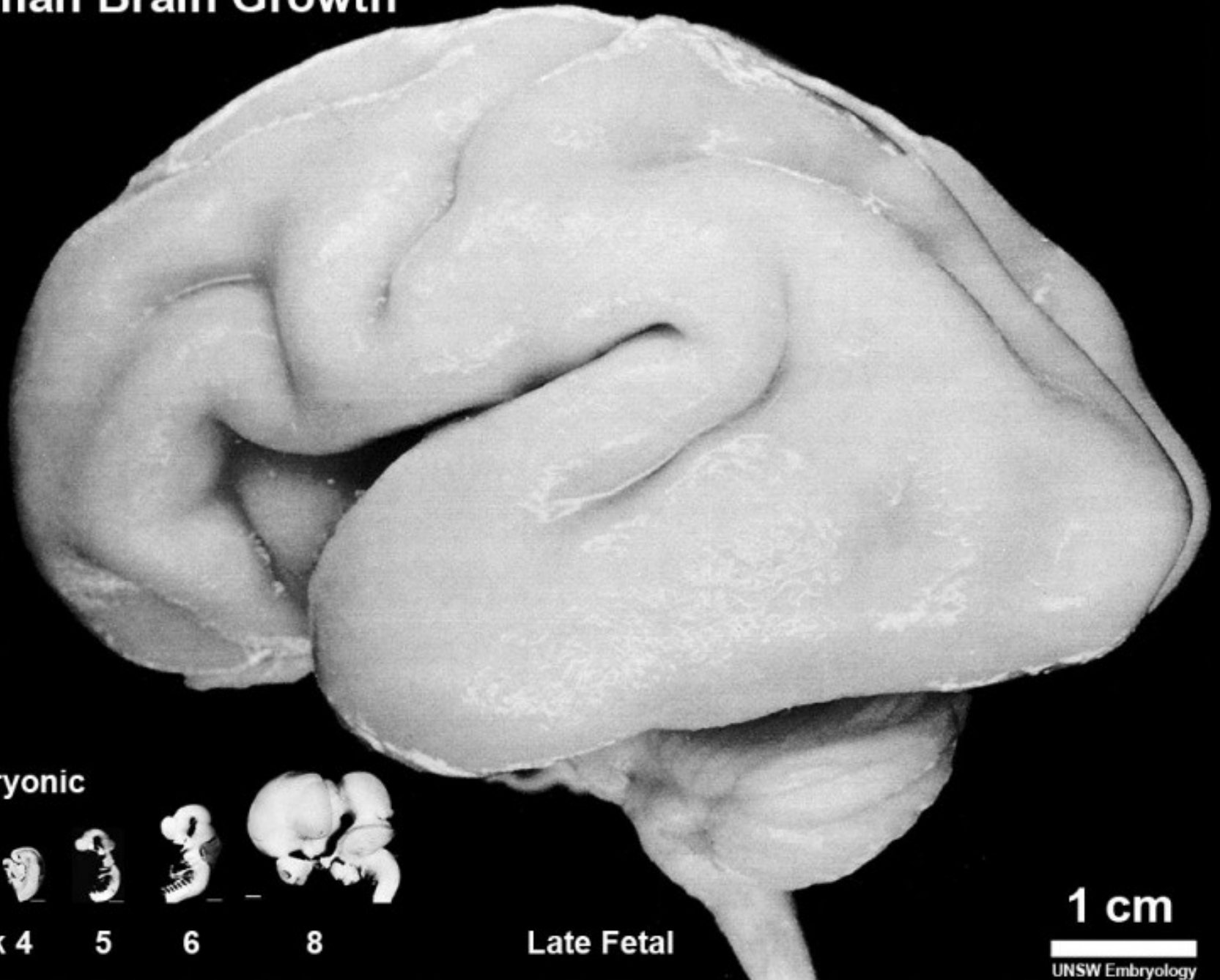


**cranial
neuropore**

**closing
neural tube**

**caudal
neuropore**

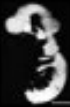Human Brain Growth



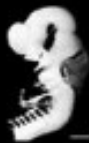Embryonic



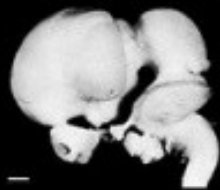Week 4



5



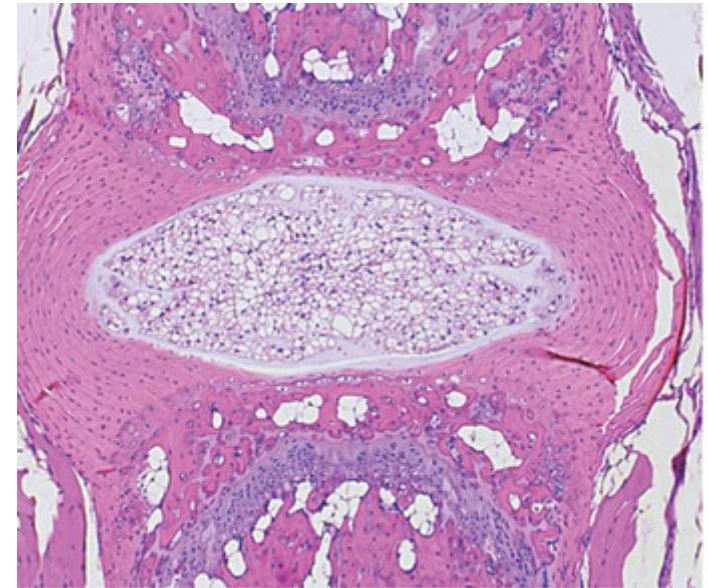
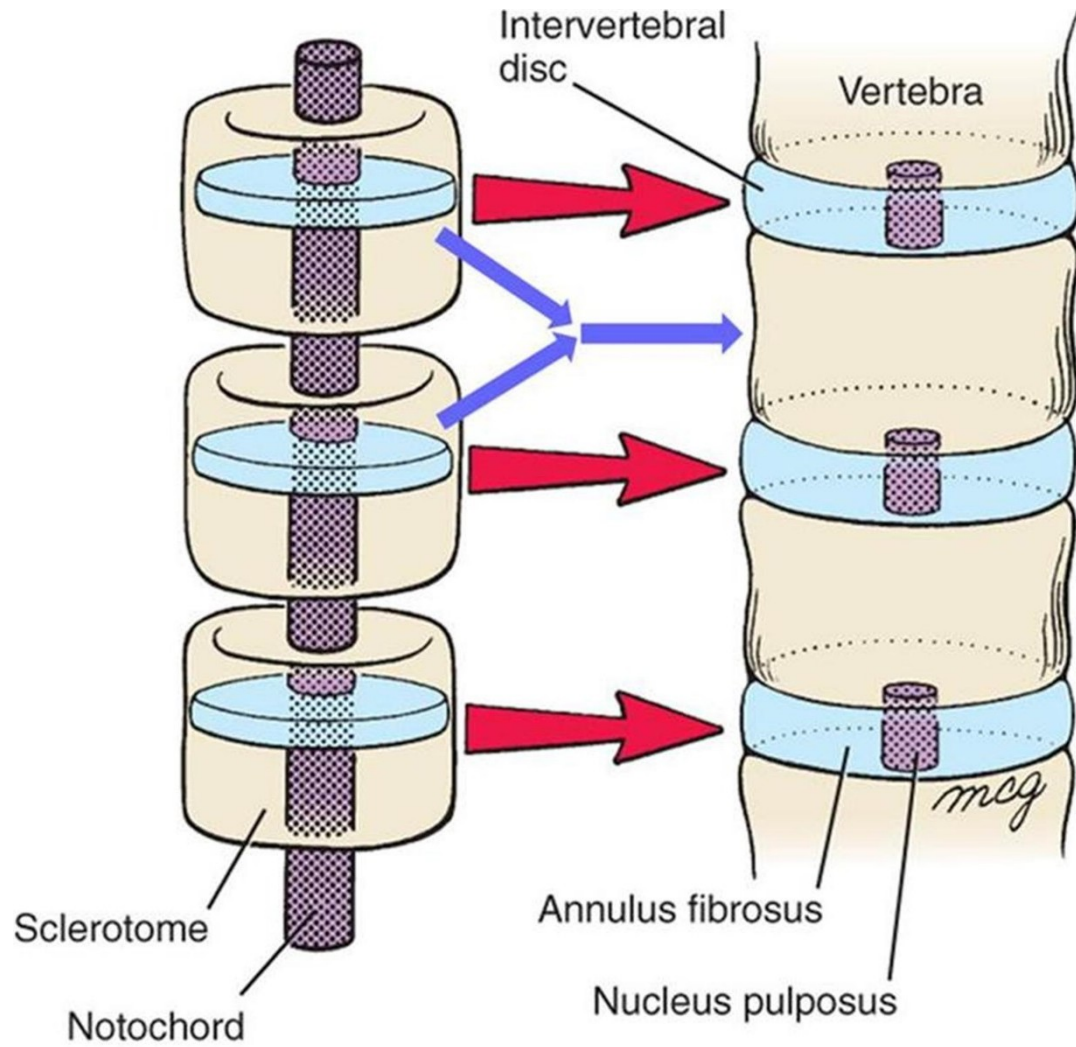
6



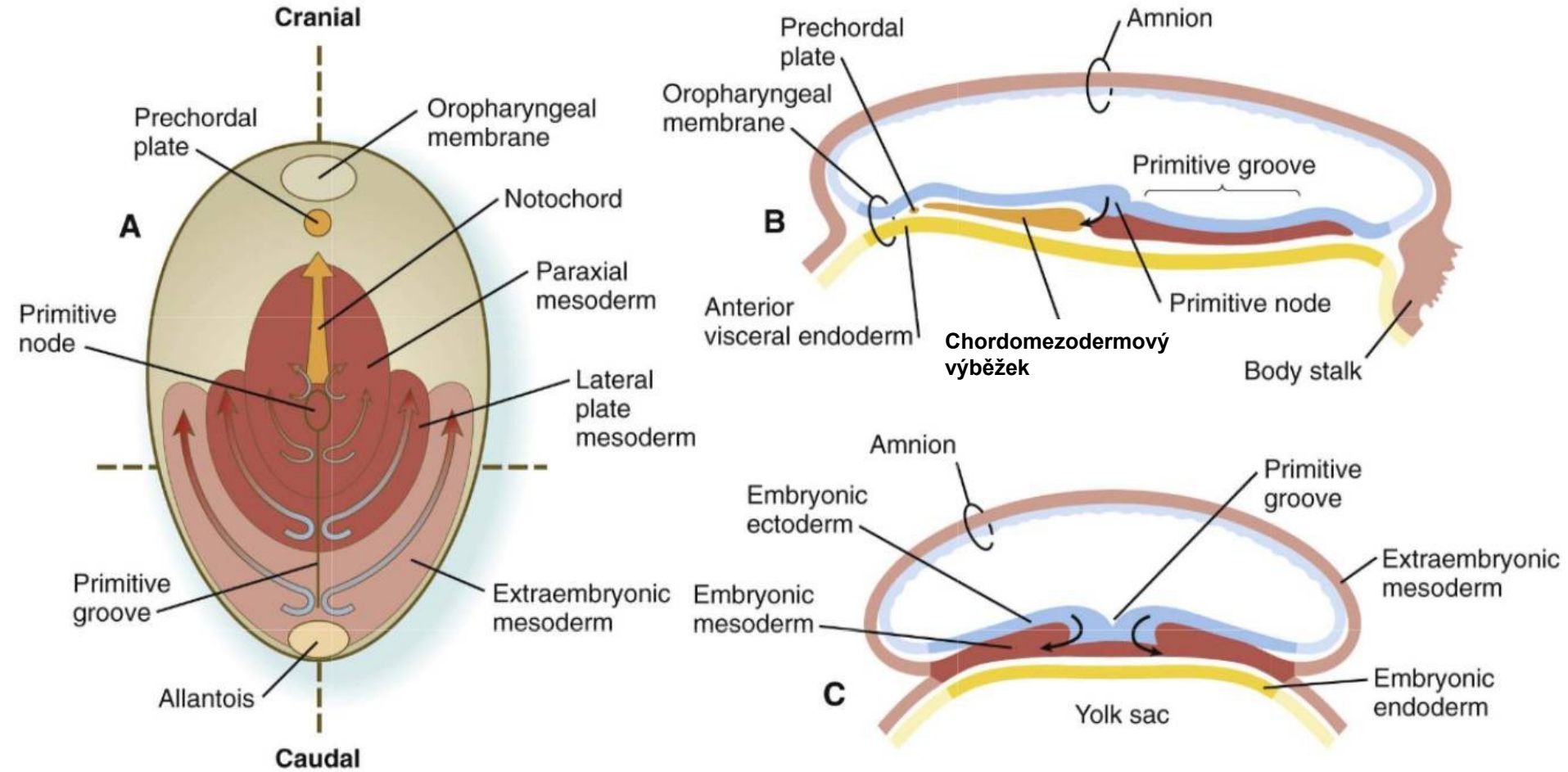
8

Late Fetal

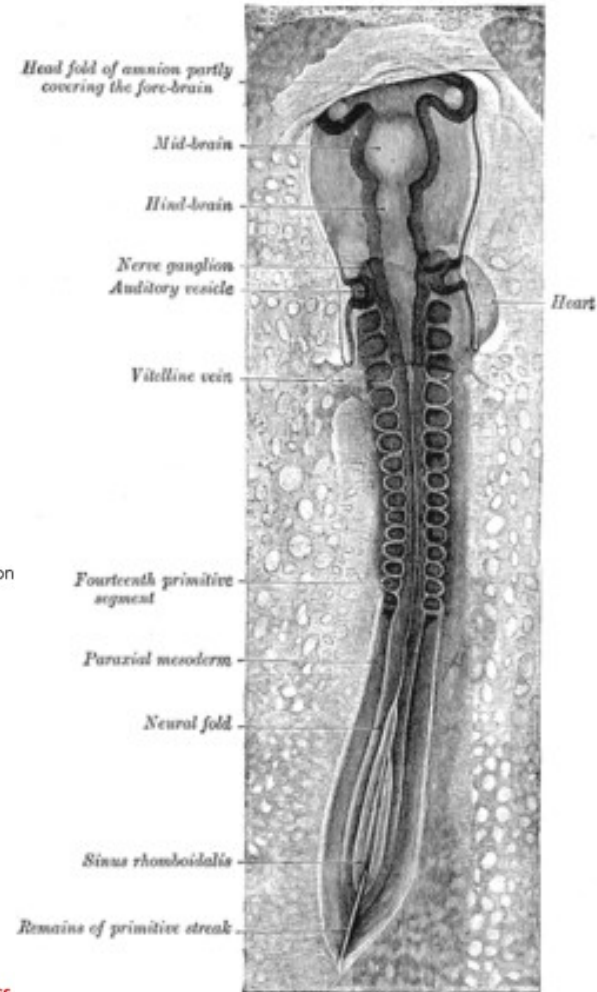
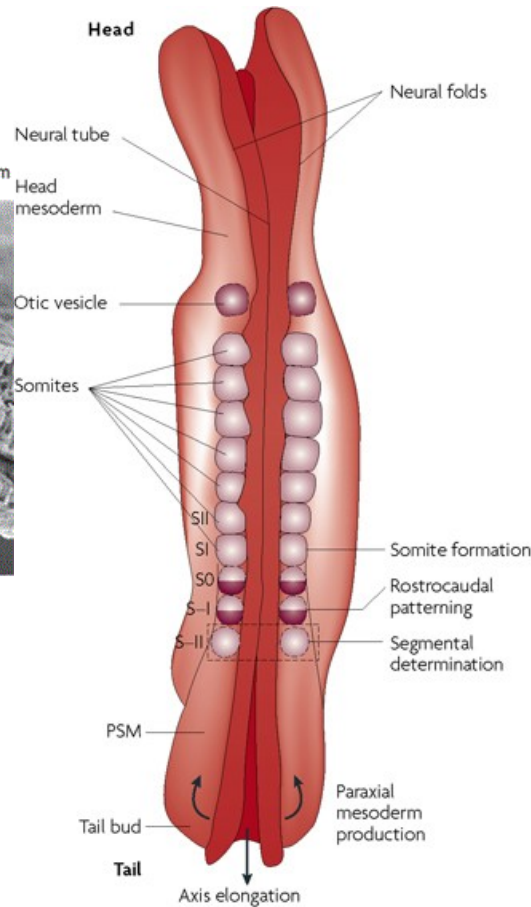
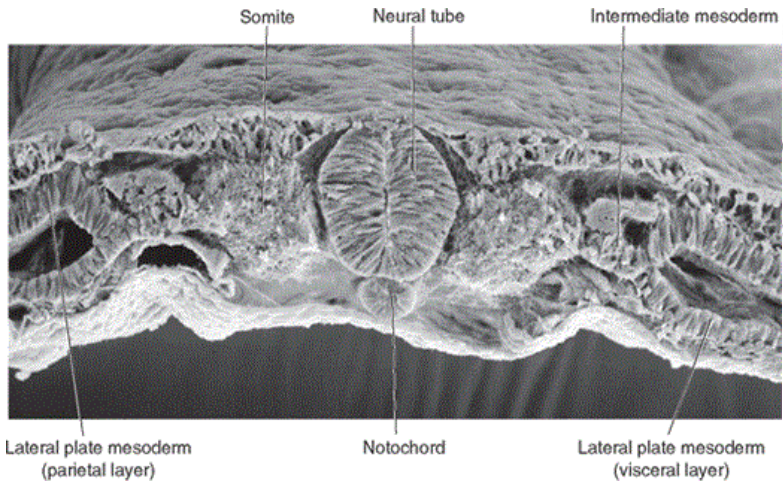
1 cm

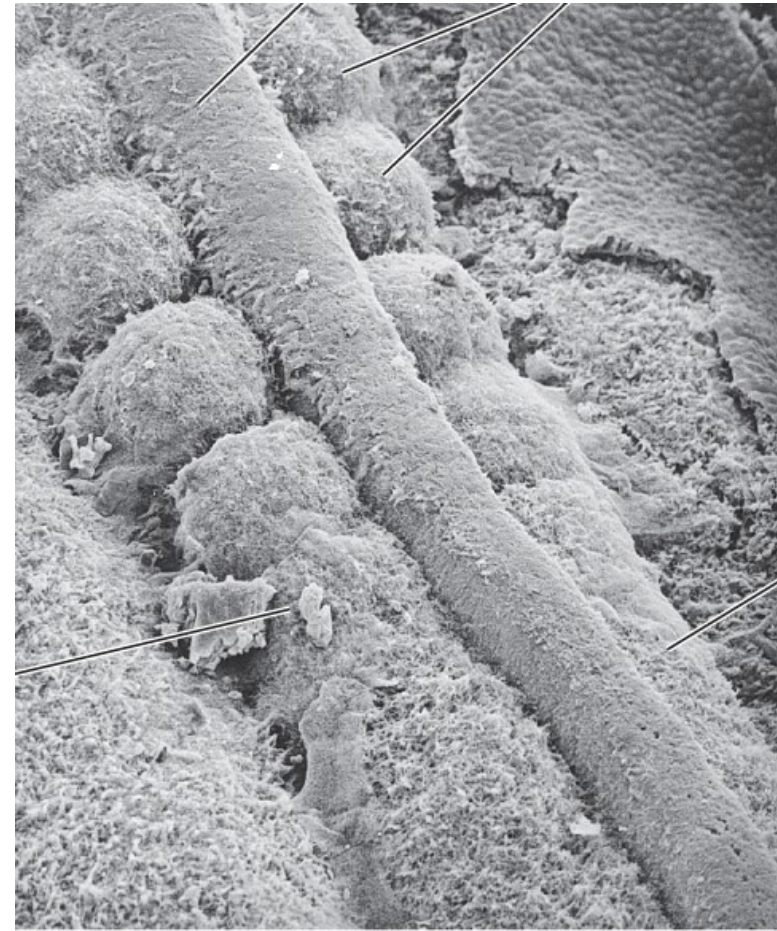
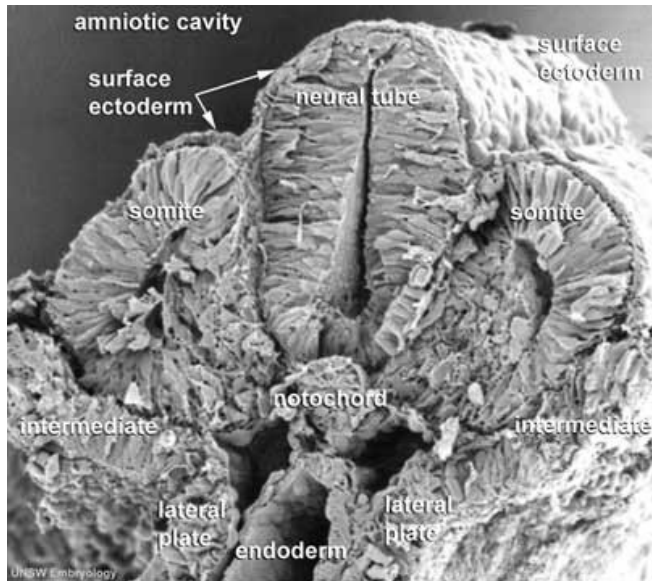
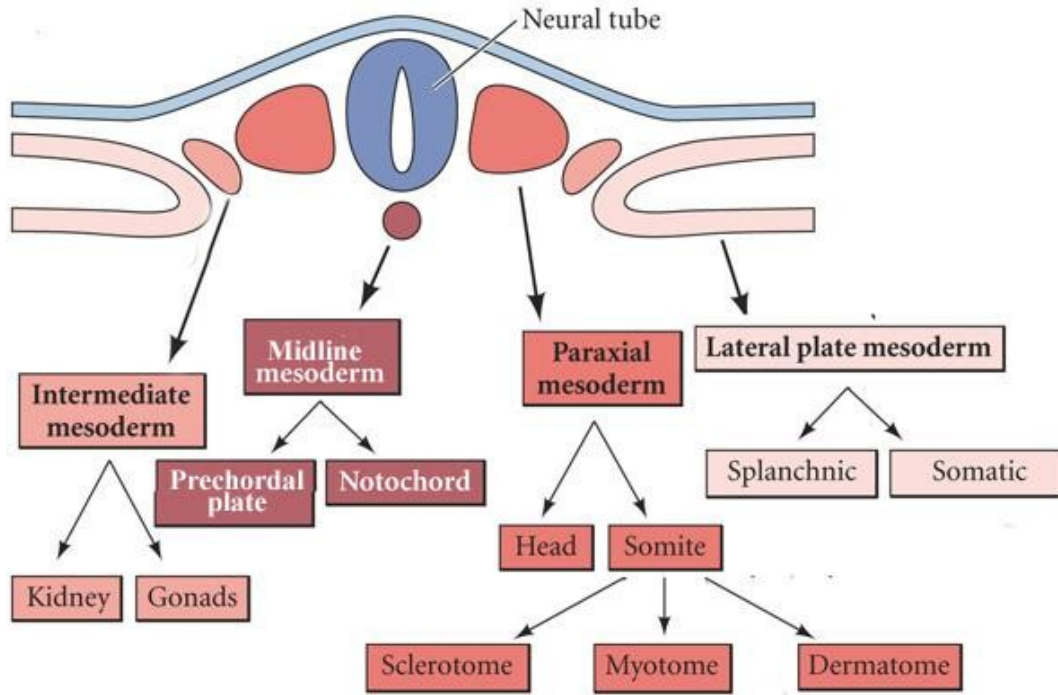


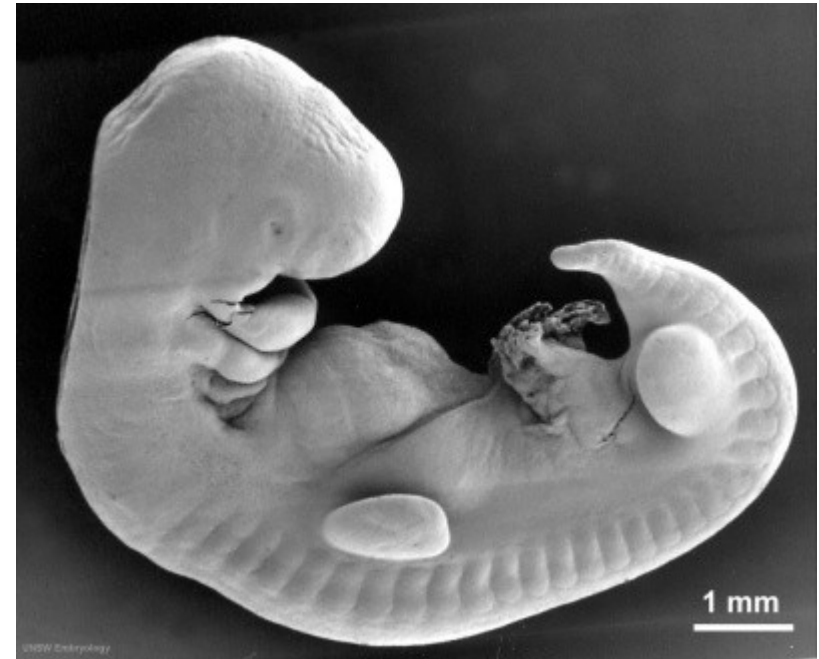
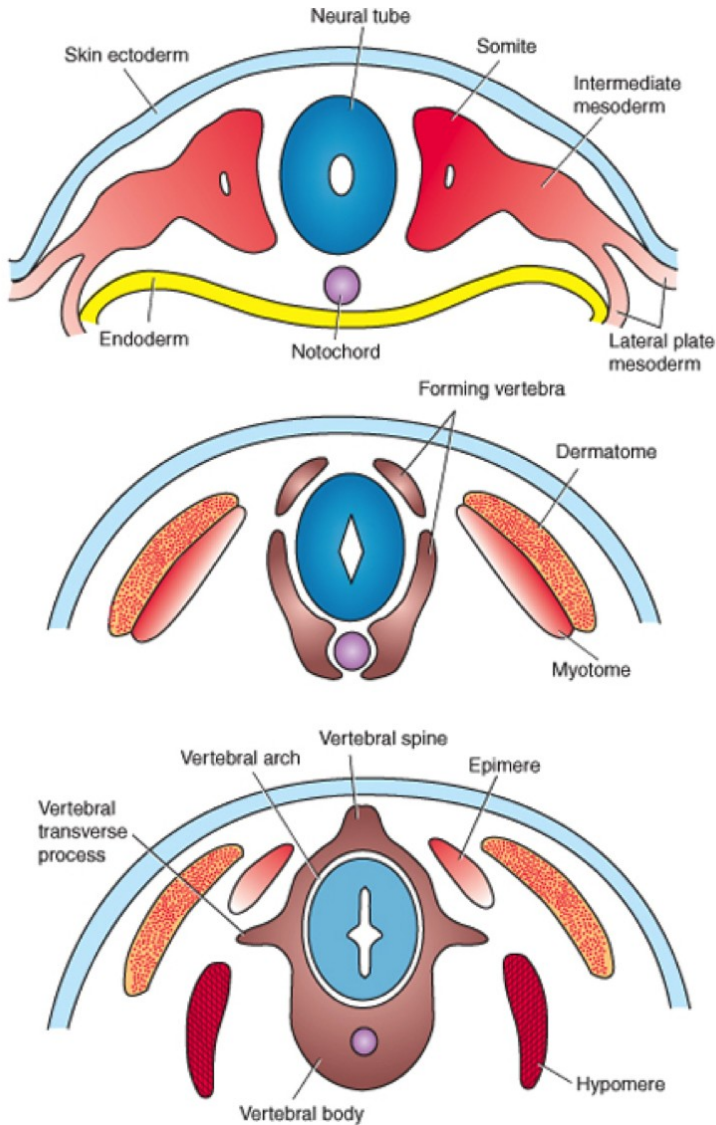
3rd week



3rd – 4th week



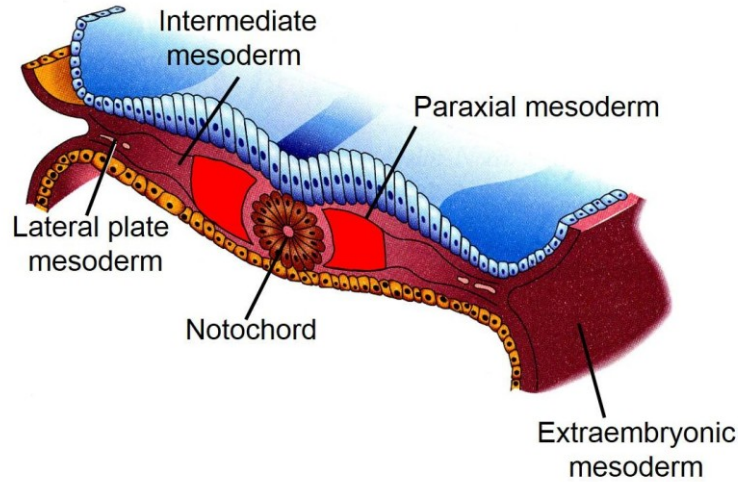




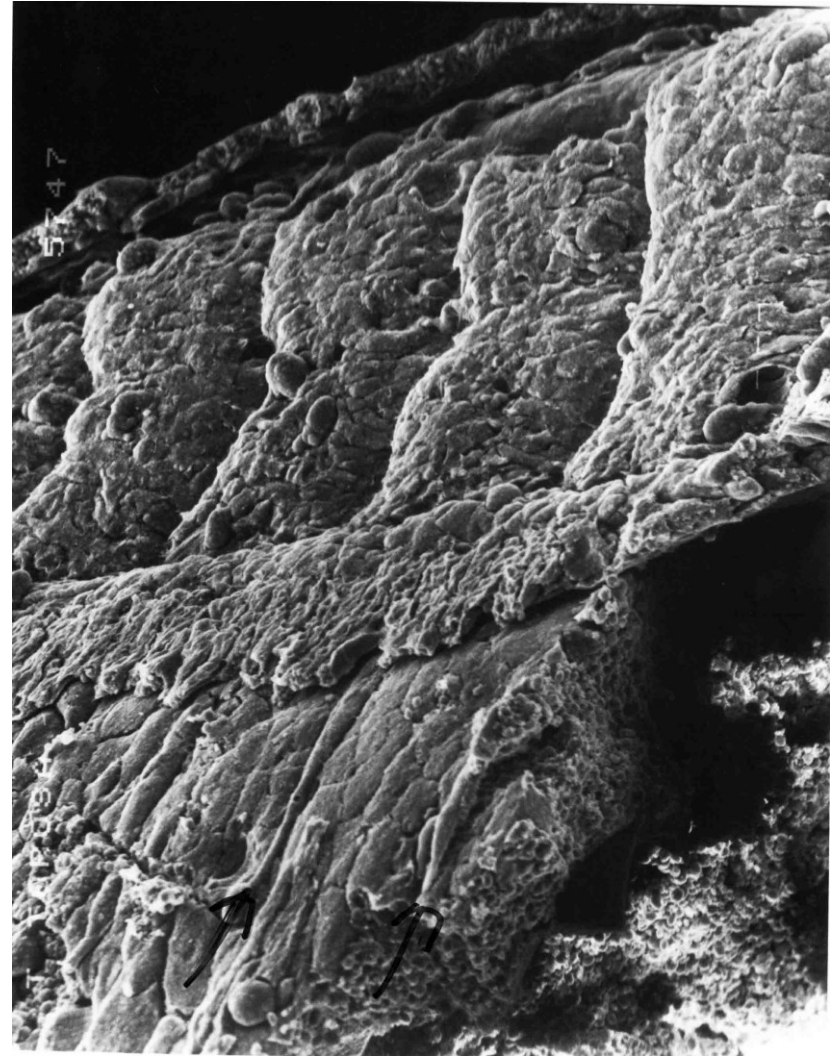
- Paraxial: sclerotomes, myotomes, dermatomes
- Intermediate: nephrotomes
- Lateral plate: somatopleura, splanchnopleura

OTHER DERIVATIVES OF MESODERM

3rd – 4th week

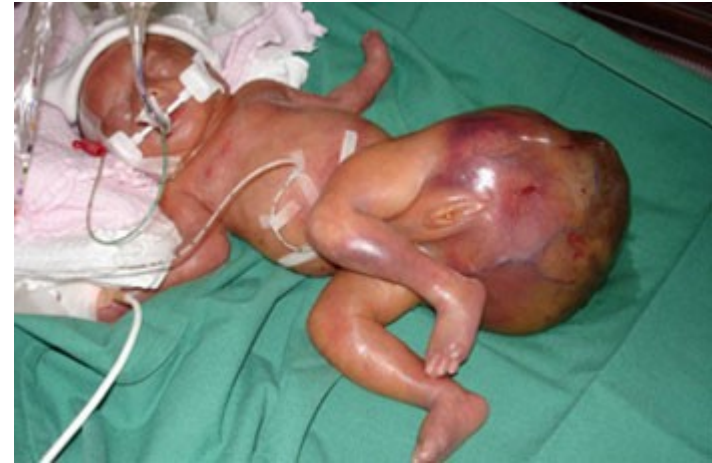
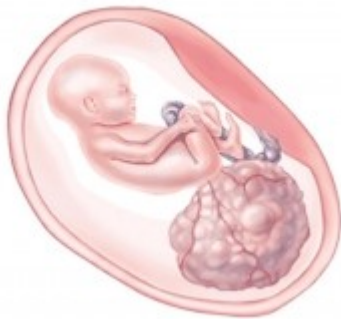
- heart, cardiovascular system
- urogenital system
- muscle and skeletal system
- hematopoietic and lymphatic systems
- connective tissue, dermis
- mesothelium



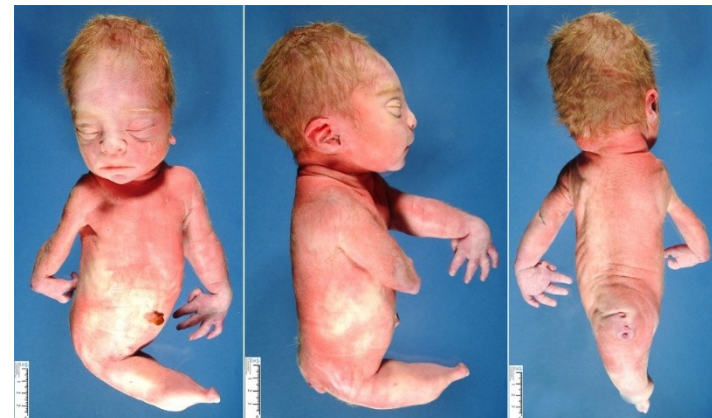DEVELOPMENTAL DISORDERS DURING GASTRULATION

- Primitive streak is a temporary embryonic structure. Persistent primitive streak causes **sacroccocgyeal teratoma**.



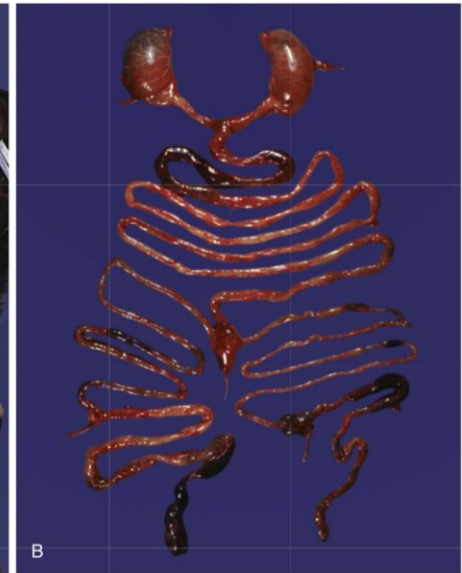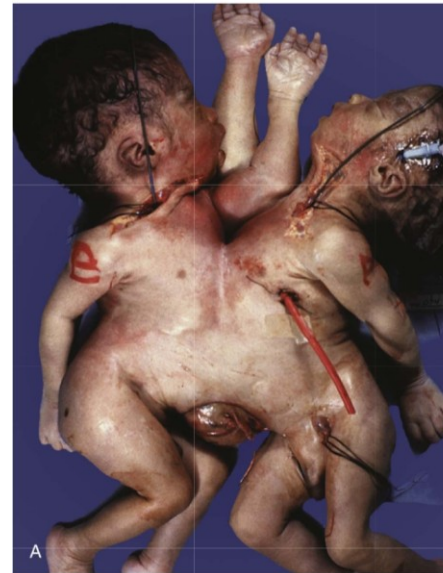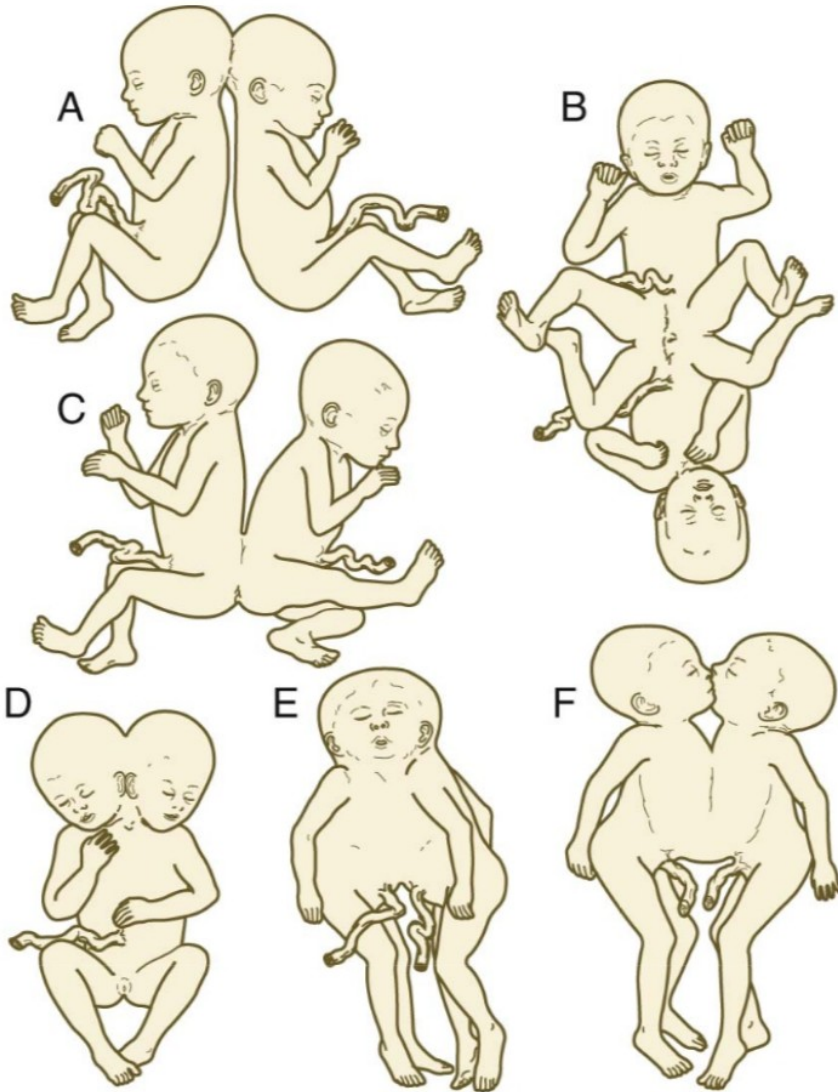
- Failure of primitive streak leads to absence of mesoderm in affected region - **sirenomelia**

- limbs
- urogenital system
- GIT

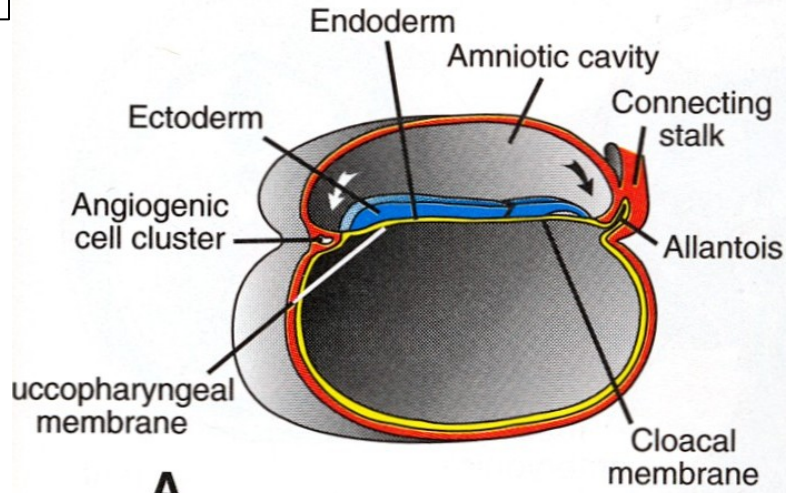


DEVELOPMENTAL DISORDERS DURING GASTRULATION

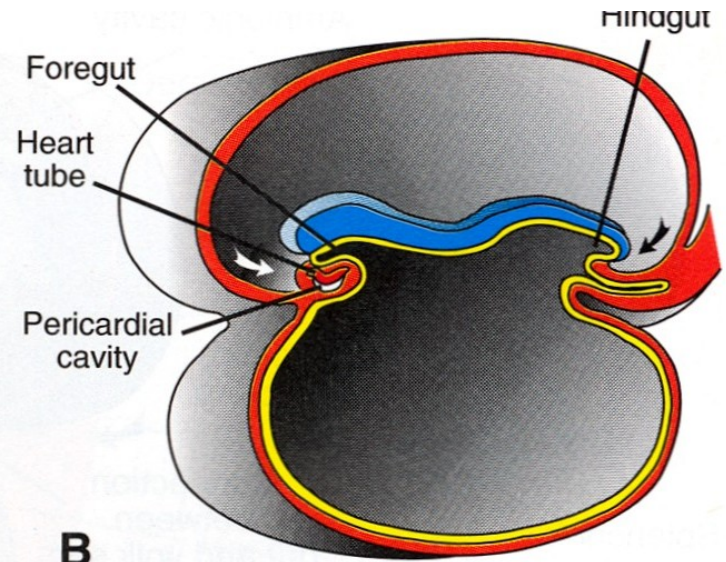
- If two primitive streaks form, conjoined twins may develop



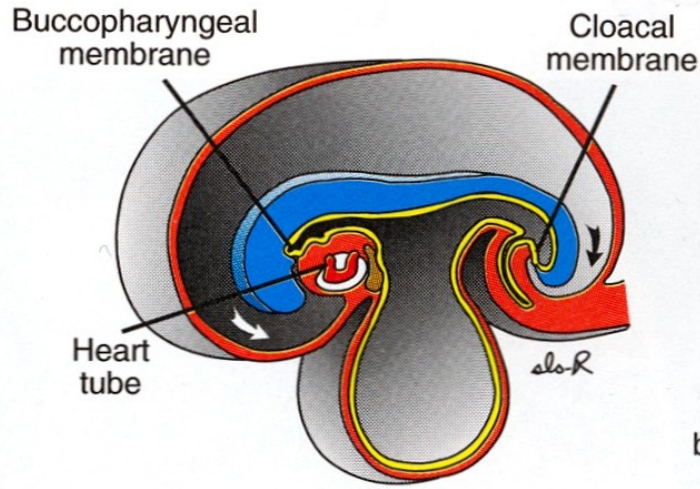
4th week



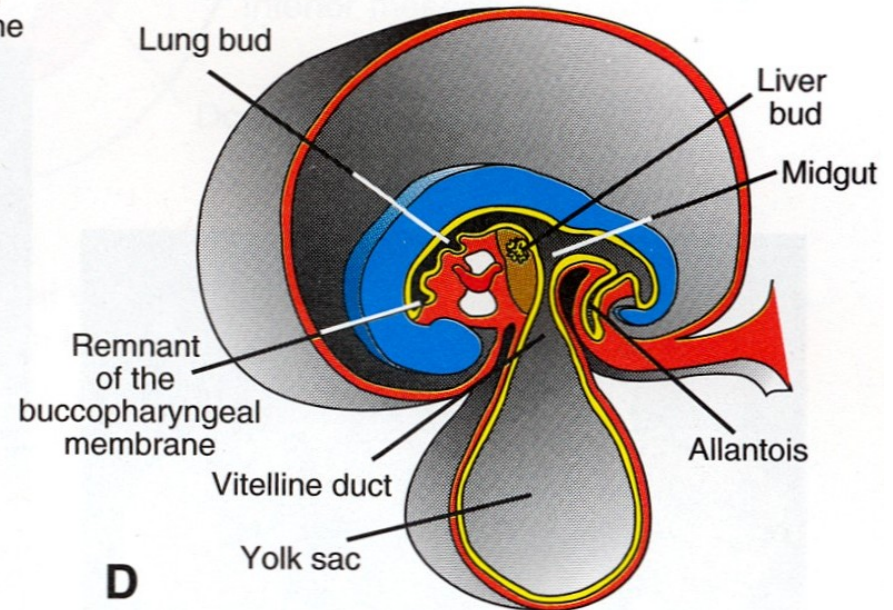
A



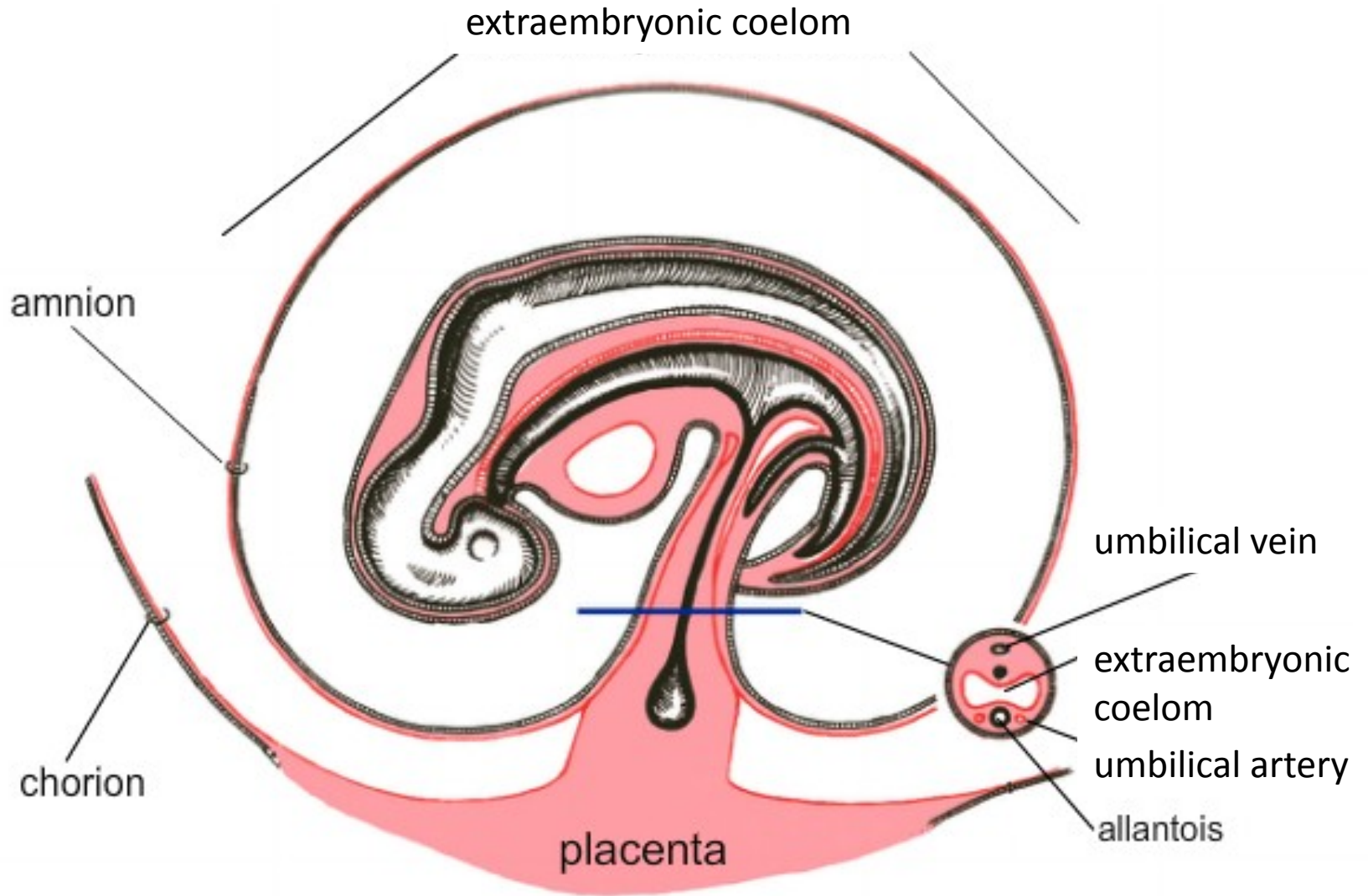
B

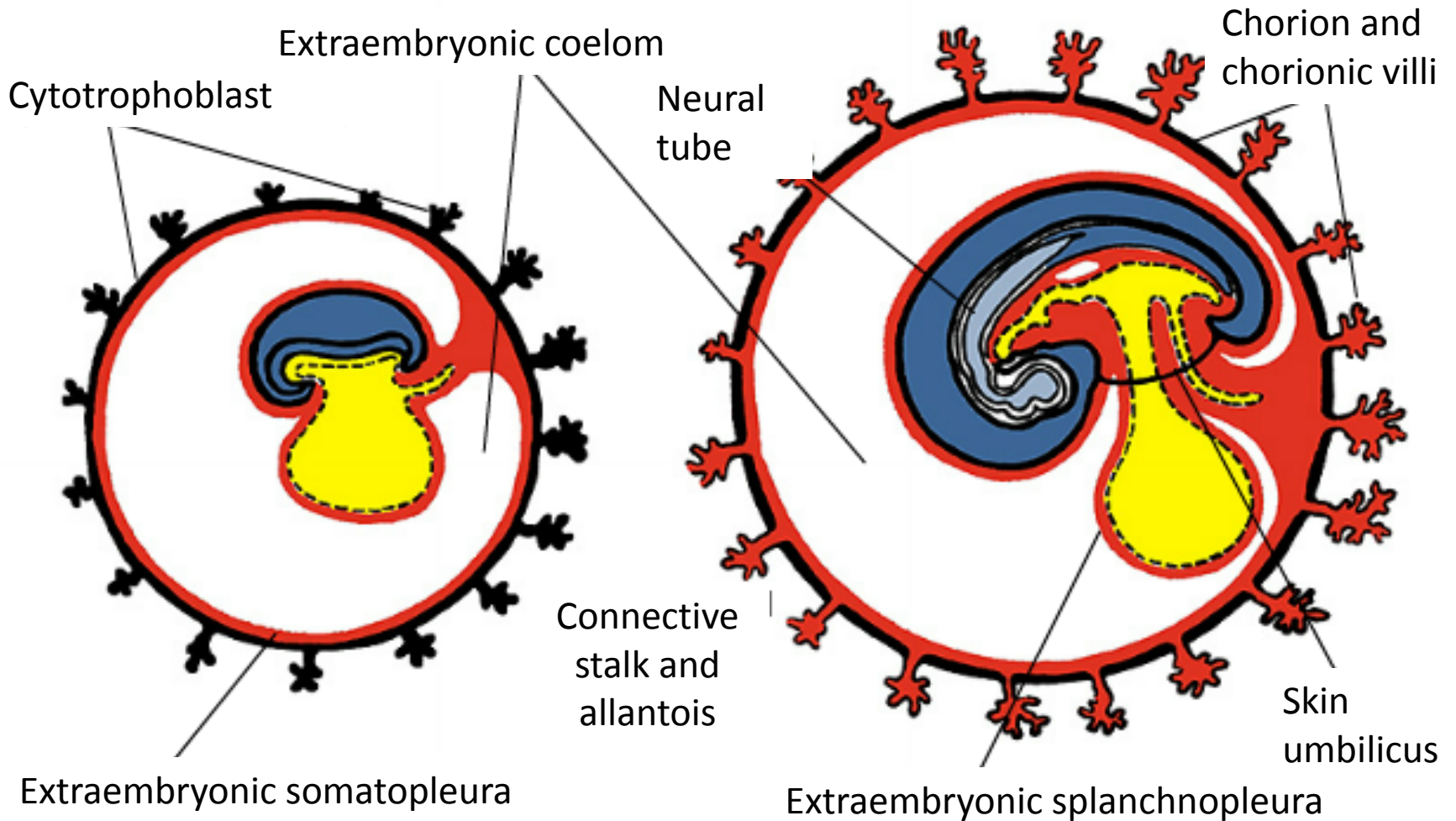


C



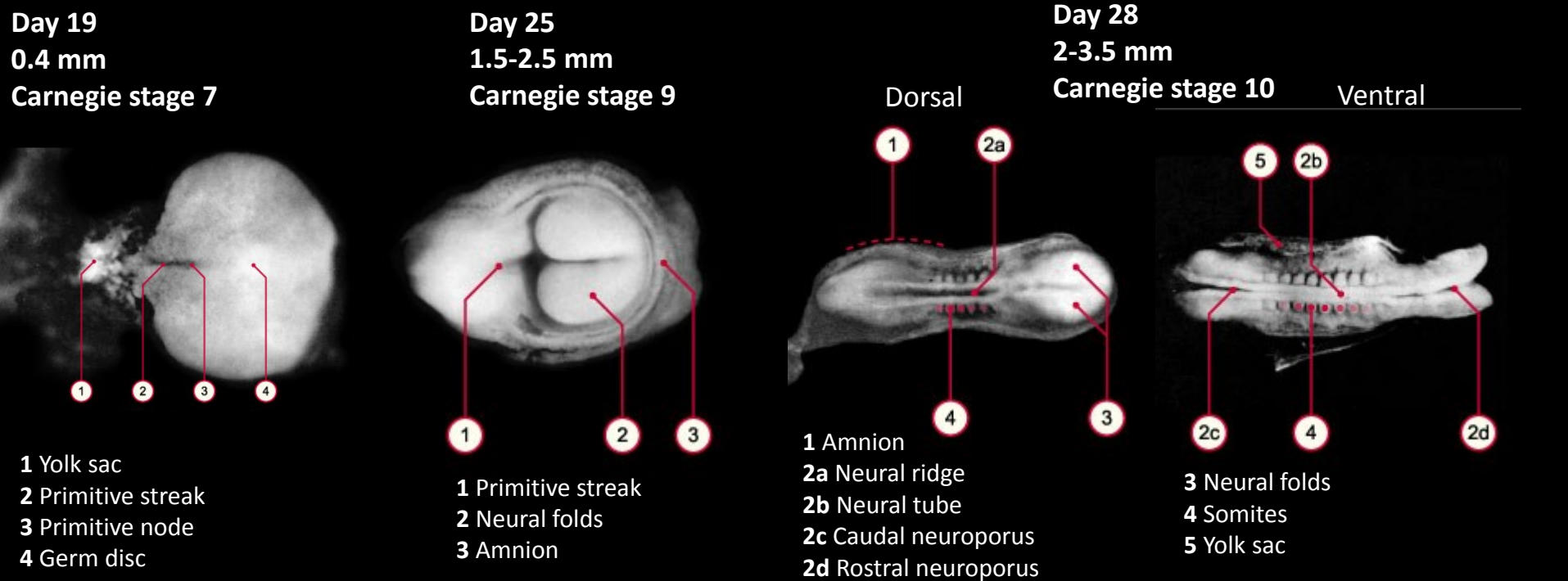
D

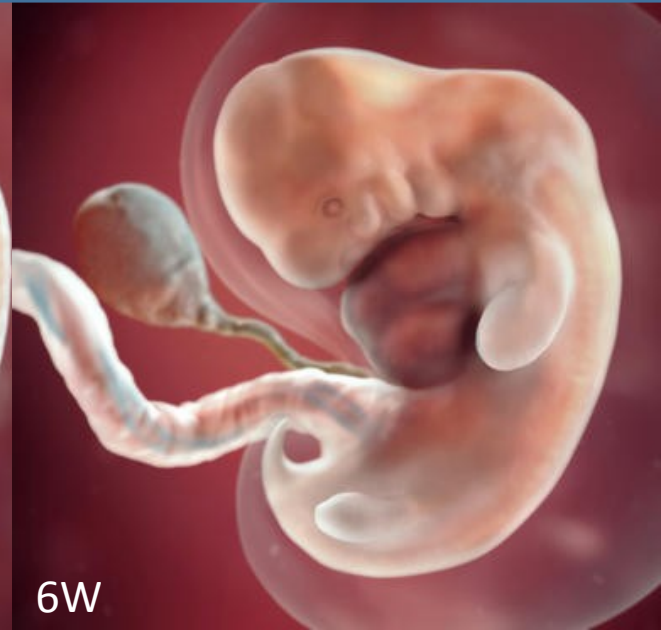
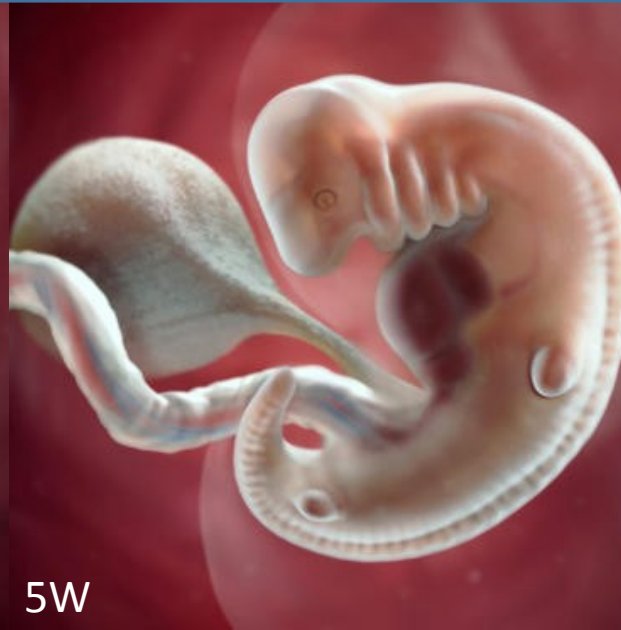
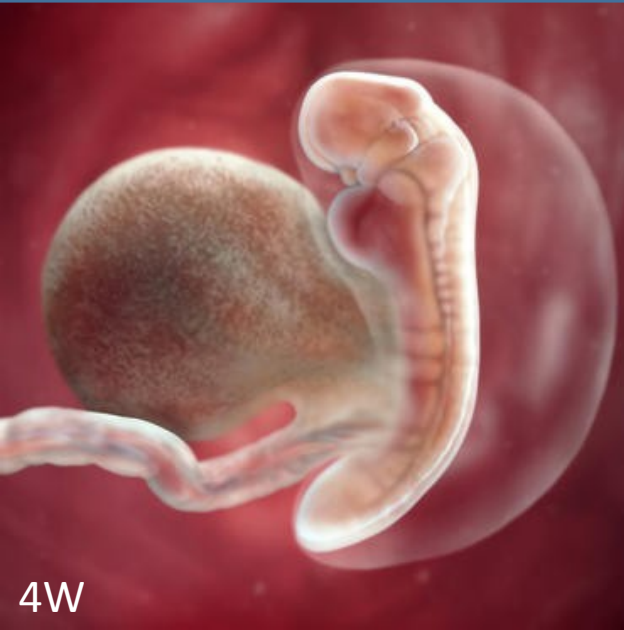

- bilaminar → trilaminar germ disc
- cephalocaudal and lateral flexion of embryo

<http://www.embryology.ch/anglais/iperiodeembryo/carnegie03.html#st710>





4W

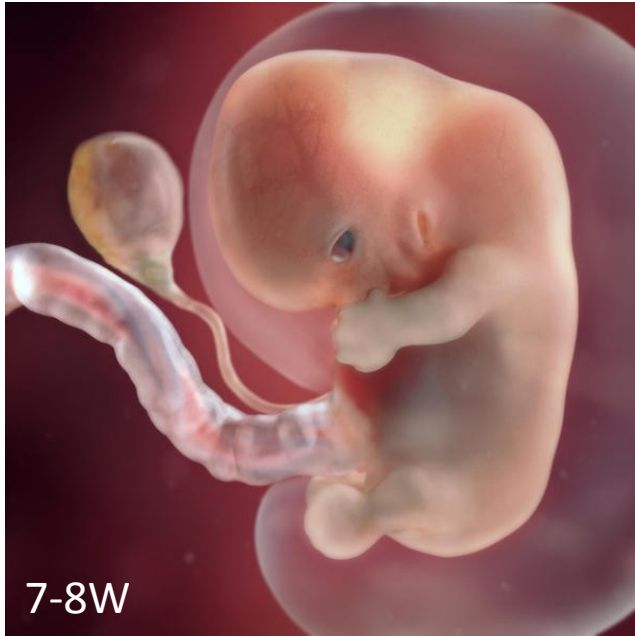5W

6W

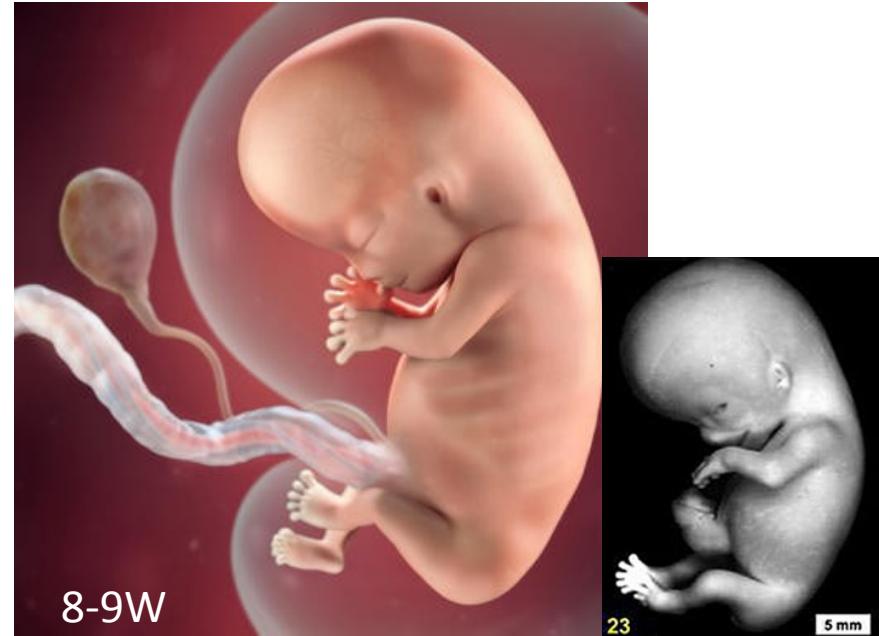- Mesoderm segmentation
- Primitive gut
- Esophagotracheal diverticulum
- Heart (starts beating day 22-23)
- Limb buds
- Primary brain vesicles, closing of neuropores
- Differentiation of neural crest
- Origin of thyroid and anterior pituitary
- Ectodermal placodes, optic vesicle
- Liver diverticulum
- Septum transversum

- Segmentation of mesoderm continues
- Posterior pituitary
- Heart septation begins
- Lung buds branch - pseudoglandular stage of lung development
- Cochlea grows
- Lens vesicle, nasal placodes
- Fourth brain ventricle forms
- Pharyngeal arches, ridges and pouches
- Limb buds grow
- Hematopoiesis in liver
- Retinal pigment

- Derivatives of endodermal pharyngeal pouches (parathyroid, thymus)
- Adrenal gland
- Heart and lungs descended to thorax
- Innervation of limbs, differentiation of myoblasts
- Face development – maxillary and mandibular processes, palatine, choans
- Telencephalon stratifies – archicortex, paleocortex and neocortex. Choroid plexus
- Rotation of stomach
- Pancreatic diverticula fuse



- Secretion from endocrine pancreas
- Growth of liver, growth and luminization of bile ducts
- Ossification of limbs begin
- Development of brain nuclei



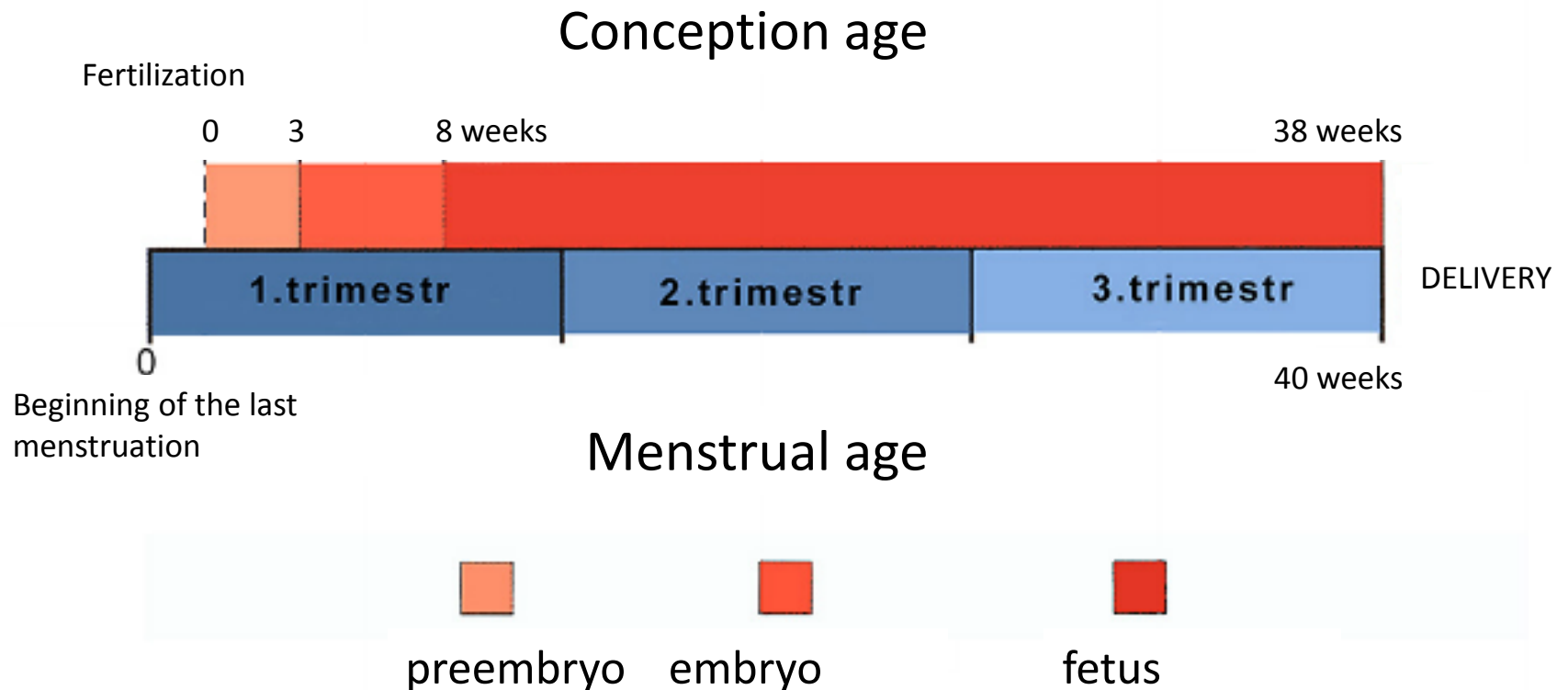
- Joints of upper and later lower limbs allow rotation
- Fingers grow
- Stratification of cerebellar cortex
- Perforation of anal membrane
- Herniation of intestinal loops
- Testes produce testosterone
- Nose, meatus, eyelids, developer, external ears start to grow
- Backbone - 33-34 cartilaginous vertebrae
- Embryonic tail diminished

LENGTH OF PREGNANCY

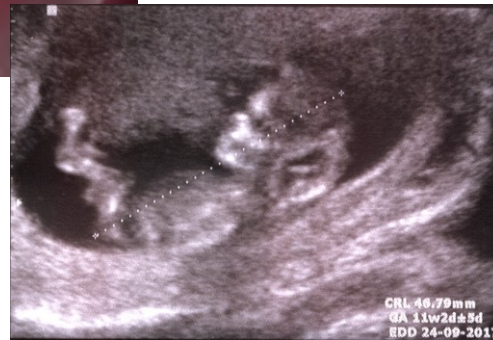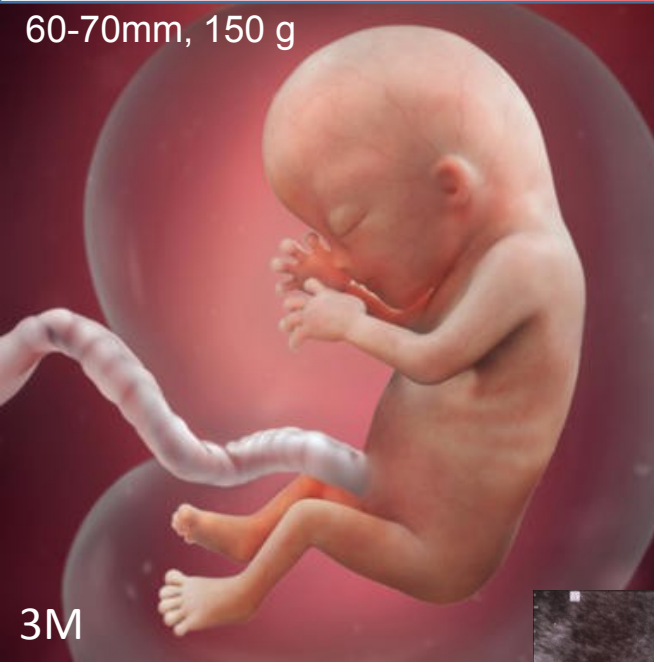280 days (= 40 weeks = 10 lunar months) from the first day of the last **menstruation**

266 days (= 38 weeks) **from ovulation** (gestation age)

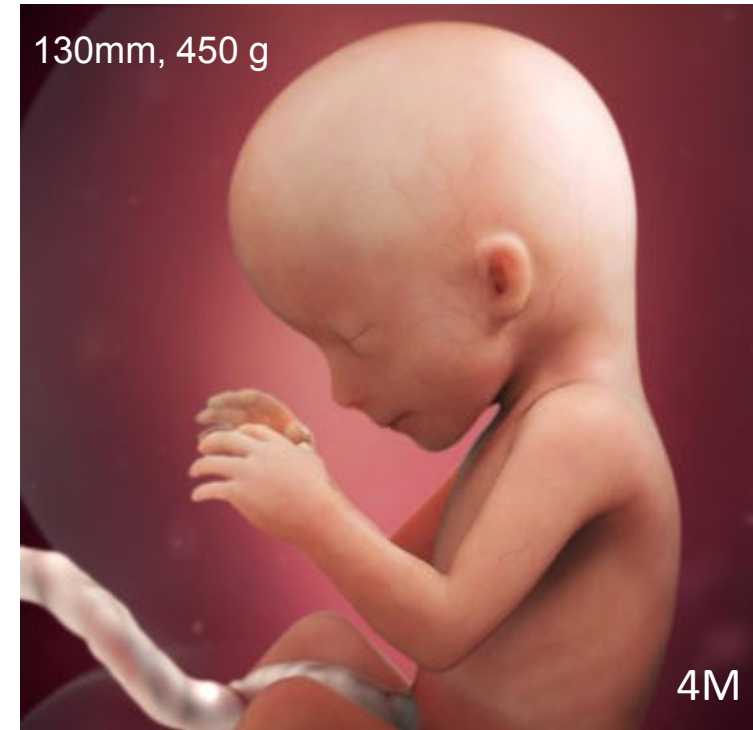
Calculation of term: First day of the last **menstruation** + **1 year– 3 months + 7 days**



60-70mm, 150 g

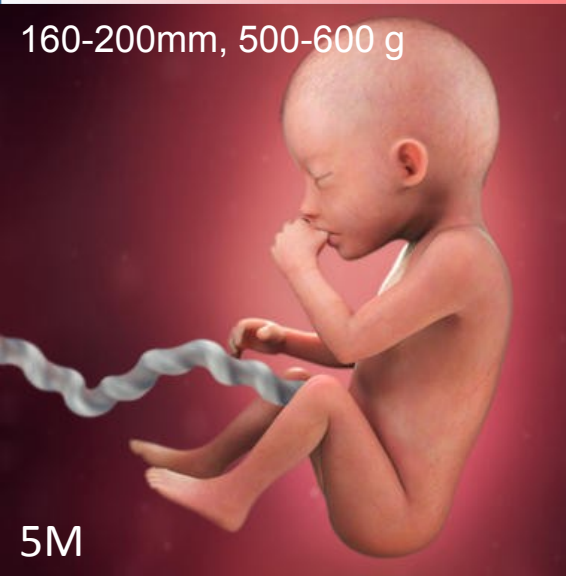

130mm, 450 g

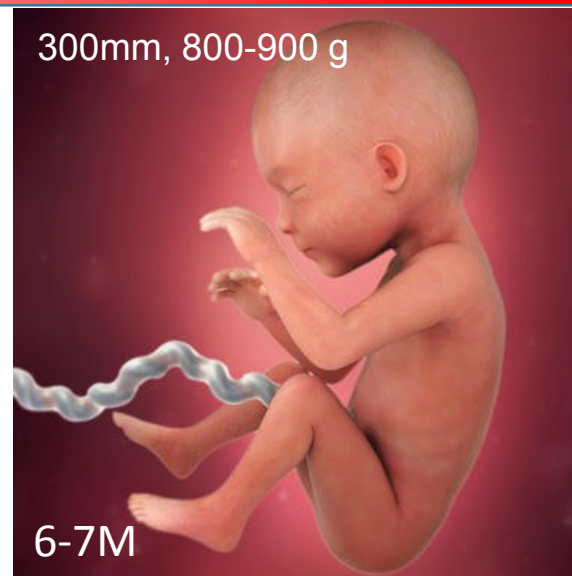


- Rapid growth of fetus
- Ossification of skeleton
- Face growths, mandible visible
- Apparent external genitalia

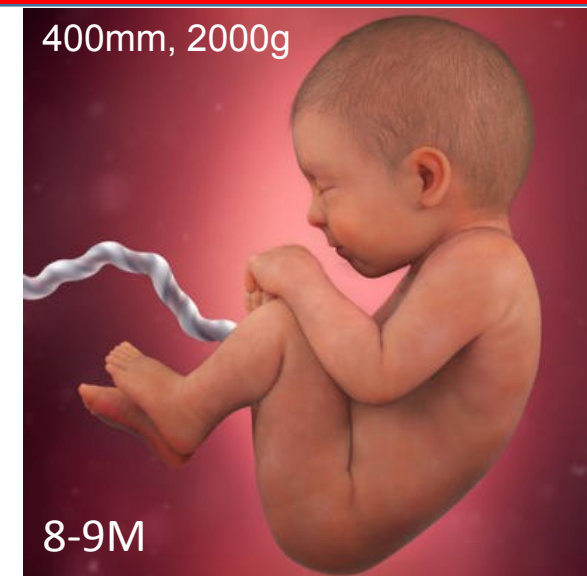
- Fetus swallows amniotic fluid – necessary for GIT development
- Rapid growth of head (non-proportional to rest of body)
- Eyelids fuse
- Ossification centers visible by ultrasound examination
- Development of external genitalia
- Kidneys produce urine, other organs start to work
- Skeletal muscles innervated
- Physiological umbilical hernia, in 12th weeks reposition of intestinal loops



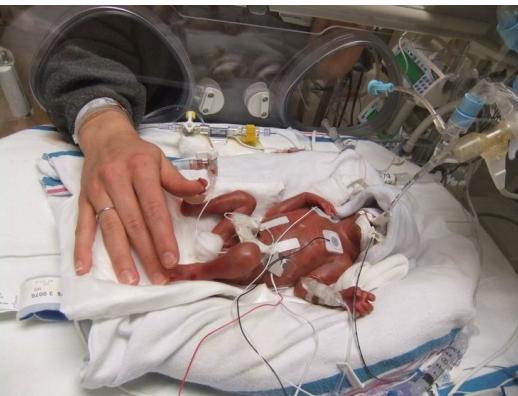- Limbs growth
- Mother feels fetal movements
- Vernix caseosa, lanugo
- Short hairs and eyelashes
- Fetus reacts to sound and later to light
- Lungs start to produce surfactant
- Limit of viability



- Eyelids open
- Wrinkled skin with visible capillaries
- Subcutaneous fat
- Hairs grow
- Maturing of organ systems



- Subcutaneous fat accumulates in limbs
- Smooth, red skin
- Hallmarks of full term fetus



Full term – related to length of pregnancy (menstrual age)

- preterm (<37 weeks)
- full term (38 – 40 weeks)
- after term (>42 weeks) (meconium in amniotic fluid)

Fetal maturity – development of fetus: **mature X immature**

HALLMARKS OF FETAL MATURITY

Major:

- **length (50 – 51 cm),**
- **weight** (around **3500 g**, physiological range 2500 - 4000g),
- head sizes
- boys - testes in scrotum, girls - labia majora over labia minora

Minor:

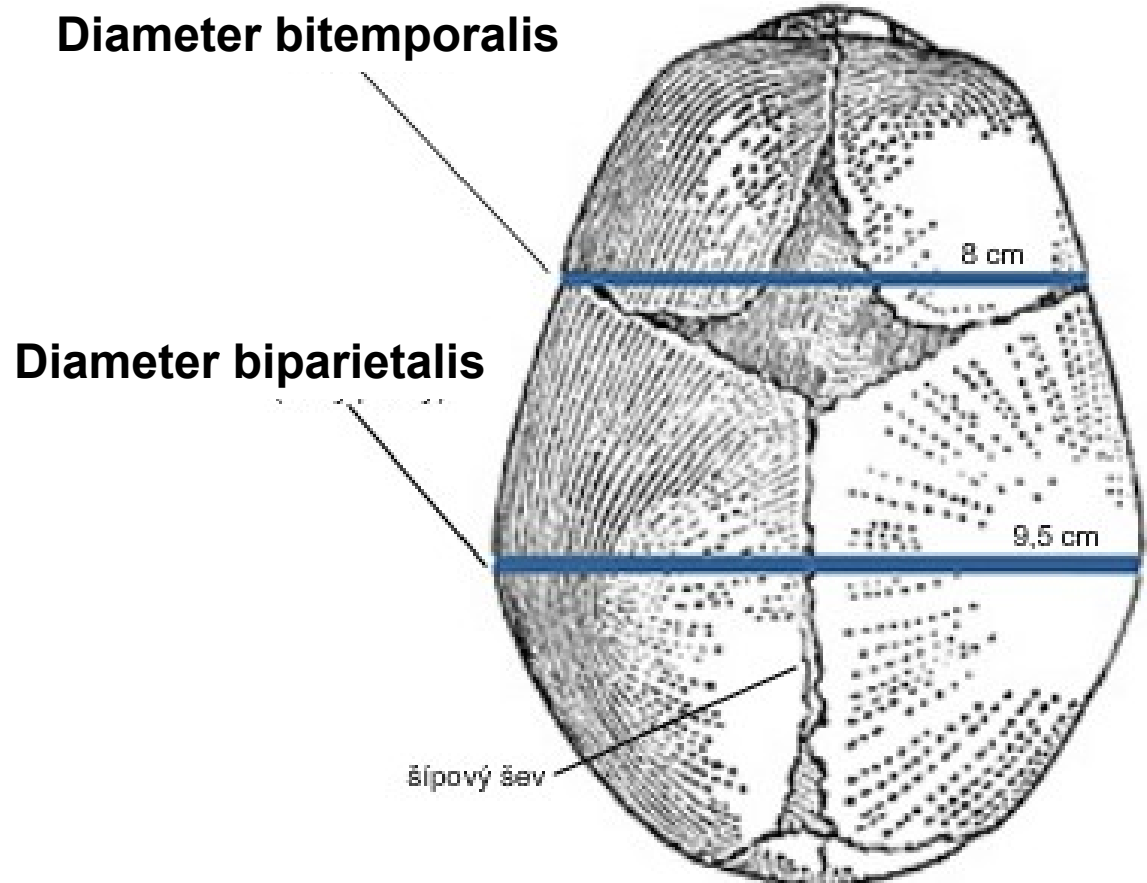
- eutrophic fetus, subcutaneous fat
- skin is not blue (no cyanosis), lanugo remains on shoulders and back,
- eyelashes, hairs several cm long, nails over fingertips
- cranial bones hard, anterior and posterior fontanelle are palpable, and separated
- newborn cries and moves (Apgar score)

Diameter bitemporalis – 8,00 cm

(join of the most distant points on sutura coronaria)

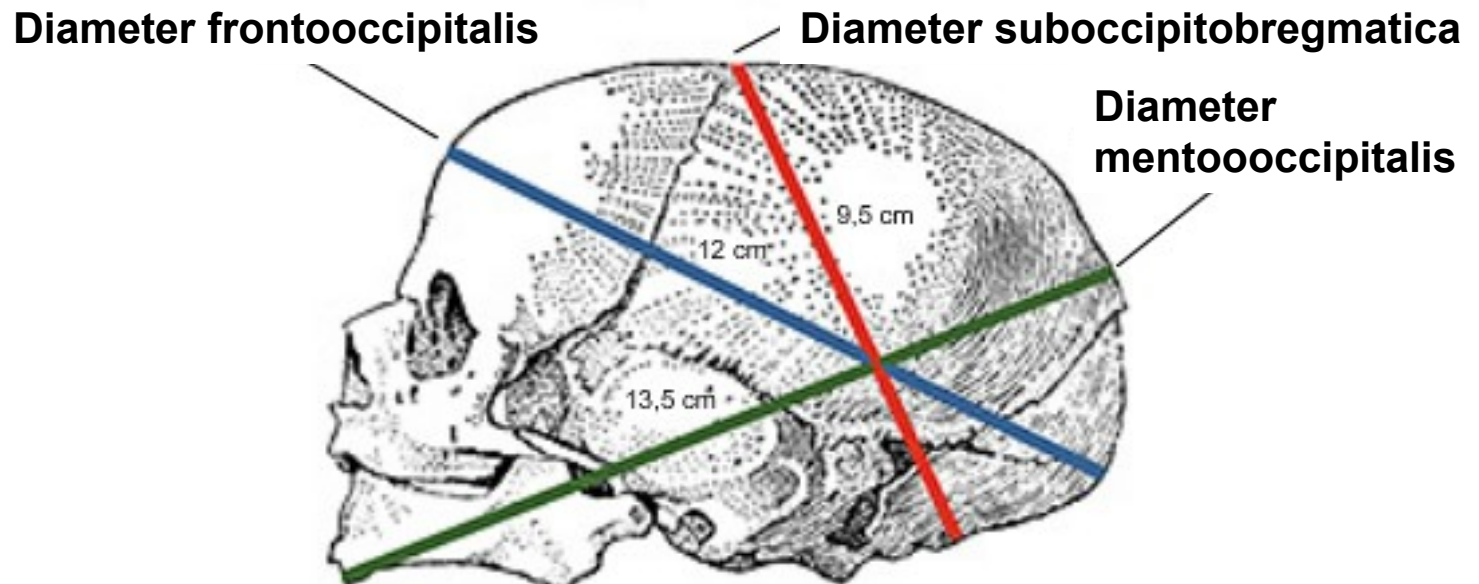
Diameter biparietalis – 9,5 cm

(join of midpoints of tubera parietalia)



Oblique sizes:

- **Diameter frontooccipitalis – 12.0 cm** (join of forehead midpoint and most distant point of occiput)
- **Circumferentia frontooccipitalis – 34.0 cm**
- **Diameter suboccipitobregmatica – 9.5 cm** (join of protuberantia occipitalis externa and midpoint of large fontanelle)
- **Circumferentia suboccipitobregmatica – 32.0 cm**
- **Diameter mentooccipitalis – 13.5 cm** (join of chin midpoint and most distant point of occiput)
- **circumferentia mentooccipitalis – 35 - 36 cm**
- **Diameter biacromialis – 12.0 cm, circumferentia biacromialis – 35 cm**
(join of acromion – acromion)



RULE OF HASSE

- forensic medicine

3. – 5. lunar month: length in cm = square of month

6. – 10. lunar month: length in cm = months multiplied by 5

Lunar month	Length of fetus[cm]
3	9
4	16
5	25
6	30
7	35
8	40
9	45
10	50

FETUS IN UTERUS

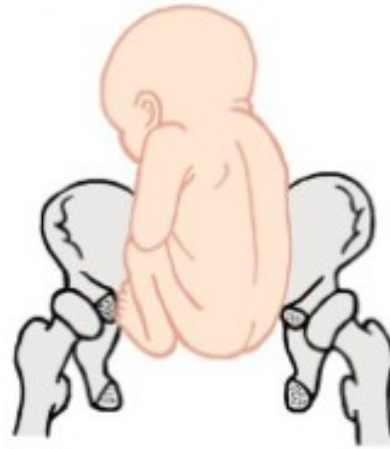
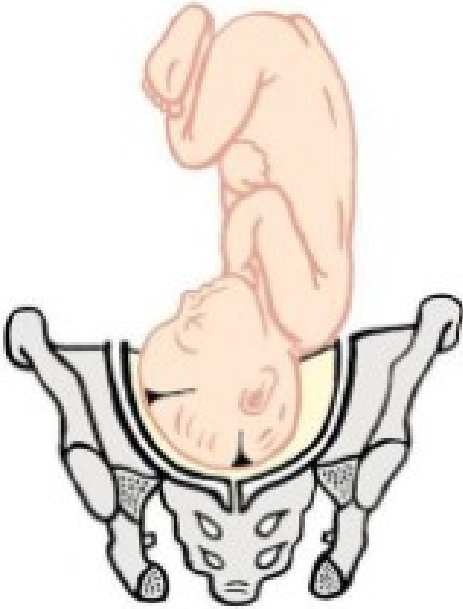1. **LIE (*SITUS*)** = relationship of the long axis of the fetus to that of the mother
 - longitudinal: (99 %)
 - transverse: (1 %) perpendicular axes
 - oblique: unstable → longitudinal or transverse position
2. **POSITION (*POSITIO*)** = fetal backbone relative to uterus ridge
 - **first**= left (back to the left)
 - **second**= right (back to the right)
 - first/second common/less common
3. **FETAL HABITUS (*HABITUS*)** = relationship of one fetal part to another
 - regular = head and limbs in flexion
 - irregular = everything else
4. **PRESENTATION (*PRAESENTATIO*)** = that part of the fetus lying over the pelvic inlet; the presenting body part of the fetus.
 - occiput (most common)
 - vertex, forehead, face (1%)
 - breech
 - trunk, shoulder

FETUS IN UTERUS

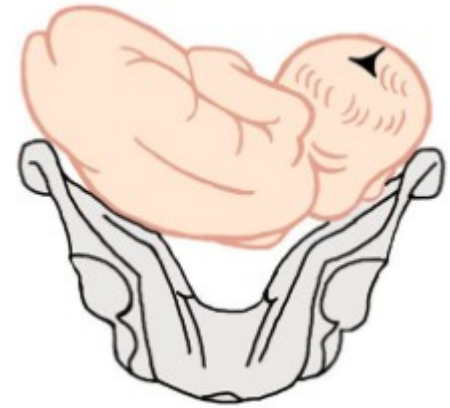1. **LIE (SITUS)** = relationship of the

- longitudinal: (99 %)
- transverse: (1 %) perpendicular a:
- oblique: unstable → longitudinal c

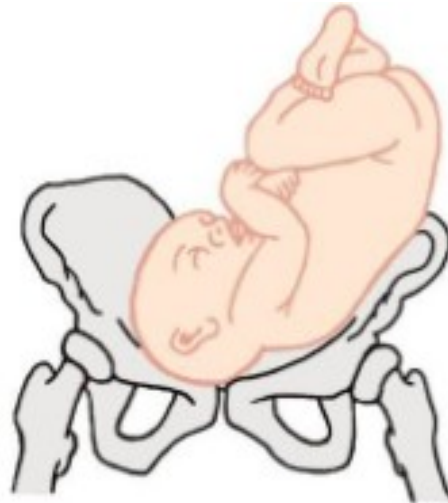longitudinal - occiput



longitudinal - breech



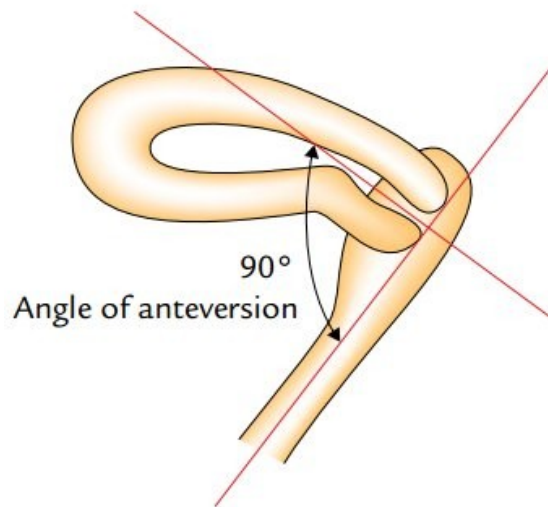
transverse



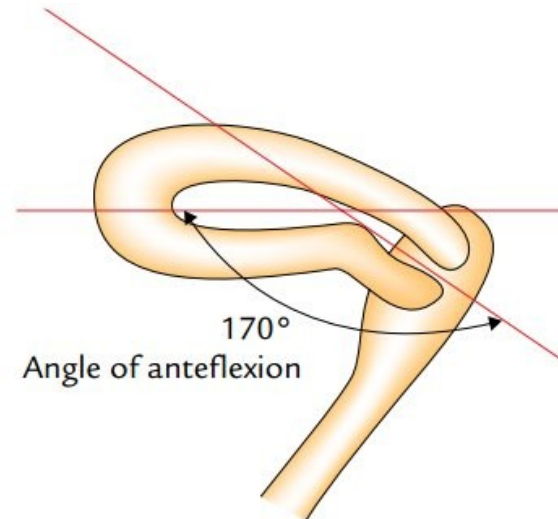
oblique

2. POSITION (*POSITIO*) = fetal backbone relative to uterus ridge

- **first**= left (back to the left)
- **second**= right (back to the right)
- first/second common/less common
- tranverse



Position of anteversion



Position of anteflexion

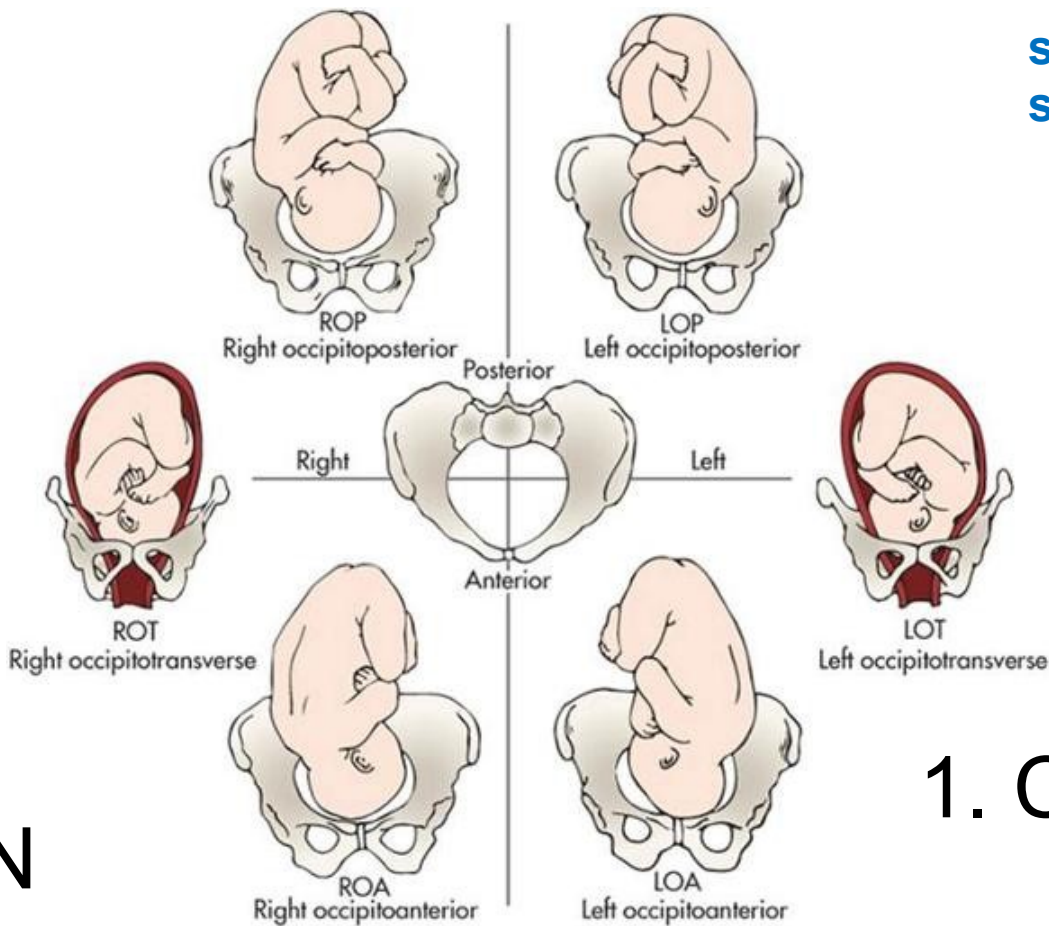
Note: Normally uterus is in anteversion and anteflexion (rarely retroversion, retroflexion)
In late pregnancy, uterus is in dextroversion and dextrotorsion (rarely sinistroversion, sinistrotorsion)

2. COMMON

dextroversion
dextrotorsion

1. LESS COMMON

sinistroversion
sinistrotorsion



2. LESS COMMON

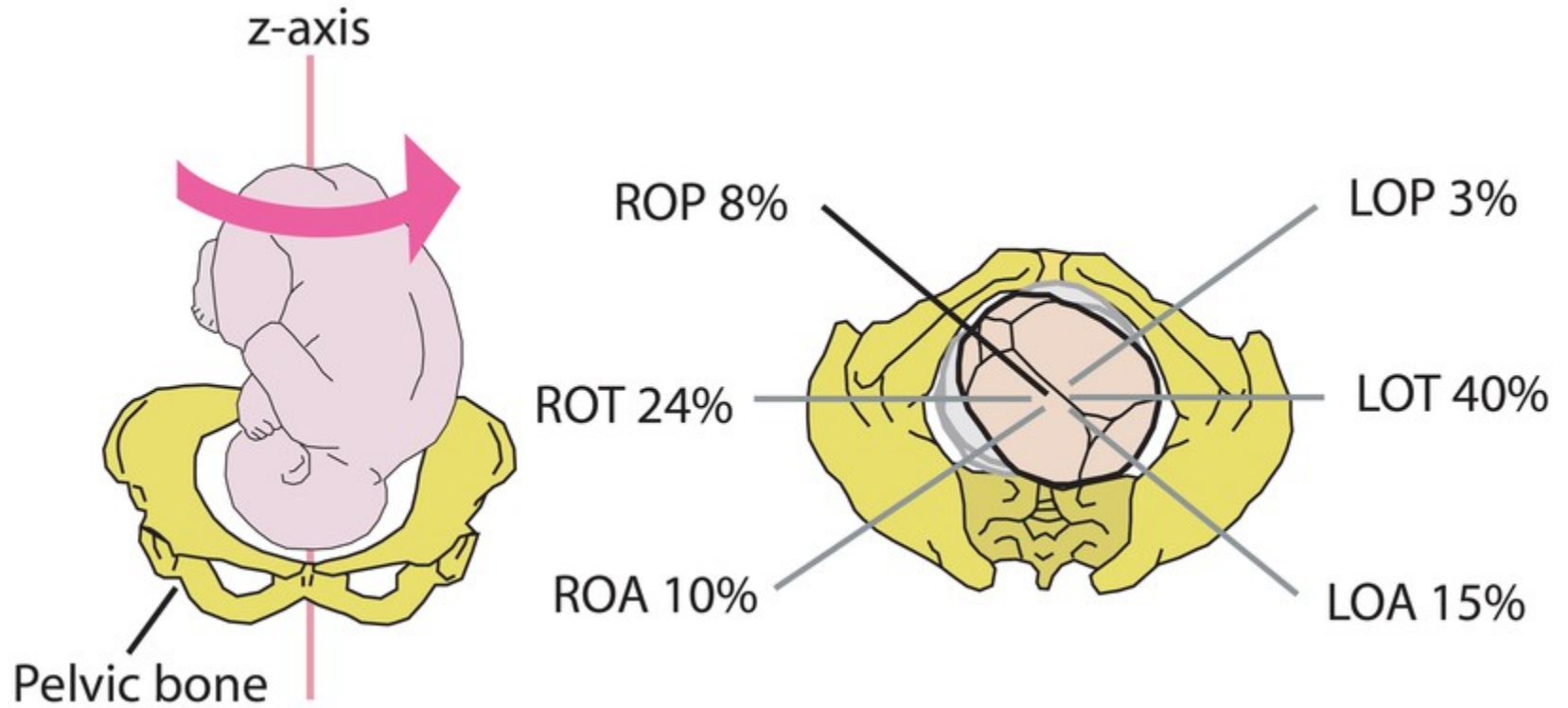
sinistroversion
sinistrotorsion

1. COMMON

dextroversion
dextrotorsion

Lie: Longitudinal or vertical
Presentation: Vertex
Reference point: Occiput
Attitude: General flexion

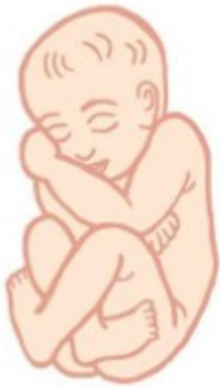POSITION OF FETUS



FETUS IN UTERUS

3. **FETAL HABITUS (*HABITUS*)** = relationship of one fetal part to another

- regular = head and limbs in flexion
- irregular = everything else



regular

HABITUS

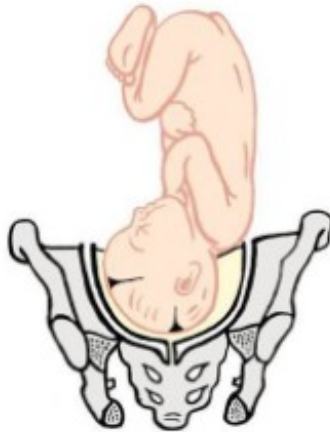irregular (any other)

4. **PRESENTATION (*PRAESENTATIO*)** = that part of the fetus lying over the pelvic inlet; the presenting body part of the fetus.

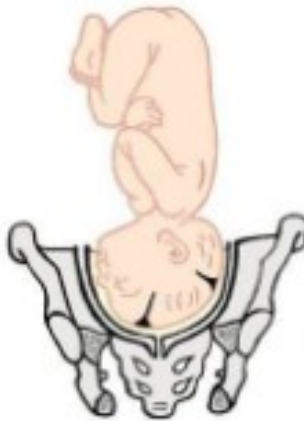- occiput (most common)
- vertex, forehead, face (1%)
- breech
- trunk, shoulder

PRESENTATION

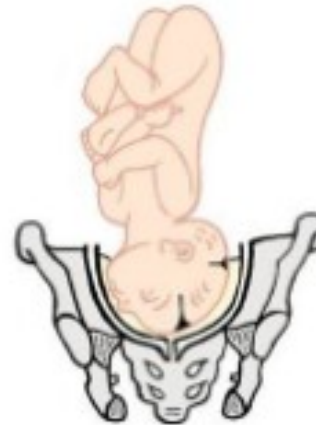occiput



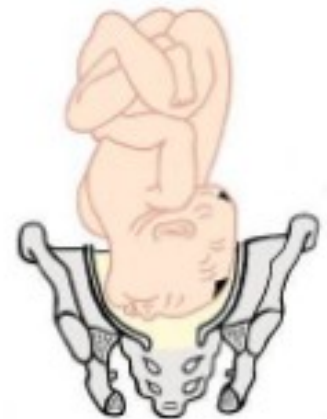vertex



forehead

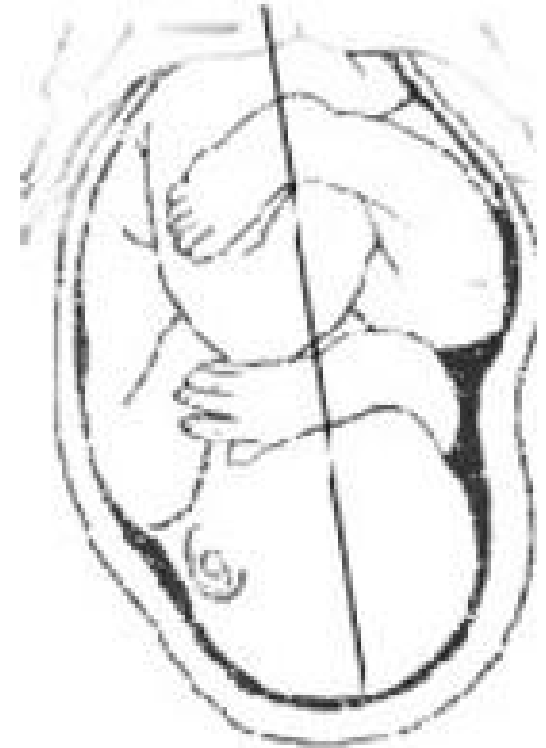


face



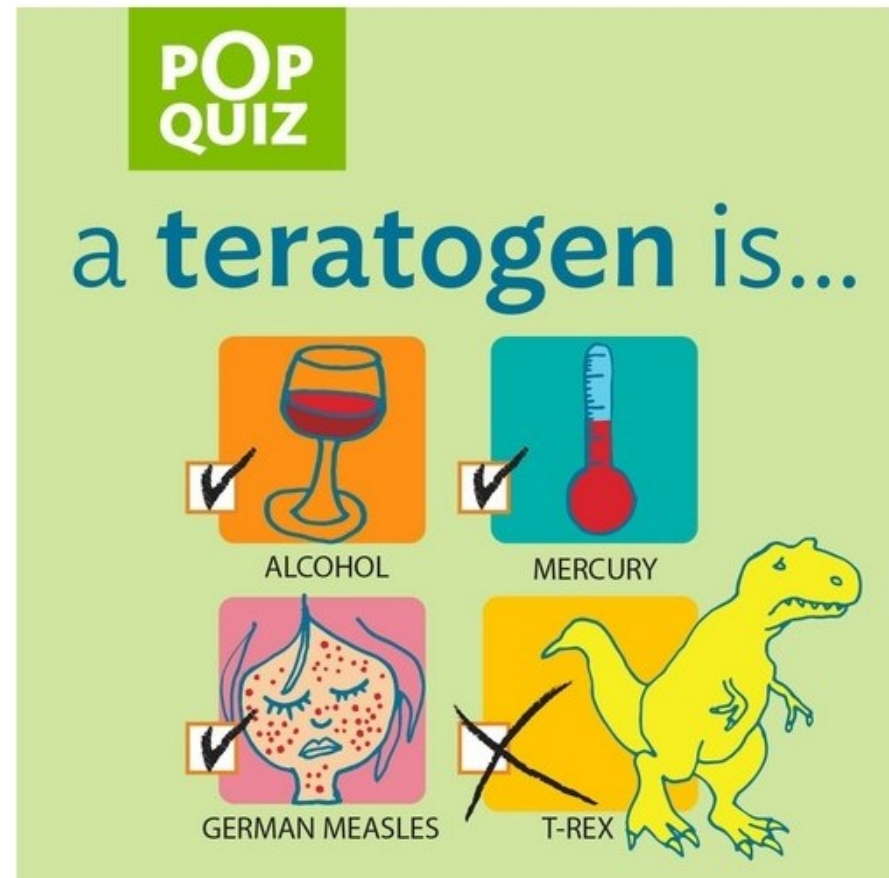
PHYSIOLOGICAL IMPOSITION OF FETUS IN UTERUS

- LIE LONGITUDINAL - HEAD FIRST
- POSITION FIRST COMMON
- HABITUS REGULAR
- PRESENTATION - OCCIPUT



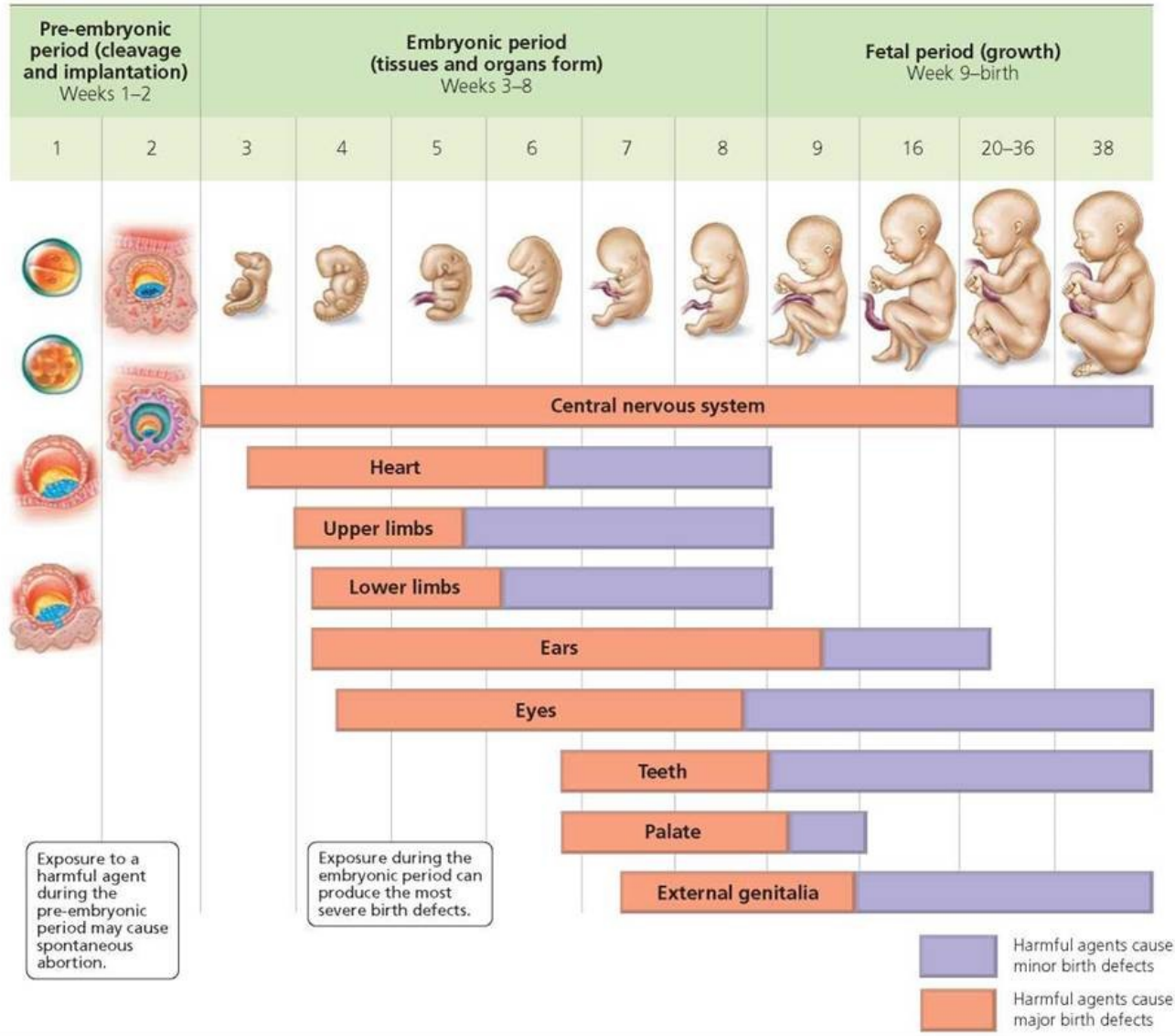
INTRODUCTION TO TERATOLOGY

- Congenital disorders – due to abnormal developmental events
- Genetic (inherited) or nongenetic (external) causes
- Teratogens
- Life style (alcohol, smoking, drugs)
- Infections (rubeola, HIV, toxoplasmosis)
- Lack or abundance of key substances (folic acid × retinoids)
- Chronic diseases (medical treatment)
- Physical (temperature, radiation)



INTRODUCTION TO TERATOLOGY

Critical developmental periods

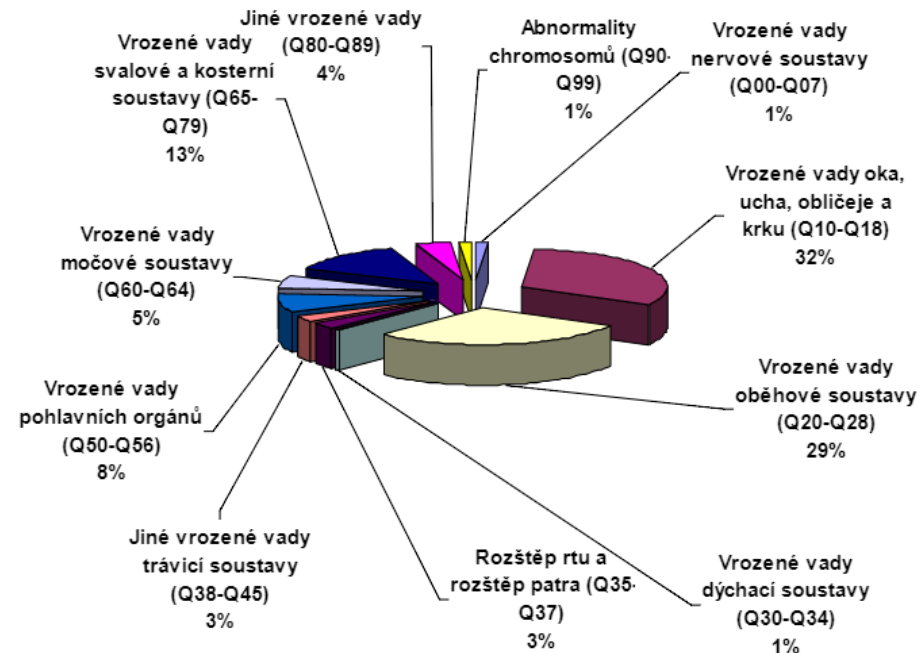


INTRODUCTION TO PRENATAL DIAGNOSTICS

- Interdisciplinary care – biochemistry, genetics, gynecology and obstetrics, neonatology – parts of fetal medicine
- Revealing high risk pregnancies, access to preventive and therapeutic care
- Preventing delivery of fetuses with severe congenital malformations
- Support of delivery of genetically high-risk babies
- Planning and providing clinical care

- Genetic counselling
- Biochemical and ultrasound screening
- Karyotyping and DNA diagnostics
- Clinical diagnostics

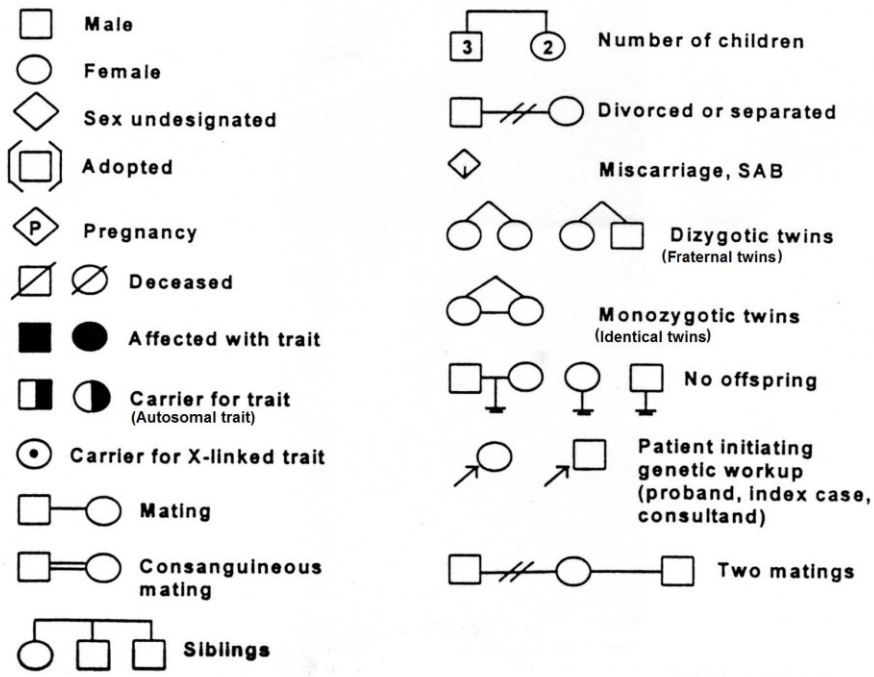
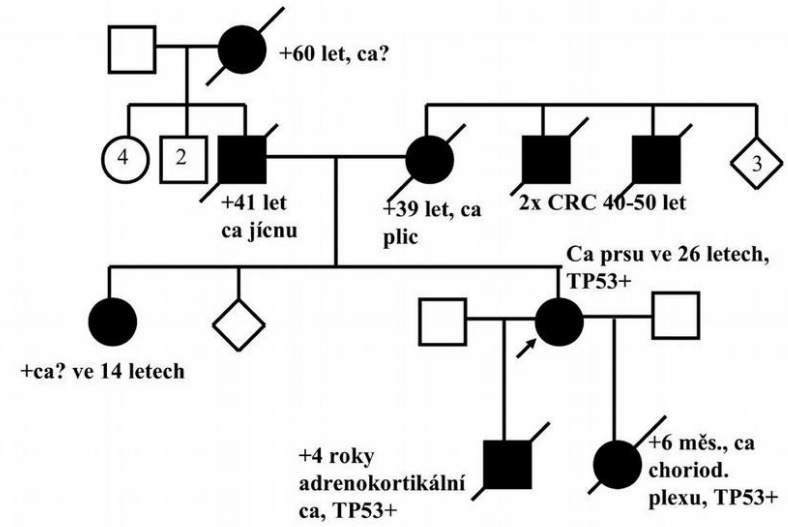
- Indication:
 - congenital disorders in family
 - positive screening in 1st or 2nd trimester
 - abnormal finding by ultrasound
 - maternal age (over 35 years)



ČR 1994-2008

GENETIC COUNSELING

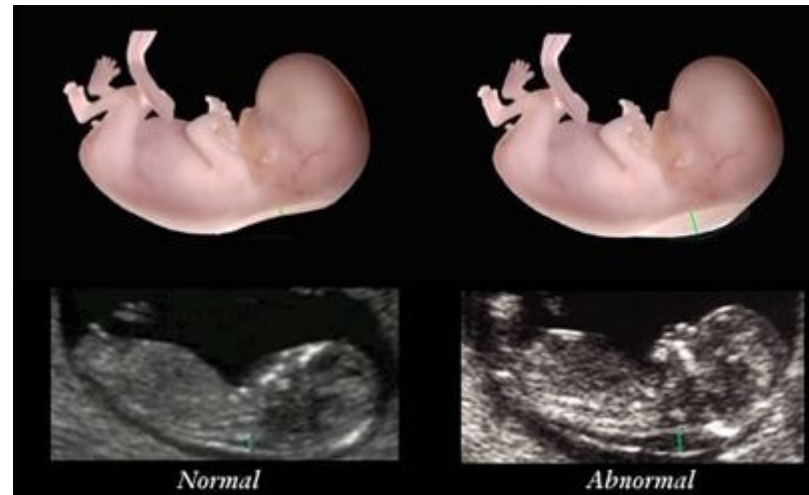
- Anamnesis (case history)
- Preconception counselling
- Explaining of examination results, causes, clinical symptoms, therapeutic options
- Minimization of risk of repeated disease
- Providing diagnosis and information for free choice
- Providing precise diagnosis and risk estimation
- Providing care during pregnancy and later



NONDIRECTIVE
 ALL EXAMINATIONS AND
 PROCEDURES ARE VOLUNTARY

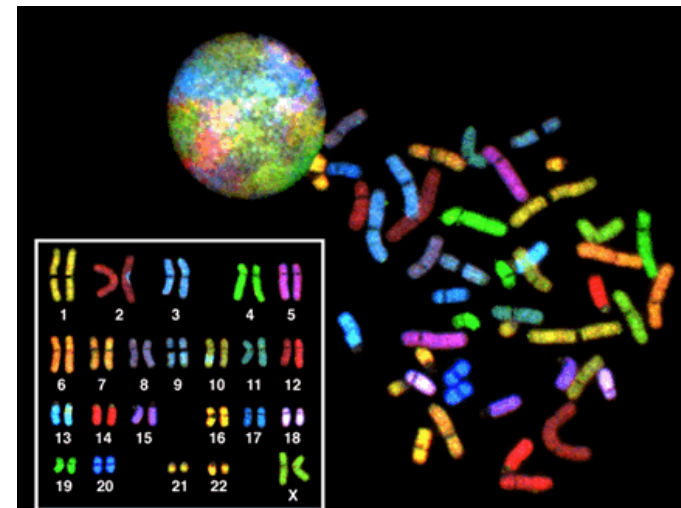
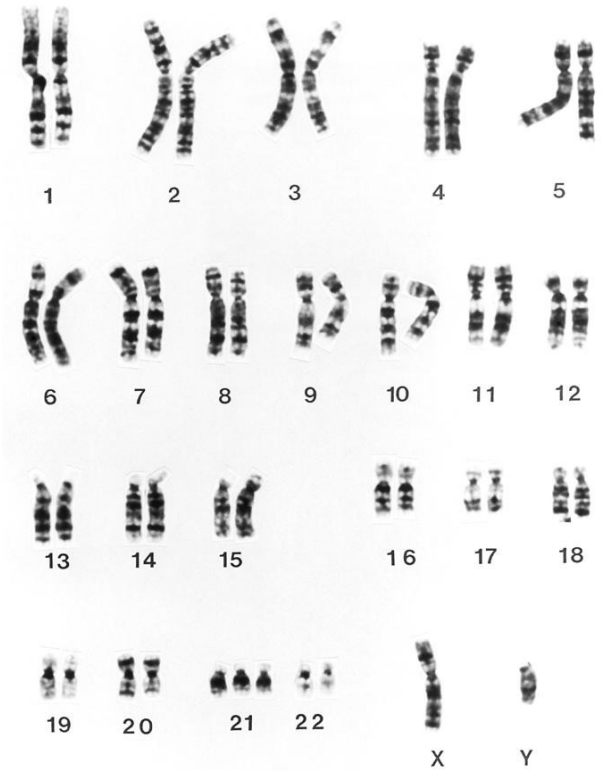
BIOCHEMICAL SCREENING

- Non invasive
 - Revealing high risk pregnancies – chromosomal aberrations and clefts
 - **Screening is not a diagnostics** → further examinations (amniocentesis, karyotype, US)
- Tests between weeks 14-16 („TRIPLE test“)
 - low sensitivity and specificity (50-60%), high false positivity (70%)
 - AFP, E3, hCG
 - chromosomal aberrations, abnormal closing of neural tube, defects of body walls
- Combined screening in week 11-13
 - chromosomal aberrations – Down: 47,XY,+21, Edwards: 47,XY,+18, Patau 47,XY,+18
 - US –nuchal translucence, NT
 - PAPP-A, hCG (multiplies of median, MoM)
 - age included in algorithm
 - output: screening positive vs. negative (limit 1:100)



INVASIVE DIAGNOSTICS

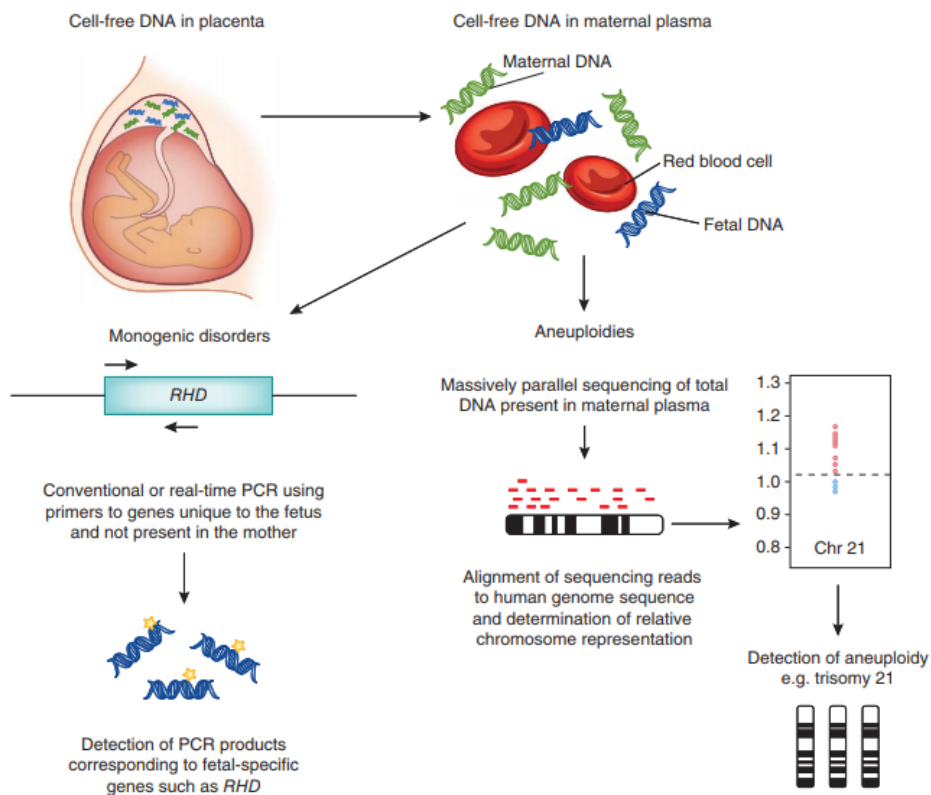
- Amniocentesis
 - 16th-20th week
 - US controlled amniotic fluid aspiration
 - Cell culture, karyotype
 - Risk of miscarriage 0.5-1%
- Chorion villus biopsy
 - 10th-13th week
 - Karyotype, molecular genetic examination
 - Risk 0.5-1%
- Cordocentesis
 - 22nd week
 - Sampling of venous umbilical blood
 - Now diagnostics and therapy of blood diseases (anemia, infections), or diagnostics in multiple pregnancies
 - Risk 1%
- Fetoscopy
 - Transabdominally (earlier transcervically)
 - Visualization and fetal biopsy
 - Risk 3-10%, done rarely



ULTRASOUND DIAGNOSTICS

- 6-8th week
 - confirmation of pregnancy, heart action
 - number of fetuses
- 13-14th week
 - nuchal translucence (risk > 3 mm)
 - nasal bone (present × absent), **minor markers** (omphalocele, tricuspidal regurgitation, abnormality in ductus venosus flow, enlargement of urinary bladder-megavesica)
 - fetal size
- 20-22nd week
 - detailed screening
 - fetal biometry (biparietal diameter, head circumference, length of femur)
 - head and CNS (shape, cavity in septum pellucidum, ventricles, cerebellum, cisterna magna), face (lip, jaws, nose, orbits, profile), heart (action, size, axis, 4-chamber projection, outflow tracts, ...), thorax (pathological structures), abdominal cavity (stomach, intestine, kidneys, urinary bladder, umbilicus and umbilical vessels), backbone, limbs, palms, feet
 - placenta, volume of amniotic fluid
- 30th week
 - fetal size
 - volume of amniotic fluid
 - placenta (exclusion of *placenta praevia*)

ADVANCEMENTS IN MOLECULAR GENETICS



Analysis of cell-free fetal DNA in maternal blood
 Since 12th week
 Massive parallel sequencing (Next-Gen Sequencing)
 Common aneuploidies (trisomy 21,13,18)
 Monogeneous disorders

SOP-M8 NEINVAZIVNÍ DETEKCE ANEUPLOIDIÍ CHROMOZOMŮ 13, 18 A 21 POMOCÍ MULTIPLEX PCR A MASIVNÍHO PARALELNÍHO SEKVENOVÁNÍ (MPS)

Test Clarigo se značkou „CE“, která je nezbytná pro provedení tohoto vyšetření v zemích EU, splňuje základní požadavky Směrnice Rady IVD 98/79/EC pro *in vitro* diagnostiku.

VÝSLEDEK VYŠETŘENÍ:

Chromozom	Stav	Fetální frakce	Předpokládané pohlaví plodu
13	normální	7,1 %	ženské
18	normální		
21	normální		

ZÁVĚR:

Analýzou volné fetální DNA cirkulující v krvi těhotné nebylo zjištěno zvýšené riziko aneuploidie chromozomů 13, 18 a 21.

Komentář: doporučujeme genetickou konzultaci.

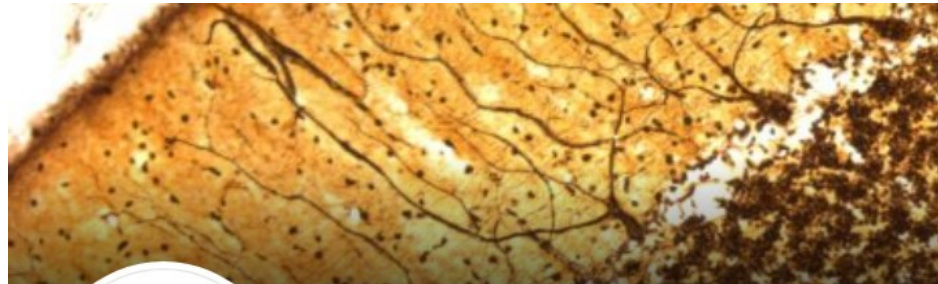
Pozn: Při patologickém nálezů je výsledek nutné ověřit některým z invazivních postupů (např. odběr plodové vody, choriových klků, kordocentéza s následnou QF-PCR analýzou nebo stanovením klasického karyotypu apod.).

Thank you for attention

Questions and comments

pvanhara@med.muni.cz

<http://www.med.muni.cz/histology>



HistoKlub MED MUNI

@HistoKlubMEDMUNI · Vzdělávací web