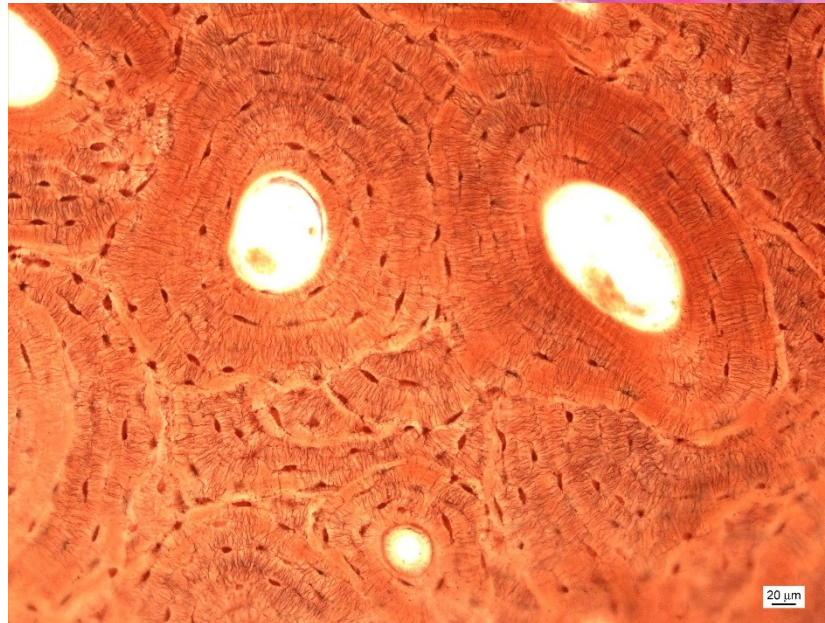
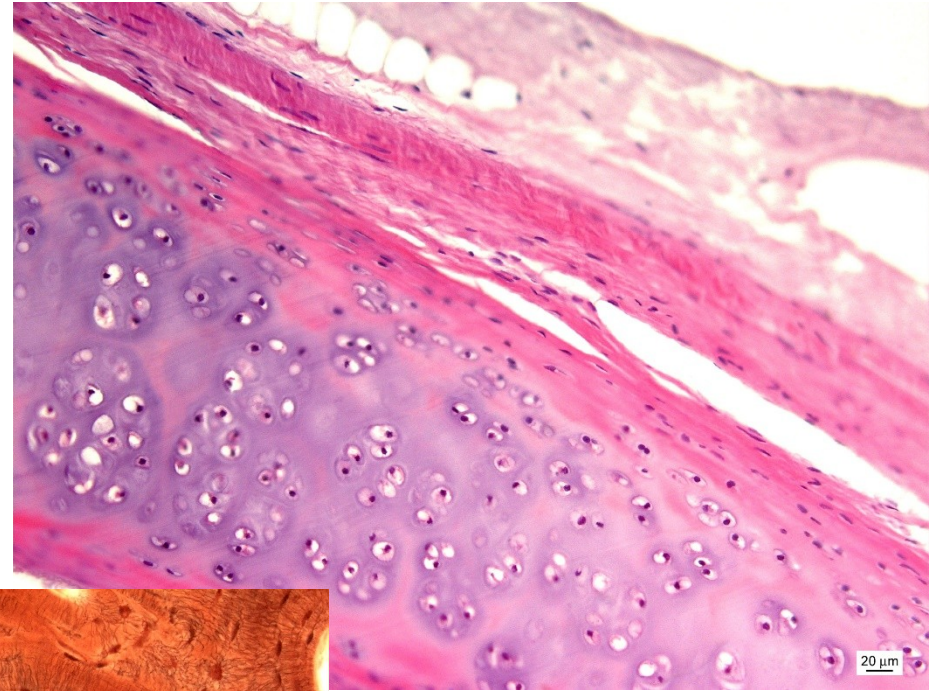
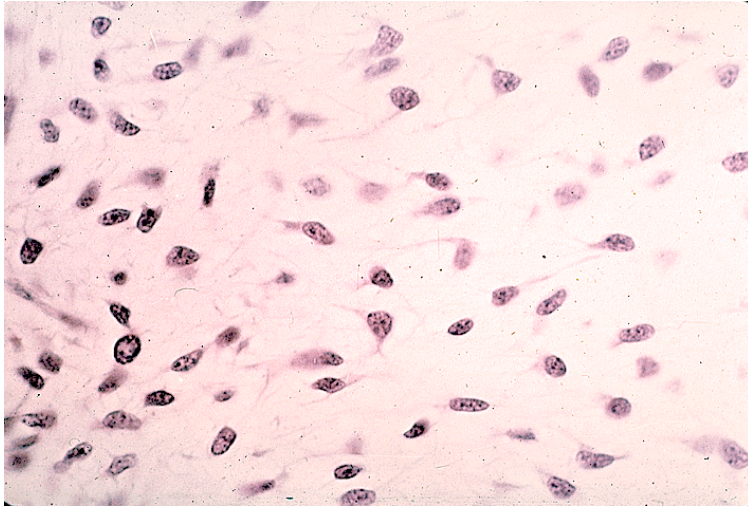


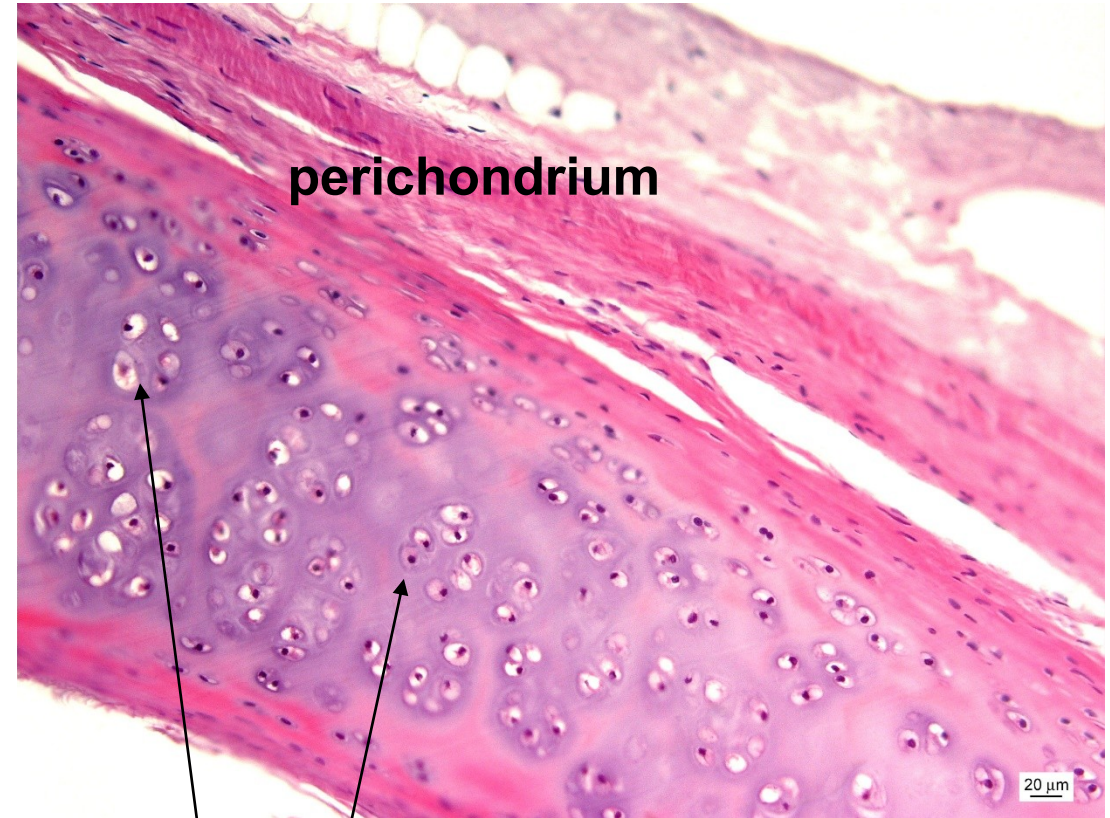
# CHRUPAVKA & KOST



# Hyalinní chrupavka

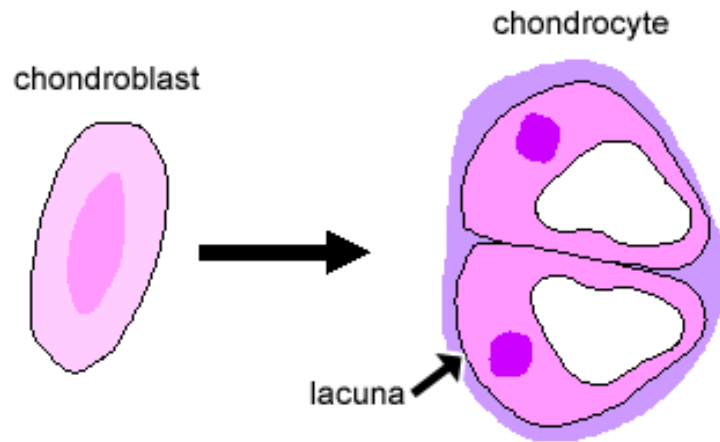


mesenchym

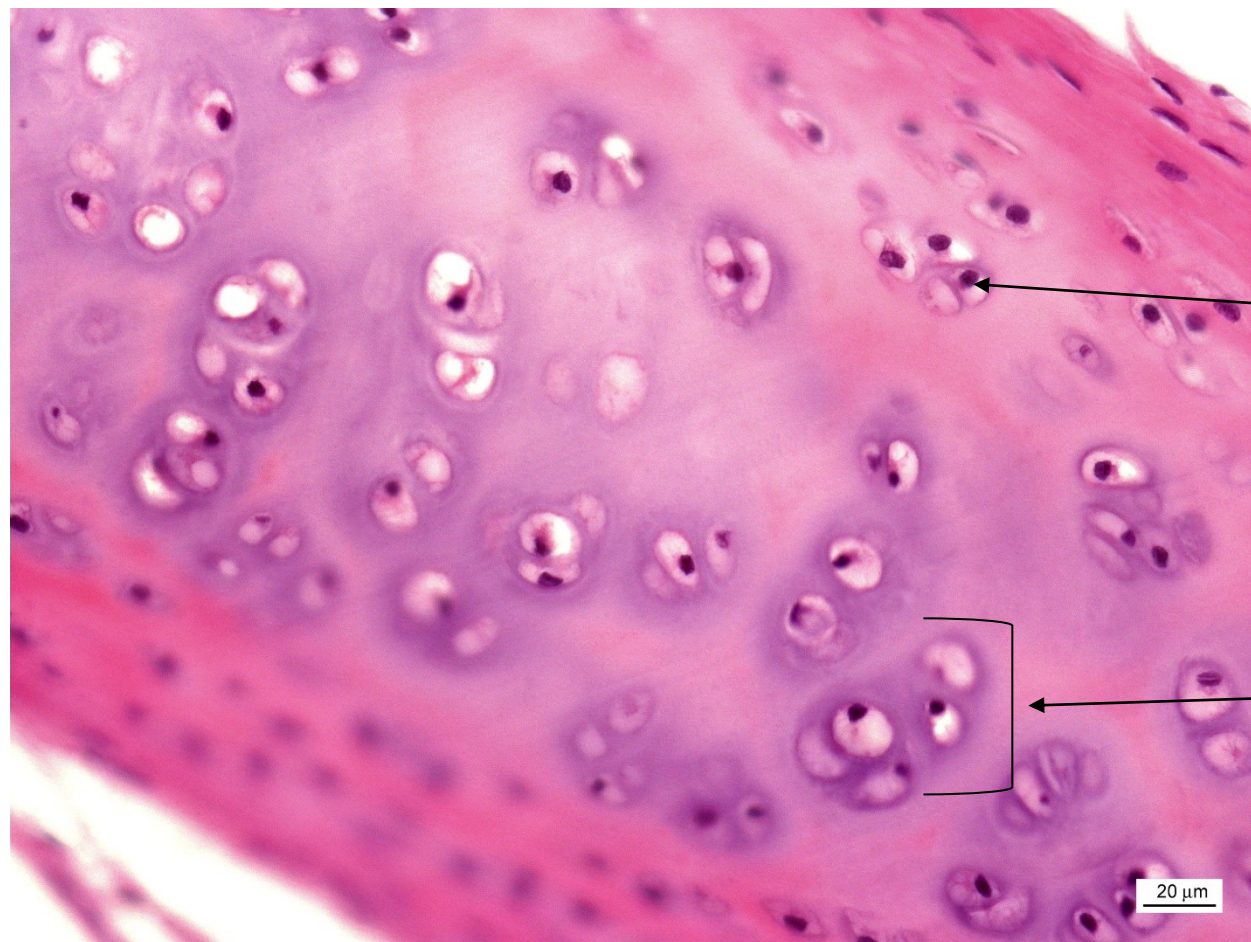


perichondrium

izogenetická skupina



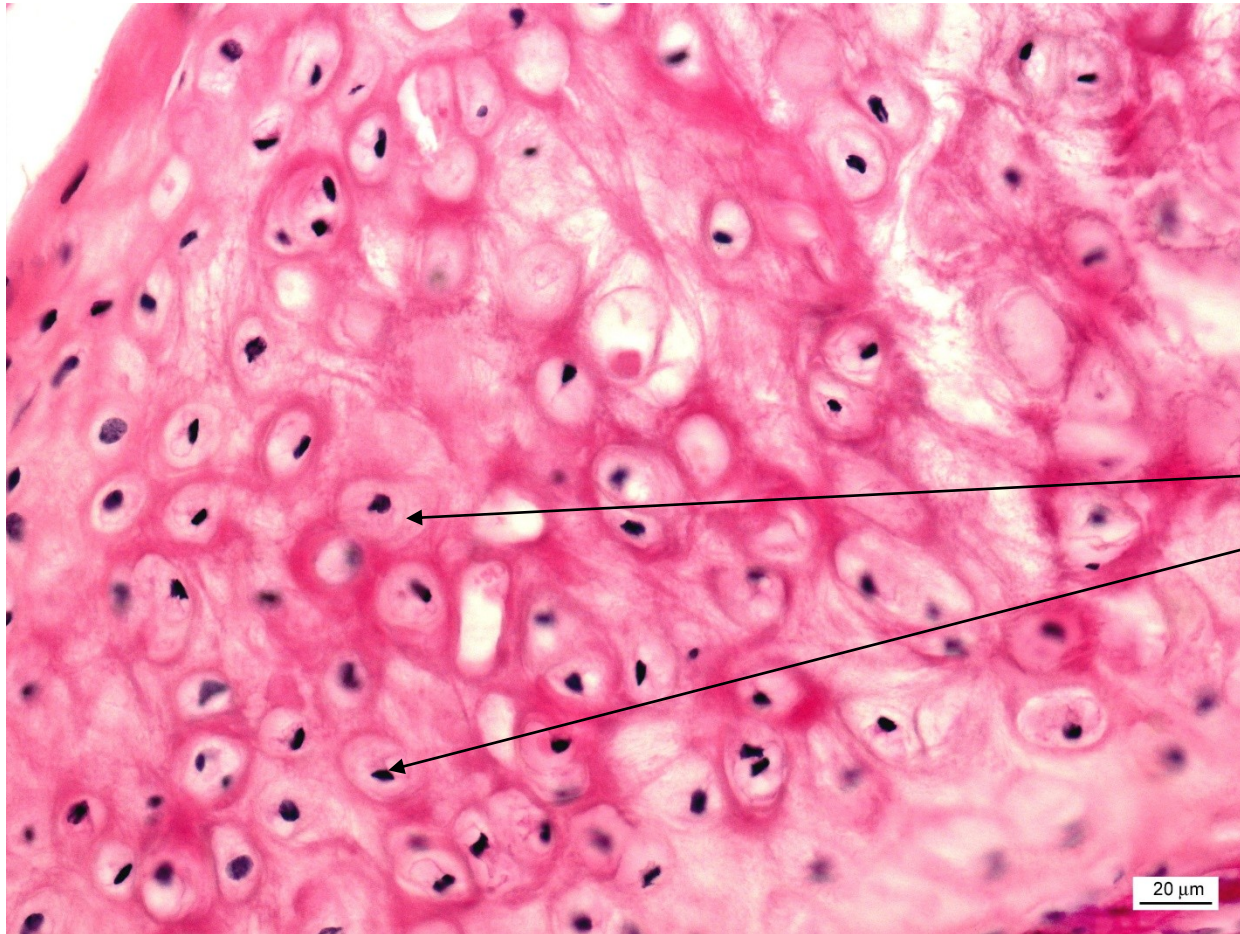
# Hyalinní chrupavka



izogenetické skupiny

chondrony

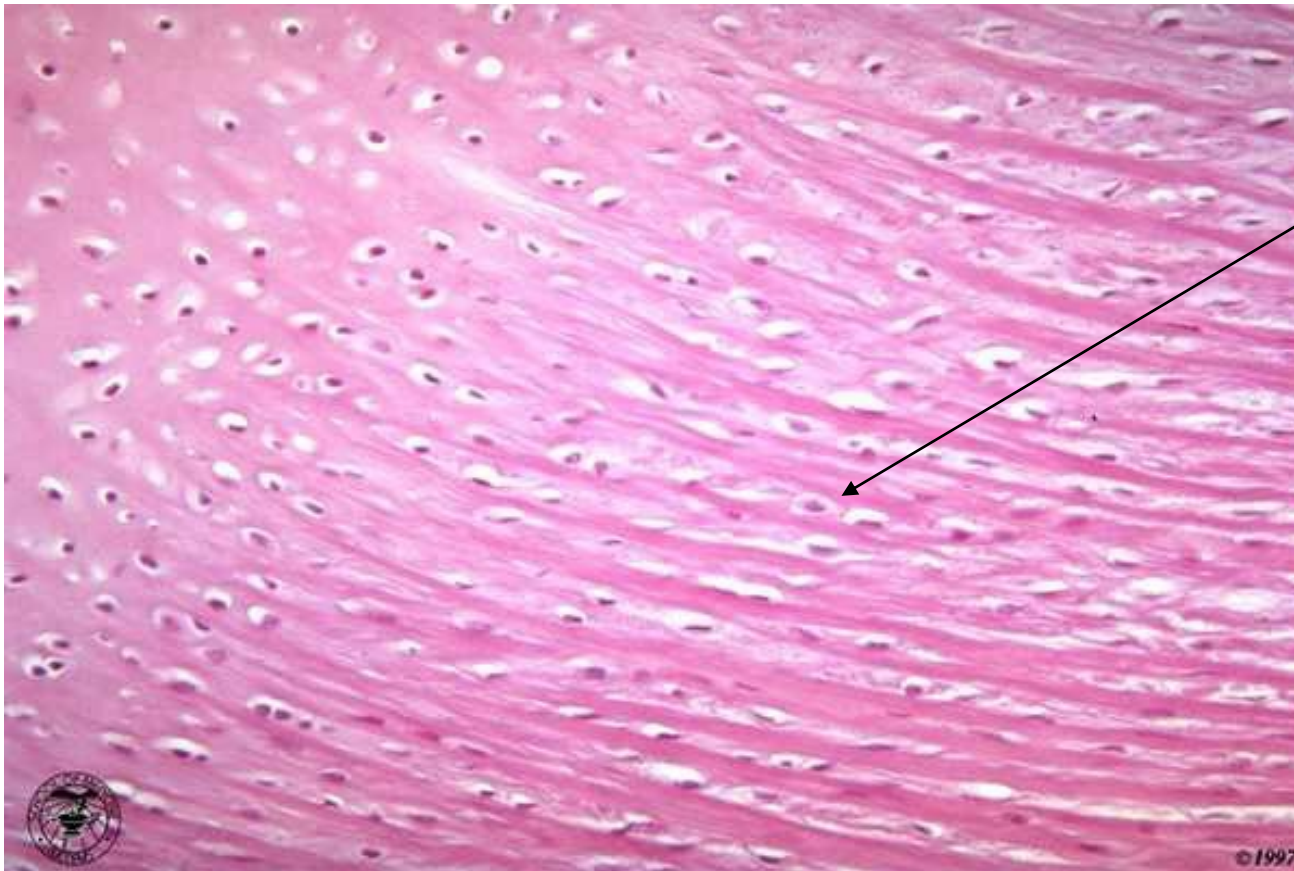# Elastická chrupavka



**BEZ izogenetických skupin**

**chondrocyty rozptýlené**

# Vazivová chrupavka


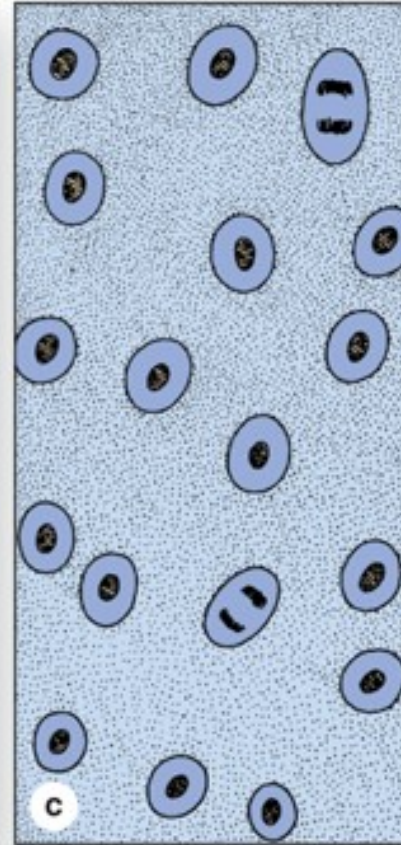

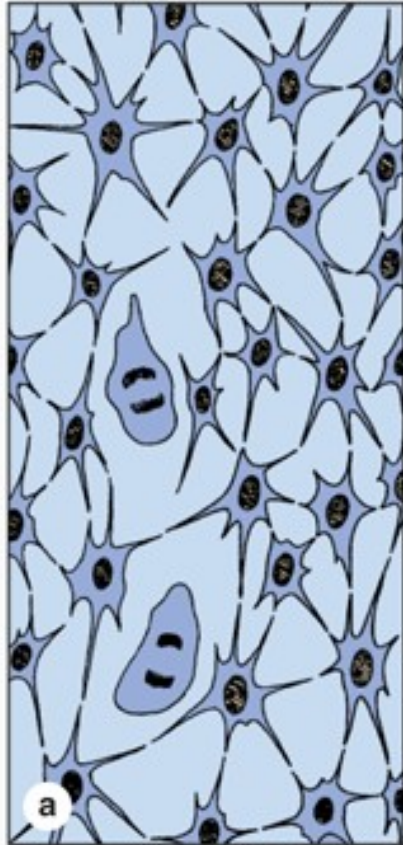


**chondrocyty v řadě**

**bez perichondria**

**podobná hustému kolagennímu  
vazivu**

# Chondrogeneze

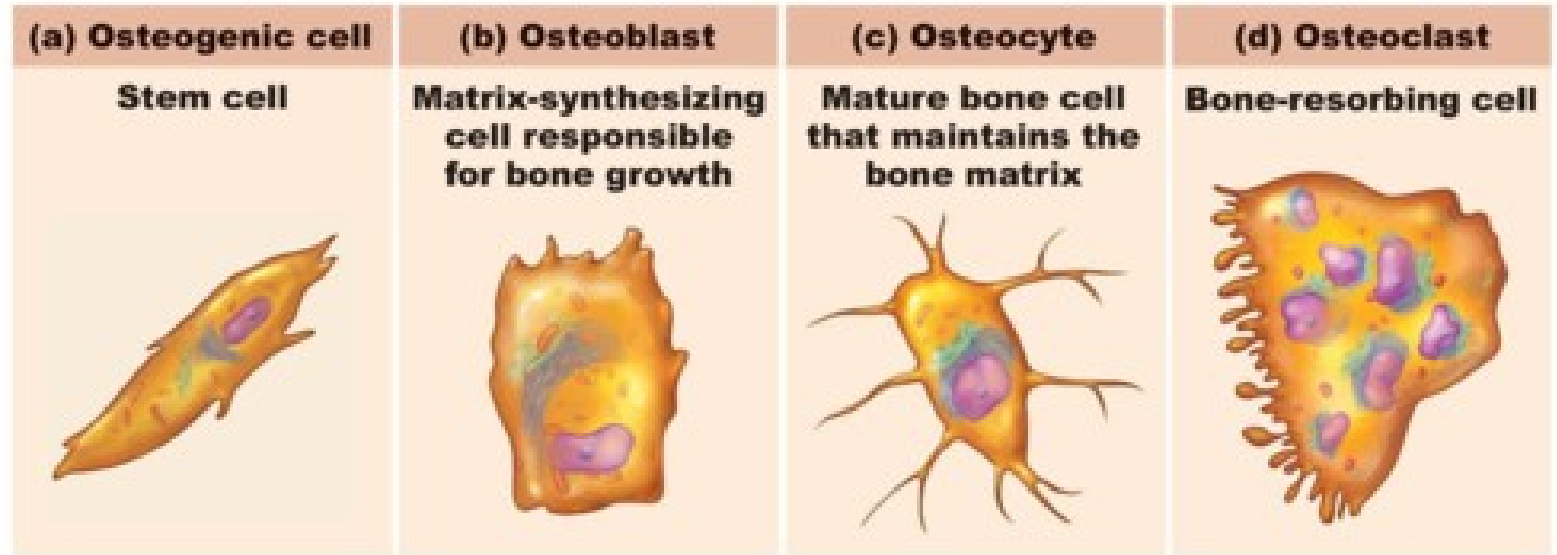


Mesenchym


Chrupavčitý blastém

Chrupavka

# Kost

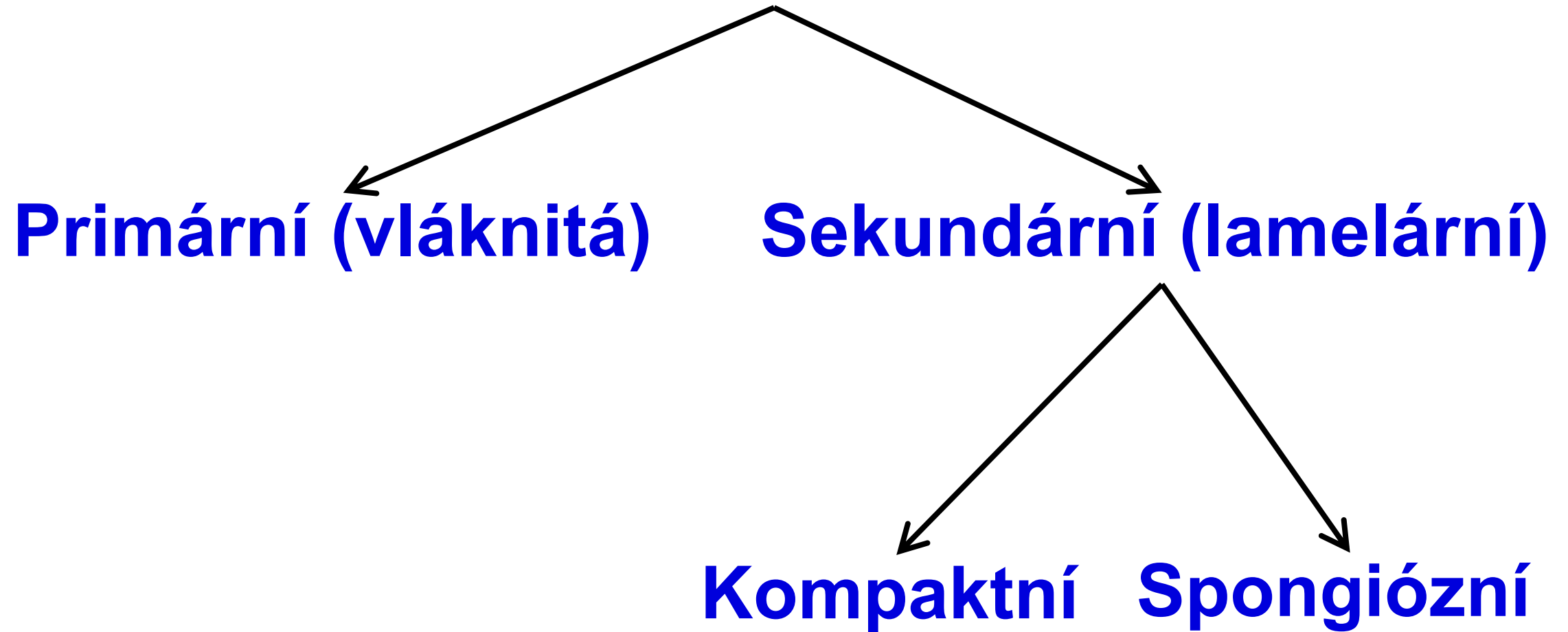


Copyright © 2010 Pearson Education, Inc.



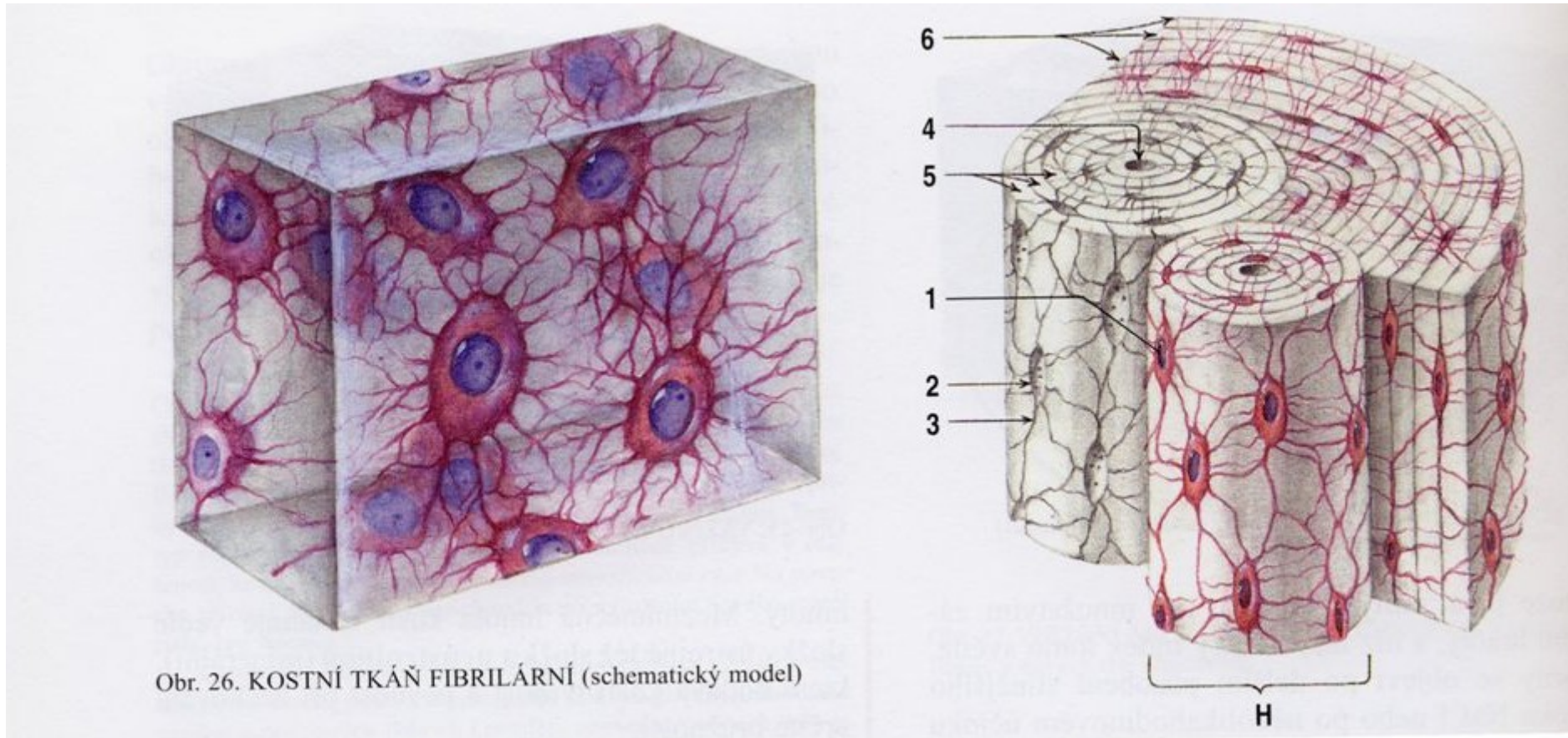
## hydroxyapatitové krystaly

# Kost

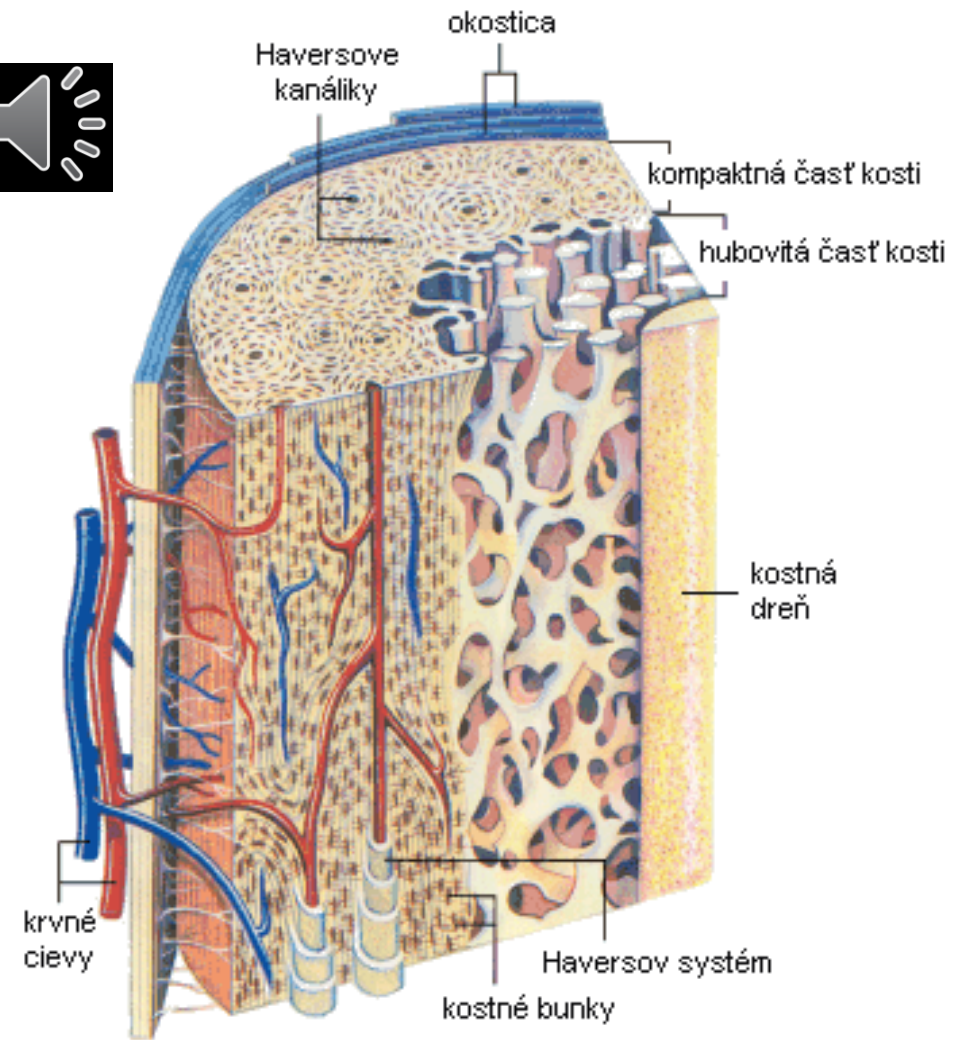





# Vláknitá vs. lamelární kost



# Kompakta vs. spongióza



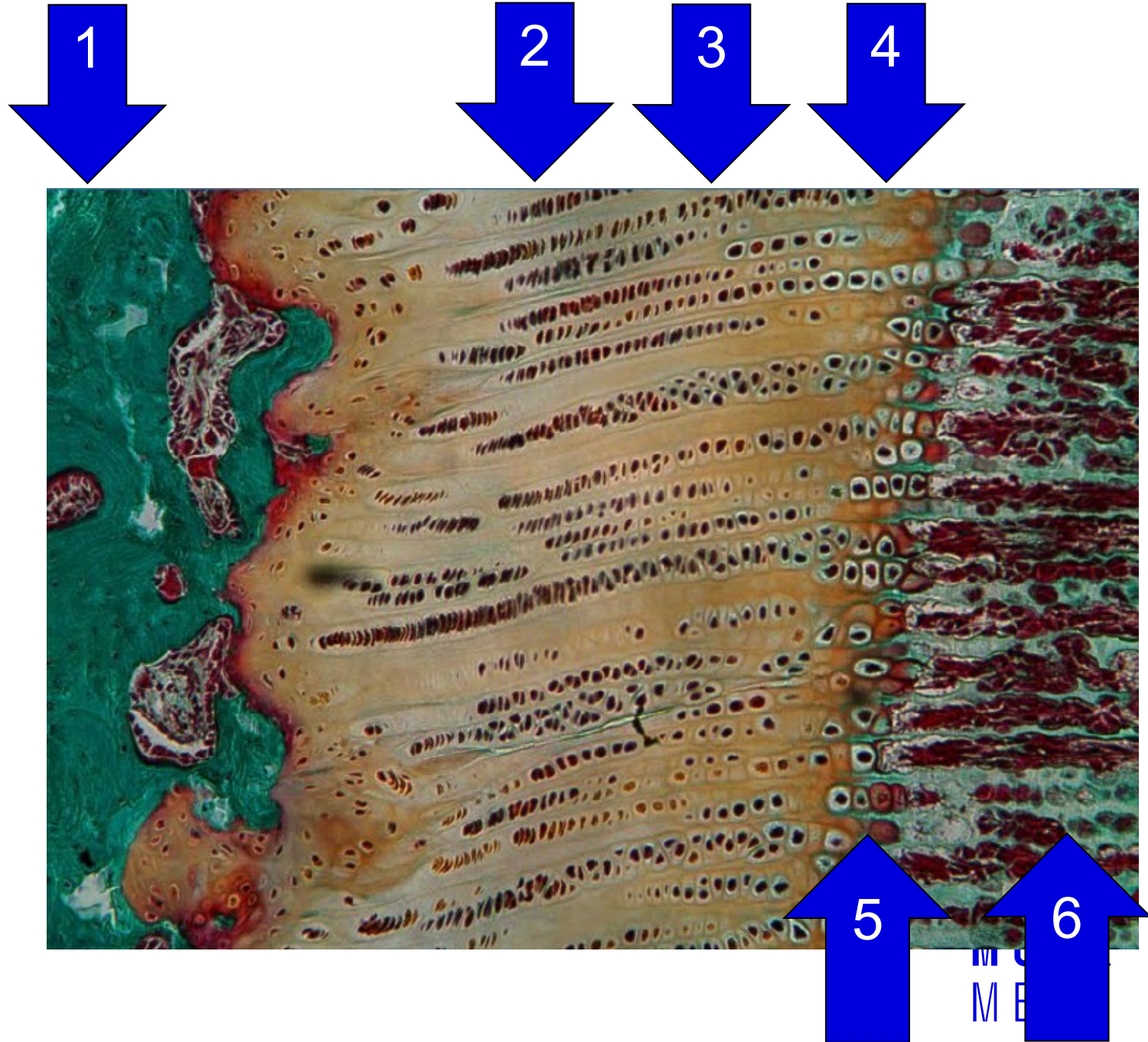
Obr. Stavba dlhej kosti

# Osifikace



## Zonace růstové ploténky

1. Rezervní chrupavka
2. Proliferace
3. Hypertrofie
4. Kalcifikace
5. Eroze
6. Kost





**MUNI** Department  
of Histology  
and Embryology  
**MED**

**Klára Dolinová**

**Yoni Solomonov**

**Peter Staňo**

**Petr Vaňhara**