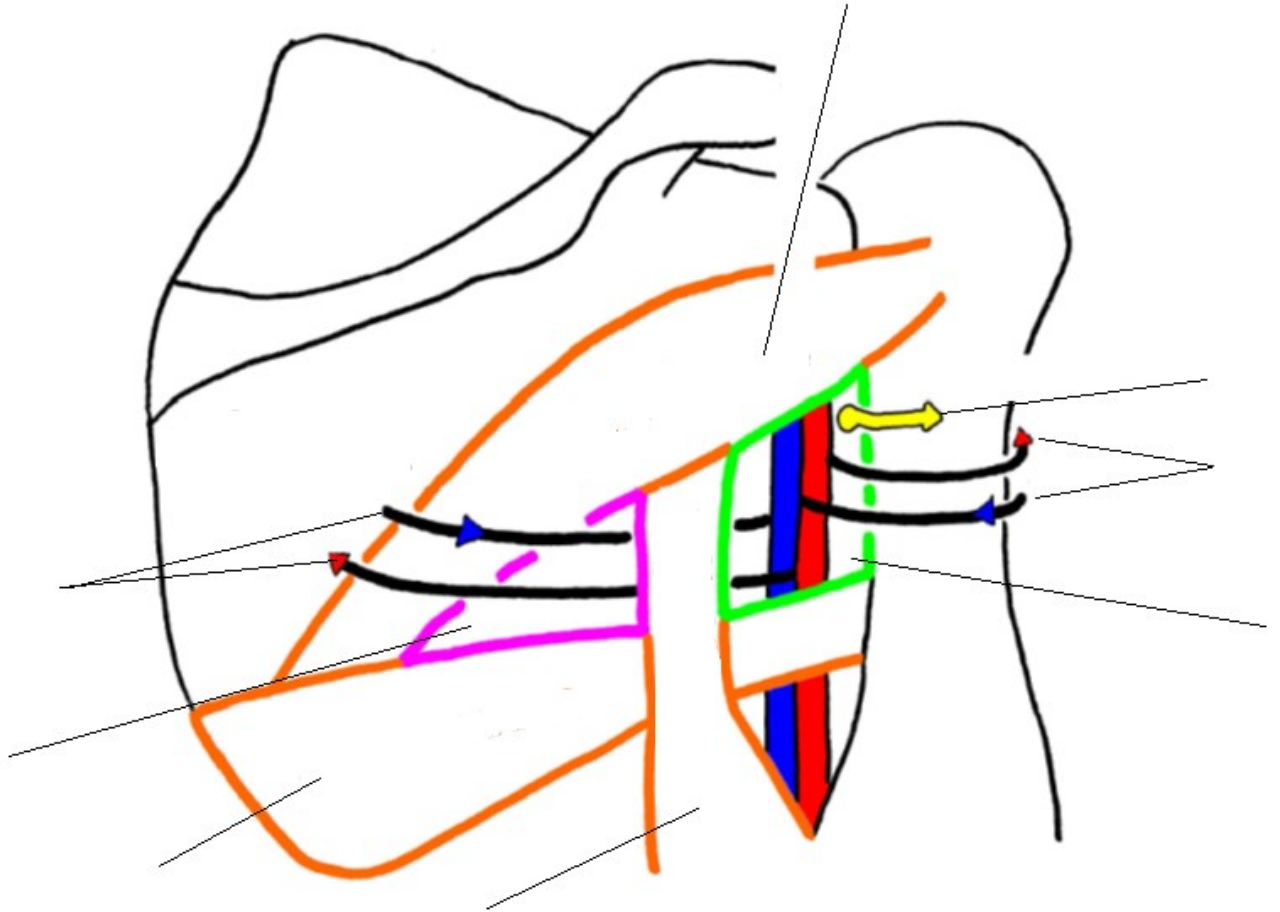
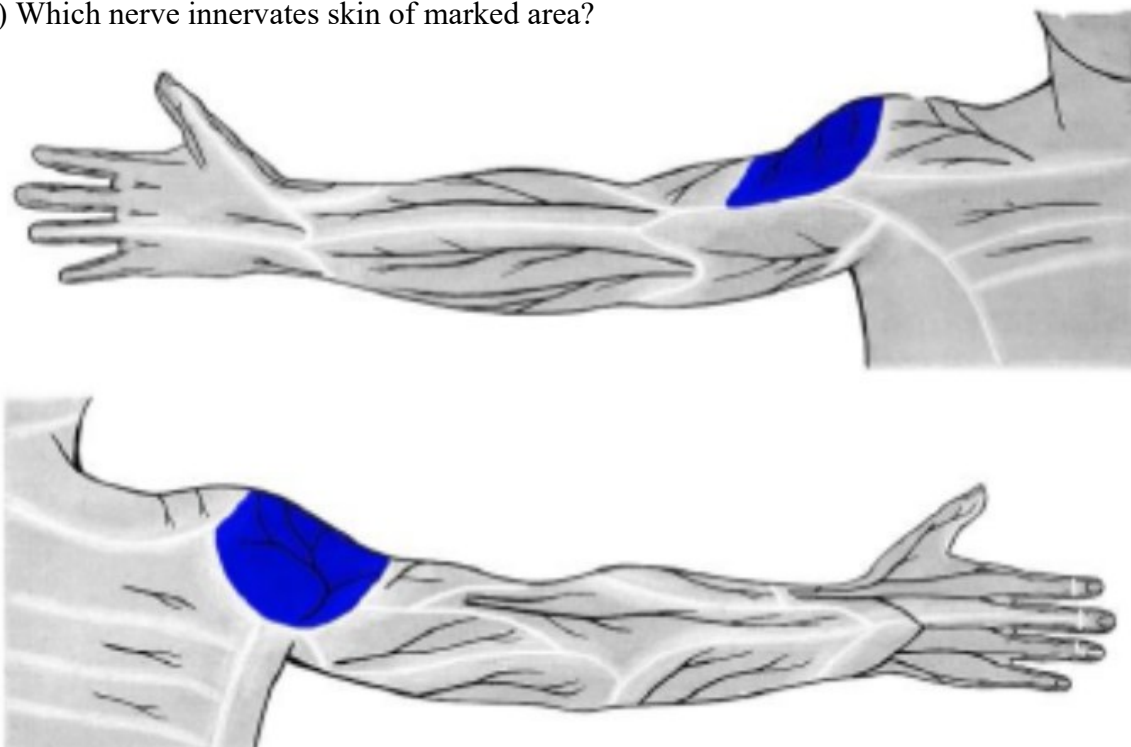


## THE REGIONAL ANATOMY

1) Describe this picture:

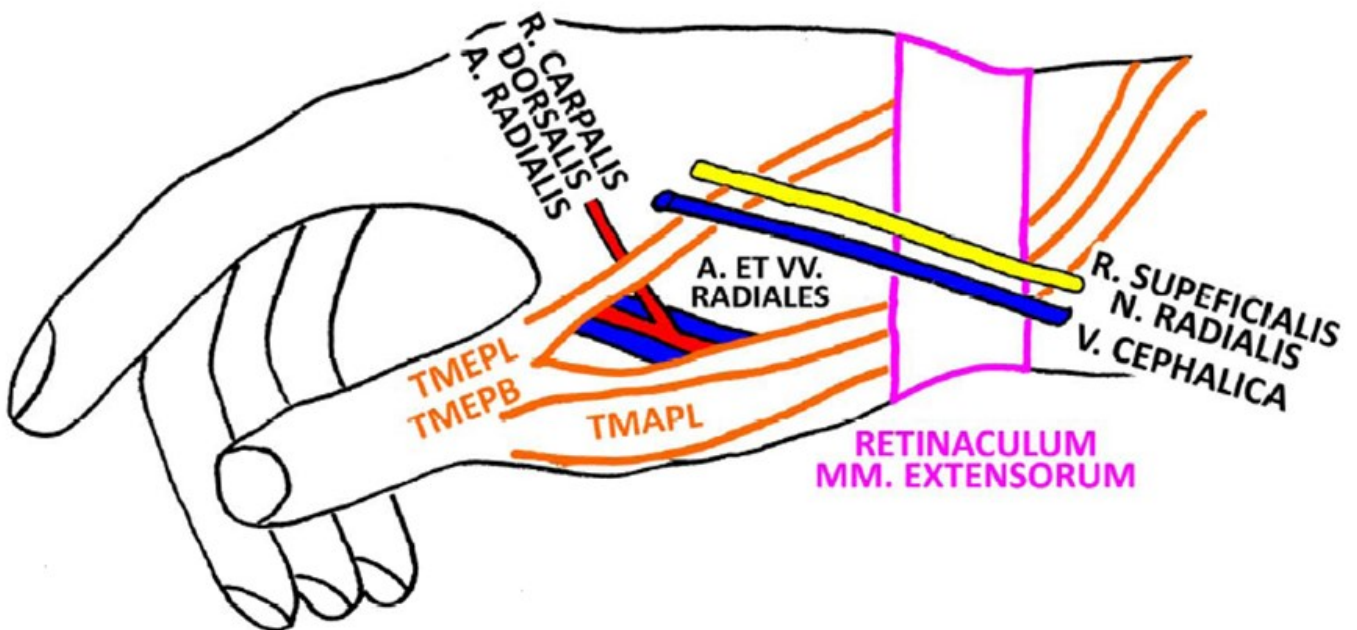


2) Which nerve innervates skin of marked area?



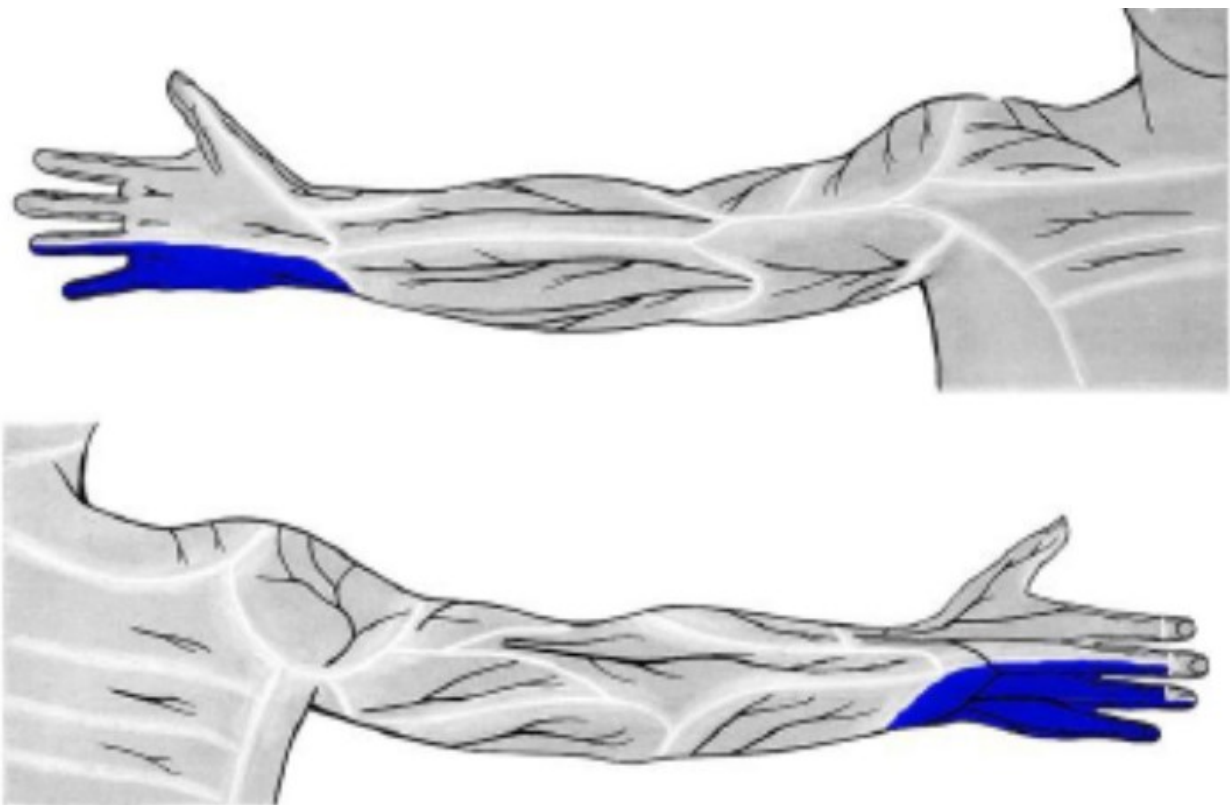
3) Explain the abbreviations:

## FOVEOLA RADIALIS DX.

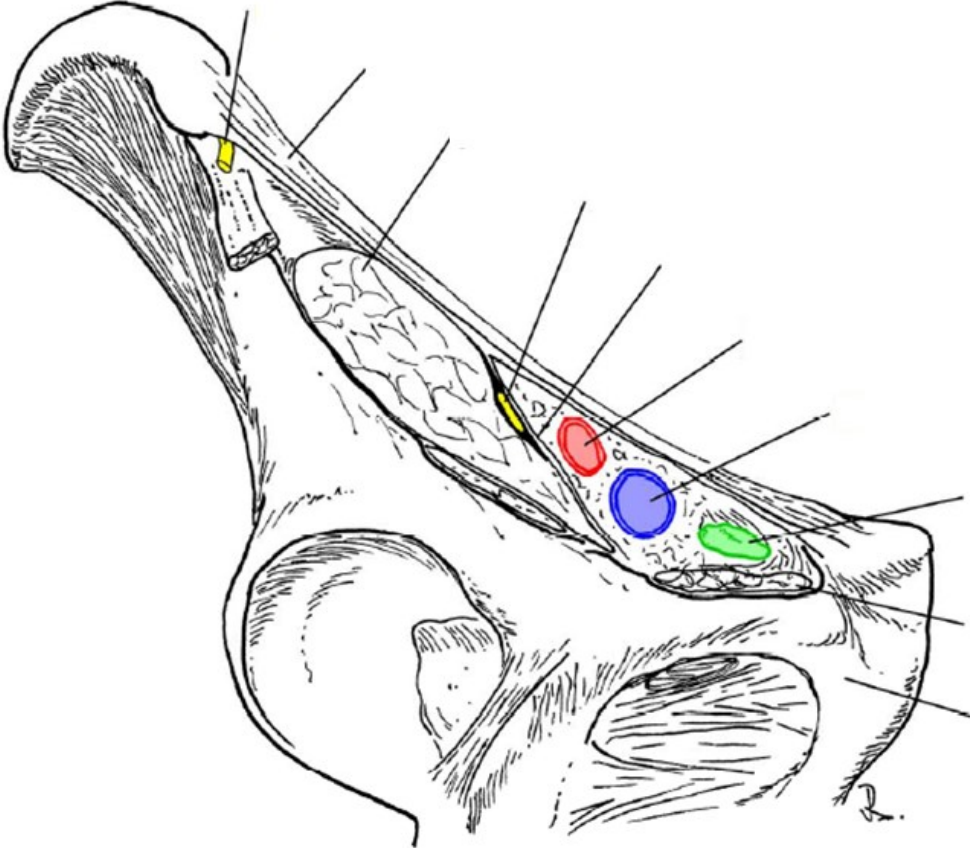


TMEPL =  
TMEPB =  
TMAPL =

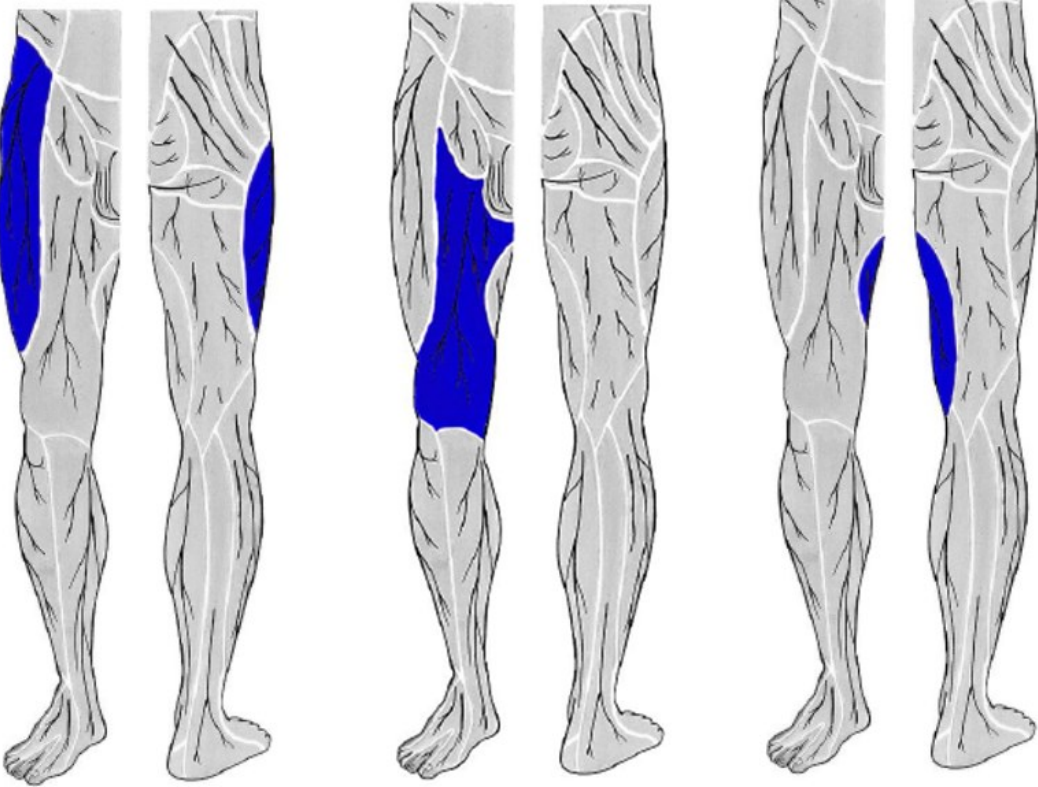
4) Which nerve innervates skin of the marked area?



5) Describe the picture:



6) Which nerves innervate skin of marked areas of the thigh?

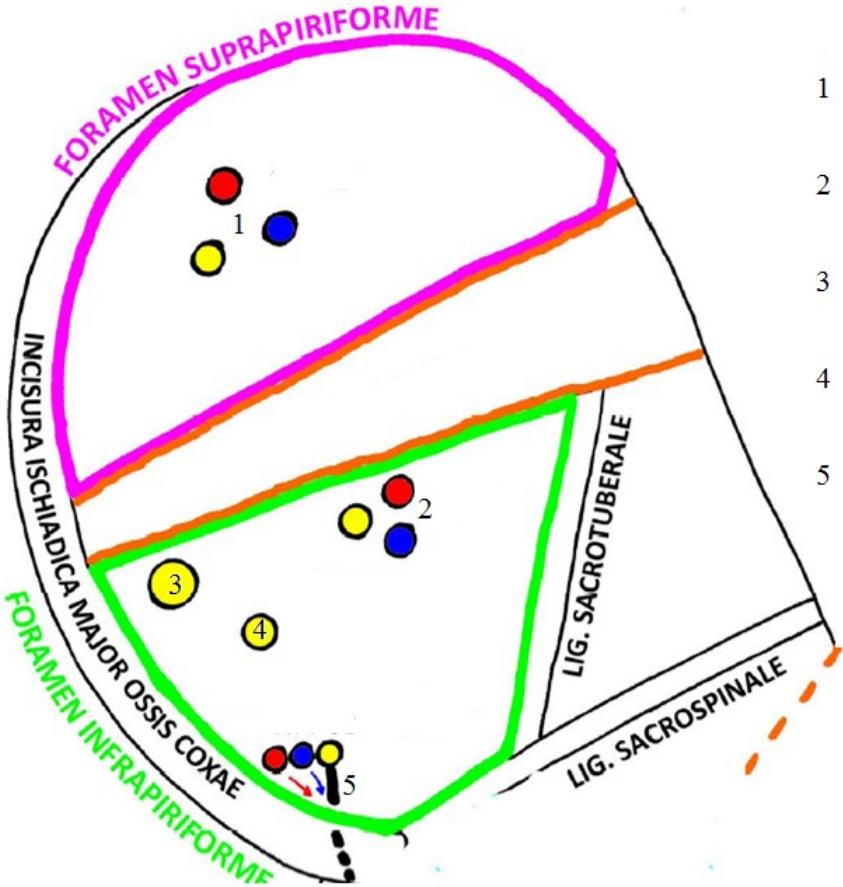


1 \_\_\_\_\_

2 \_\_\_\_\_

3 \_\_\_\_\_

7) Describe the picture:



8) Describe the picture:

