

5) Which is the longest branch of n. femoralis? _____

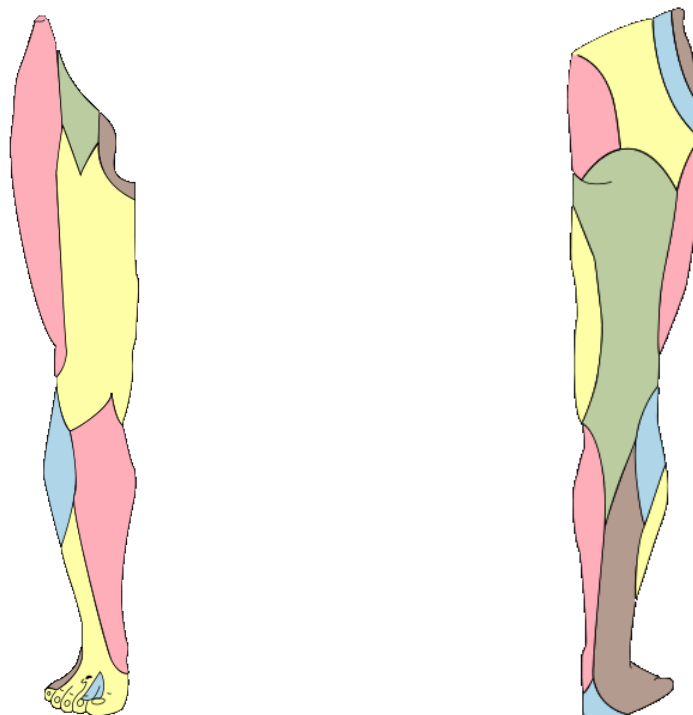
Please draw its course.



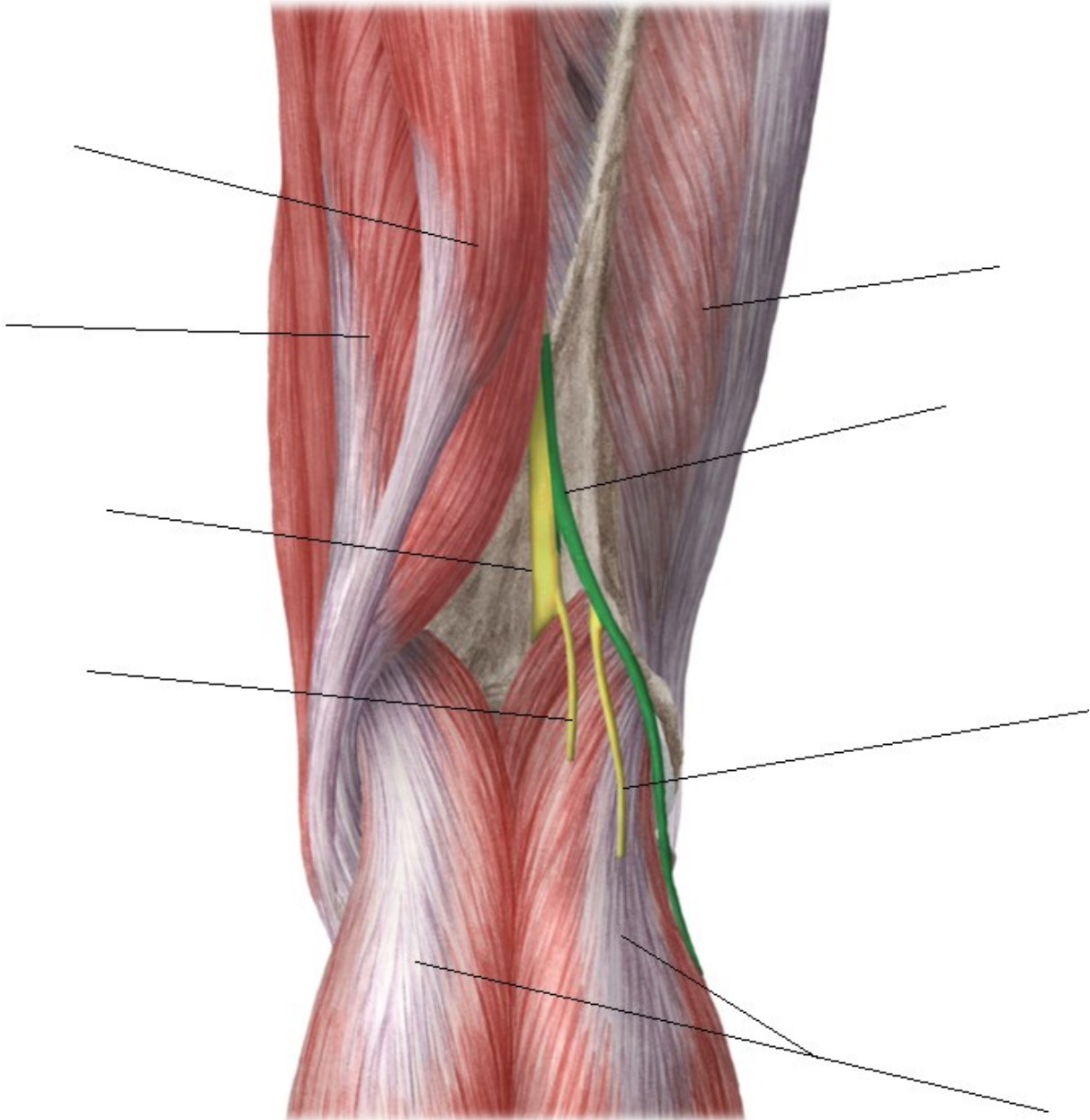
6) Write all muscles (6), which are innervated by nervus obturatorius:

7) Which nerves (of sacral plexus) are passing through foramen suprapiriforme?

8) Which area is innervated by n. cutaneus femoris posterior and which one by n. cutaneus femoris lateralis?



9) Describe the picture.



10) Which nerve is the marked area innervated by:

