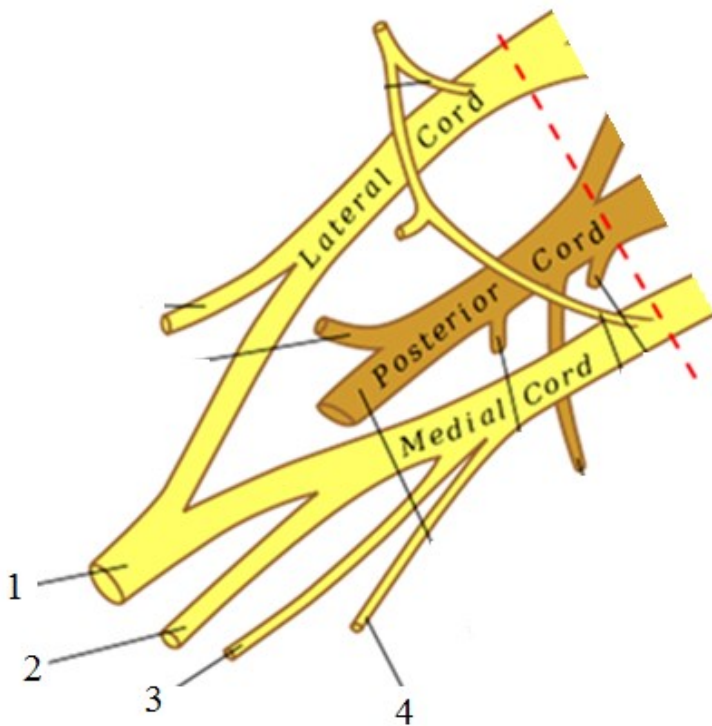


THE BRACHIAL PLEXUS

1) Musculus brachialis is innervated by n. _____, which pierces through m. _____.

2) The above mentioned nerve continues onto the forearm as n. _____, which is purely _____.



3) Describe the scheme of fasciculus medialis:



- 1 _____
- 2 _____
- 3 _____
- 4 _____

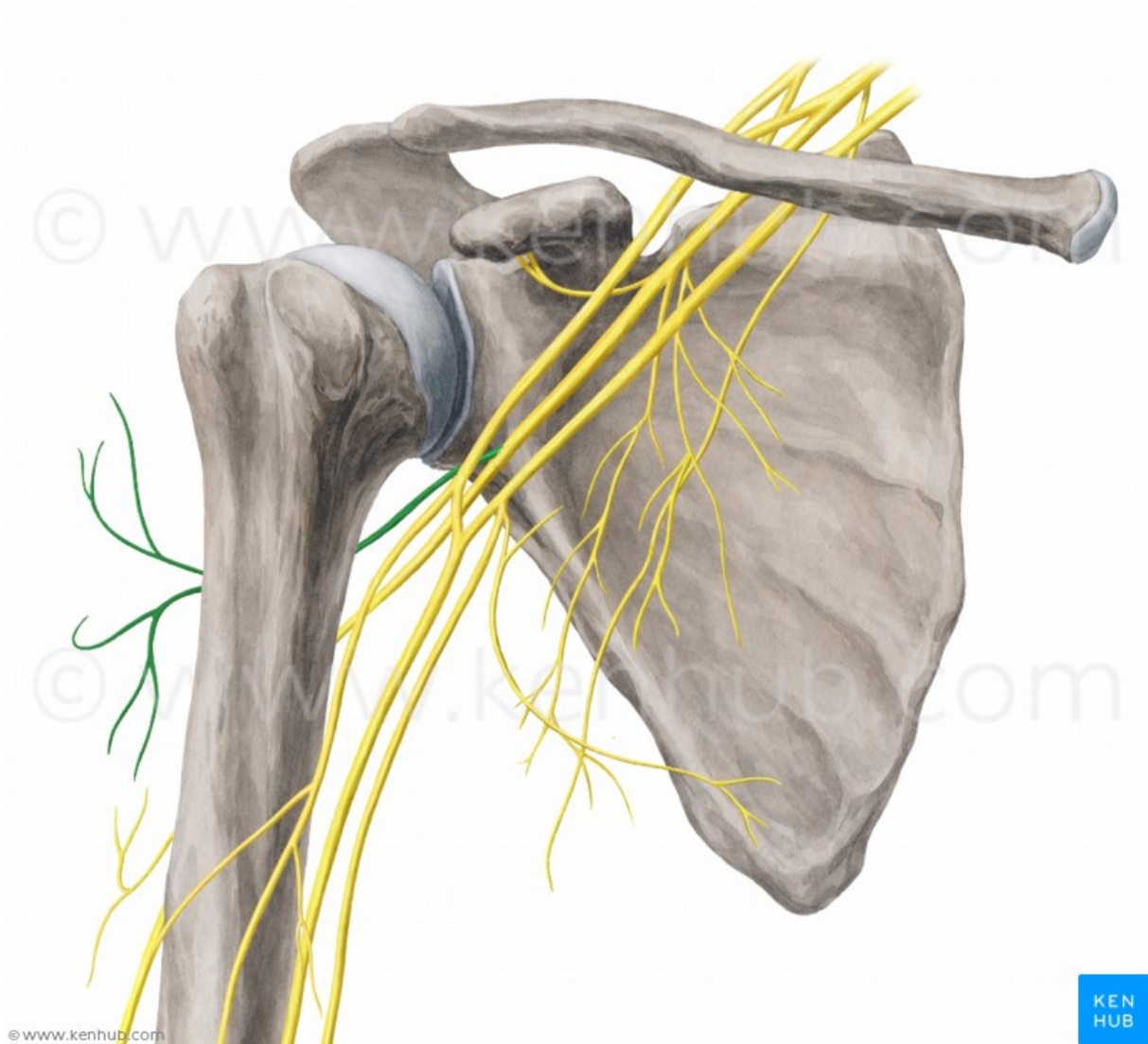
4) Write at least three nerves, which arise from pars supraclavicularis plexus brachialis.

5) Draw schematically the sensory innervation of the palm and dorsum manus:



5) Which are the terminal branches of nervus radialis?

6) Mark nervus axillaris.



7) Musculus adductor pollicis is innervated by _____.

Musculus abductor pollicis brevis is innervated by _____.

Musculi interossei palmares are innervated by _____.

Musculi interossei dorsales are innervated by _____.