

THE CRANIAL NERVES (*nervi craniales*)

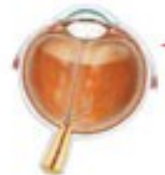- I. *Nervus olfactorius* – the olfactory nerve**
- II. *Nervus opticus* – the optic nerve**
- III. *Nervus oculomotorius* – the oculomotor nerve**
- IV. *Nervus trochlearis* – the trochlear nerve**
- V. *Nervus trigeminus* – the trigeminal nerve**
- VI. *Nervus abducens* – the abducens nerve**
- VII. *Nervus facialis* – the facial nerve**
- VIII. *Nervus vestibulocochlearis* – the vestibulocochlear nerve**
- IX. *Nervus glossopharyngeus* – the glossopharyngeal nerve**
- X. *Nervus vagus* – the vagus nerve**
- XI. *Nervus accessorius* – the accessory nerve**
- XII. *Nervus hypoglossus* – the hypoglossal nerve**



THE CRANIAL NERVES (*nervi craniales*)

— sensory fibres
— motor fibres

Optic (II)
sensory: eye

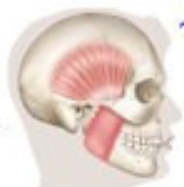

Trochlear (IV)
motor: superior oblique muscle

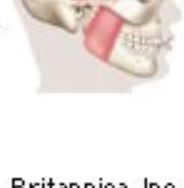
Abducent (VI)
motor: external rectus muscle



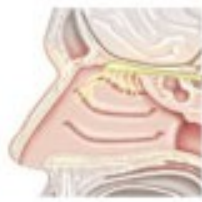Oculomotor (III)
motor: all eye muscles except those supplied by IV and VI



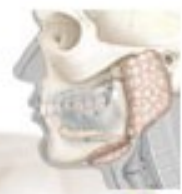Trigeminal (V)
sensory: face, sinuses, teeth, etc.
motor: muscles of mastication



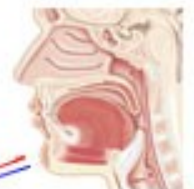Olfactory (I)
sensory: nose



Intermediate motor: submaxillary and sublingual gland
sensory: anterior part of tongue and soft palate



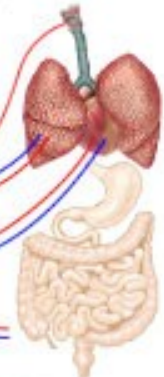Glossopharyngeal (IX)
motor: pharyngeal musculature
sensory: posterior part of tongue, tonsil, pharynx



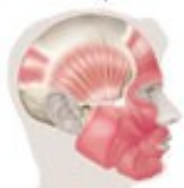Vestibulocochlear (VIII)
sensory: inner ear



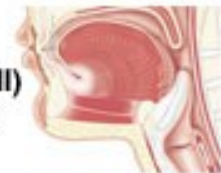Vagus (X)
motor: heart, lungs, bronchi, gastrointestinal tract
sensory: heart, lungs, bronchi, trachea, larynx, pharynx, gastrointestinal tract, external ear



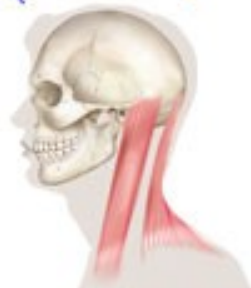Facial (VII)
motor: muscles of the face



Hypoglossal (XII)
motor: muscles of the tongue



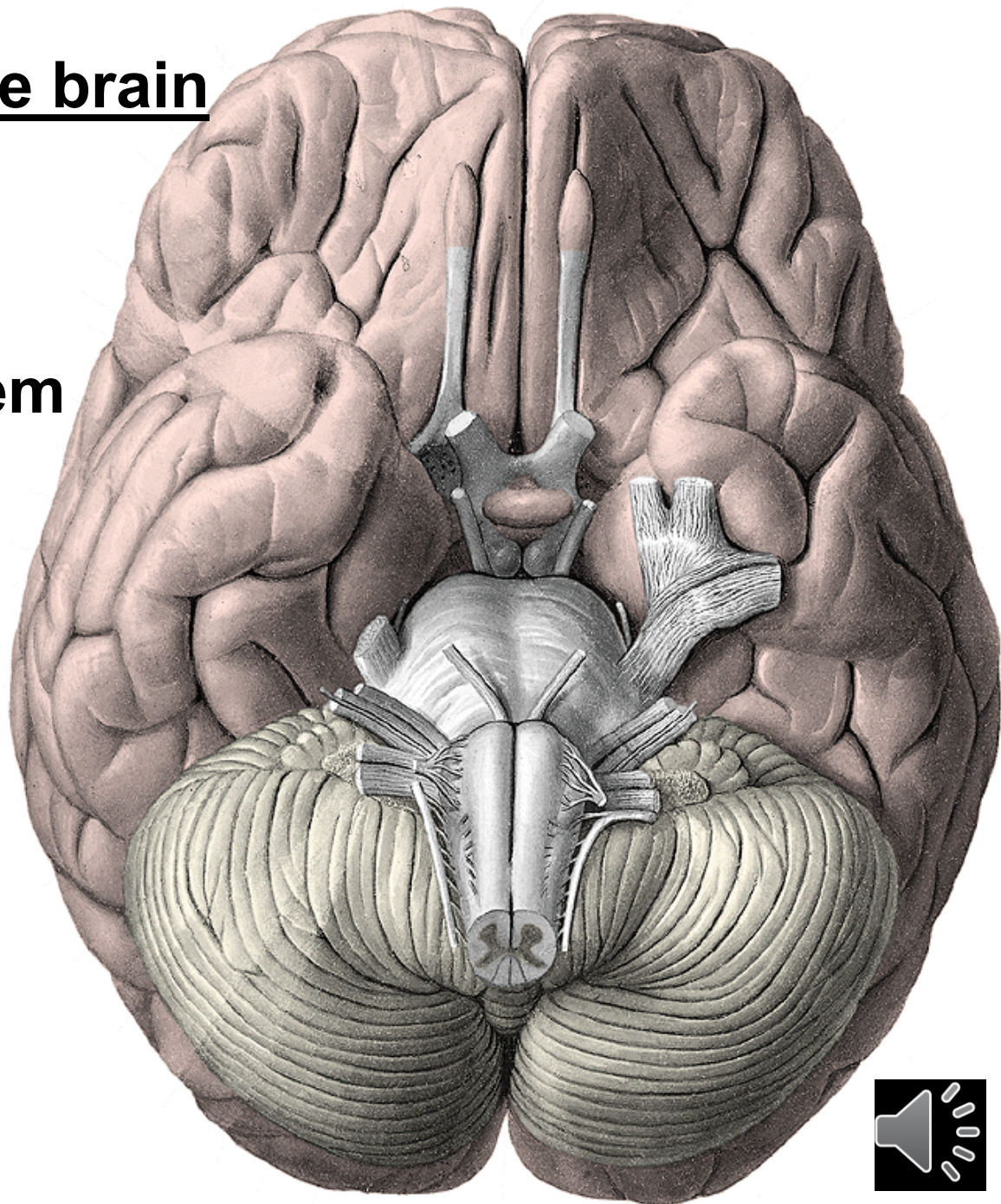
Accessory (XI)
motor: sternocleidomastoid, trapezius



The outputs from the brain

- I. – the cerebrum
- II. – the diencephalon
- III.-XII. – the brainstem

IV. – dorsally !!!



Cranial Nerves

Olfactory bulb
Olfactory tract

Optic tract

Vestibulo-cochlear (VIII)

Hypoglossal (XII)

Vagus (X)

Olfactory (I)

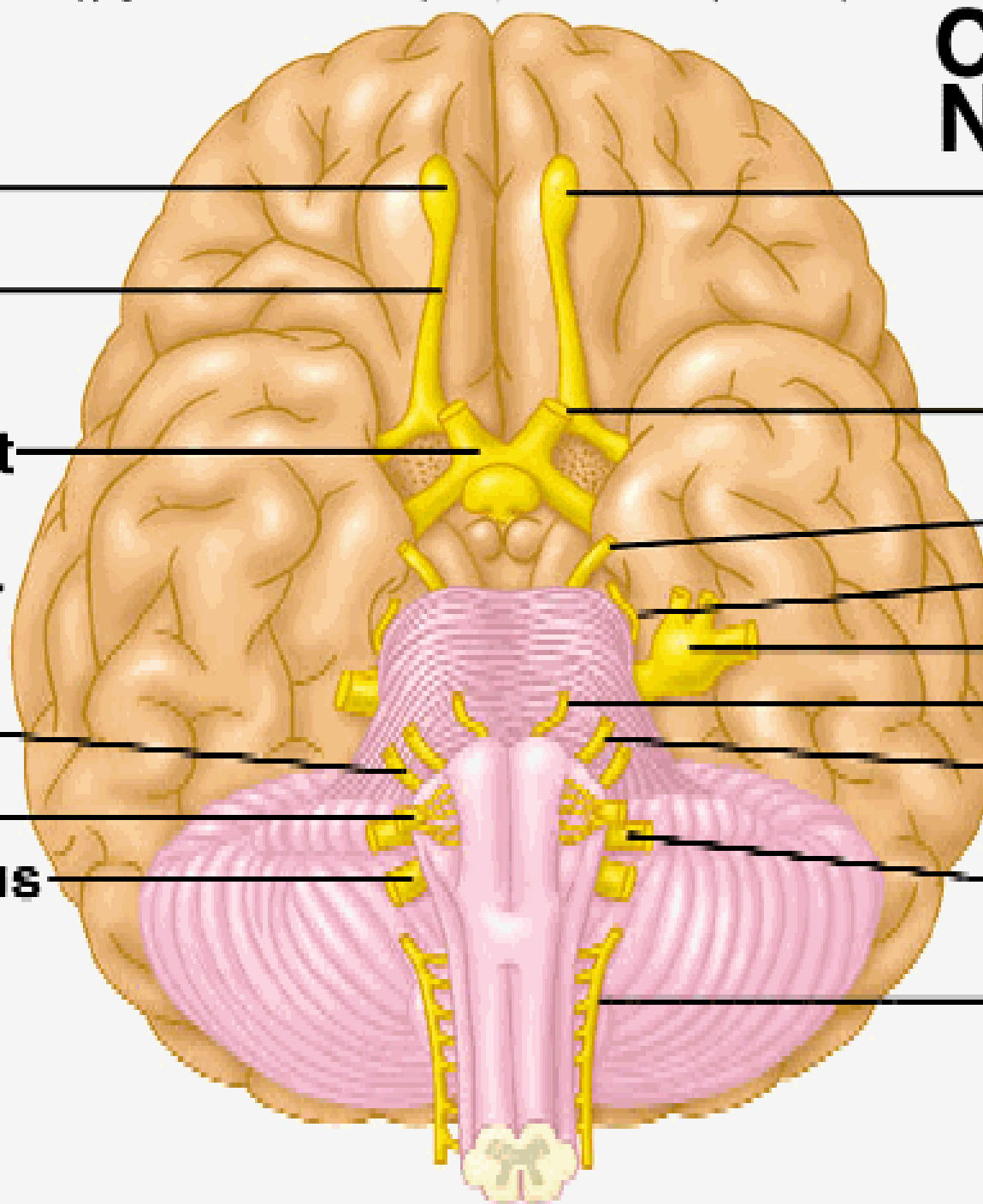
Optic (II)
Oculomotor (III)

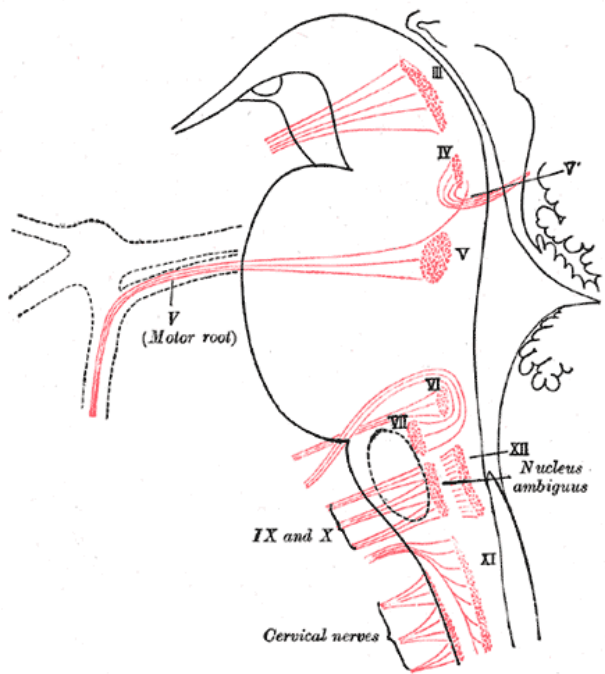
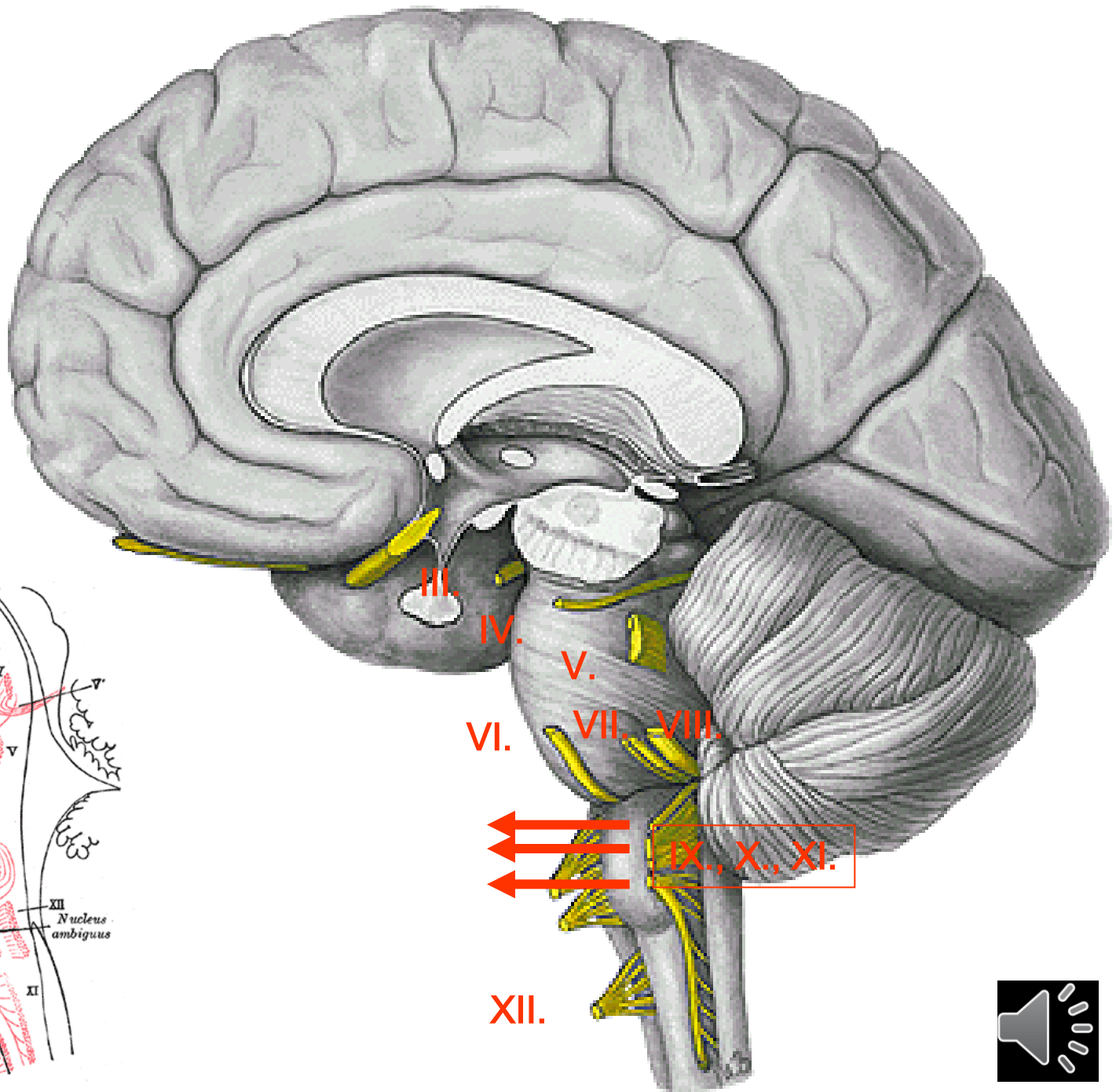
Trochlear (IV)
Trigeminal (V)
Abducens (VI)

Facial (VII)

Glossopharyngeal (IX)

Accessory (XI)

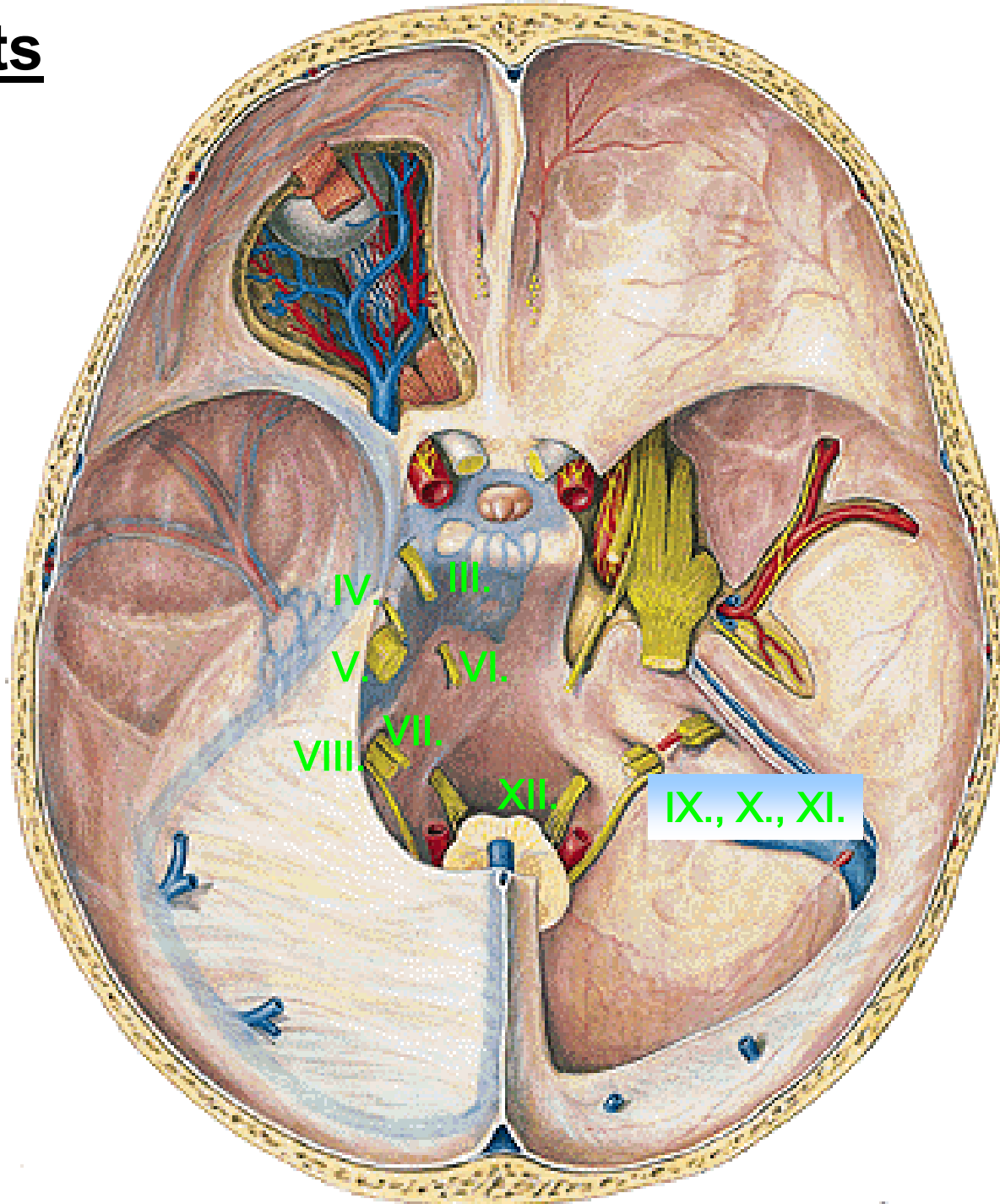




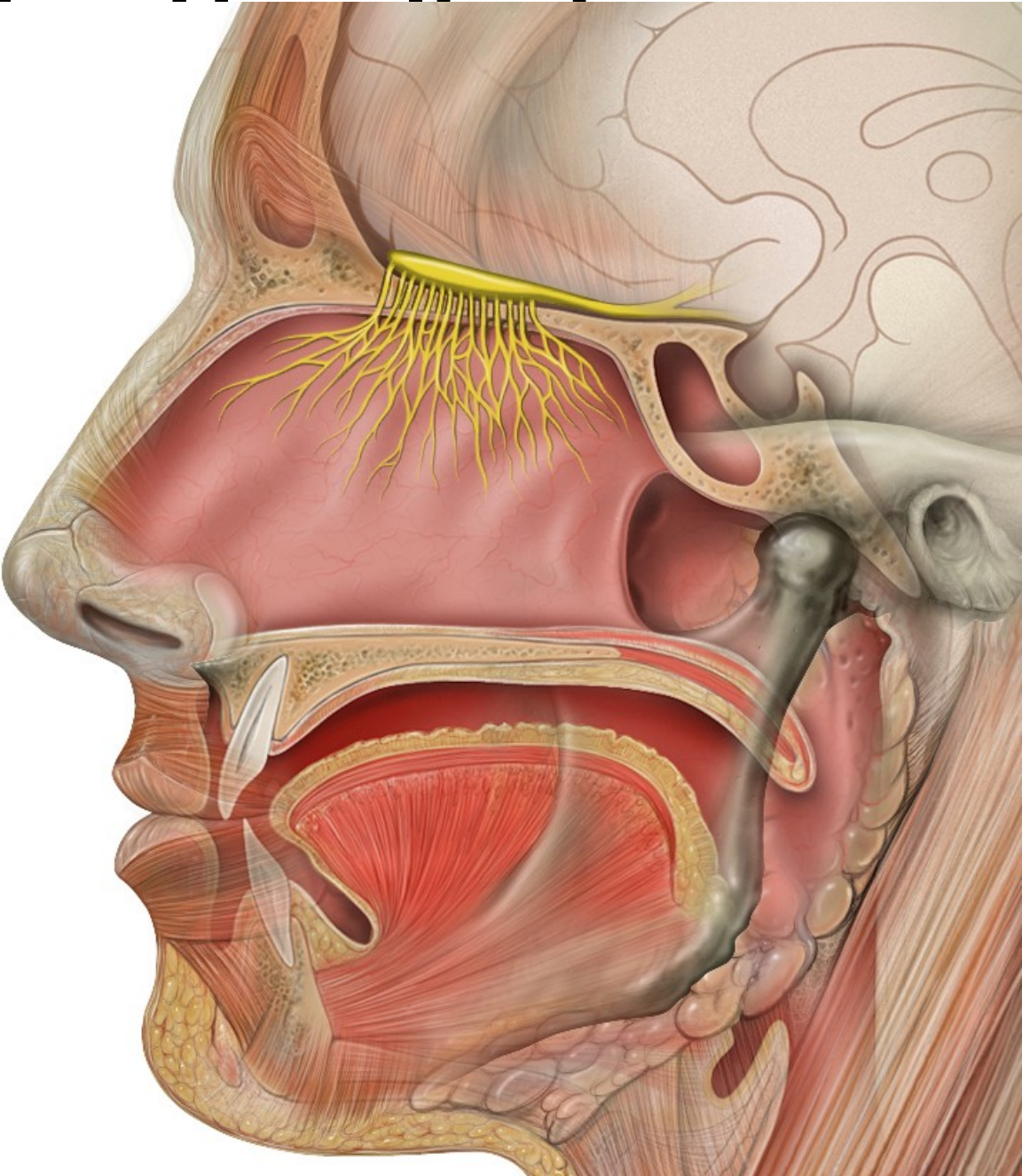
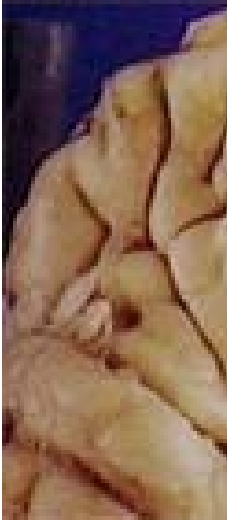III.
IV.
V.
VI.
VII. VIII.
IX., X., XI.
XII.



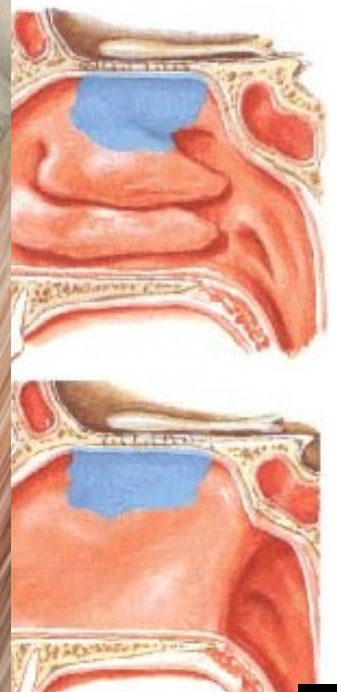
Te outputs
from the
skull



- special
- cavitas
- Superior
- nasalis



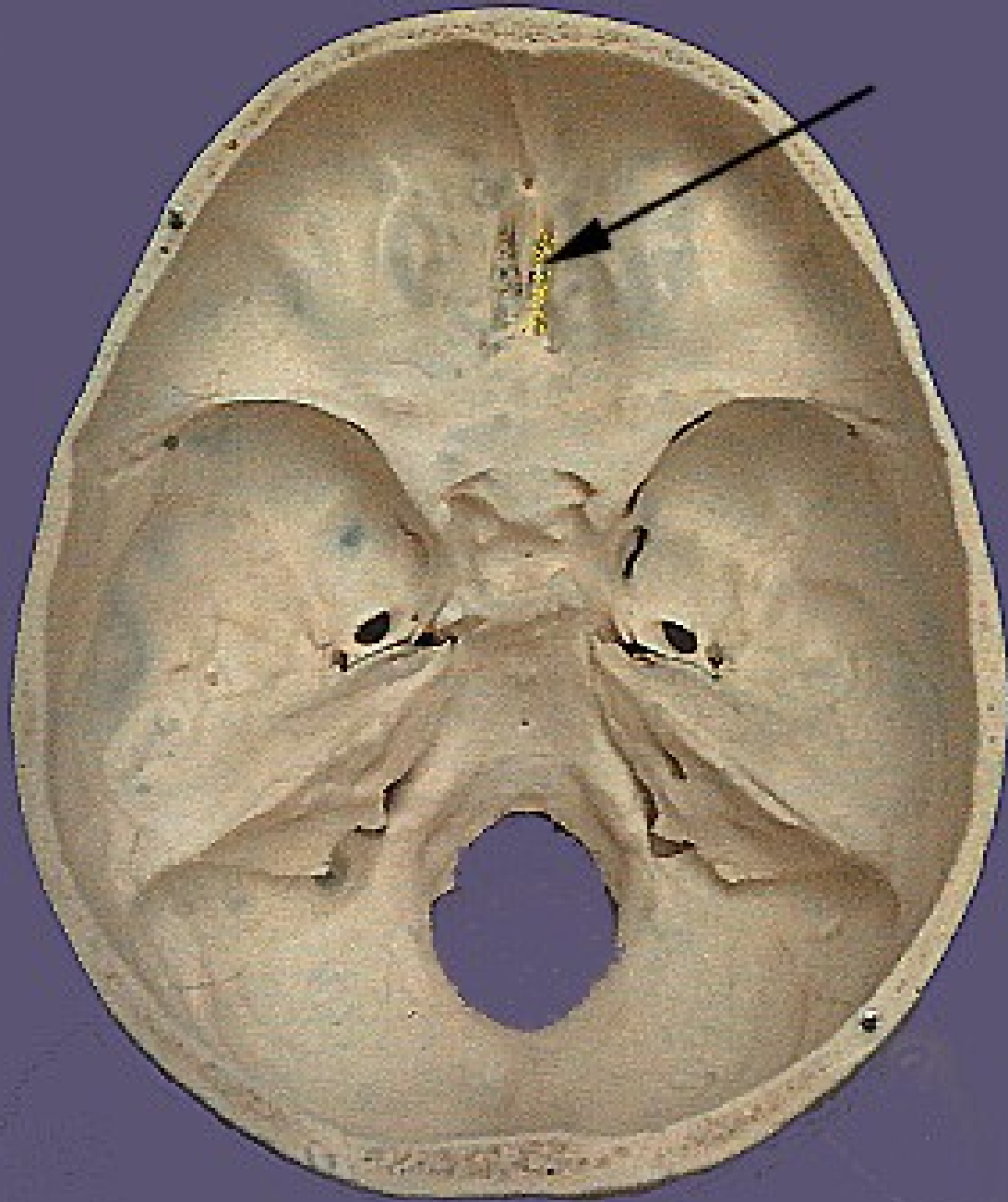
ctory tract
 ni anterior
 concha
 n



The function
sensory
 • it carries
 CNS

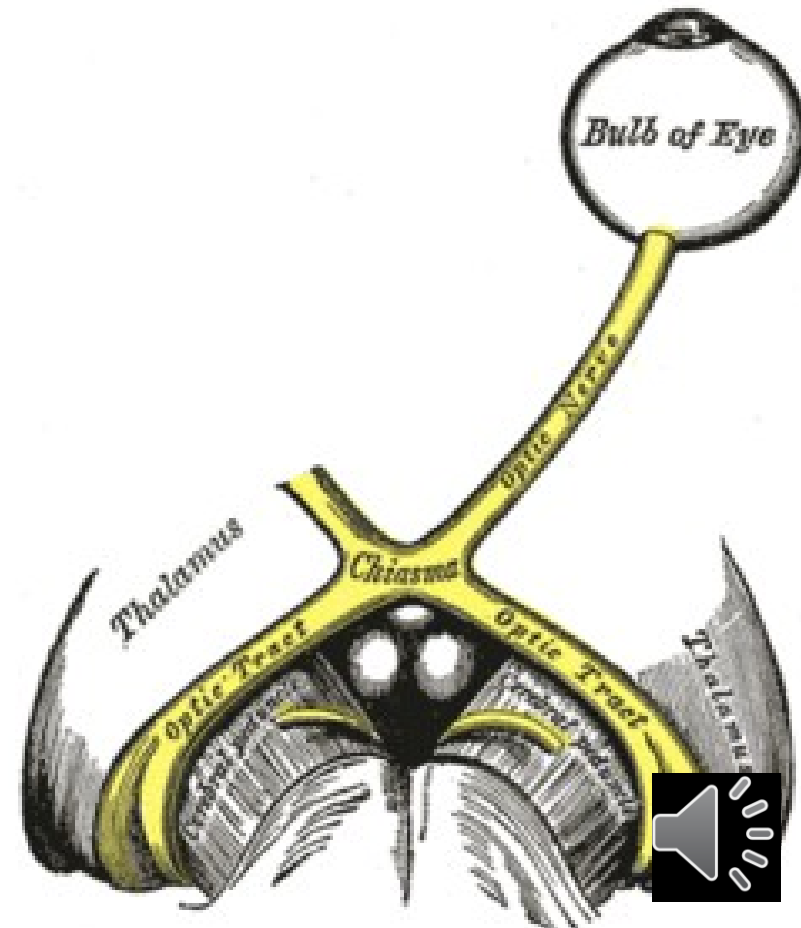
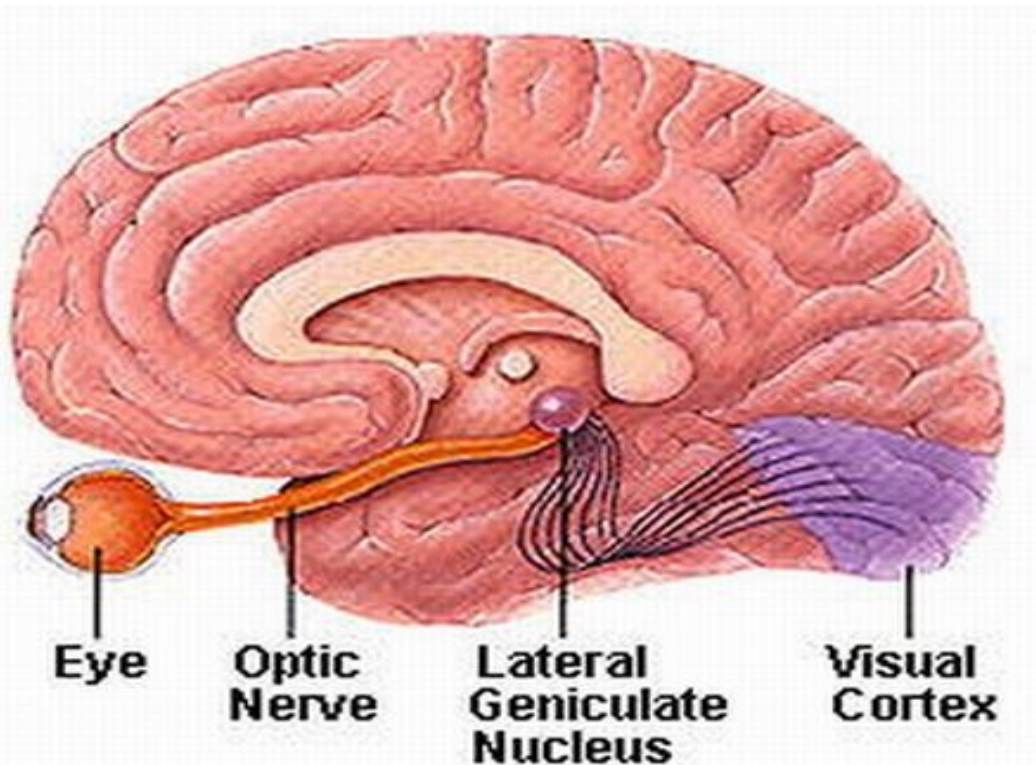
otor into t





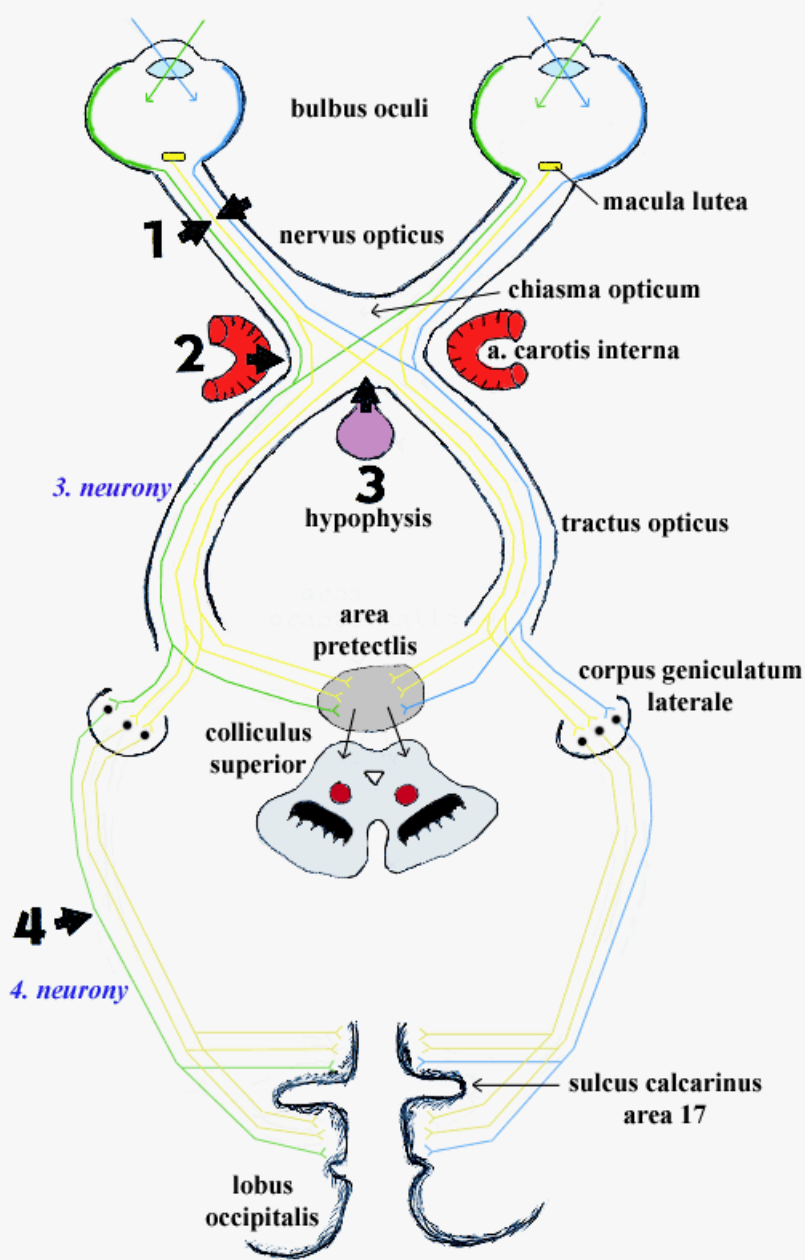
II. = The optic nerve

- It hasn't the nuclei— centre is in the occipital lobe
- special **sensory** nerve: vision, part of visual tracts
- orbita → canalis opticus → cavitas cranii media

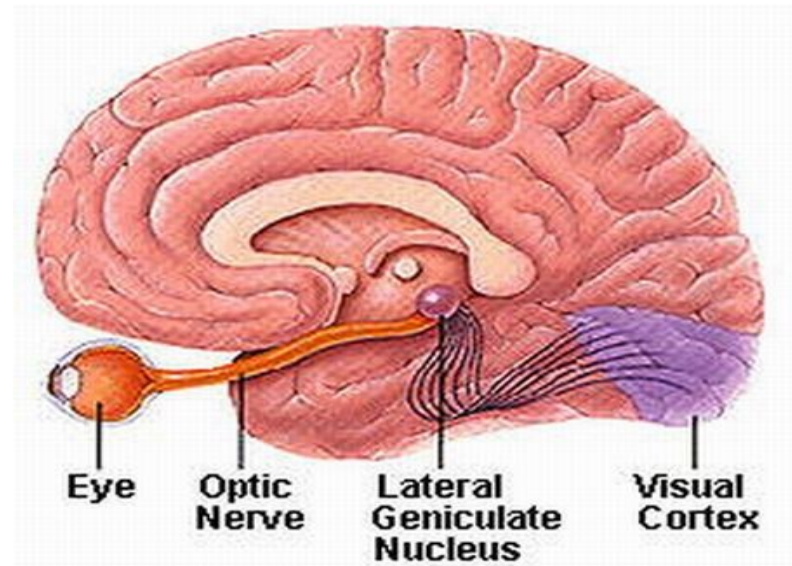


The function of the nerve *sensory*

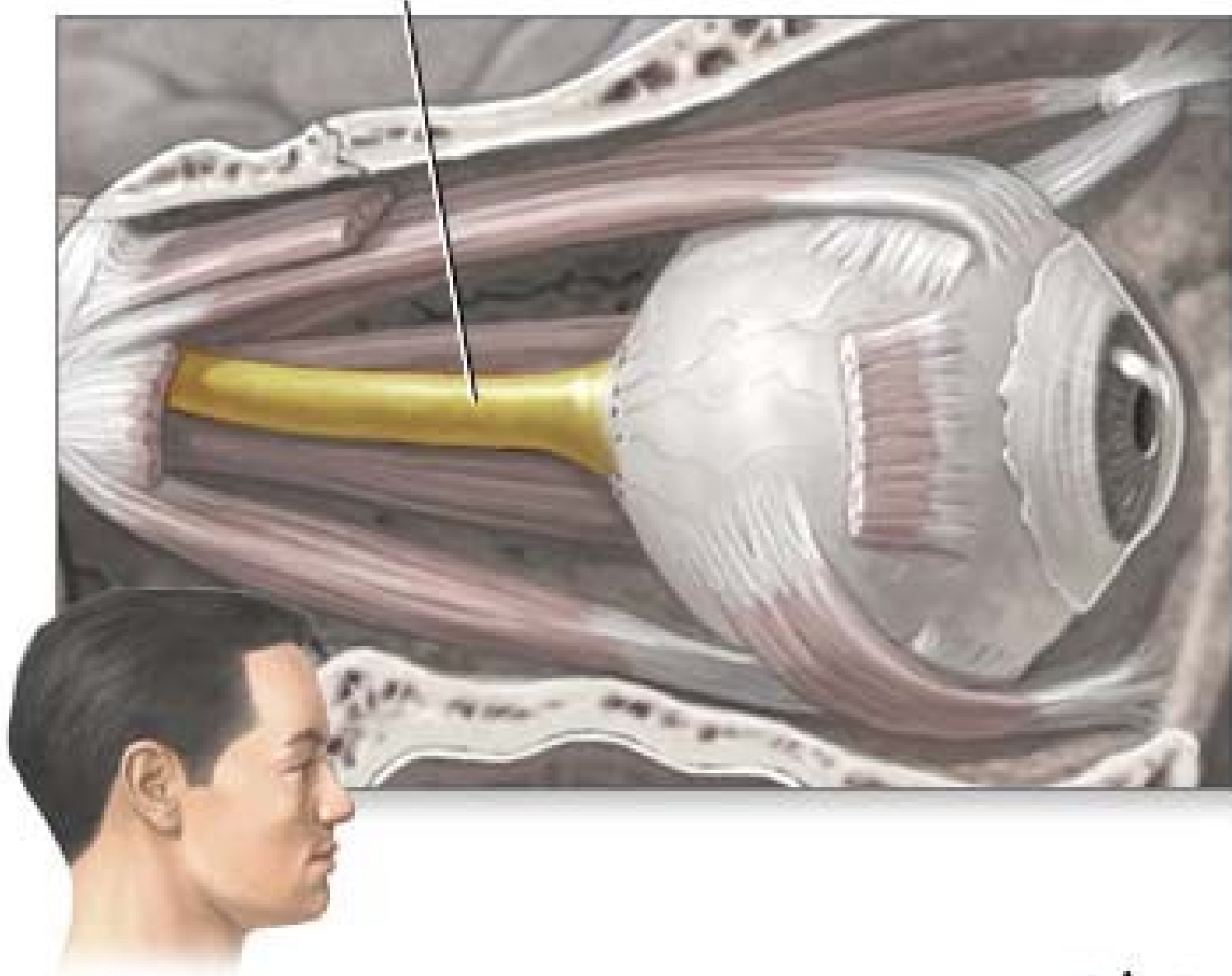
- it carries information from visual receptor into the CNS

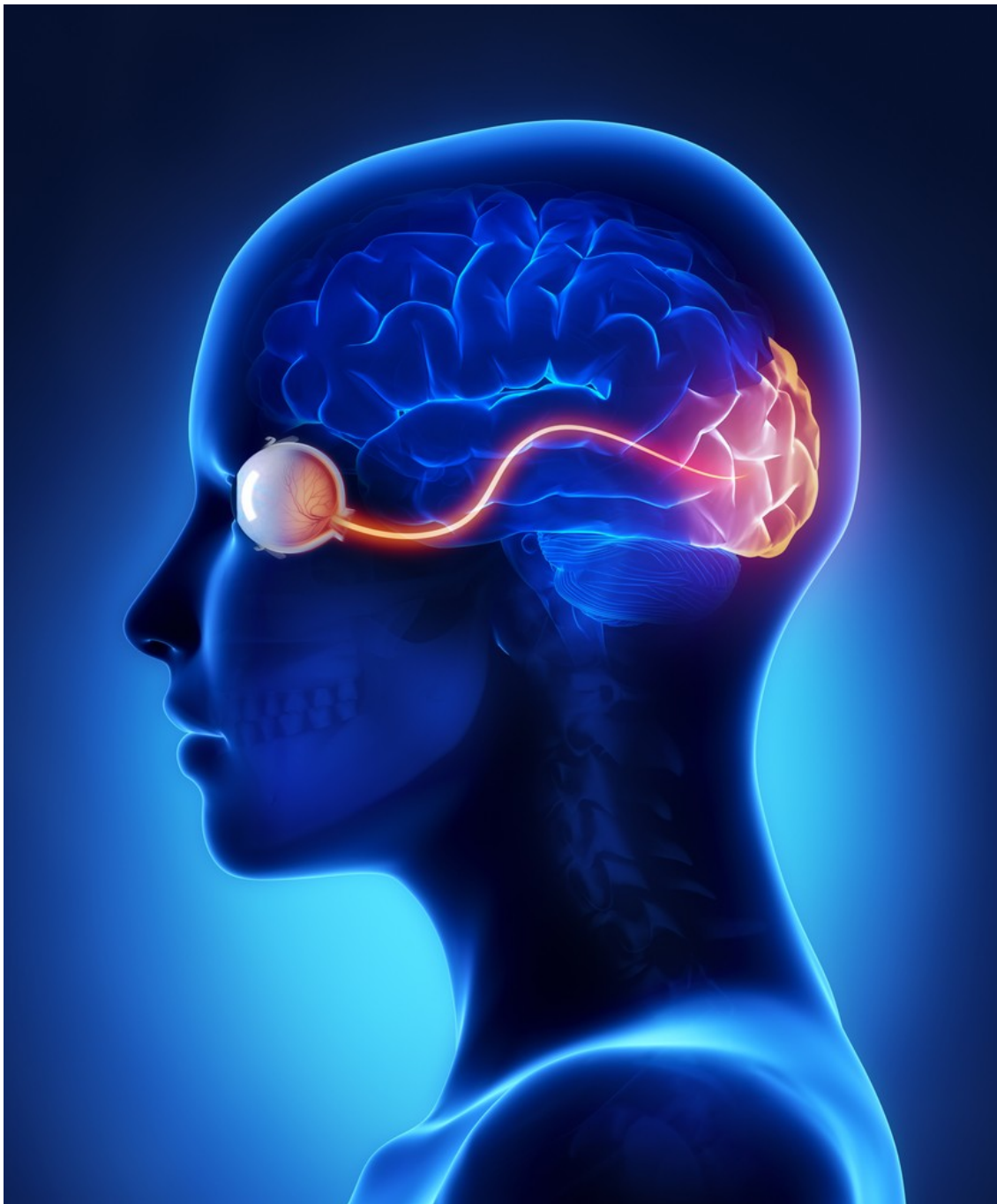

- 1 - amaurosis (= slepota) levého oka
- 2 - hemianopsia nasalis (porucha jen na levém oku)
- 3 - hemianopsia heteronyma bitemporalis
- 4 - hemianopsia homonyma dextra



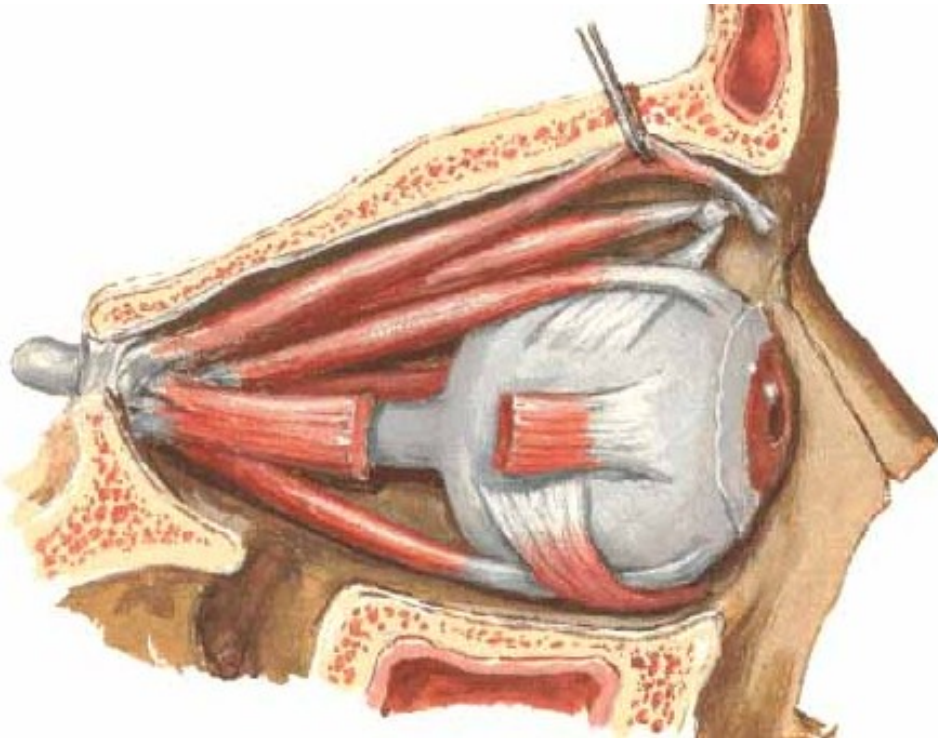
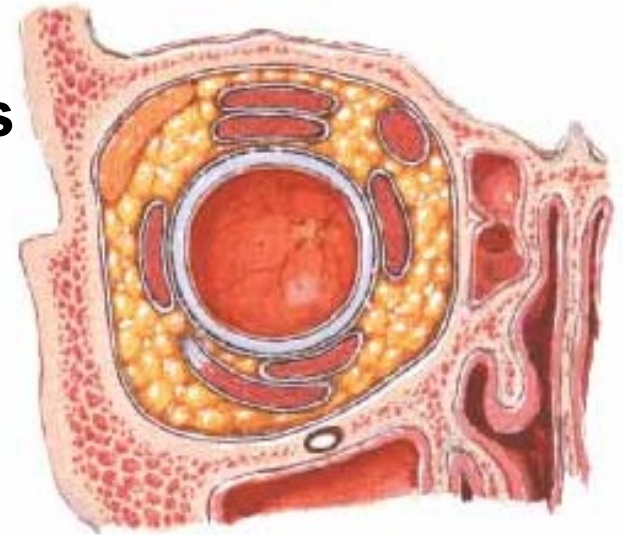
Optic nerve



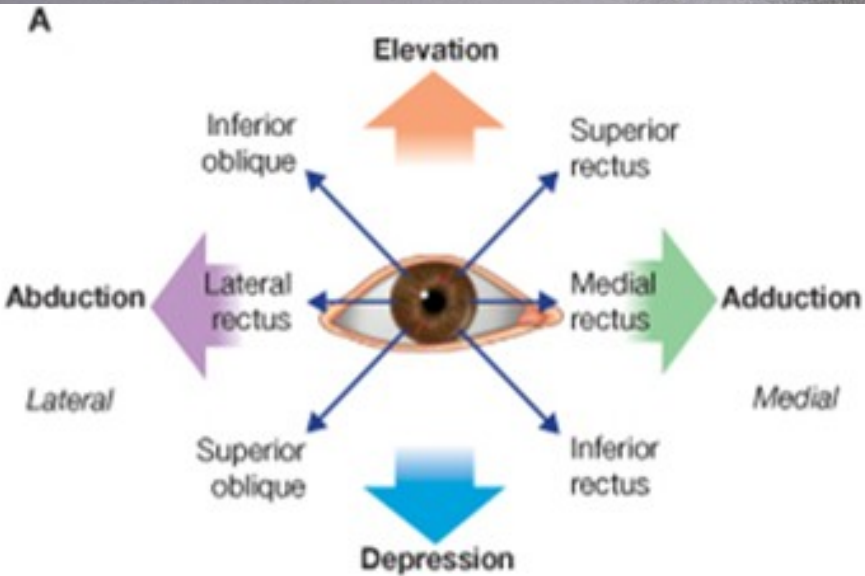
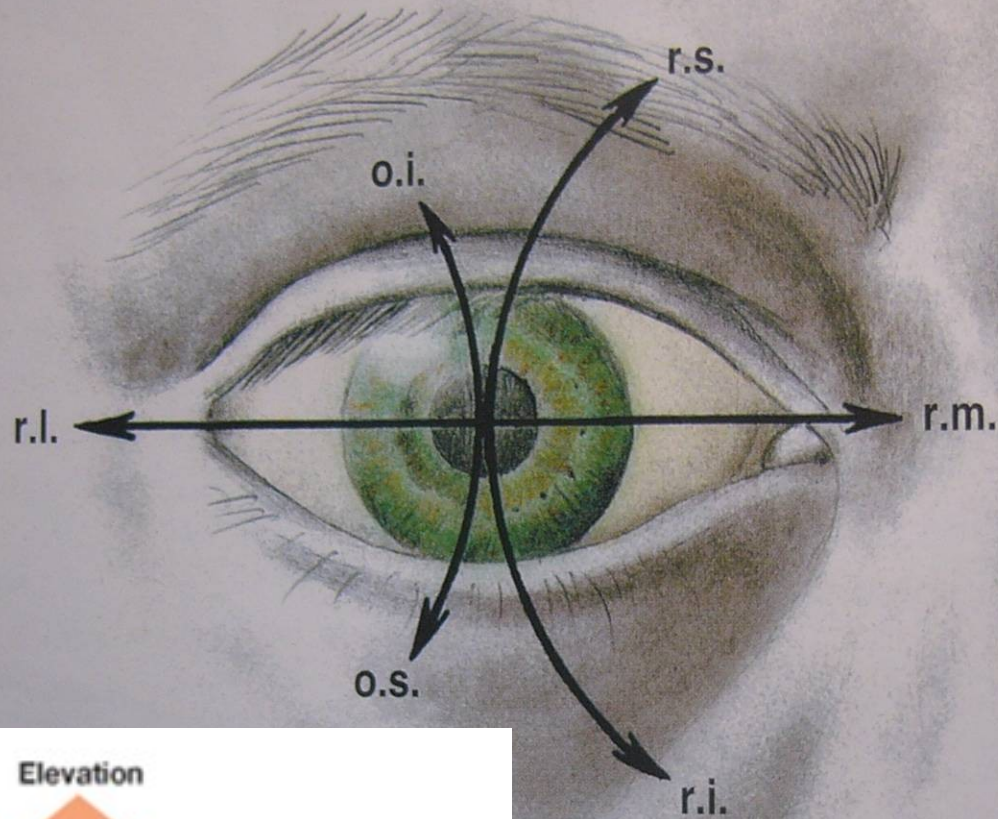


The extraocular muscles

- mm. recti (bulbi)
 - superior, inferior, medialis, lateralis
- mm. obliqui (bulbi)
 - *inferior, superior*
- m. levator palpebrae superior
- ***inervation:*** n. III., IV., VI.



Movements of the eyeball



The extraocular muscles innervation:

- Through sinus cavernosus and fissura orbitalis superior, they enter the orbit

- **III. The oculomotor nerve**

- fossa interpeduncularis (sulcus nervi oculomotorii)

motor – 5 extraocular muscles

+ parasympathetic fibers for innervation of smooth muscles of the iris - *m. sphincter pupillae* – pupil constriction (miosis) and of corpus ciliare- *m. ciliaris* – accommodation of the lens

- **IV. The trochlear nerve**

- Posterior surface of the brainstem

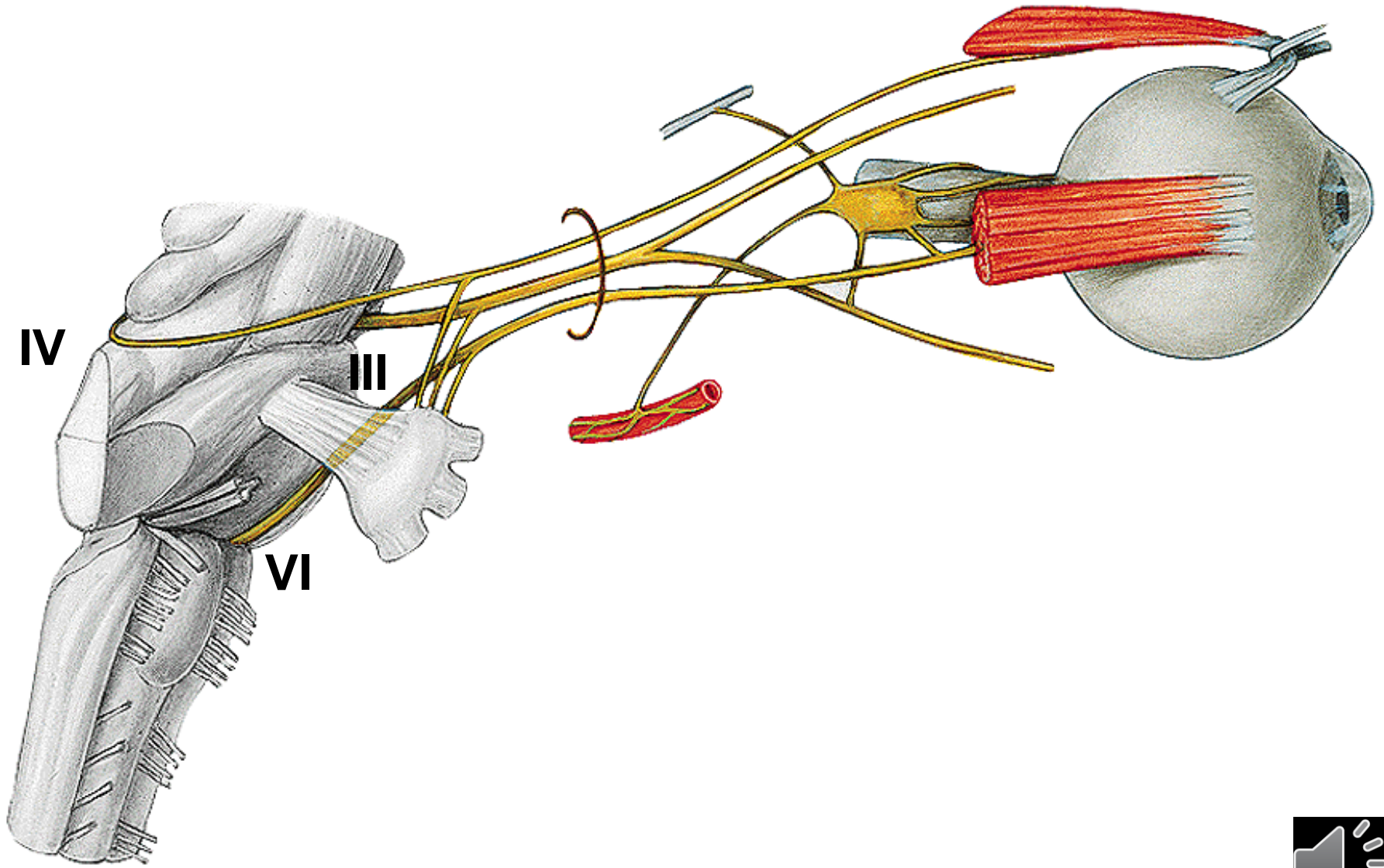
purely motor → 1 muscle = **m. obliquus superior**

- **VI. The abducens nerve**

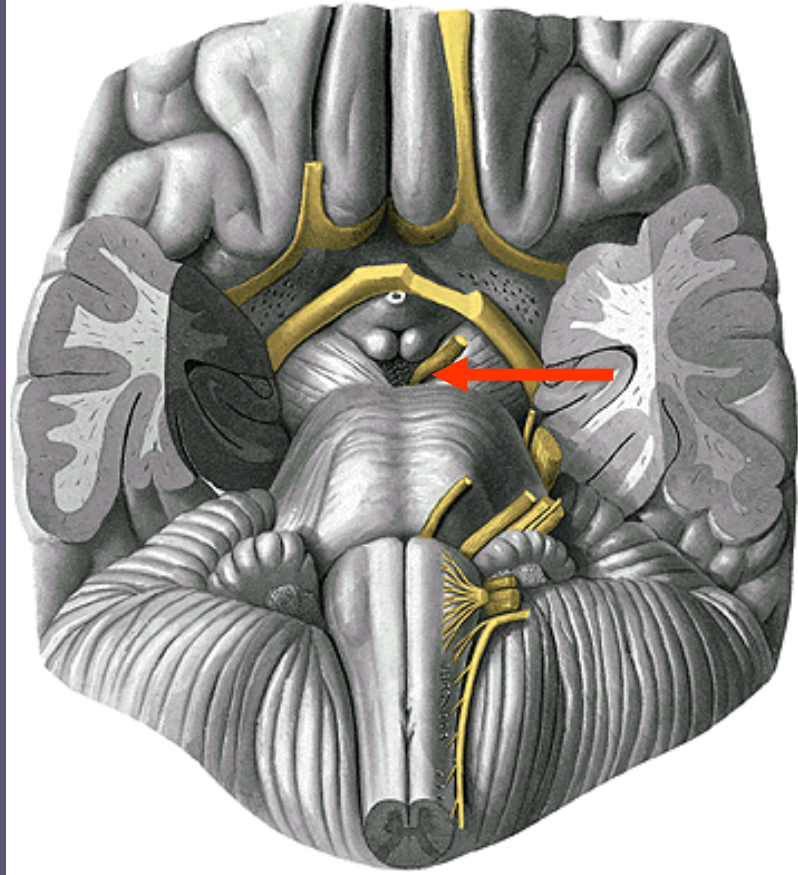
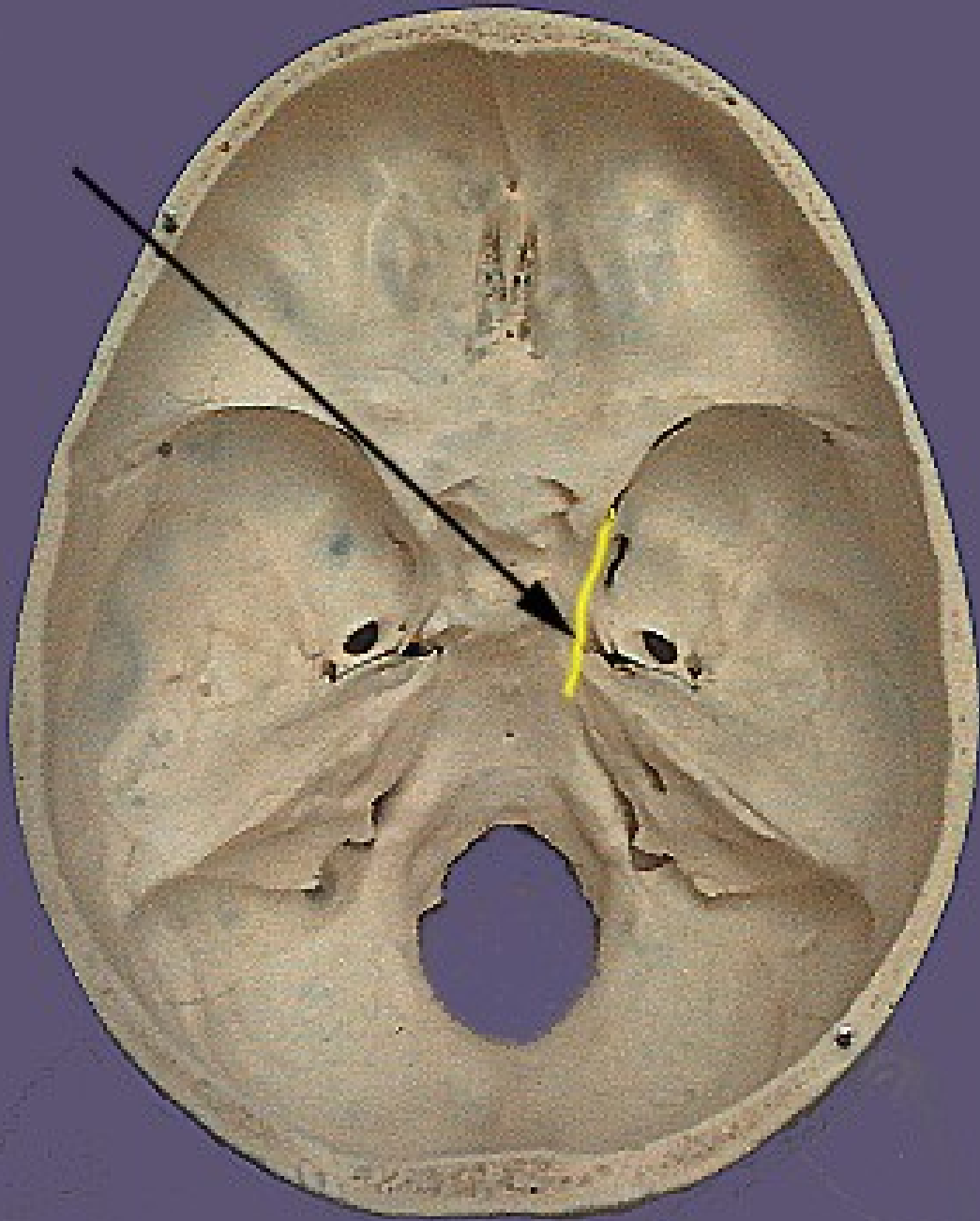
- sulcus bulbopontinus

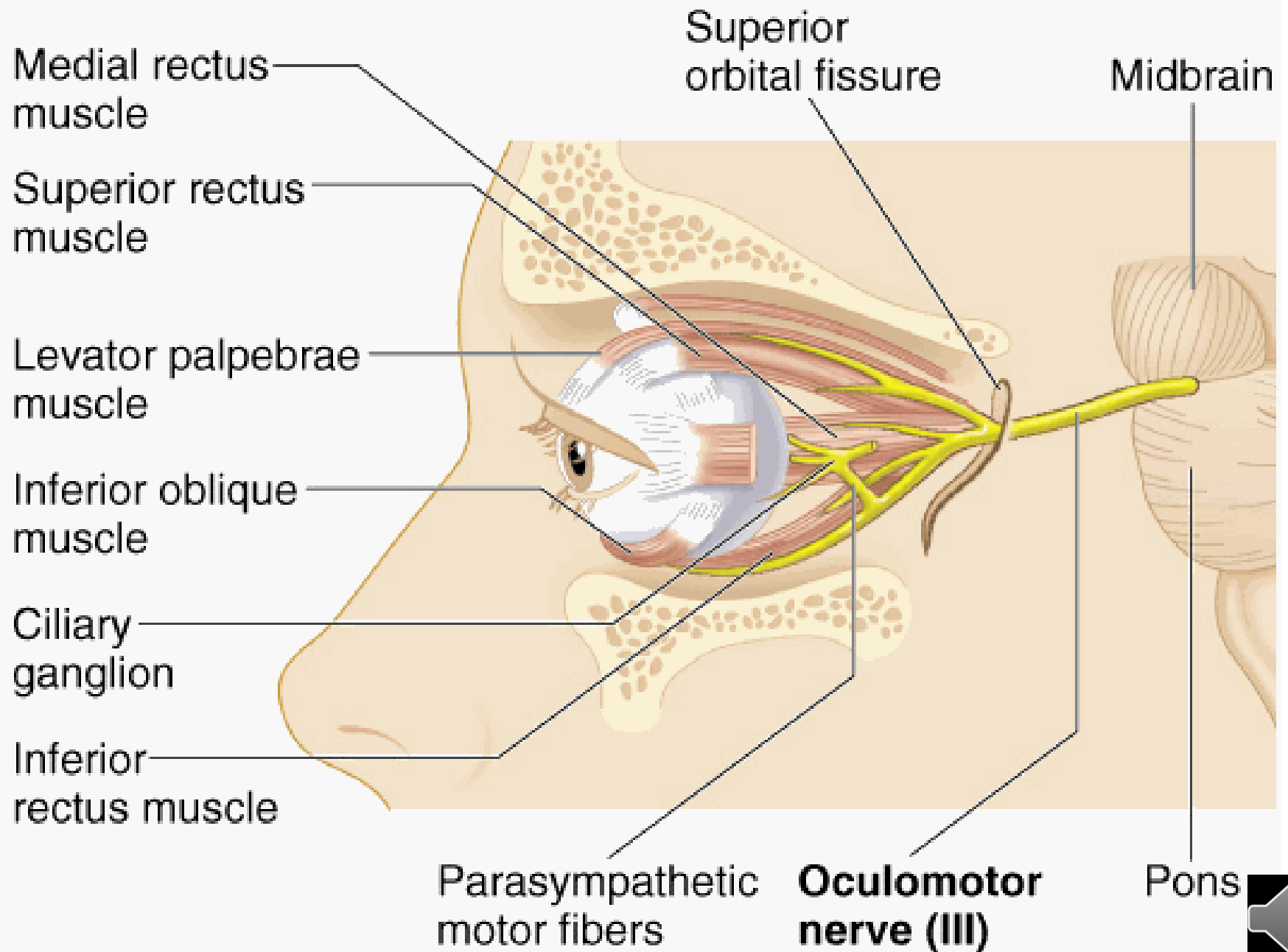
purely motor → 1 muscle - **m. rectus lateralis**

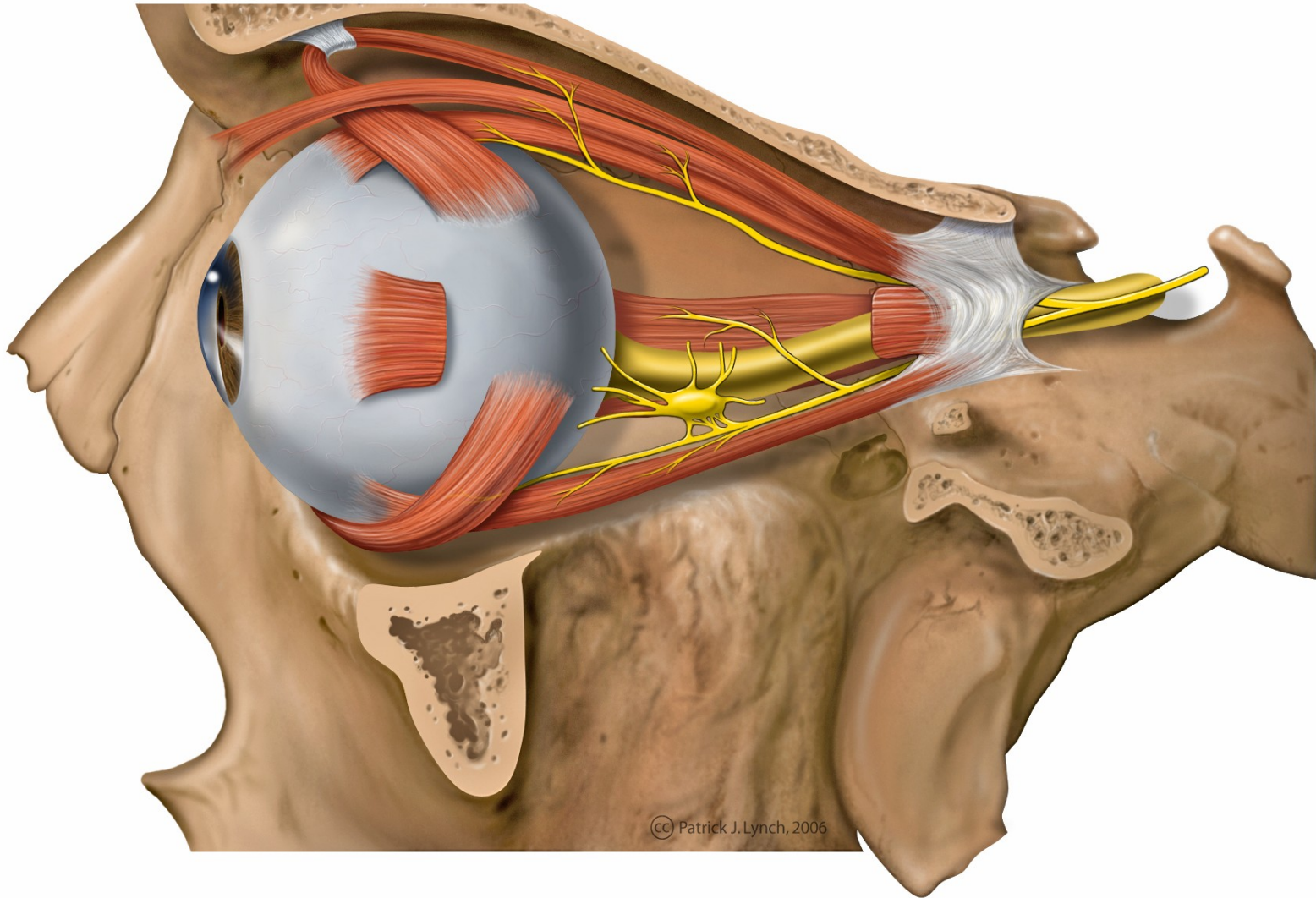




n.III.



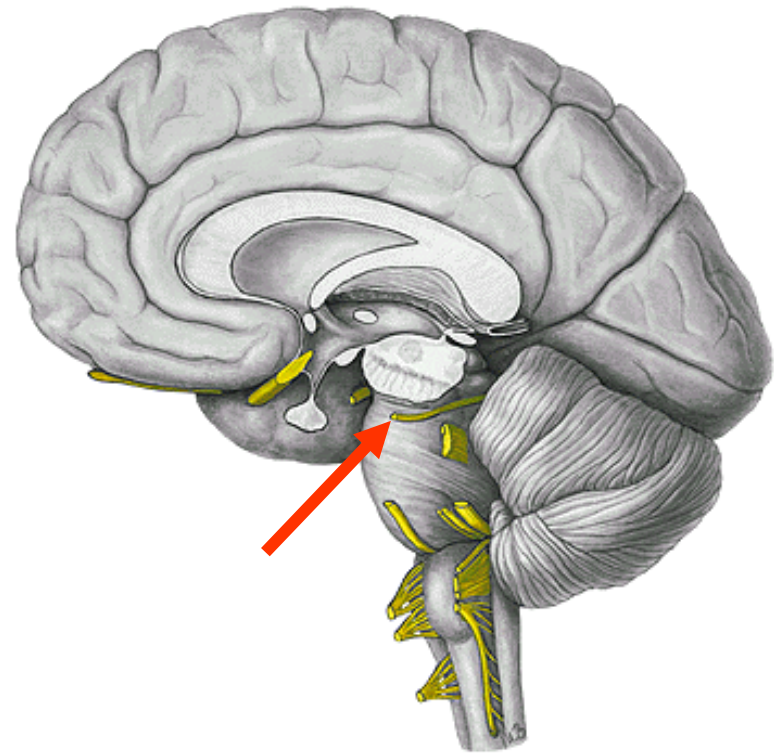
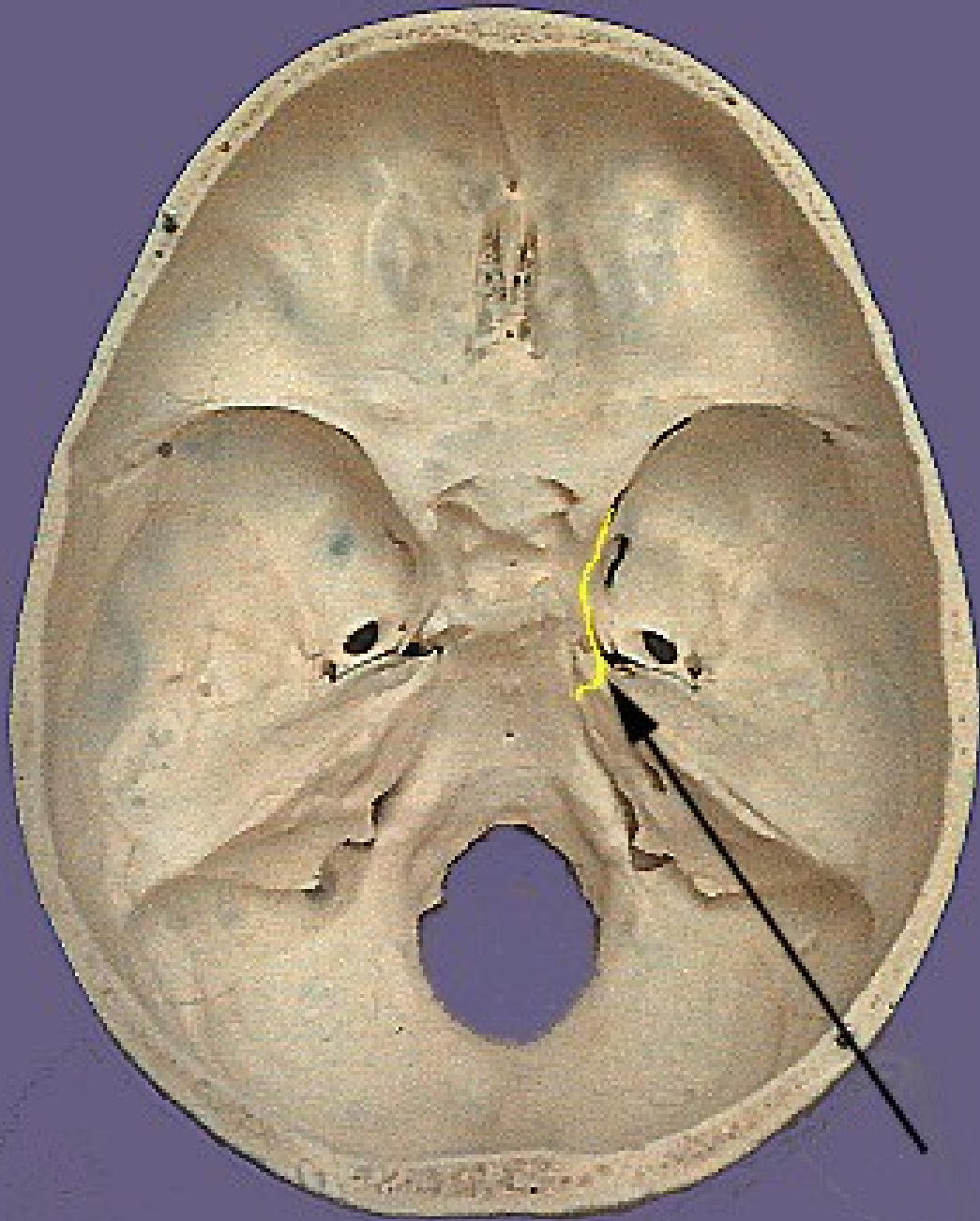




© Patrick J. Lynch, 2006

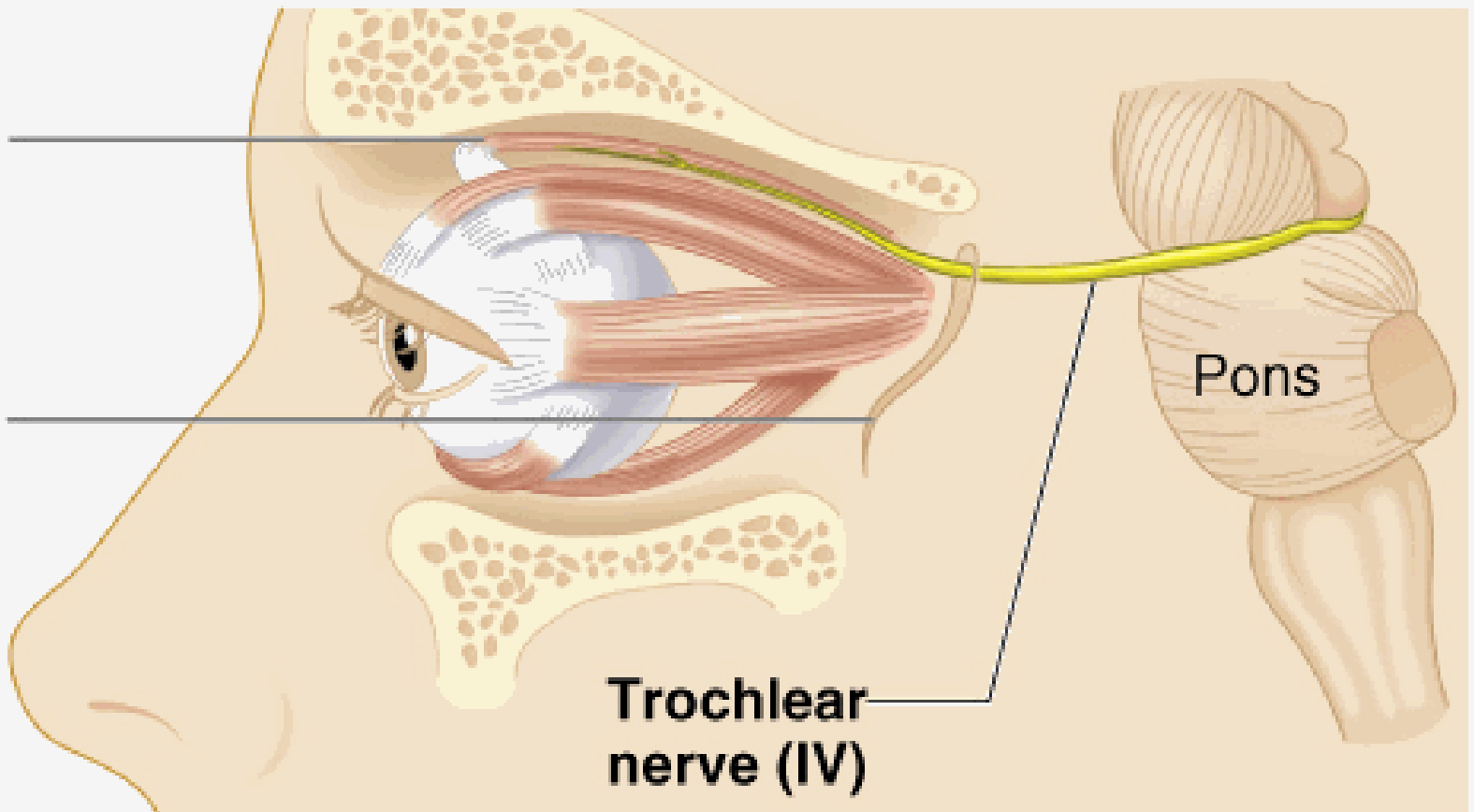


n.IV.



Superior
oblique
muscle

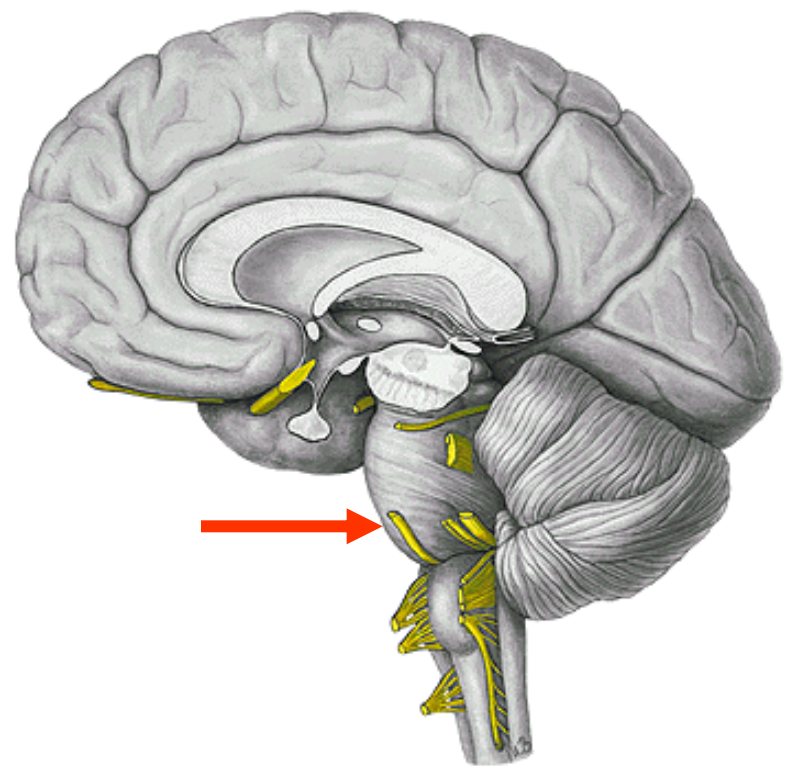
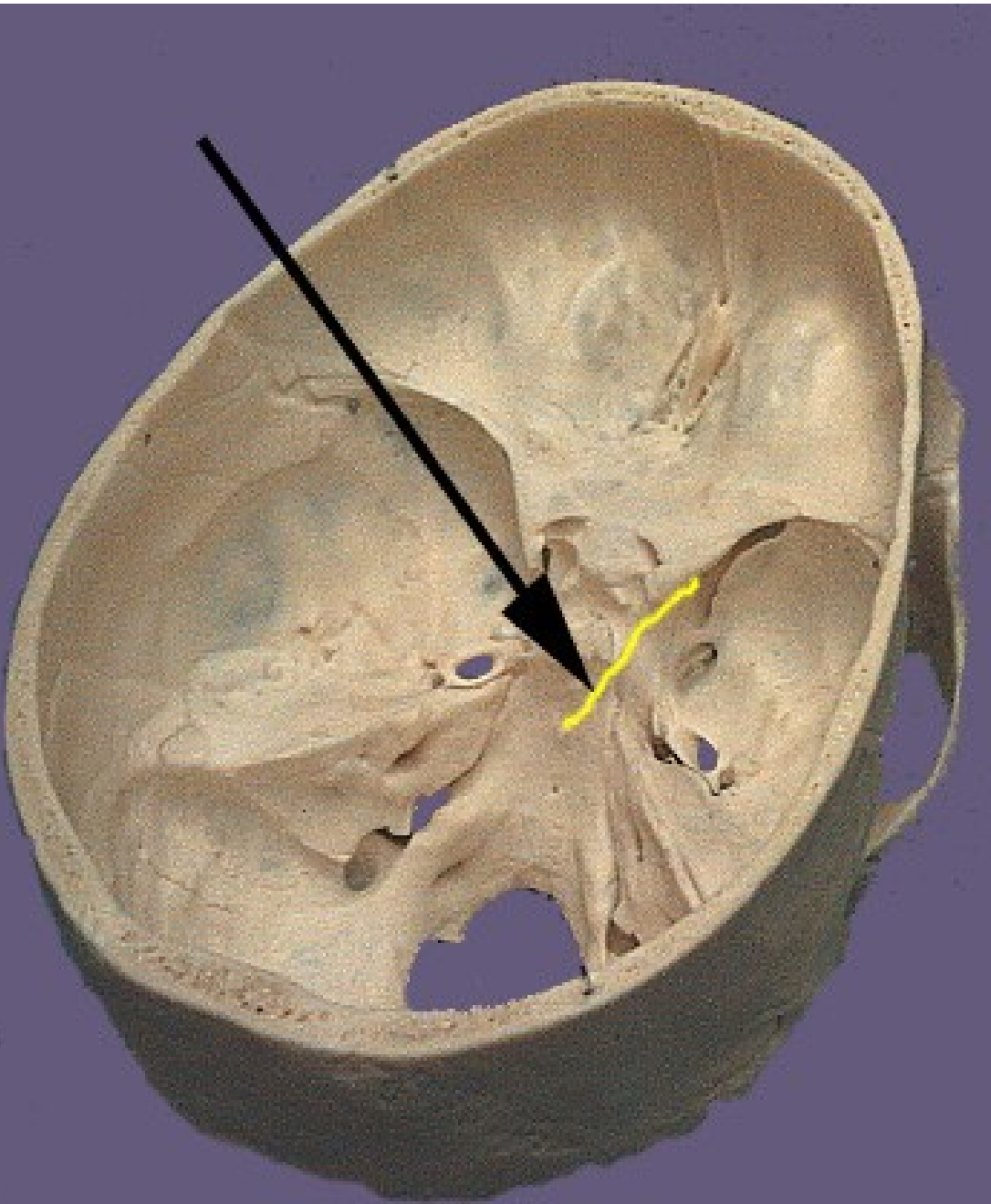
Superior
orbital
fissure



Trochlear
nerve (IV)

Pons

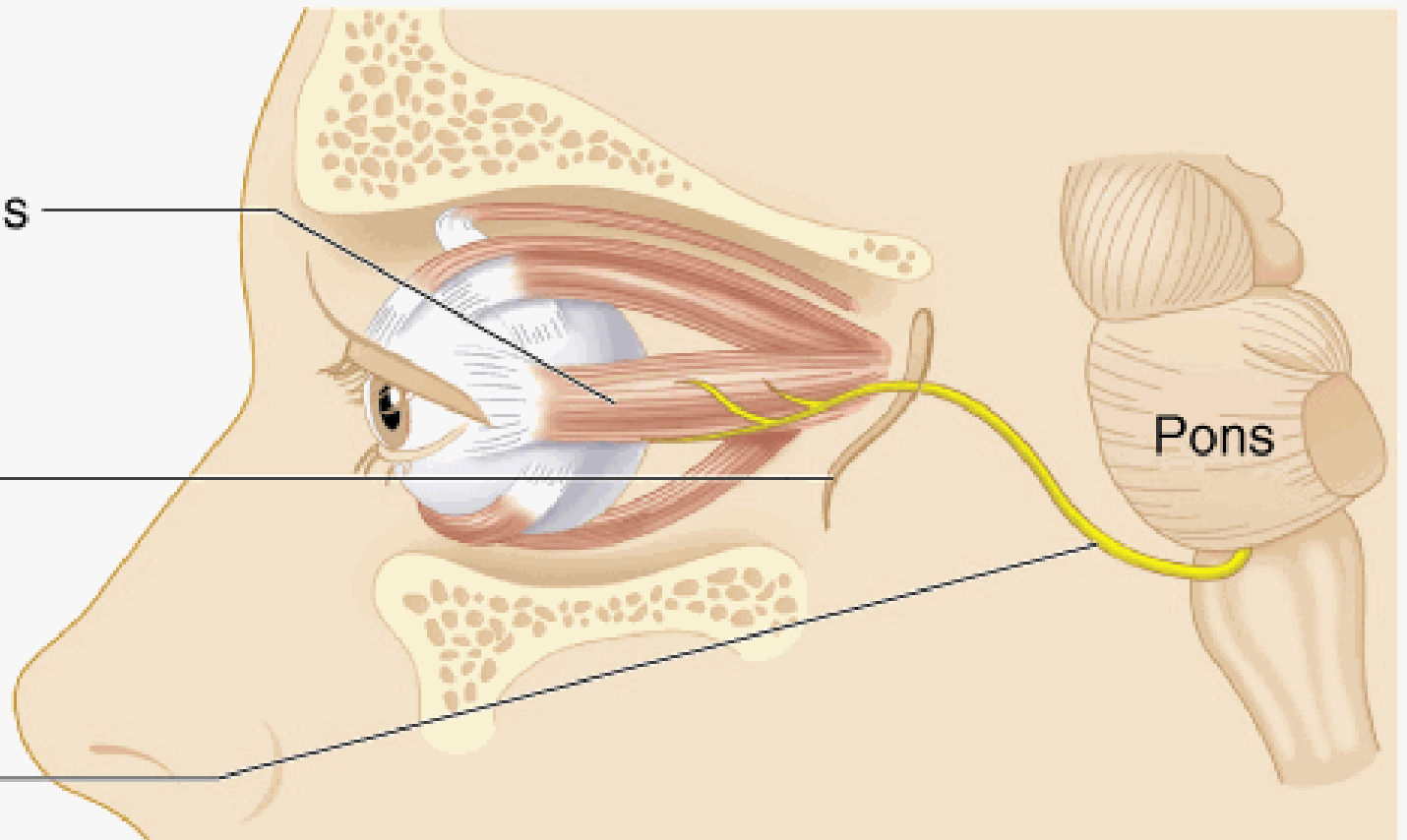




Lateral rectus muscle

Superior orbital fissure

Abducens nerve (VI)



Nerves passing through superior orbital fissure

Lacrimal nerve

Frontal nerve

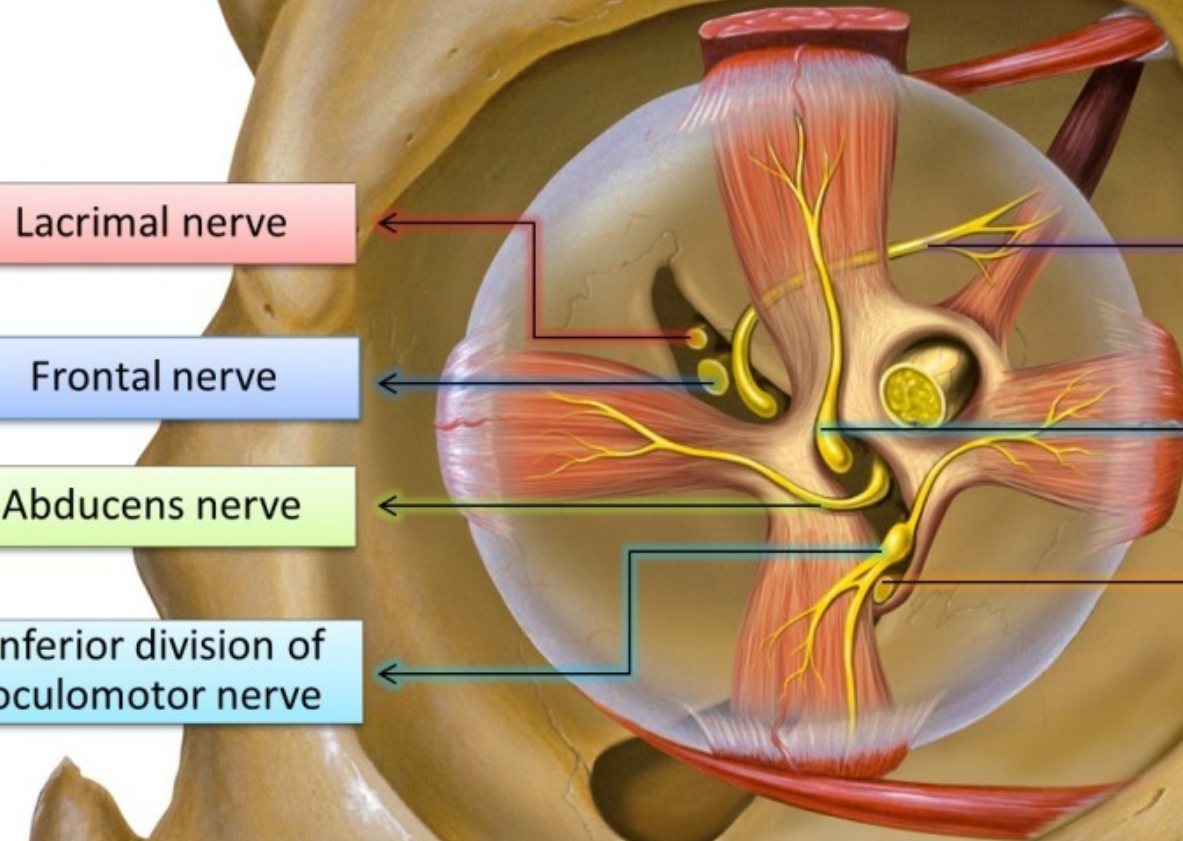
Abducens nerve

Inferior division of oculomotor nerve

Trochlear nerve

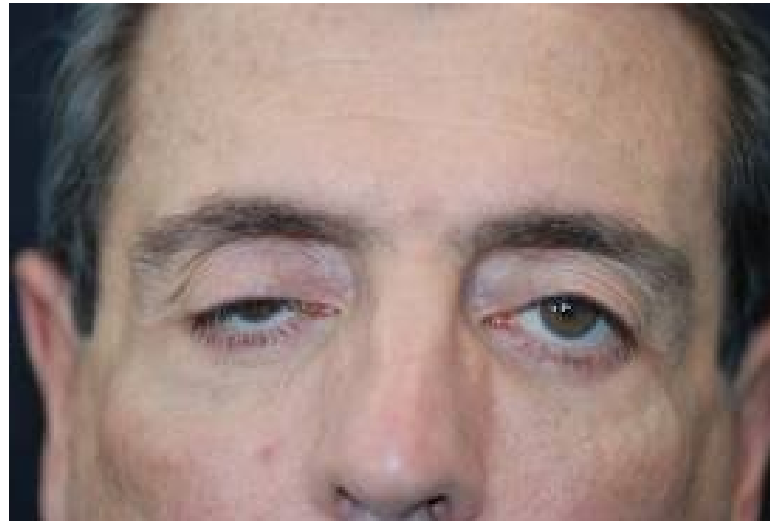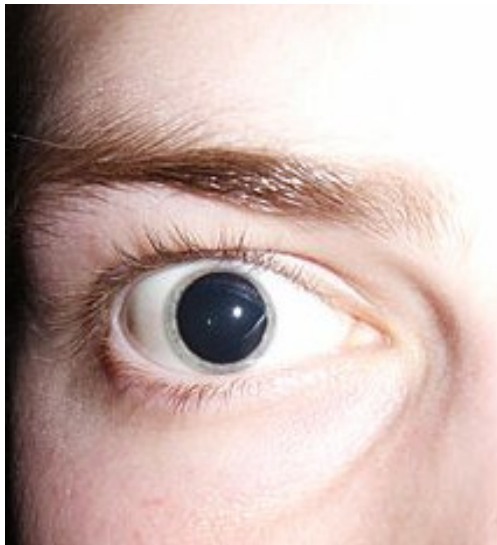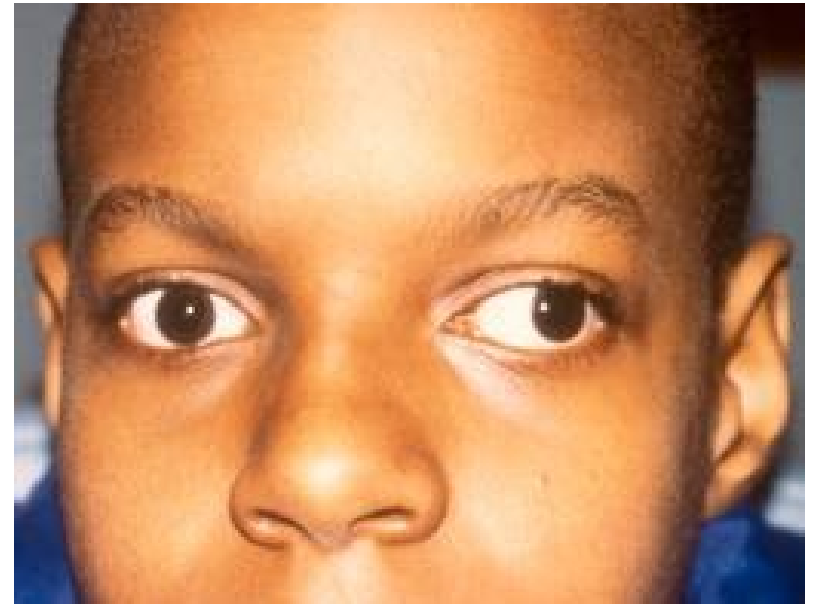Superior division of oculomotor nerve

Nasociliary nerve



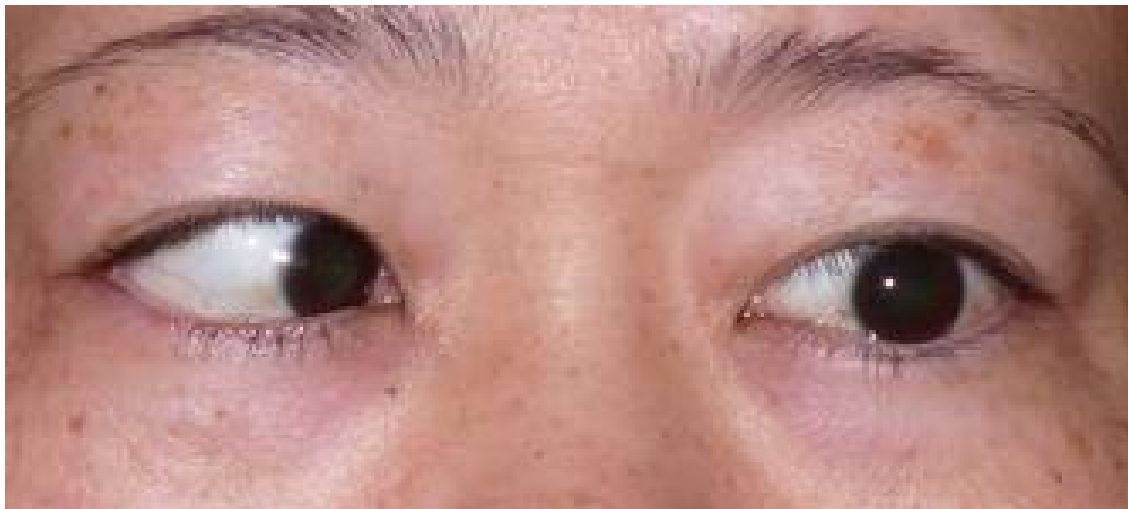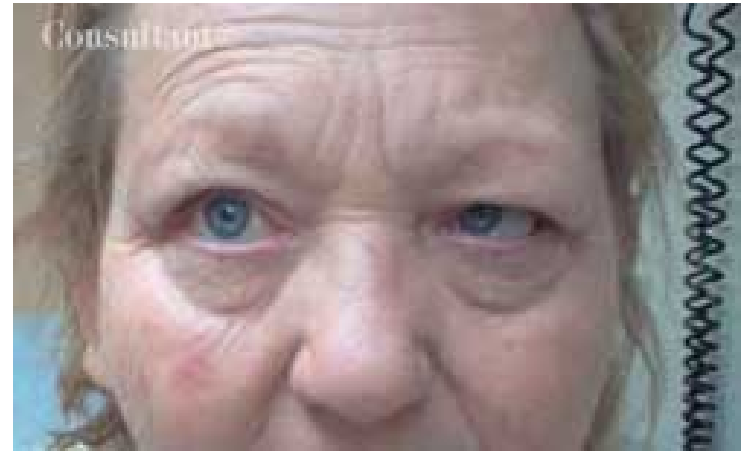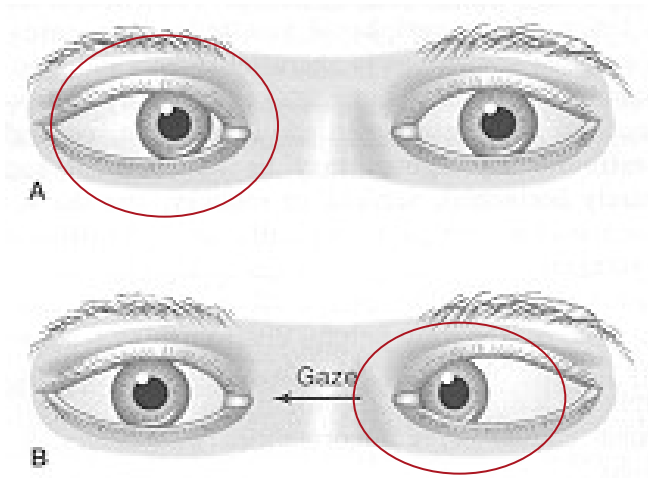
Palsy of n. III

- divergent strabismus
- Pupil dilatation- mydriasis
- Accommodation disorder
- falling of the upper eyelid - ptosis
- double vision- diplopia



Palsy of n. IV and n.VI

- convergent strabismus)



V. = The trigeminal nerve

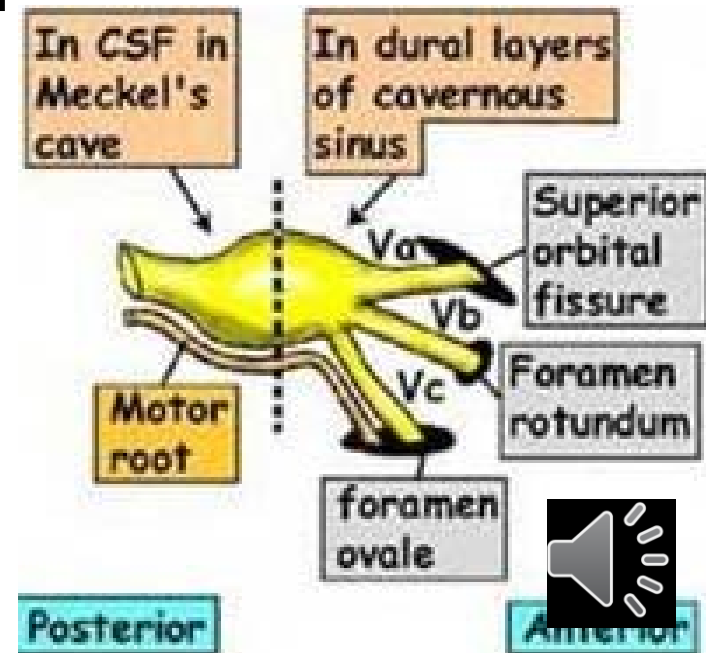
- *ganglion trigeminale* (located within *cavum trigeminale*) - sensory

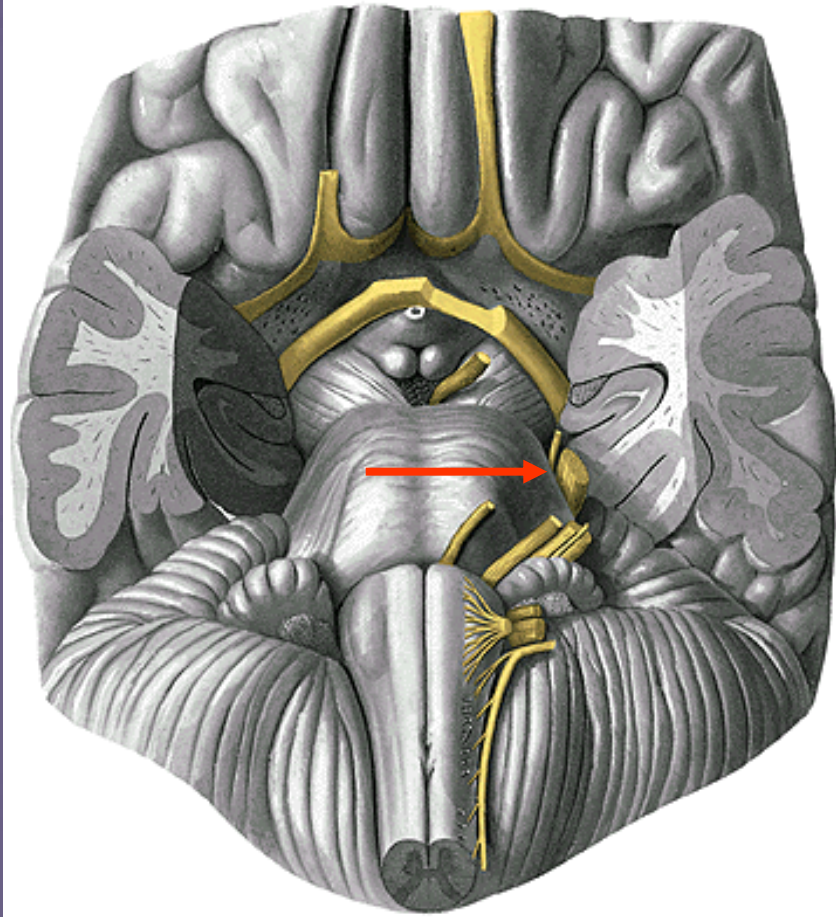
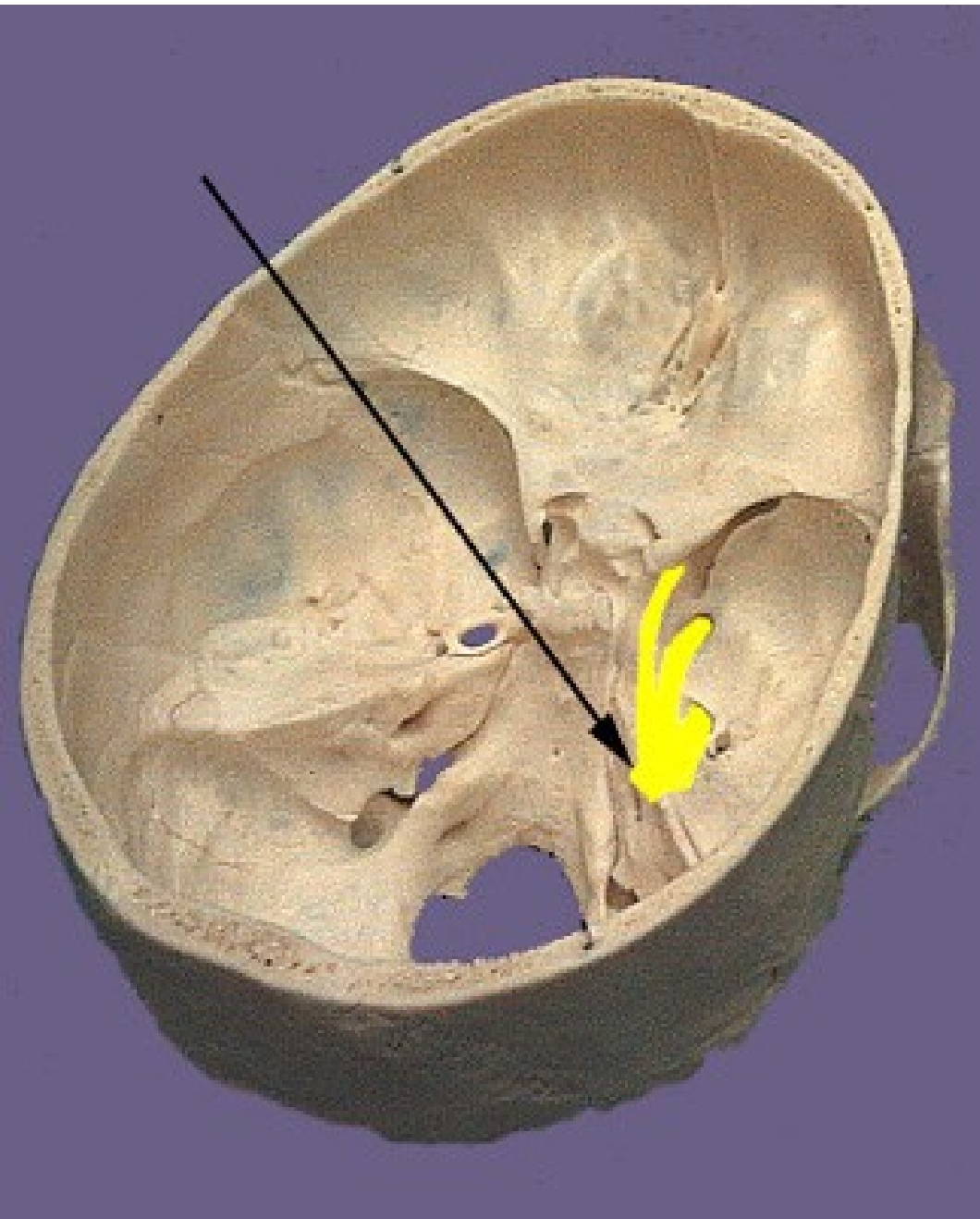
V1 = n. ophthalmicus = ophthalmic nerve (*sensory*)

V2 = n. maxillaris = maxillary nerve (*sensory*)

V3 = n. mandibularis = mandibular nerve (*mixed*)

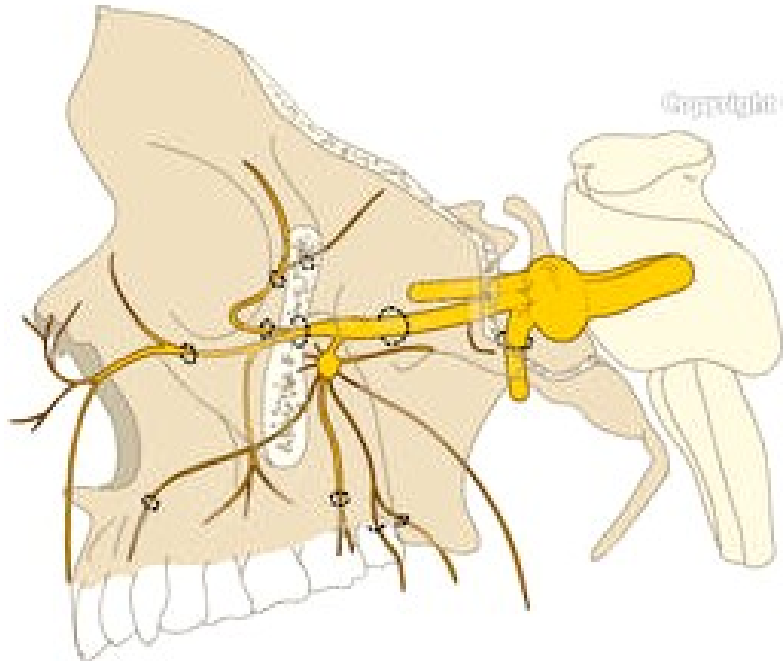
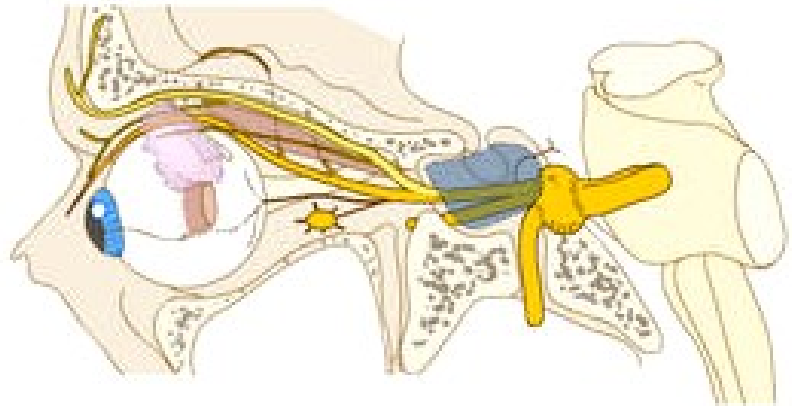
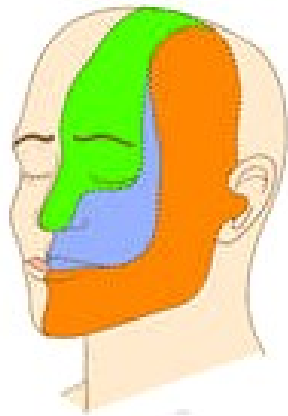
Radix motoria = somatomotor branch
for the masticatory muscles and other
4 muscles- fibers only within V3 !!!





n.V.





Copyright © Elsevier

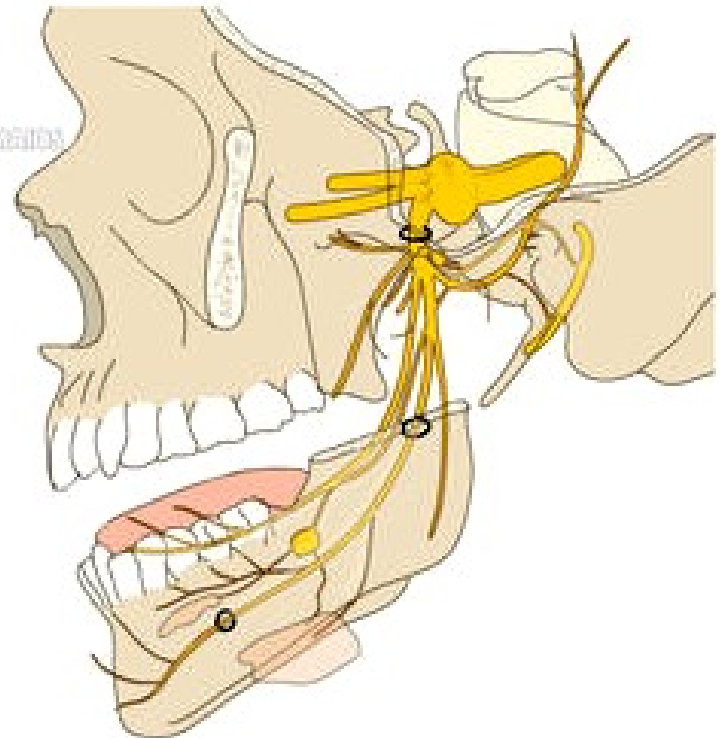
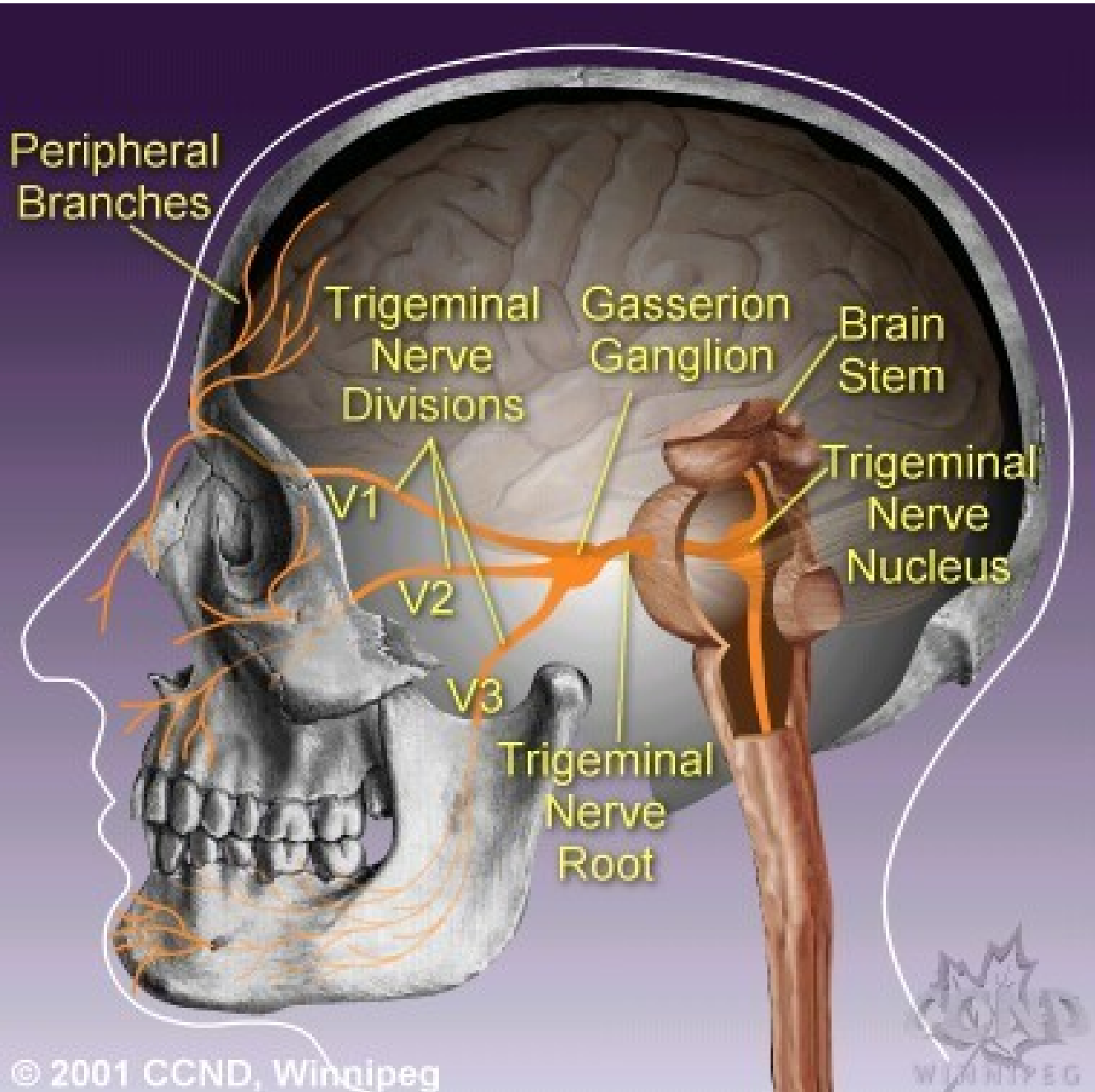


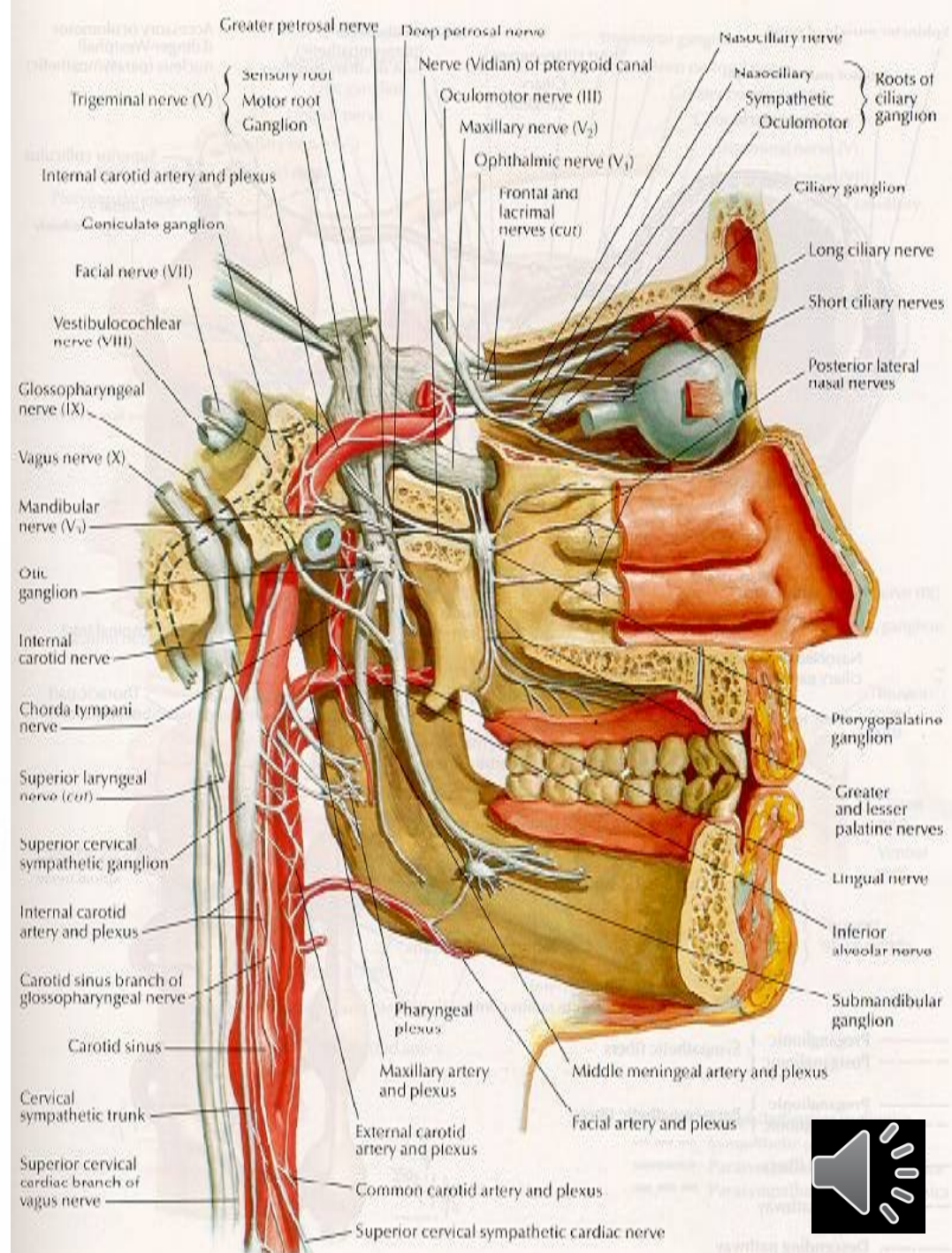
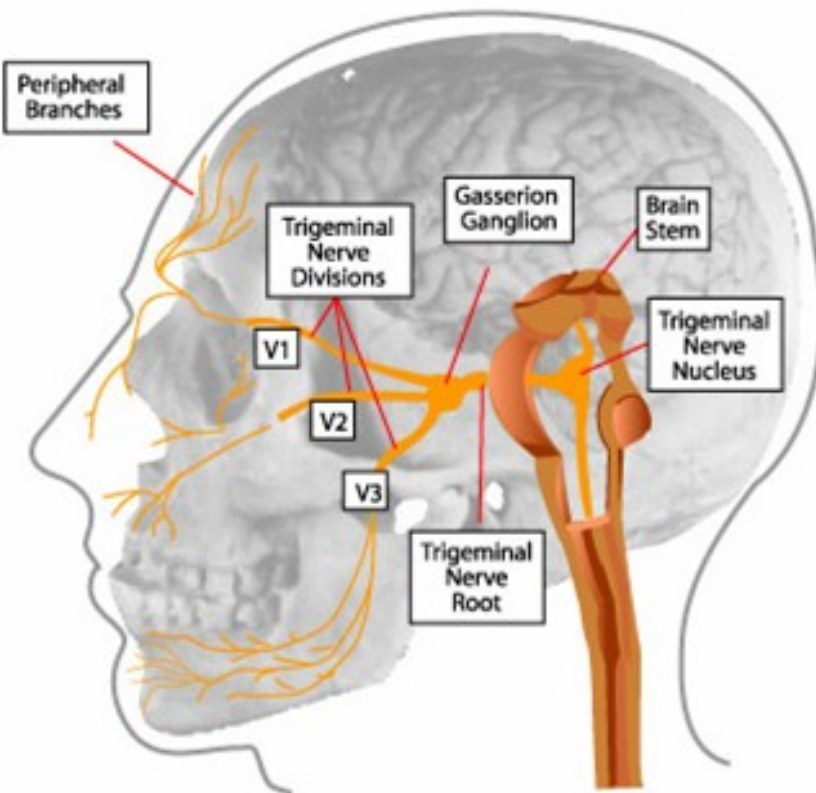
Illustration : A. Micheau, MD





N. V

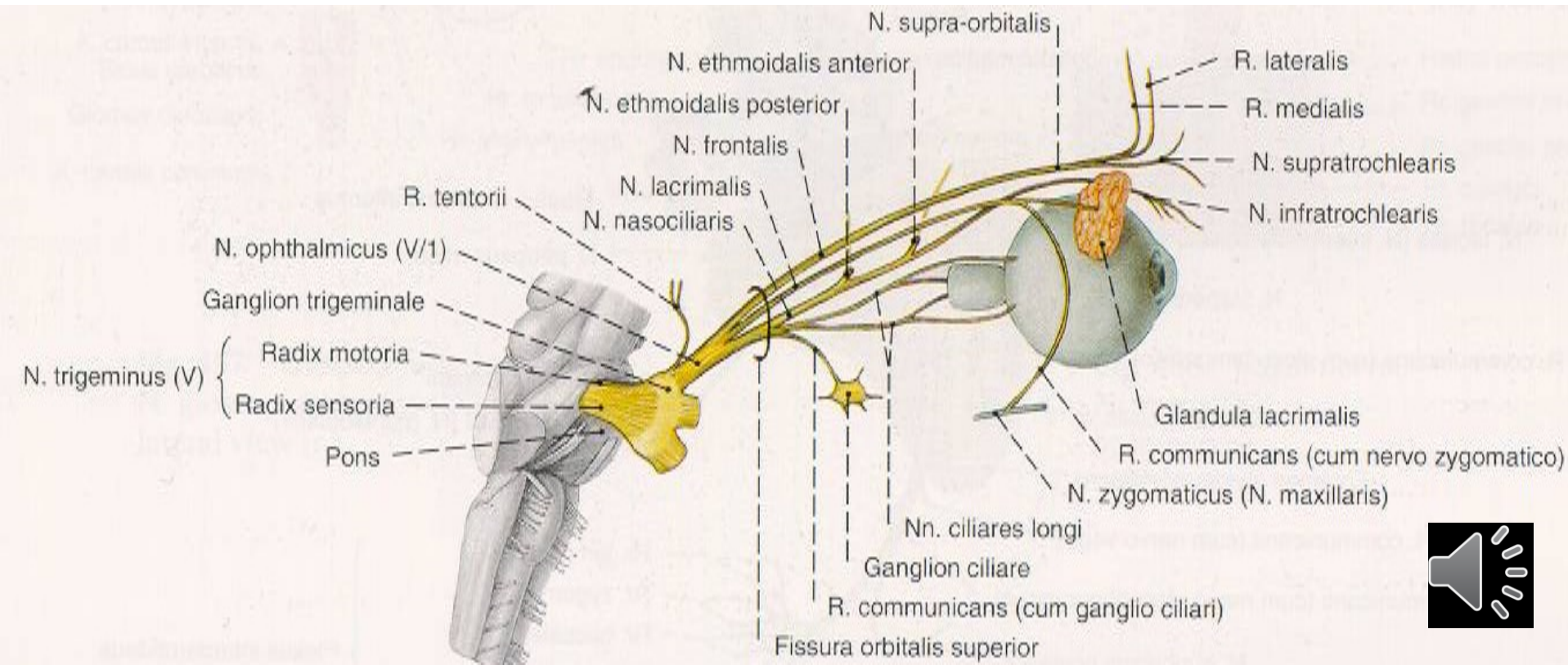
- **V1 = N. ophthalmicus**
- **V2 = N. maxillaris**
- **V3 = N. mandibularis**



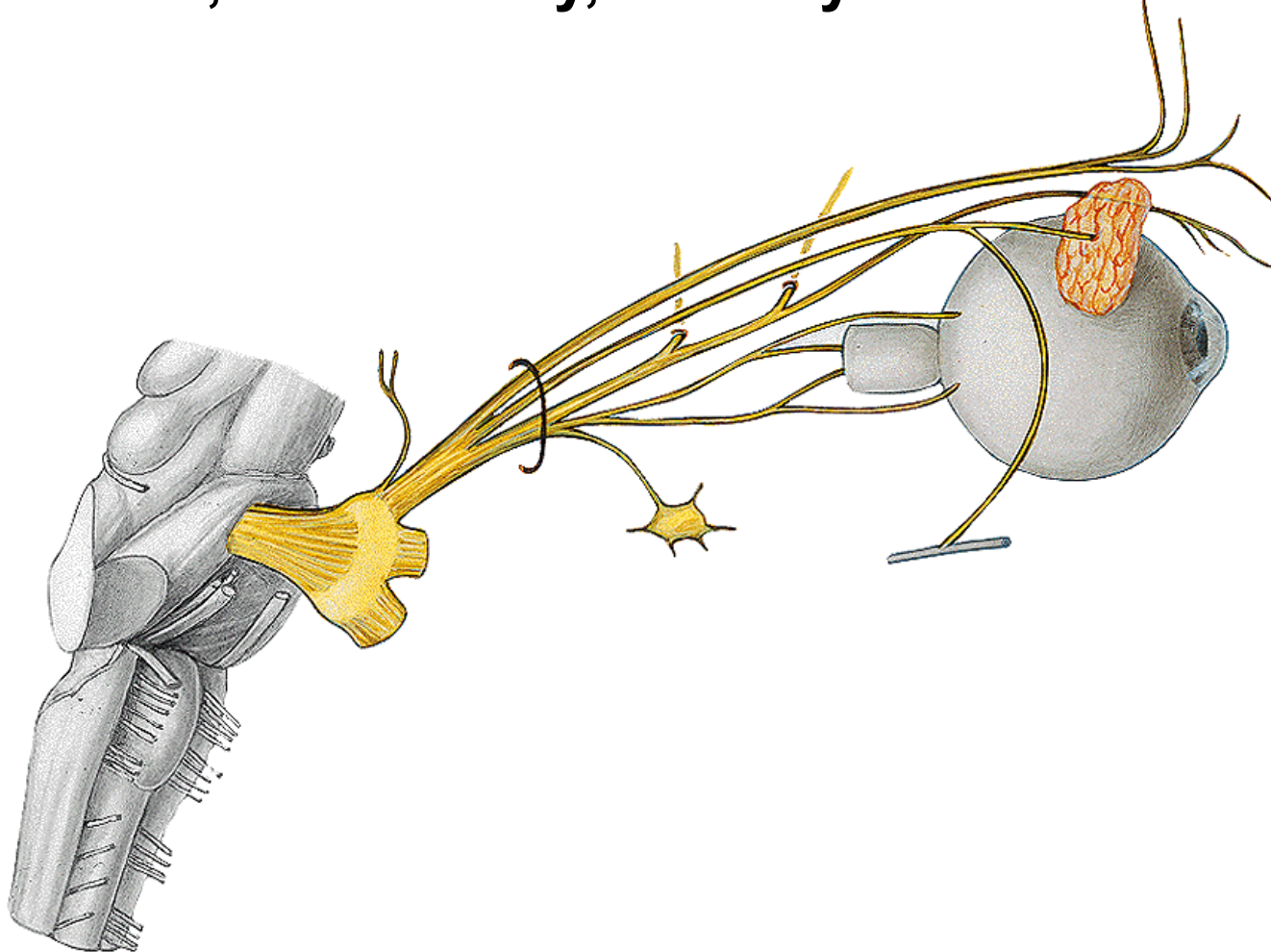
V1 = N. ophthalmicus

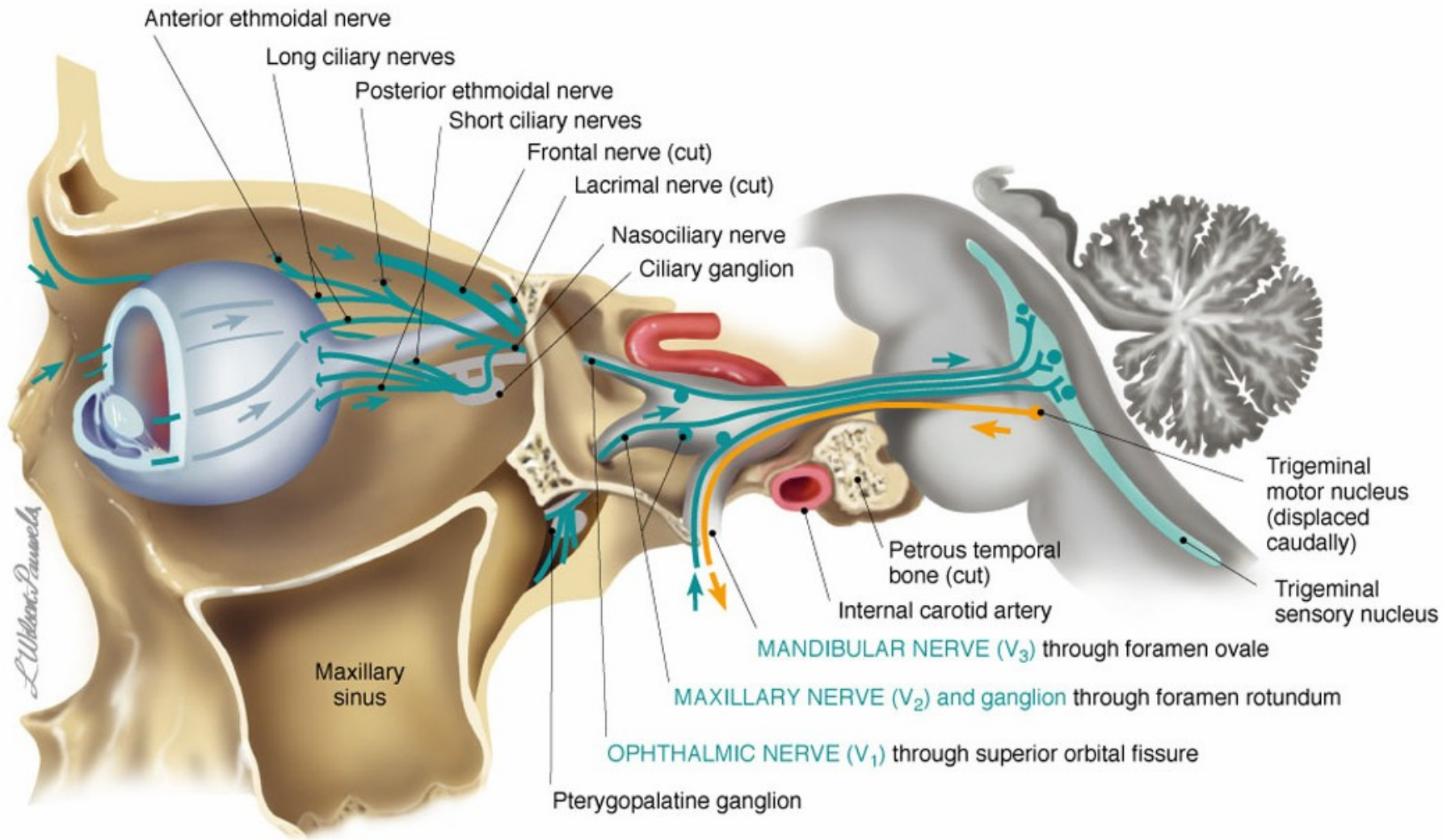
- fissura orbitalis superior into orbit – to the frontal region
- Skin of the upper part of face (forehead, upper eyelids, dorsum nasi), content of the orbit, part of mucosa of nasal cavity and paranasal sinuses)

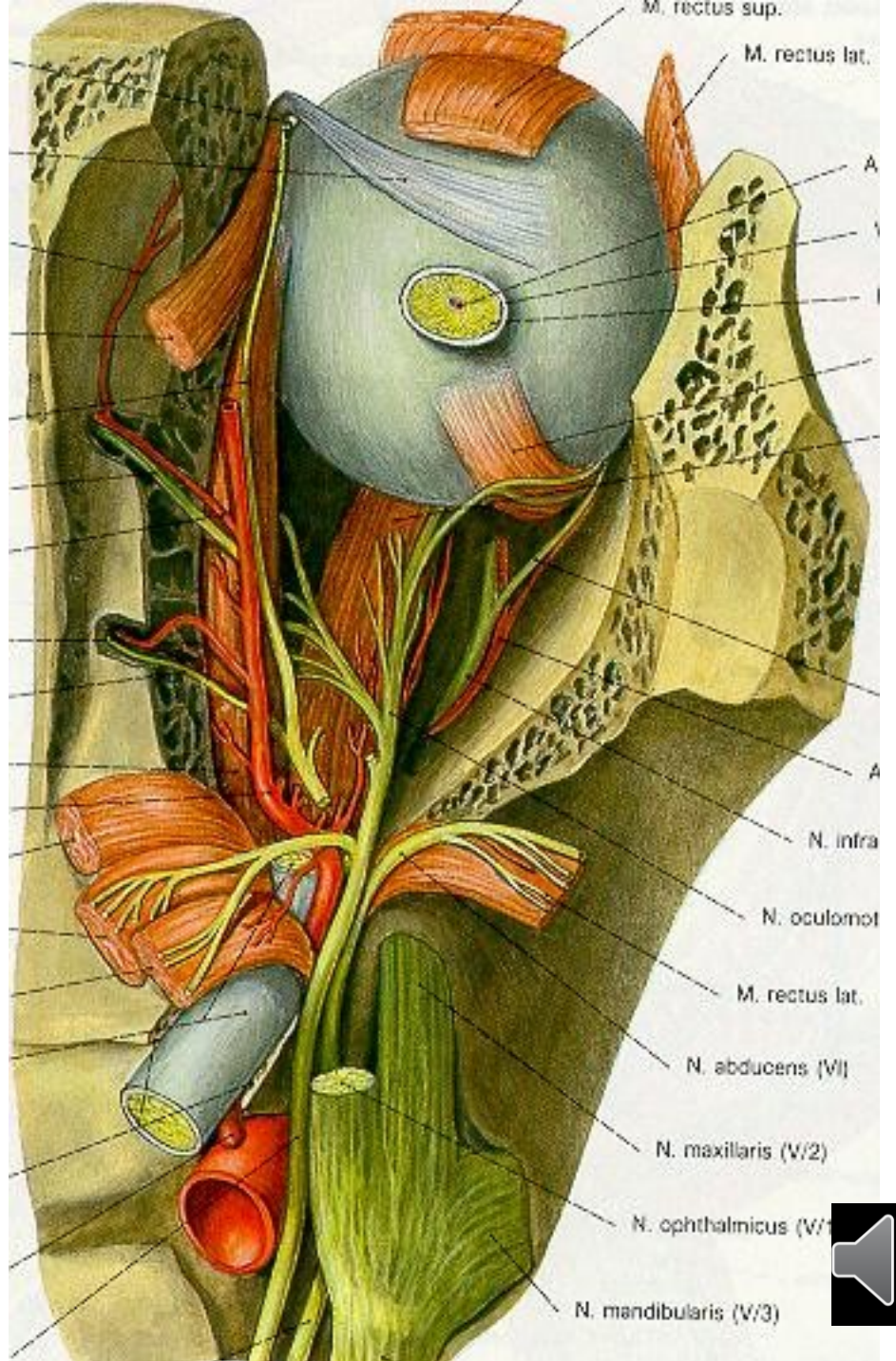
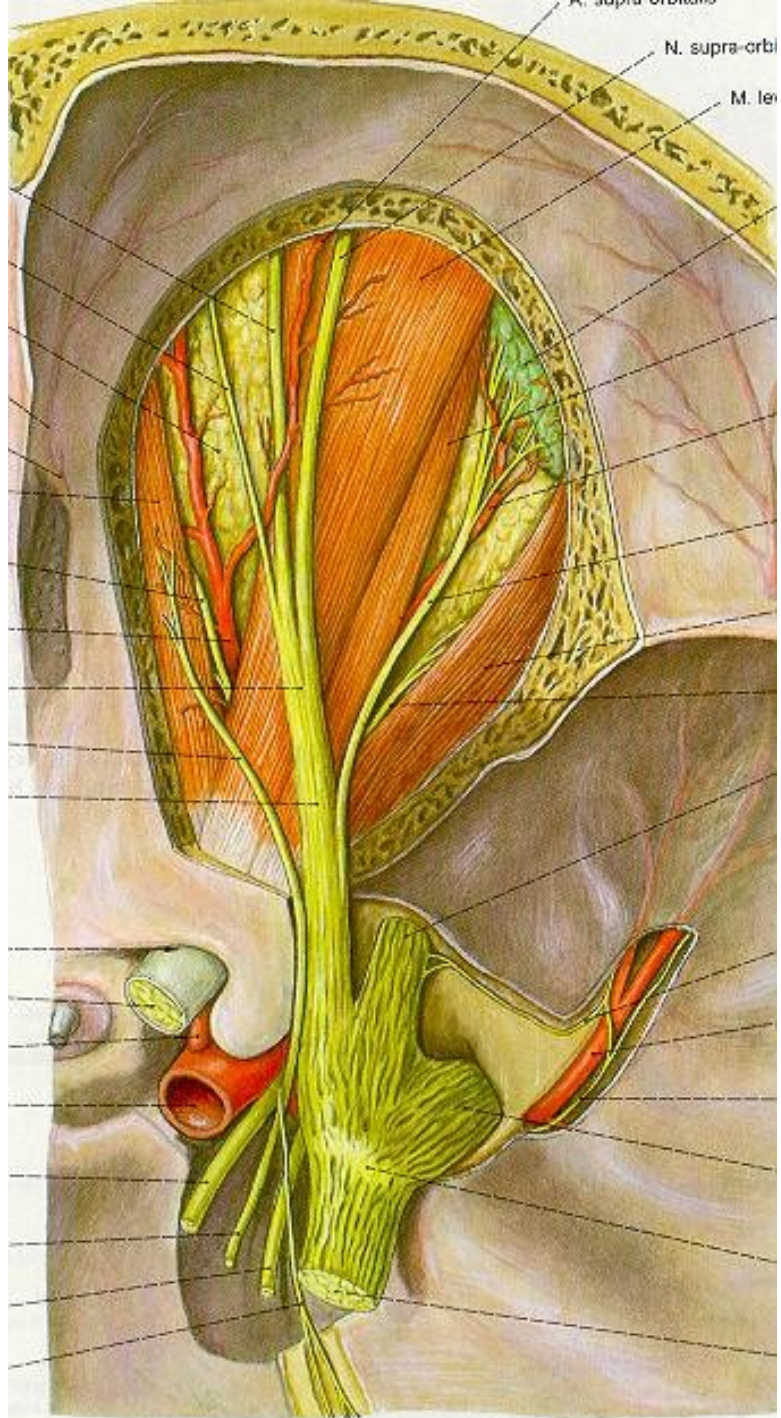
- n. frontalis
 - n. lacrimalis
 - n. nasociliaris
- n. supraorbitalis – *sensitivity to palpation*



- **n. frontalis: r. supraorbitalis (r. medialis et lateralis), r. supratrochlearis (skin of forehead till interauricular line)**
- **n. lacrimalis (lacrimal gland, upper eyelid)**
- **n. nasociliaris-branches: nn. ciliares longi, n. ethmoidalis posterior, n. ethmoidalis anterior, n. infratrochlearis (sinus sphenoidalis, nasal cavity, sensory fibres into the eye)**

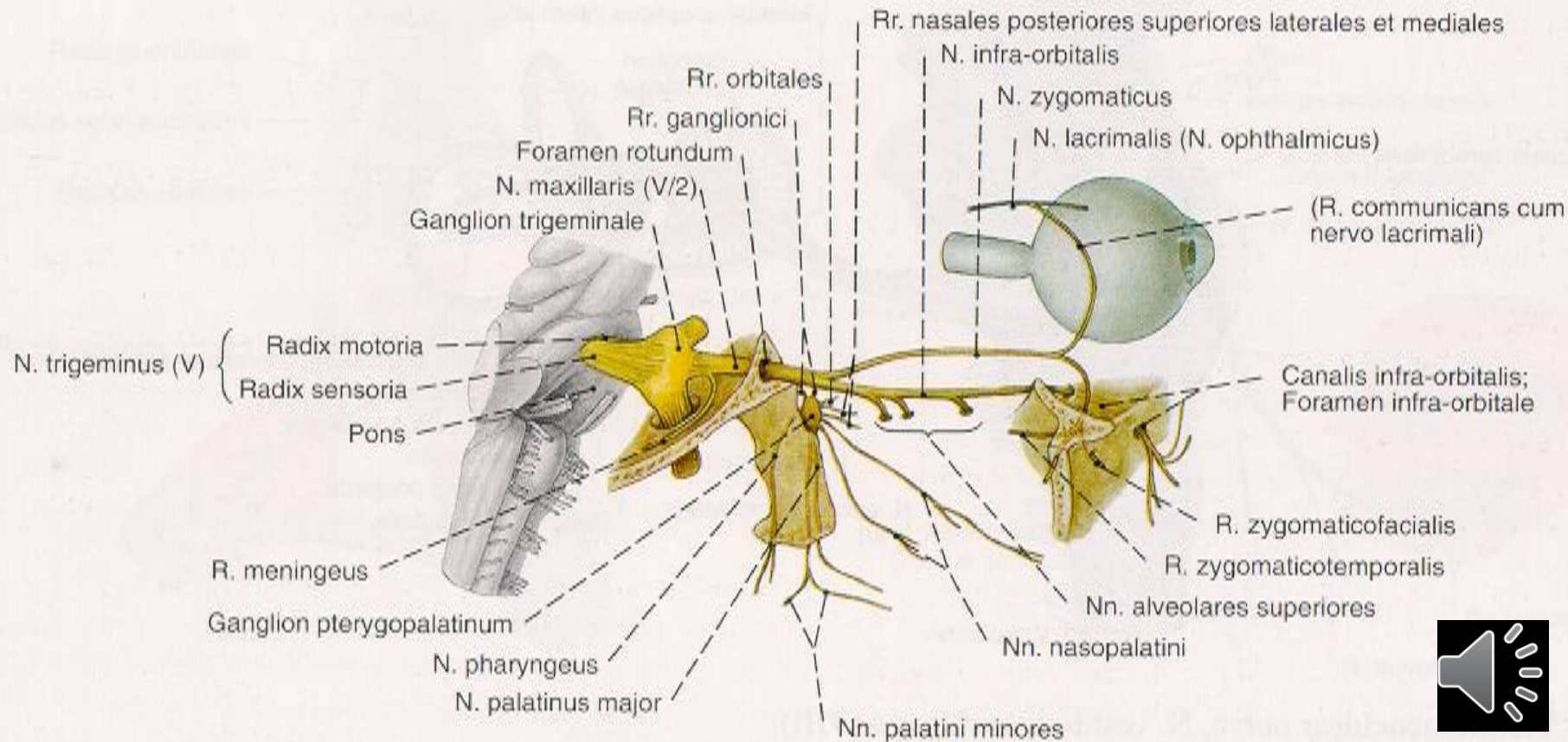




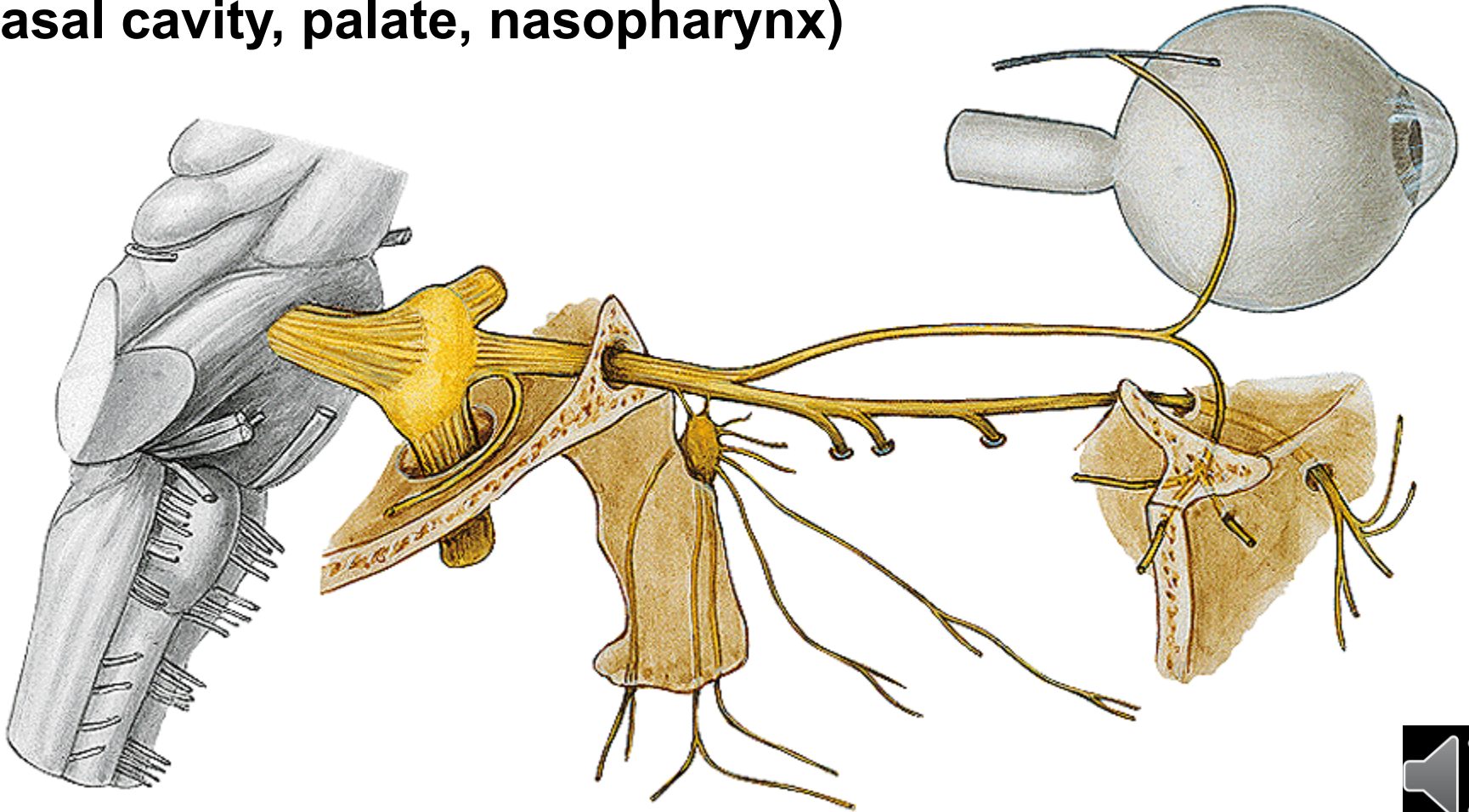


V2 = N. maxillaris

- foramen rotundum - branches out behind the maxilla- fossa pterygopalatina
- skin of middle part of face (lower eyelid, upper lip, nasal wings and upper half of cheek), **teeth of maxilla**, part of mucosa of nasal and oral cavity



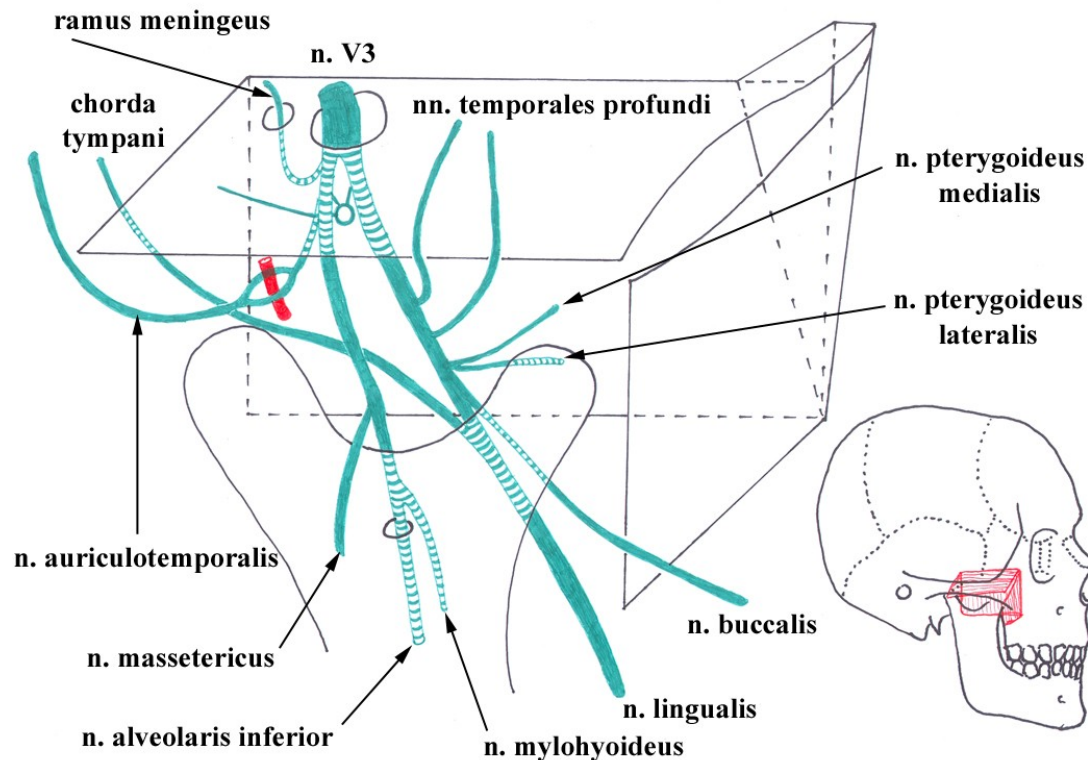
- **n. zygomaticus: n. zygomaticofacialis, n. zygomaticotemporalis, r. communicans cum nervo zygomatico (skin of cheek)**
- **n. infraorbitalis (teeth of maxilla, sinus maxilaris, mucosa of nasal cavity, palate, nasopharynx)**



V3 = N. mandibularis

- foramen ovale – branches out behind ramus mandibulae-
fossa infratemporalis
- skin of inferior part of face (lower lip, inferior half of cheek,
chin), teeth of mandibula, part of mucosa of oral cavity
- masticatory muscles, muscles of neck

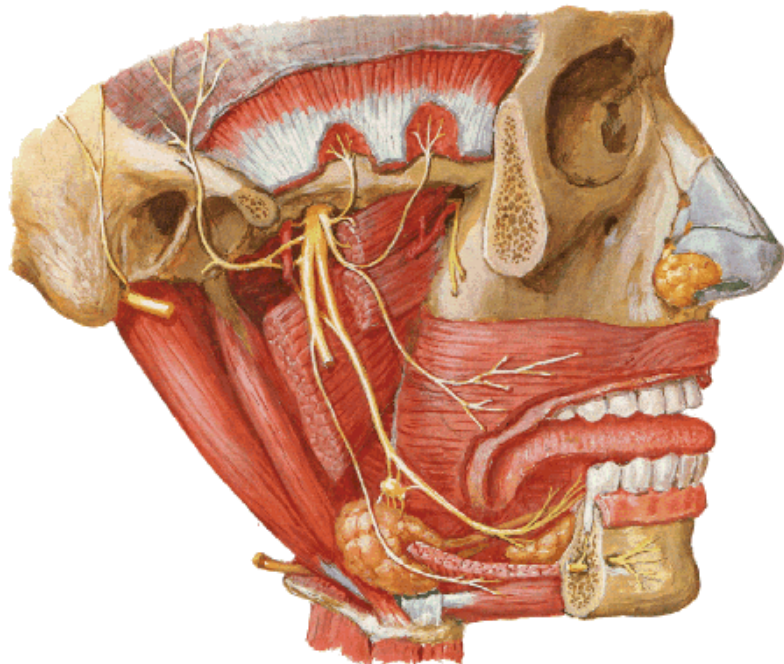
FOSSA INFRATEMPORALIS - l.dx.



n. mandibularis

somatomotor branches:

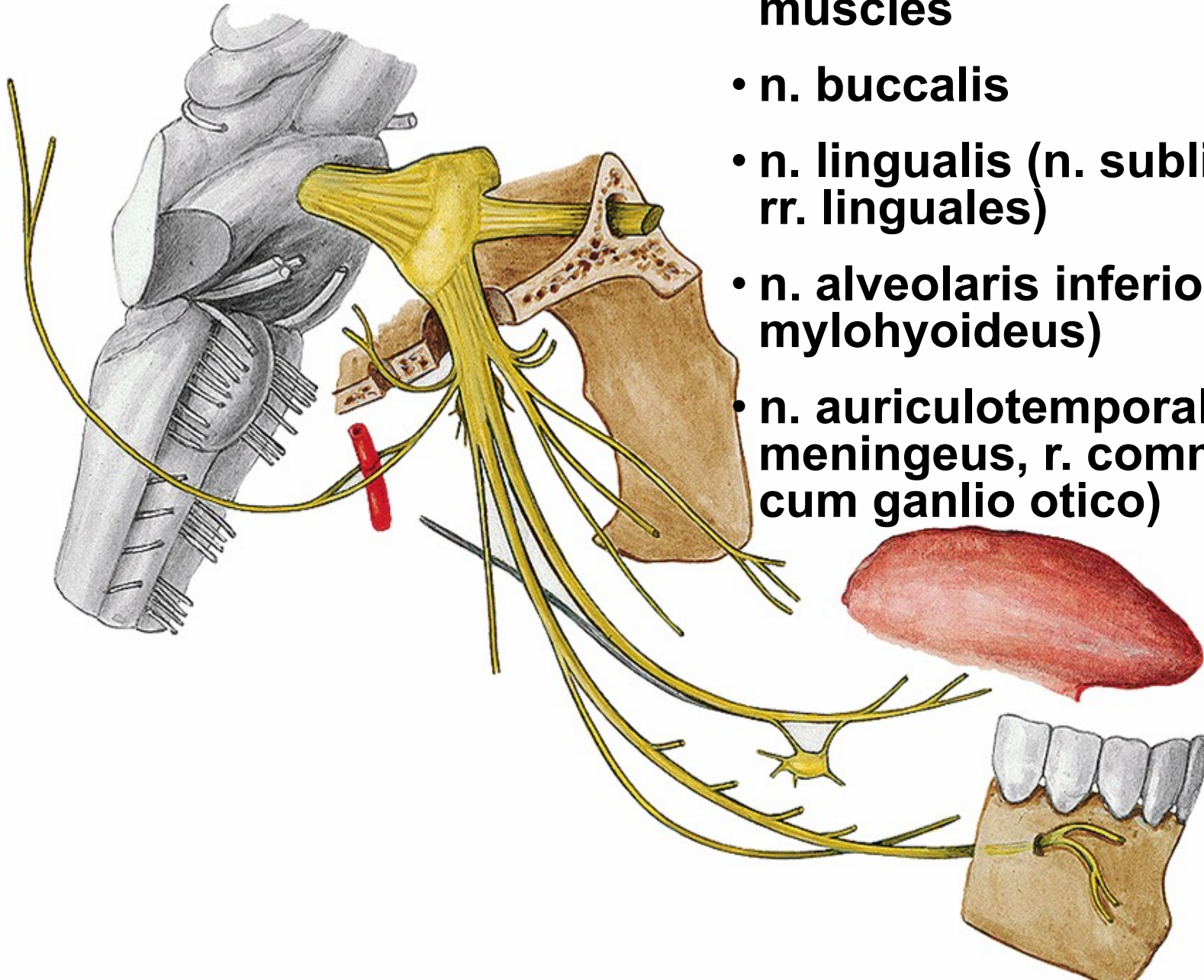
- Masticatory muscles
- suprahyoid muscles
- m. tensor veli palatini
- m. tensor tympani



somatosensory branches:

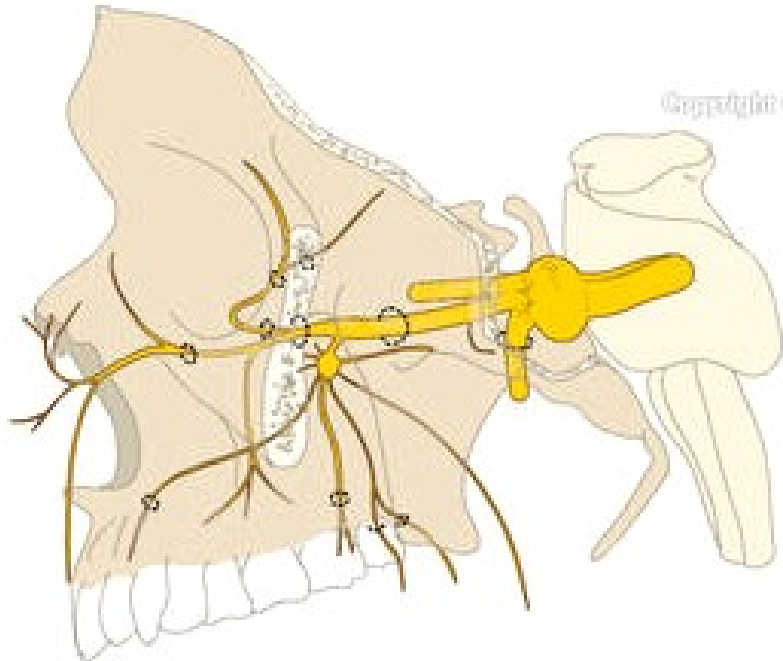
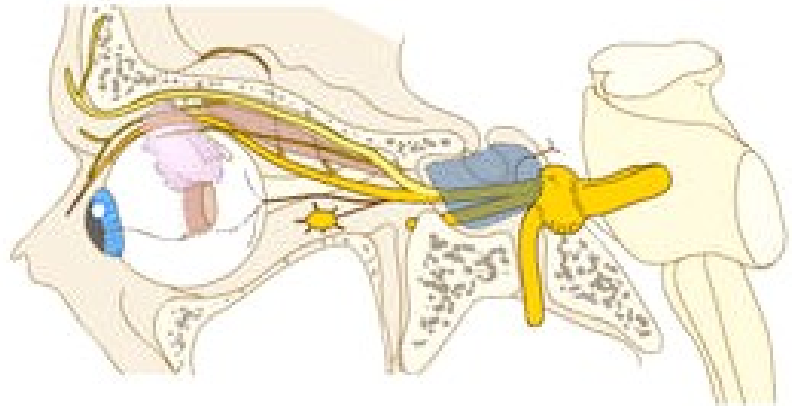
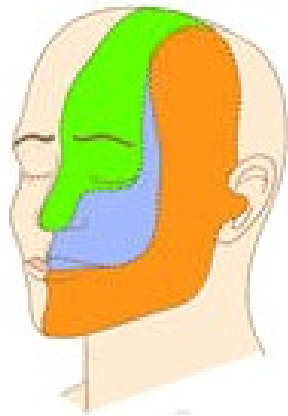
- n. alveolaris inferior (teeth)
- n. lingualis (mucosa of bottom of oral cavity, gingiva, front 2/3 of tongue)
 - chorda tympani from n. VII
- n. buccalis (skin and mucosa of cheek)
- n. auriculotemporalis (auricle and temporal region)
- **parasympathetic** ganglion submandibulare + ganglion oticum (small salivary glands of tongue and bottom of oral cavity)
- n. mentalis – *sensitivity to palpation*





- **Branches for masticatory muscles**
- **n. buccalis**
- **n. lingualis (n. sublingualis, rr. linguales)**
- **n. alveolaris inferior (n. mylohyoideus)**
- **n. auriculotemporalis (r. meningeus, r. communicans cum ganlio otico)**





Copyright © Elsevier

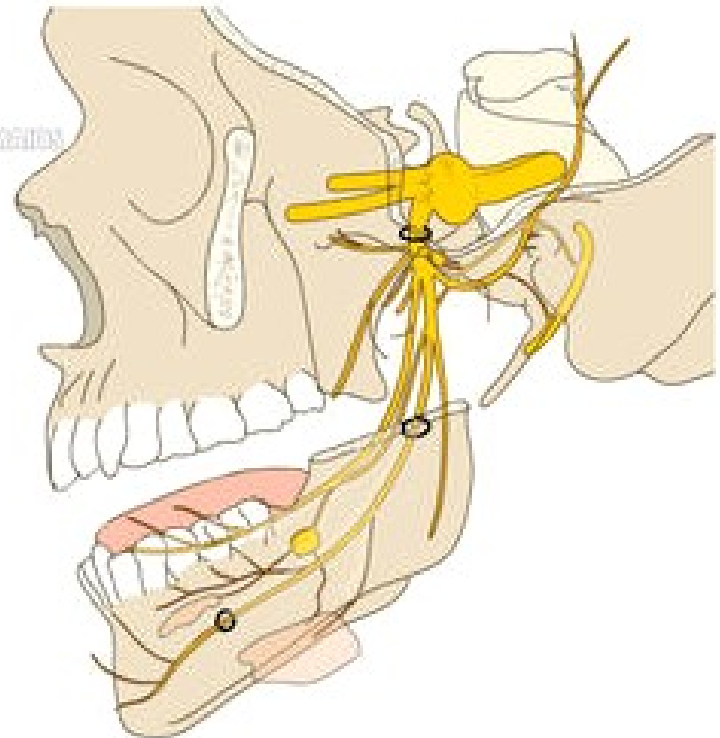
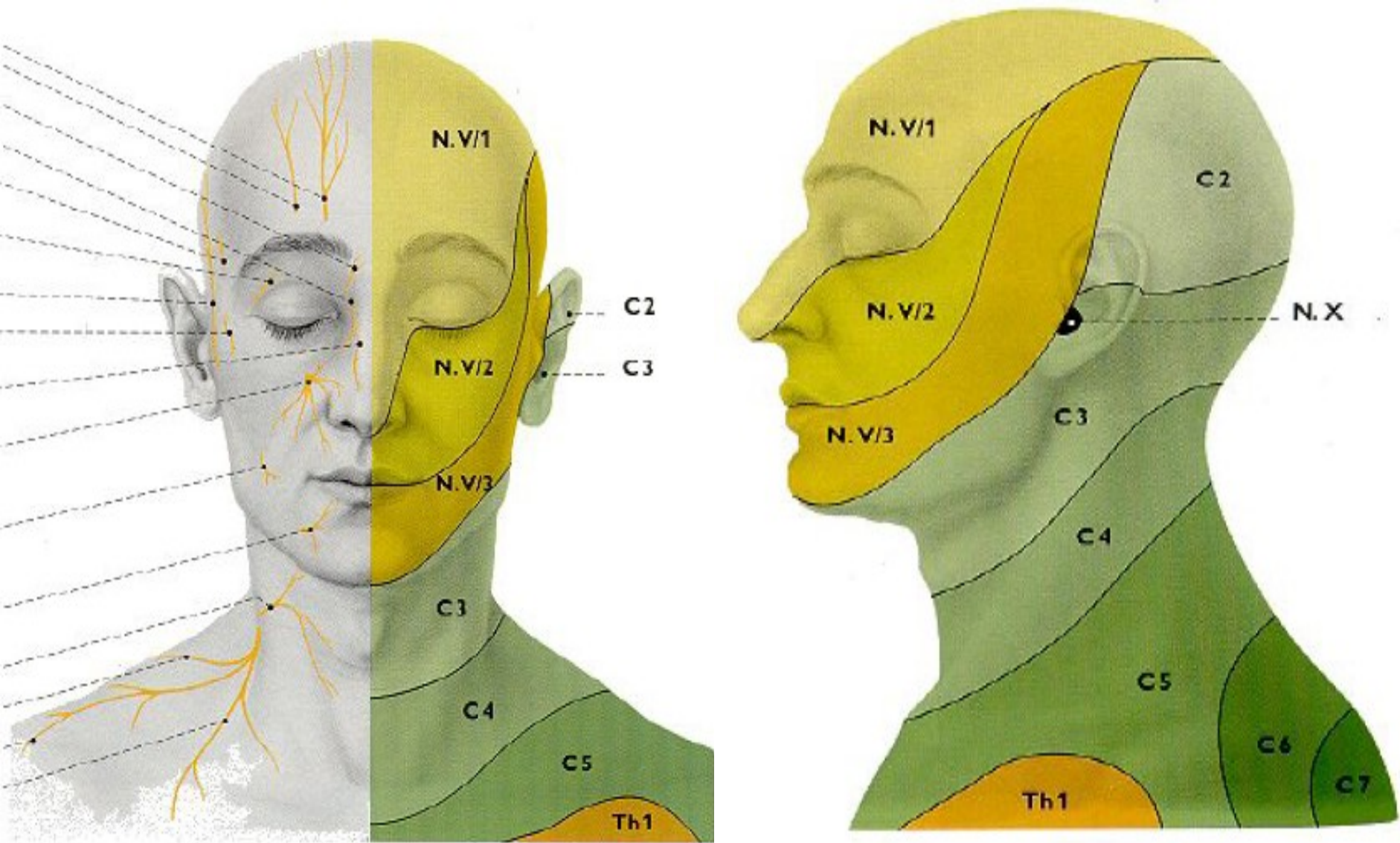
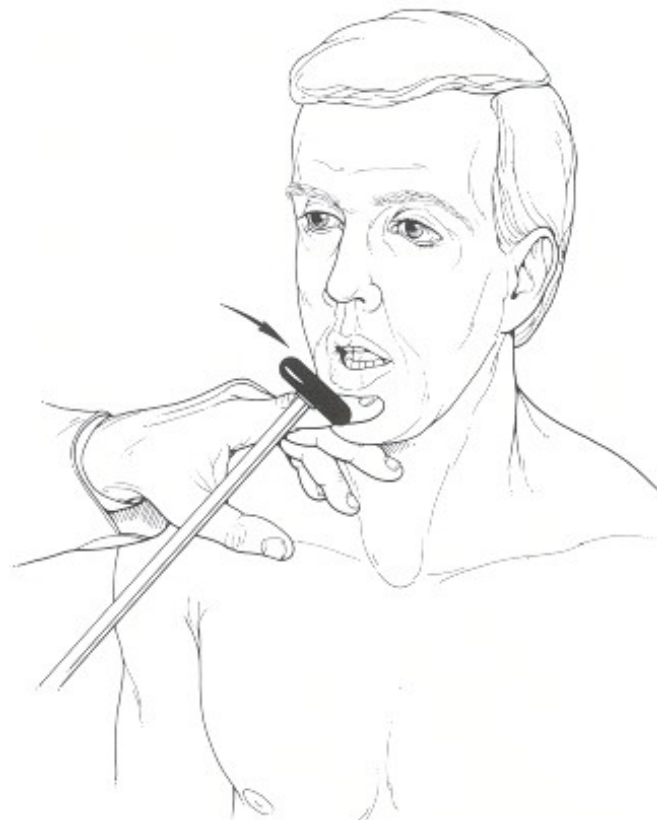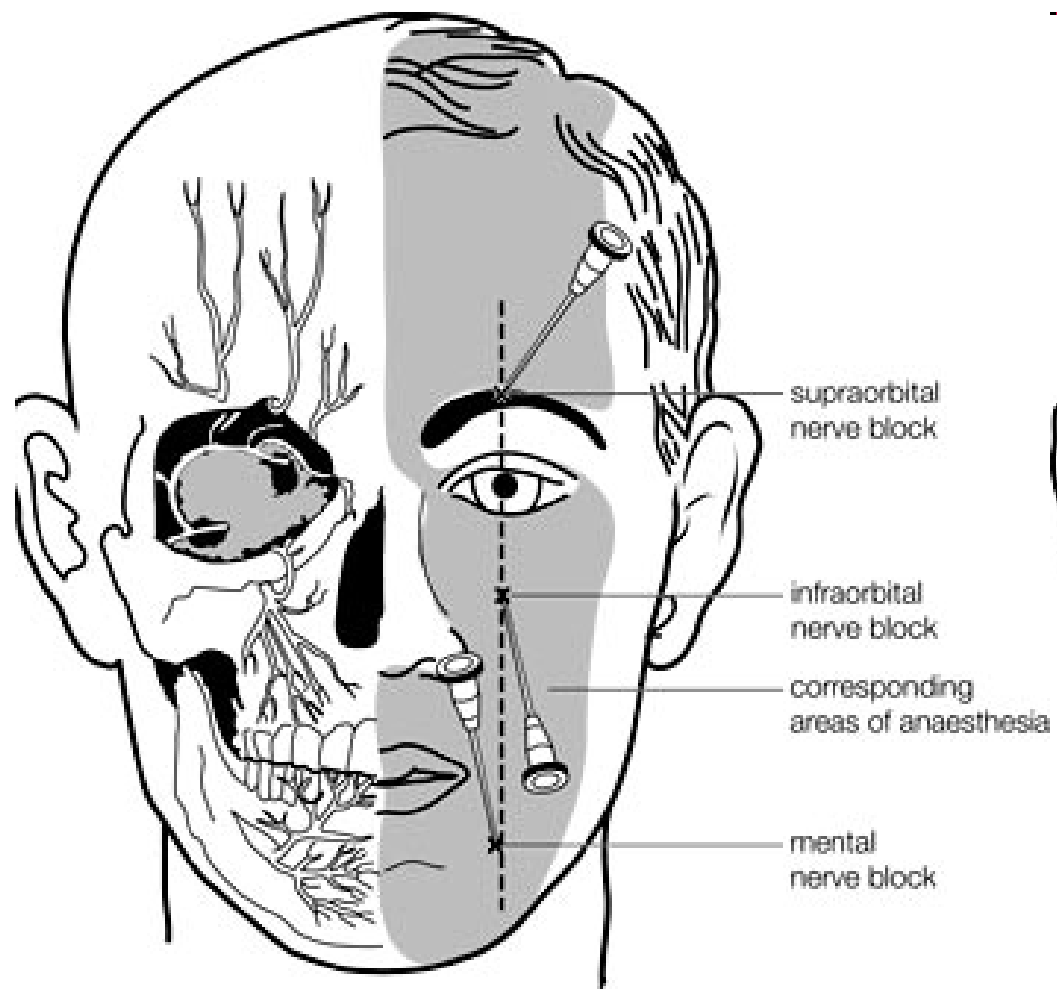


Illustration : A. Micheau, MD

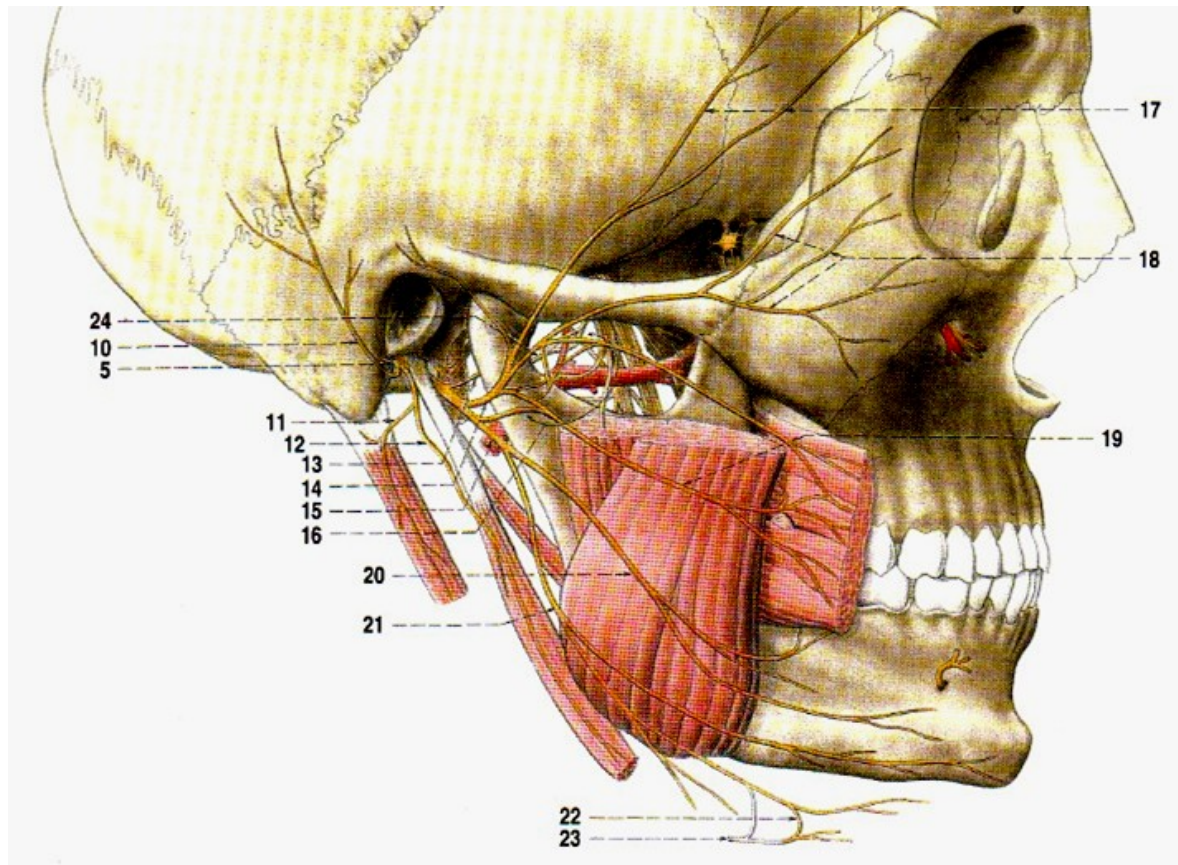


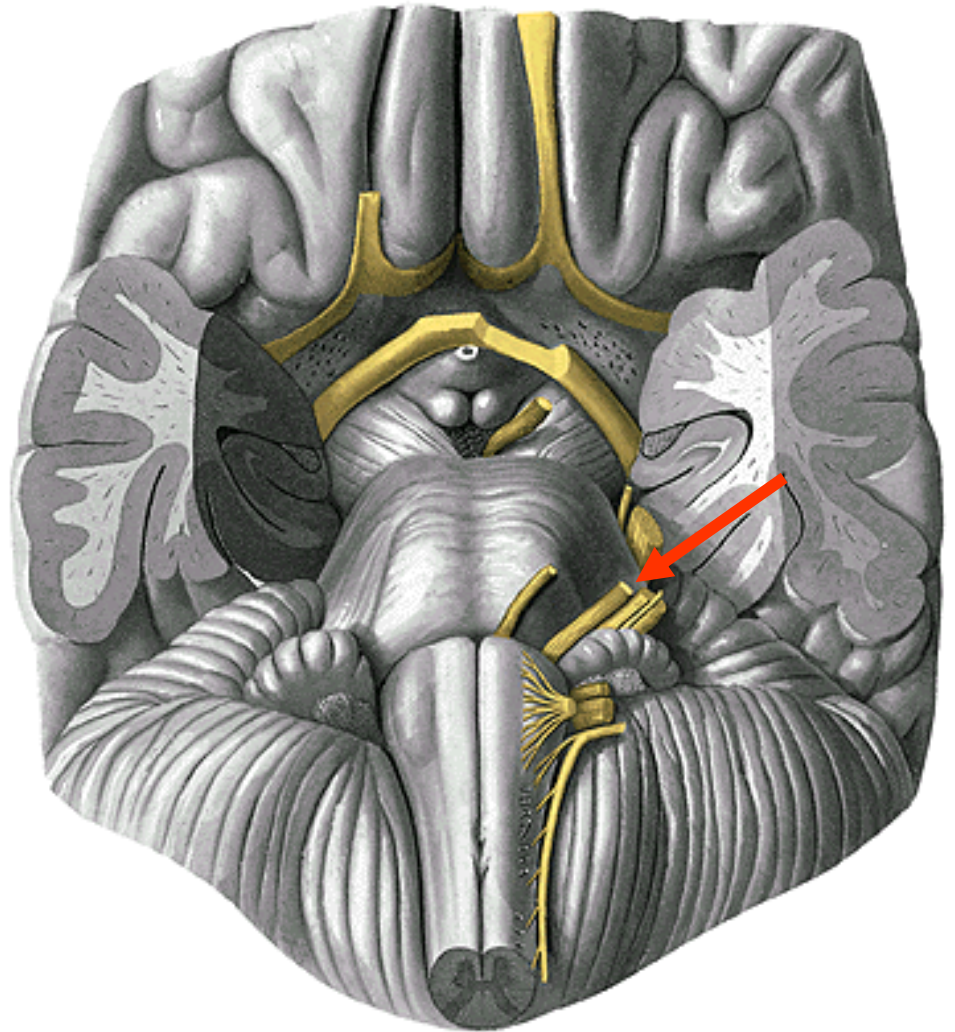
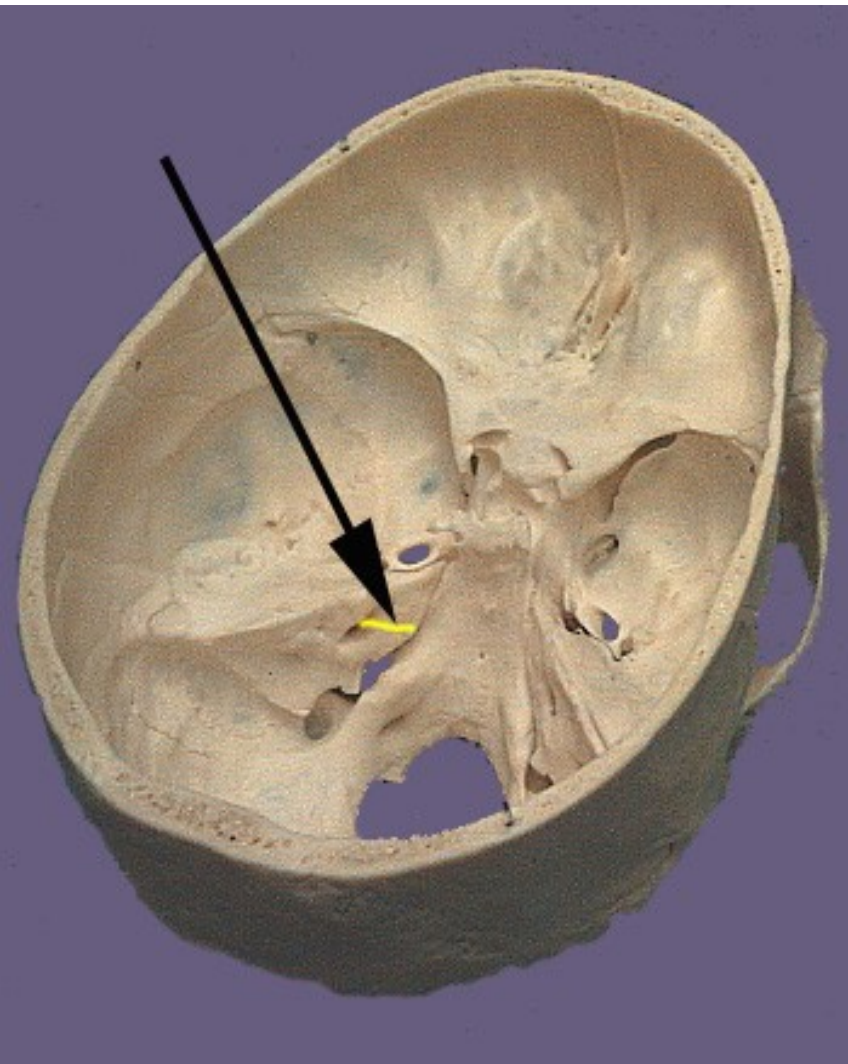




VII. = The facial nerve

- mixed nerve
- 2 basis
 - n. facialis – motor (facial muscles)
 - n. intermedius - visceromotor + taste + sensory





n. VII.

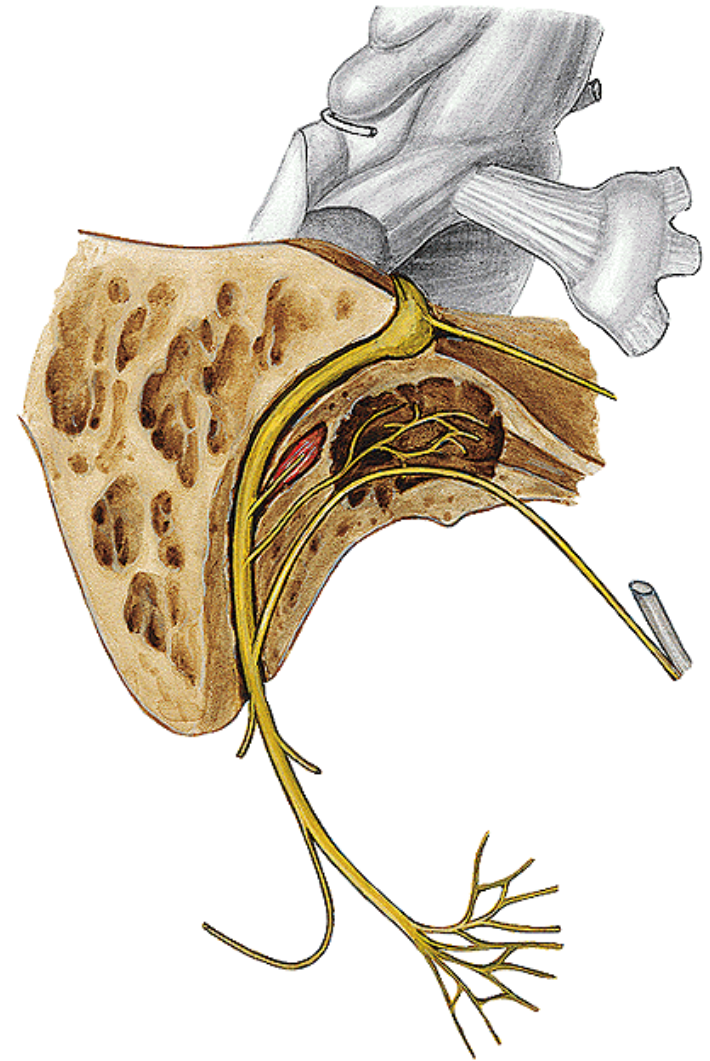


inside canalis nervi facialis

- n. petrosus major – *parasympathetic* into ggl. pterygopalatinum
- n. stapedius – m. stapedius
- chorda tympani
 - *parasympathetic* into glandula submandibularis
 - *taste* → into front 2/3 of tongue

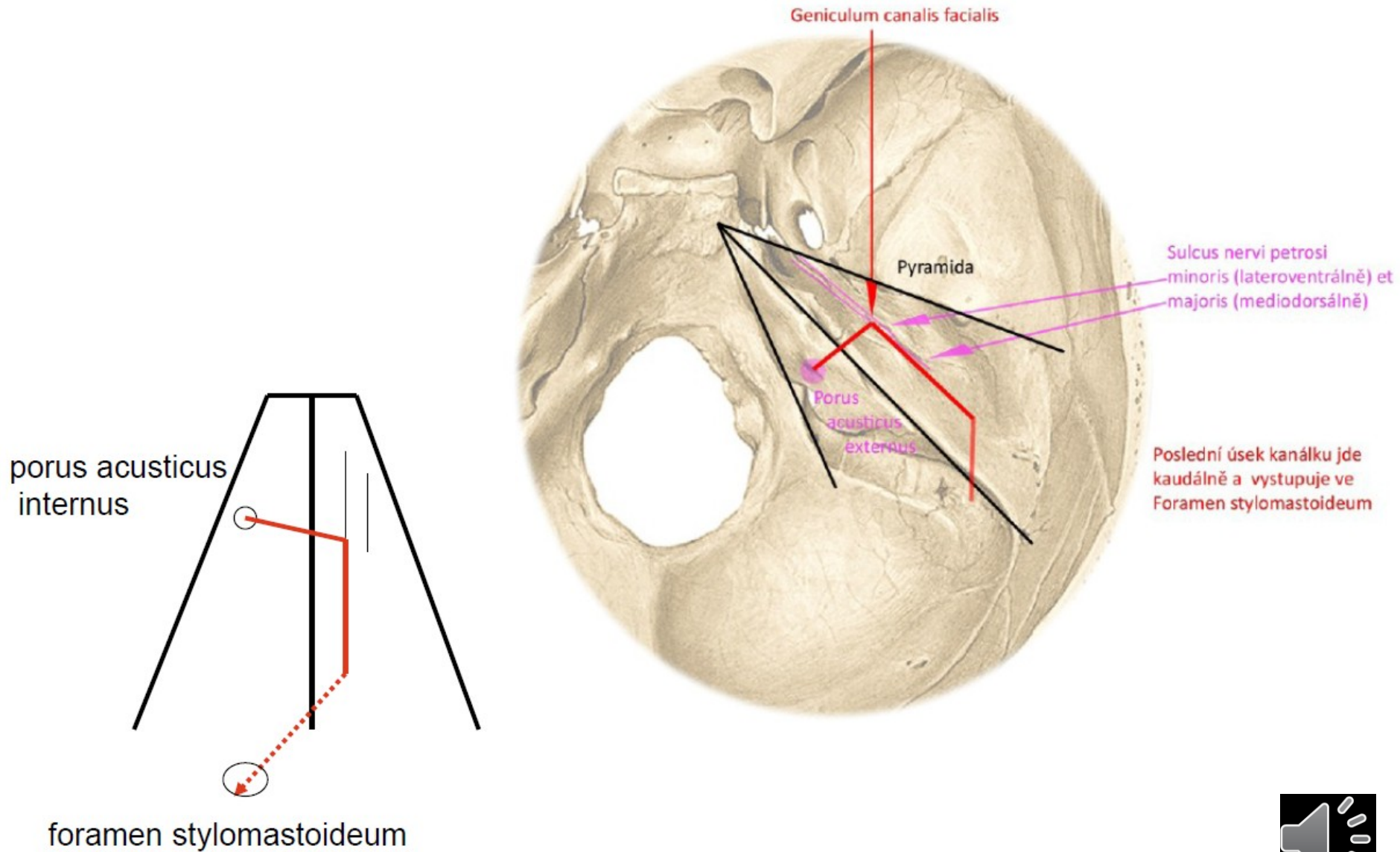
outside the skull

- n. auricularis posterior – *motor nerve* to rudimentary muscles of auricle
- nn. into m. stylohyoideus + venter post. m. digastrici
- plexus intraparotideus (facial muscles: rr. temporales, rr. zygomatici, rr. bucales, r. marginalis mandibulae, r. colli)



PRŮBĚH CANALIS NERVI FACIALIS V PYRAMIDĚ

Pohled shora

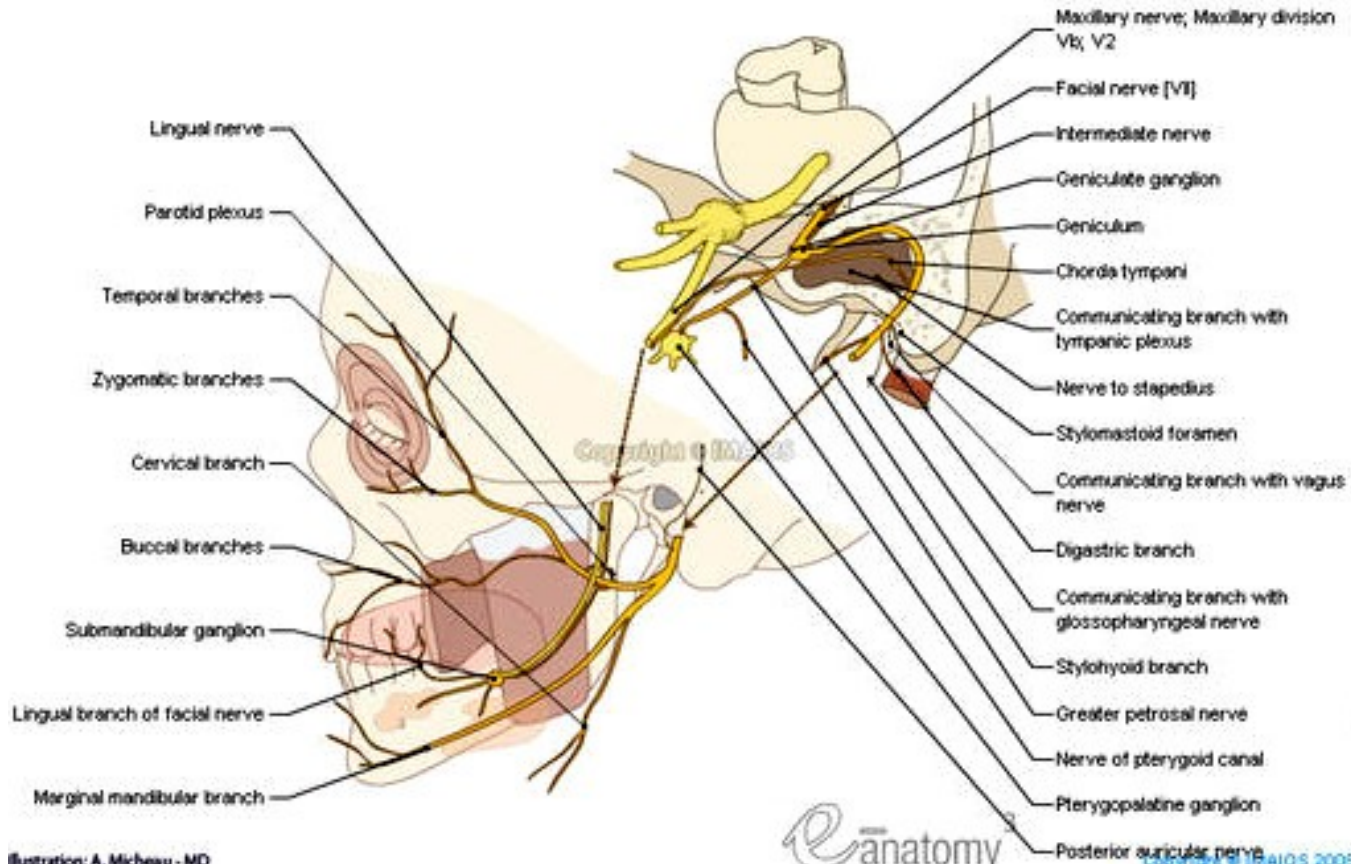


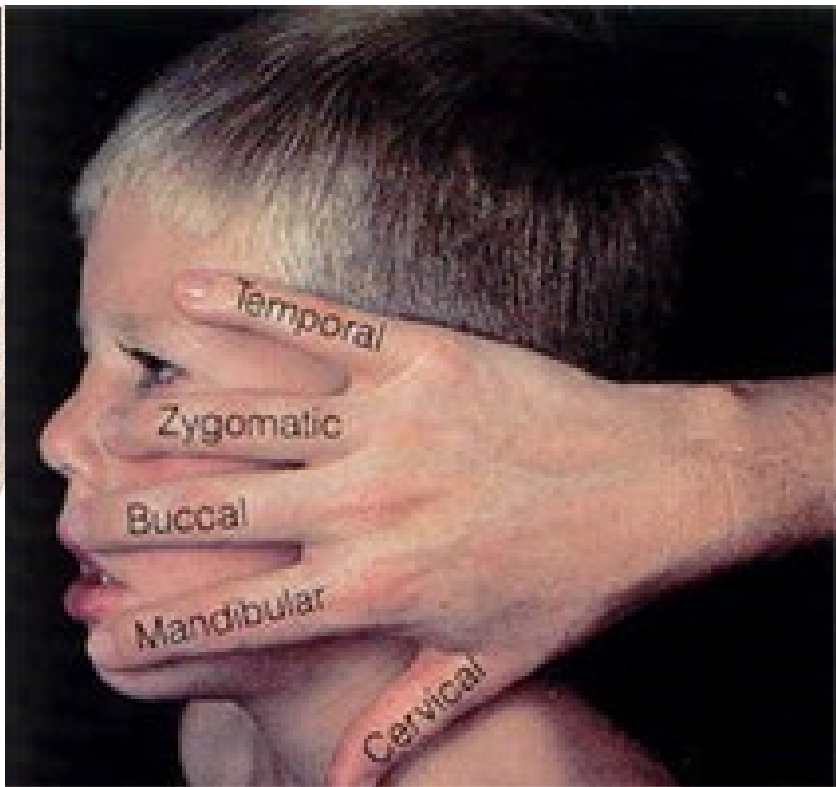
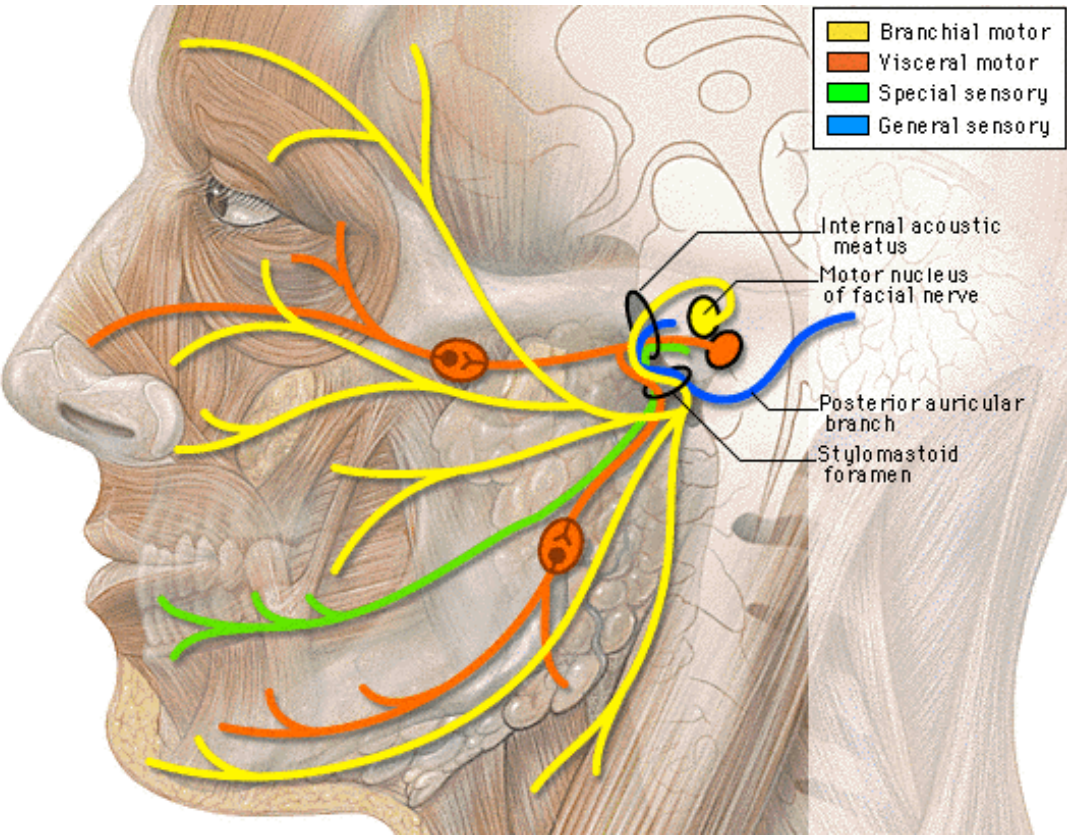
somatosensory – auricle and external auditory canal

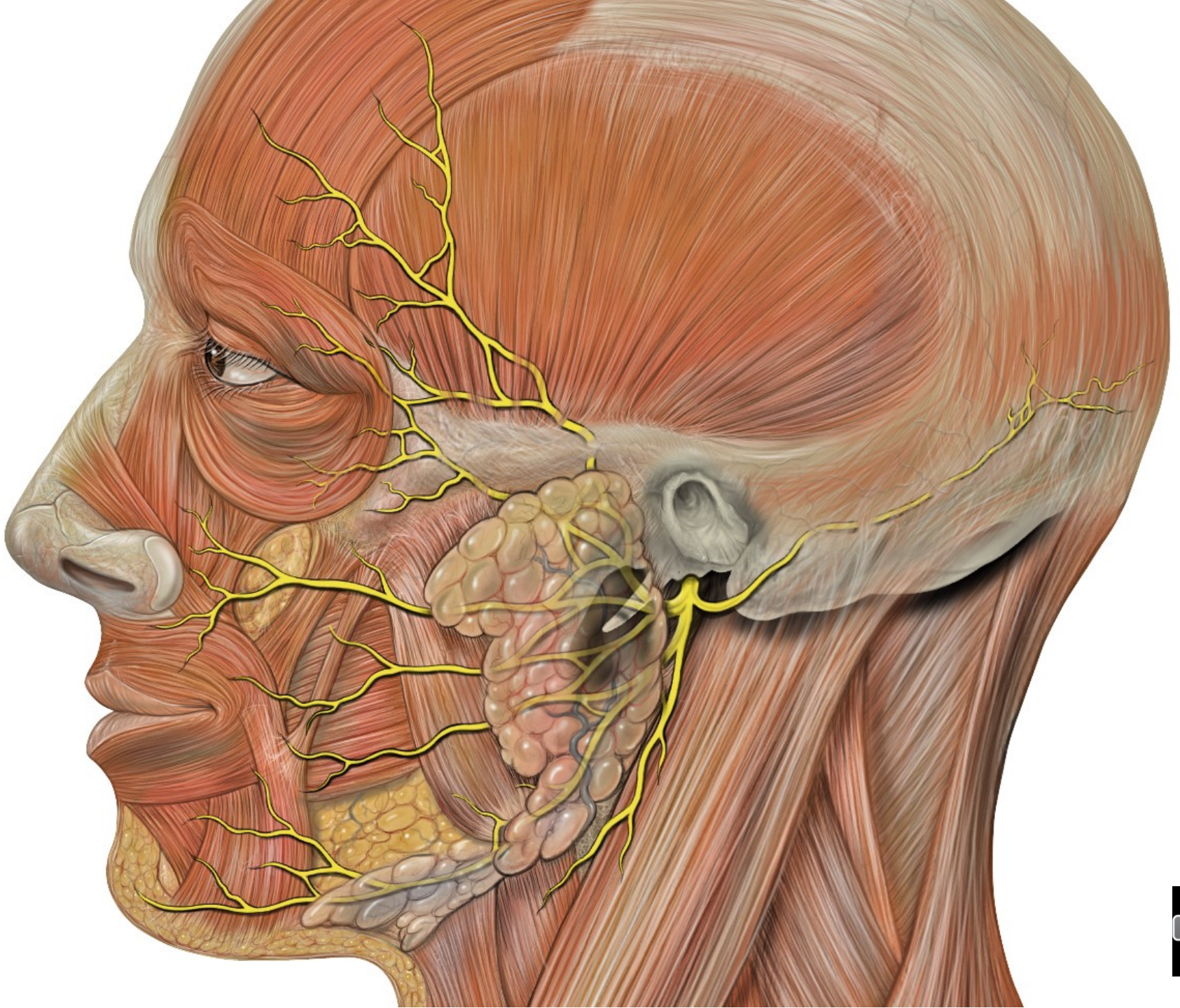
sensory – from gustatory cells of front 2/3 of tongue

somatomotor – facial muscles, musculus platysma, musculus stapedius, m.stylohyoideus, m.digastricus- posterior belly

visceromotor – parasympathetic fibres for secretion of lacrimal gland, submandibular and sublingual gland

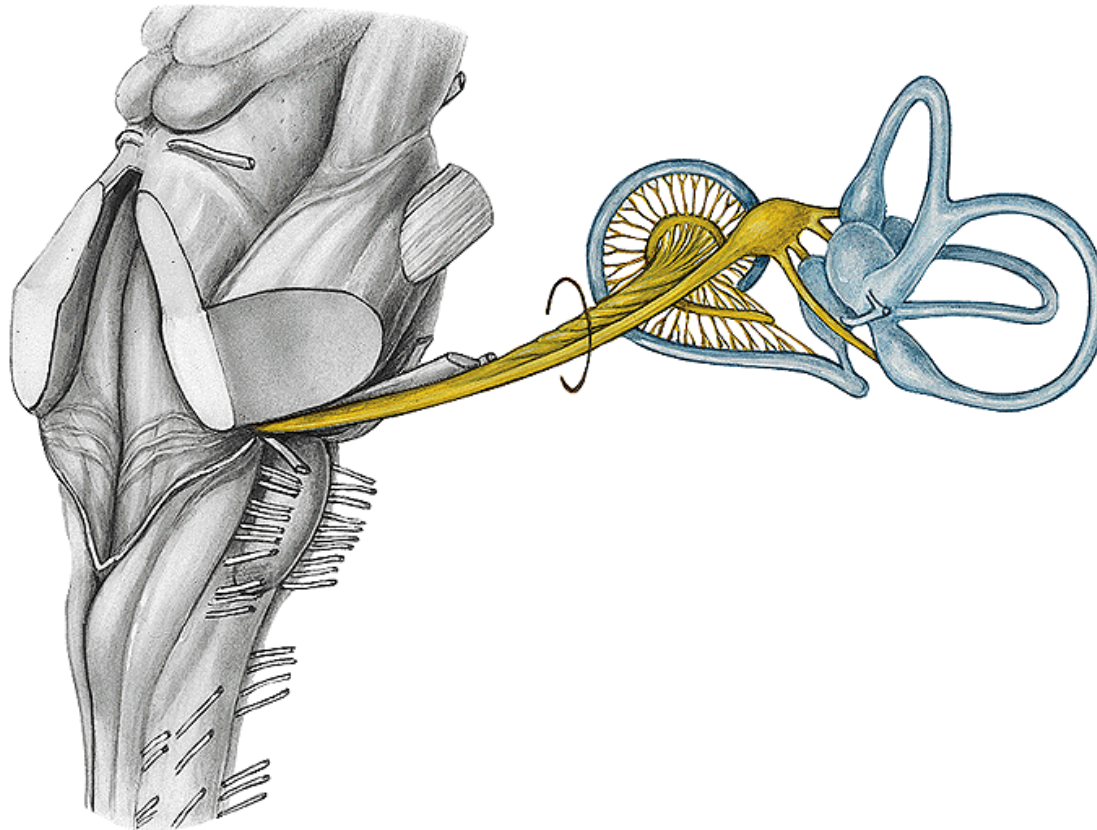


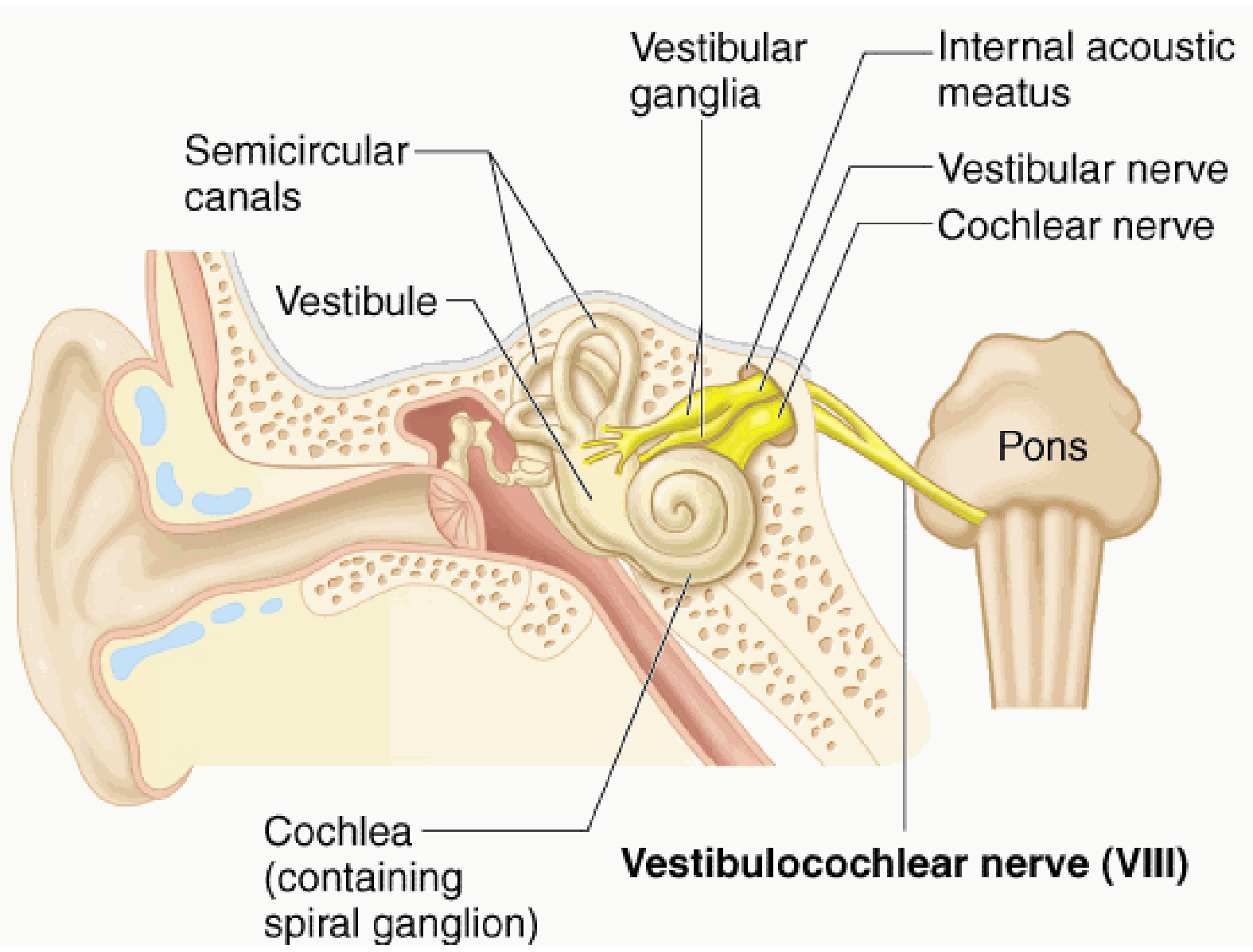




VIII. – The vestibulocochlear nerve

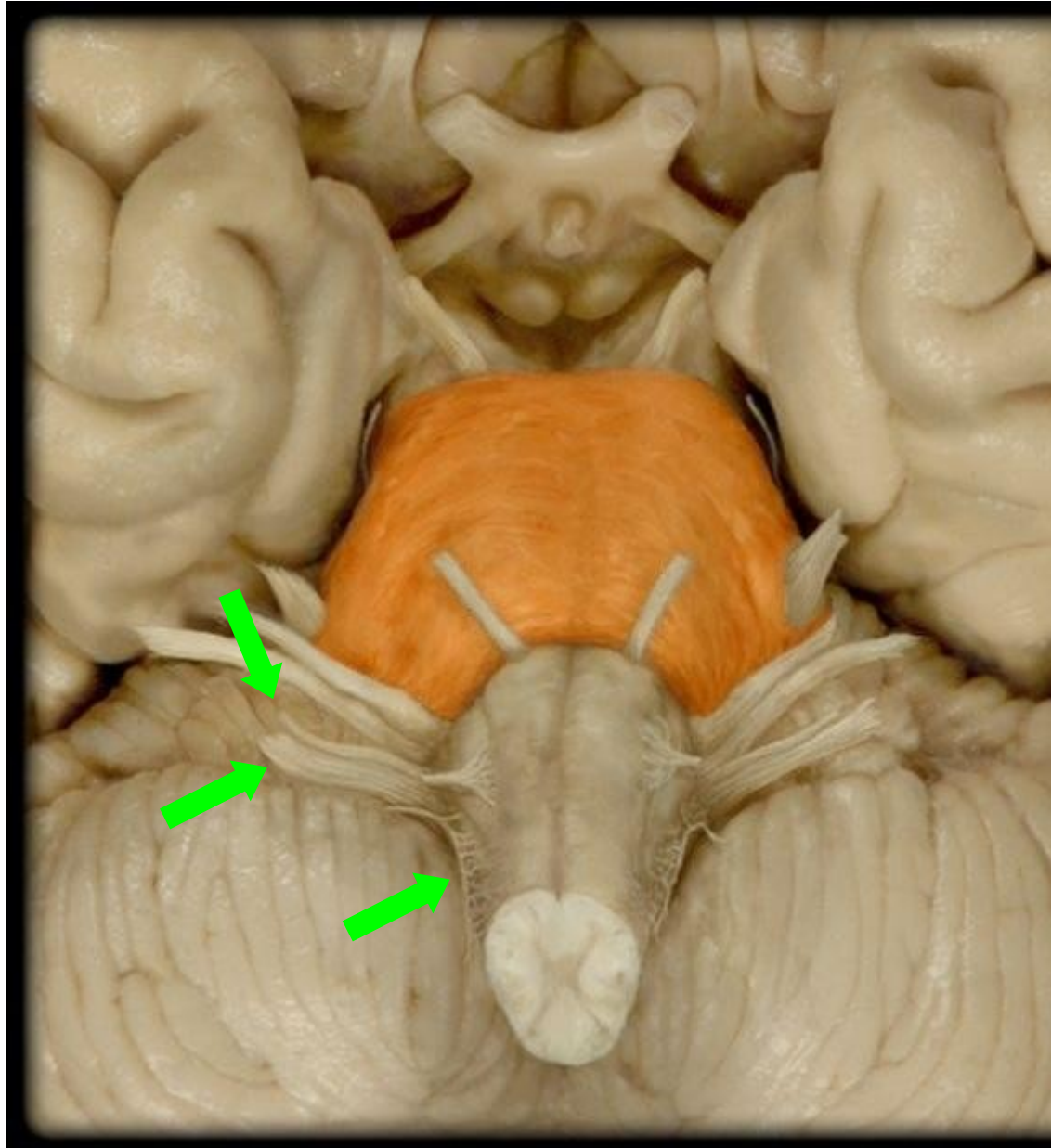
- *special **sensory nerve**– hearing + balance*





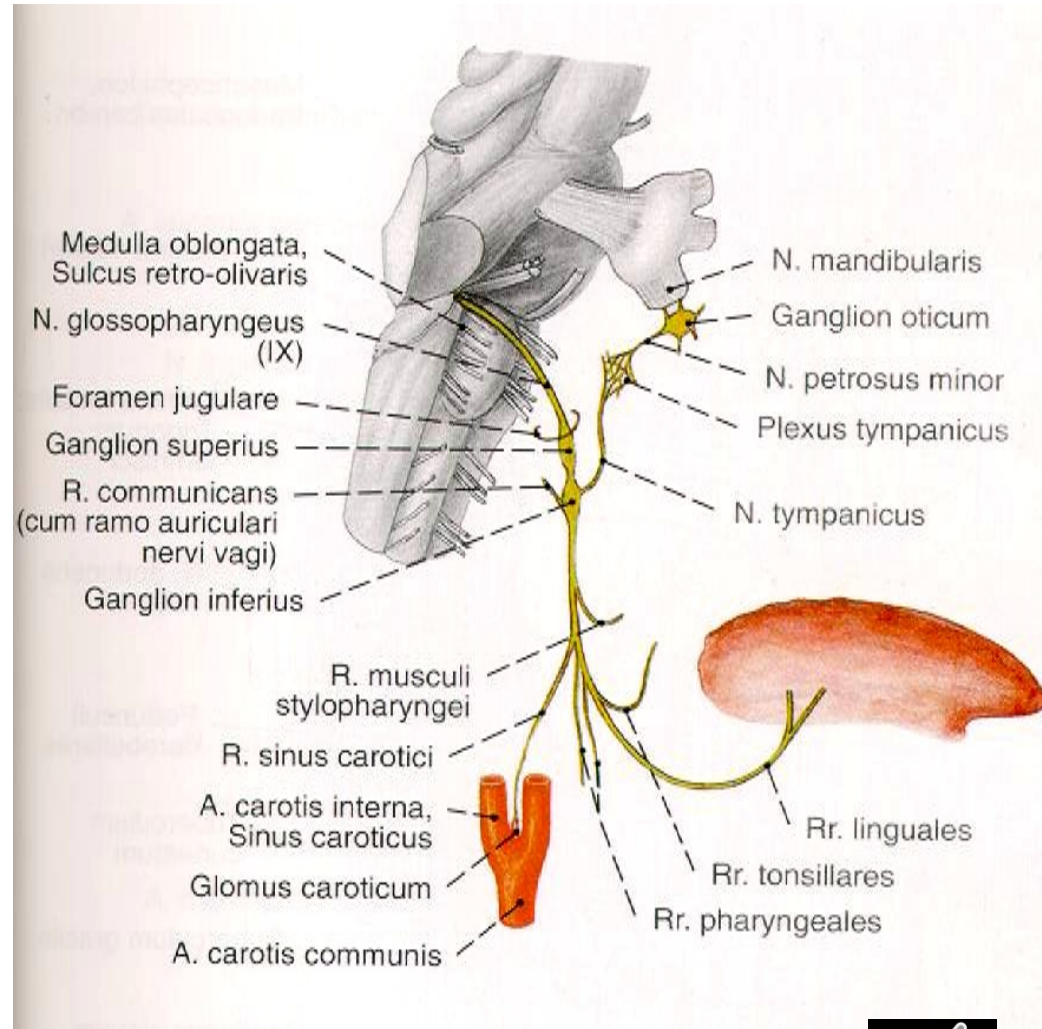
Common output of

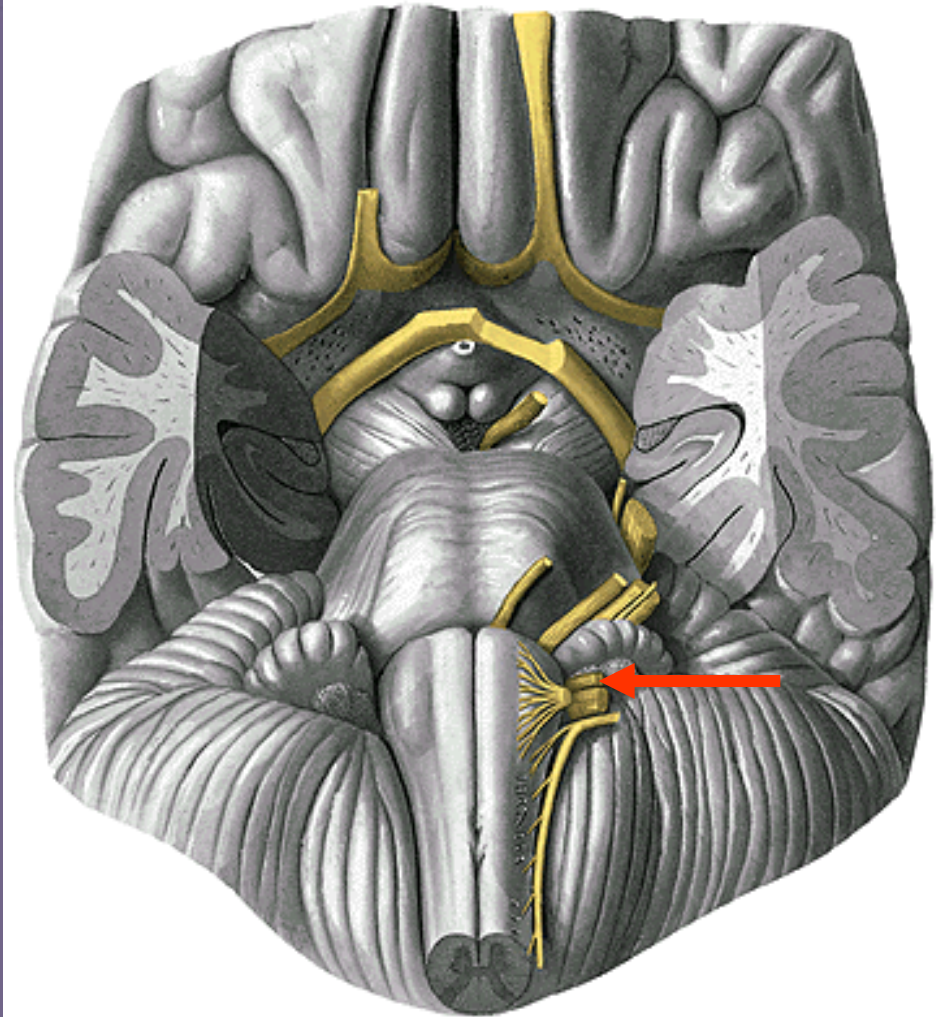
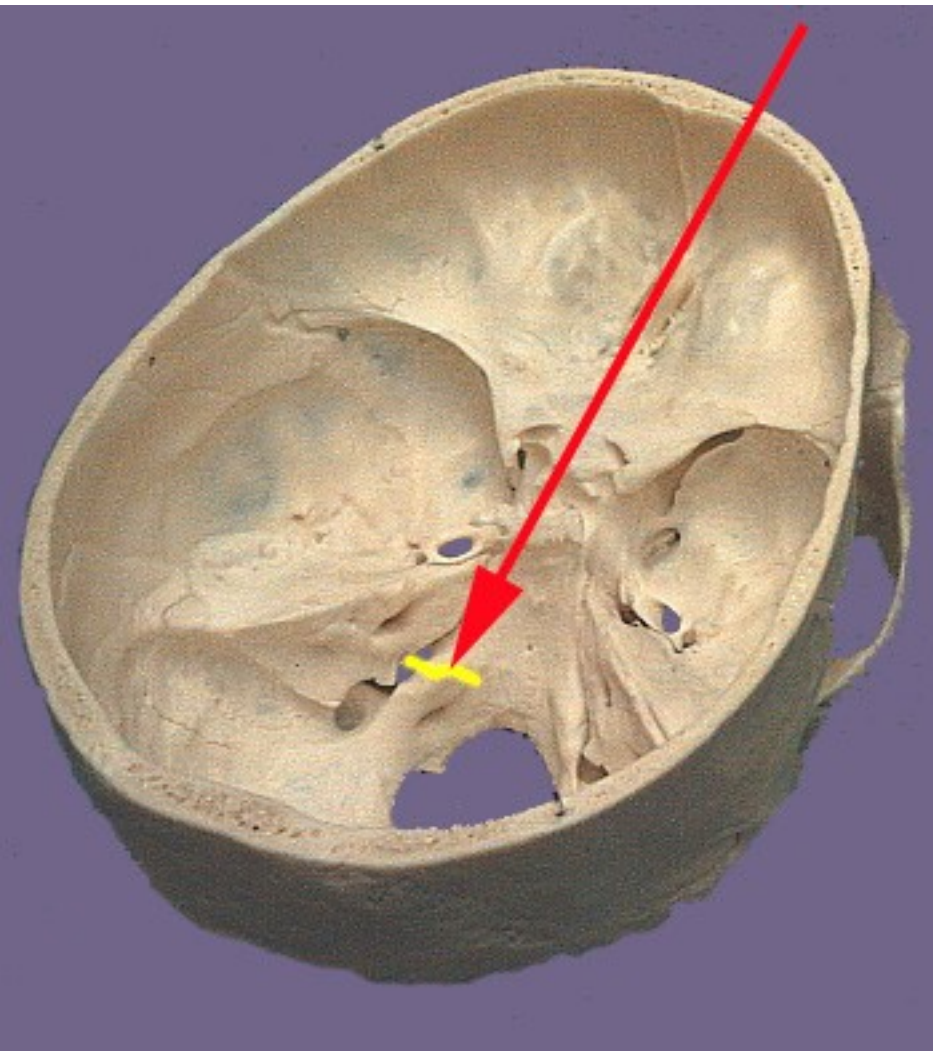
- n.IX., X., XI.



IX. The glossopharyngeal nerve

- Arises from the medulla oblongata
- Passes through foramen jugulare
- Branches out under the base of skull
- Branches: n. tympanicus → n. petrosus minor, rr. pharyngei, tonsillares, linguales



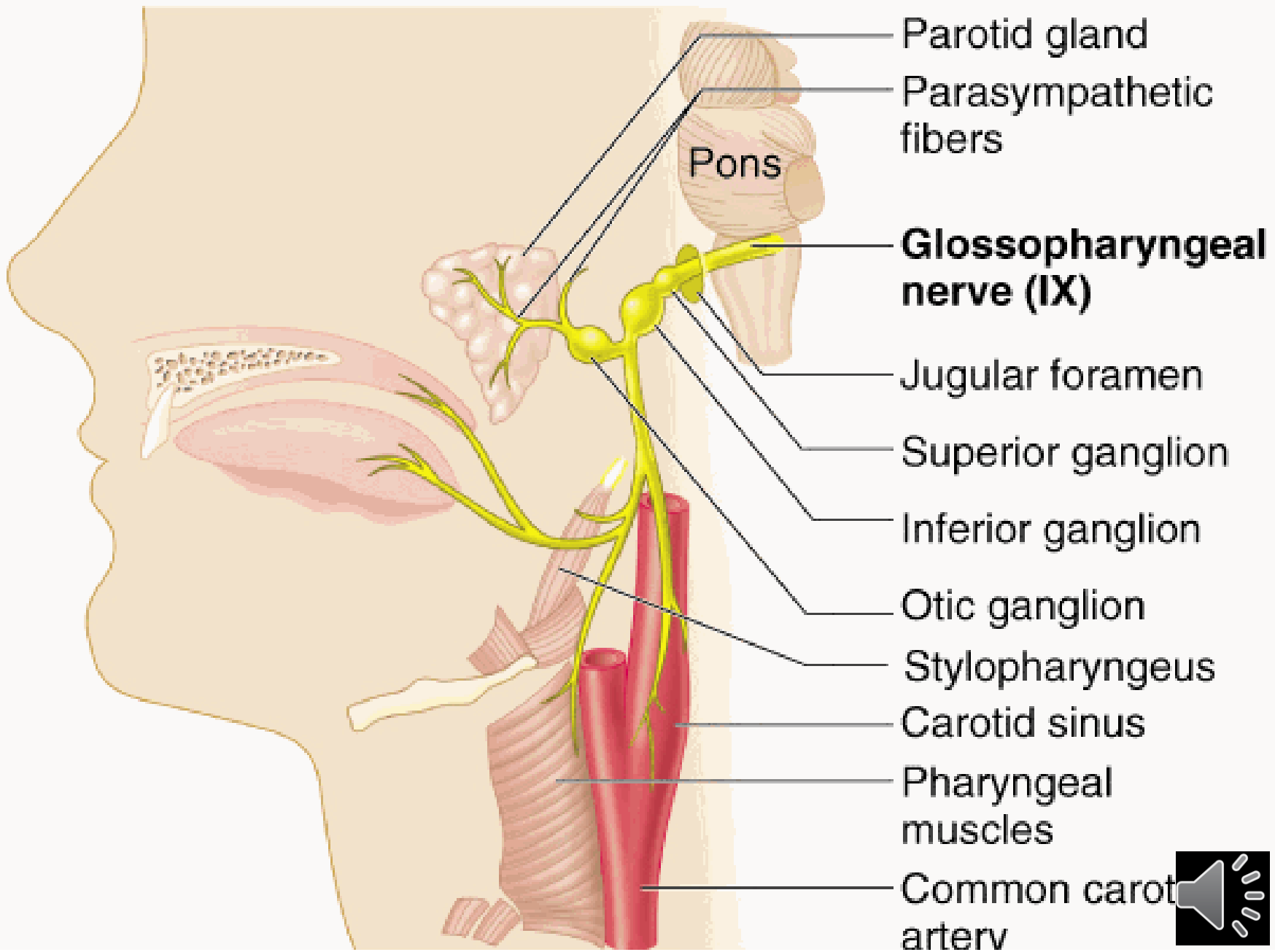


n. IX.



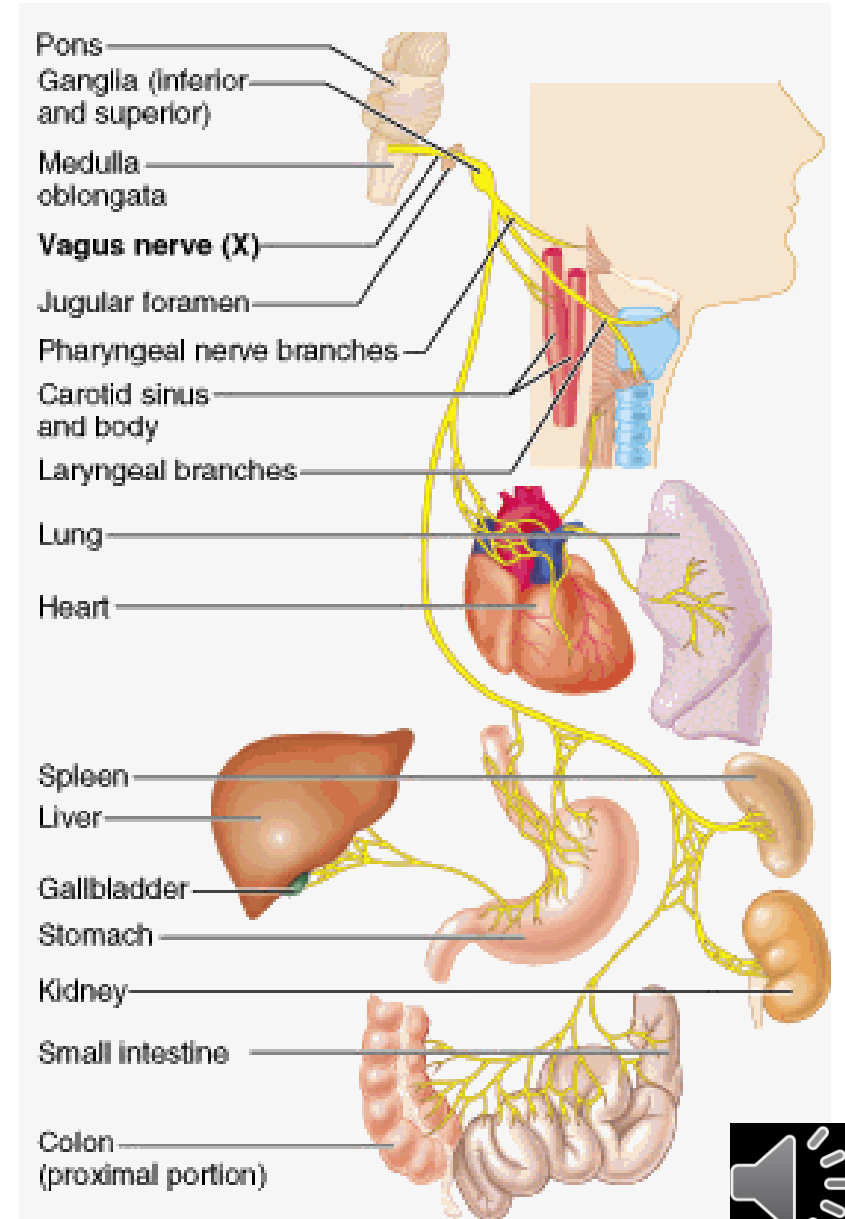
• **Motor innervation:** soft palate muscles (except tensor palatini)

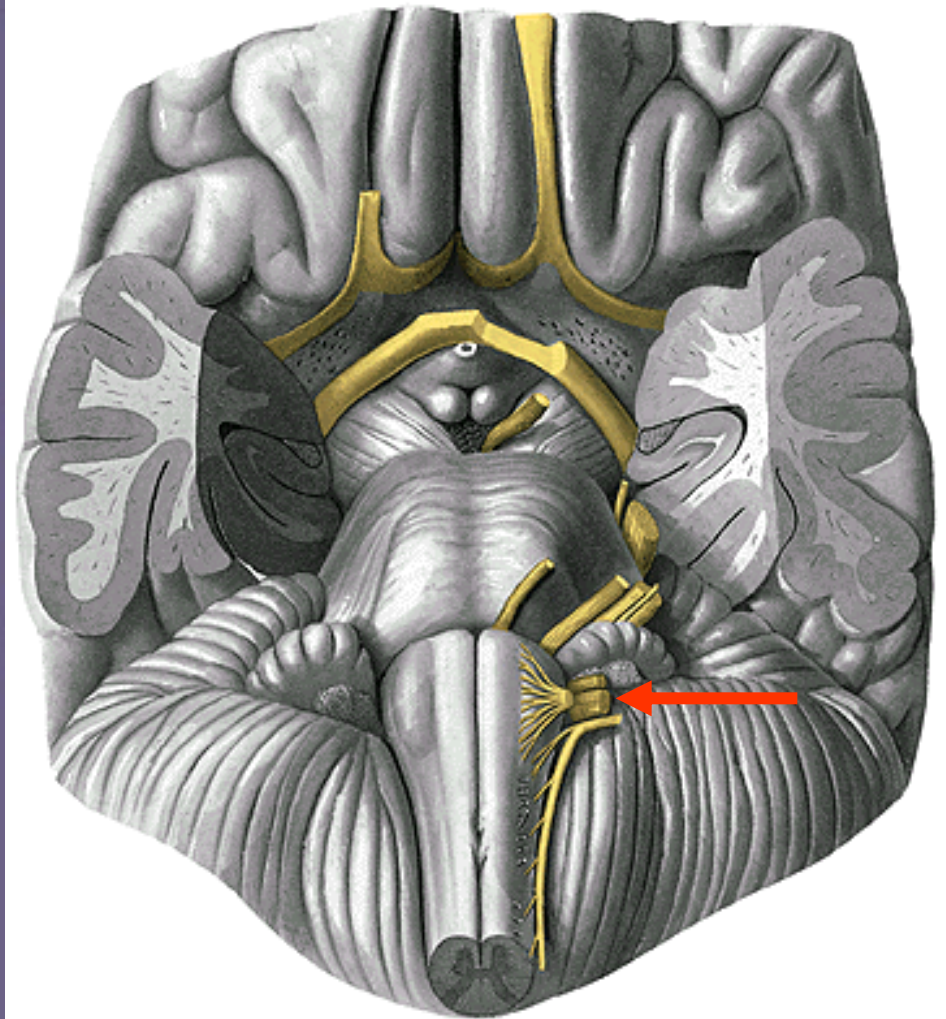
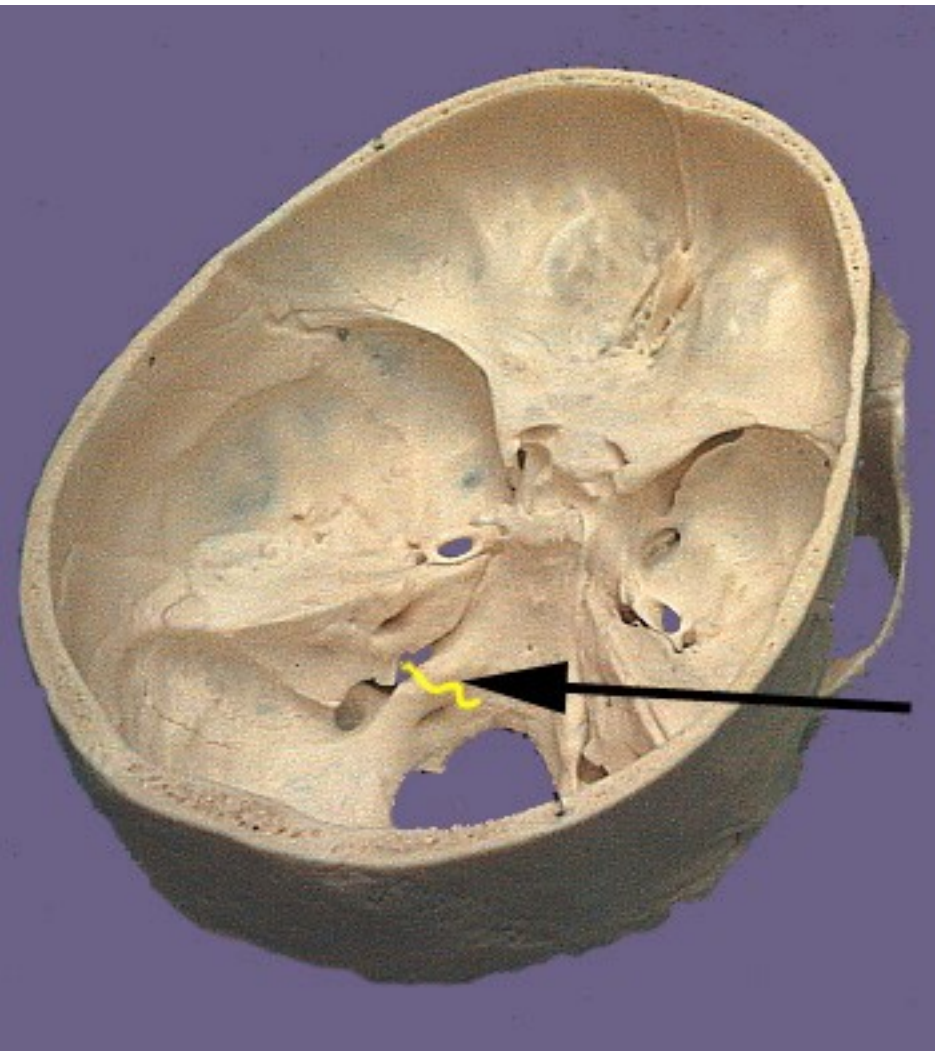
- S
- F
- C
- S
- C



X. The vagus nerve

- arises from medulla oblongata
- Passes through foramen jugulare
- Descends caudally and passes together with arteria carotis interna (lower arteria carotis communis) and vena jugularis interna, it attaches to the esophagus and along it descends through thoracic cavity till abdominal cavity (in male till scrotum)





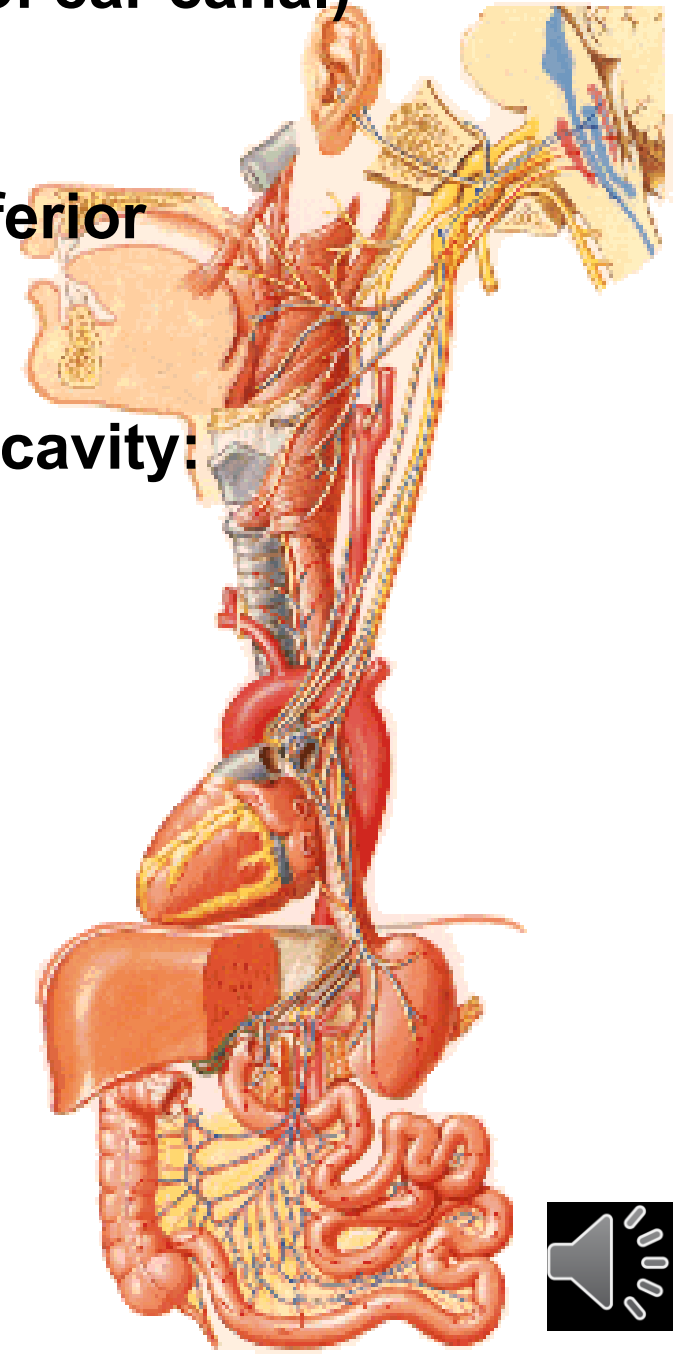
n. X.




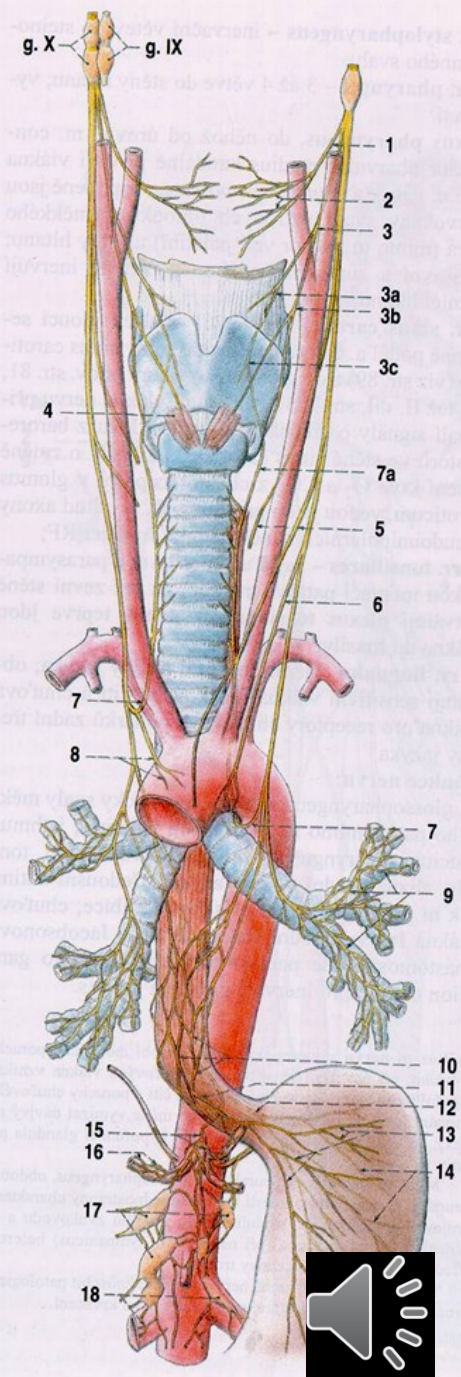
r. auricularis (sensory branch for wall of ear canal)
rr. pharyngei (muscles of pharynx)
n. laryngeus superior
n. laryngeus recurrens- n.laryngeus inferior
(muscles of larynx)

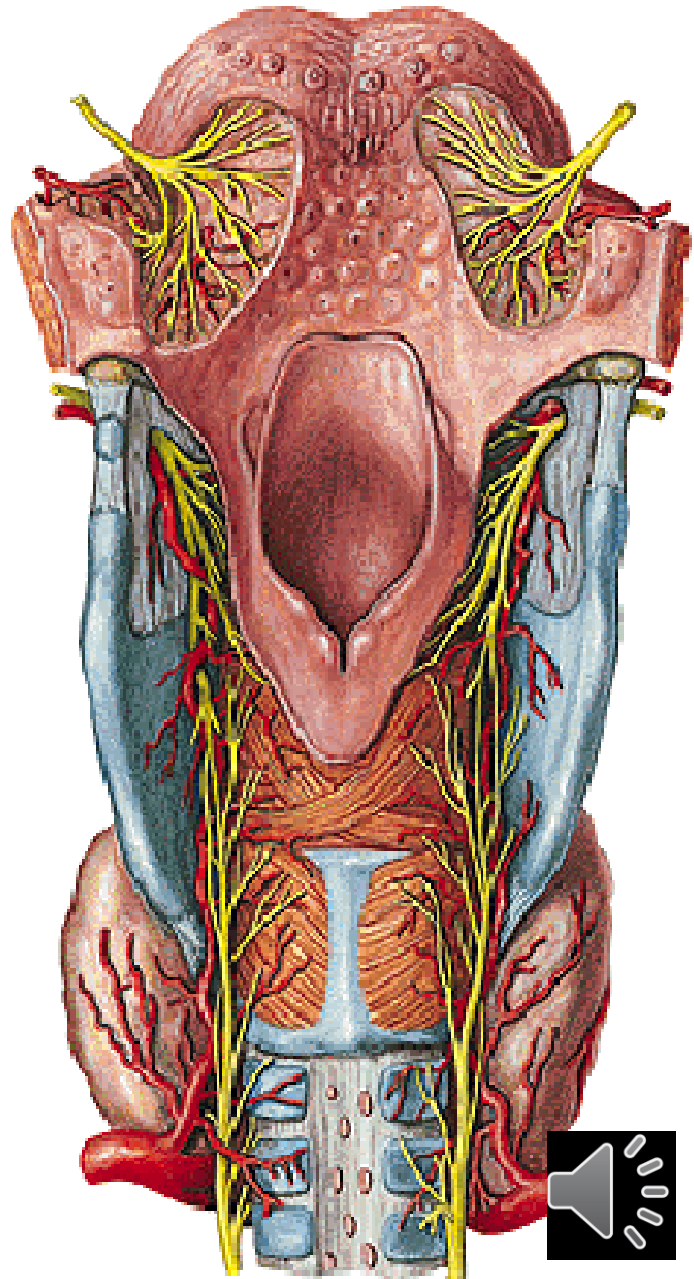
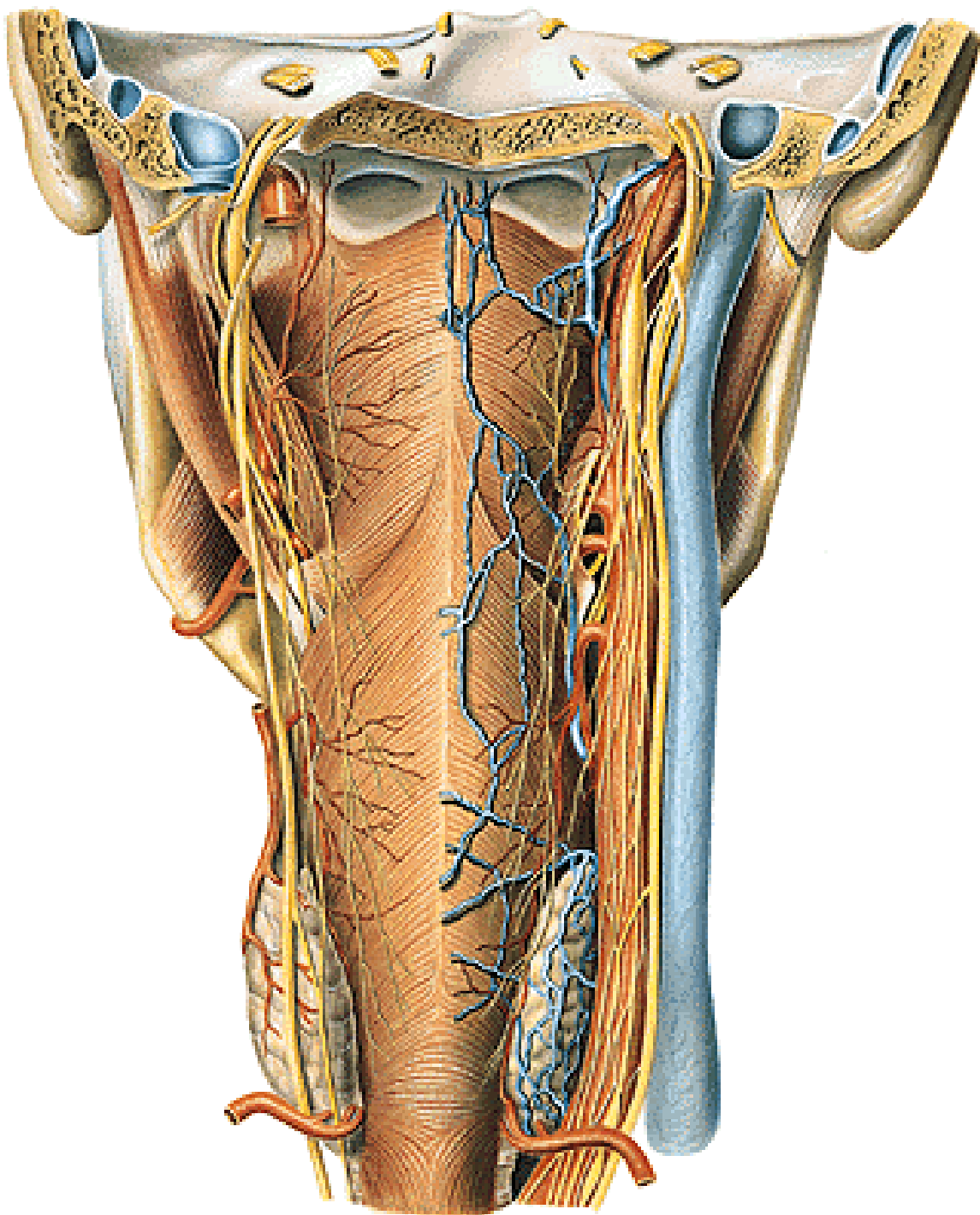
Organs within thoracic and abdominal cavity:


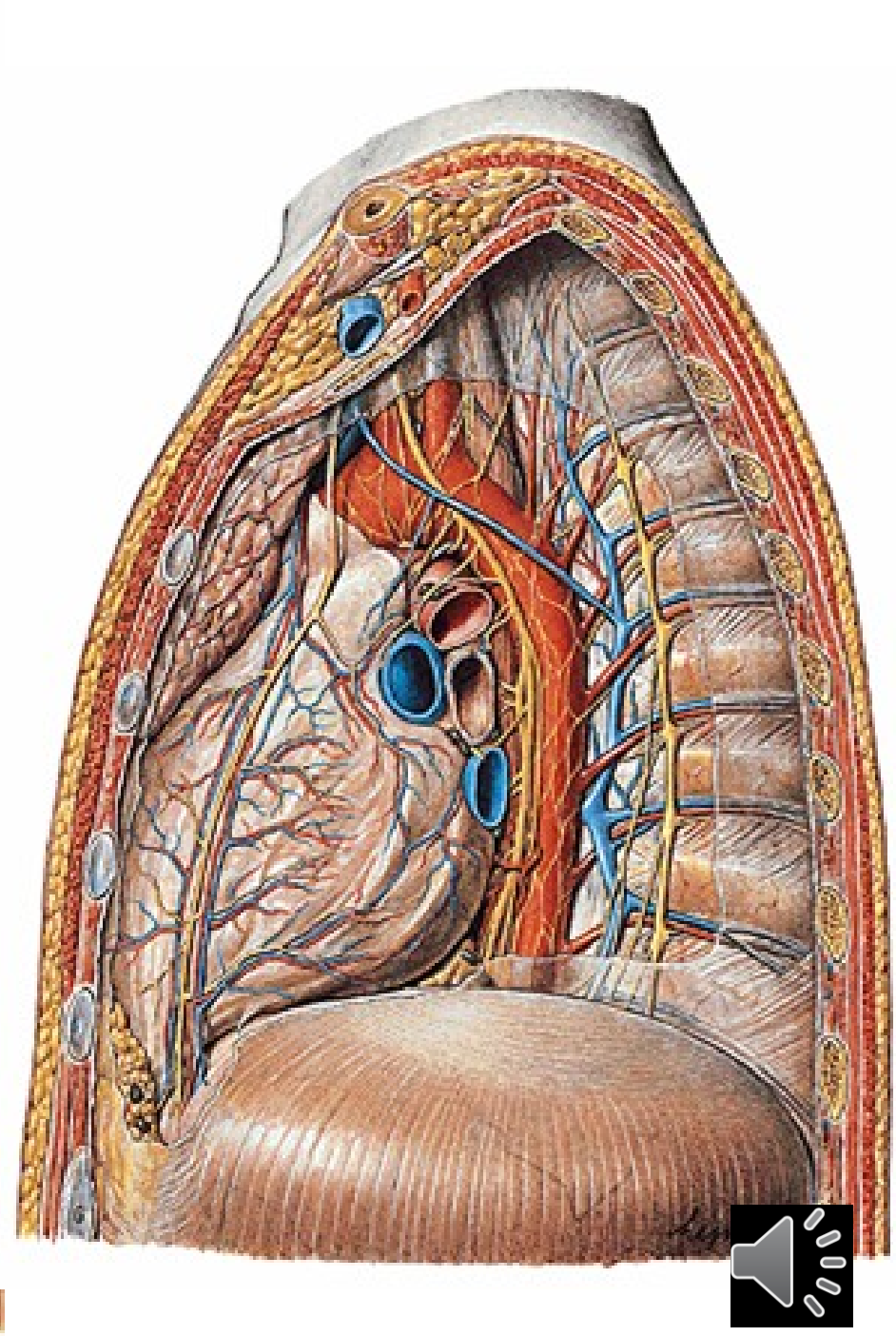
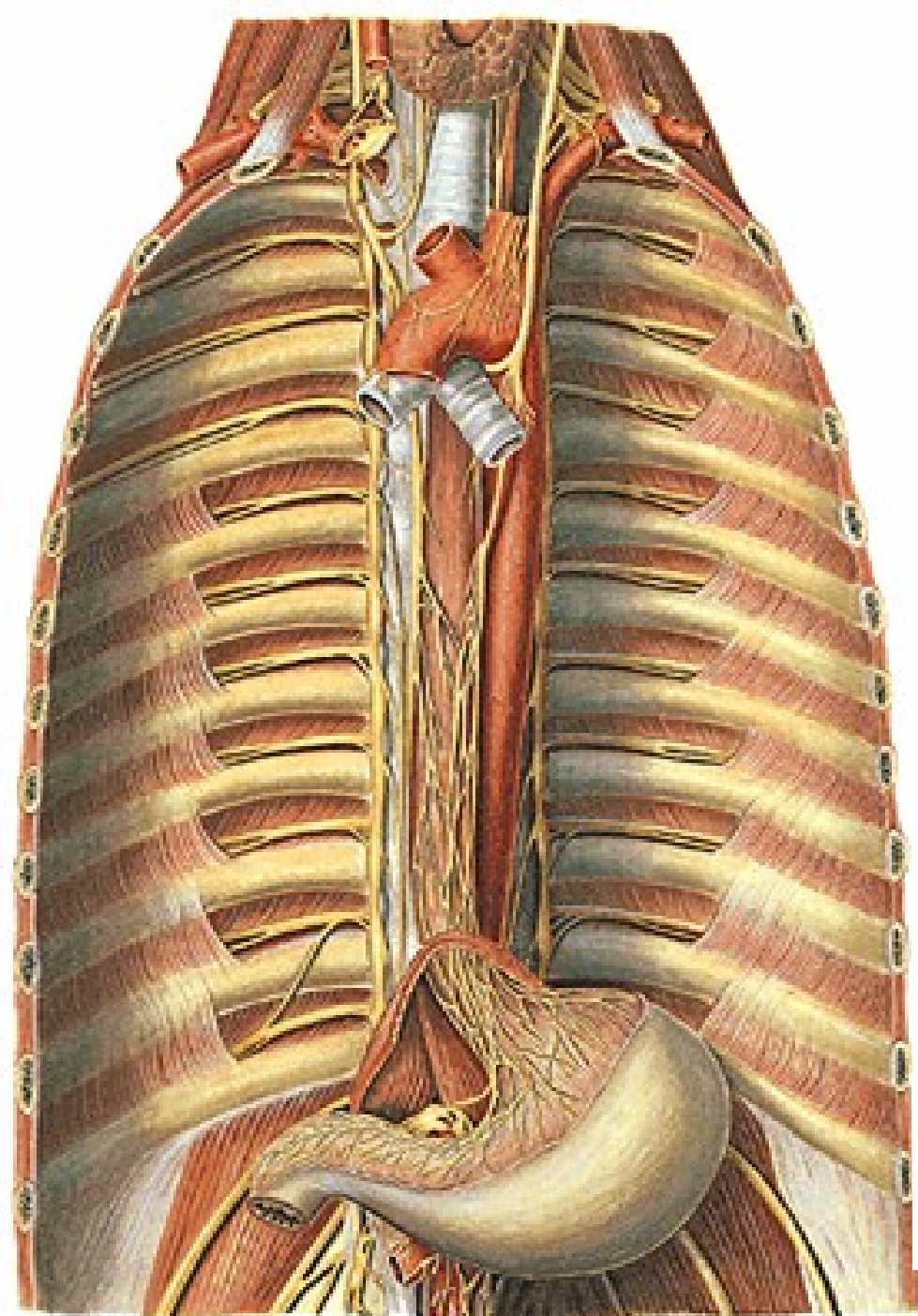
rr. cardiaci - plexus cardiacus
rr. bronchiales- plexus pulmonalis
rr. oesophagei- plexus oesophagus
rr. gastrici
rr. hepatici
rr. coeliaci - plexus coeliacus
rr. renales

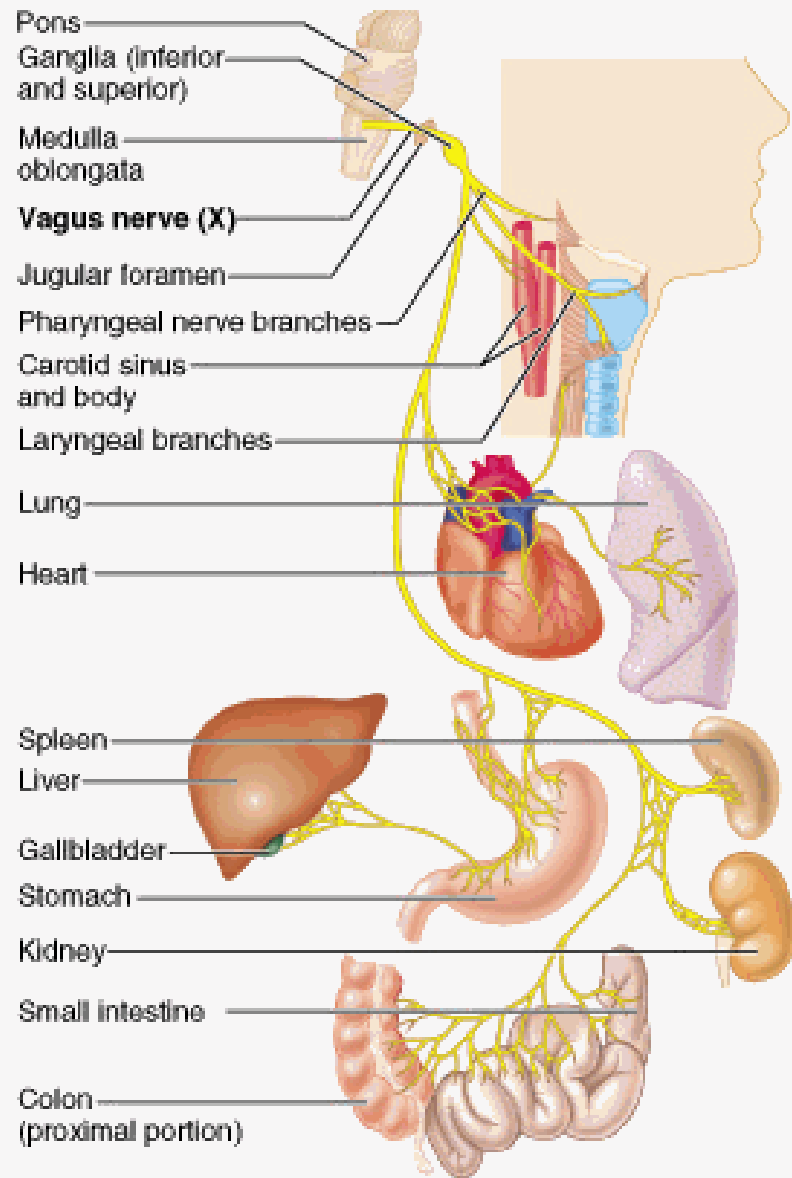


- **sensory in.:** part of skin of the auricle and ear canal
- **viscerosensory in.:** organs of thoracic and most of abdominal cavity
- **somatomotor in.:** striated muscles of pharynx and larynx
- **visceromotor in.:** smooth muscle of respiratory tract and most of alimentary tract, smooth muscle of appropriate vessels and myocardium



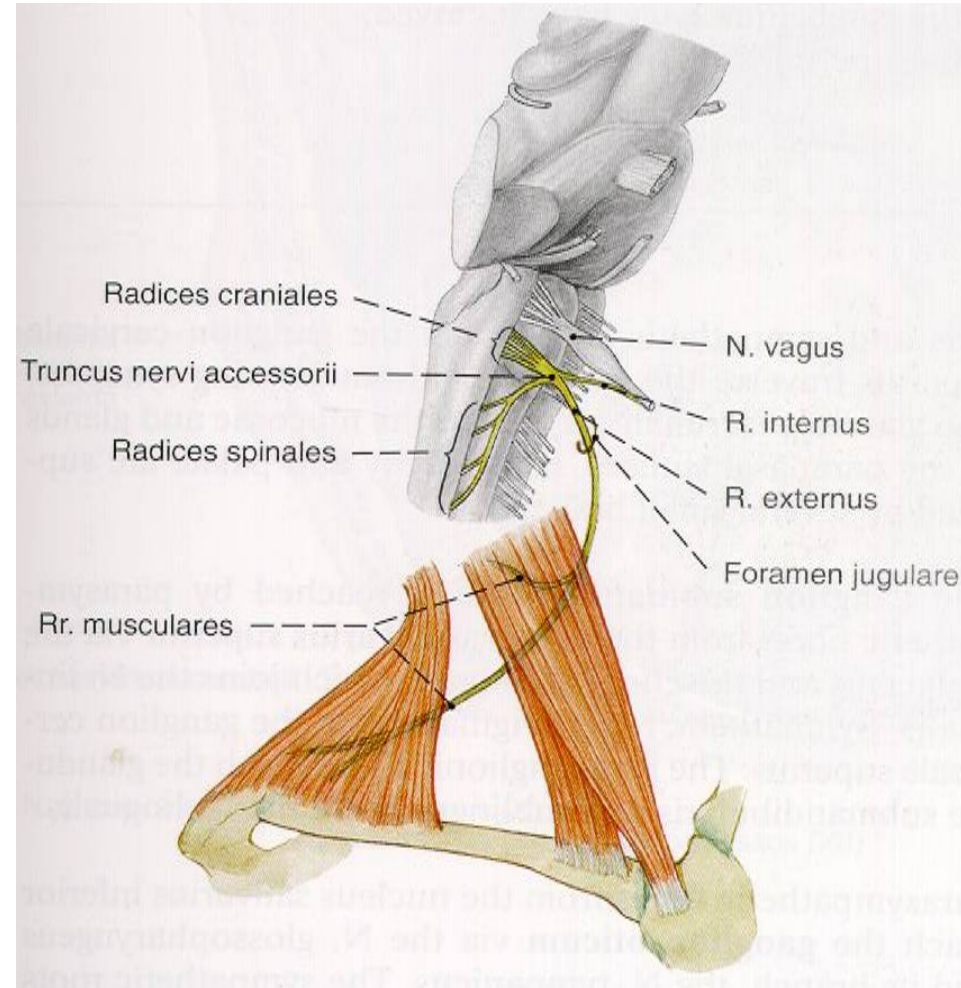


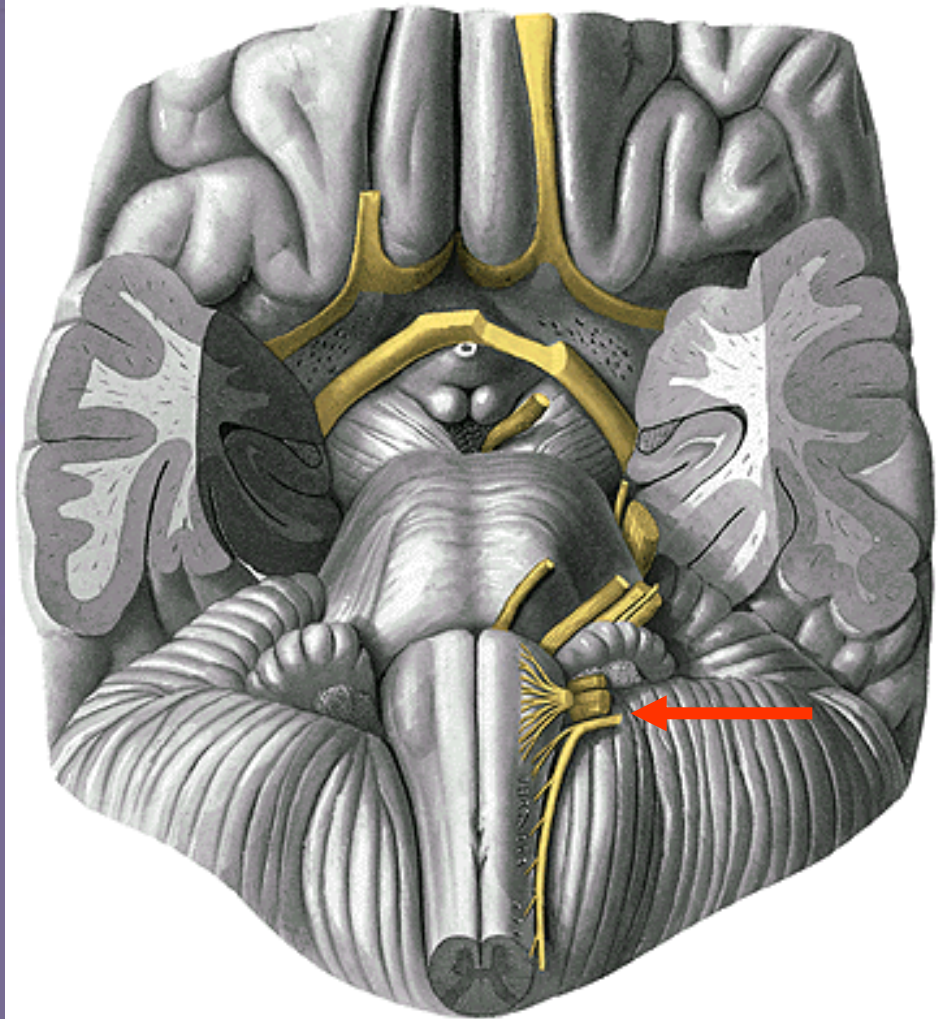
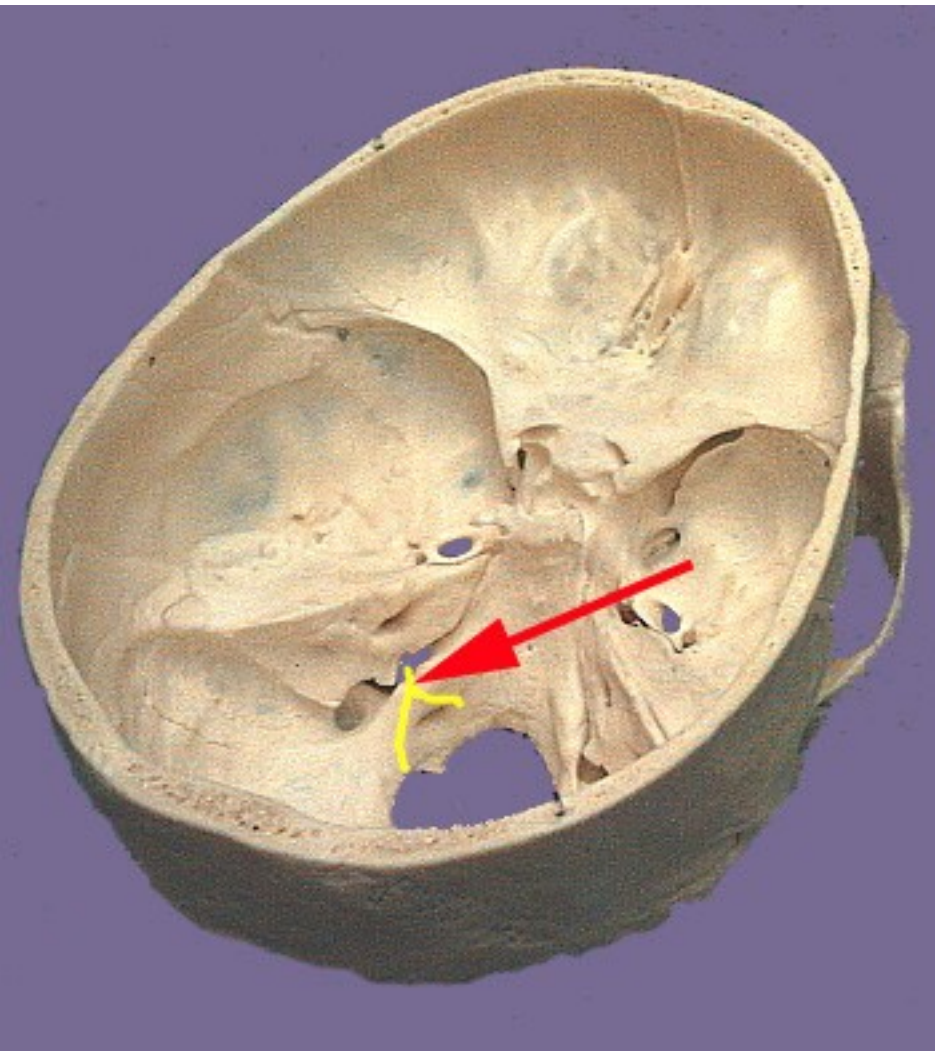




XI. The accessory nerve

- arises from the medulla oblongata
- passes through foramen jugulare
- name is abbreviation of the original name,,nervus accessorius ad vagum“ (because part of its fibers joins with nervus vagus and below it separates again and innervates muscles of larynx)
- Nerve branches out after leaving the cranial cavity





n. XI.



n.XI.

Radices craniales

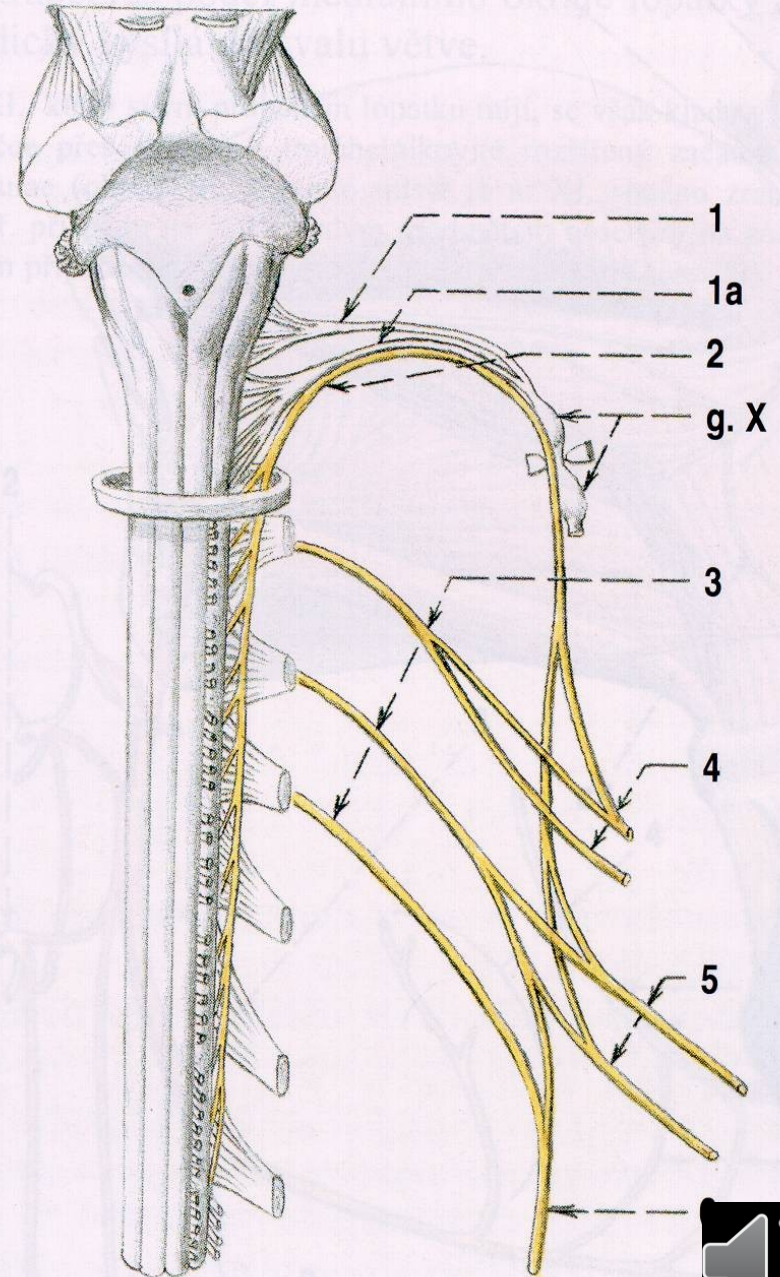
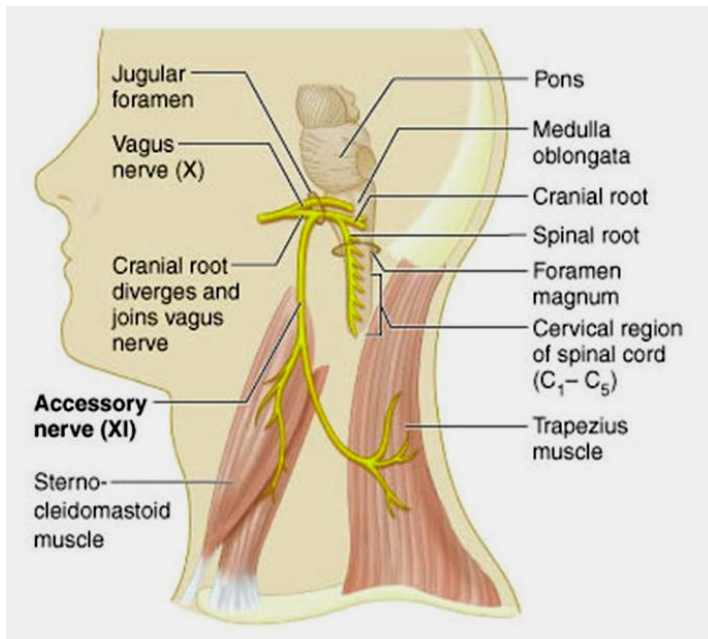
Radices spinales

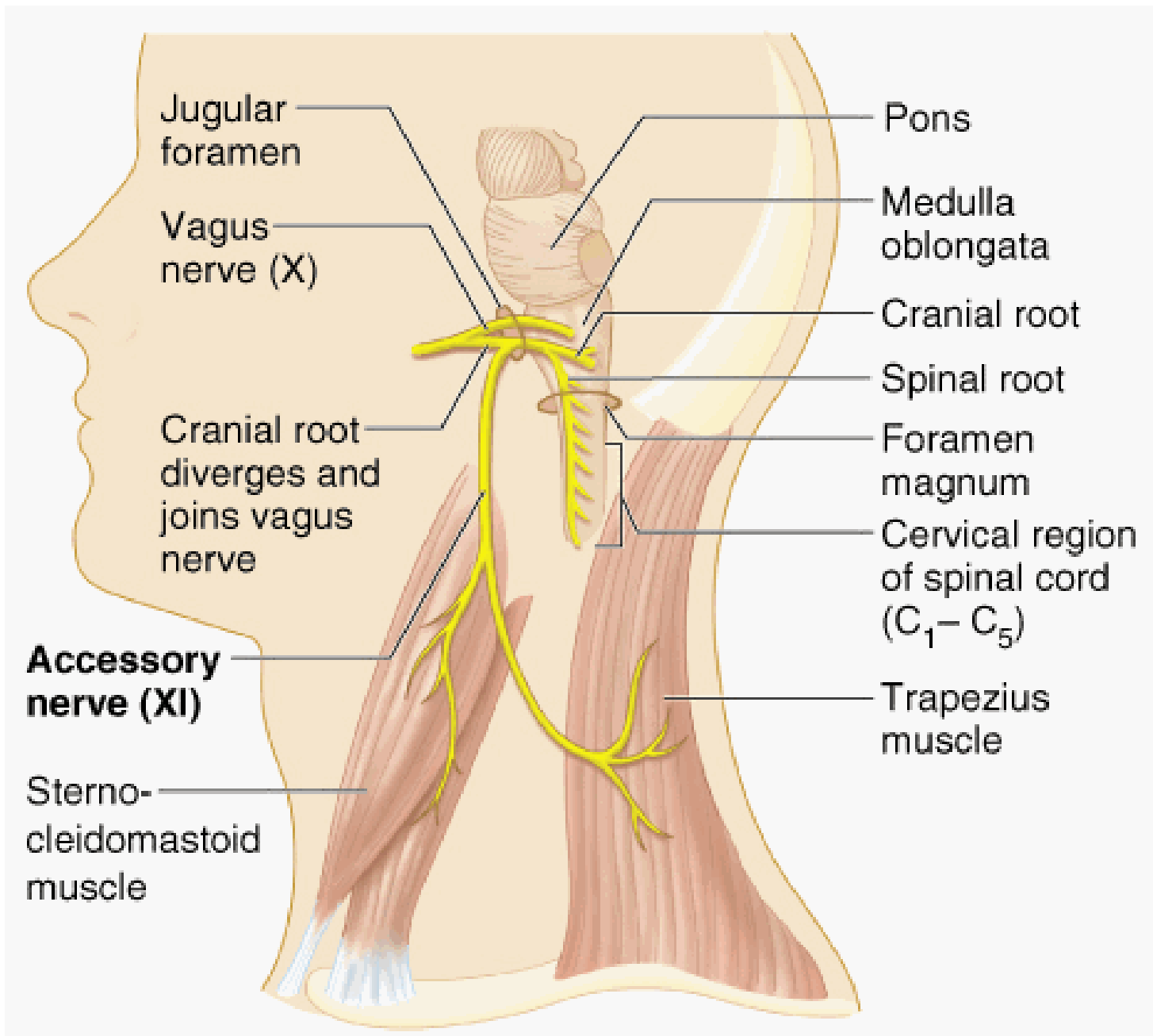
Ramus internus- joints n.X.

(muscles of larynx)

Ramus externus

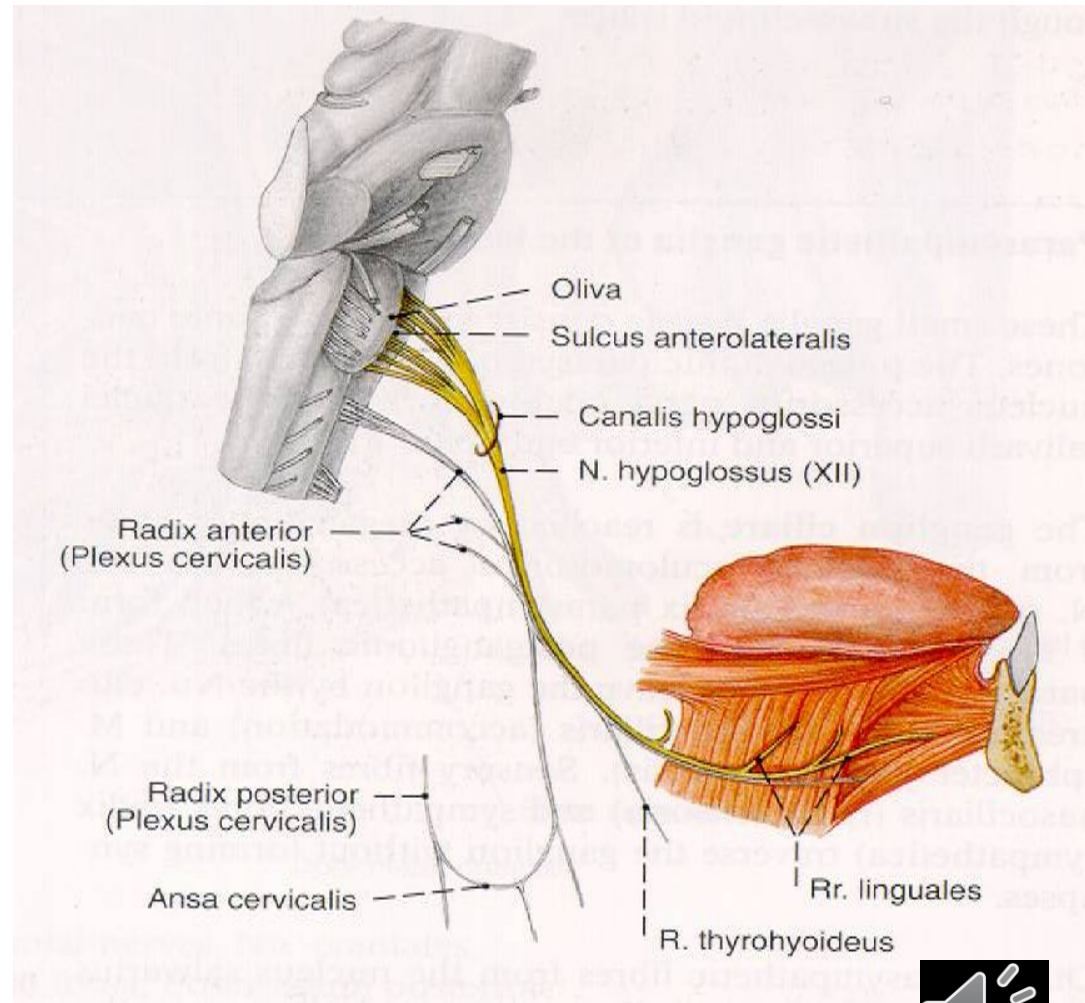
motor – part of musculus sternocleidomastoideus and musculus trapezius

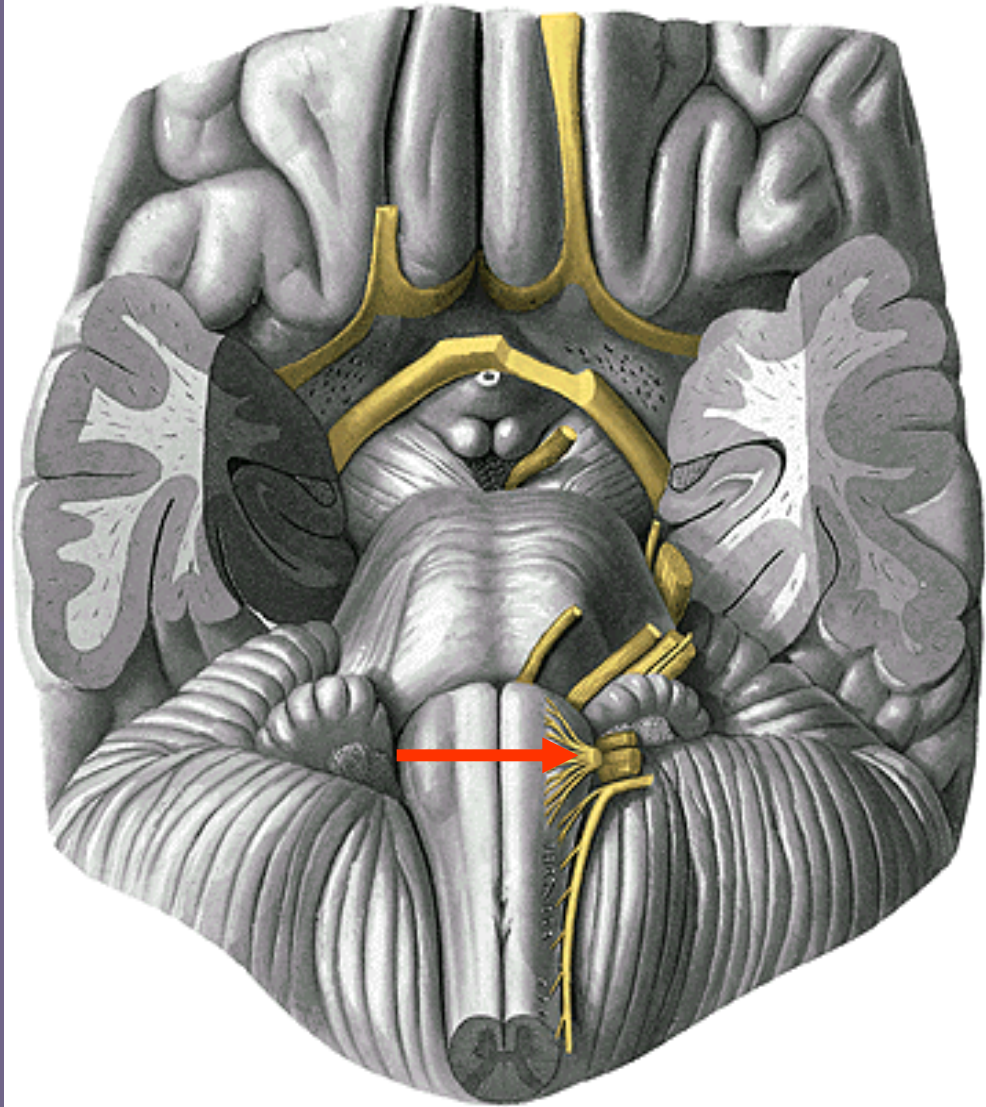
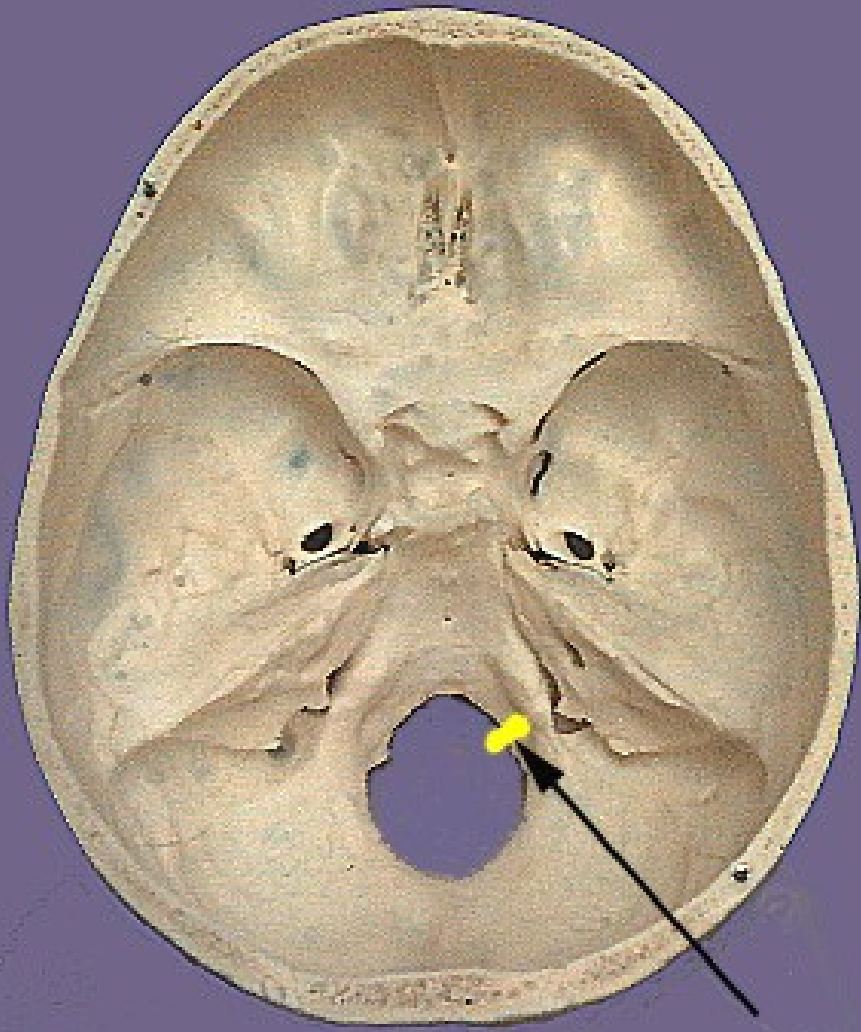




XII. The hypoglossal nerve

- Arises from the medulla oblongata - sulcus anterolateralis
- Through canalis nervi hypoglossi
- Directs to the tongue, where it branches out



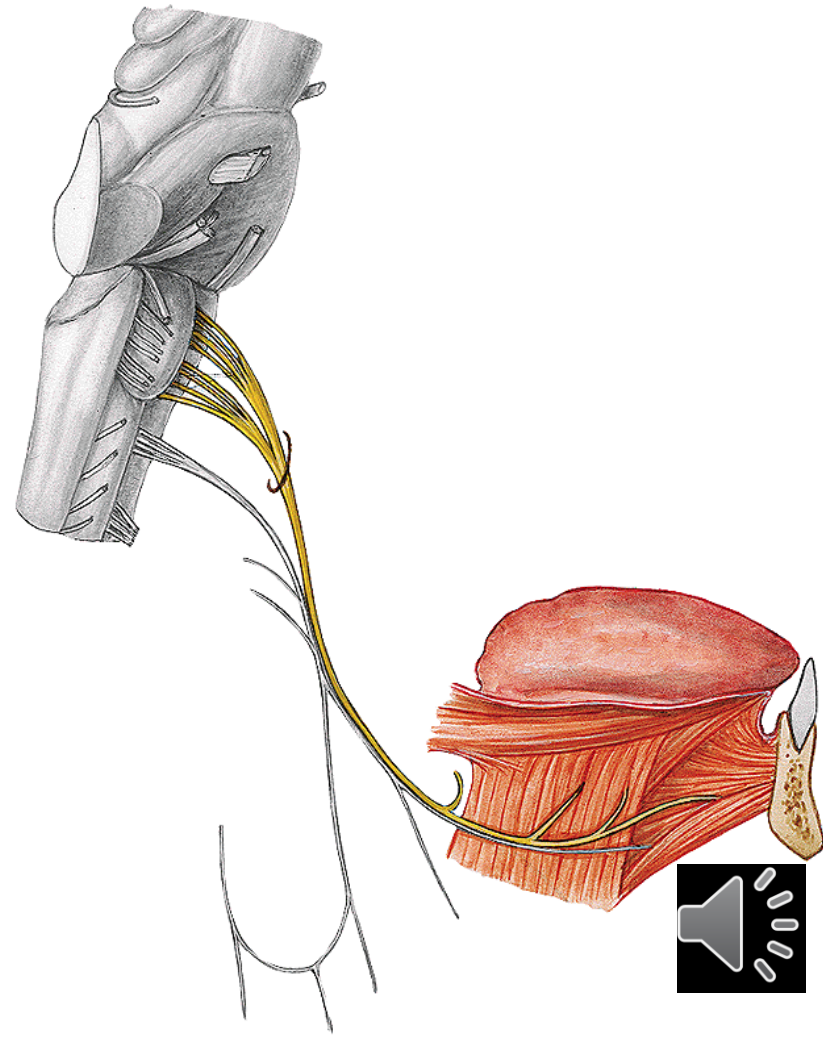
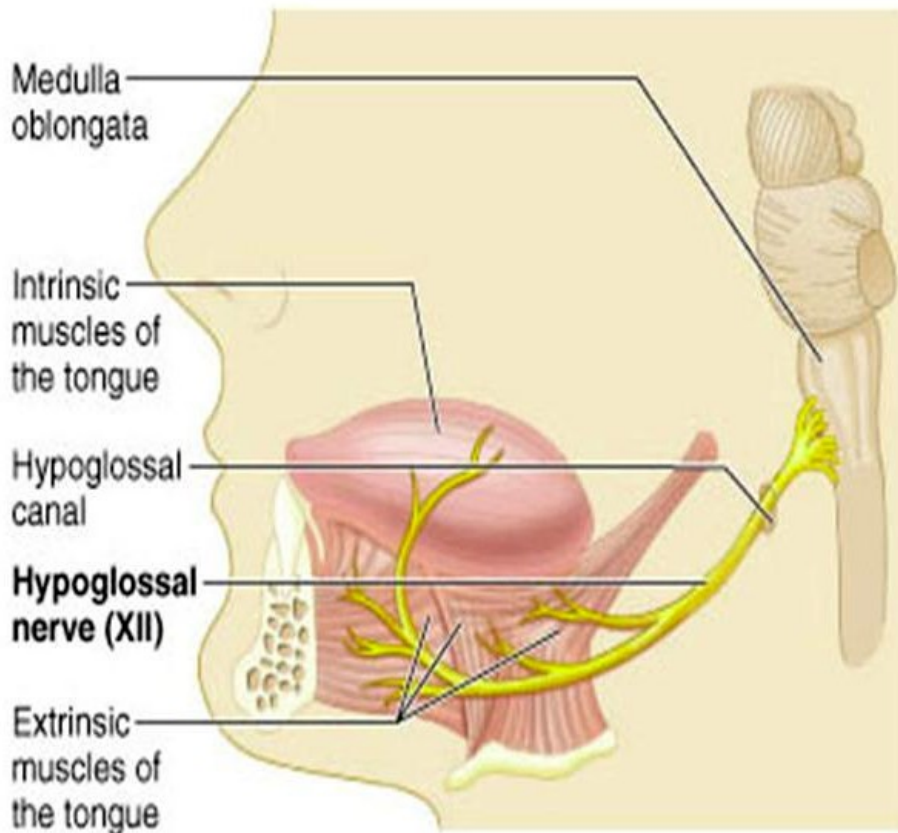


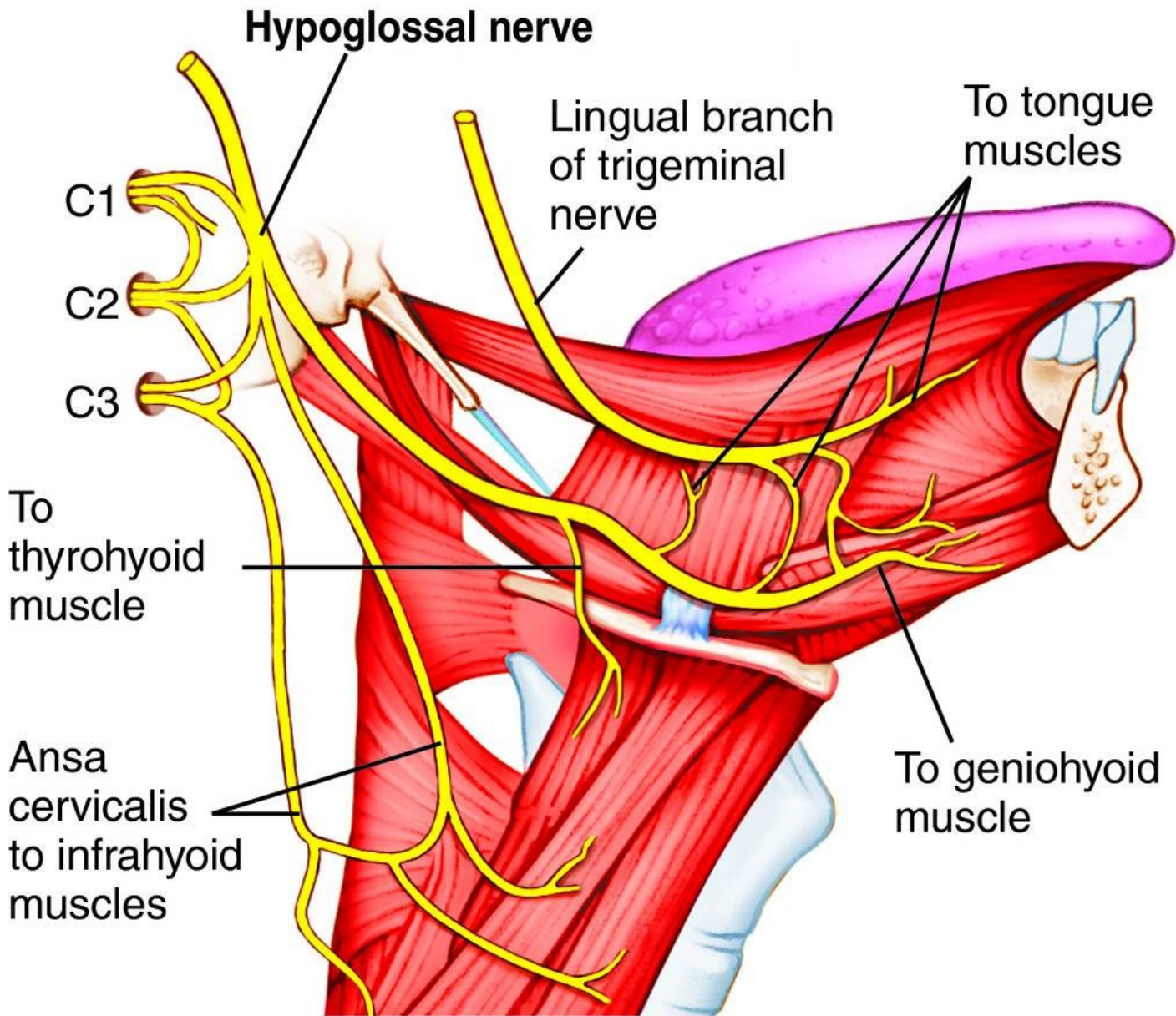
n. XII.



N. hypoglossus

Motor nerve: innervation of striated muscle of the **tongue**
ansa cervicalis profunda- infrahyoid muscles (plexus cervicalis)





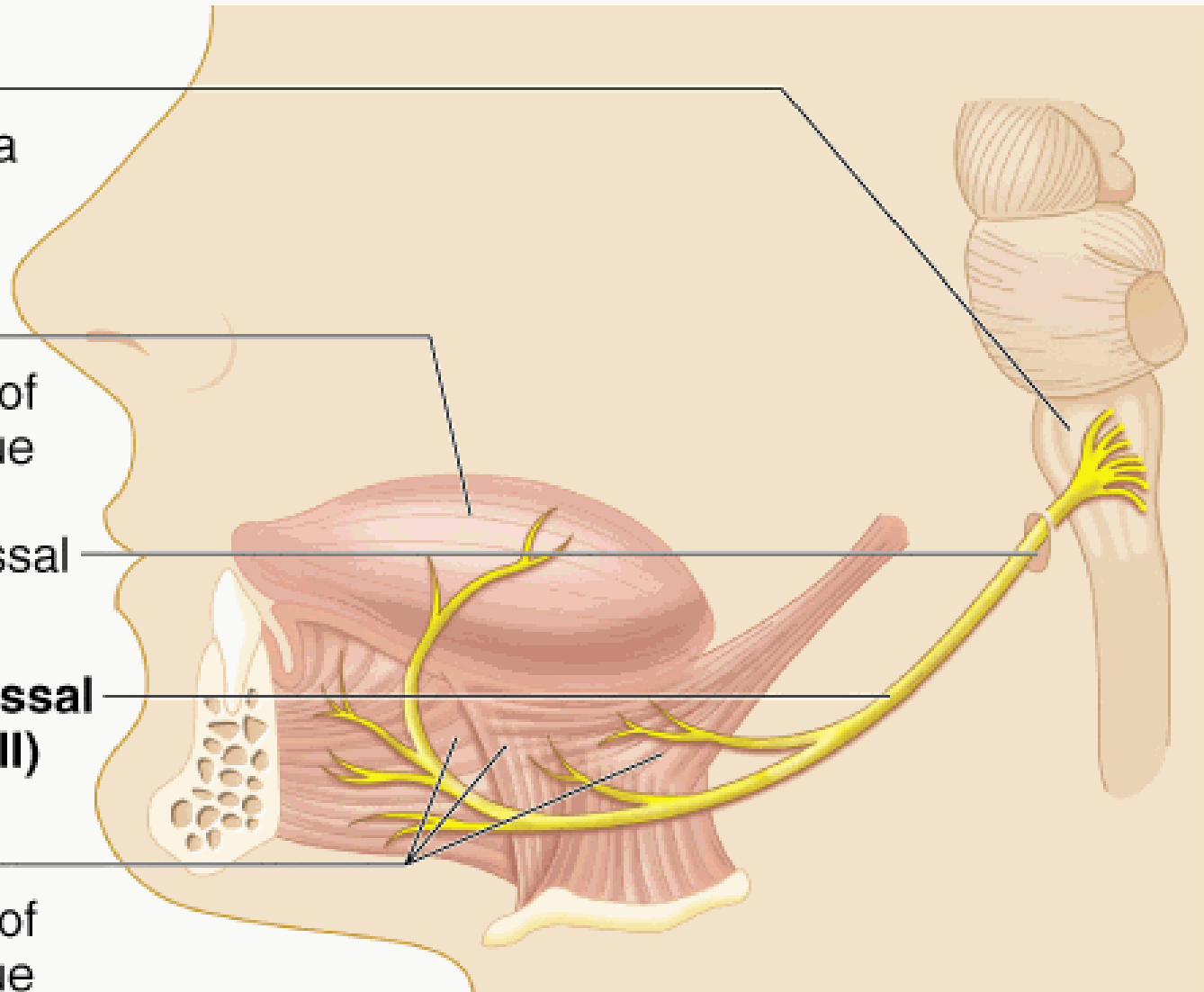
Medulla
oblongata

Intrinsic
muscles of
the tongue

Hypoglossal
canal

**Hypoglossal
nerve (XII)**

Extrinsic
muscles of
the tongue



Obrázky:

- **Atlas der Anatomie des Menschen/Sobotta. Putz,R., und Pabst,R. 20. Auflage. München:Urban & Schwarzenberg, 1993**
- **Netter: Interactive Atlas of Human Anatomy.**
- **Naňka, Elišková: Přehled anatomie. Galén, Praha 2009.**
- **Čihák: Anatomie I, II, III.**
- **Drake et al: Gray's Anatomy for Students. 2010**

