
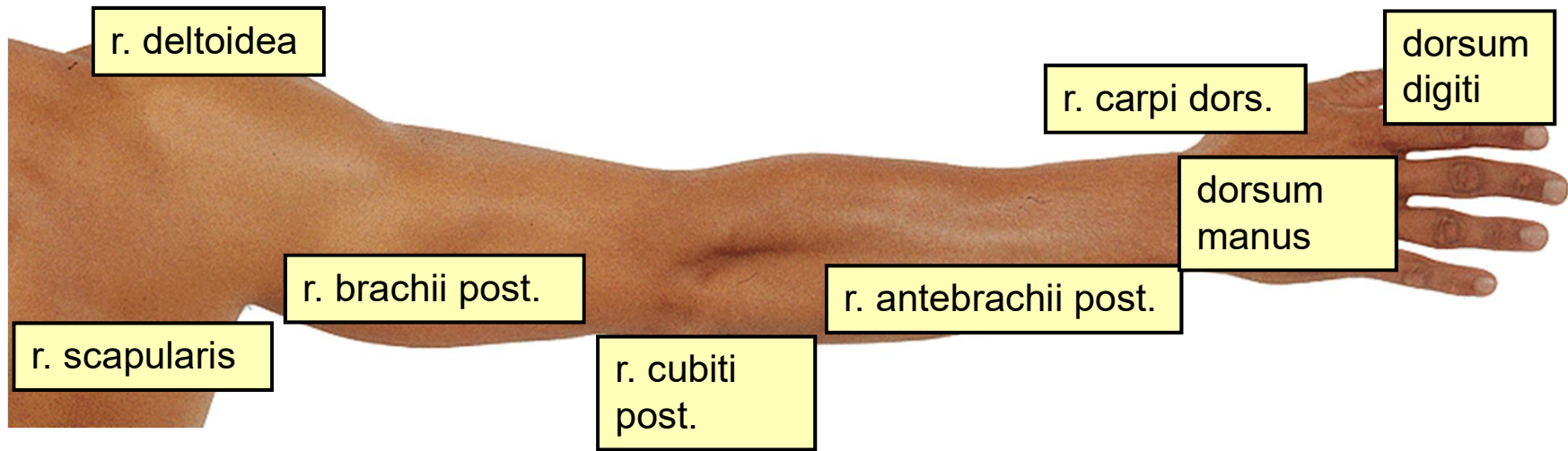

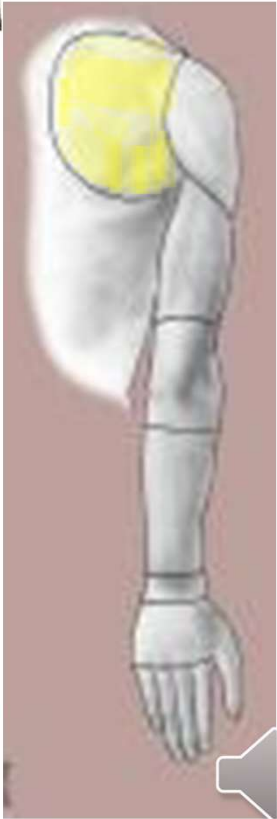
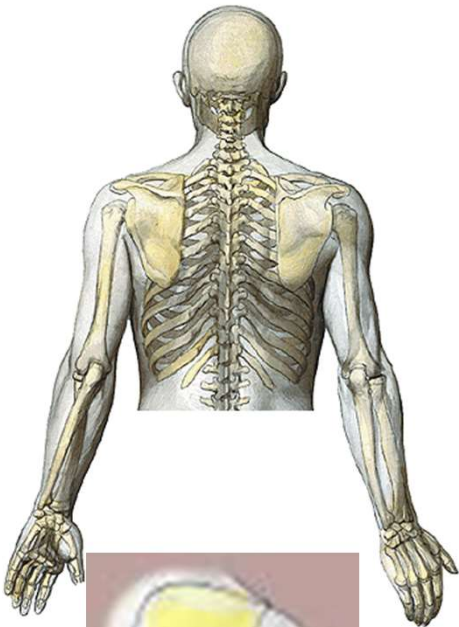
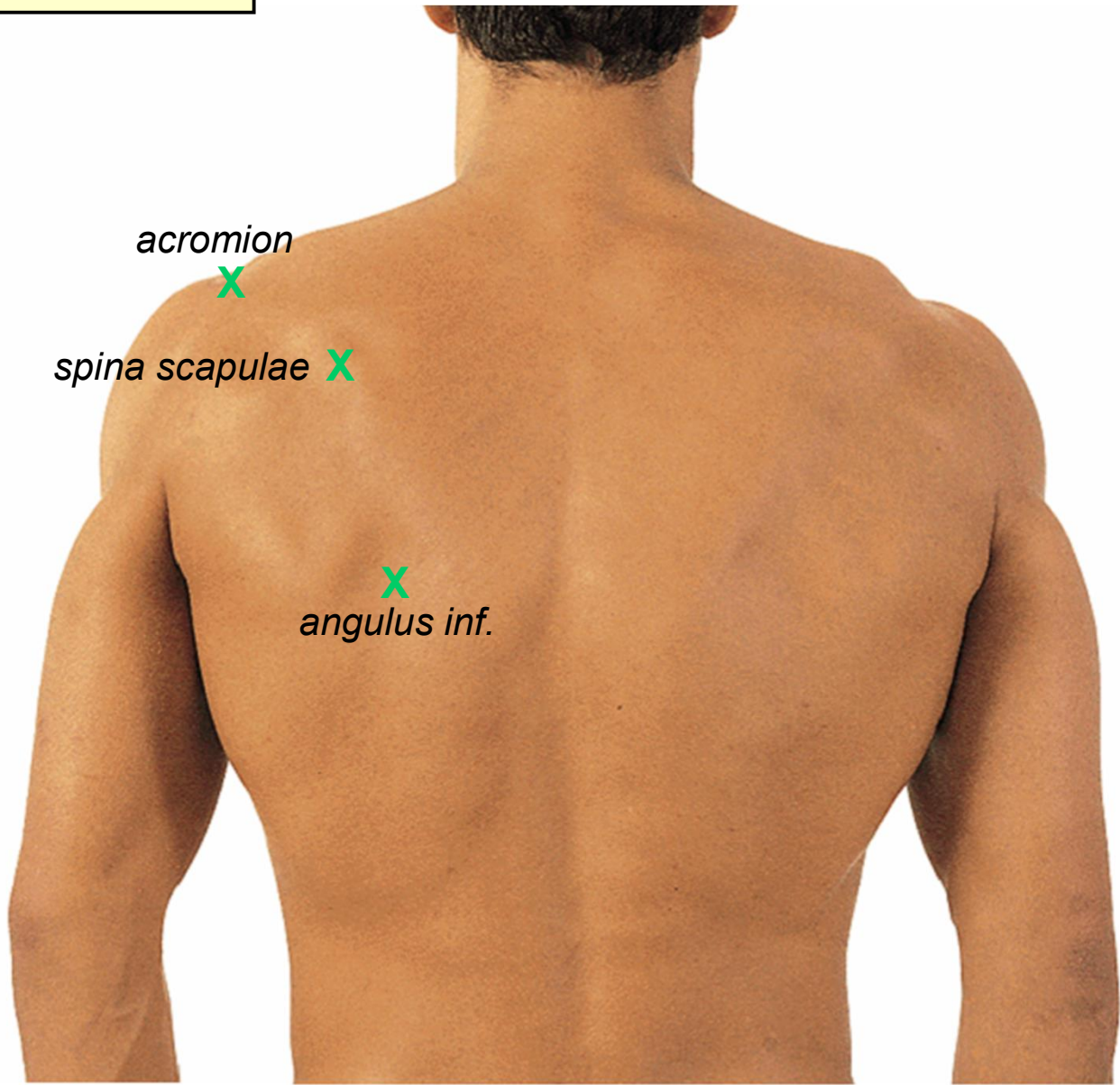
The regional anatomy of the upper limb

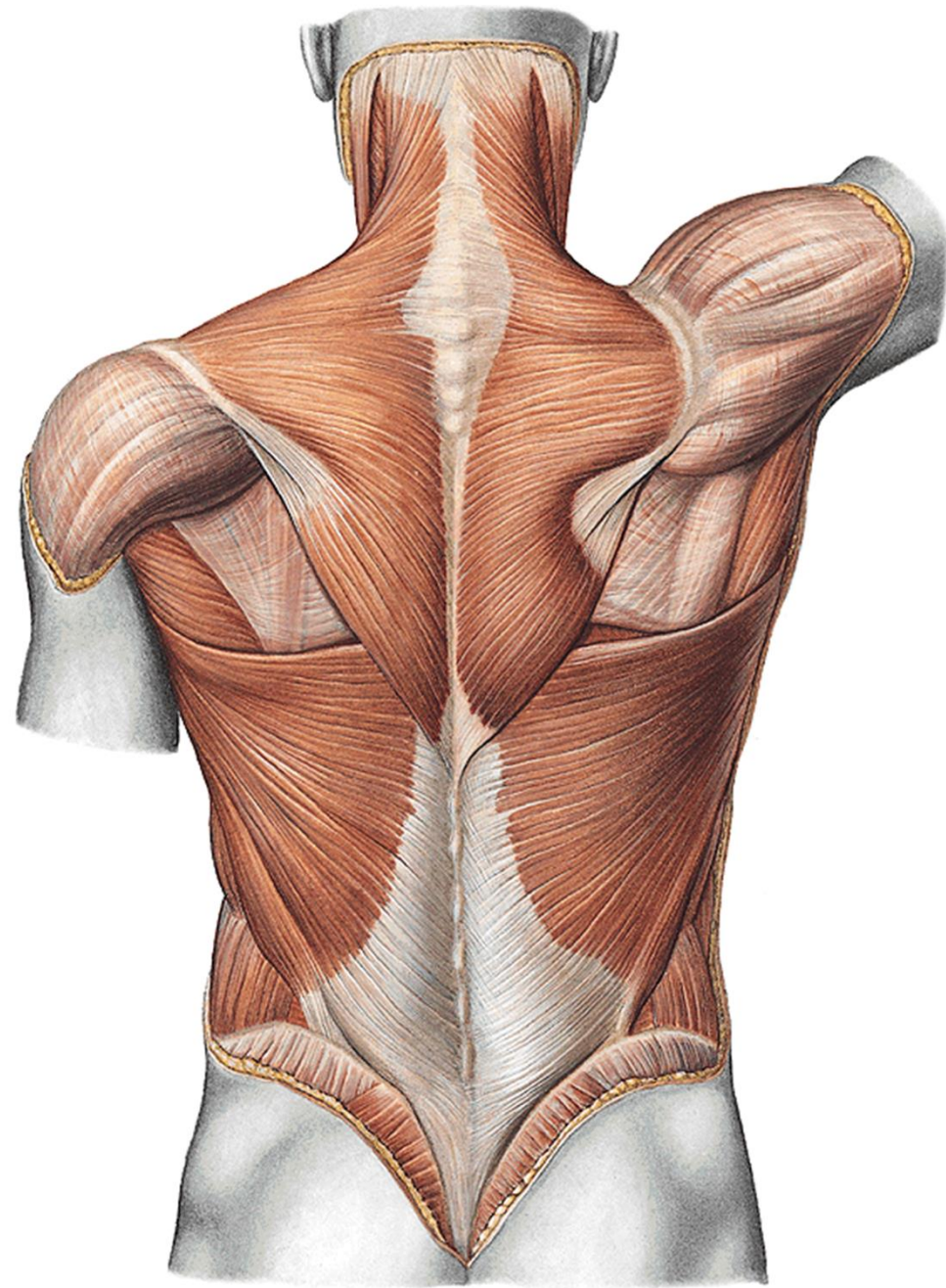


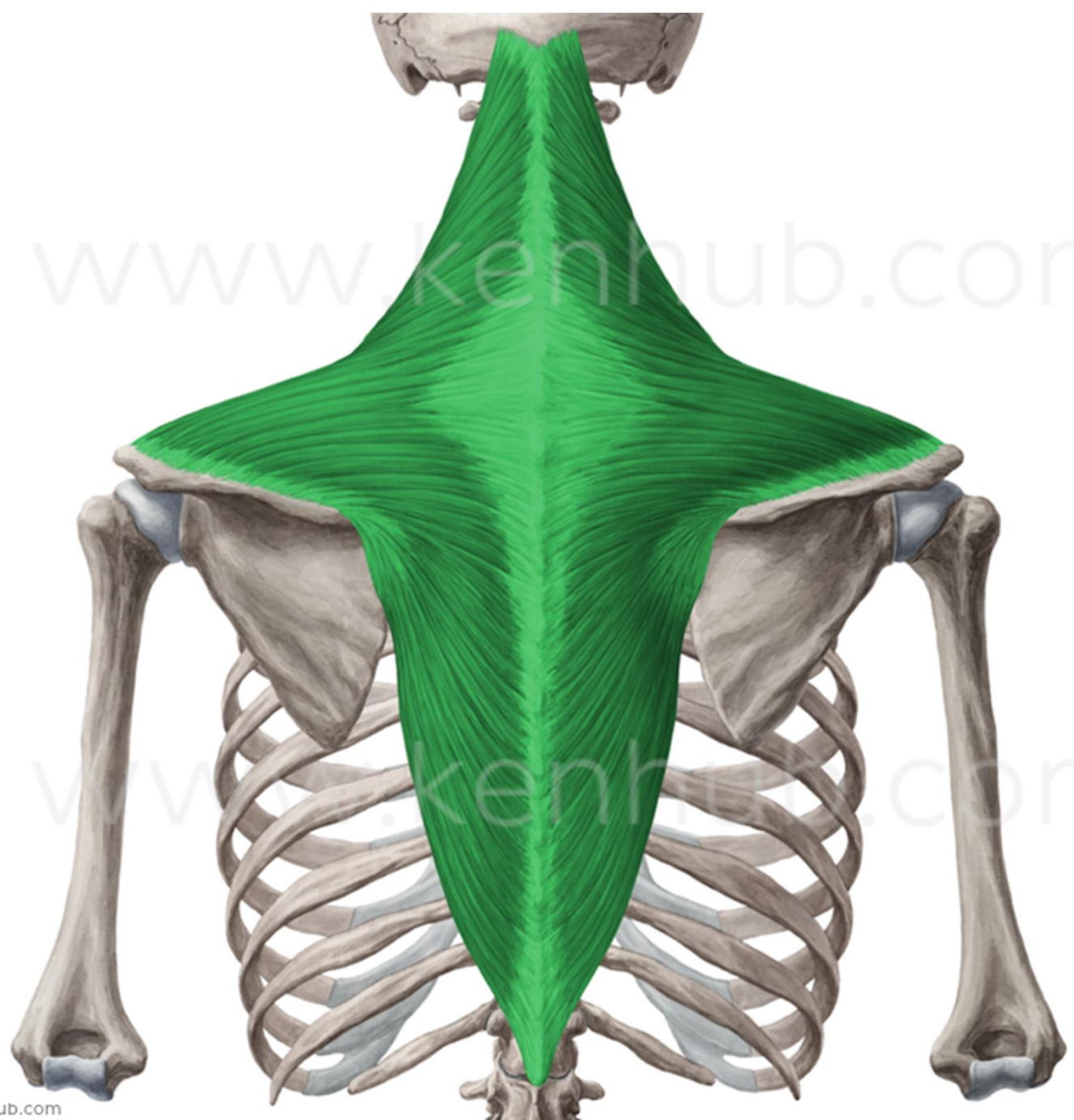




r. scapularis

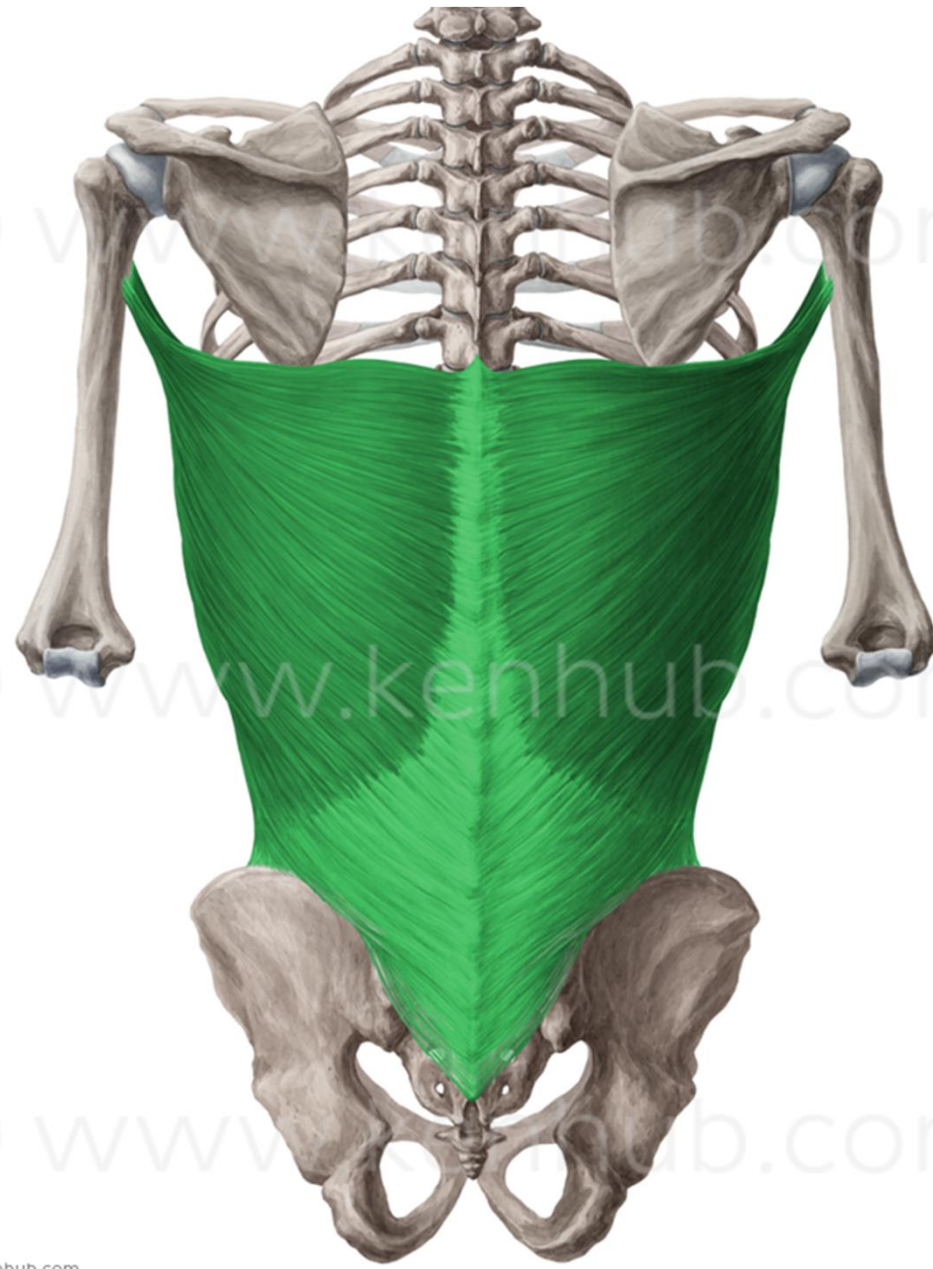






© www.kenhub.com

© www.kenhub.com

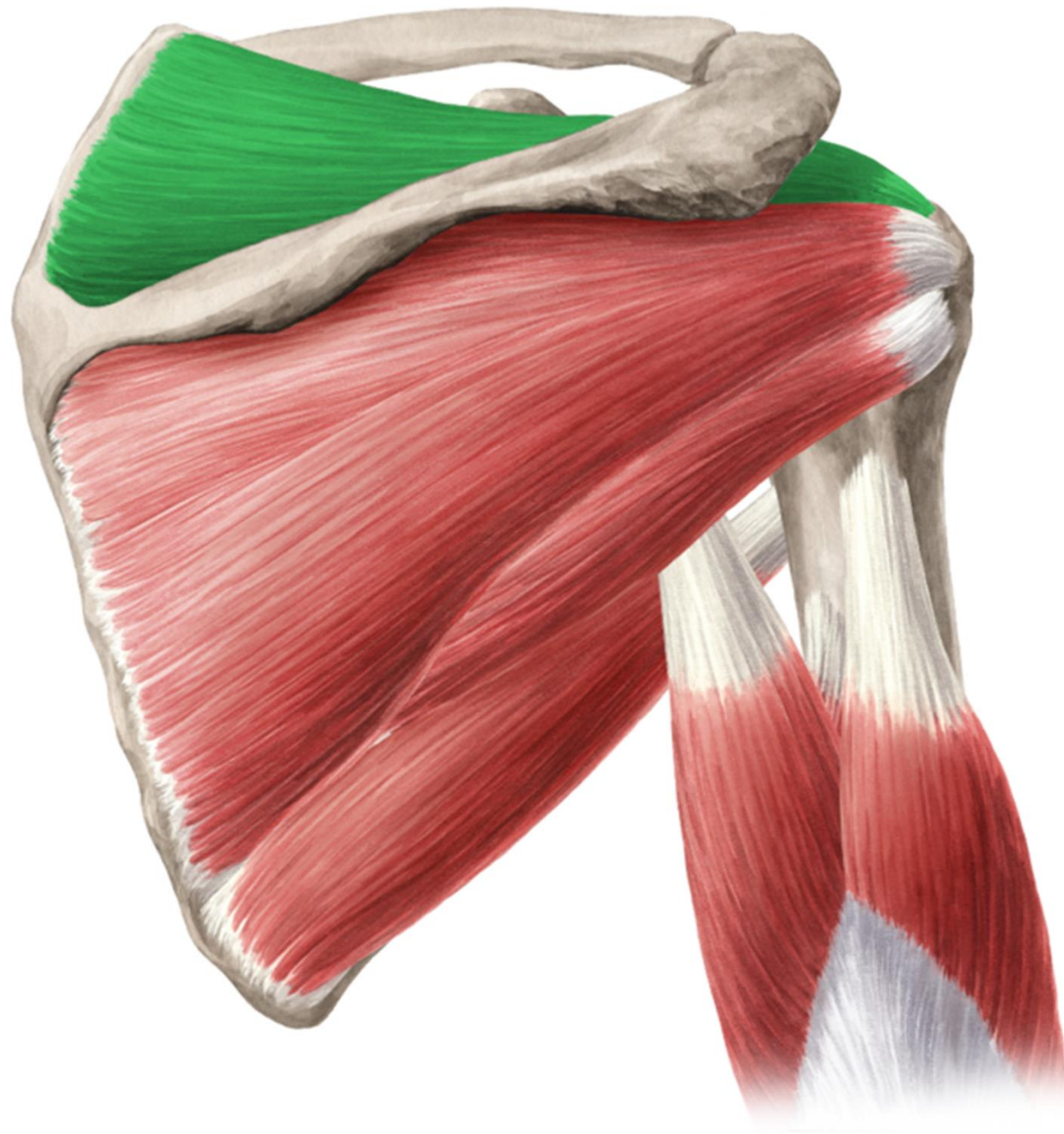


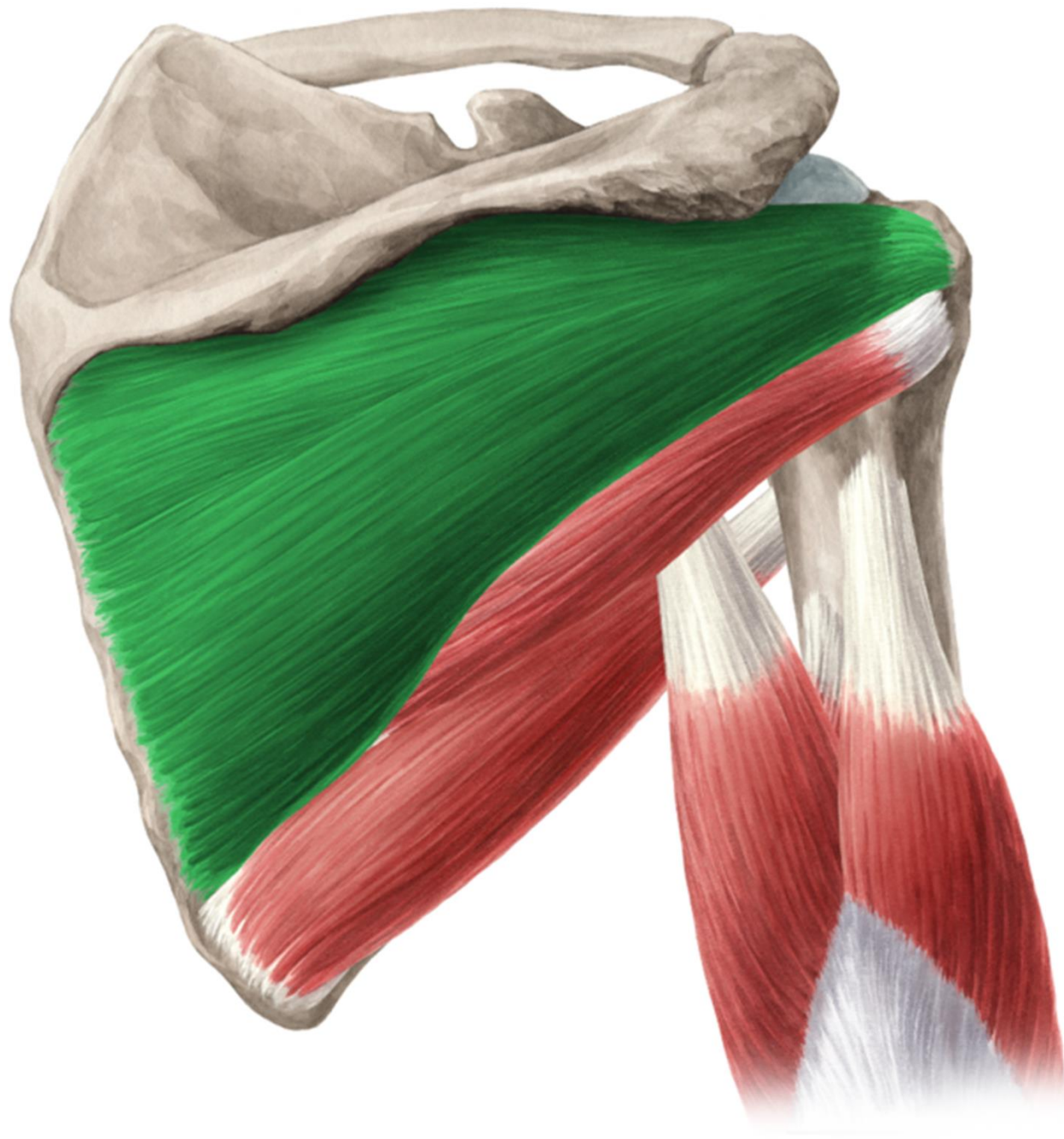
© www.kenhub.com

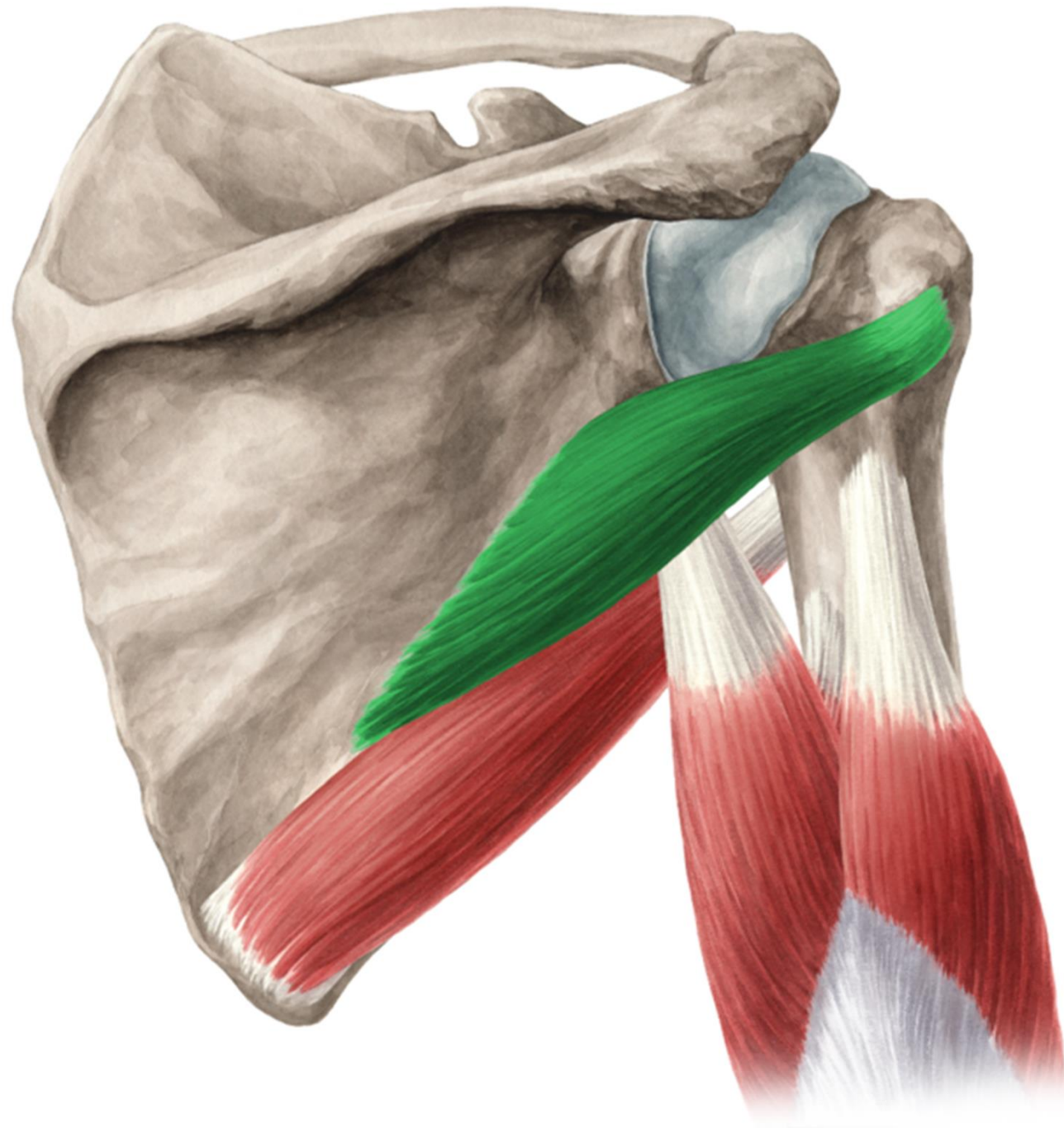
© www.kenhub.com

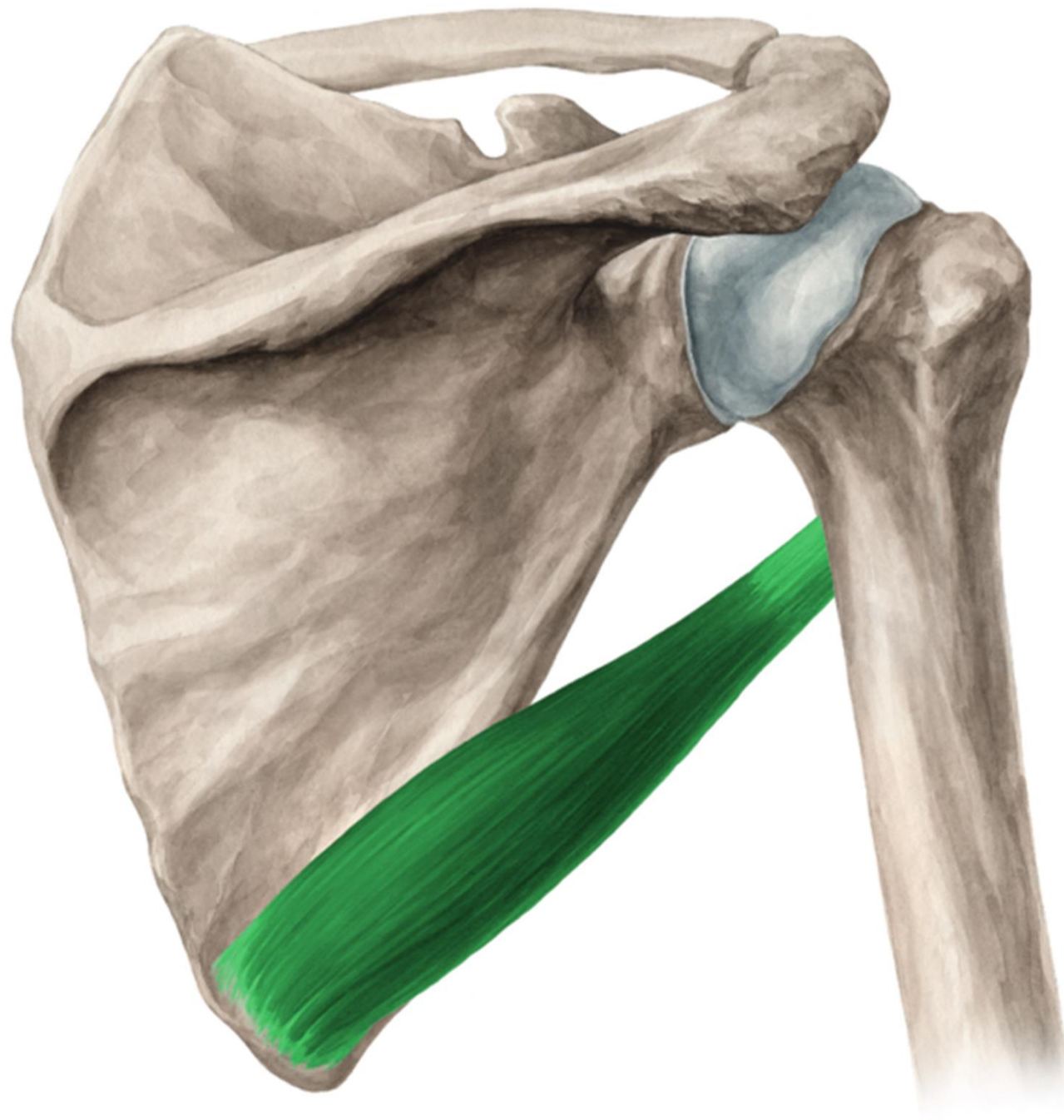
© www.kenhub.com

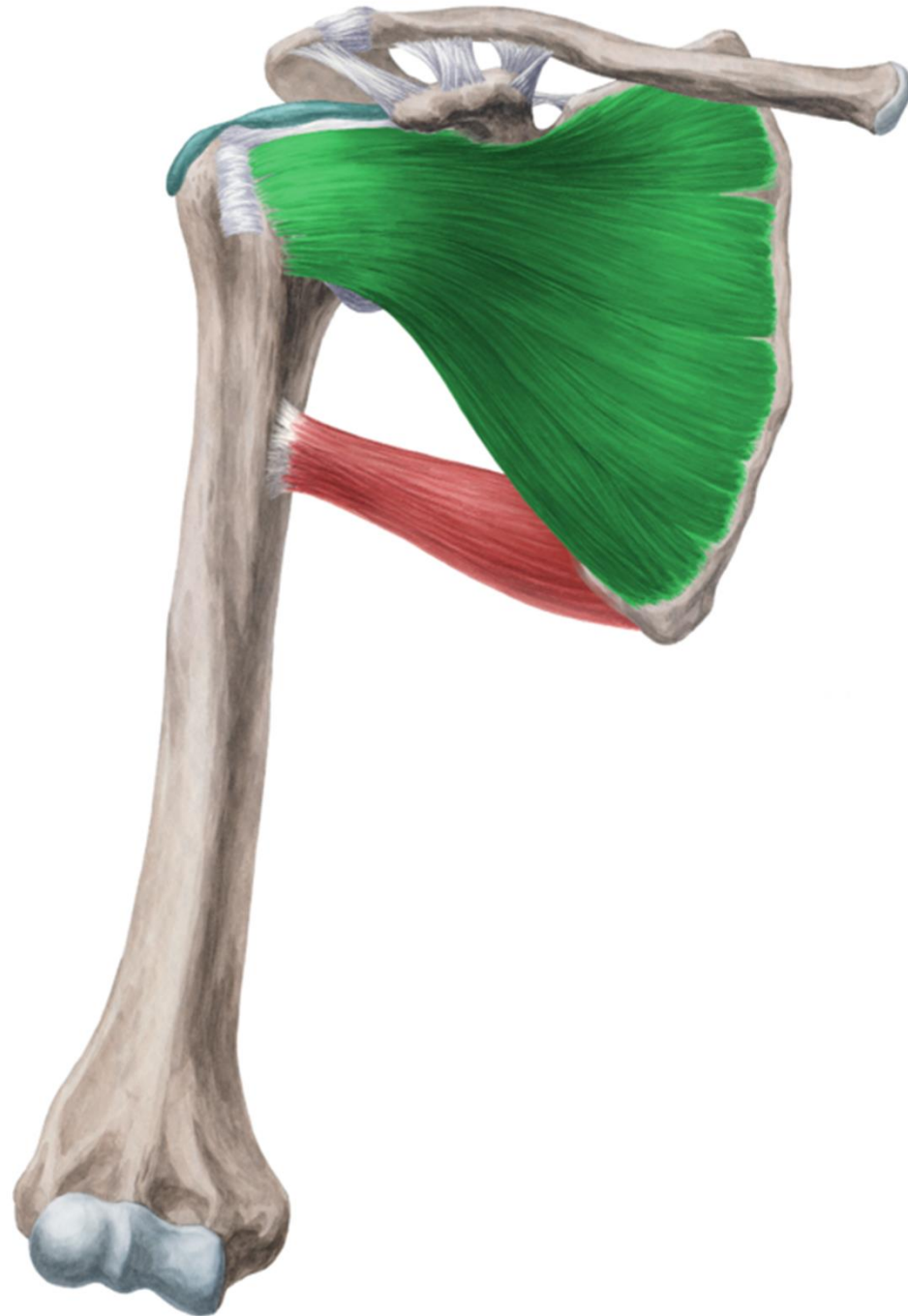

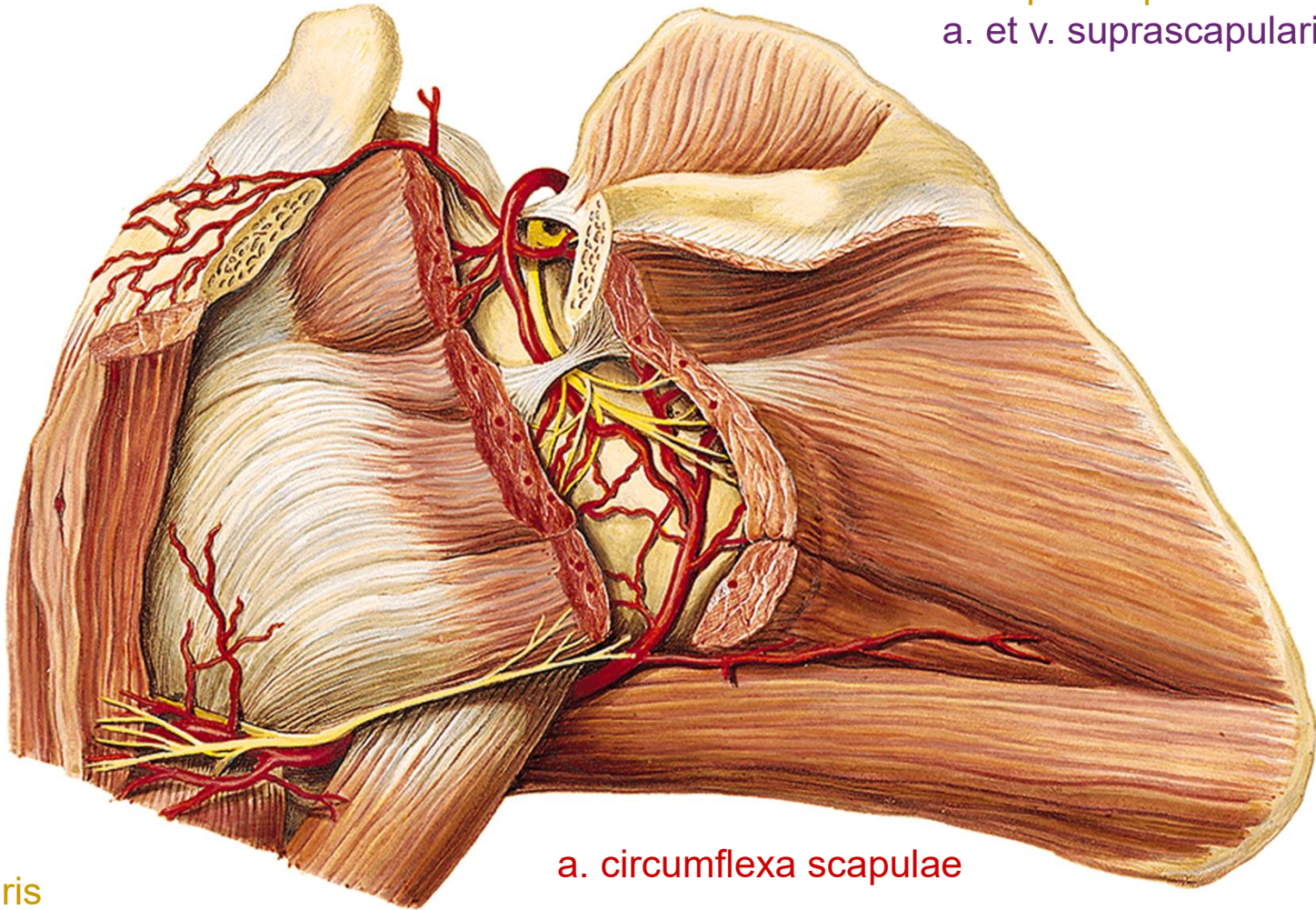












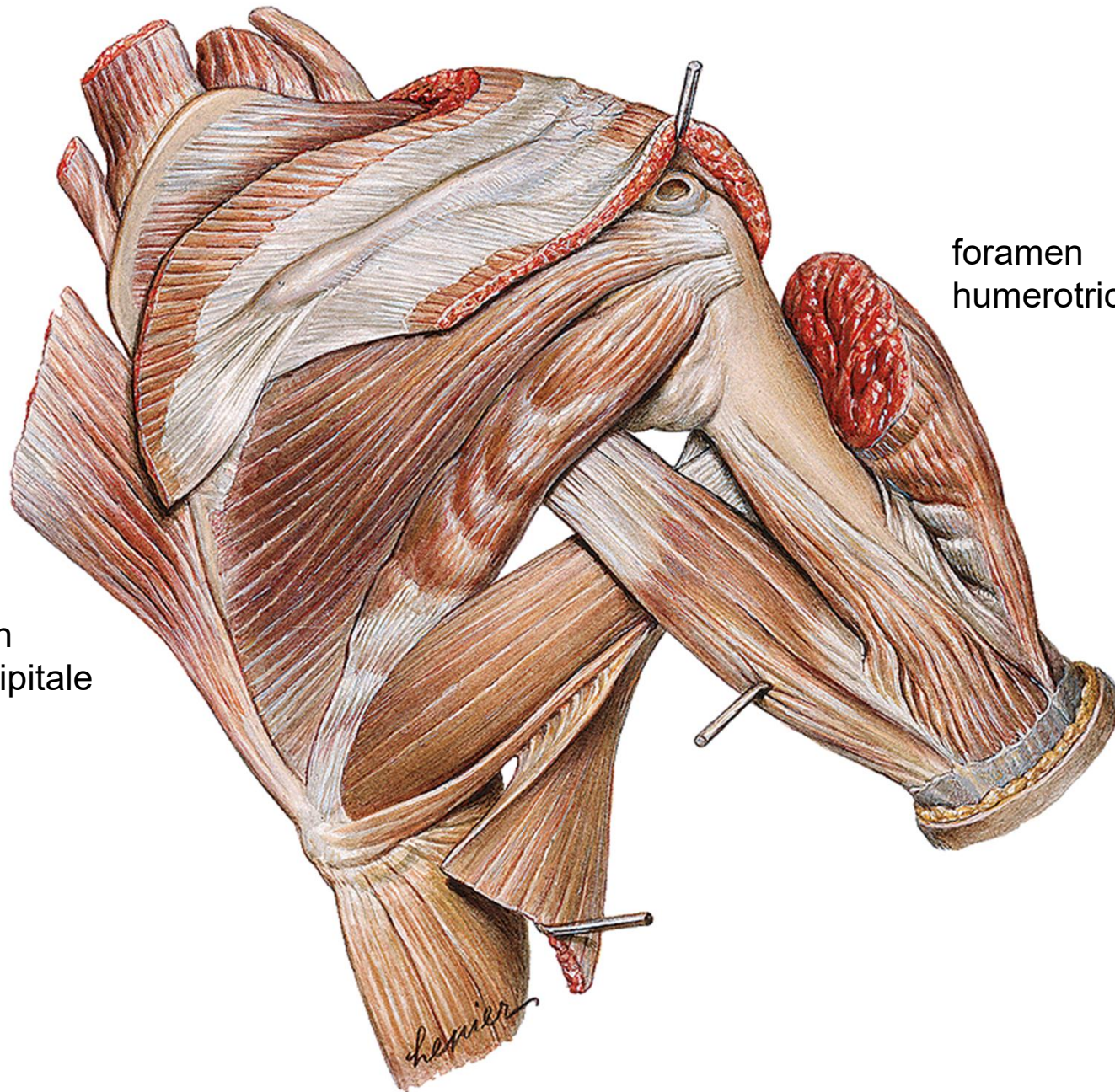
n. suprascapularis
a. et v. suprascapularis

n. axillaris
a. et v. circumflexa humeri post.

a. circumflexa scapulae



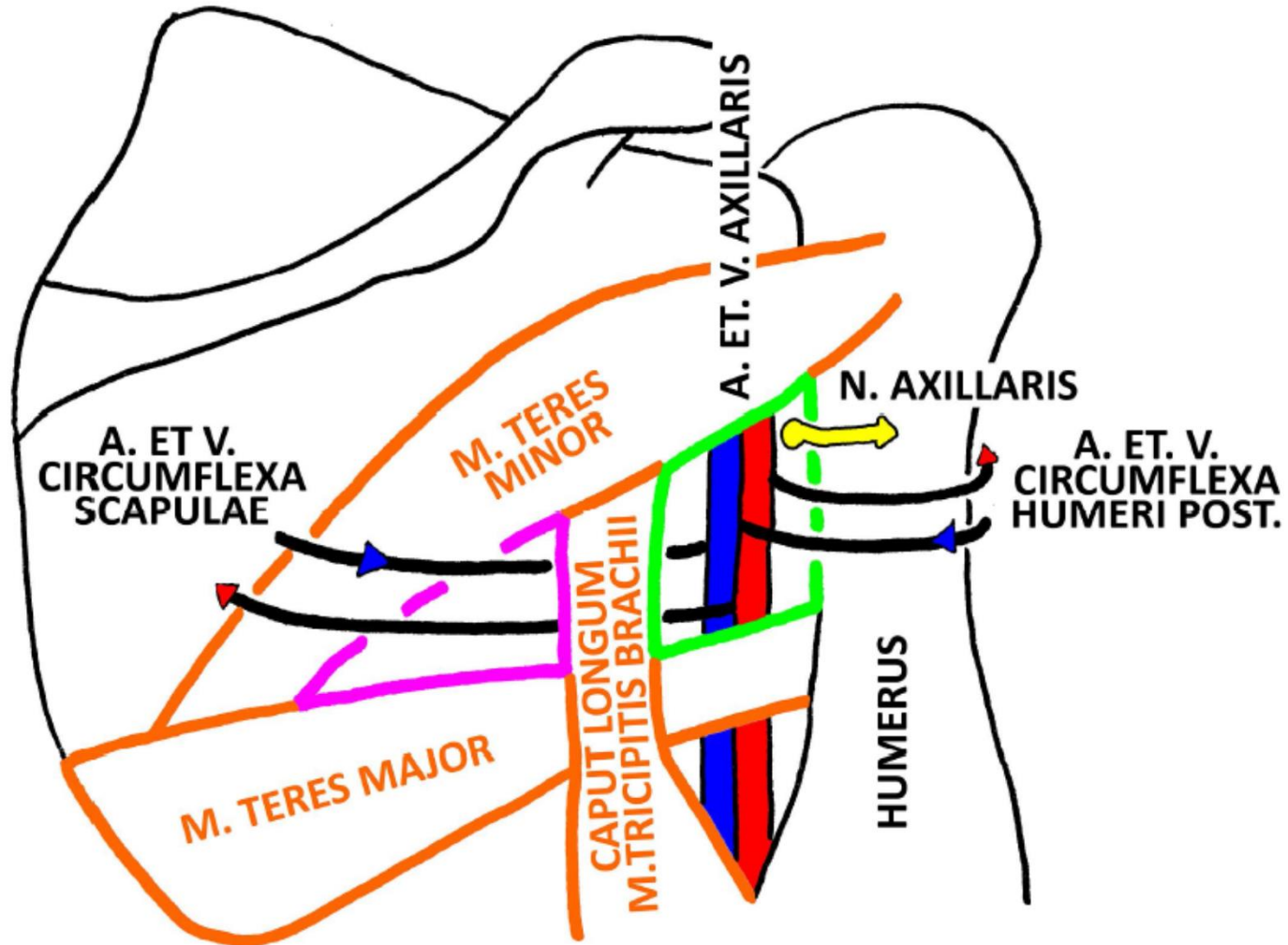
foramen
omotricipitale

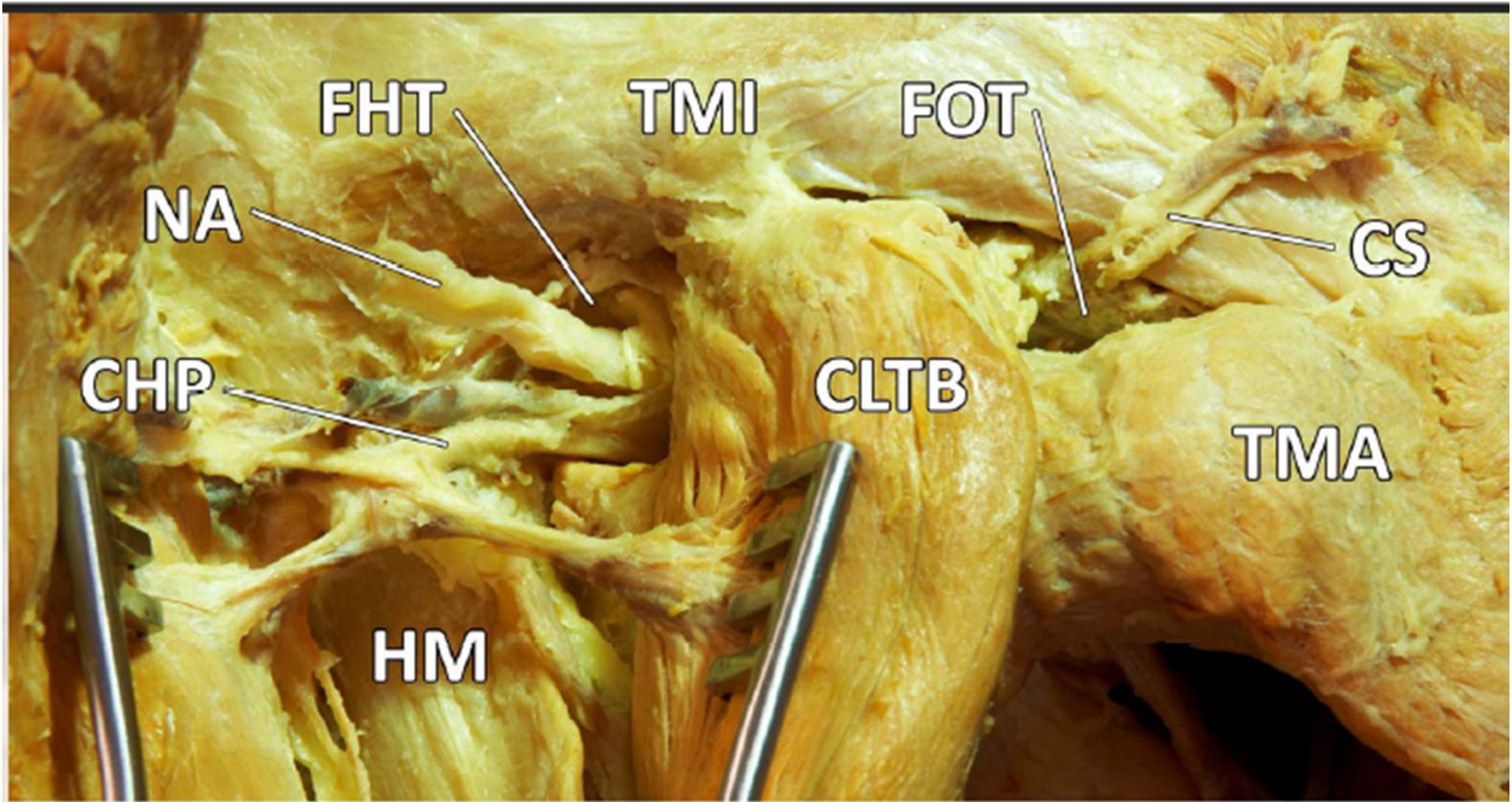


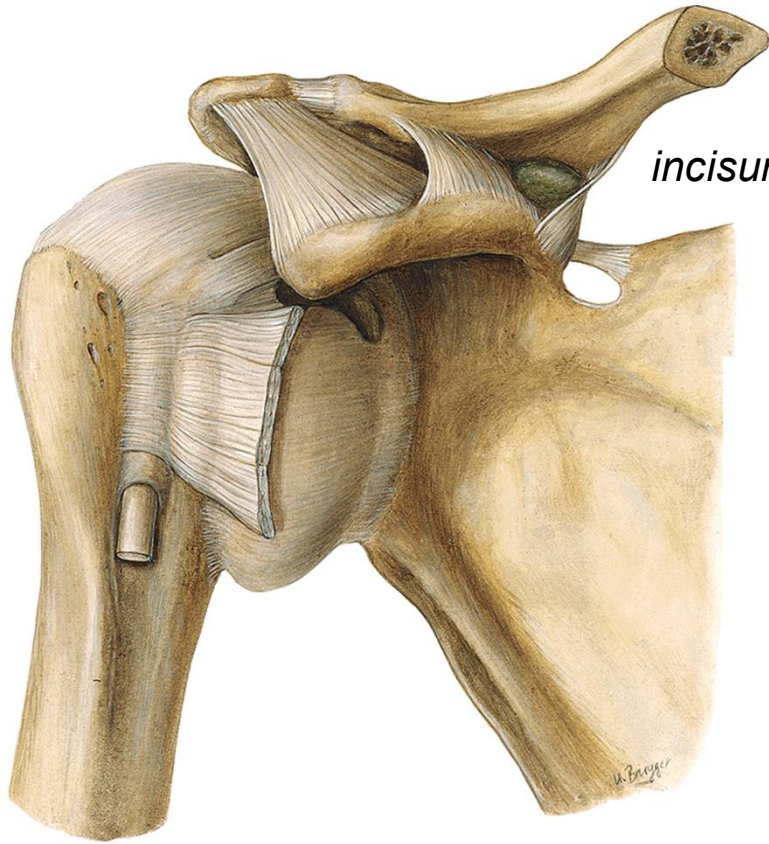
foramen
humerotricipitale



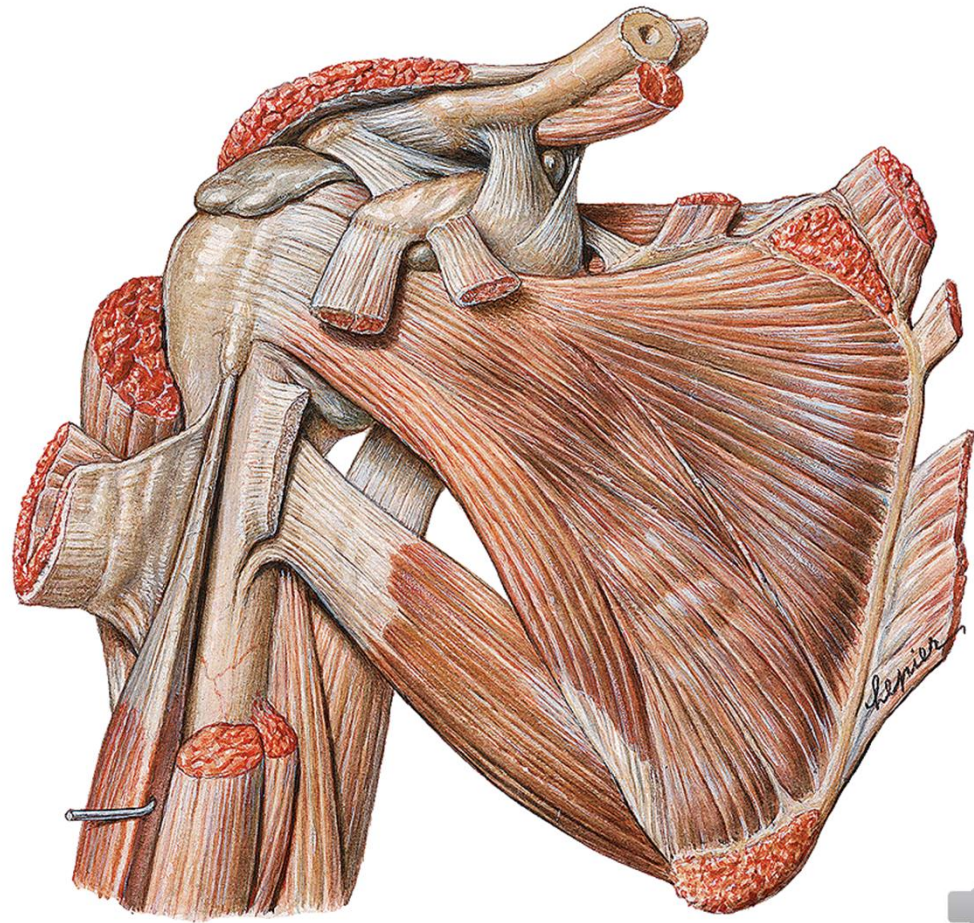
FORAMEN OMOTRICIPITALE ET HUMEROTRICIPITALE

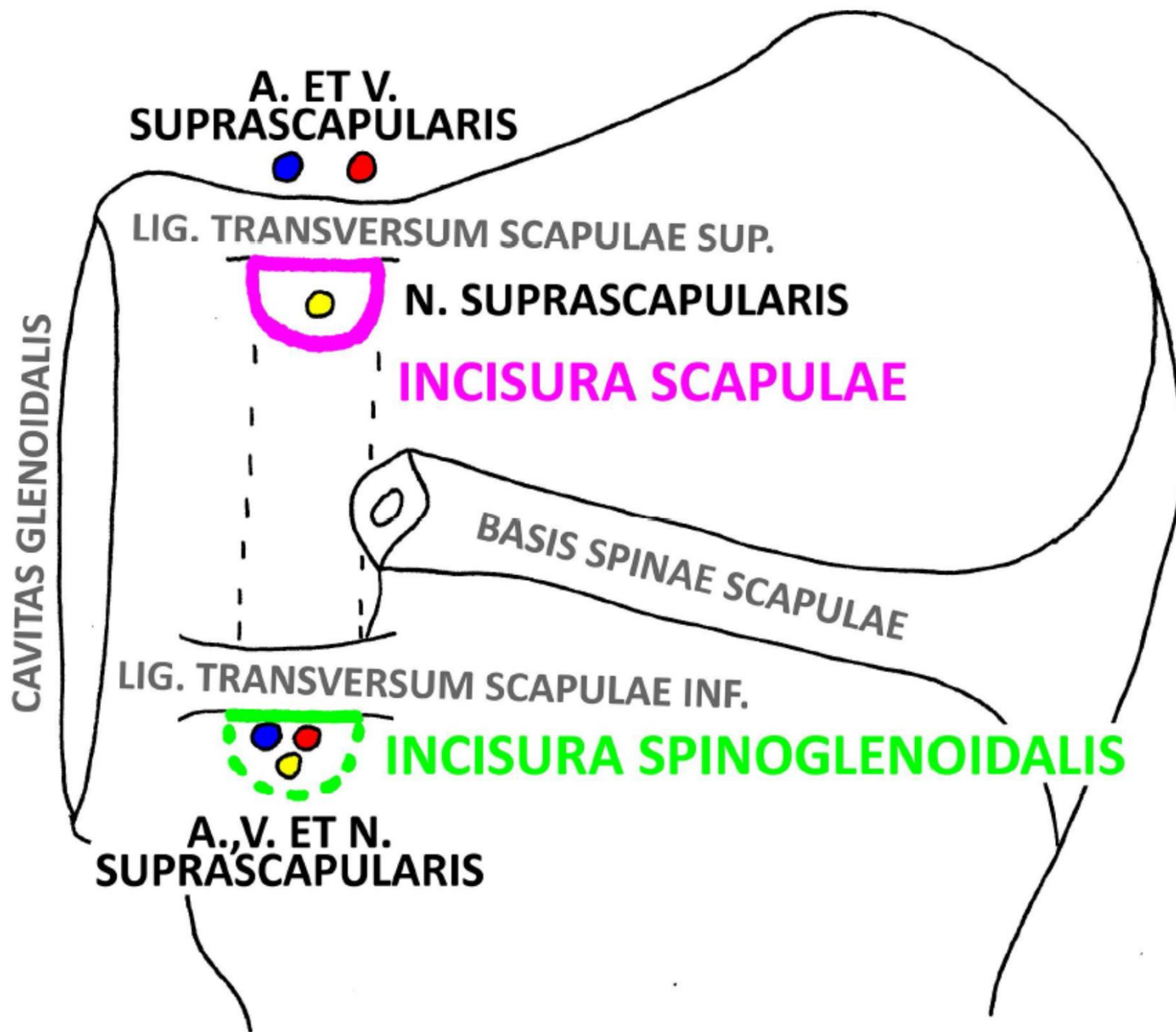




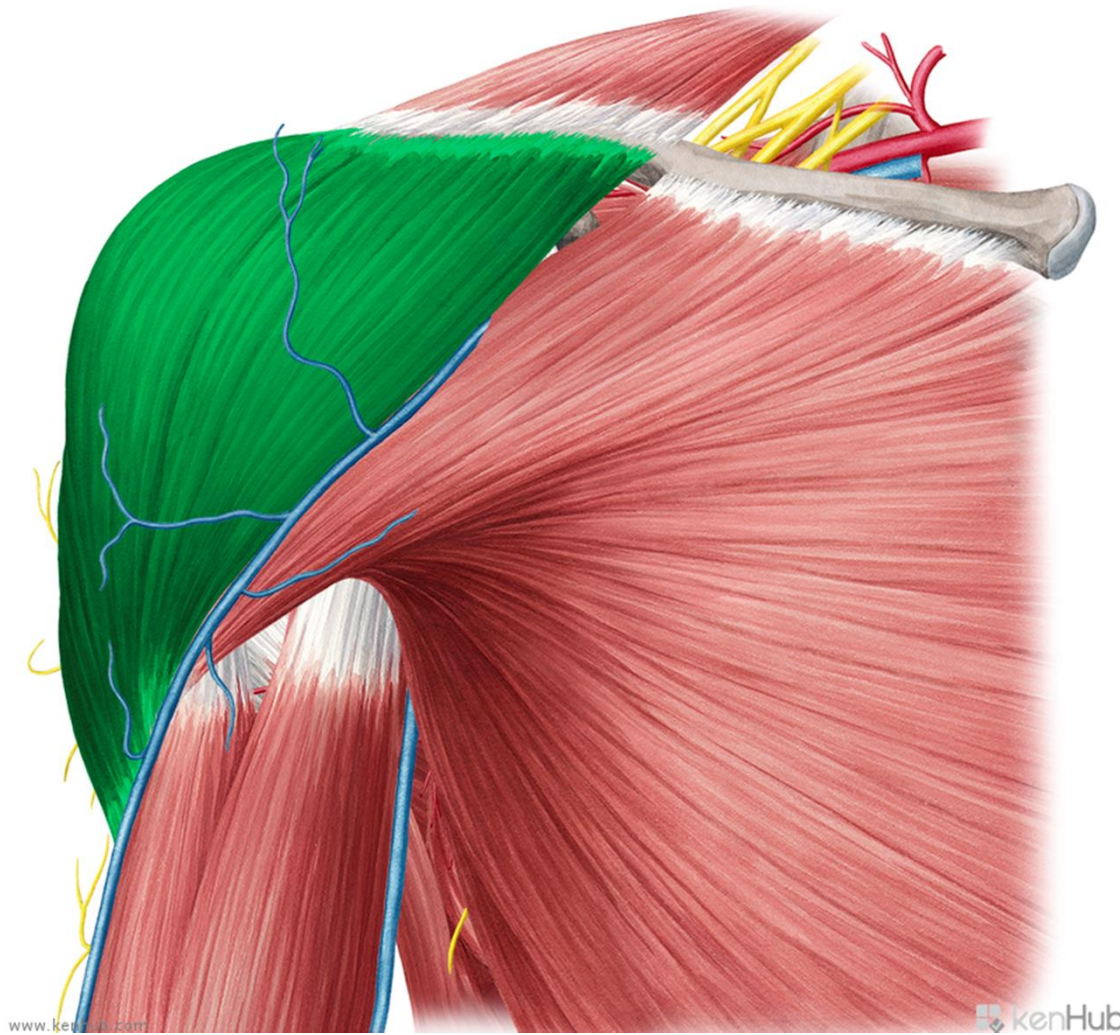
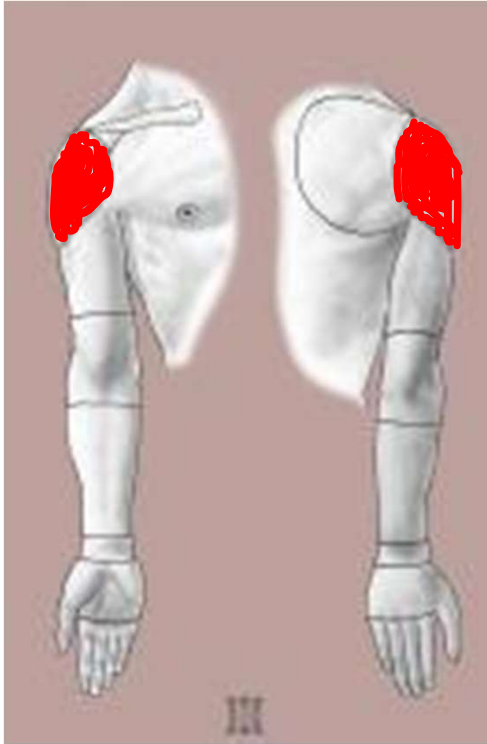


incisura scapulae





r. deltoidea

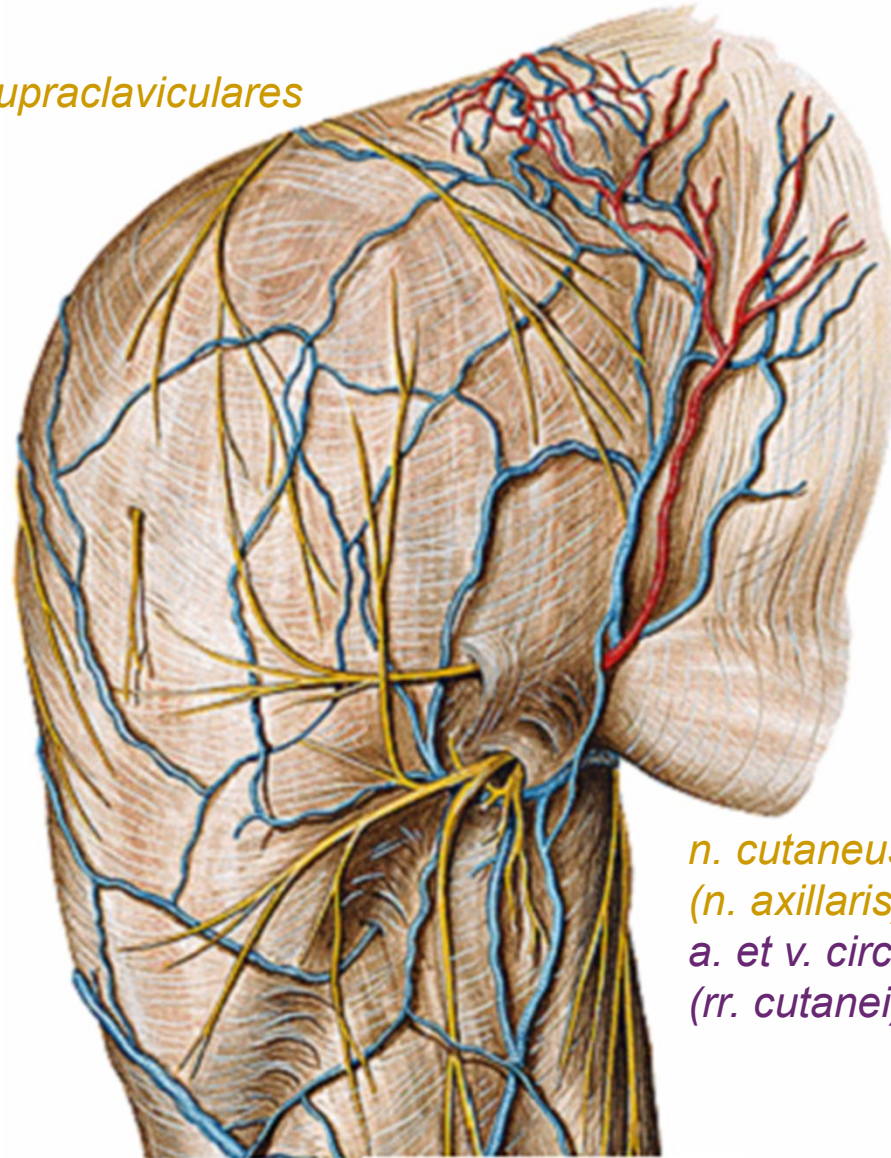


www.kenhub.com

kenHub



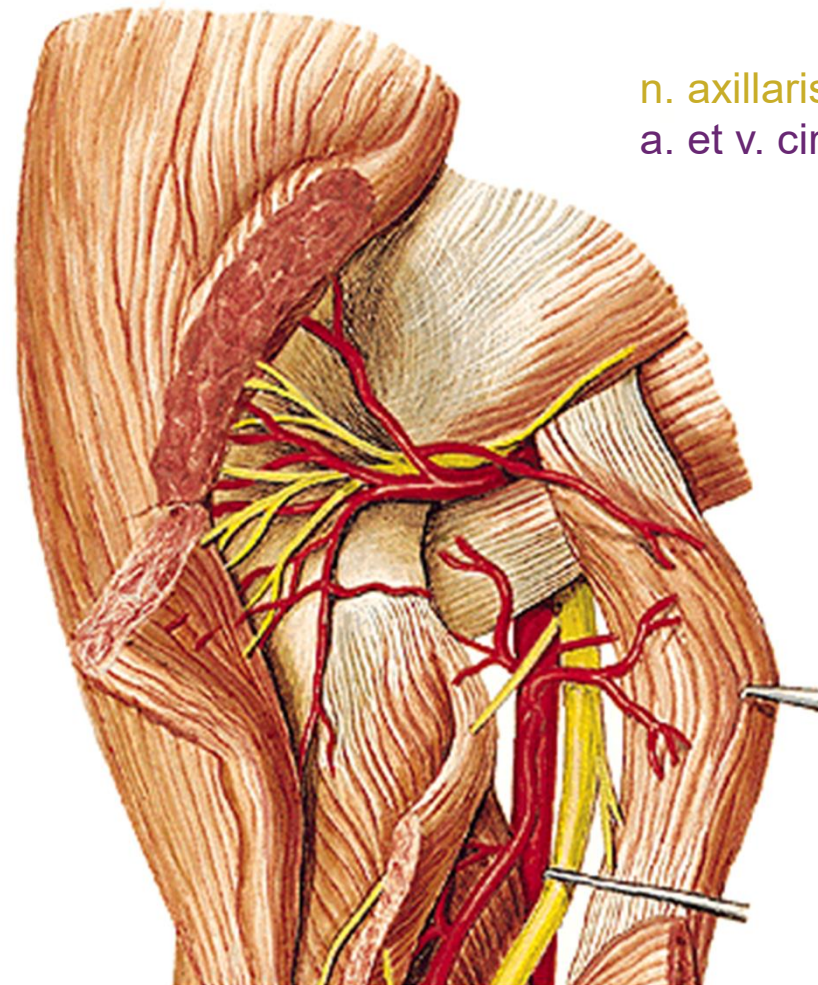
nn. supraclaviculares



*n. cutaneus brachii lat. sup.
(n. axillaris)
a. et v. circumflexa humeri post.
(rr. cutanei)*

*Left extremity
from behind*





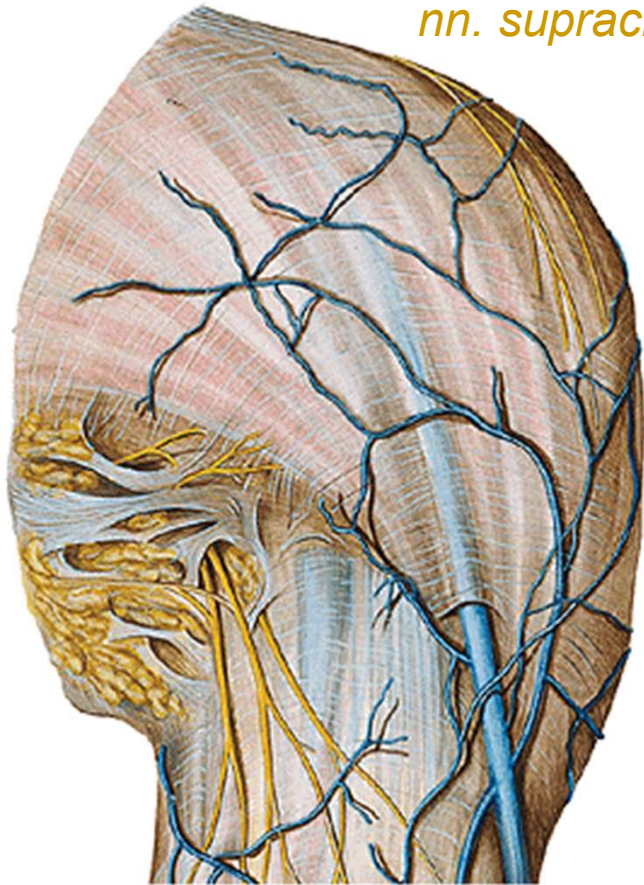
n. axillaris

a. et v. circumflexa humeri post.

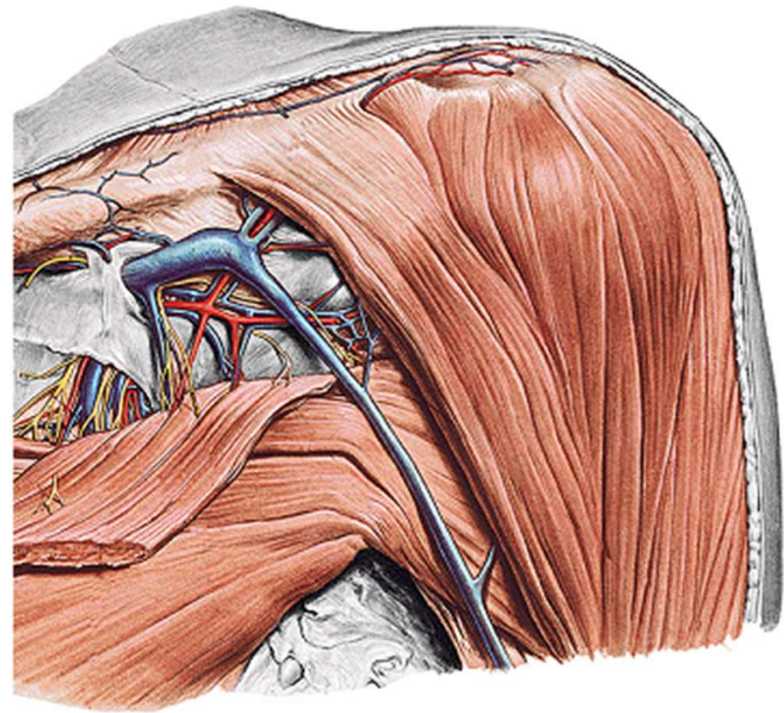
From behind



nn. supraclaviculares



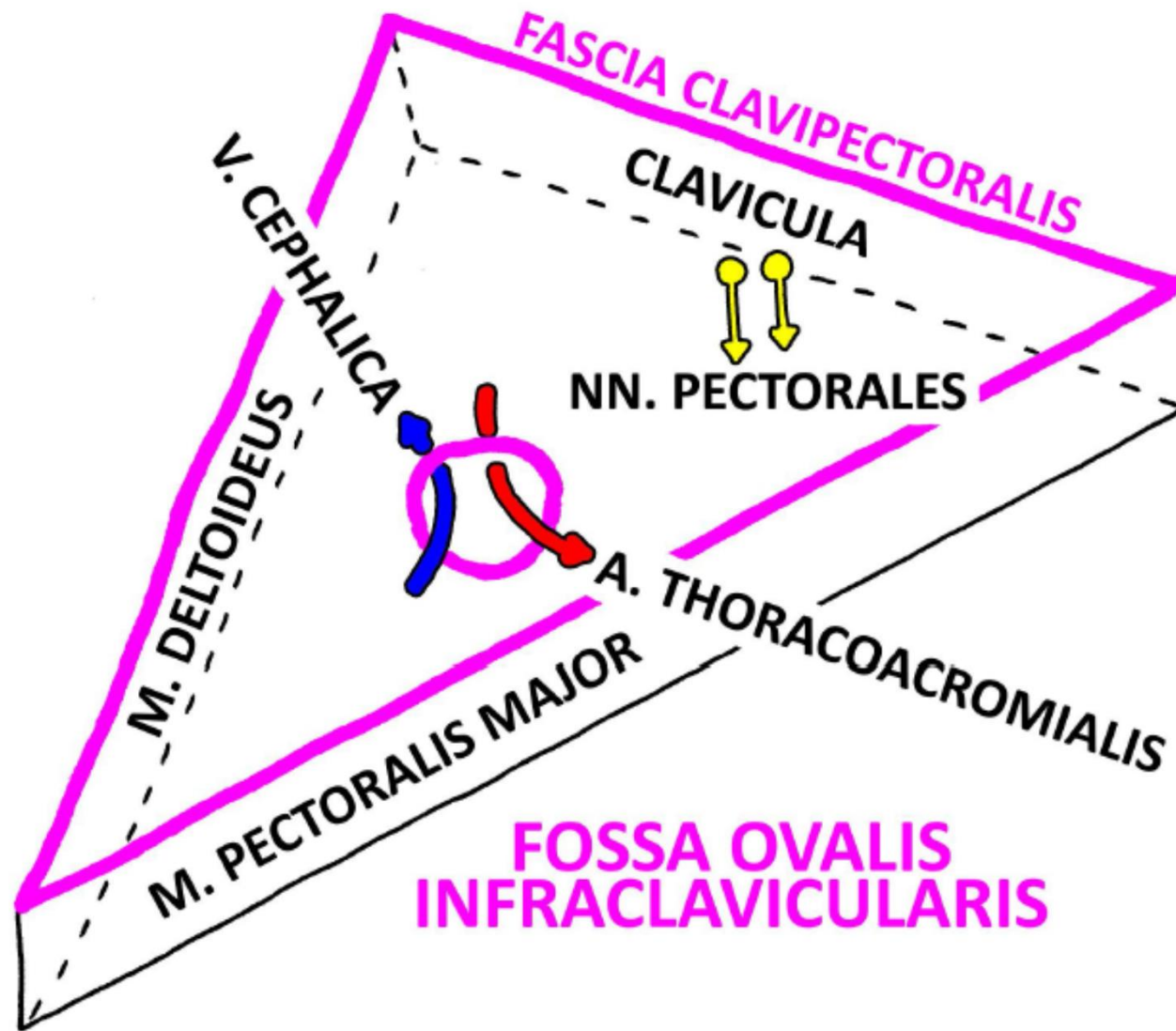
From the front

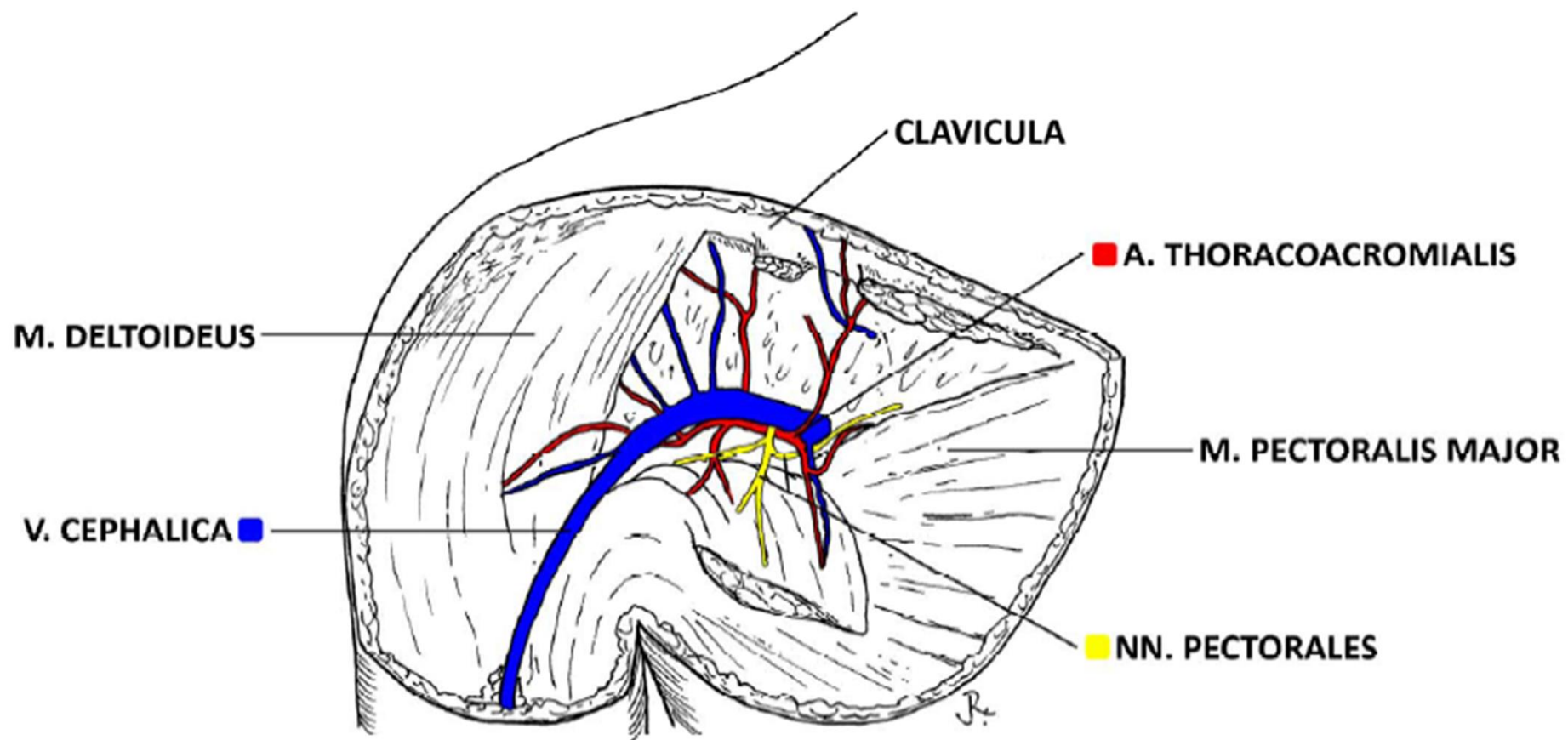


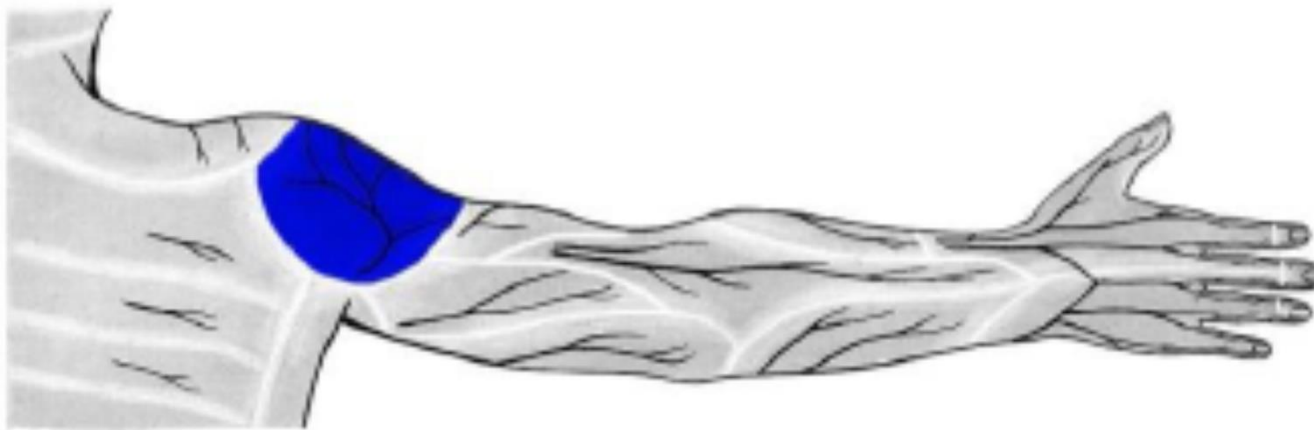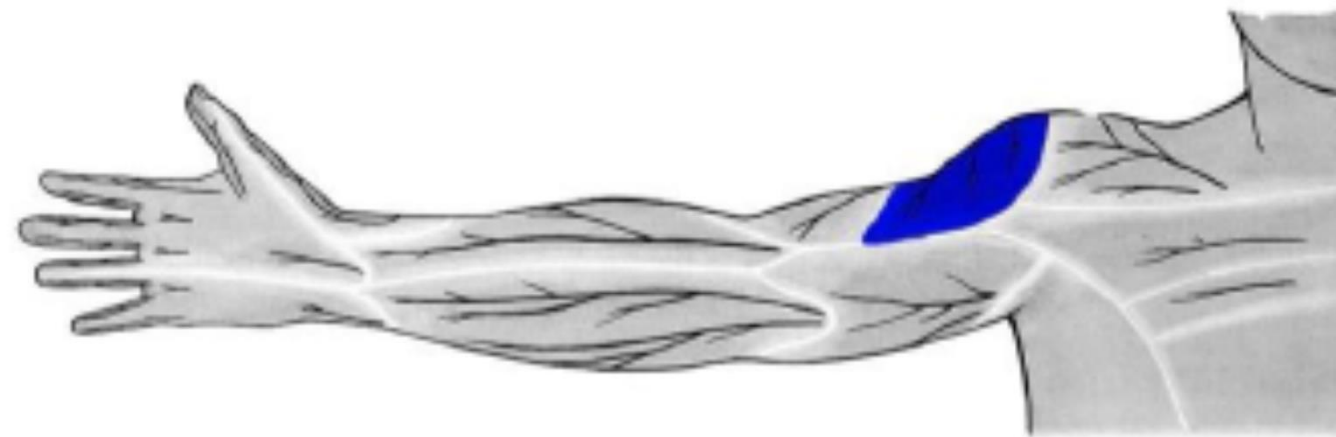
trigonum
deltoideopectorale



TRIGONUM CLAVIPECTORALE DX.



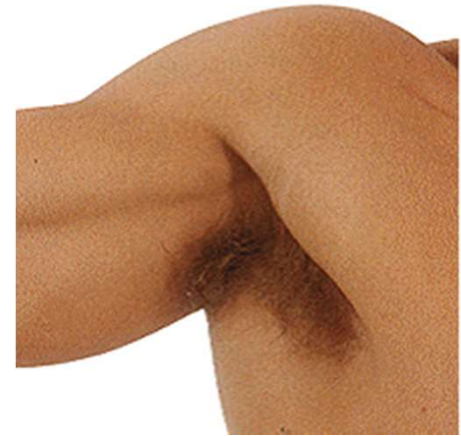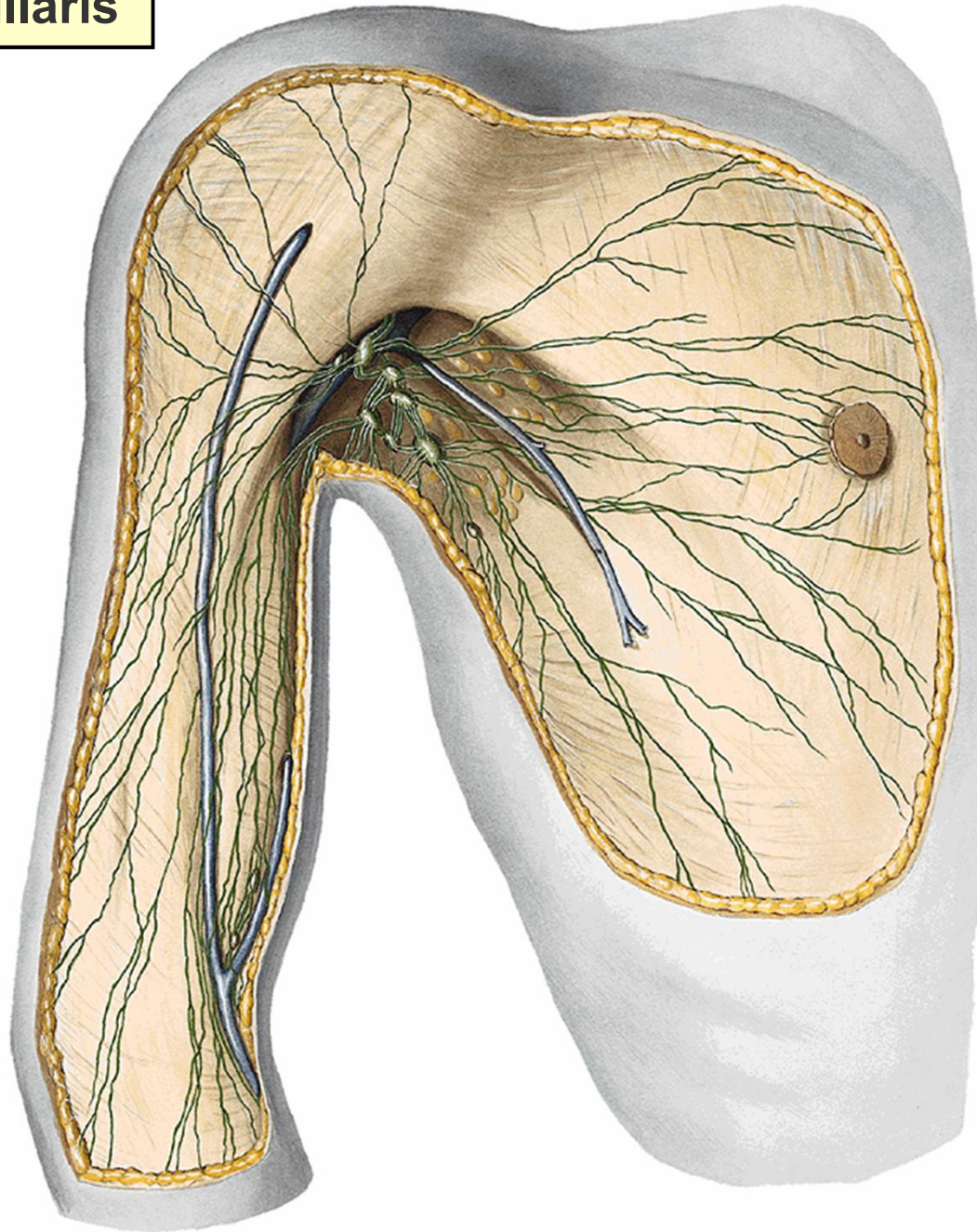




n. cutaneus brachii lat. sup. (z n. axillaris)

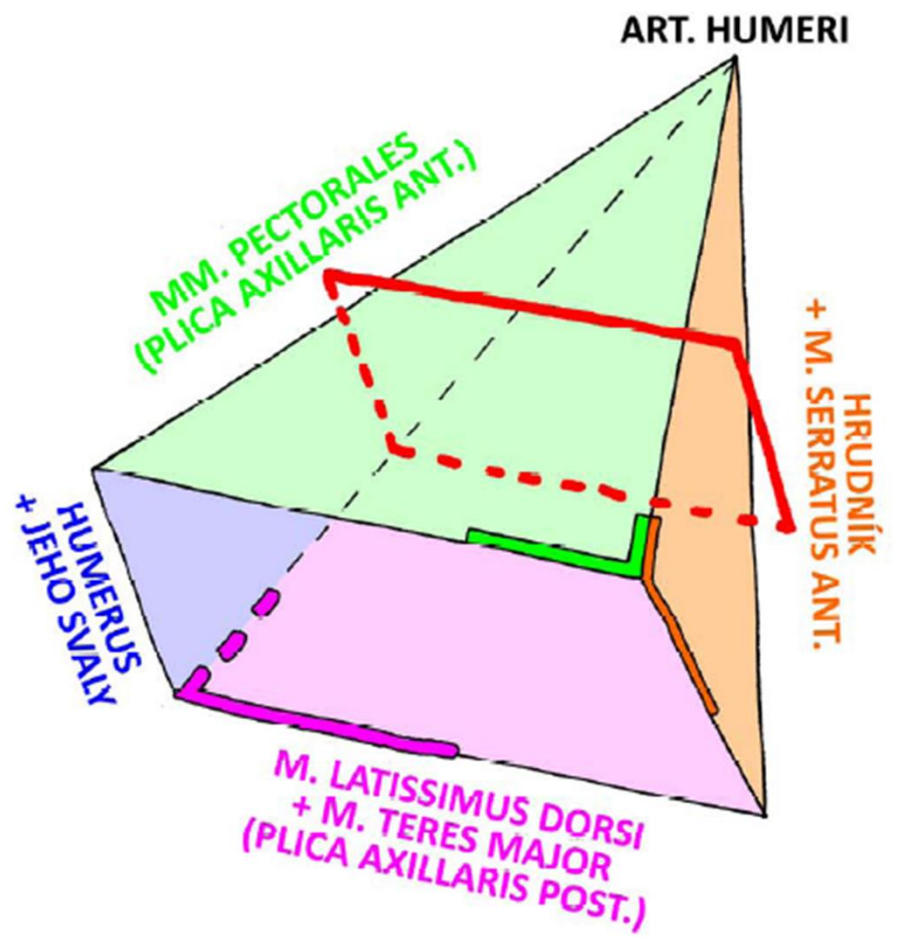
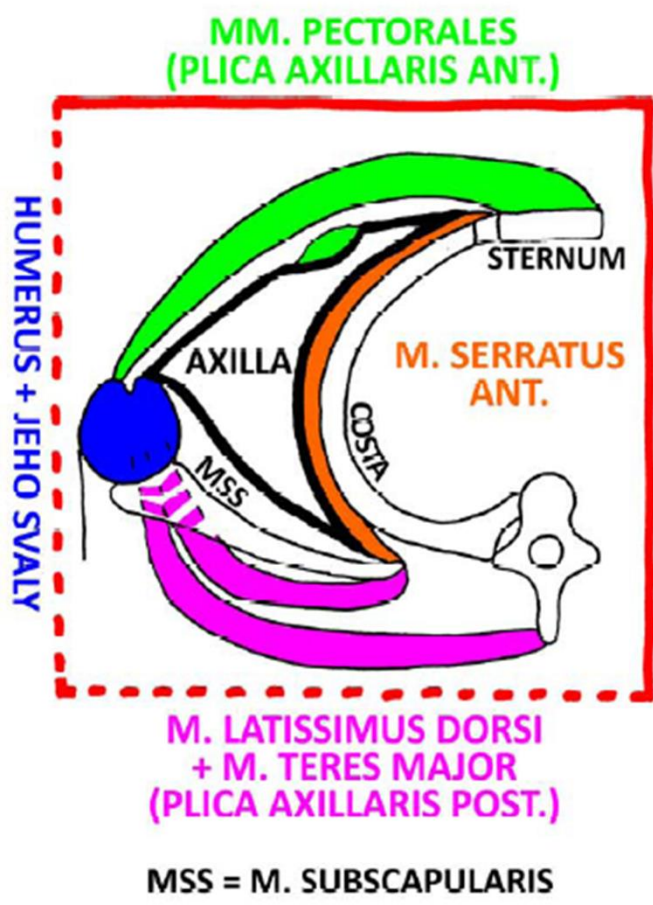

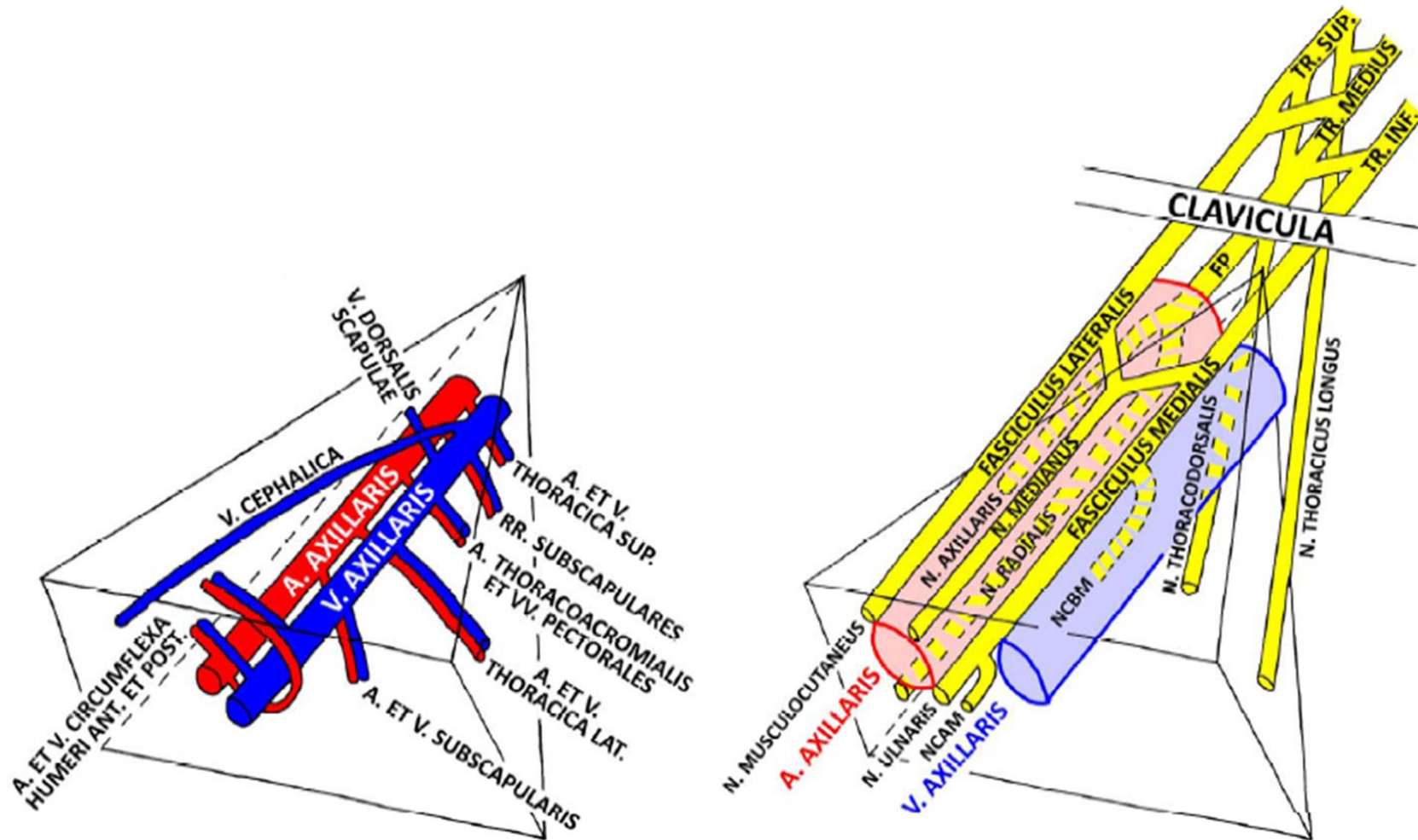
fossa axillaris



v. thoracoepigastrica
lymphatic vessels

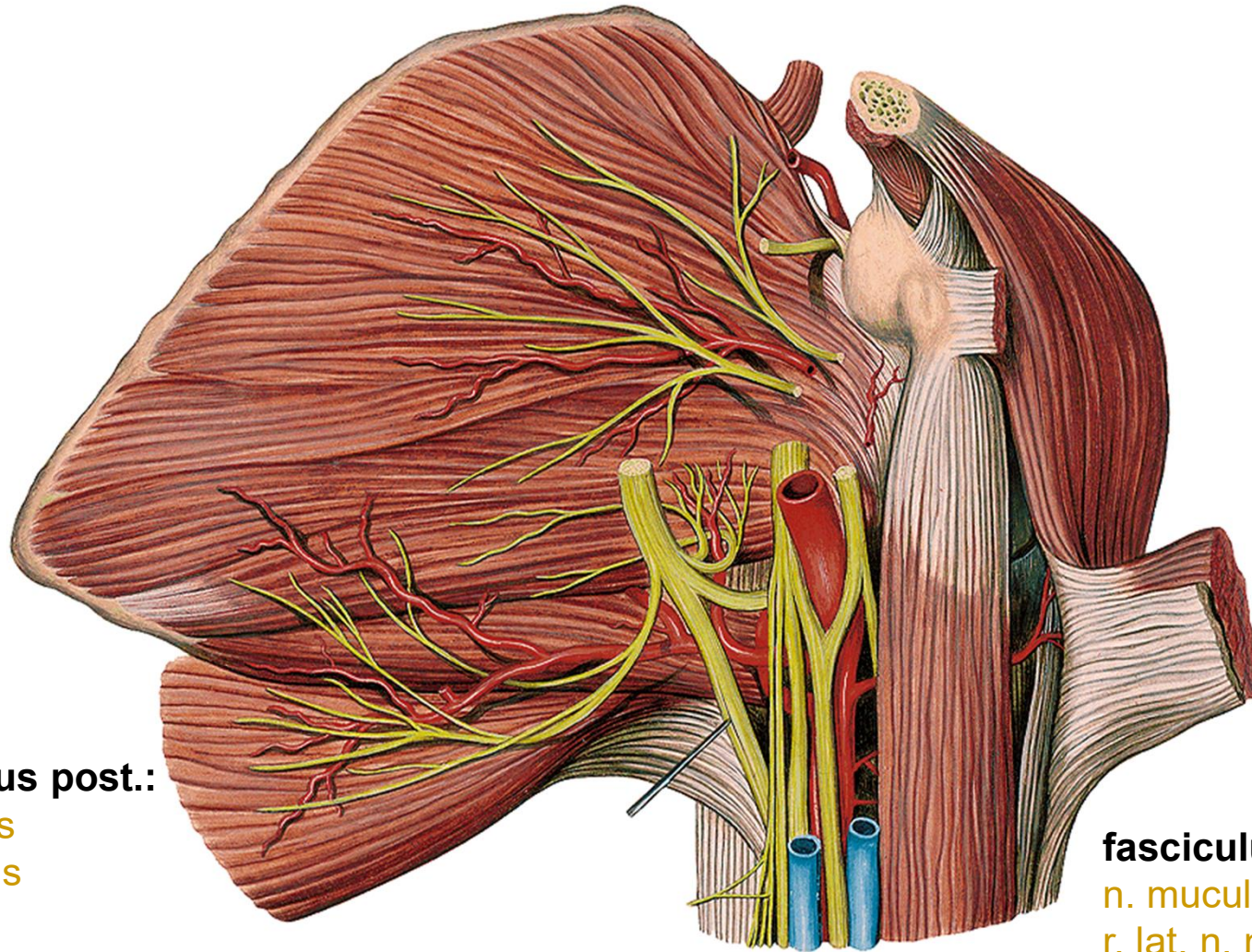






FP = FASCICULUS POSTERIOR
 NCBM = N. CUTANEUS BRACHI MEDIALIS
 NCAM = N. CUTANEUS ANTEBRACHII MEDIALIS





fasciculus post.:

n. radialis
n. axillaris

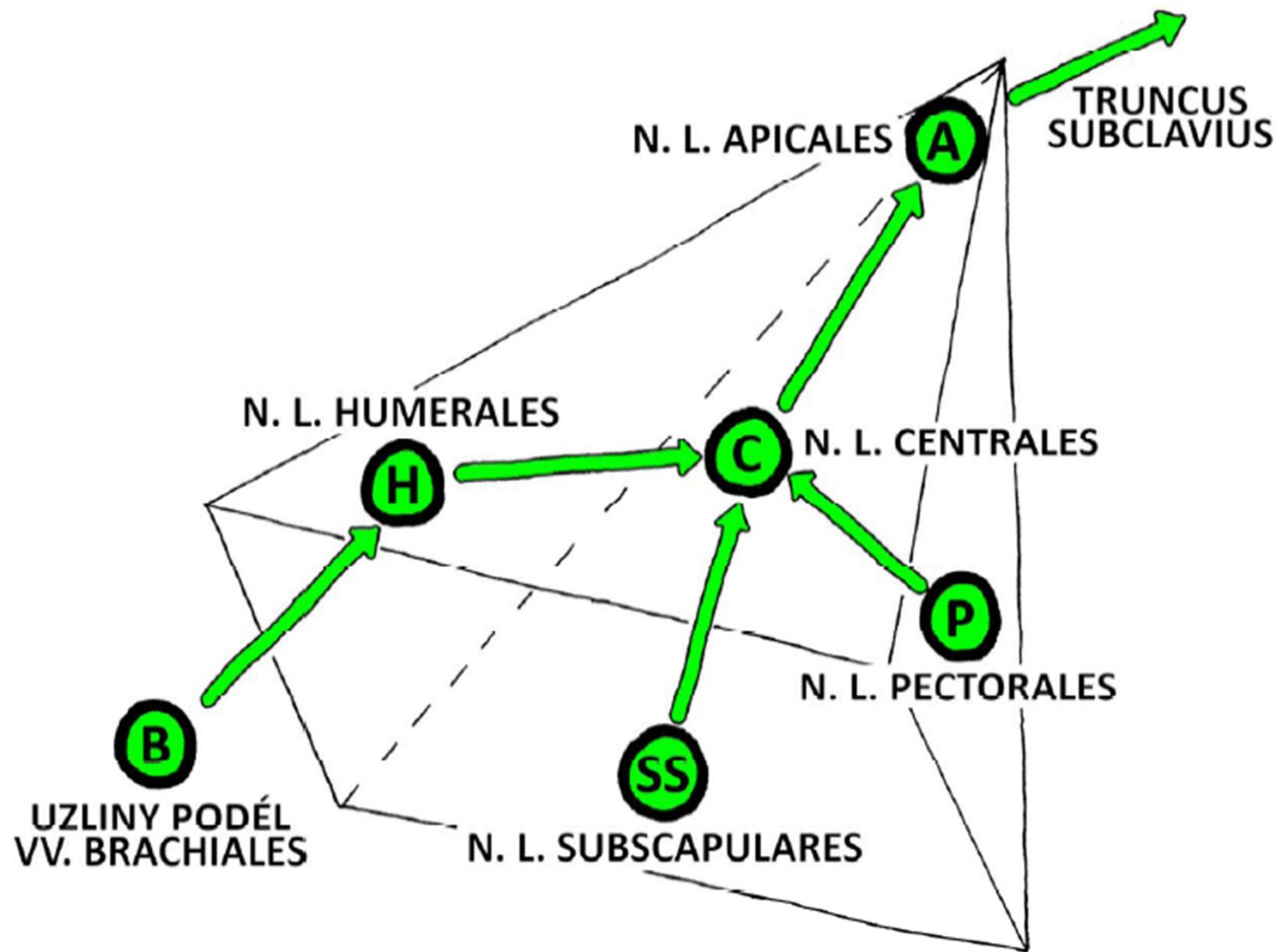
fasciculus lat.:

n. musculocutaneus
r. lat. n. mediani

fasciculus med.:

r. med. n. mediani
n. ulnaris
n. cutaneus brachii med.
n. cutaneus antebrachii med.

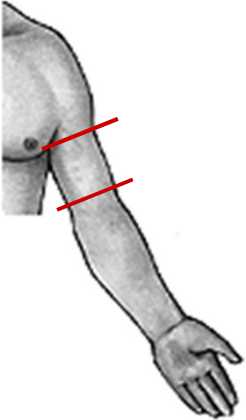
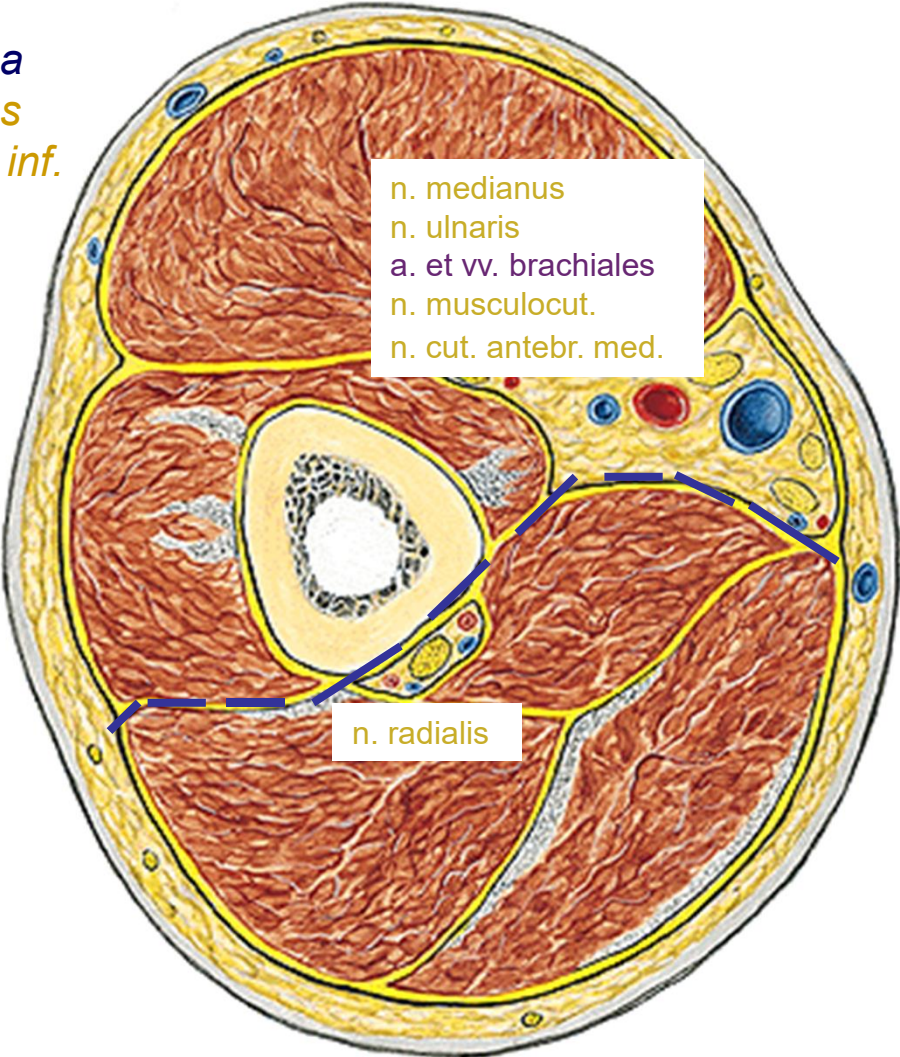




r. brachii

Right one , from below

v. cephalica
n. cutaneus
brachii lat. inf.

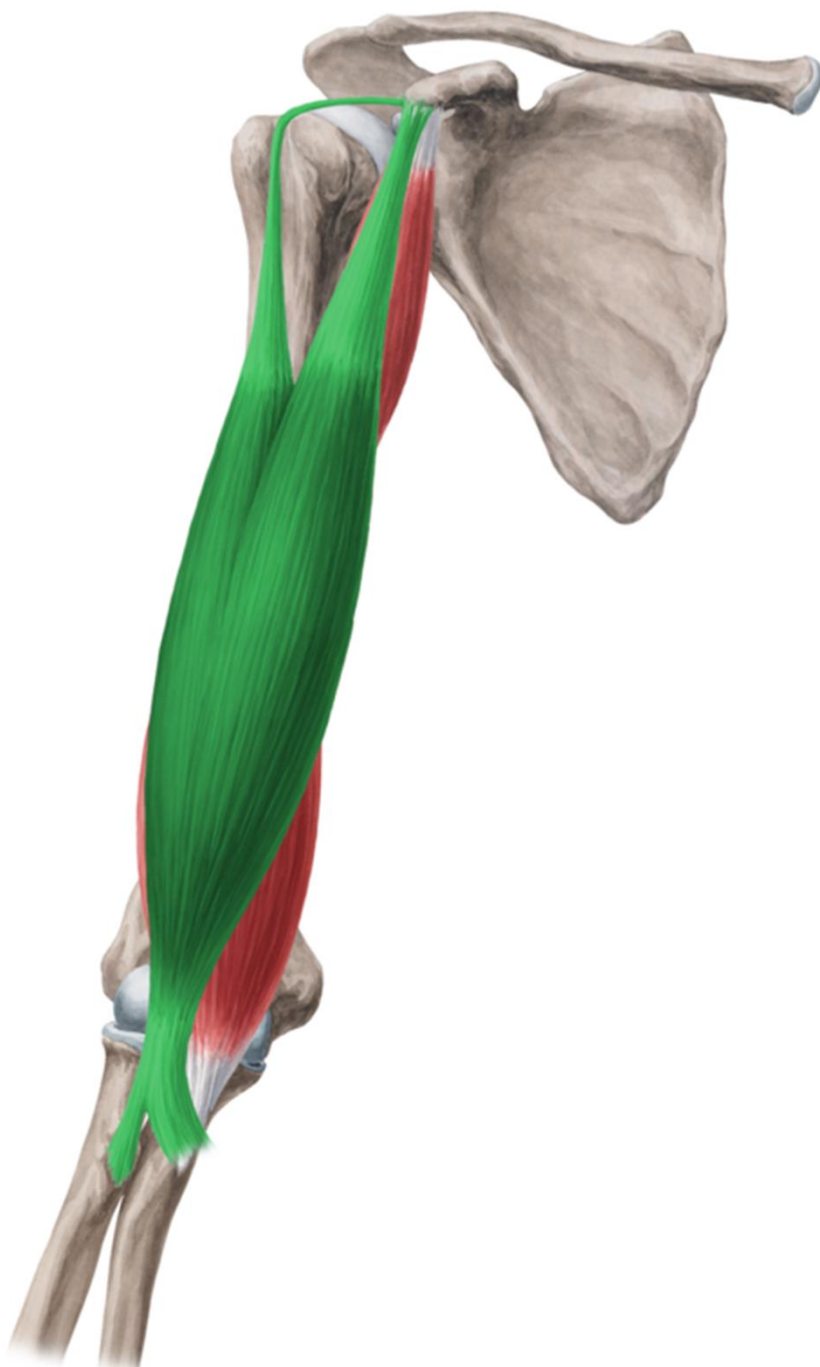

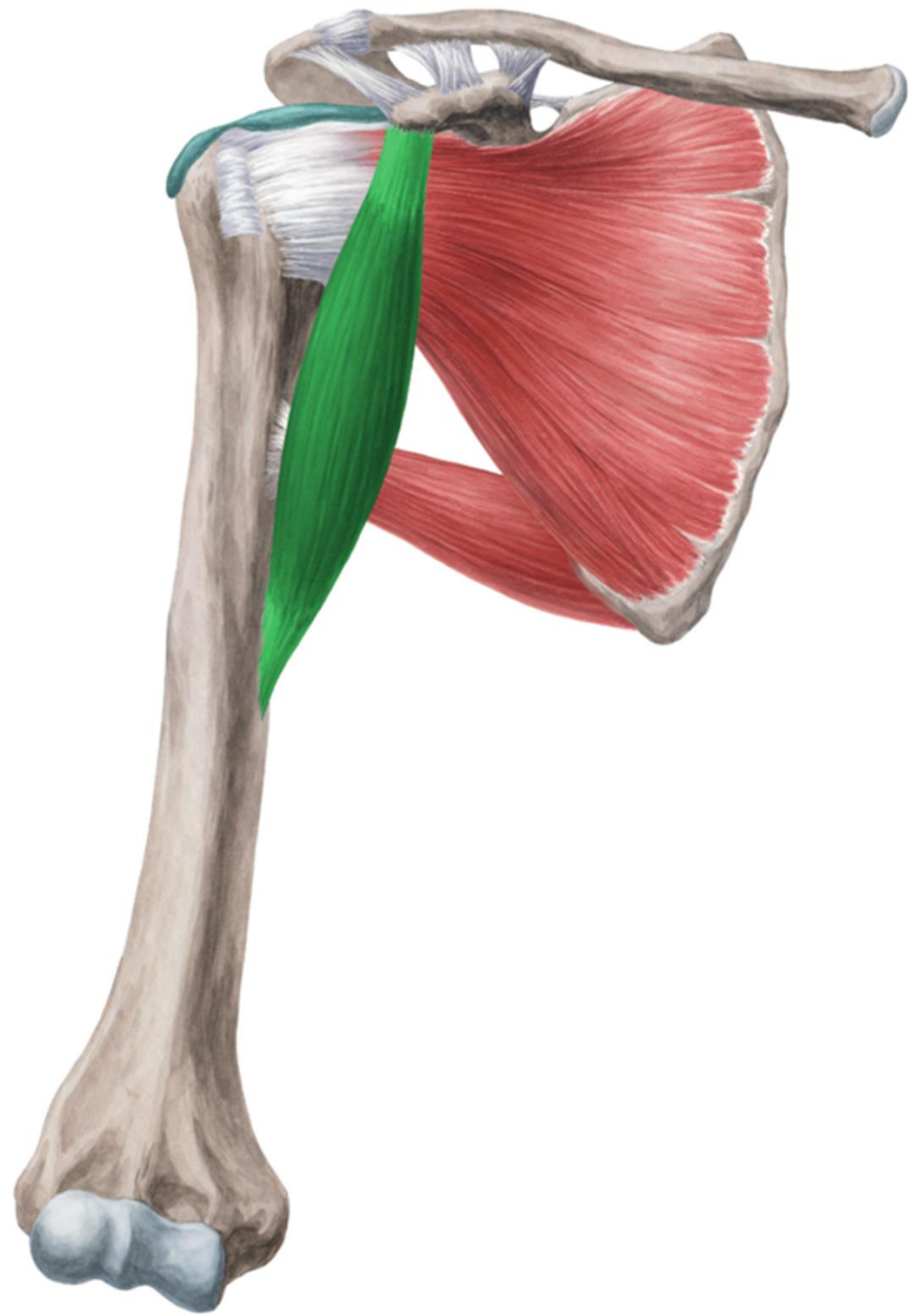
v. basilica
n. cutaneus
brachii med.

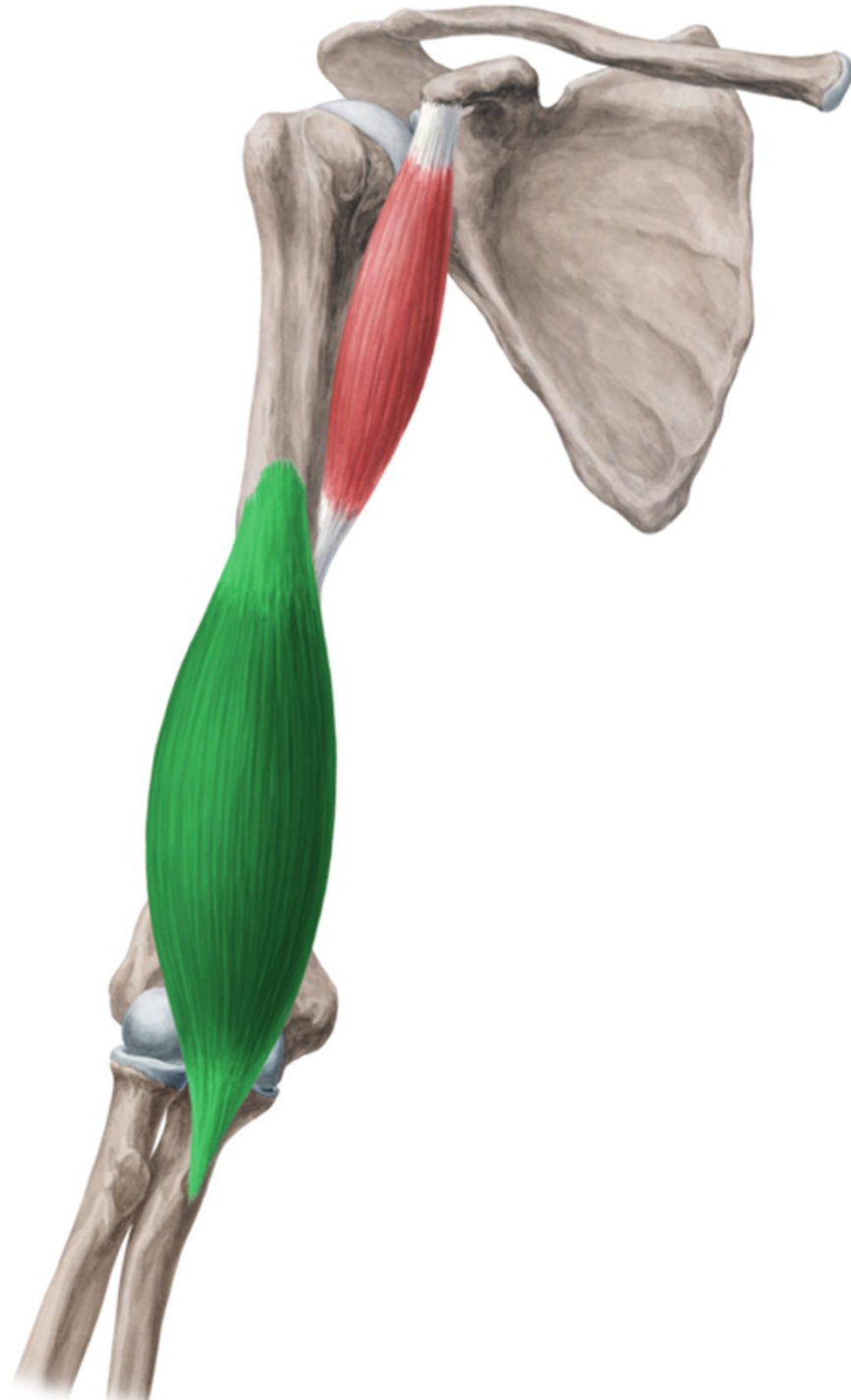
n. cutaneus brachii
post.



r. brachii ant.





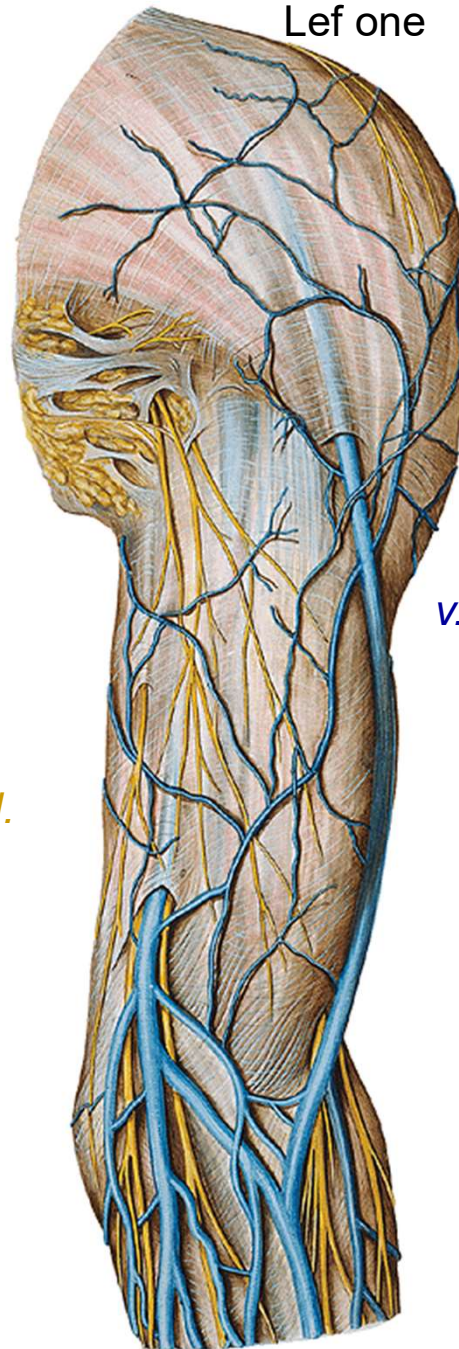


Lef one

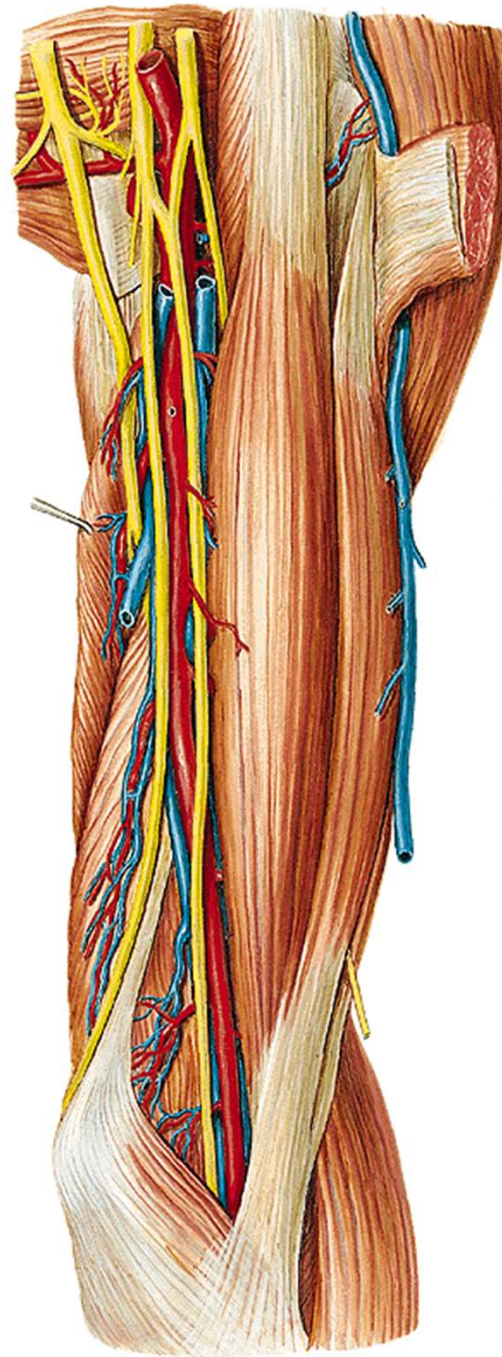
n. cutaneus brachii med.

n. cutaneus antebrachii med.
v. basilica

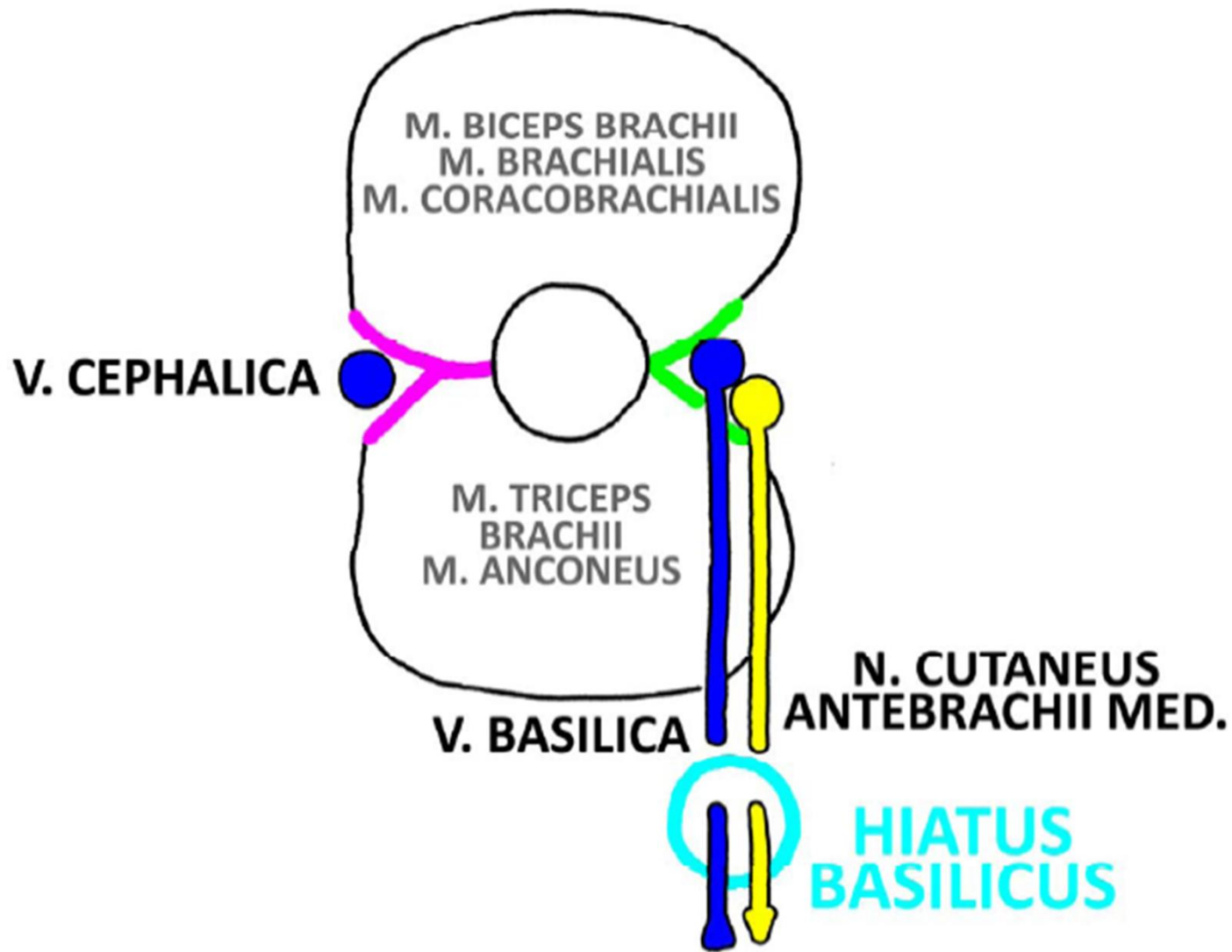
v. cephalica

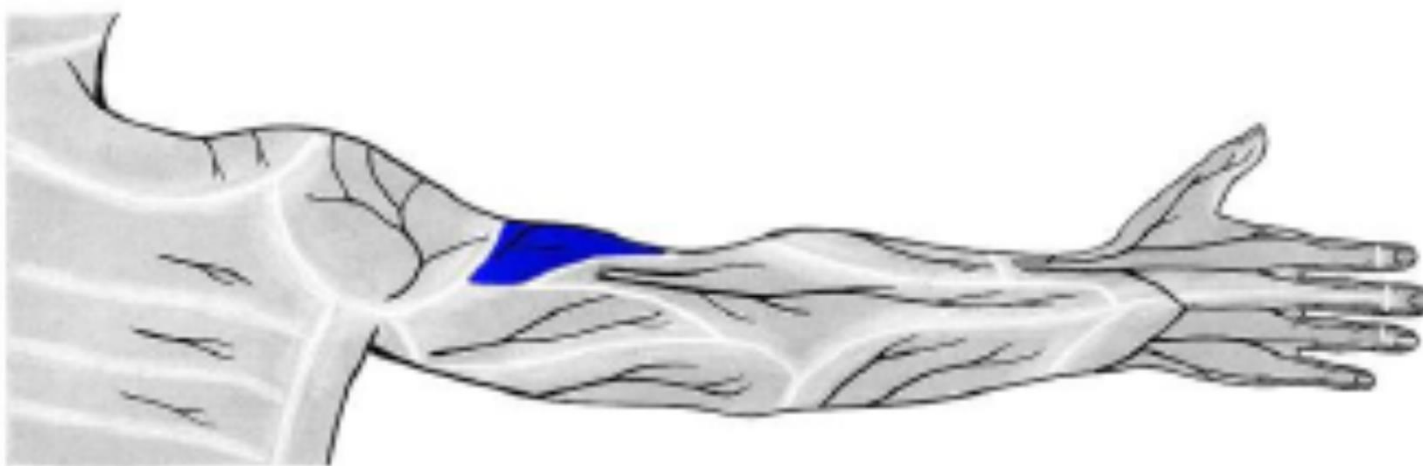

a. et. v. brachialis
n. musculocutaneus
n. medianus
n. ulnaris



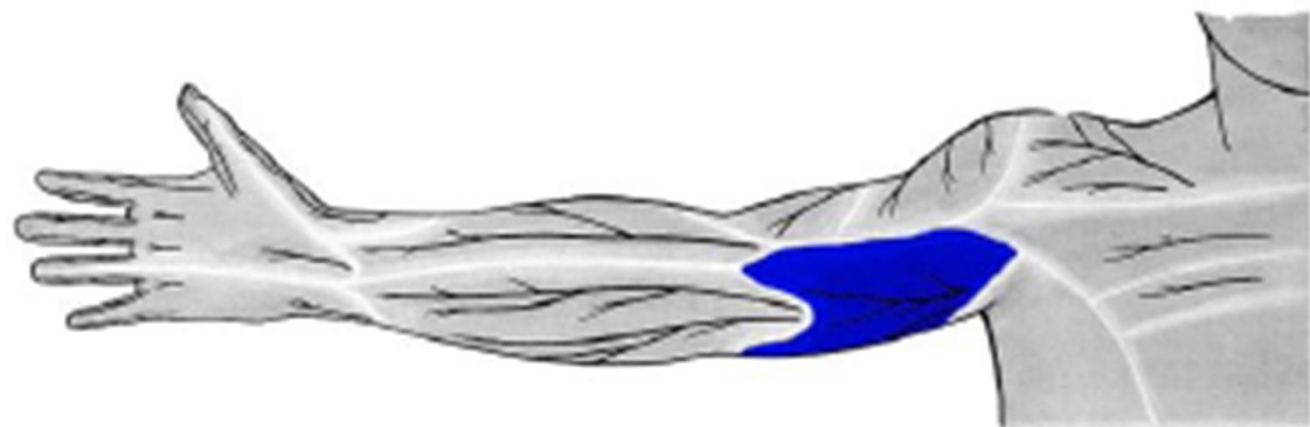
SULCUS BICIPITALIS MEDIALIS ET LATERALIS





n. cutaneus brachii lat. inf. (z *n. radialis*)

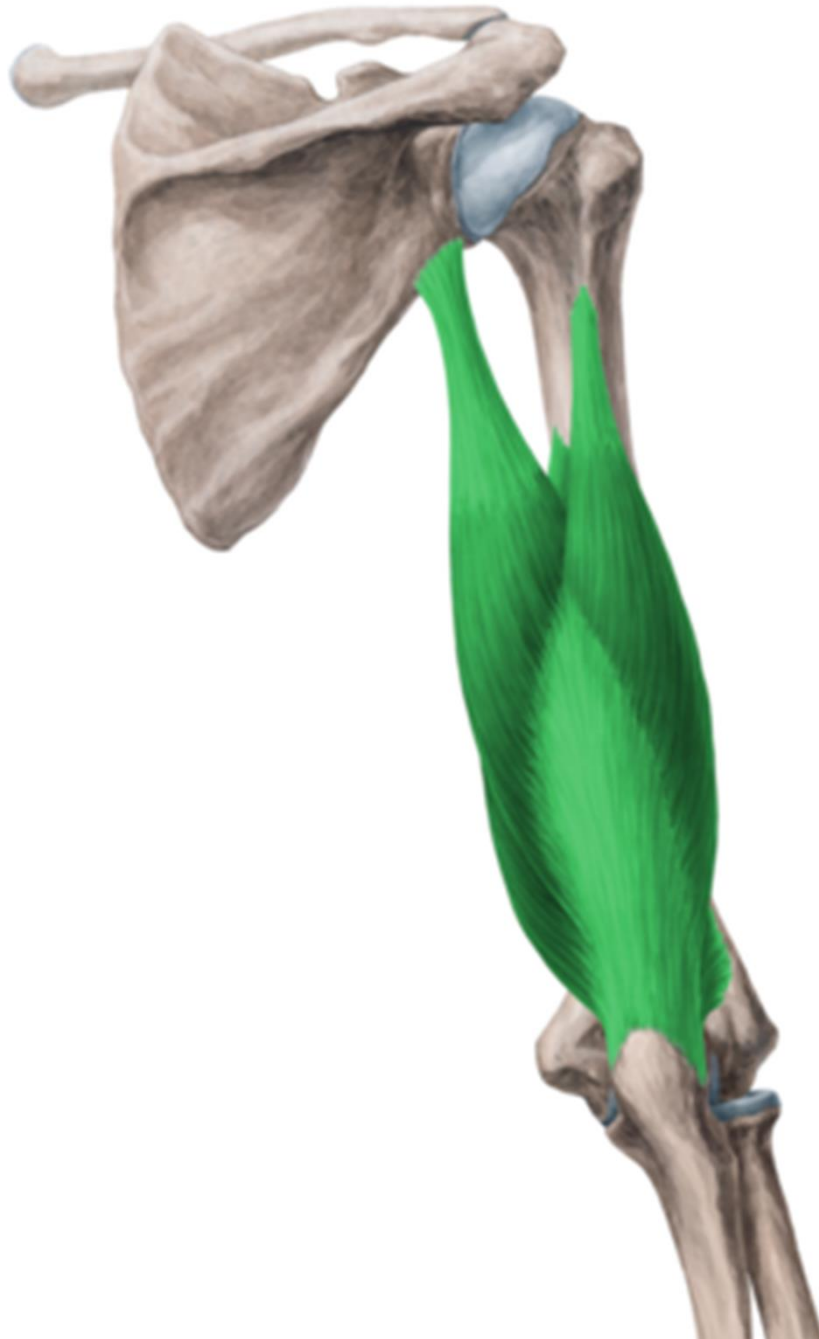


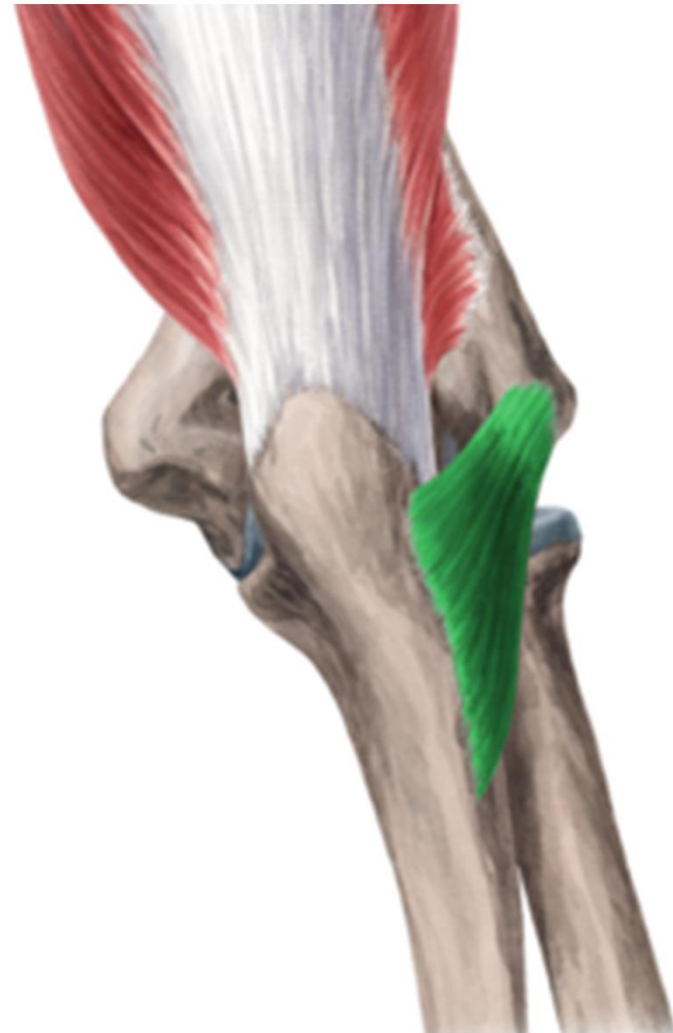
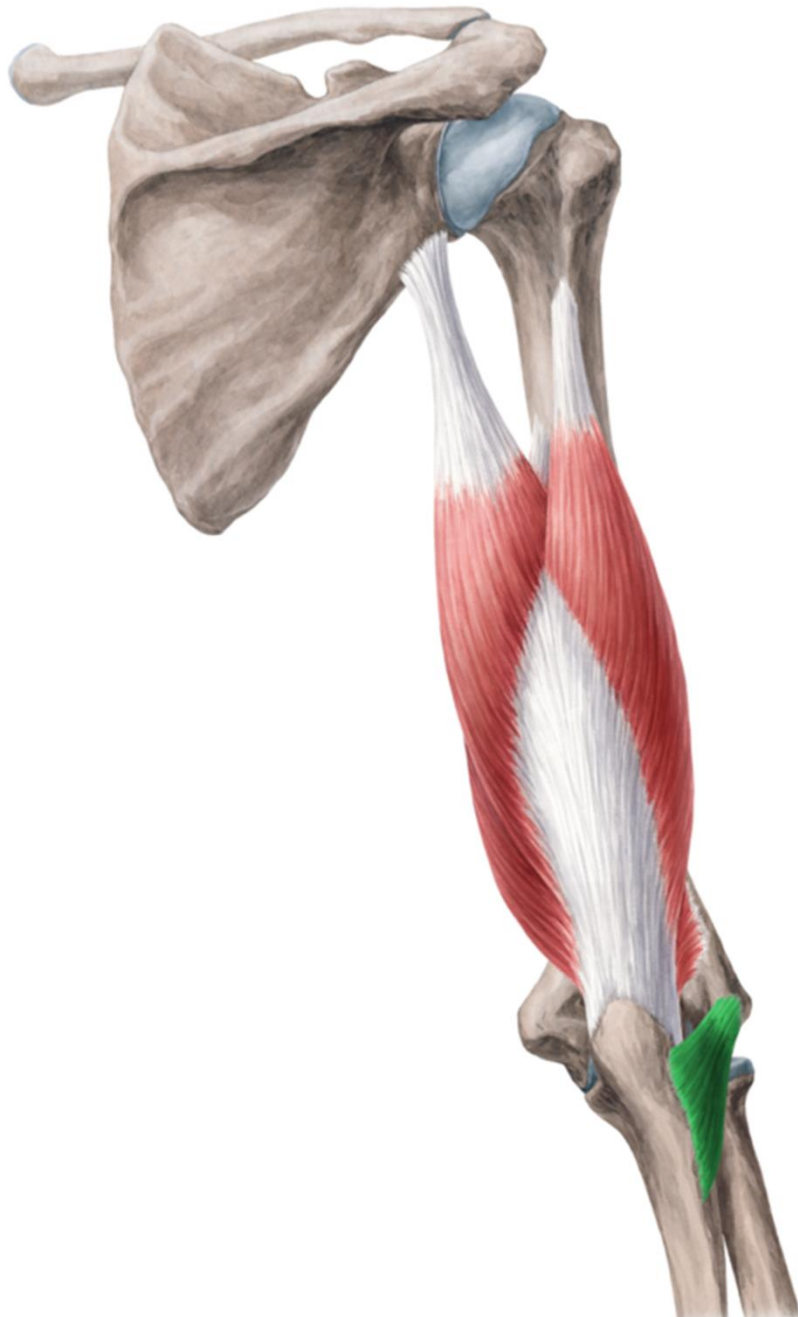n. cutaneus brachii med.
(z *fasciculus medialis*)



r. brachii post.

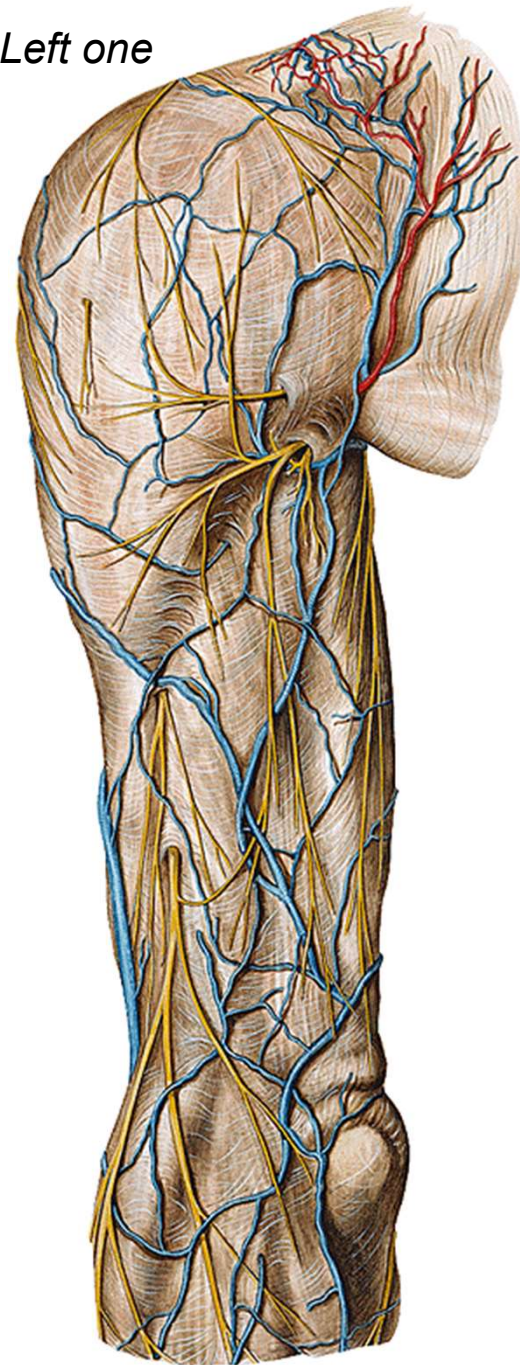




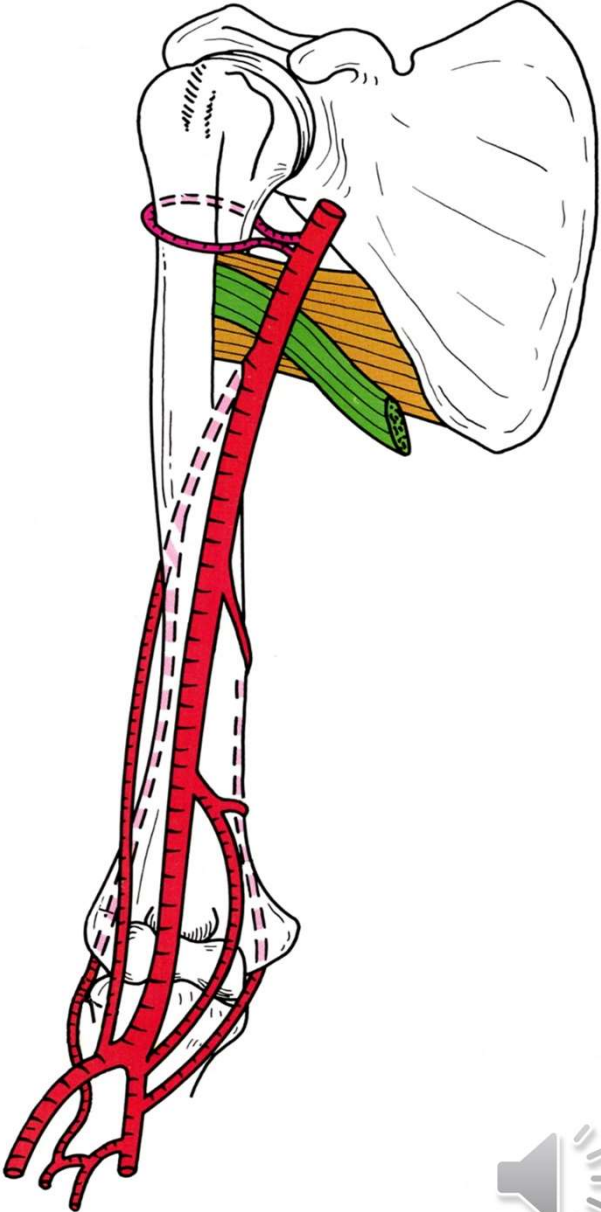
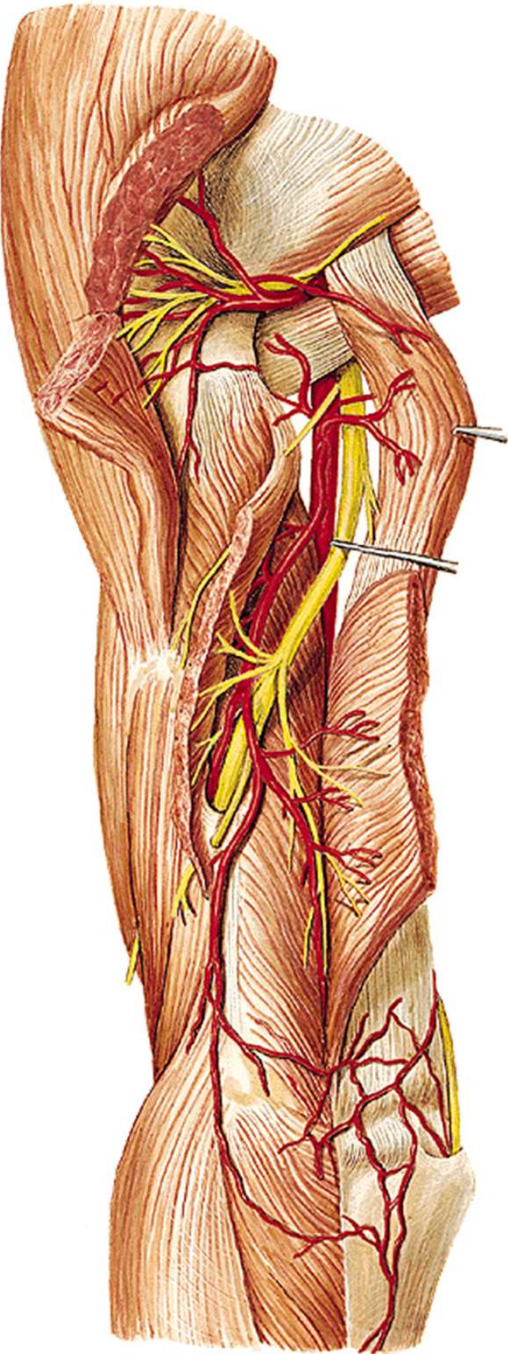
Left one

n. cutaneus brachii lat. sup.
(*n. axillaris*)

cutaneus brachii lat. inf.
n. cutaneus brachii post.
n. cutaneus antebrachii post.
(*n. radialis*)



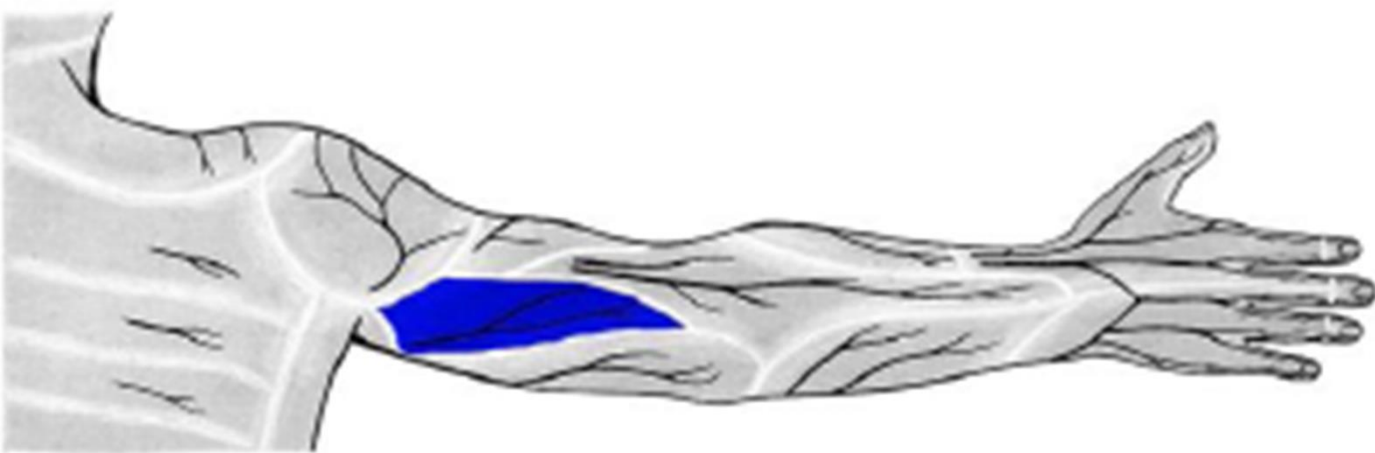
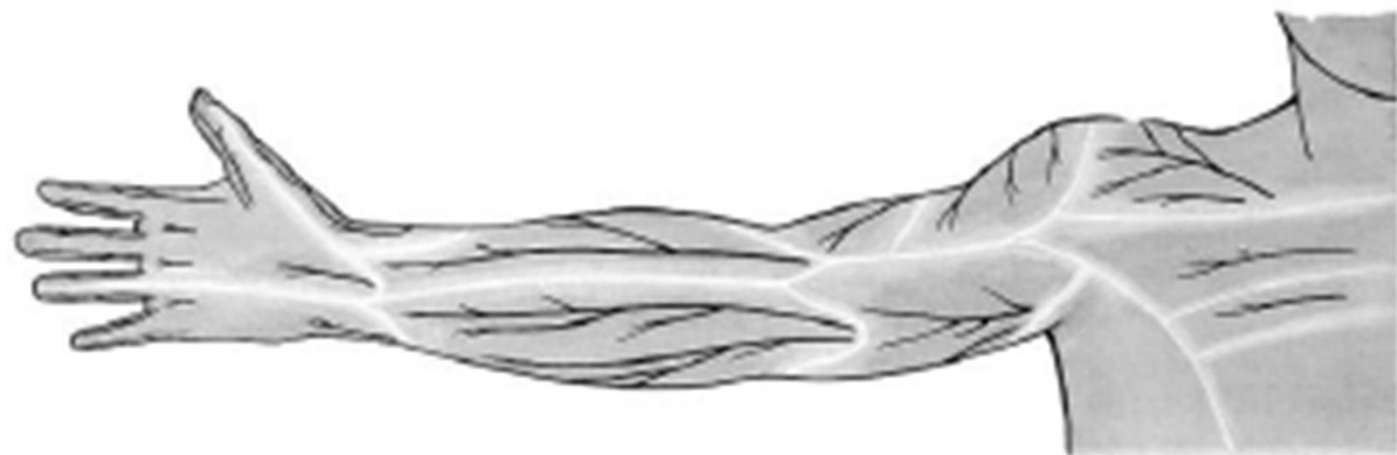n. radialis
a. et. v. profunda brachii





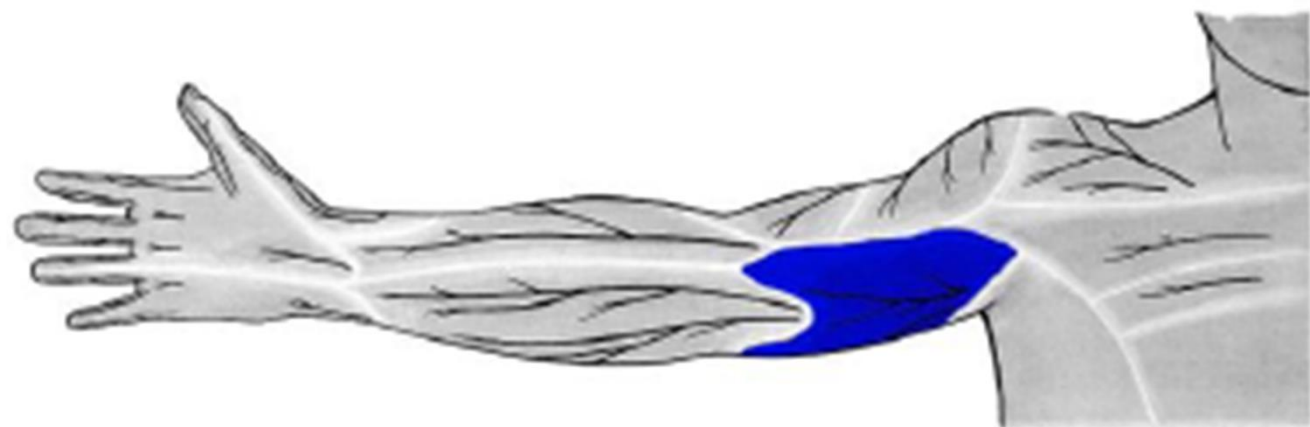
n. cutaneus brachii lat. inf. (z *n. radialis*)





n. cutaneus brachii post. (z n. radialis)

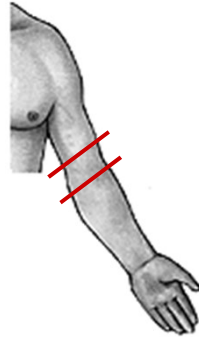




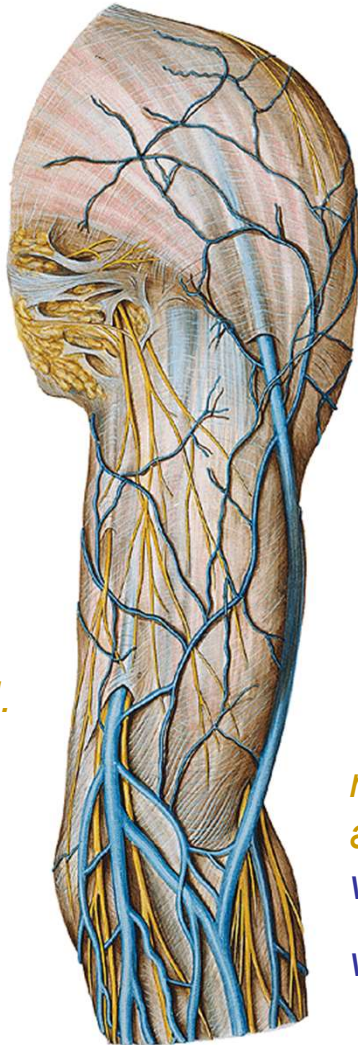
n. cutaneus brachii med.
(z *fasciculus medialis*)



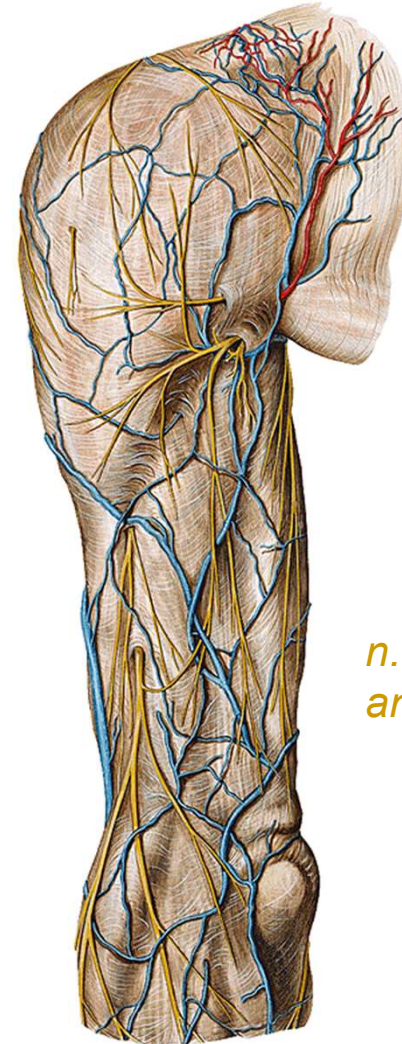
r. cubiti



*n. cutaneus
antebr. med.
v. basilica*



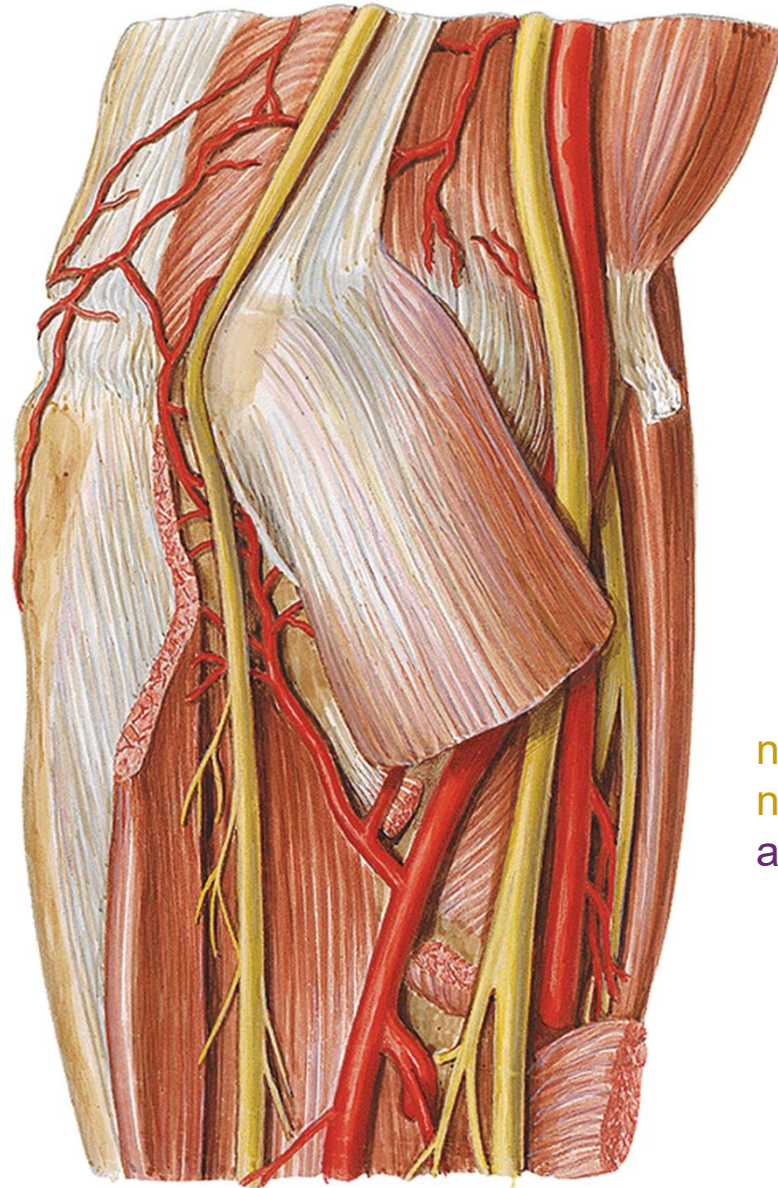
*n. cutaneus
antebr. lat.
v. cephalica
v. mediana cubiti*



*n. cutaneus
antebr. post.*



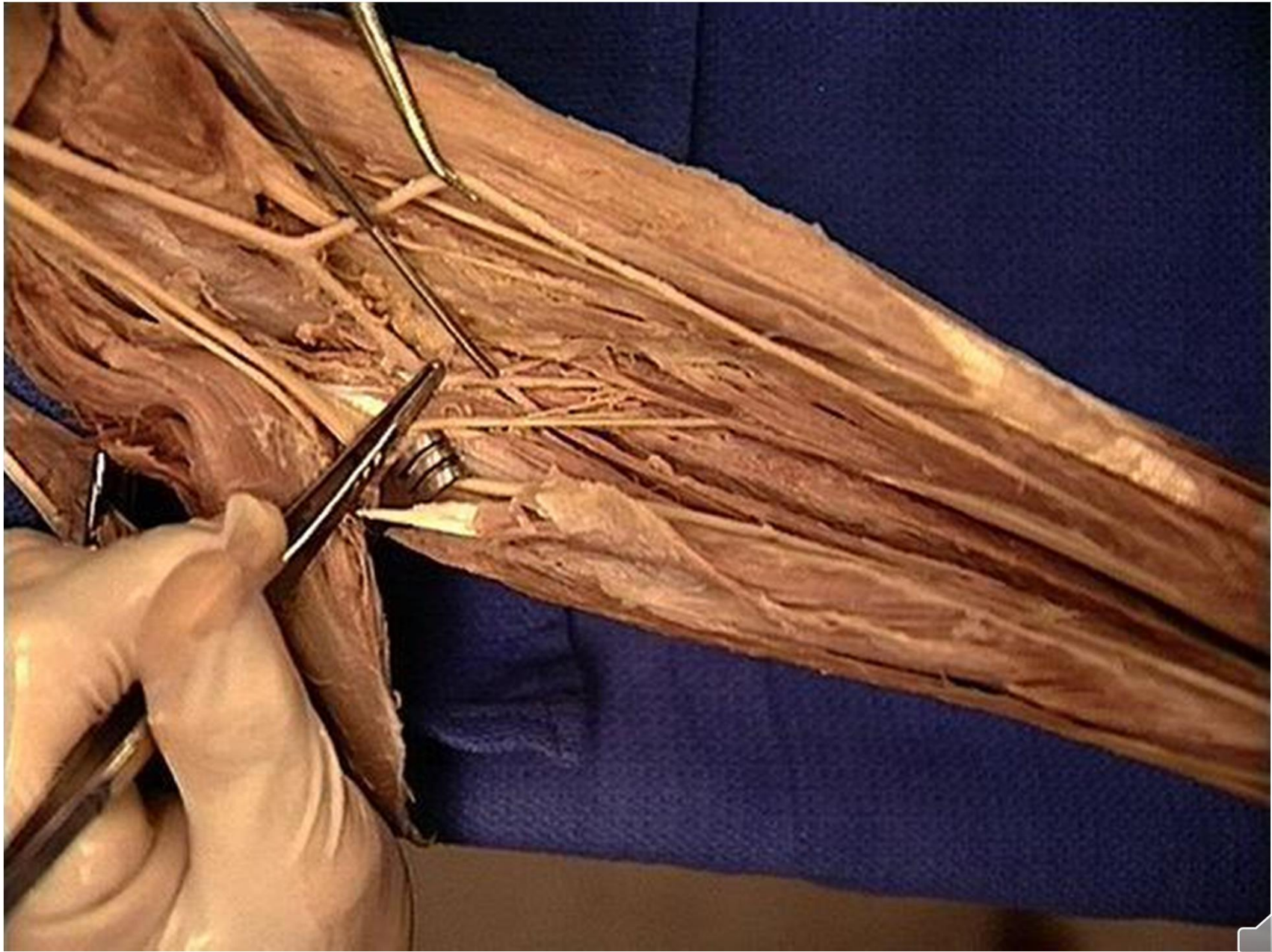
From the front



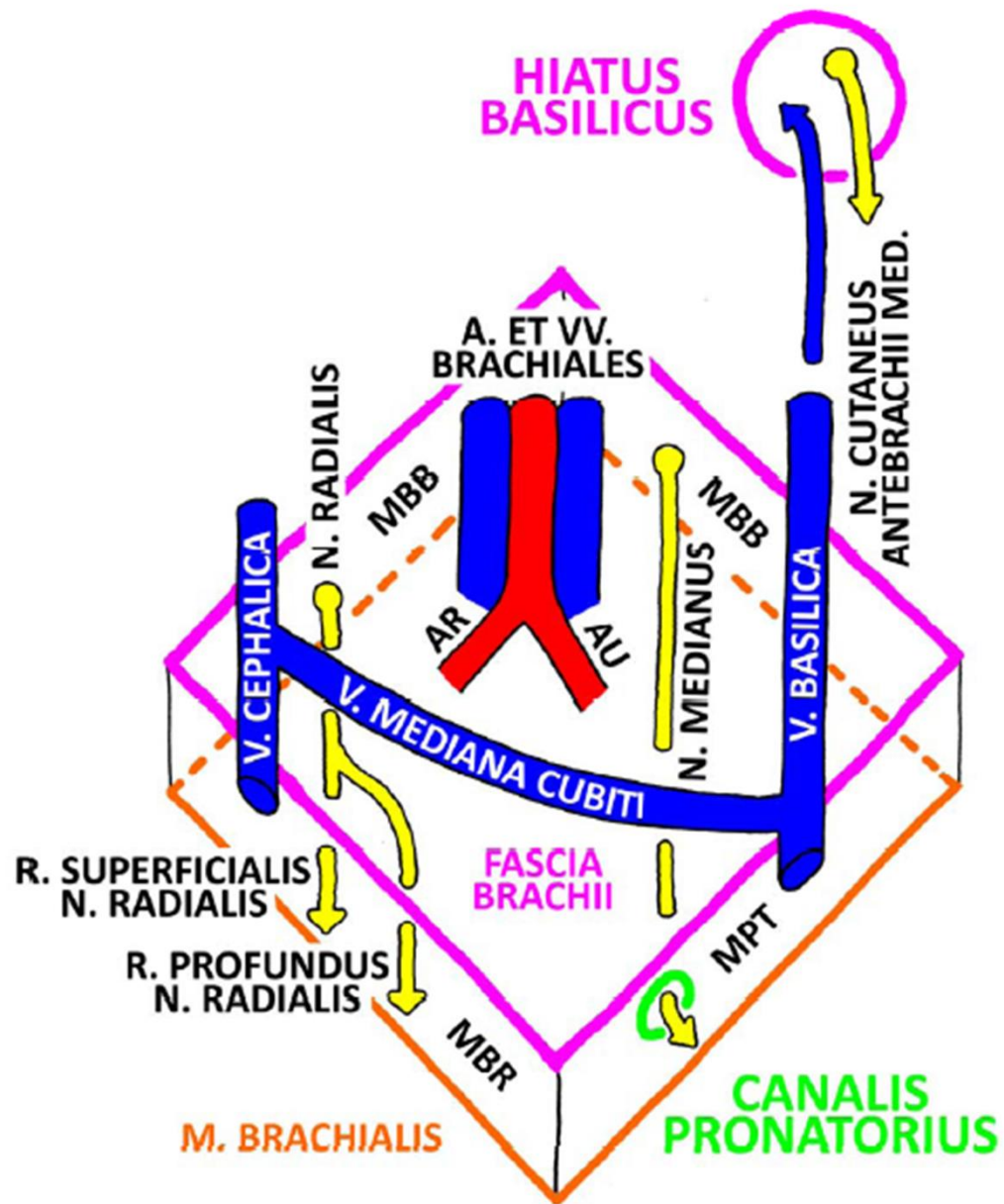
n. ulnaris
a. et v. ulnaris

n. medianus
n. radialis (r. superf.)
a. et v. radialis



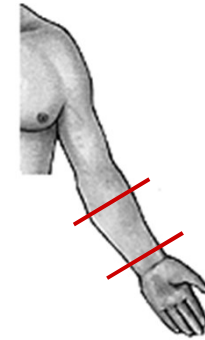


FOSSA CUBITALIS DX.

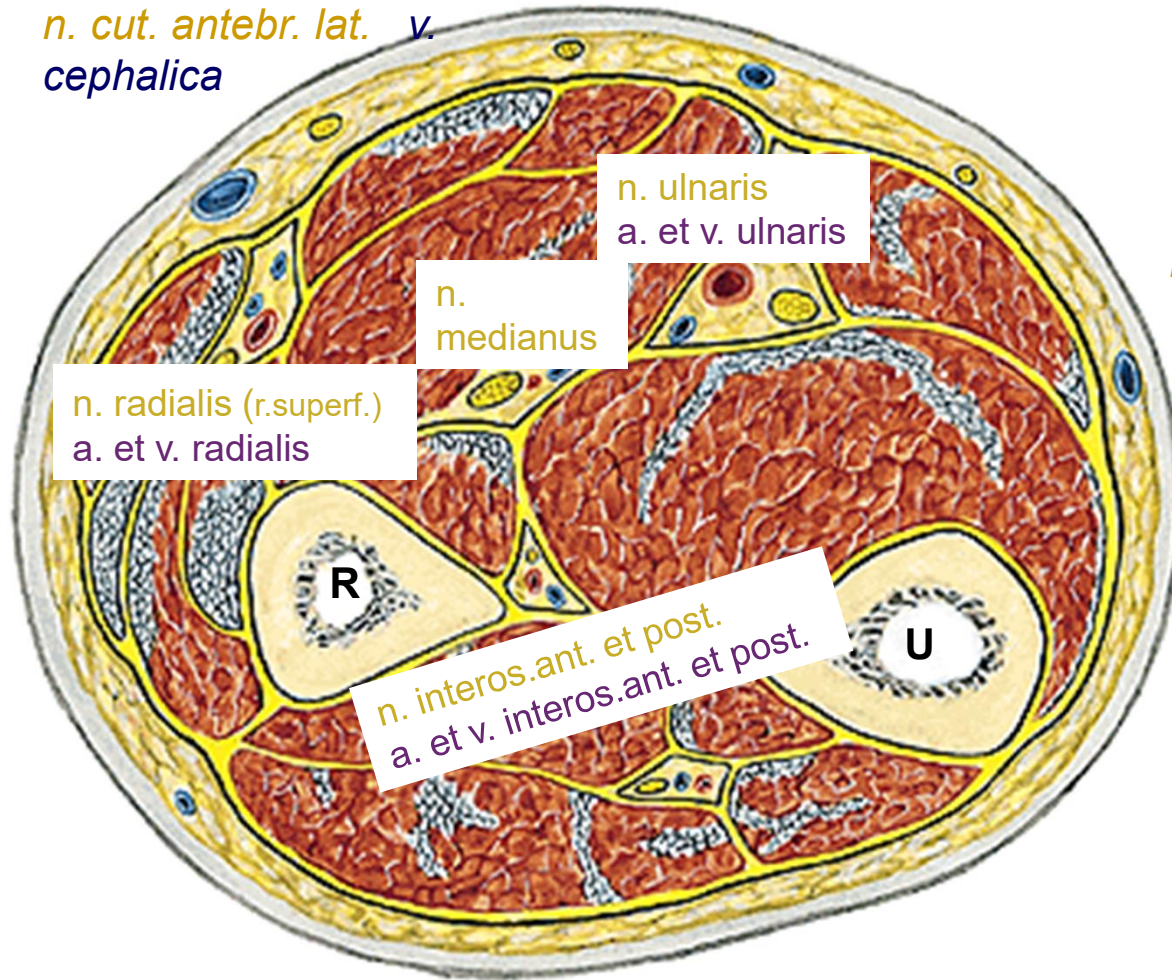


r. antebrachii

Right one, from below



n. cut. antebr. lat. v. cephalica



*n. ulnaris
a. et v. ulnaris*

*n.
medianus*

*n. radialis (r.superf.)
a. et v. radialis*

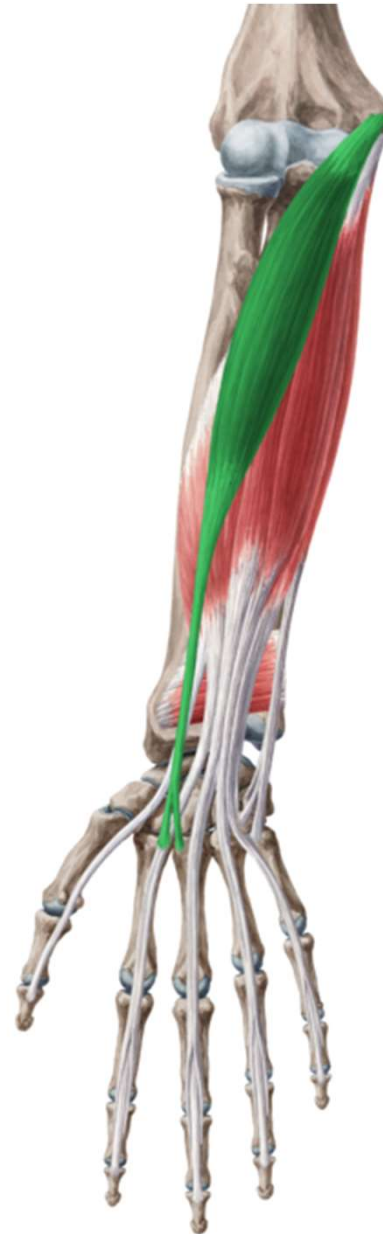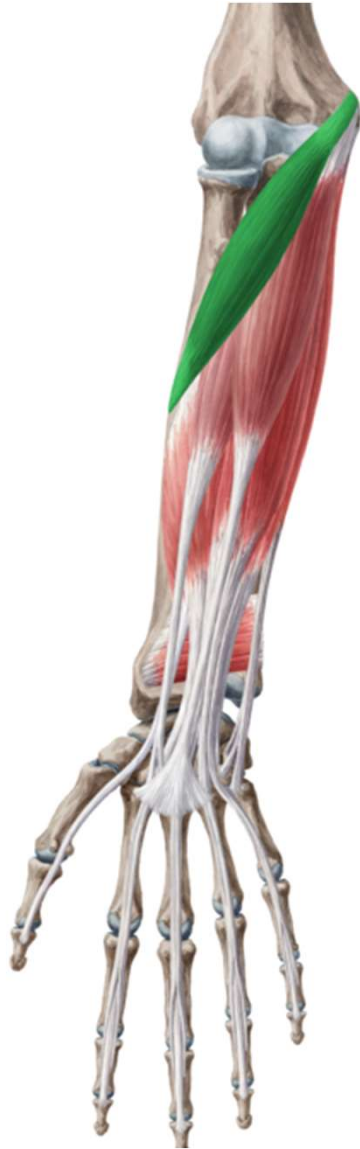*n. interos.ant. et post.
a. et v. interos.ant. et post.*

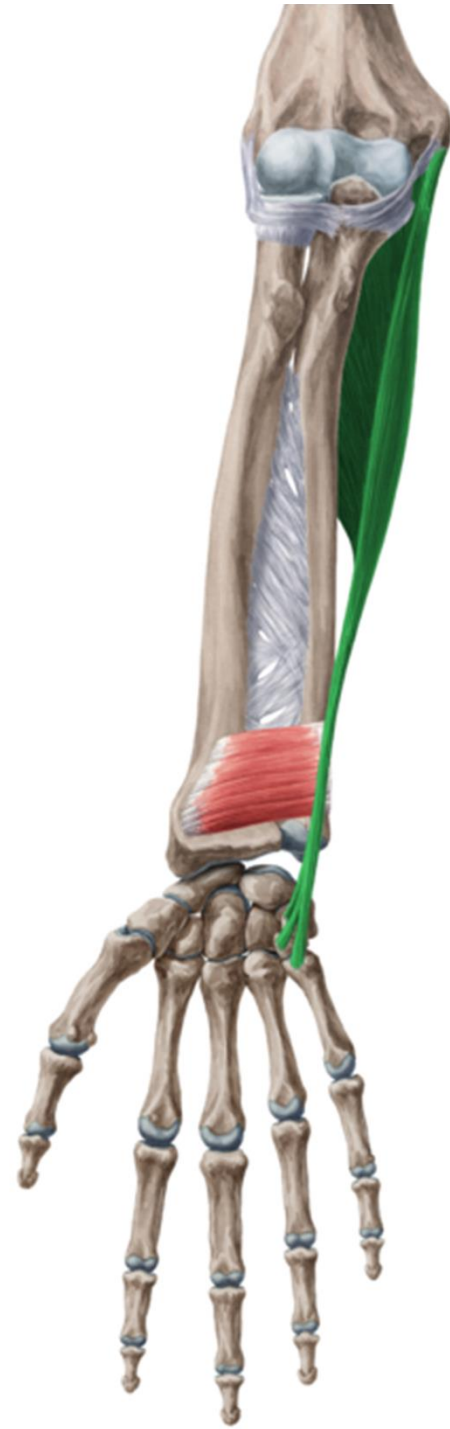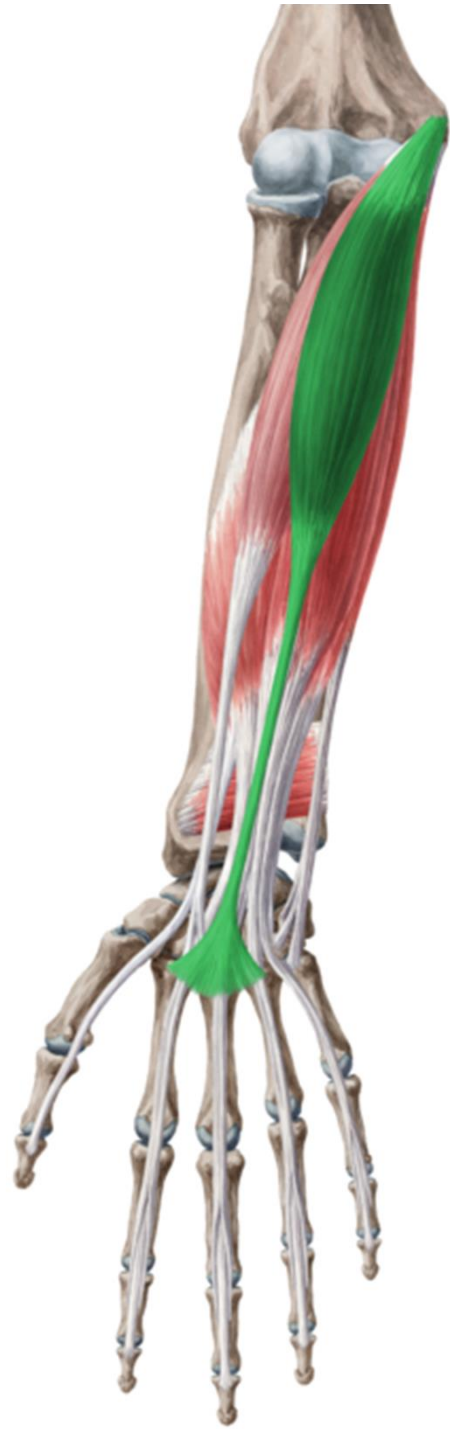*n. cut. antebr. med.
v. basilica*

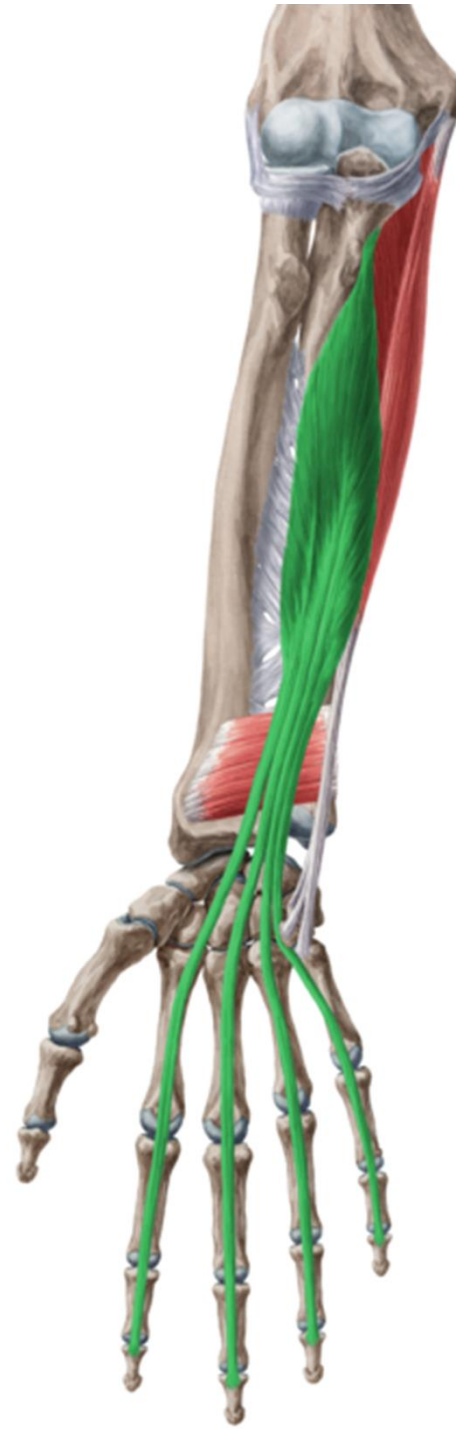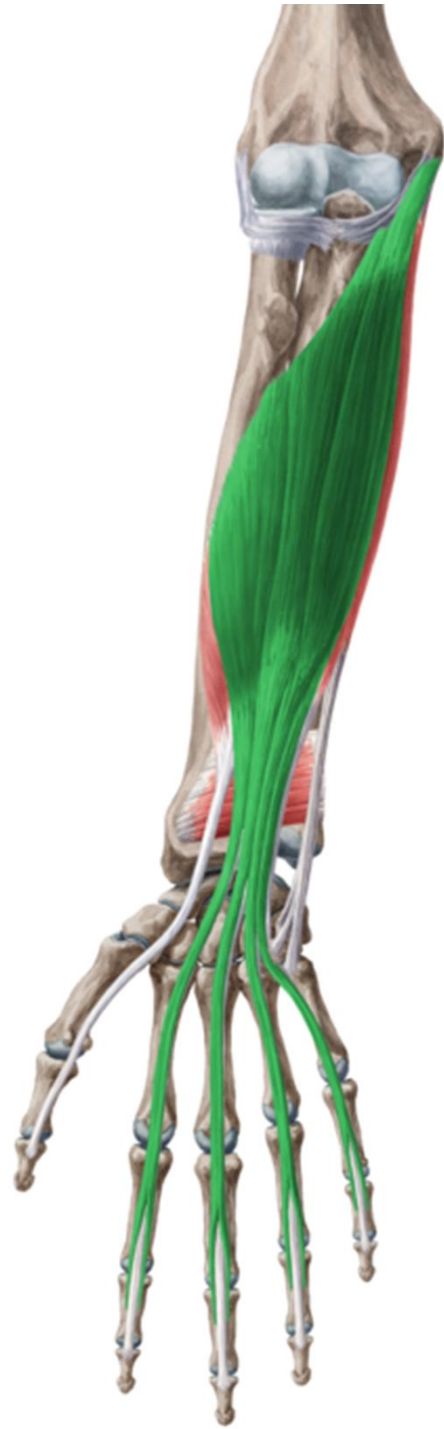n. cut. antebr. post.

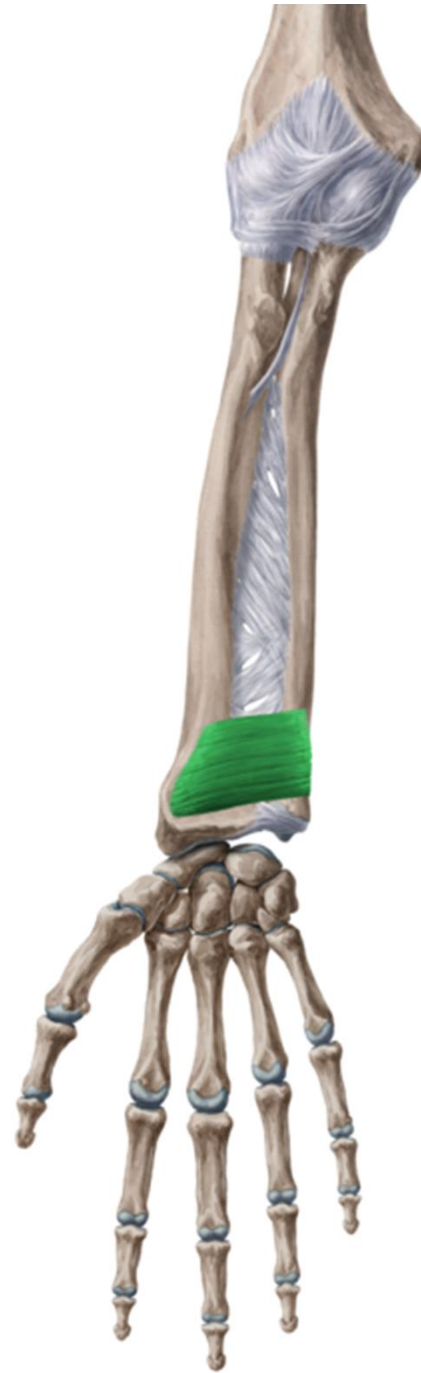
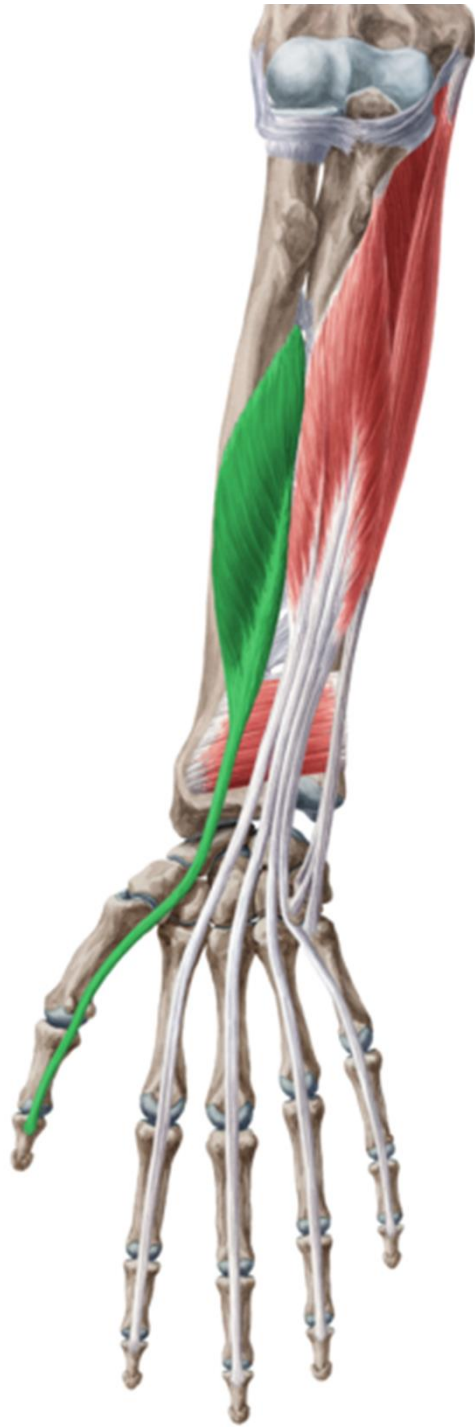
r. antebrachii ant.

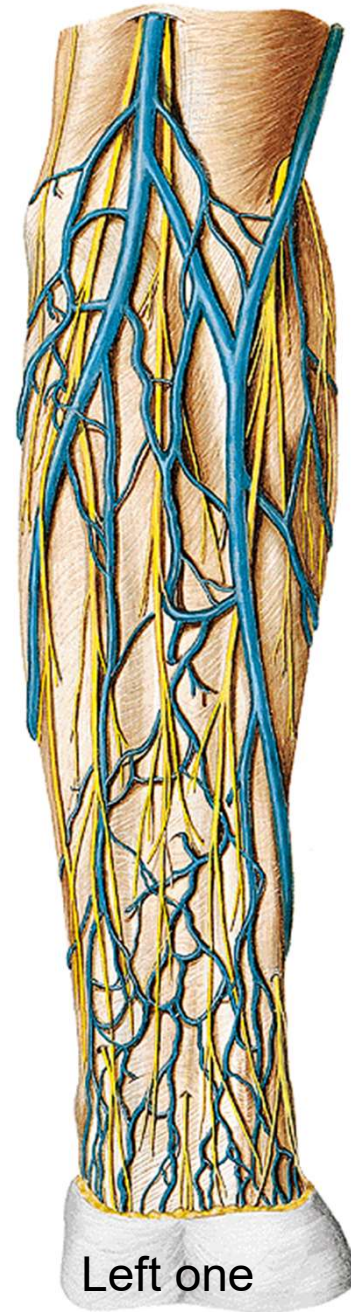








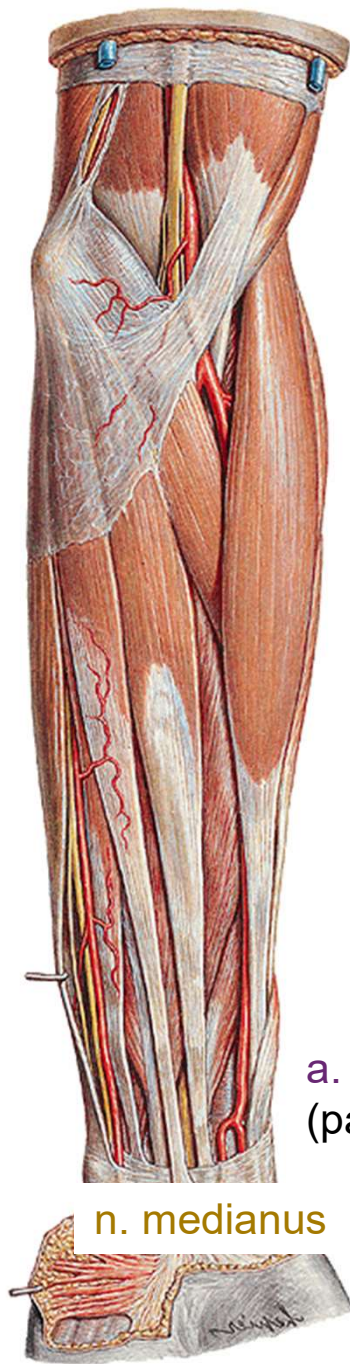n. cutaneus antebr. med.
v. basilica



n. cutaneus antebr. lat.
v. cephalica

Left one

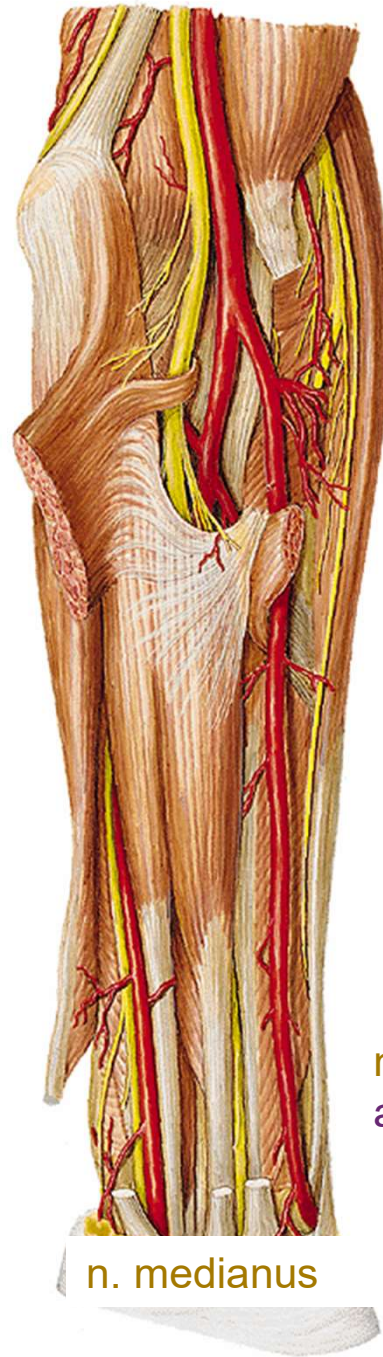



a. et v. radialis
(palpable puls)

n. medianus



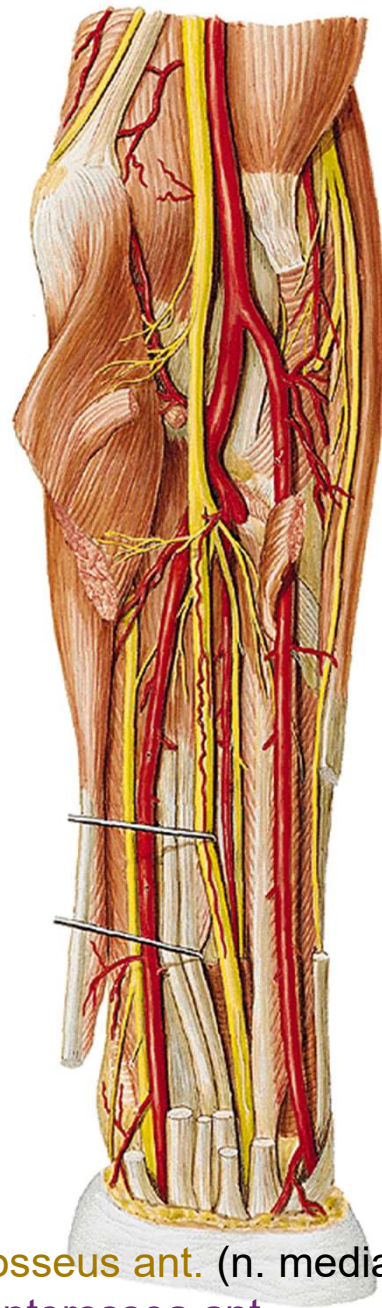


n. ulnaris
a. et v. ulnaris

n. radialis (r. superf.)
a. et v. radialis

n. medianus

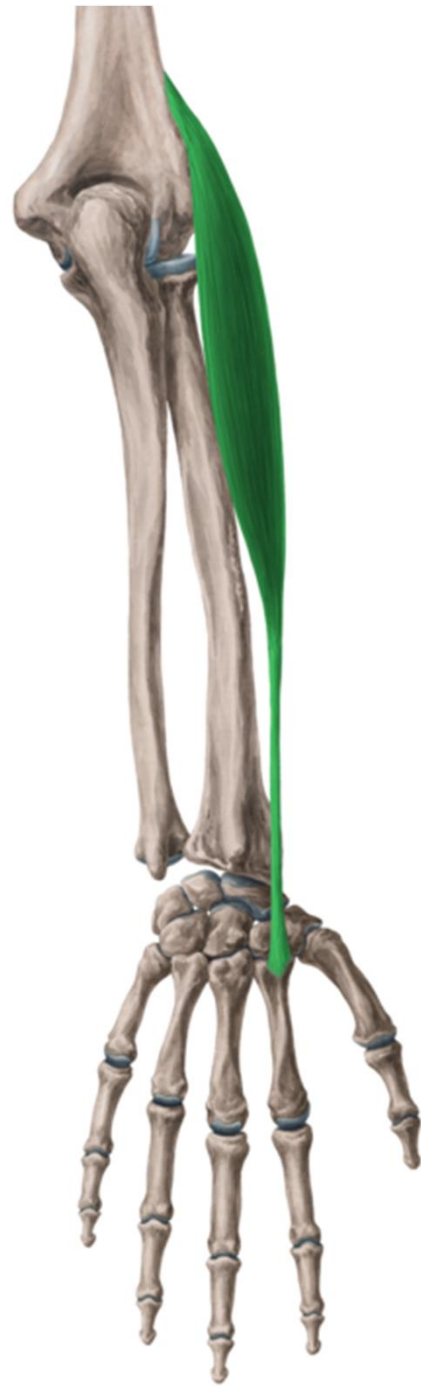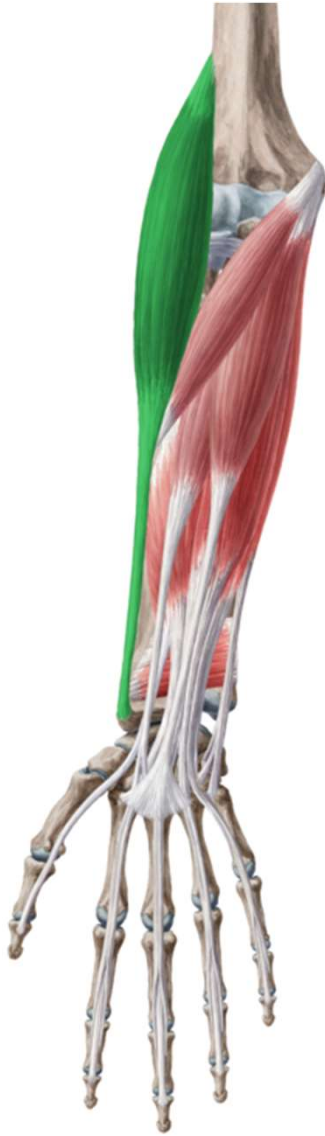



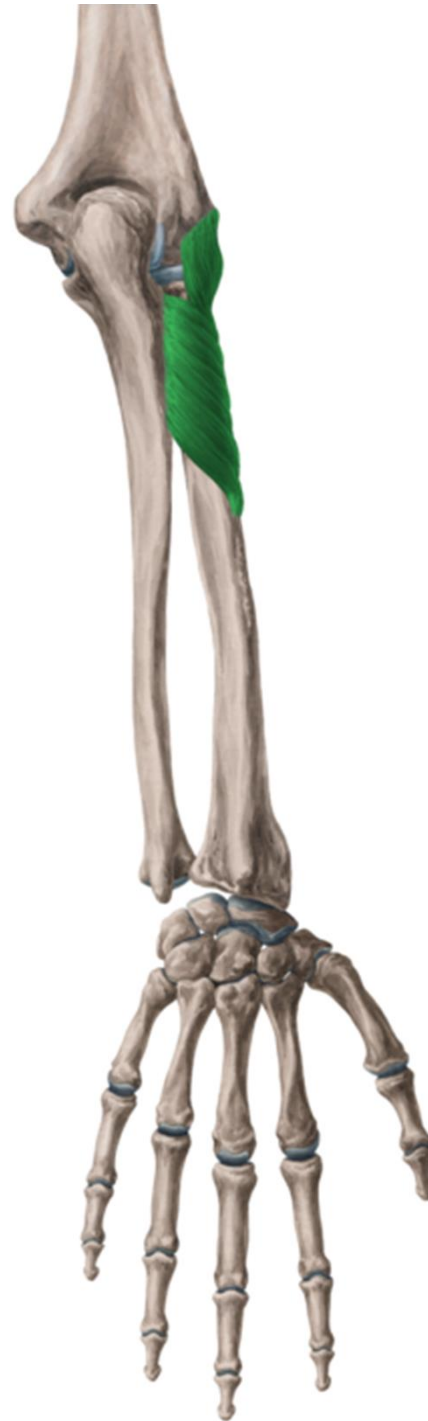
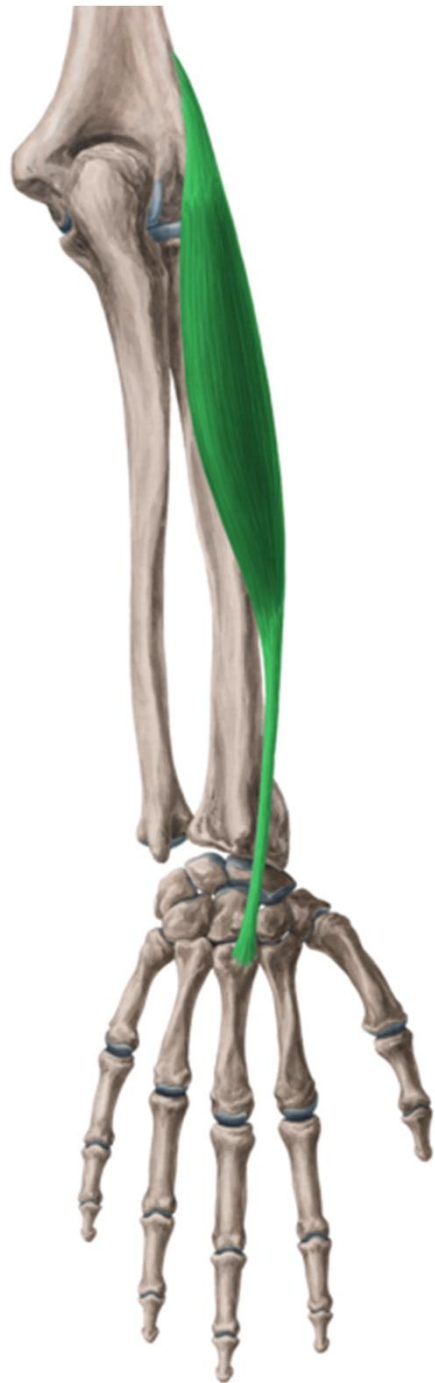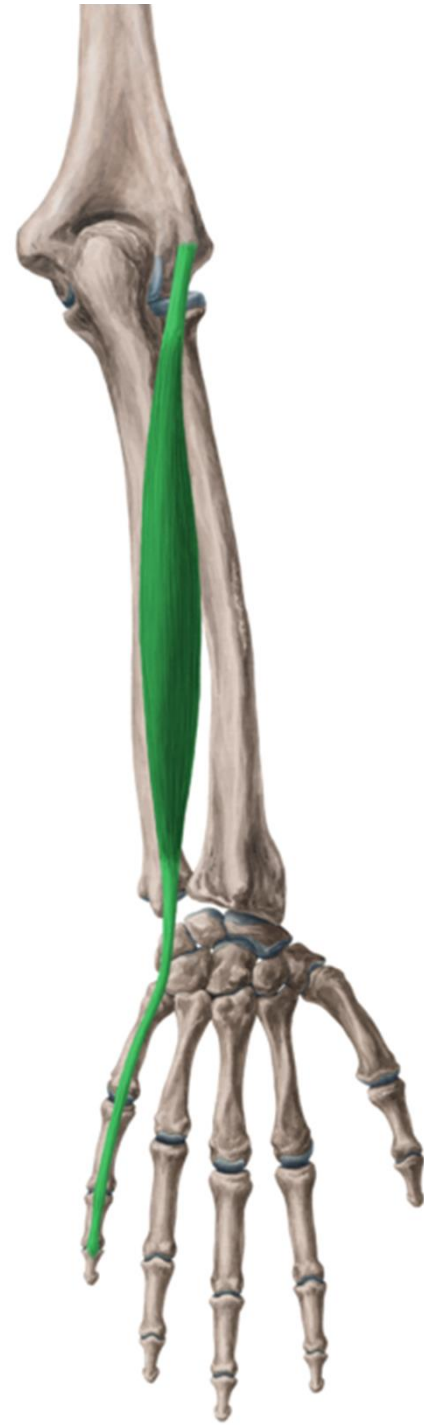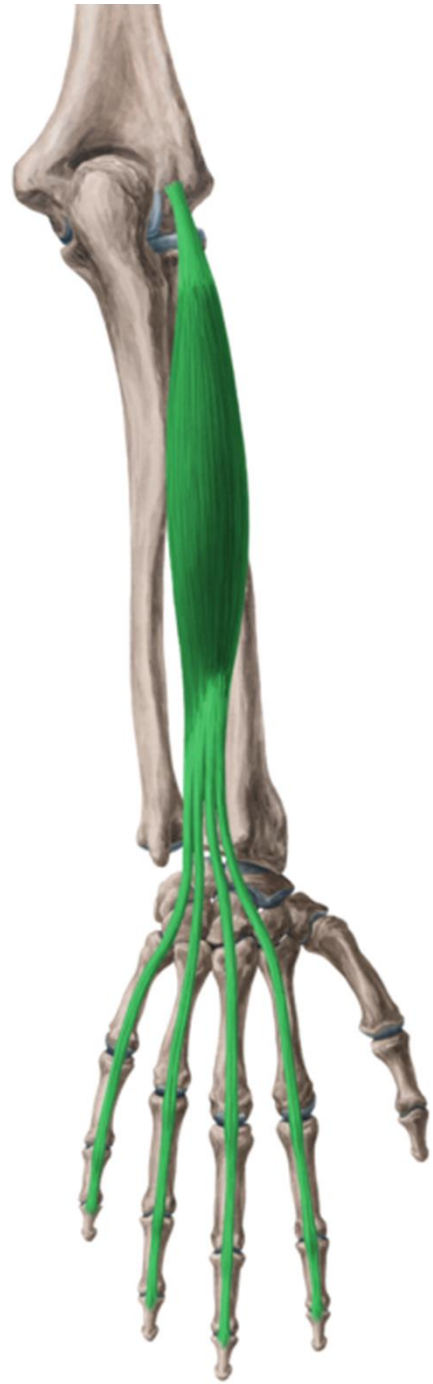n. interosseus ant. (n. medianus)
a. et v. interossea ant.

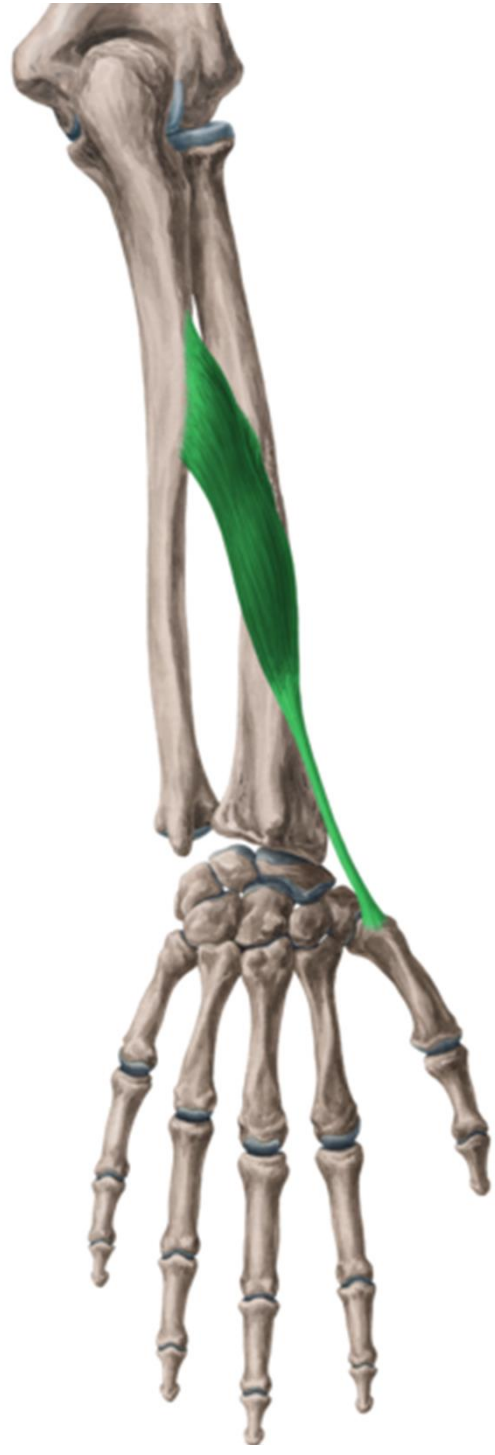
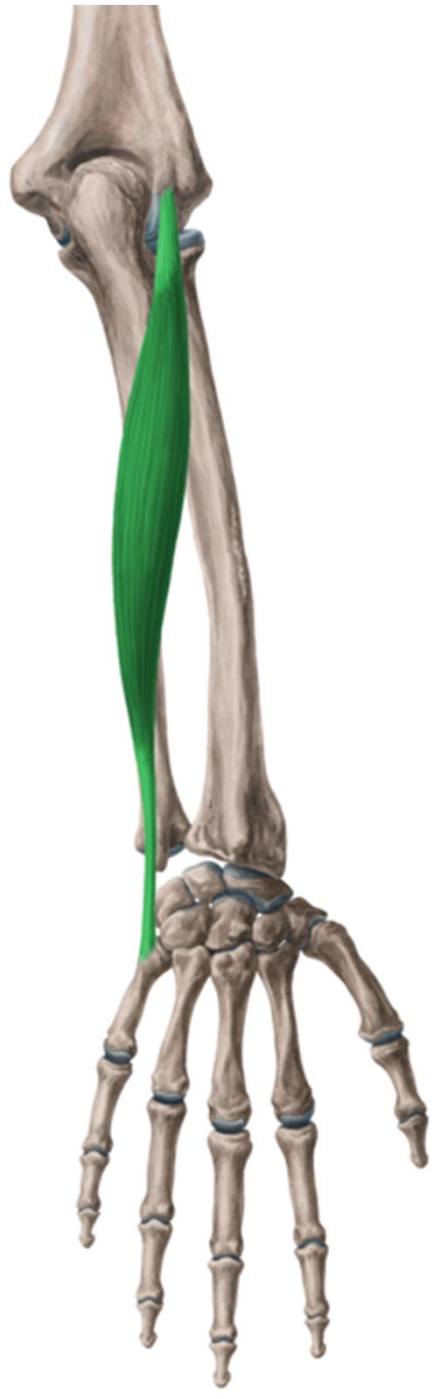

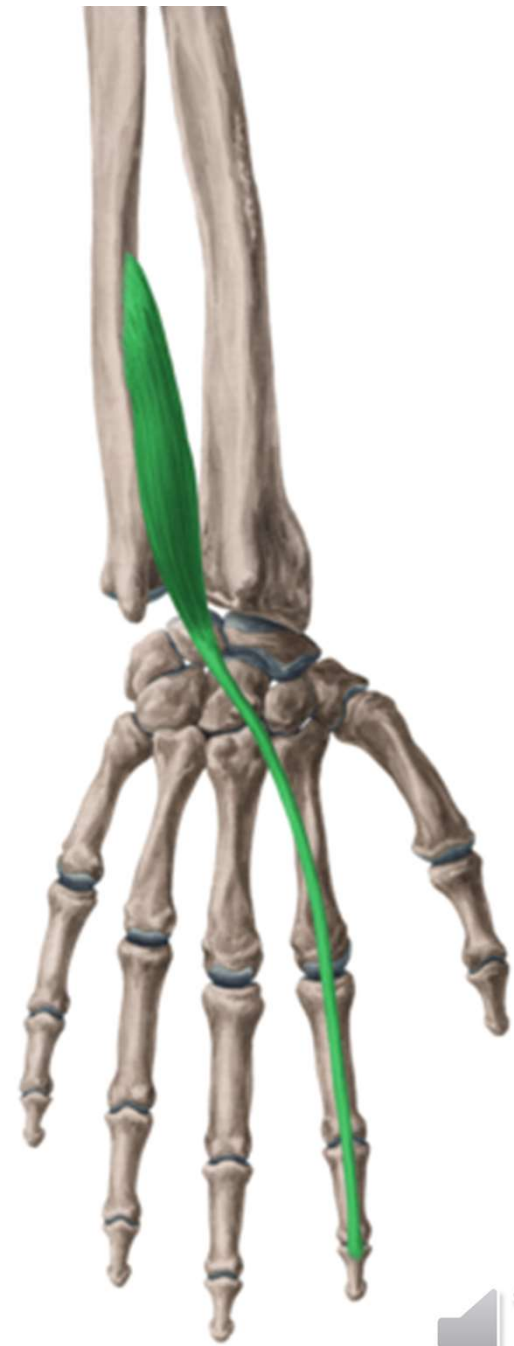
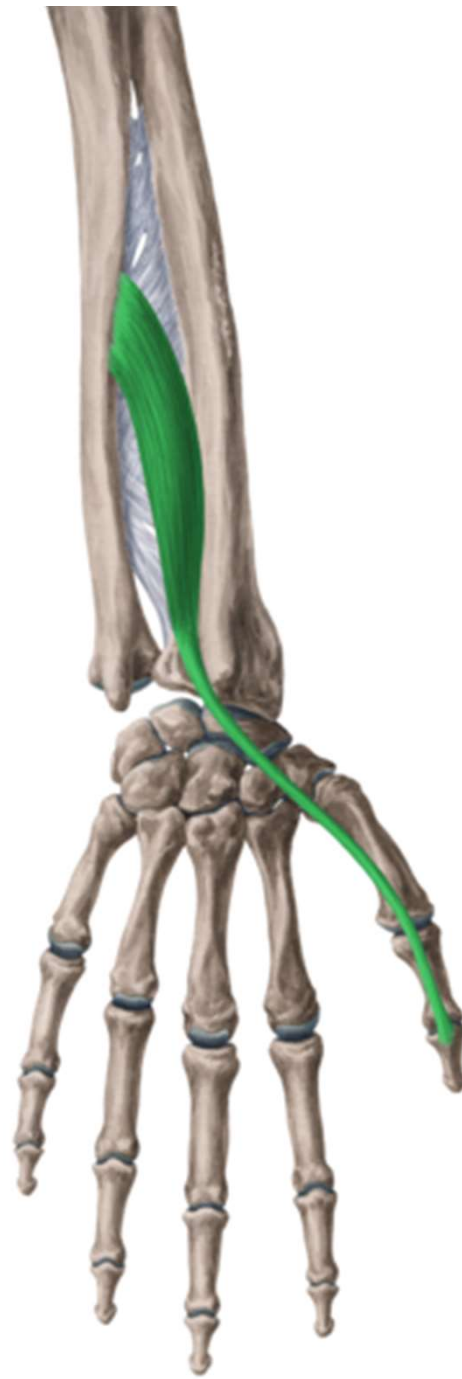
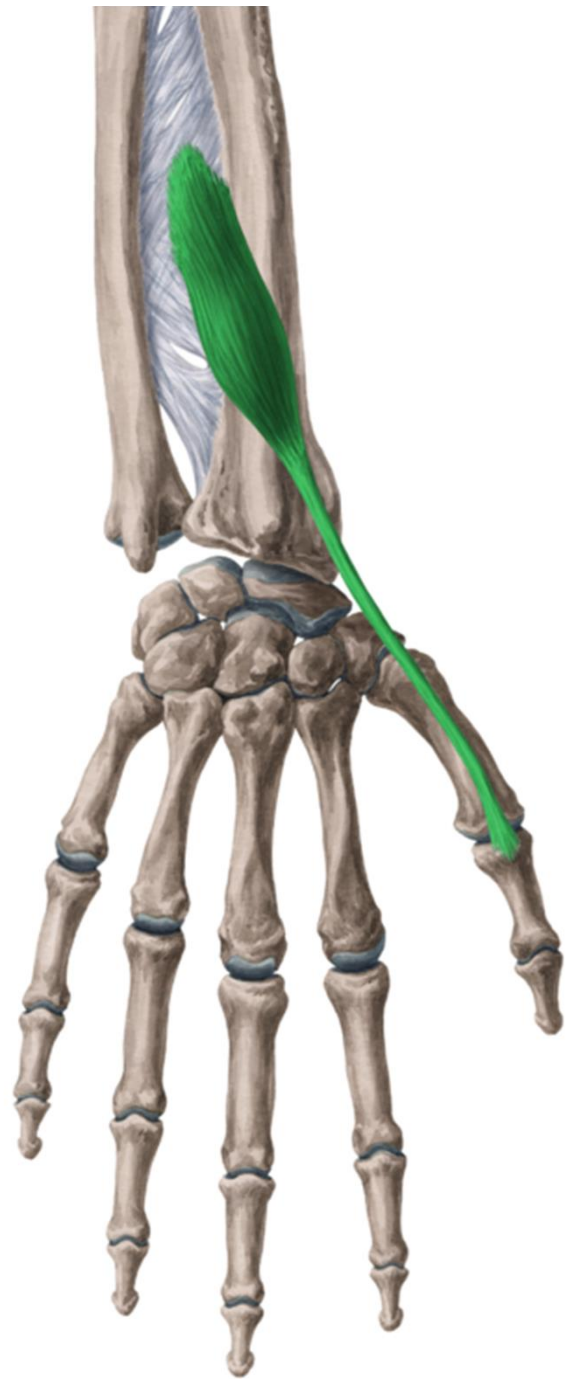
r. antebrachii post.



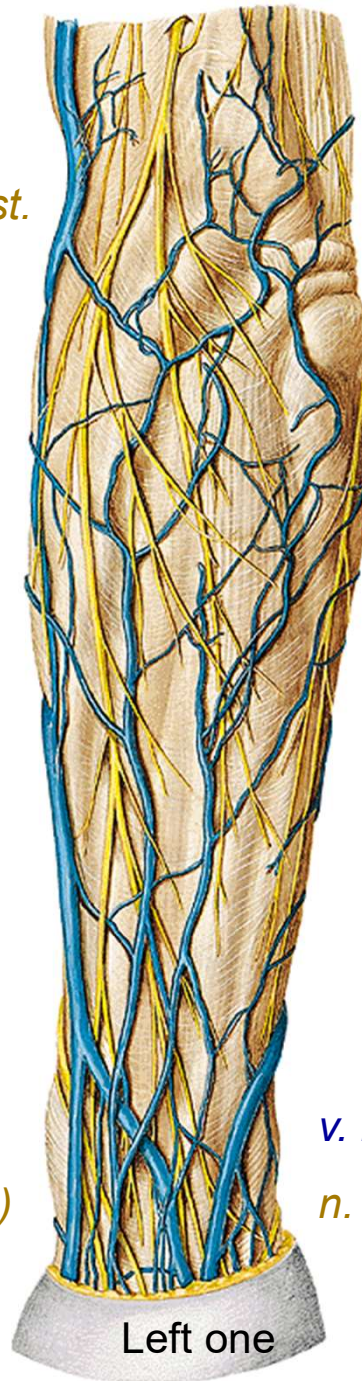







n. cutaneus antebrachii post.



v. cephalica

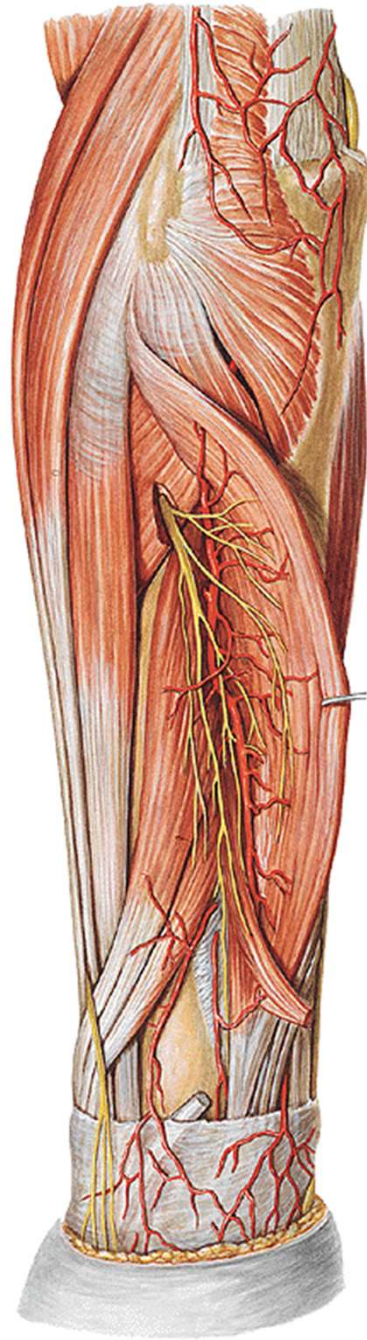
n. radialis (r. superf.)

v. basilica

n. ulnaris (r. dorsalis)

Left one



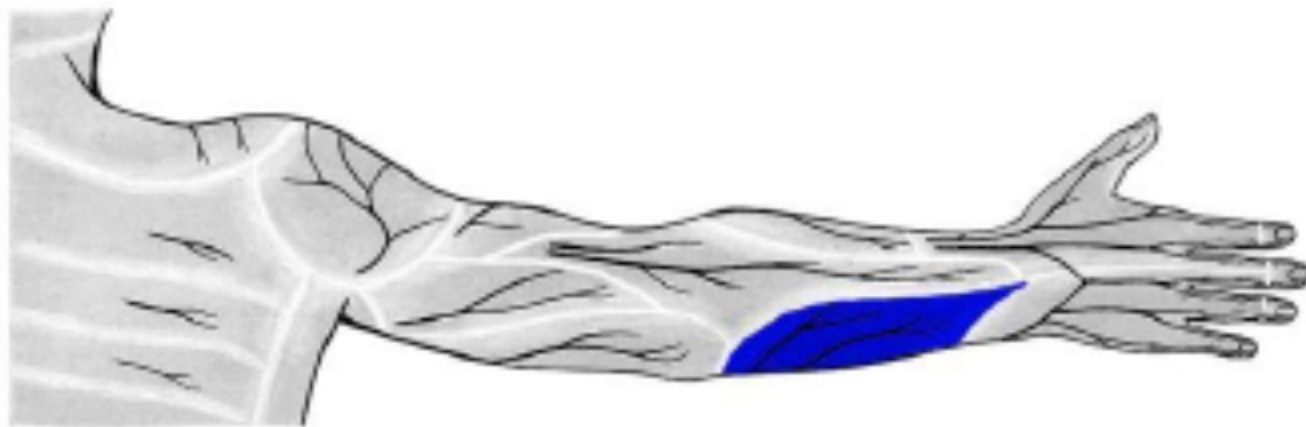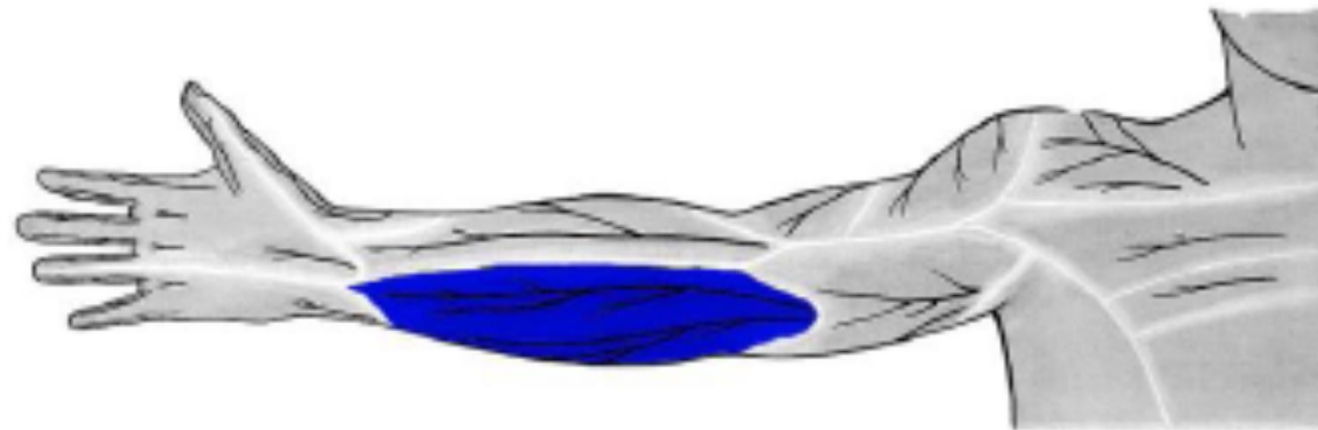


n. radialis

(r. prof., n. interosseus post.)

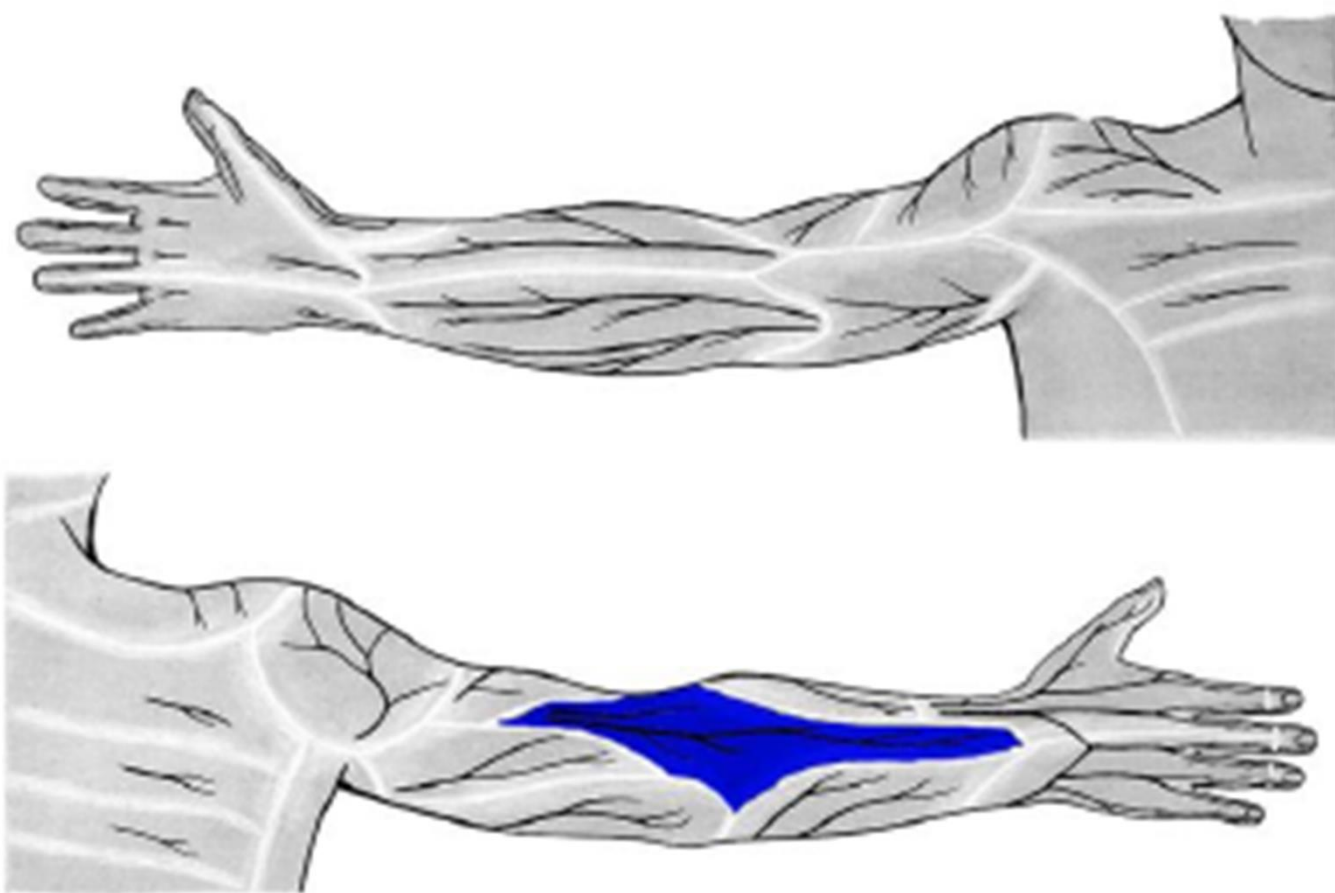
a. et v. interossea post.





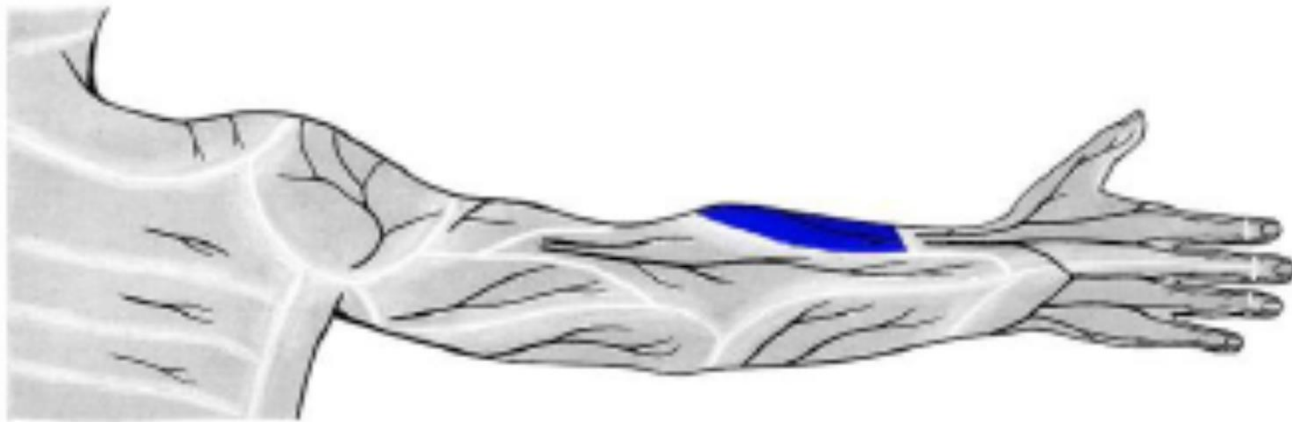
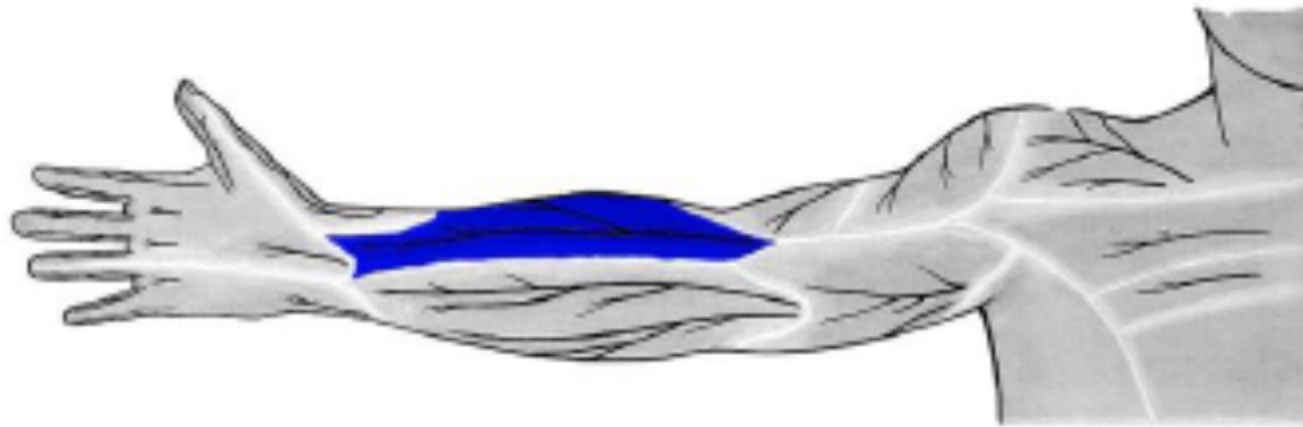
n. cutaneus antebrachii med.
(z *fasciculus medialis*)





n. cutaneus antebrachii post.
(z. *n. radialis*)

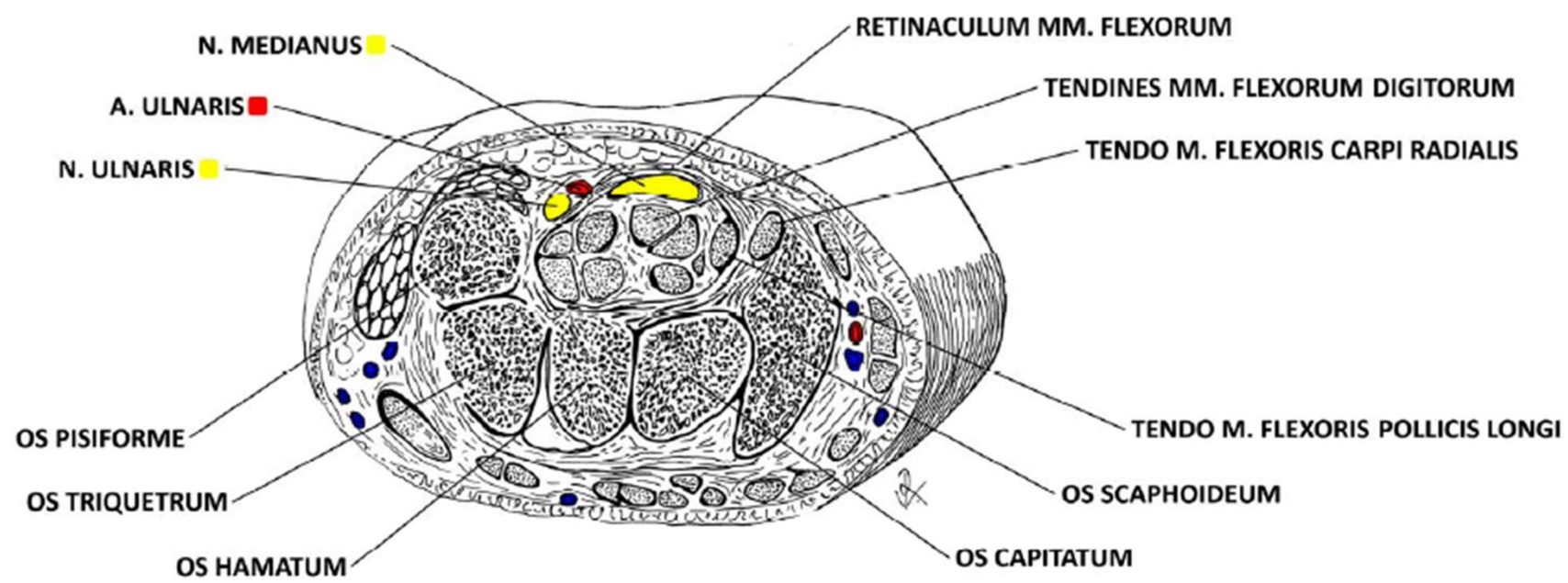




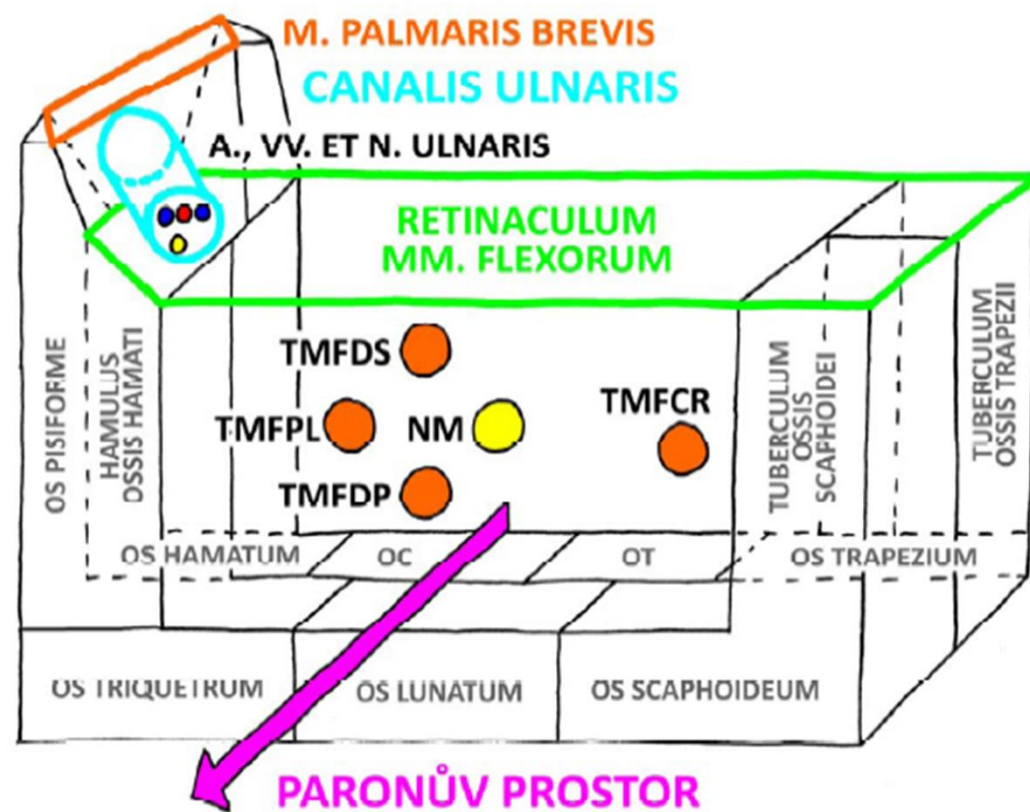
n. cutaneus antebrachii lat.
(z *n. musculocutaneus*)



r. carpi palm.



CANALIS CARPI DX.

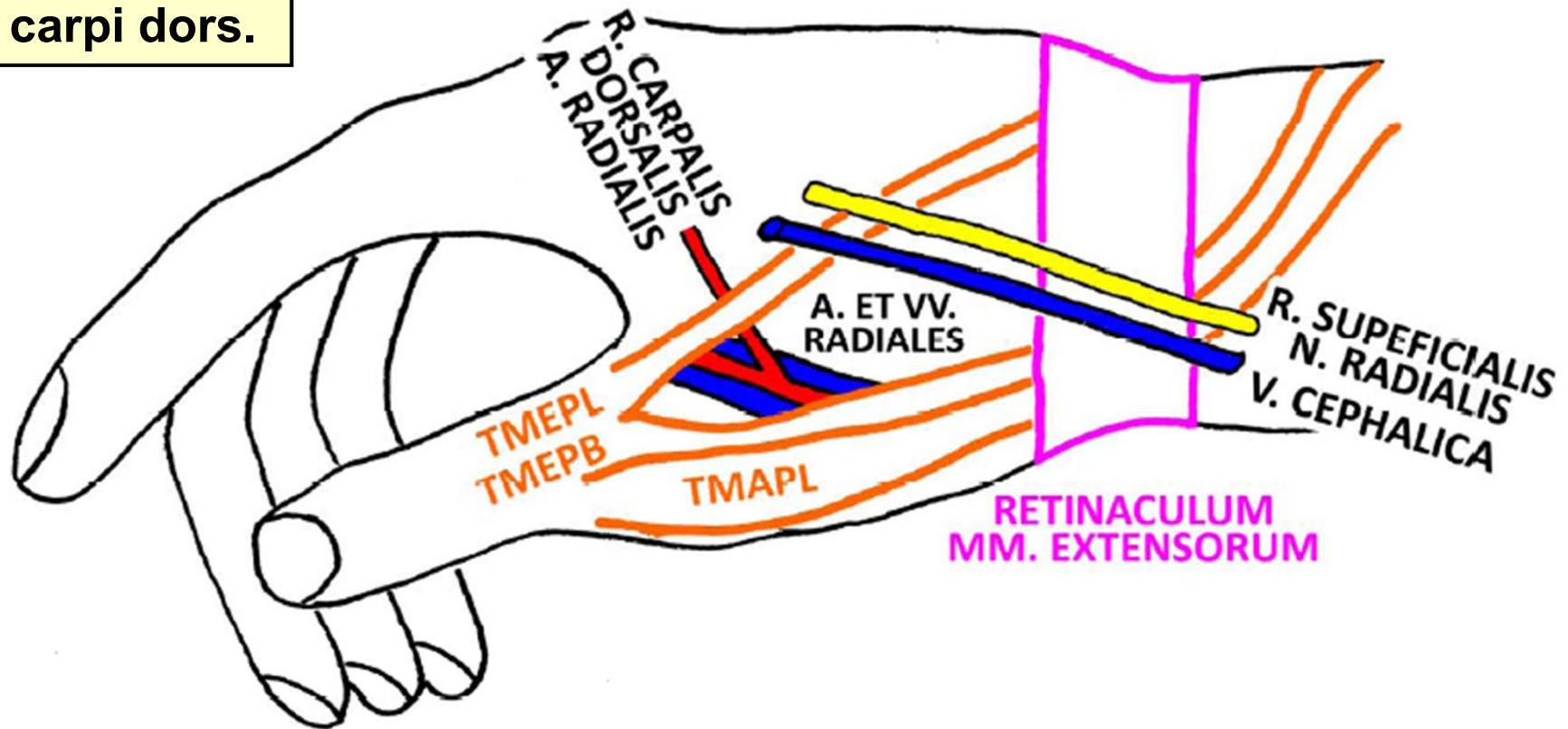


TMFDS = TENDO M. FLEXORIS DIGITORUM SUPERFICIALIS
TMFPL = TENDO M. FLEXORIS POLLICIS LONGI
NM = N. MEDIANUS
TMFDP = TENDO M. FLEXORIS DIGITORUM PROFUNDI
TMFCR = TENDO M. FLEXORIS CARPI RADIALIS
OC = OS CAPITATUM
OT = OS TRAPEZOIDEUM



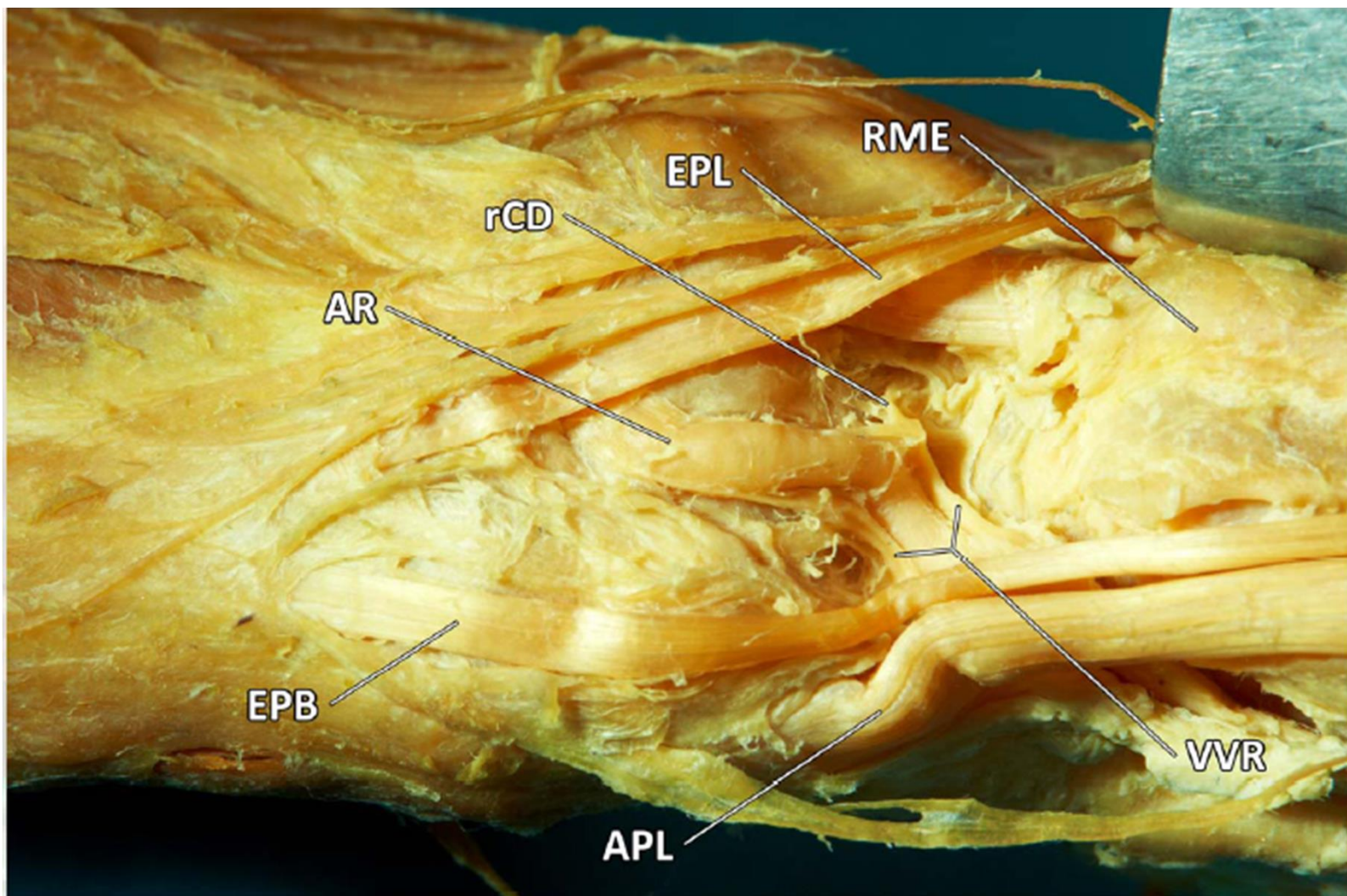
FOVEOLA RADIALIS DX.

r. carpi dors.



TMEPL = TENDO M. EXTENSORIS POLLICIS LONGI
TMEPB = TENDO M. EXTENSORIS POLLICIS BREVIS
TMAPL = TENDO M. ABDUCTORIS POLLICIS LONGI

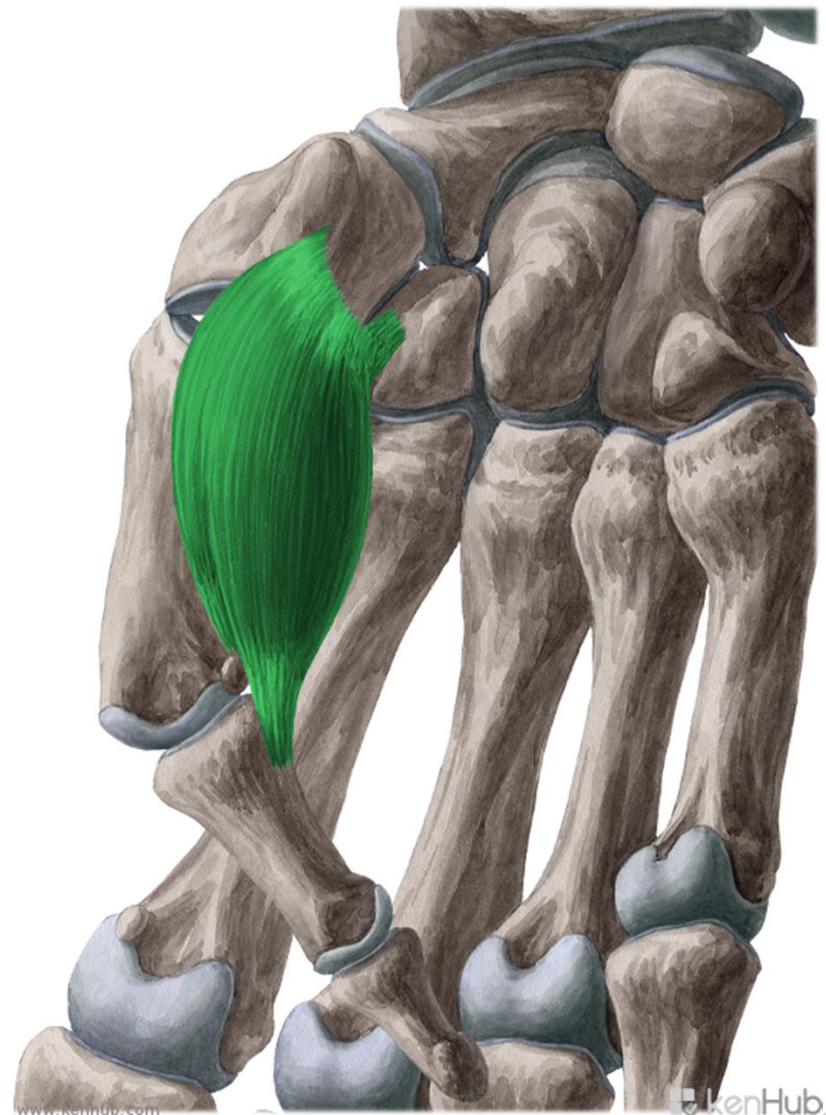
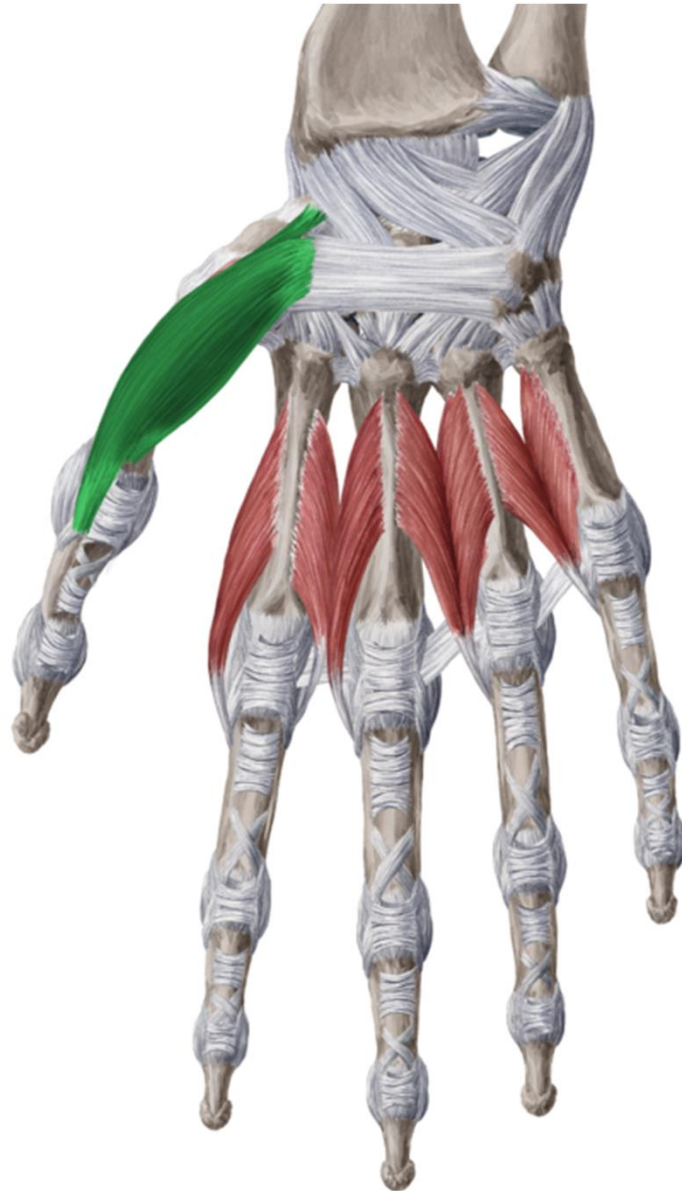


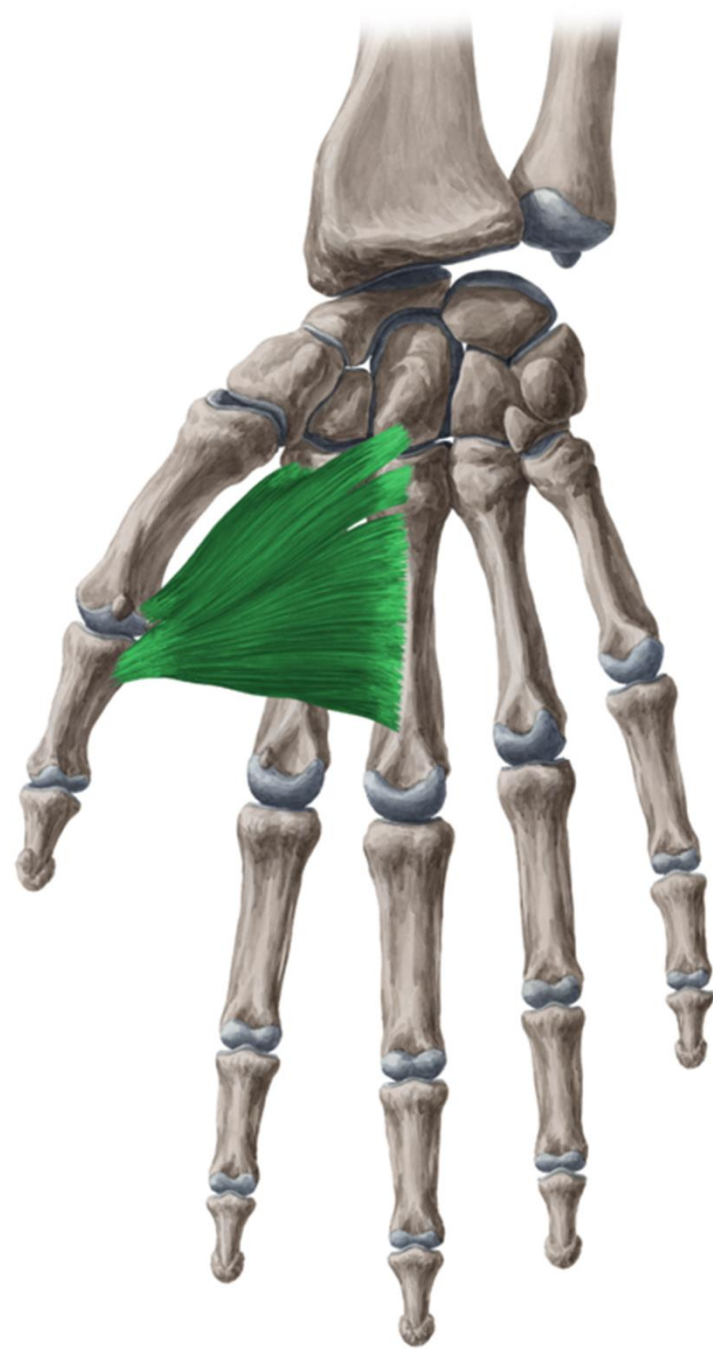
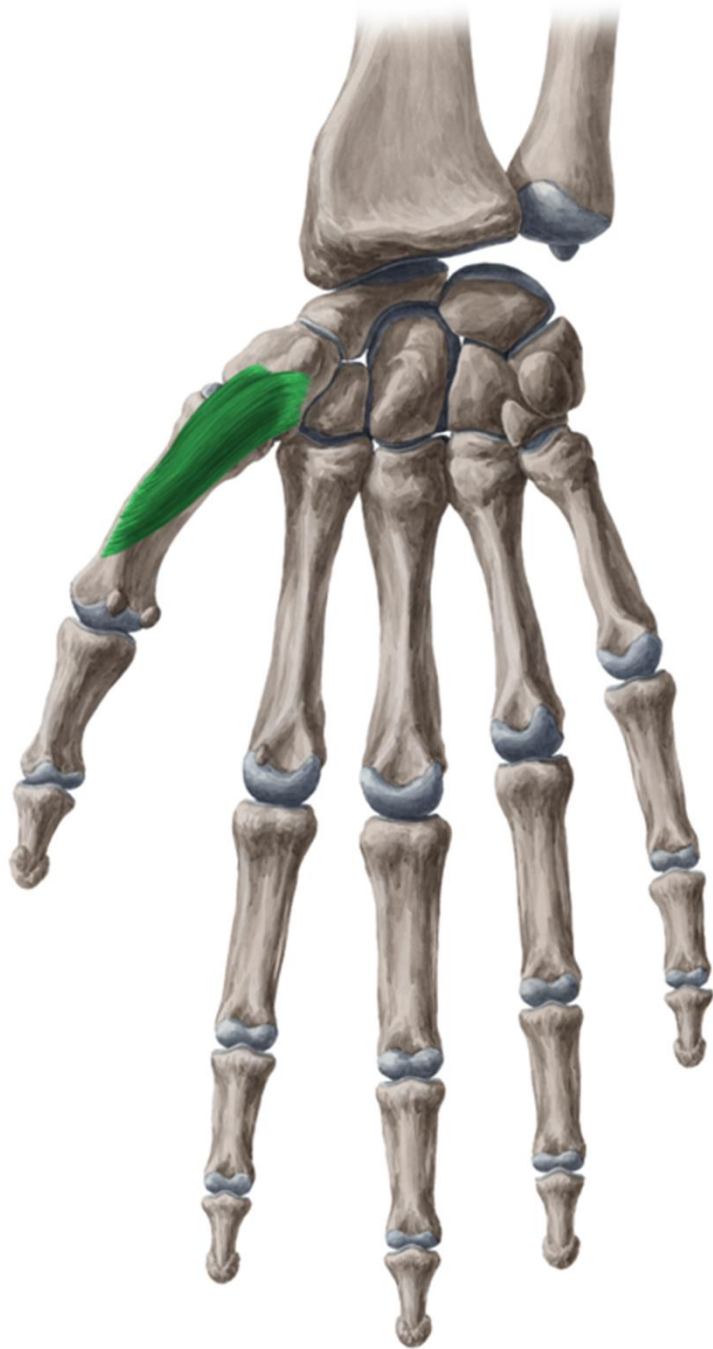


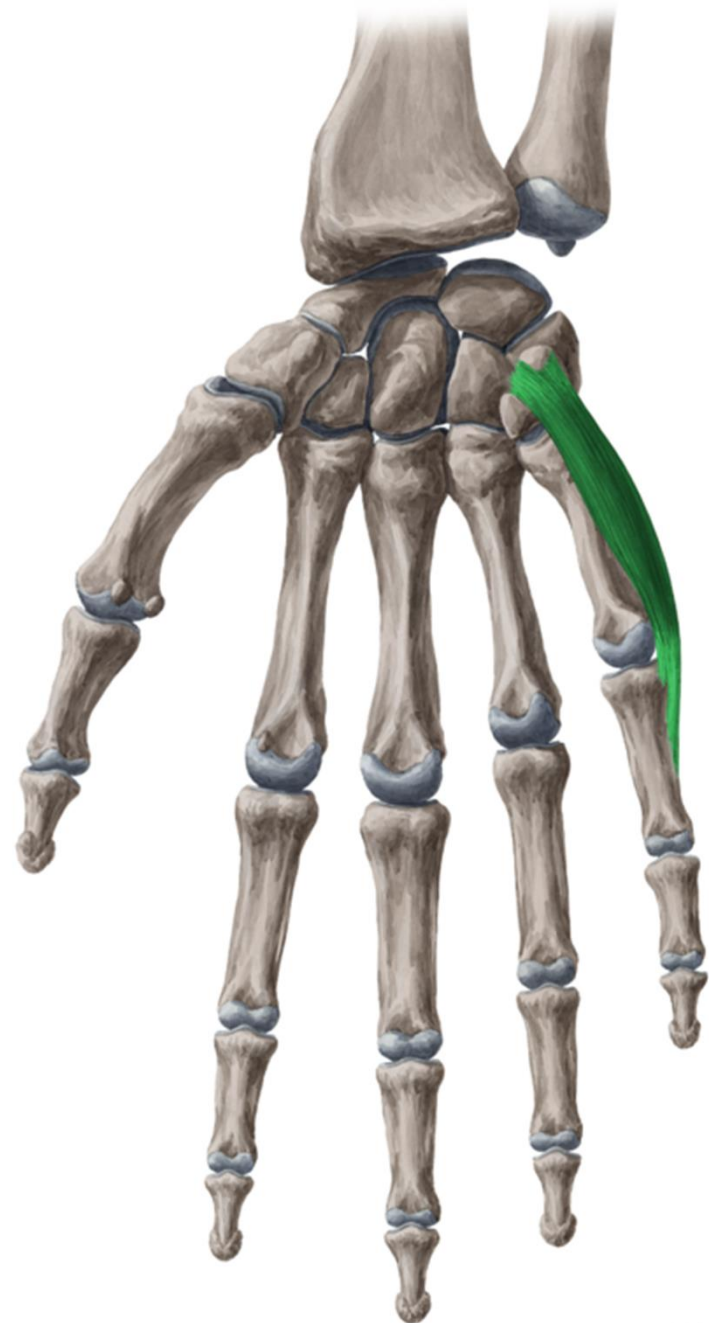
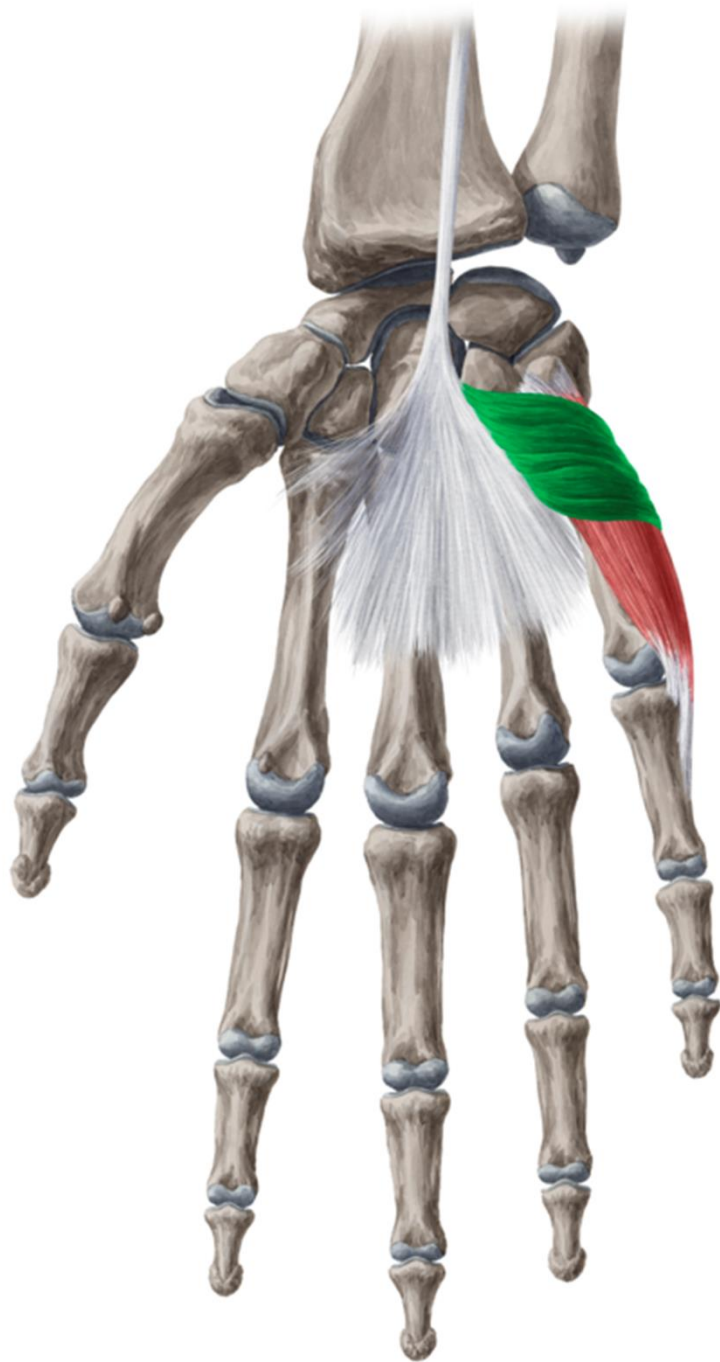
AR - A. RADIALIS
rCD - R. CARPALIS DORSALIS A. RADIALIS
EPL - TENDO M. EXTENSORIS POLLICIS LONGI
RME - RETINACULUM MM. EXTENSORUM
VVR - VV. RADIALES
APL - TENDO M. ABDUCTORIS POLLICIS LONGI
EPB - TENDO M. EXTENSORIS POLLICIS BREVIS

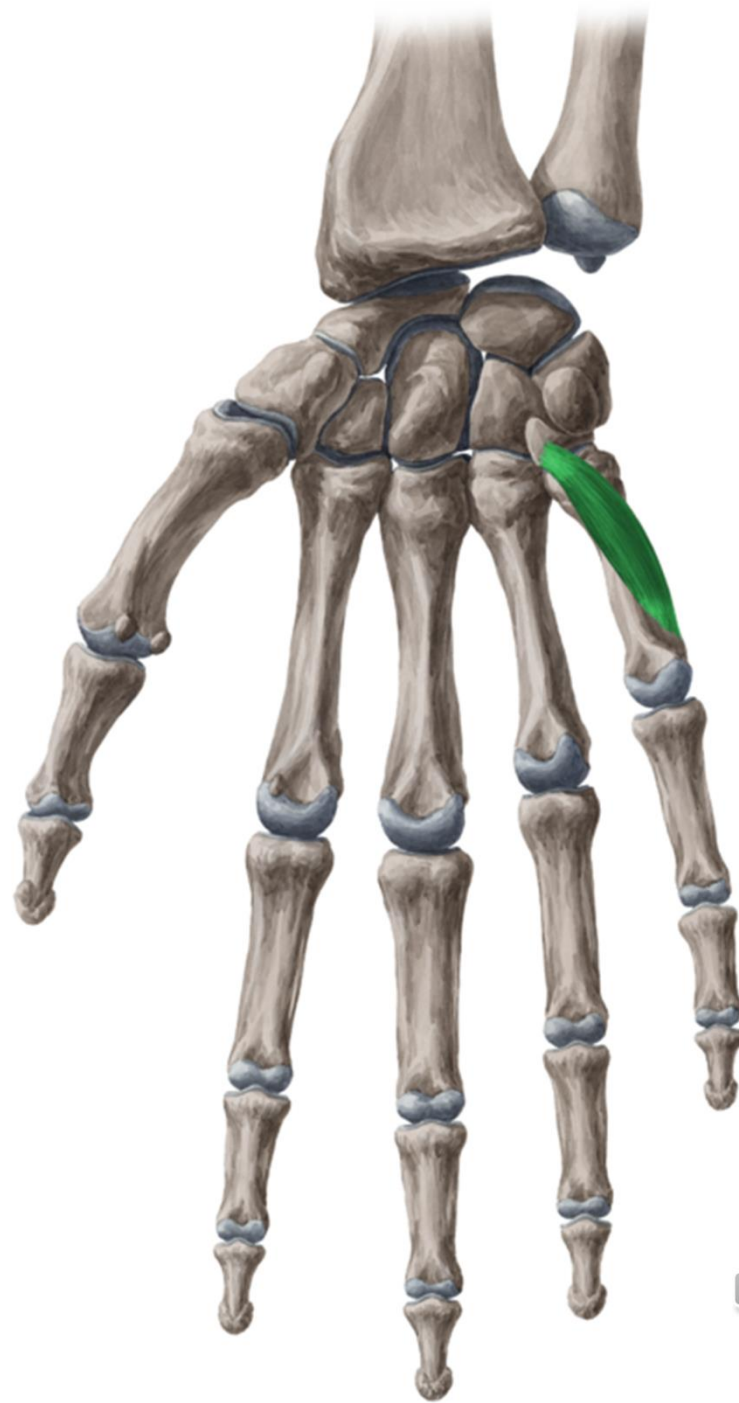
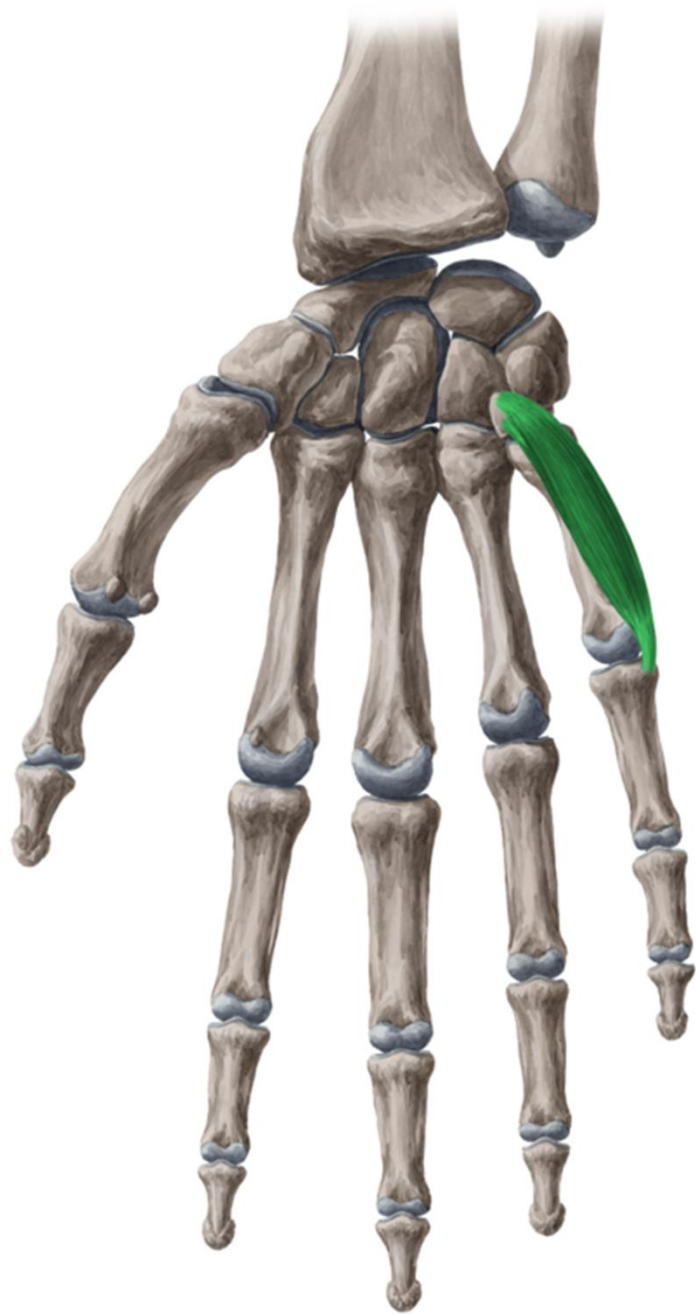


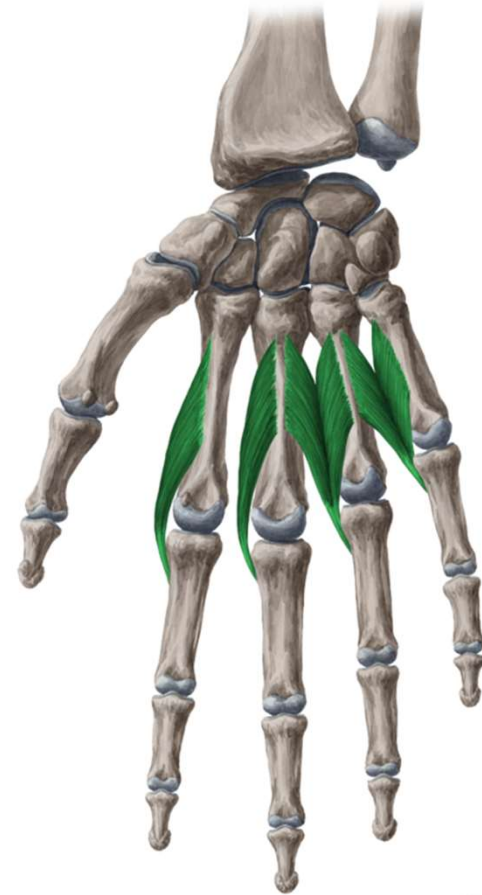
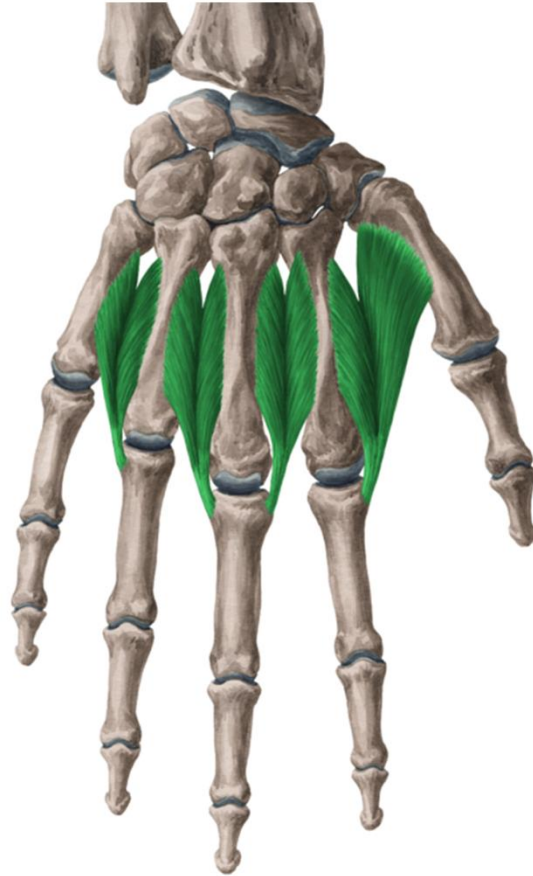
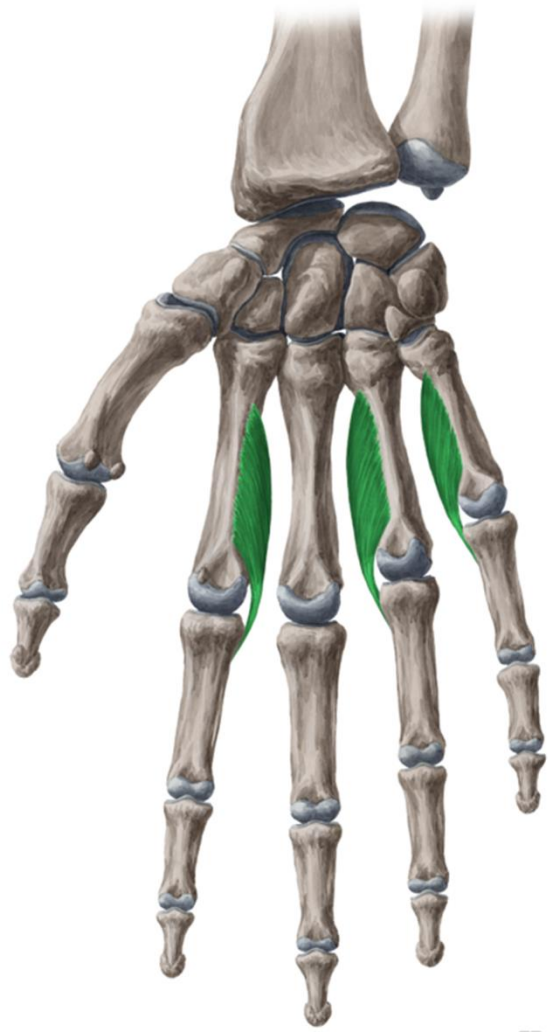
palma manus









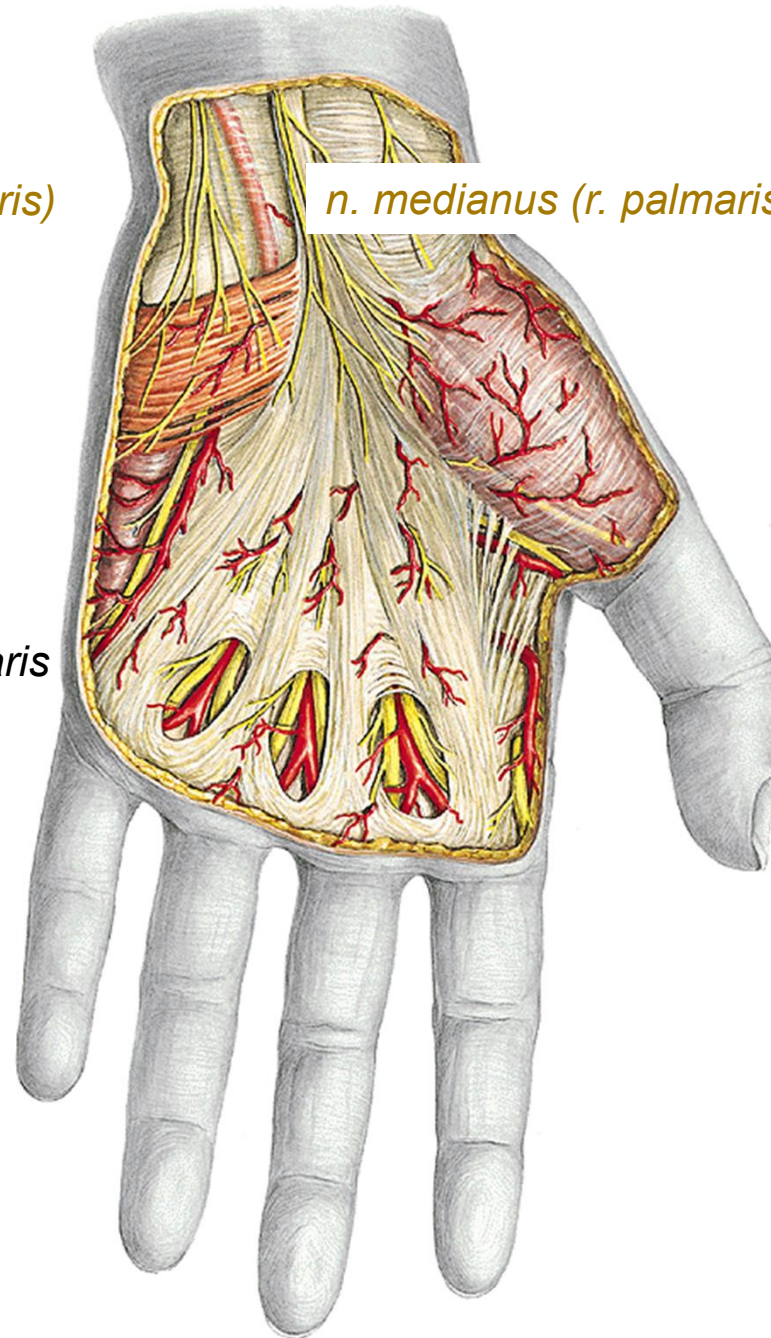
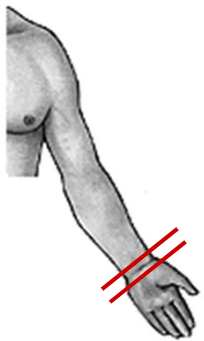


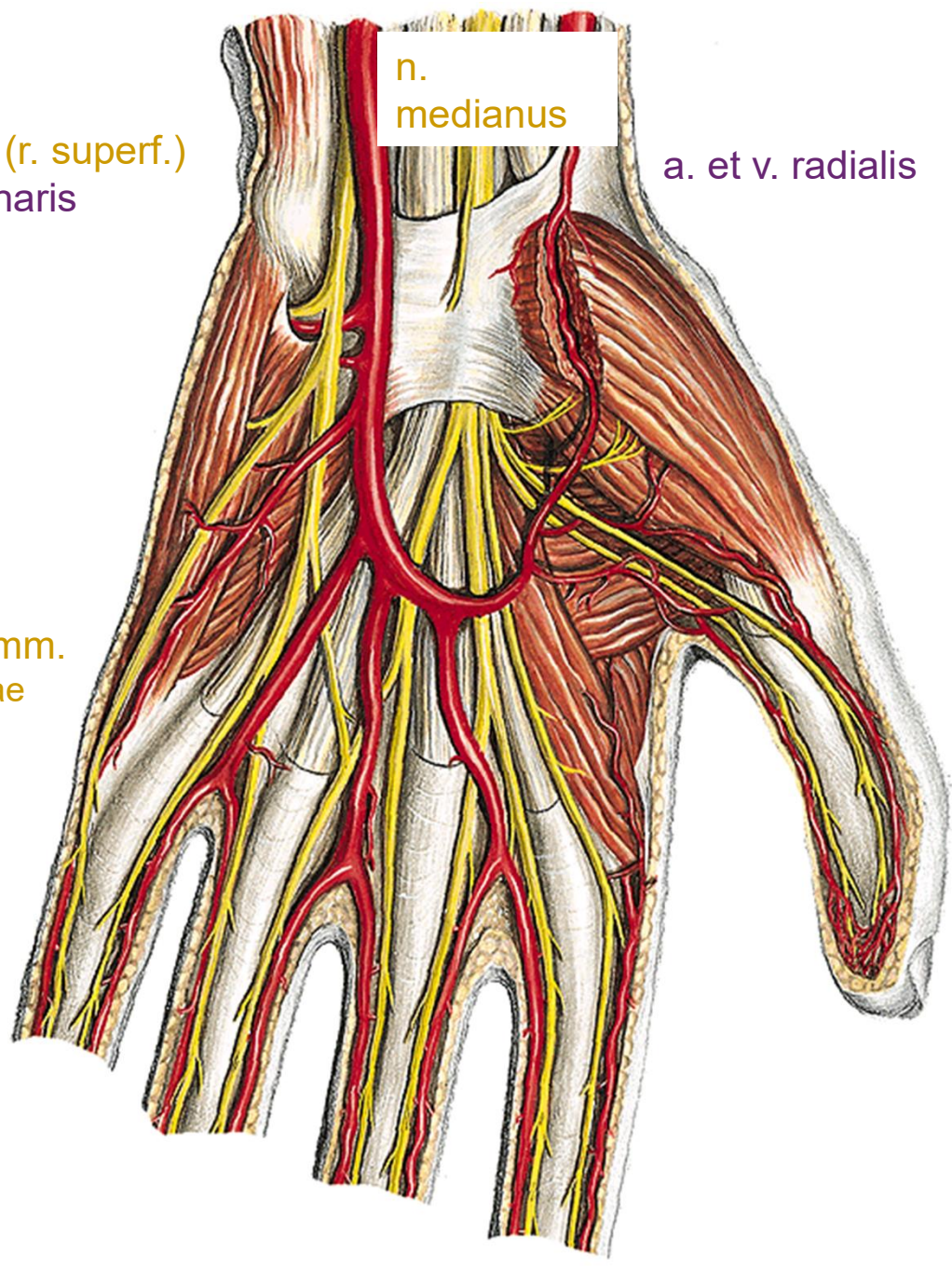
n. ulnaris (r. palmaris)

n. medianus (r. palmaris)

superficial veins

aponeurosis palmaris





n. ulnaris (r. superf.)
a. et v. ulnaris

n.
medianus

a. et v. radialis

arcus palmaris superf.

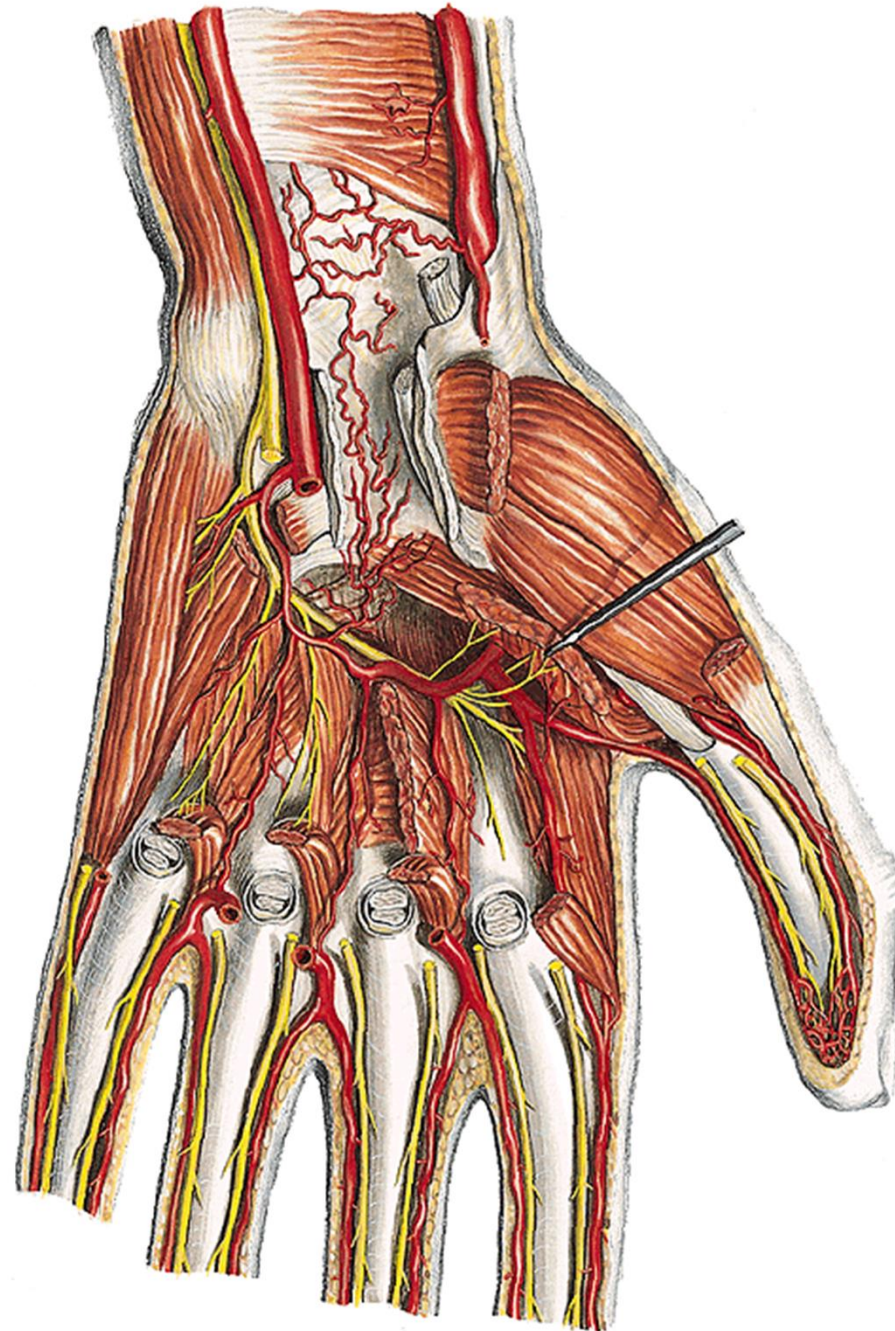
- aa. digitales palm. comm.
- aa. digitales palm. propriae

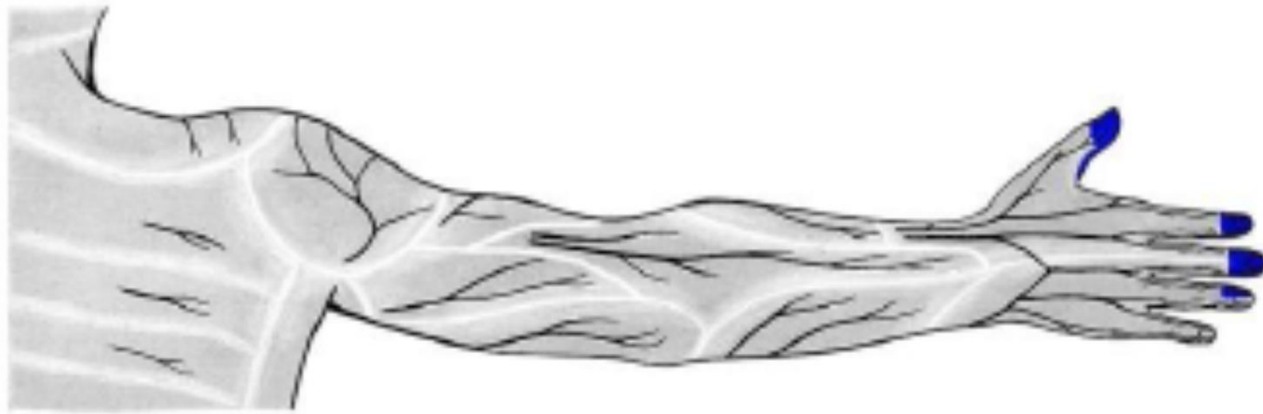
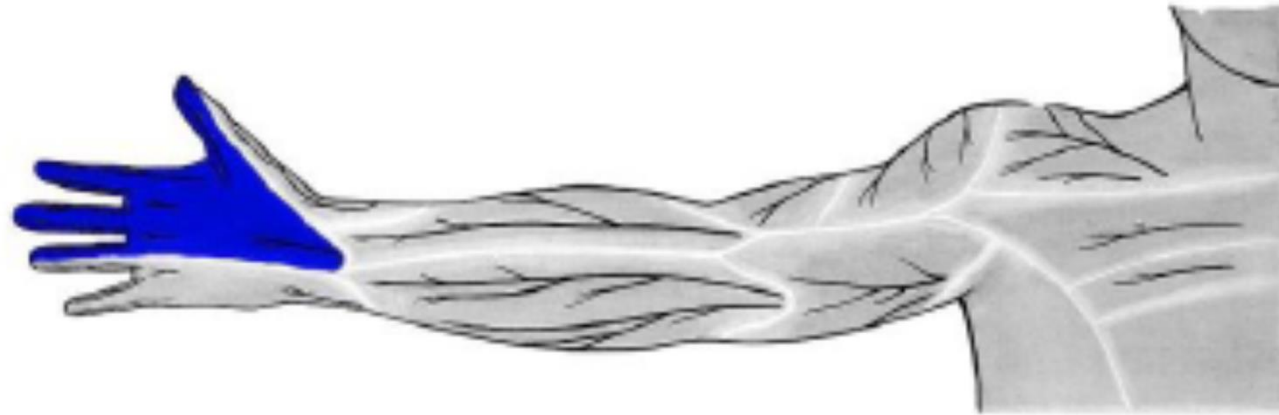
- nn. digitales palmares comm.
- nn. digitales palmares propriae



n. ulnaris (r. prof.)

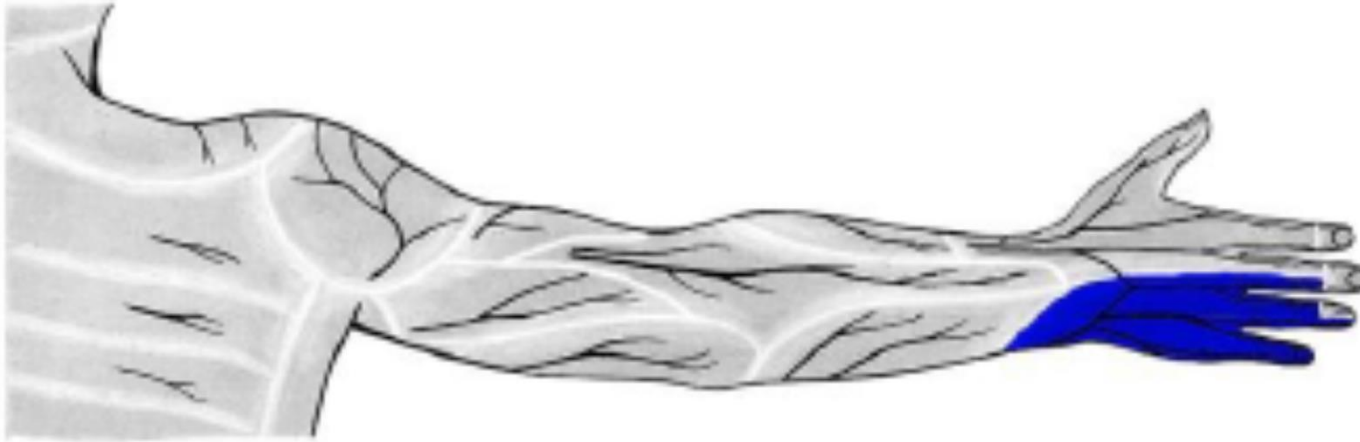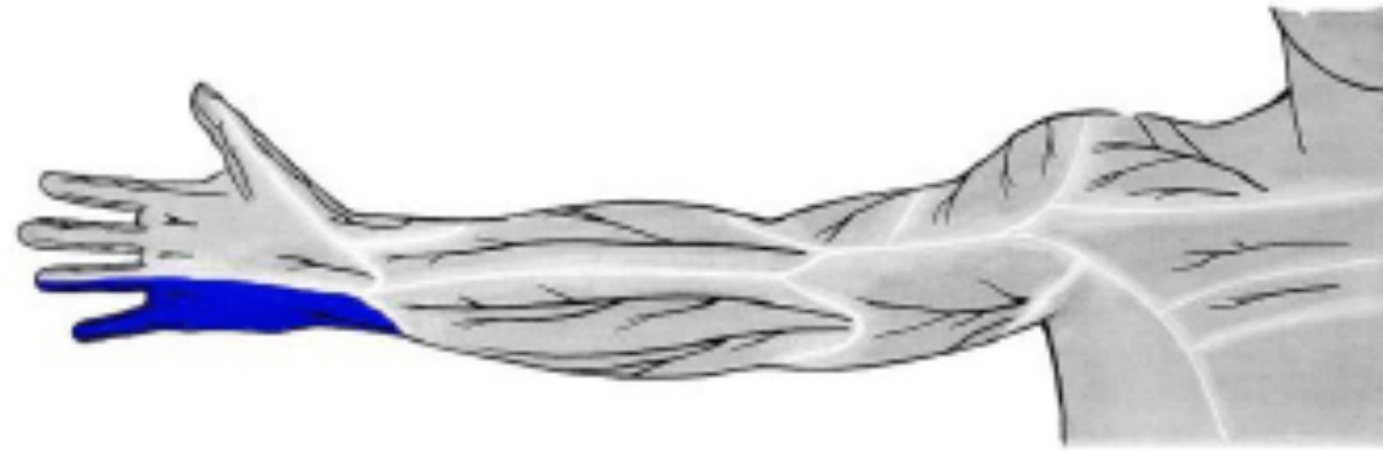
arcus palmaris prof.
aa. metacarpeae palm.





n. medianus





n. ulnaris

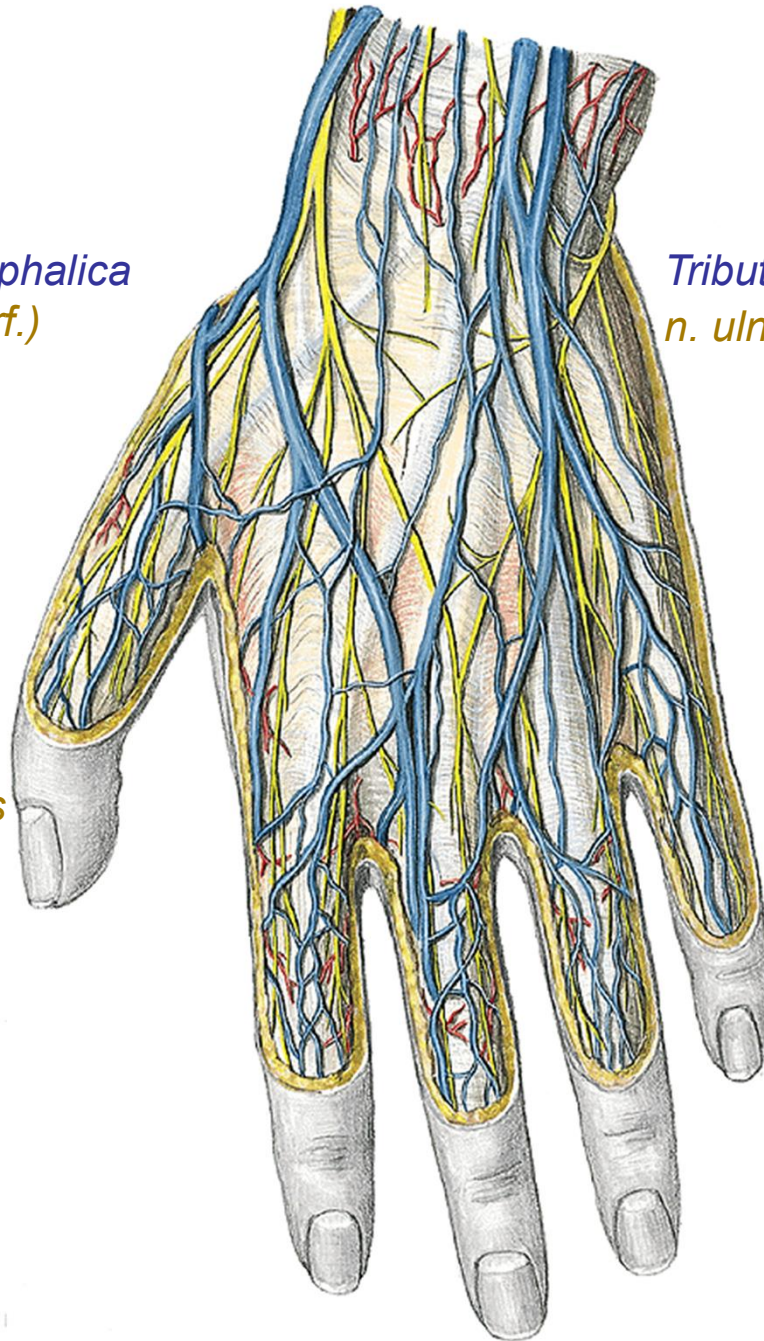


Tributaries of v. cephalica
n. radialis (r. superf.)

Tributaries of v. basilica
n. ulnaris (r. dorsalis)

dorsum manus

rete venosum
nn. digitales dorsales

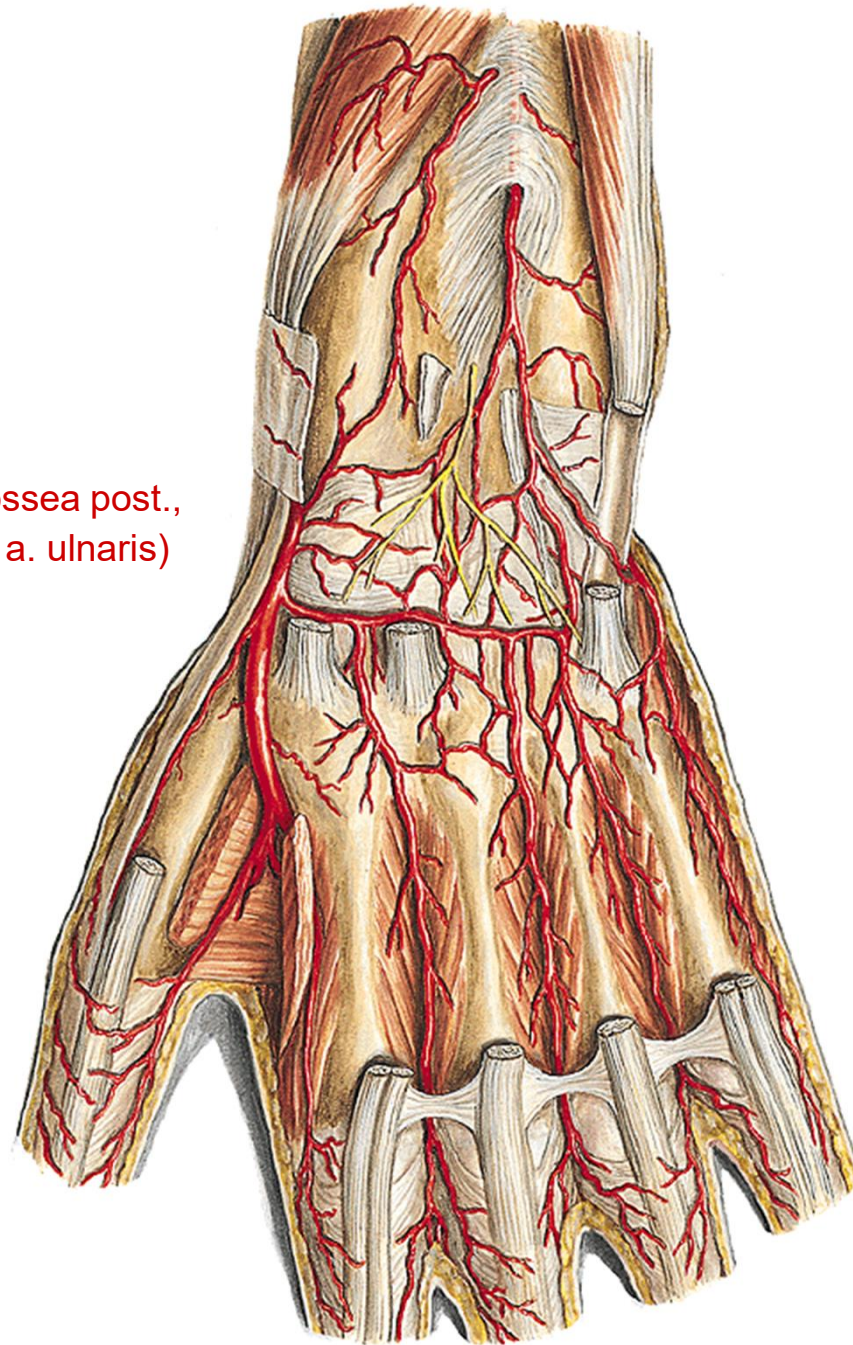


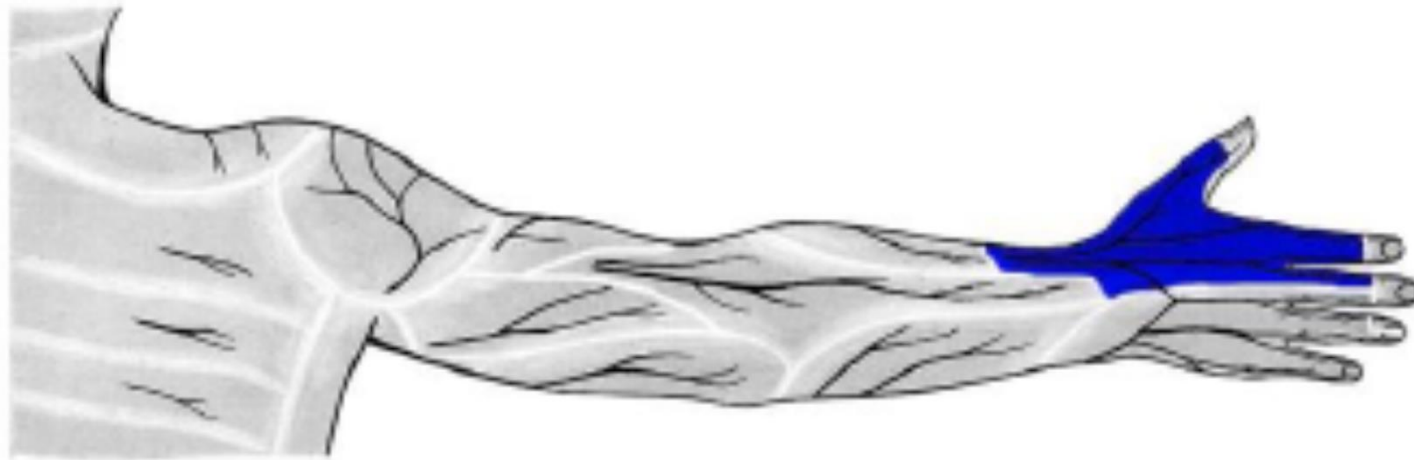
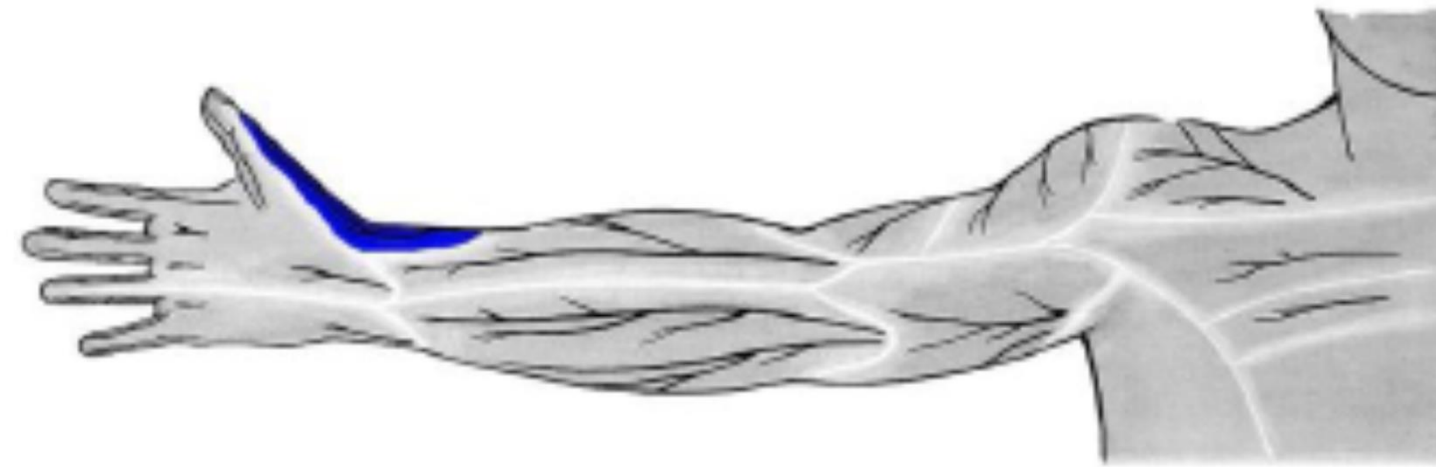n. interosseus post.

rete carpi dorsale

(a. interossea ant., a. interossea post.,
r. carpeus dors a. radialis et a. ulnaris)

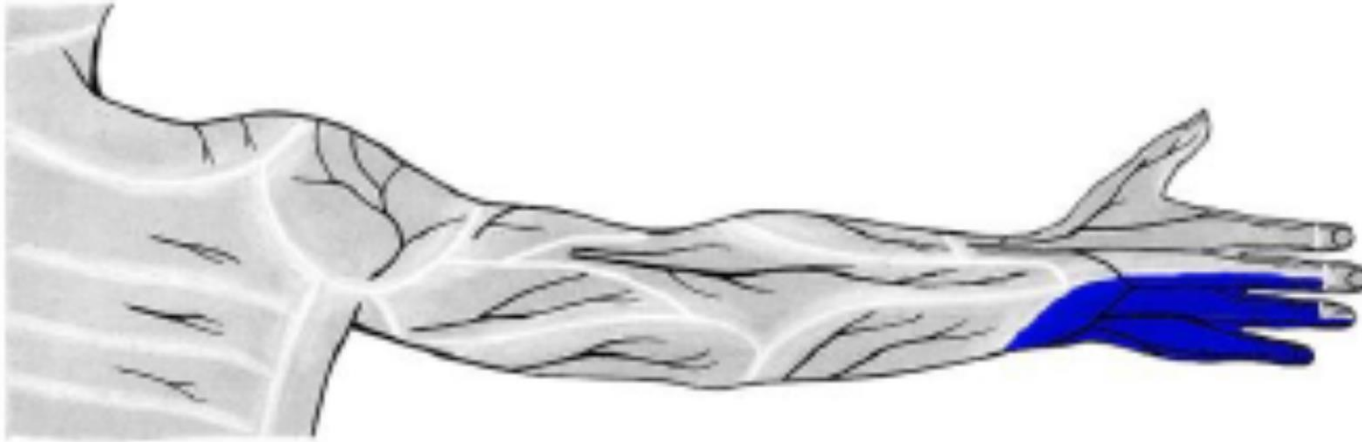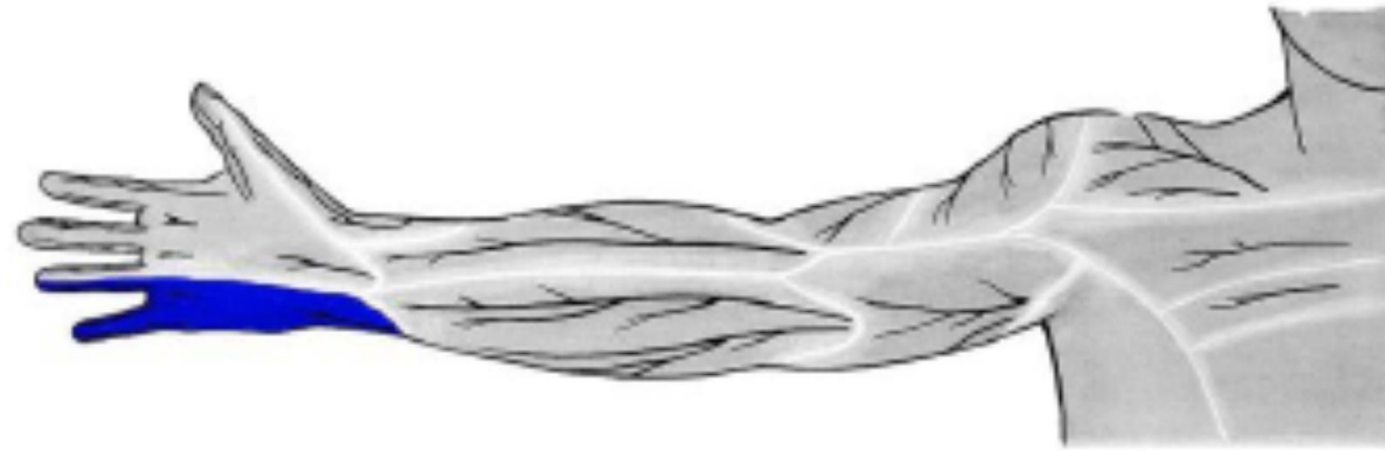aa. metacarpeae dors.





n. radialis



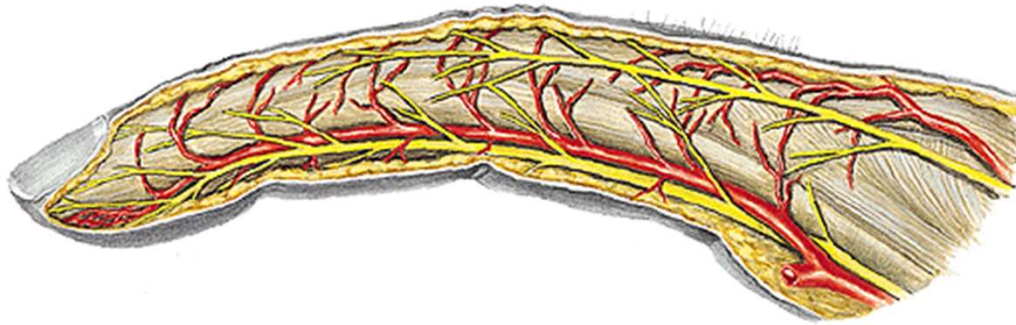


n. ulnaris

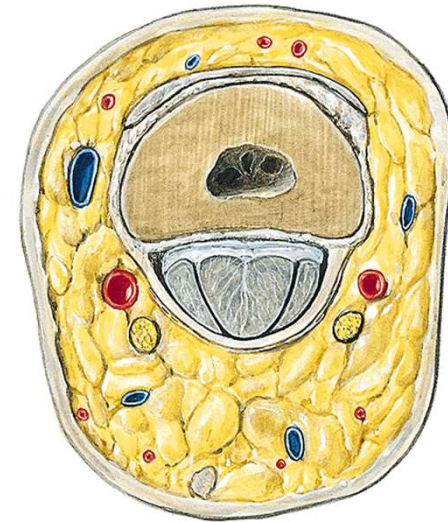


digiti manus

nn. digitales dors. (n. radialis et n. medianus)
aa. digitales dors.



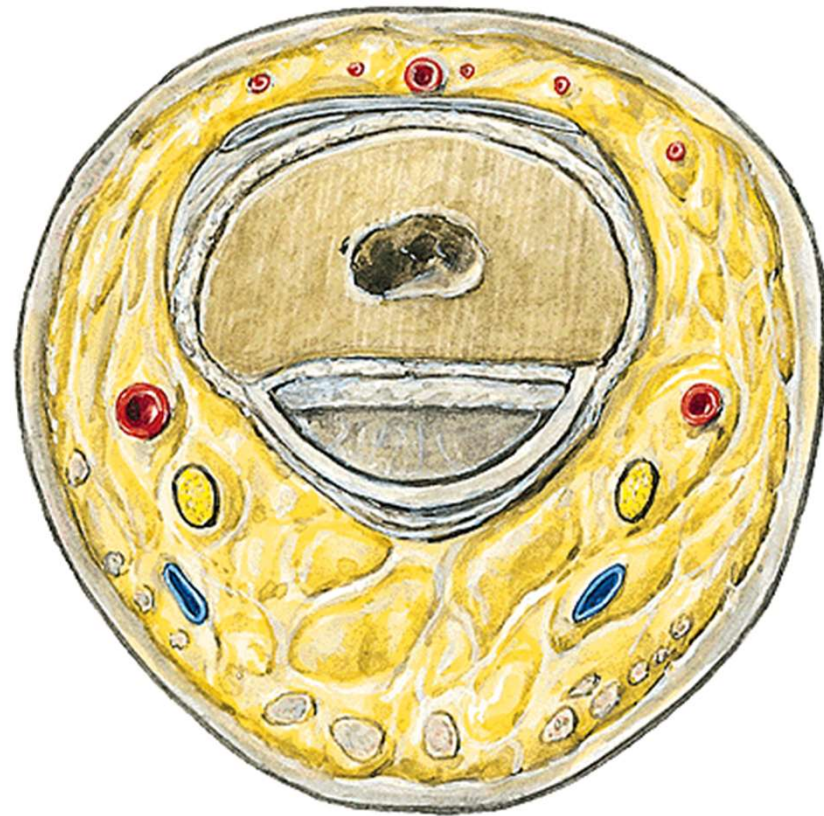nn. digitales palm. propr. (n. medianus et n. ulnaris)
aa. digitales palm. propr.



phalanx proximalis



From dorsal

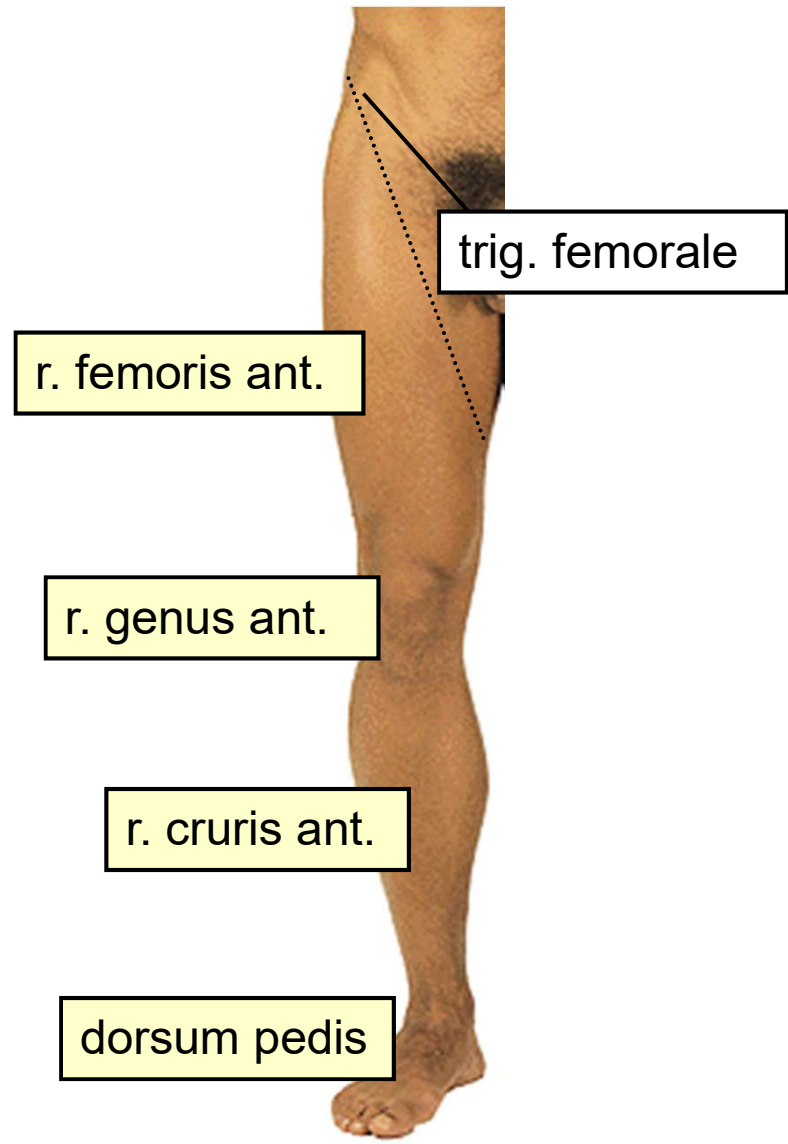


phalanx media



The regional anatomy of the lower extremity





trig. femorale

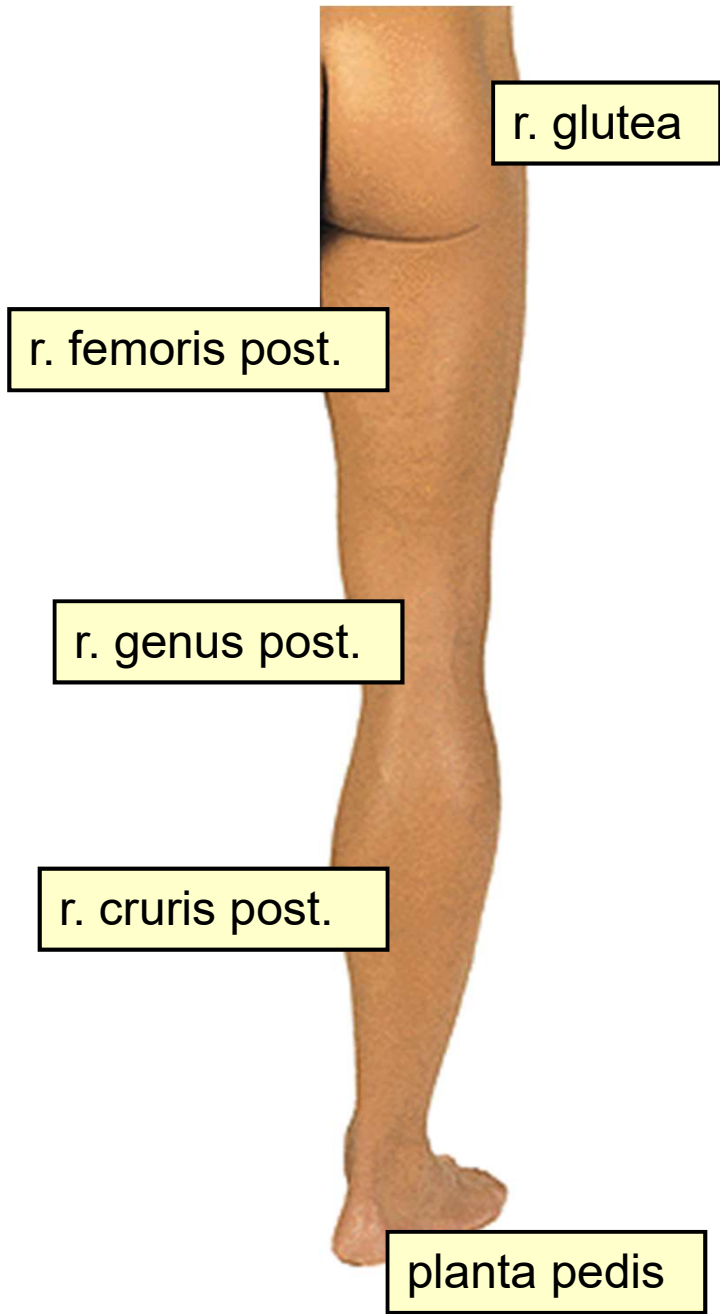
r. femoris ant.

r. genus ant.

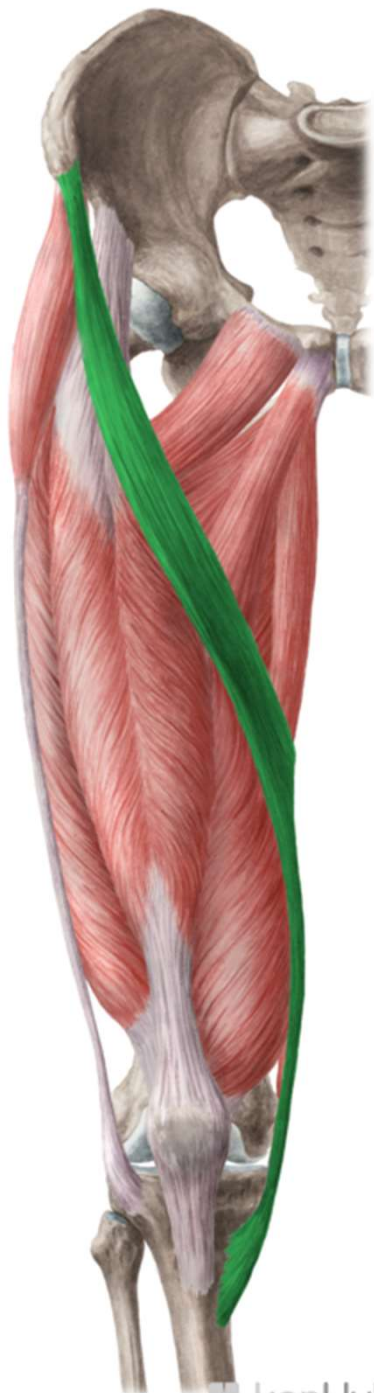r. cruris ant.

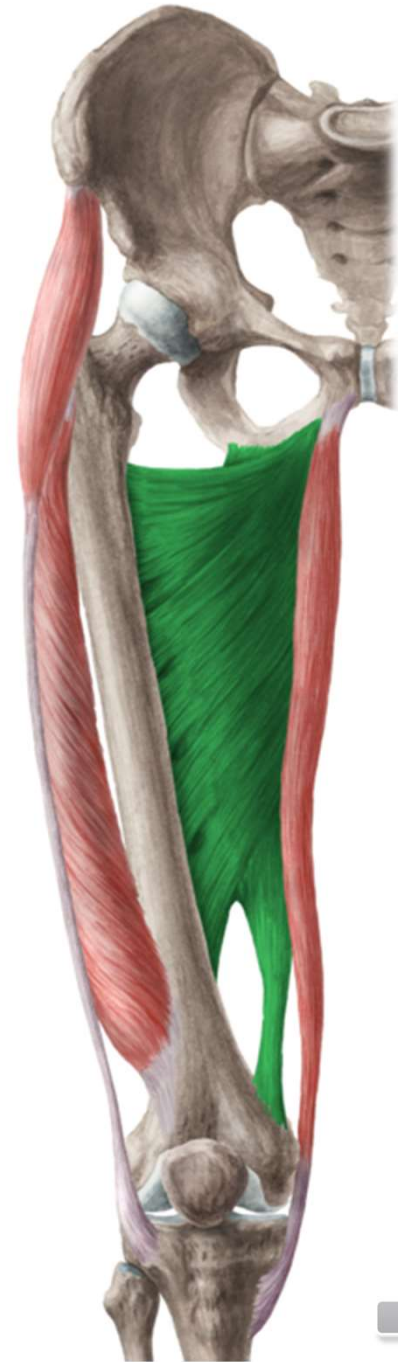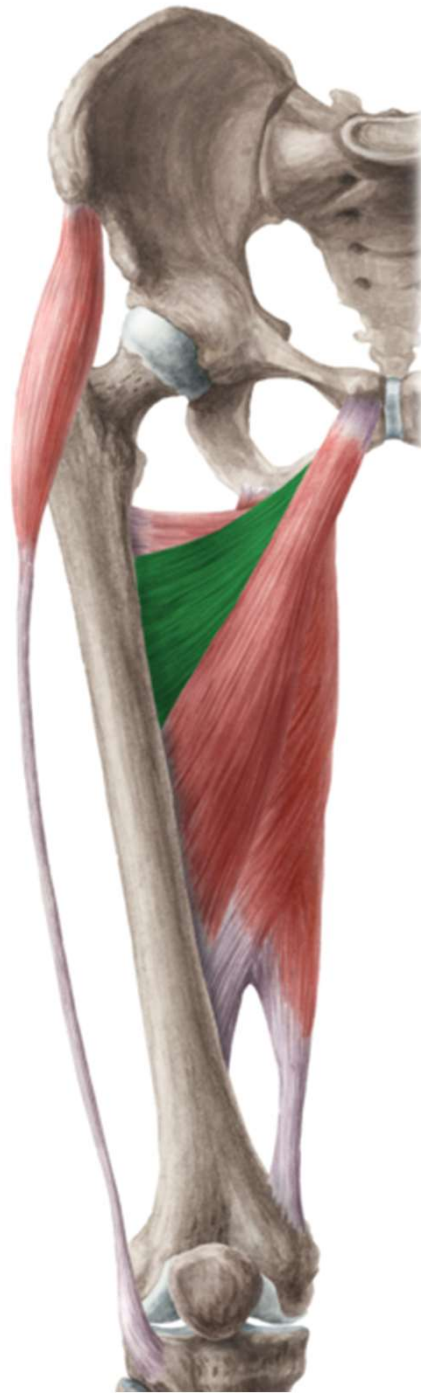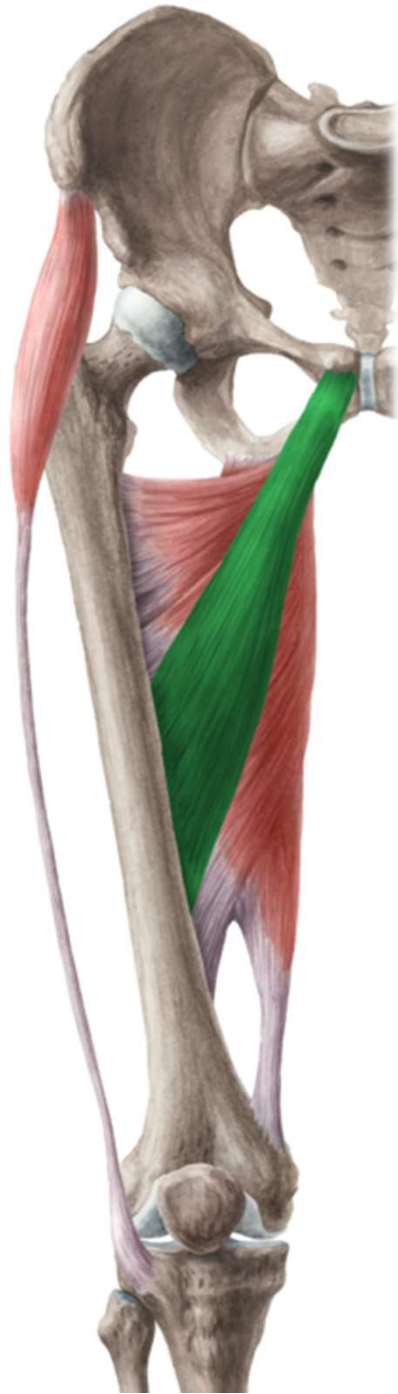dorsum pedis

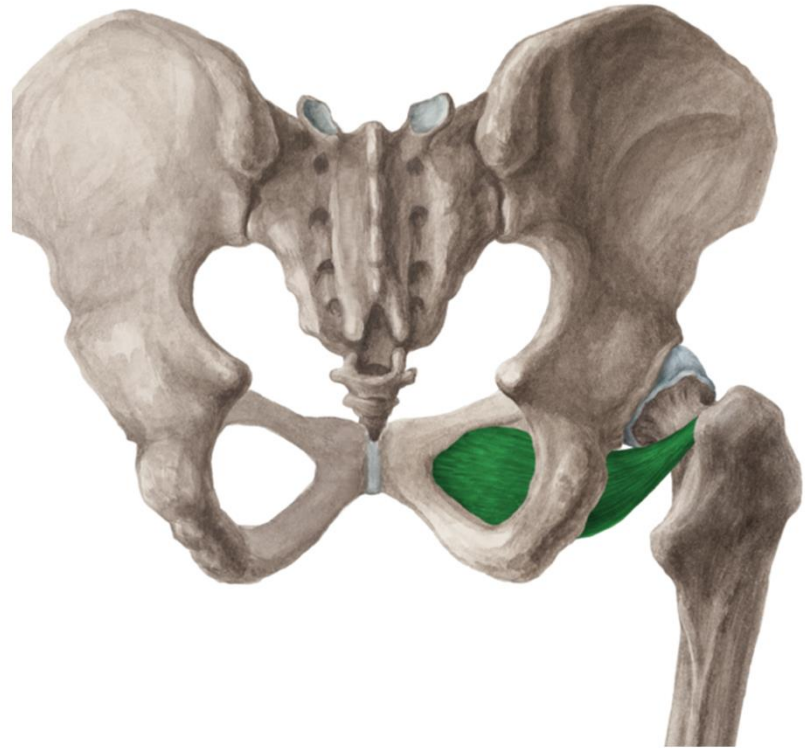
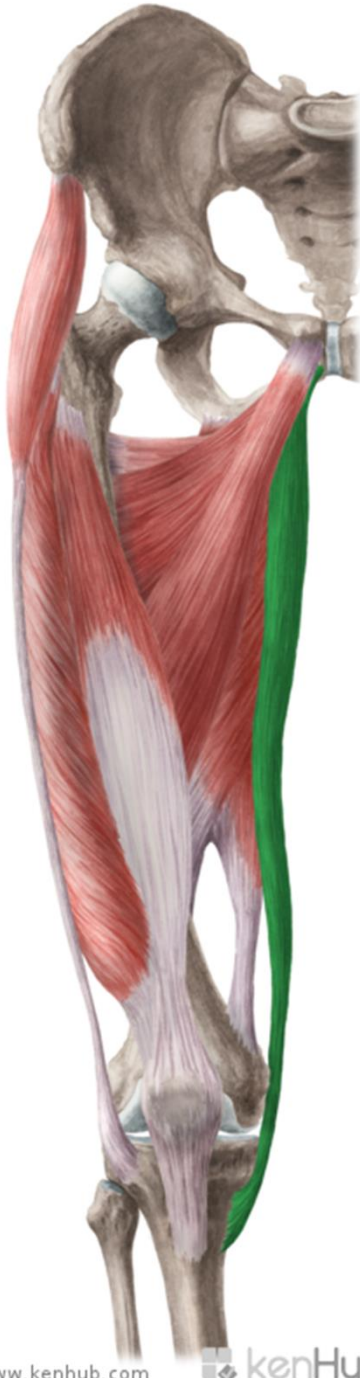
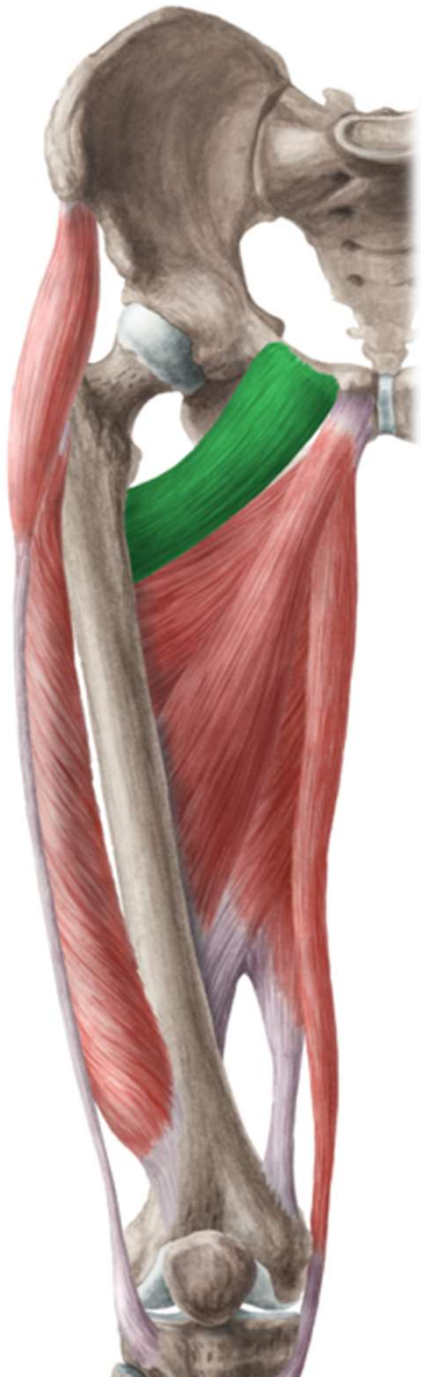


**r. femoris
ant.**







v. saphena magna + tributaries

n. cutaneus femoris lat.

n. cutaneus femoris post.

rr. cutanei ant. (from n. femoralis)

r. cutaneus (from n. obturatorius)

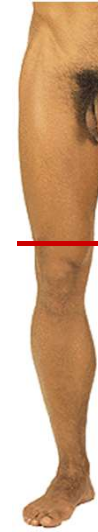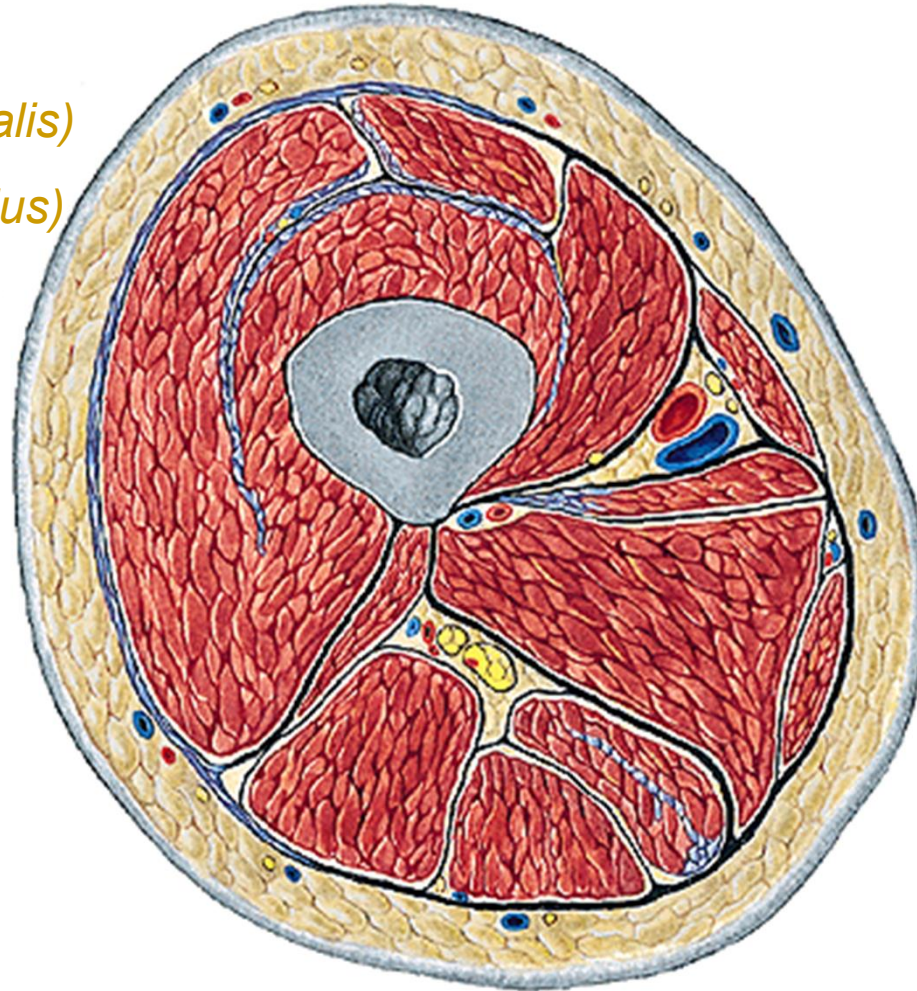
n. femoralis → n. saphenus

a. et v. femoralis

n. obturatorius

a. et v. obturatoria

n. ischiadicus



r. femoris ant.

v. saphena magna + tributaries

a. epigastrica superf.

a. circumflexa ilium superf.

aa. pudendae ext.

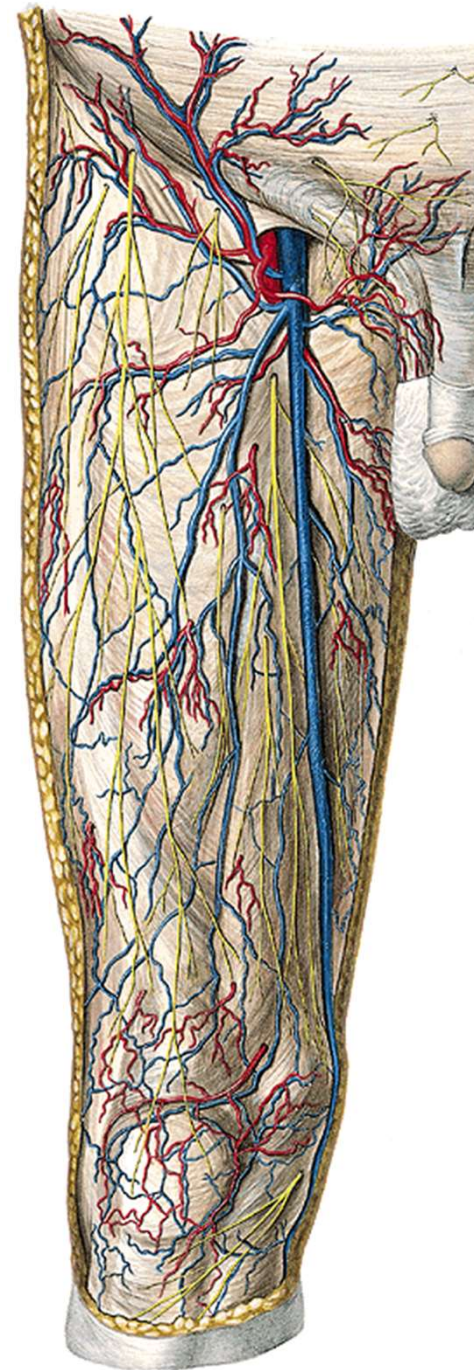
n. cutaneus femoris lat.

r. femoralis (from n. genitofemoralis)

rr. cutanei ant. (from n. femoralis)

r. cutaneus (from n. obturatorius)

nll. inguinales superf.



trig. femorale

m. sartorius, lig. inguinale, m. adductor longus

v. saphena magna

v. saphena accessoria

v. epigastrica superf. a. epig. superf.

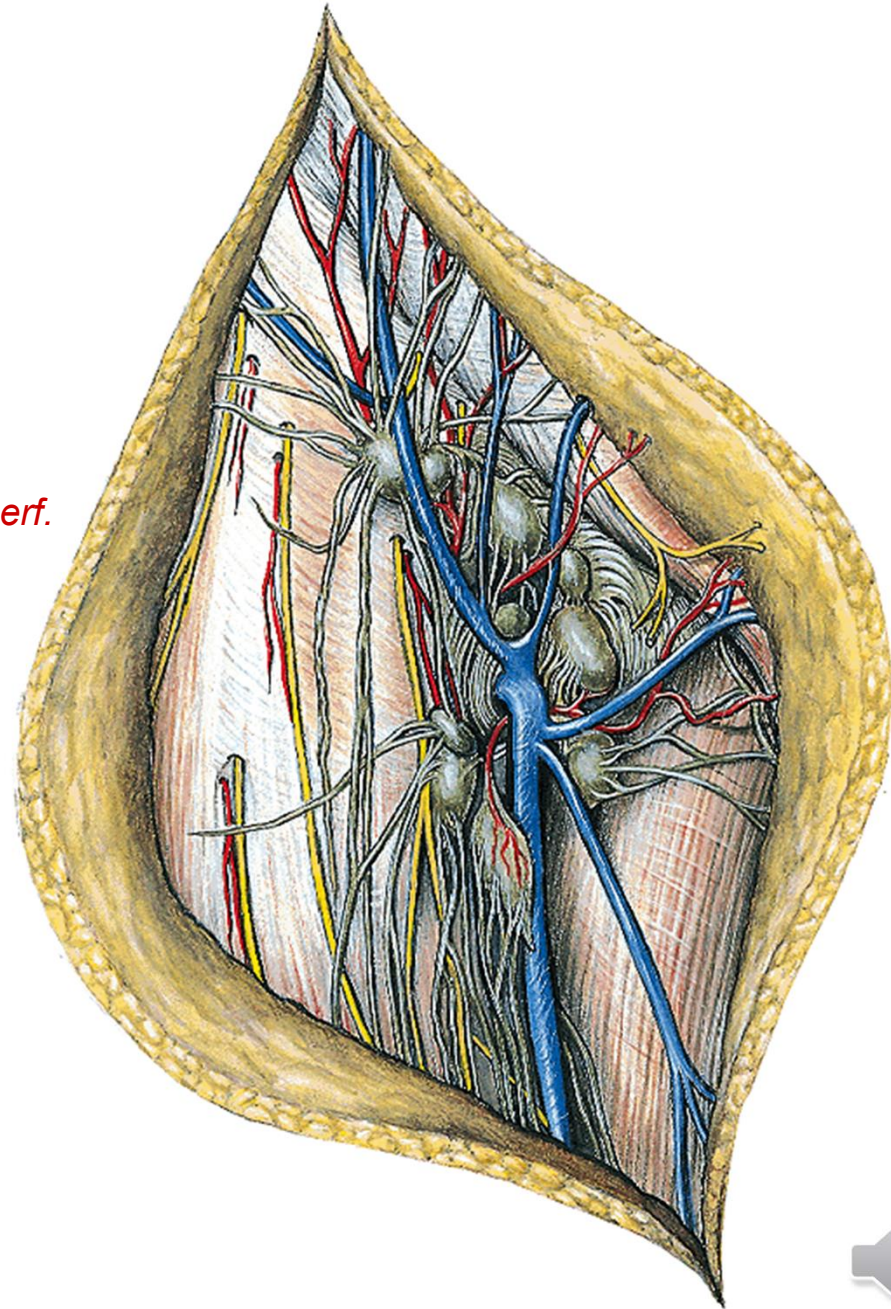
v. circumfl. ilium superf. a. circumfl. ilium superf.

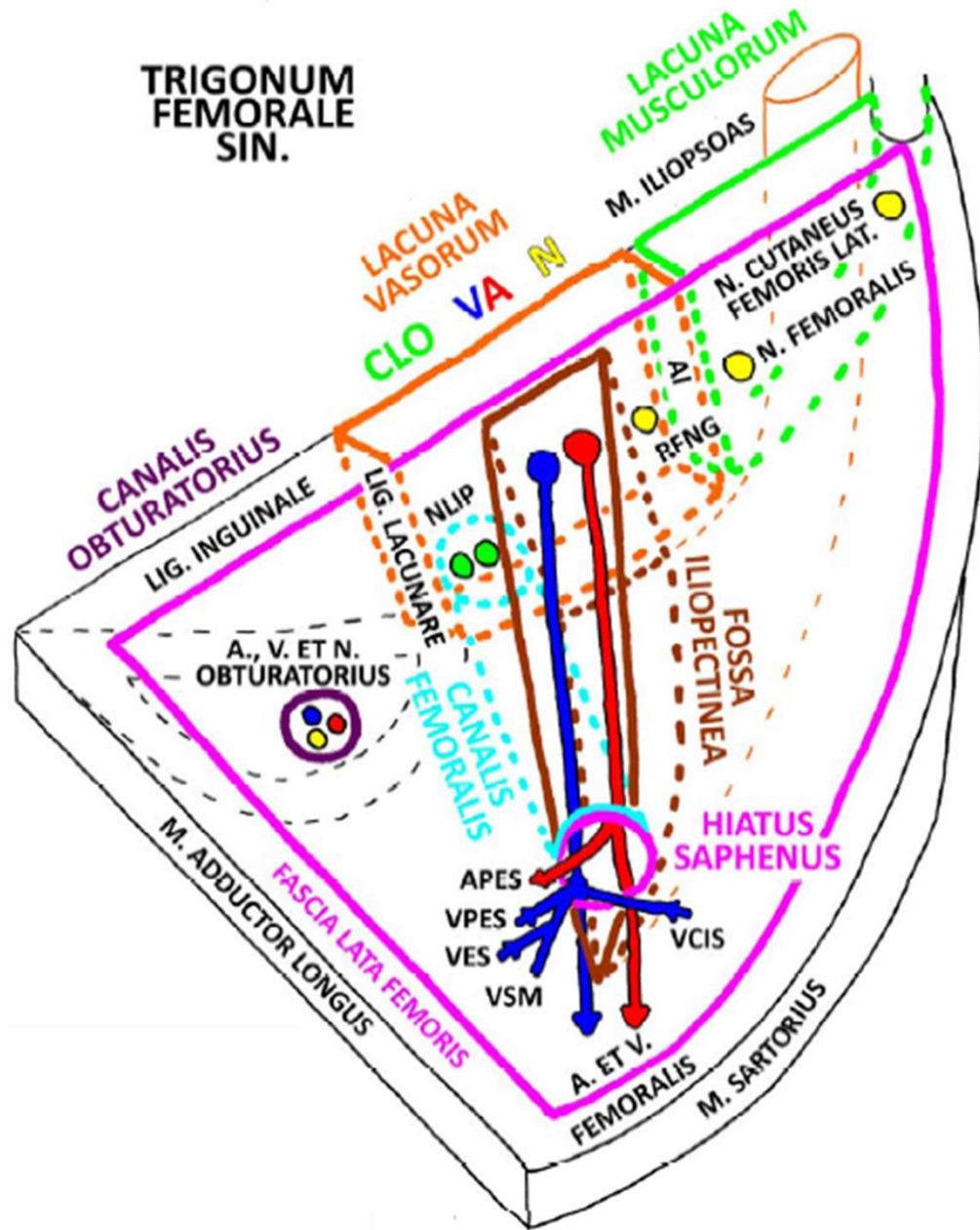
vv. pudendae ext. aa. pudendae ext.

nll. inguinales superf.

n. ilioinguinalis

n. genitofemoralis (r. femoralis)



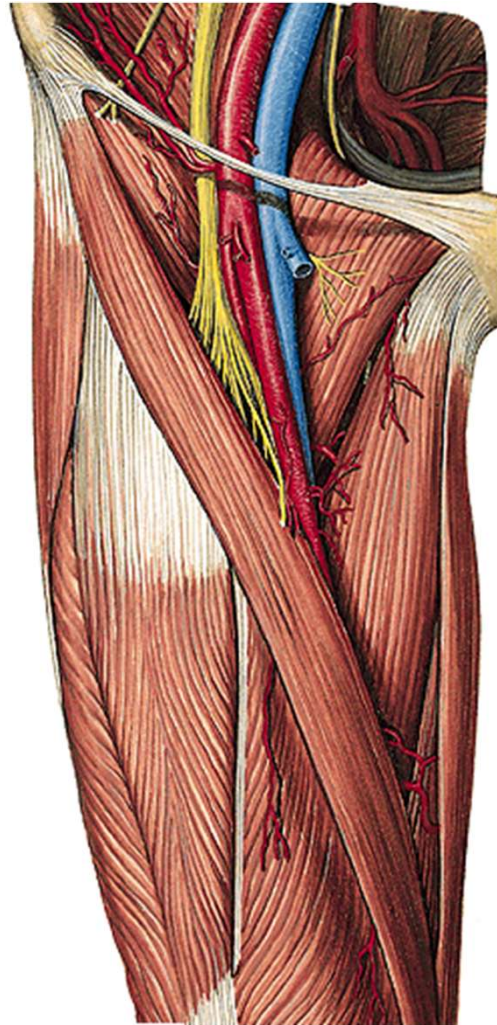


fossa
iliopectinea

a. et v. femoralis

n. femoralis

nll. inguinales prof.



FOSSA ILIOPECTINEA



lacuna musculorum:

m. iliopsoas

n. femoralis

lacuna vasorum:

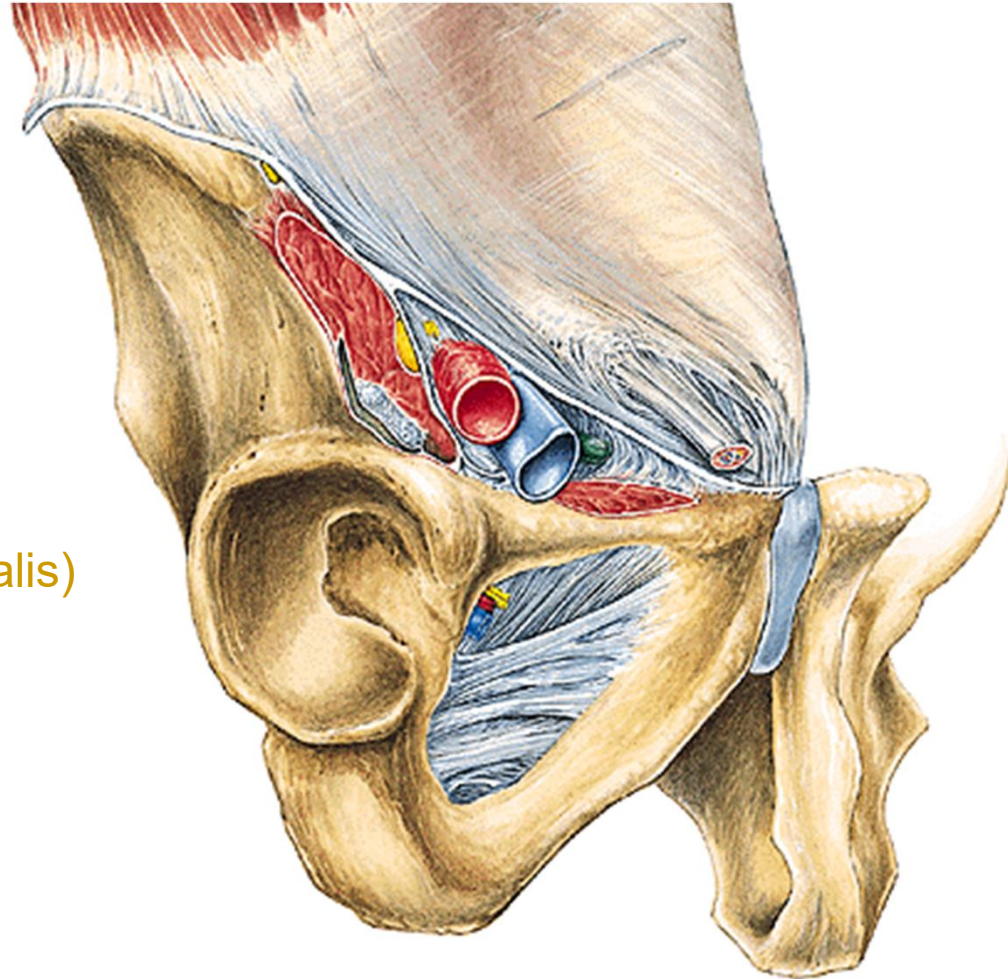
n. genitofemoralis (r. femoralis)

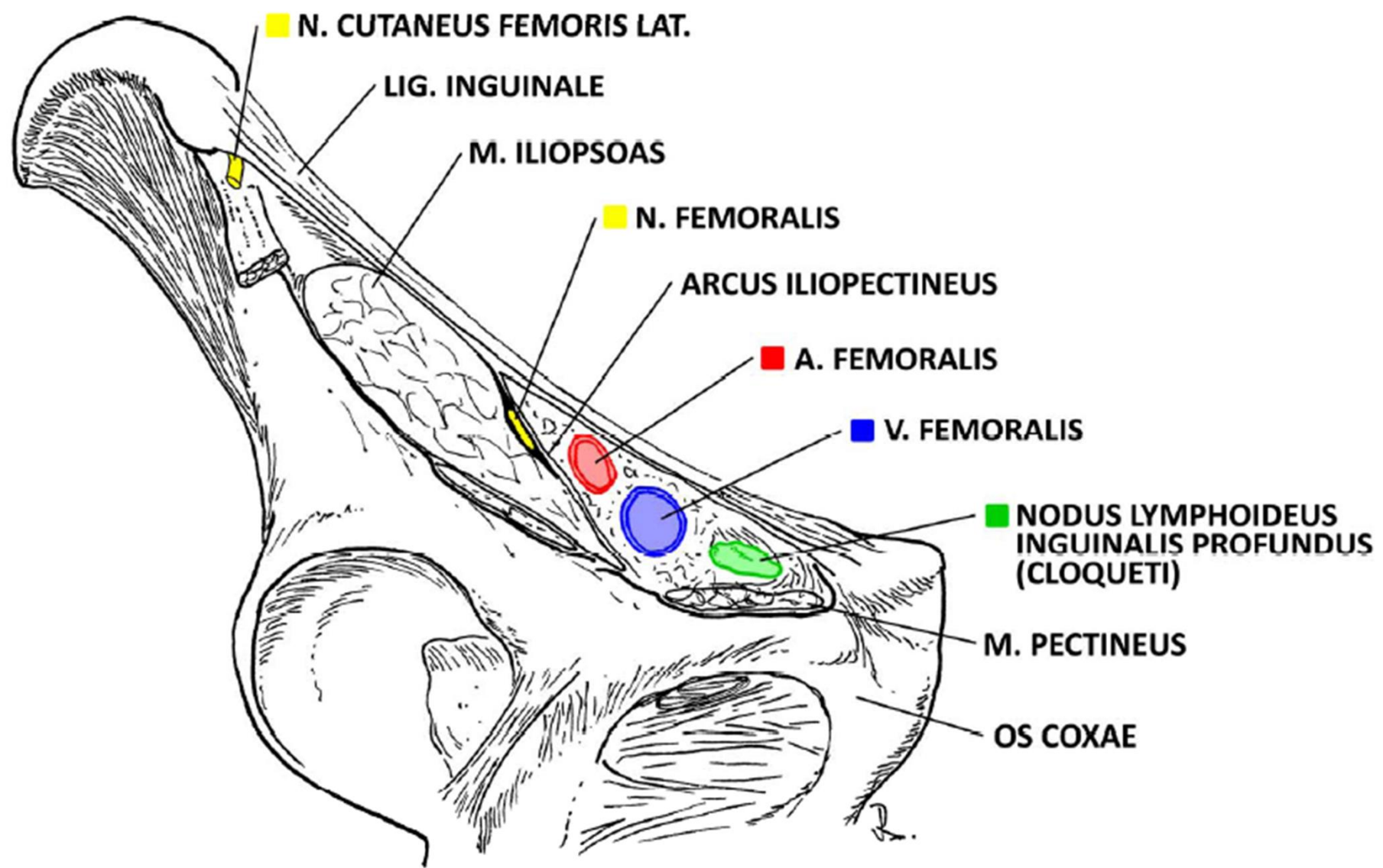
a. femoralis

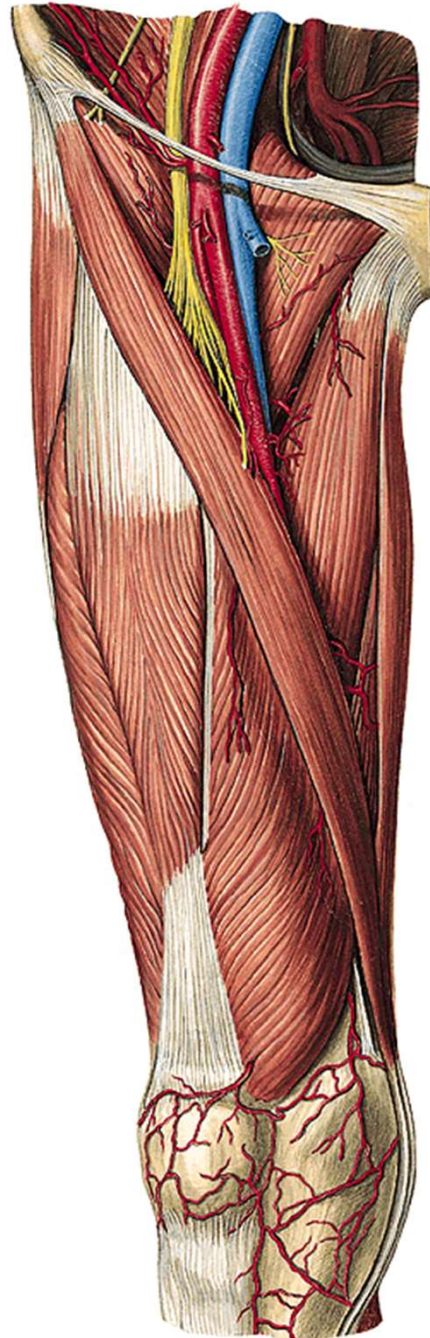
v. femoralis

nl. Cloqueti

Femoral hernia







canalis adductorius

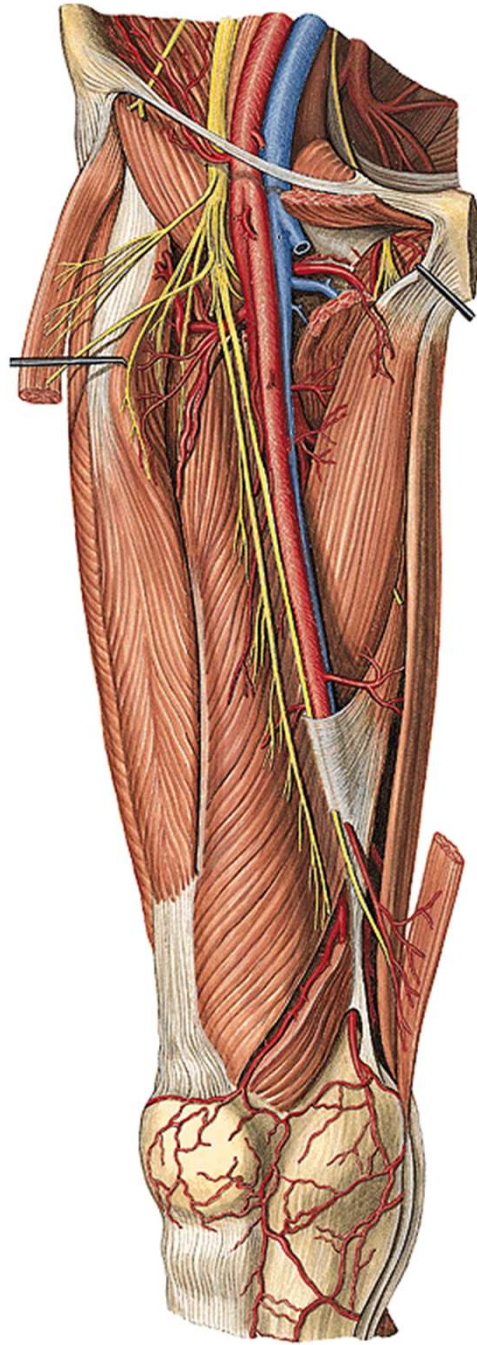
(m. vastus med. and m. adductor magnus)

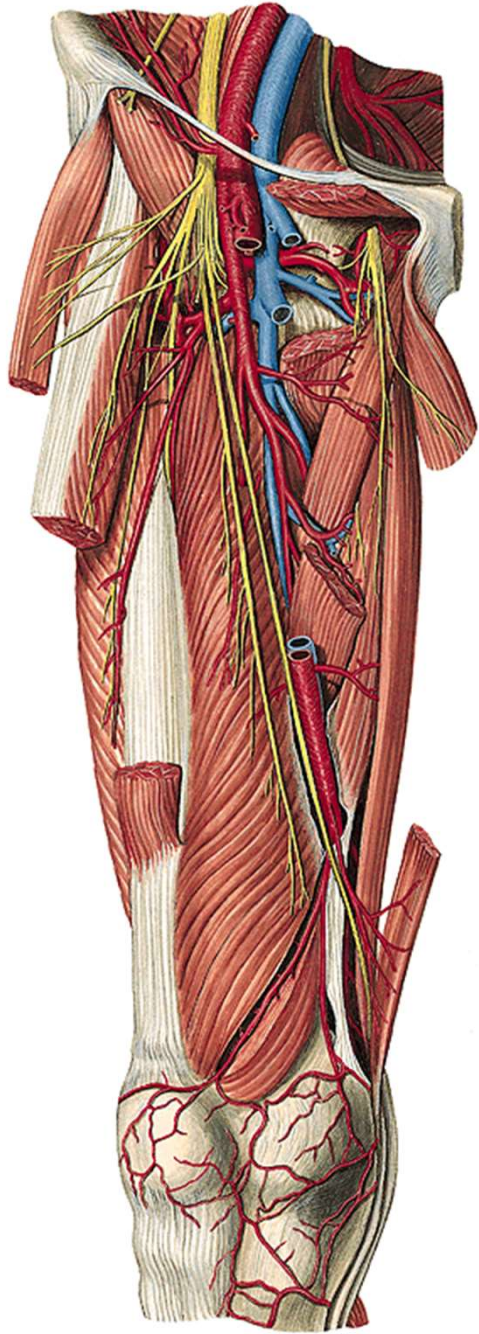
a. et v. femoralis

n. saphenus

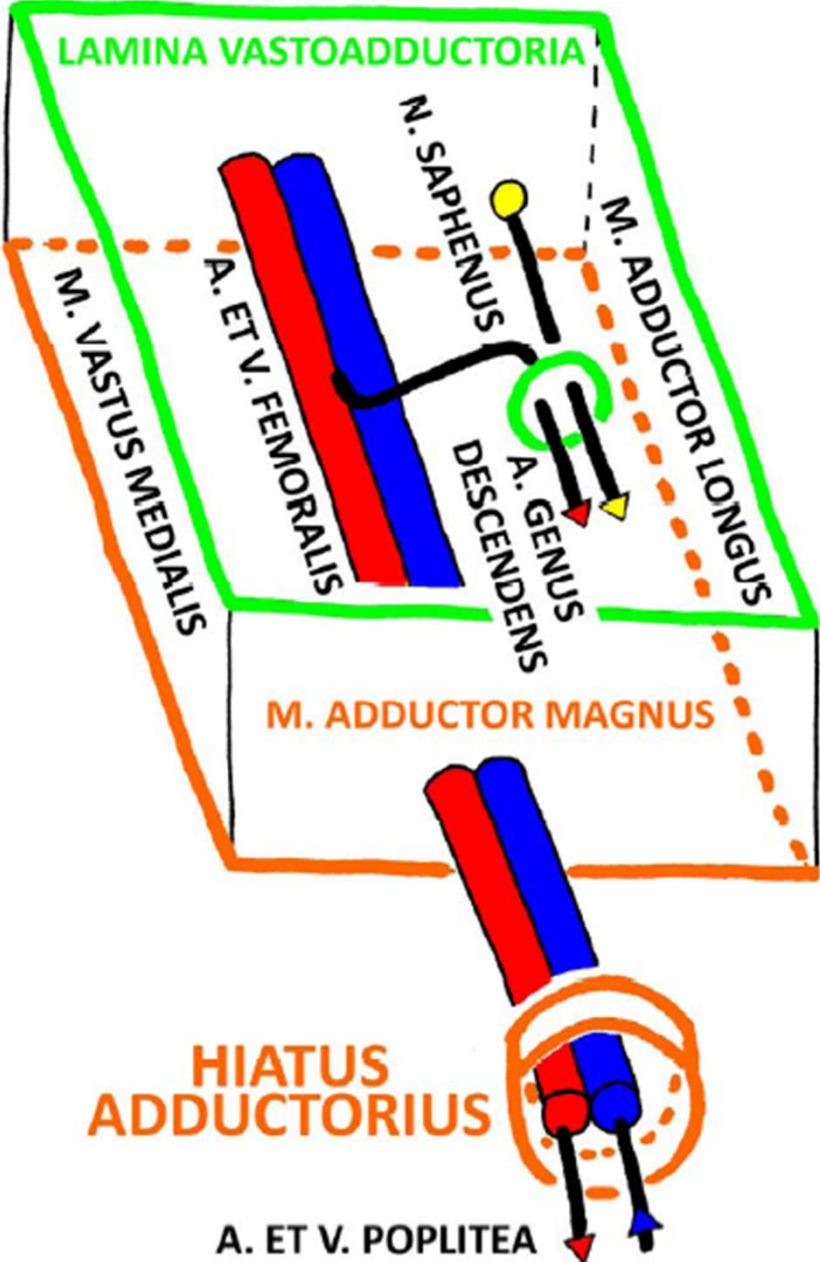
hiatus tendineus

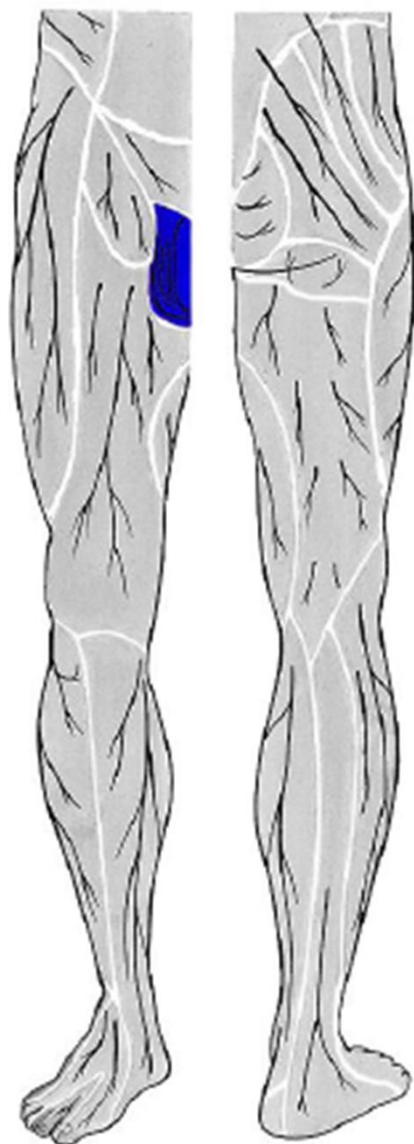




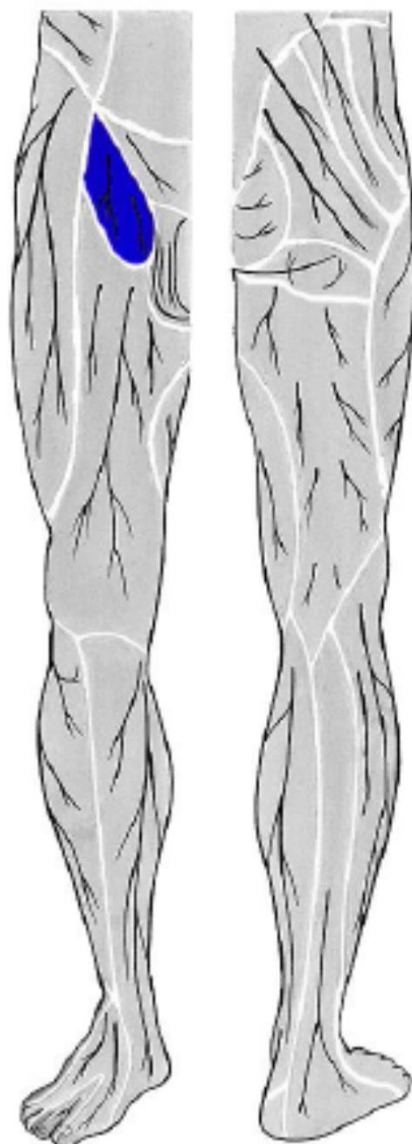


CANALIS ADDUCTORIIUS DX.



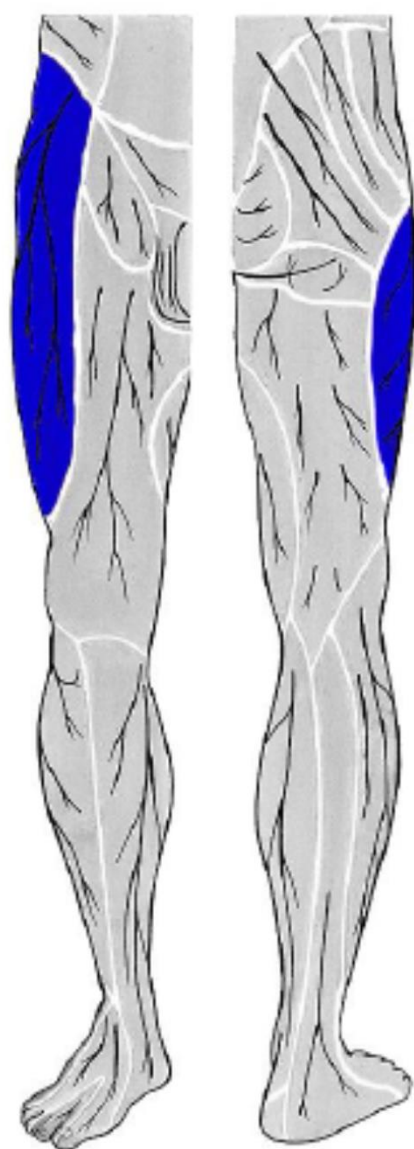


n. ilioinguinalis

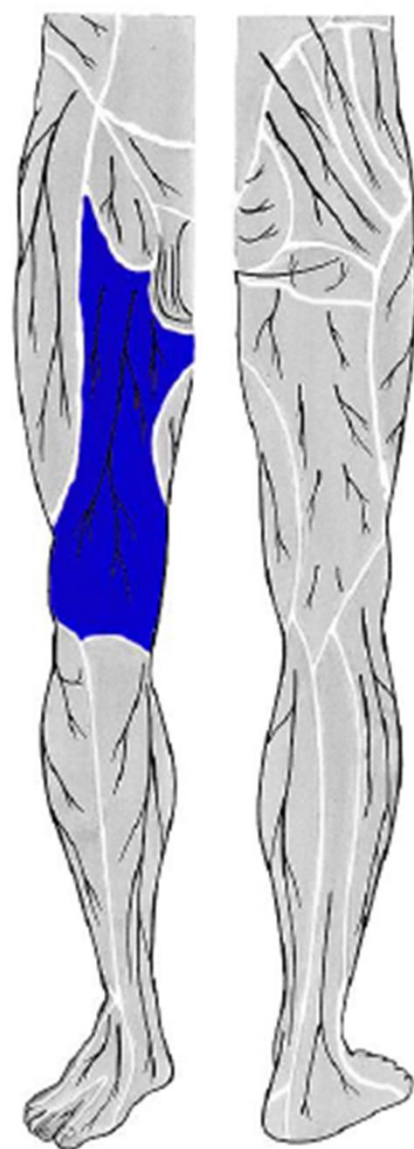


n. genitofemoralis

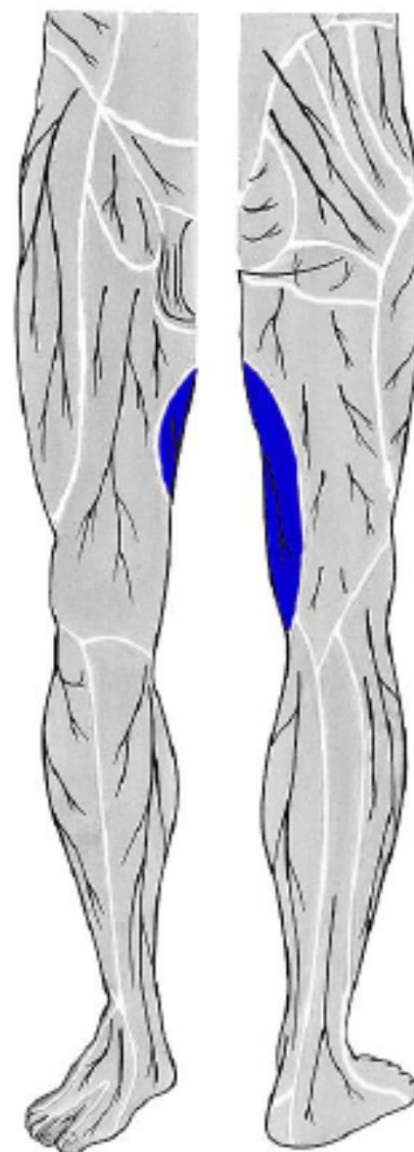




**n. cutaneus femoris
lateralis**



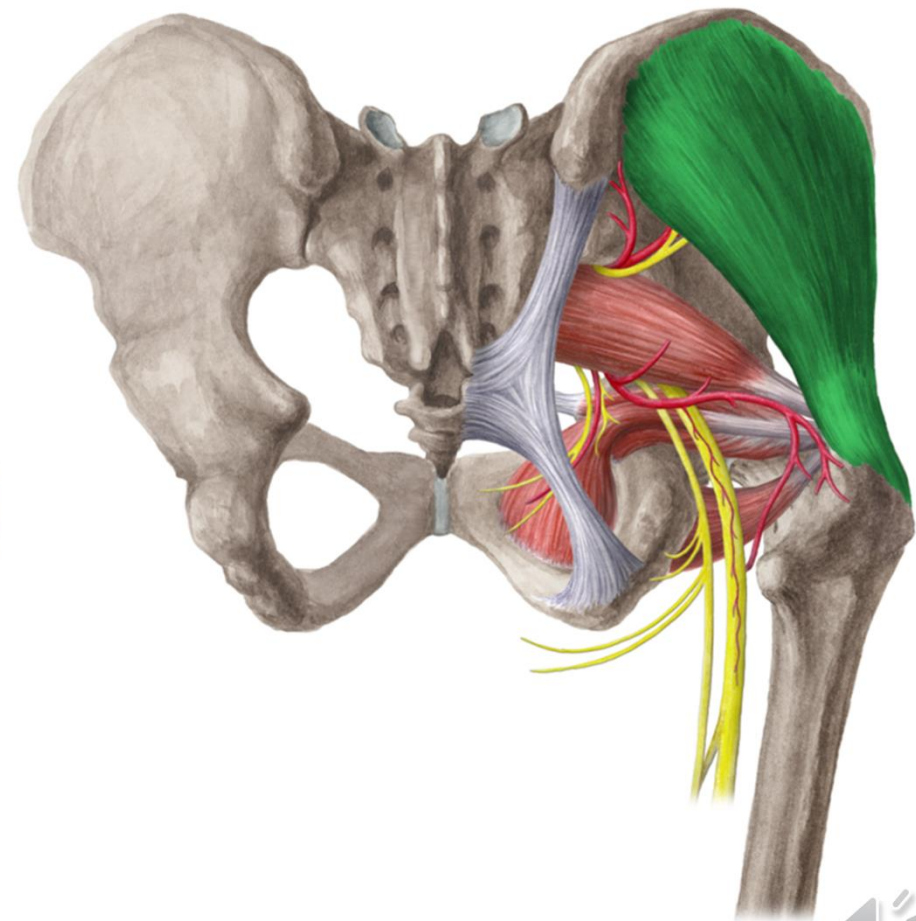
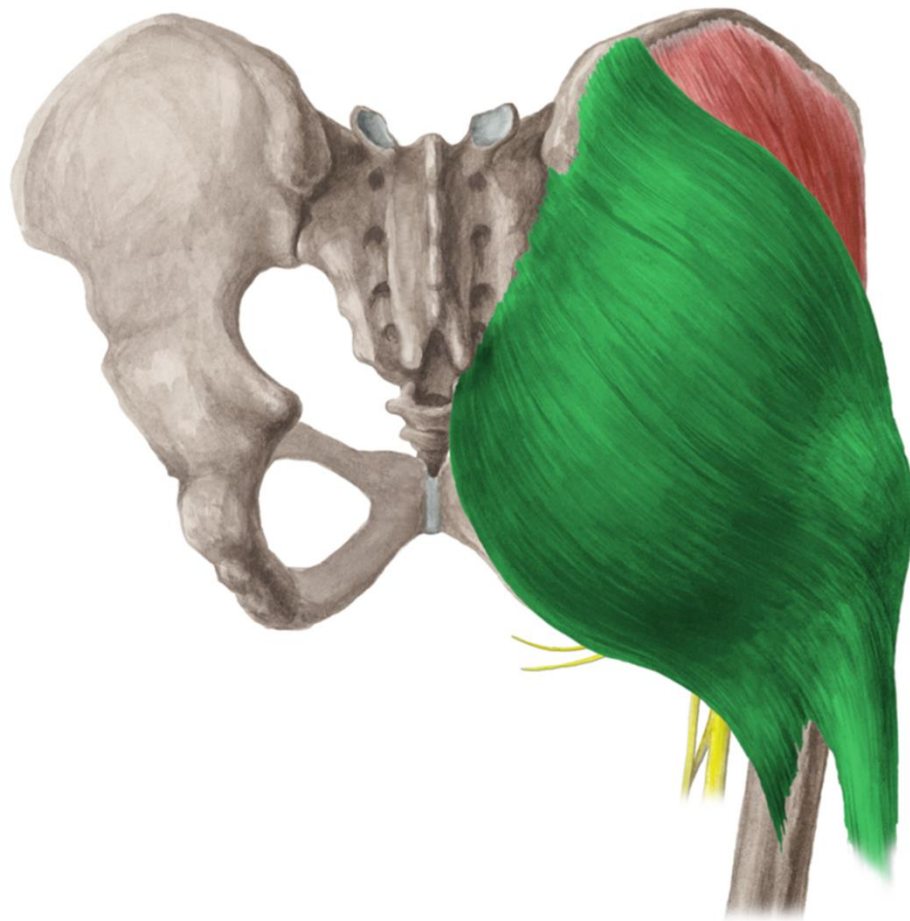**rr. cutanei ant. femoris
(z n. femoralis)**

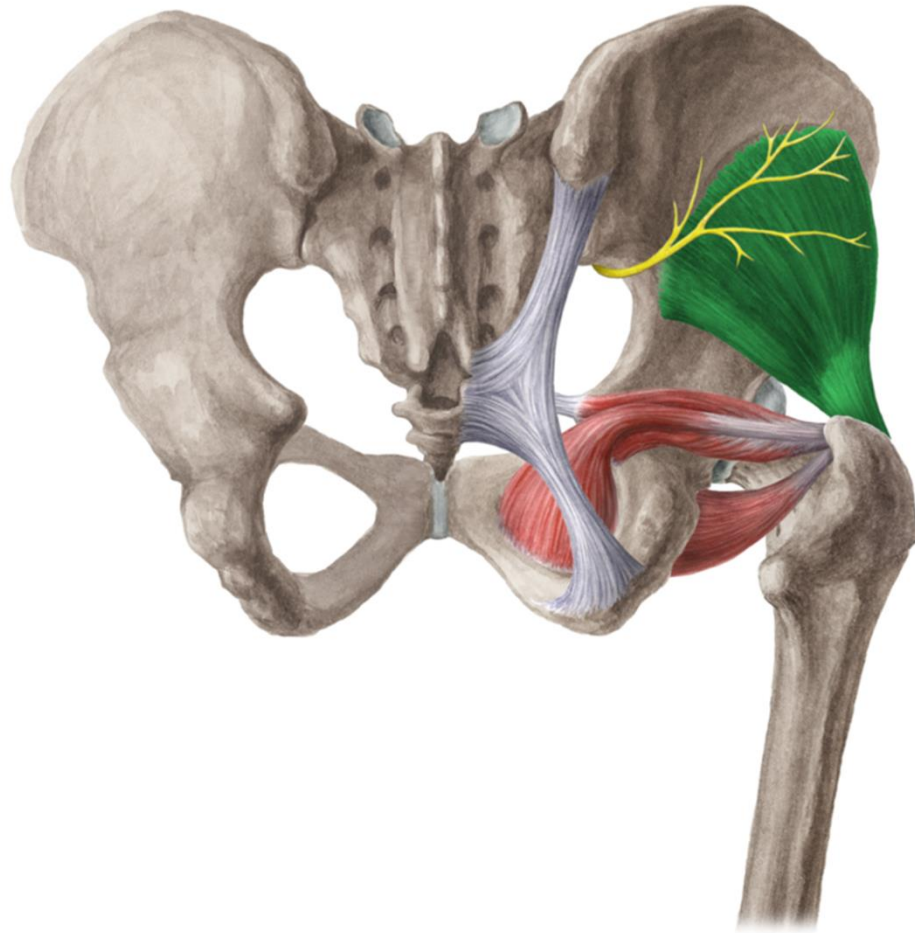


**r.cutaneus n. obturatorii
(z n. obturatorius)**



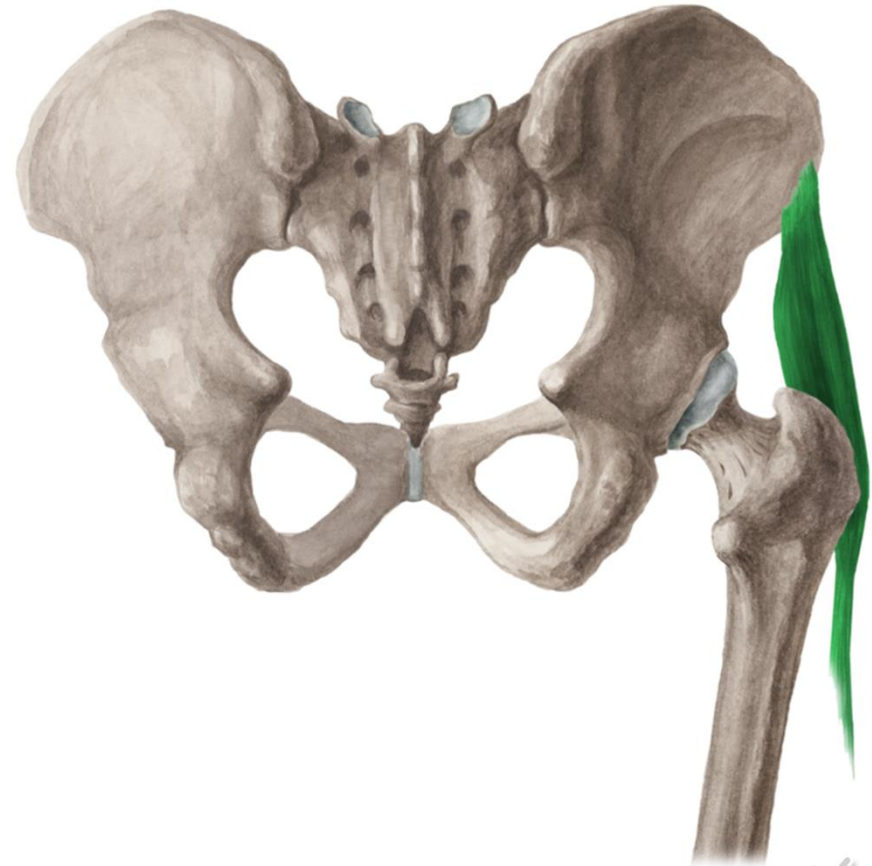
r. glutea
r. femoris post.





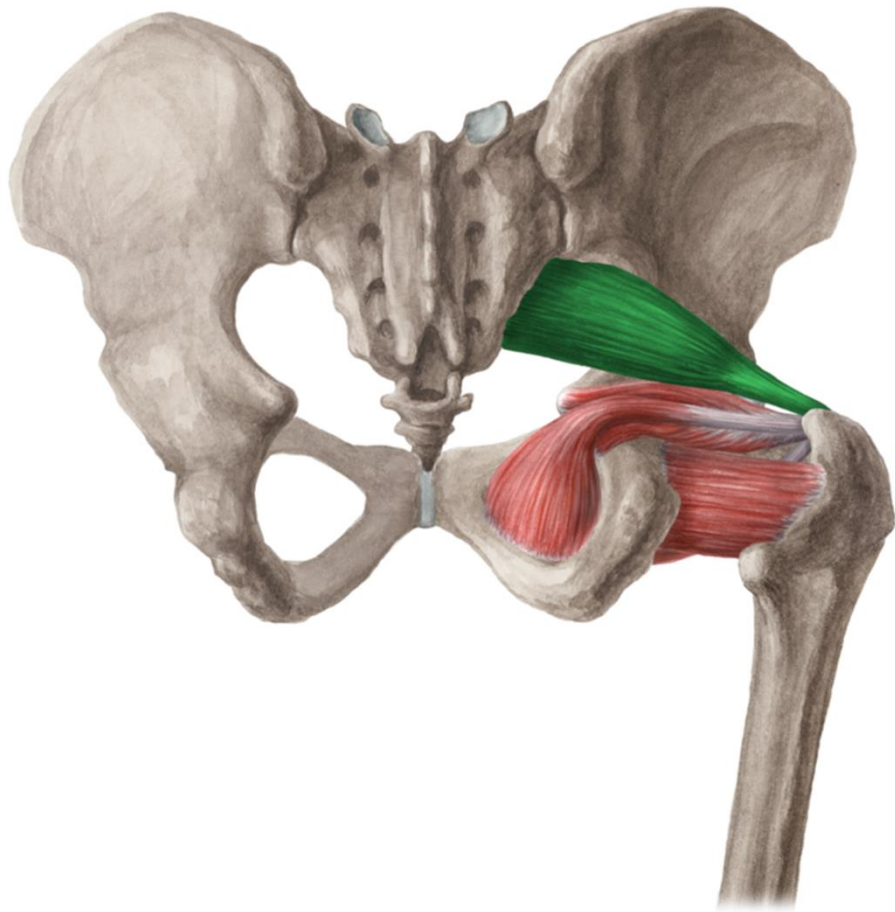
www.kenhub.com

kenHub



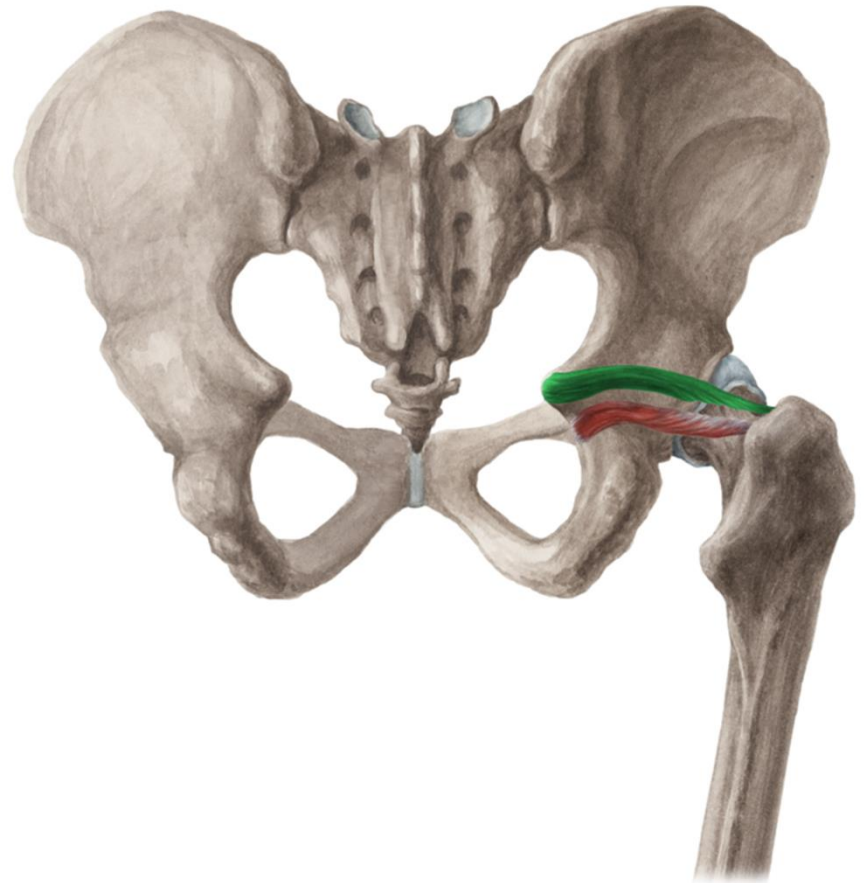
www.kenhub.com





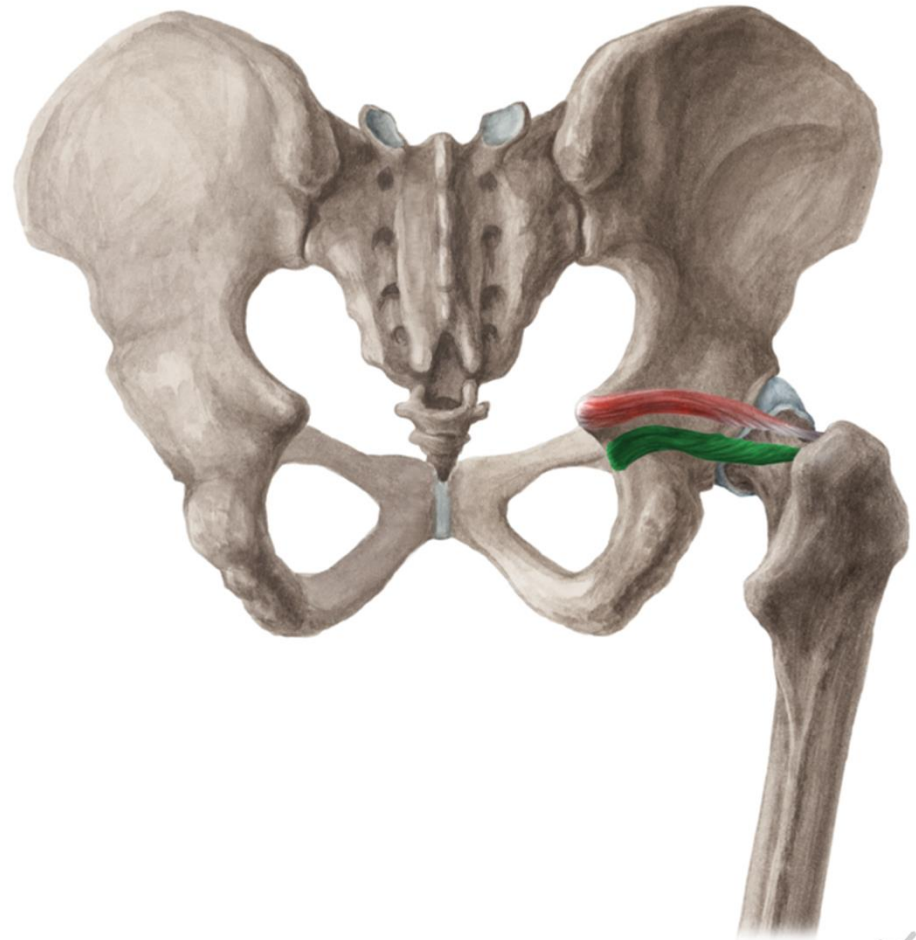
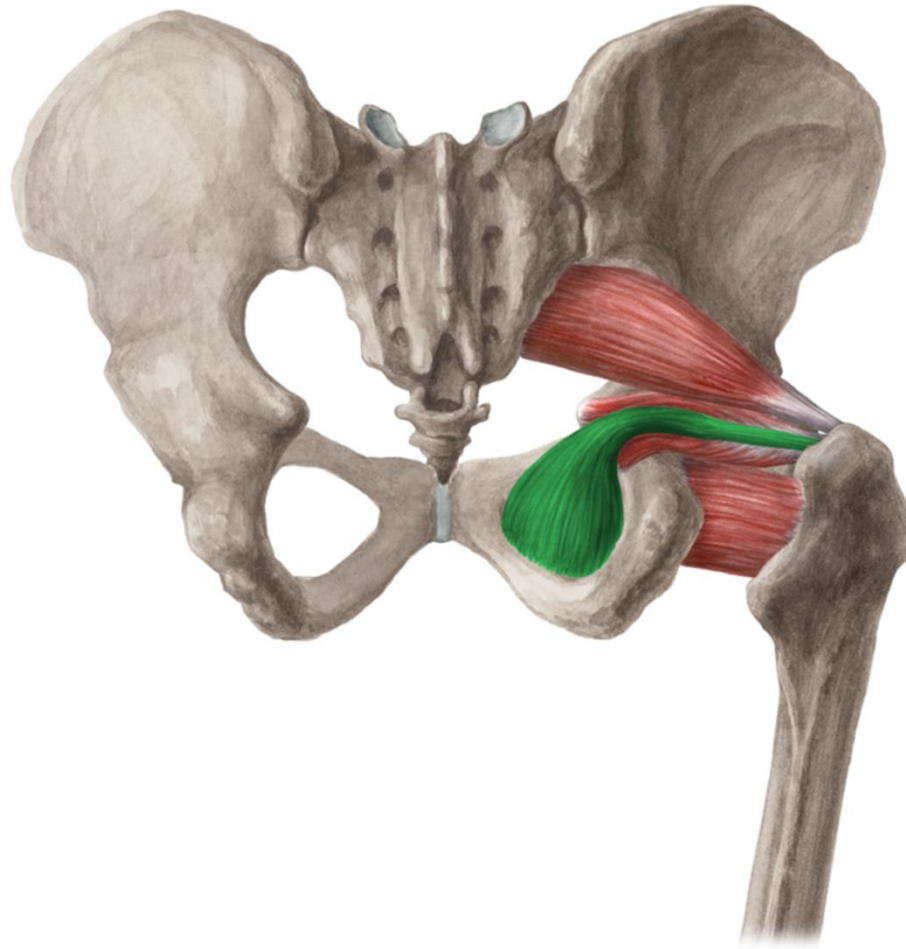
www.kenhub.com

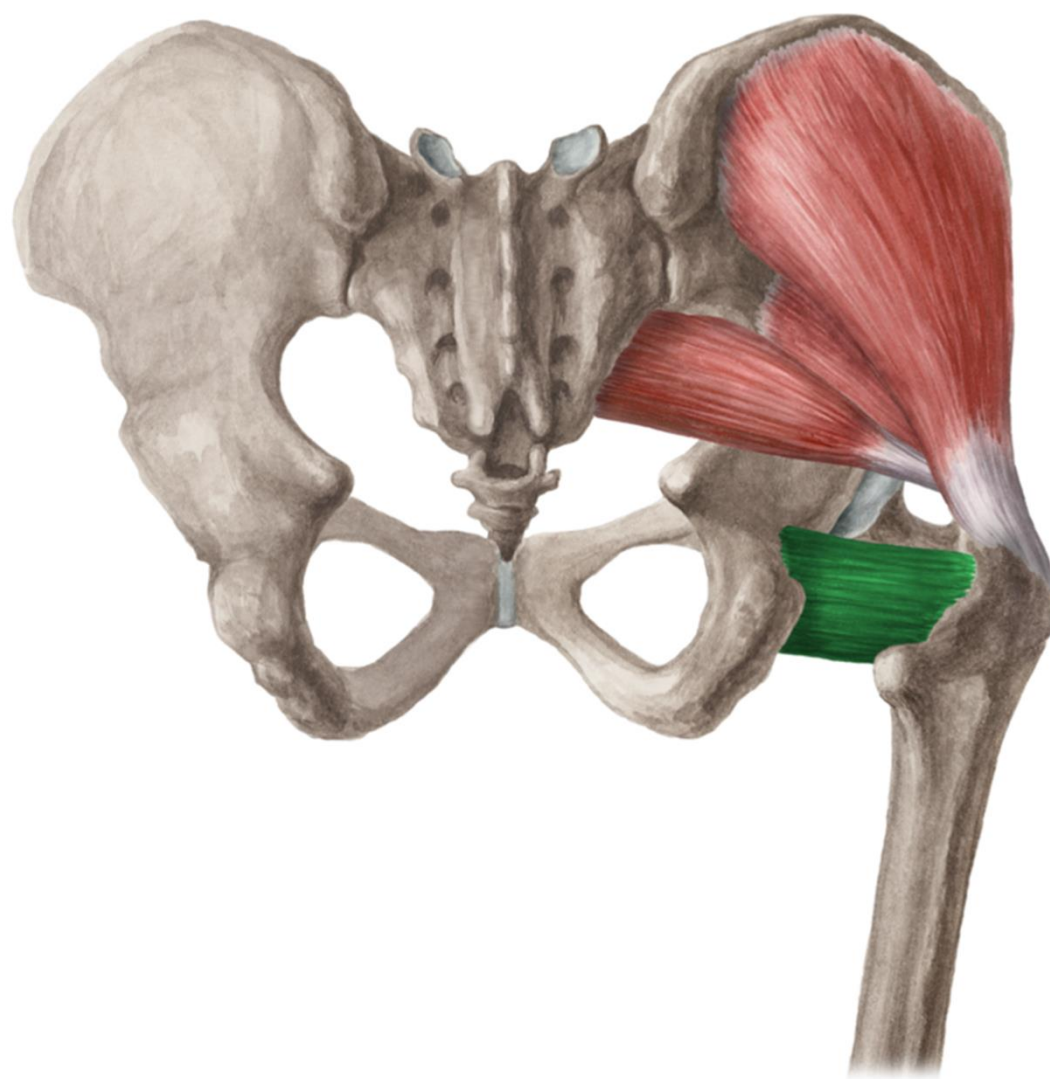
www.kenhub.com
kenHub

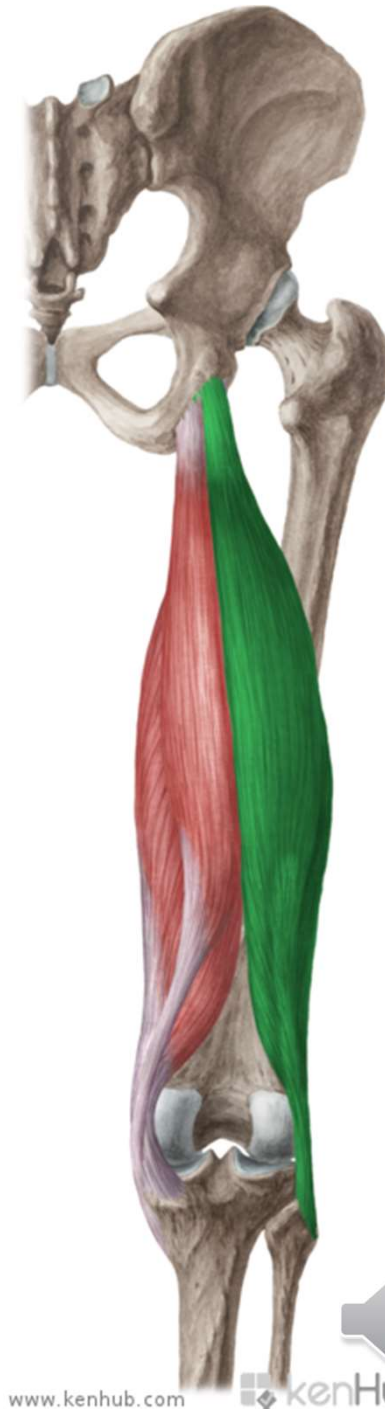
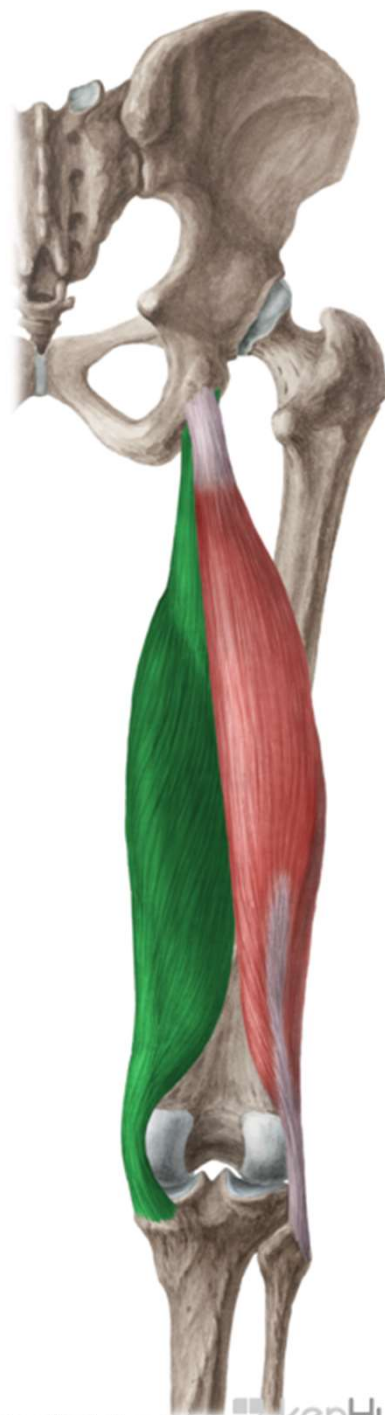
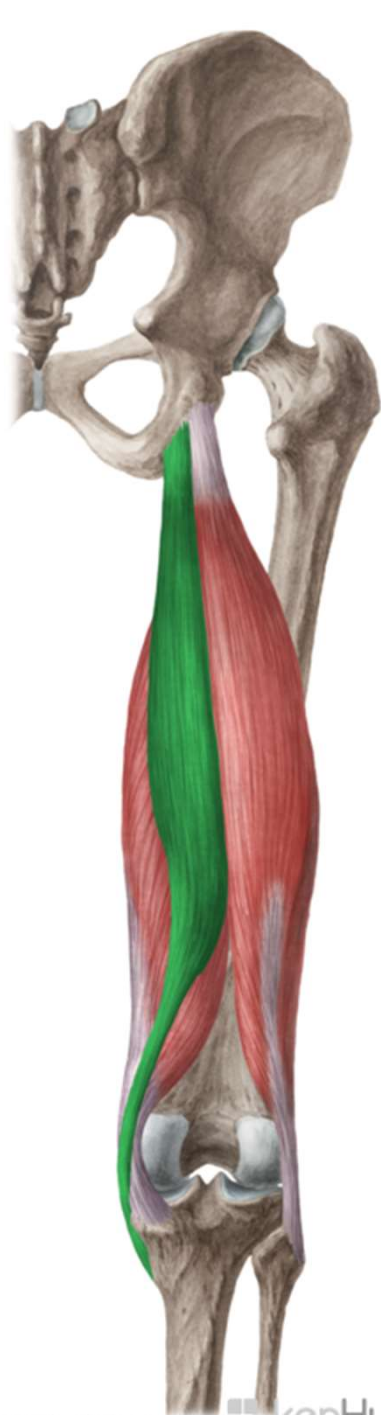


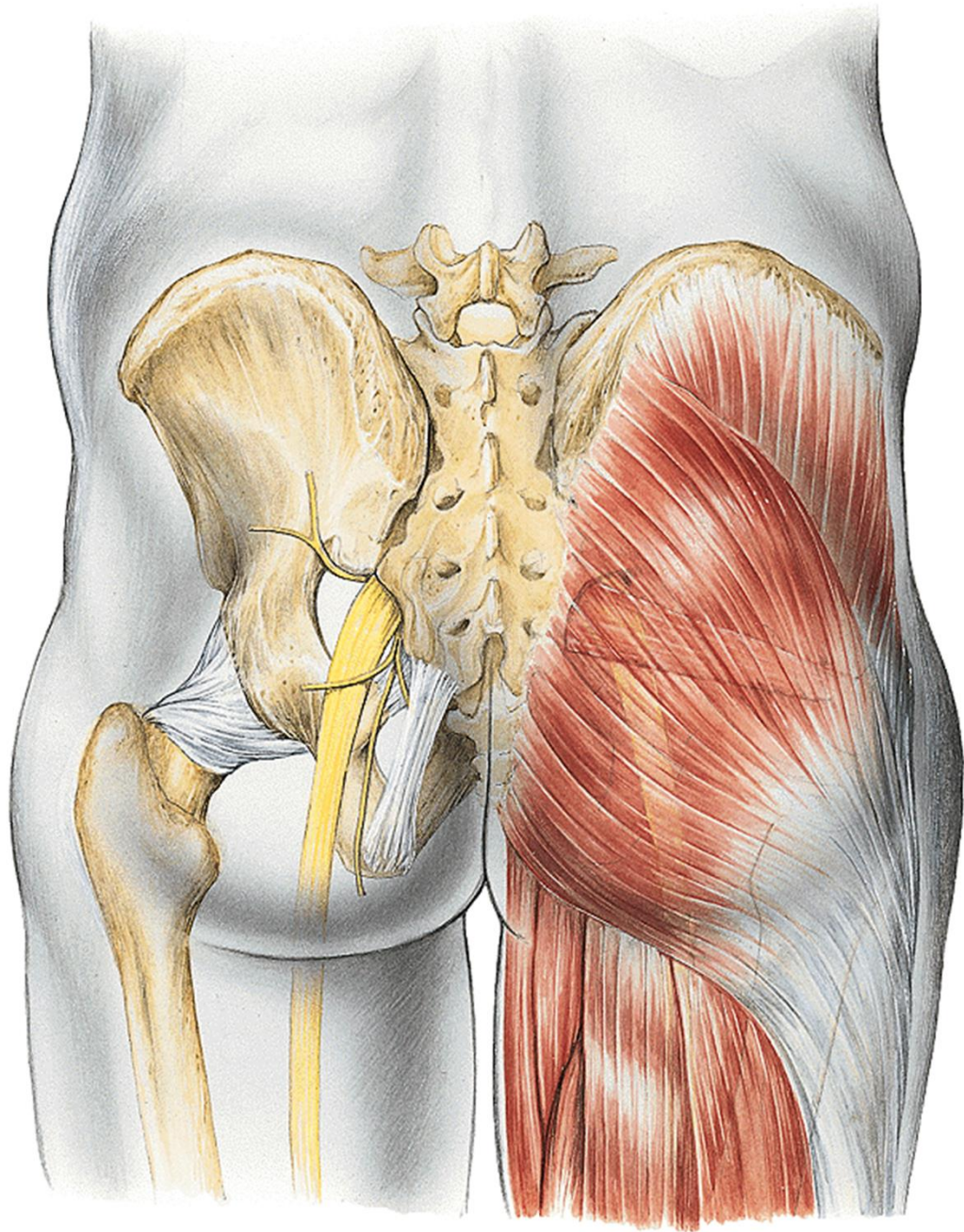
kenHub





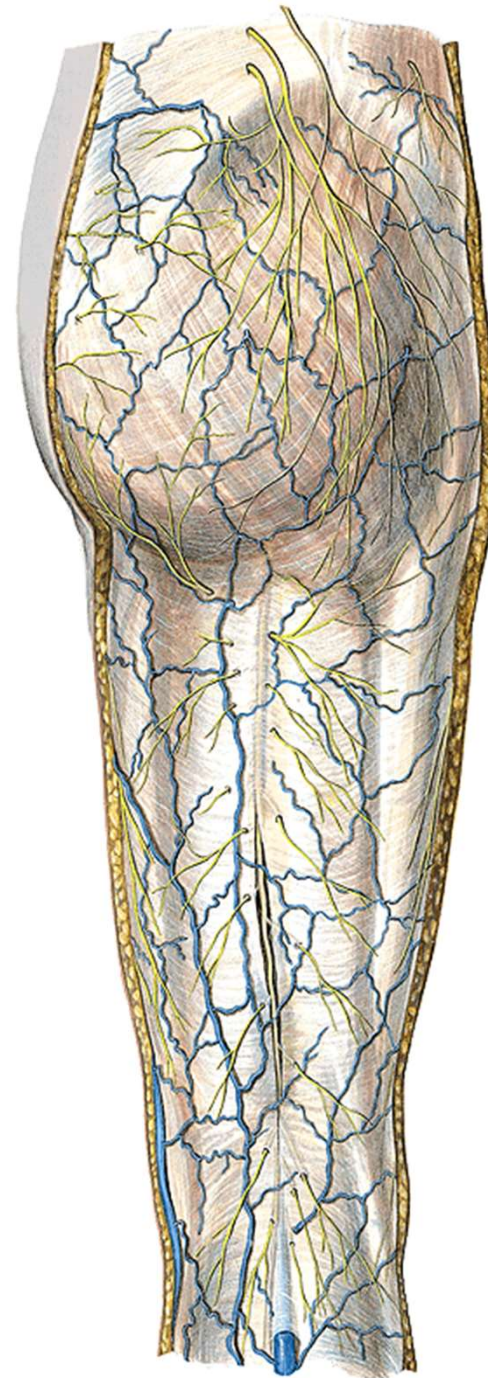


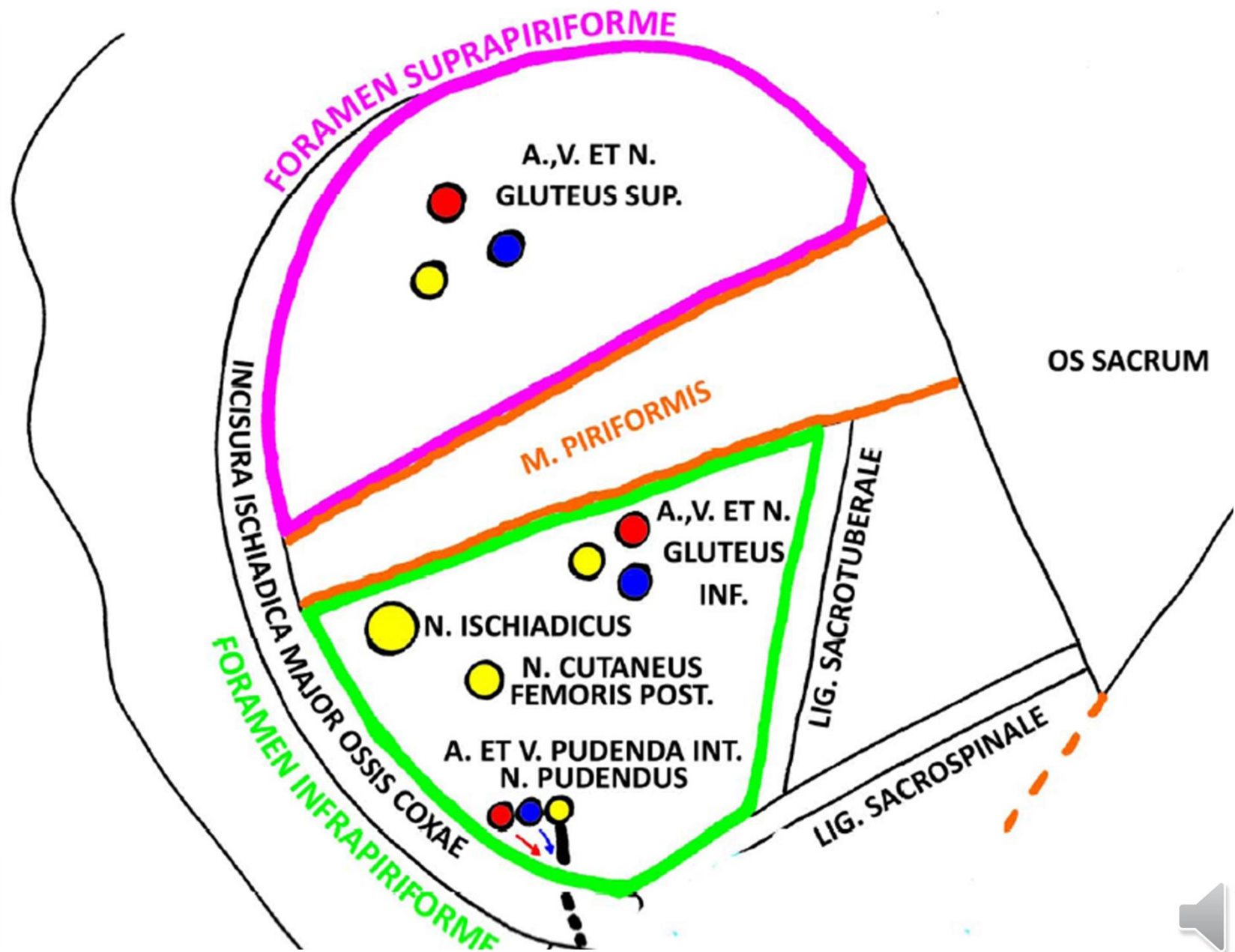


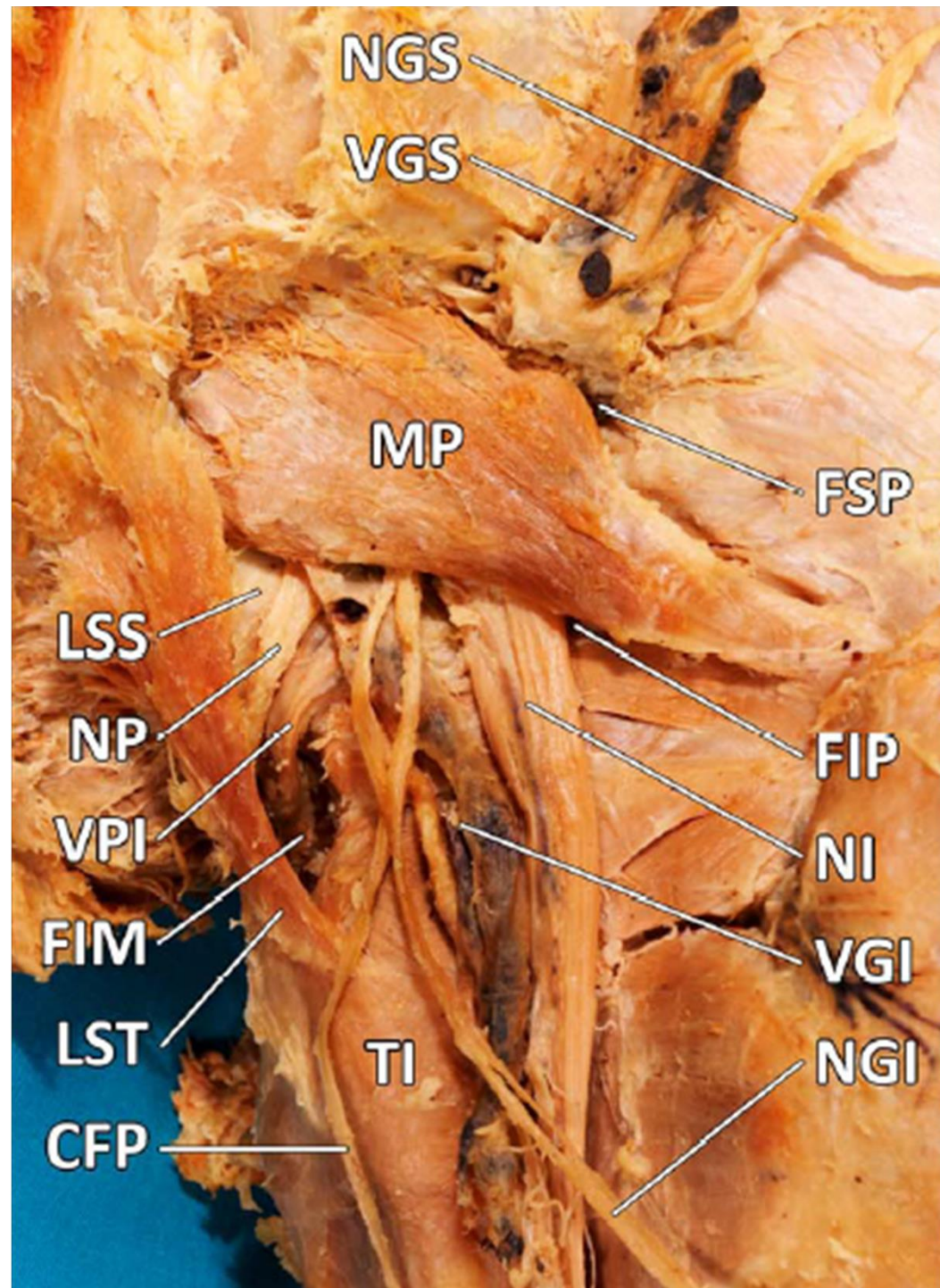


nn. clunium sup.
nn. clunium medii } rr. dors. nn. spinalium
nn. clunium inf. (z n. cutaneus fem. post.)

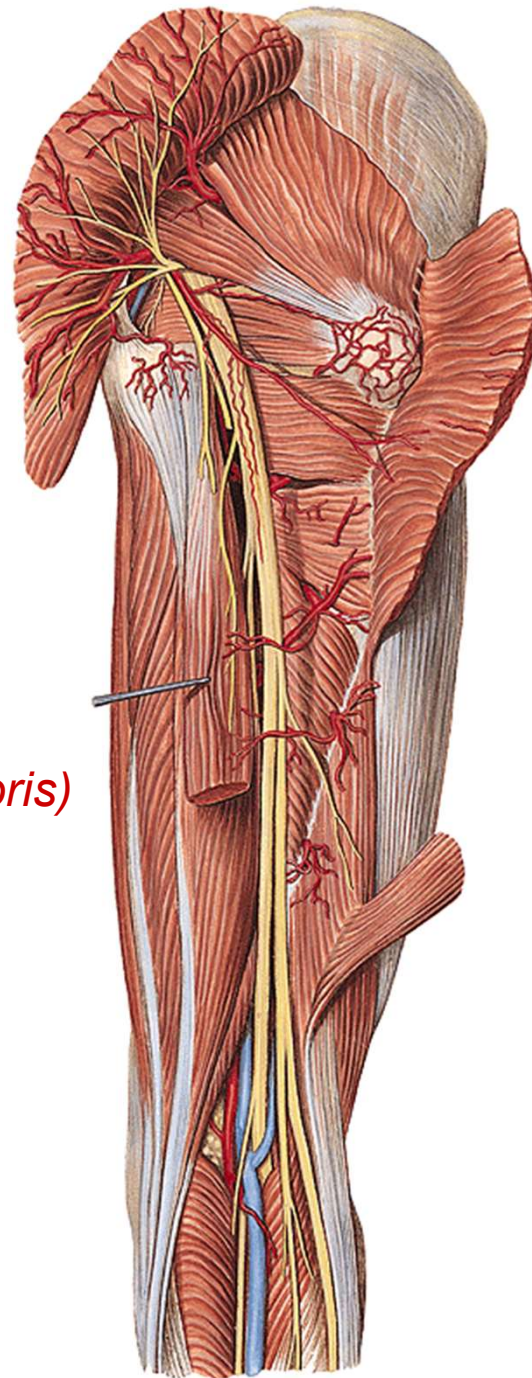
n. cutaneus femoris post.

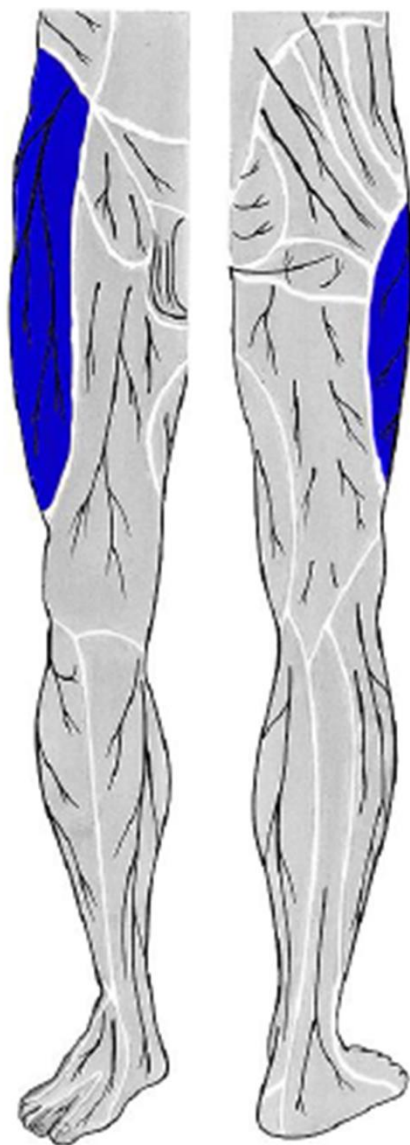




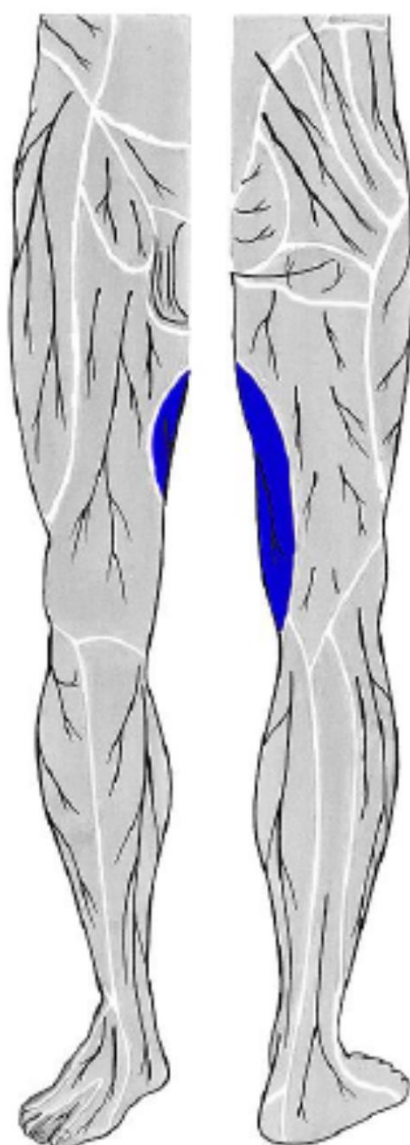


n. ischiadicus
rr. perforantes (from a. prof. femoris)

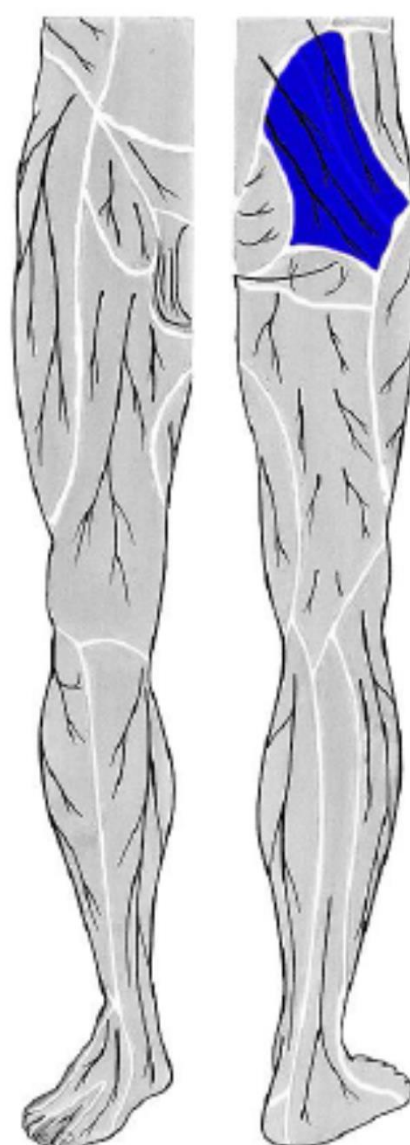




**n. cutaneus femoris
lateralis**

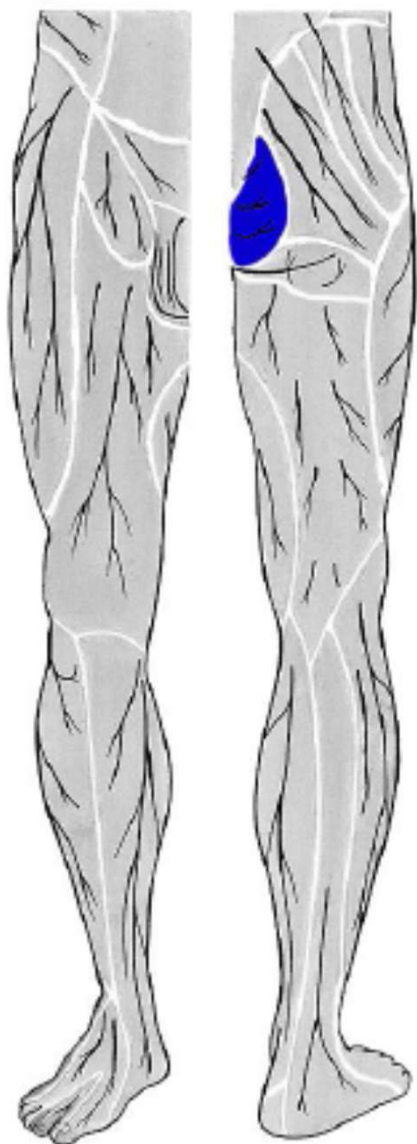


**r.cutaneus n. obturatorii
(z n. obturatorius)**

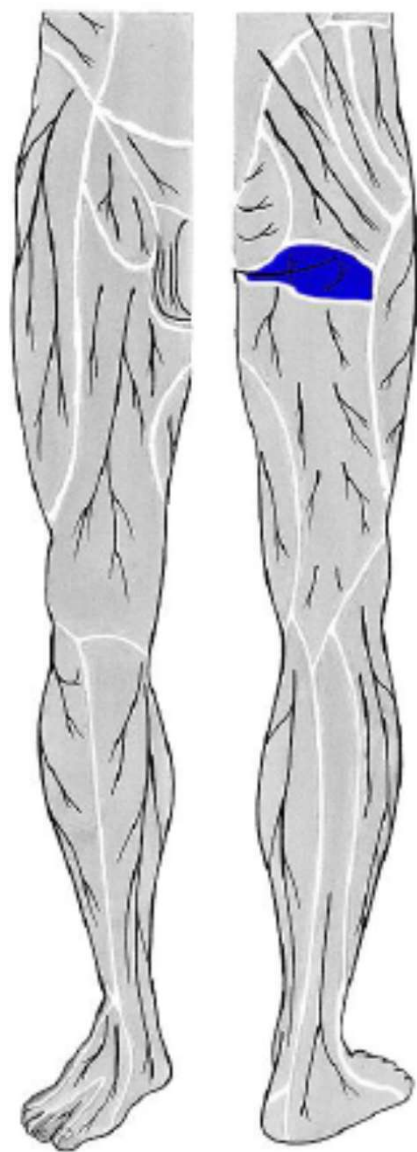


**nn. clunium sup.
(ze segmentů L1 - L3)**

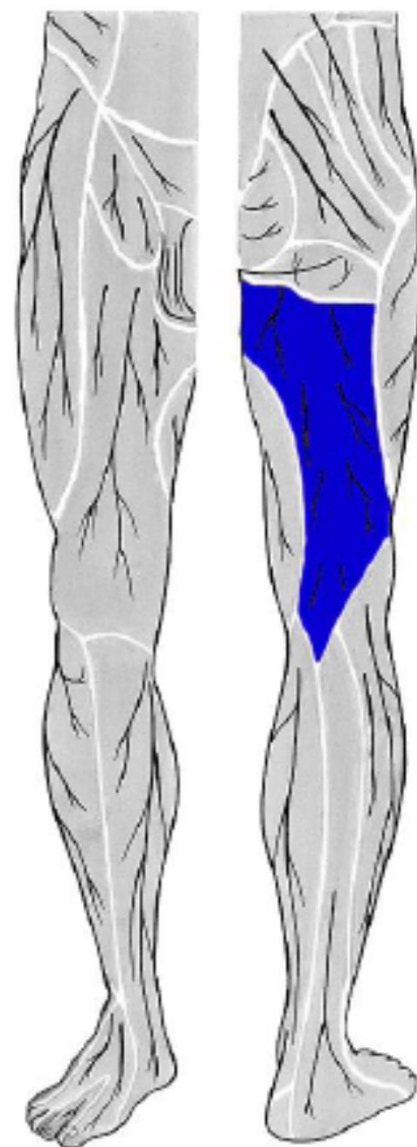




nn. clunium medii
(ze segmentů S1 - S3)



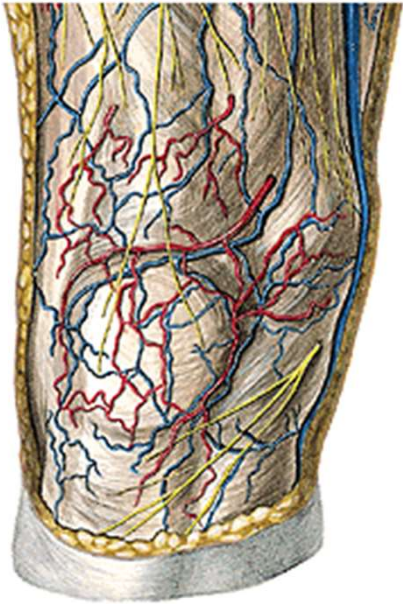
nn. clunium inf.
(z n. cutaneus femoris posterior)



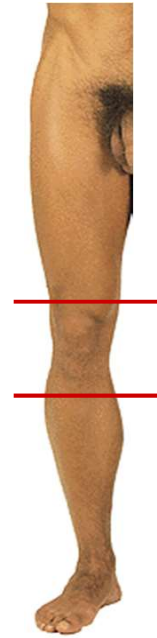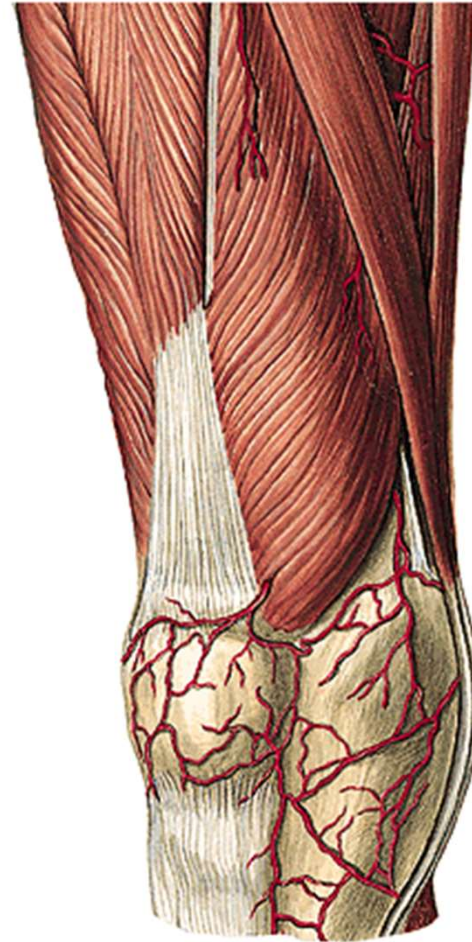n. cutaneus femoris posterior

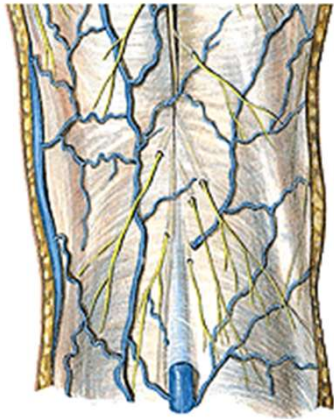

r. genus

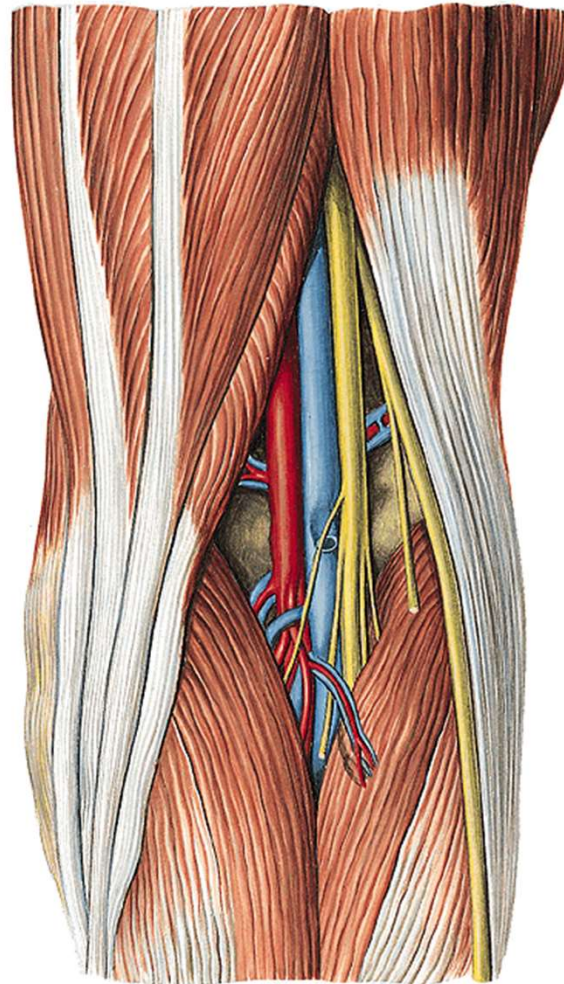


v. saphena magna
n. saphenus
rr. cut. ant. (*from n. femoralis*)



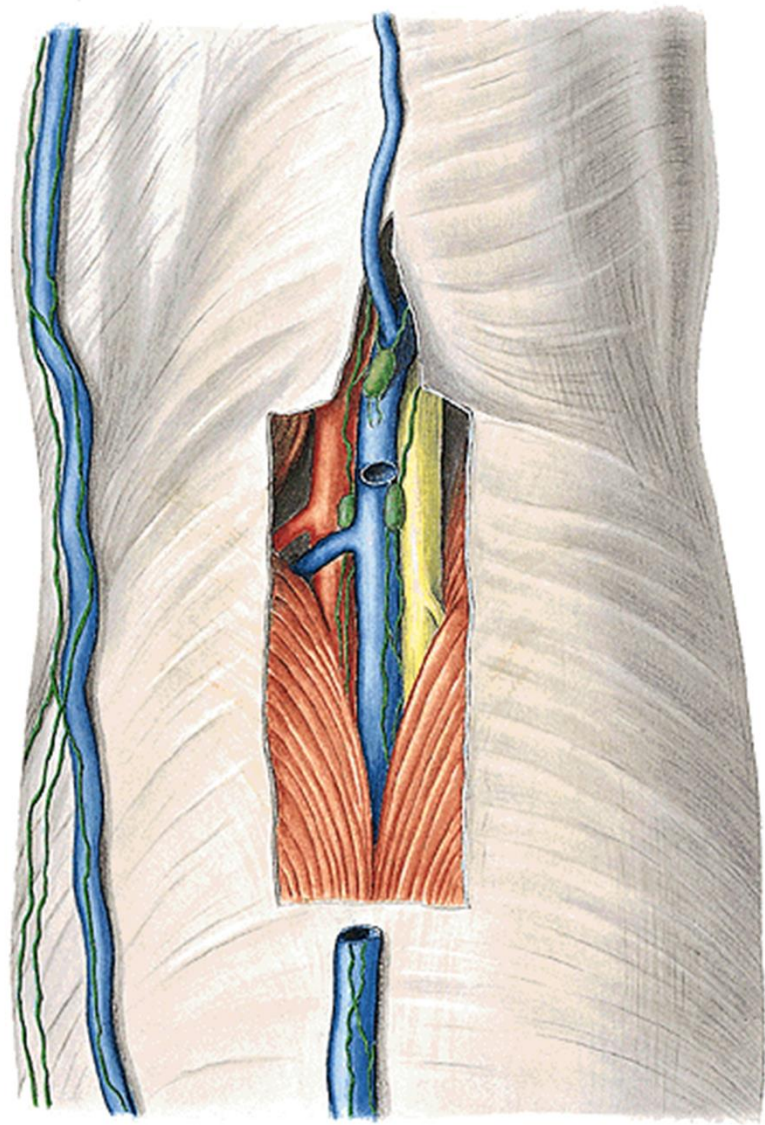


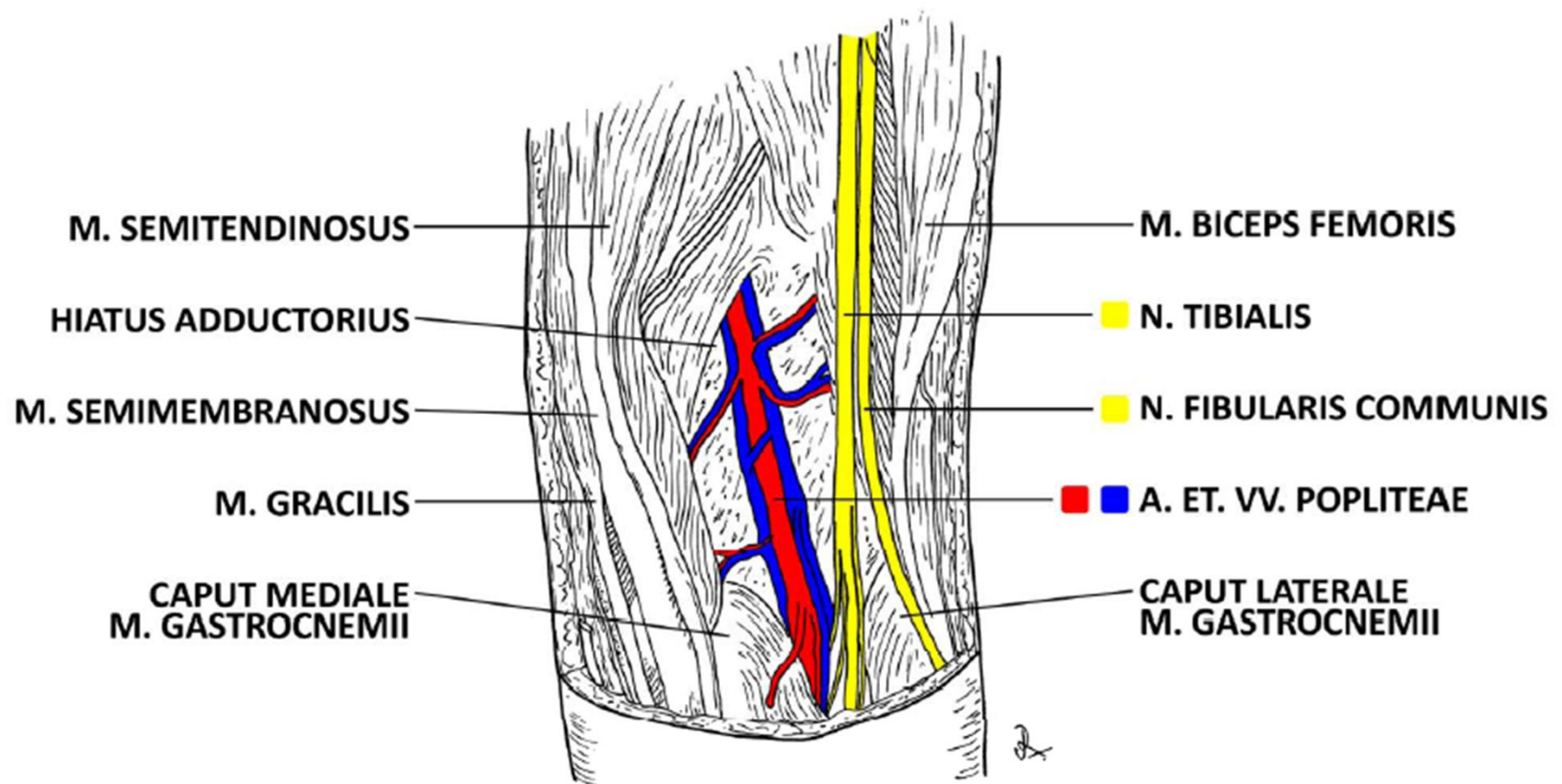
v. saphena parva
(ev. v. femoropoplitea)



n. tibialis
n. peroneus comm.
a et v. poplitea
nll. poplitei

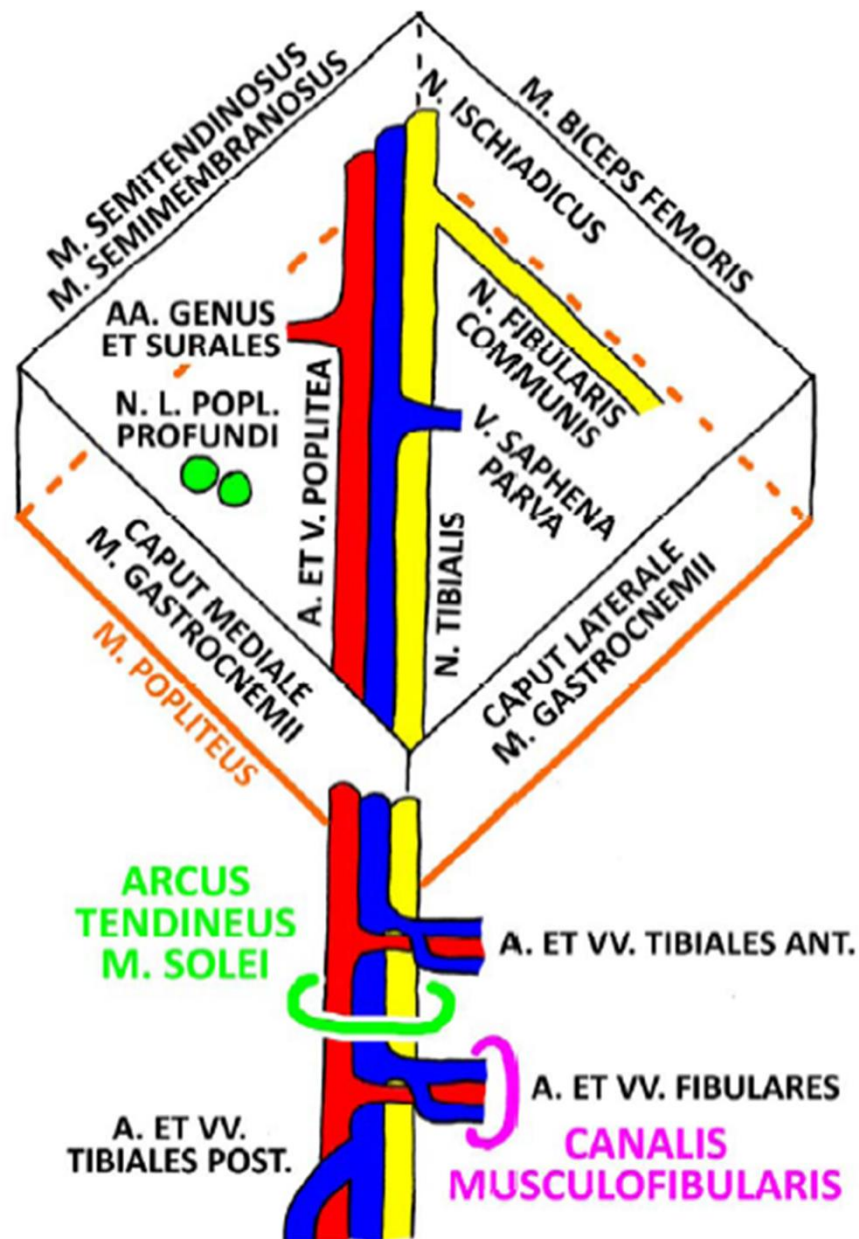


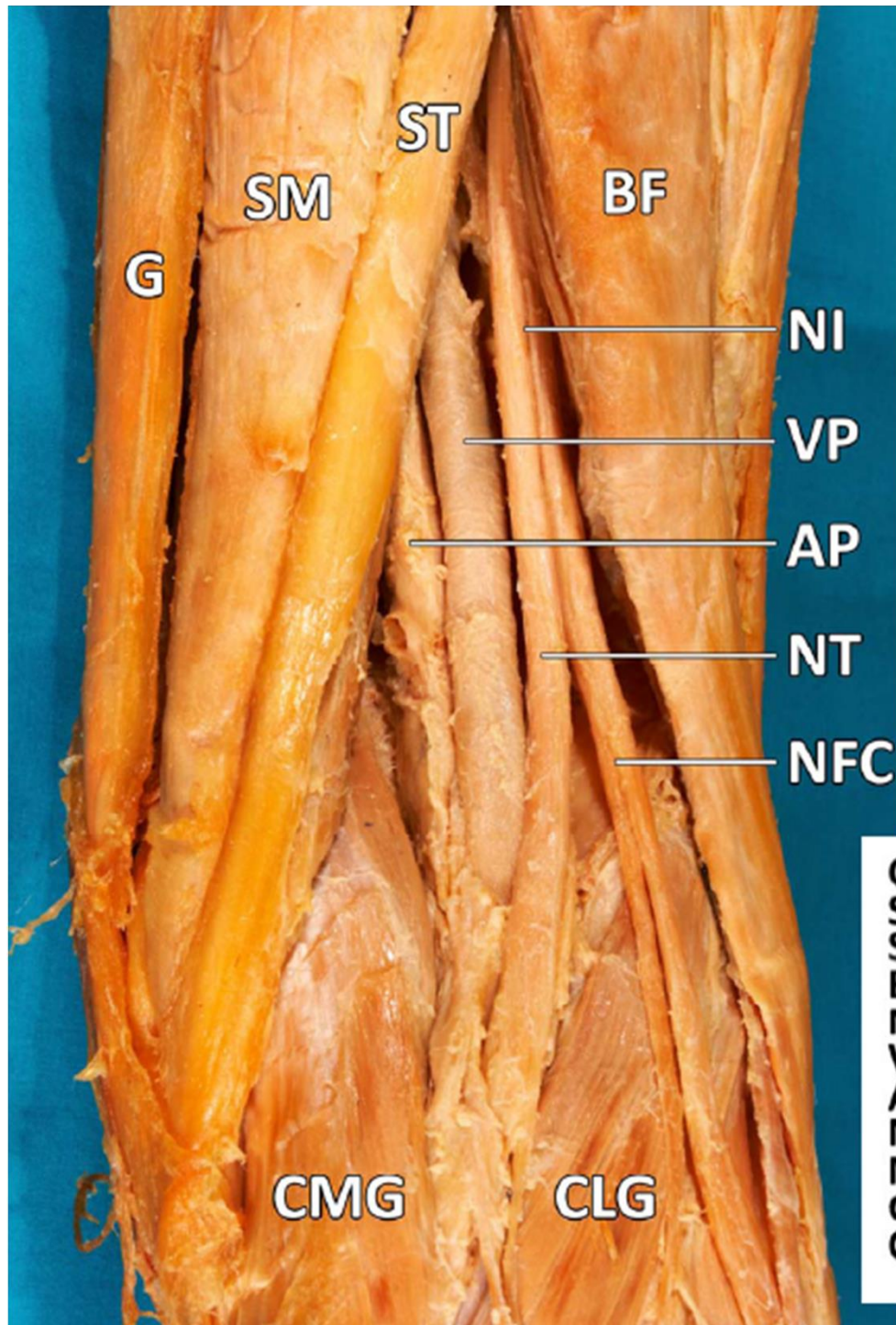




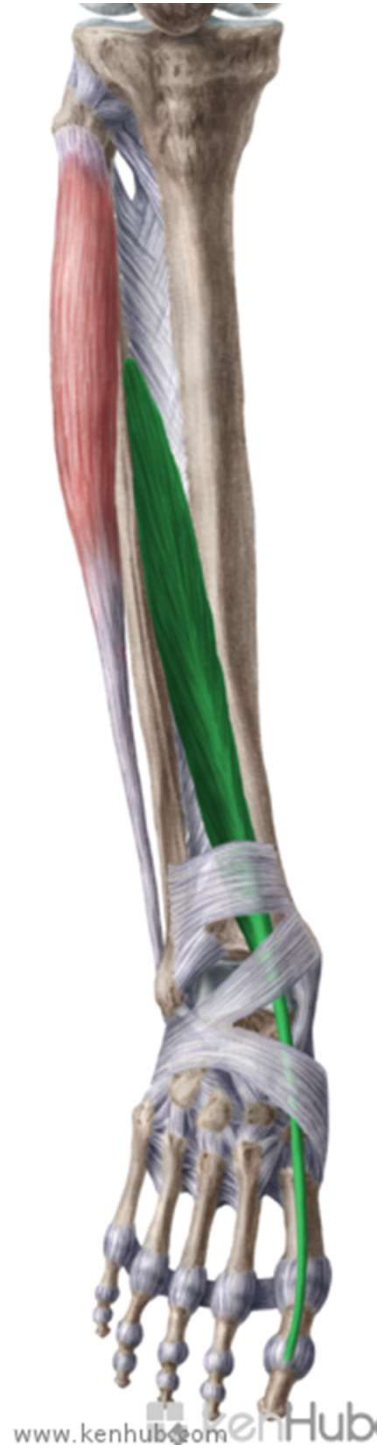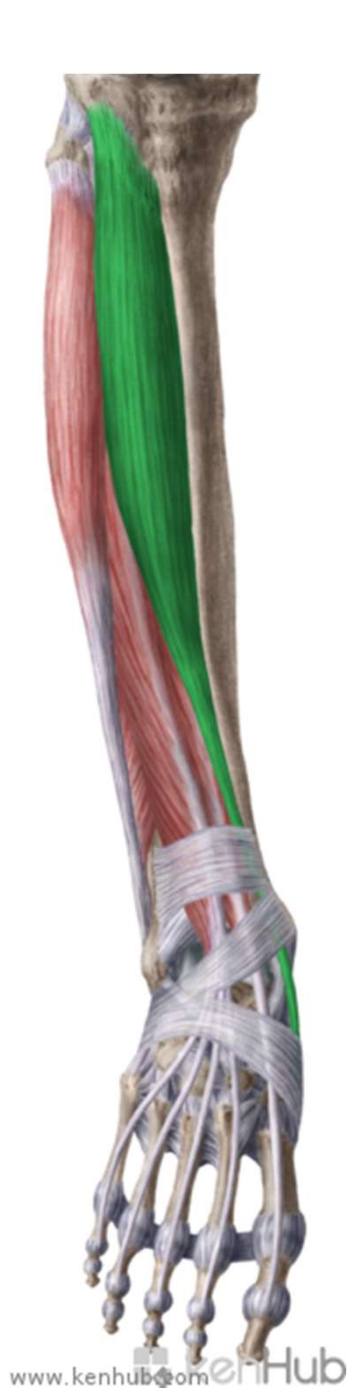FOSSA POPLITEA DX.

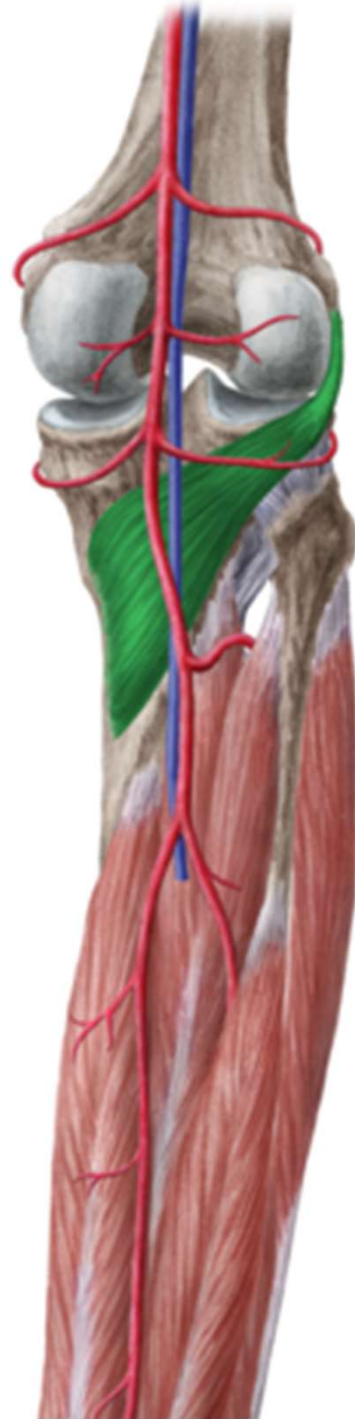
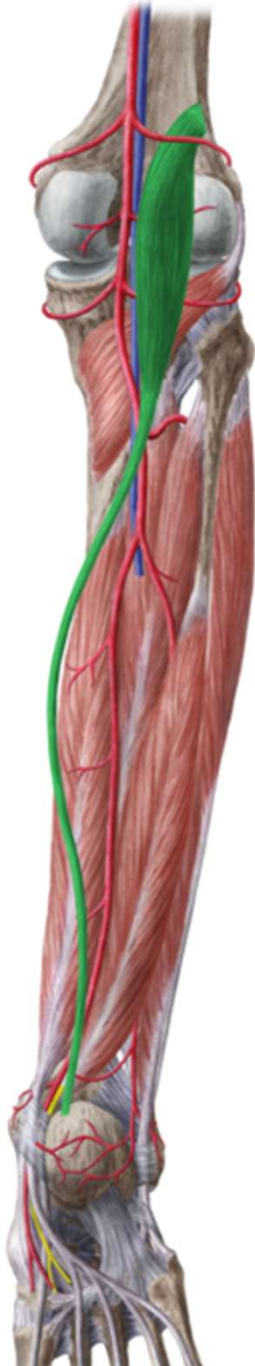
A V E N

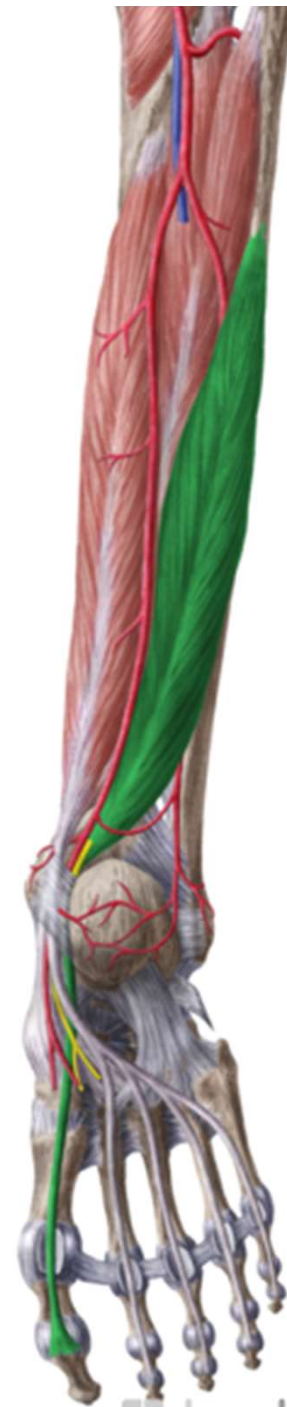
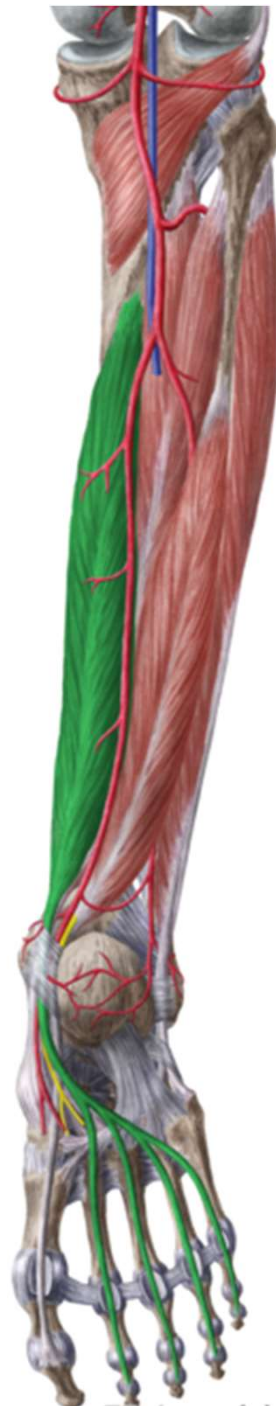


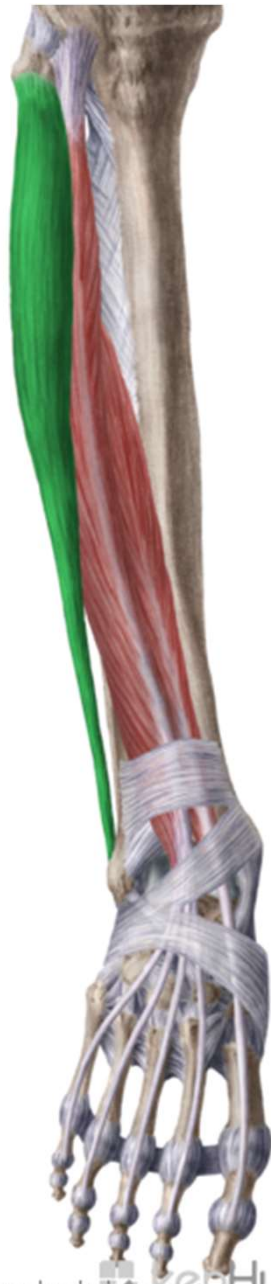r. cruris

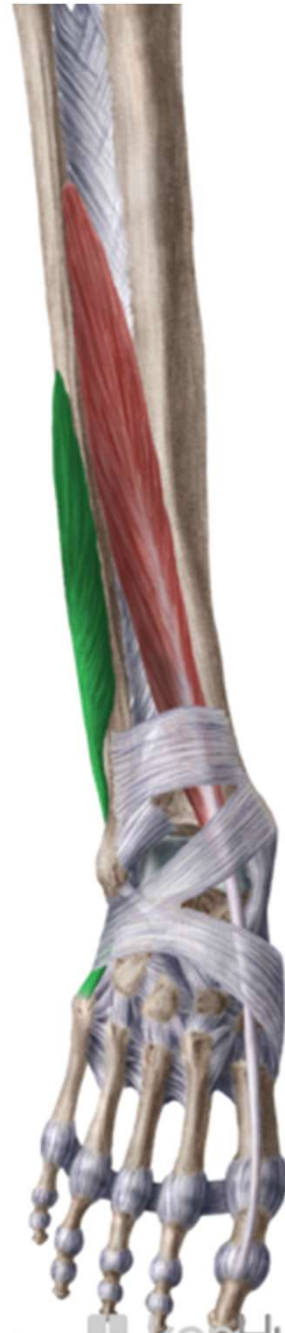







www.kenhub.com 

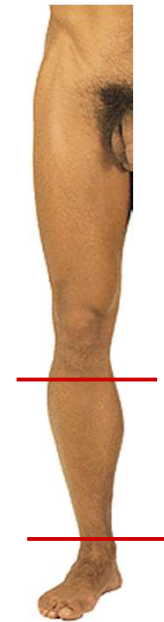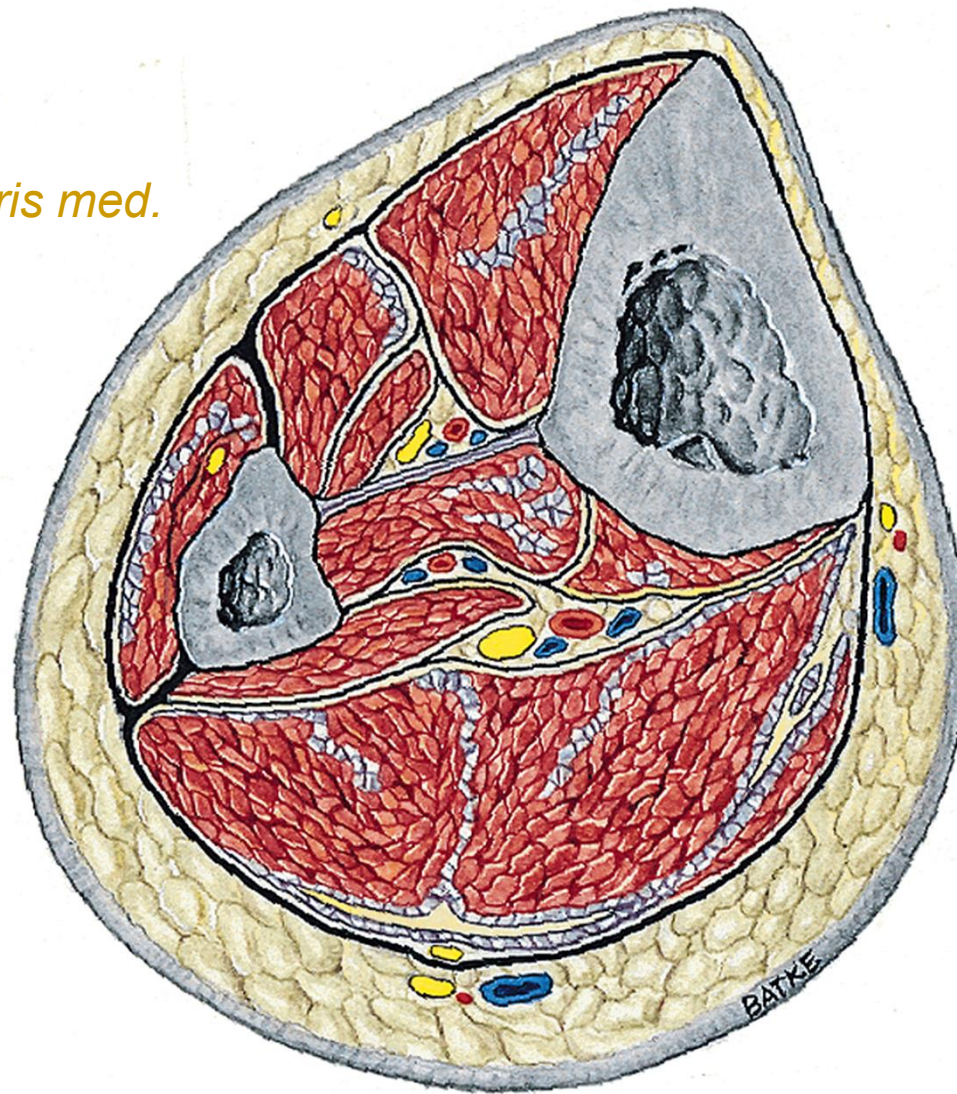


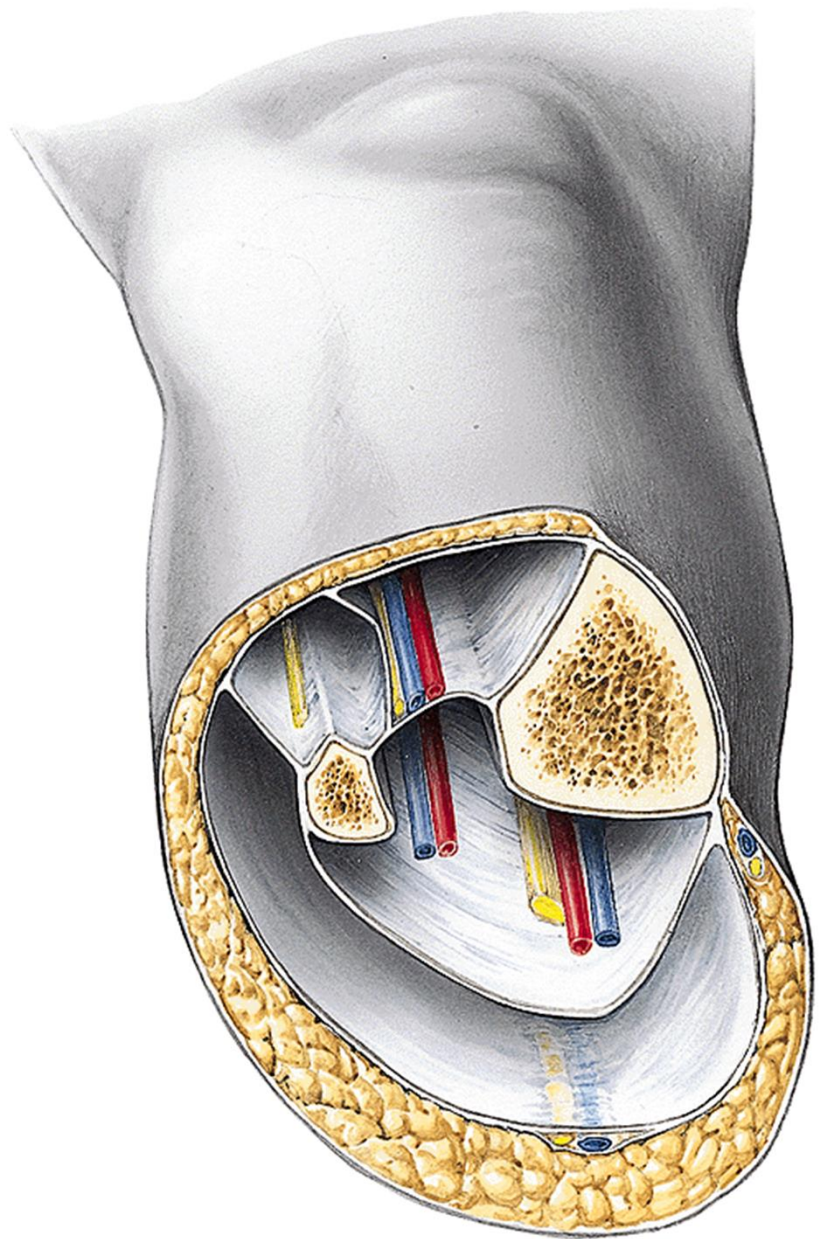
www.kenhub.com 



v. saphena magna
n. saphenus → *rr. cut. cruris med.*
v. saphena parva
n. suralis
n. cut. surae lat.
n. cut. surae med.

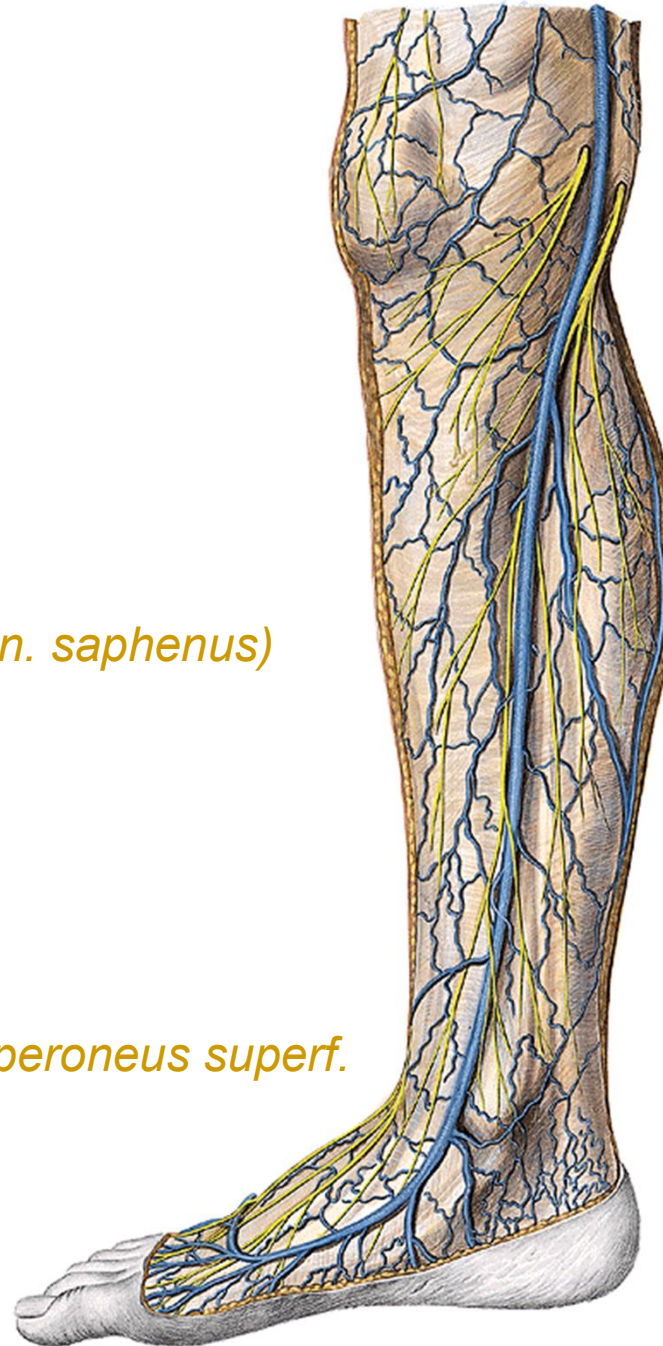n. peroneus superf.
n. peroneus prof.
a. et v. tibialis ant.
n. tibialis
a. et v. tibialis post.



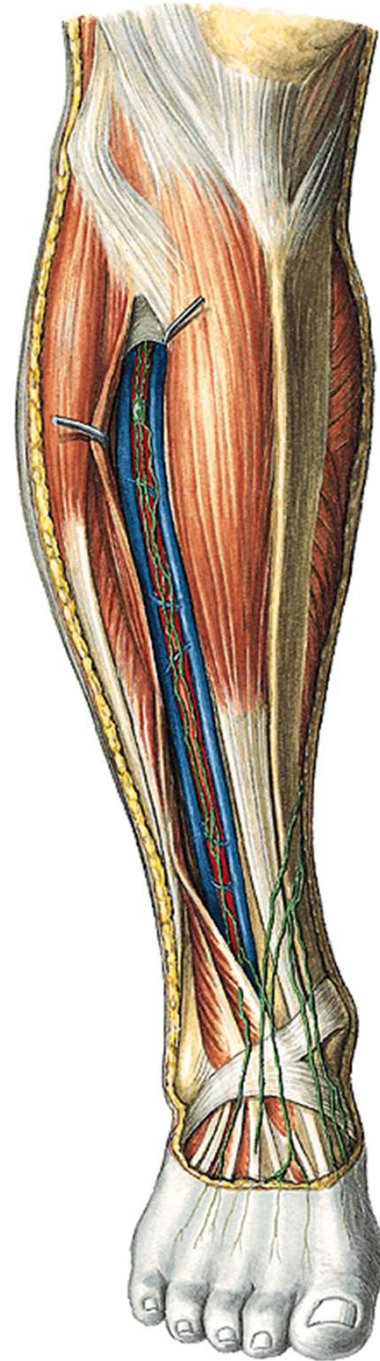


v. saphena magna
rr. cut. cruris med (z n. saphenus)

n. peroneus superf.



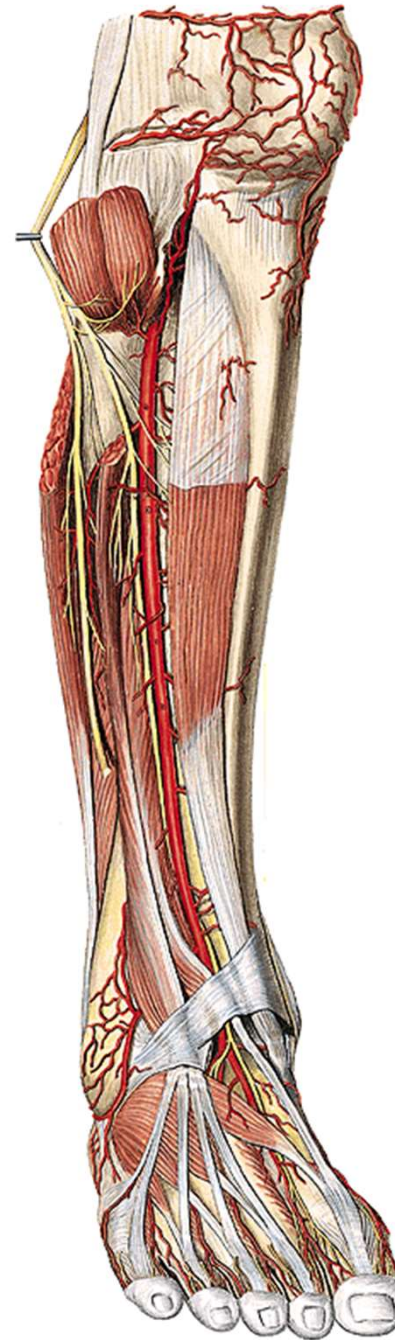
n. peroneus prof.
a. et v. tibialis ant.



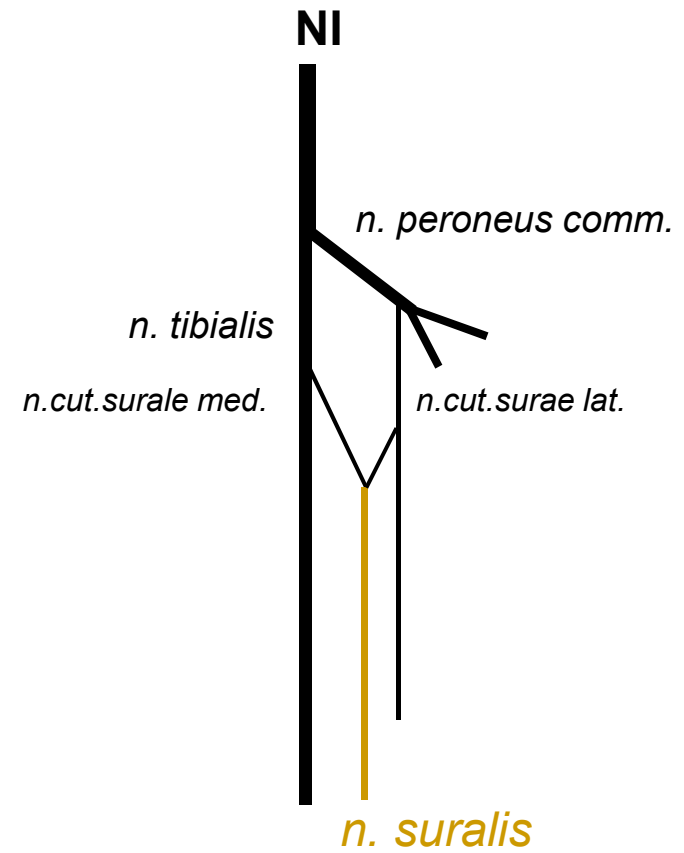
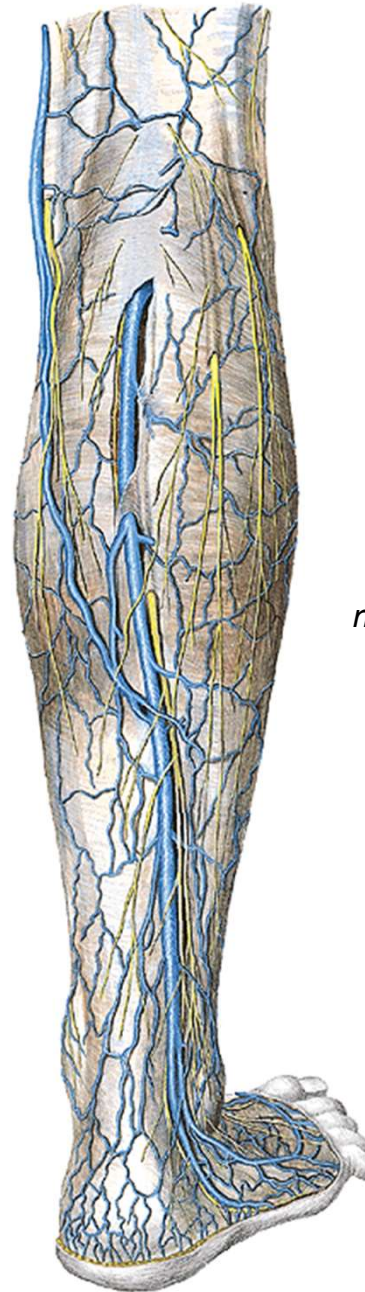n. peroneus comm.:

n. peroneus prof.

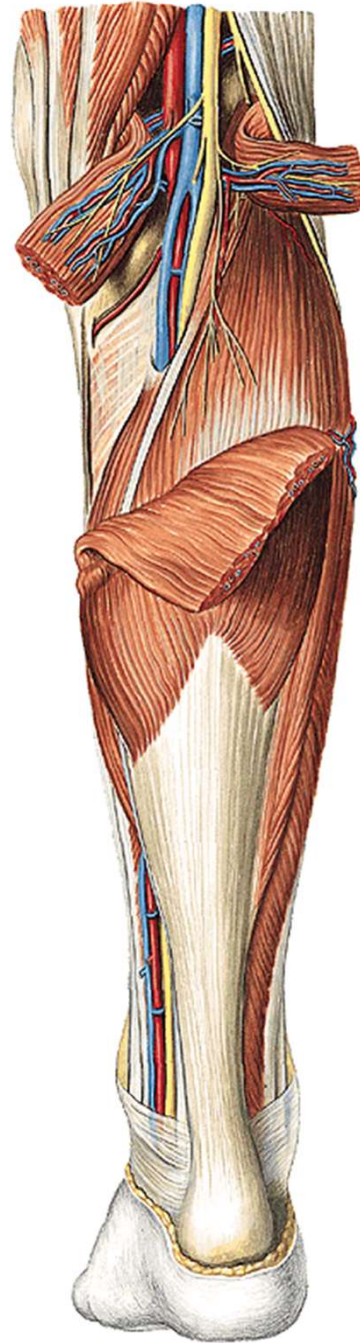
n. peroneus superf.

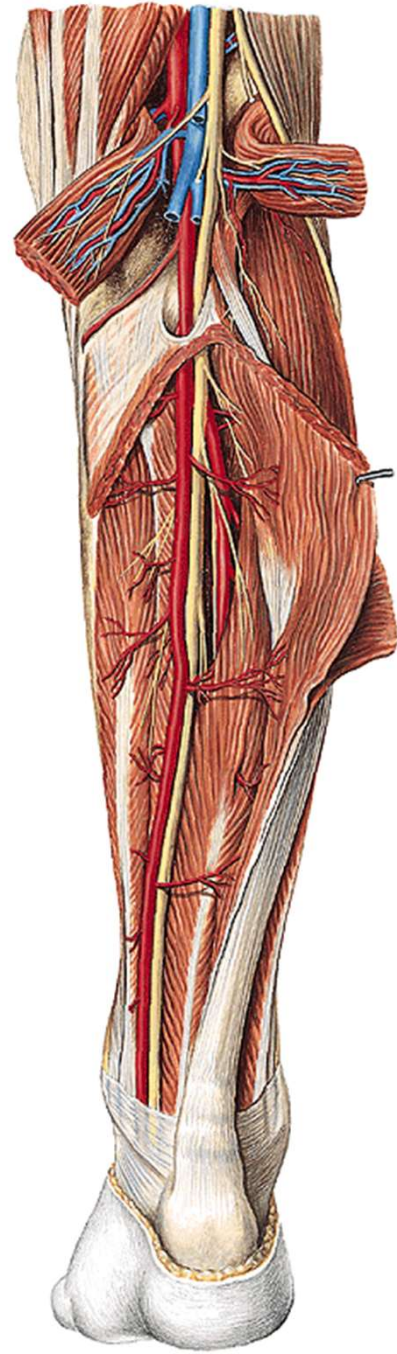


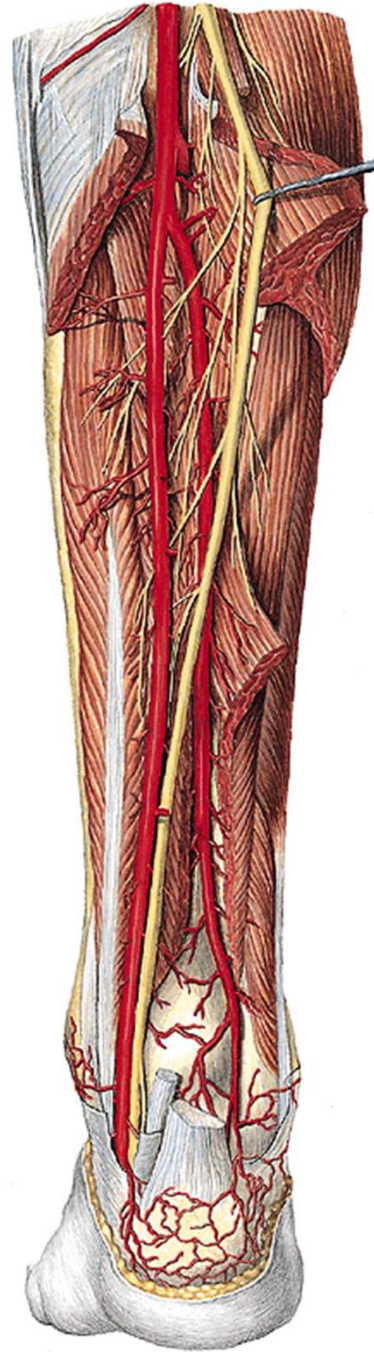v. saphena parva
n. cutaneus surae med.
+ *n. cutaneus surae lat.* =
n. suralis

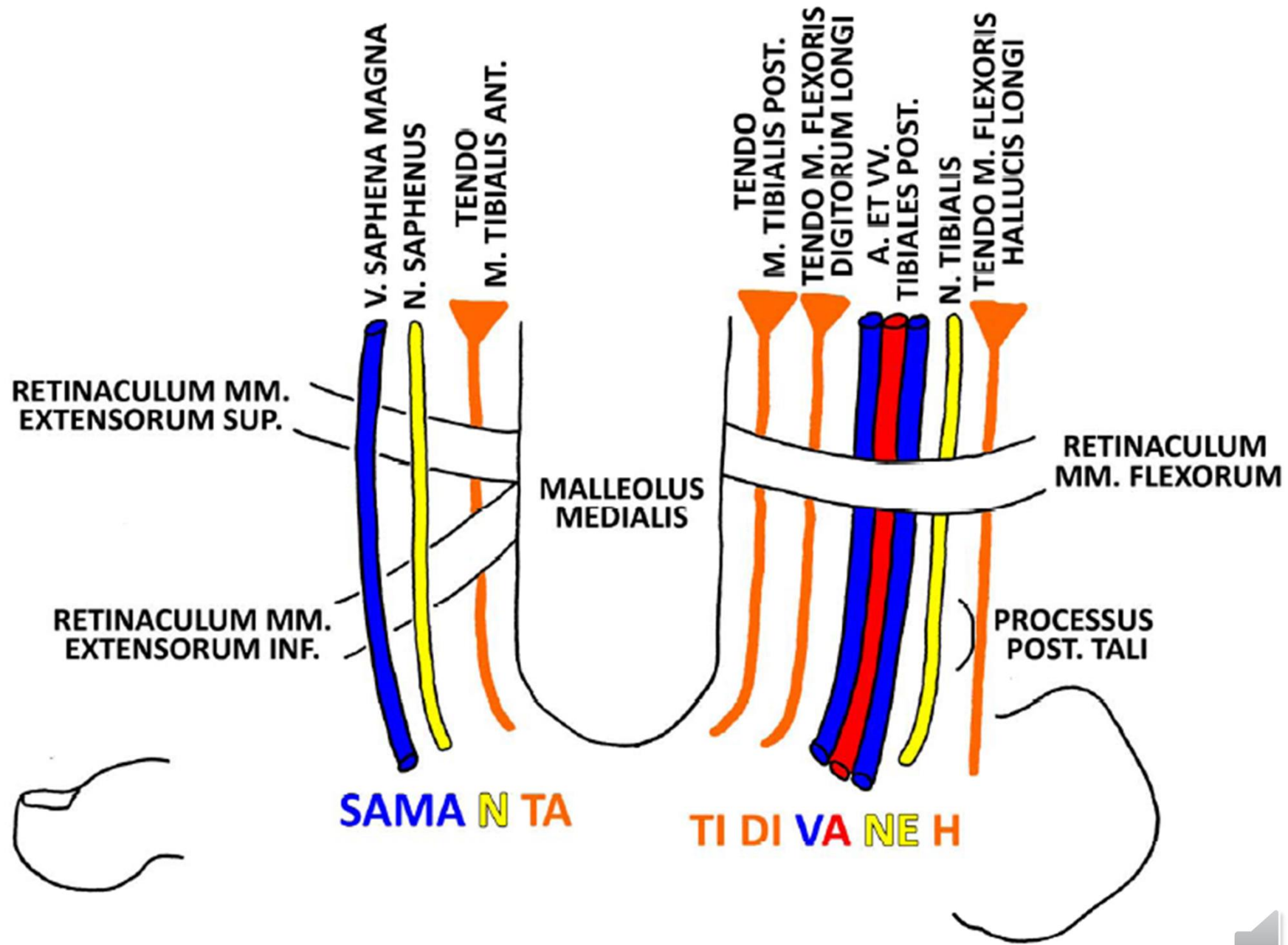


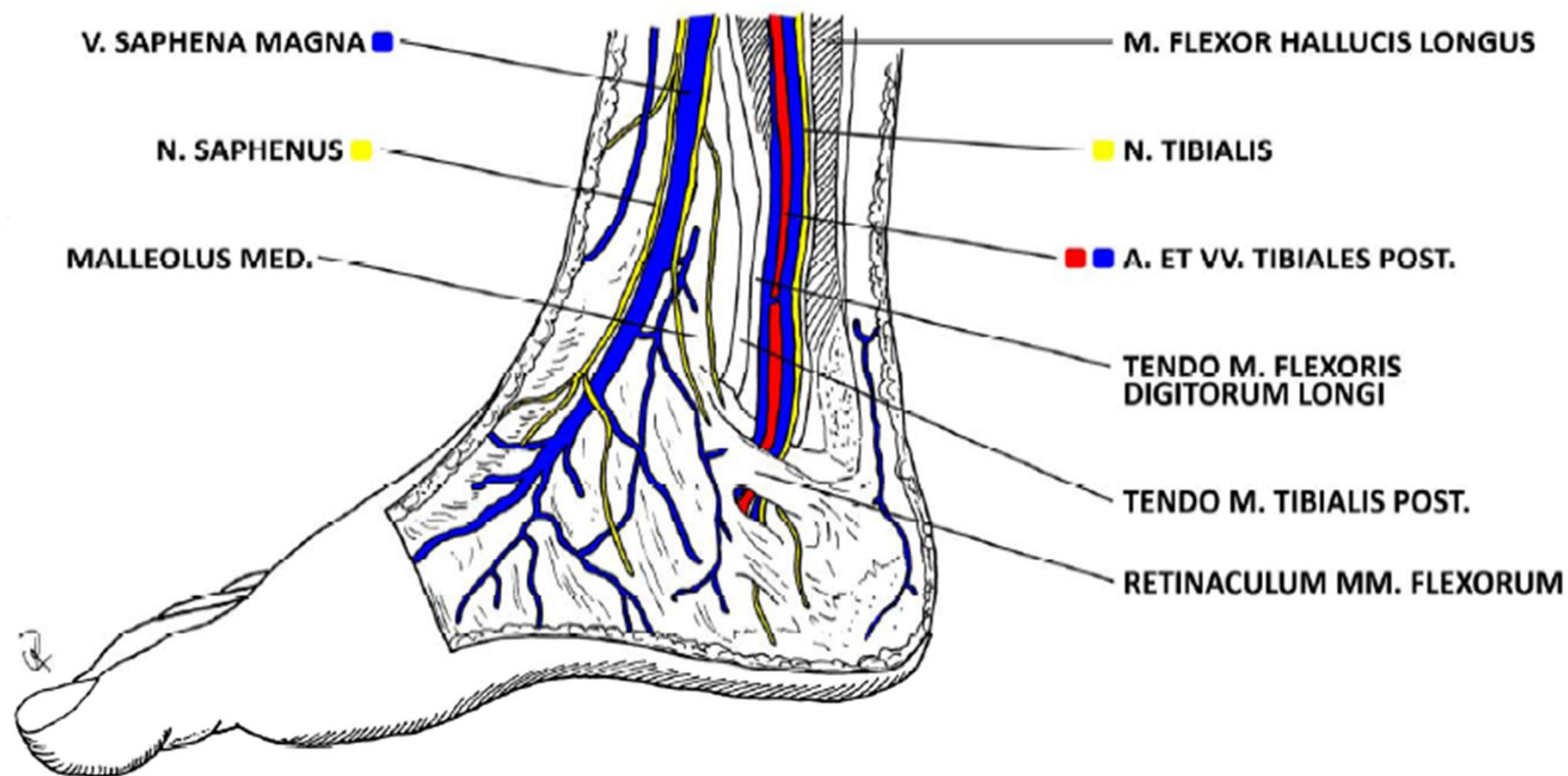
n. tibialis
a. et v. tibialis post.



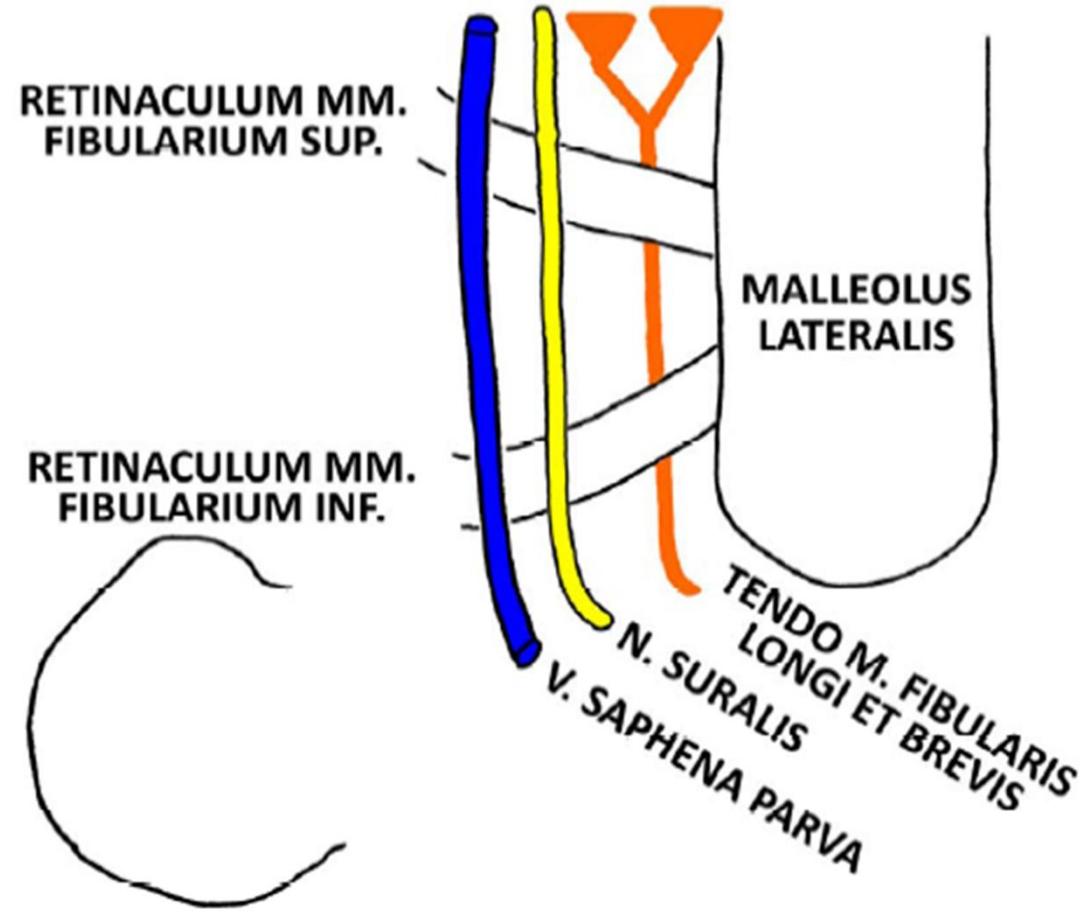


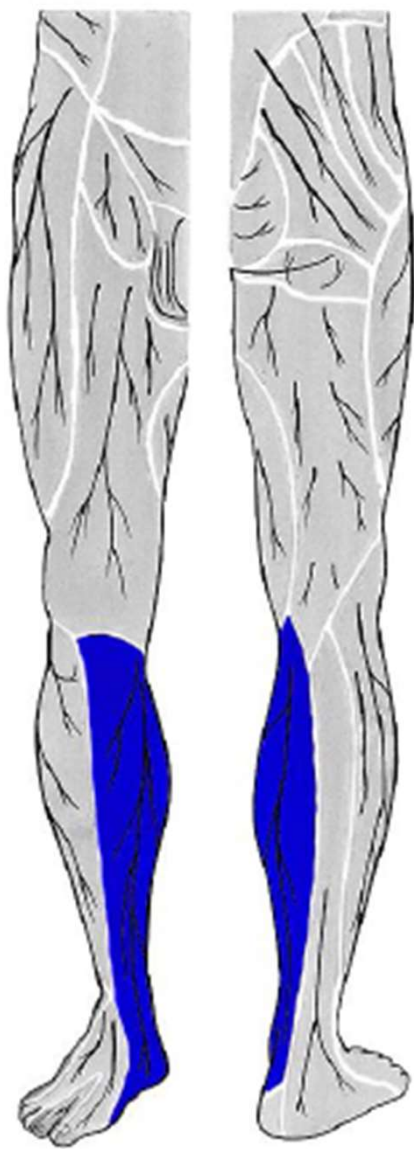




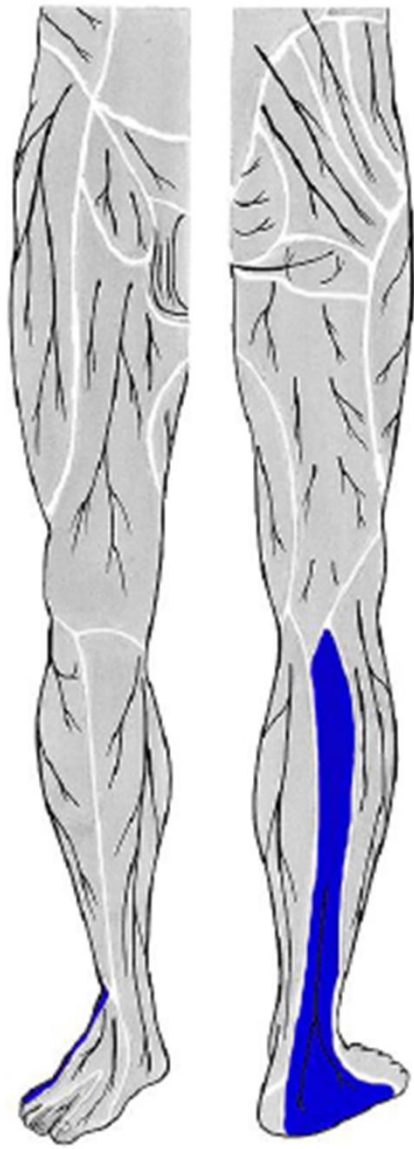


SAPA SU FI

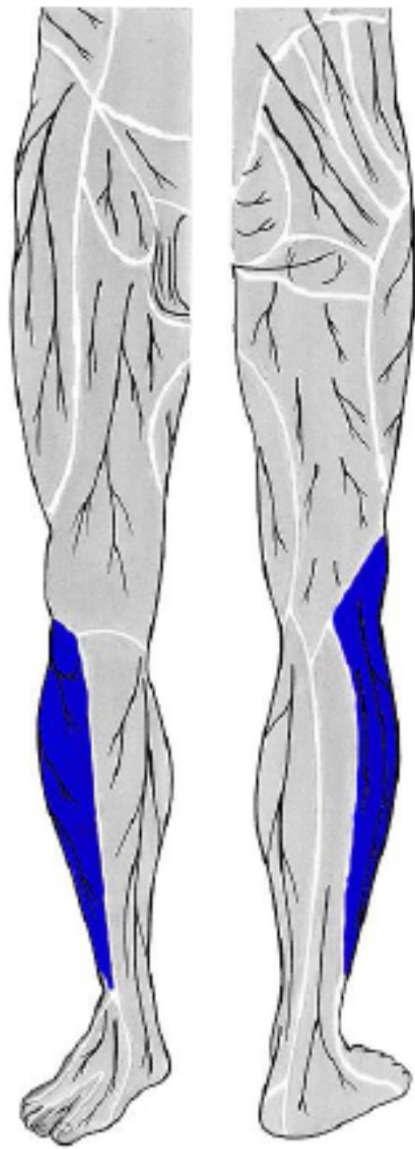




n. saphenus
(z *n. femoralis*)



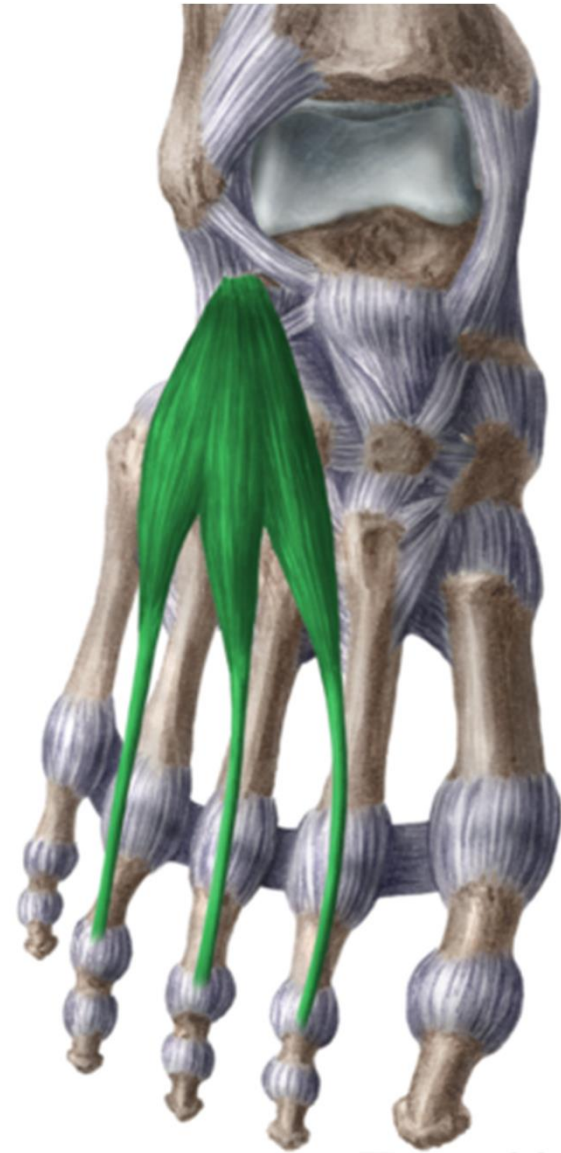
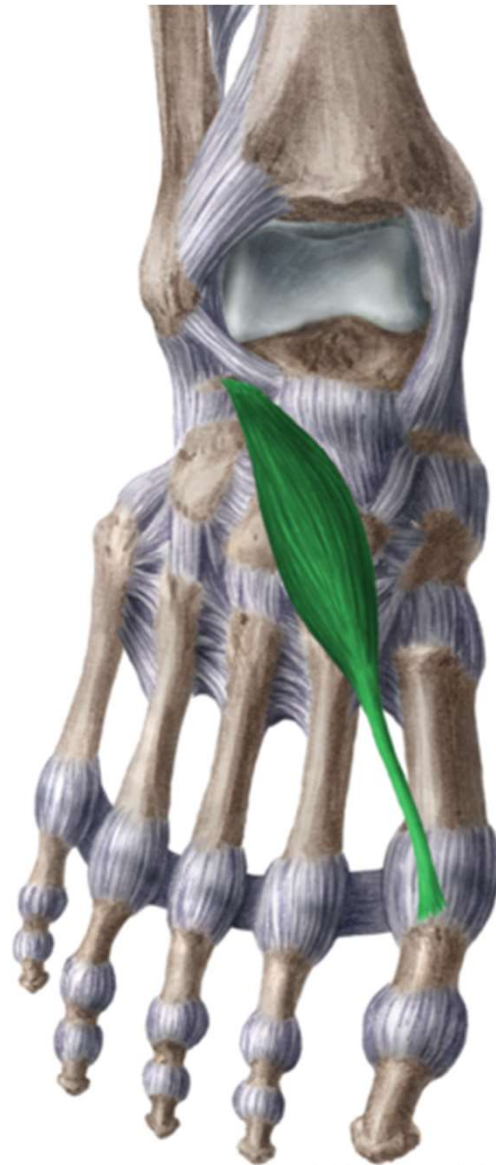n. suralis
(z *n. fibularis communis*
a *n. tibialis*)

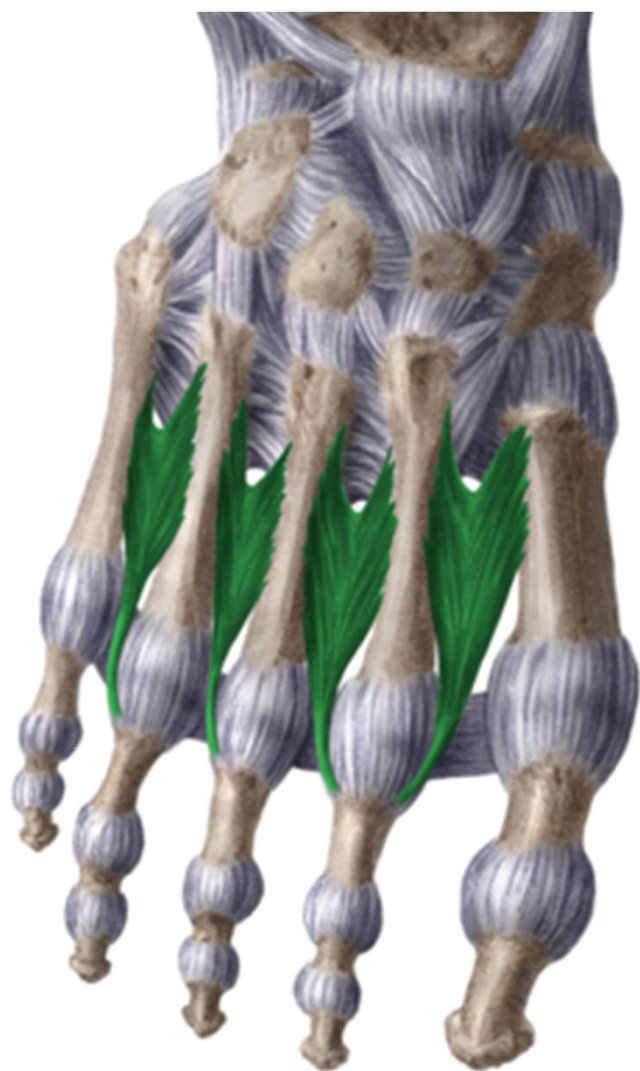

n. cutaneus surae lat.
(z *n. fibularis communis*)



dorsum pedis





www.kenhub.com

 kenHub



dorsum pedis

rete venosum dorsale pedis

n. cut. dorsalis med.
n. cut. dors. intermed. } from *n. peroneus superf.*

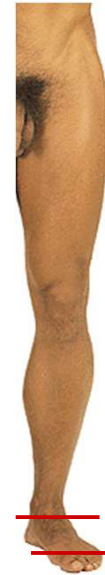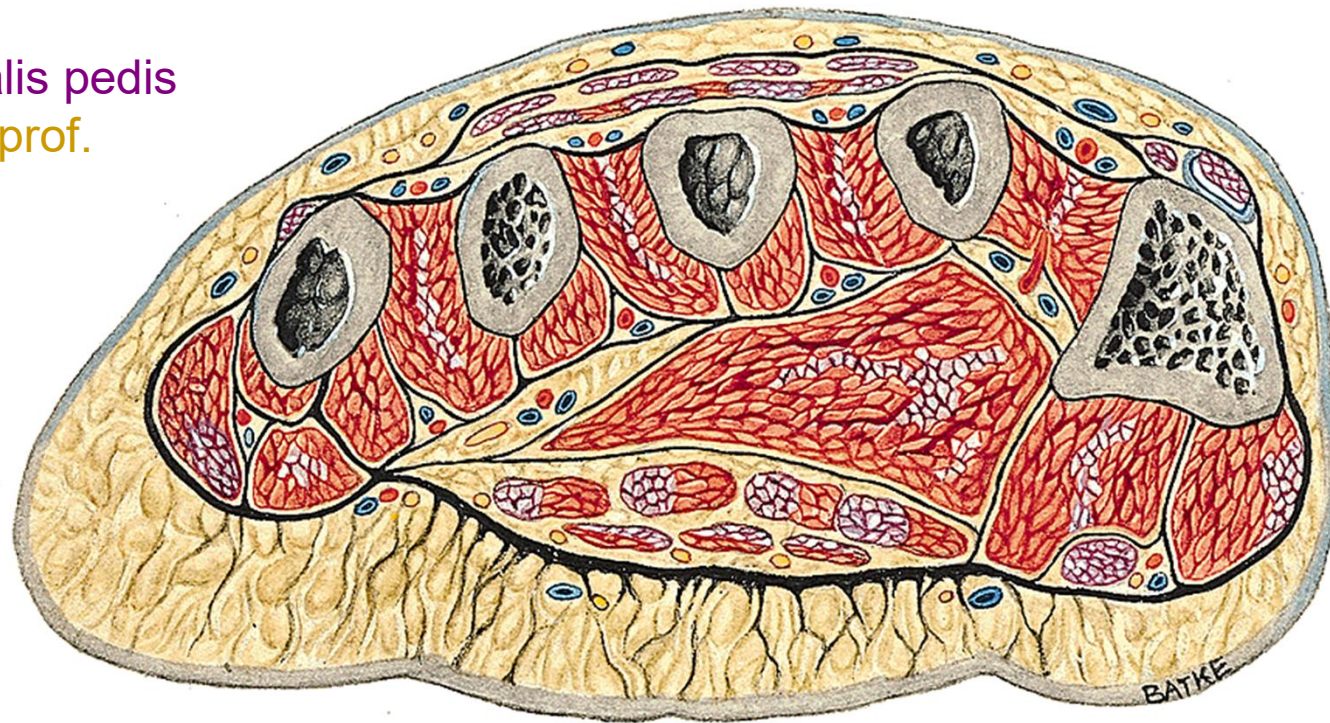n. cut. dors. lat. (from *n. suralis*)

nn. dig. dors. (from *n. peroneus prof.*)

fascia dorsalis – retinaculum extensorum

a. et v. dorsalis pedis

n. peroneus prof.



Left extremity, transsection through
foot, from distal view



rete venosum dorsale pedis

v. saphena magna

v. saphena parva

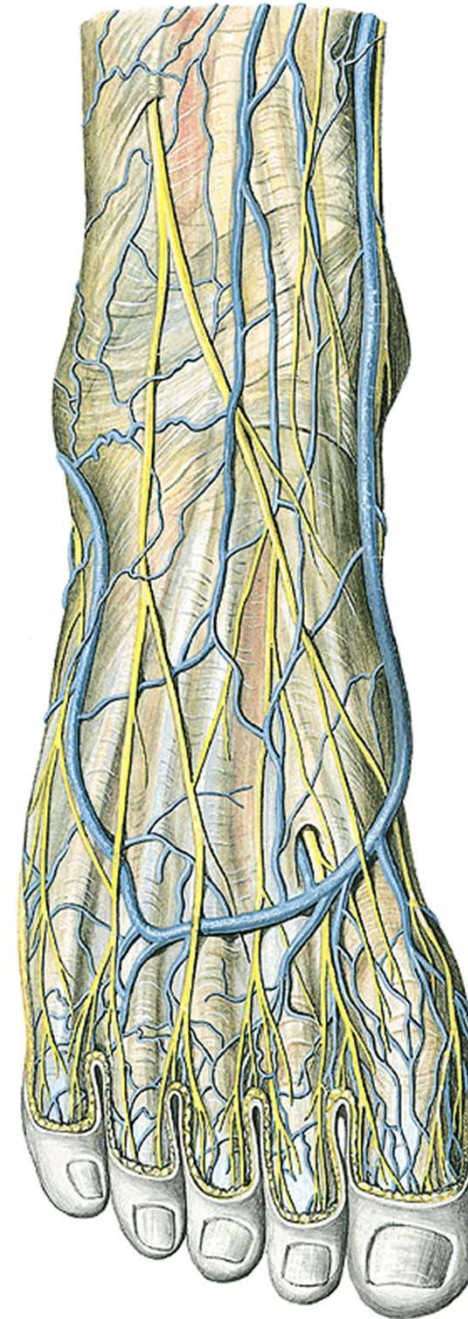
n. cut. dorsalis med.

n. cut. dors. intermed.

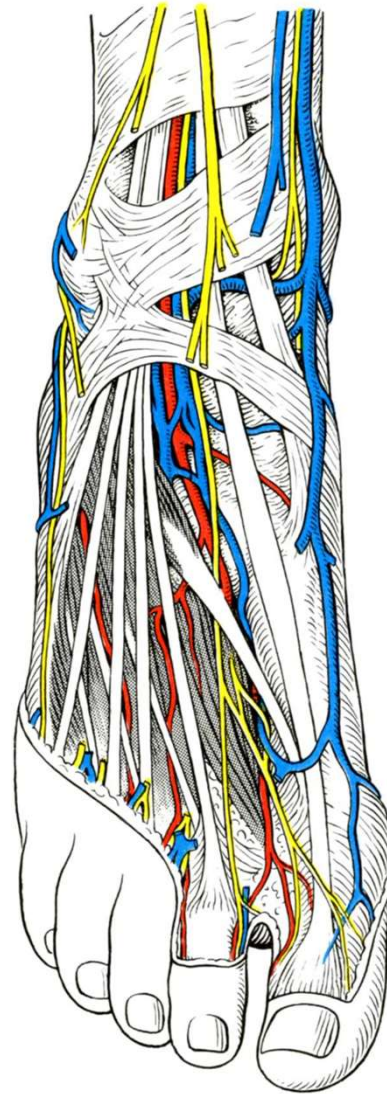
n. cut. dors. lat. (z n. suralis)

n. peroneus prof.

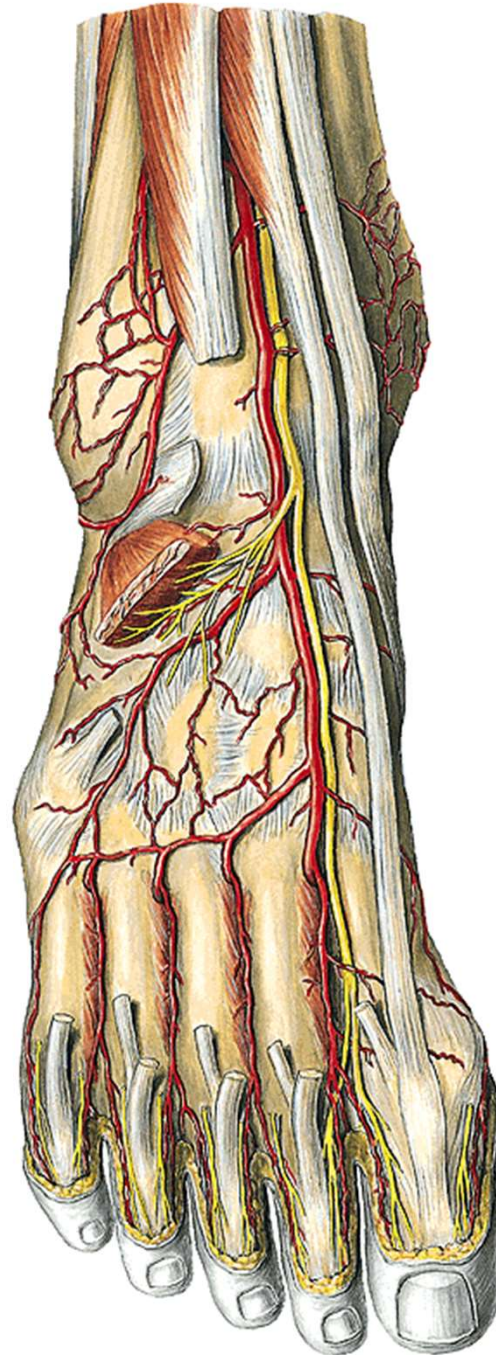
(from n. peroneus superf.)



a. et v. dorsalis pedis
n. peroneus prof.



n. peroneus prof.
a. dorsalis pedis



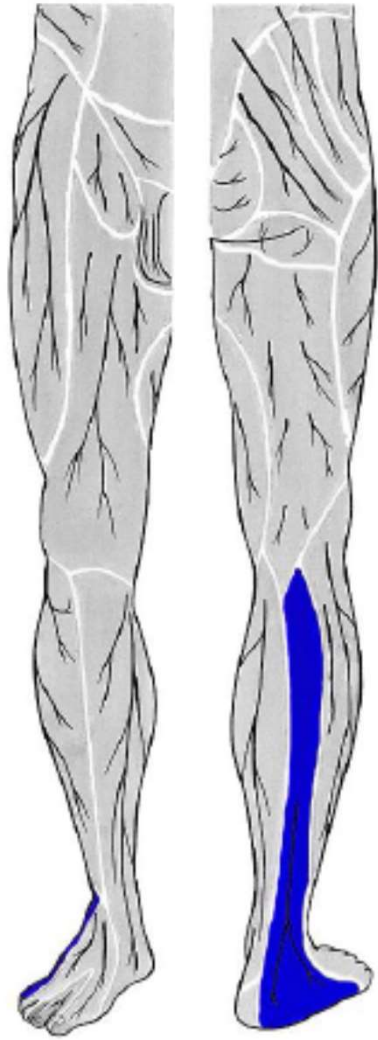
a. arcuata + a. tarsea lat.

aa. metatarsae dors.

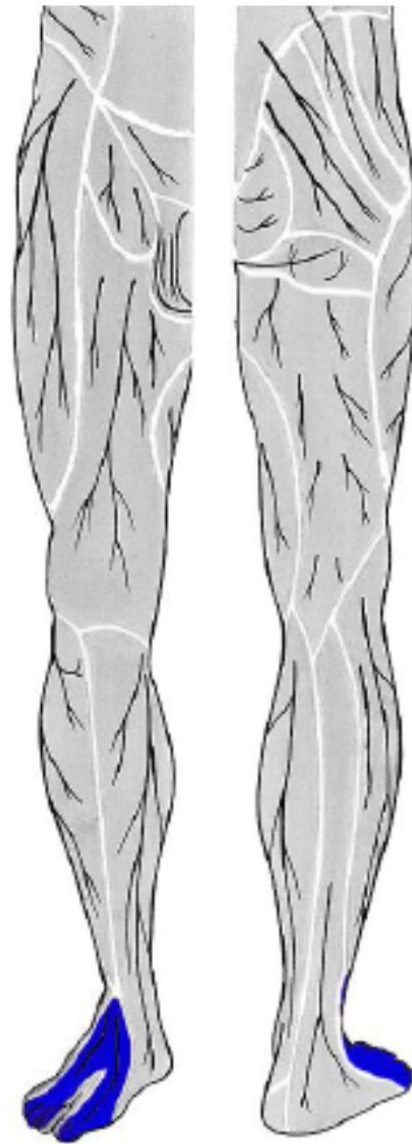
aa. digitales dorsales

a. metatarsae dors. prima

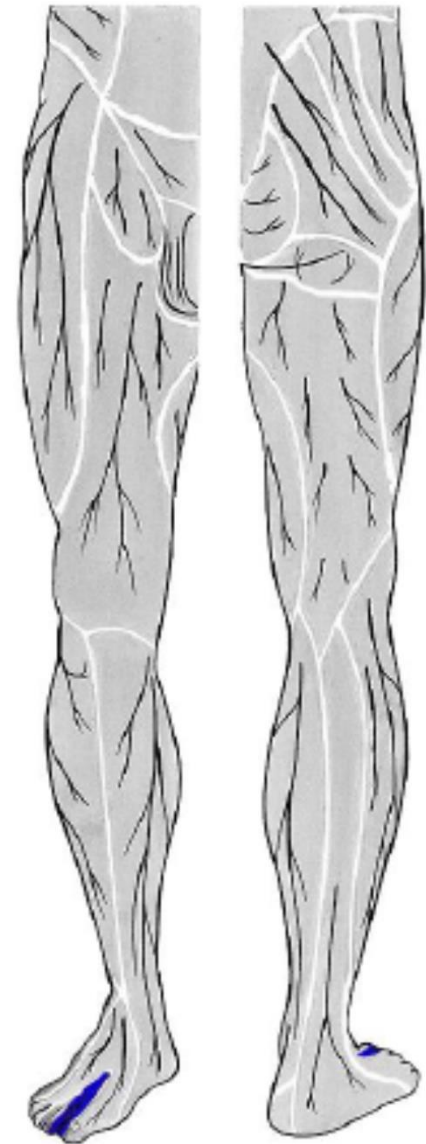




n. suralis
(z *n. fibularis communis*
a *n. tibialis*)

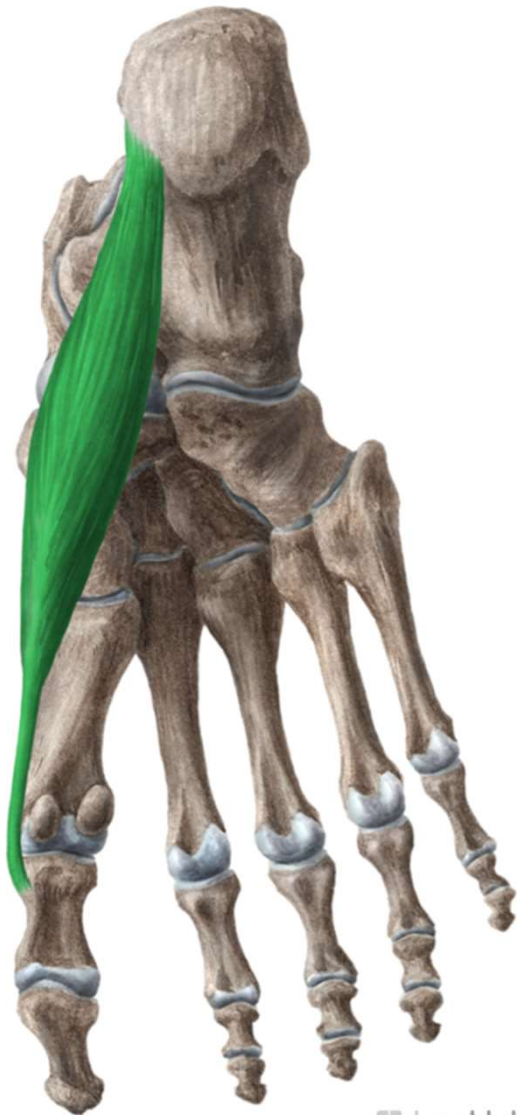


n. fibularis superficialis
(z *n. fibularis communis*)



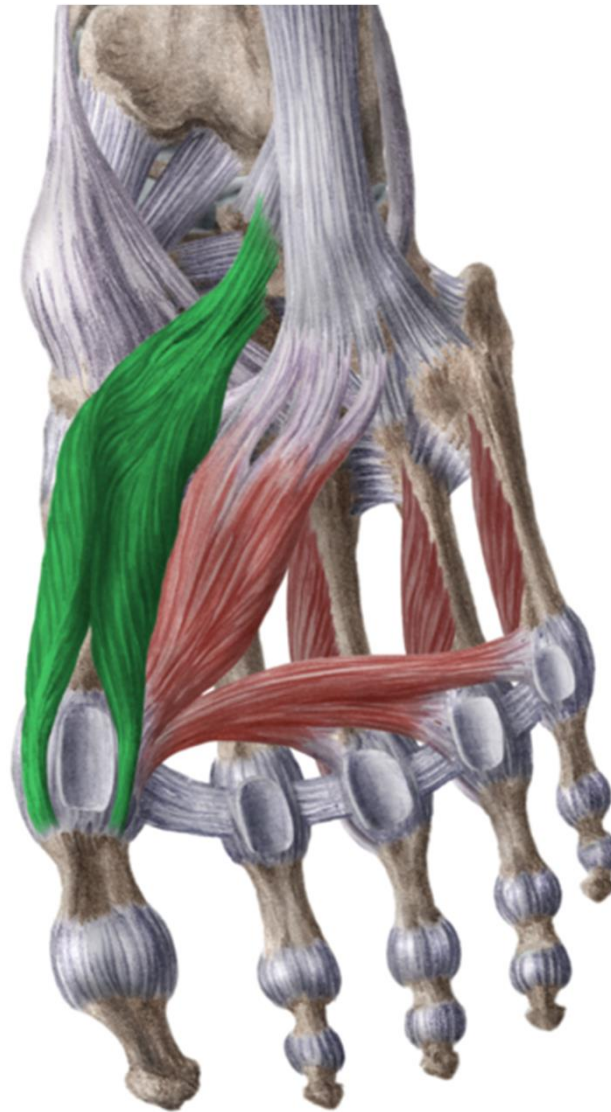
n. fibularis profundus
(z *n. fibularis communis*)

planta pedis



www.kenhub.com

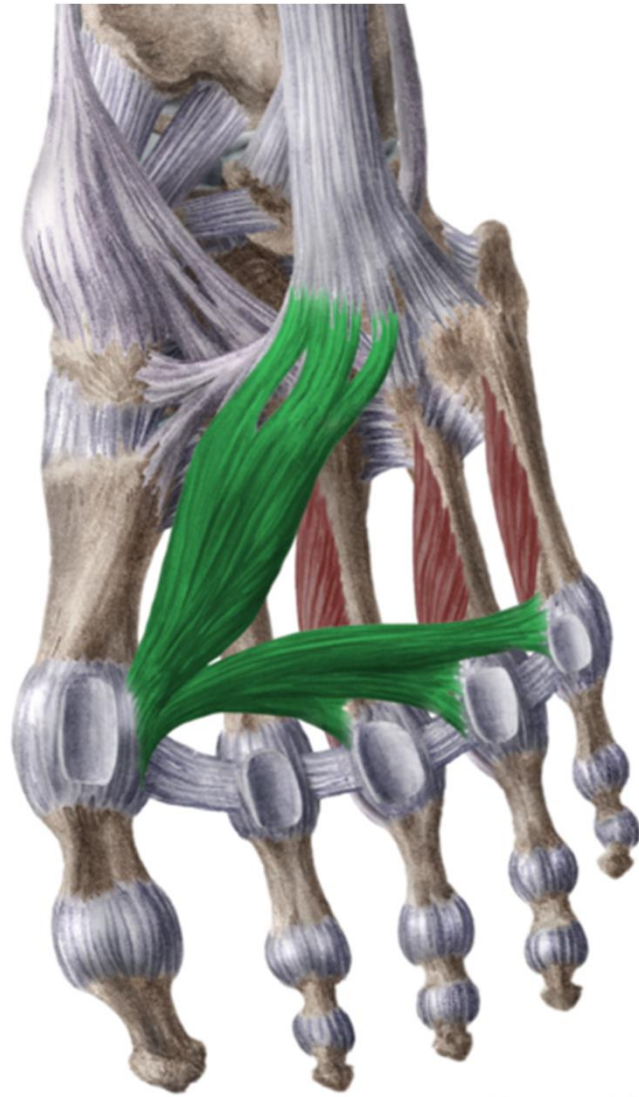
kenHub



www.kenhub.com

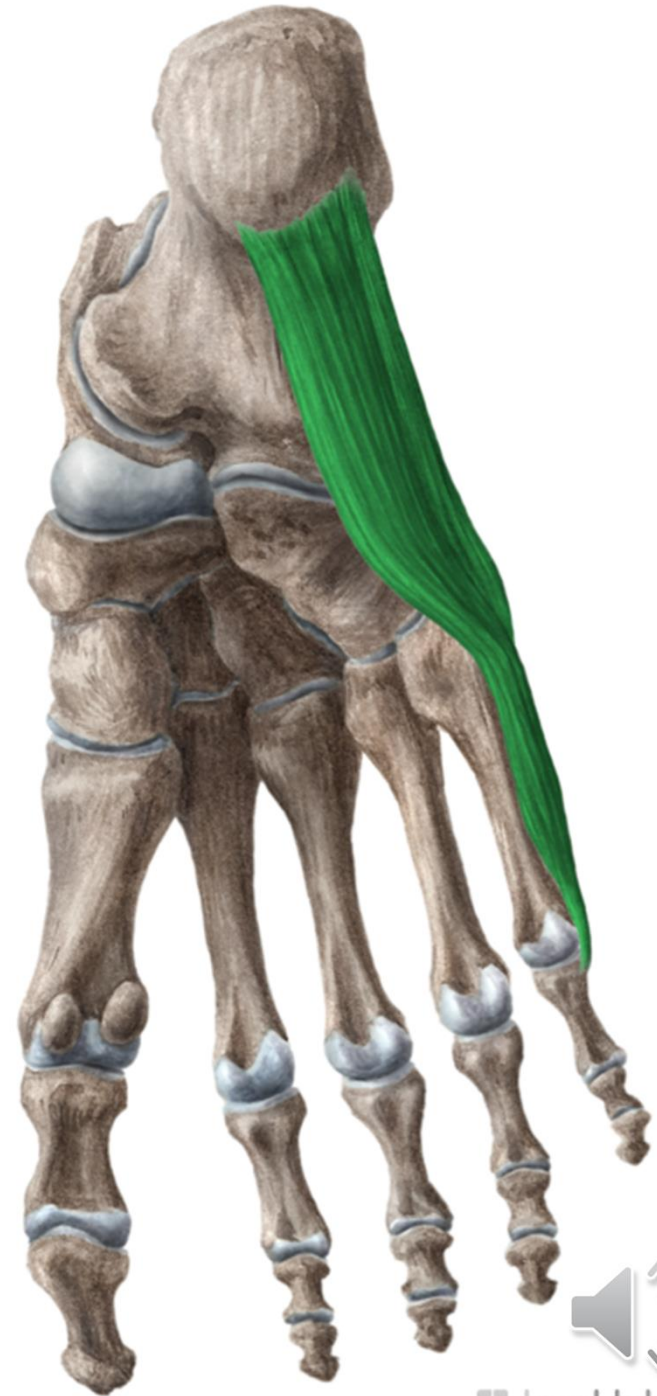
kenHub





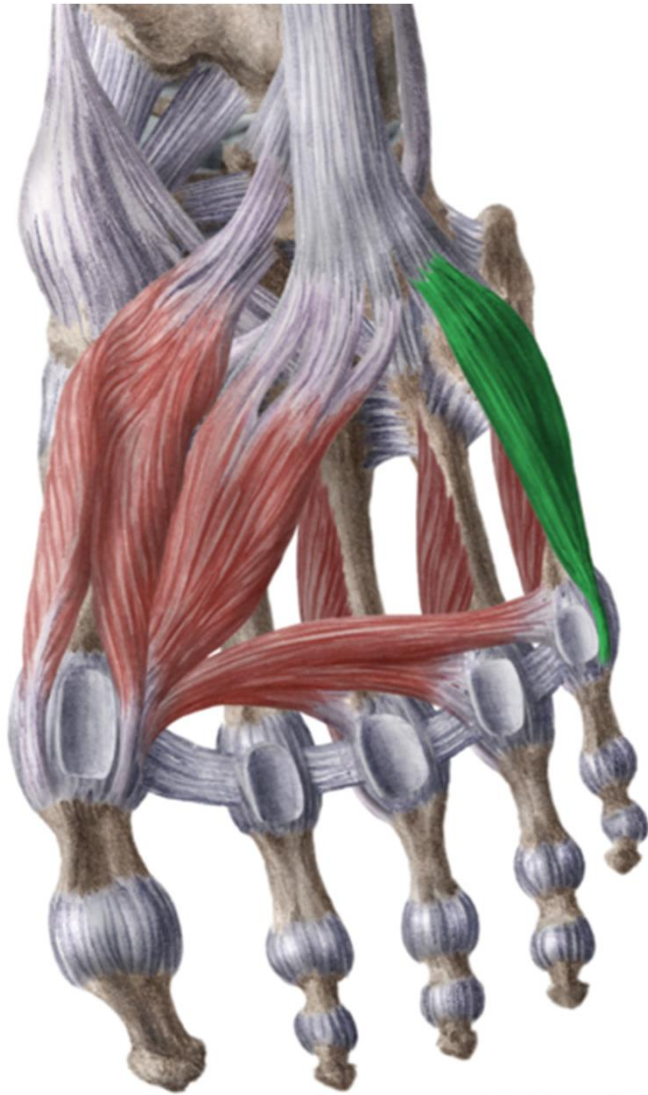
www.kenhub.com

 kenHub



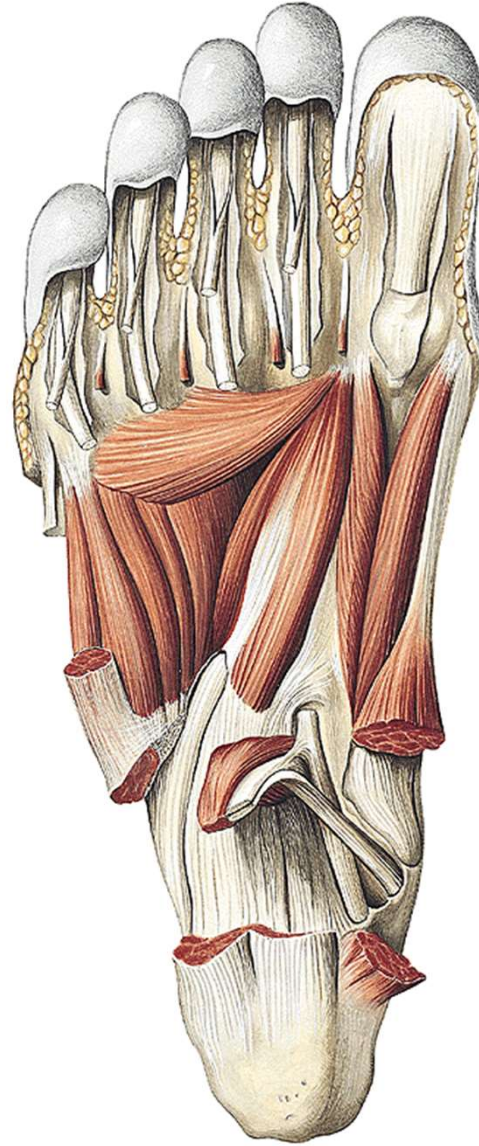
www.kenhub.com

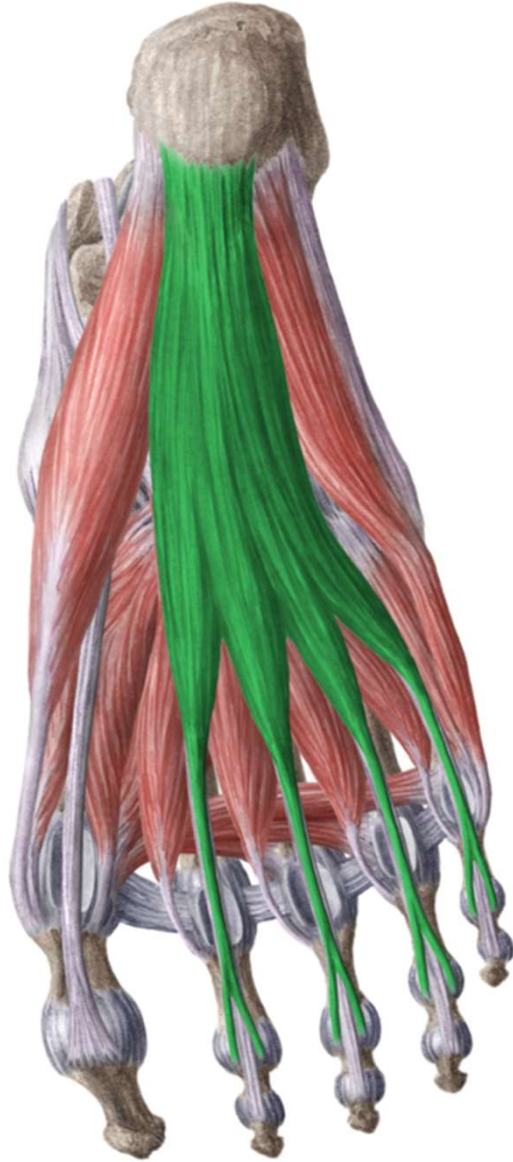

 kenHub



www.kenhub.com

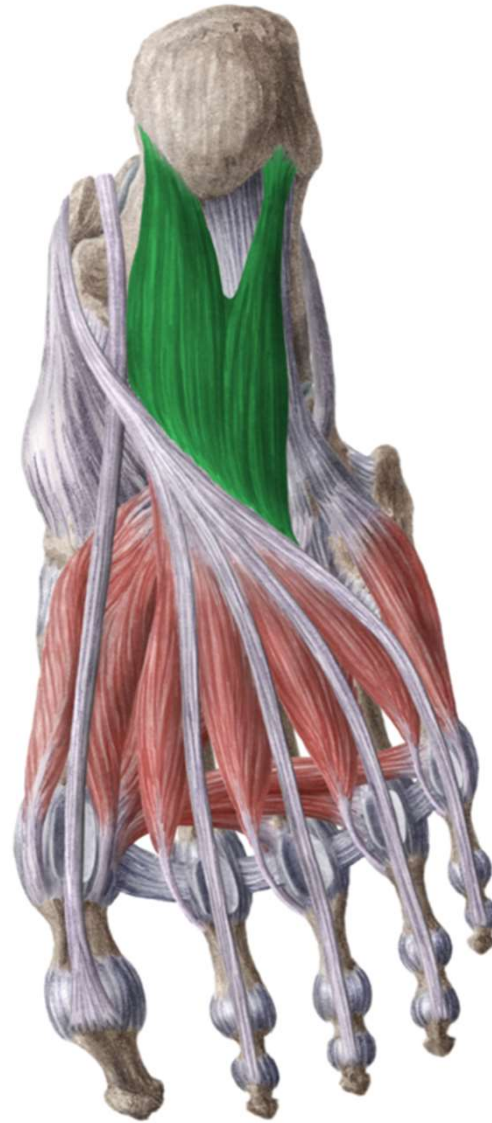
 kenHub





www.kenhub.com

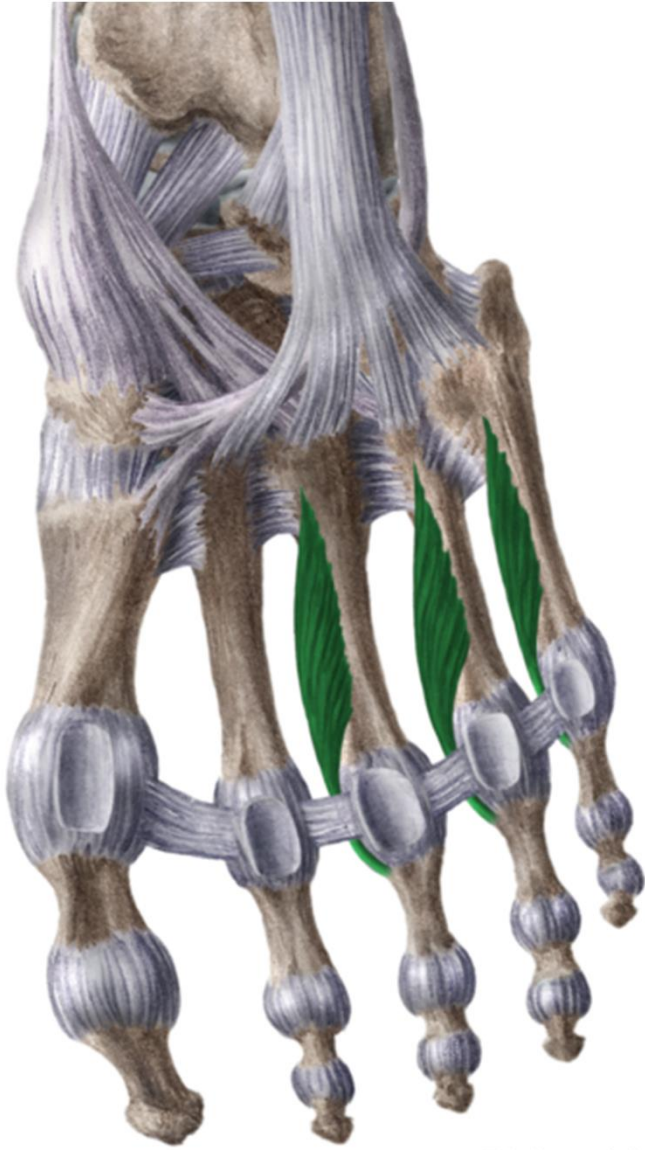
 kenHub



www.kenhub.com

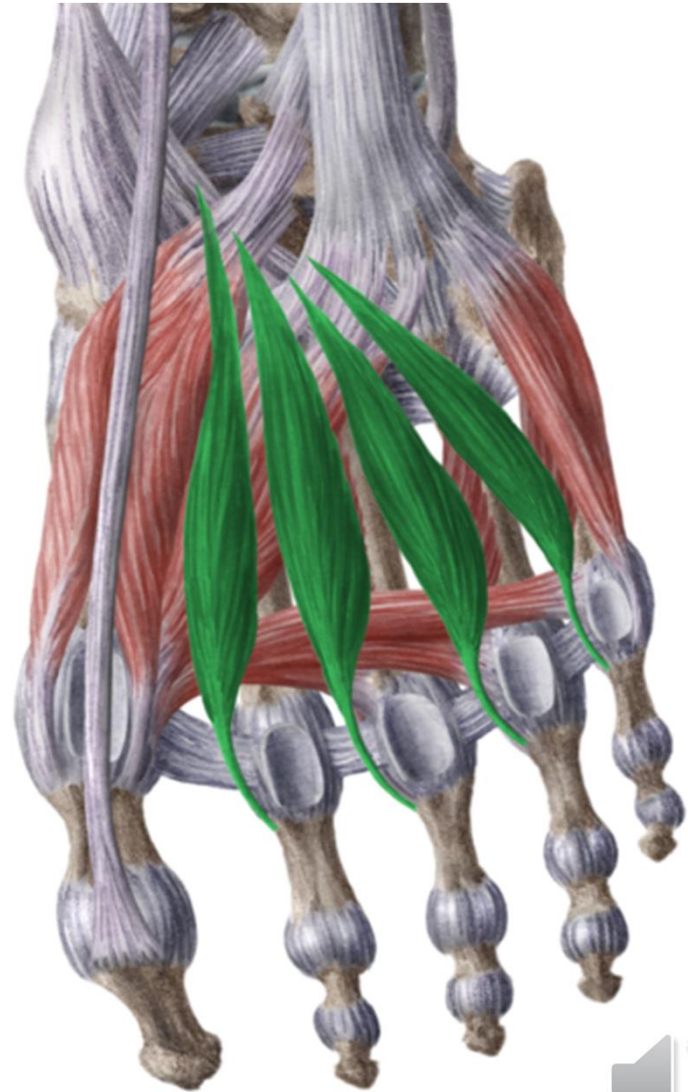
 kenHub





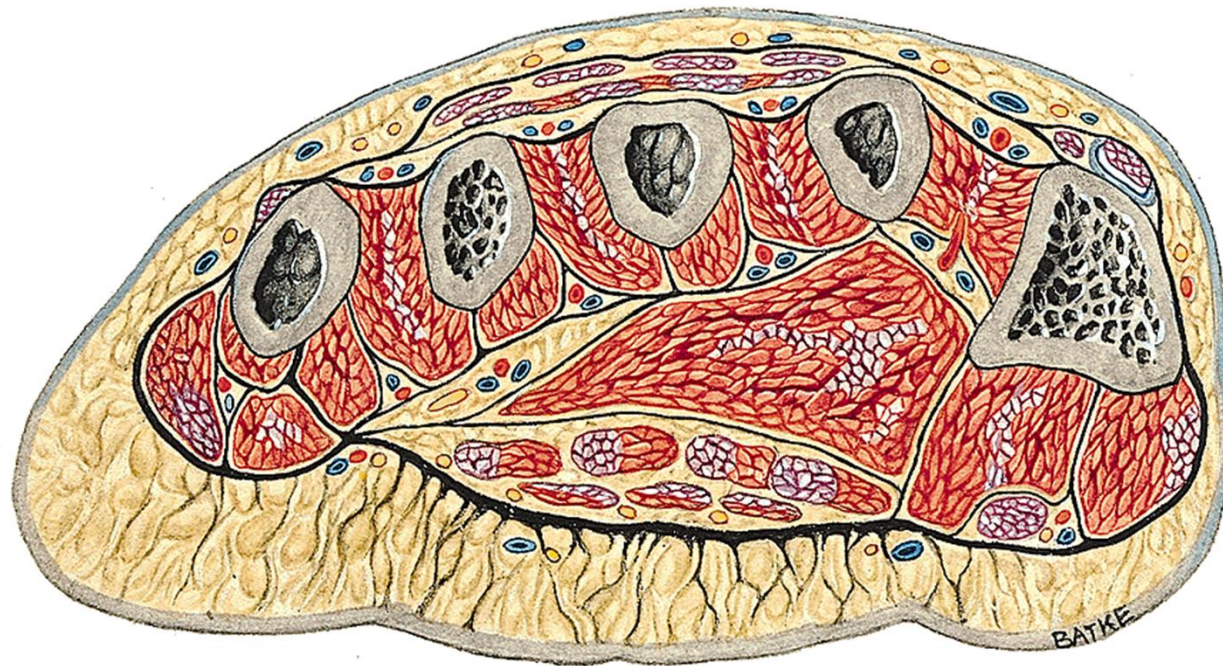
www.kenhub.com

 kenHub



www.kenhub.com

  kenHub



aponeurosis plantaris

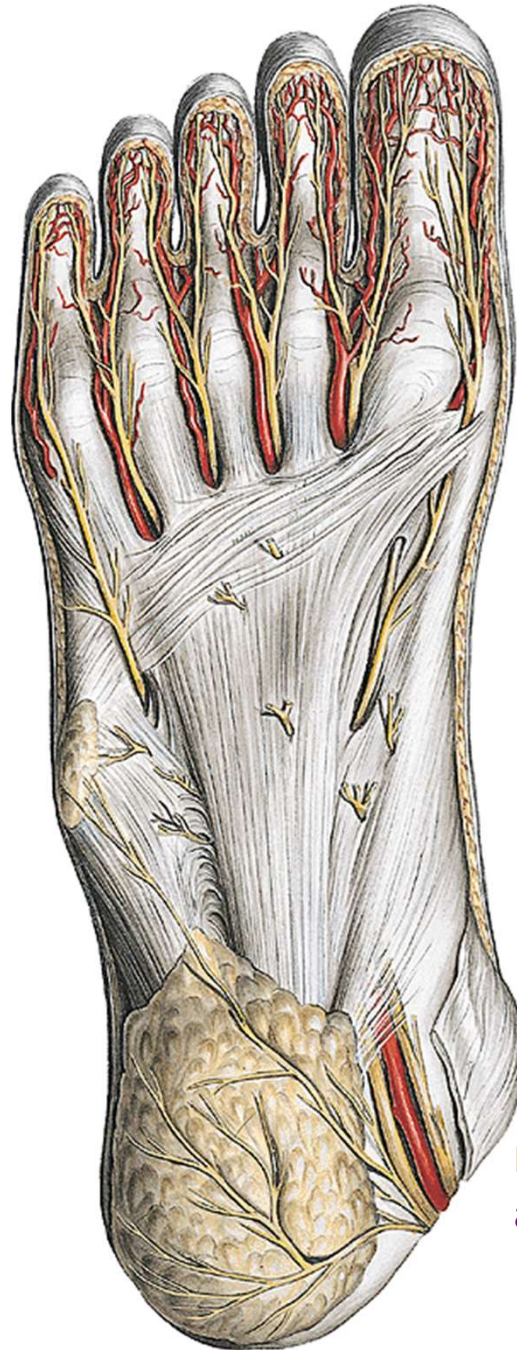rr. superf. (from n. plantaris med. et lat.)

rr. superf. (from a. et v. plantaris med.)

a. et v. plantaris med. et lat.

n. plantaris med. et lat.

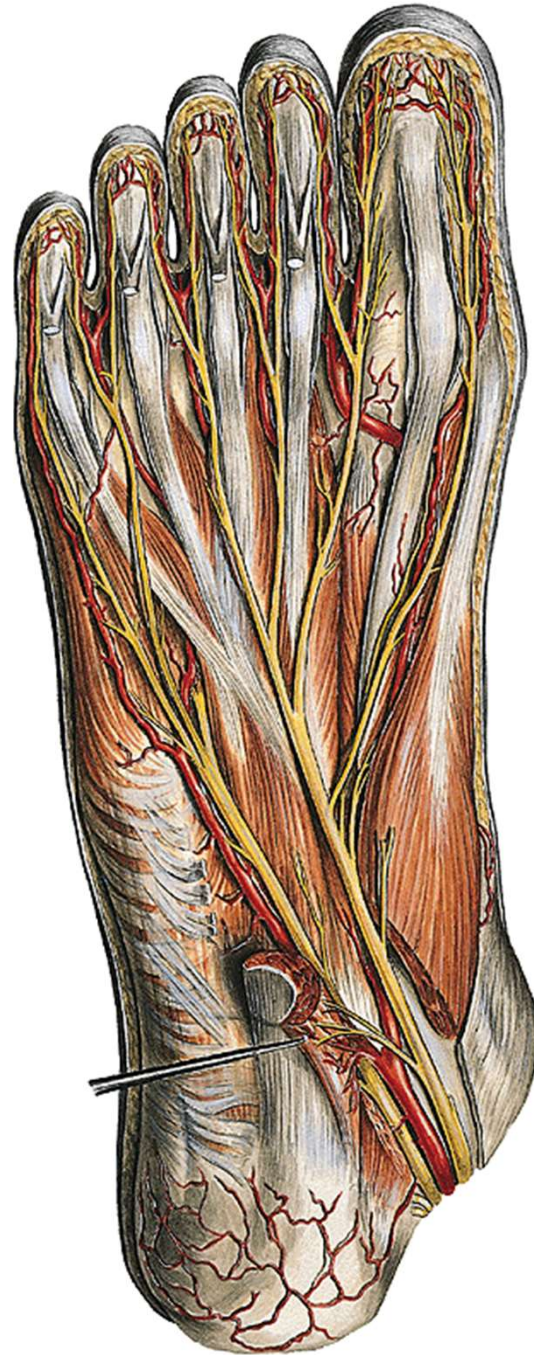




rr. superf. (z n. plantaris med. et lat.)

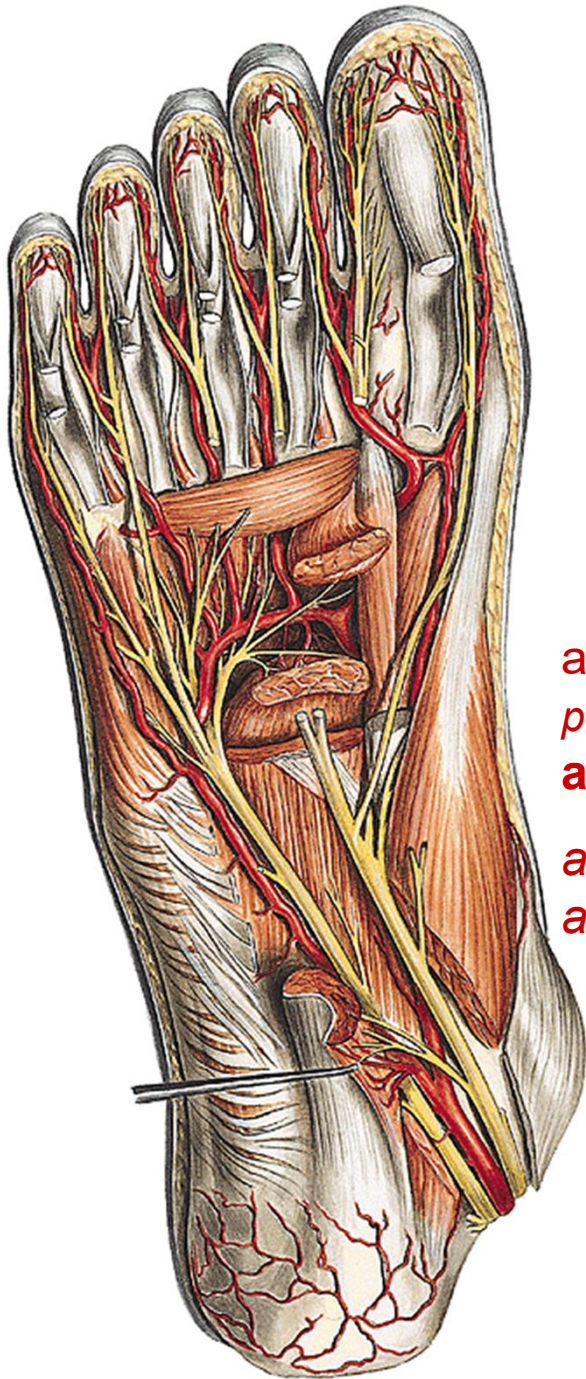
n. tibialis
a. et v. tibialis





n. plantaris med. et lat.
a. et v. plantaris med. et lat.





a. plantaris lat. + r. plantaris prof (*from a. dorsalis pedis*) + branch from a. plantaris med.

arcus plantaris

aa. metatarsae plant.

aa. digitales plant.

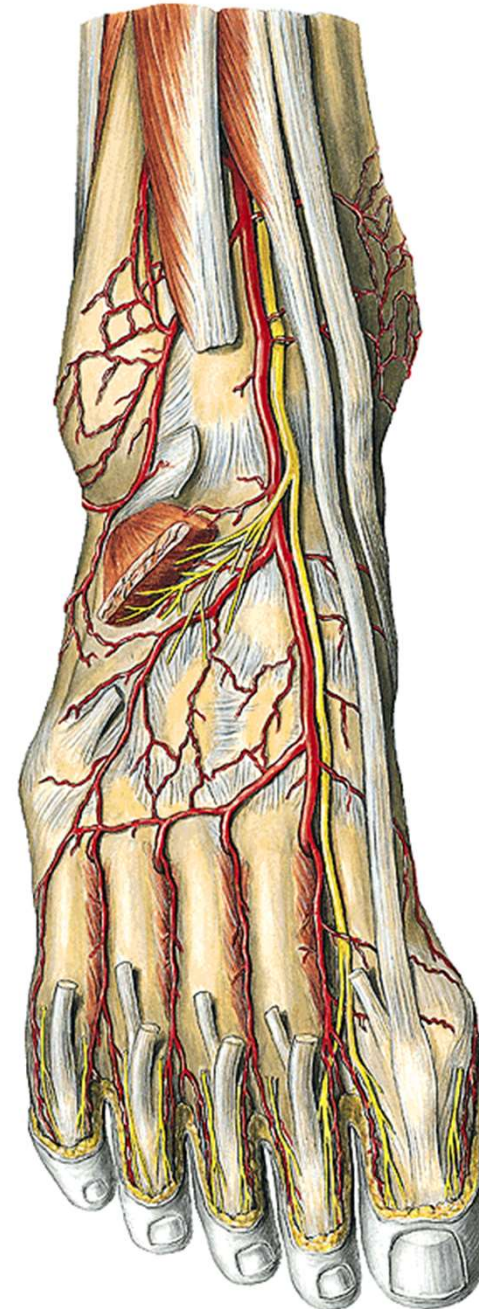


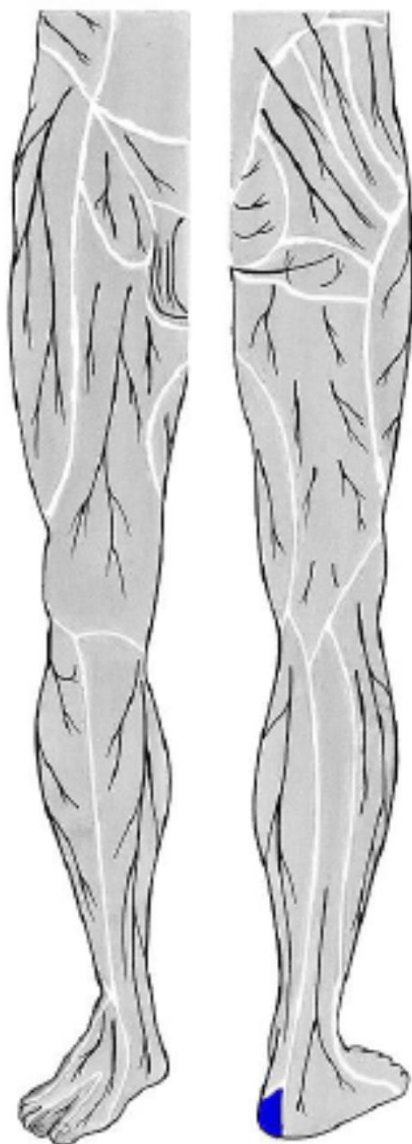
digiti pedis

Dorsal aponeurosis

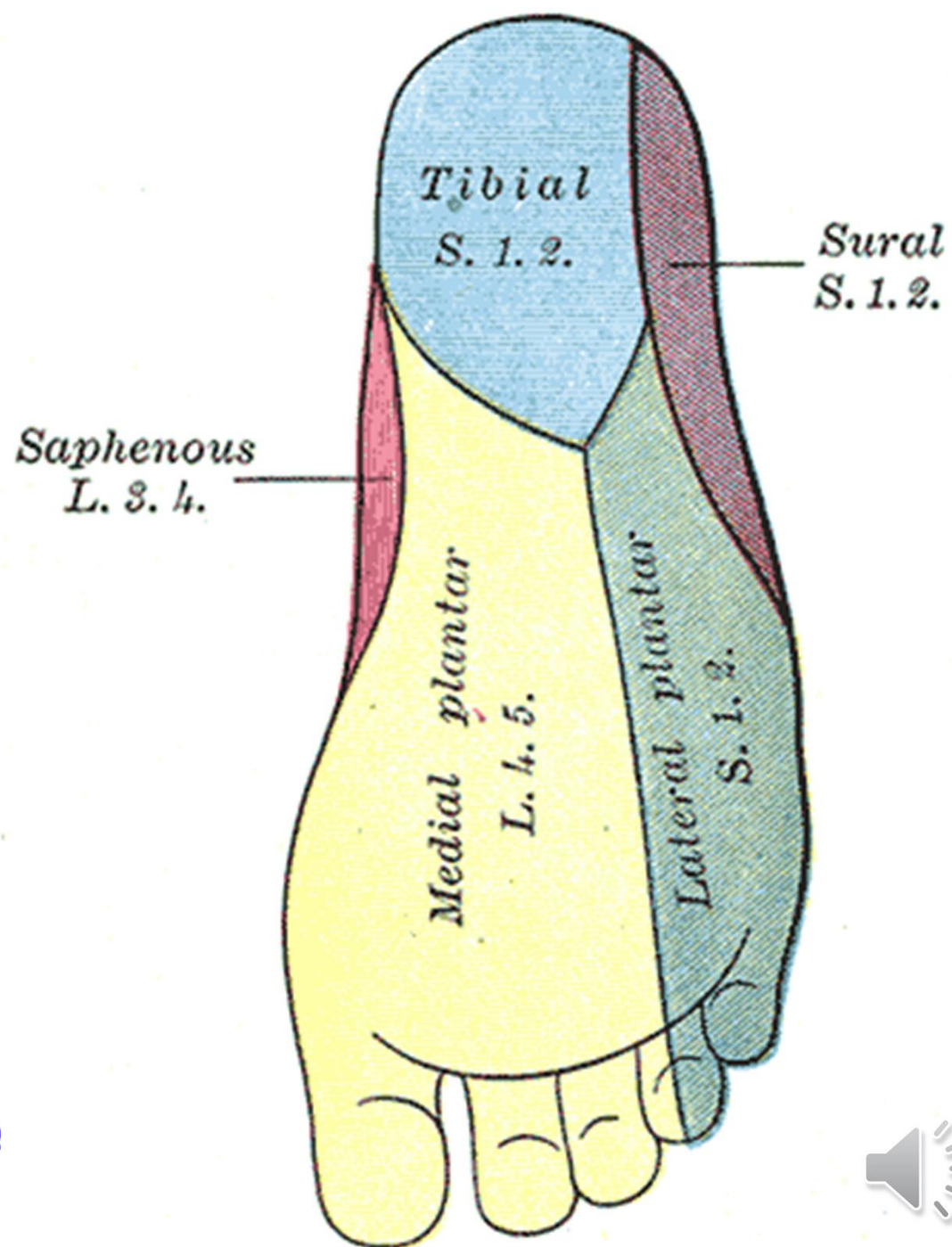
nn. digitales dorsales

aa. et vv. digitales dorsales



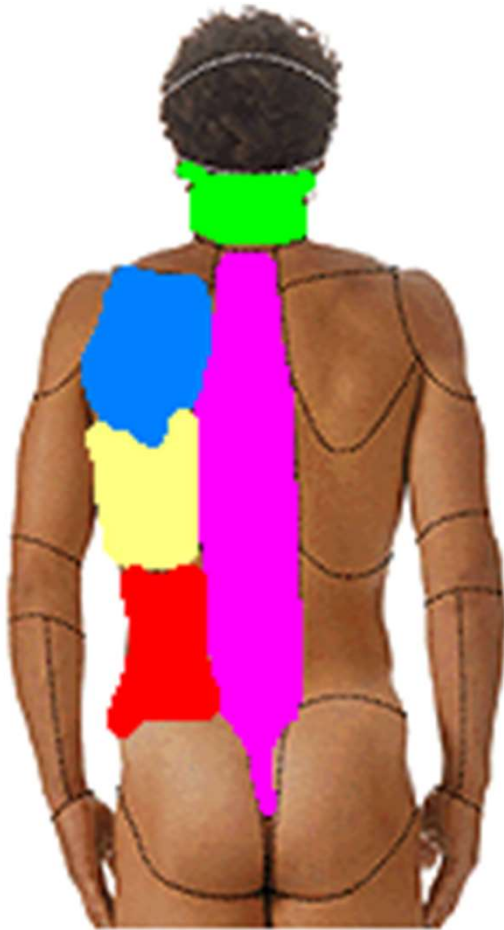


n. plantaris medialis et lateralis:
(z n. tibialis)



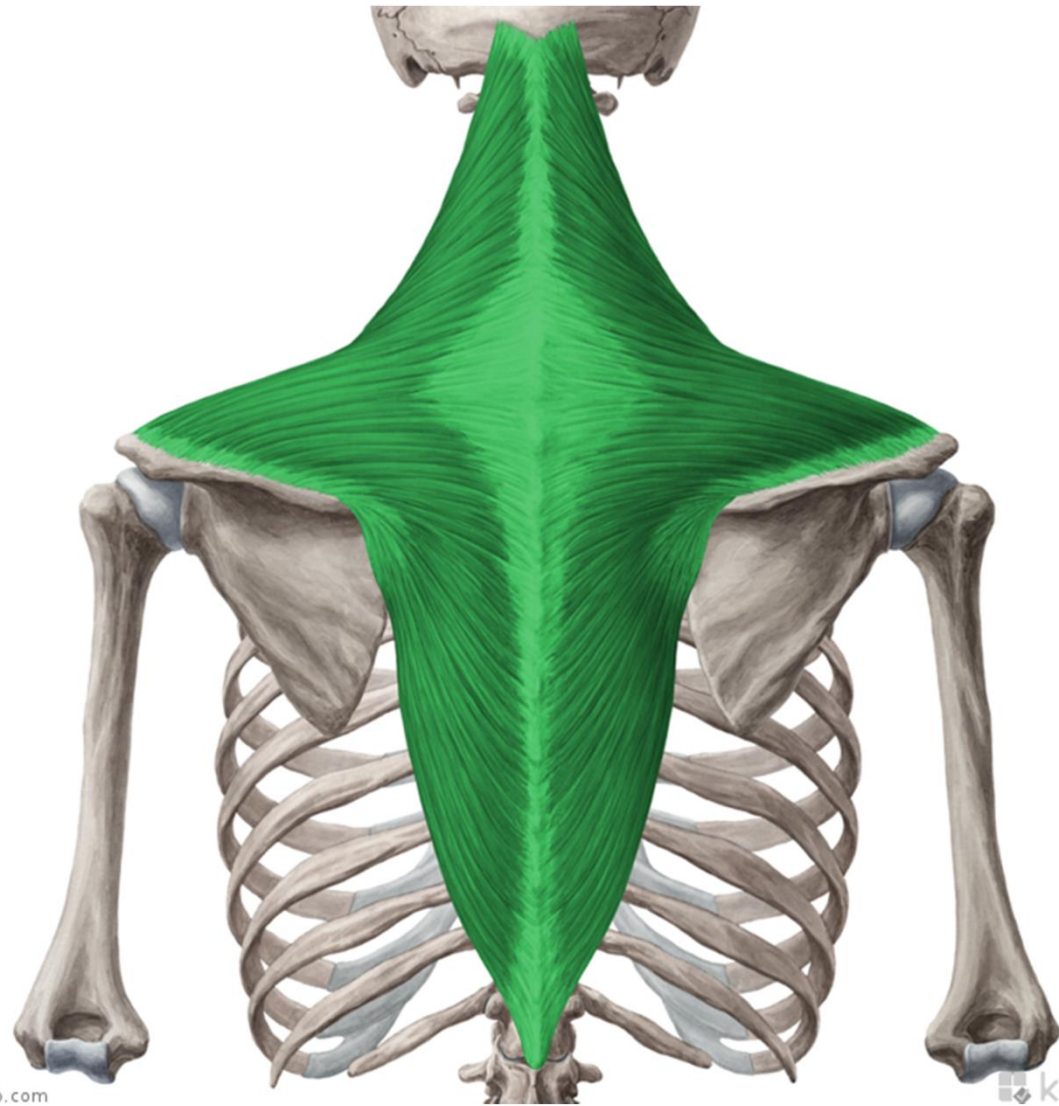
The regional anatomy of the back





- regio nuchae
- regio vertebralis
- regio infrascapularis
- regio lumbalis

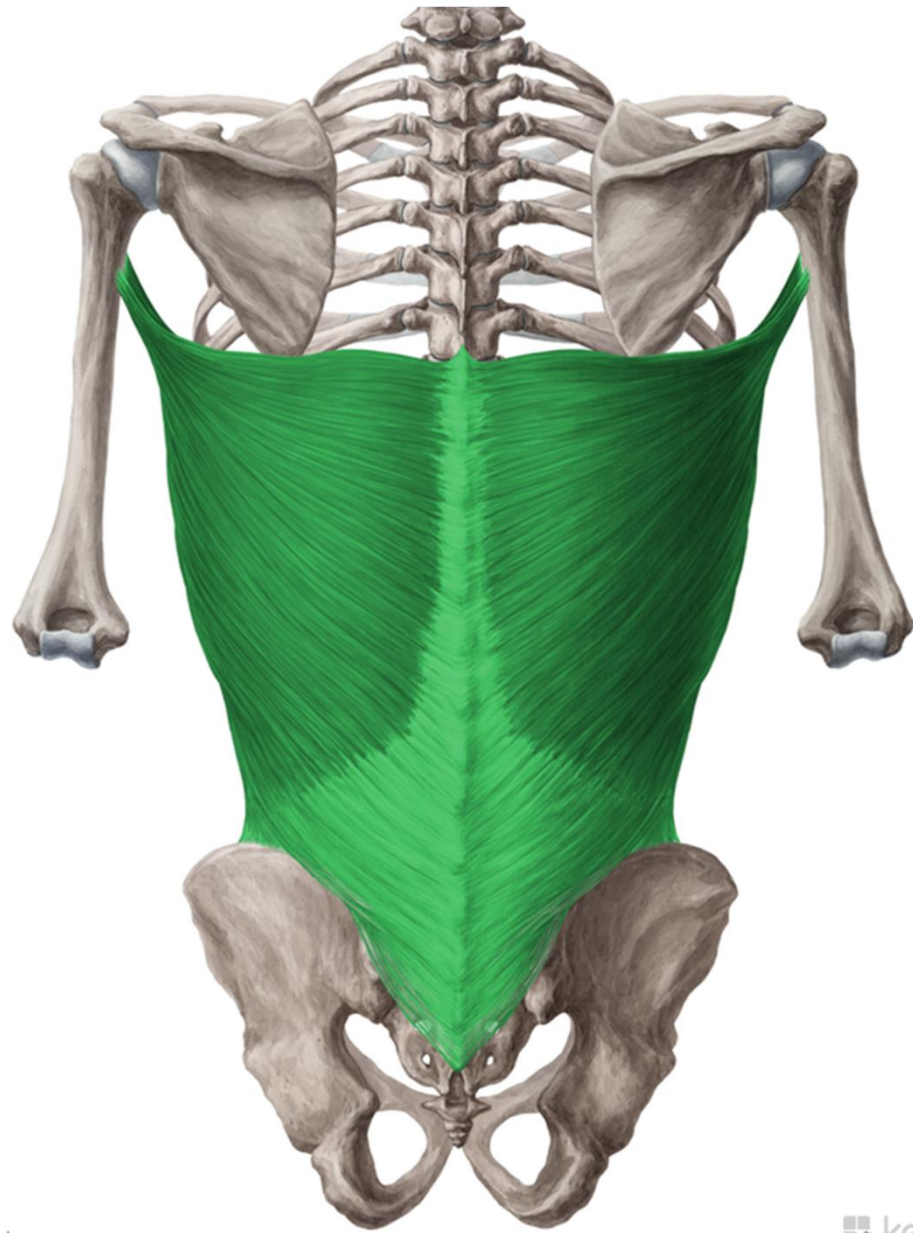


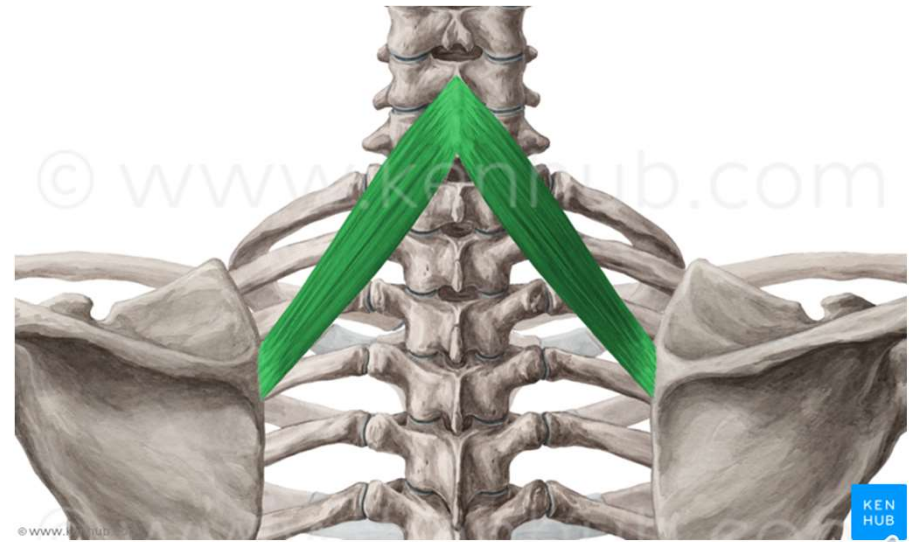
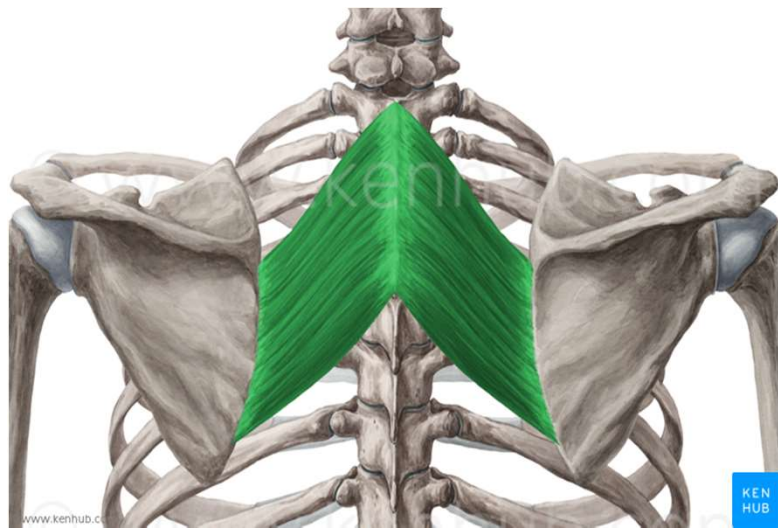
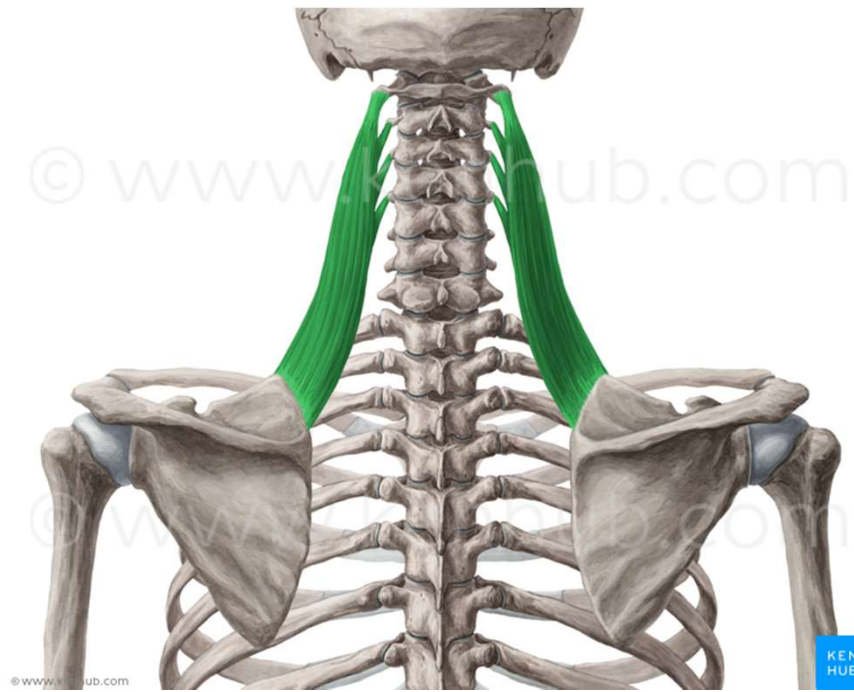


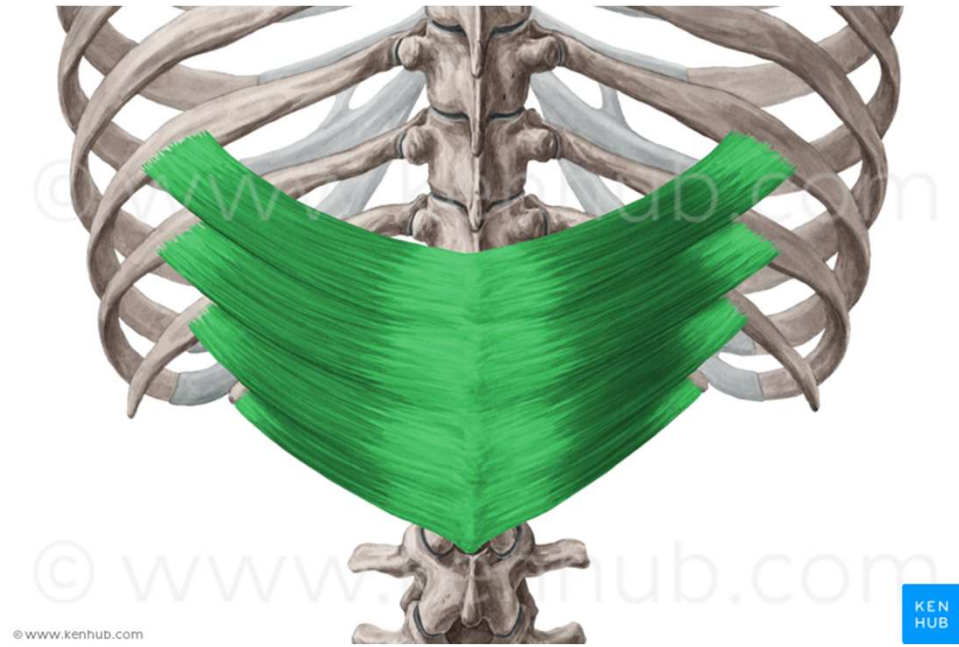
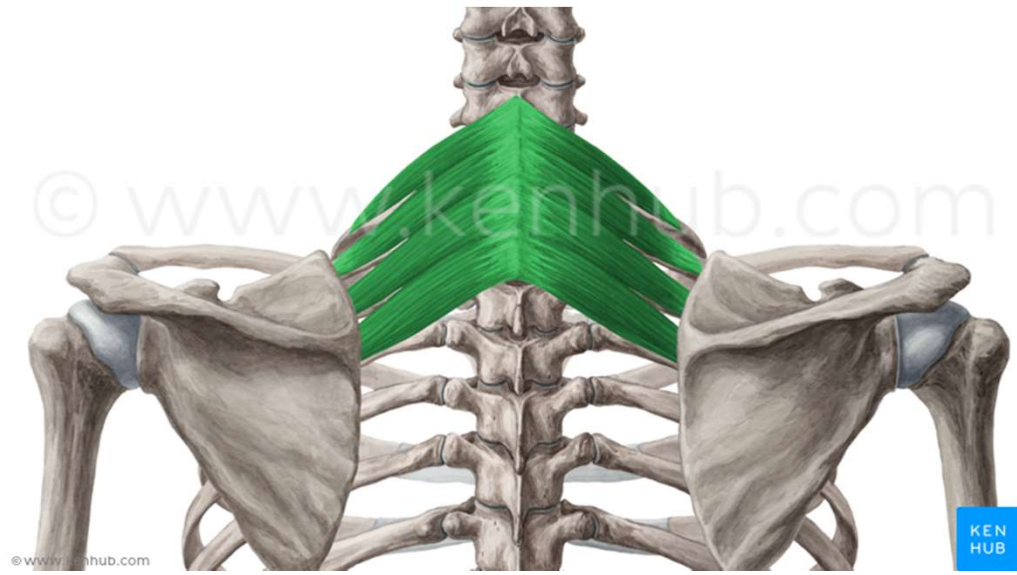
www.kenhub.com

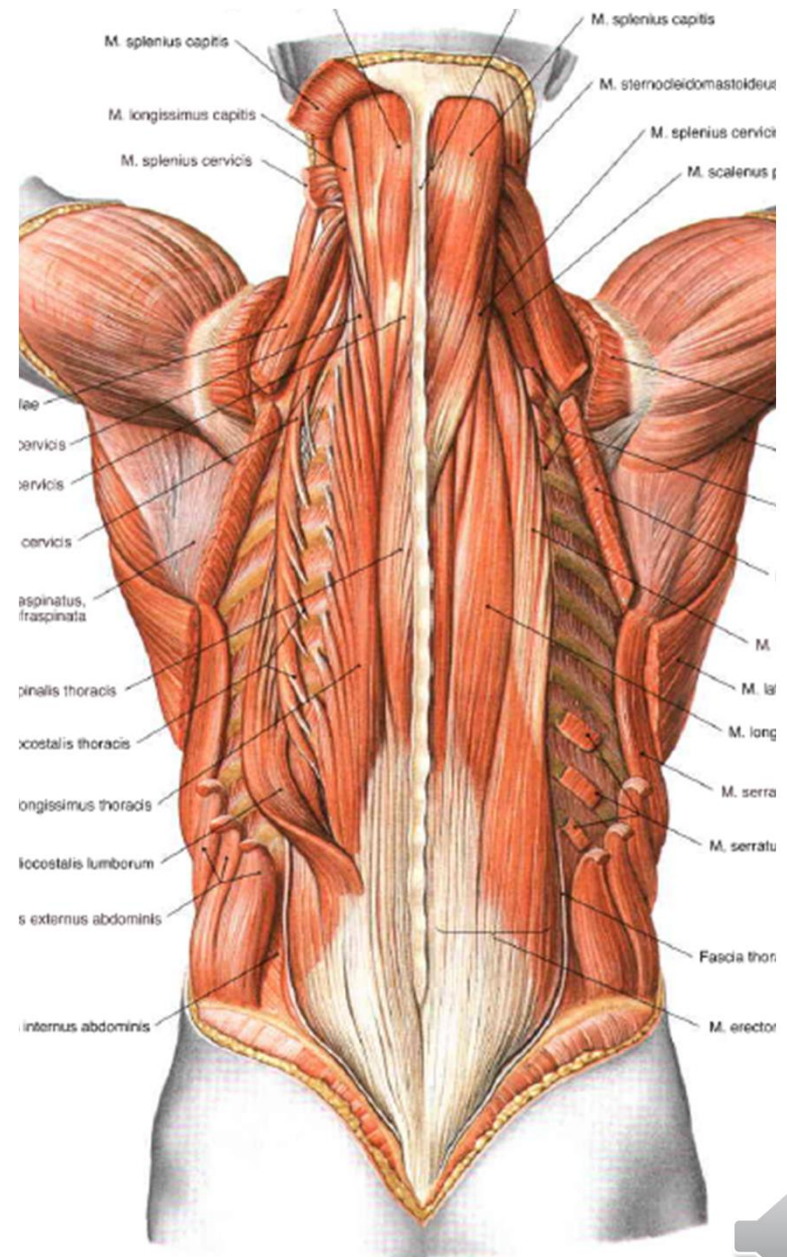
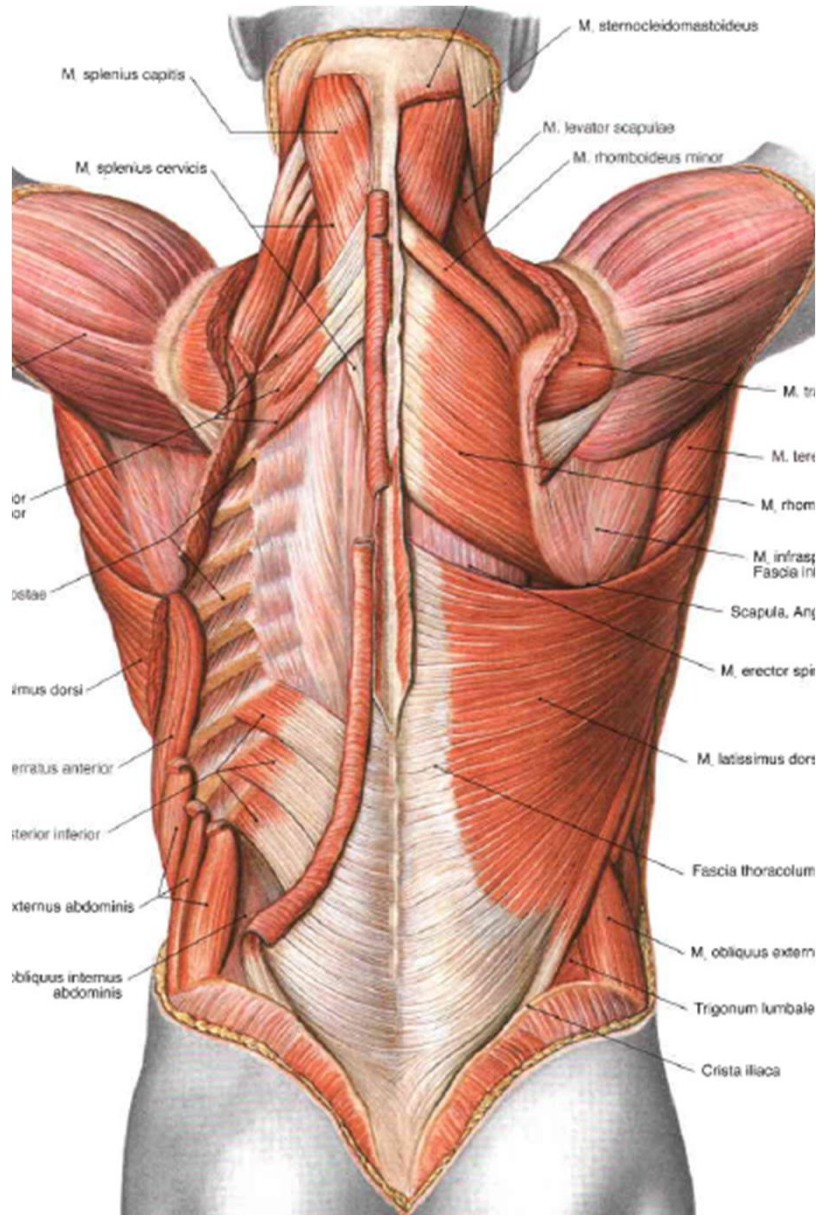
kenHub



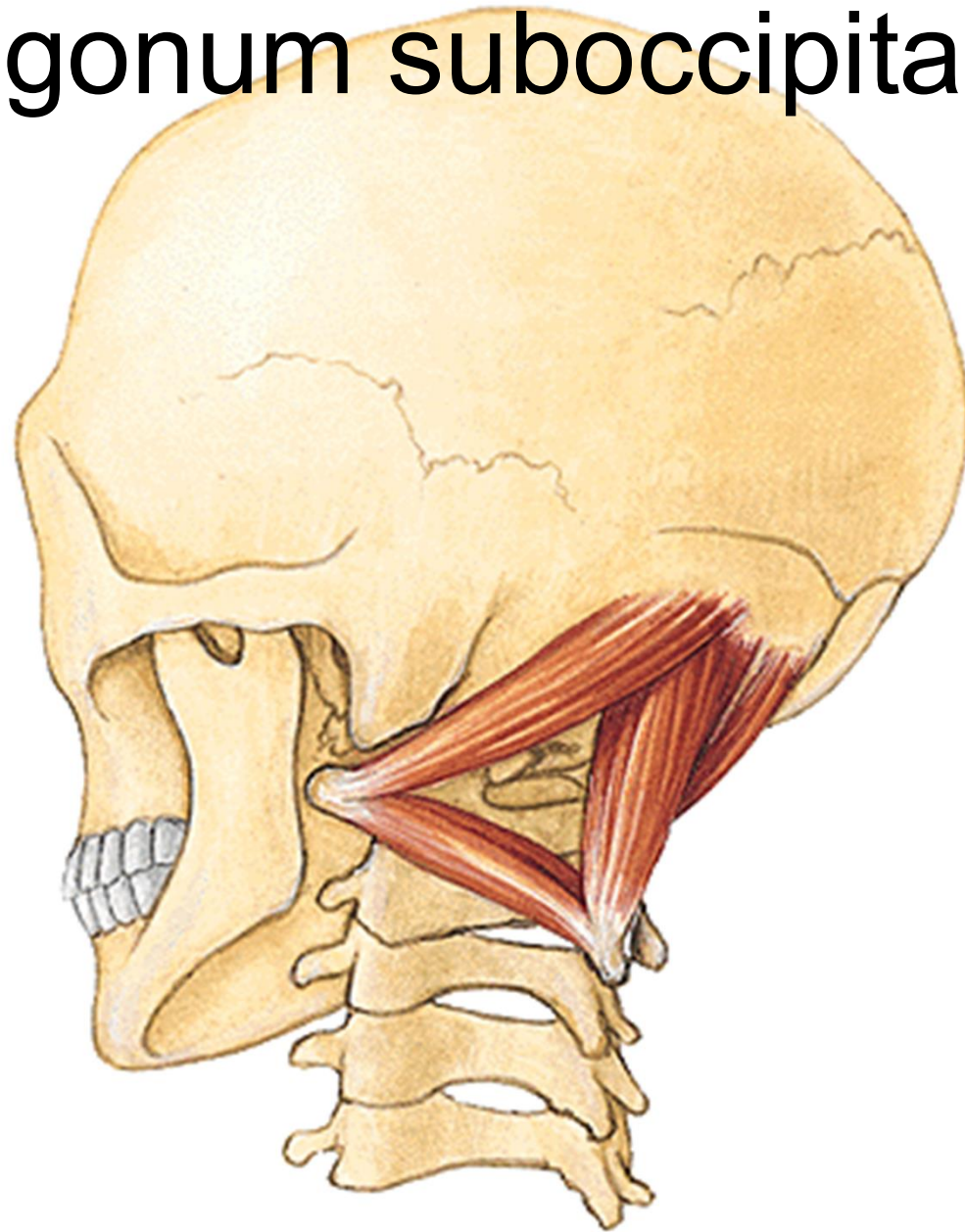


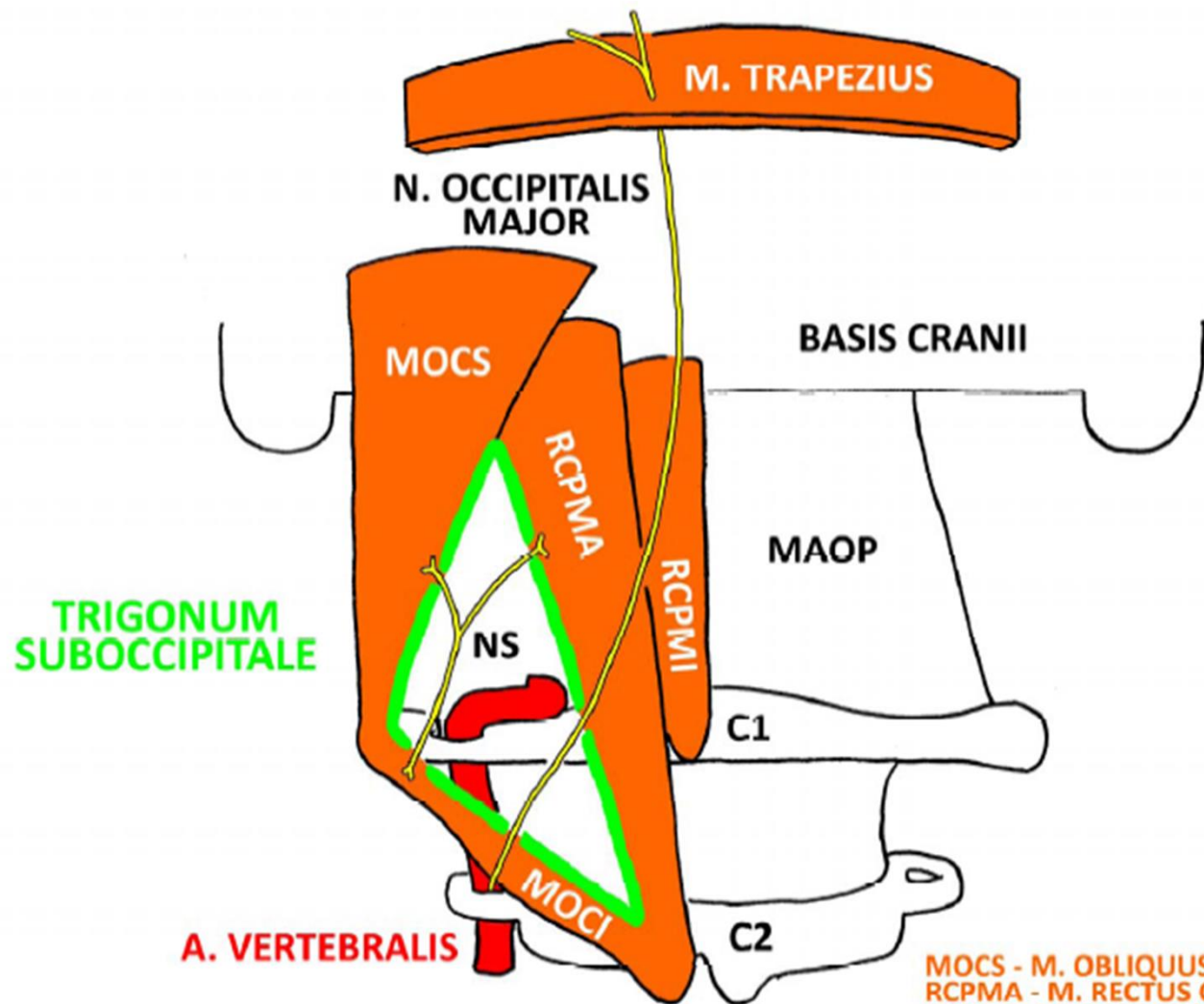






Trigonum suboccipitale

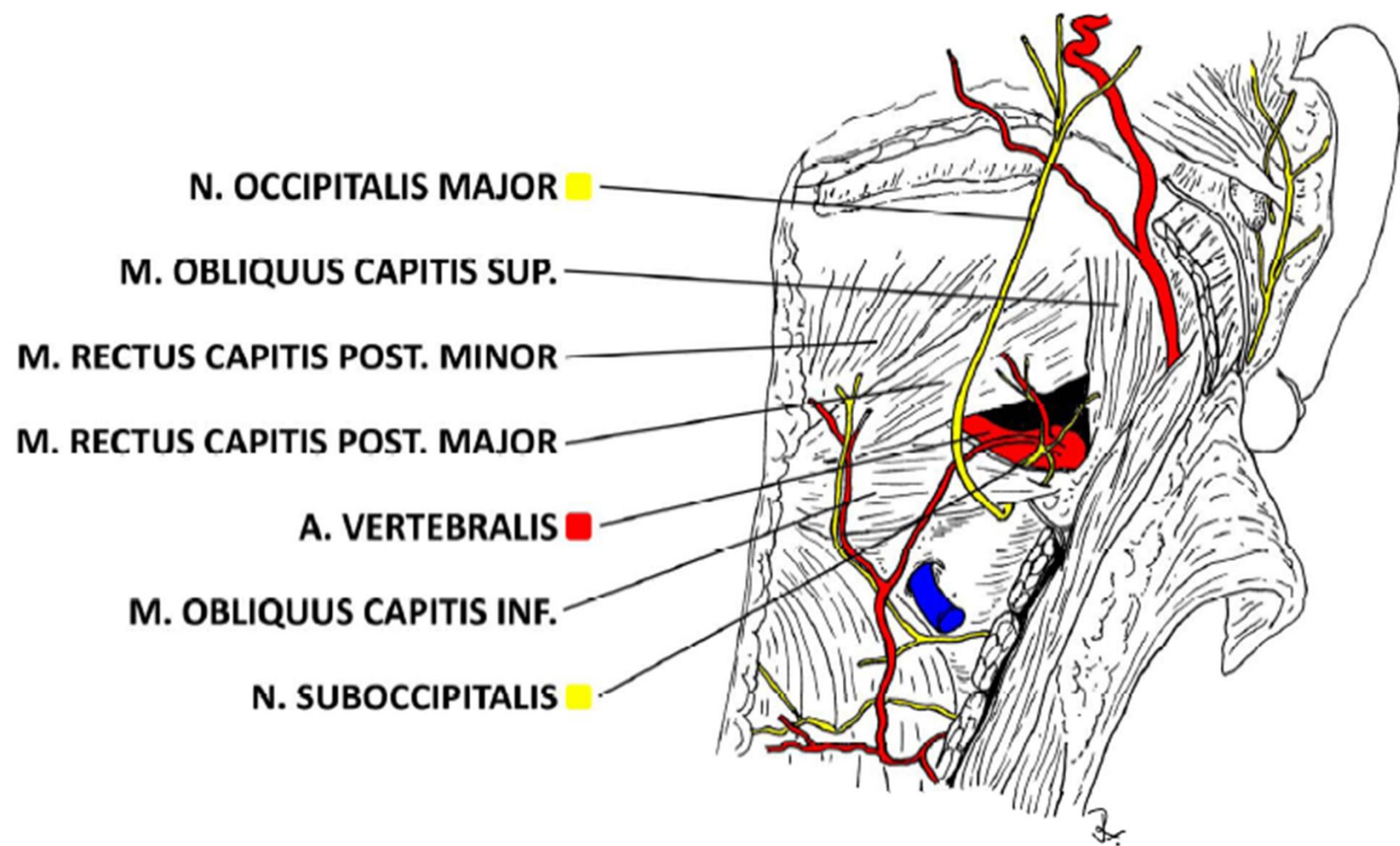




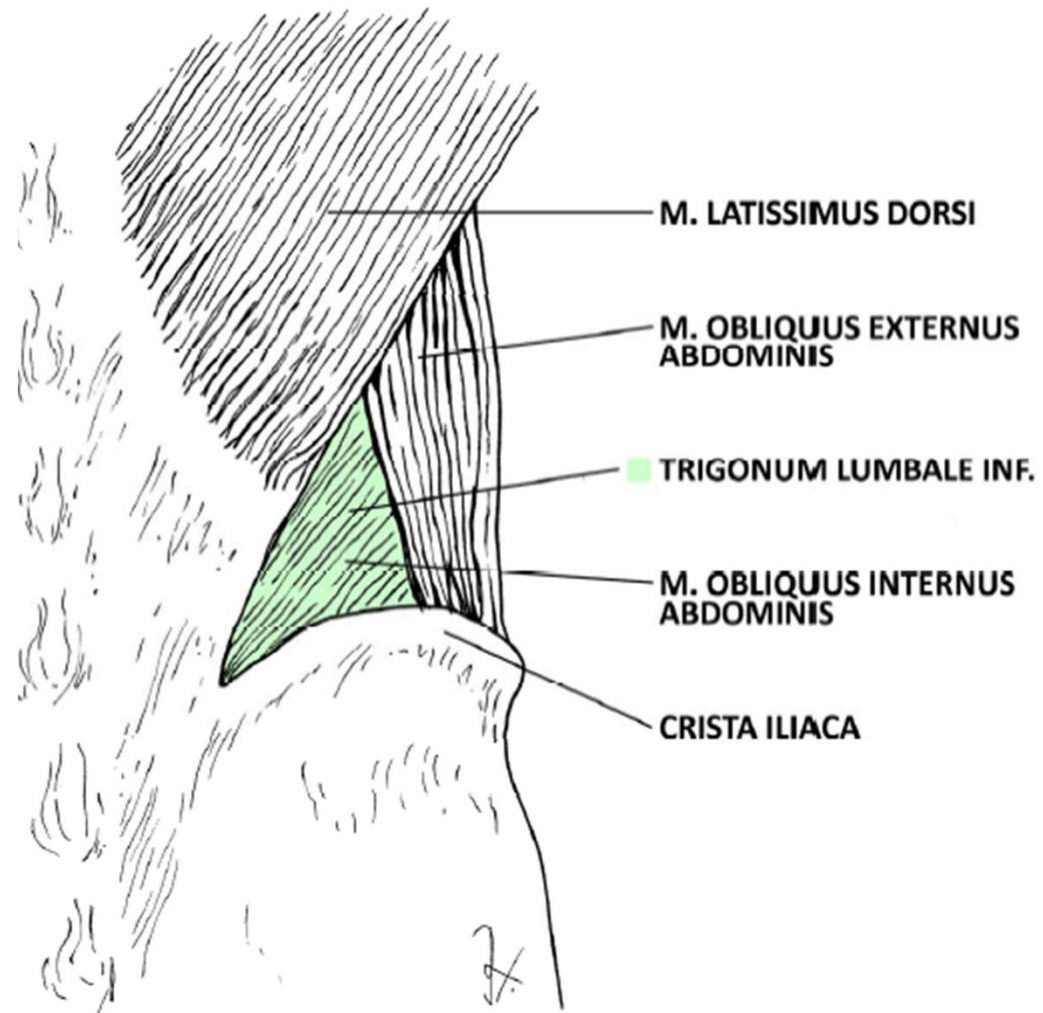
A. VERTEBRALIS

MOCS - M. OBLIQUUS CAPITIS SUP.
 RCPMA - M. RECTUS CAPITIS POST. MAJOR
 RCPMI - M. RECTUS CAPITIS POST. MINOR
 MOCI - M. OBLIQUUS CAPITIS INF.
 MAOP - MEMBRANA ATLANTOCCIPITALIS POST.
 NS - N. SUBOCCIPITALIS

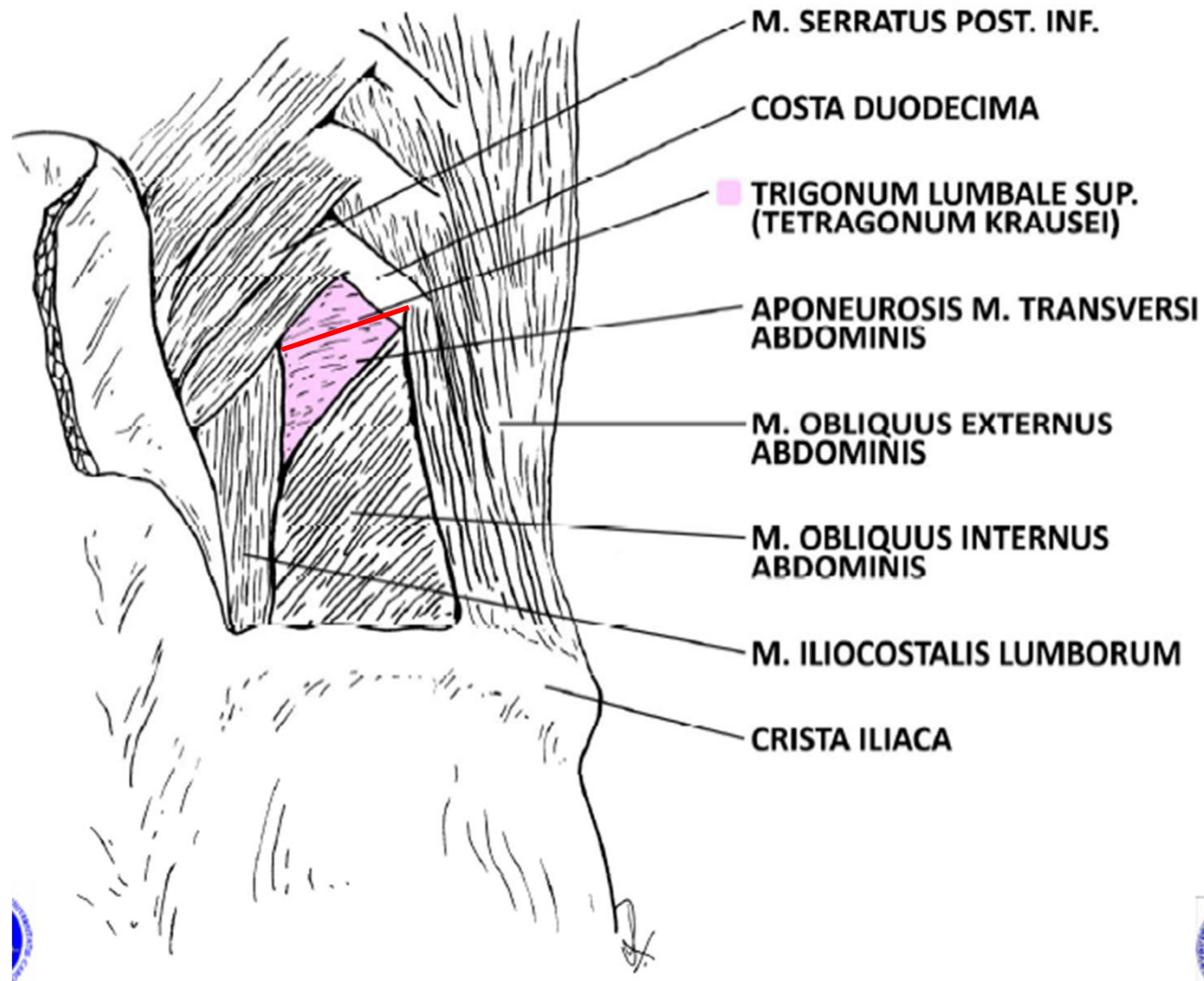




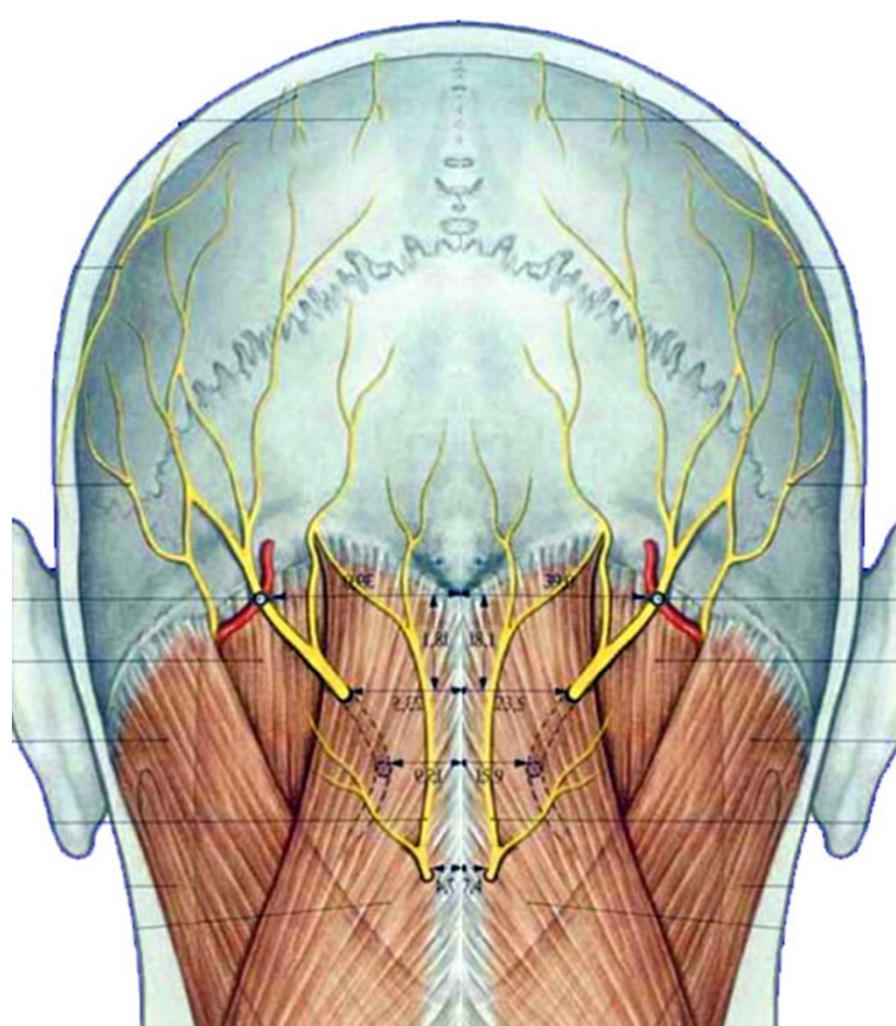
Trigonum lumbale petiti



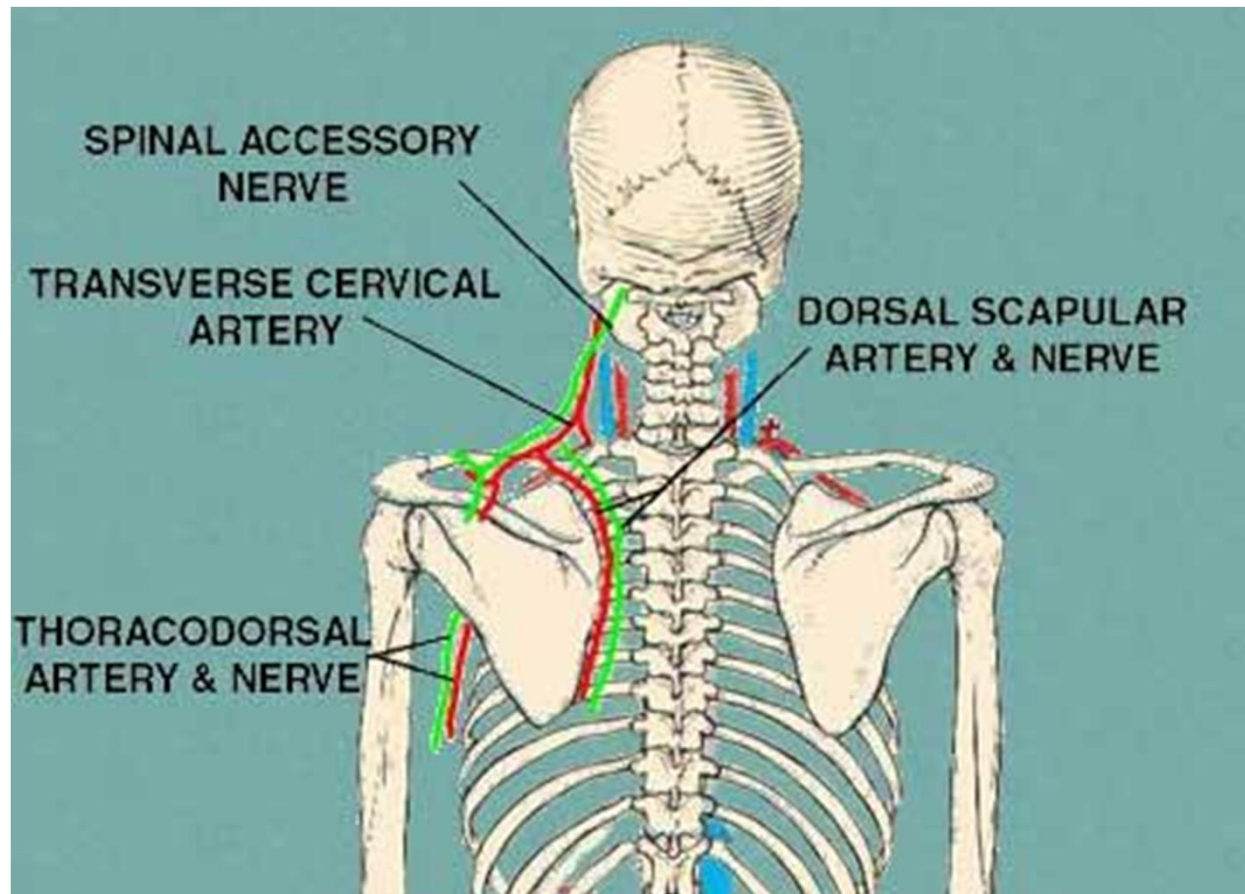
Trigonum Grynfelti/Tetragon Krausei



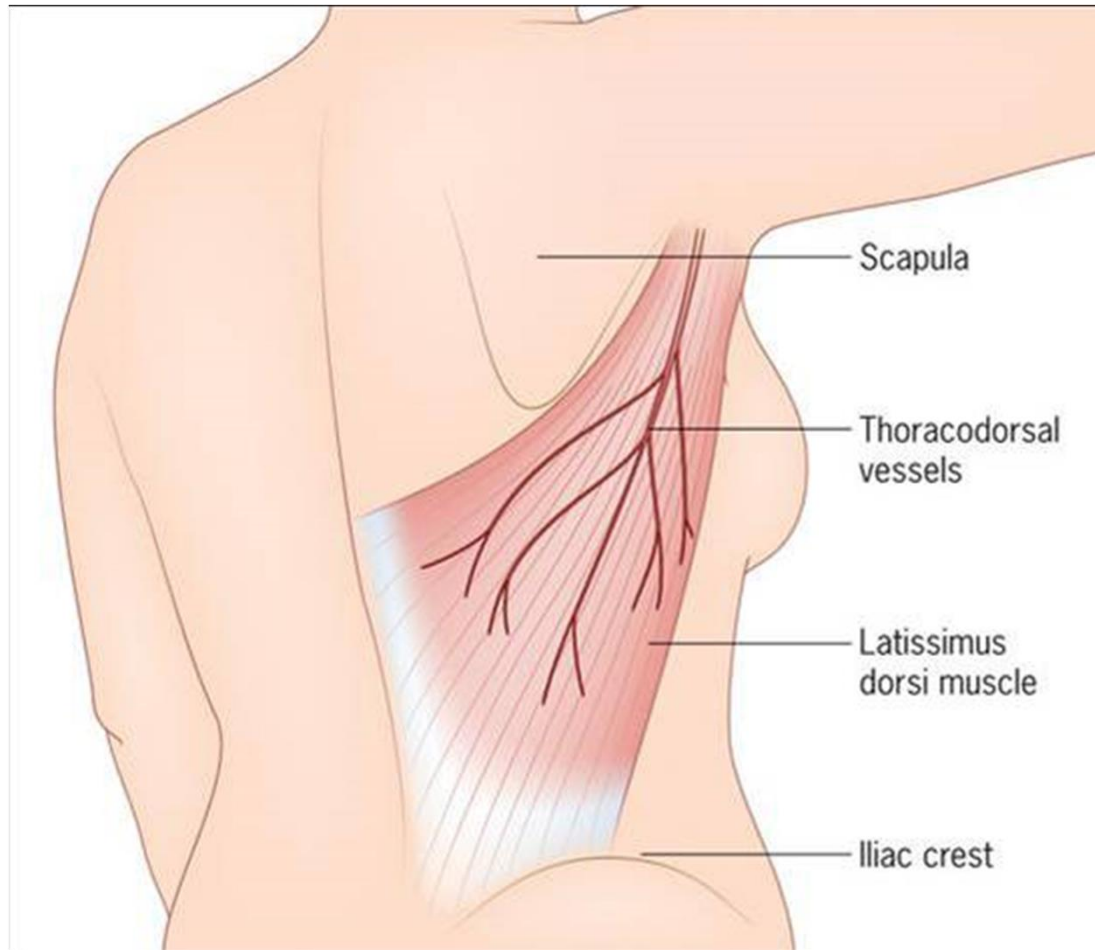
n. occipitalis major, minor et tertius, a.
occipitalis



a. cervicalis profunda, a.
transversa coli, n. dorsalis
scapulae, n. accessorius



a. + n. thoracodorsalis



Thank you for your attention!



- **Obrázky:**
- **Atlas der Anatomie des Menschen/Sobotta. Putz,R., und Pabst,R. 20. Auflage. München:Urban & Schwarzenberg, 1993**
- **Netter: Interactive Atlas of Human Anatomy.**
- **Naňka, Elišková: Přehled anatomie. Galén, Praha 2009.**
- **Čihák: Anatomie I, II, III.**
- **Drake et al: Gray's Anatomy for Students. 2010**

