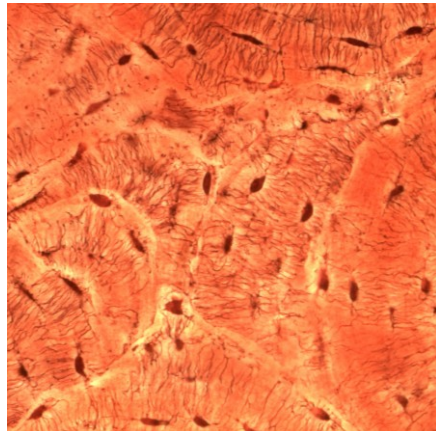
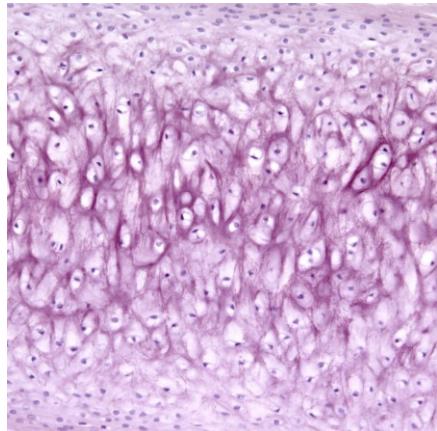
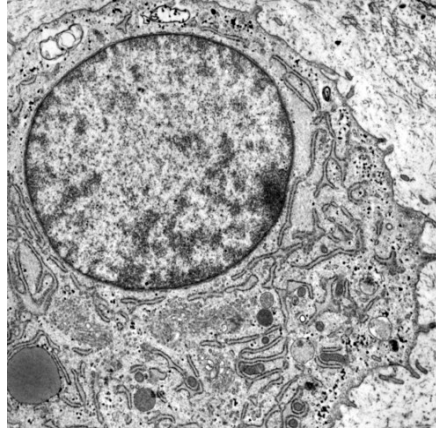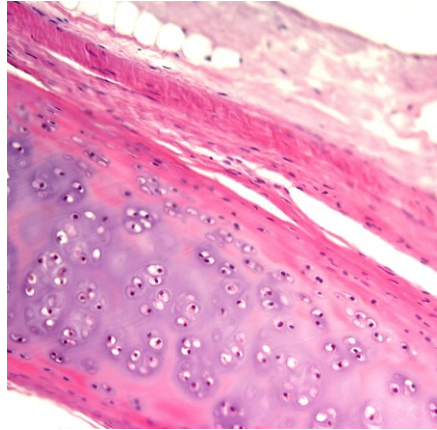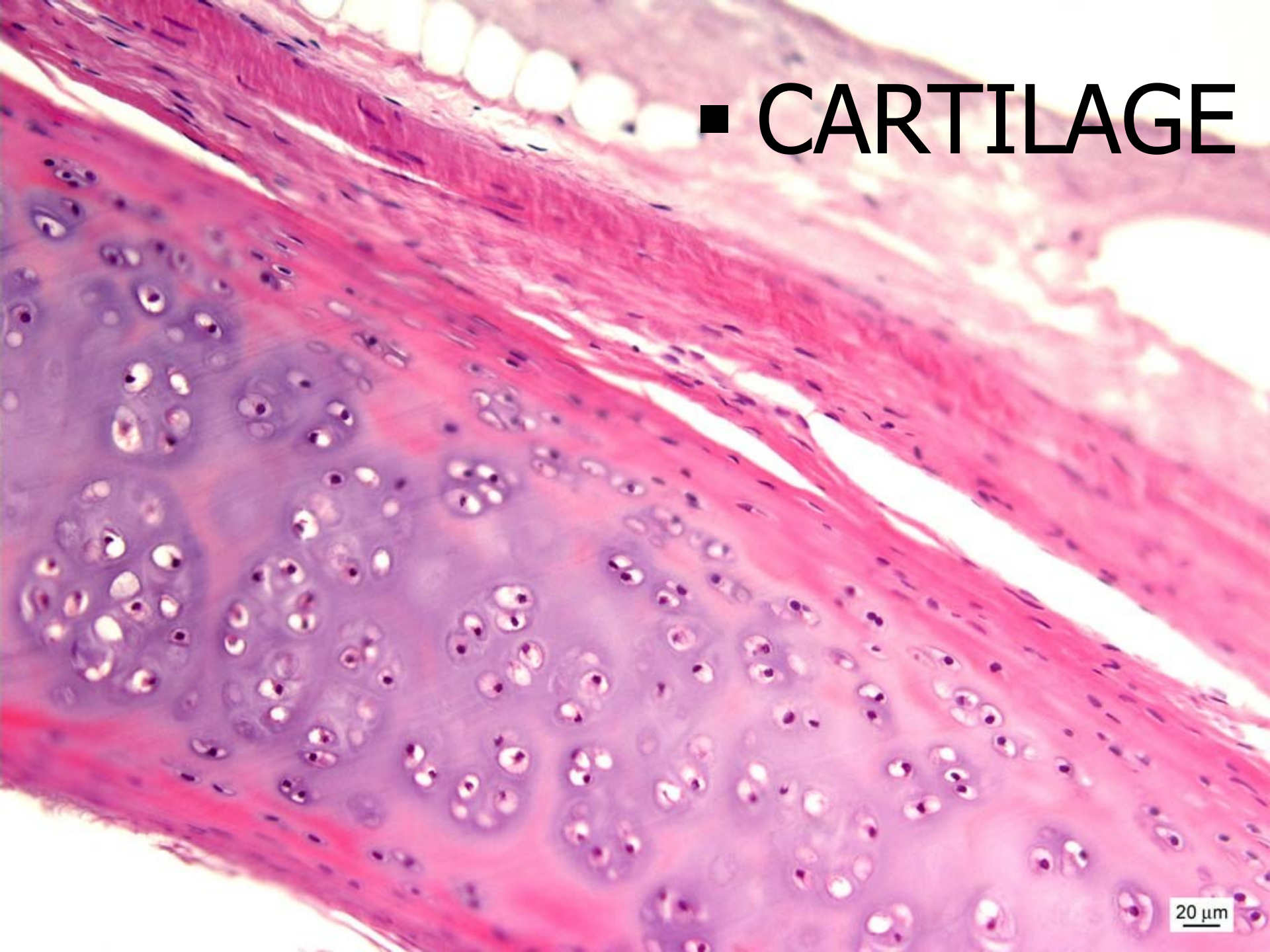
CARTILAGE AND BONE

Petr Vaňhara, PhD

Department of Histology and Embryology,
Faculty of Medicine MU

pvanhara@med.muni.cz

■ CARTILAGE



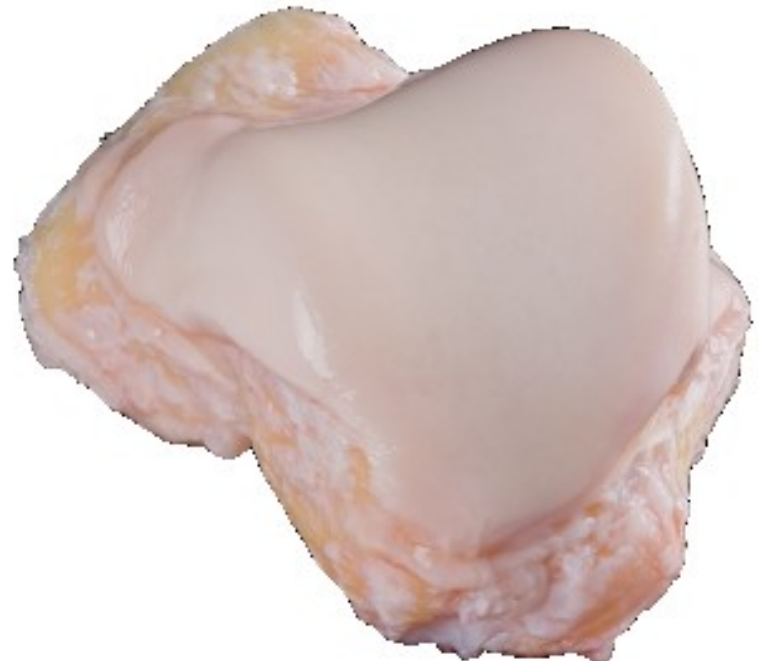20 μ m

CARTILAGE

General features:

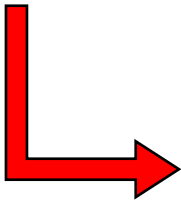
- **specialized connective tissue** with continuous ECM
- flexible, mechanically resistant
- avascular, non-innervated
- support of soft tissues - trachea, larynx
- skeletal support - costal cartilages
- diarthrosis - joints
- bone growth

1. **cells**
2. **fibrils**
3. **amorphous ground substance**



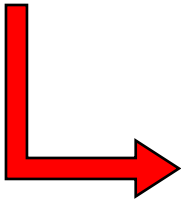
CARTILAGE – COMPOSITION AND STRUCTURE

- Perichondrium – connective tissue around cartilage (except joints)




Nutrition
Growth

- Extracellular matrix – water, proteoglycans and collagen fibrils

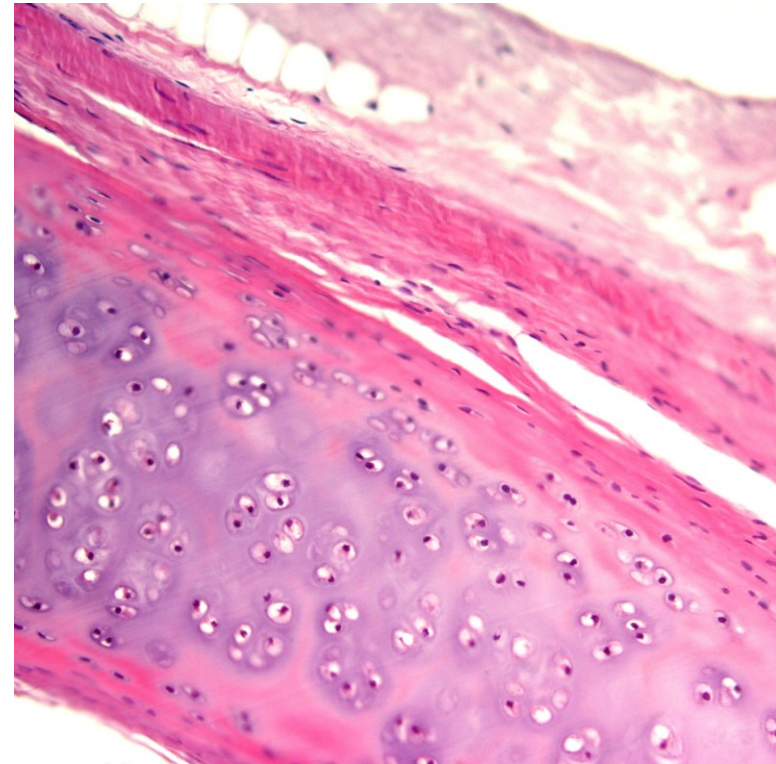


Solid consistence
Pressure elasticity

- Cells of cartilage - chondroblasts, chondrocytes



Growth
ECM production



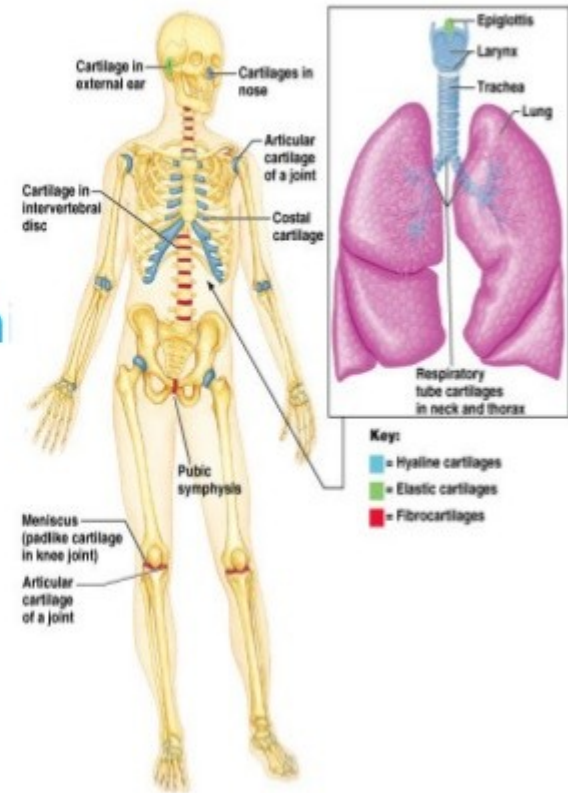
Hyaline

Elastic

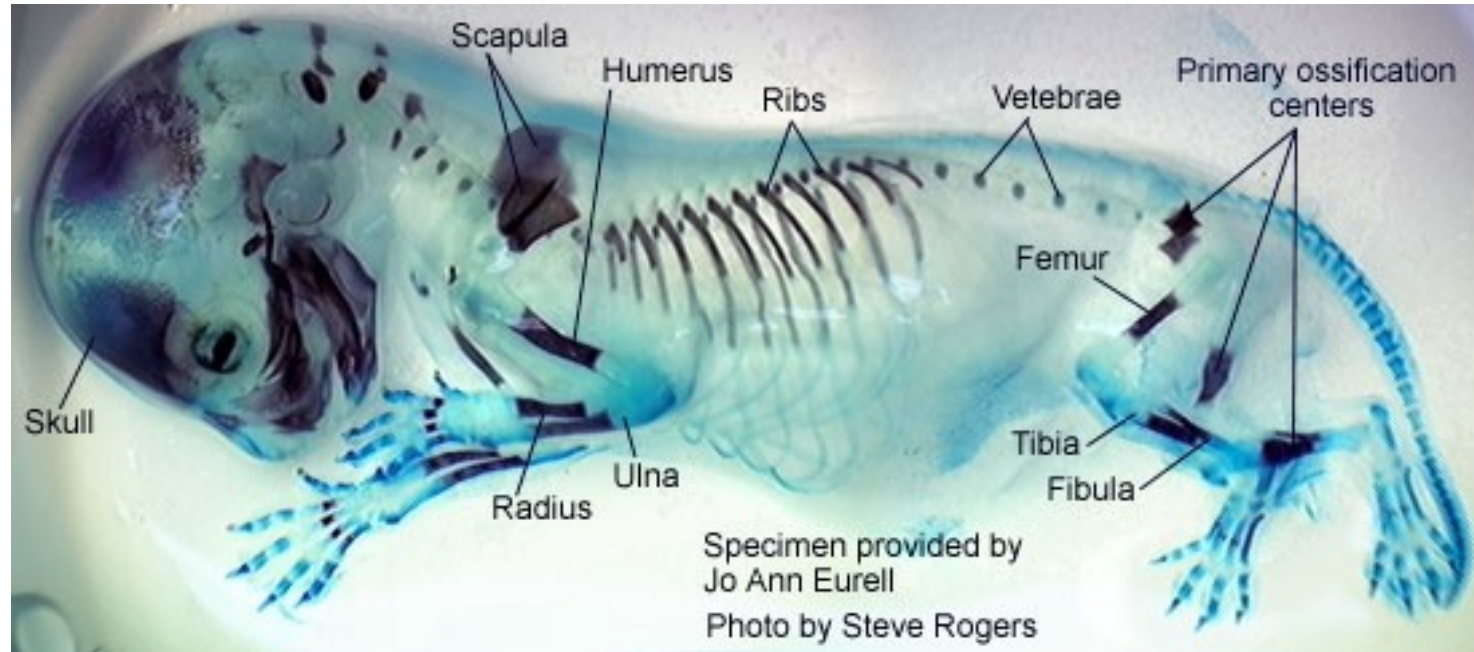
Fibrous

cartilage in adults

- Nose
 - Joint surfaces
 - Costal
 - Larynx - voice box
 - rings of trachea & bronch
-
- External ear
 - Epiglottis
 - Eustachian tube
-
- IVDs
 - Pubic symphysis
 - meniscus in knee joint



Hyaline



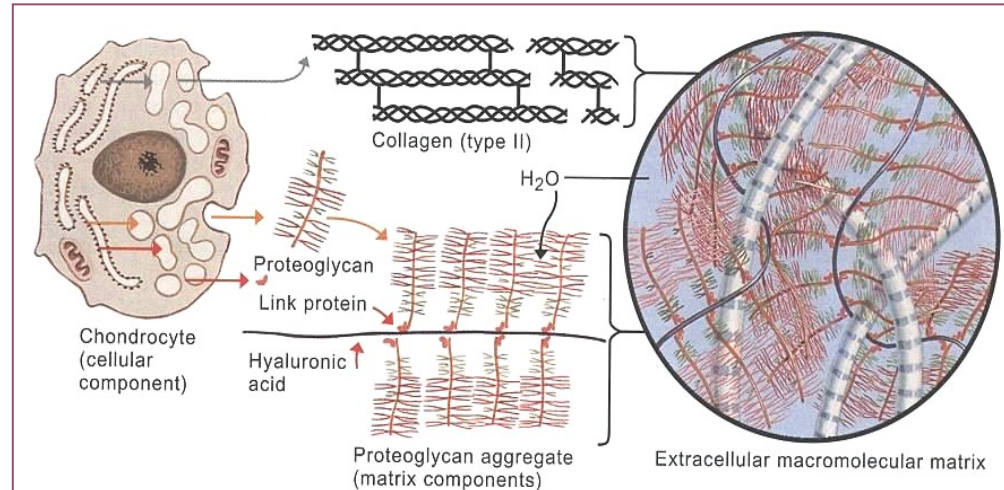
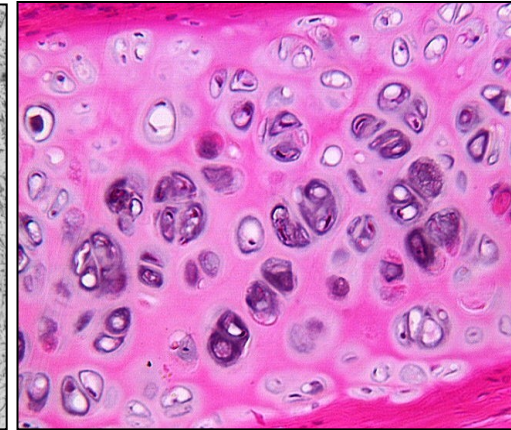
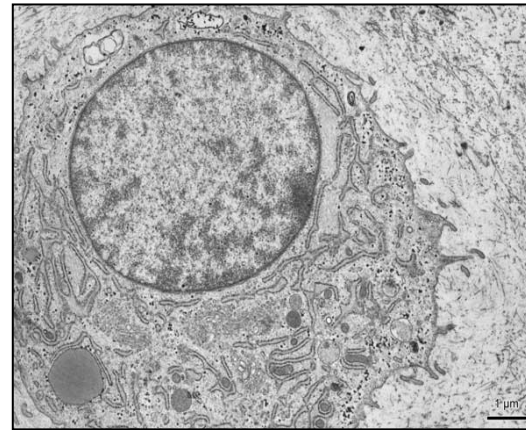
Alcian Blue&Alizarin Red

- most abundant
- temporary embryonal/fetal skeleton
- epiphyseal growth plate
- articulation (joints) respiratory passages

CELLS OF CARTILAGE

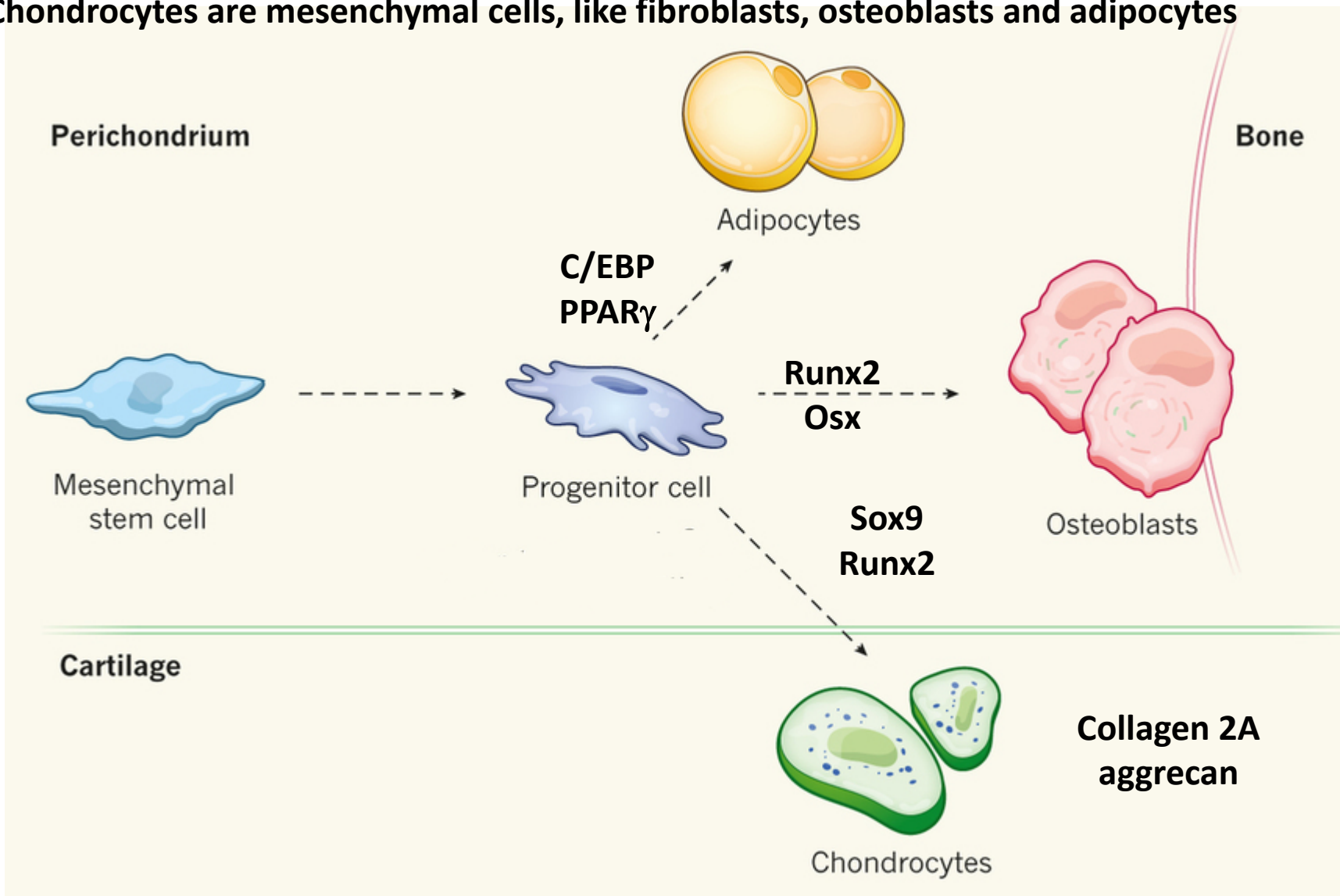
▪ Chondroblasts and chondrocytes

- mesenchymal origin
- typical ultrastructure of proteosynthetically active cells
- production of extracellular matrix
- interstitial proliferation
- isogenetic groups, lacunae



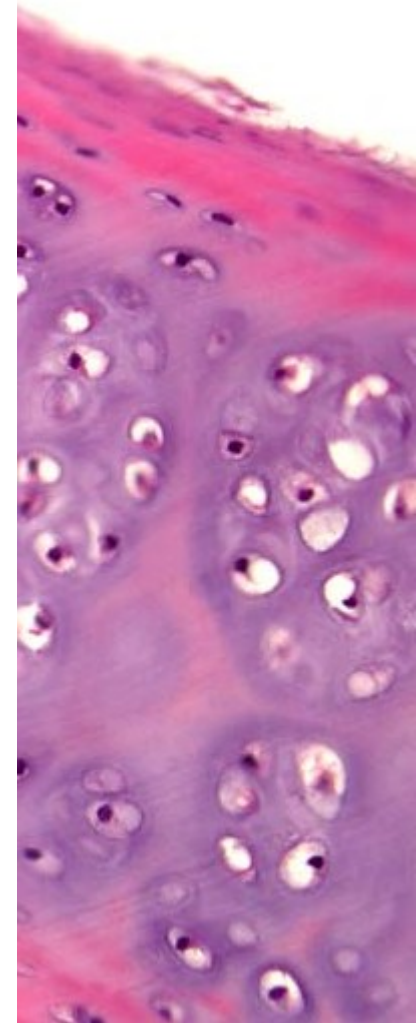
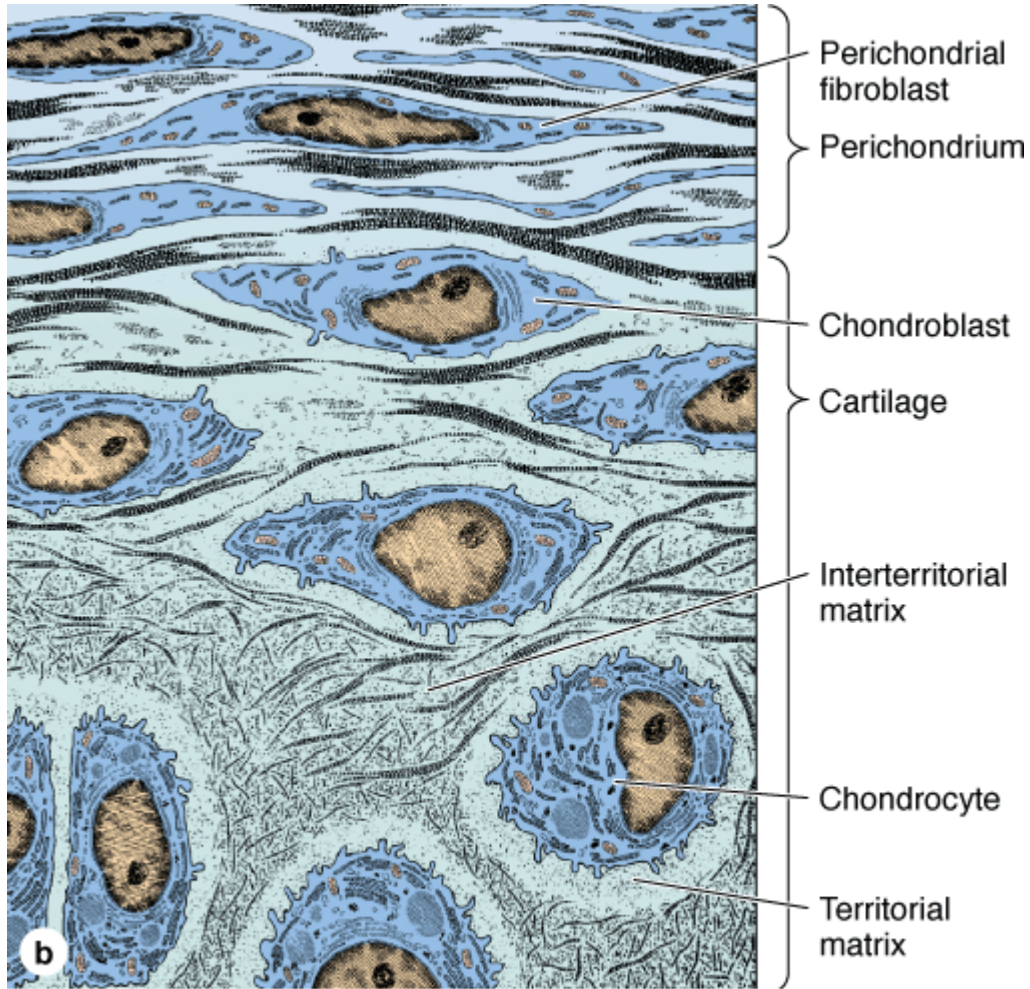
DIFFERENTIATION OF CHONDROBLASTS

Chondrocytes are mesenchymal cells, like fibroblasts, osteoblasts and adipocytes



- Chondroblasts proliferate, acquire capability to produce huge amounts of ECM and differentiate to chondrocytes.
- Chondrocytes are postmitotic, fully differentiated cells

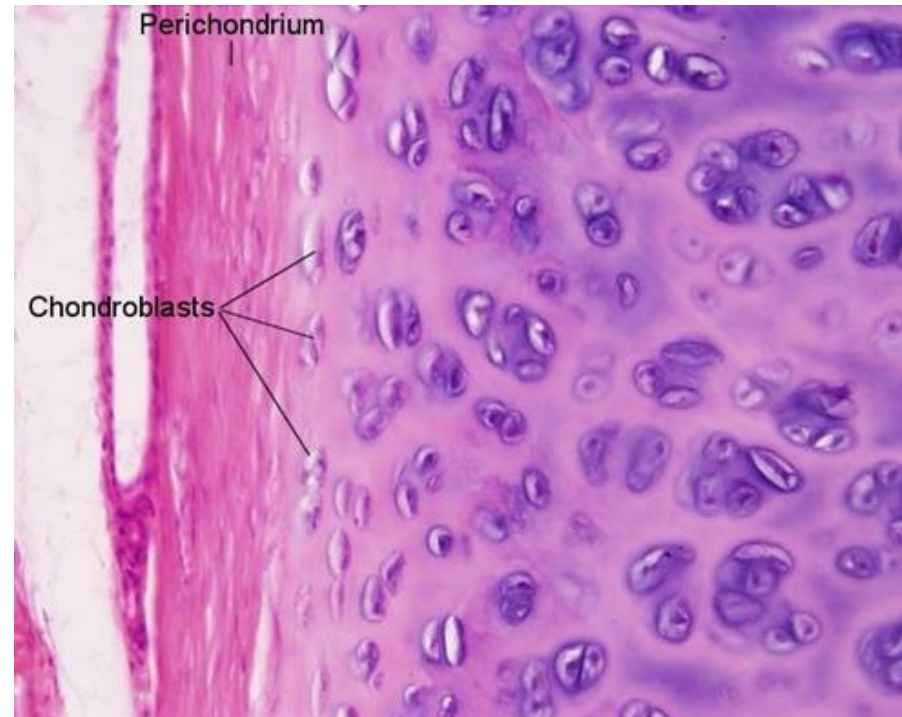DIFFERENTIATION OF CHONDROBLASTS



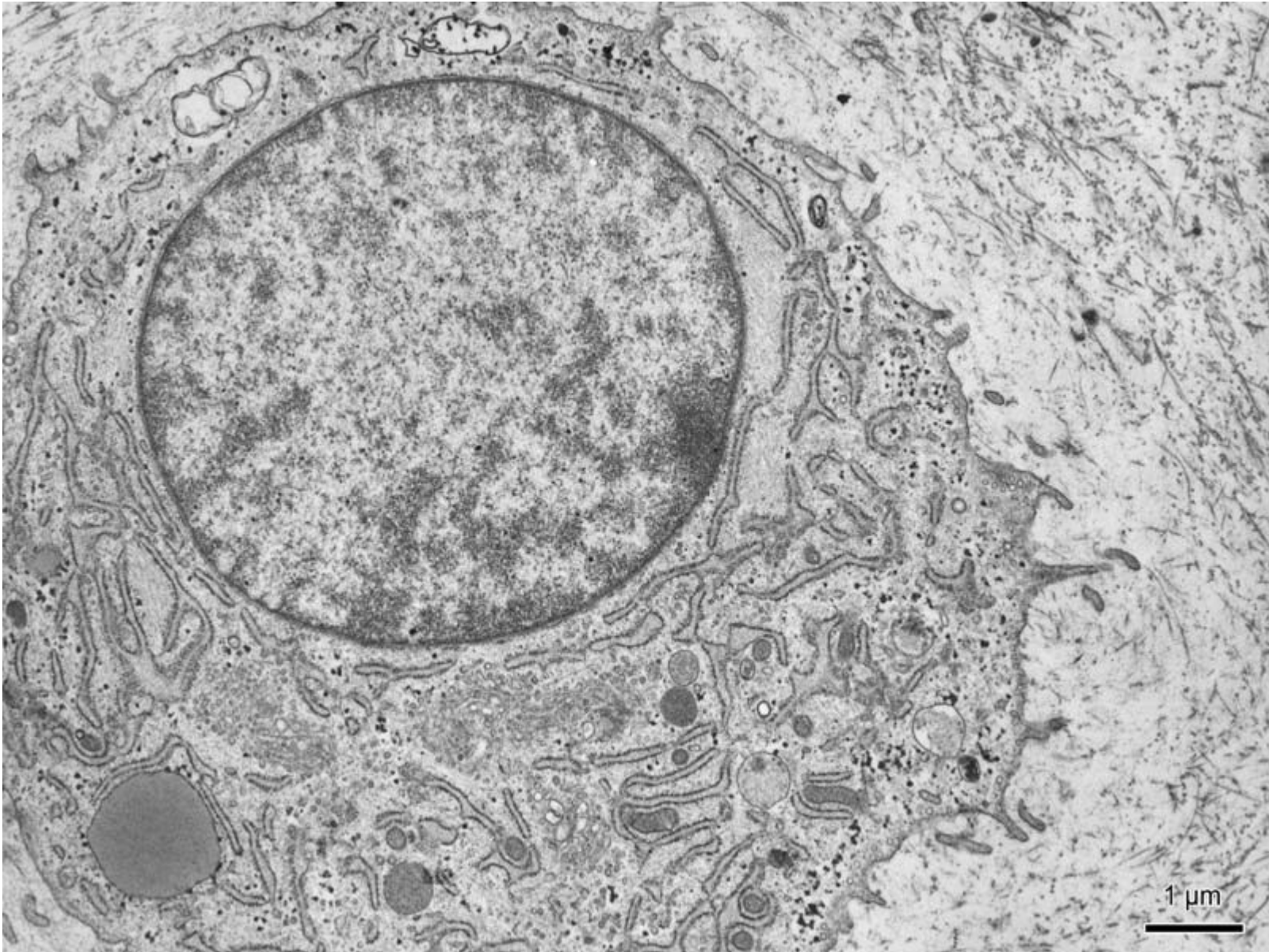
Source: Mescher AL: *Junqueira's Basic Histology: Text and Atlas, 12th Edition*: <http://www.accessmedicine.com>
Copyright © The McGraw-Hill Companies, Inc. All rights reserved.

ULTRASTRUCTURE OF CHONDROBLASTS

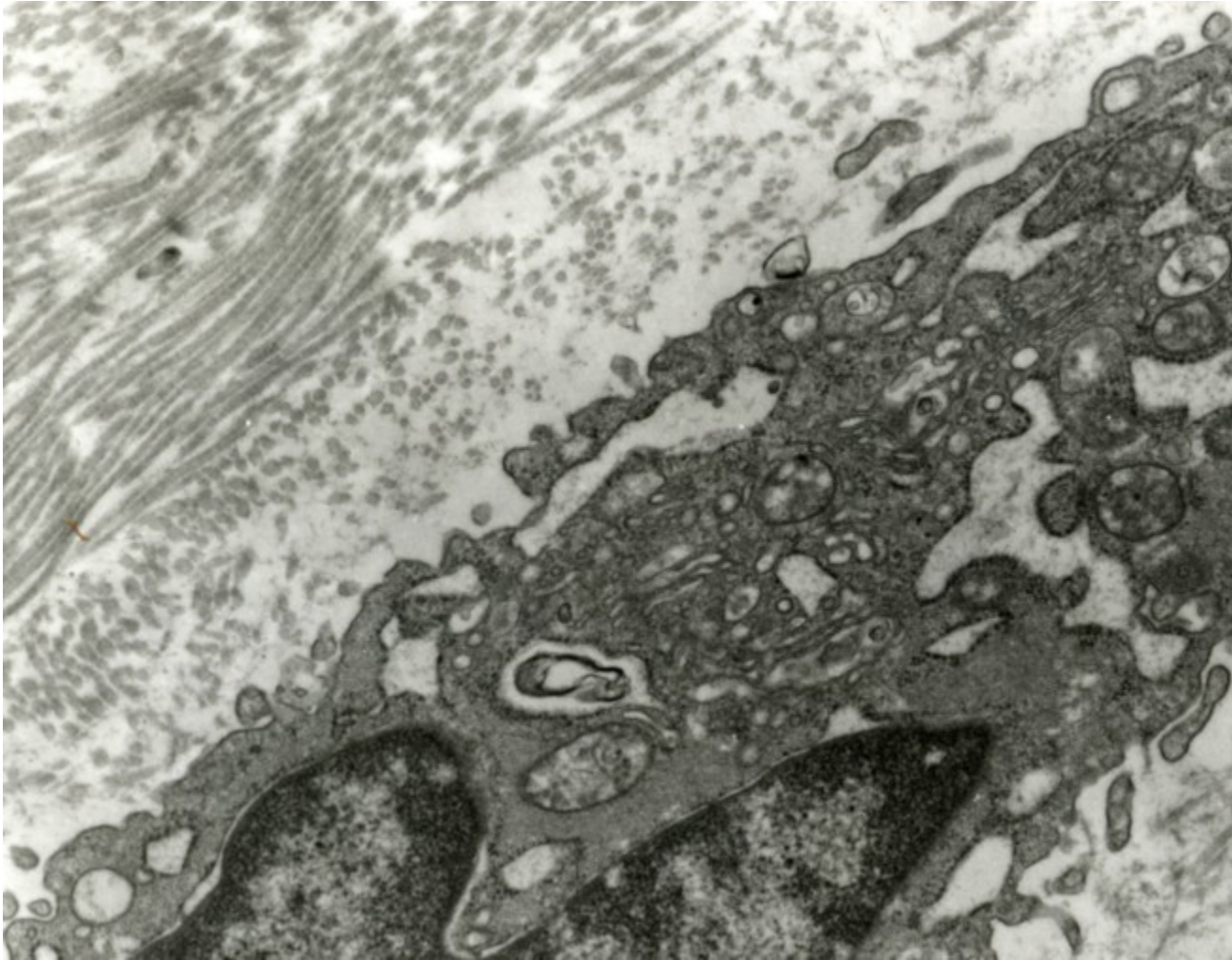
- oval → round cells
- rich in organelles, especially rER and GA
- glycogen granules (anaerobic metabolism)
- occasionally lipid droplets



ULTRASTRUCTURE OF CHONDROBLASTS



ULTRASTRUCTURE OF CHONDROBLASTS




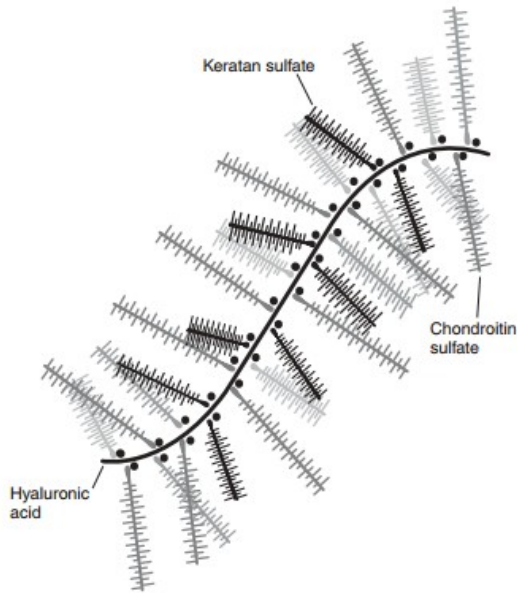
- Extracellular matrix

glycosaminoglycans

proteoglycans

fibers

water

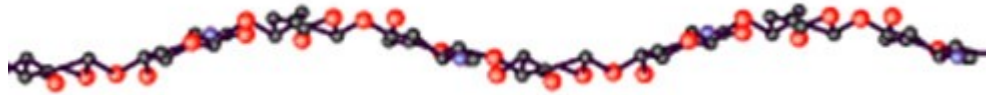

biomechanical properties

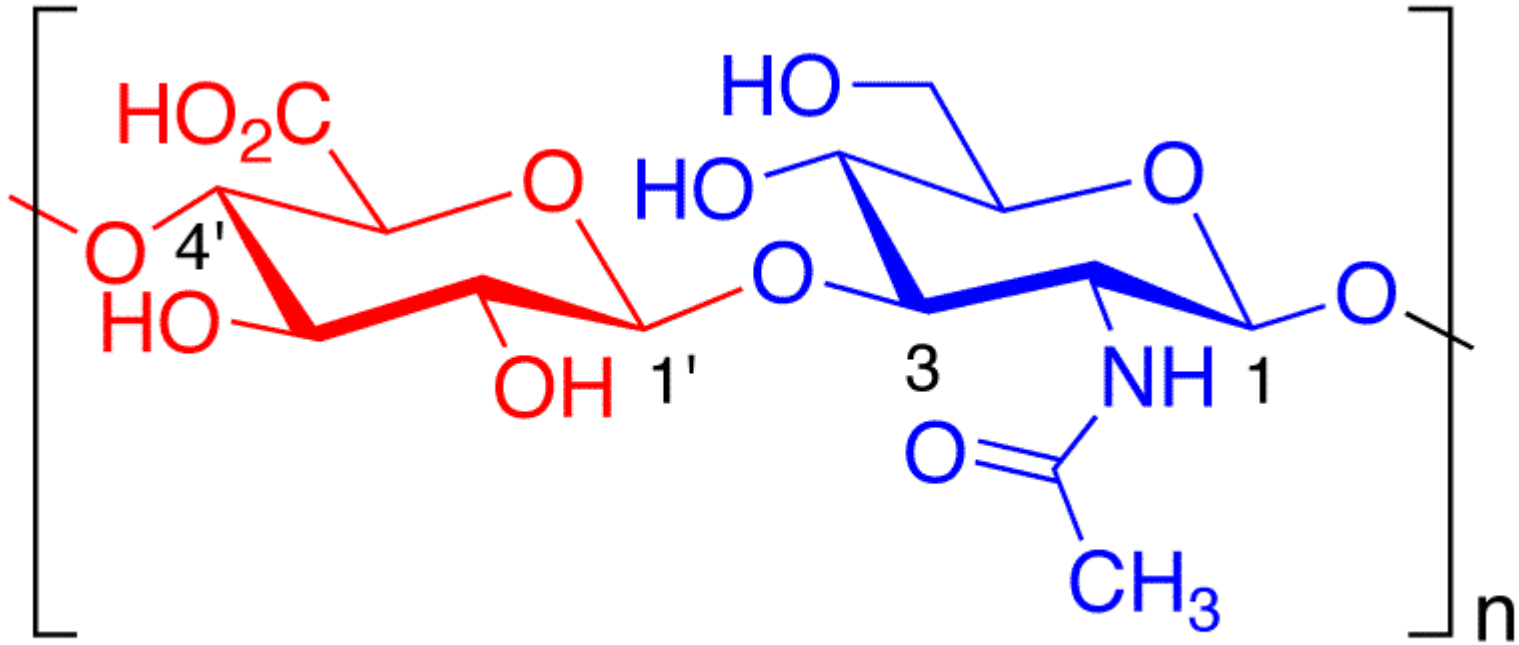
GLYCOSAMINOGLYCANS IN CARTILAGE

linear unbranched polysaccharides containing a repeating disaccharide unit:

1. *N*-acetylgalactosamine (GalNAc) or *N*-acetylglucosamine (GlcNAc)
2. uronic acid (glucuronate (GlcA)) or iduronate.



hyaluronic acid



Glucuronic Acid N-Acetyl-D-glucosamine

GLYCOSAMINOGLYCANS IN CARTILAGE

Glycosaminoglycan

Localization

Hyaluronic acid

Umbilical cord, synovial fluid, fluid of corpus vitreum, cartilage

Chondroitinsulphate

Cartilage, bone, cornea, skin, notochord, aorta

Dermatansulphate

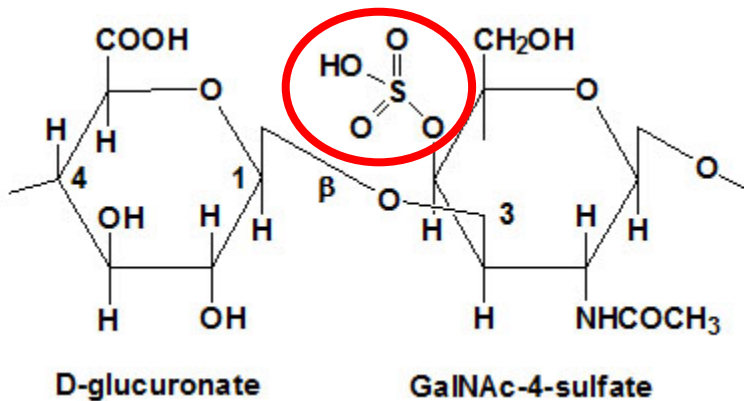
Skin, ligaments, adventitia of aorta

Heparansulphate

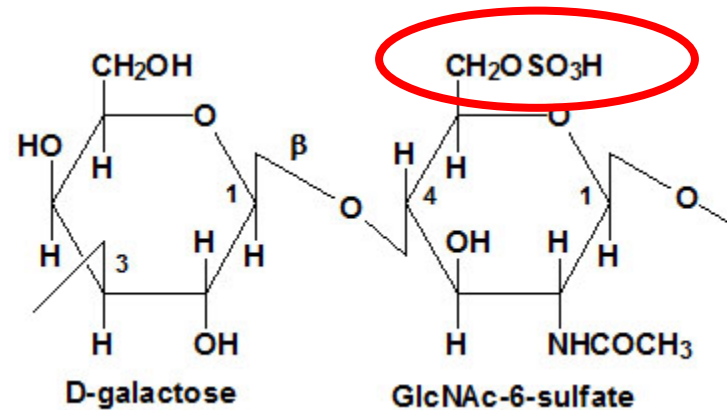
Aorta, lungs, liver, basal membranes

Keratansulphate

Iris, cartilage, nucleus pulposus, anulus fibrosus



Chondroitinsulphate



Keratansulphate

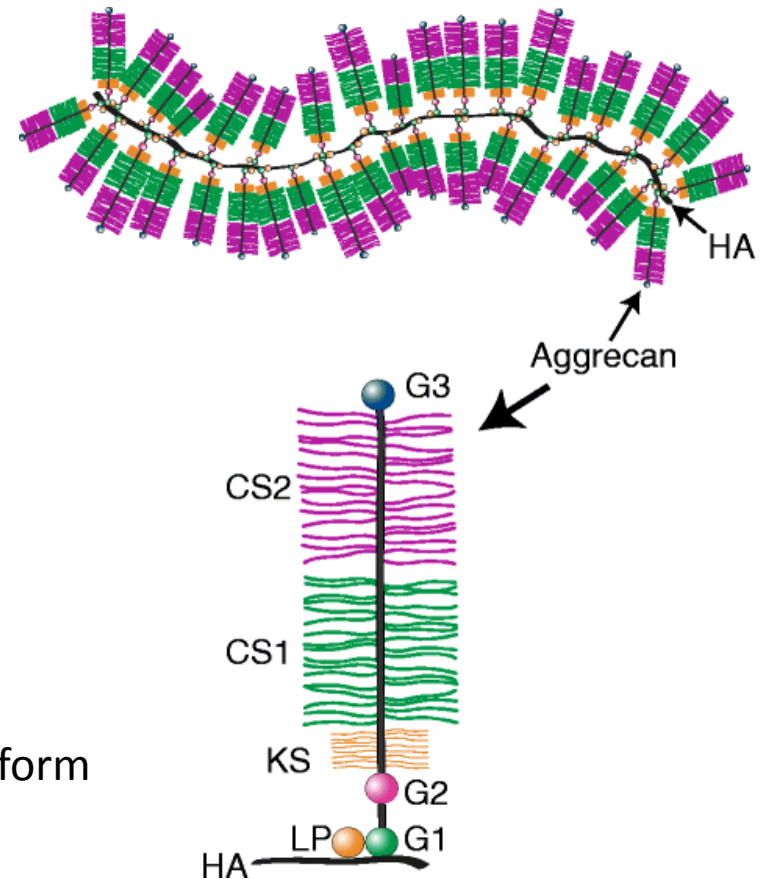
PROTEOGLYCANS AND FIBERS

- **proteoglycans**

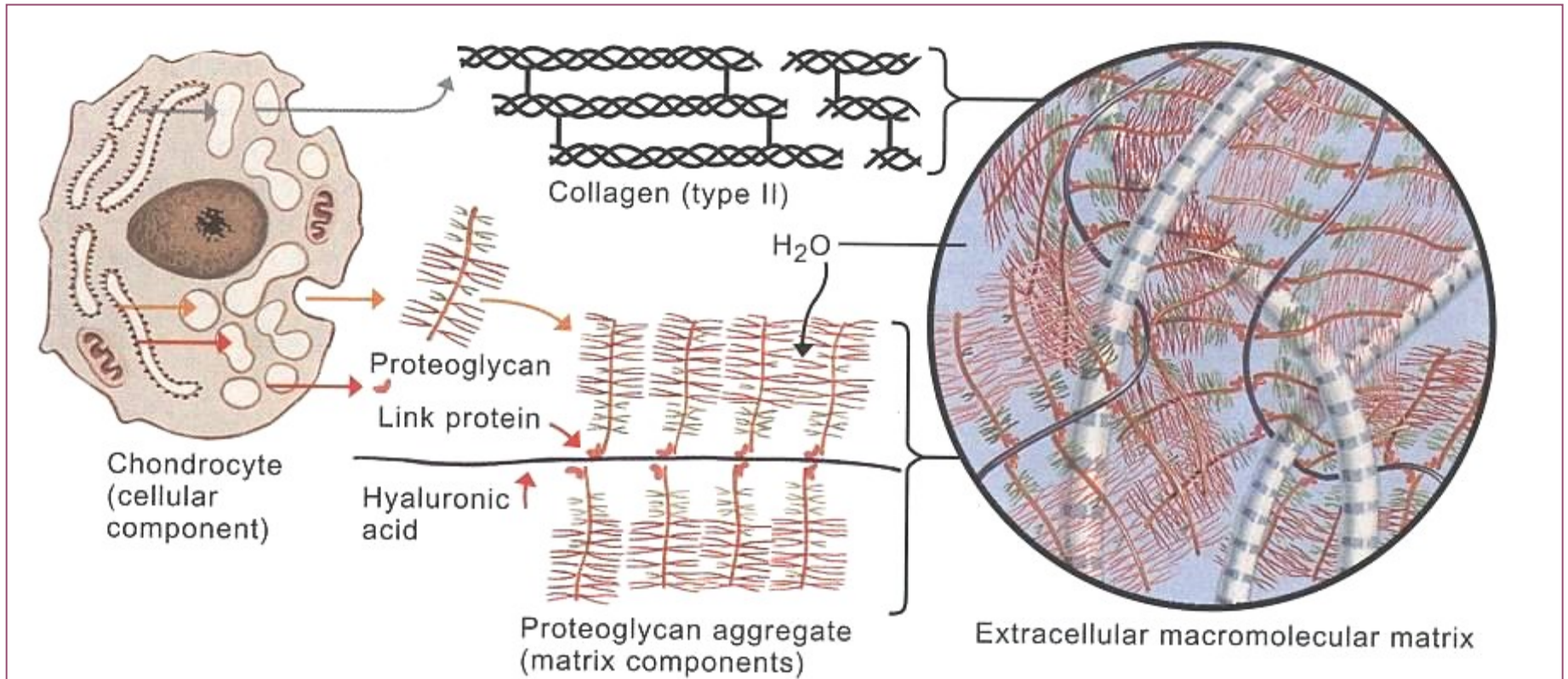
- protein + dominant linear saccharide component
- proteoglycan aggregates
- water-binding – 80%, volume dependent of hydration
 - **aggrecan (cartilage)**
 - syndekan
 - fibroglykan

- **collagen fibrils**

- col II + col IX/XI
- thin fibrils (15-20 nm → no striation) that do not form fibers like col I
- interconnected with perichondrium
- elastic fibers



TISSUE ARCHITECTURE OF CARTILAGE ECM

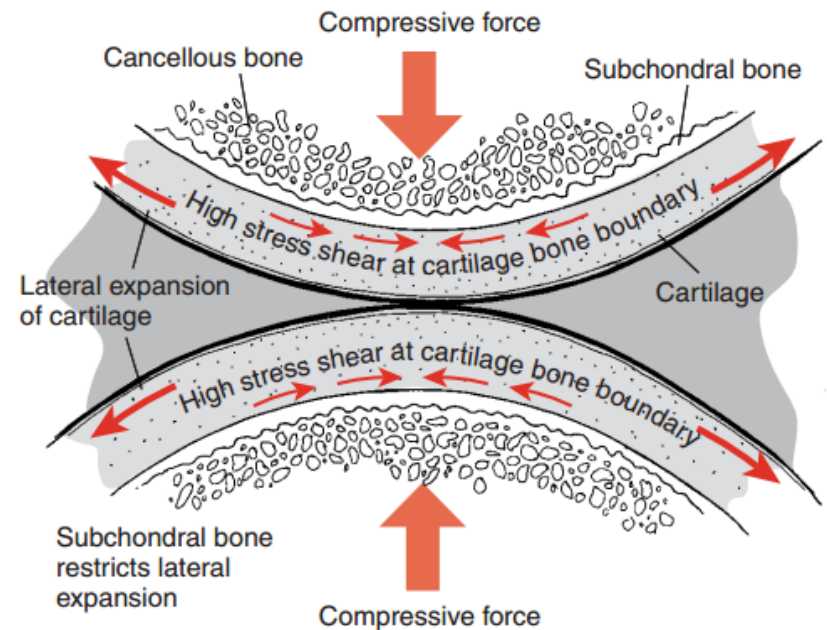


transduction of biochemical and biomechanical signals

TISSUE ARCHITECTURE OF CARTILAGE ECM

- **pressure elasticity**

- proteoglycans – polyanionic (COO^- , $\text{SO}_4^{\text{II}-}$)
- expansion prevented by collagen fibrils
- repulsion forces



- **biphasic model of cartilage** conditioned by ECM composition

- proteoglycans, collagen, cells, and lipids constitute the solid phase of the mixture
- interstitial fluid that is free to move through the matrix fluid phase)
- under impact loads, fluid flows through the framework, until the cartilage start to behave as a single-phase, incompressible, elastic solid - the fluid does not flow
- after load release, fluid returns
- nutritive aspect

TISSUE ARCHITECTURE OF CARTILAGE ECM

- **synovial cartilage**

I. tangential (superficial) zone

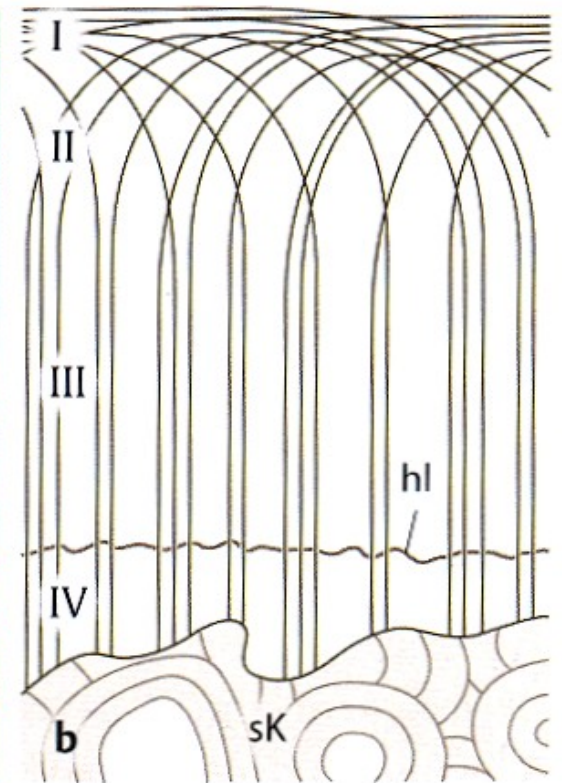
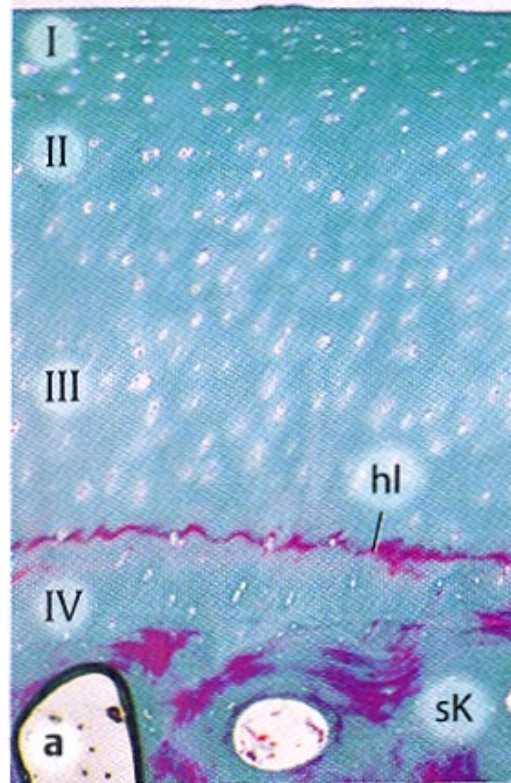
II. transitional zone

III. radial (deep) zone

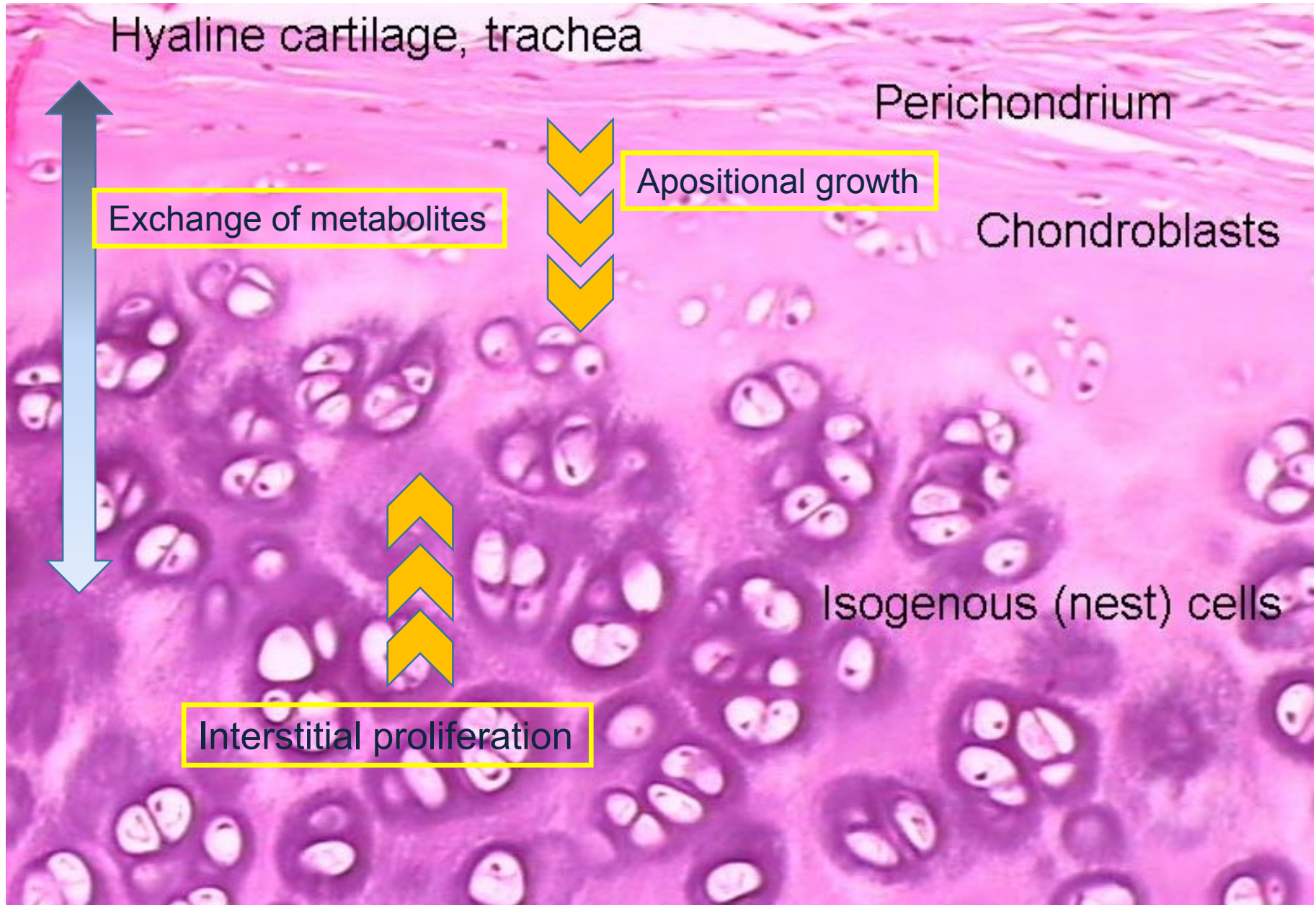
tide mark

I. mineralized cartilage zone

subchondral bone

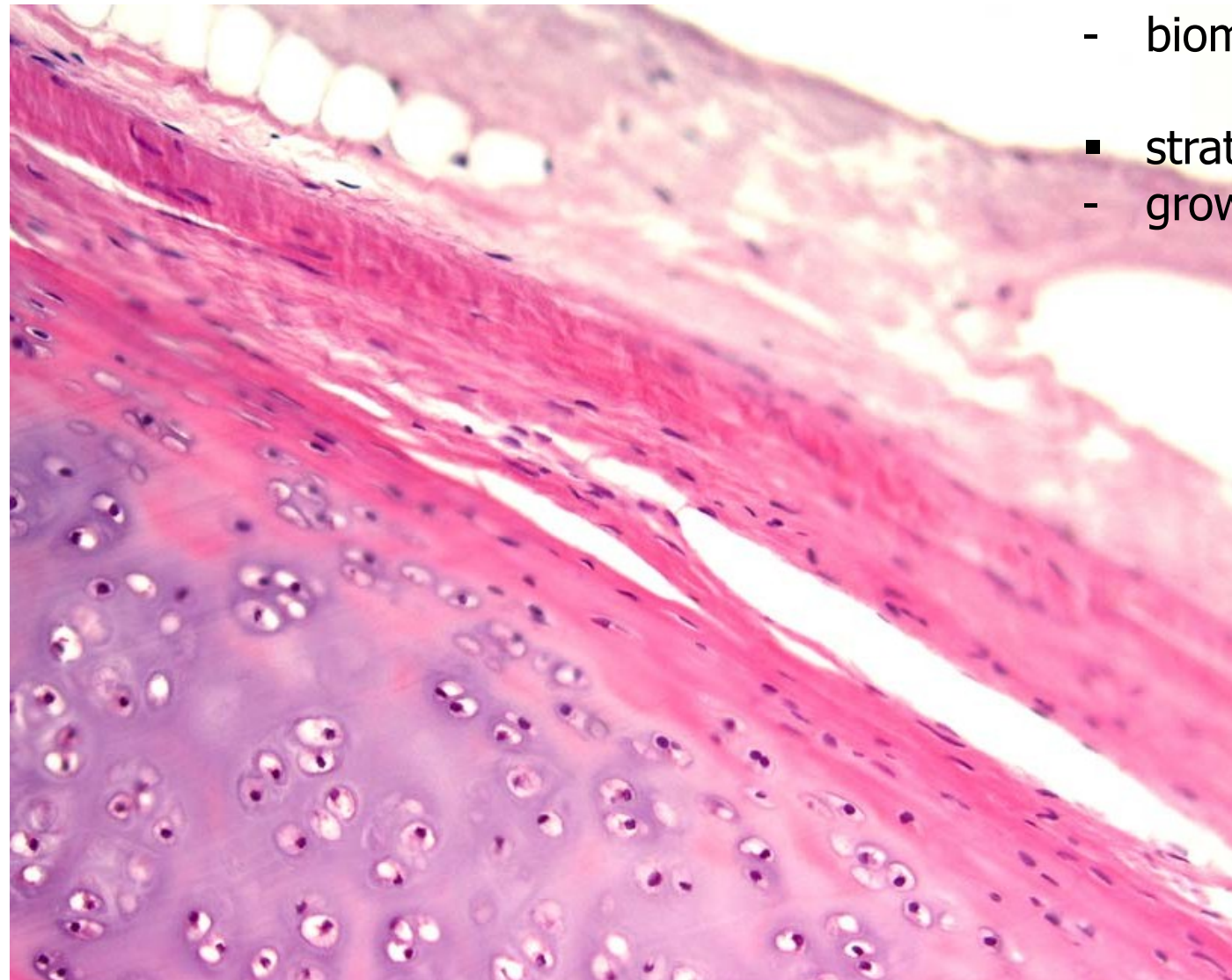


NUTRITION AND GROWTH



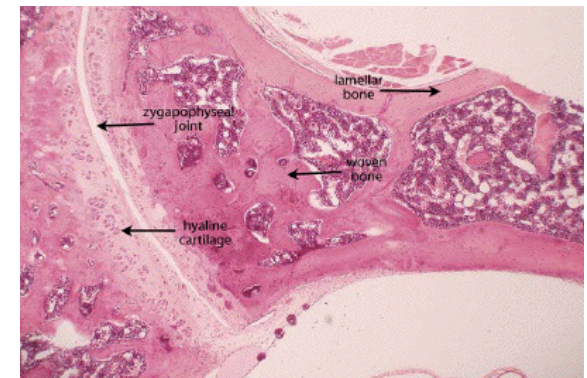
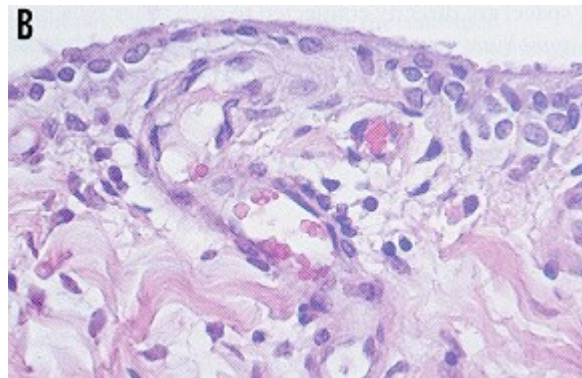
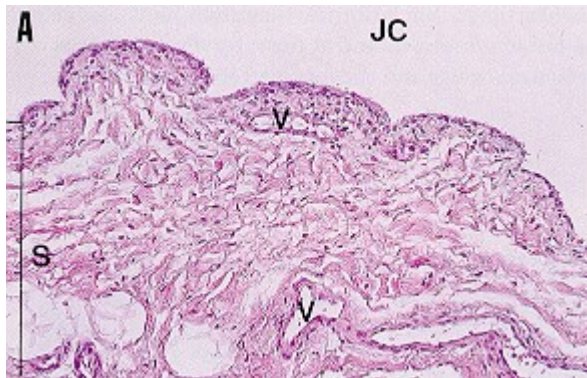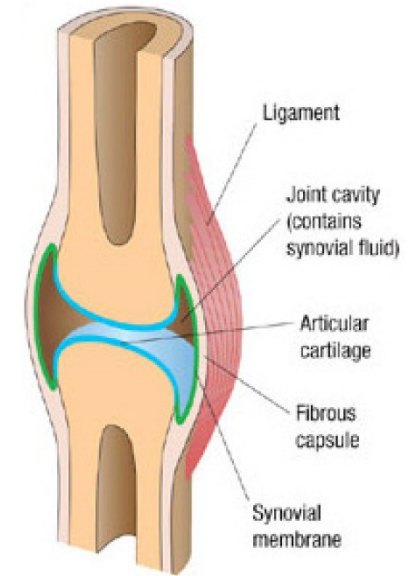
PERICHONDRIUM

- stratum fibrosum
 - biomechanics
- stratum chondrogenicum
 - growth



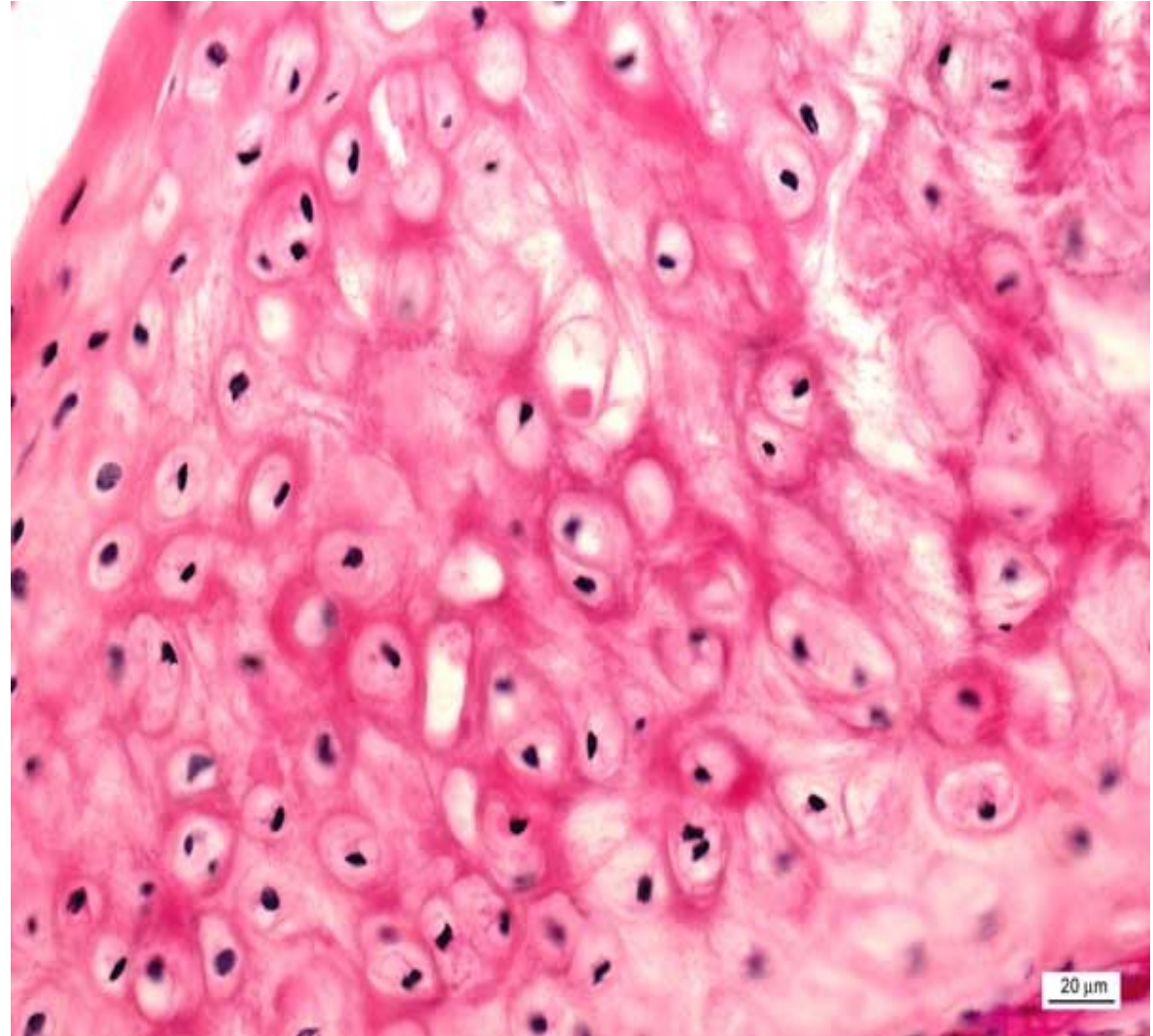
SYNOVIUM

- *membrana fibrosa*
 - dense collagen c.t.
- *membrana synovialis*
 - intima, subintima
 - folds extending to the joint cavity
 - numerous blood and lymphatic vessels, nerves
 - discontinuous cell layers (synovialocytes)
 - basal membrane and intercellular junctions absent - **not an epithelium**: mesenchymal (c.t.) origin
 - synovial fluid rich in hyaluronans
 - *bursae synoviales, vaginae tendineum*



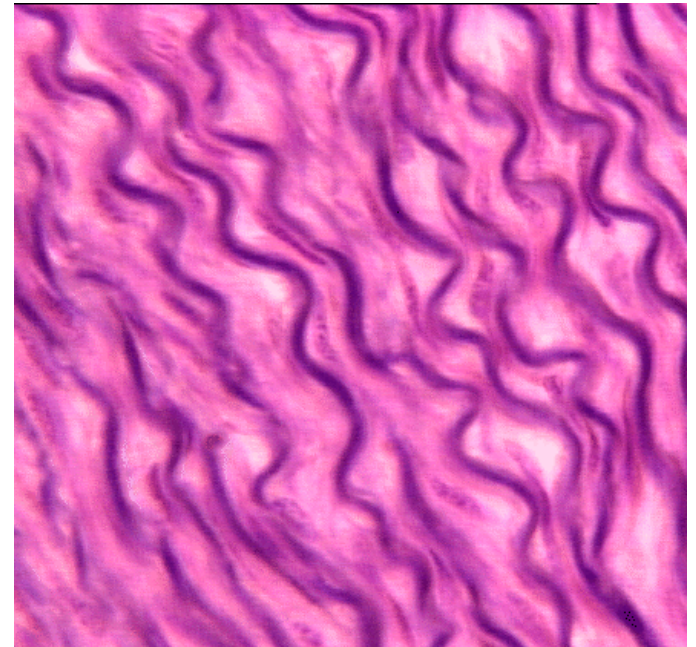
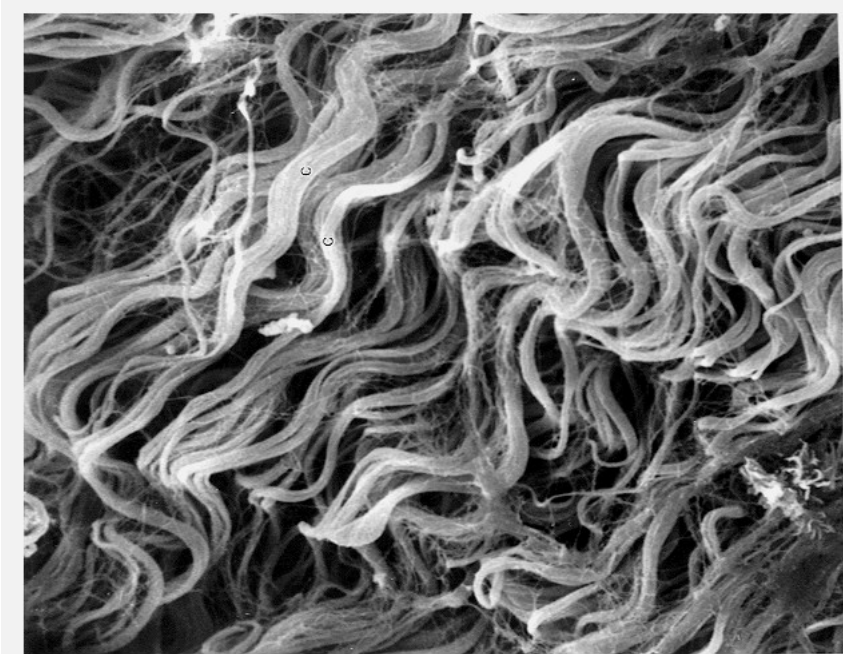
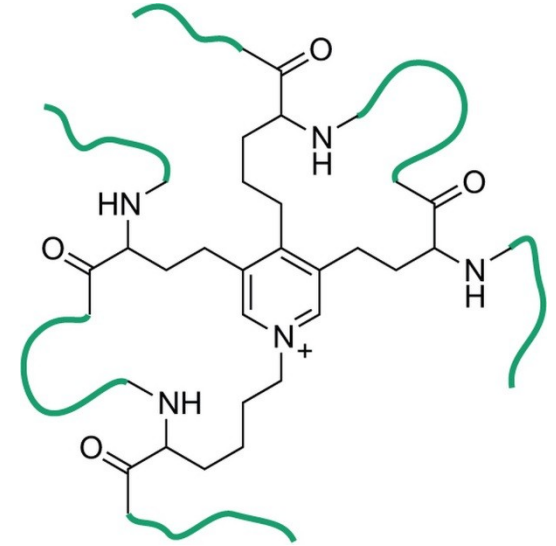
ELASTIC CARTILAGE

- acidophilic elastic fibers dispersed in matrix
- no isogenetic groups
- auricula, meatus, larynx, epiglottis

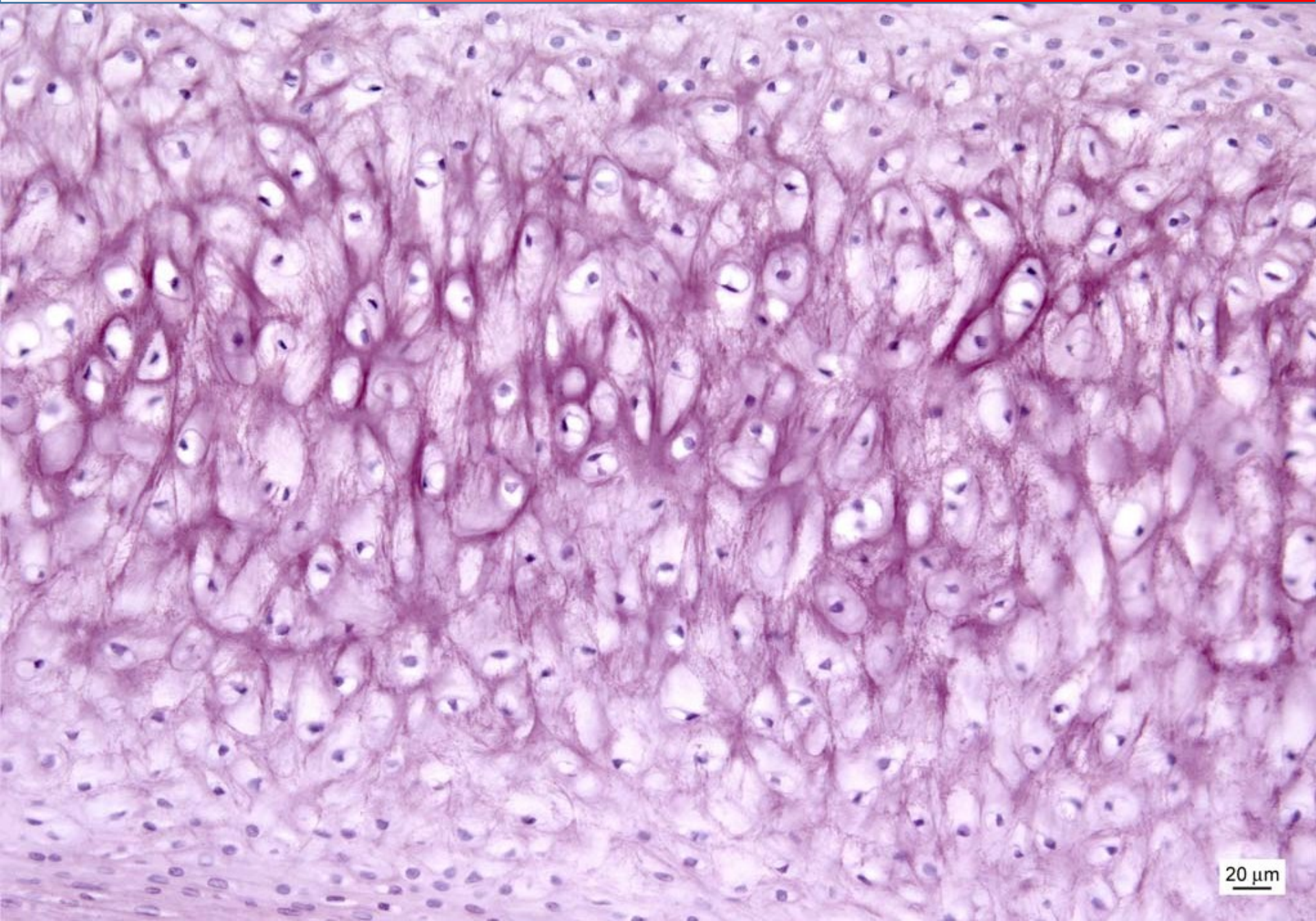


ELASTIC FIBERS

- less abundant than collagen
- polymer – tropoelastin
- minimal tensile resistance, loss of elasticity if overstretched
- reduction of hysteresis = allow return back to original state after mechanic change



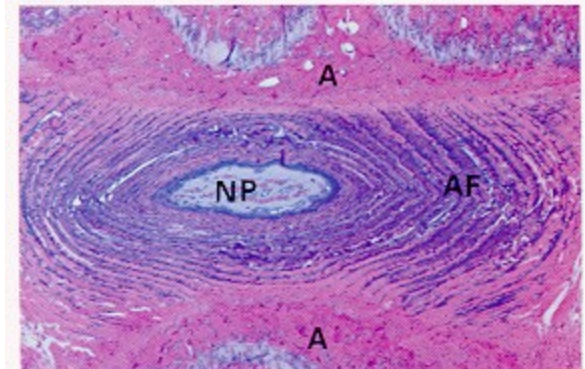
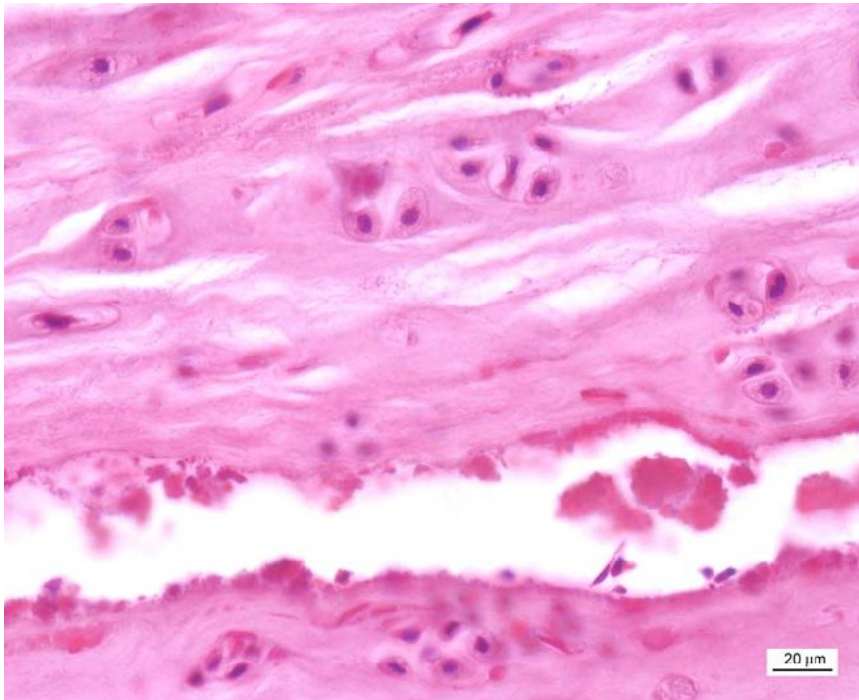
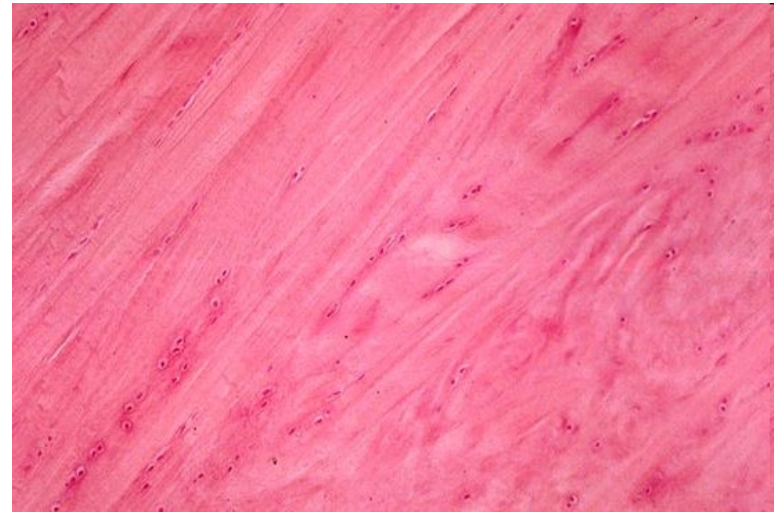
ELASTIC CARTILAGE



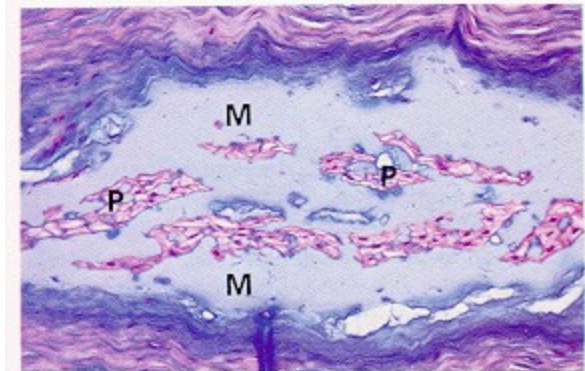
20 μ m

FIBROCARILAGE

- fibrous compound dominant – collagen I and II
– mechanical durability
- minimum of amorphous matrix-fibers visible
- intervertebral discs, symphysis pubis, articular discs, meniscus



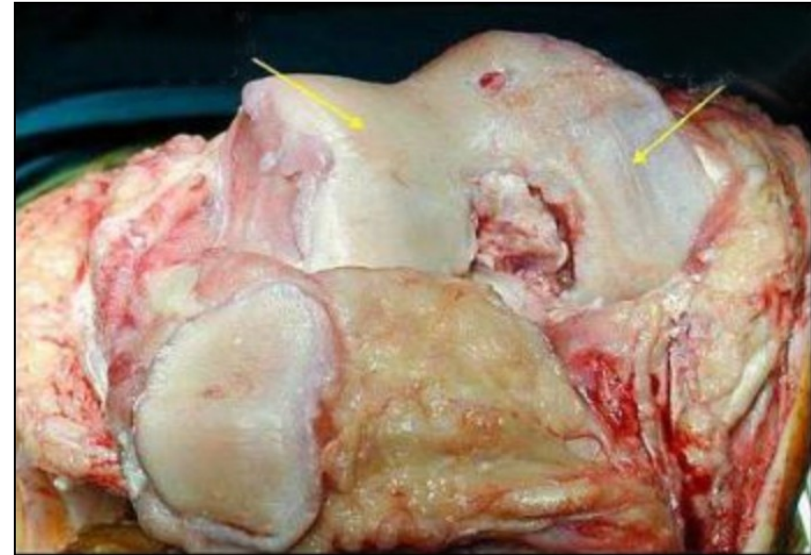
(a)



(b)


CLINICAL CORRELATION

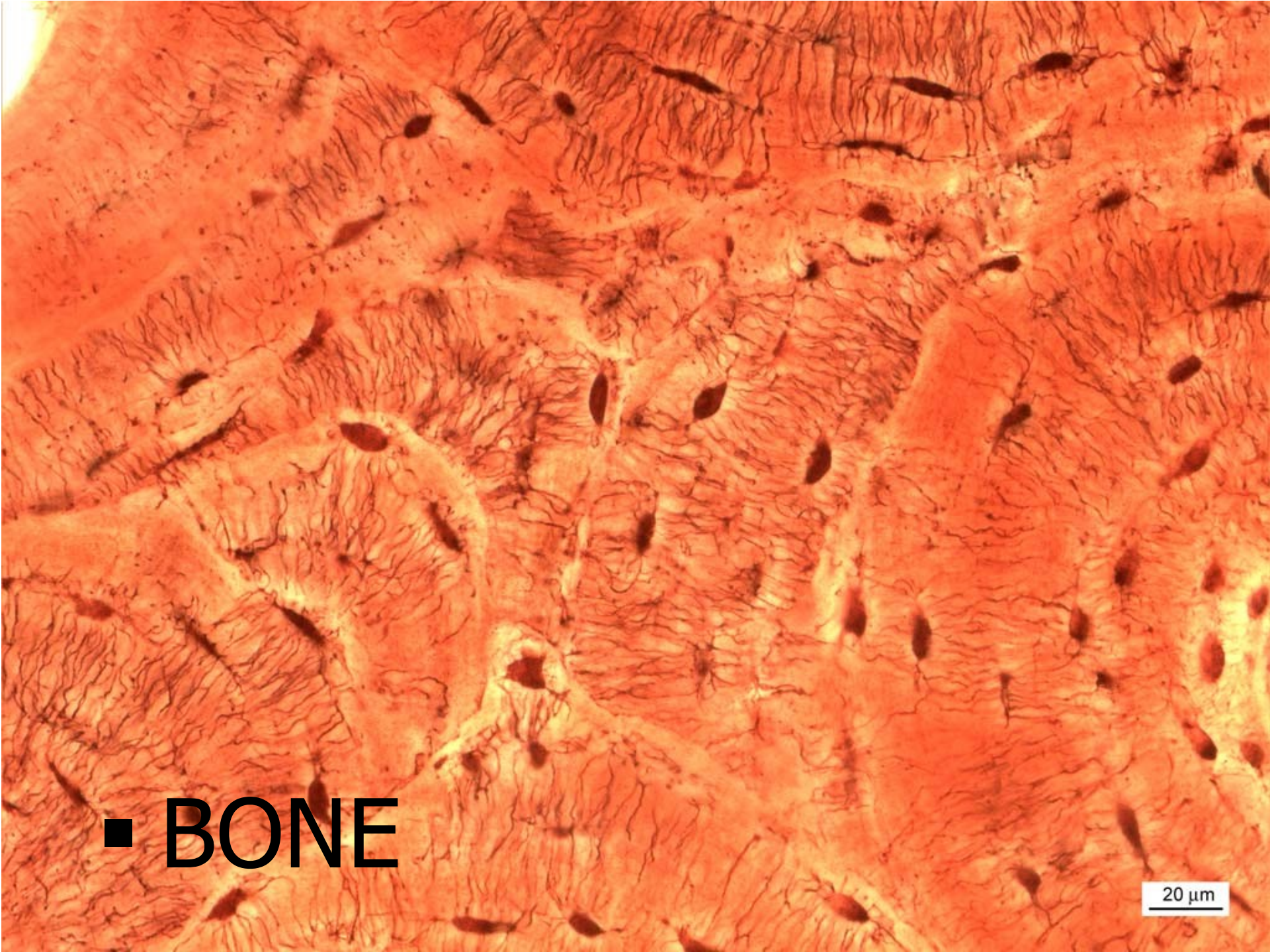- Cartilage – no innervation, no vascularization – no spontaneous regeneration
- No migration of chondrocytes to site of damage
- Initiation of other degenerative events leading to cartilage erosion (arthritis)



Therapy:

- joint mobility
- restoration of biochemical and biophysical parameters of cartilage
- prevention of further damage
- removal of damaged tissue, autologous transplantation, MSCs on biocompatible scaffolds





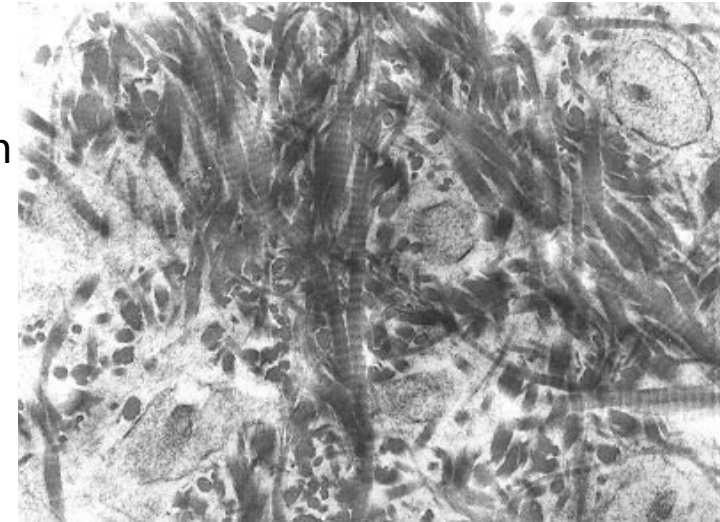
■ BONE

20 μ m

HISTOLOGICAL CLASSIFICATION OF BONE TISSUE

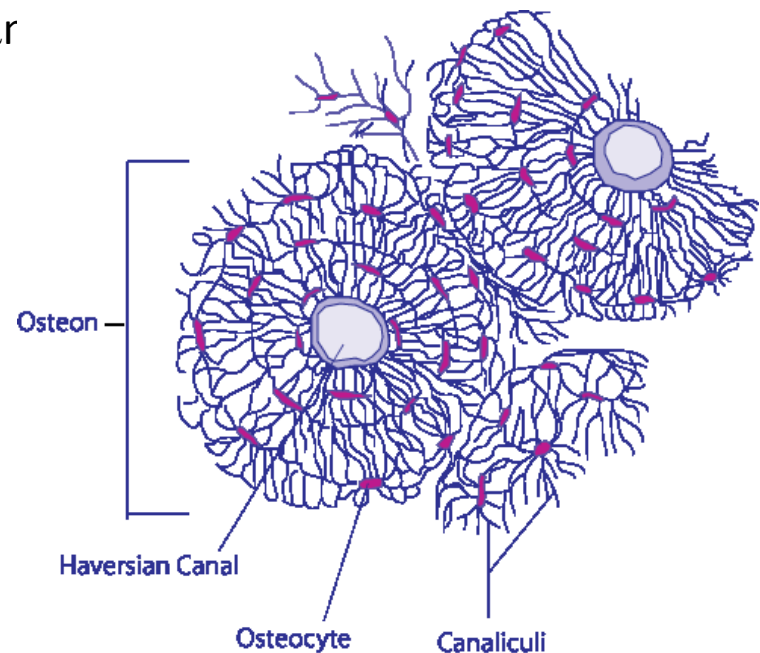
- **Primary (woven, fibrous)**

- Temporary, growth and regeneration of bones, collagen fibrils woven
- Replaced by secondary bone
- Remains only in some parts of body - sutures of skull, *tuberositas ossium*, tooth cement



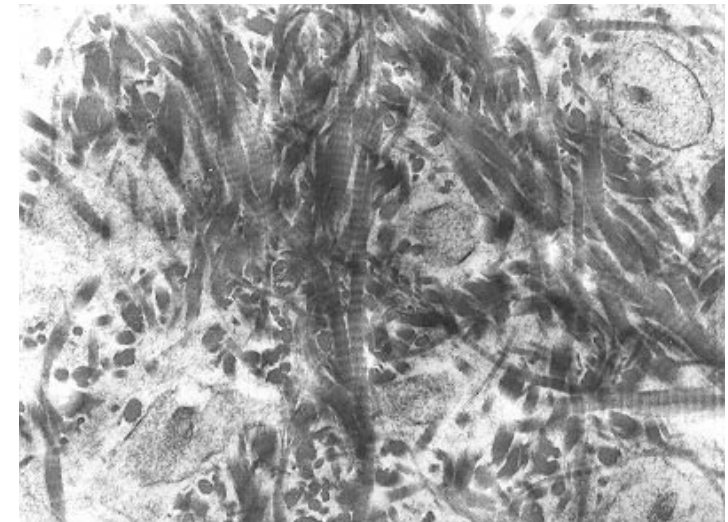
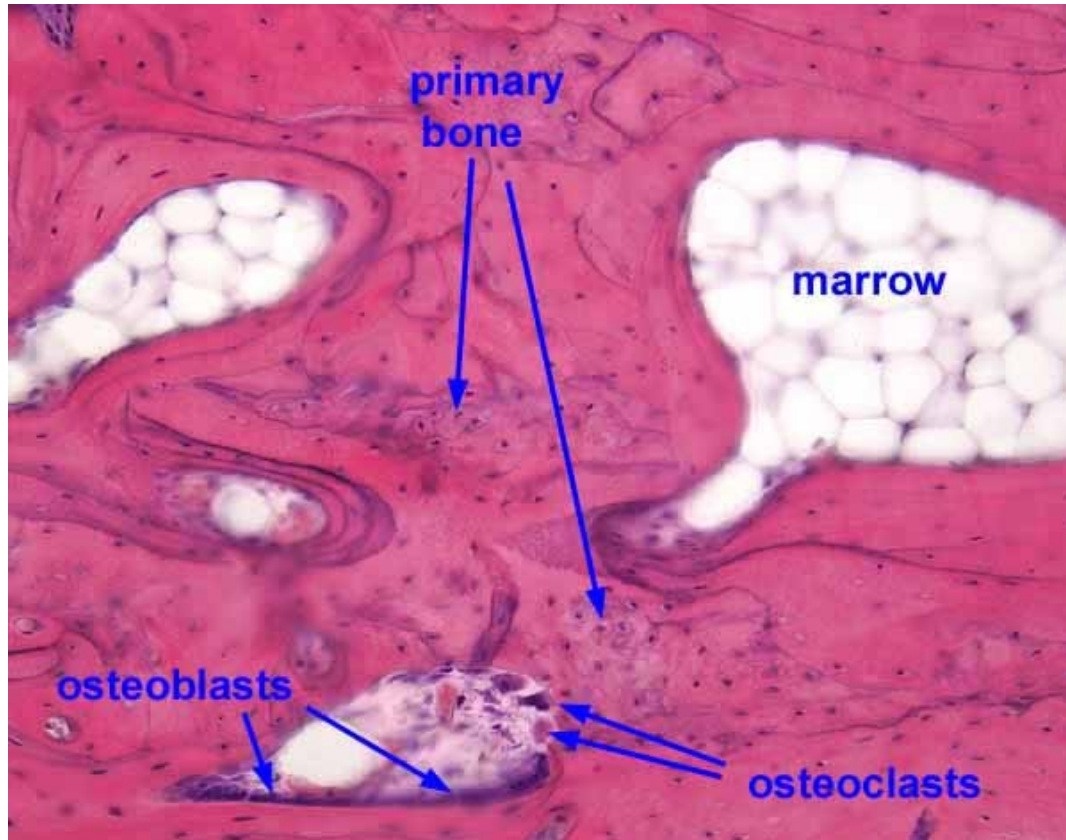
- **Secondary (lamellar)**

- Lamellae – collagen fibers in concentric layers (3-7 μ m around a canal with capillaries = Haversian system (osteon)



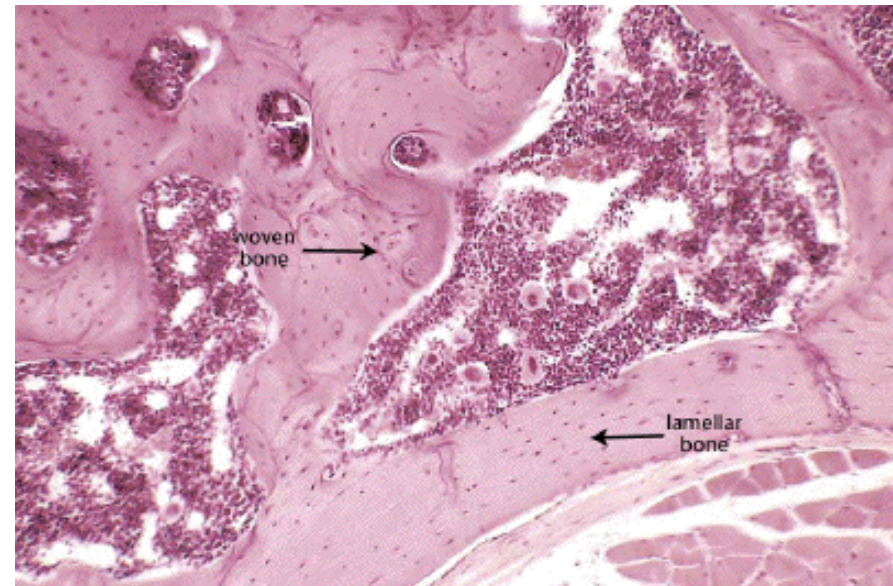
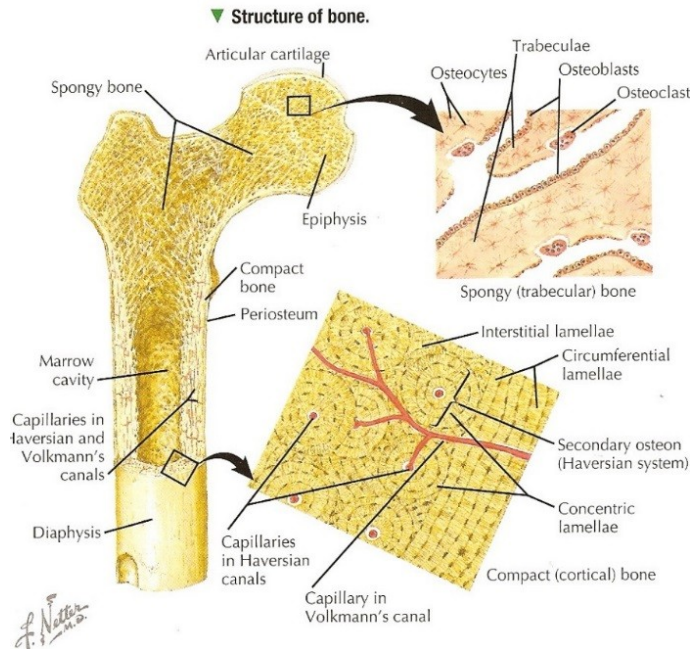
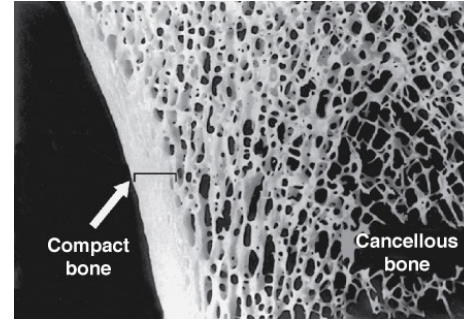
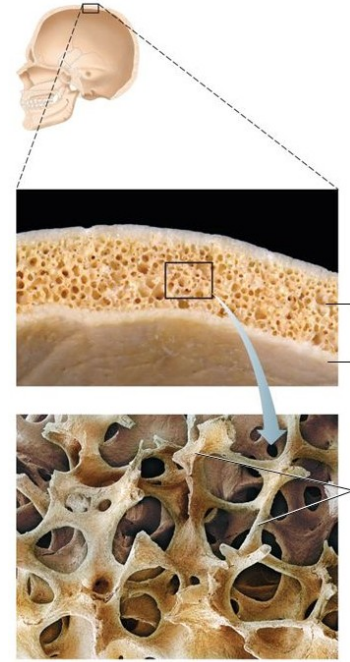
PRIMARY (WOVEN) BONE

- Temporary, growth and regeneration of bones, collagen fibrils woven
- Replaced by secondary bone
- Remains only in some parts of body - sutures of skull, *tuberositas ossium*, tooth cement



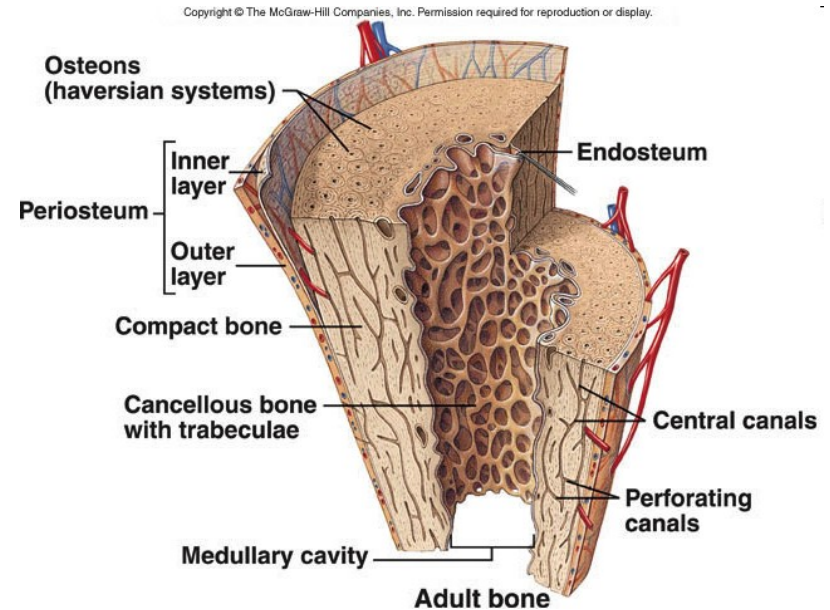
SECONDARY (LAMELLAR) BONE

- Lamellae – collagen fibers in concentric layers (3-7 μ m) around a canal with capillaries = Haversian system (osteon)
- **Spongy (trabecular)**
 - Trabeculae, similar to compact
 - Epiphyses of long bones, short bones, middle layer of flat bones of the skull (*diploe*)
- **Compact**
 - Outer and inner coat lamellae typical Haversian systems
 - Volkmann's canals
 - Interstitial canals

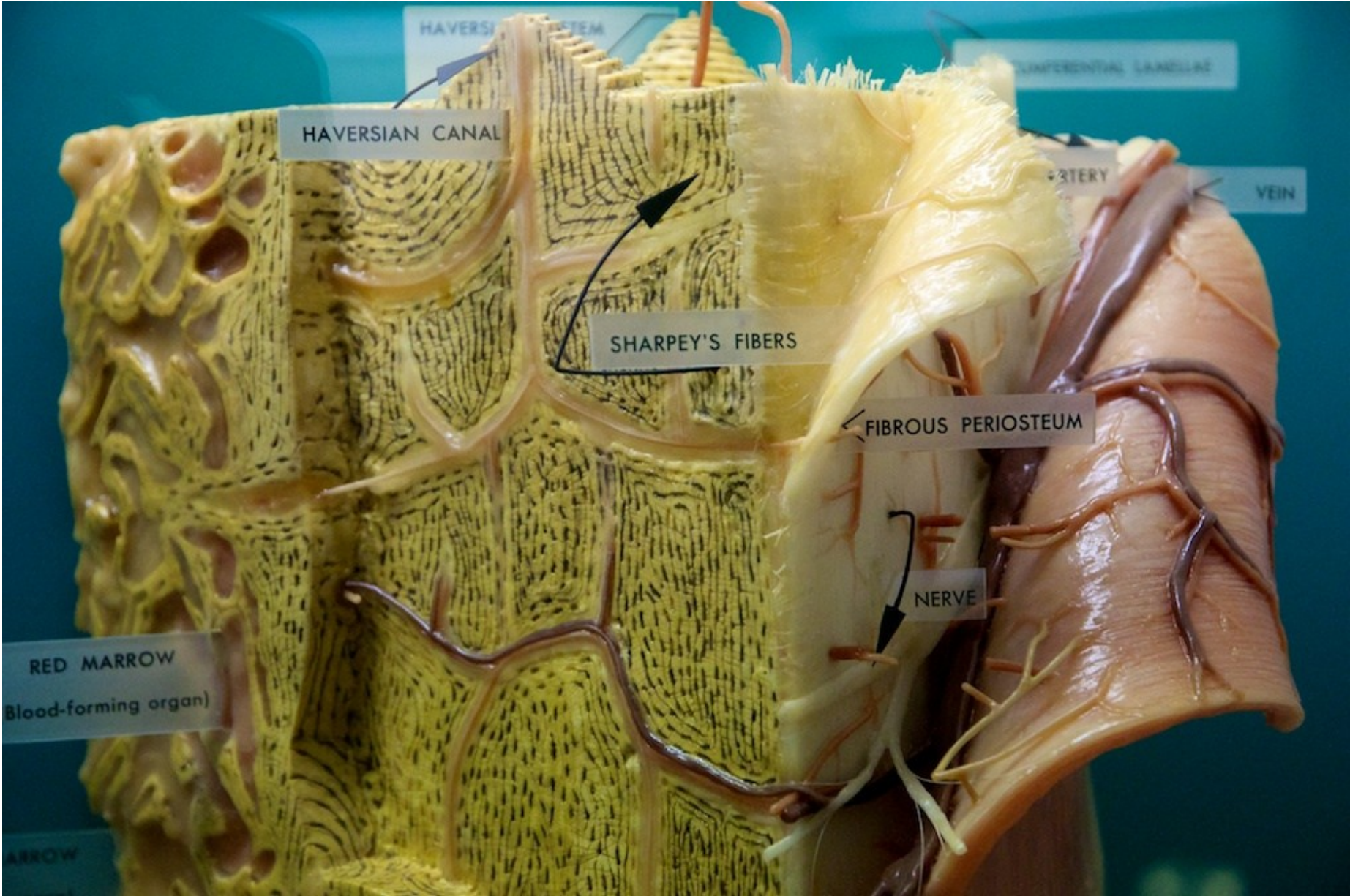


BONE SURFACES

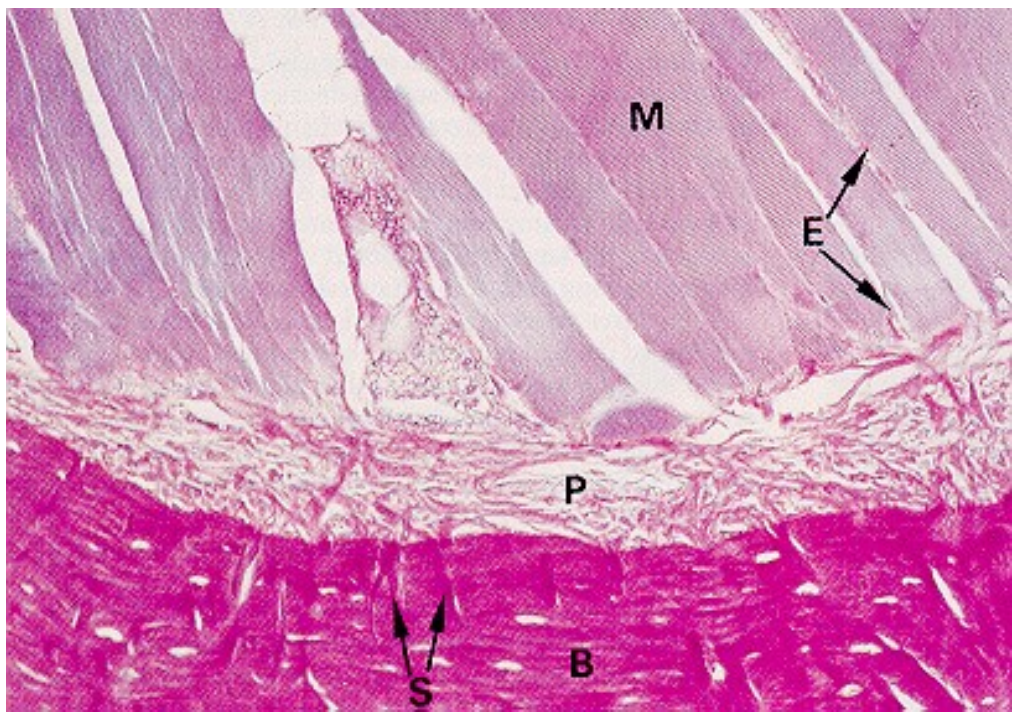
- **Outer surface**
- Synovial joint – hyaline cartilage
- **Periosteum (periost)** – membrane – dense CT, inner layer (osteoblasts) and outer layer (fibrous CT)
- Inactive bone - fibrous CT in periost dominant
- Collagen fibers – parallel to the bone surface
- Sharpey's fibers fix periost to the bone



BONE SURFACES

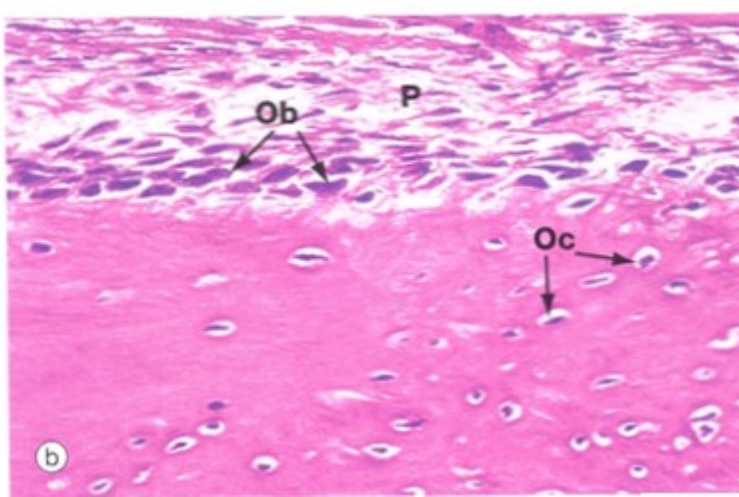
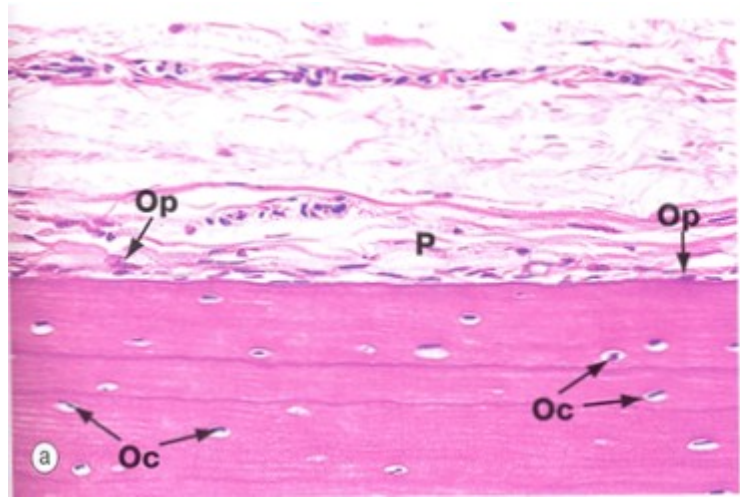


BONE SURFACES



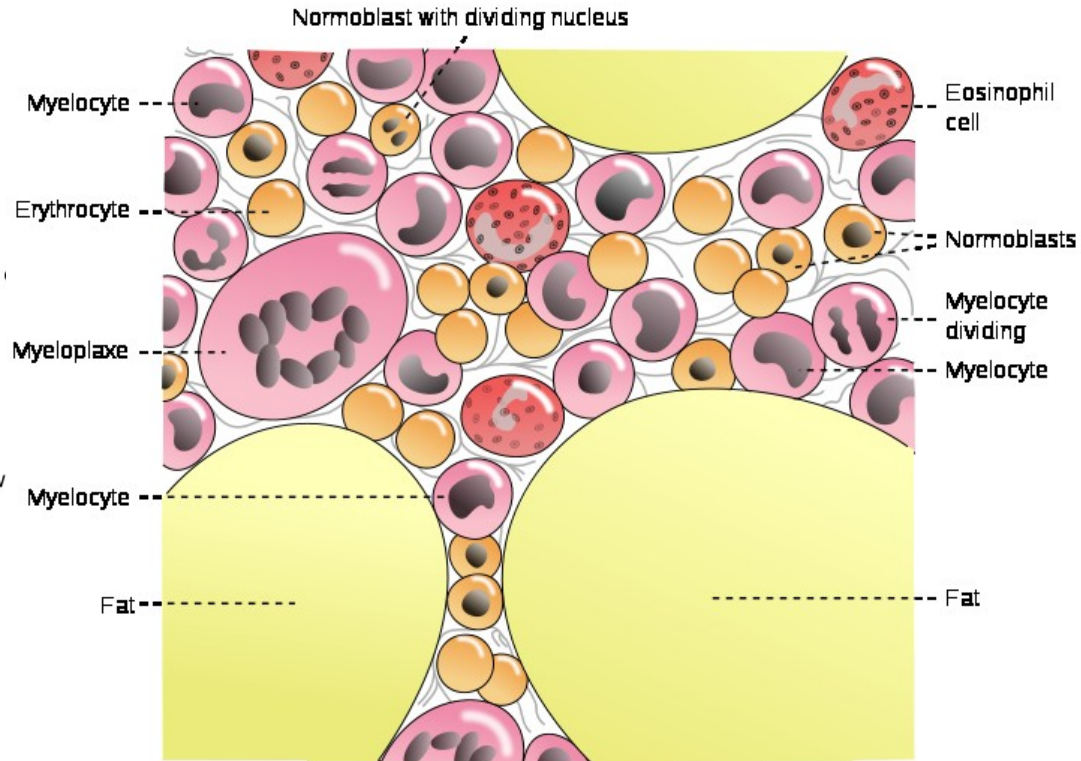
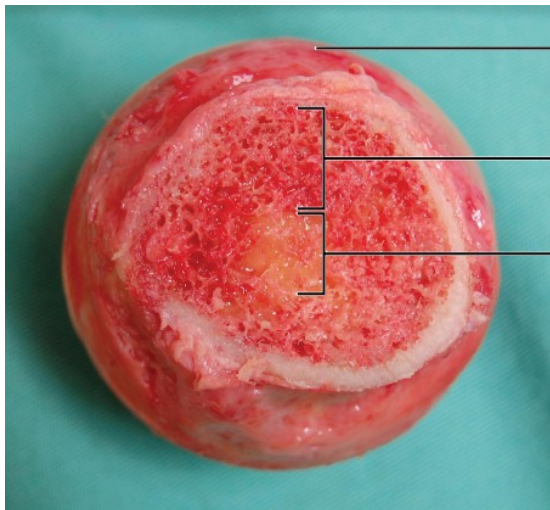
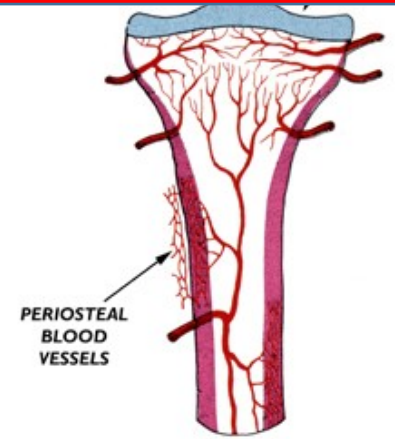
Inactive

Active

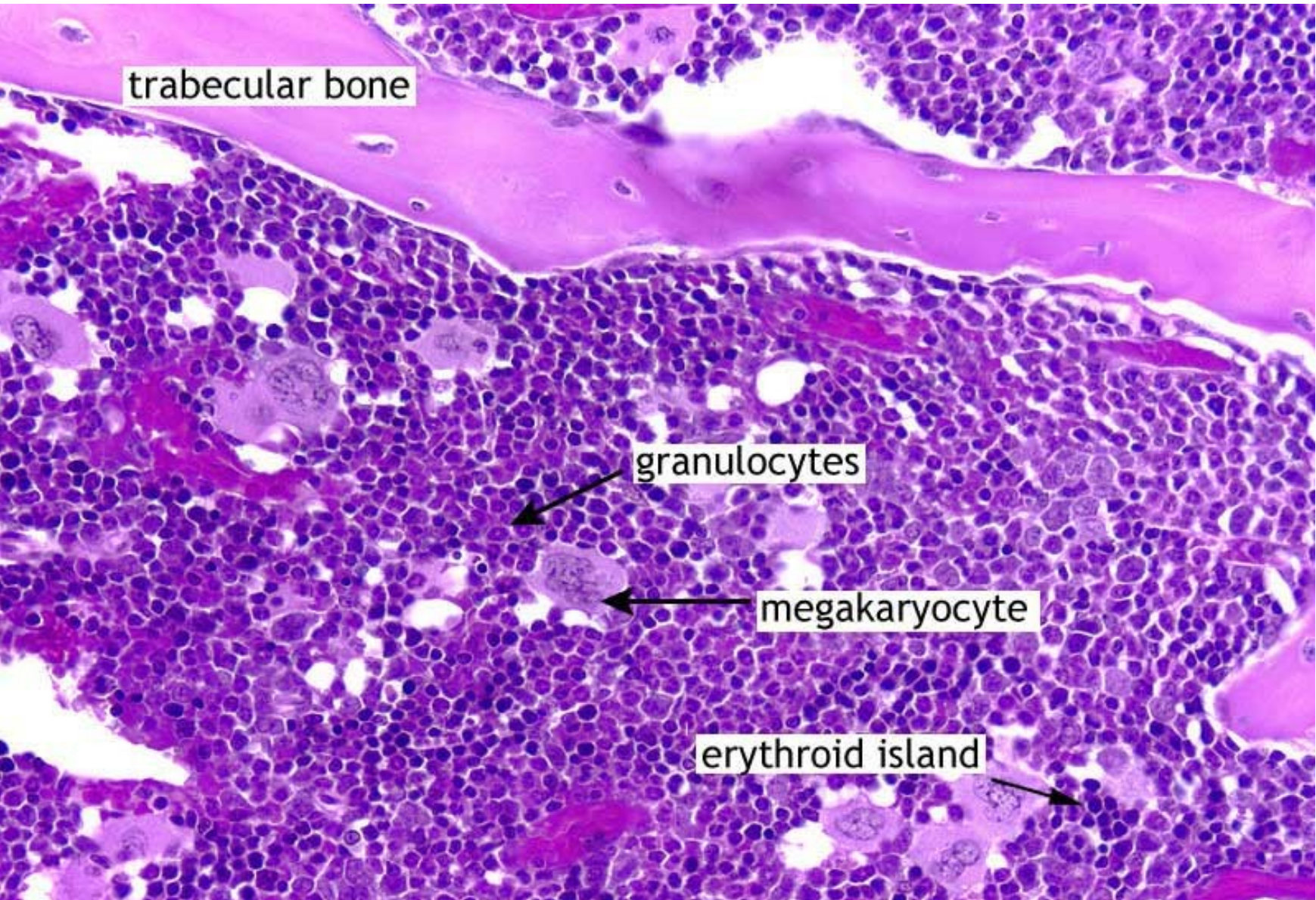


BONE SURFACES

- **Inner surface** – lining of cavities
 - medullar cavity
 - endosteum (endost) – single cell lining – bone remodeling
 - red bone marrow – hematopoiesis
 - yellow and gray bone marrow – adipocytes or CT
 - rich vascularization
 - hematopoietic niche

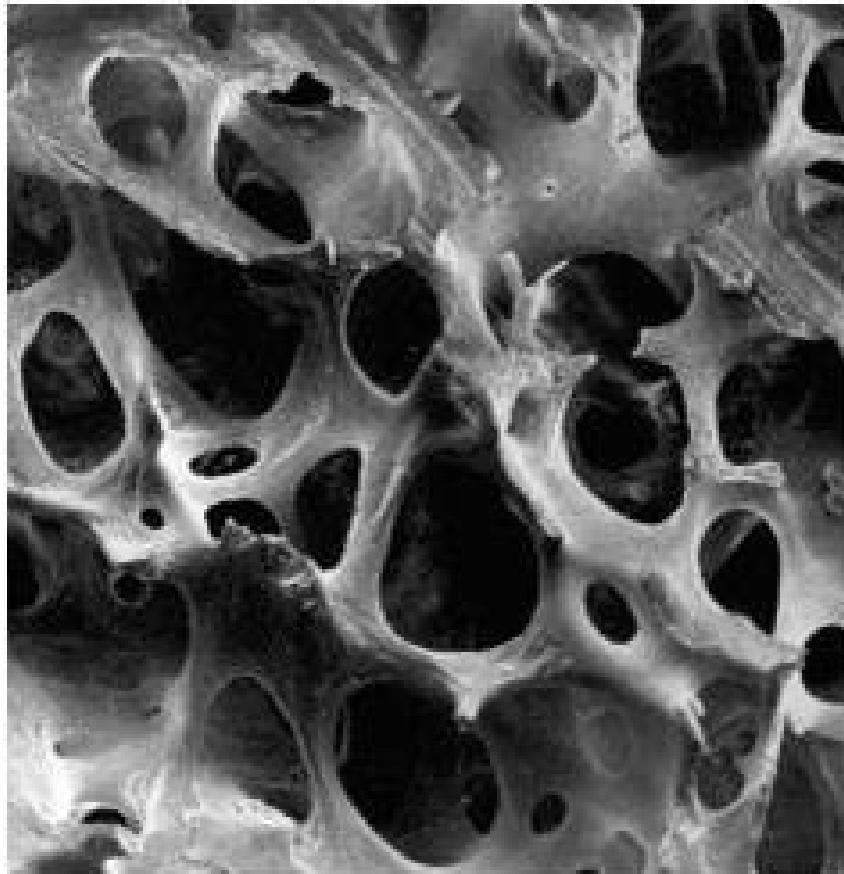


ENDOSTEAL SURFACE OF COMPACT BONE

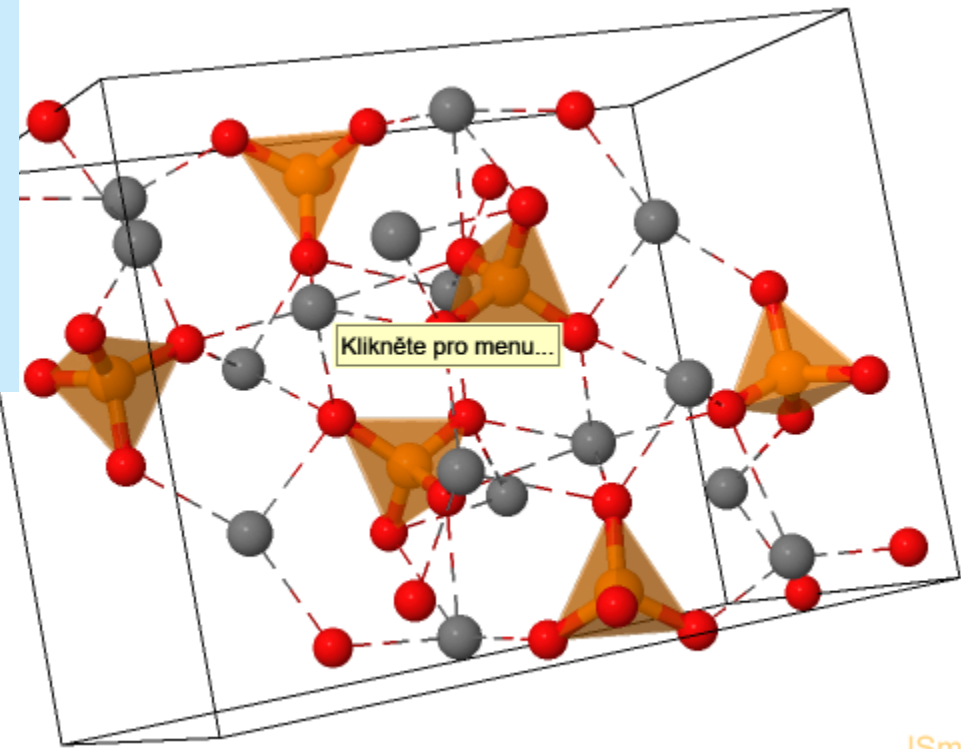
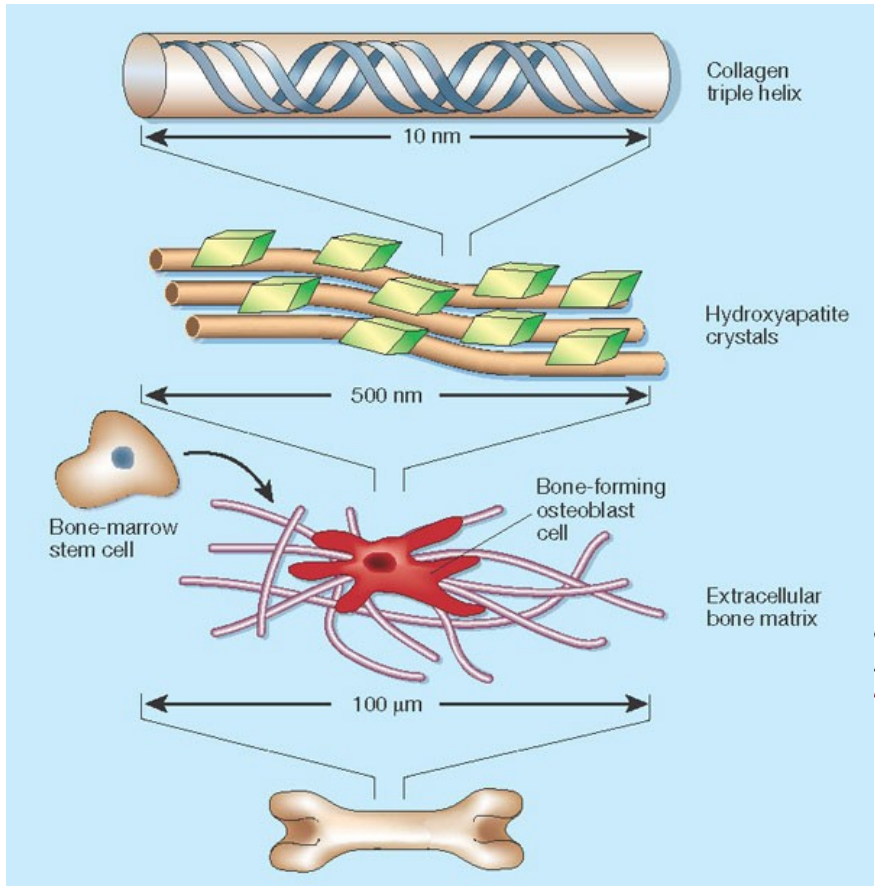


BONE MATRIX

- 60% mineral compound, 24% organic compound 12% H₂O, 4% fat
- crystals – calcium phosphate, hydroxyapatite

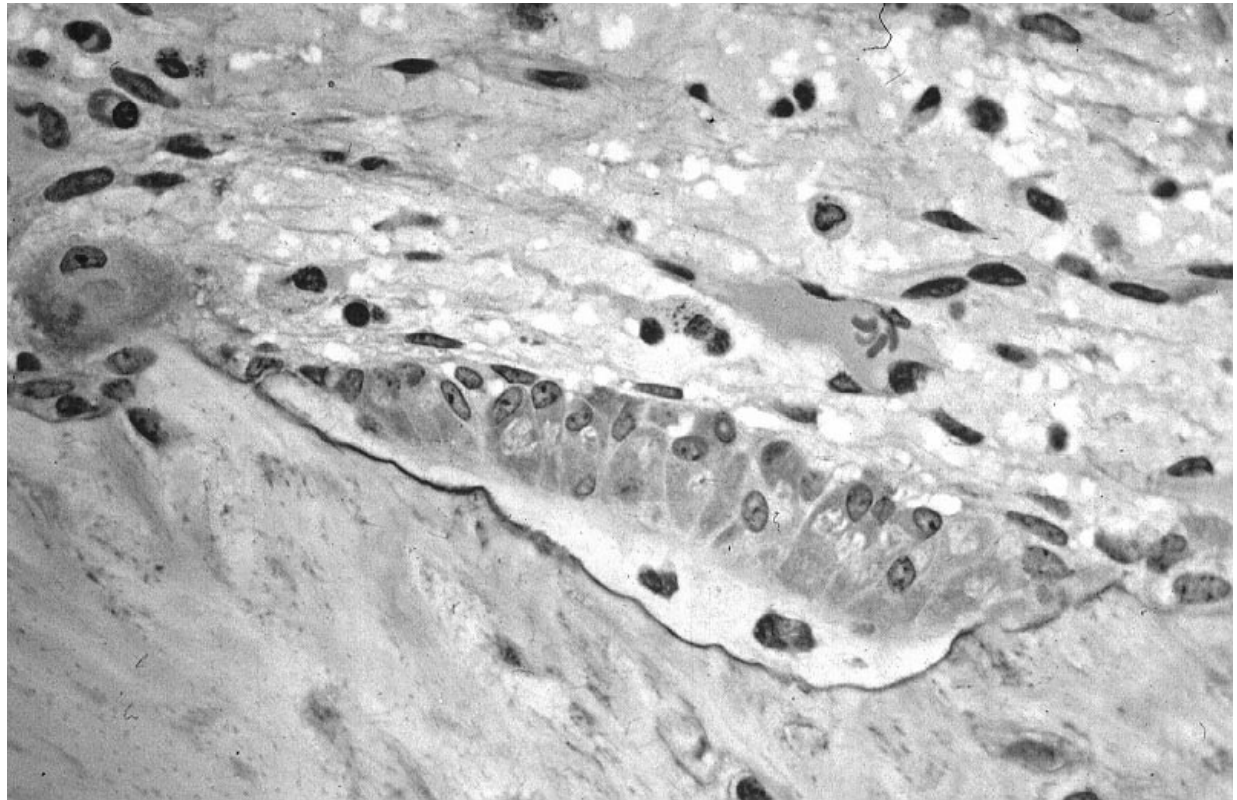


BONE MATRIX

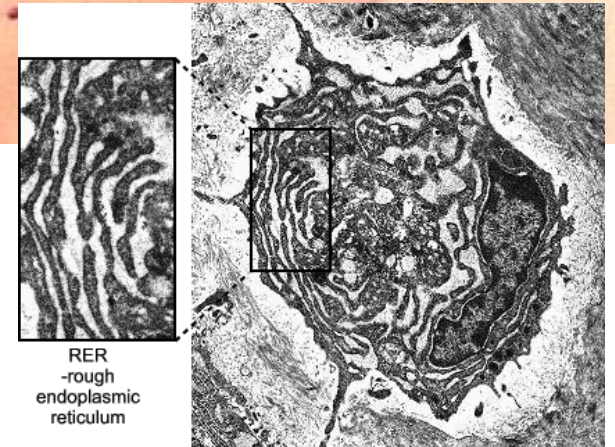
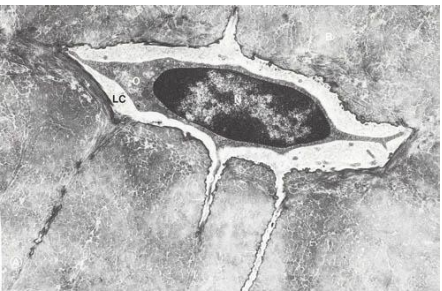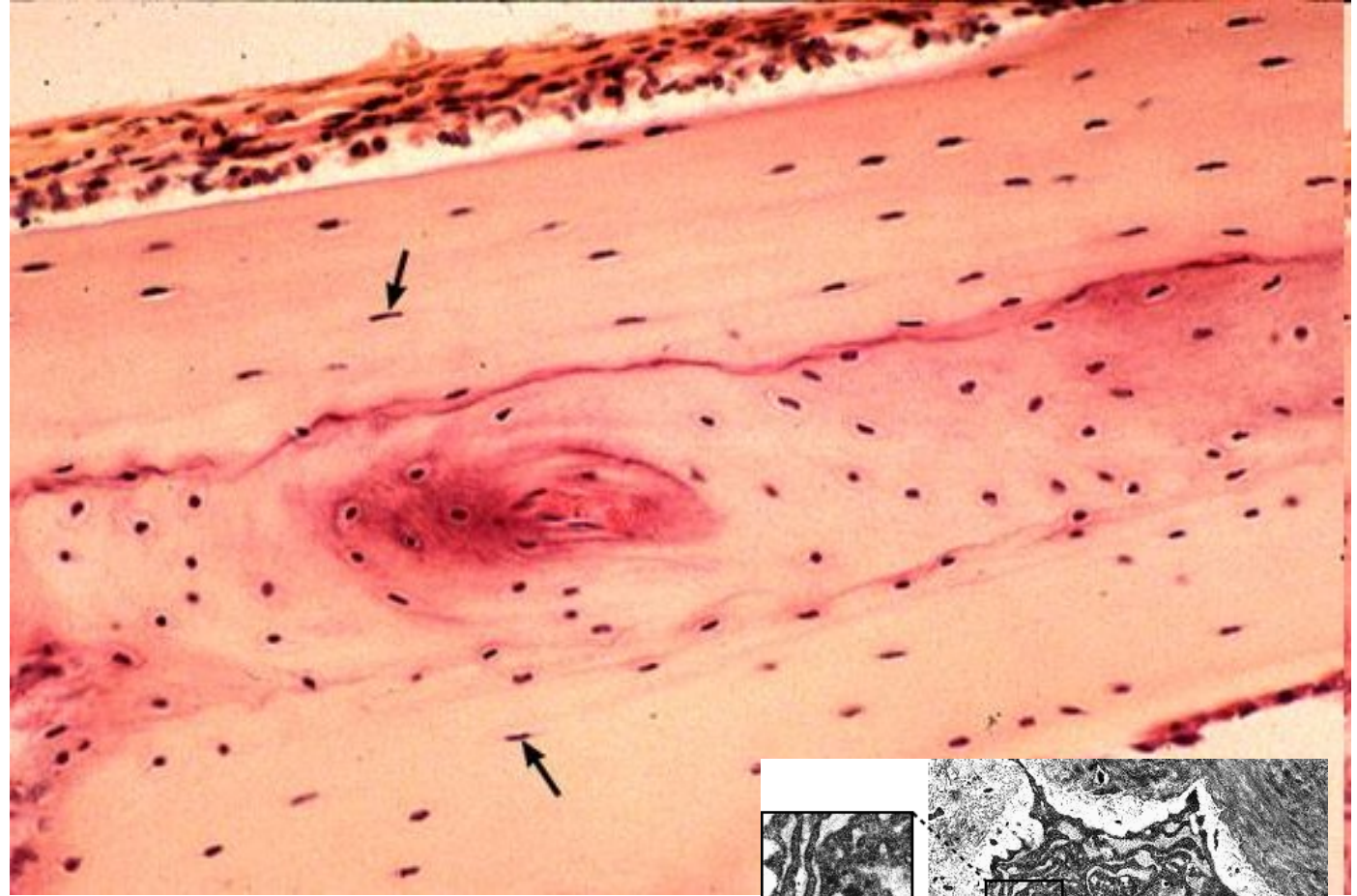
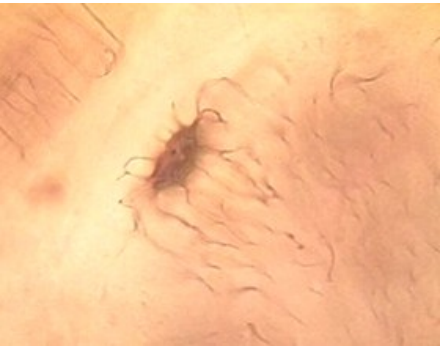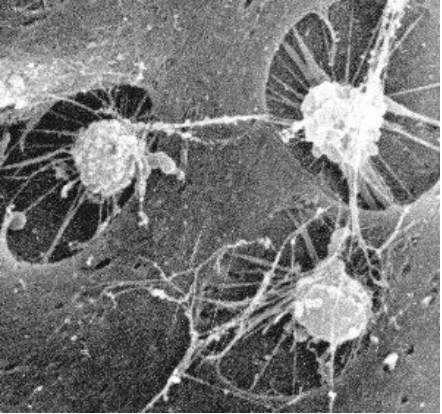


CELLS OF BONE – OSTEOBLASTS

- lining bone surface
- produce ECM – collagen (I) and noncollagenous proteoglycans, glycoproteins
- basophilic cytoplasm, rER, well developed Golgi Apparatus
- euchromatin nucleus
- **osteocytes** embedded in matrix
- *canaliculi ossium*

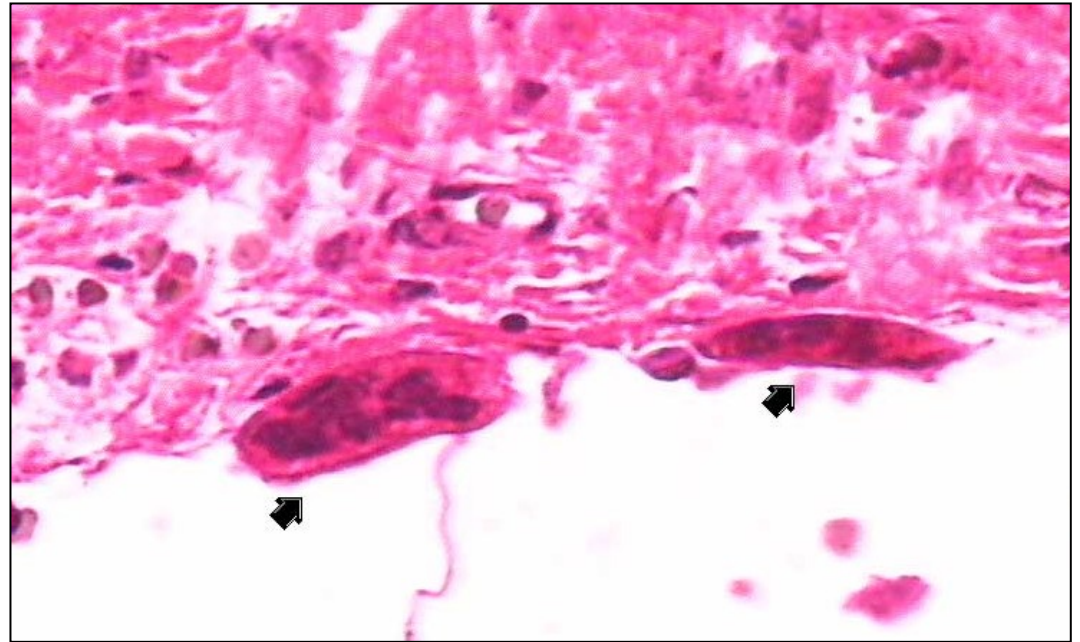
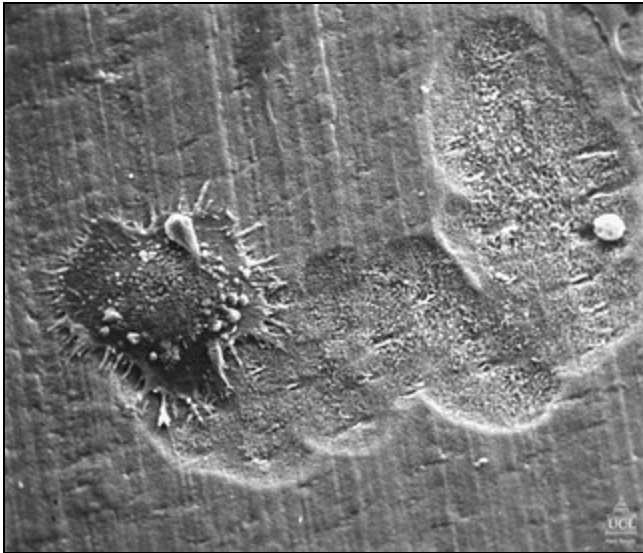


CELLS OF BONE – OSTEOCYTES



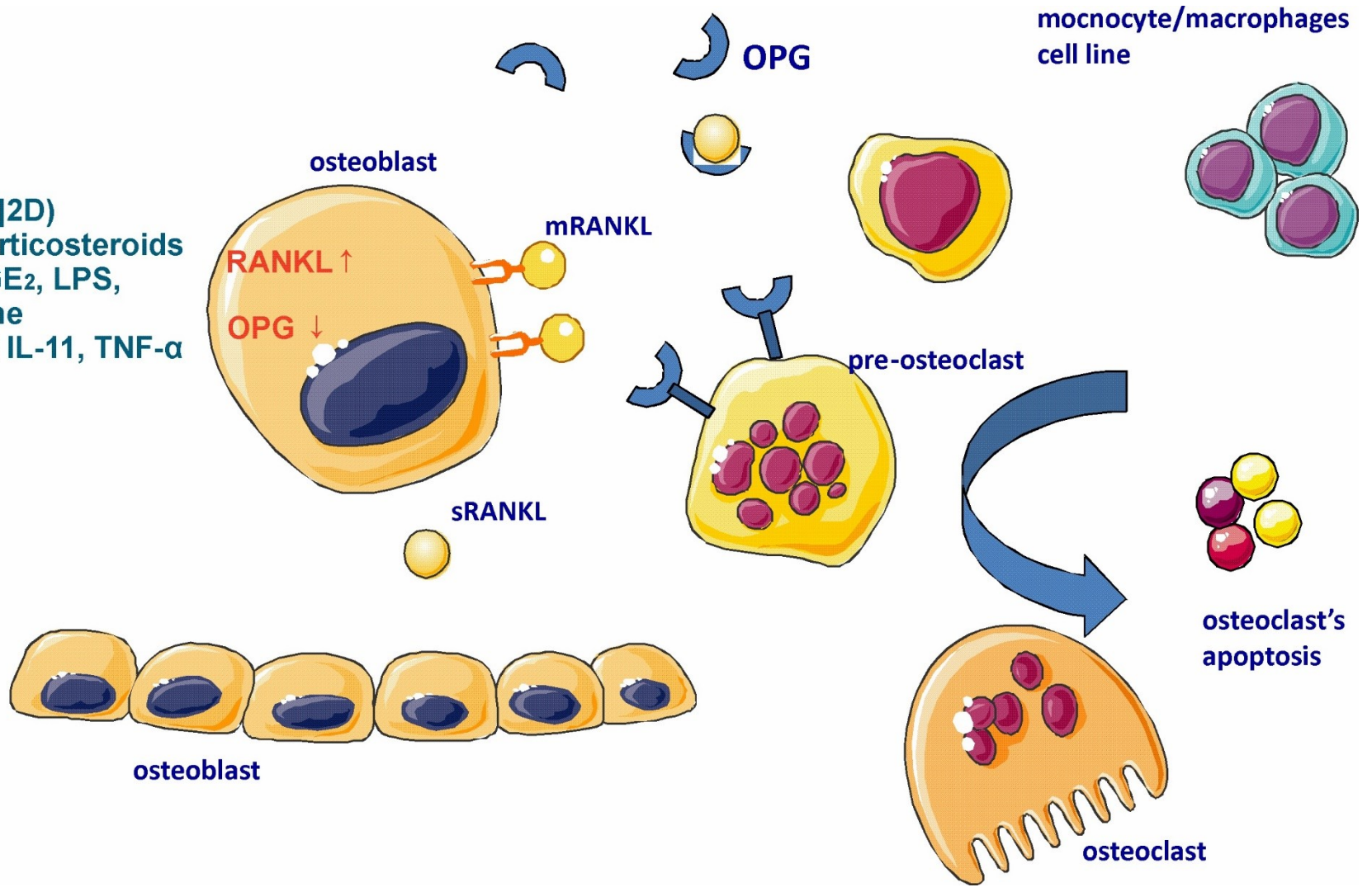
CELLS OF BONE – OSTEOCLASTS

- multinuclear, formed by fusion of mononuclear macrophages
- bone matrix resorption



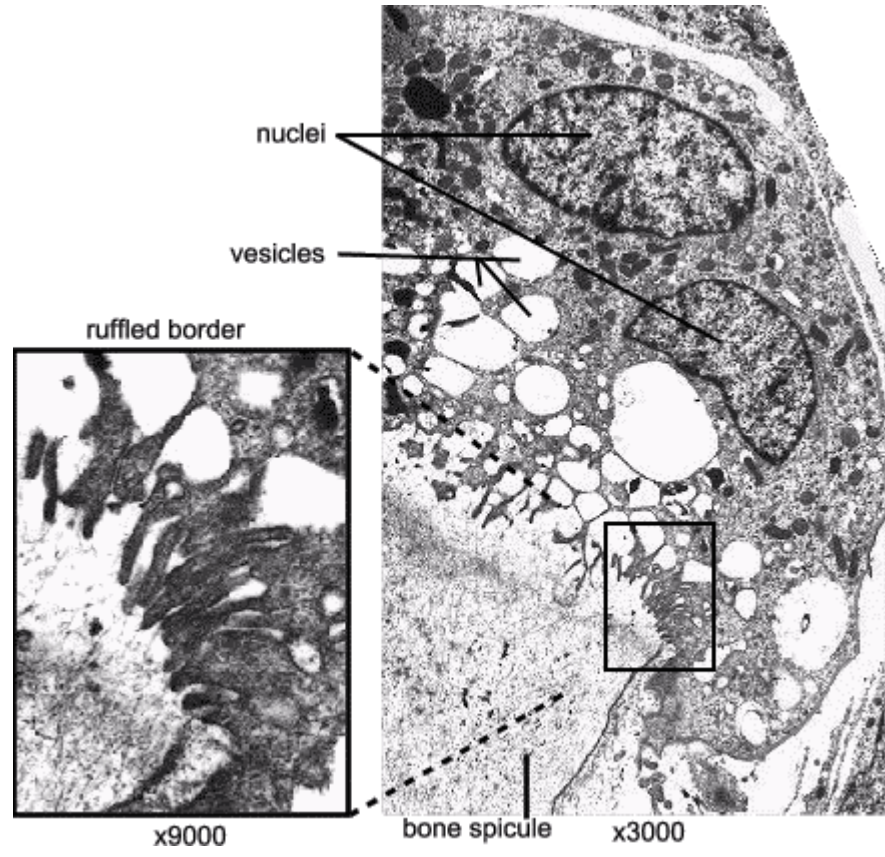
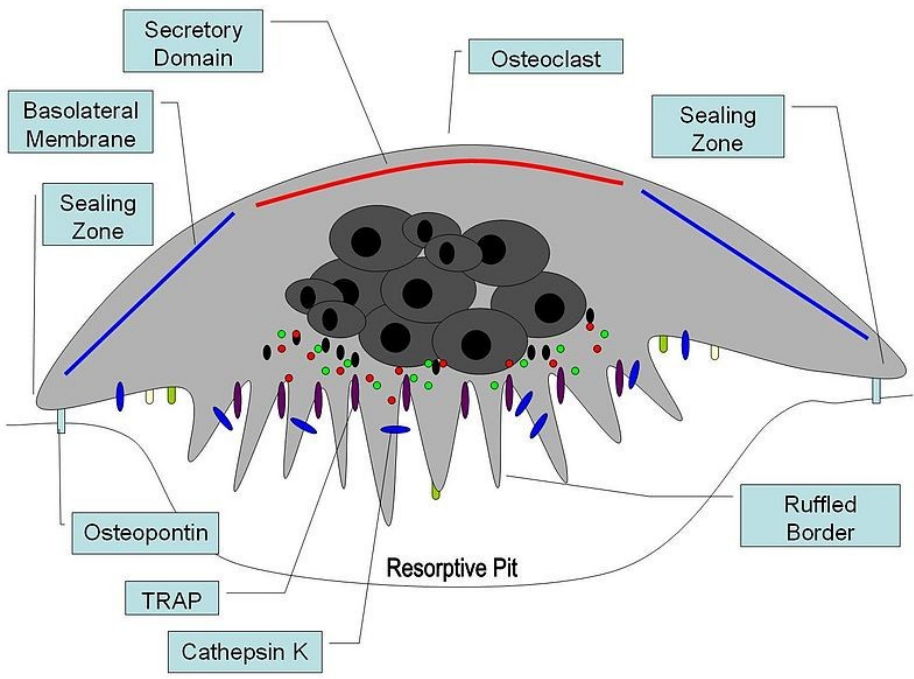
CELLS OF BONE – OSTEOCLASTS

1,25[OH]2D)
glucocorticosteroids
PTH, PGE₂, LPS,
histamine
IL-1 and IL-11, TNF- α



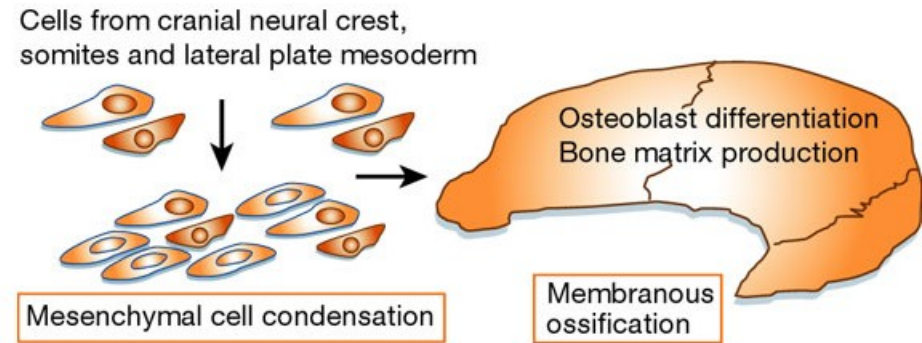
CELLS OF BONE – OSTEOCLASTS

- complex architecture
- enzymes degrading organic matrix
- HCl

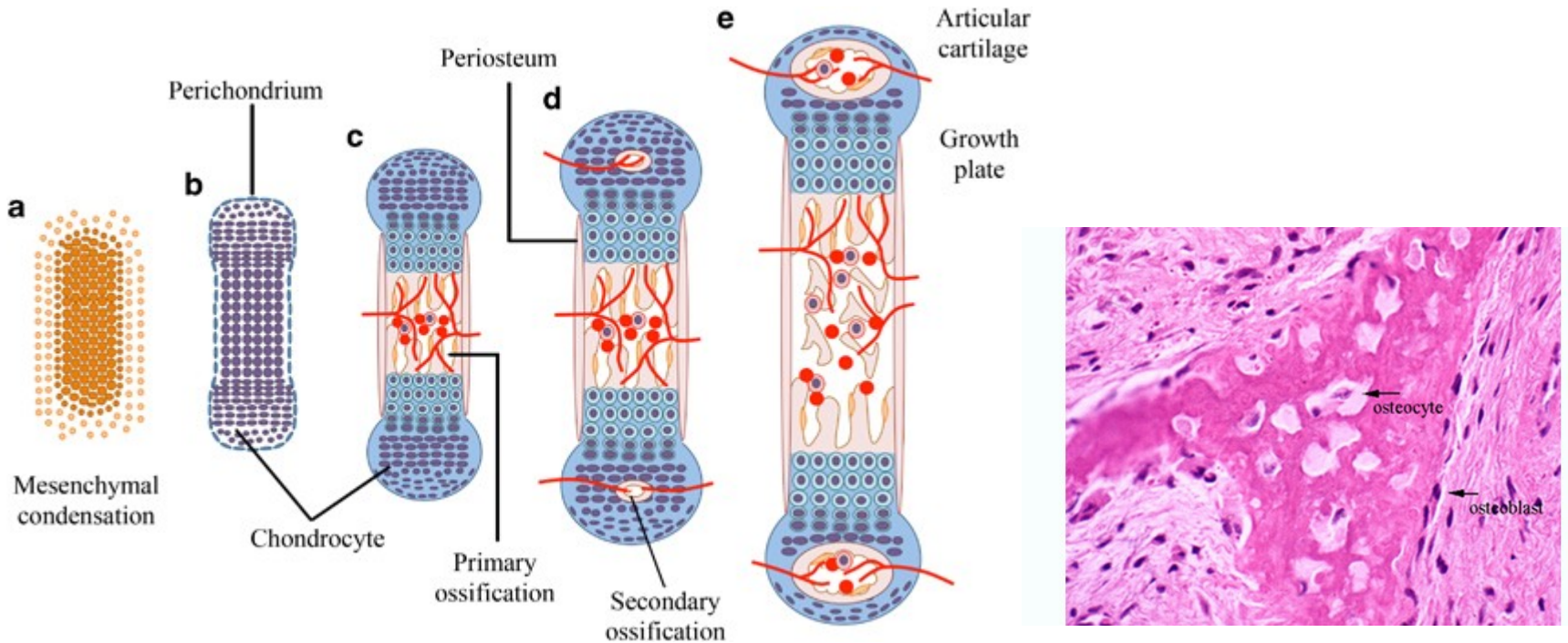


BONE OSSIFICATION

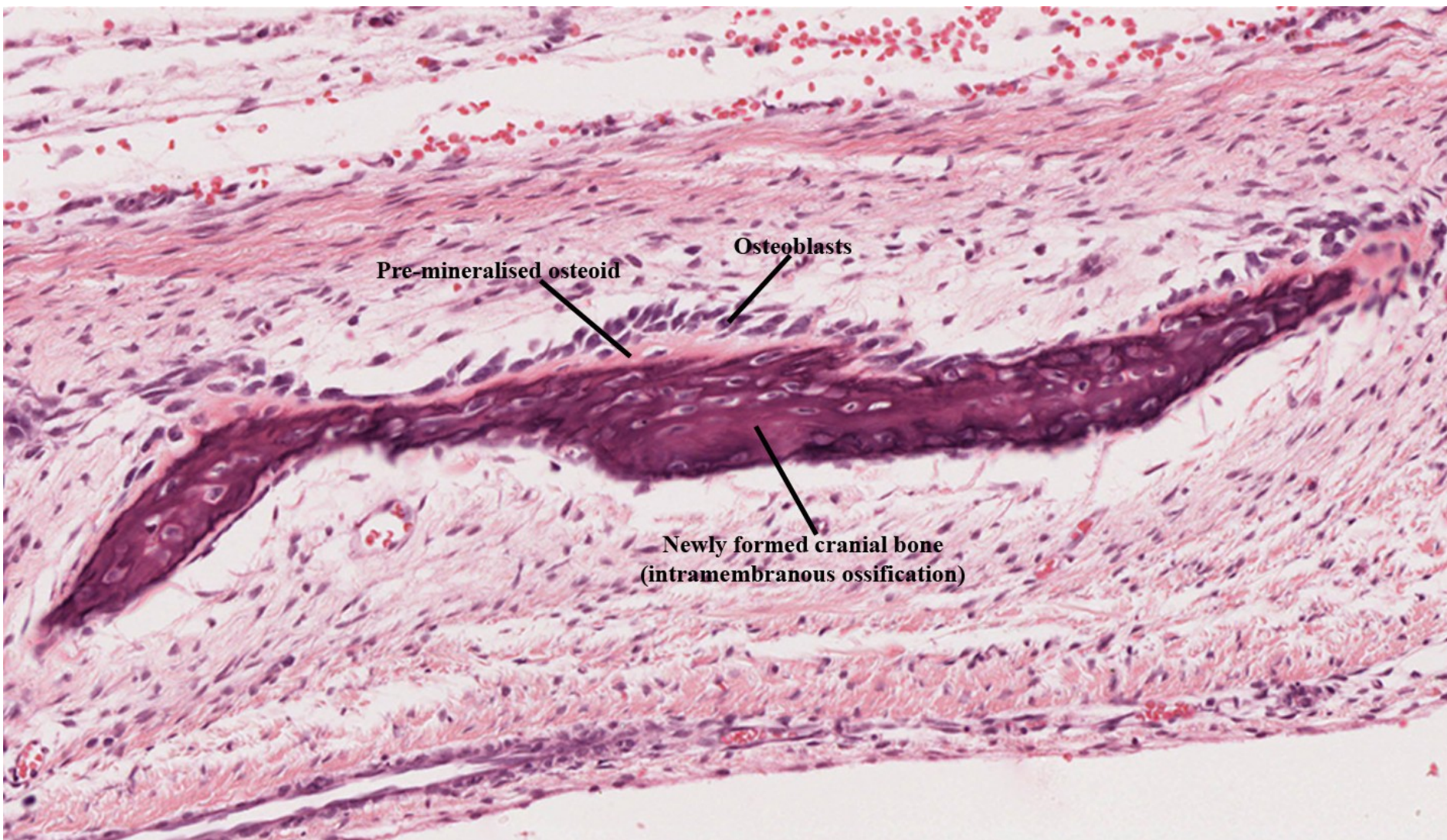
- Intramembraneous



- Endochondral



INTRAMEMBRANEOUS OSSIFICATION

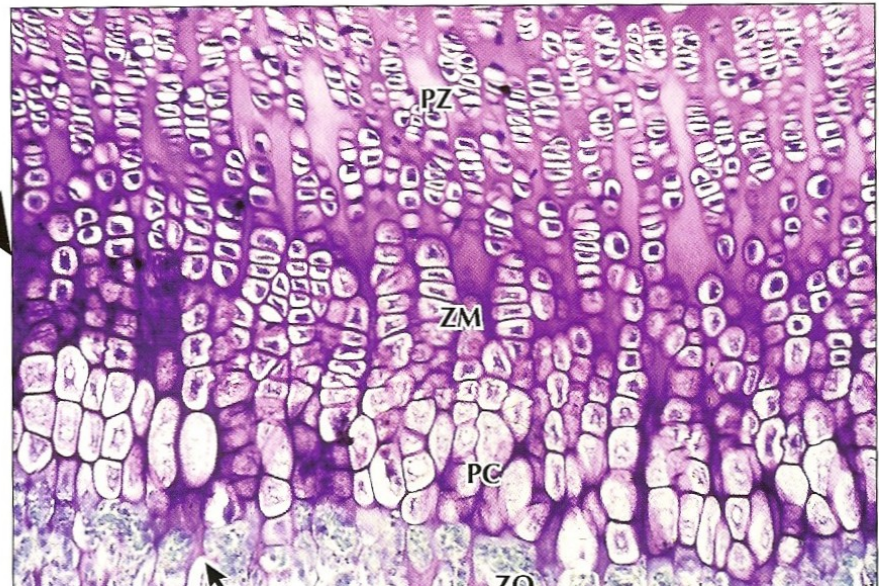
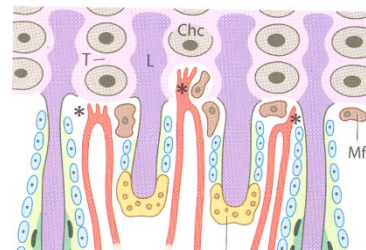
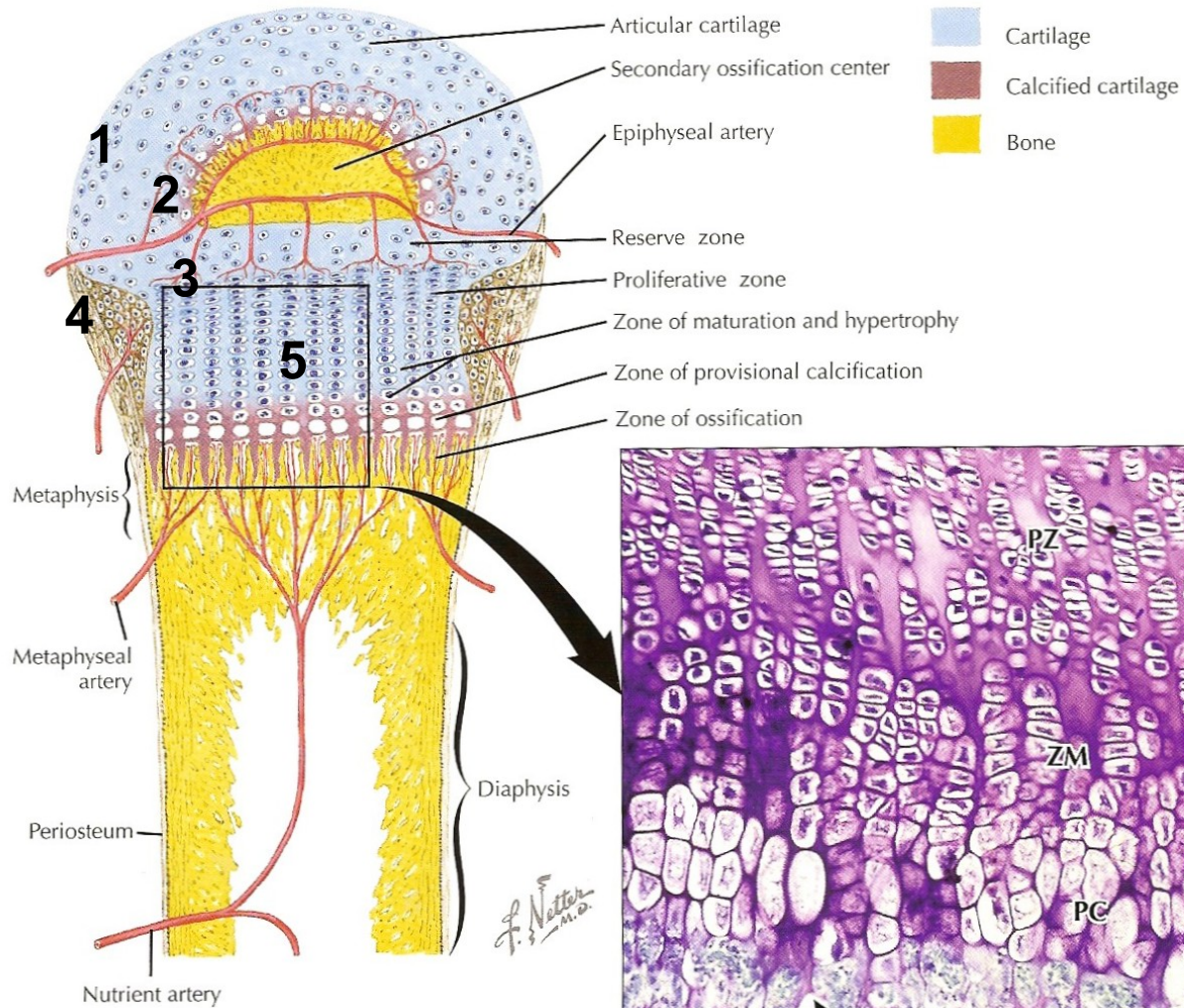


Pre-mineralised osteoid

Osteoblasts

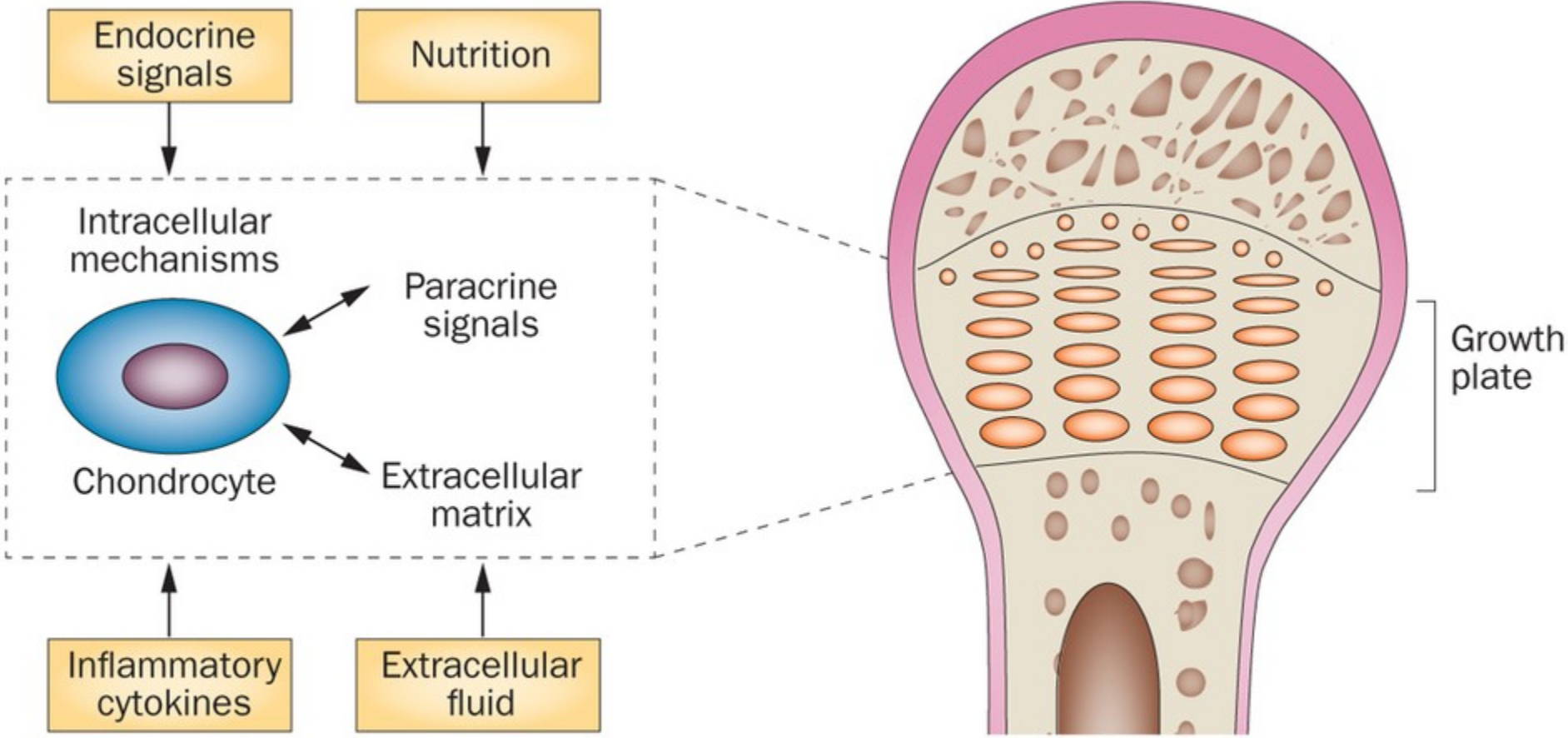
Newly formed cranial bone
(intramembranous ossification)

ENDOCHONDRAL OSSIFICATION

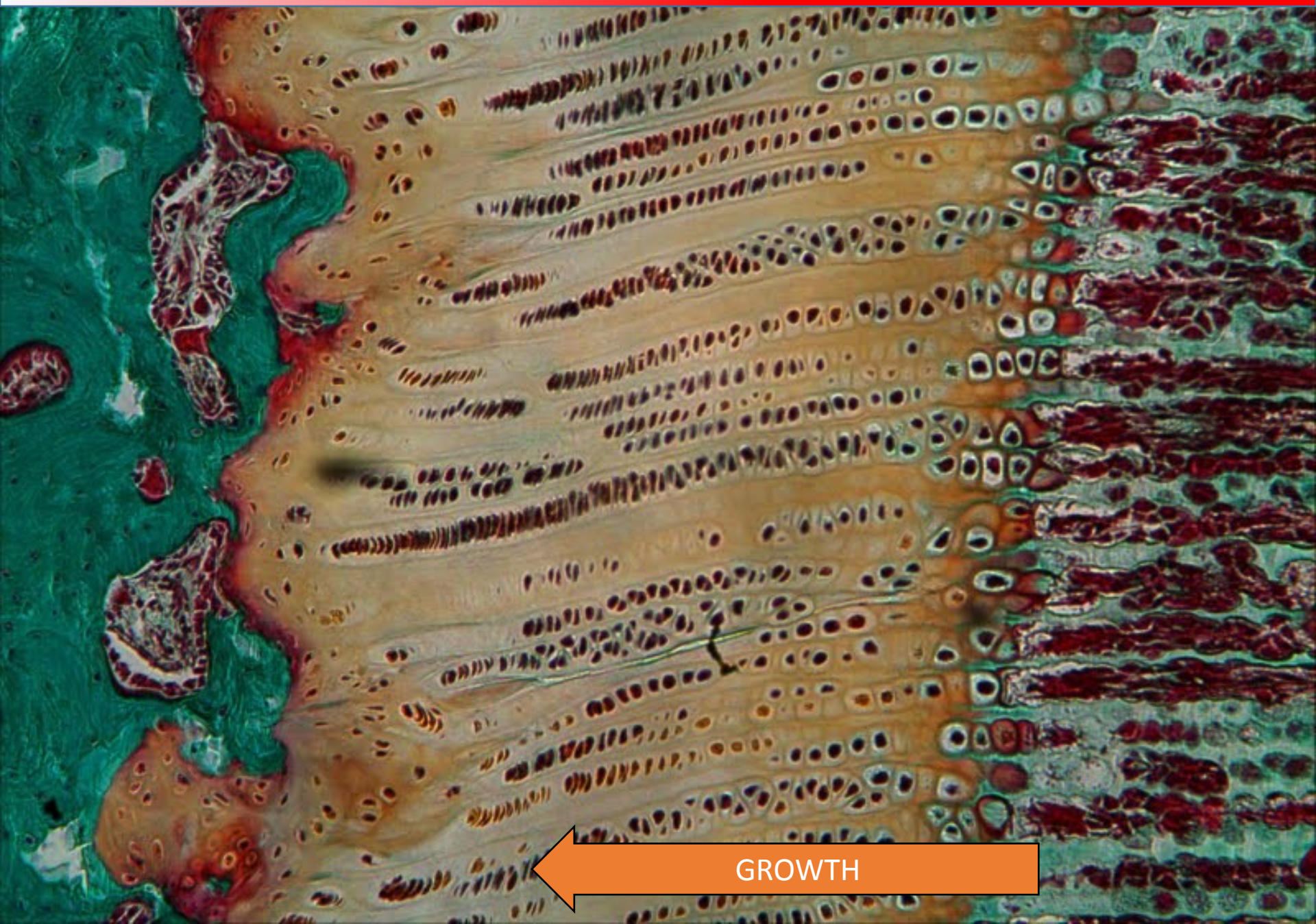


F. Netter M.D.

ENDOCHONDRAL OSSIFICATION

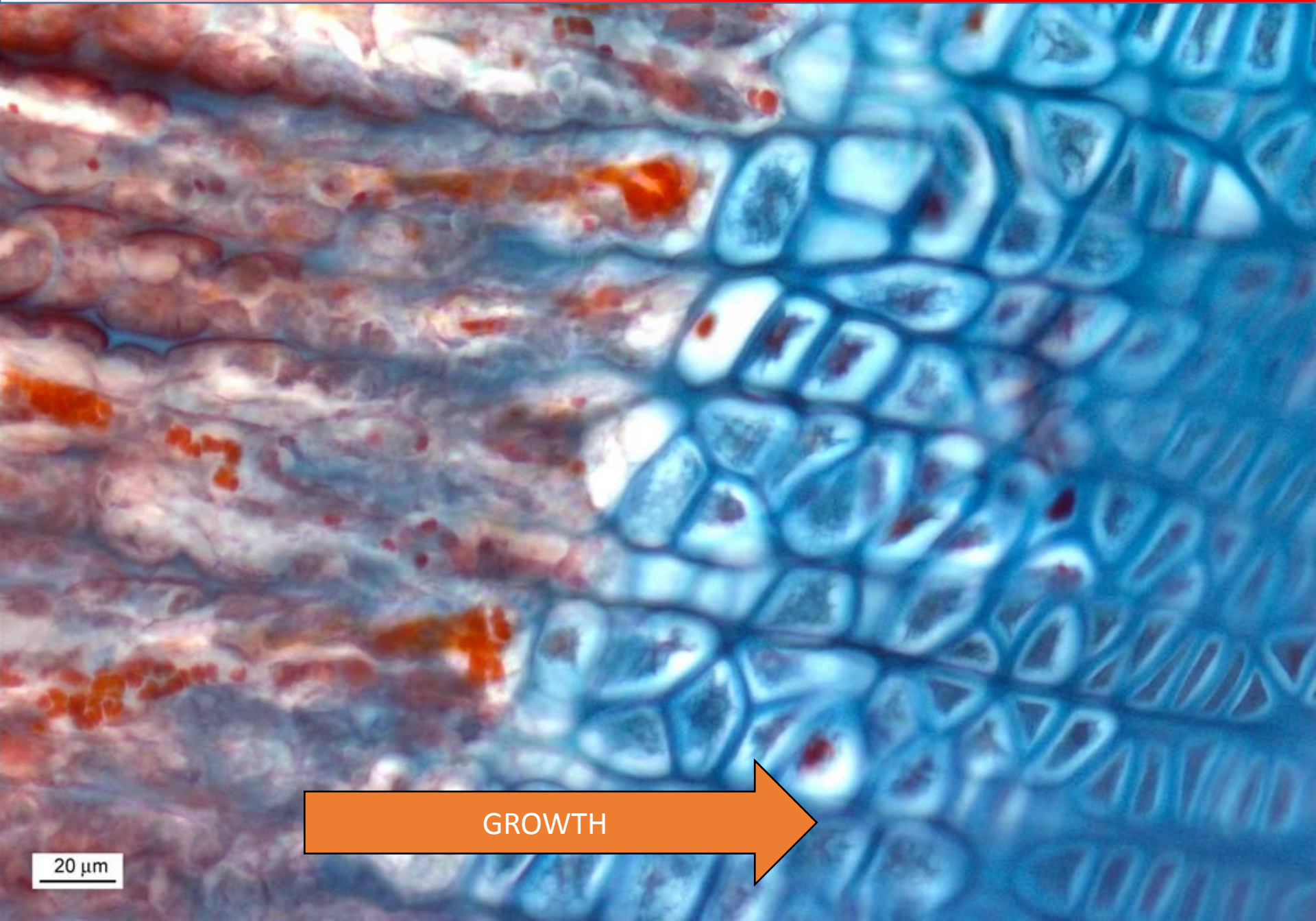


GROWTH PLATE



GROWTH

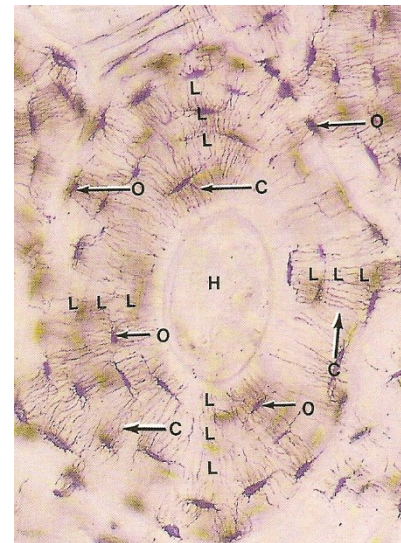

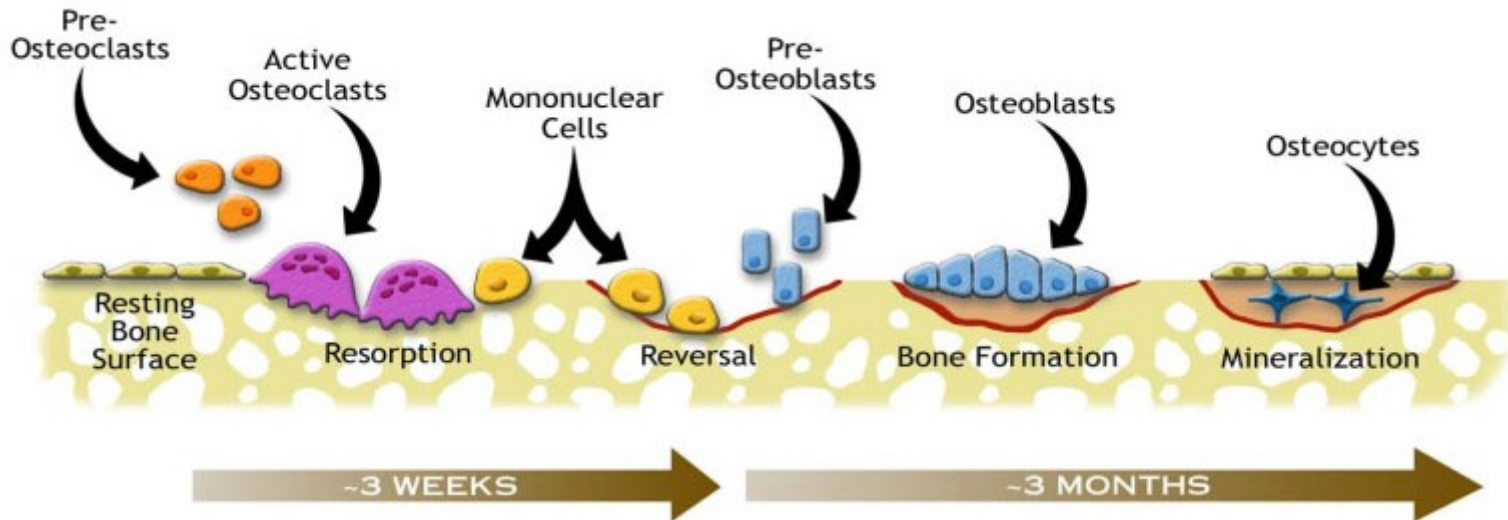
GROWTH PLATE



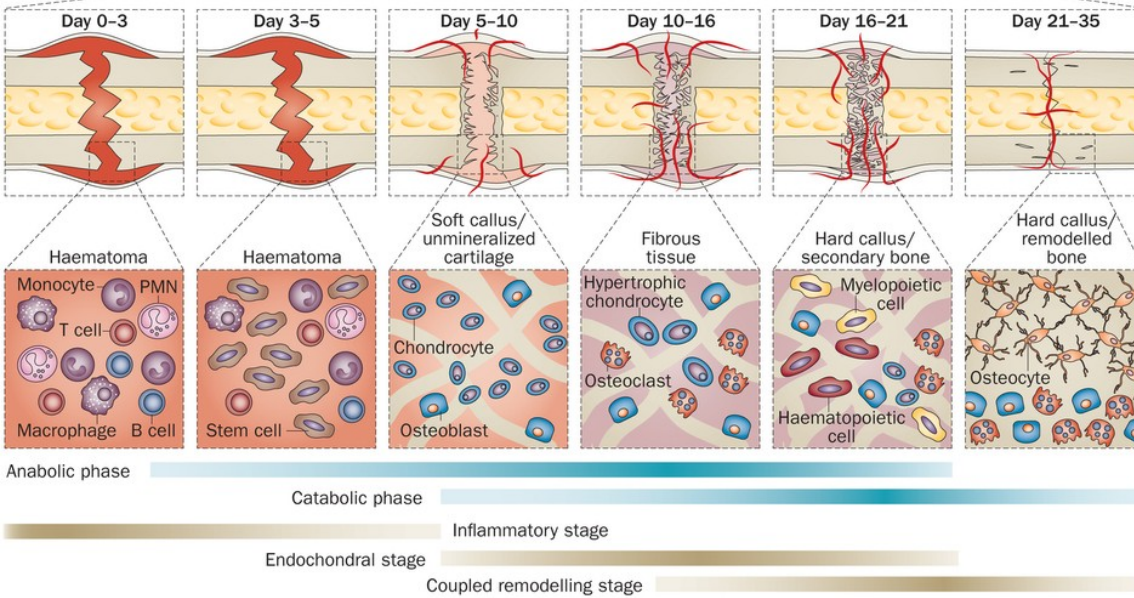
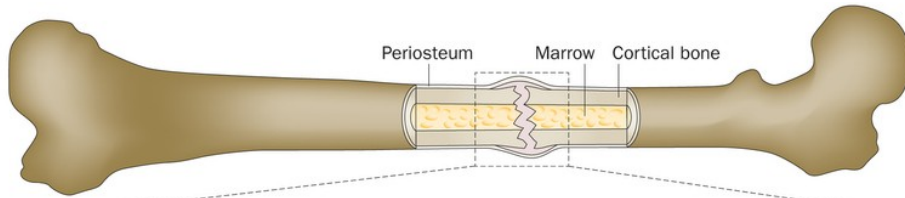
GROWTH

20 μ m

BONE REMODELLING



CLINICAL CORRELATIONS – FRACTURE HEALING



Reactive phase

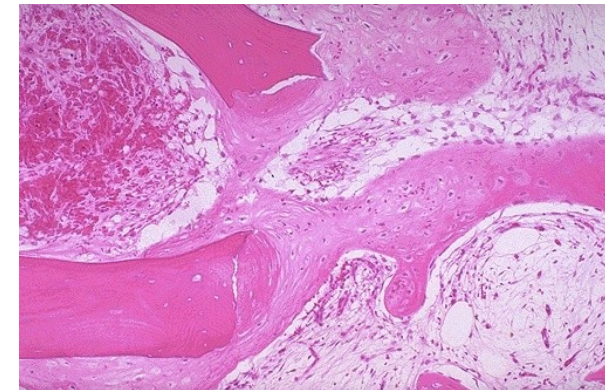
- fracture and inflammatory phase
- granulation tissue formation

Reparative phase

- cartilage *callus* formation
- lamellar bone deposition

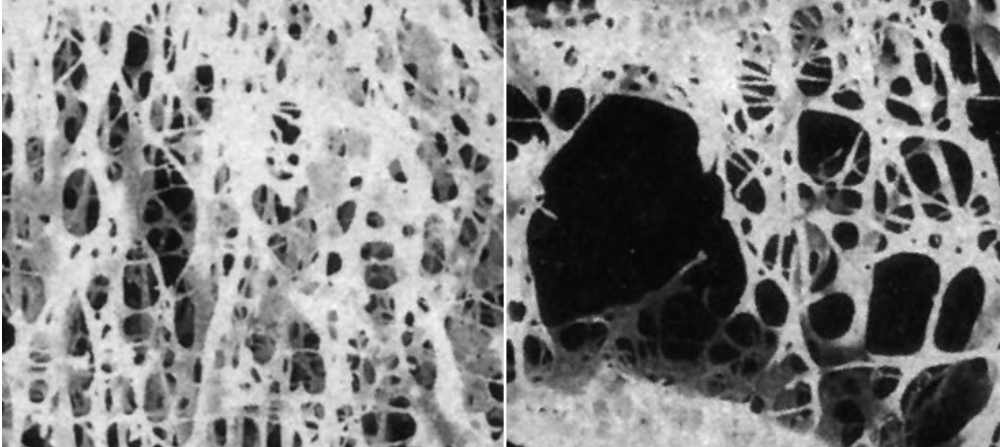
Remodeling phase

- remodeling to original bone shape

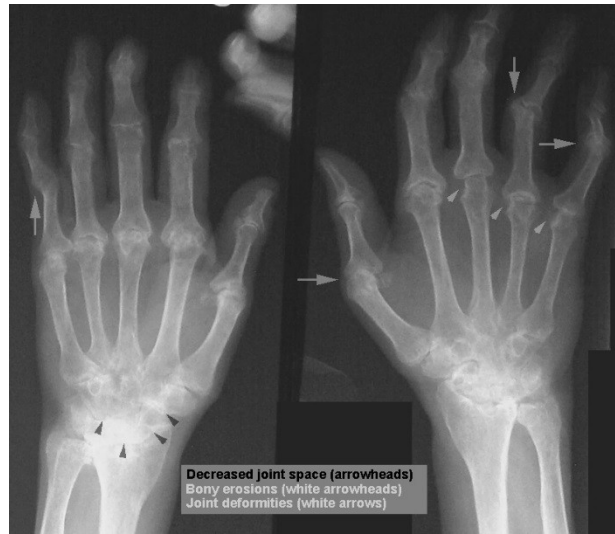

CLINICAL CORRELATIONS – DISBALANCE OF BONE HOMEOSTASIS

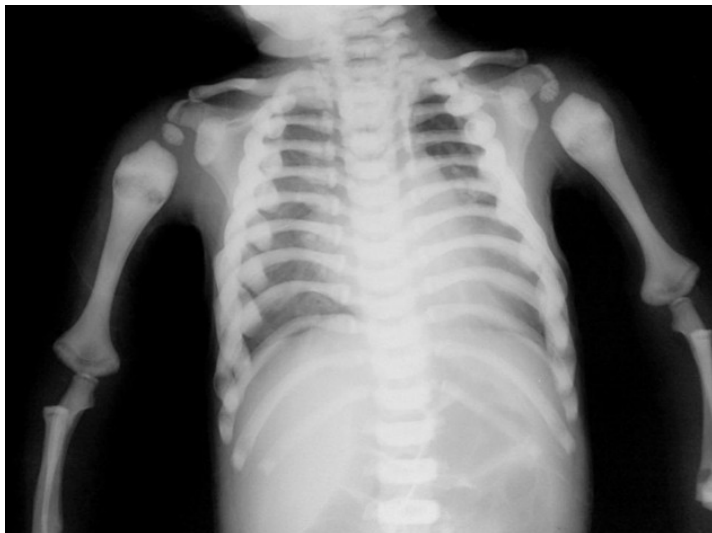- OSTEOPOROSIS**



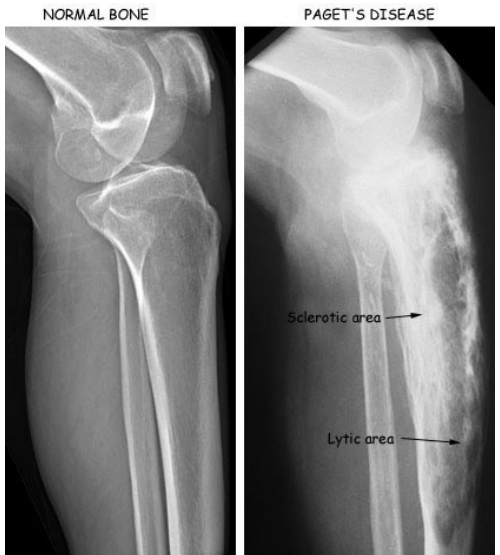- REVMATOID ARTHRITIS**



- OSTEOPETROSIS**



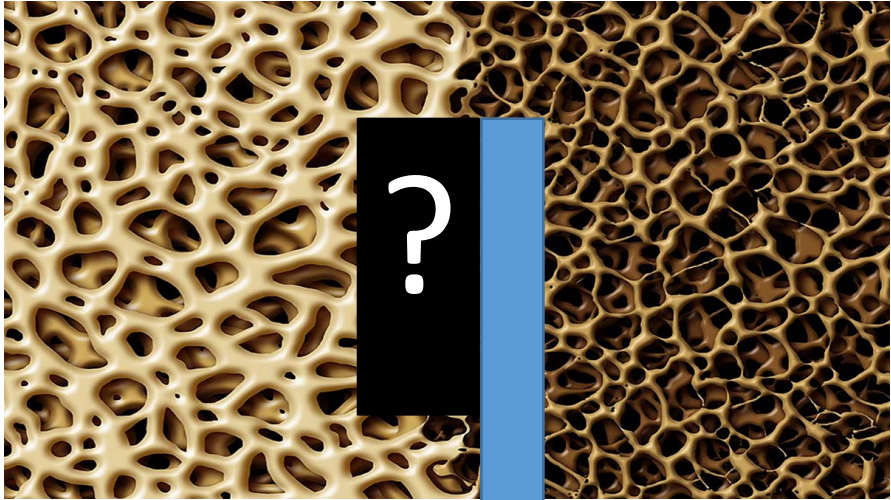


- PAGET DISEASE**



DISBALANCE OF BONE HOMEOSTASIS

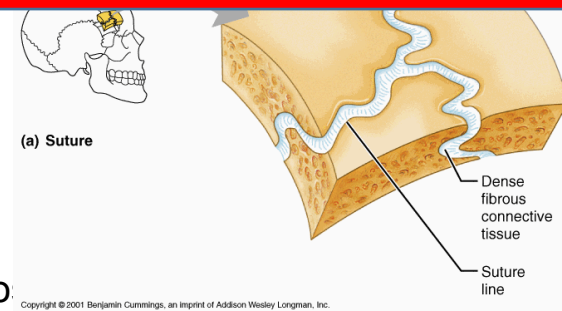
Valerij Poljakov
438 days in space
MIR



JOINTS

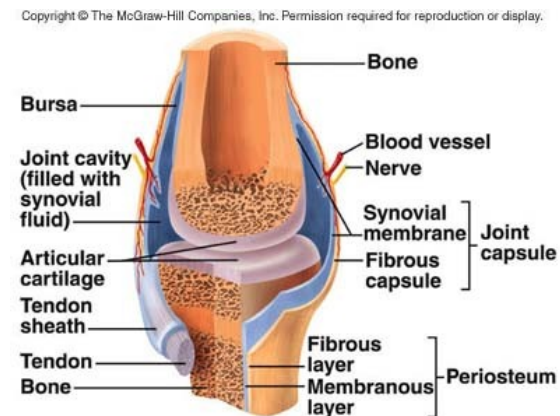
Synarthrosis

- joint by intercalated tissue (cartilage, bone or c.t.)
 - **Synostoses** – joint by bone tissue – os coxae, os sacrum
 - **Synchondrosis** – joint by hyaline cartilage – development of synostosis
 - **Symphysis** – joint by fibrocartilage – os pubis, intervertebral discs
 - **Syndesmosis** – dense collagen regular c.t. – sutures of skull, gomphosis

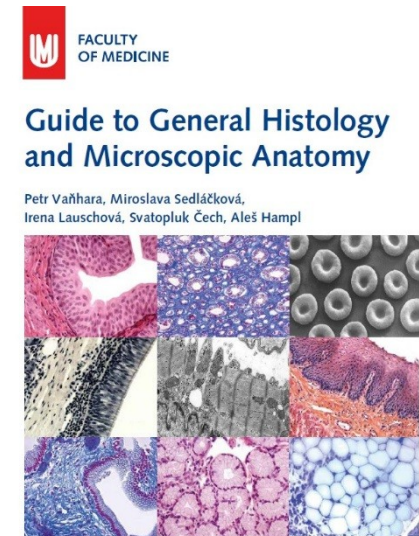

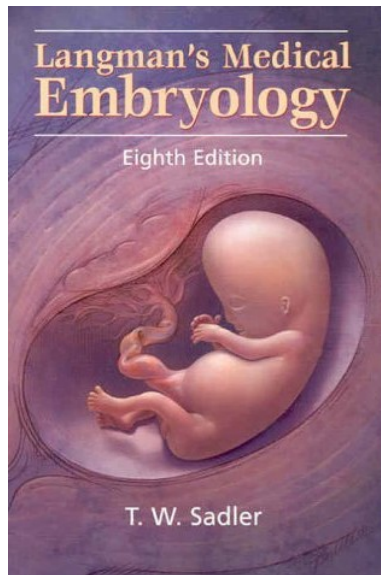







Diarthrosis

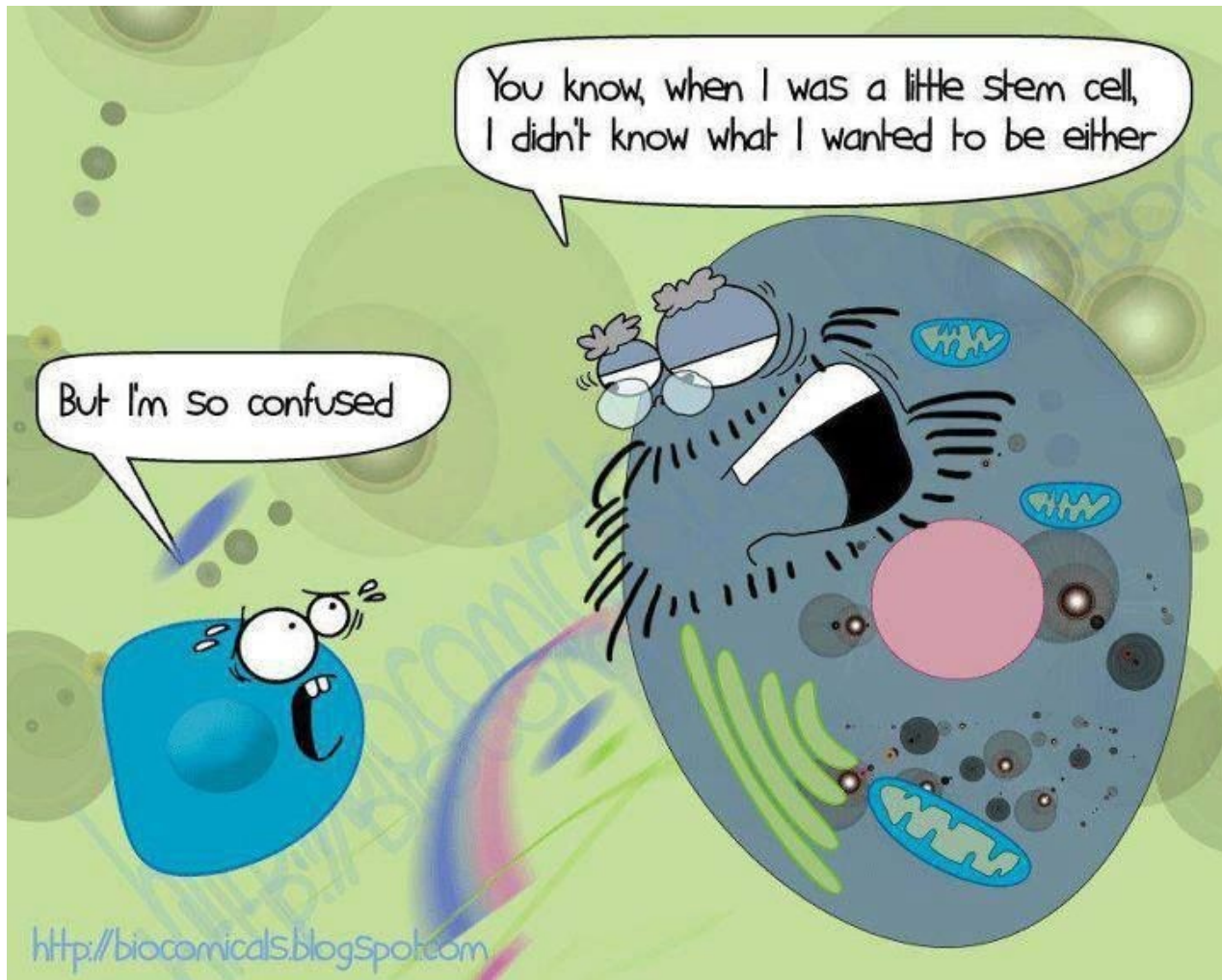
- synovial joint
 - hyaline cartilage without perichondrium
 - cartilage calcification in site of attachment to the bone
 - joint capsule
 - *Stratum fibrosum*
 - *Stratum synoviale*
 - meniscus – fibrocartilage, avascular, without innervation
 - tendons – dense collagen regular c.t., elastic fibers
 - bursae – like joint capsule



FURTHER STUDY



Masaryk University, Brno 2017



Thank you for attention