

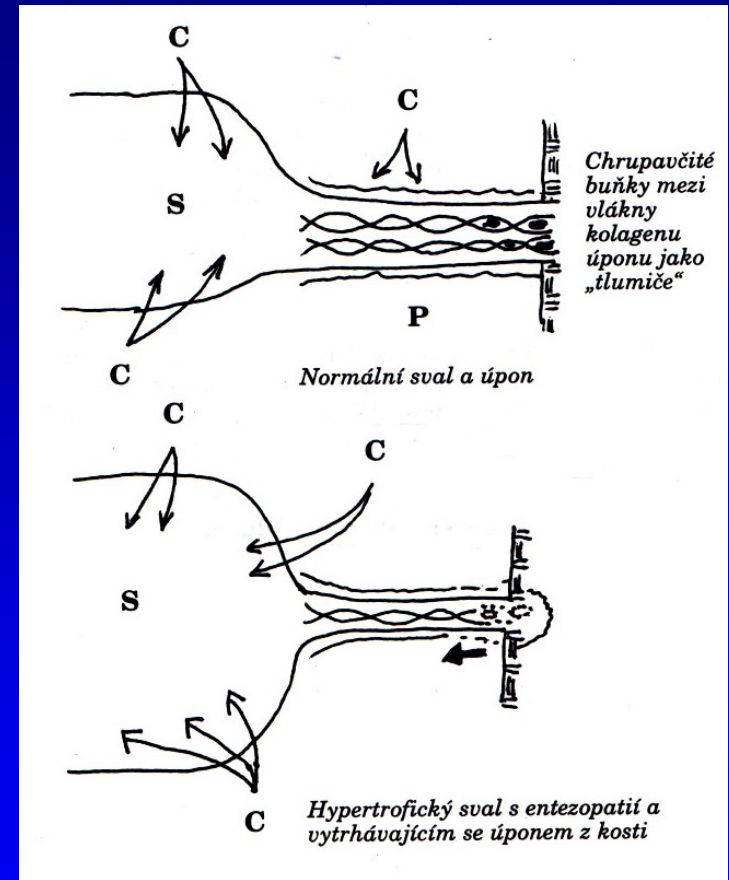
# Entesopathy

Z. Rozkydal

# Entezopathy

Pathological changes of insertions of tendons, ligaments and joint capsules into the bone

Dystrophia, microruptures of Sharpey's filaments from bone inflammation, periostitis ossifications, metaplasia



Tendinopathy: disorders in tendons and tendon sheaths

# Cause

Acute and chronic overloading

Microtraumatisation

Repetitive movements and activities

# Tennis elbow

## Epicondylitis radialis humeri

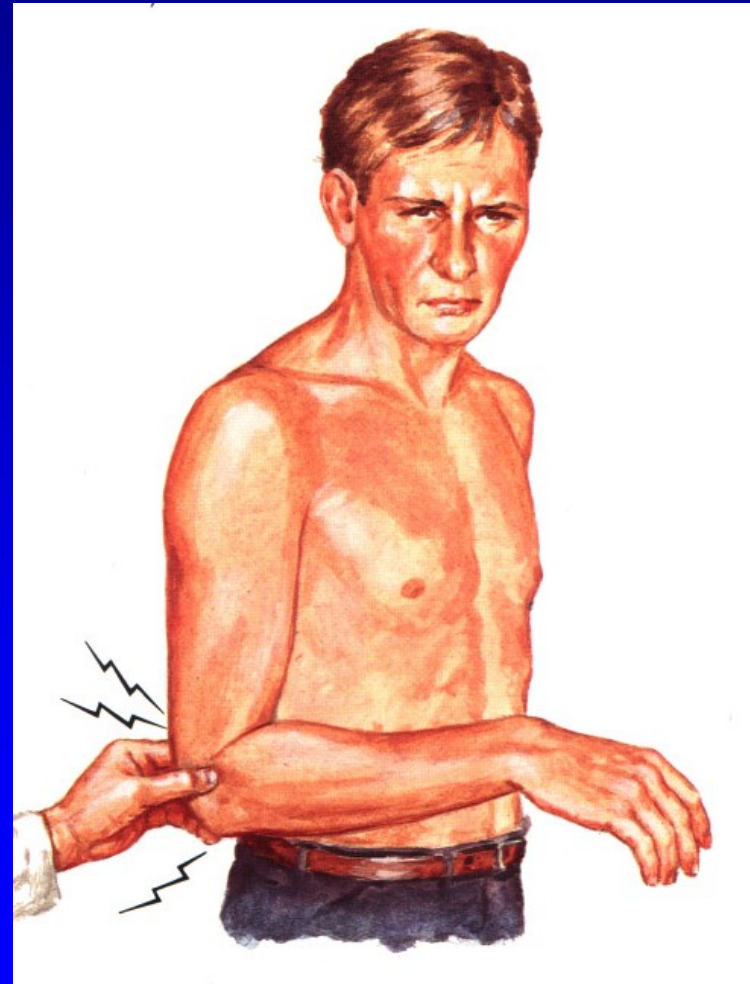
Pain with activity of extensors

Tenderness

Painful supination

Painful resisted dorsiflexion of the wrist  
and of the third finger

Chair test



# Tennis elbow- the cause

Entesopathy

Bursitis

Ossifications of insertion of extensors

Painful annular ligament

Painful synovial plica

Osteochondrosis dissecans

Pressure of radial nerve

Referred pain from cervical spine and shoulder

# Tennis elbow

## Conservative treatment

Rest, NSAID

Stretching, sling

Corticosteroids locally

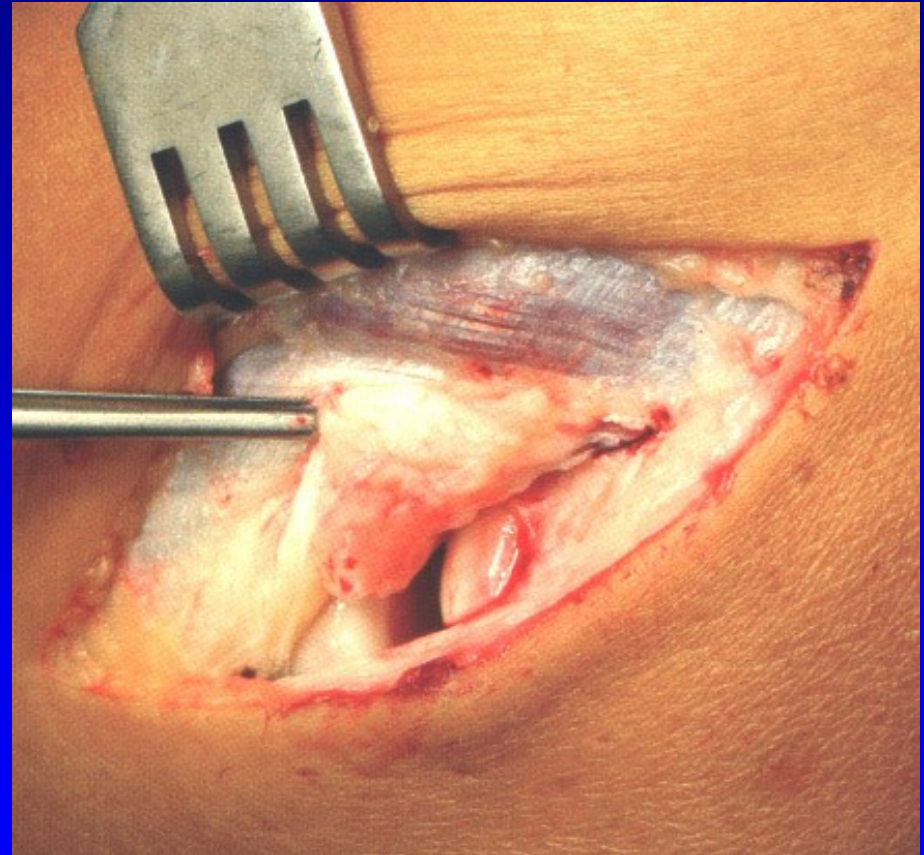
Physiotherapy

Orthosis or immobilisation

## Operative treatment

Op. sec. Hohman

Op. sec. Boyd- McLeod



# Golf elbow - Epicondylitis ulnaris humeri

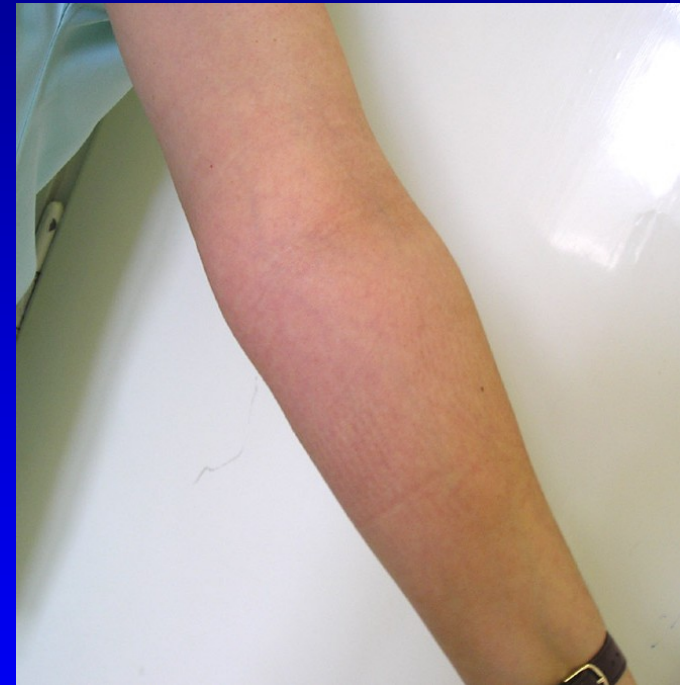
Entesopathy of insertions of flexors  
on the ulnar epicondyle

Pain, tenderness

Resisted movements

Treatment:  
Conservative

Operative  
Distalisation of flexor's insertion



# Bursitis of olecranon

Swelling and fluid  
Tenderness

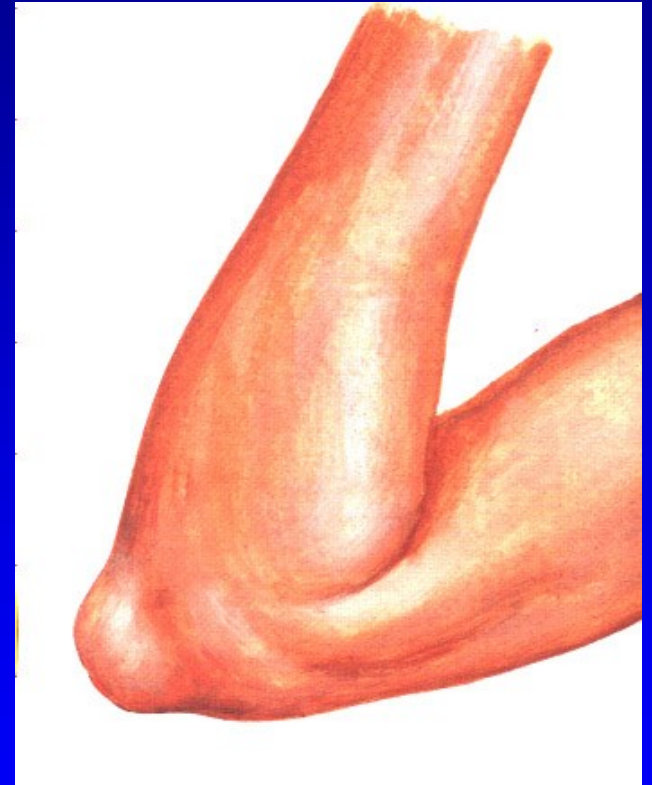
Treatment:

Aspiration, NSAID

Bandage, immobilisation

Corticoids locally

Risk of pyogenic inflammation





# M. de Quervain

Stenosing tenosynovitis of  
long abductor and short extensor  
of the thumb

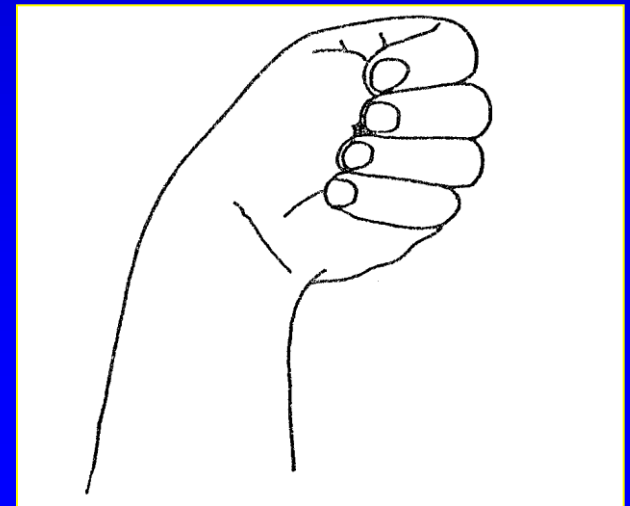
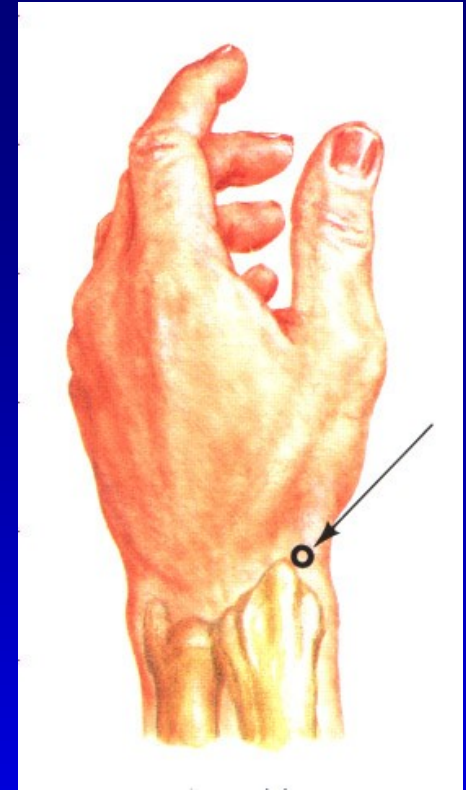Tenderness over styloid process  
Finkelstein test

Treatment

Rest, orthosis, plaster

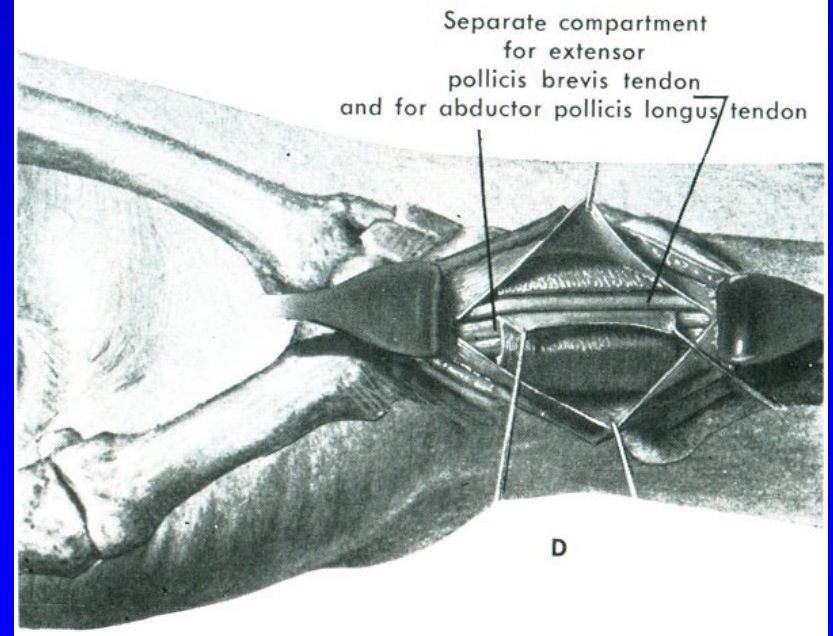
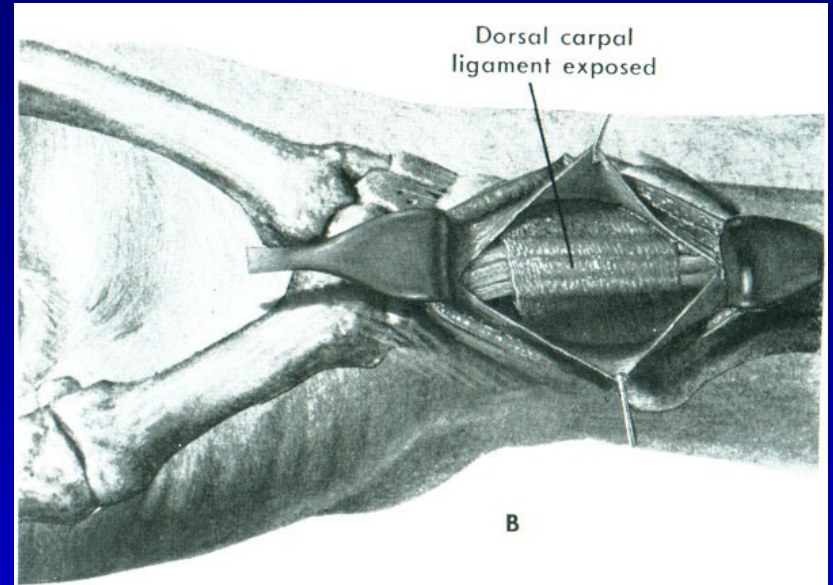
NSAID, corticoids

Surgery



# M. de Quervain

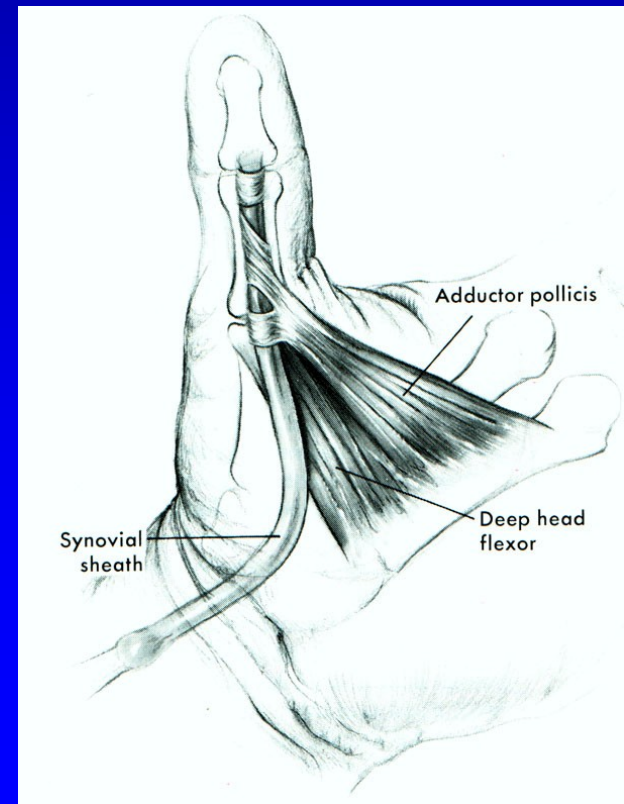
## Dissection of the tendon sheat



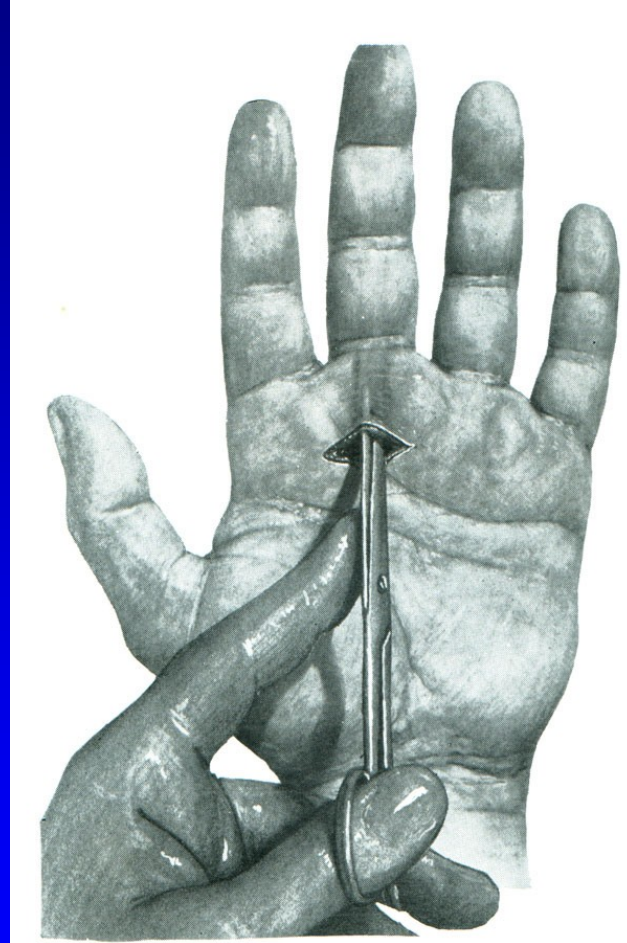# Trigger thumb - pollex saltans

- Snapping of the thumb
- In childhood, in adults
- Narrowing of flexor sheath
- Enlargement of the tendon

**Therapy:** conservative  
surgery



# Trigger finger- digitus saltans



**Th:** corticoids, rest, surgery

# Carpal tunnel syndrom

Compression neuropathy of median nerve

Pain, diminished muscle power

Hypotrophy of thenar muscles

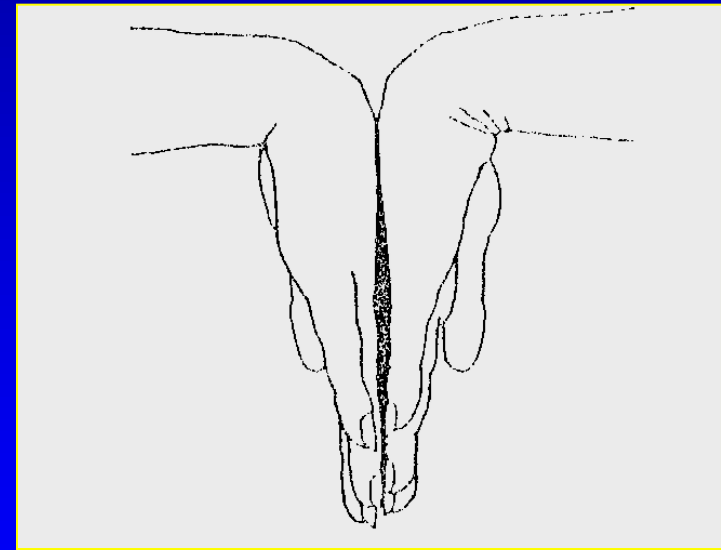
Paresthesia and numbness

Limited function of fingers

Tenderness

Tinnel sign

Phalen test



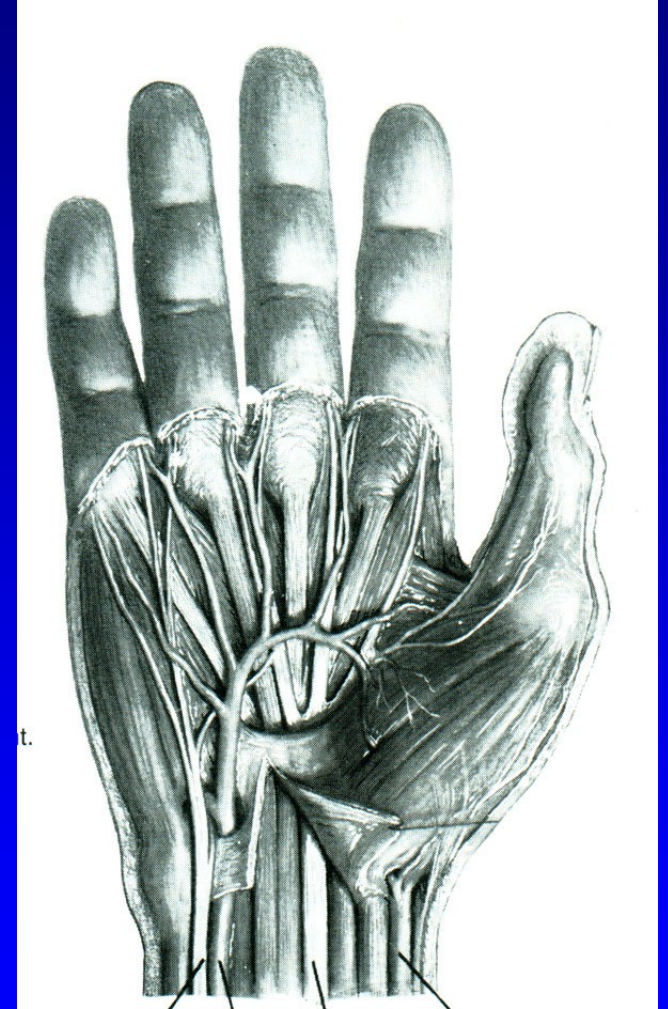

# Carpal tunnel syndrom

Therapy

Conservative

Surgery



# Guyon channel syndrom

Compression neuropathy of ulnar nerve  
in hand

Paresthesia and numbness on  
ulnar side

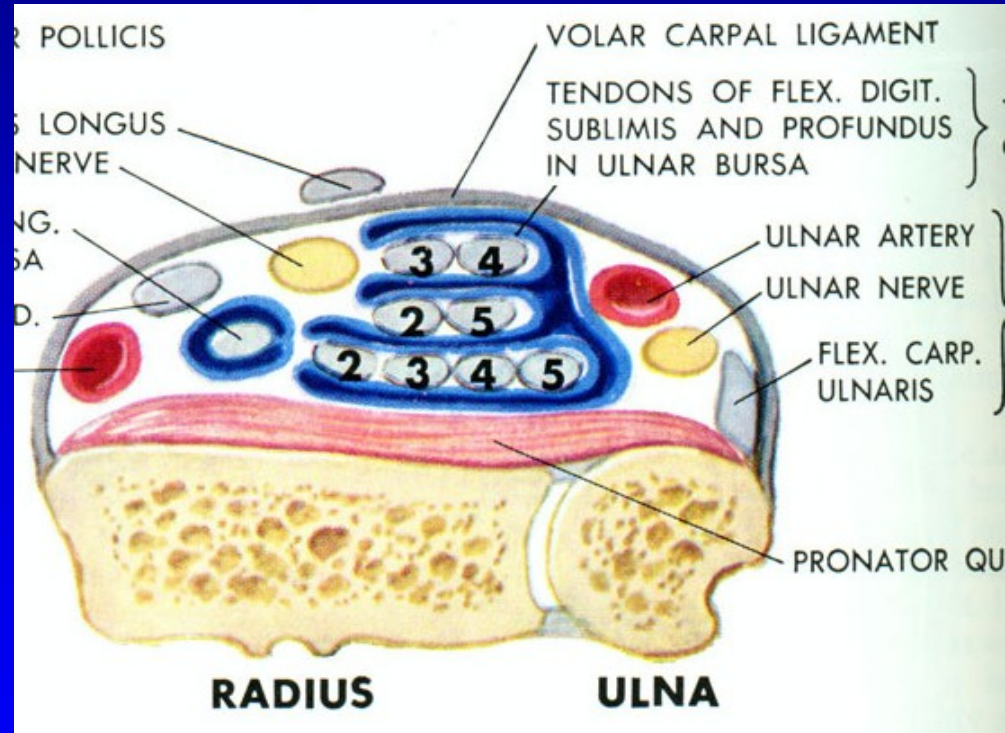
Hypotrophy of hypothenar

Limited function of 4.5. finger

**Therapy**

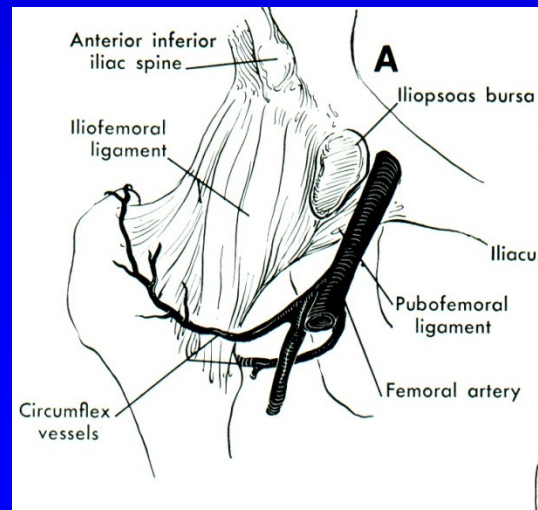
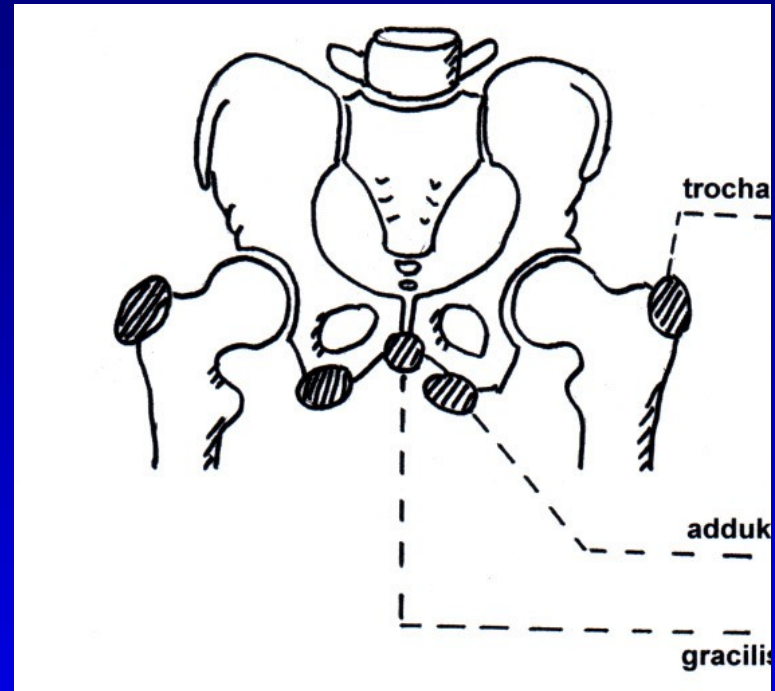
**Conservative**

**Surgery**



# Bursitis and entesopathies in the hip region

Greater trochanter  
Ischial tubercle  
Bursa ileopectinea  
Gracilis syndrom  
Spina iliaca ant. sup.  
Spina iliaca ant inf.  
Adductor entesopathy  
Snapping hip- coxa saltans  
Femoroacetabular impingement

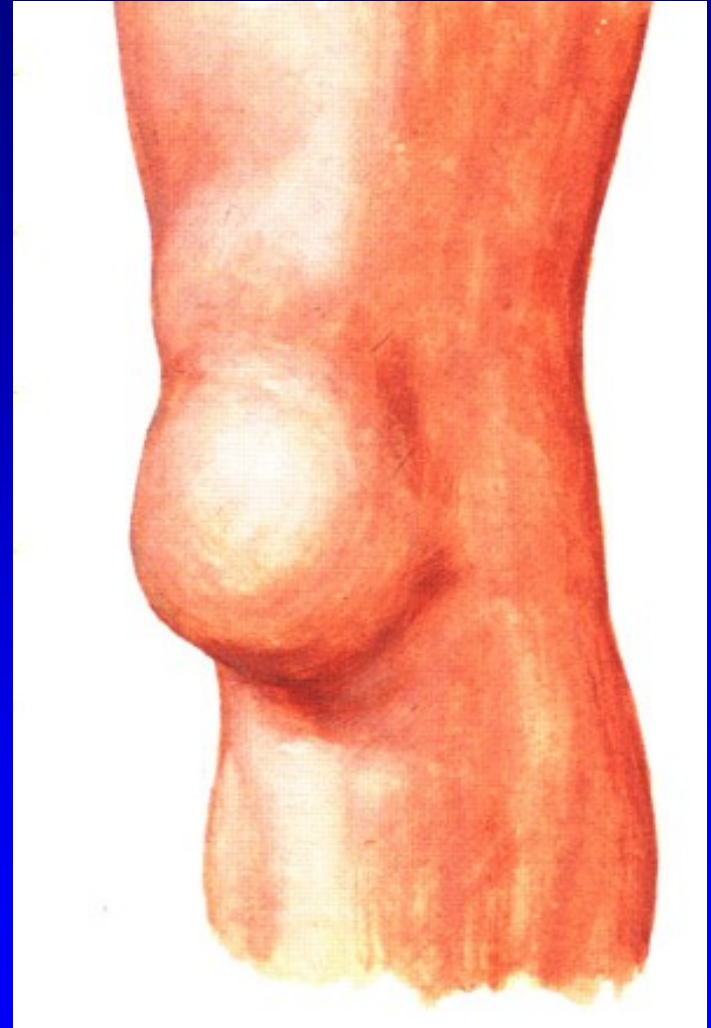




# Bursitis in the knee region

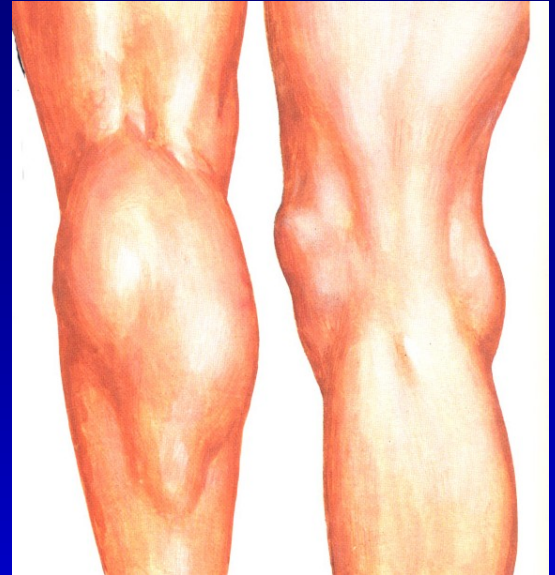
Prepatellar bursitis  
Infrapatellar bursitis  
Bursitis of pes anserinus

Therapy:  
Rest, aspiration, corticoids  
NSAID, surgery



# Baker's cyst

Bursa gastrocnemio- semimembranacea  
Is connected with joint space  
Swelling, soft mass in popliteal region  
Limited movements  
Pressure onto large veins in  
popliteal region.

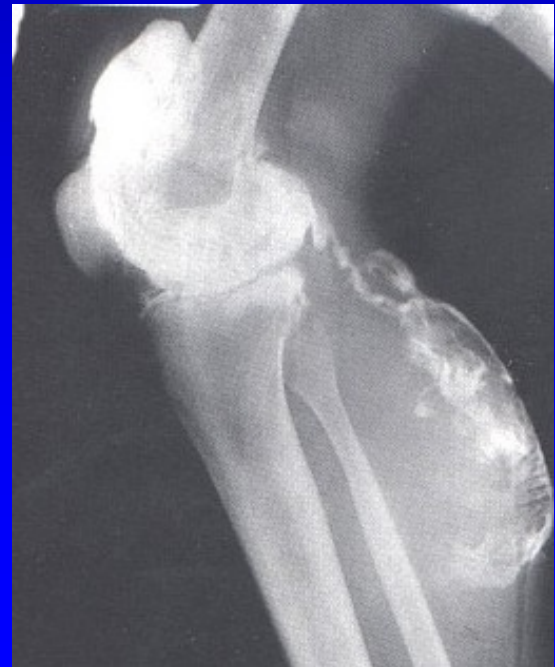

Secondary to pathology in the knee joint

Therapy:

Conservative – aspiration, local corticoids,  
NSAID

Surgery



# Entesopathies in knee region

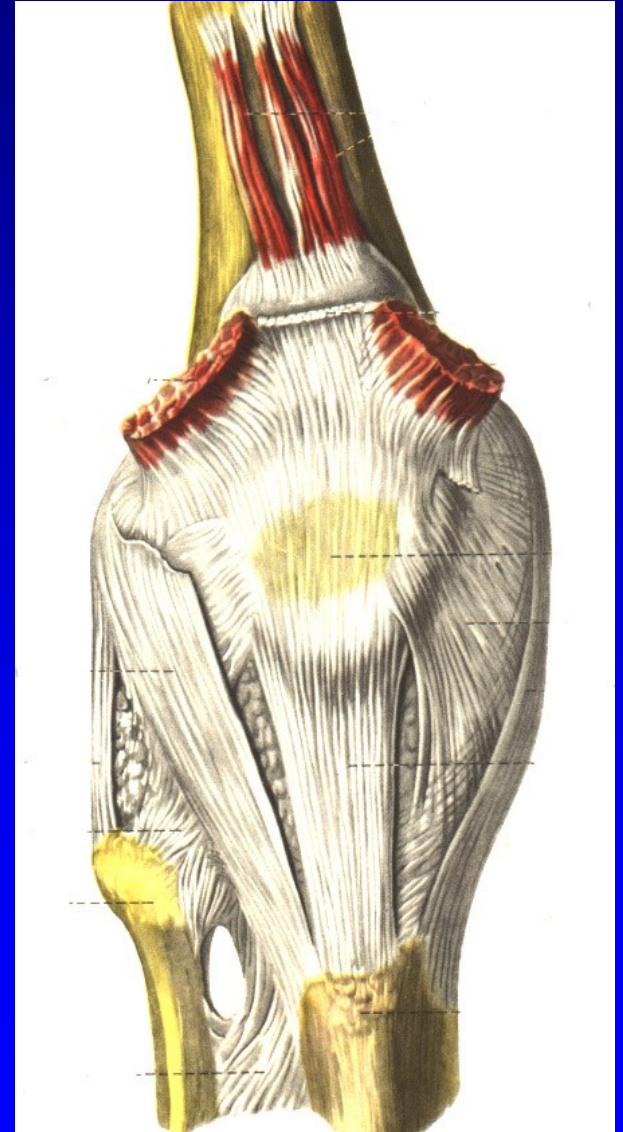
Jumper's knee

- distal pole of the patella

m. Osgood- Schlatter

Entesopathy in ligaments insertion

Entesopathy at Gerdy's tubercle



# Bursitis and entesopathies in the foot

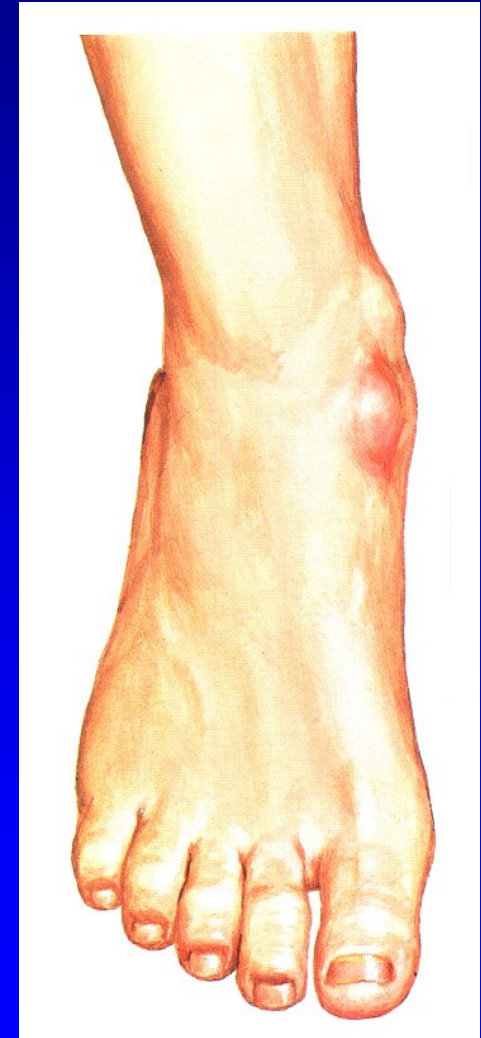
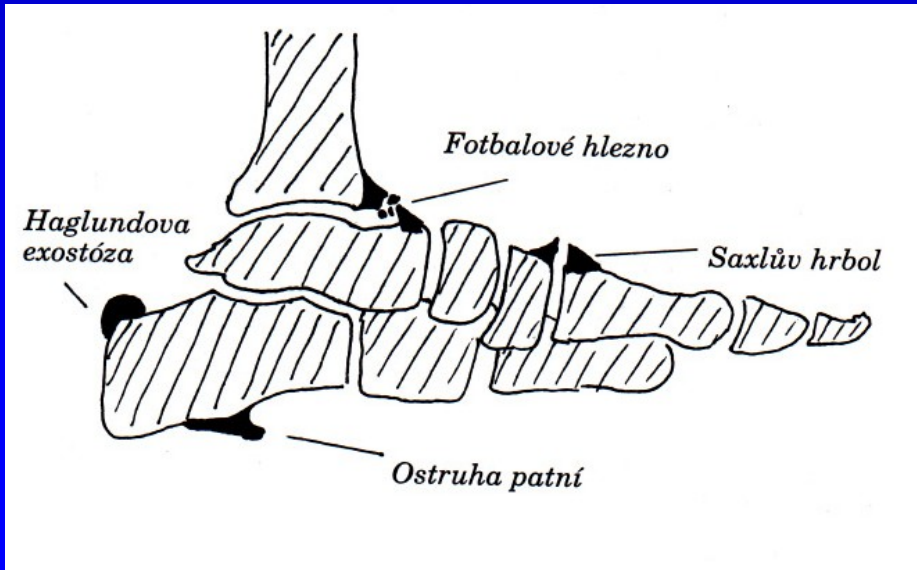
Achillodynia

Calcaneal spur

Haglund's exostosis

Osteophytes – dorsal

Os tibiale externum

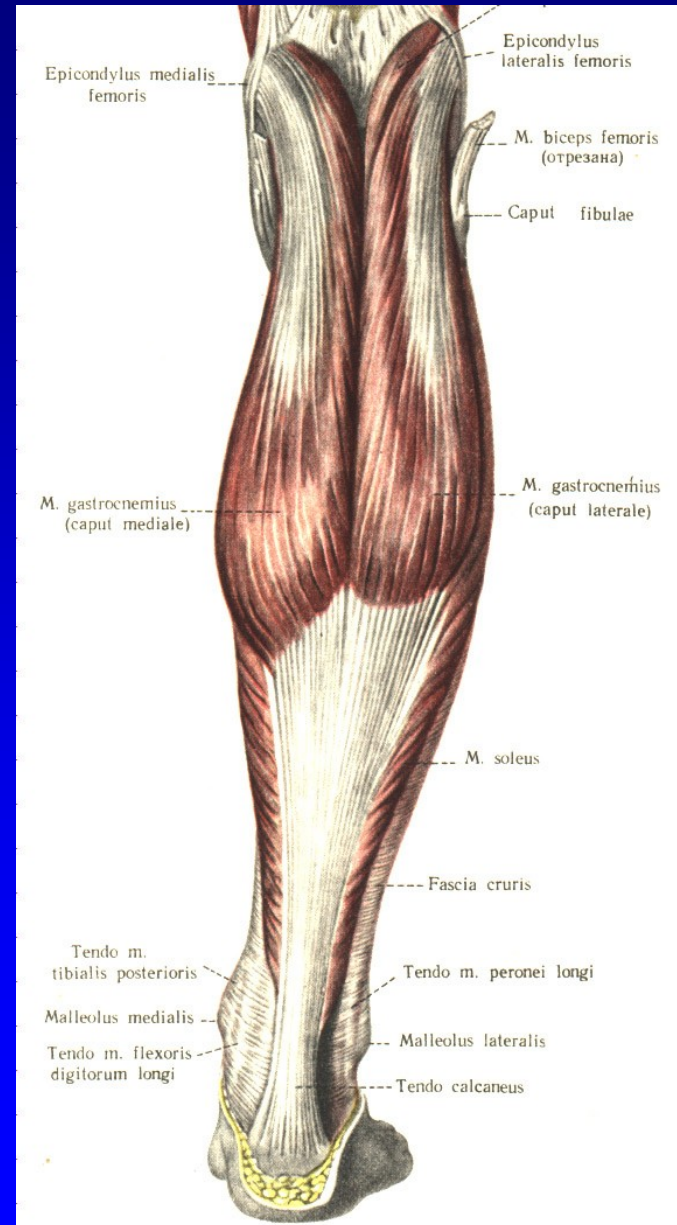


# Achillodynia

Painful Achilles tendon  
and it's insertion

Degeneration  
Haemorrhage, ruptures  
Peritenonitis

The risk of rupture





# Achillodynia

## Conservative treatment

Rest, taping, NSAID

Physiotherapy

Orthosis

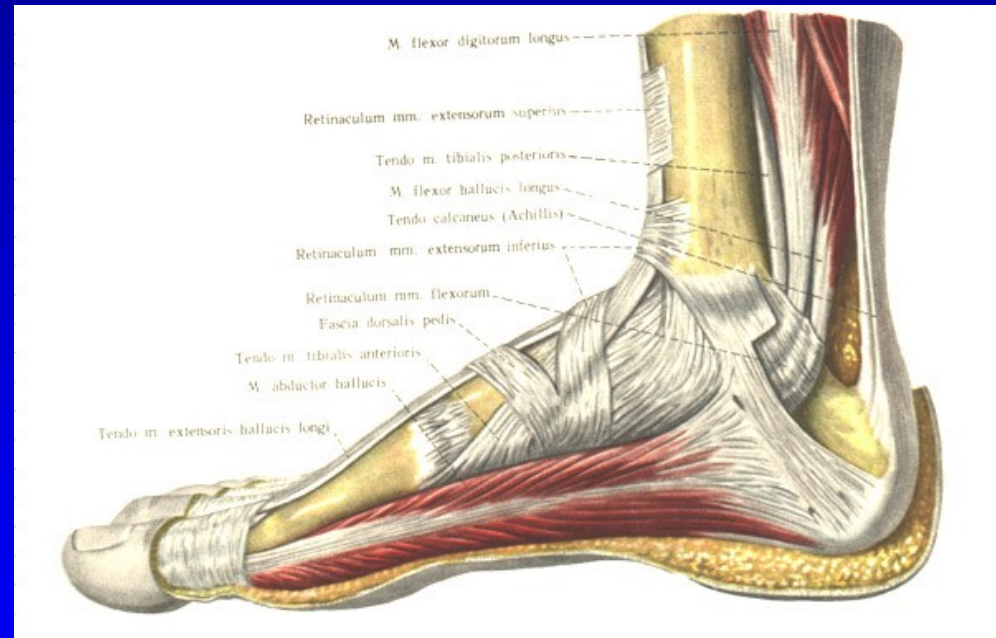
Hyaluronic acid

No corticoids !

Surgery:

Peritenonectomy

Excision of necrotic tissue



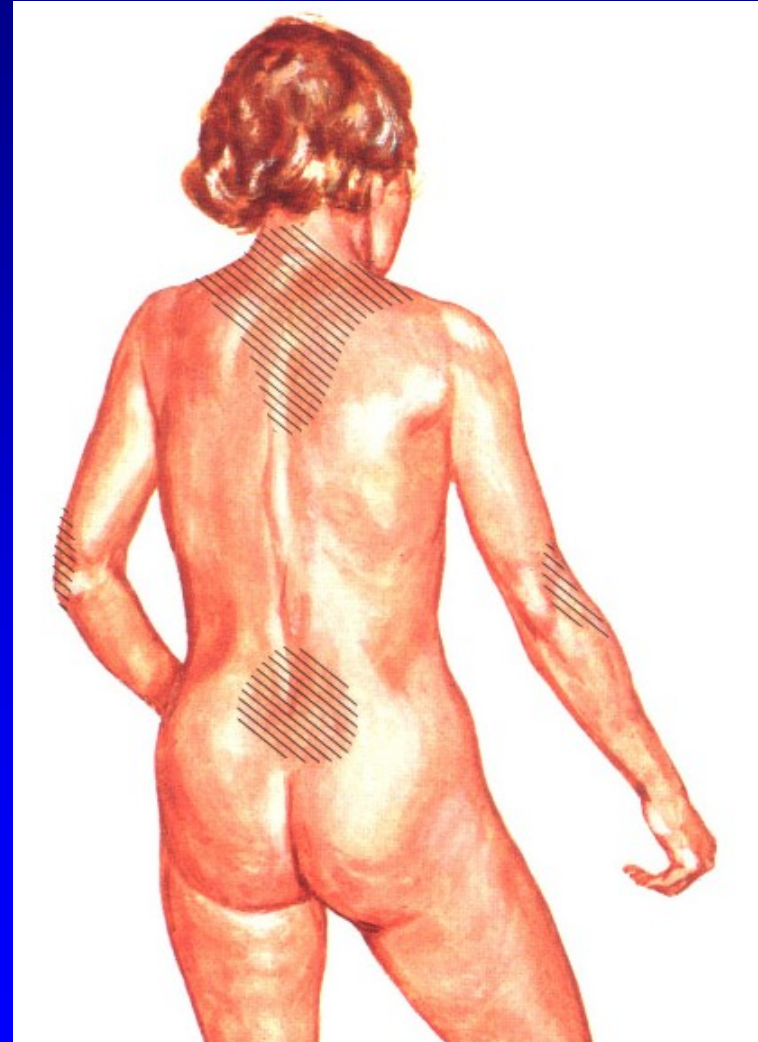# Entesopathy at the spine

Painful insertions of ligaments  
and tendons

Transverse or spinal processes

Scapula

Pelvis



# Painful shoulder

Tenosynovitis of tendon of long head of biceps

Rupture of tendon of long head of biceps

Subacromial bursitis

Supraspinatus tendinitis

Rotator cuff rupture

Impingement syndrom

Frozen shoulder syndrom

Osteoarthritis of glenohumeral joint

Disorders of acromioclavicular joint

Inflammations

Tumors

Referred pain from cervical spine



# Tenosynovitis of long head of biceps

Tenderness

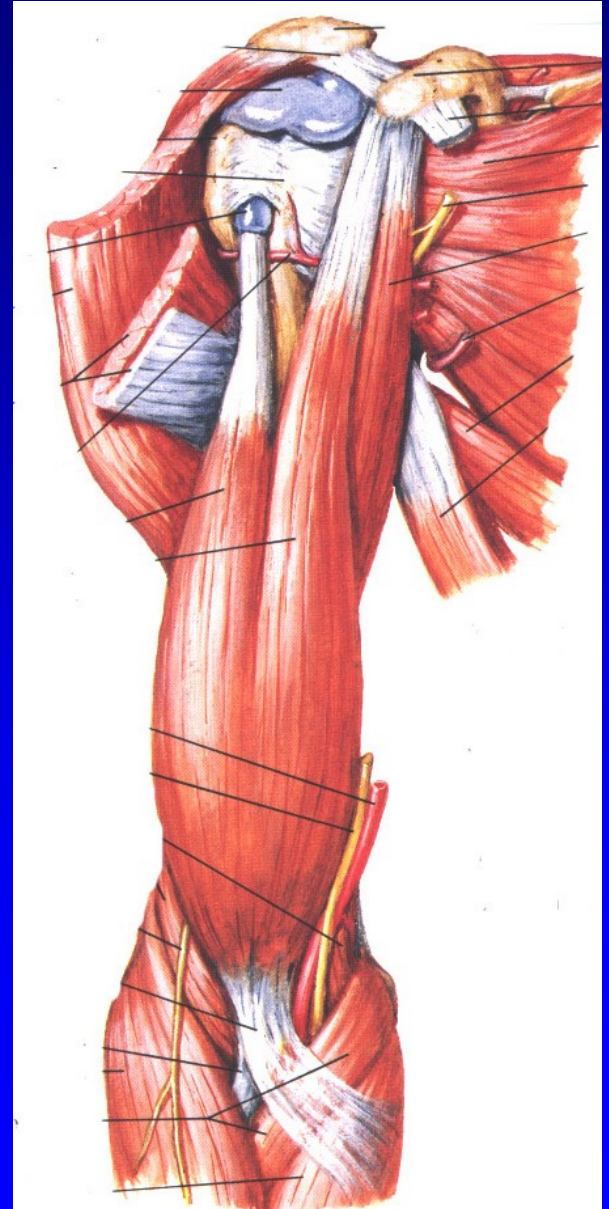
Resisted flexion and supination  
of the elbow

Therapy:

Corticosteroids locally

Rest, sling

NSAID



# Rupture of long head of biceps

Therapy:

Rest, sling

NSAID

Surgery – up to 40 years

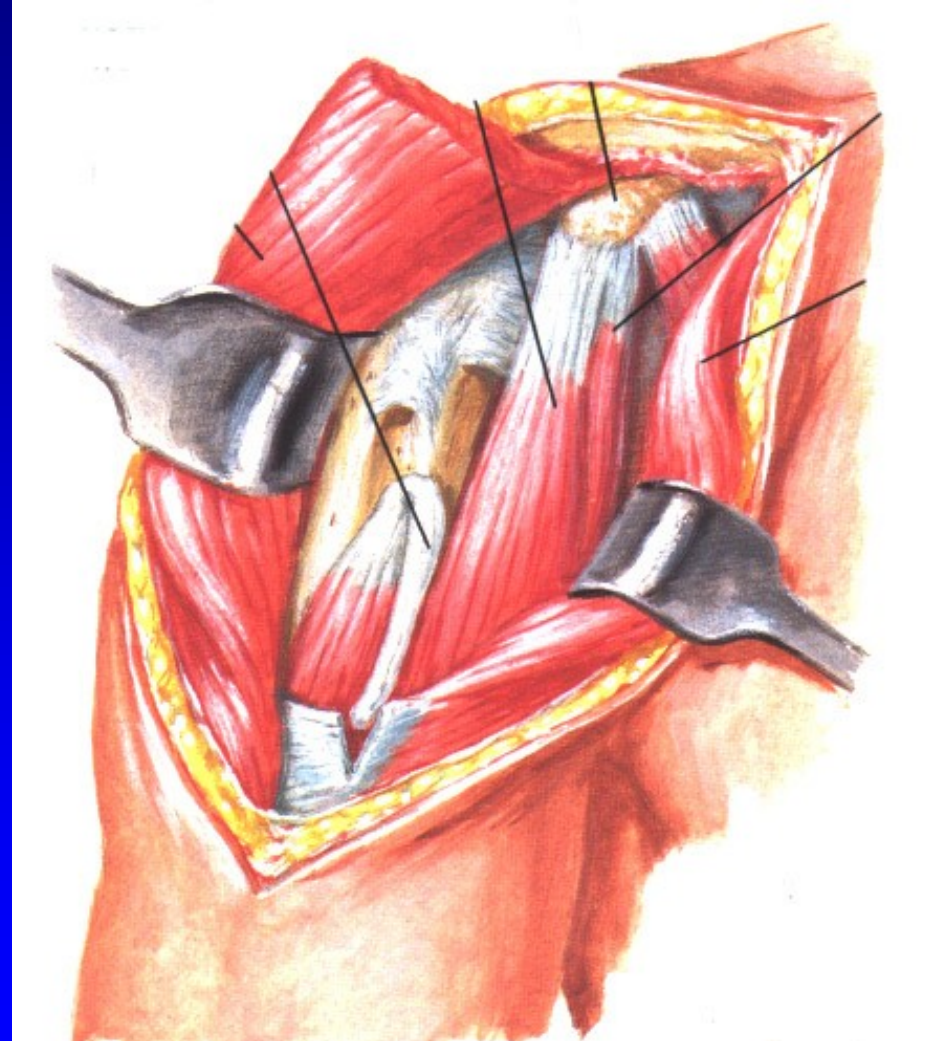
Conservative- over 40 years

Surgery:

key hole fixation to the humerus

Suture to the short head

of biceps



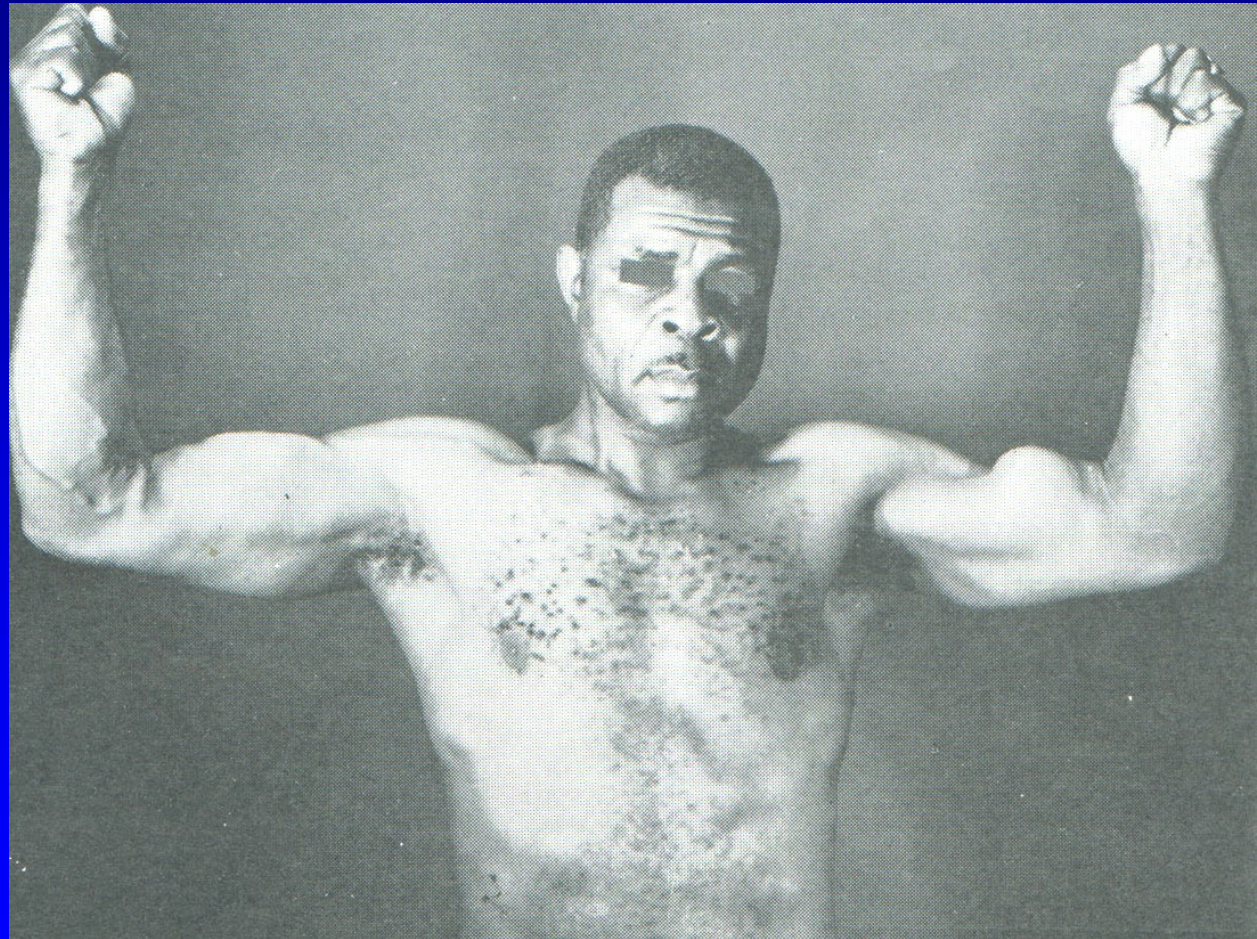


# Rupture of long head of biceps

Tenderness

Distalisation of  
muscle belly

Diminished strength





# Subacromialis bursitis

Inflammation

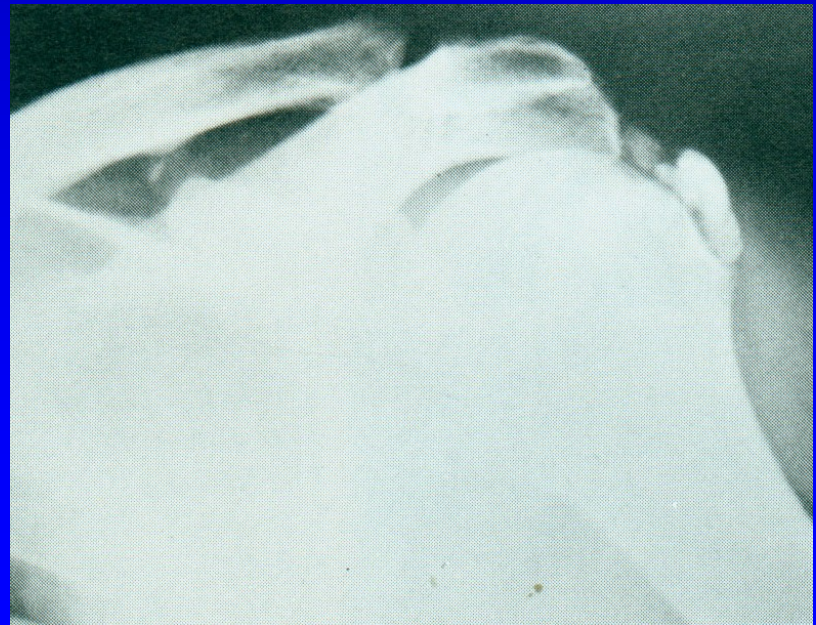
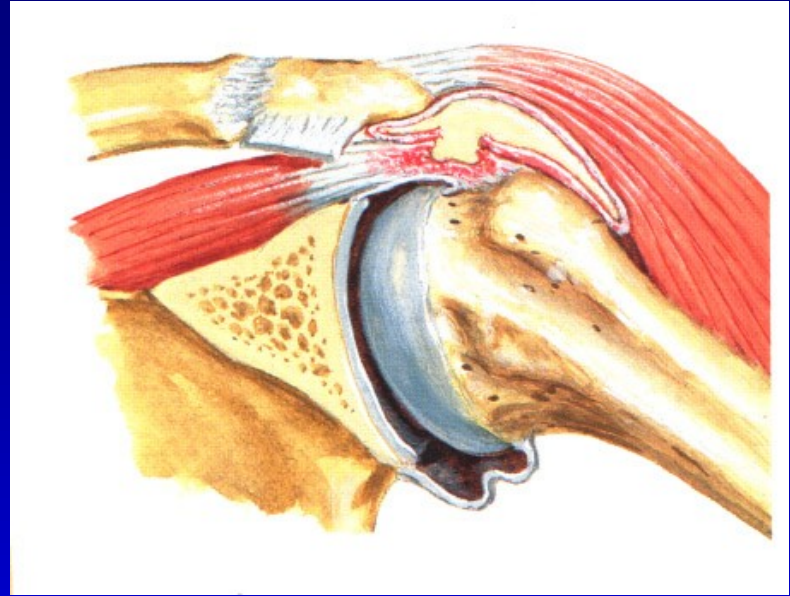
White fluid

Severe, burning pain

Restricted movements

Tenderness

Calcifications



# Subacromial bursitis

Conservative treatment:

Rest, sling

Lavage with 2 needles

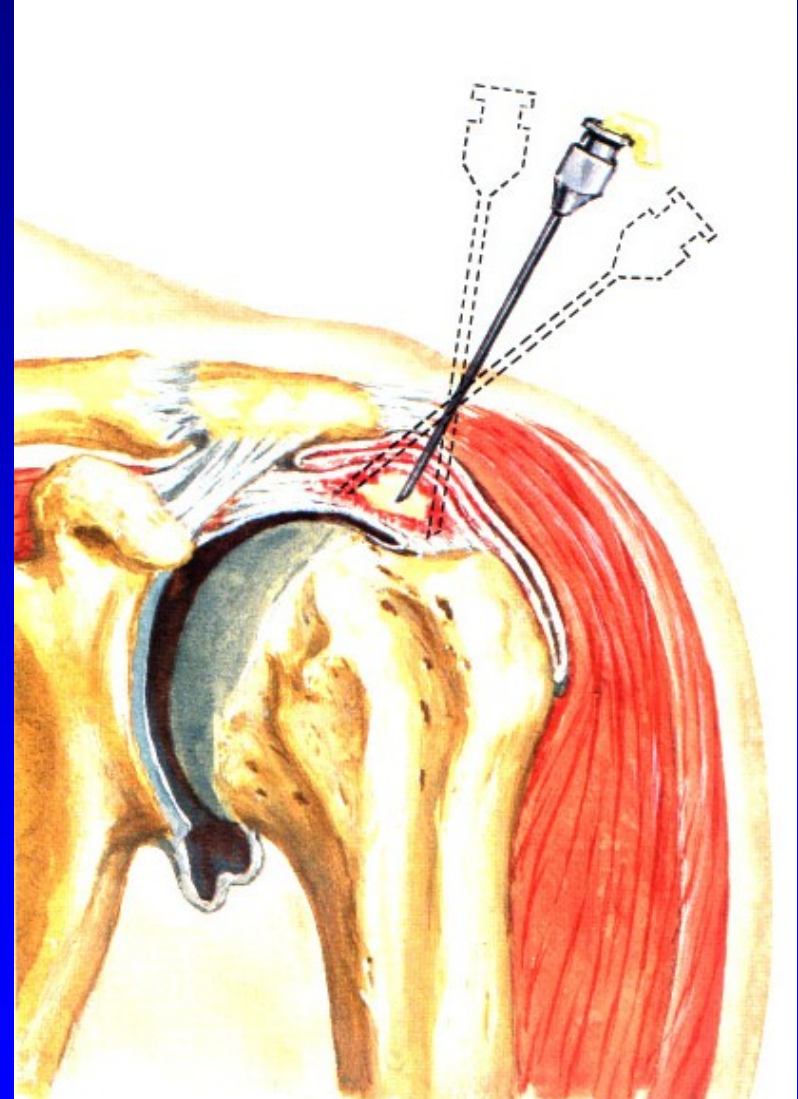
Corticosteroids locally

NSAID

Physiotherapy

Surgery:

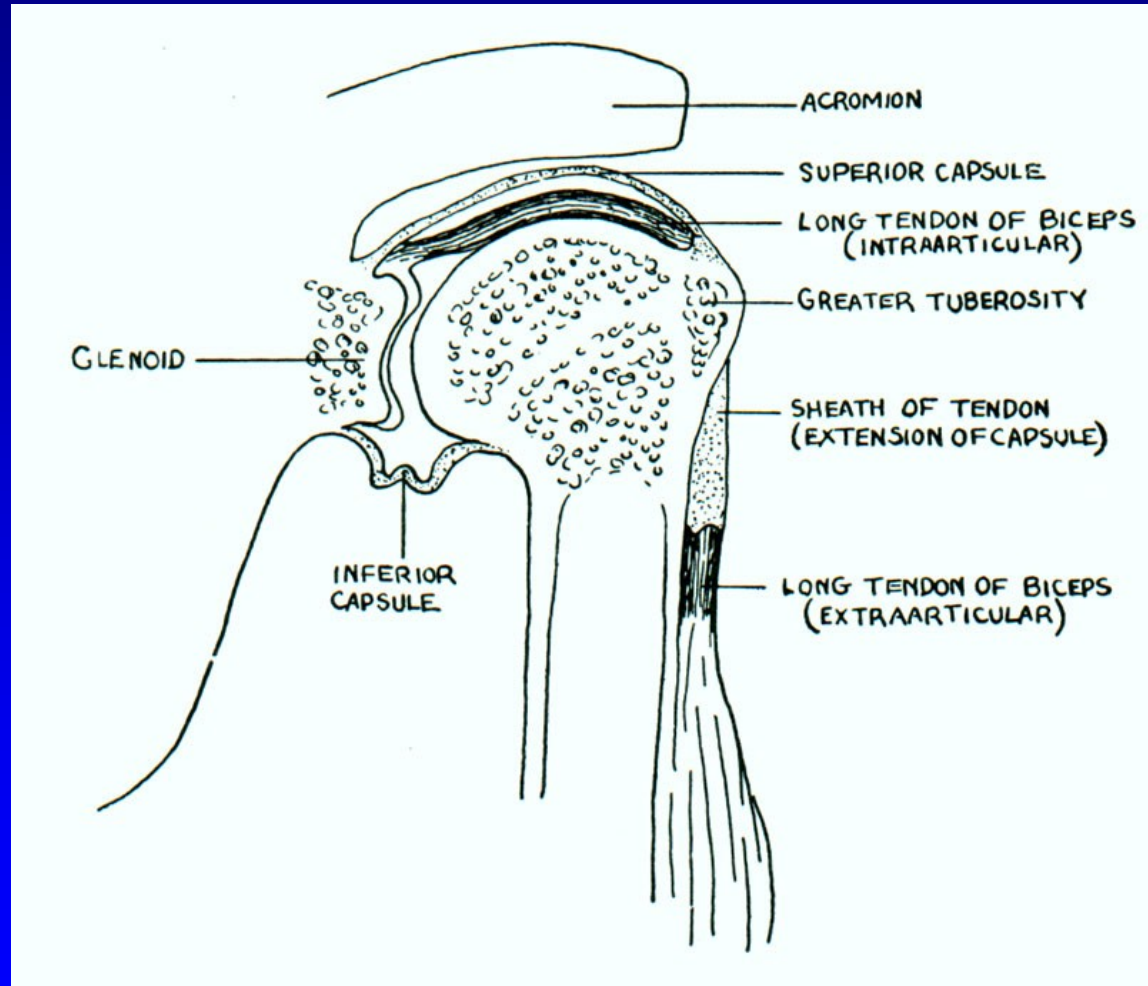
Removal of bursa



# Supraspinatus tendinitis

Tenderness over greater tuberosity  
Limited movements

Therapy:  
Rest, NSAID  
Corticosteroids  
Physiotherapy





# Rotator cuff

Rotator cuff:

m. supraspinatus

m. infraspinatus

m. teres minor

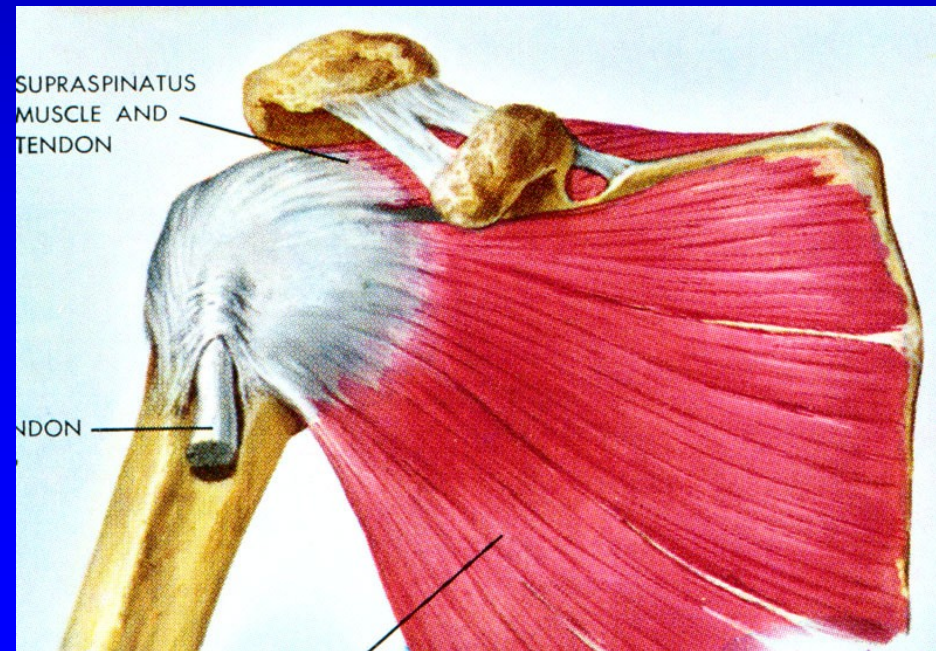
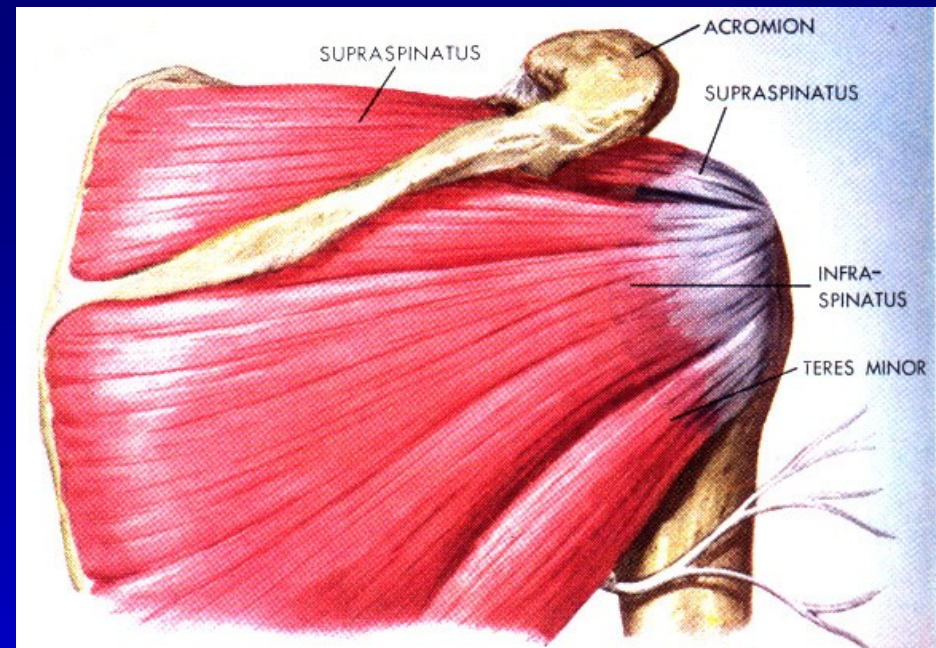
m. subscapularis

Function:

First 30° of abduction

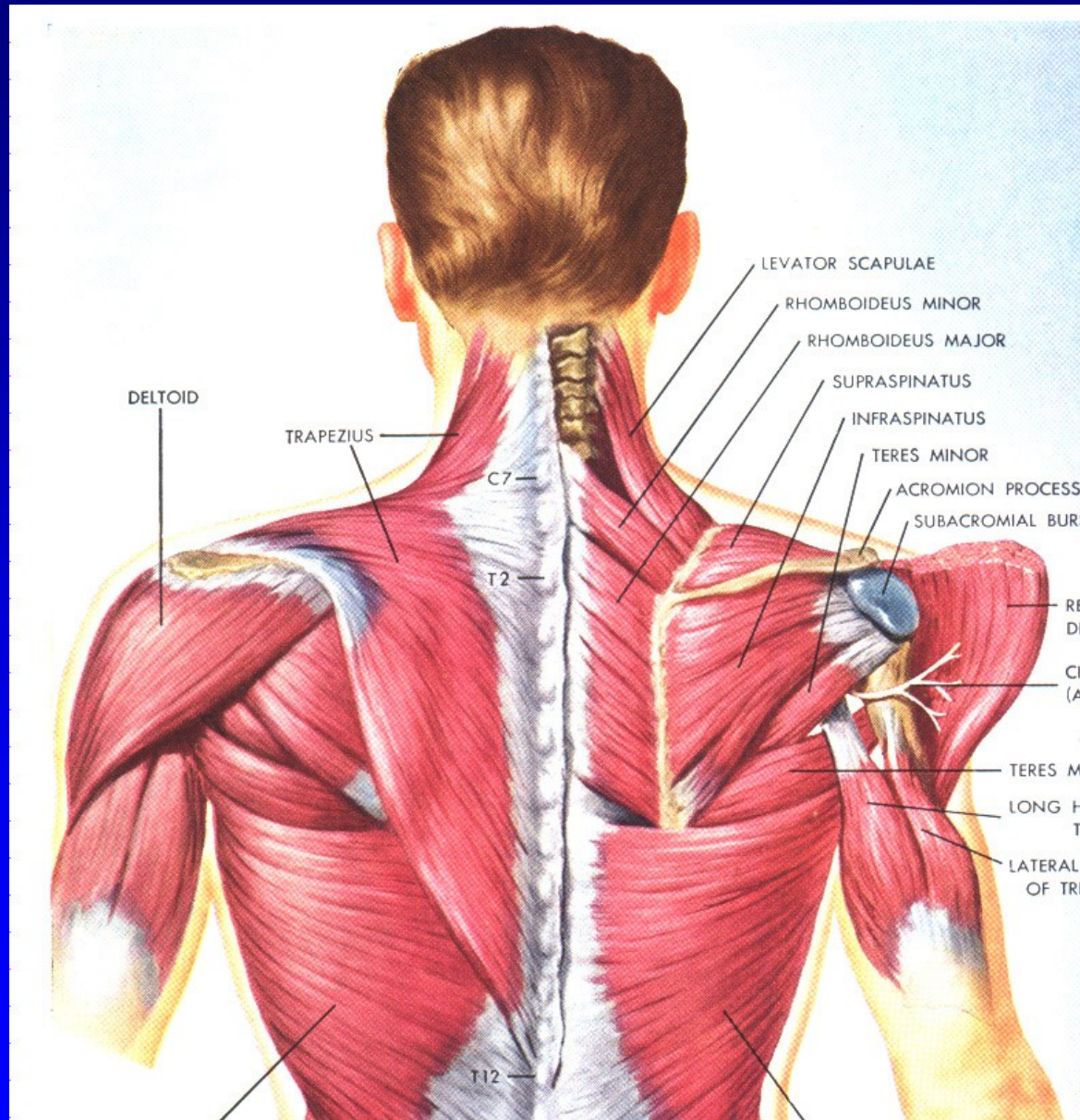
Pressure of the humeral head  
into glenoid cavity

Depressor of the humeral  
head



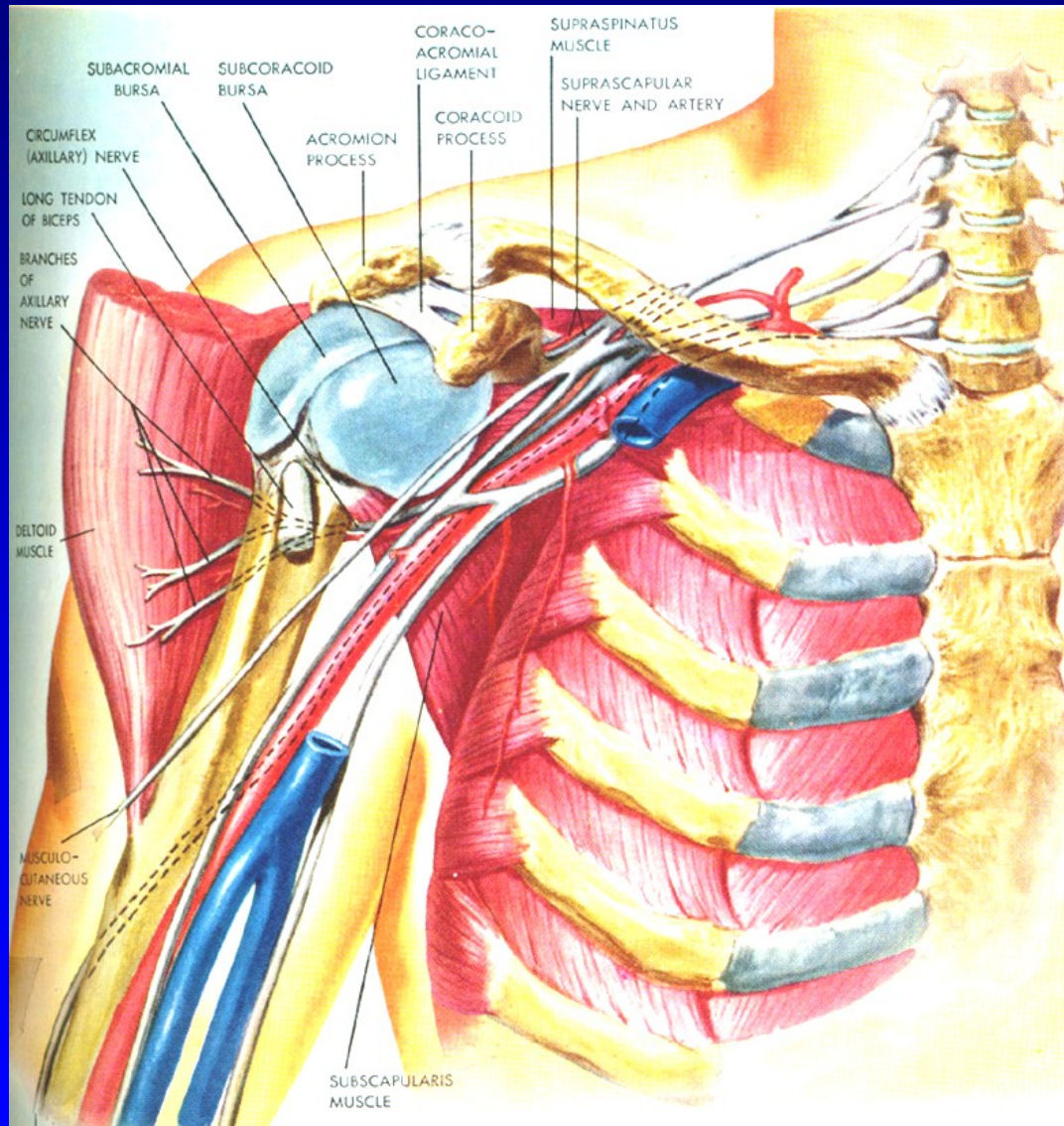


# Anatomy of the shoulder





# Anatomy of the shoulder



# Rupture of rotator cuff

Partial rupture:

Severe pain

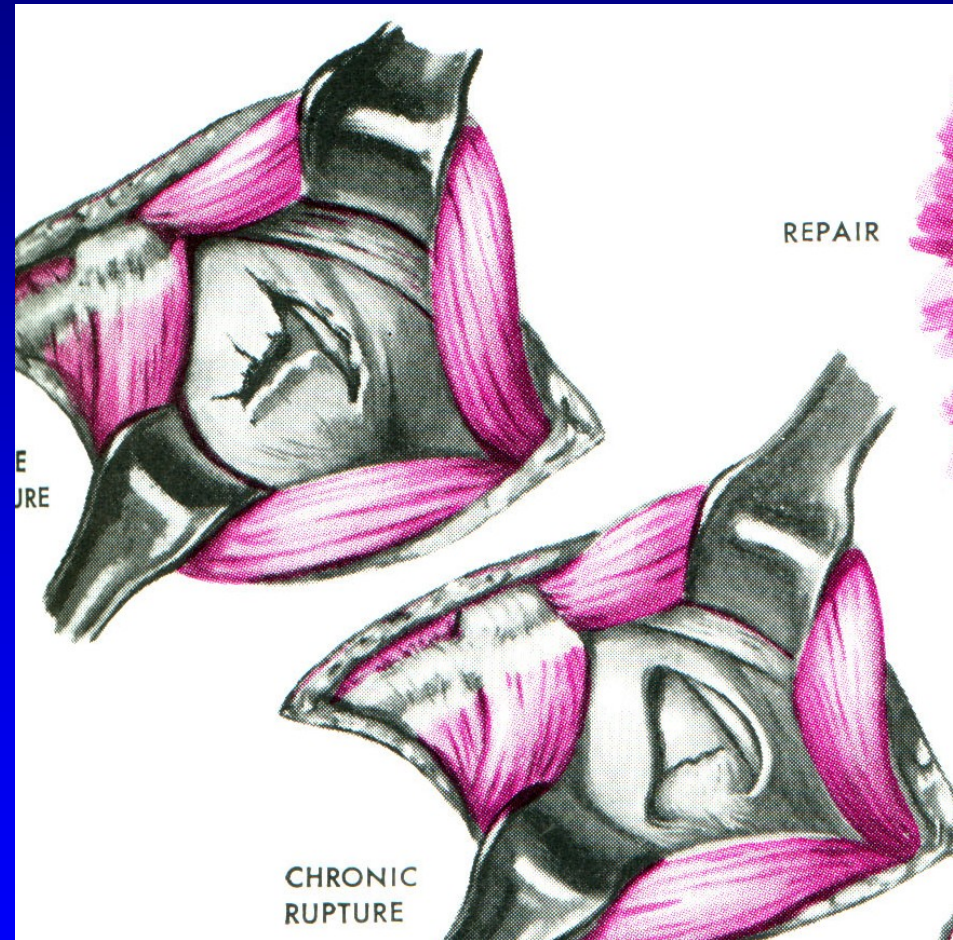
Painful arc

Painful abduction

Keeps the arm in position  
of adjusted abduction

Ultrasonography

Management: conservative

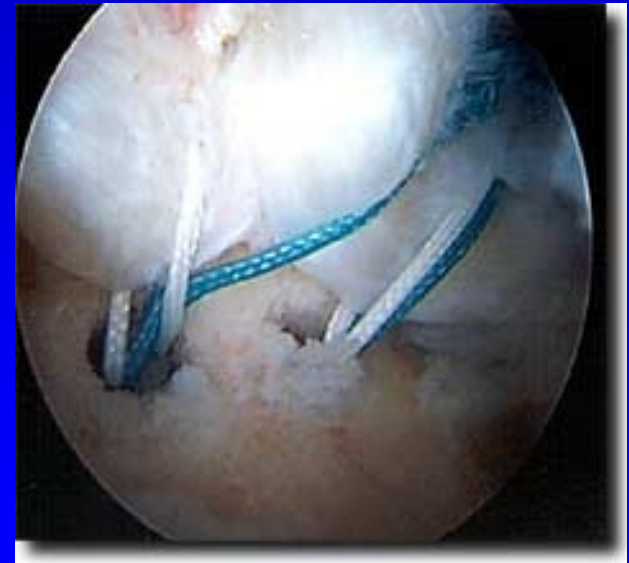
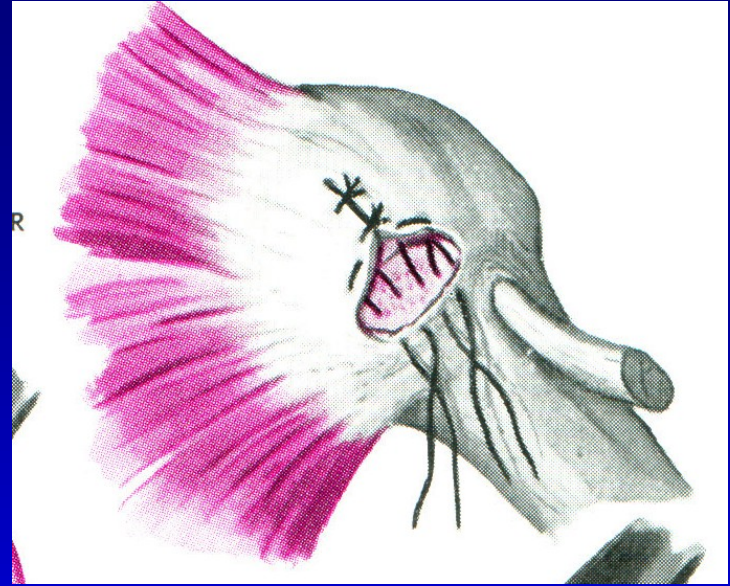




# Rupture of rotator cuff

Complete rupture:  
No active abduction  
Lifting of the shoulder

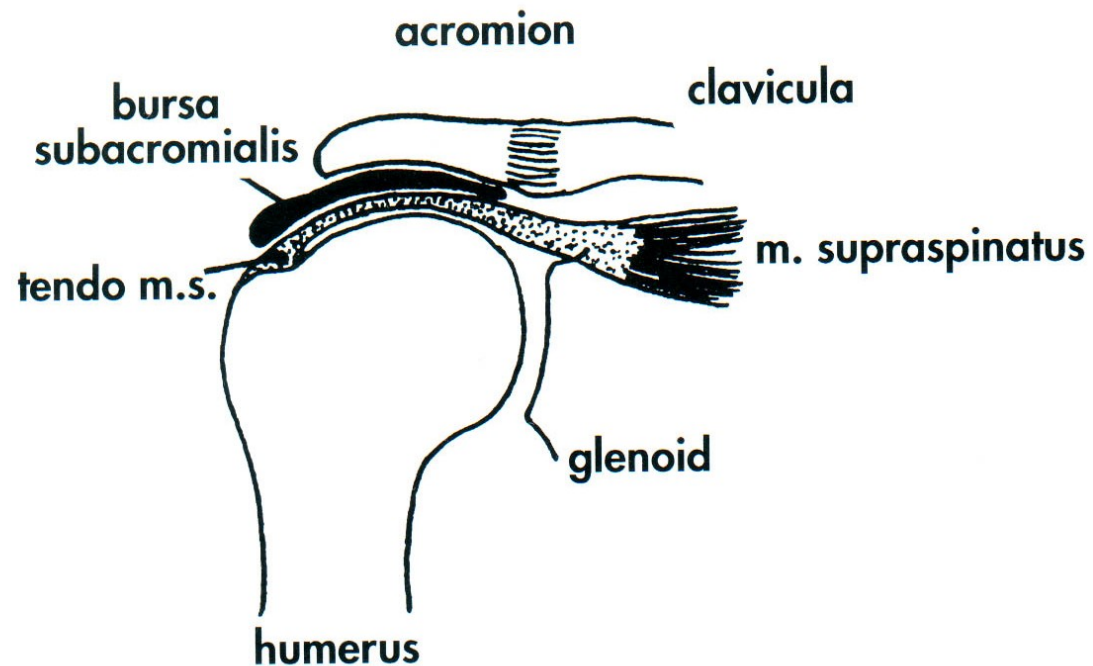
Managemet:  
suture: ASC, open surgery  
- attachment to greater  
tuberosity



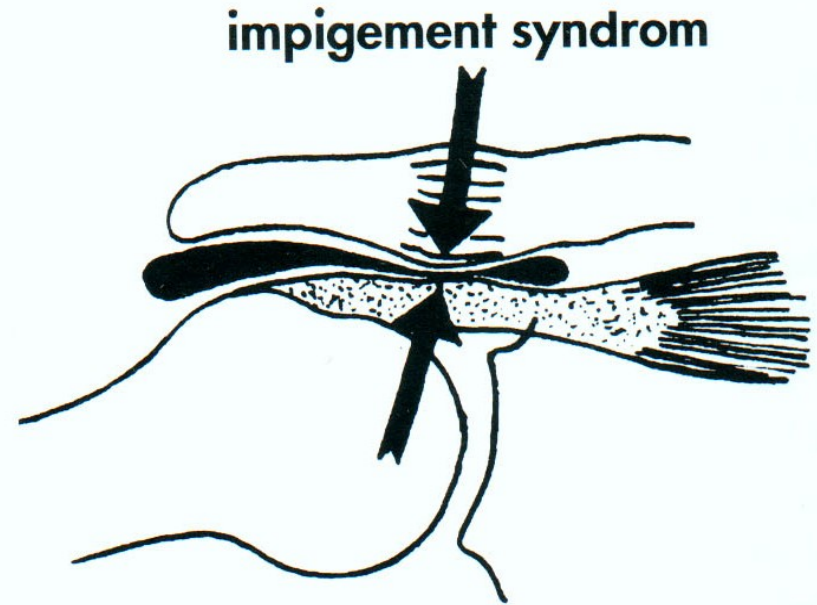
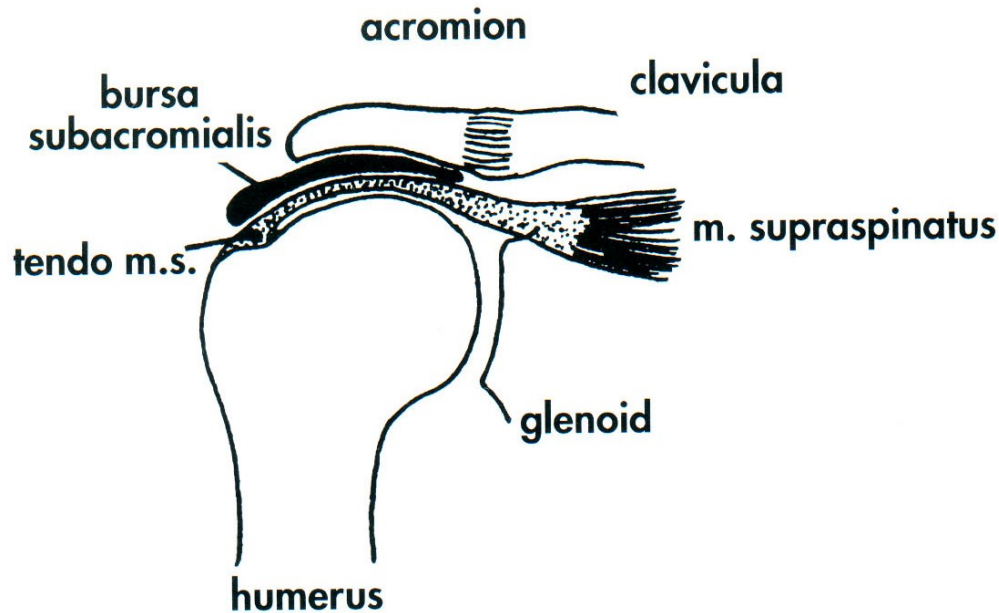
# Impingement syndrom

Greater tuberosity impinges  
to distal surface  
of acromion and  
coracoacromial ligament

Narrowing of subacromial  
space

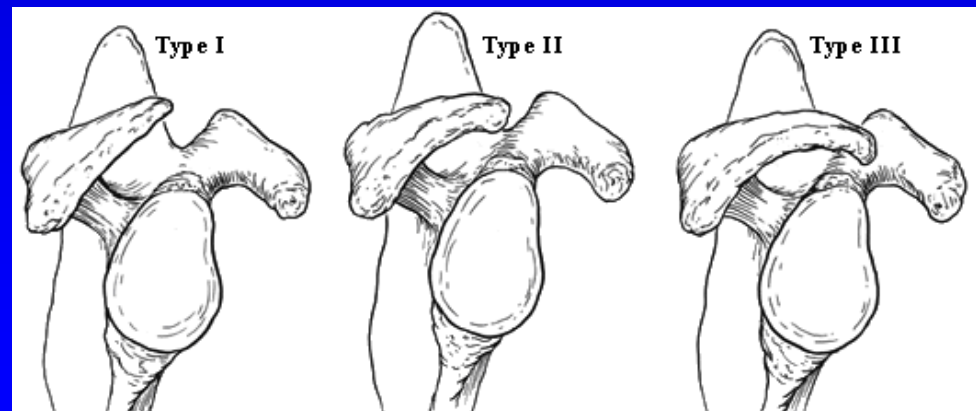


# Impingement syndrom



## Causes

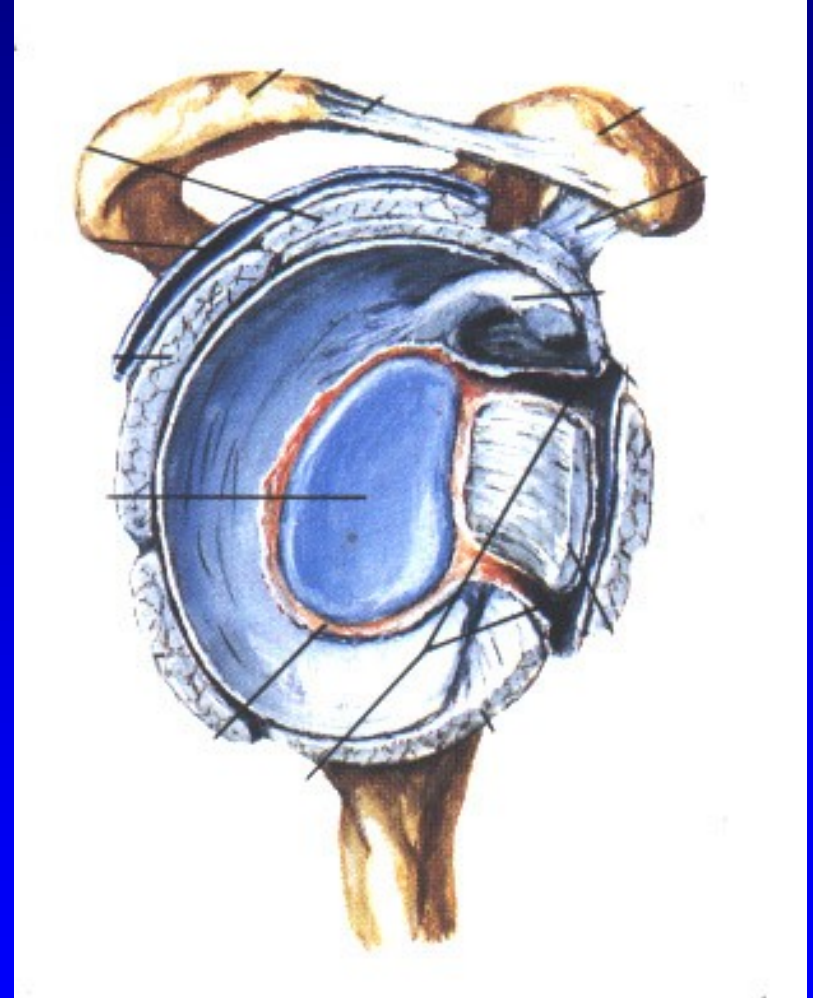
- acromion spur
- Change of acromion
- Distal osteophytes of AC
- Prominence of tuberculum maius



# Impingement syndrom

## Stages:

1. Swelling, hemorrhage of supraspinatus
2. Fibrosis, tendinitis, bursitis  
degenerative changes of cuff
3. Rupture of rotator cuff  
and long biceps tendon



# Impingement syndrom

Symptoms:

Painful arc

Impingement sign

Impingement test

Jobe test

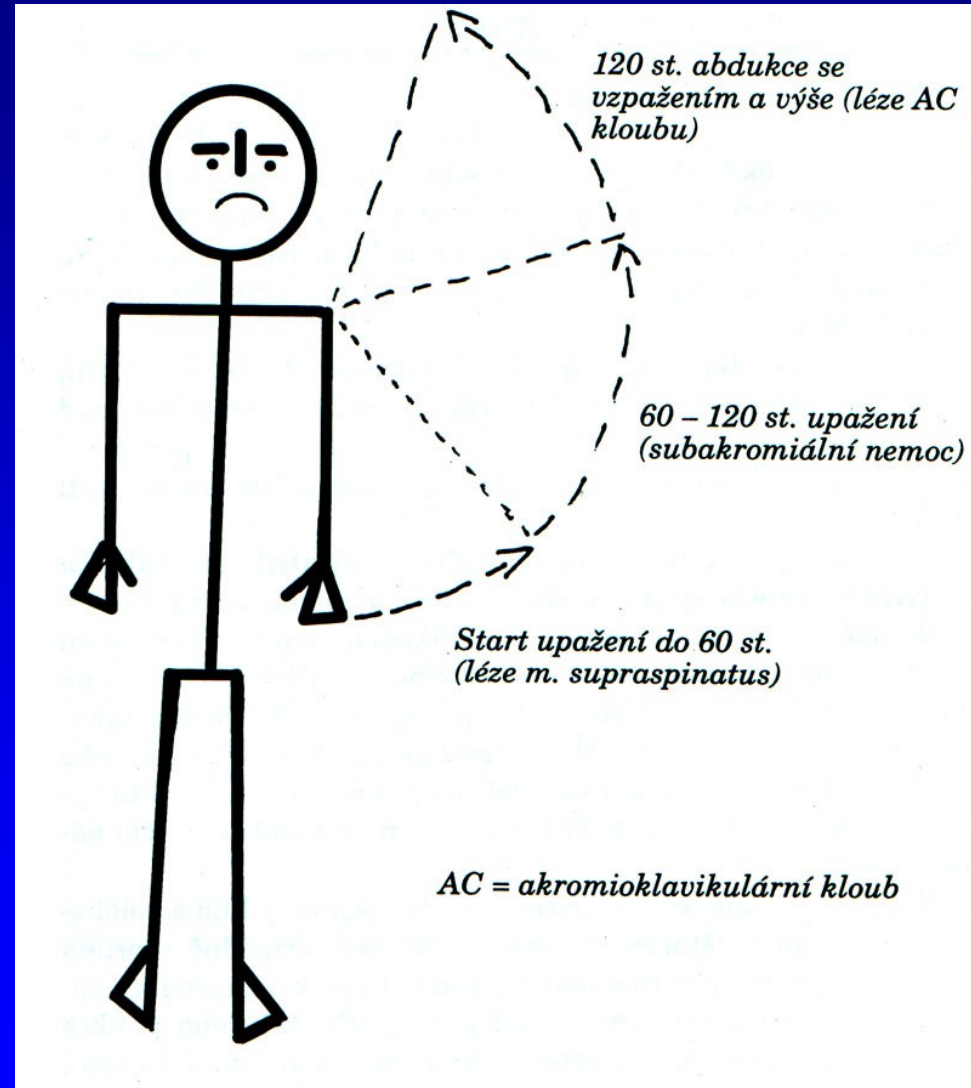
X-ray:

Narrowed subacromial space

Y view- outlet view

Arthrography

Ultrasonography



# Impingement syndrom

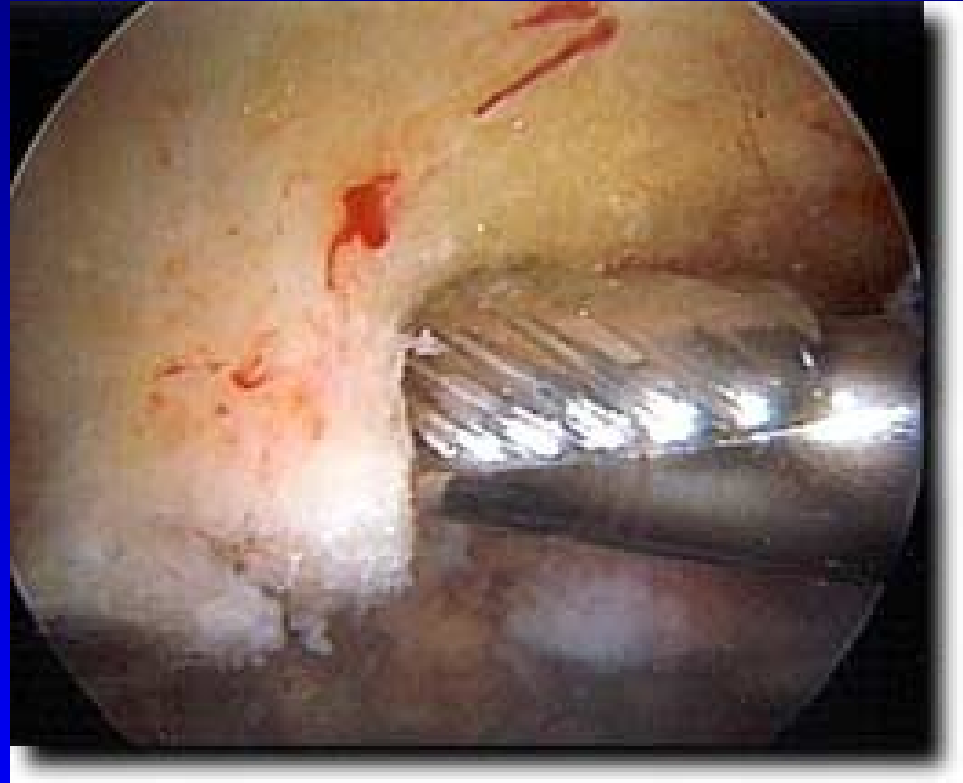
Therapy:

1. stage: conservative

Rest, NSAID,  
Physiotherapy,  
Local corticosteroids

2. stage: the same  
+ bursectomy, ASAD

3. stage: ASAD  
Subacromial decompression





# Frozen shoulder- capsulitis adhesiva

Progressive limitation  
of movements

Pain

No motivation for movement

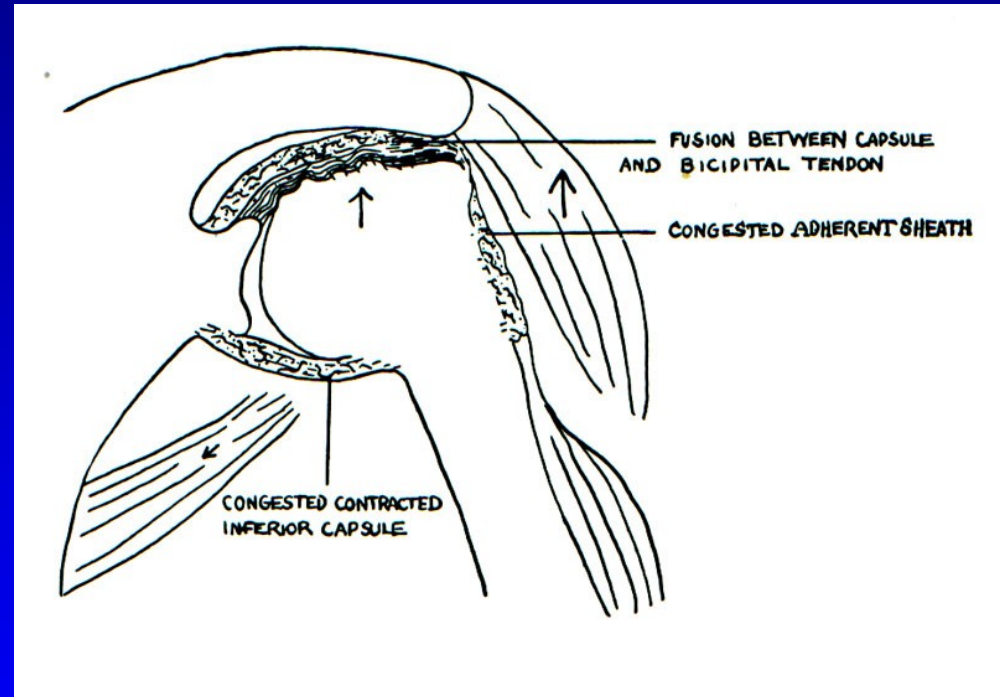
Shrinkage of capsule

Adhesions in distal recessus

Tightening of soft tissue

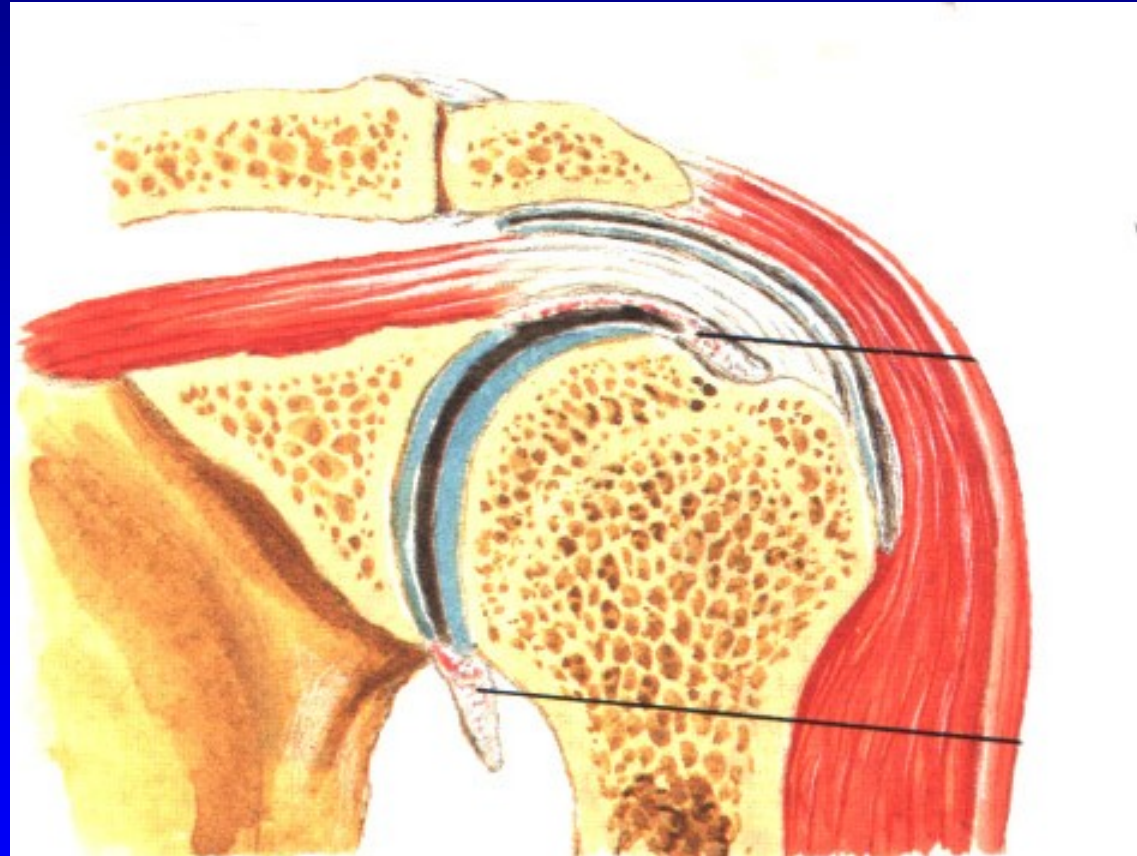
Muscle spasm

Low capacity of joint space



# The cause

All conditions limiting  
joint movements:  
Impingement syndrom  
Arthrosis of AC joint  
Posttraumatic conditions  
Inflammations  
Thoracic outlet syndrom  
Tumors of the lungs  
Disorders of pleura  
Cardiac disorders



# Frozen shoulder

Management:

Long lasting period

Heat

Passive movements

Positioning

Active movements

Physiotherapy

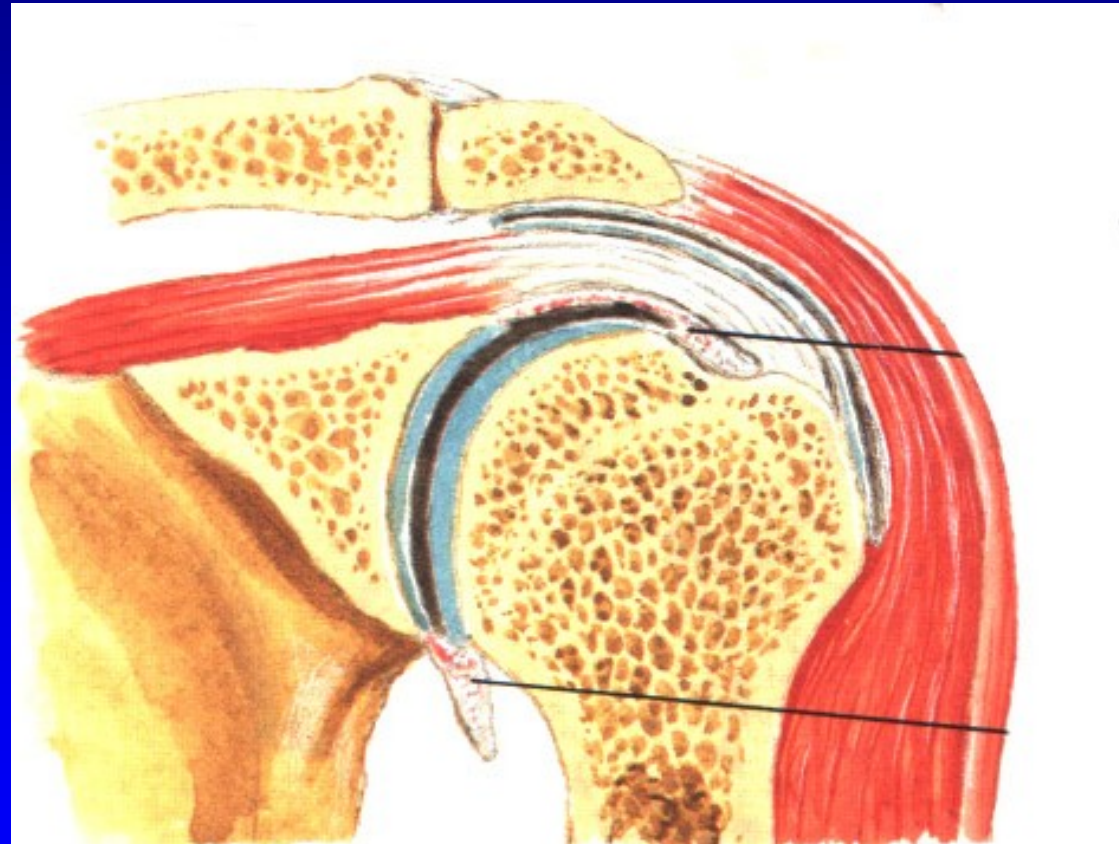
NSAID

Local corticosteroids

ASC- decompression

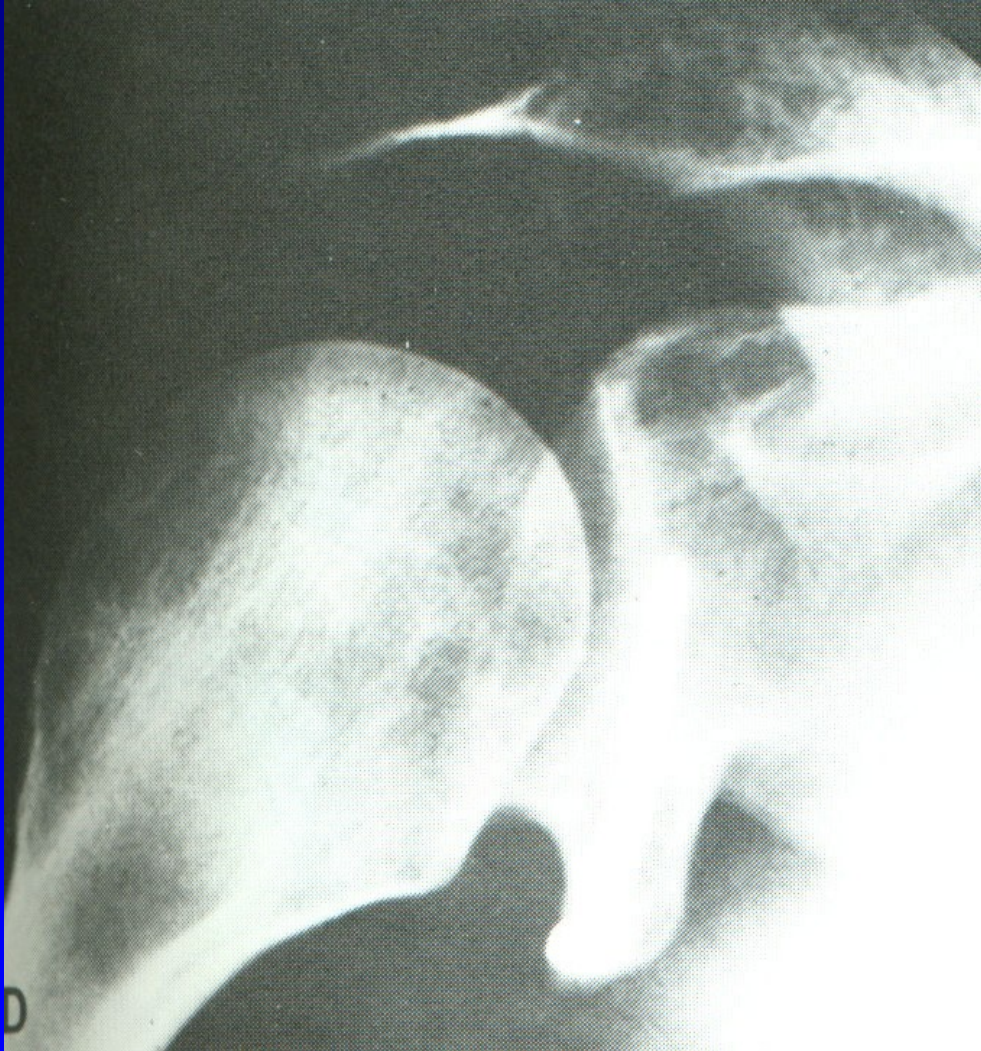Redressement force

Removal of adhesions





# Glenohumeral osteoarthritis - omarthrosis



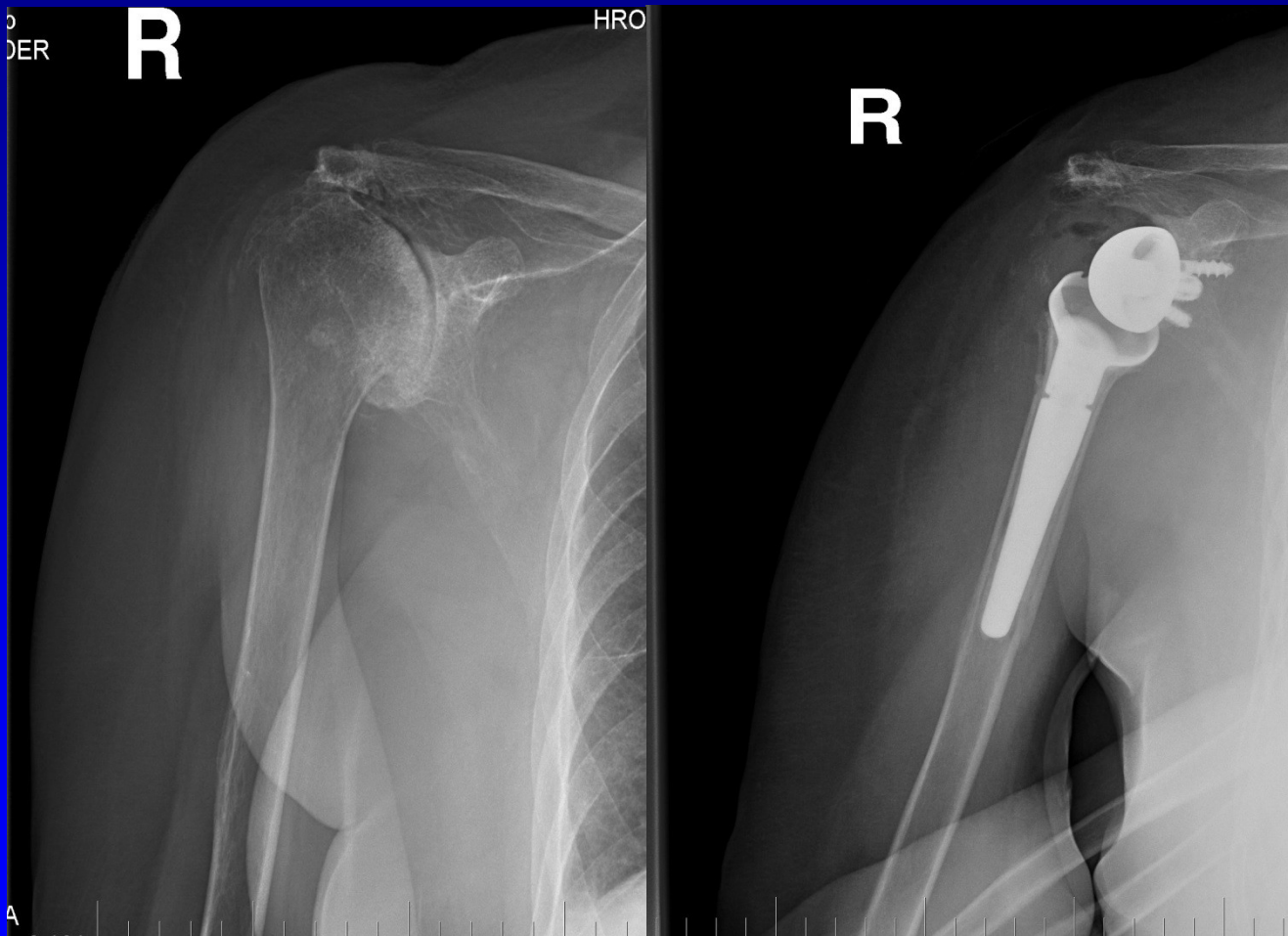
Therapy:

Conservative

Total shoulder replacement



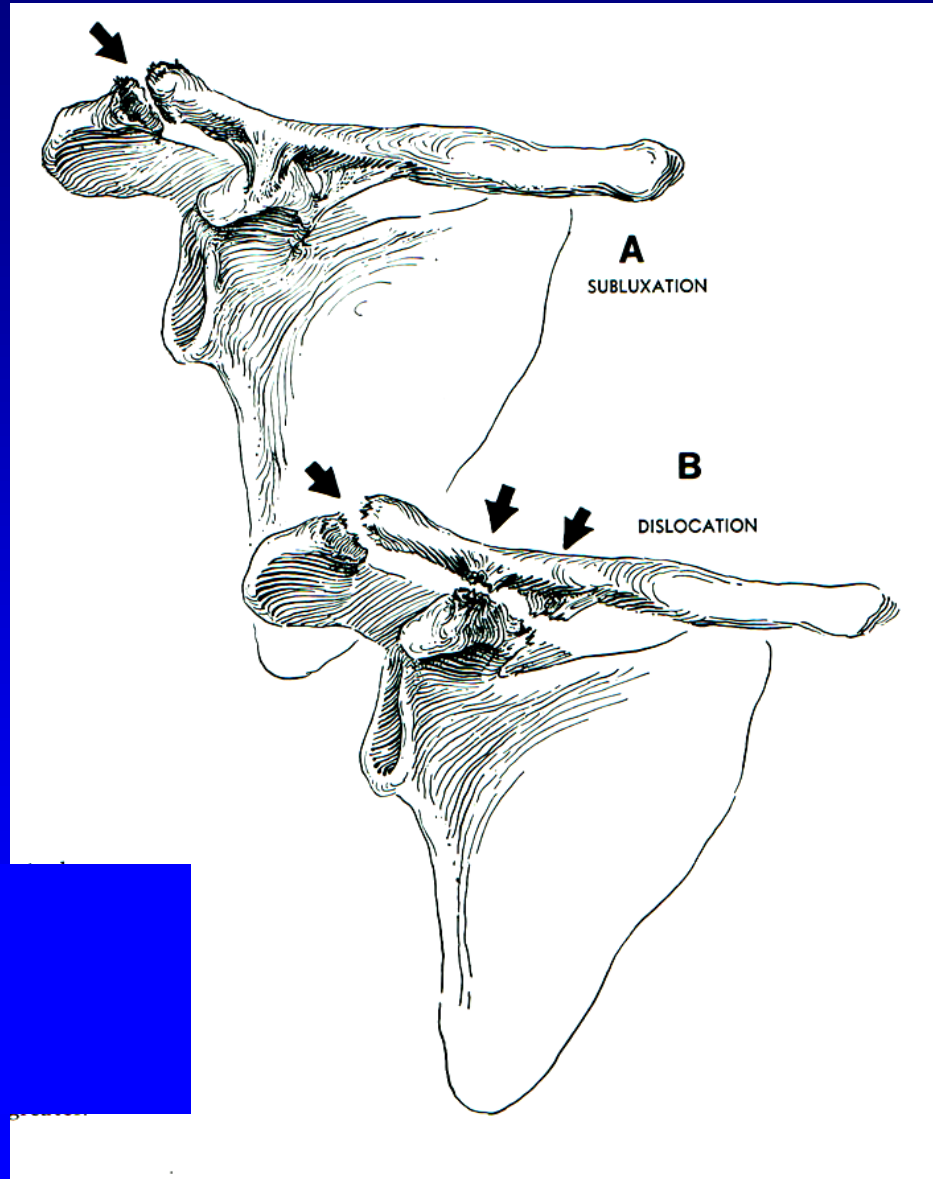
# Rotator arthropathy



Reverse total shoulder arthroplasty

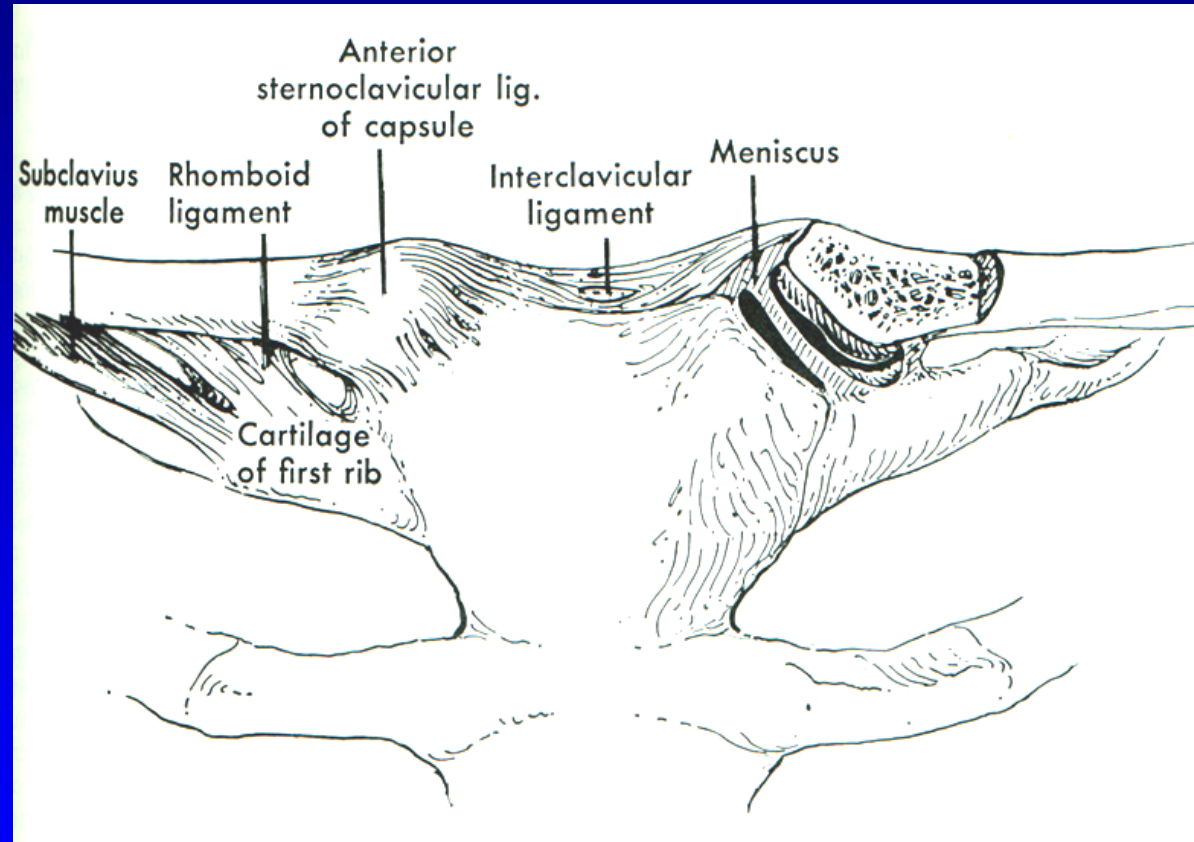
# Disorders of acromioclavicular joint

Synovitis  
O.A.  
Sprain  
Subluxation  
Dislocations



# Disorders of sternoclavicular joint

Synovitis  
O.A.  
Sprain  
Subluxation  
Dislocations  
Chronic subluxation



# Referred pain to the shoulder

Cervical spine

Thoracic outlet syndrom

Cardiac diseases

Lung and pleura disorders

Herpes zoster neuralgia