

Amputation

Z. Rozkydal

Amputation

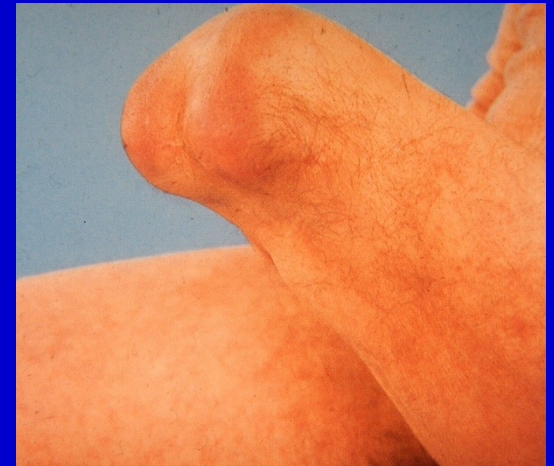Removal of periphery part of the limb at a level of the bone



Obr. 1. Amputation in the calf

Disarticulation

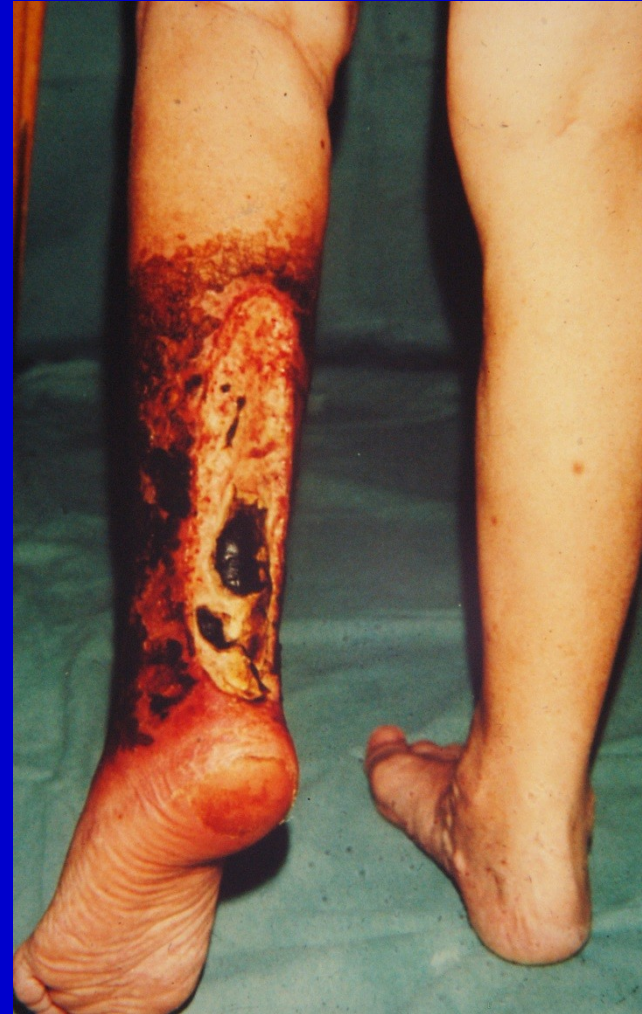Removal of periphery part of the limb at a level of the joint



Obr. 2. Disarticulation in the knee joint

Indications

- Severe ischemia
- Severe trauma
- Infection with sepsis
- Malignant tumors
- Congenital diseases
- Neuropathies leading to deep trophic ulcers



Obr. 3. deep necrosis in the calf

Preop. assessment

Individual access

Angiography

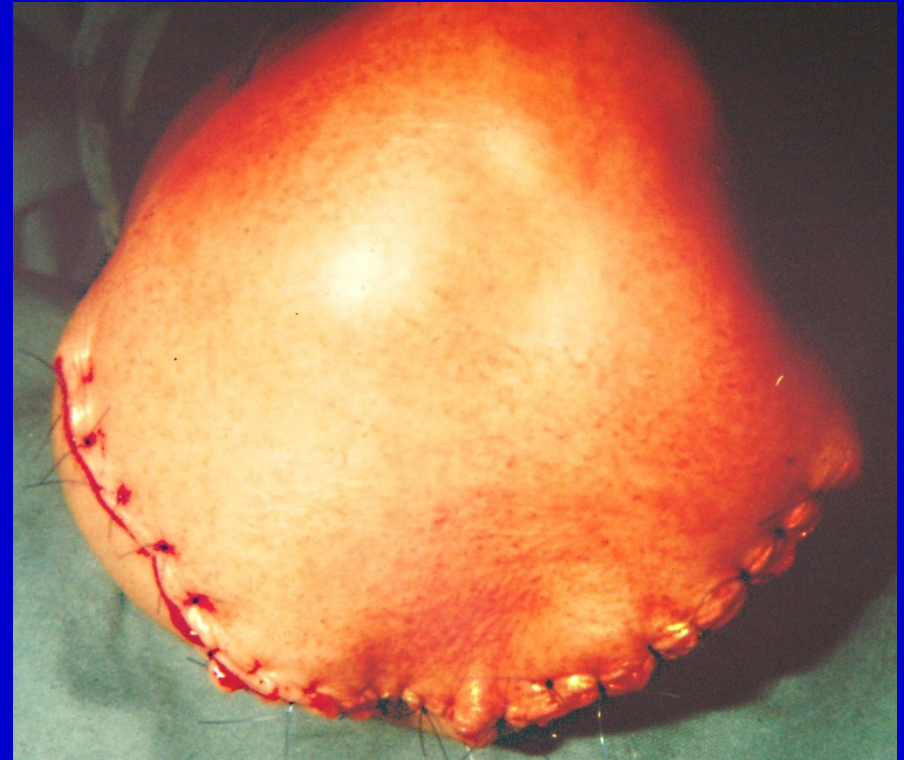General condition

Occupation

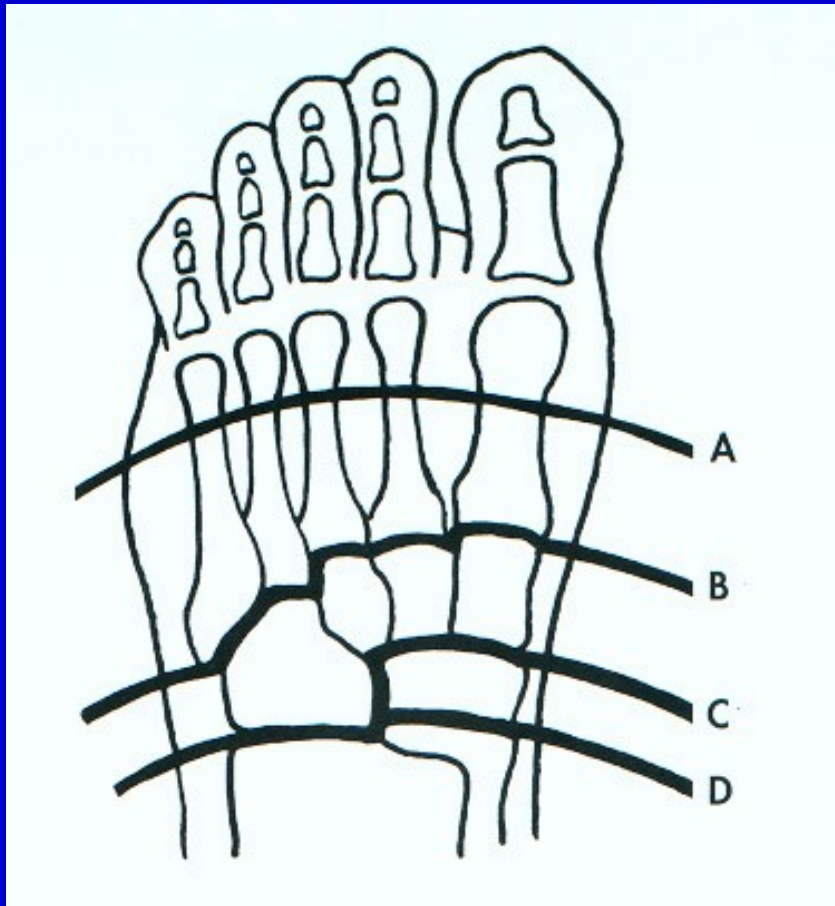
Level of amputation- consultation

Technique

- Turniquet
- Safe surgical approach
- Carefull ligating of vessels
- Myoplastic surgery
 - suture of muscles end to end
- Dreinage of the wound
- Enough soft tissues
- Good skin coverage



Amputation in the foot



Phalanx

Toes

A- Metatarsals- Sharp

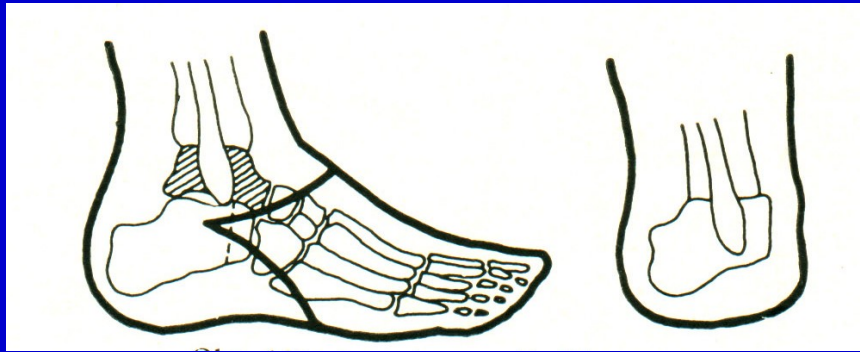
B- Lisfranc

C- Bon-Jäger

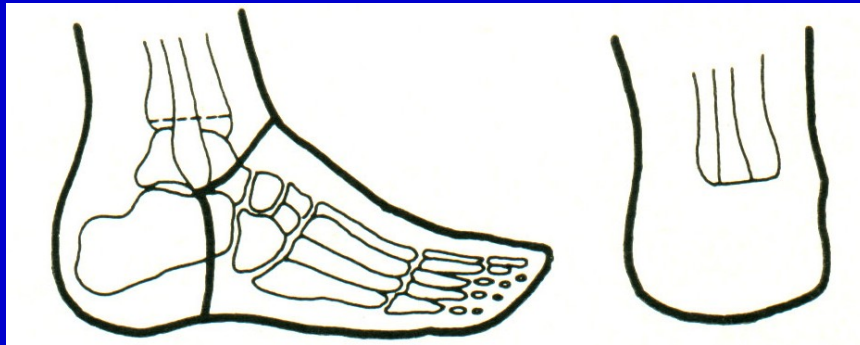D- Chopart

Level of amputation in the foot

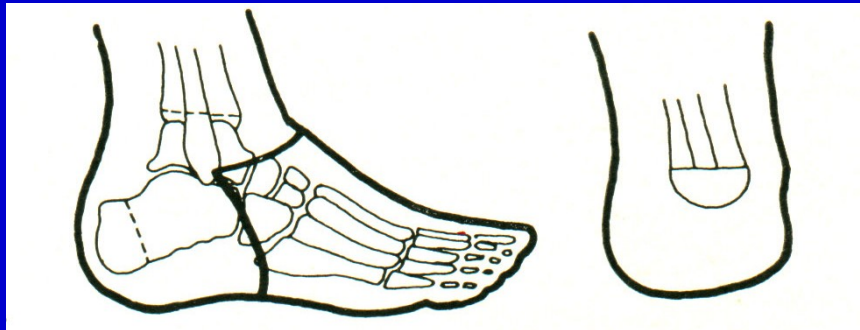Amputation in the foot and in the ankle



Pirogov

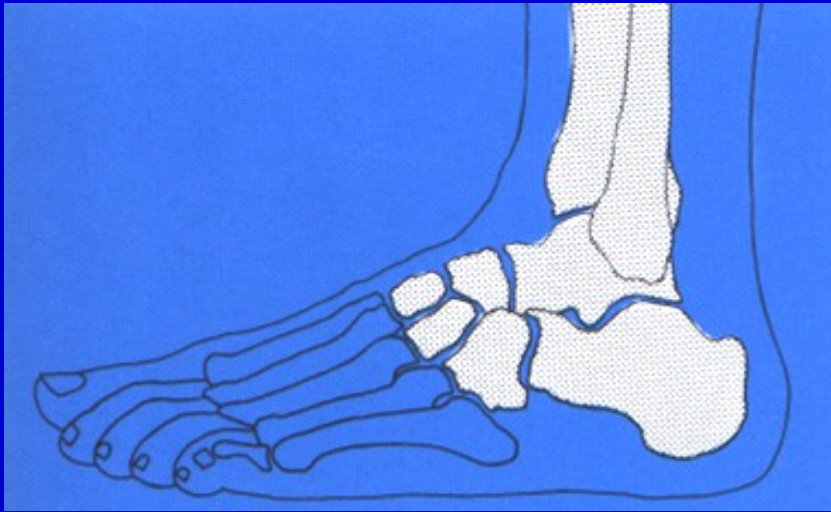


Syme

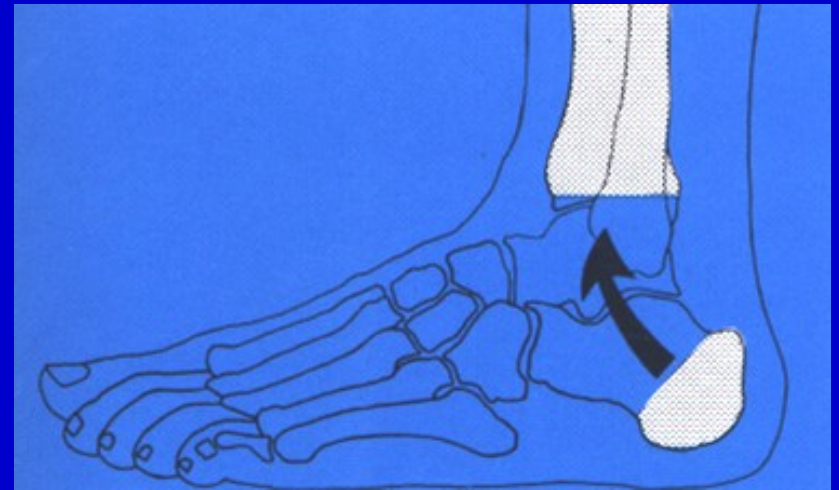


Boyd

Amputation in the foot and the ankle

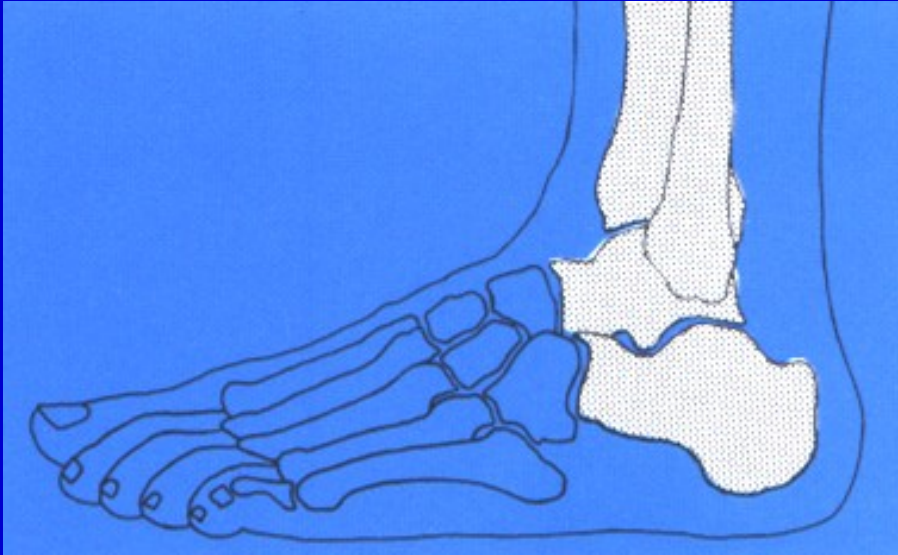


Amputation in Lisfranc joint

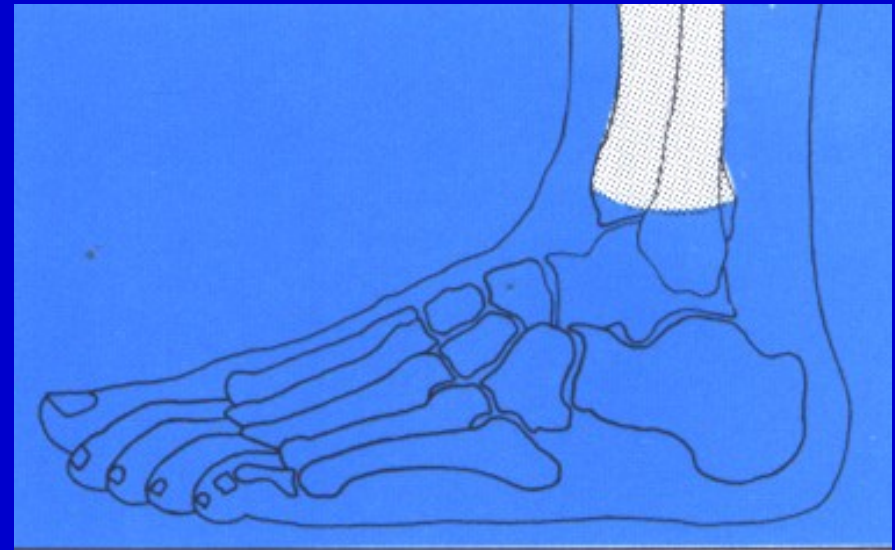


Pirogov amputation

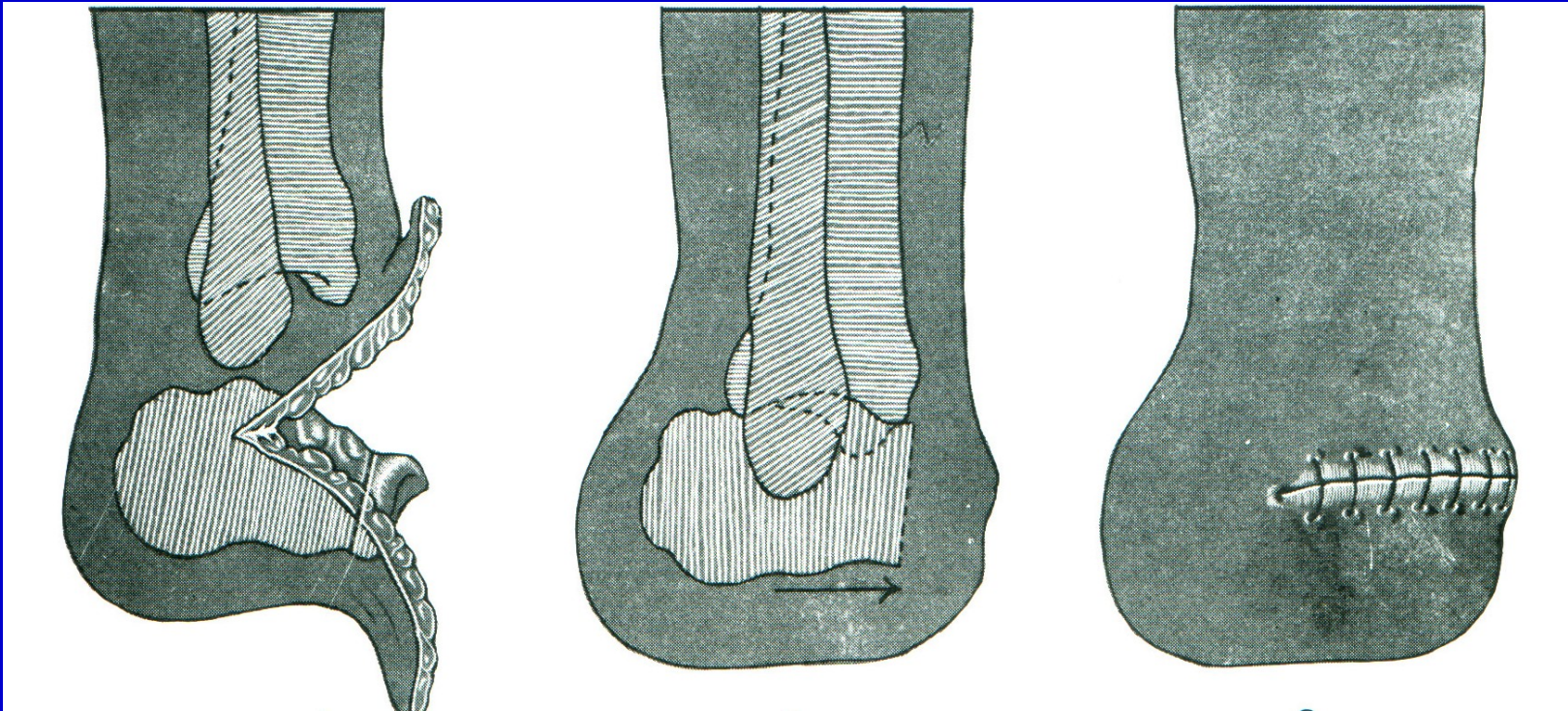
Amputation in the foot and the ankle



Amputation in Chopart joint



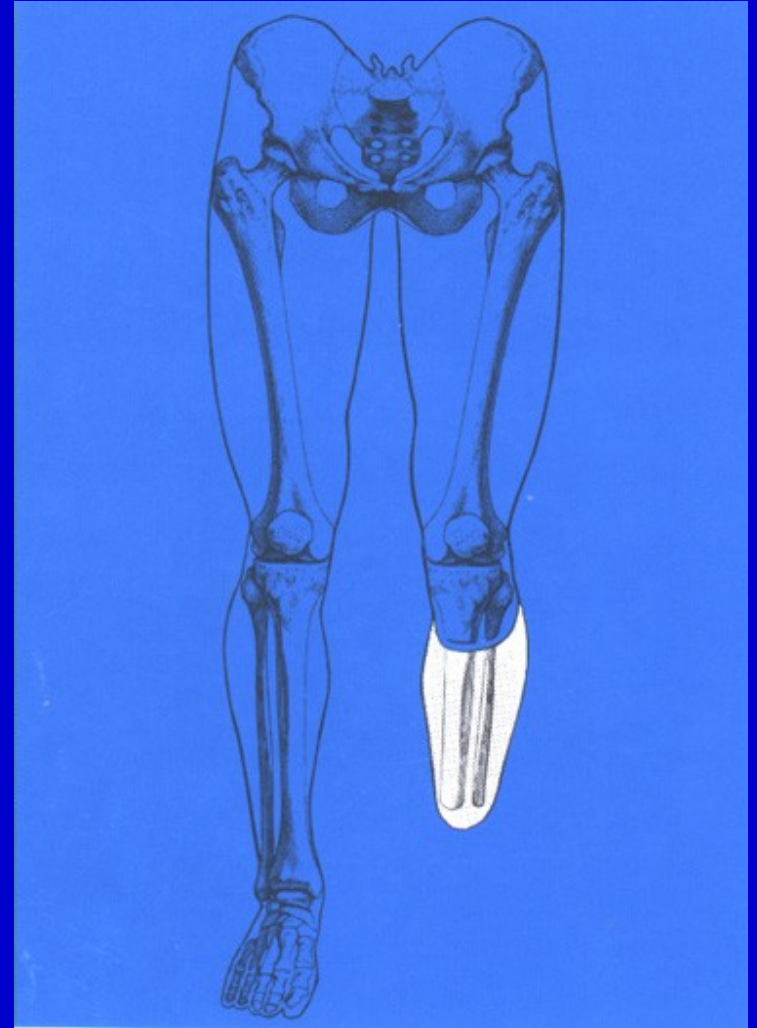
Syme amputation



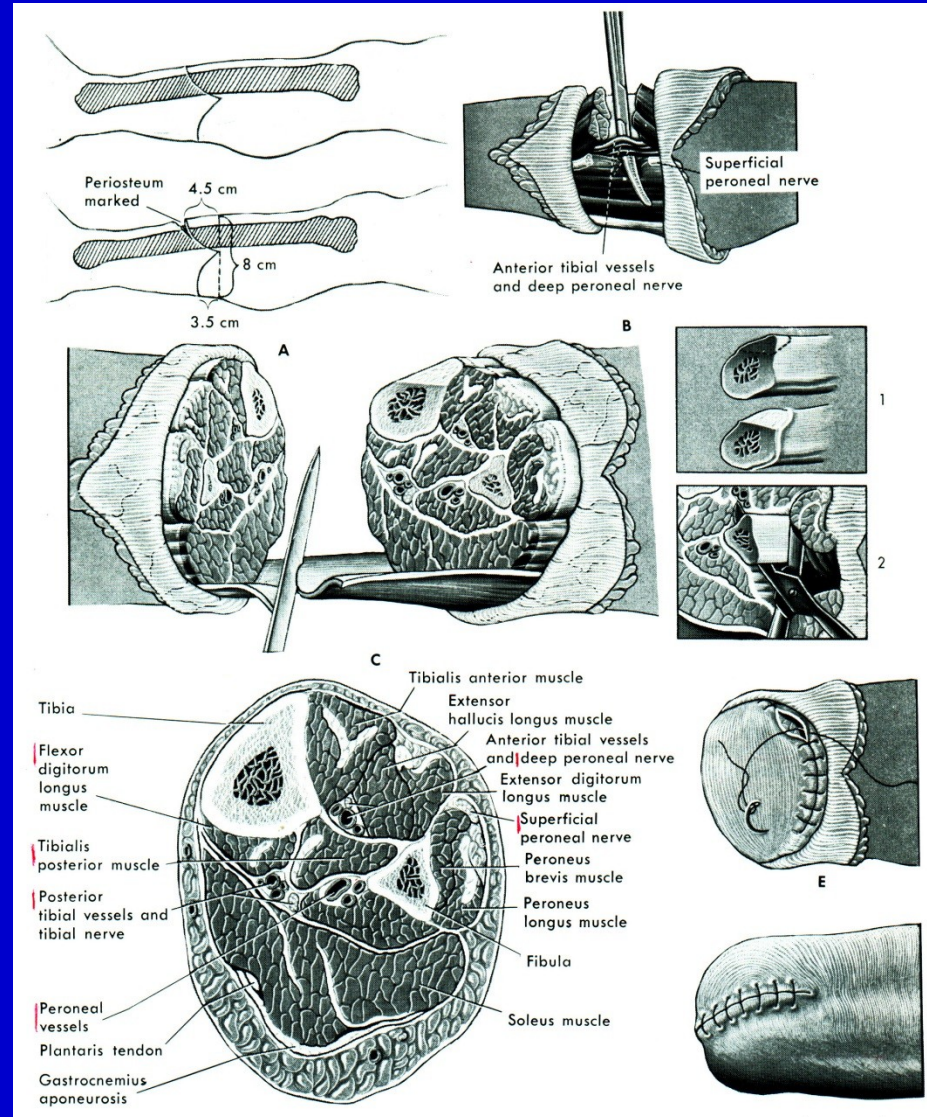
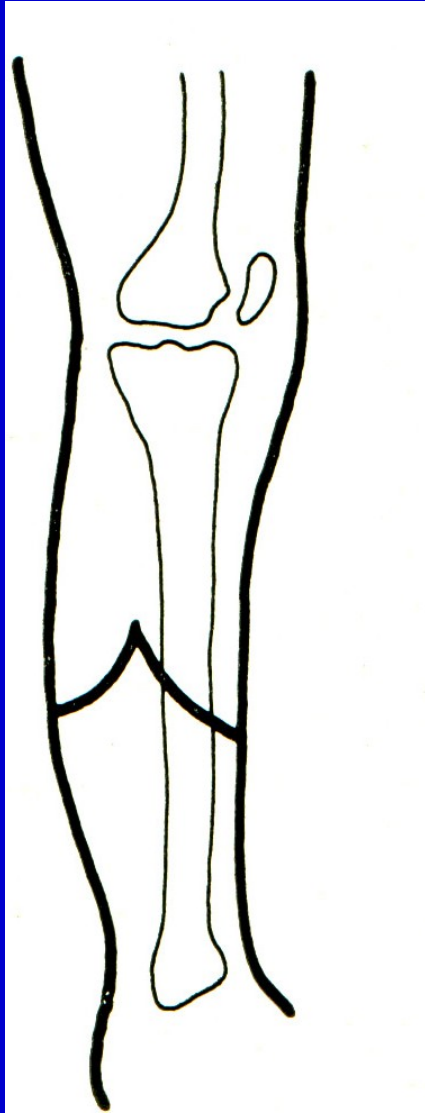
Boyd amputation

Bellow knee amputation

8-15 cm bellow knee joint line

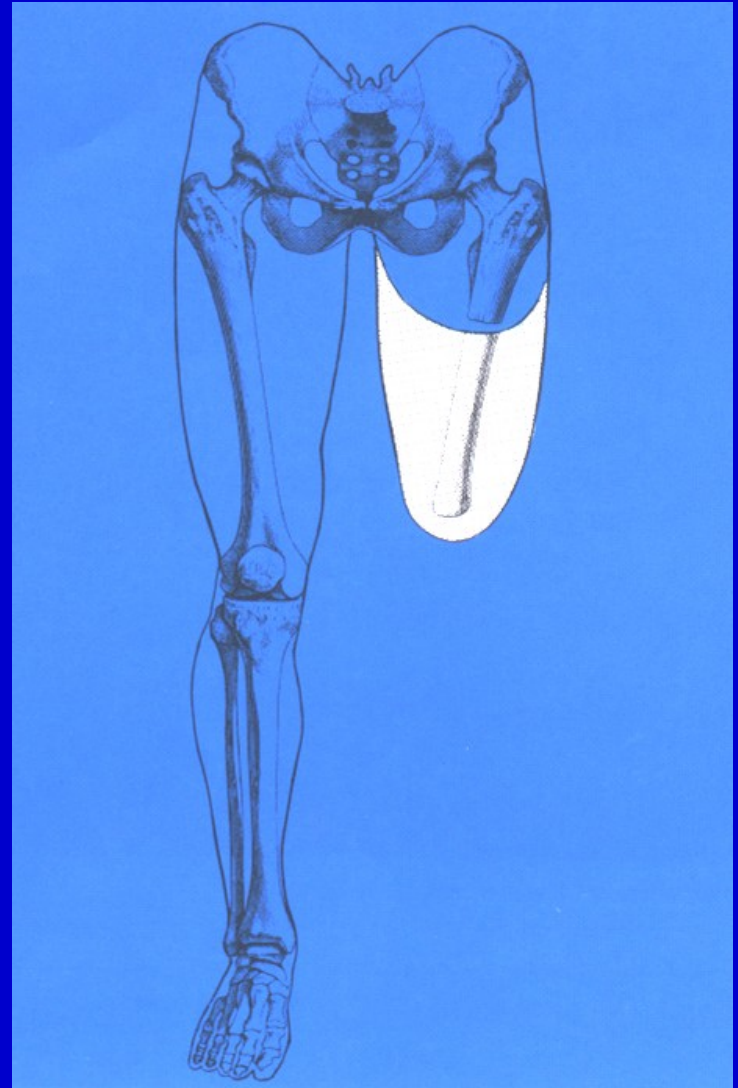


Bellow knee amputation

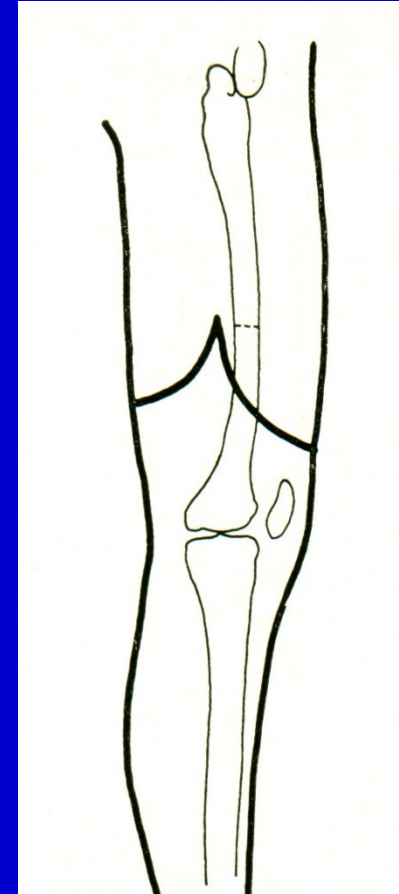
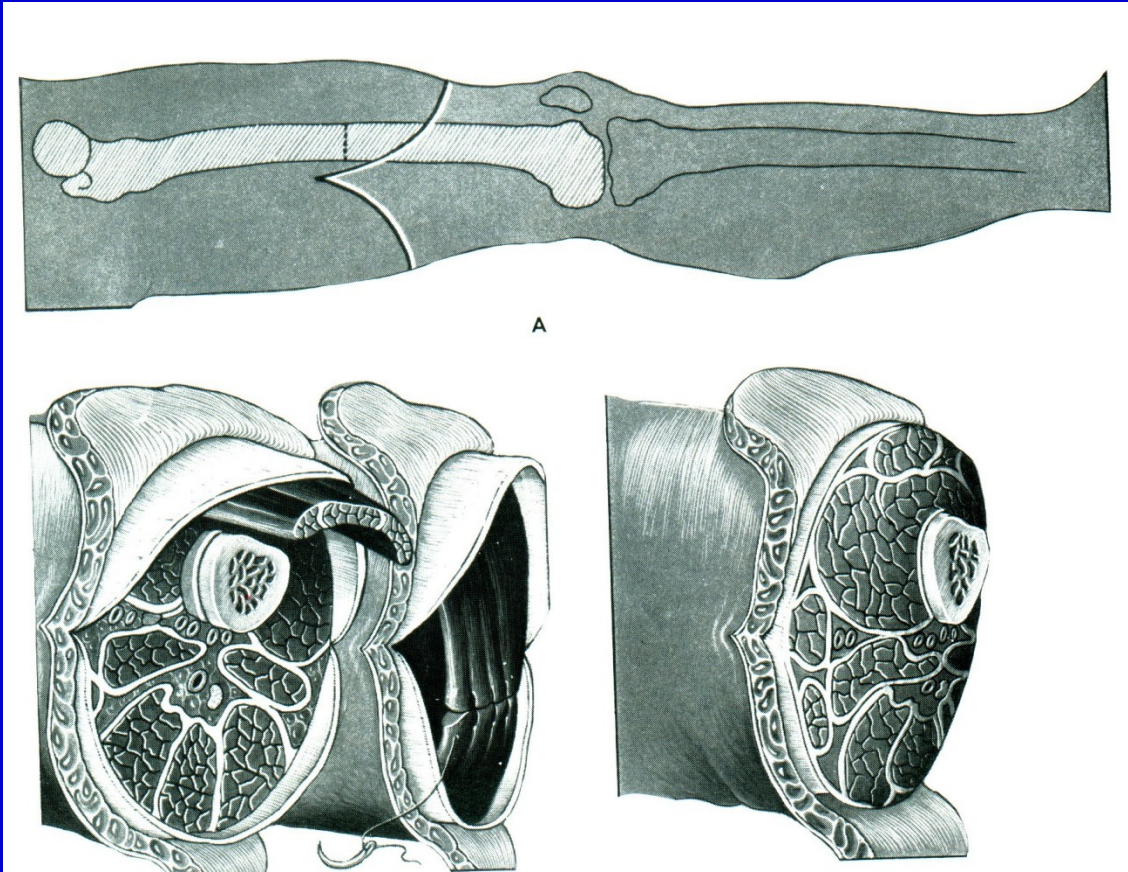


Above knee amputation

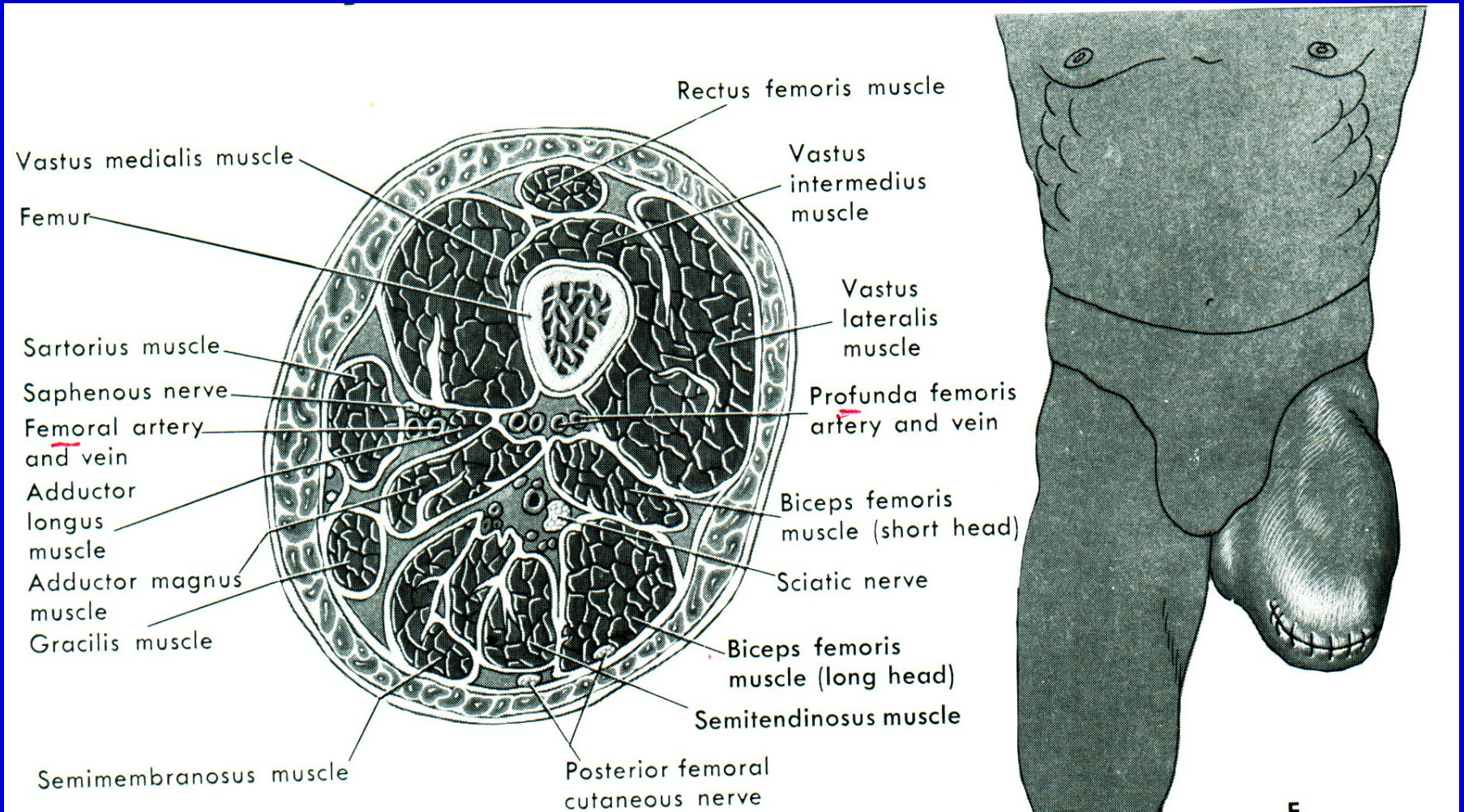
In the middle third of the thigh



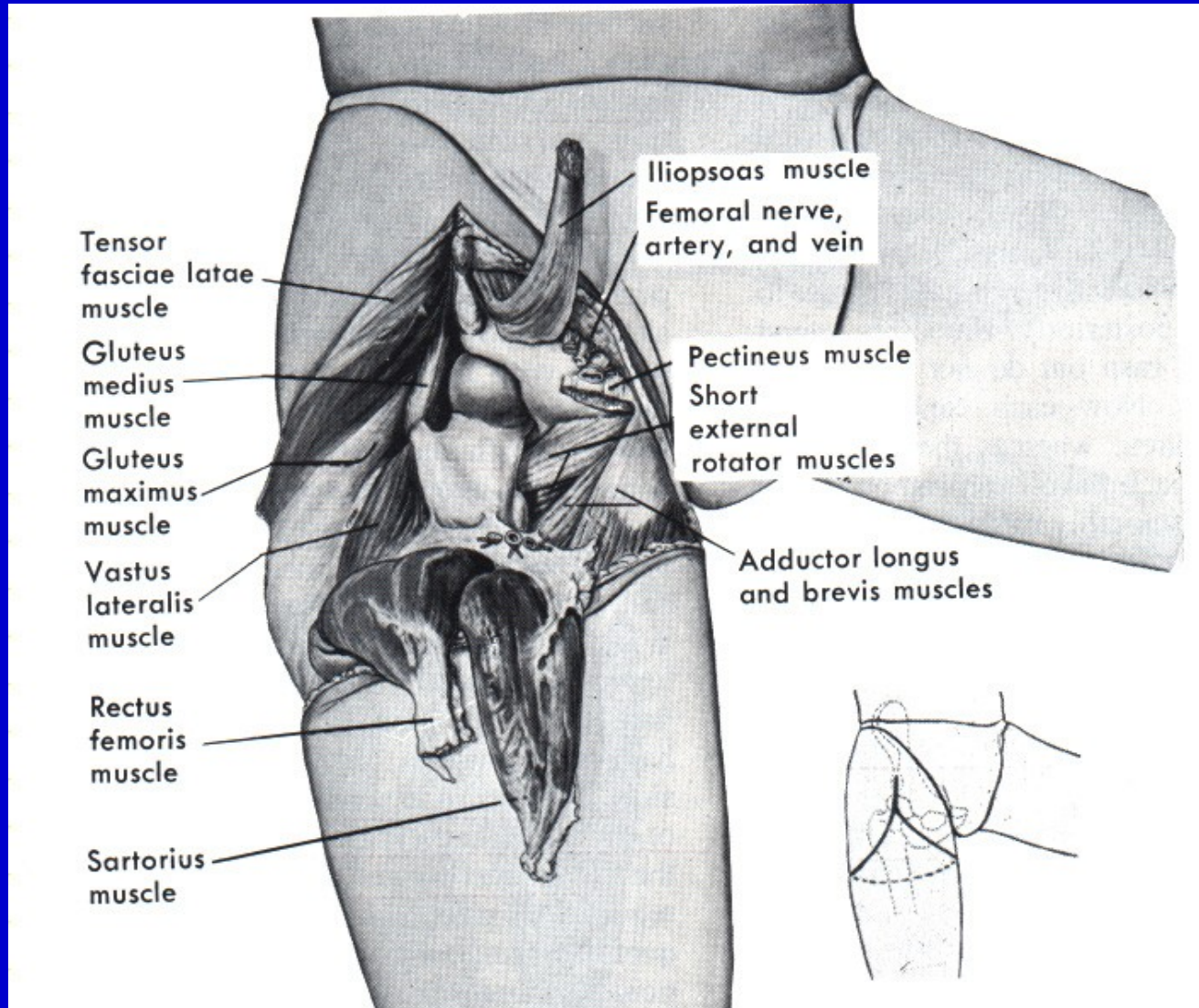
Above knee amputation



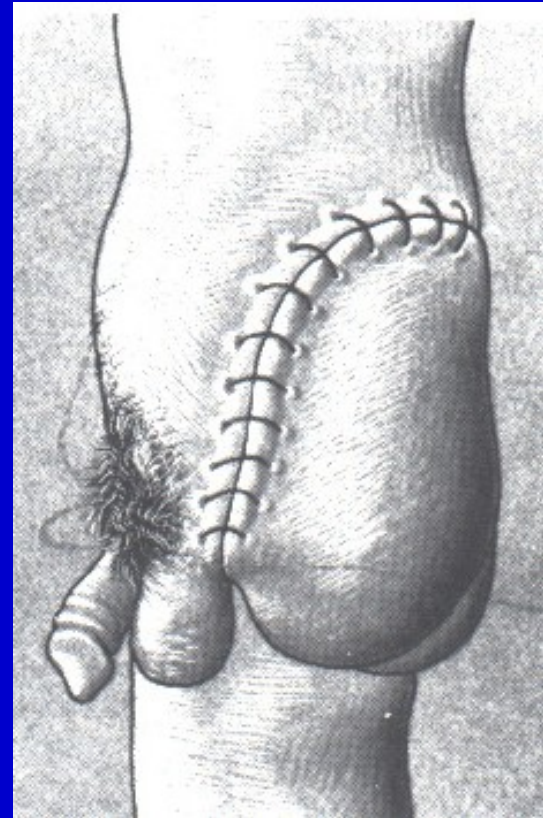
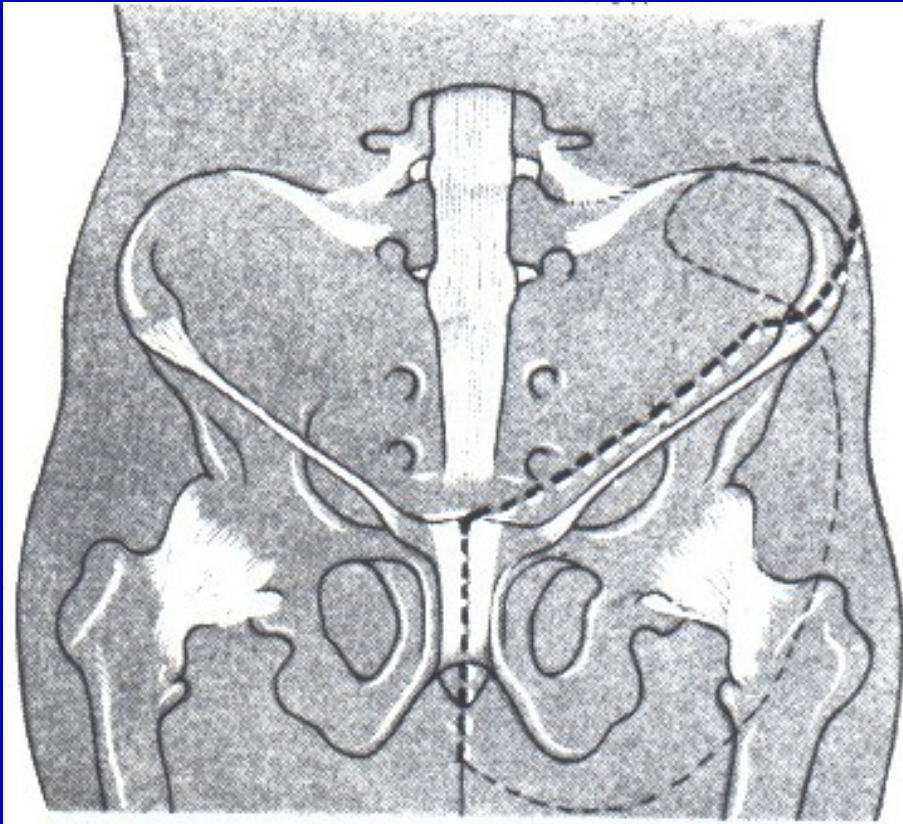
Above knee amputation



Disarticulation of the hip



Hindquarter amputation - hemipelvectomy

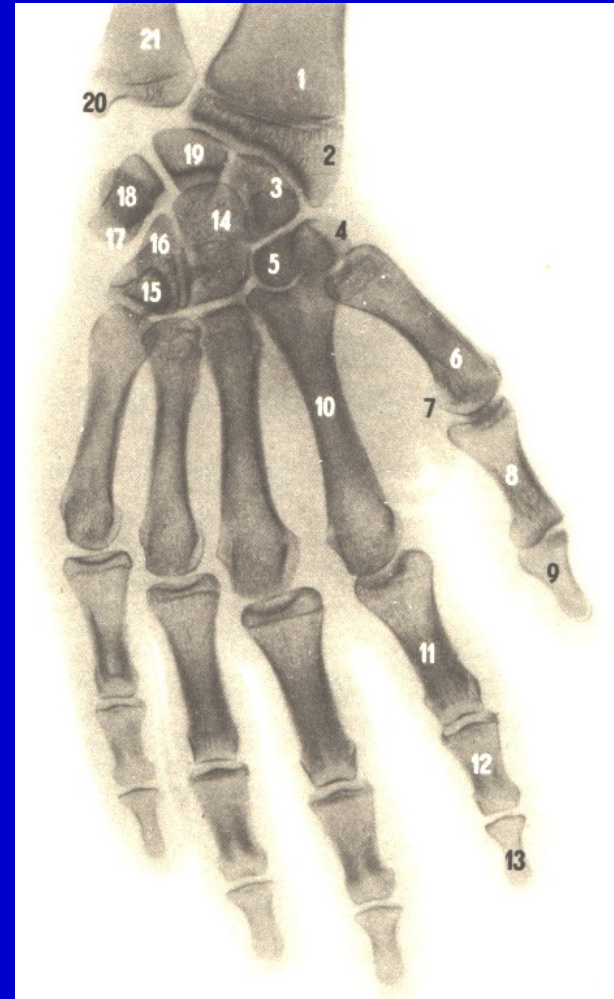


Amputation in the hand

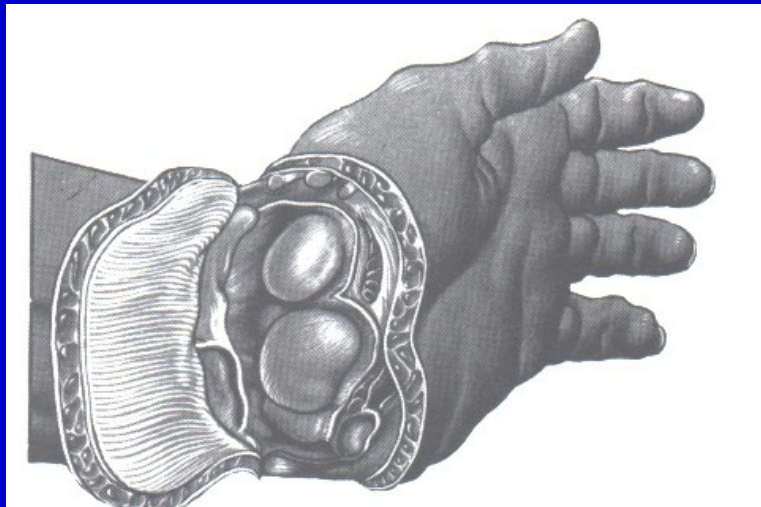
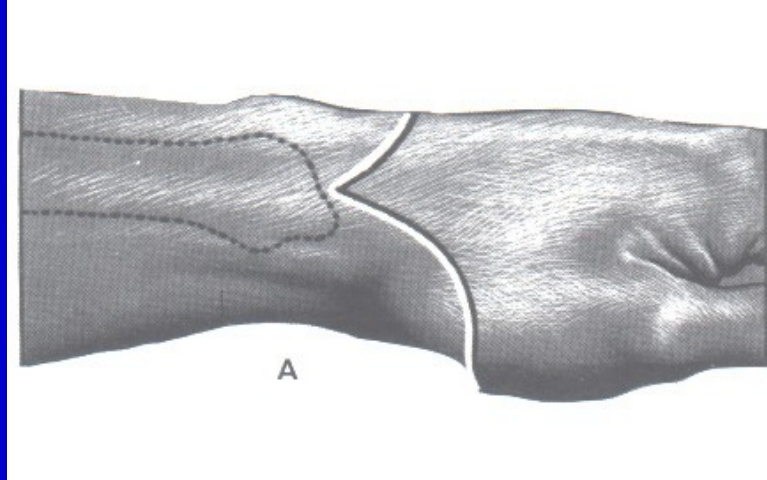
Phalanx

Fingers

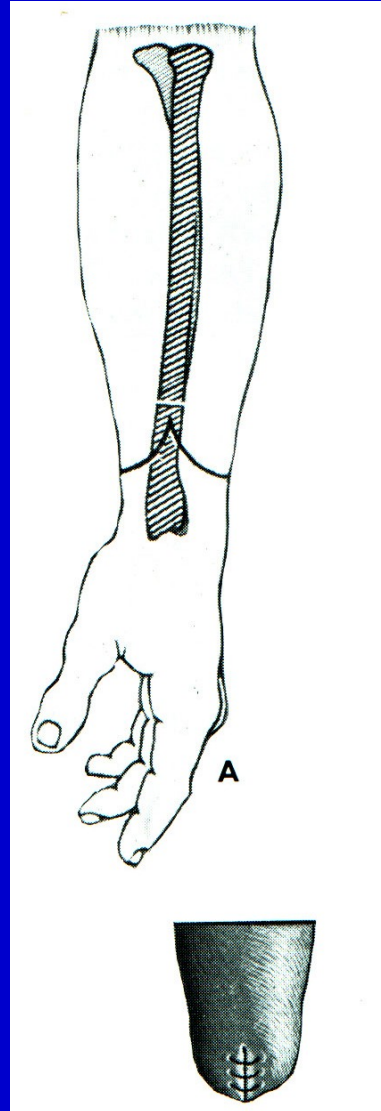
Metacarpals



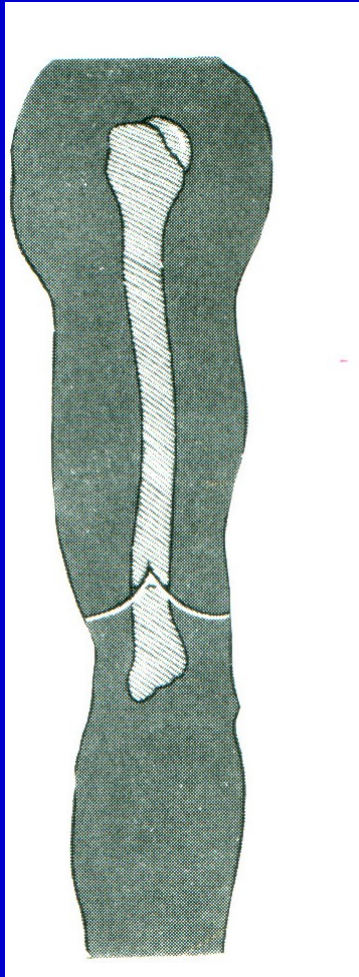
Disarticulation in wrist joint



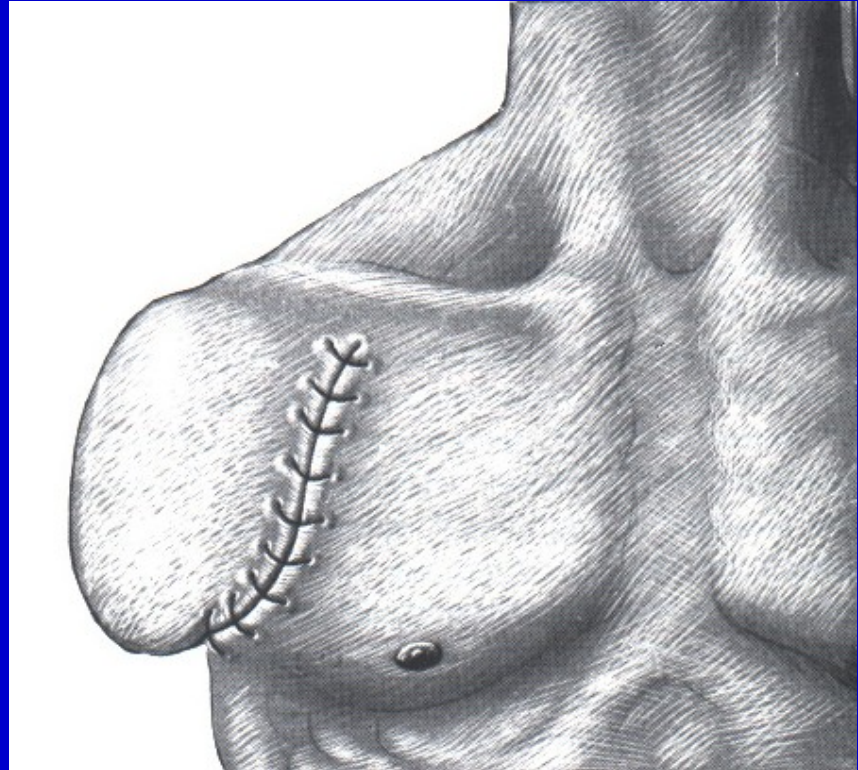
Amputation through forearm



Amputation through arm

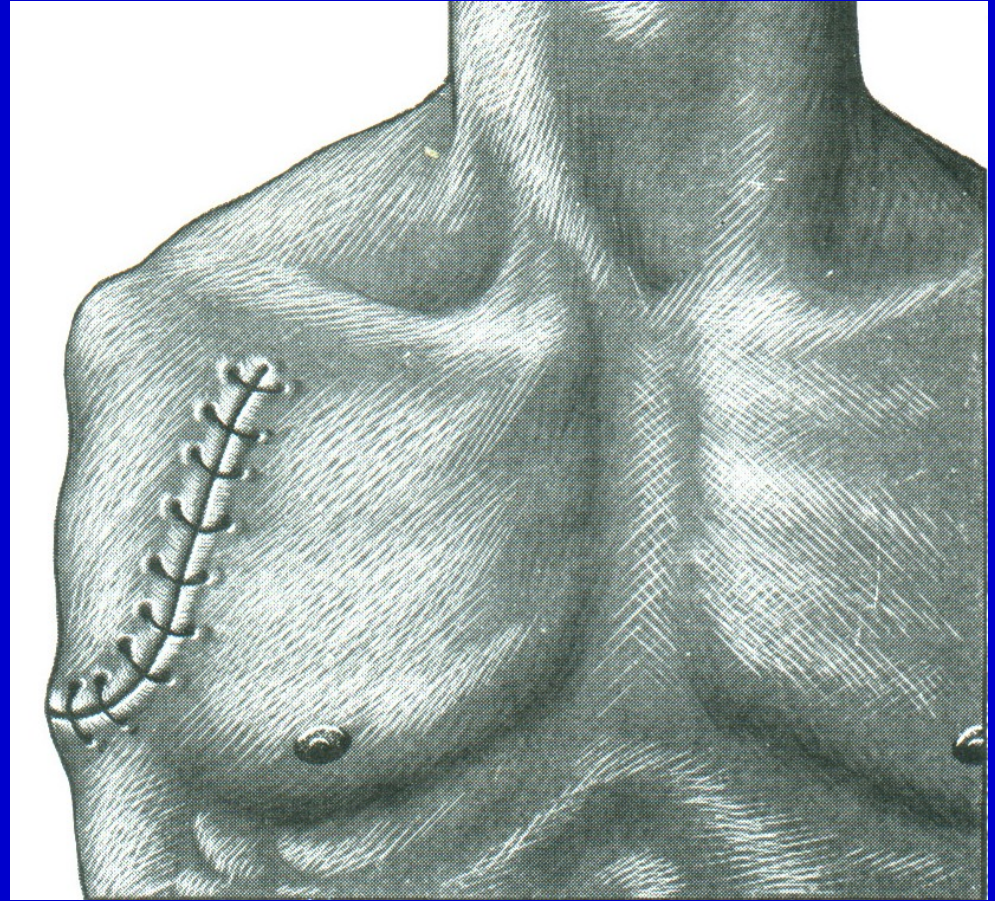
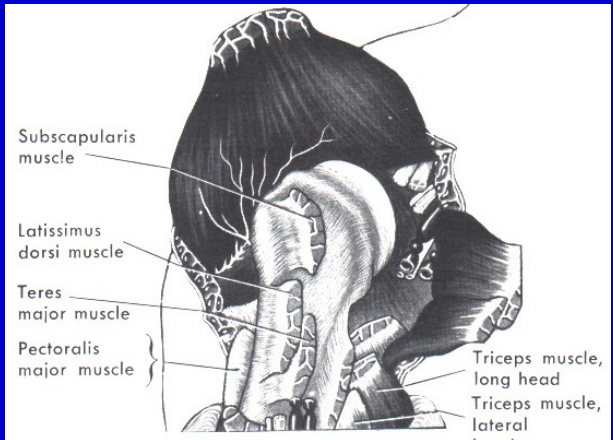
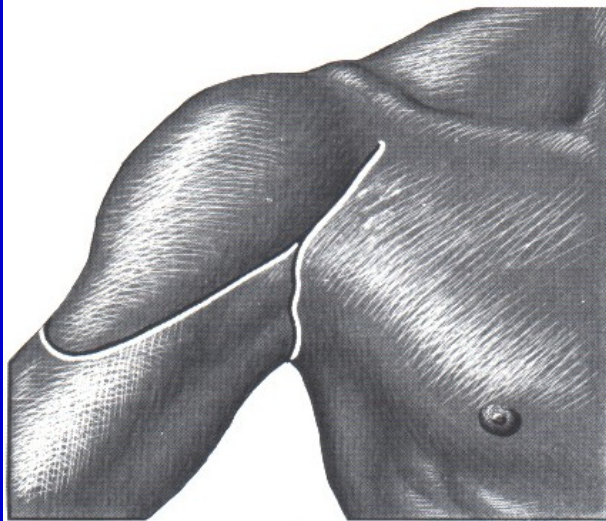


Above elbow amputation

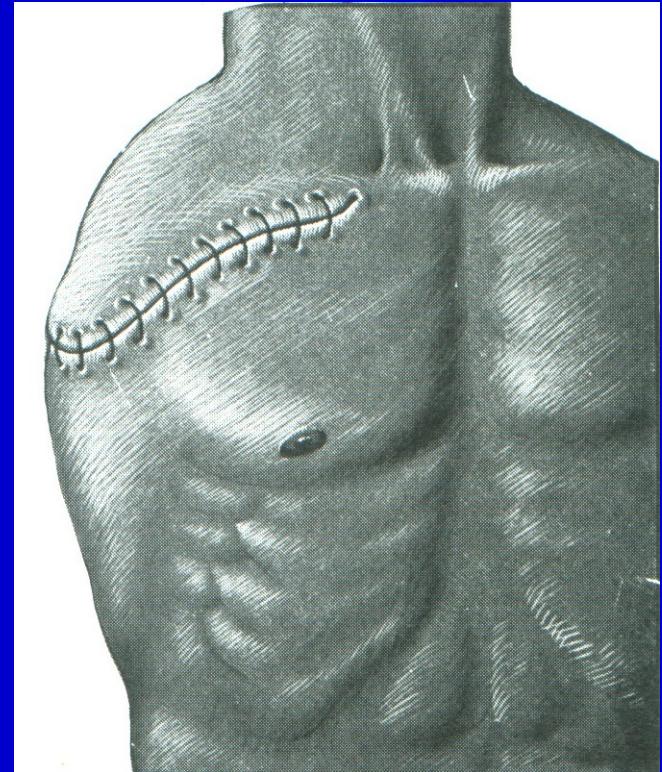
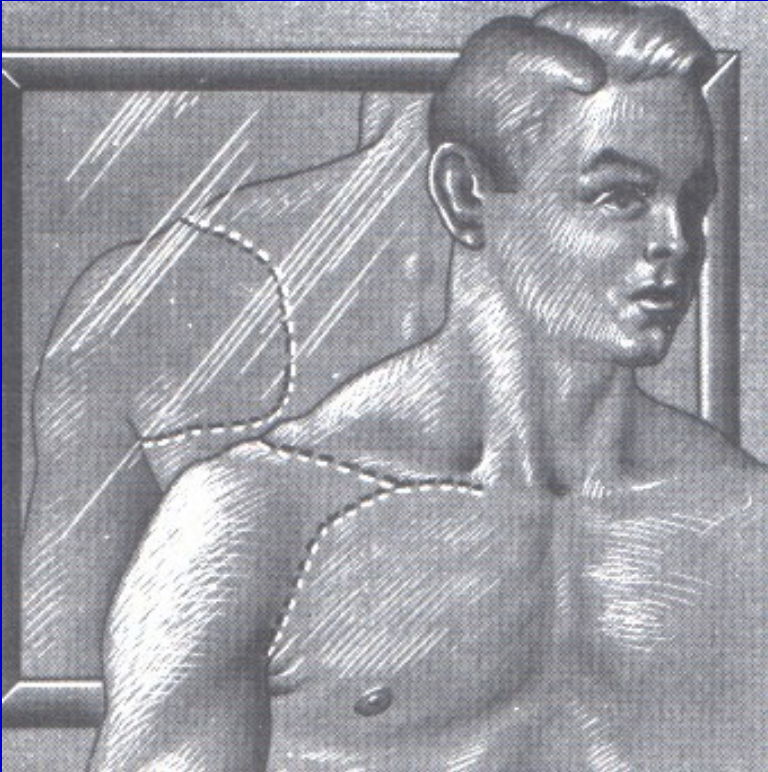


Amputation in surgical neck

Disarticulation in the shoulder

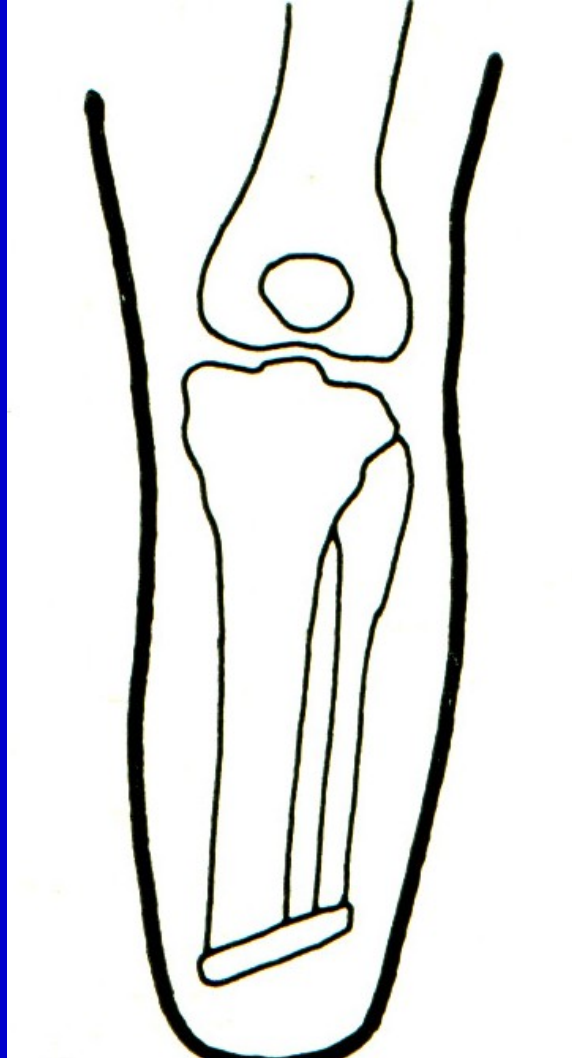


Forequarter amputation



Interthoracoscapular amputation

Osteoplastic amputation



Gilotine amputation

War surgery

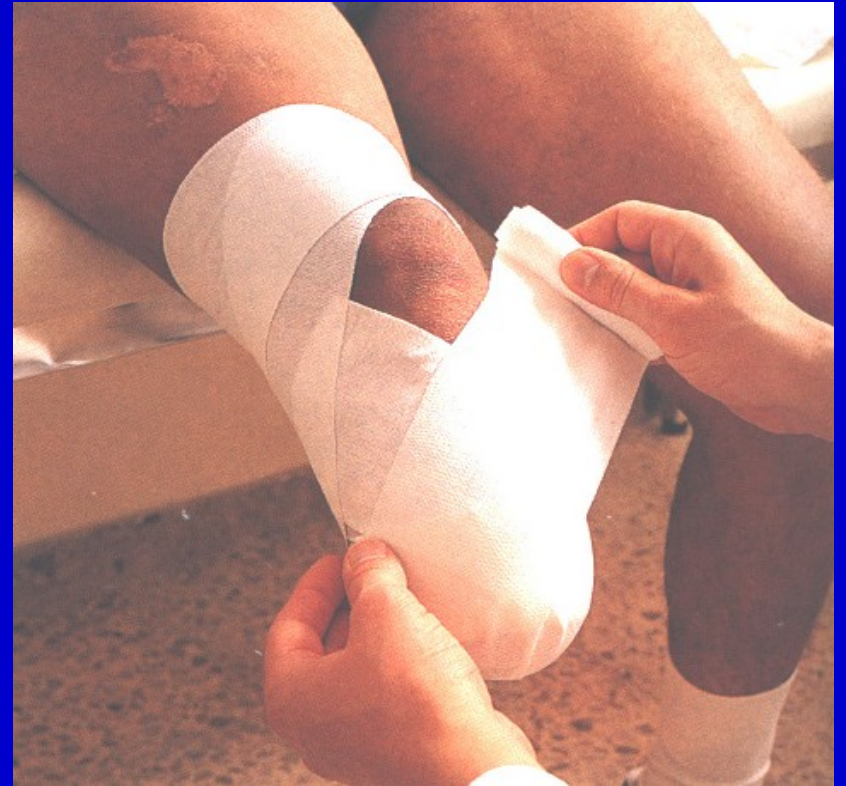One level cut of all structures

No suture of the wound

Requires reamputation

Post op. management

Elastic bandage to conical shape
Positioning
Prevention of flexion contracture
Proprioception
Exercise in bed
Verticalisation
Walking



The aim

Good quality stump

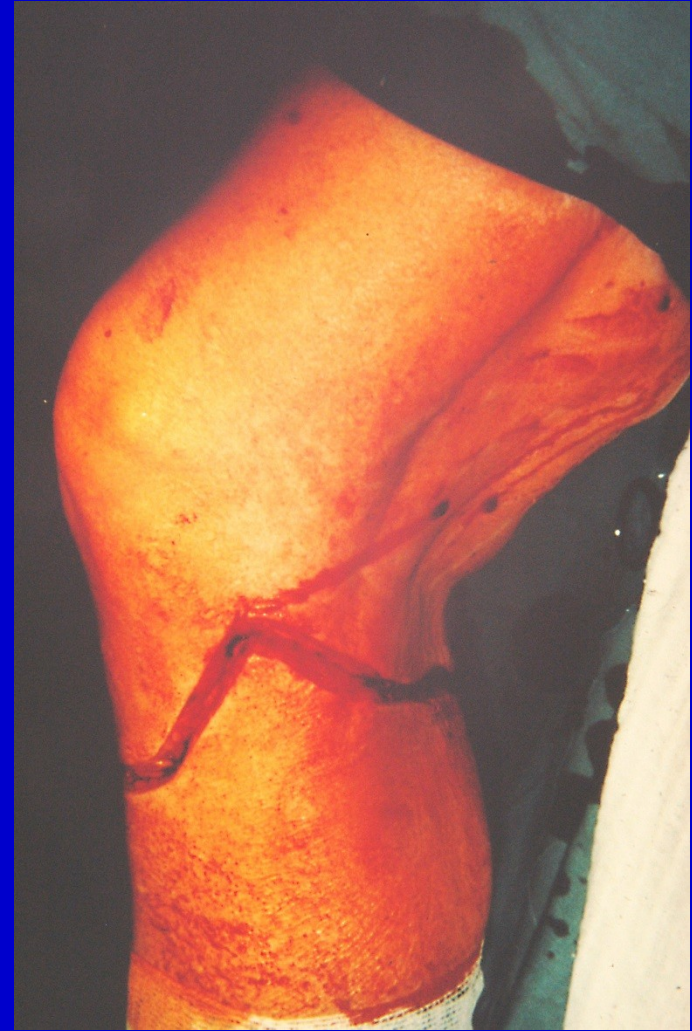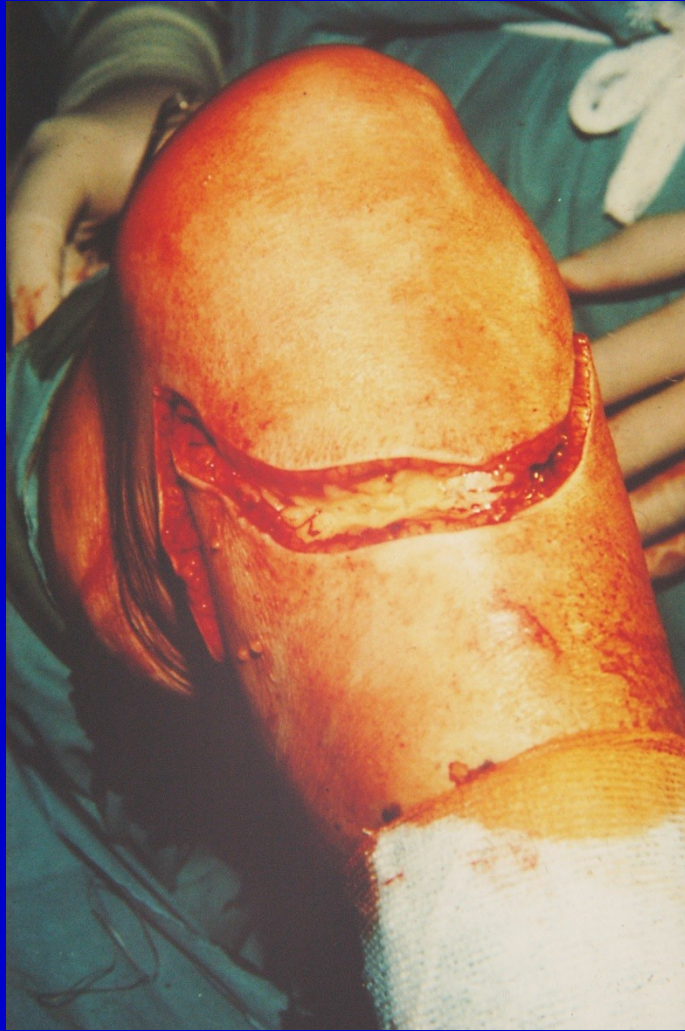Enough soft tissues

Strong muscles

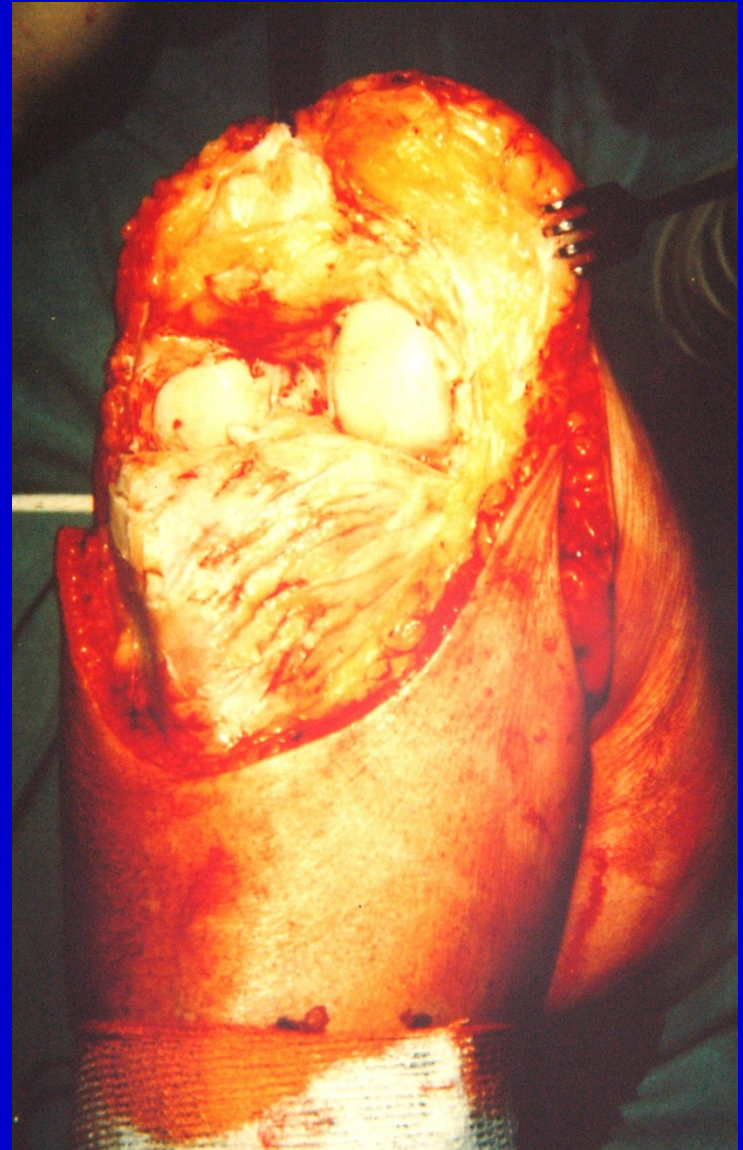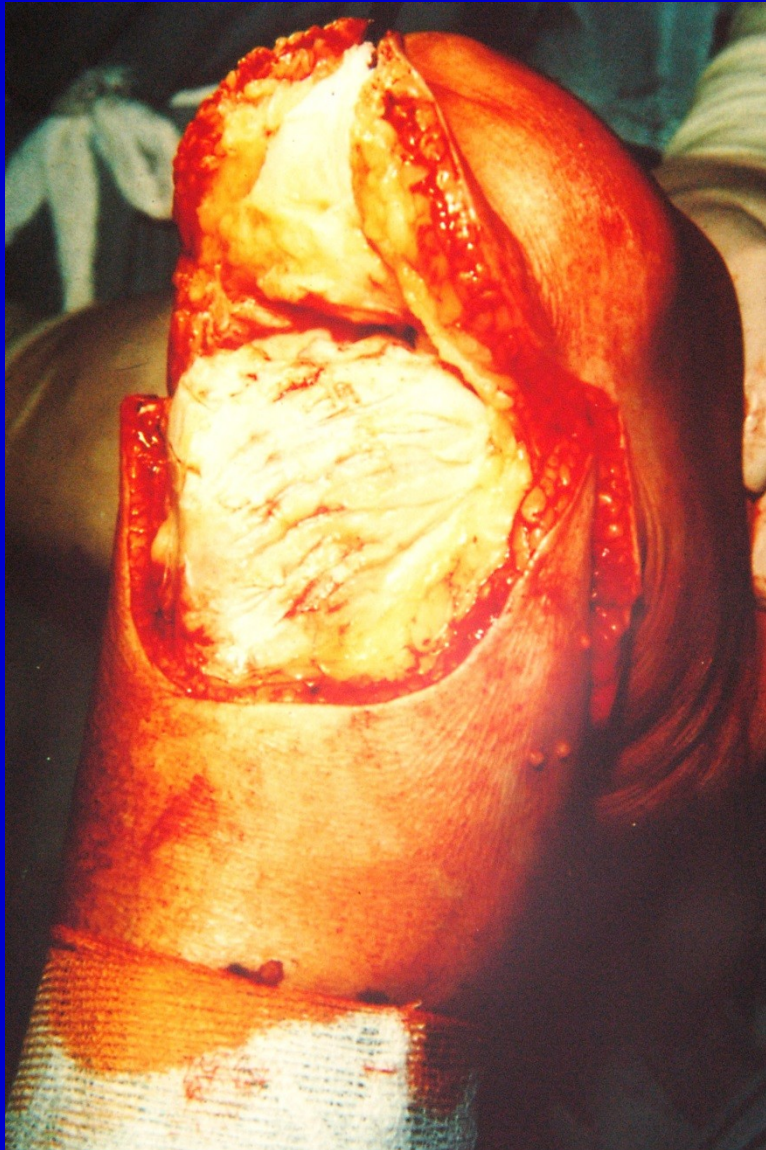Ability to walk



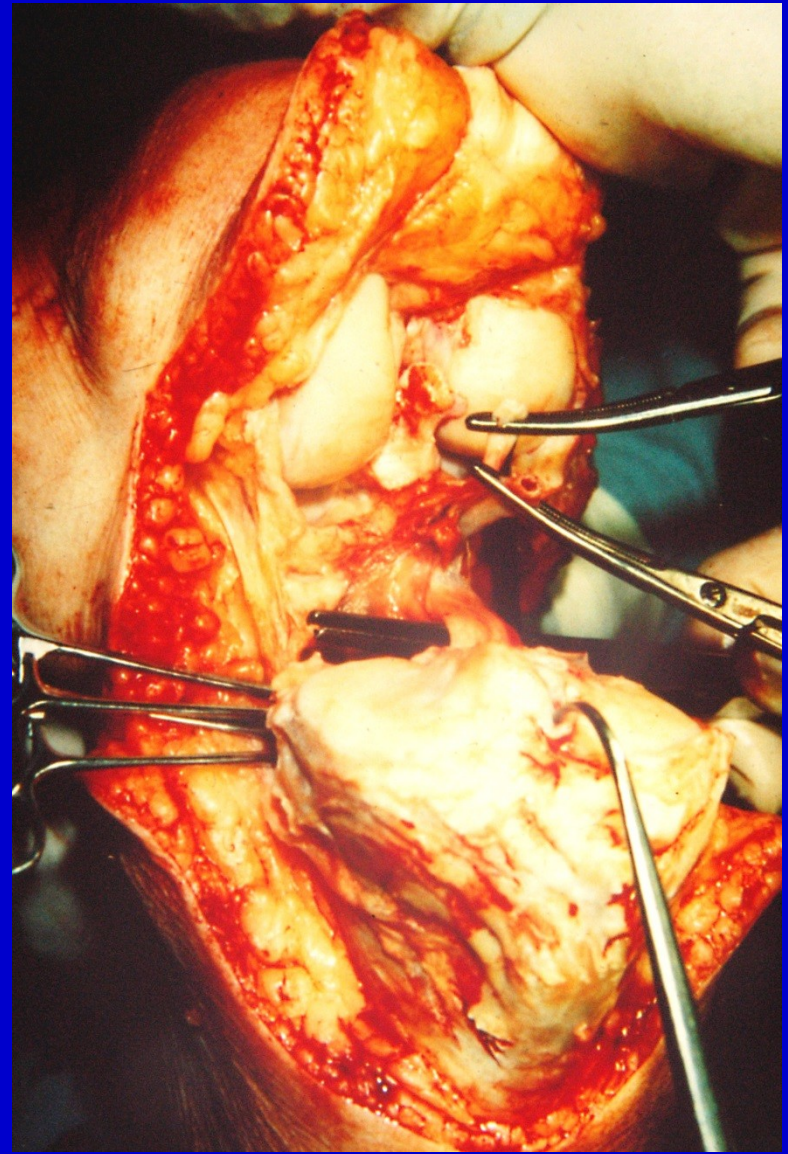
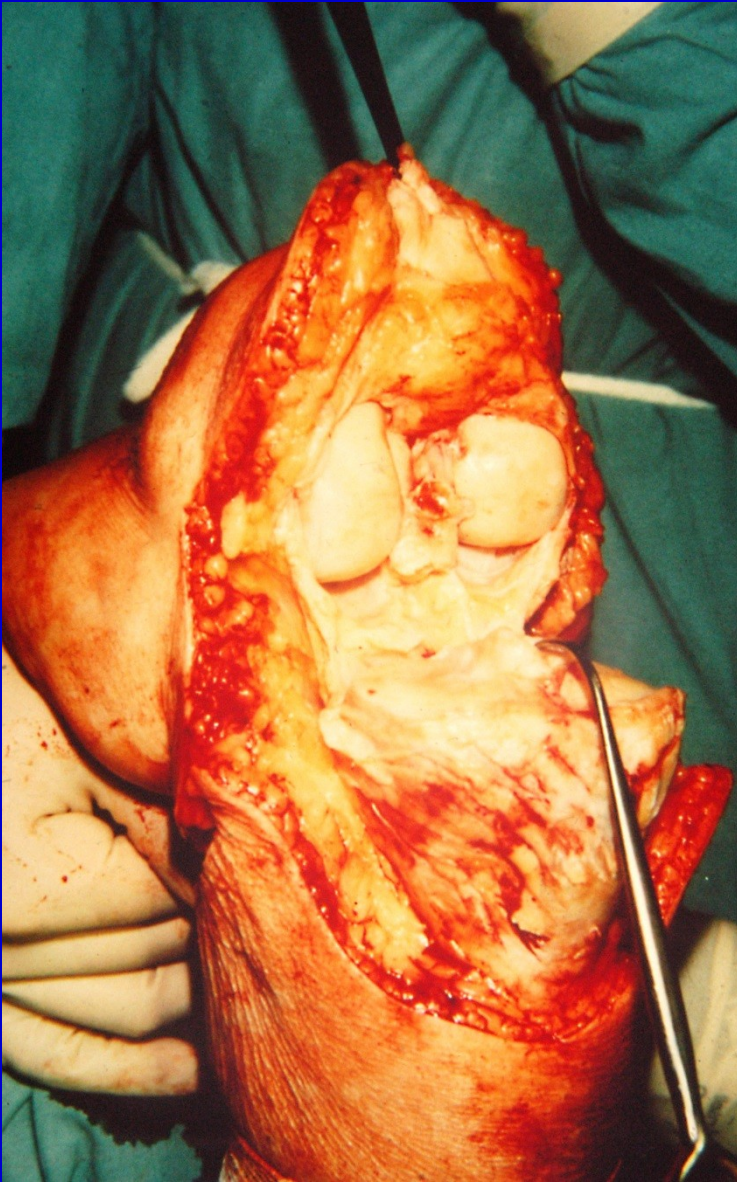
Disarticulation in the knee region



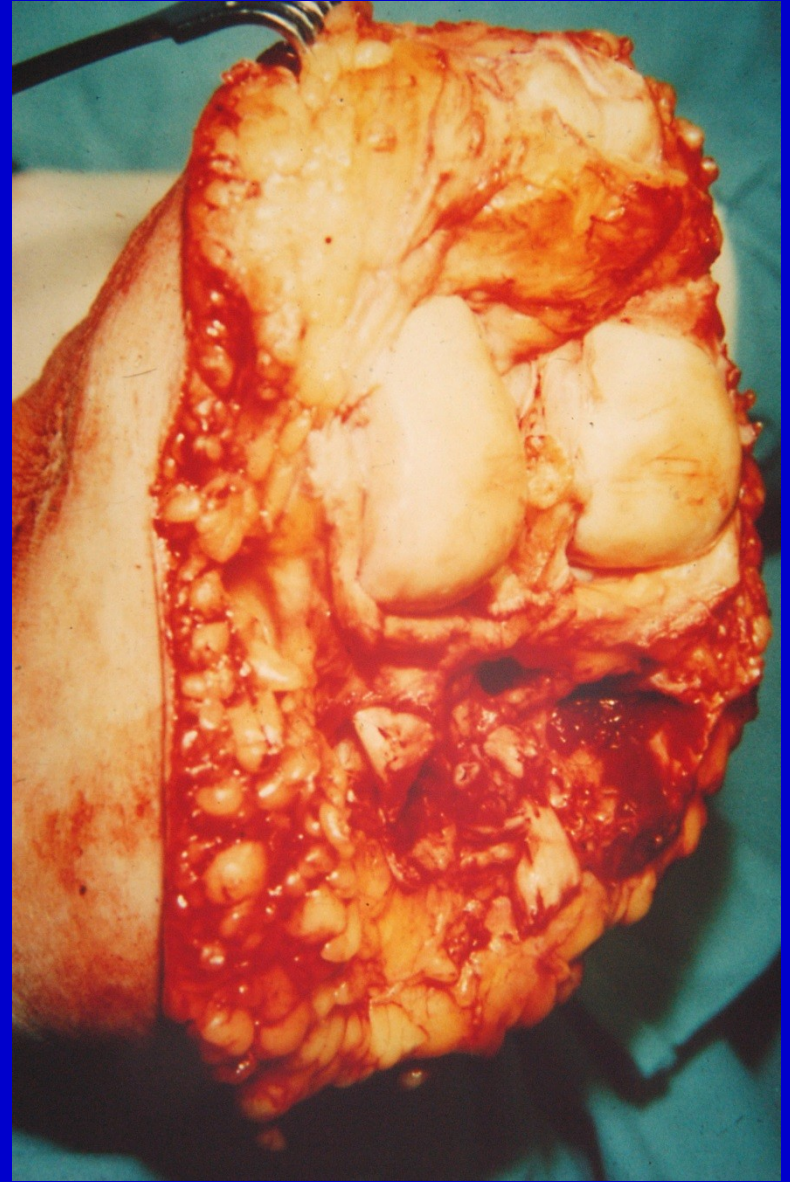
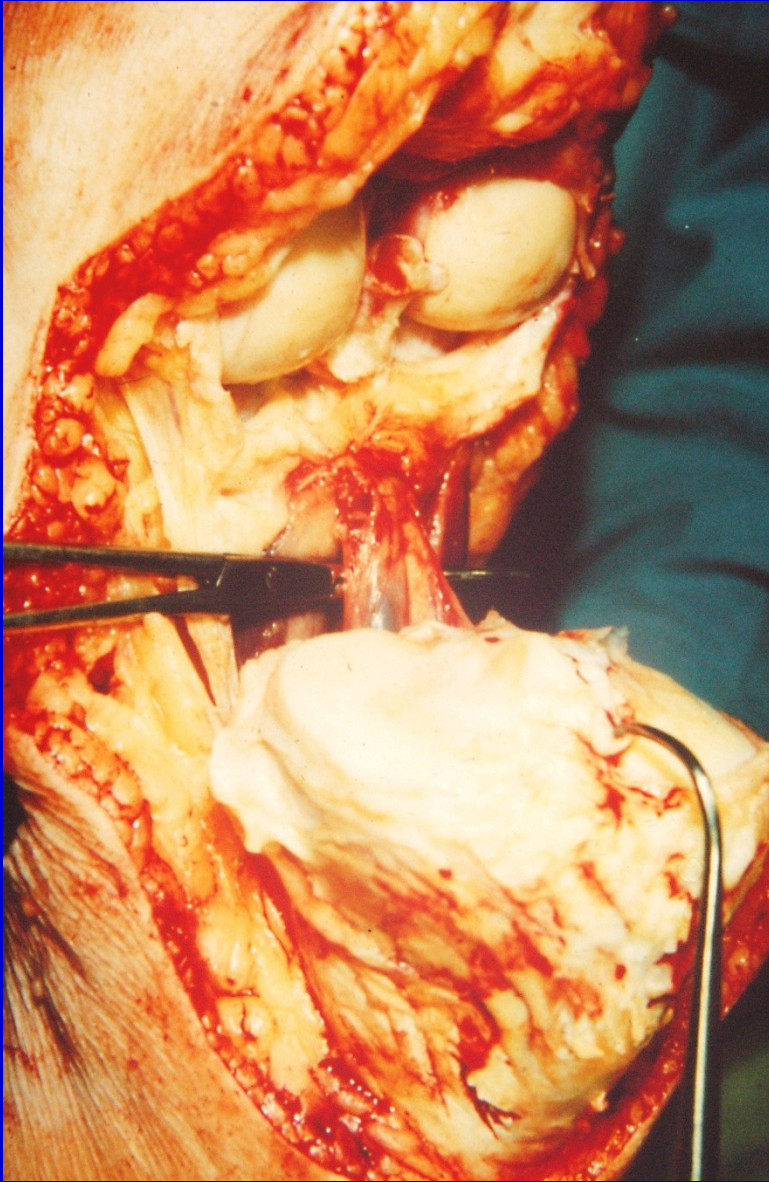
Skin incision



Joint capsule incision, elevation of the patella

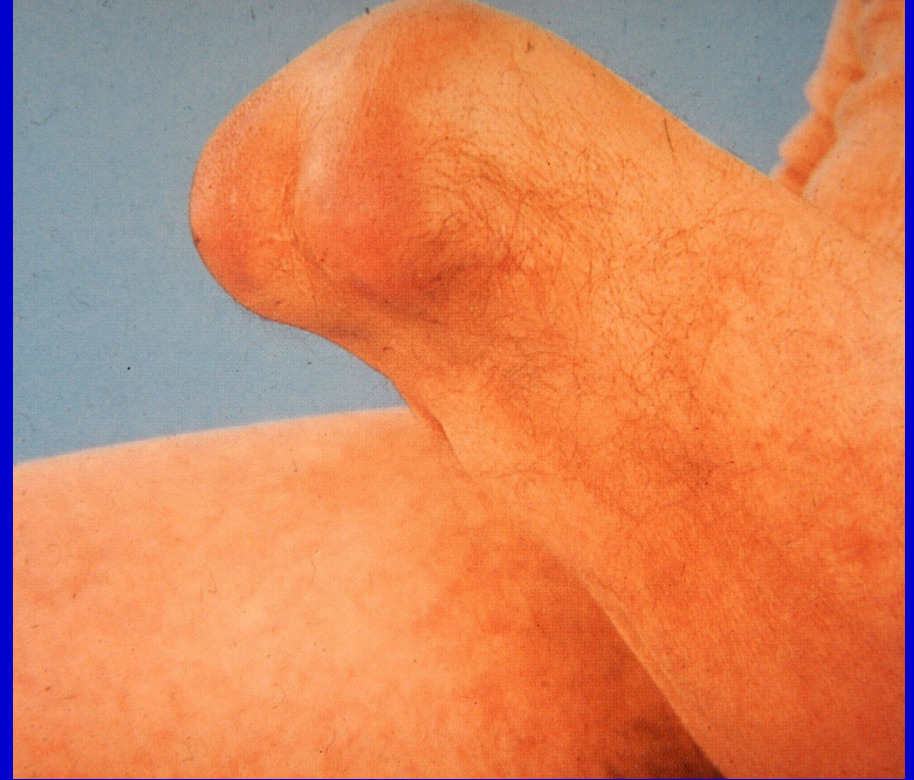
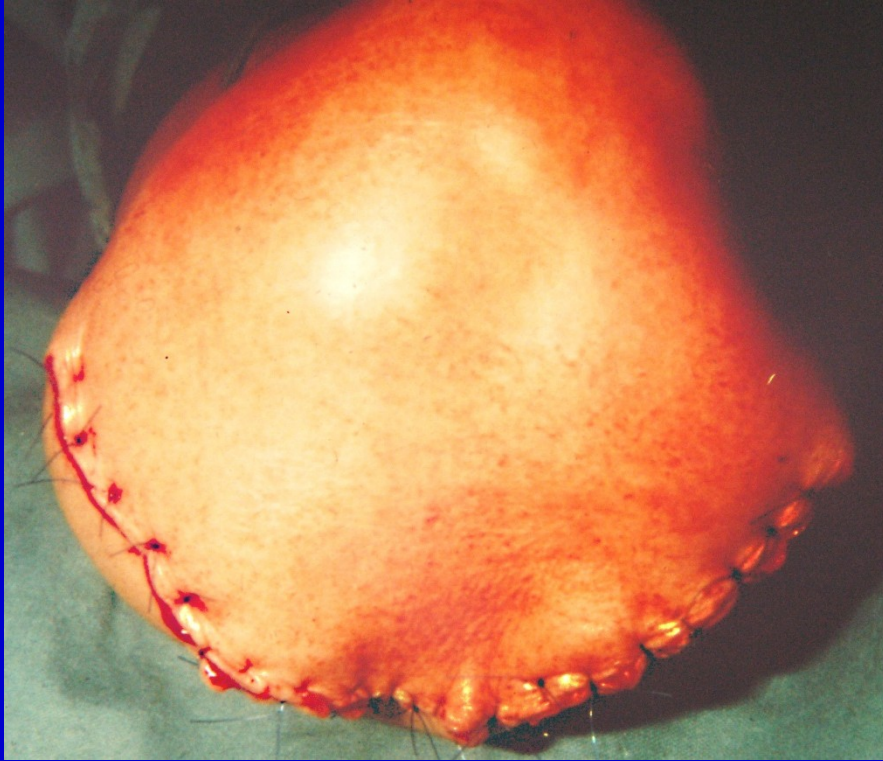
Dissection of posterior joint capsule, section of tibial nerve

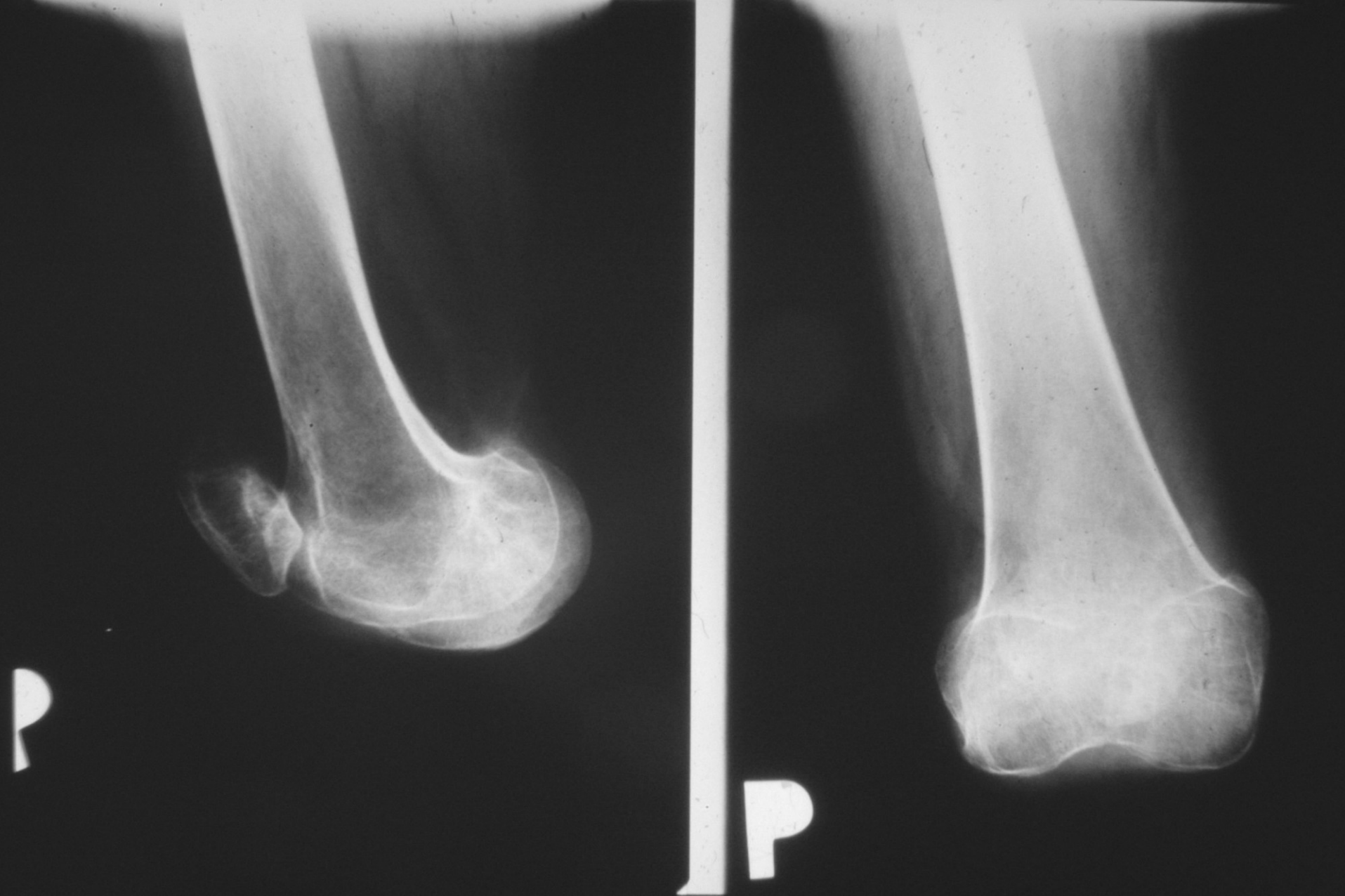


Ligation of popliteal vessels, removal of the limb

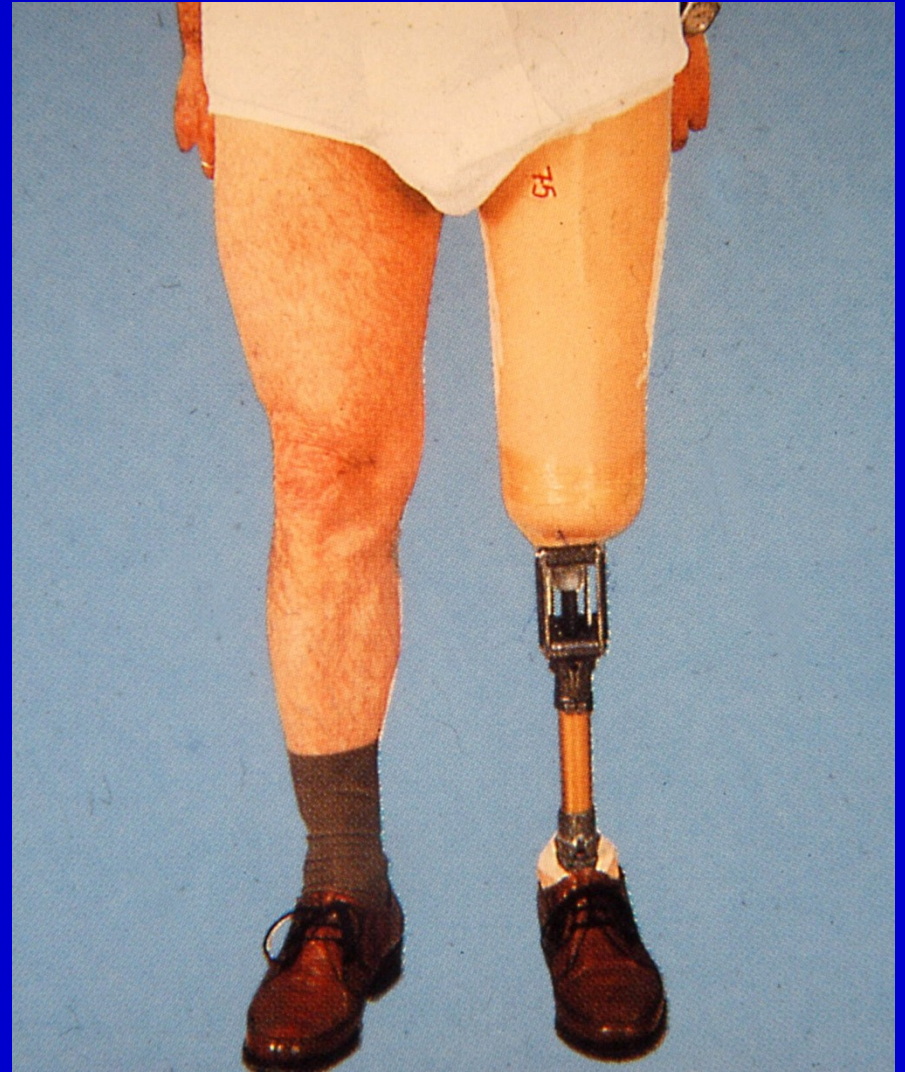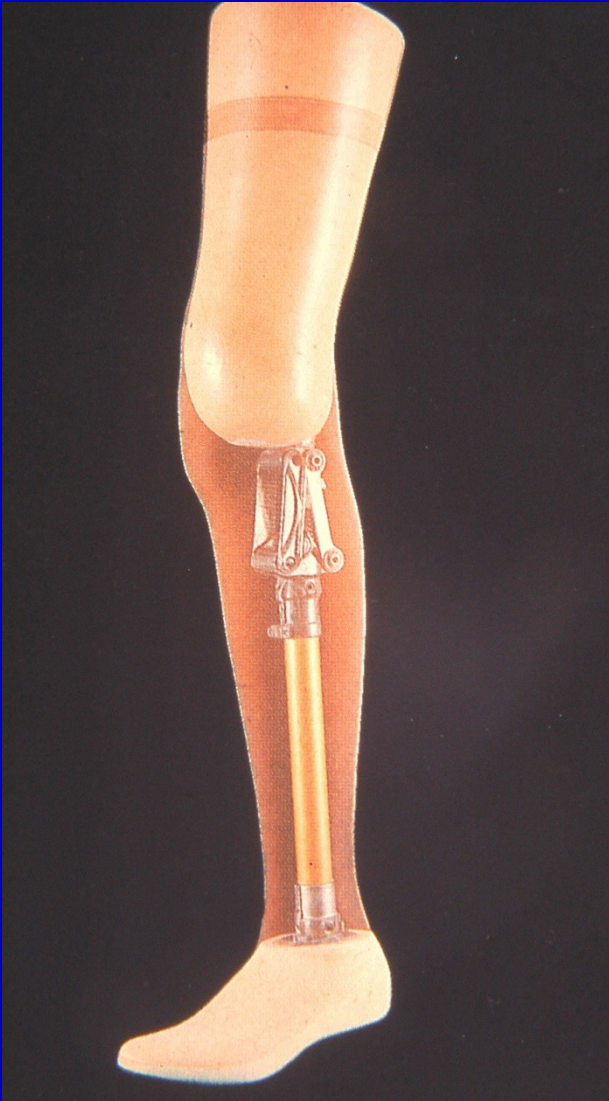Suture without tension



Suture of the wound, healed stump



X - ray after disarticulation



Prosthesis after disarticulation of the knee region