



Petr Fila

CARDIAC SURGERY

- heart transplantation
- mechanical circulatory support

Heart transplantation

Indications

**terminal heart failure
(coronary artery disease, valve disease, cardiomyopathy)**

Contraindications

**fixed pulmonary hypertension
neoplasms
active alcohol or drug abuse
age over 65 years (individual assessment),**

Potential relative contraindications

active infection, pulmonary embolism, active peptic ulcer disease

liver, kidney failure – 2 or 3 organs transplantation

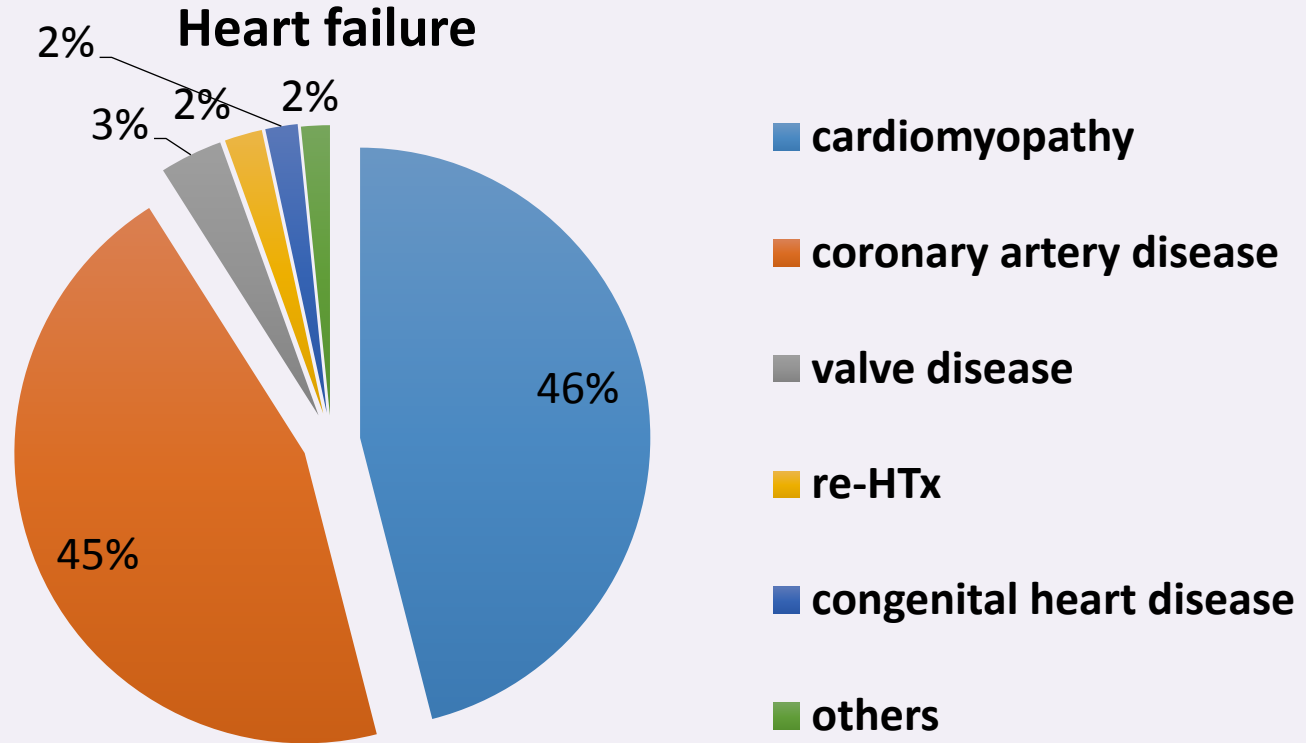


CKTCH

Center of Cardiovascular
Surgery & Transplantation

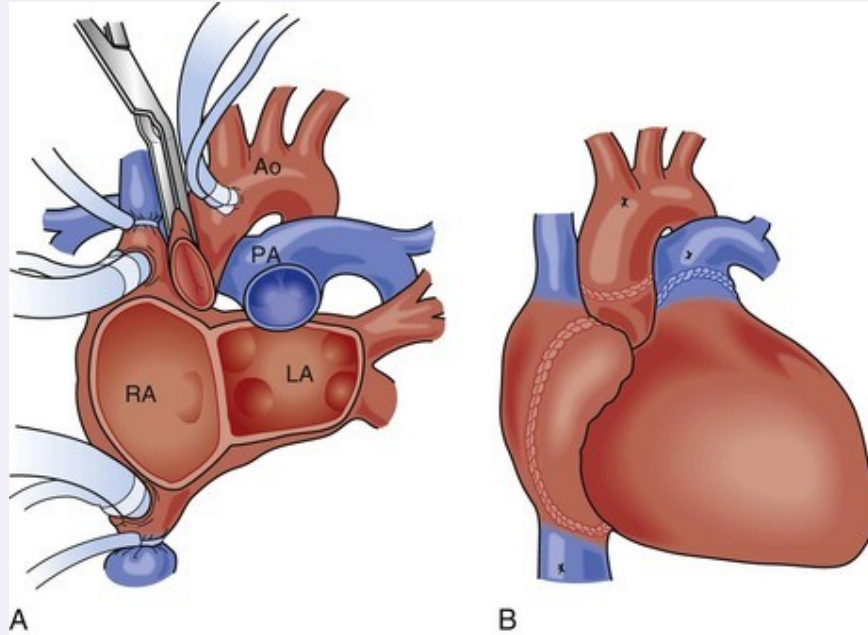


Heart failure - etiology

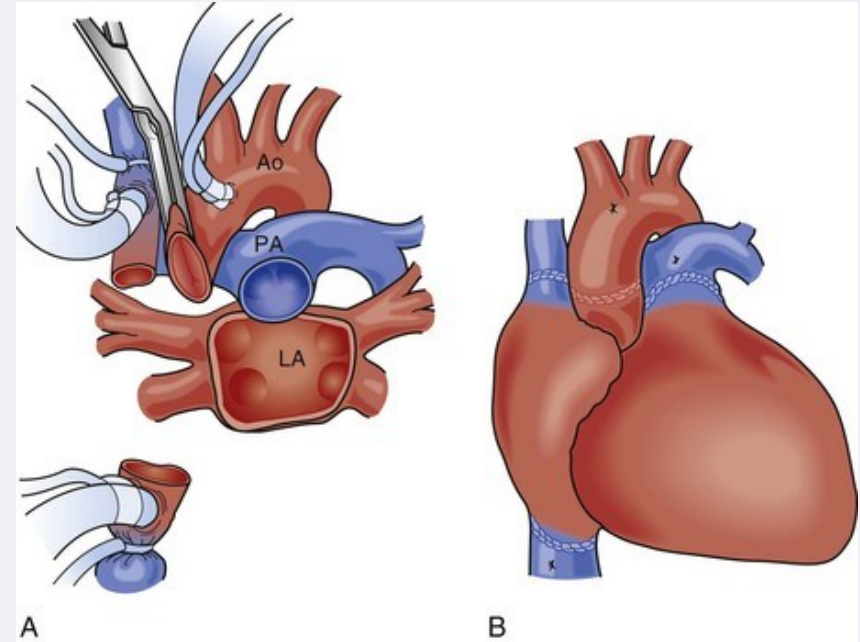


Heart transplantation - surgical technique

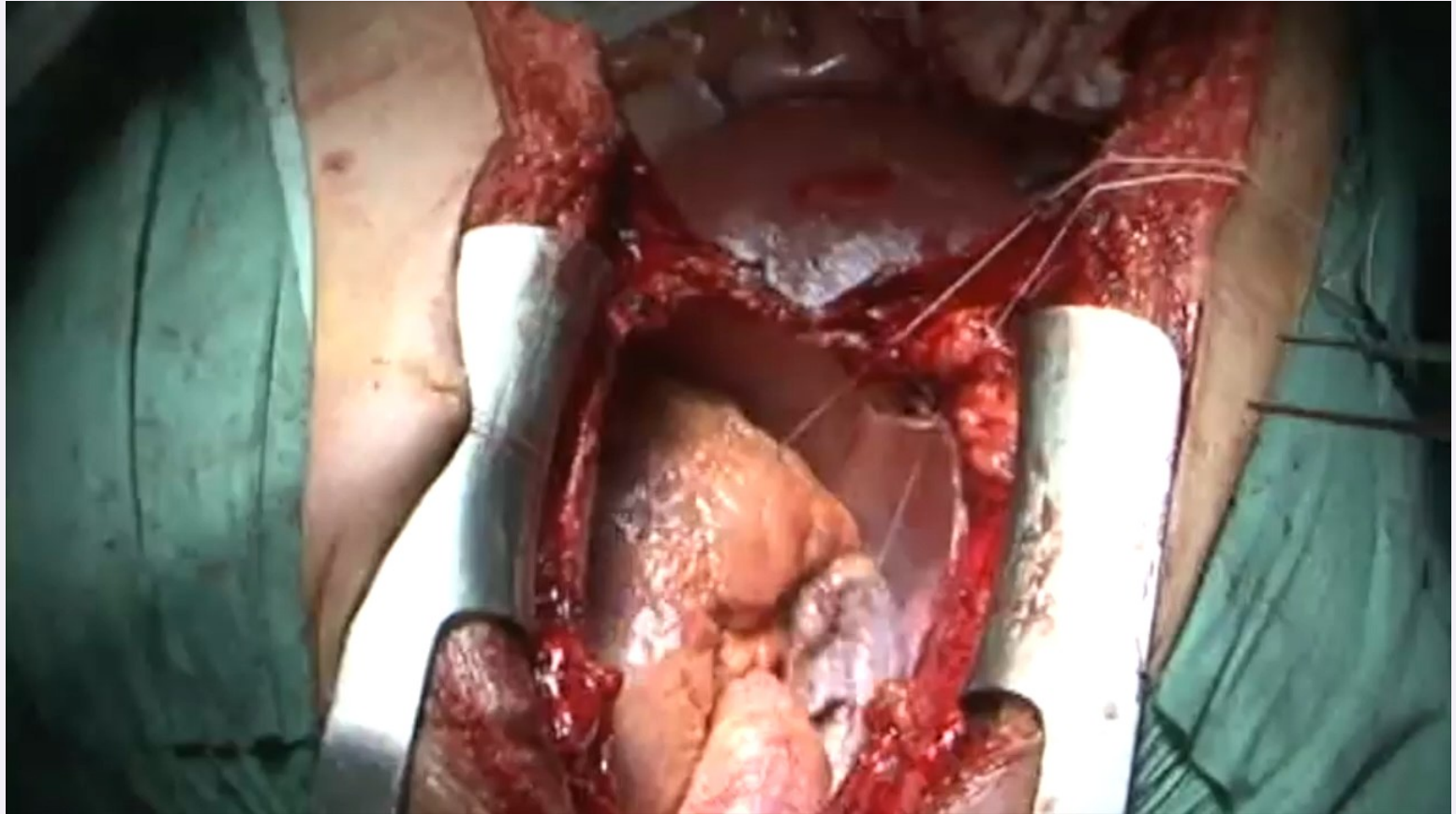
biatrial (Lower-Shumway)



bicaval



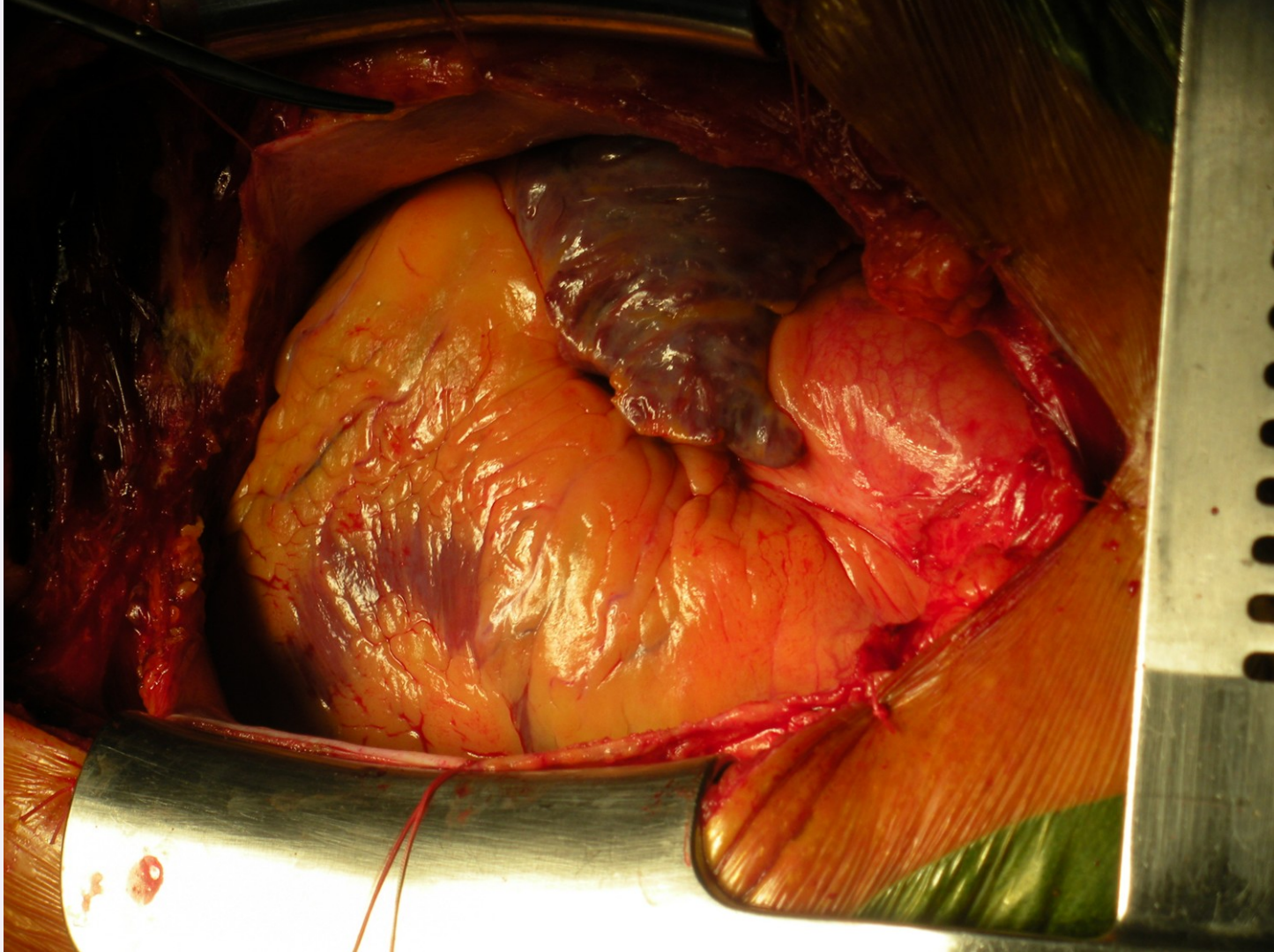
Heart transplantation - video

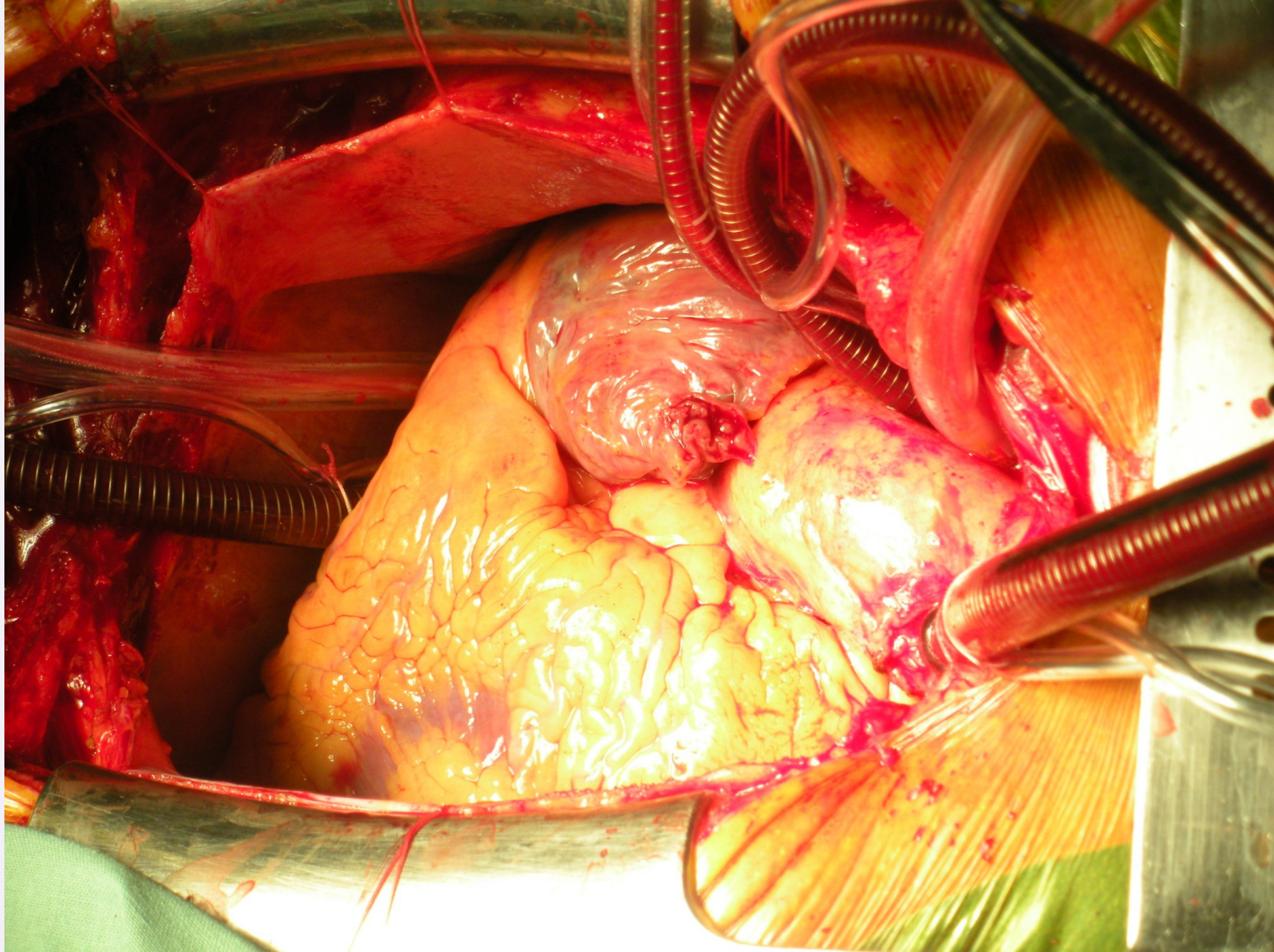


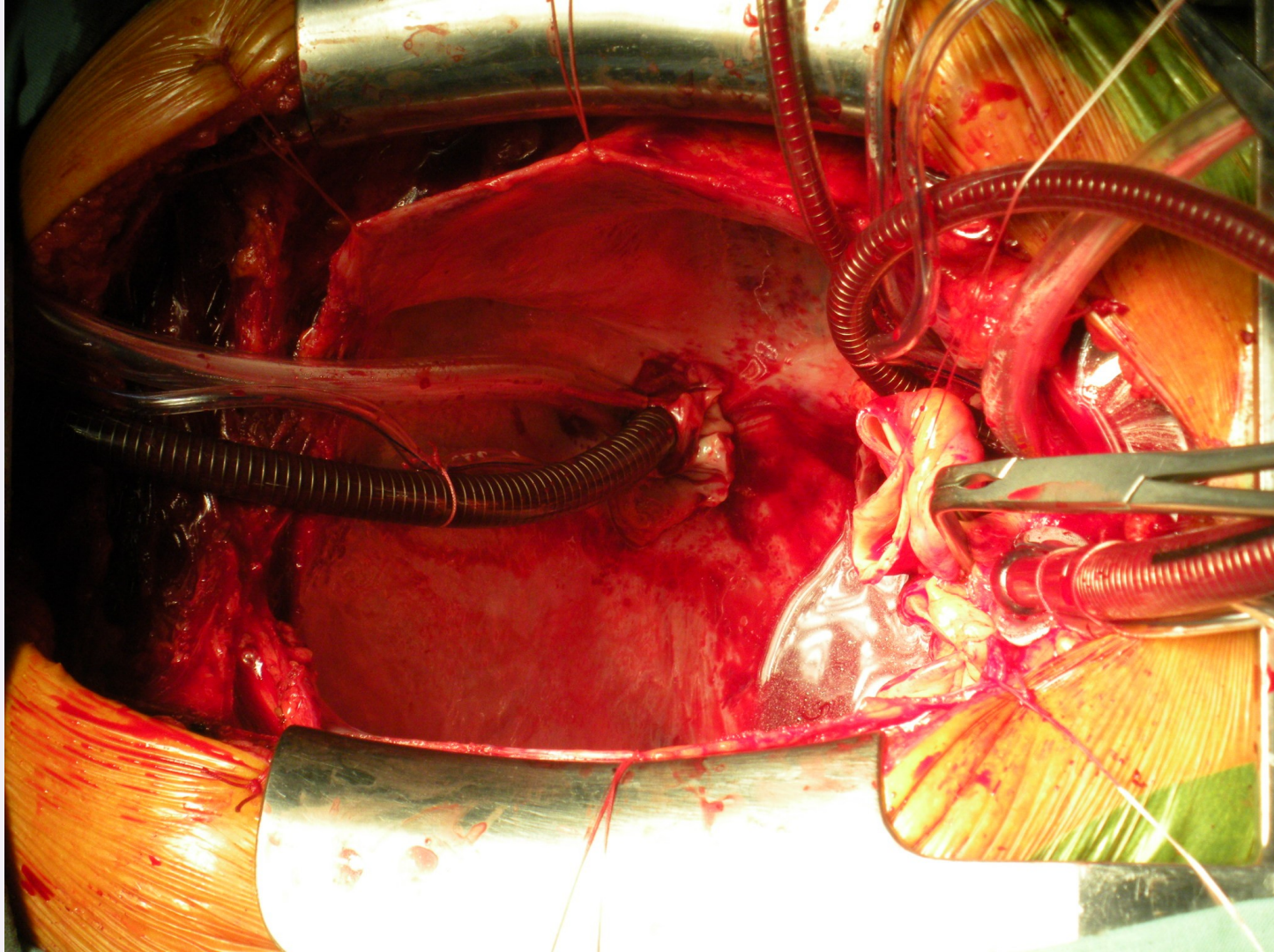
CKTCH

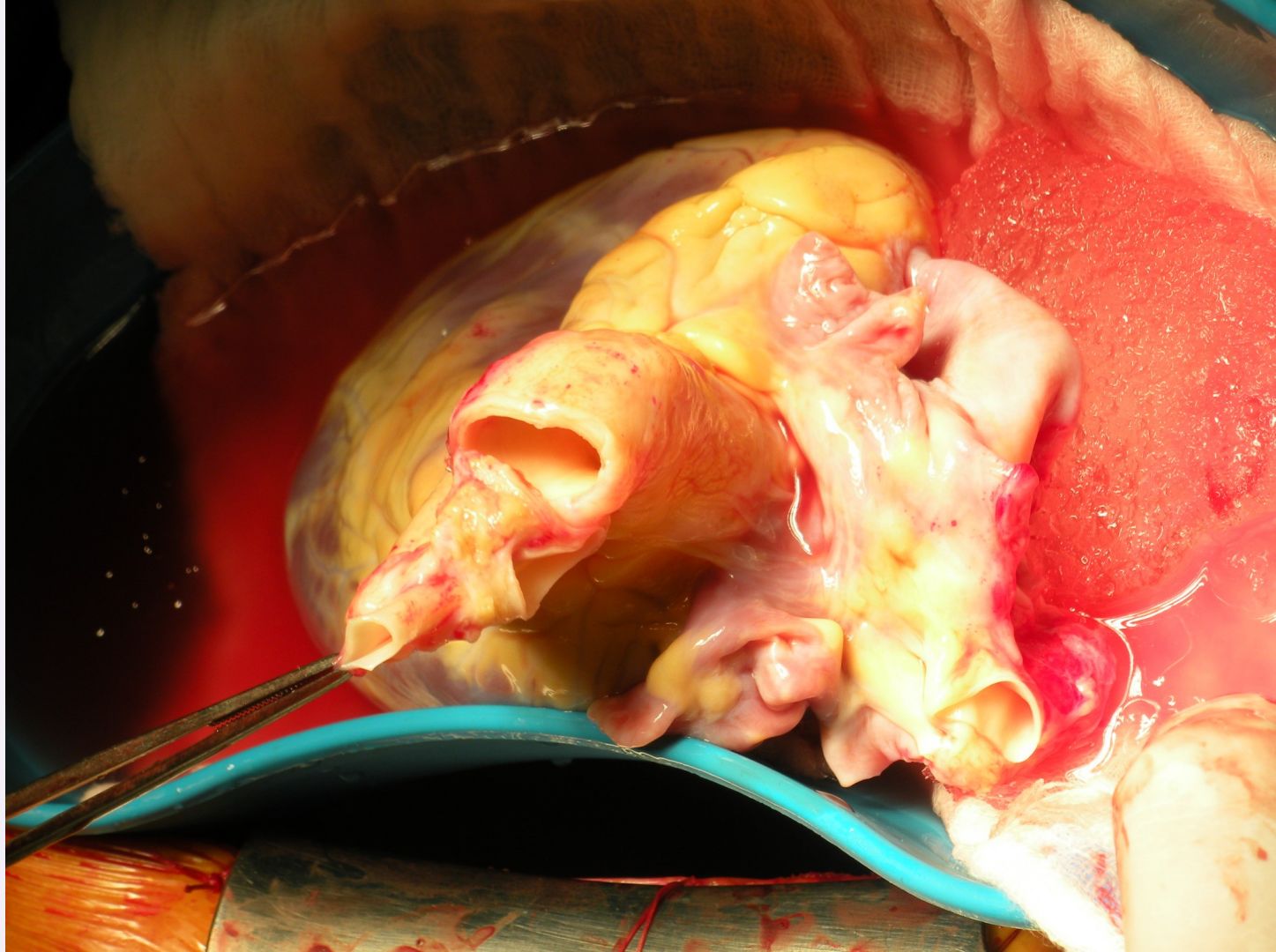
Centrum kardiovaskulárnej
a transplantačnej chirurgie

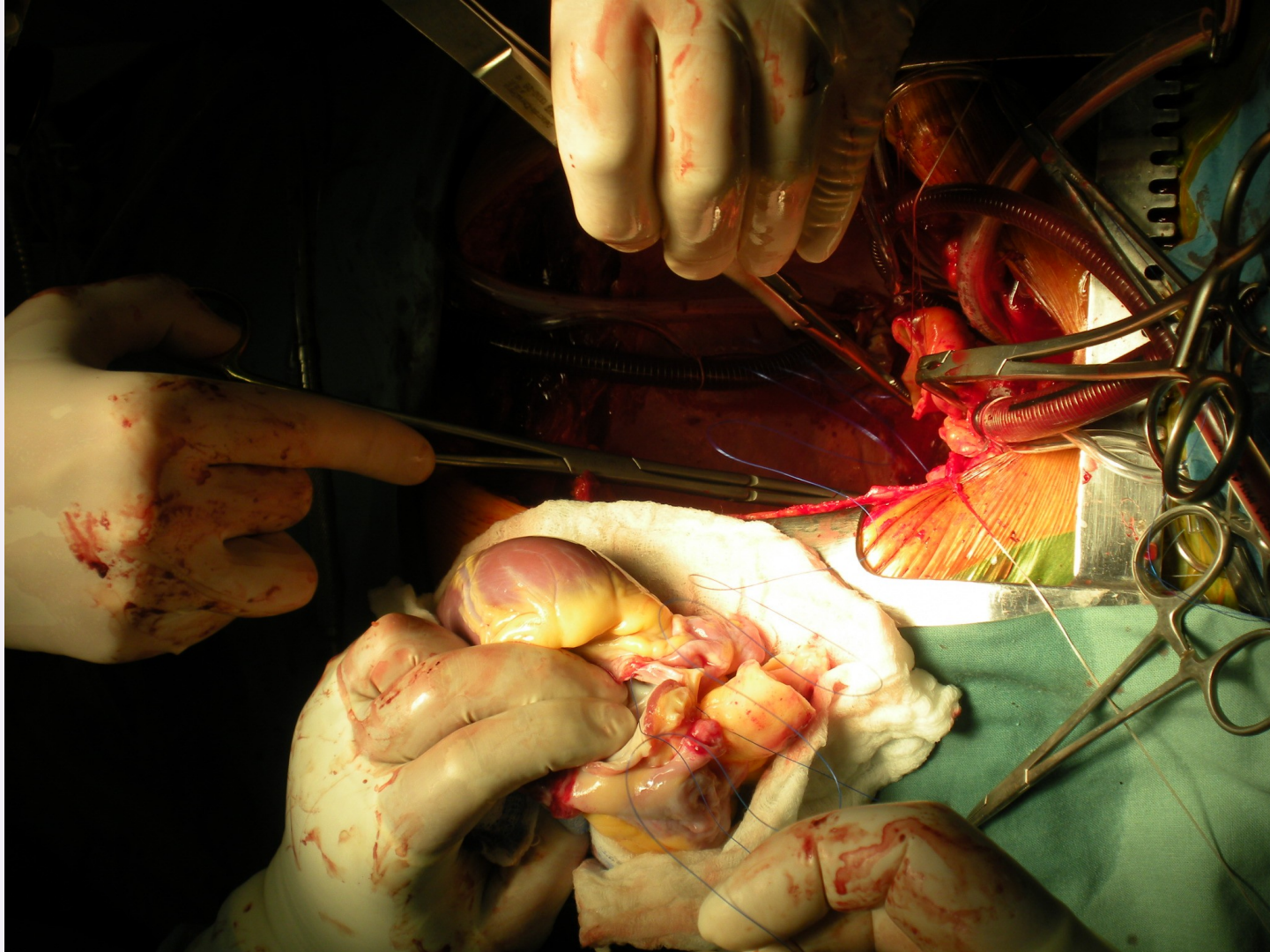


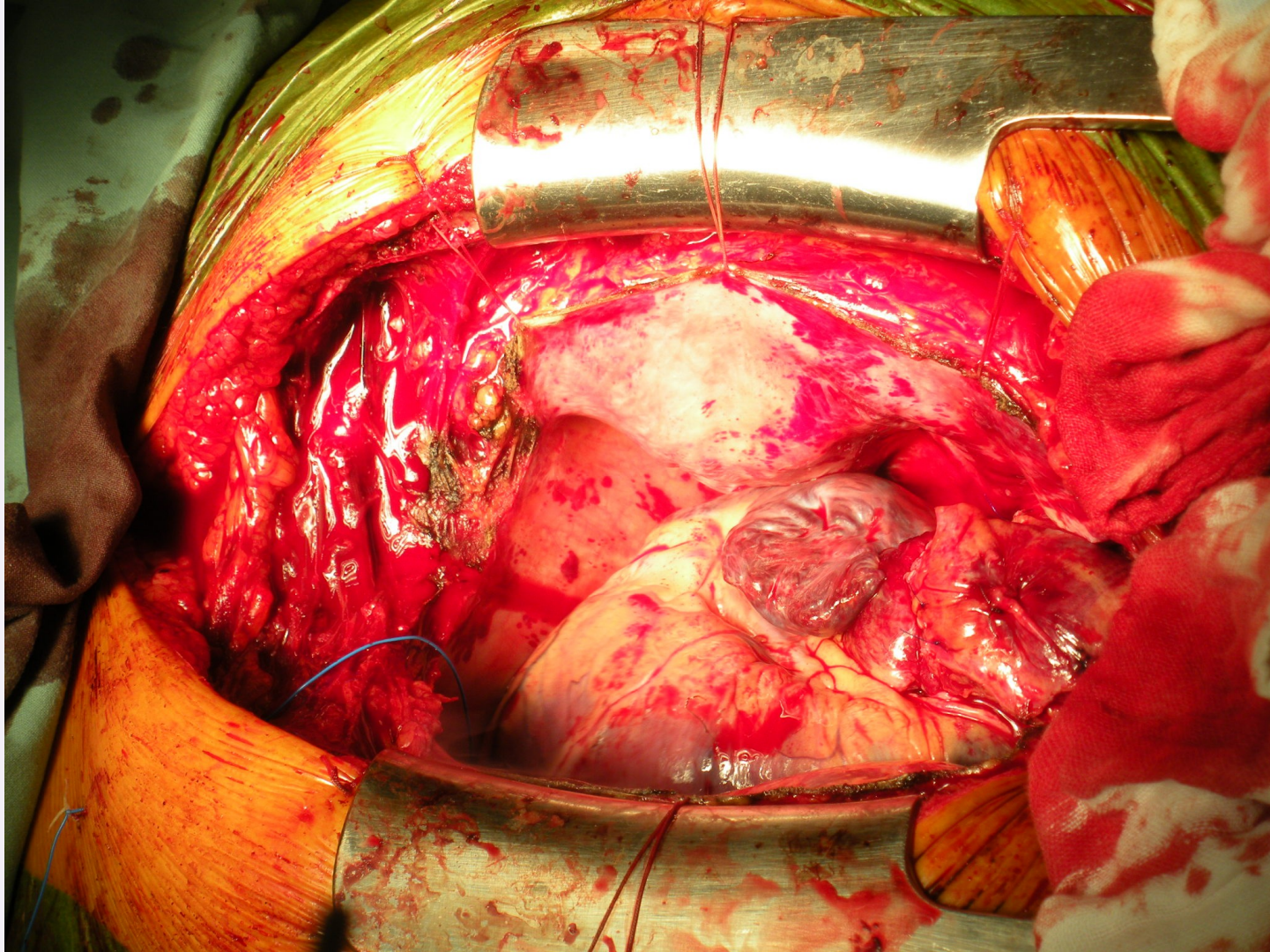


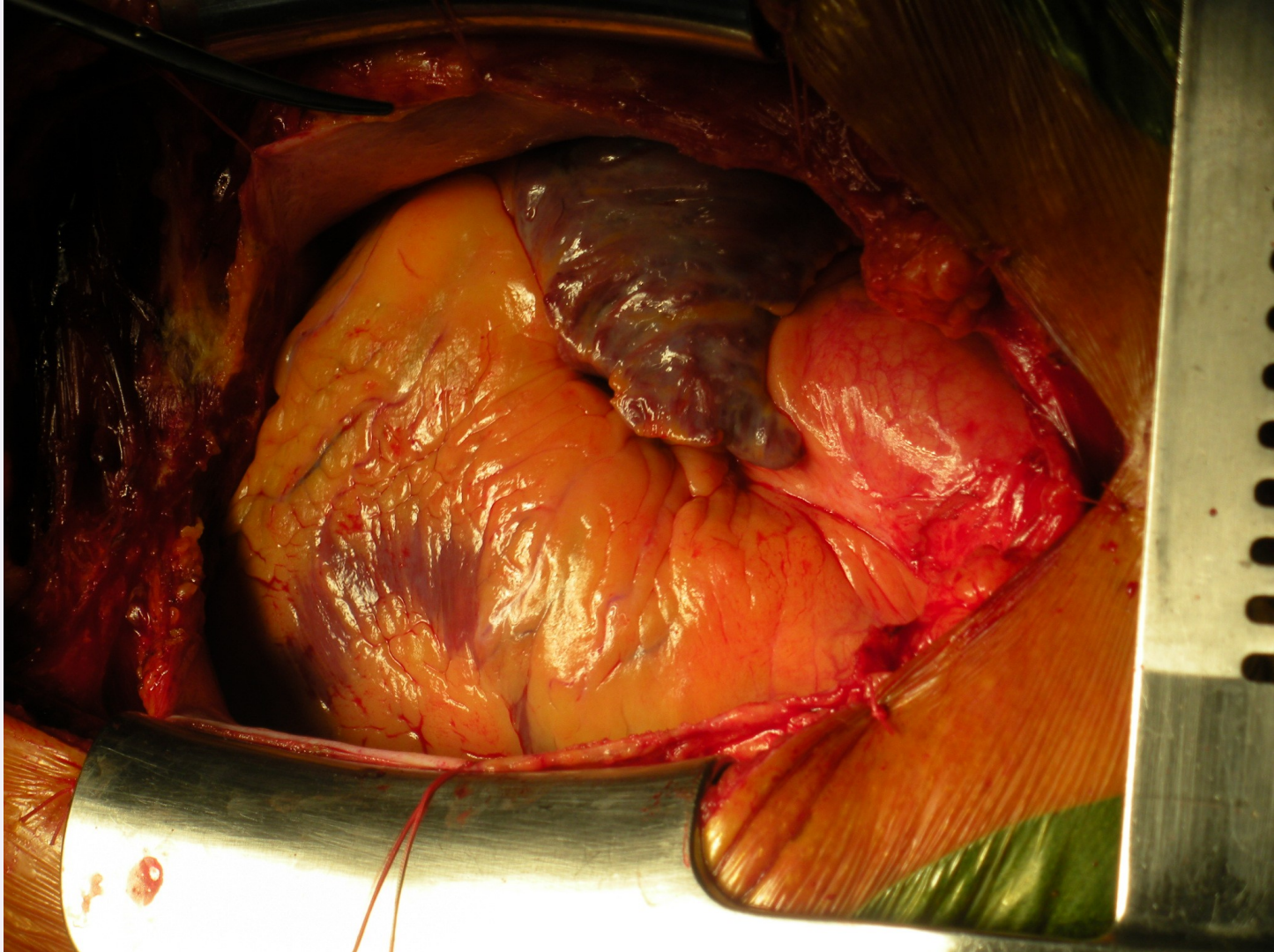












Mechanical circulatory support

Duration of support

- **short-term**
reversible damage
- **long-term**
„brigde-to-transplantation“
- **permanent**
contraindications for heart transplantation

Type of support needed

- **left-side**
- **right-side**
- **biventricular**

Localization

- **paracorporeal**
- **implantable**

Flow

- **Pulsatile**
 - pneumatic
 - electromechanic
- **Non-pulsatile**
 - axial
 - centrifugal



Mechanical circulatory support - indication

Postcardiotomy cardiogenic shock

unsuccessful weaning from extracorporeal circulation
malignant ventricular arrhythmias
low cardiac output syndrom

Other etiology of cardiogenic shock

after acute myocardial infarction, after PCI, myocarditis...

Chronic heart failure

pts on waiting list for heart transplantation

Acute rejection after HTx

Heart failure (primary graft non-function) after HTx

Patients with contraindications for heart transplantation

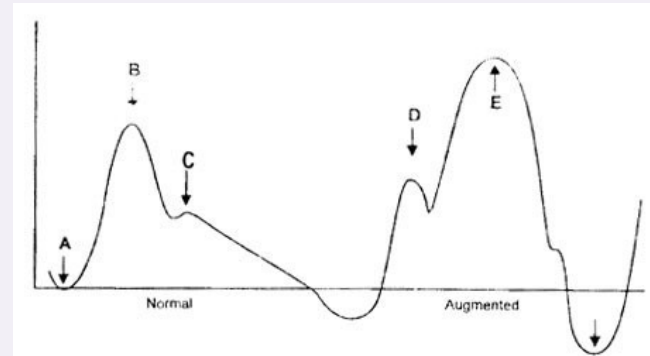
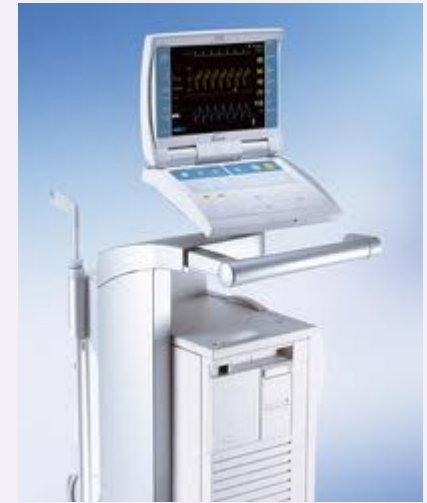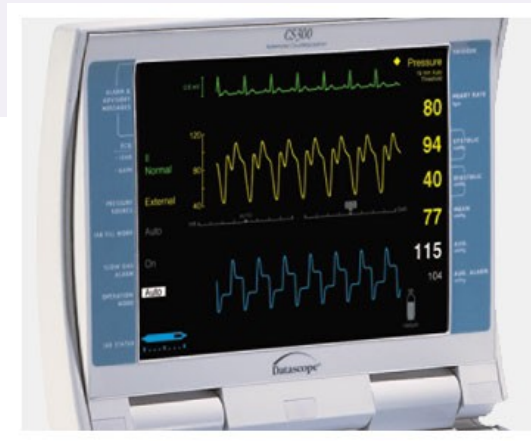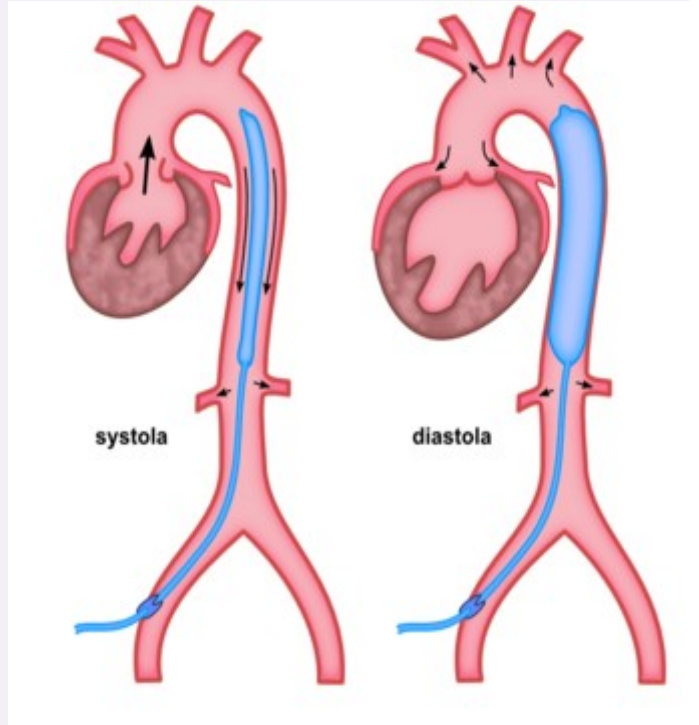


CKTCH

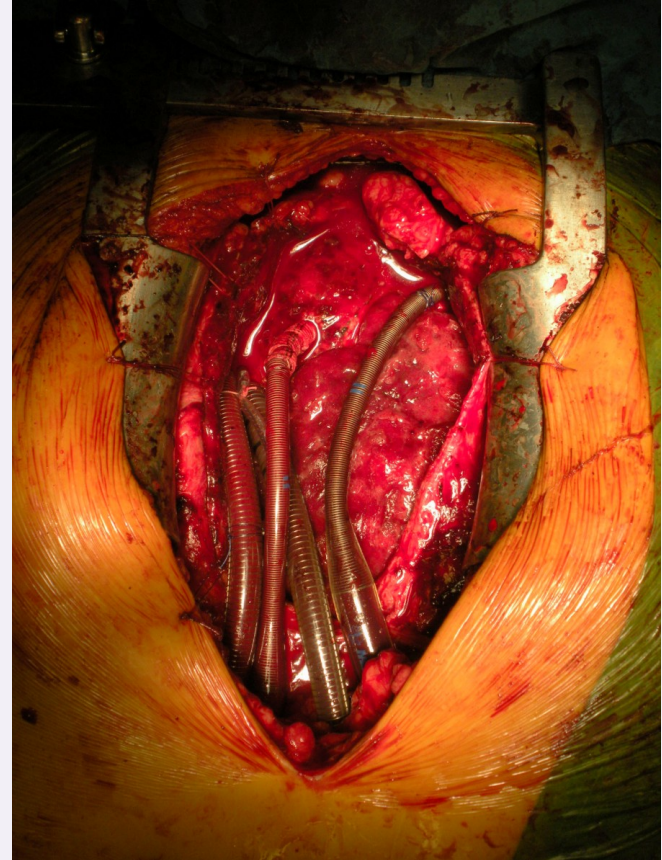
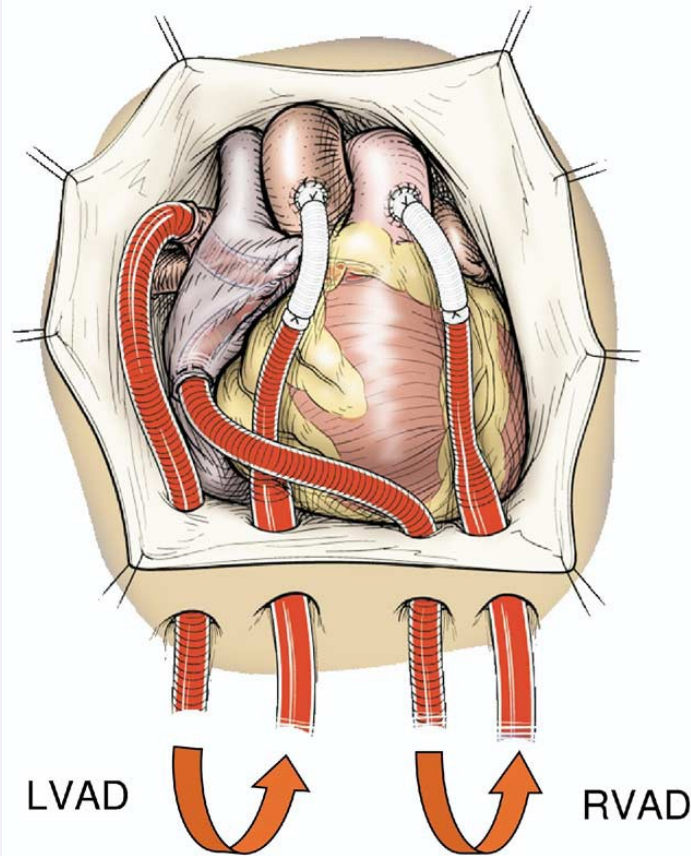
Center of Cardiovascular
Surgery & Transplantation



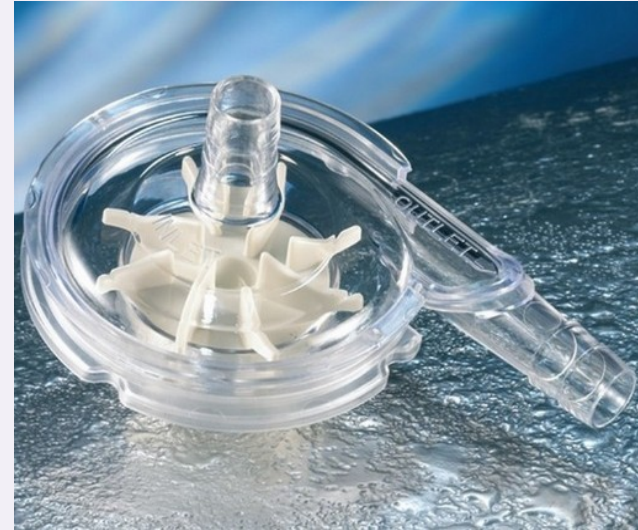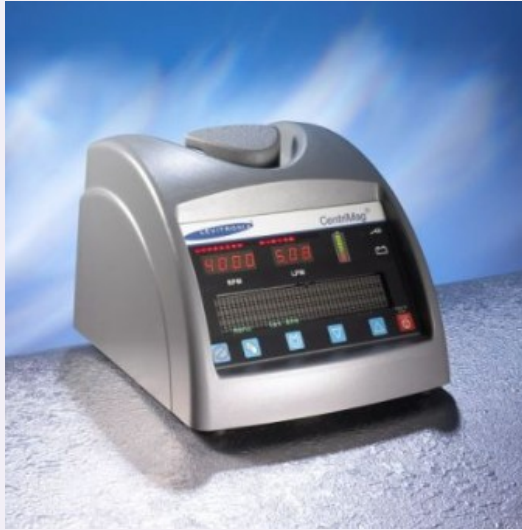Intraaortic balloon counterpulsation



Short-term MCS - Centrimag



Short-term MCS - Centrimag

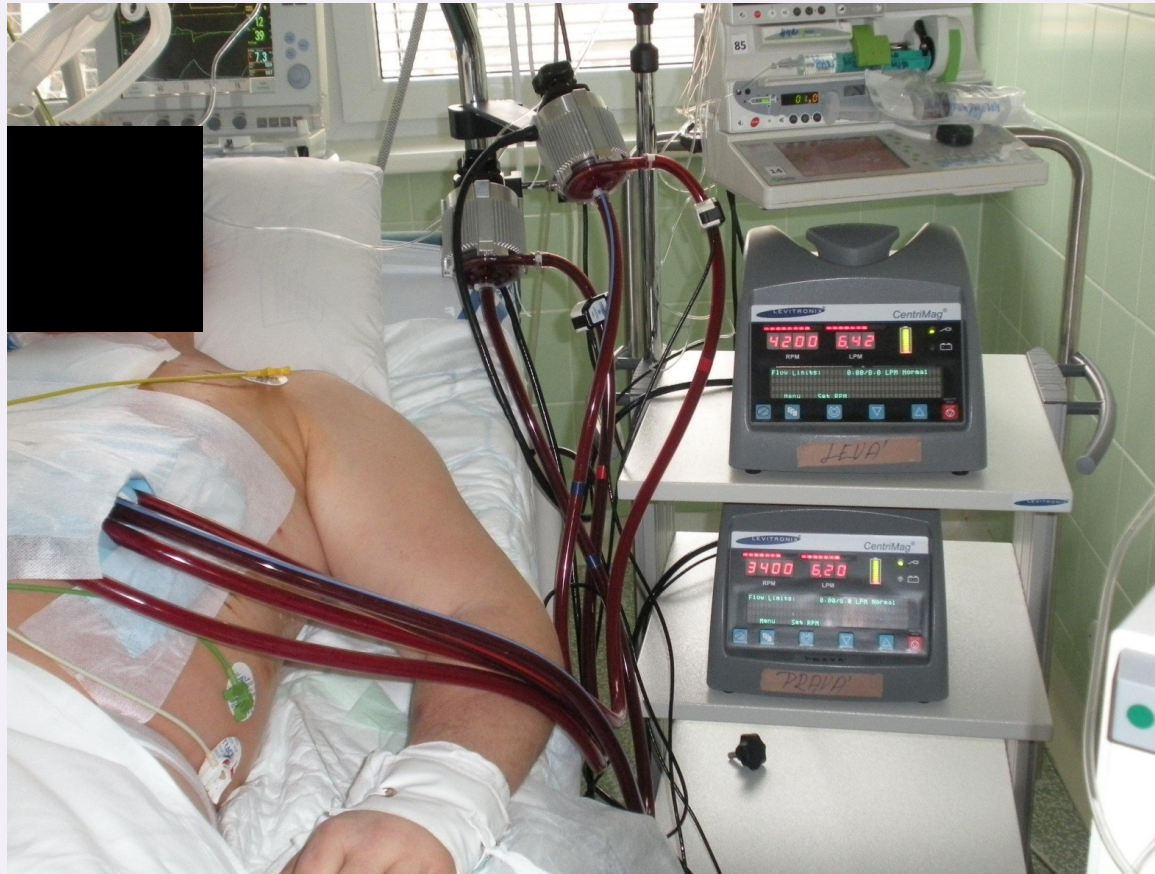

CKTCH

Center of Cardiovascular
Surgery & Transplantation

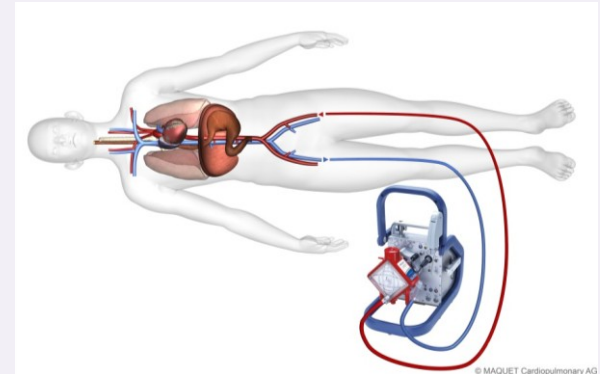
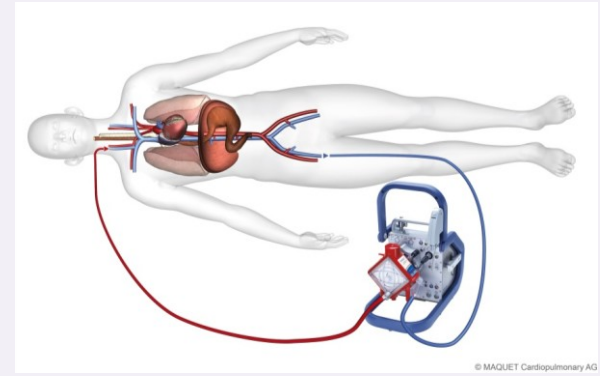


Short-term MCS - Centrimag

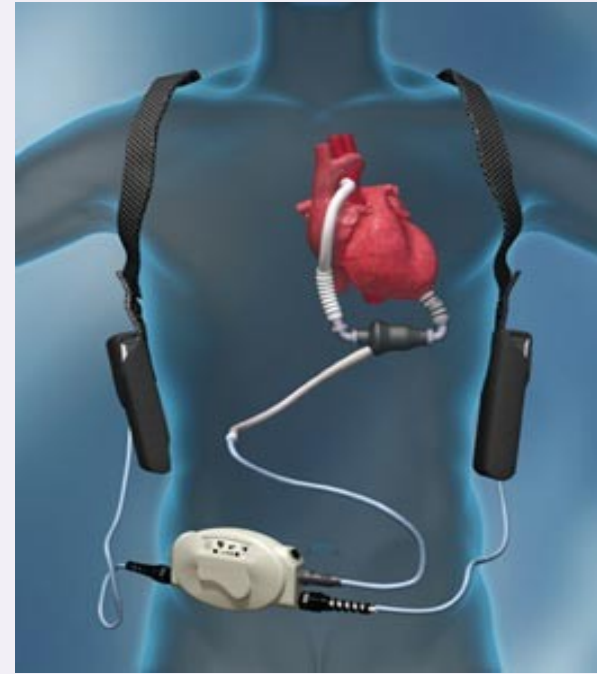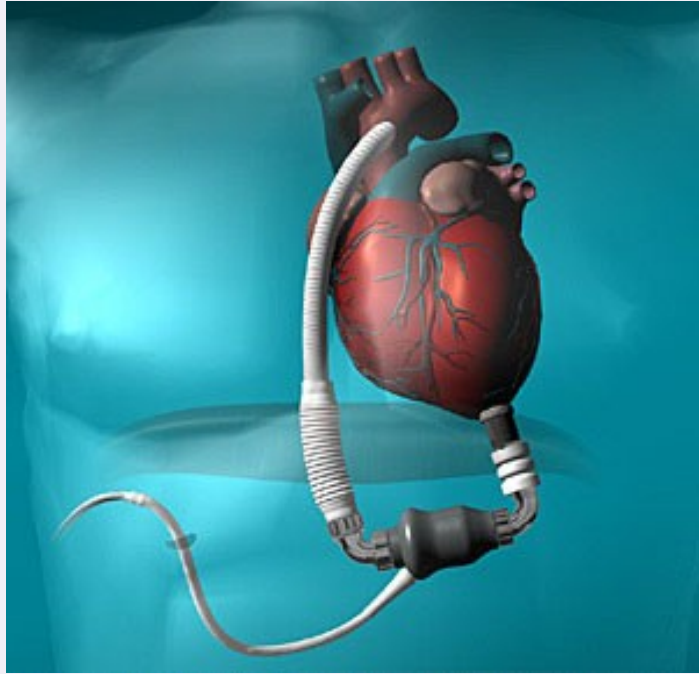


Short-term MCS - ECMO

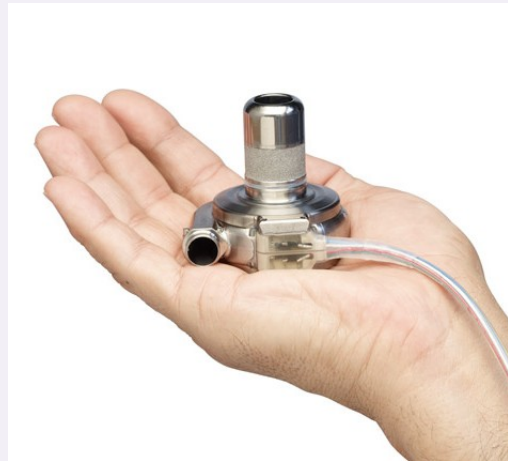
extracorporeal membrane oxygenation

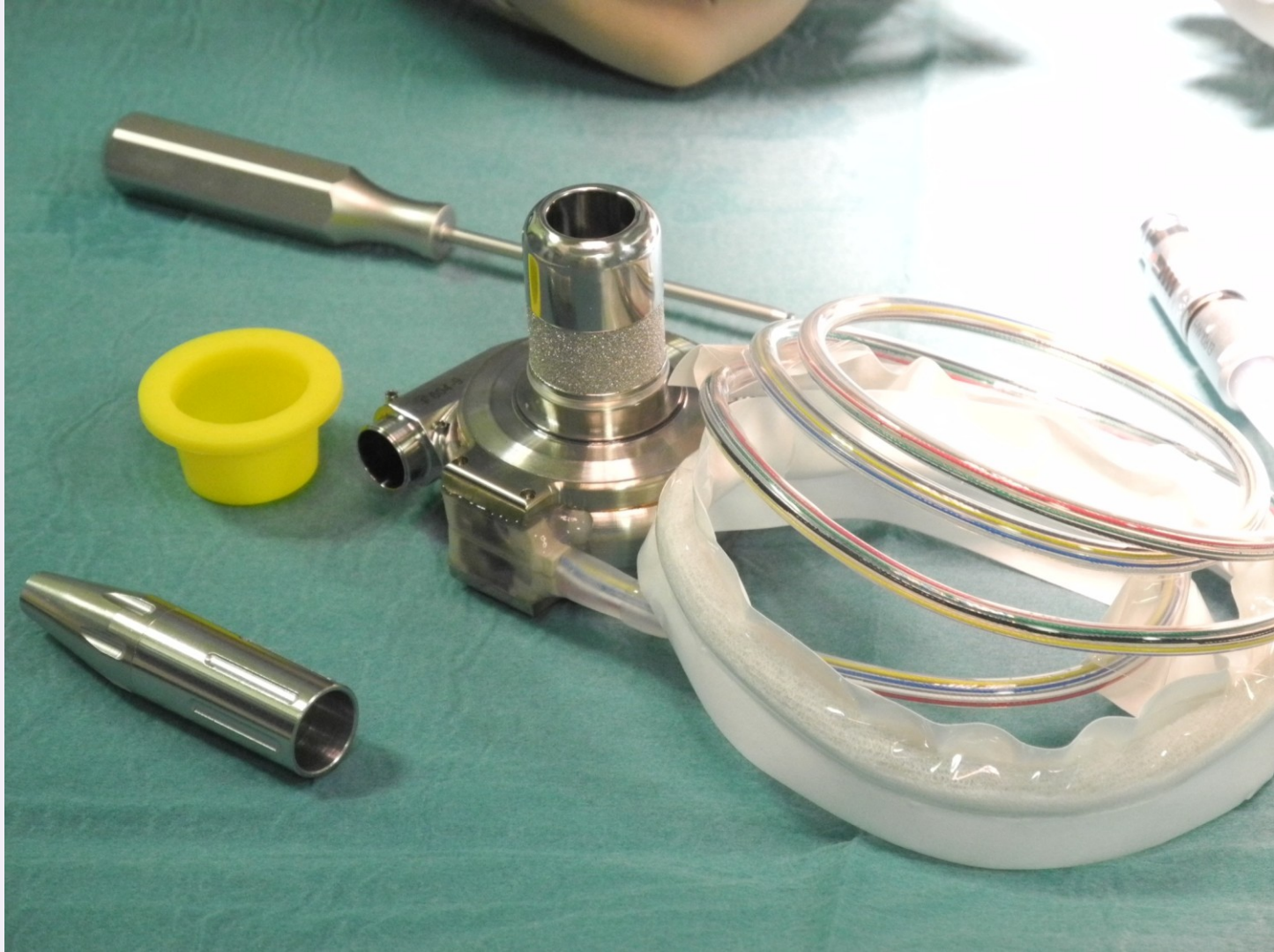

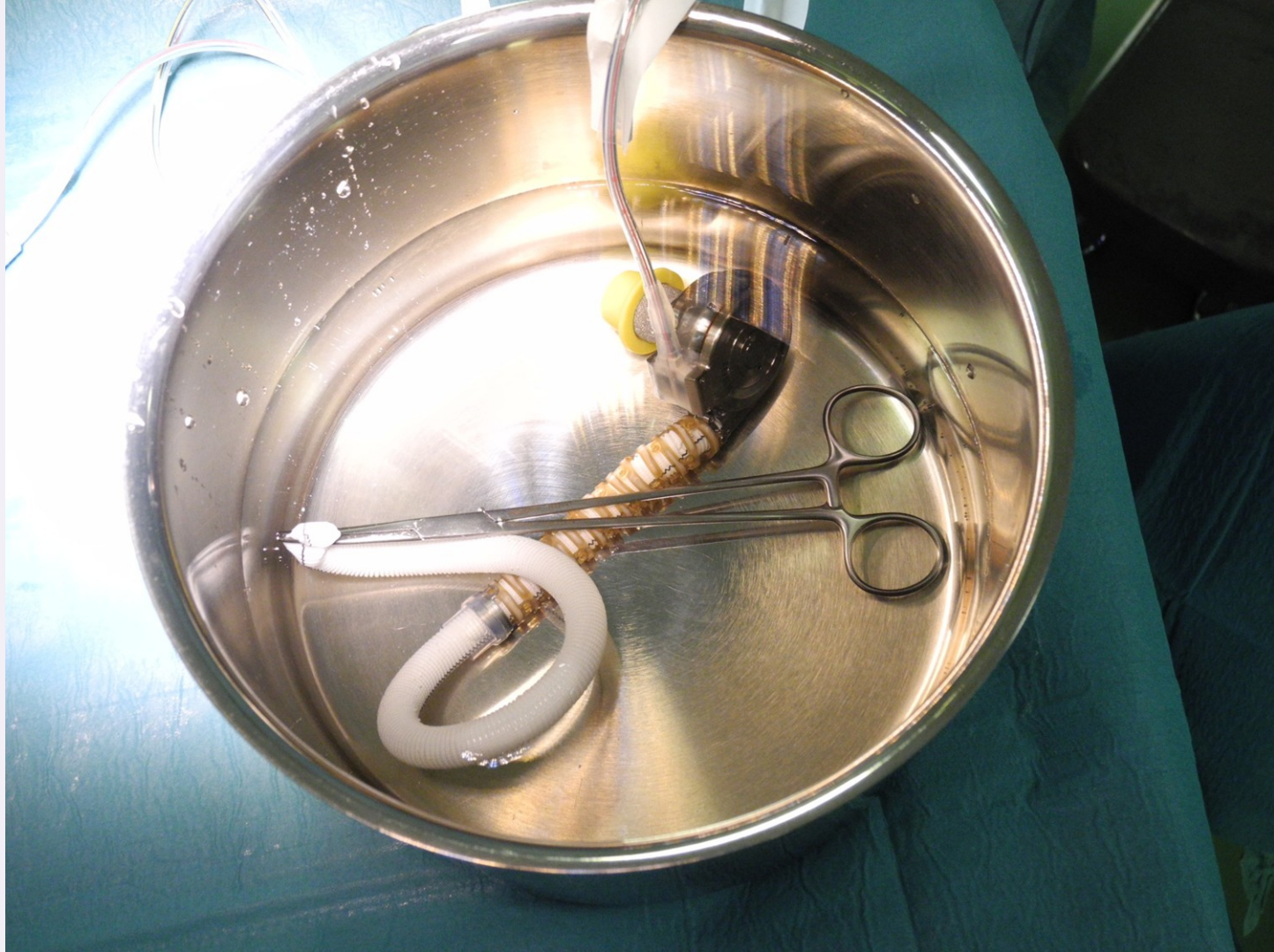Long-term MCS – Heartmate II

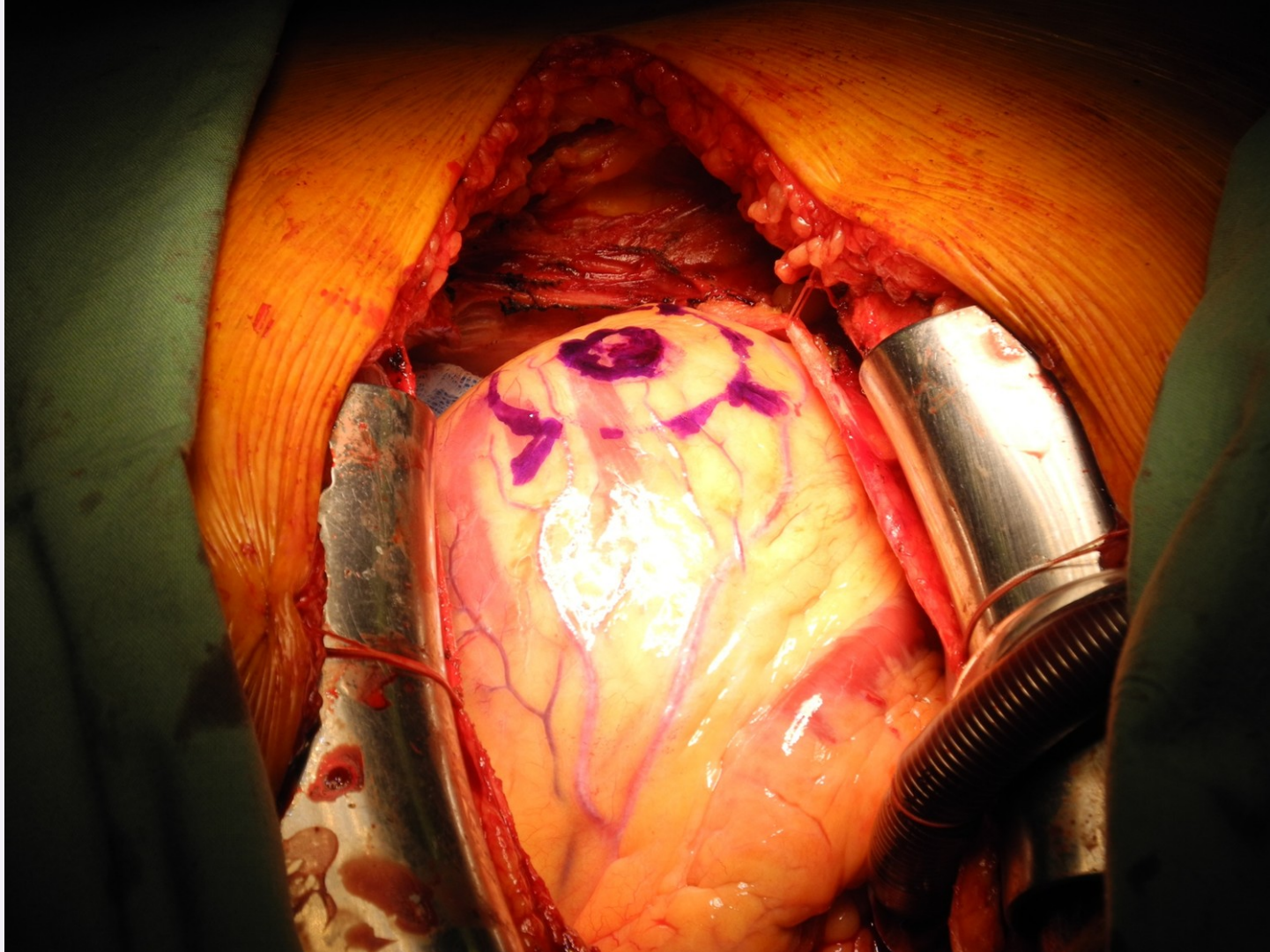


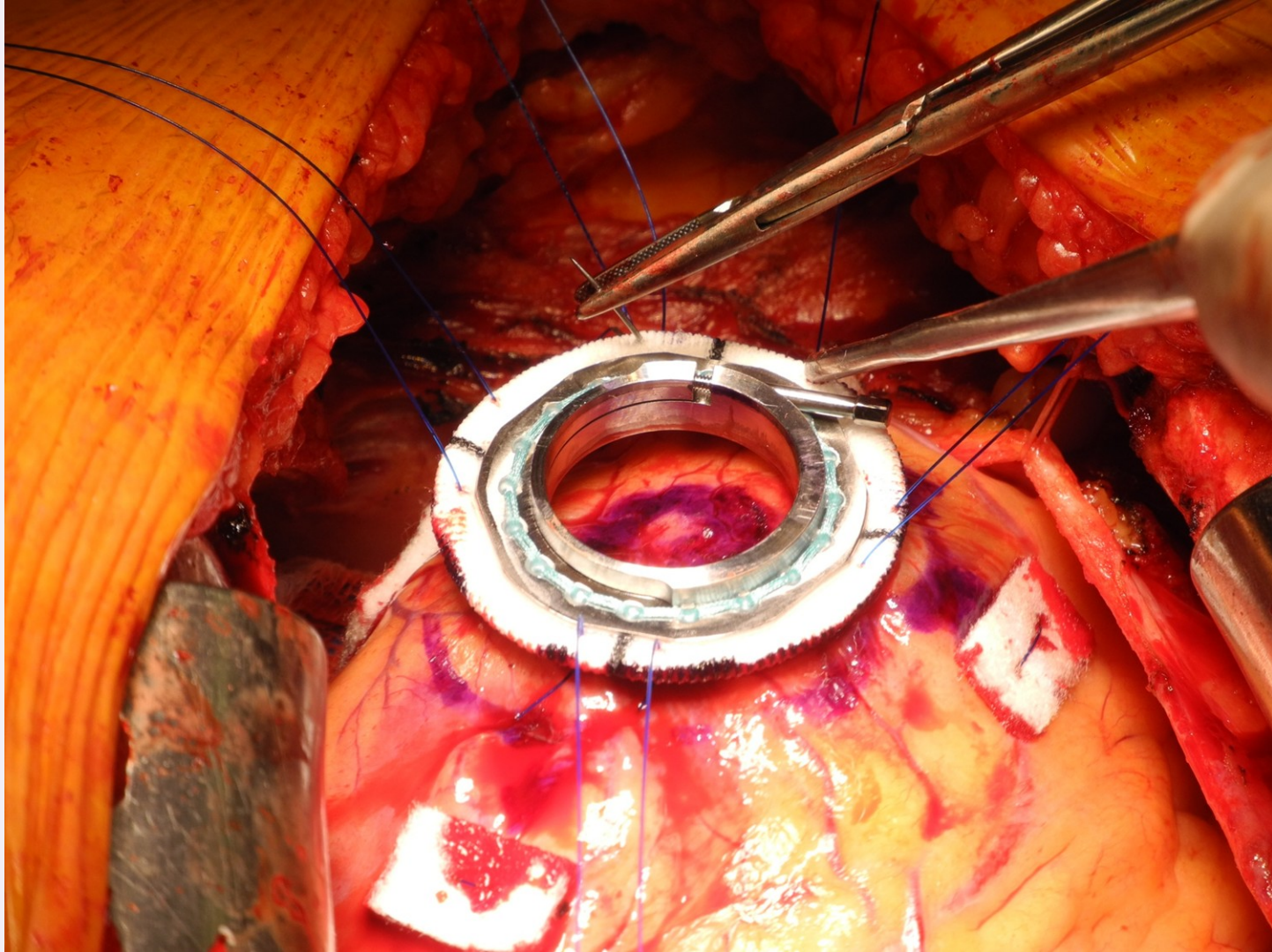
MCS – HeartWare HVAD

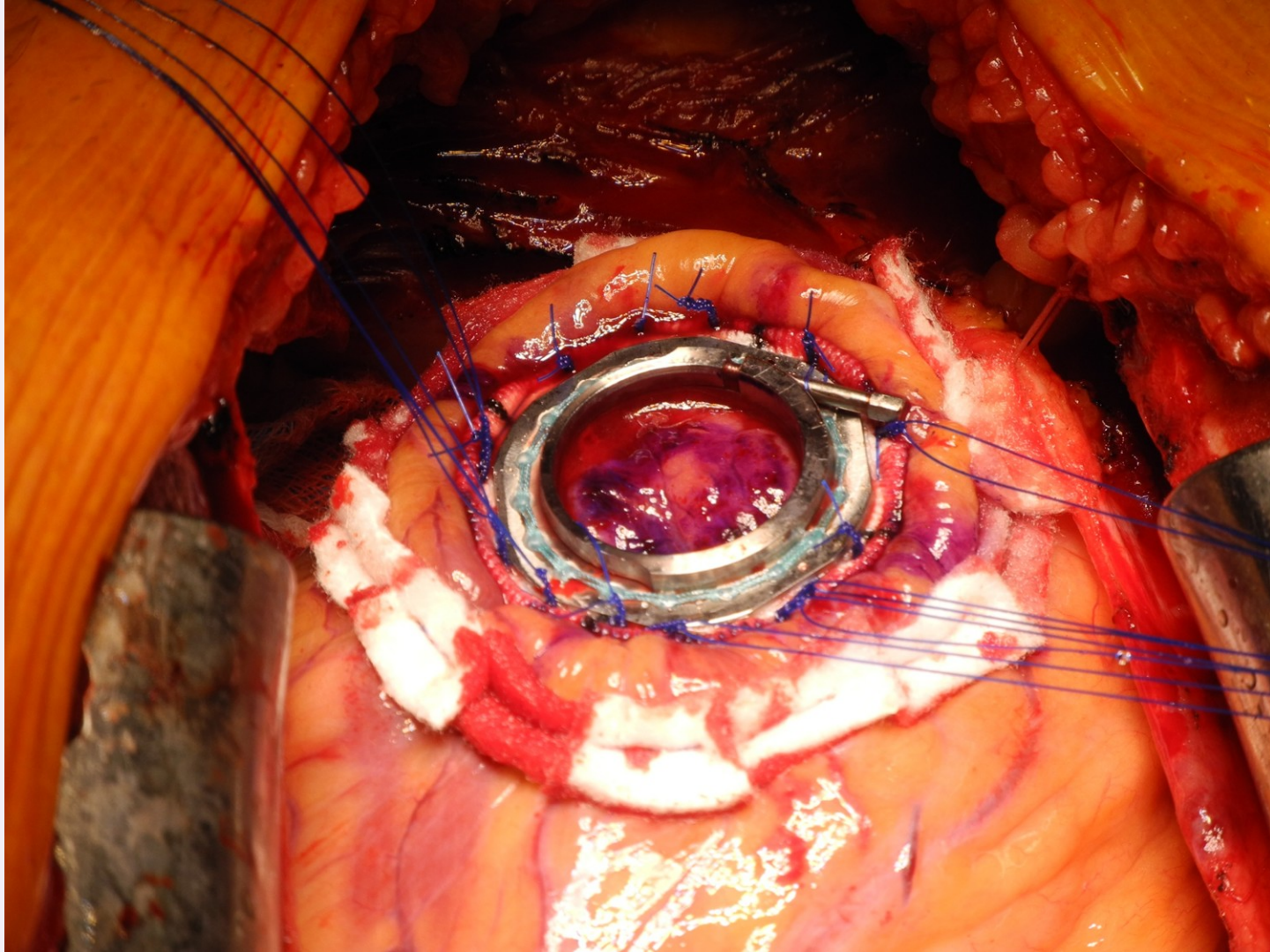


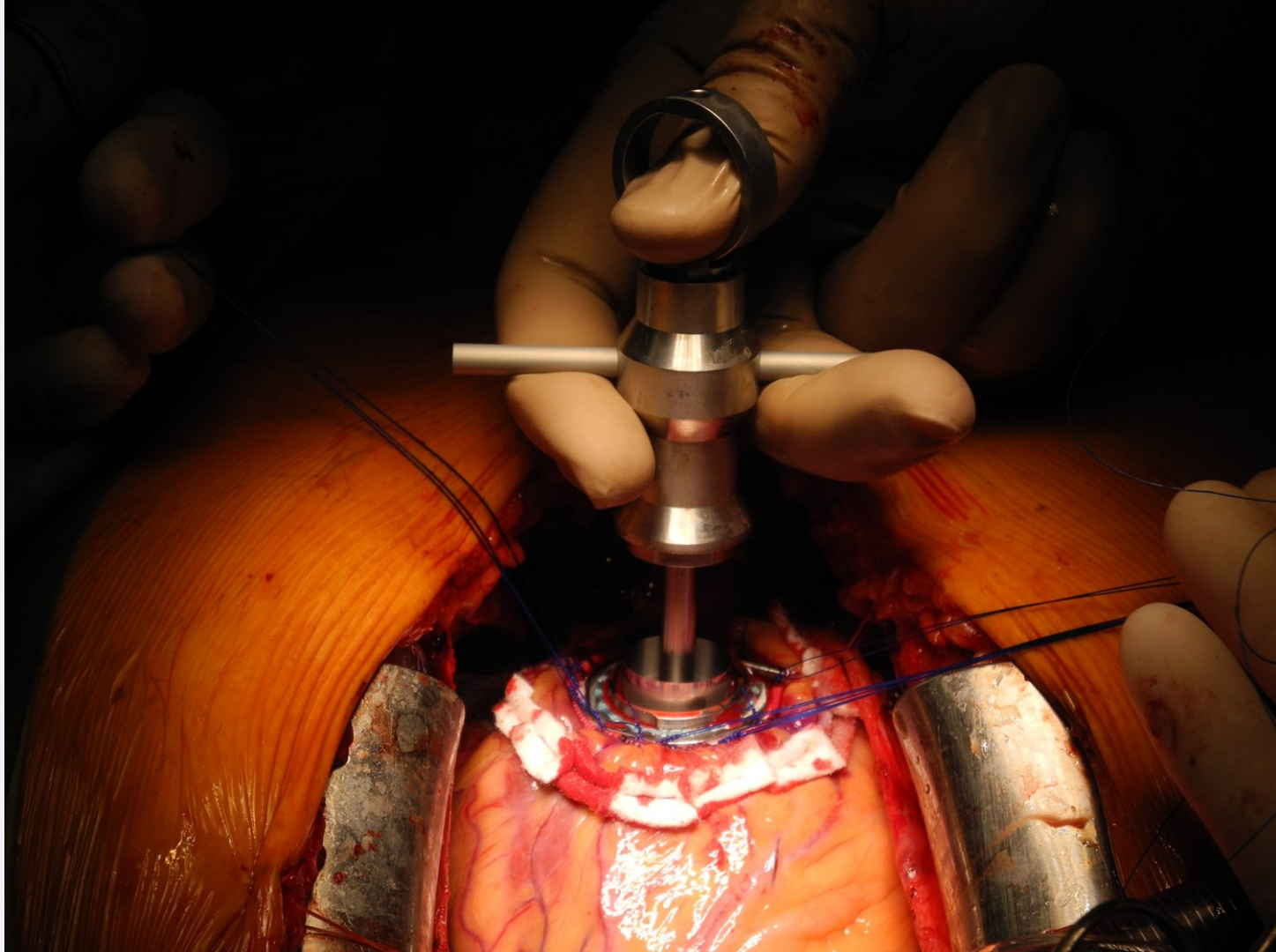


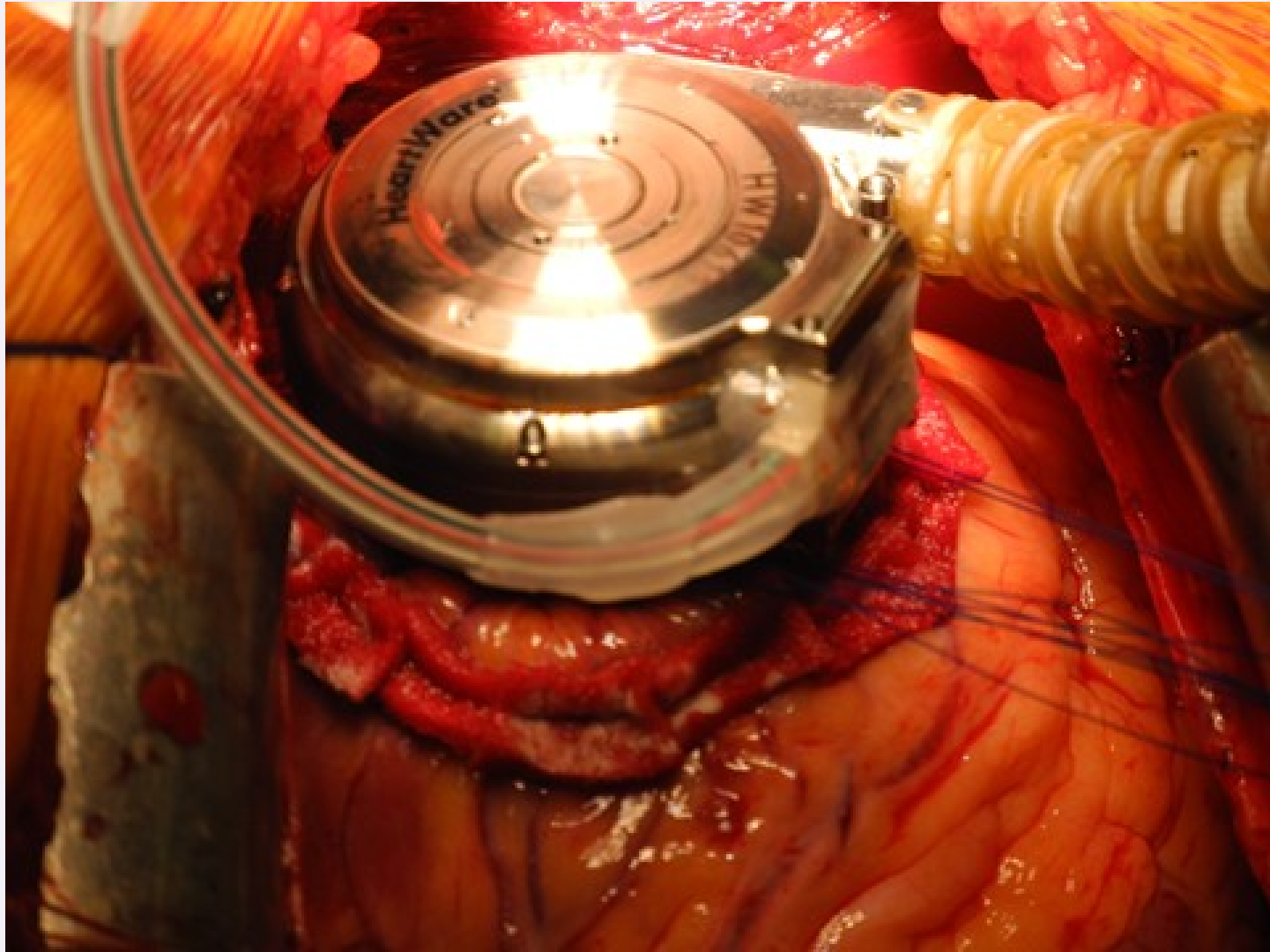


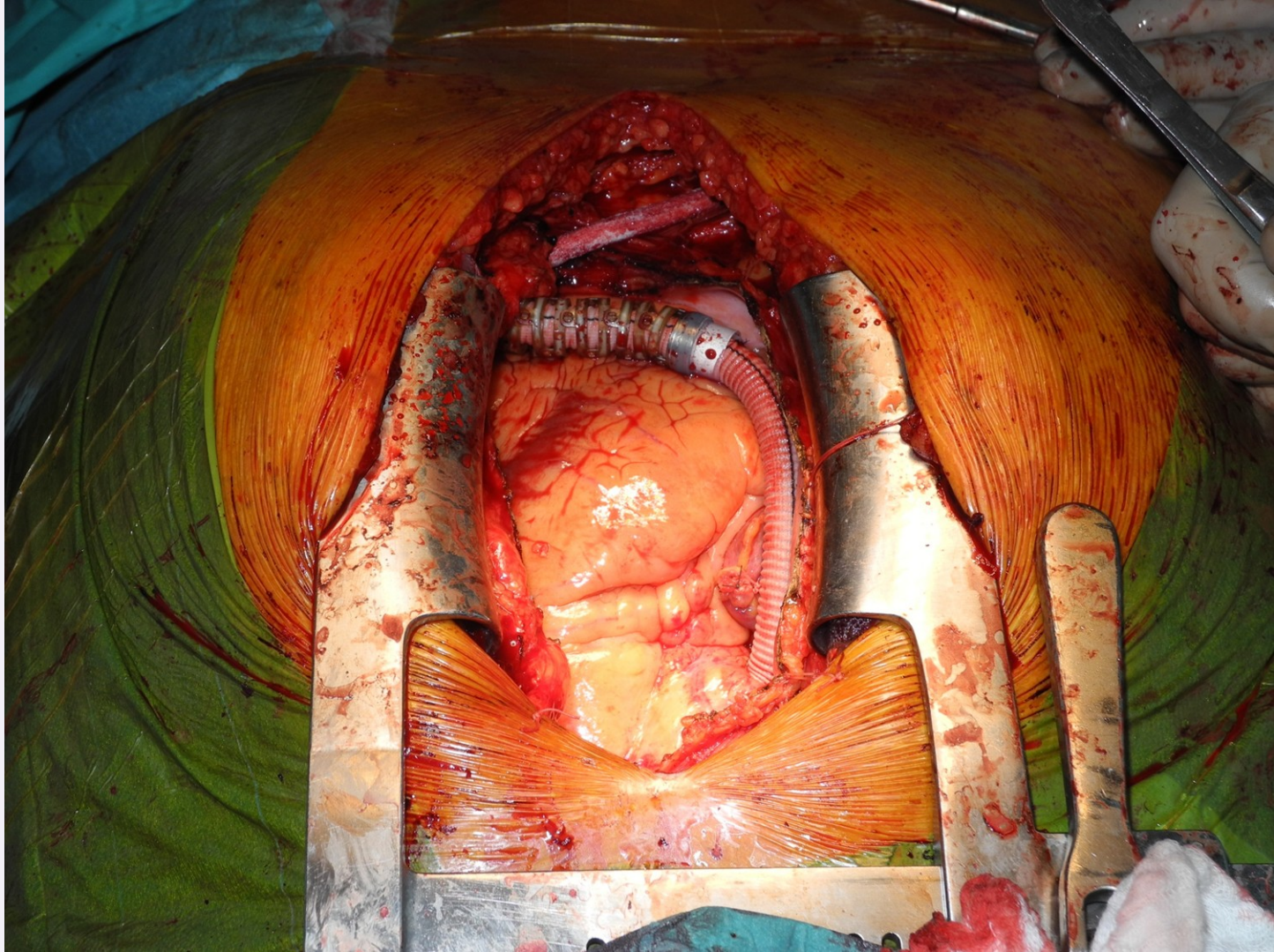

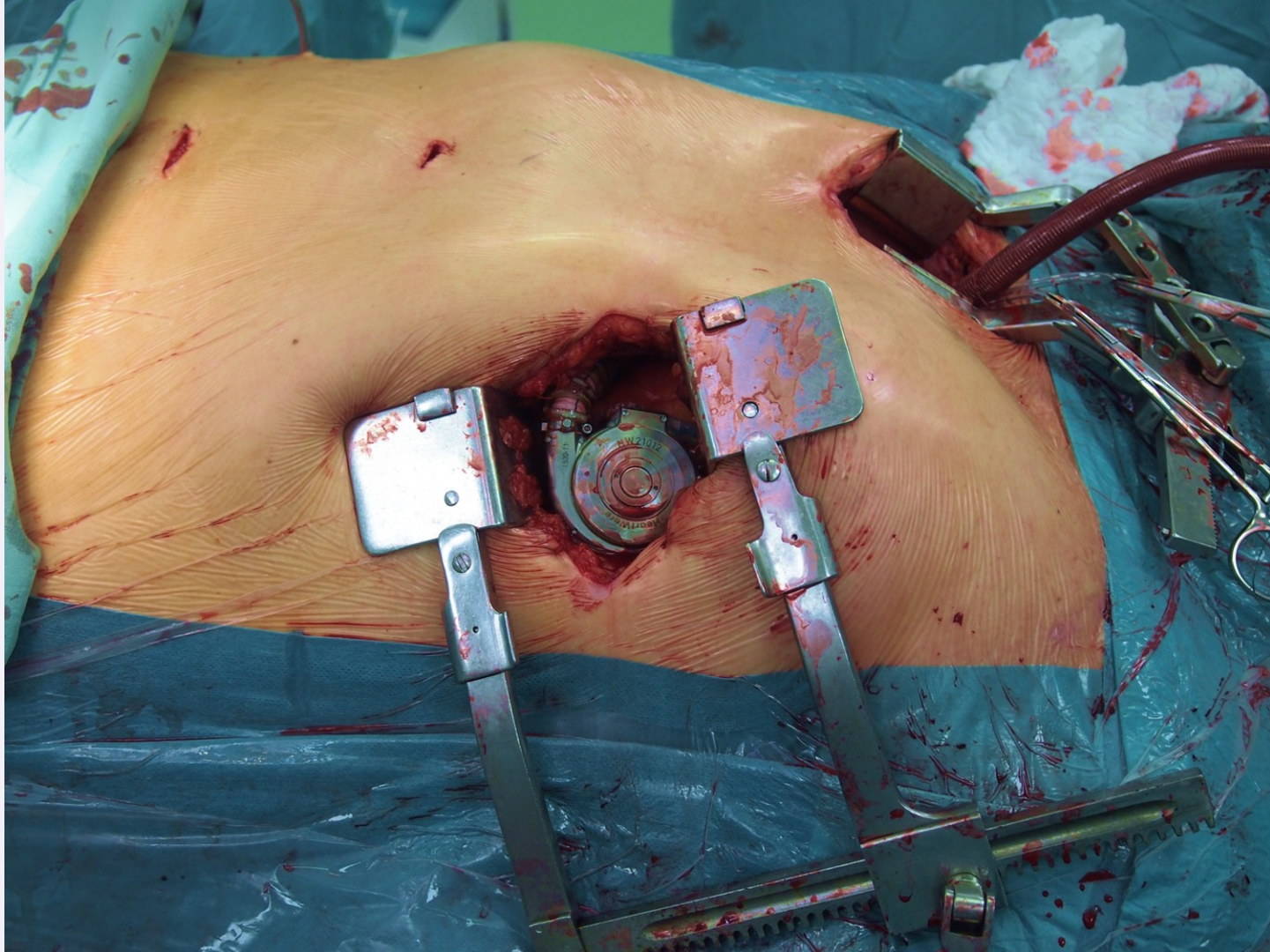


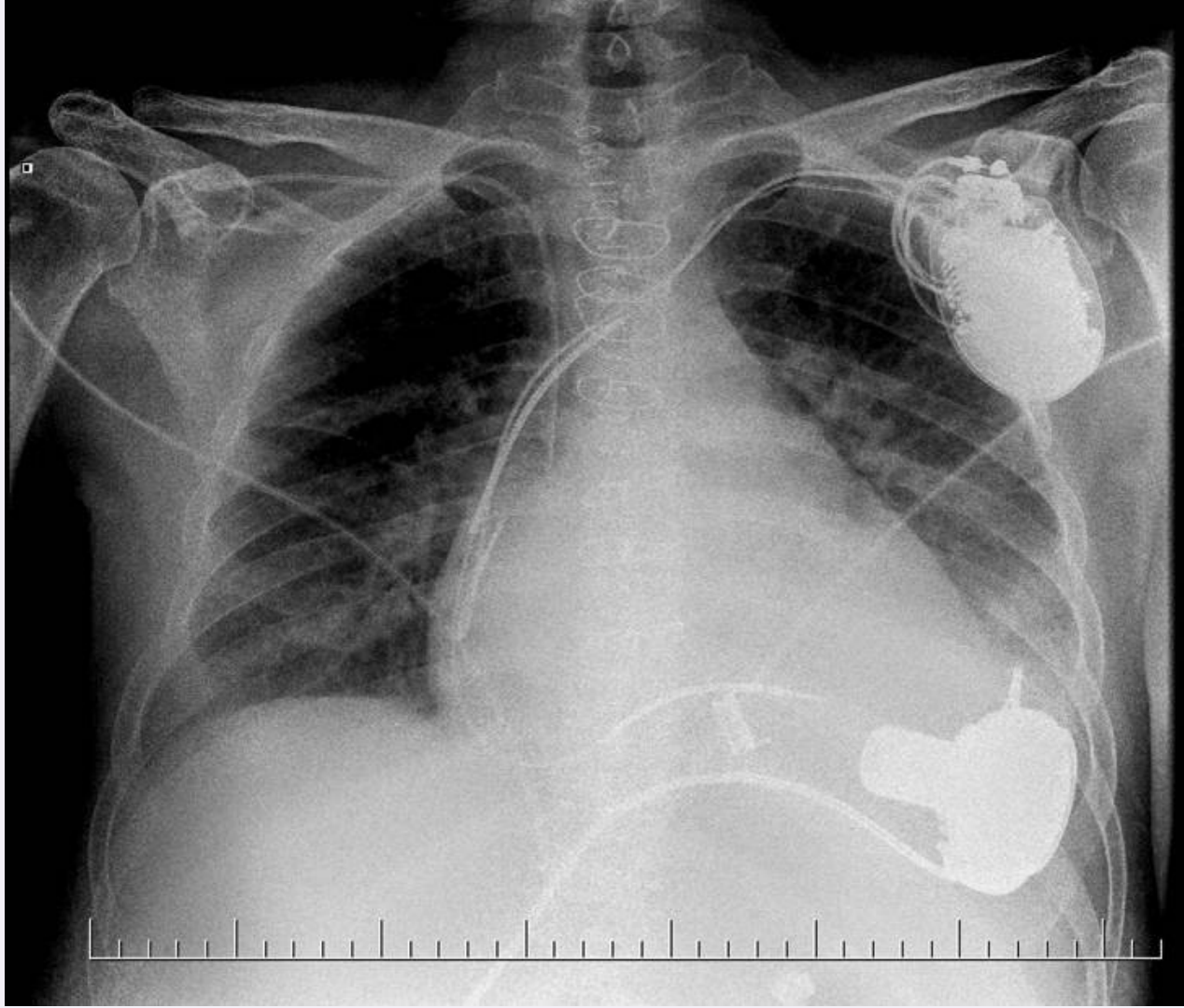




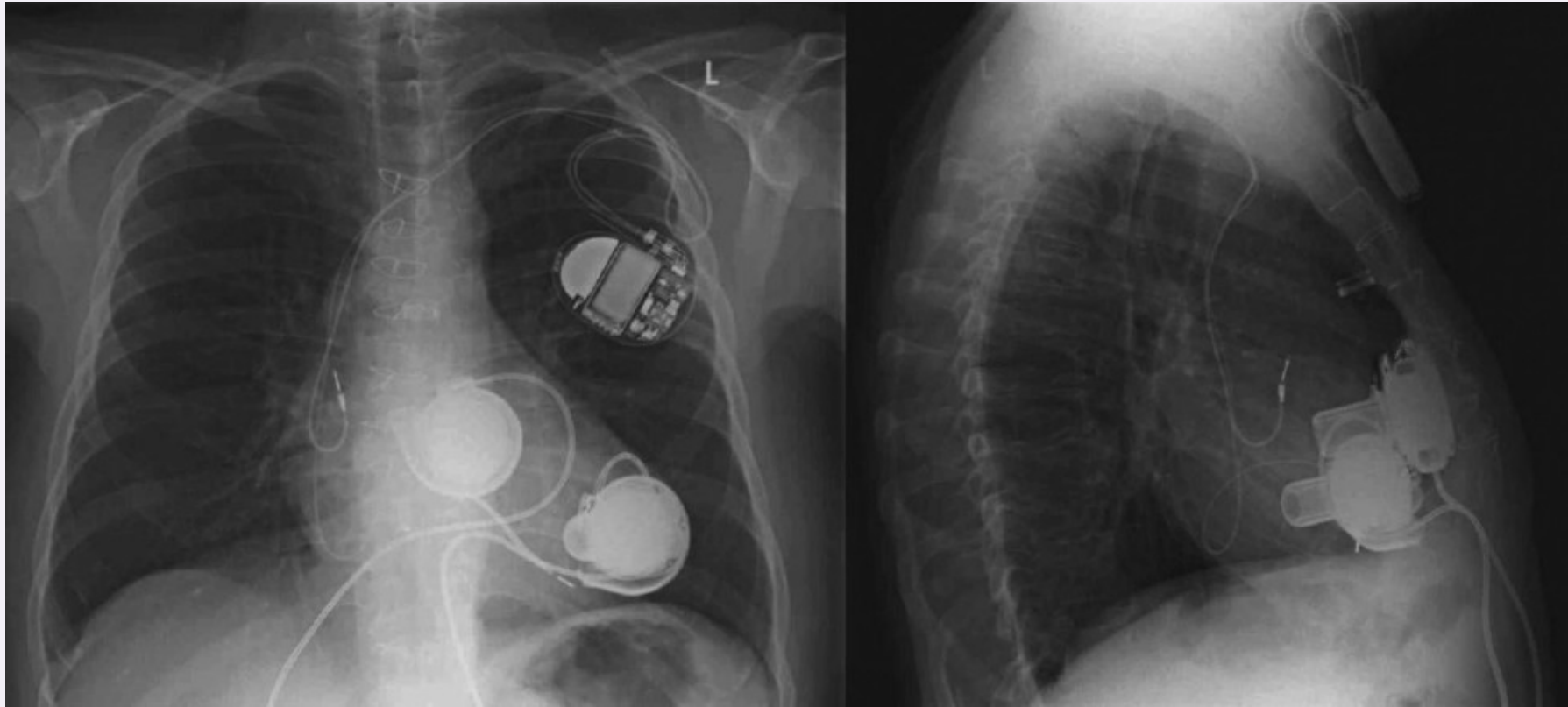








MCS – 2x LVAD as BiVAD


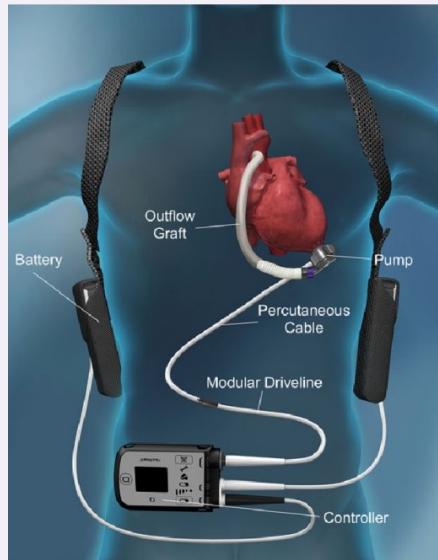


CKTCH

Center of Cardiovascular
Surgery & Transplantation

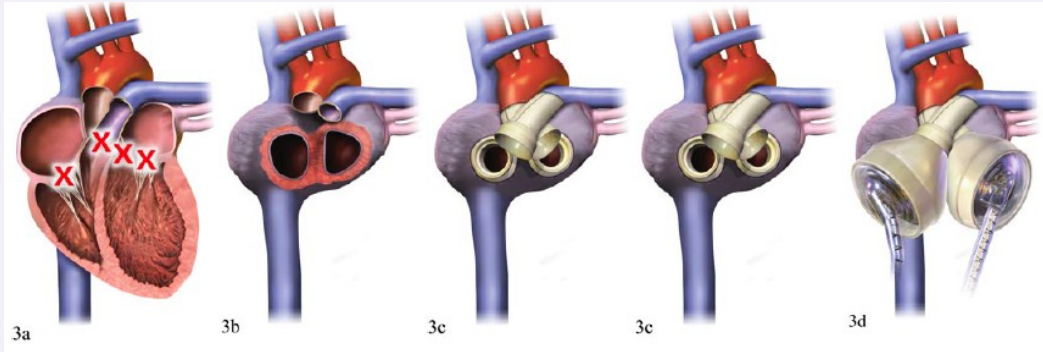
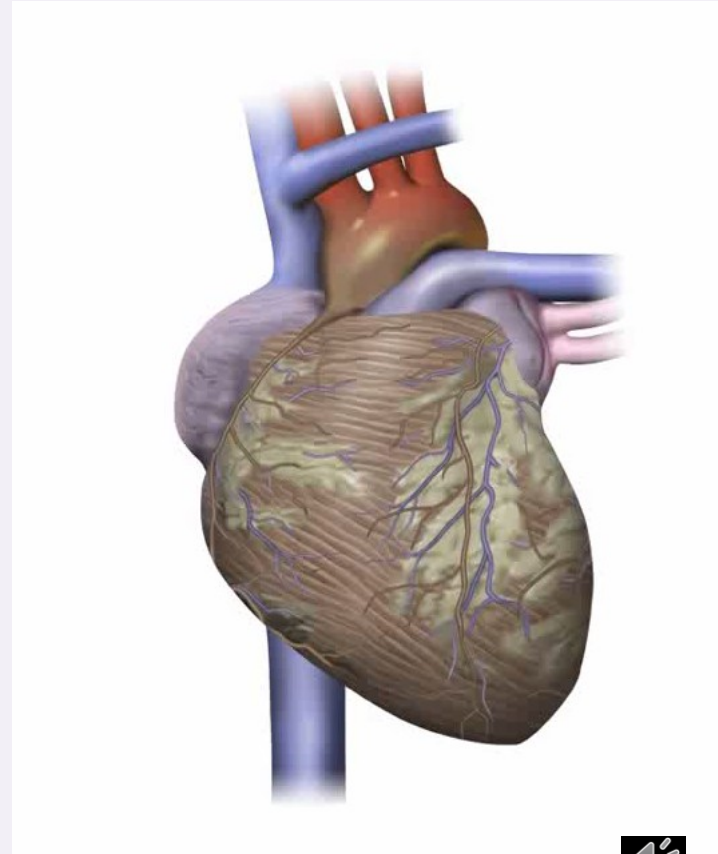


MCS – HEARTMATE 3



Total artificial heart - Syncardia

- pneumatic pump – pulsatile flow
- bridge-to-transplant
- noise



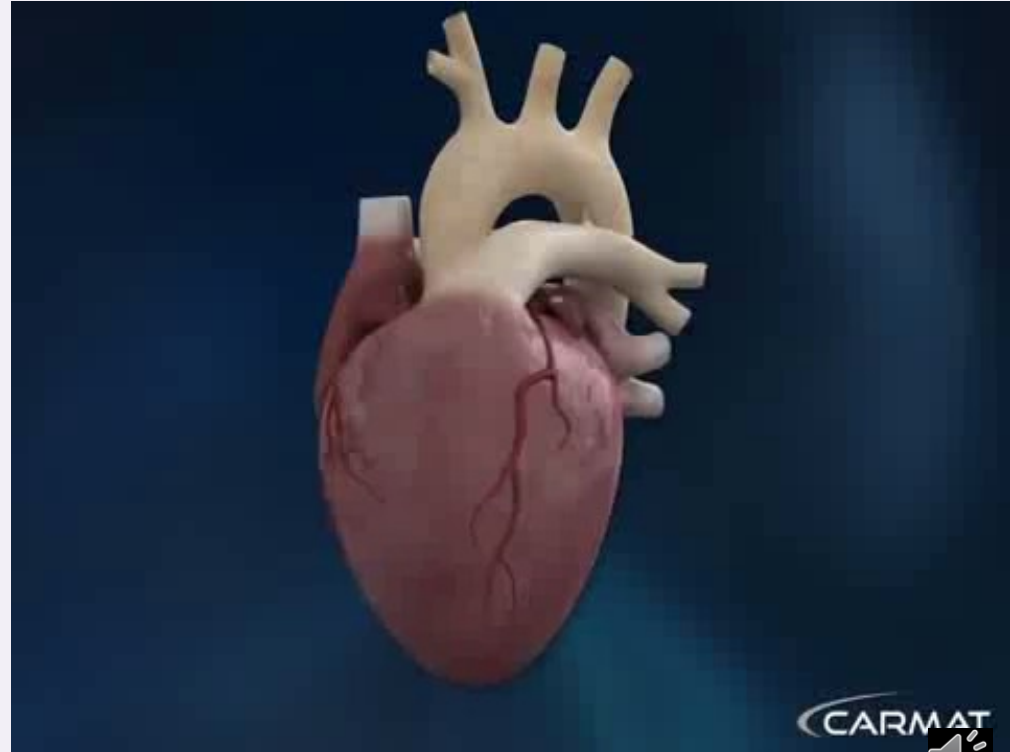

CKTCH

Center of Cardiovascular
Surgery & Transplantation



Total artificial heart - Carmat

- electrohydraulic pump, biological valves, membranes - bovine pericardium
- pulsatile flow, autoregulation



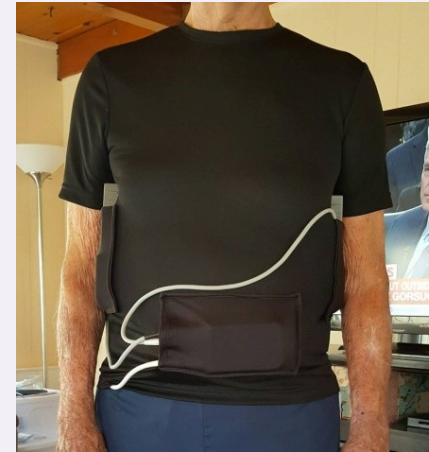
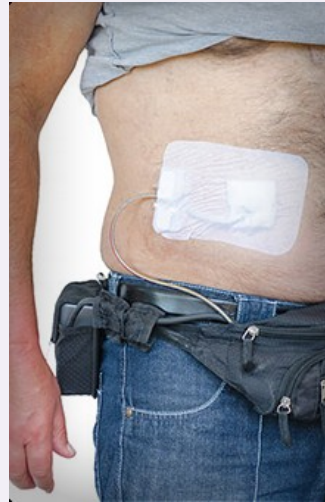MCS - future

- miniaturization???
- external components
- wireless
- telemonitoring
- no anticoagulation


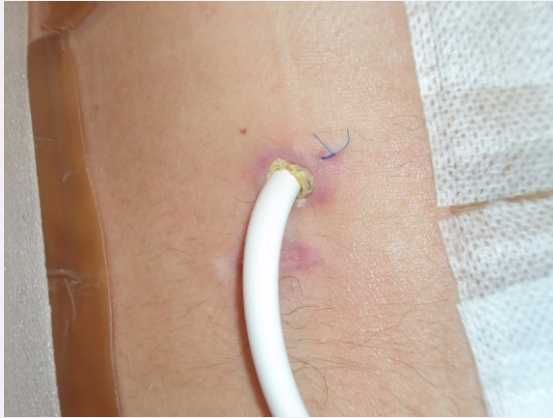
	HVAD™	MVAD™	IV-VAD™
Procedure	Surgical	Minimally Invasive	Catheter Delivery System
Flow	10 L/min	10 L/min	3 L/min
Patient Class	Late Class IV	Class IV	Class III / Early Class IV
Treatable Pop.	100,000	350,000	1,000,000



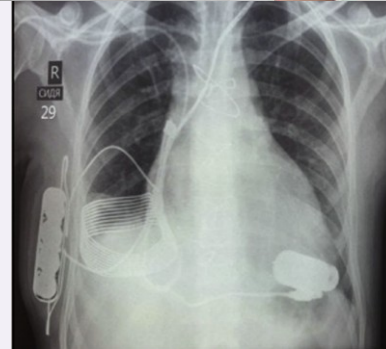
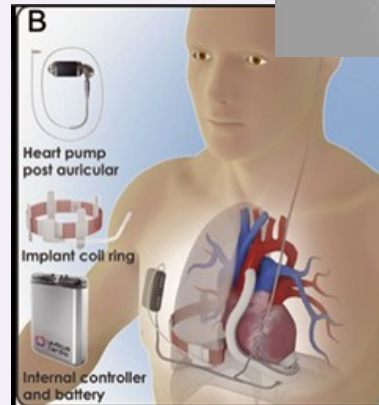
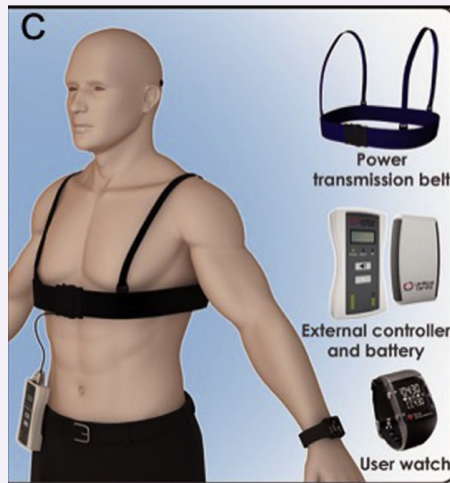
MCS – future - miniaturization



MCS – future - wireless



The FIV

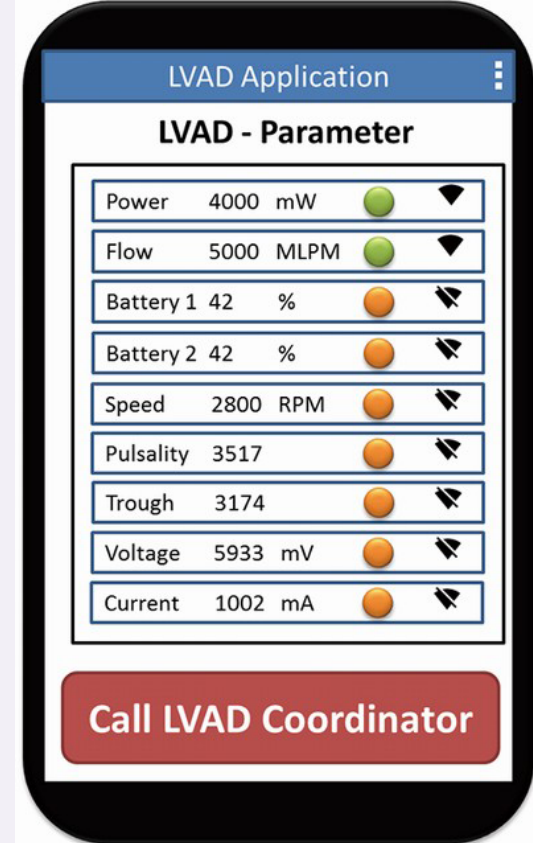


CKTCH

Center of Cardiovascular
Surgery & Transplantation



MCS – future - telemonitoring



MCS – future – no anticoagulation

Evaluation of low-intensity anti-coagulation with a fully magnetically levitated centrifugal-flow circulatory pump—the MAGENTUM 1 study

Ivan Netuka, MD, PhD^{a,*}, Peter Ivák, MD, PhD^{a,b}, Zuzana Tučanová, MD^a, Stanislav Gregor, PharmD^c, Ondrej Szárszoi, MD, PhD^a, Poornima Sood, MD^d, Daniel Crandall, PhD^d, Jessica Rimsans, PharmD, BCPS^e, Jean Marie Connors, MD^f, Mandeeep R. Mehra, MD^g

after 6 weeks - ↓ INR 1,5-1,9

n = 15

after 6 months

- no stroke, no pump thrombosis

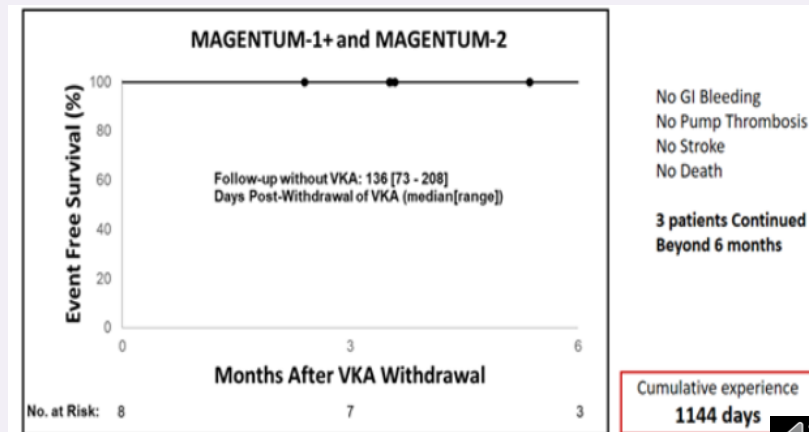
- 1x GI bleeding

A Trial of Complete Withdrawal of Anticoagulation Therapy in the Heartmate 3 Pump

I. Netuka^{1,*}, P. Ivák¹, Z. Tucanova¹, S. Gregor¹, O. Szarszoi¹, J. Rimsans², J. Connors², D. Crandall³, P. Sood³, M. Mehra²

from MAGENTUM 1 study – n = 5

MAGENTUM 2 – after 6 months – complete withdrawal anticoagulation therapy





Petr Fila
petr.fila@cktch.cz



CKTCH

Center of Cardiovascular
Surgery & Transplantation

