

Practice no. 6 – Introduction to practical histology (deadline March 29, 2020)

1. Explain the terms: orthochromatic, metachromatic, chromophilic, chromophobic, neutrophilic, basophilic, eosinophilic, acidophilic, trichrome.

Draw a memo that will help you to distinguish basophilic and eosinophilic structures. You can share the memos on [Padlet](#).

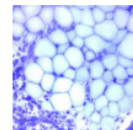


2. What is the difference between routine and special stains?

3. Using [Atlas of histology](#) find examples of the following types of routine staining and draw the appropriate details to your protocol:

- a) hematoxylin and eosin
- b) hematoxylin, eosin, saphron
- c) impregnation
- d) AZAN

Histologický atlas
Doporučený studijní materiál



Indicate, what structures are visualized.

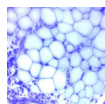
4. By means of any information resource identify, what does the abbreviation „PAS“ mean in histology techniques, and give an example of use.

5. What do the Congo Red and Oil Red visualize?

6. You are going to do the immunohistochemical staining for Ki-67 in a sample of tumor from a patient. What is the principle of the method, and why do the clinicians want to know that.

Study resources:

Histologický atlas
Doporučený studijní materiál



WWW

presentation from practice