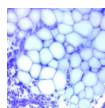


Practice no. 7 – Connective tissue proper (deadline Friday April 3, 2020)

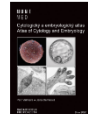1. What is the general composition of connective tissues?
2. Fibroblasts are dominant producers of extracellular matrix (ECM). How are their organelles adapted to this task?
3. Collagen type I is a fascinating protein with unique biomechanical properties. Describe and schematize its synthesis and arrangement into fibrils and fibers. What is the role of vitamin C in this process?
4. What histochemical methods can be used for collagen visualization? In what color is the collagen stain?
5. What is the structural and functional difference between collagen and elastic fibers?
6. What protein constitutes reticular fibers?
7. Draw the white adipose tissue and adipocytes. Where are the nucleus and other organelles of adipocytes localized? Why? What histochemical methods can be used for adipose tissue visualization? In what color is the adipose tissue stained?
8. Compare the composition and structure of loose and dense collagen connective tissue. Summarize the hallmarks into a table.
9. Secretory granules of mast cells contain among others histamine and heparin. Using any information resource determine, what happens to a tissue if mast cells release these substances. What is the stimulus for their release?
10. Reticular connective tissue is present in various organs that are structurally and functionally very dissimilar, such as spleen, lymph node or intestine. What is the role of reticular connective tissue in these organs?
11. What is the difference between the reticular cell and reticulocyte?

Study resources:

Histologický atlas
Doporučený studijní materiál



Cytologický a embryologický atlas
Doporučený studijní materiál



Presentation from
practice