

Internal Medicine (Physical Examination)

Examination of the Abdomen

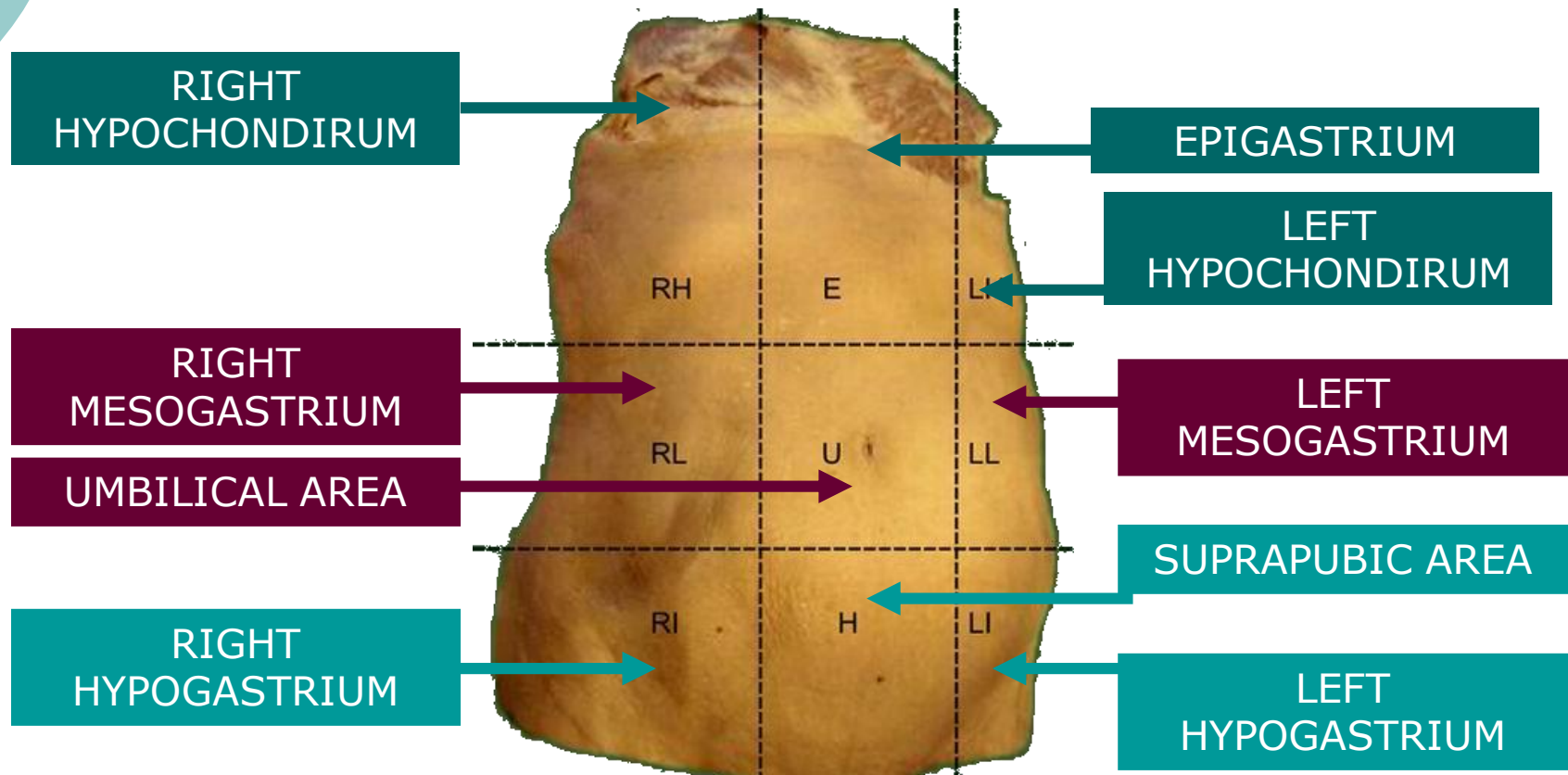
MUDr. Yvona Pospíšilová, IHOK FN Brno a LF MU

MUDr. Andrea Křivanová, Ph.D. IHOK, FN Brno

Examination of the Abdomen

- The lowest points of both costal margins and both anterior superior iliac spines, + midclavicular lines

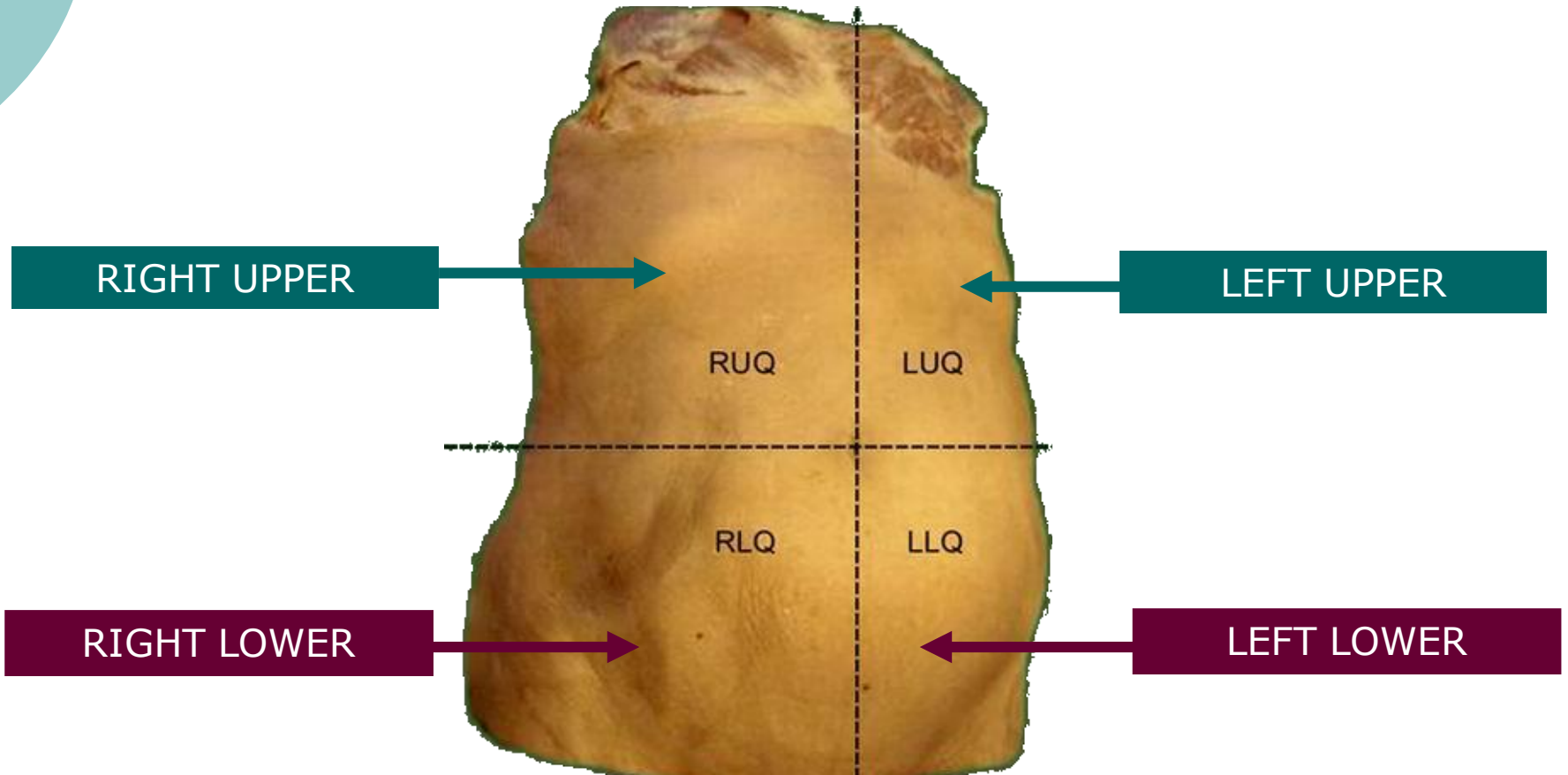
9 areas



Examination of the Abdomen

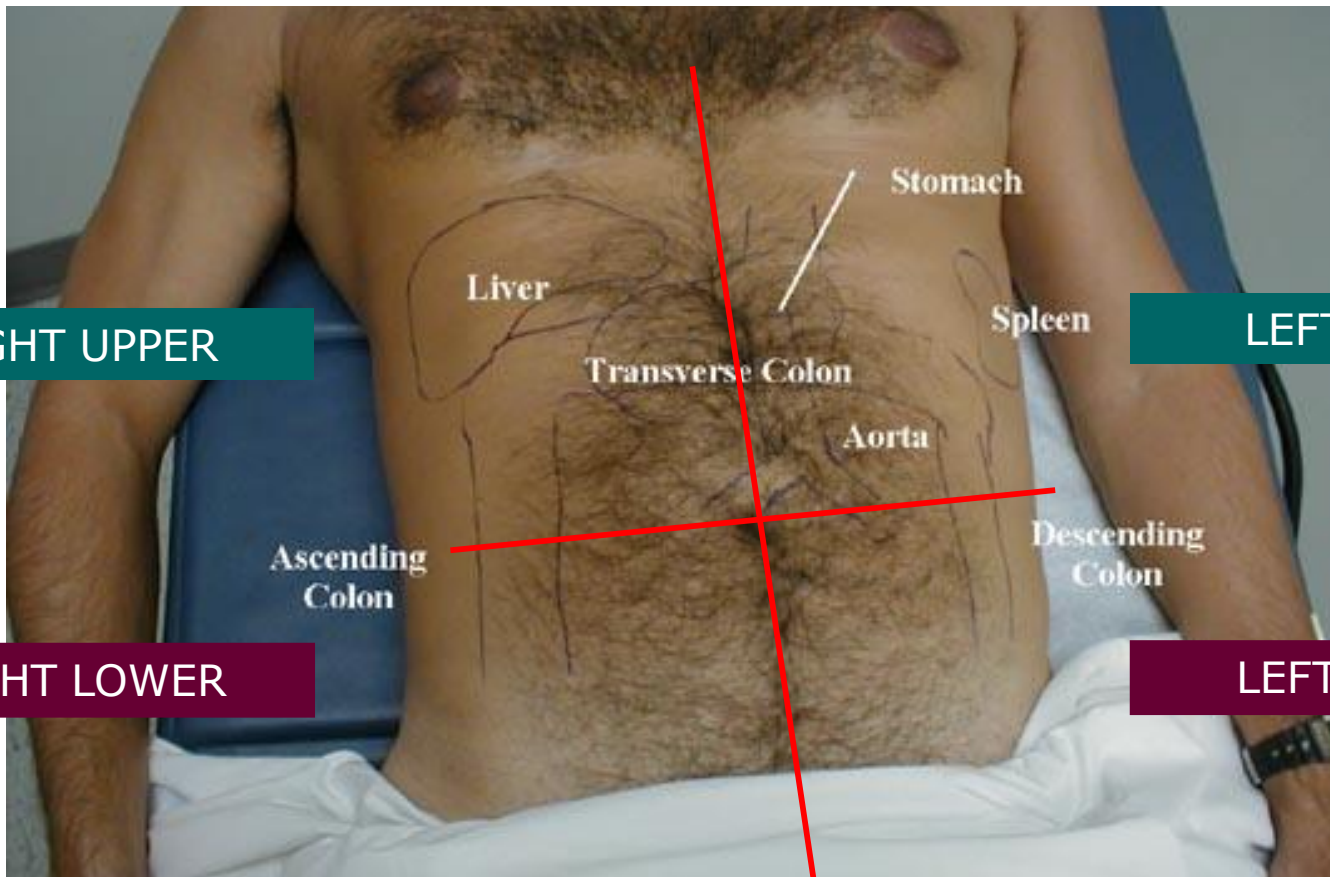
- Line between the xiphoid process and the pubic symphysis + line across umbilicus

4 QUADRANTS



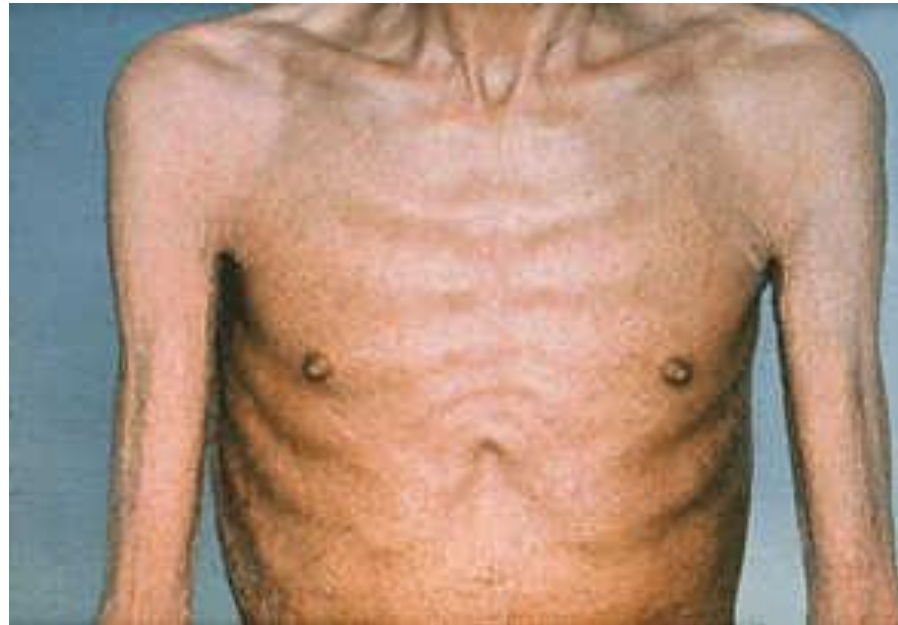Examination of the Abdomen

4 QUADRANTS



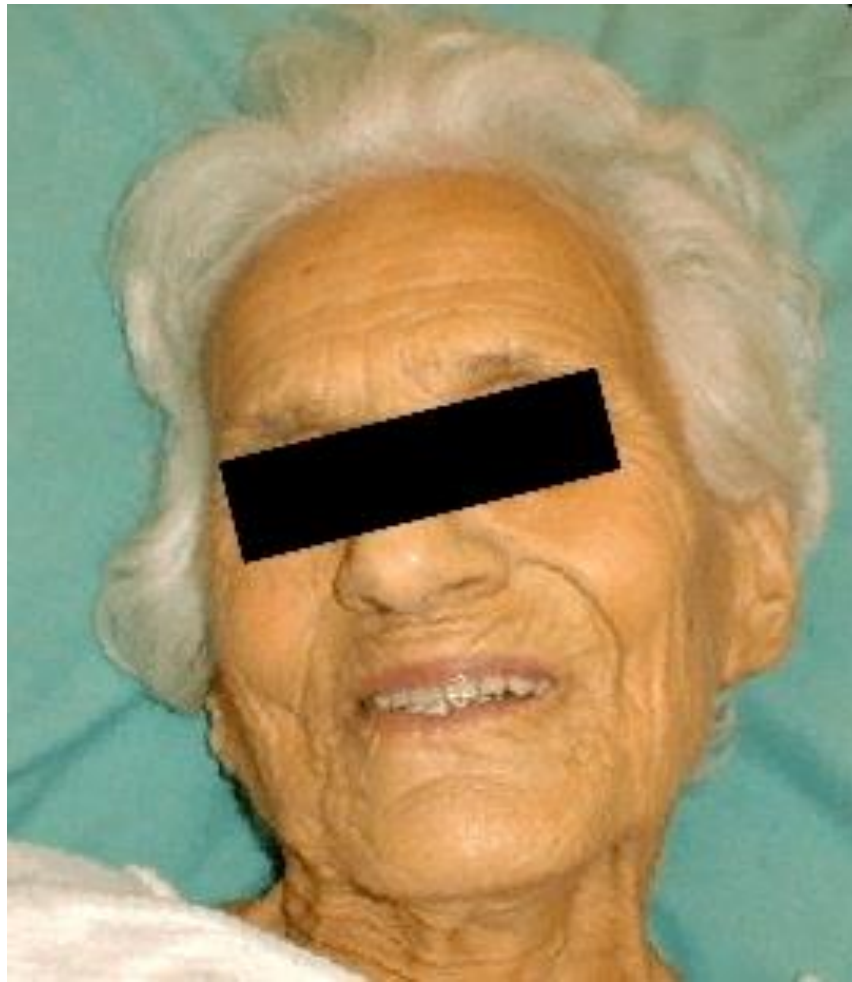Examination of the Abdomen - Inspection

- Kachexia



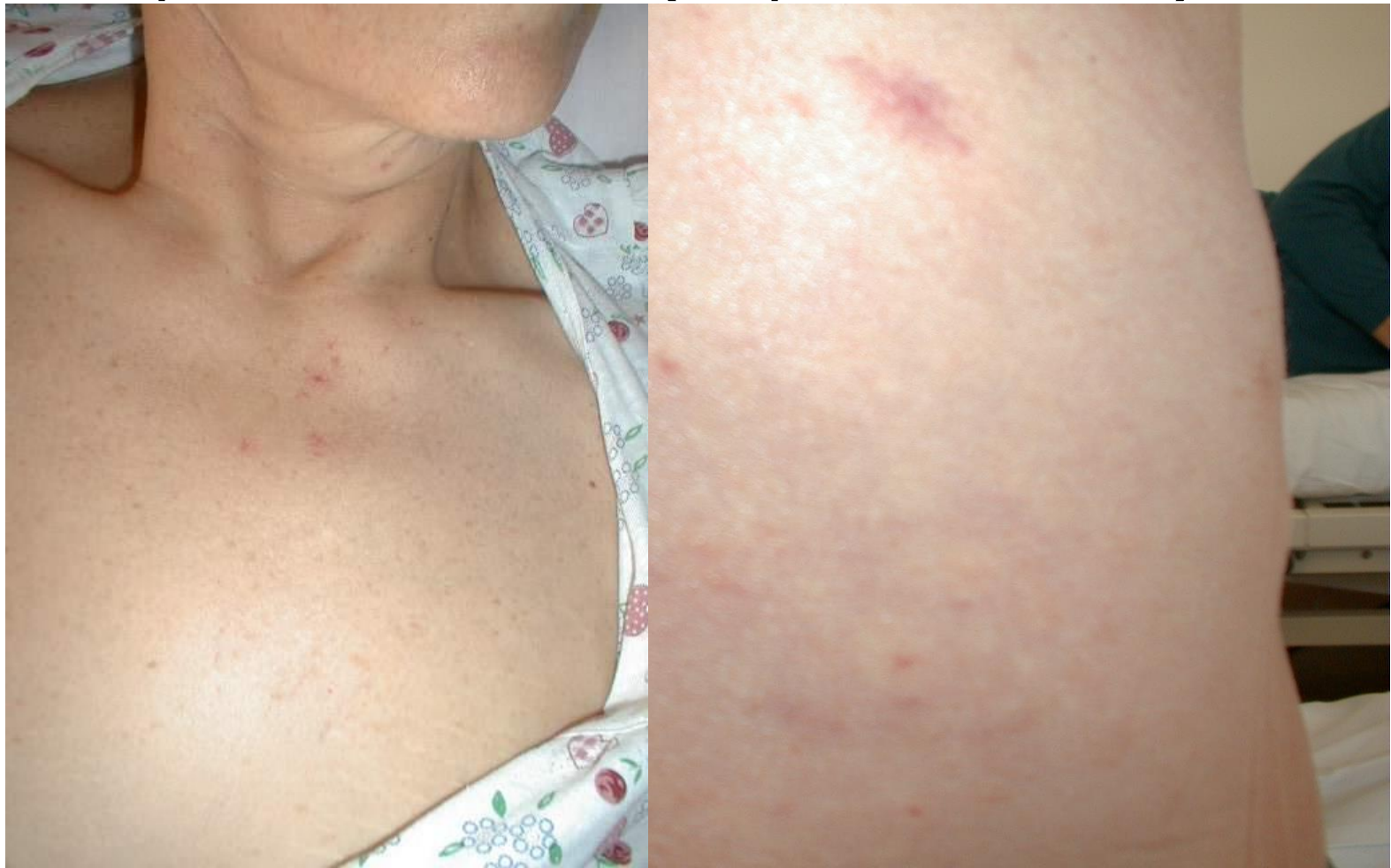Examination of the Abdomen - Inspection

- Icterus



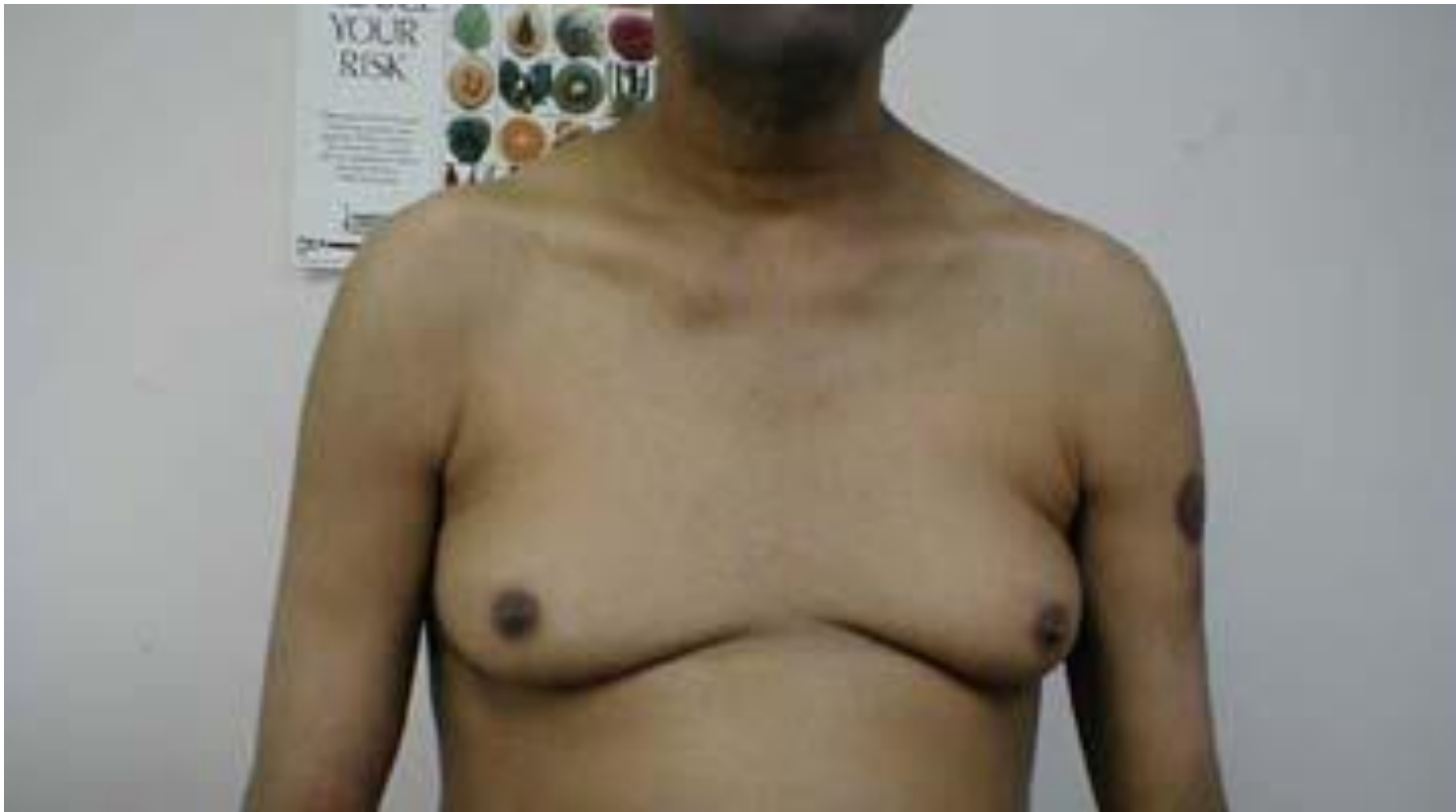Examination of the Abdomen - Inspection

- „Spider naevus“ (hepatic failure)



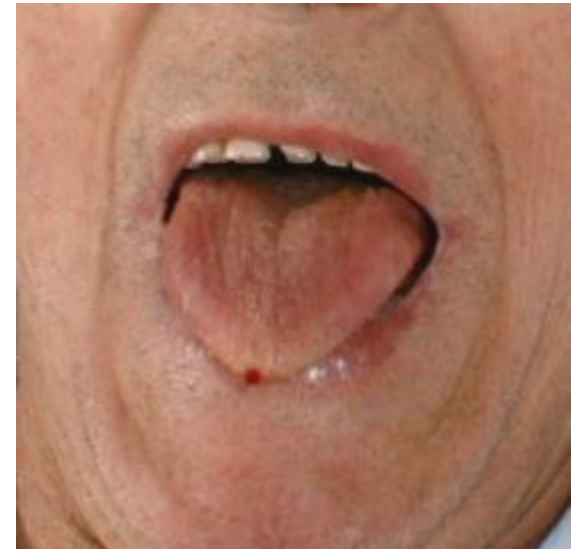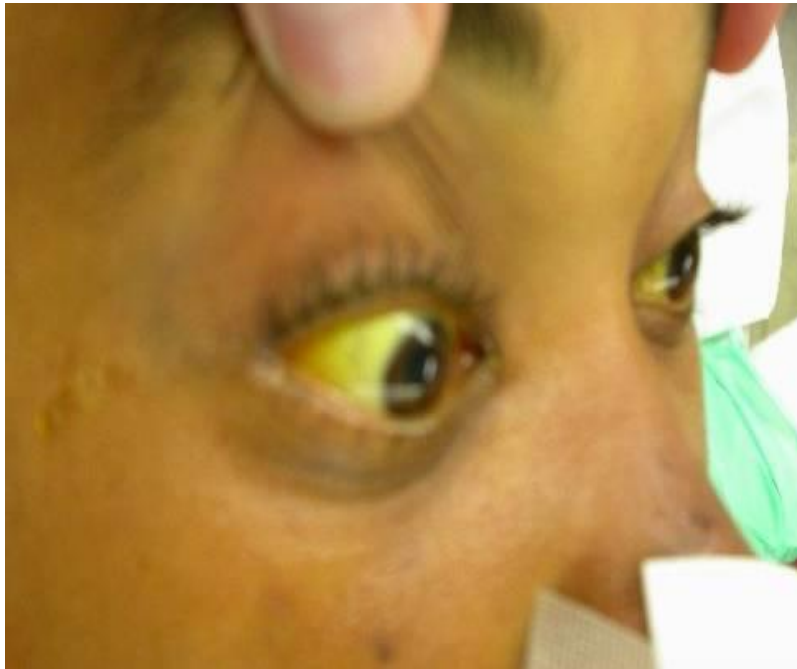Examination of the Abdomen - Inspection

- Gynecomasty – failure of the liver



Examination of the Abdomen - Inspection

- Icterus (jaundice), foetor ex ore, dehydration...(hepatic failure)

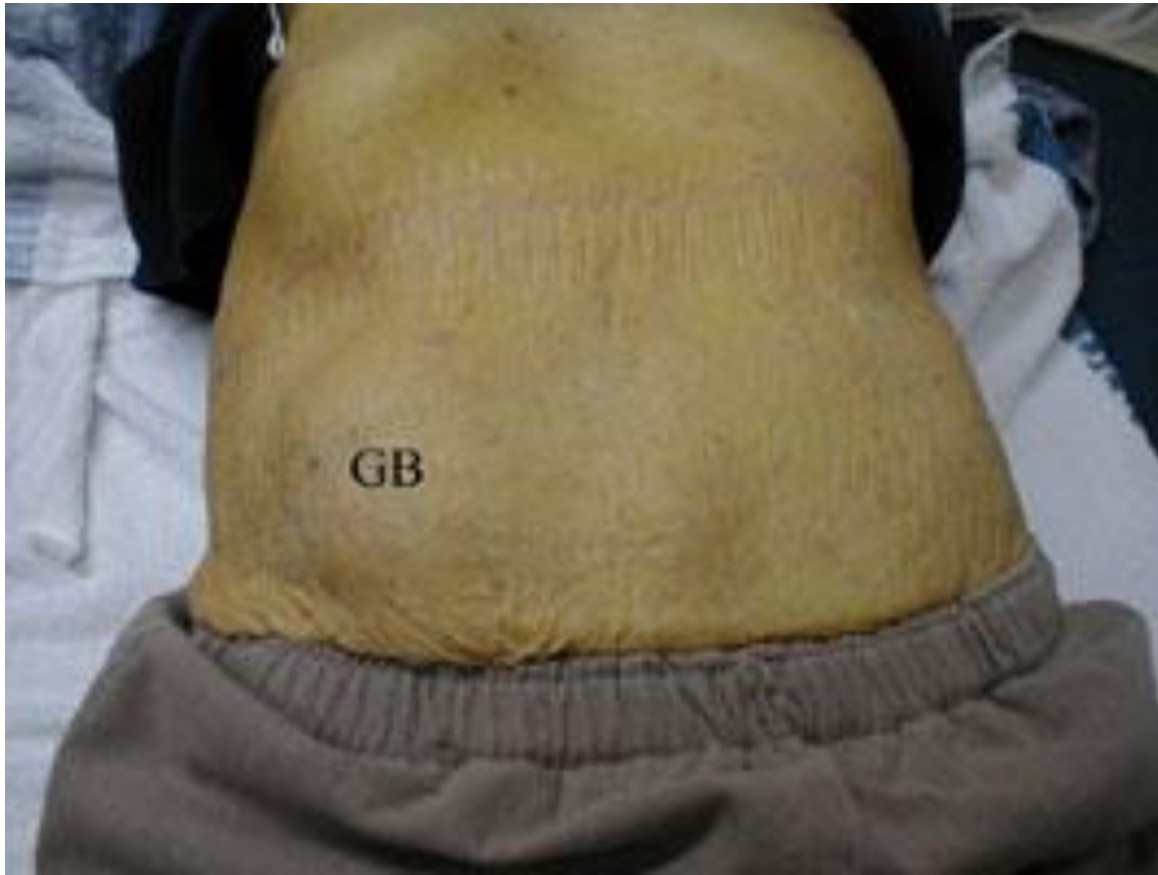


Examination of the Abdomen - Inspection

- Movements of of the abdominal wall during breathing, protrusion in some parts of abdomen, collateral venous circulation in obstruction portal system (caput medusae) etc....

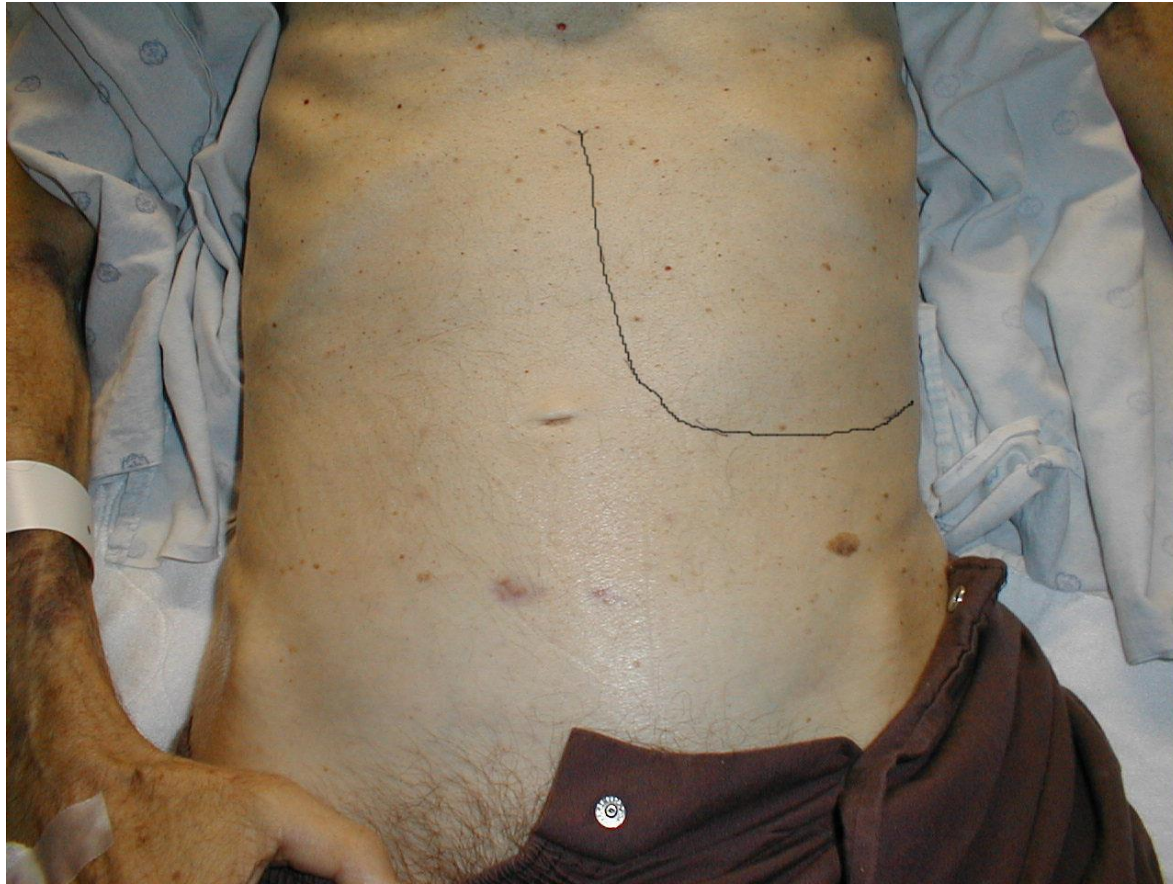
Examination of the Abdomen - Inspection

- Tumor of gallbladder



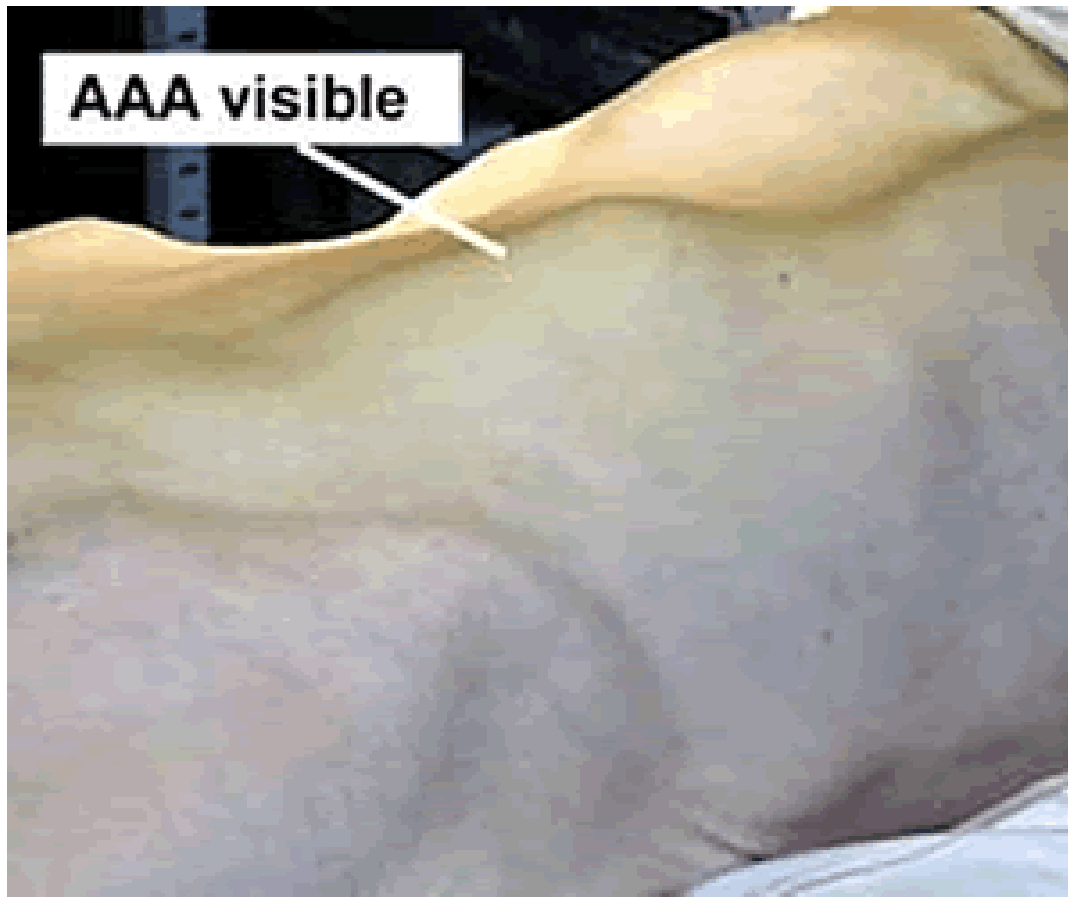
Examination of the Abdomen - Inspection

- Enlargement of the spleen



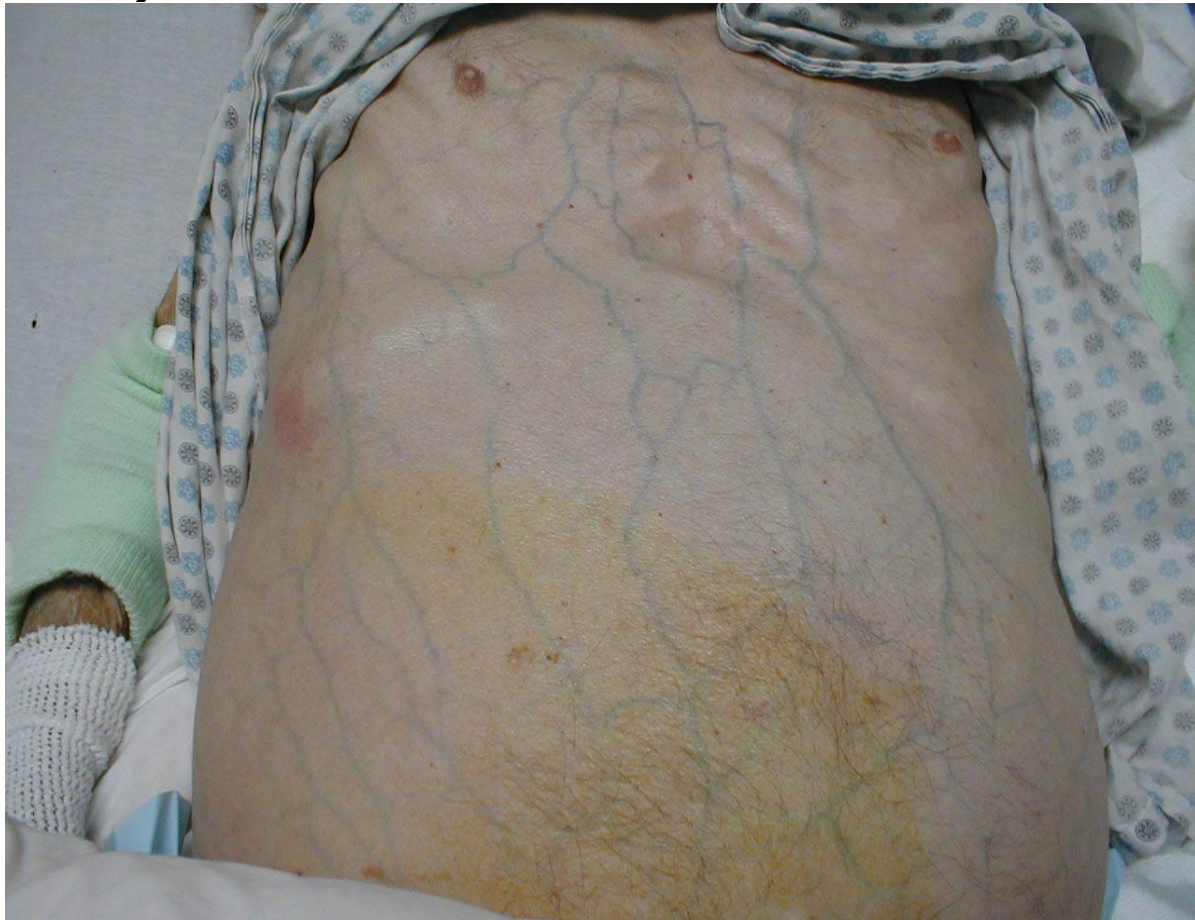Examination of the Abdomen - Inspection

- Aortic artery



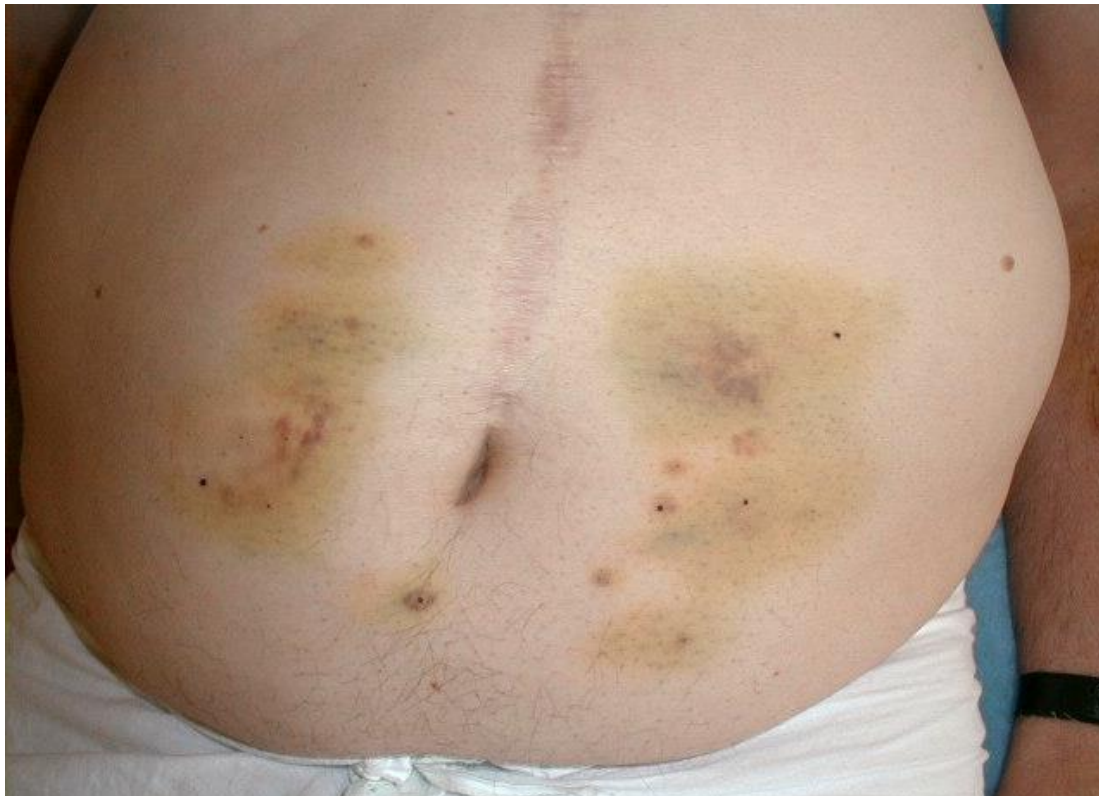Examination of the Abdomen - Inspection

- Collateral venous circulation (hepatic failure)



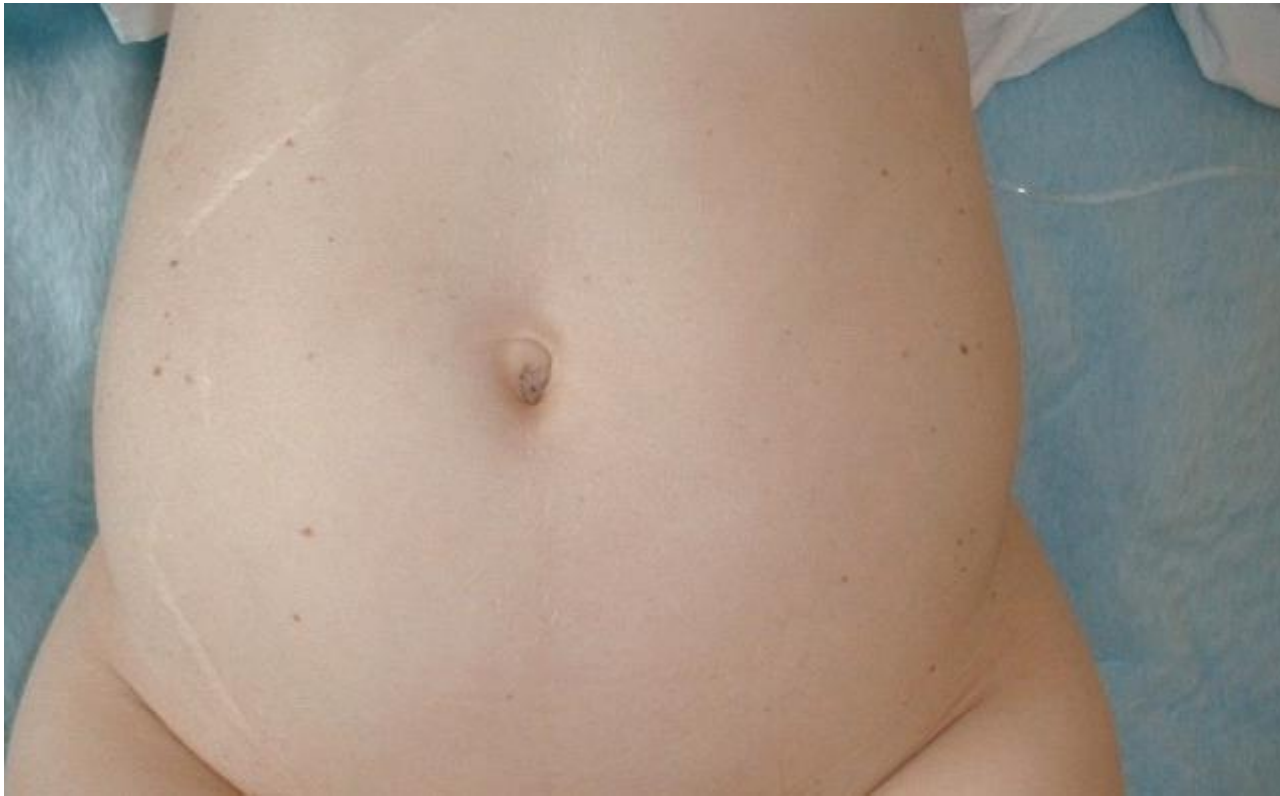Examination of the Abdomen - Inspection

- SCARS – scar following upper-mid-laparotomy



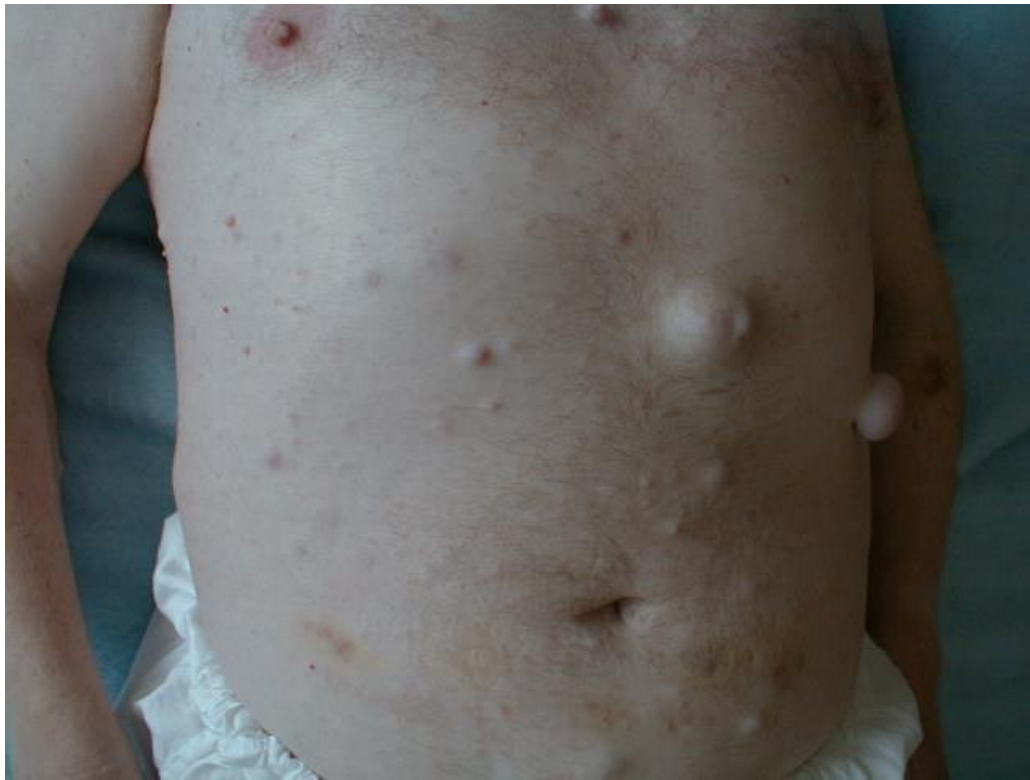Examination of the Abdomen - Inspection

- Scars – scar following gallbladder surgery and appendectomy

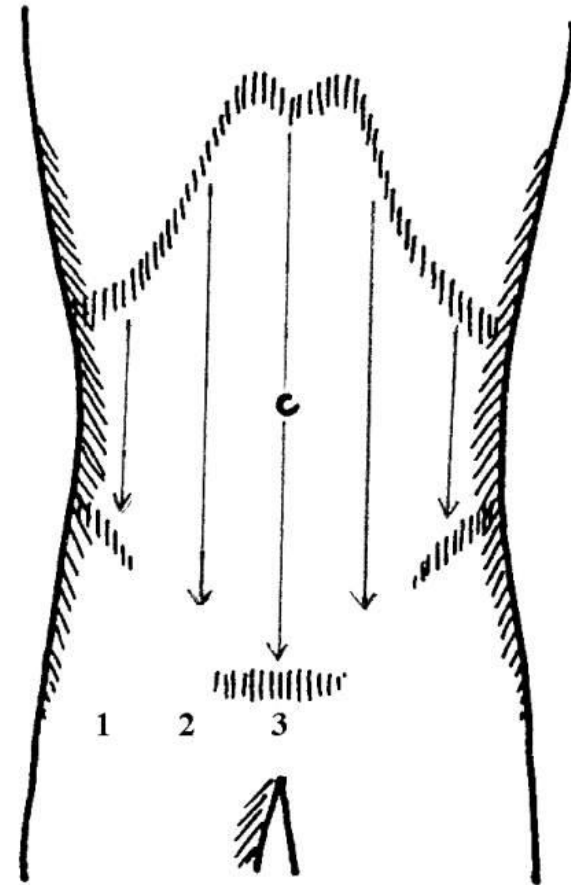
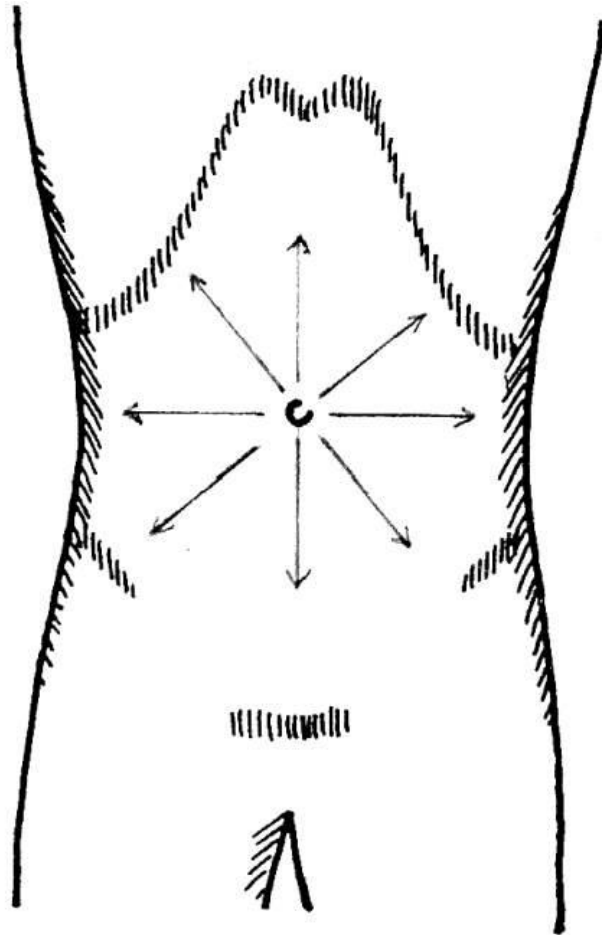


Examination of the Abdomen - Inspection

- Fibroma – benign skin tumors



Examination of the Abdomen - Inspection - Percussion



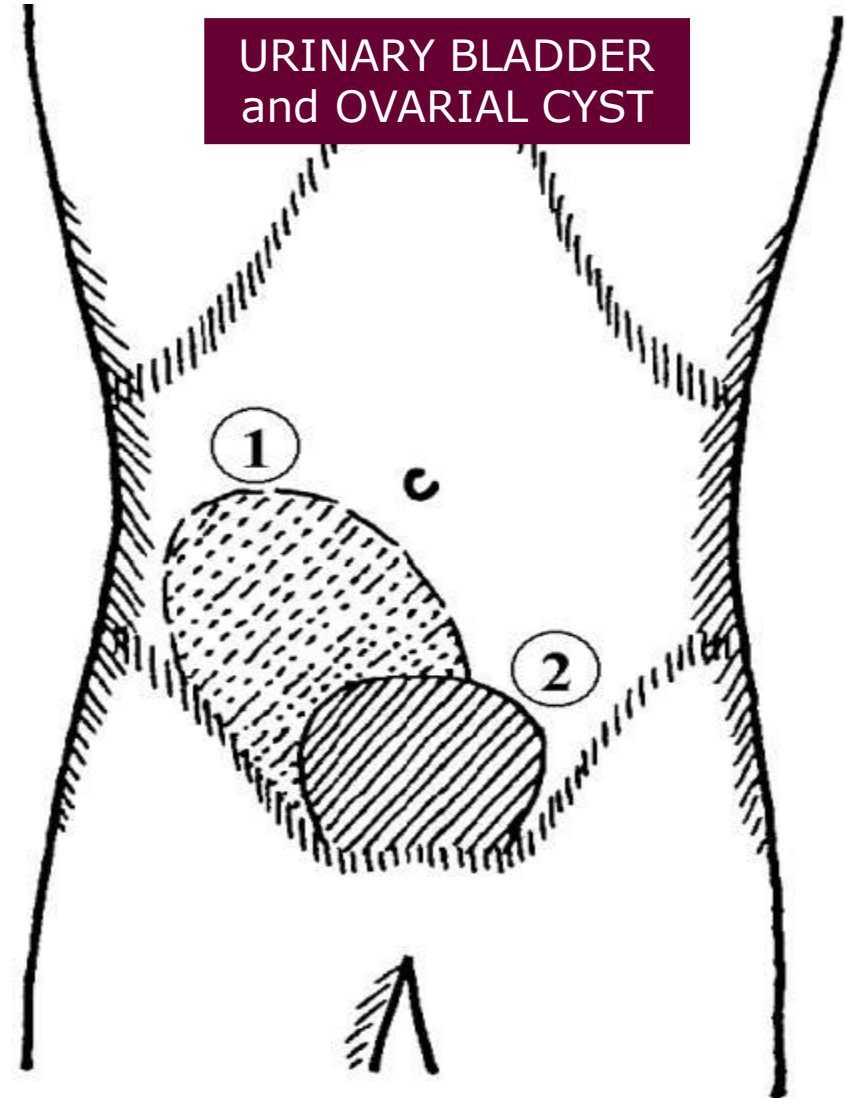
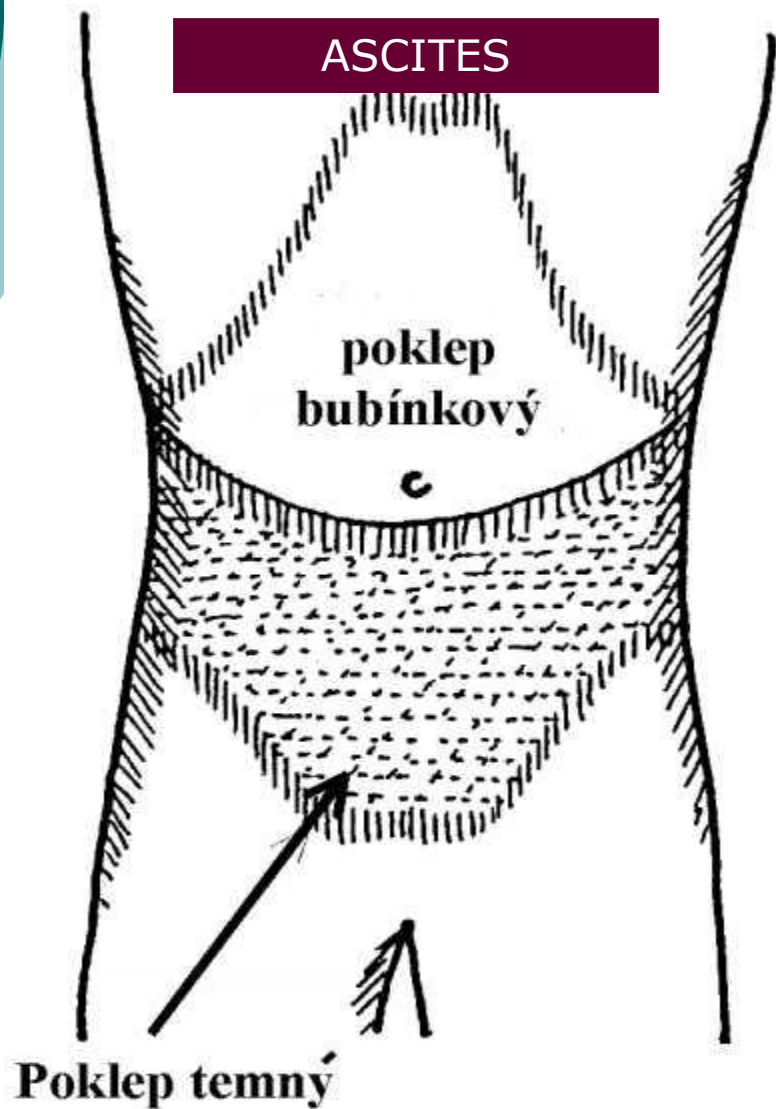
Examination of the Abdomen - Inspection - Percussion

- Examination of the Abdomen - Percussion
- Pain
 - „Plenis ´ sign“
 - Peritonitis (peritoneal irritation) – diffuse rigidity of the abdominal muscles

Examination of the Abdomen - Inspection - Percussion

- Examination of the Abdomen - Percussion
 - Physiologically: **TYMPANY**
 - the pitch and timbre of the percussion sound change according to the presence and amount of gas, fluid or other material in the peritoneal cavity:
 - **„DIFFERENTIAL TYMPANITIC percussion“**

Examination of the Abdomen - Percussion



Examination of the Abdomen - Auscultation

- Examination of the Abdomen – Auscultation
 - normal gut peristalsis
 - functional disturbances of bowel motility
 - silence in paralytic ileus
 - pulse of aorta (systolic murmur in aneurysm of the abdominal aorta)

Examination of the Abdomen - Inspection - Palpation

- Examination of the Abdomen - Palpation
- (to bend the knees slightly and relax the abdominal wall as much as possible to relieve the tension of the abdominal muscles...)
 - Size
 - Edge
 - Texture
 - Surface
 - Tenderness (pain) on palpation
 - Guarding (peritoneal irritation – diffuse rigidity of the abdominal muscles)

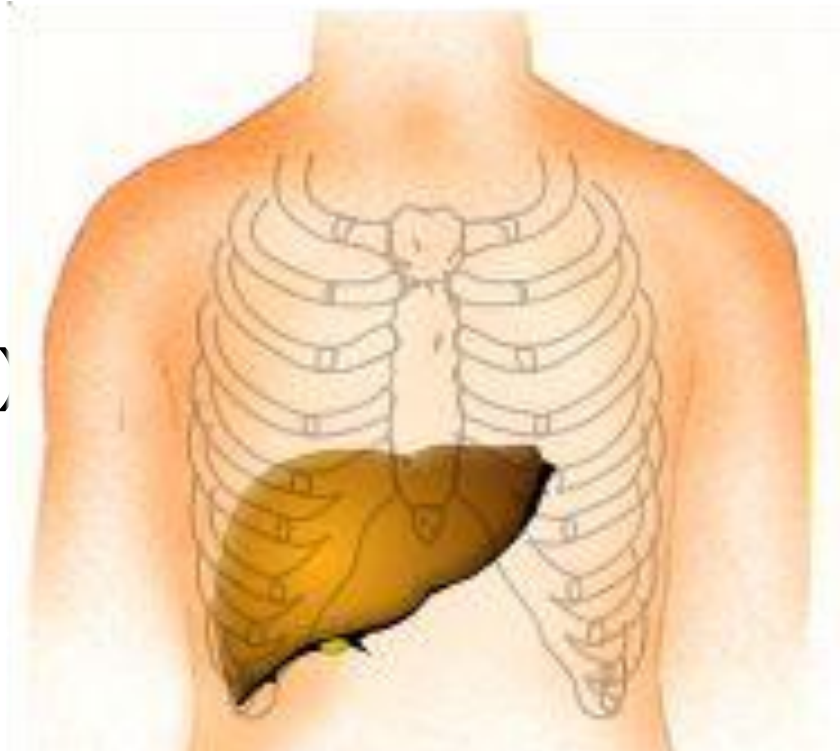


Examination of the Abdomen

- LIVER
- GALLBLADDER
- SPLEEN
- KIDNEYS

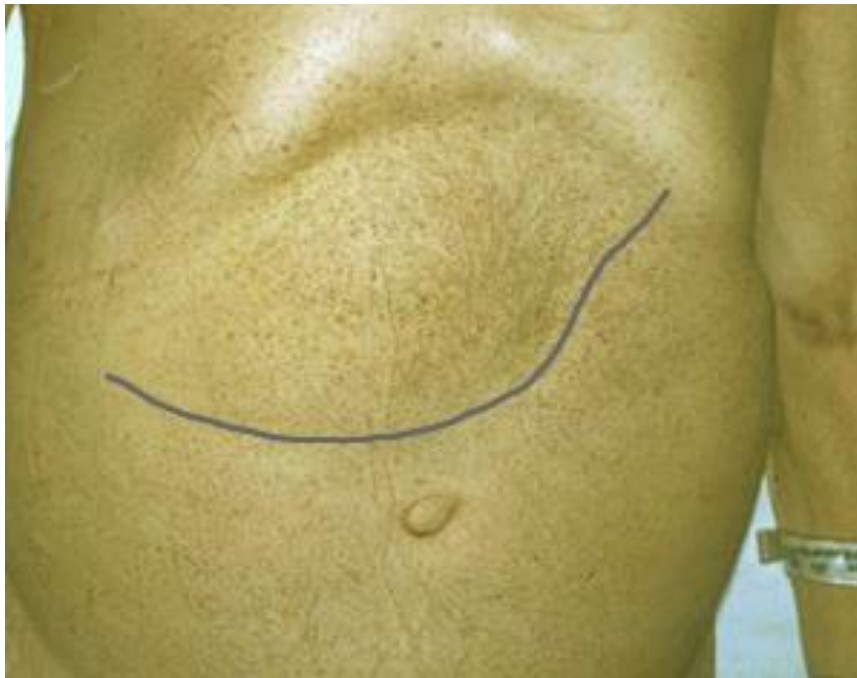LIVER

Inspection
Percussion
Palpation
(auscultation)



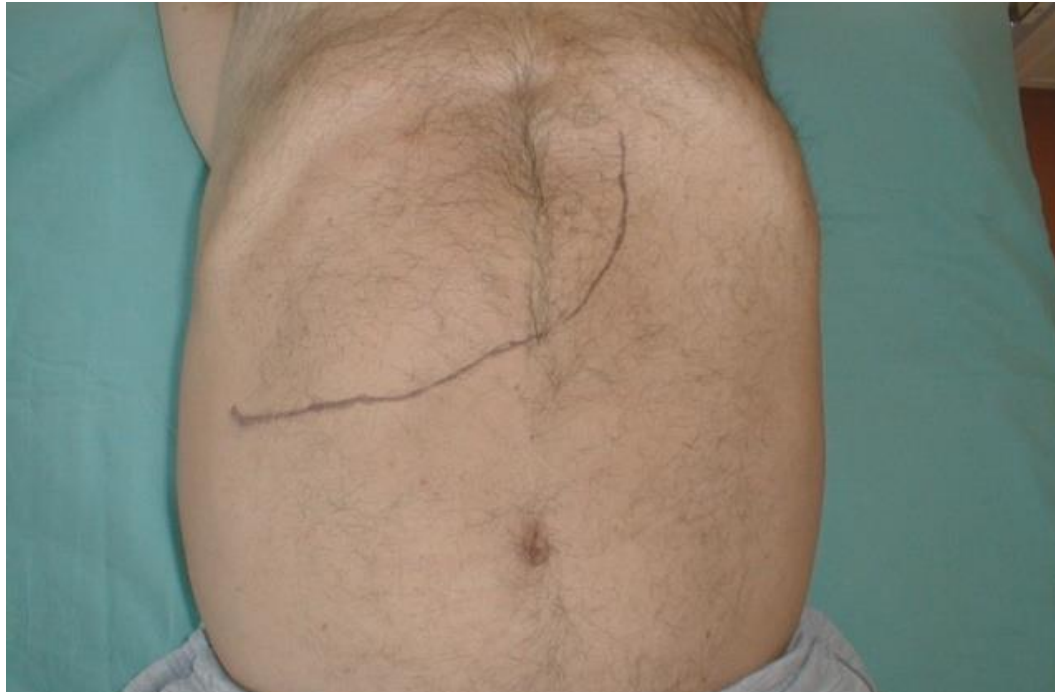LIVER

- Enlargement of the liver - hepatomegaly



LIVER

- Enlargement of the liver - hepatomegaly



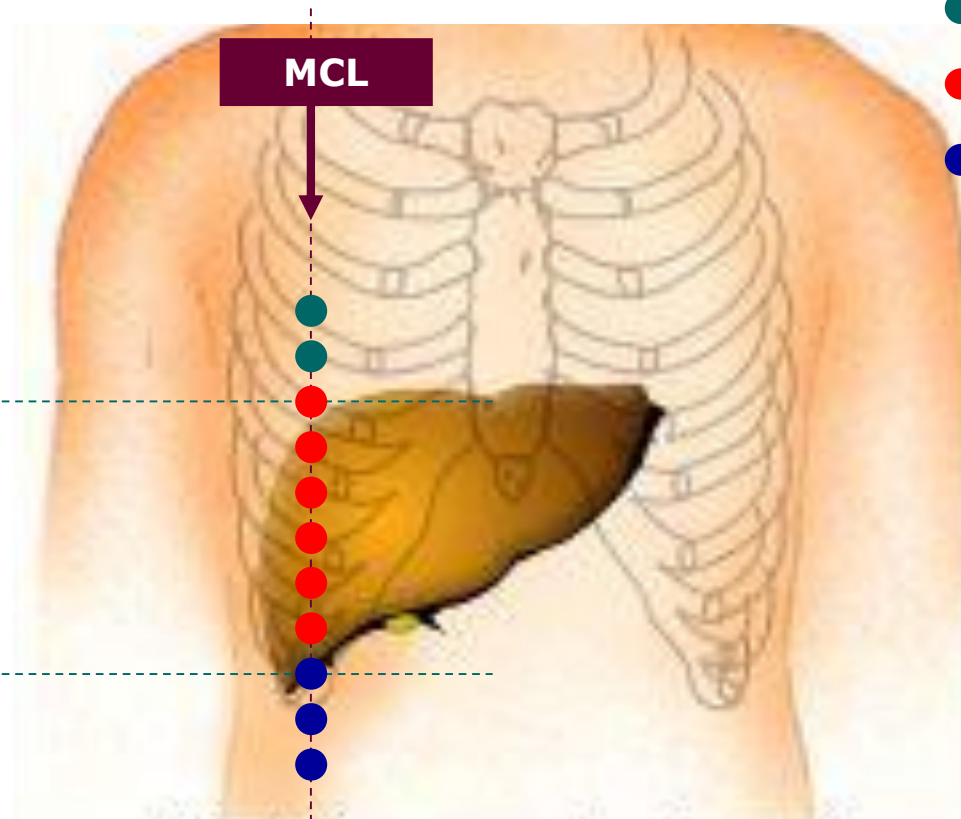
LIVER

○ Percussion

NORMAL
8-12 cm

6.th interspace

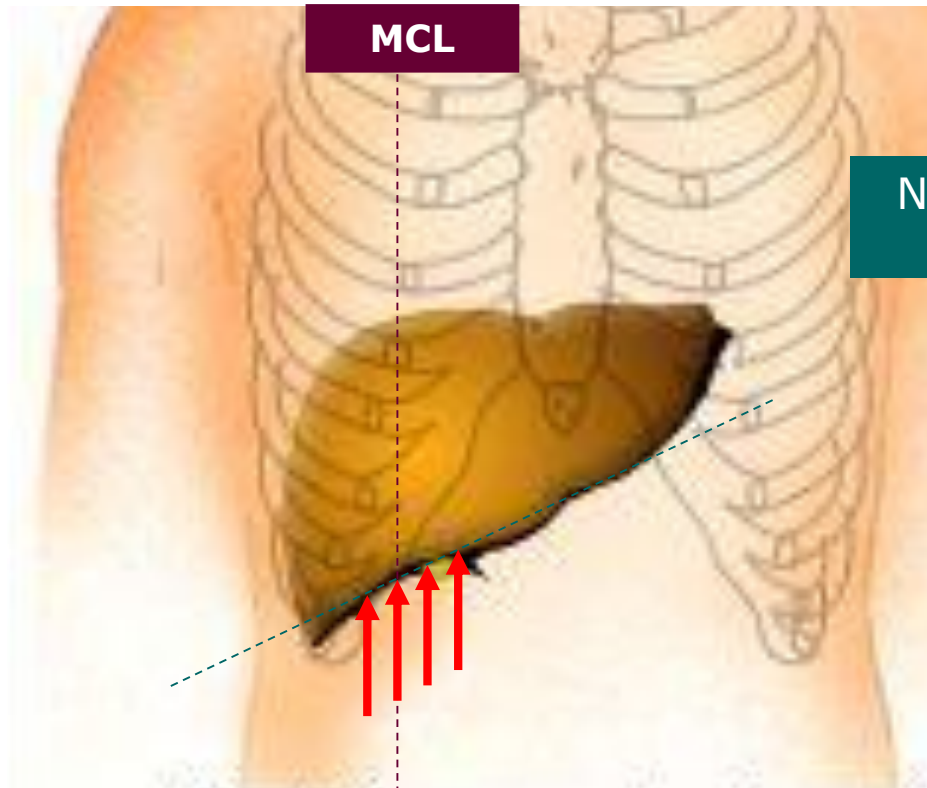
right costal margin



- Resonant
- Dull or flat
- Tympany

LIVER

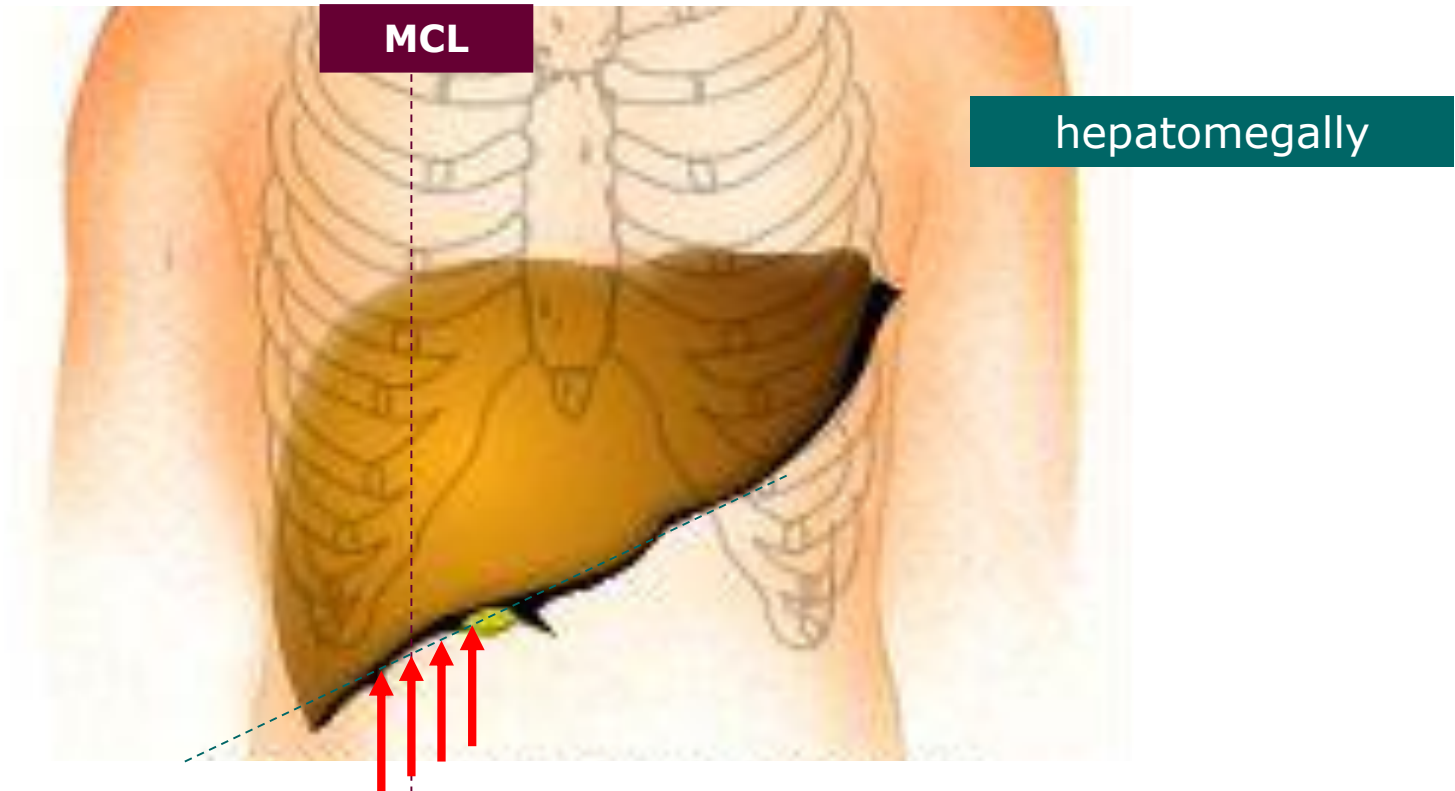
- Palpation



Normal size of the liver

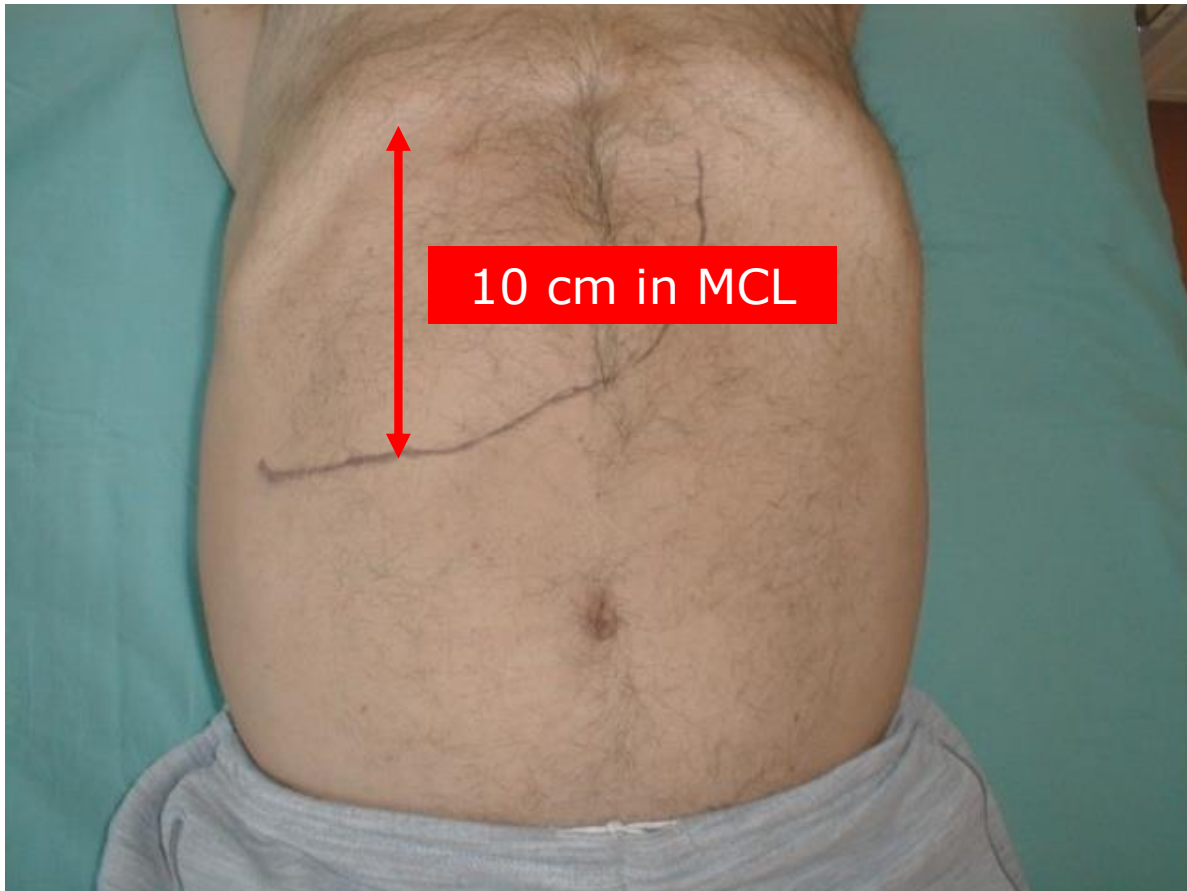LIVER

- Palpation



LIVER

- Palpation - enlargement

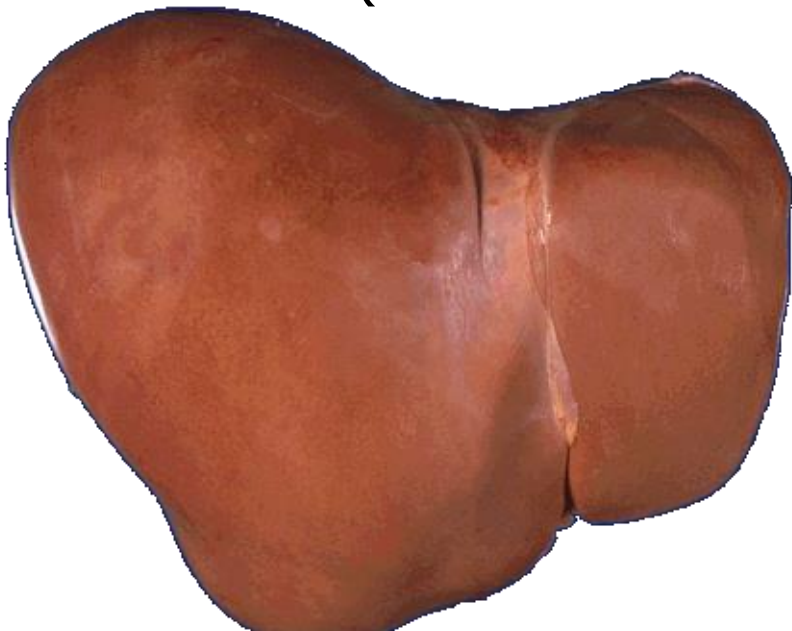


LIVER

- Palpation

- Edge of the liver

- sharp – normal
 - rounded – right heart failure, hepatitis (inflammation of the liver)



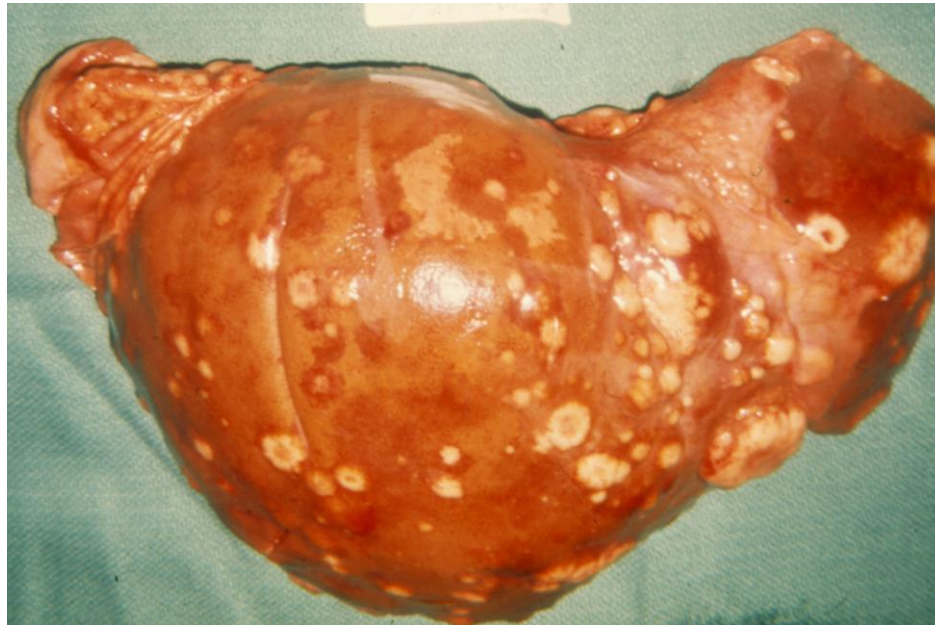
Normal Liver

LIVER

- Palpation

- Edge of the liver

- hard and bumpy – metastasis, carcinoma of the liver



LIVER

○ Palpation

● Texture

- I. – soft, smooth
 - – normal liver tissue
- II. – firmer, but still elastic
 - – heart failure
- III. – hard, non-elastic
 - – liver cirrhosis
- IV. - very hard, stone-hard
 - - cancer

LIVER

○ Palpation

- **Tenderness (pain)**

- Non-painfull

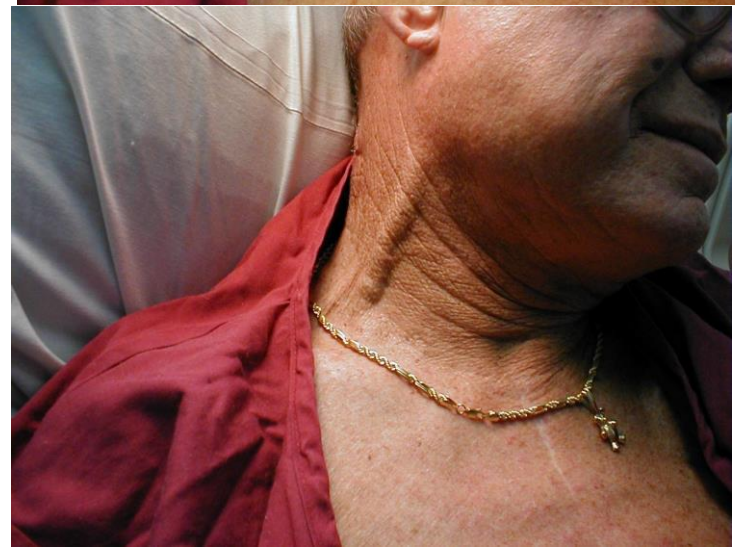
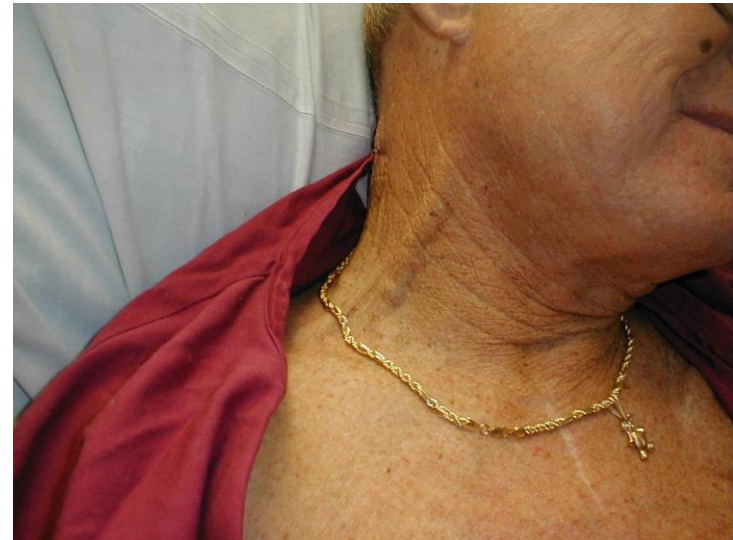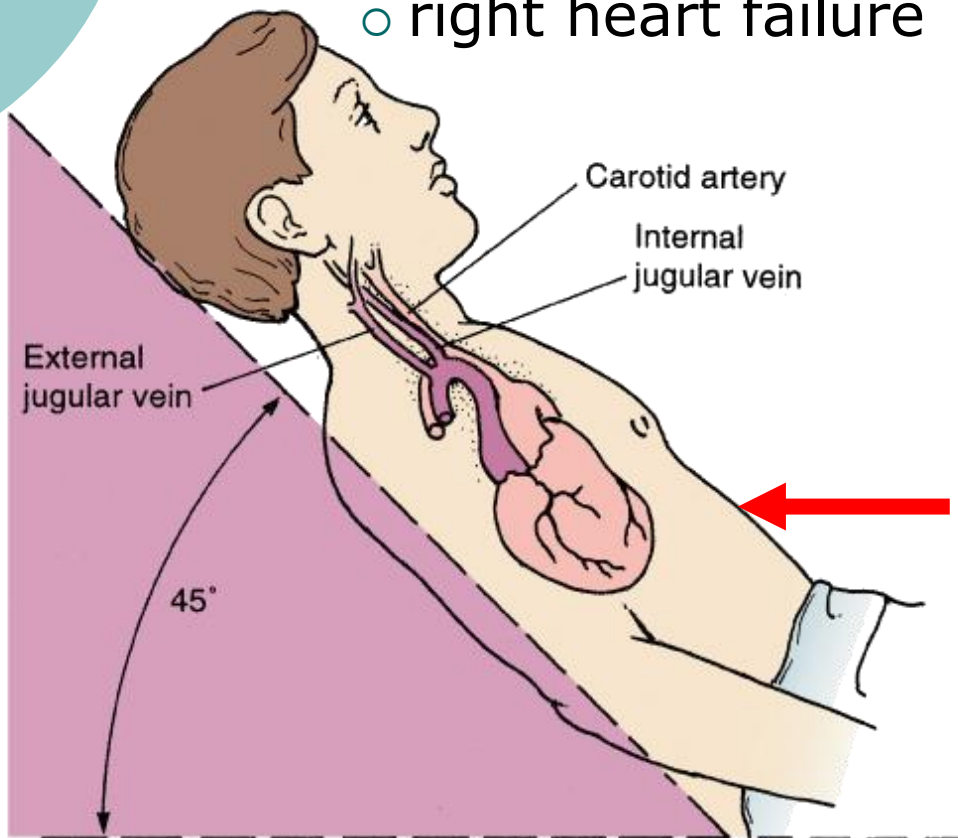
- Cirrhosis of the liver
- Carcinoma of the liver, metastasis to the liver

- Painfull

- Congestion of the liver
- Inflammation - hepatitis

LIVER

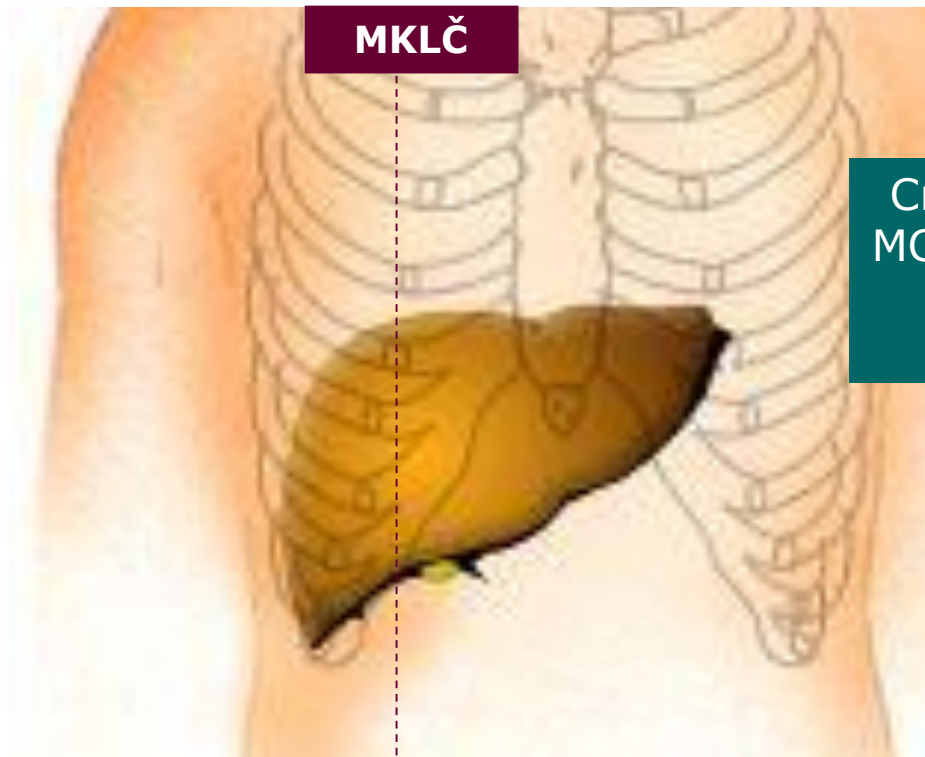
- Palpation
 - Hepatojugular reflux
 - right heart failure



GALLBLADDER

○ Inspection

- Non - visible – normal finding
- Visible – hydrops



MKLČ

Cross-section between
MCL and the right costal
margin – slightly
medially

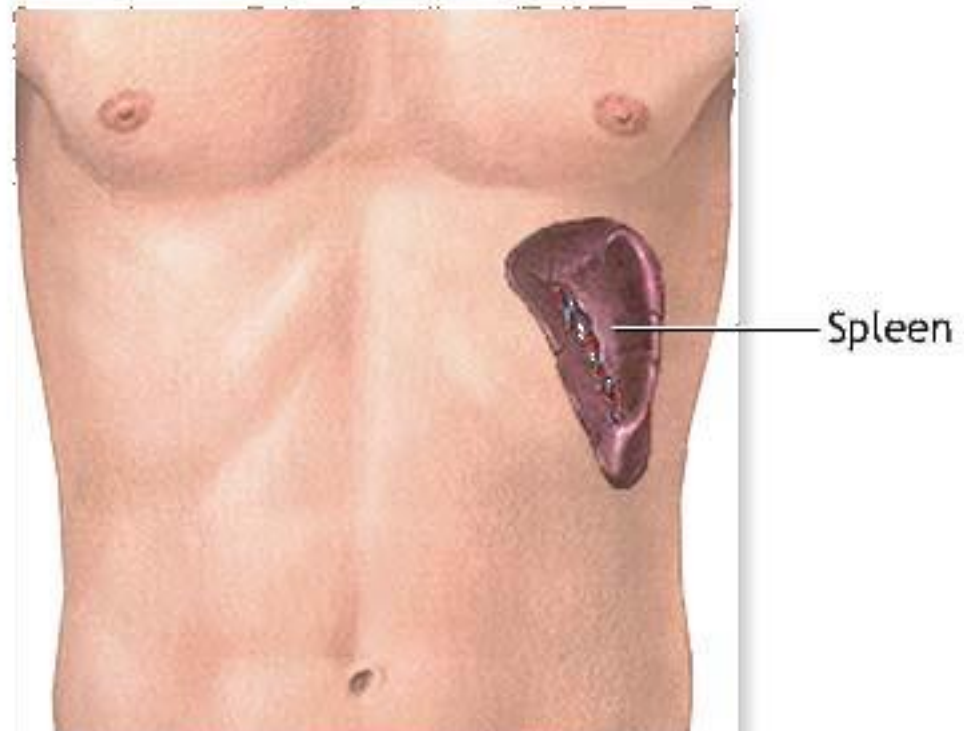
GALLBLADDER

- Palpation

- **Murphy's sign** – inflammation of the gallbladder
 - Palpation in the gallbladder position
 - Strong pain in inspiration

SPLEEN

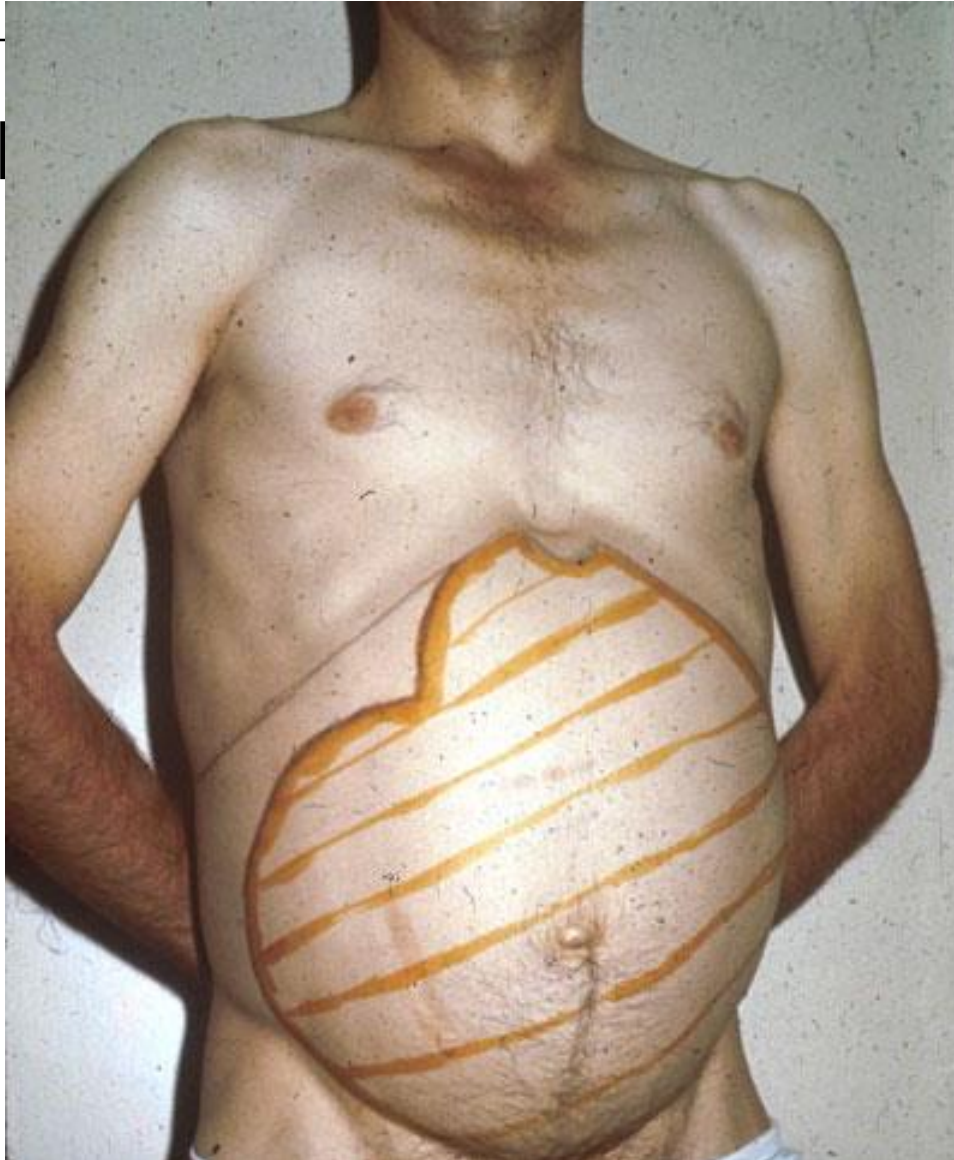
- Inspection
- Palpation
- (auscultation)
- (percussion)



NORM

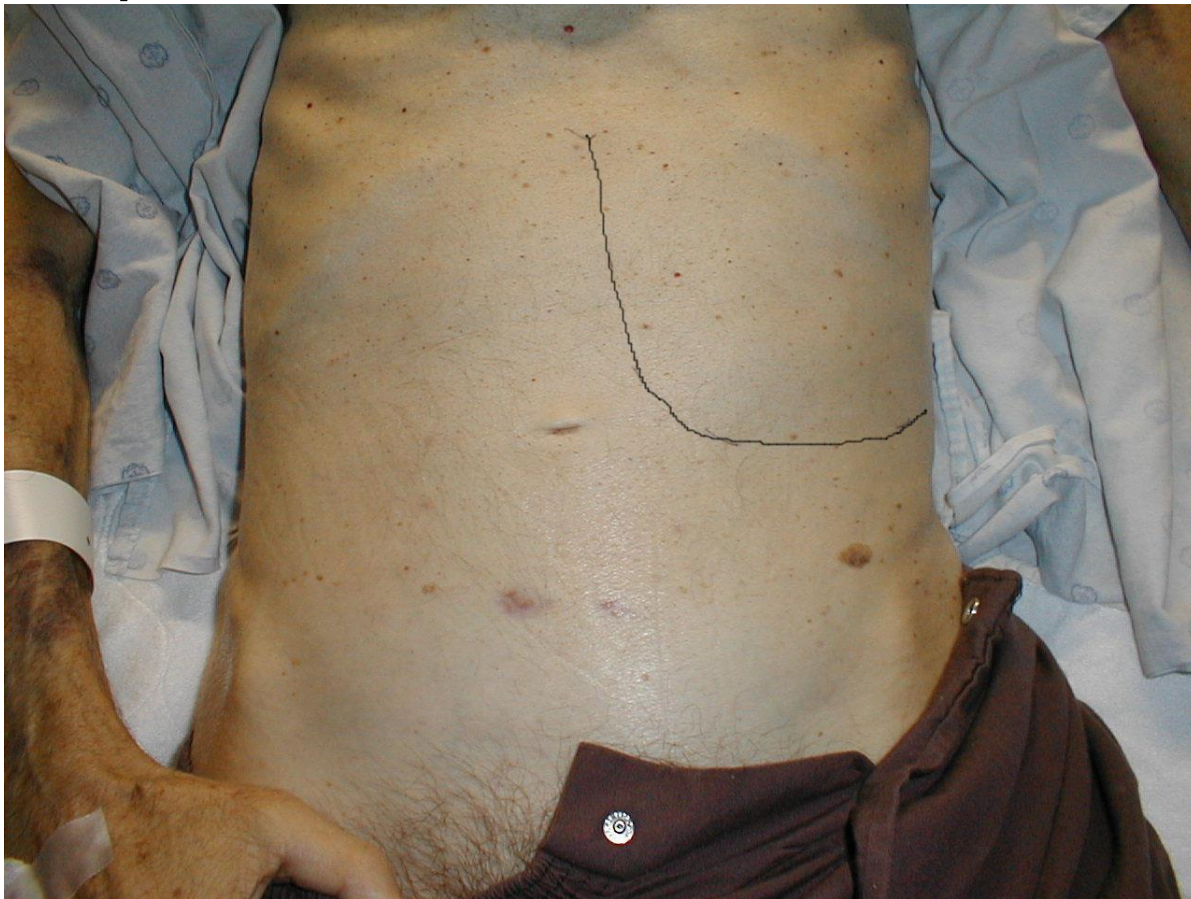
SPLEEN

- Insp
- N
- V



SPLEEN

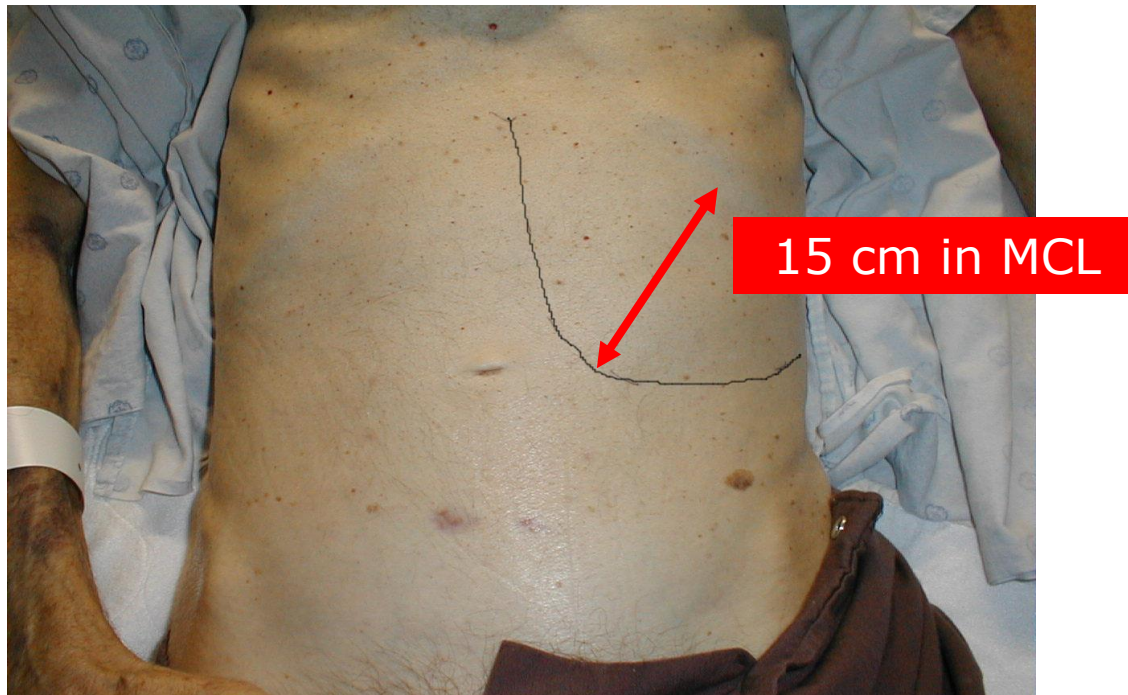
- Inspection



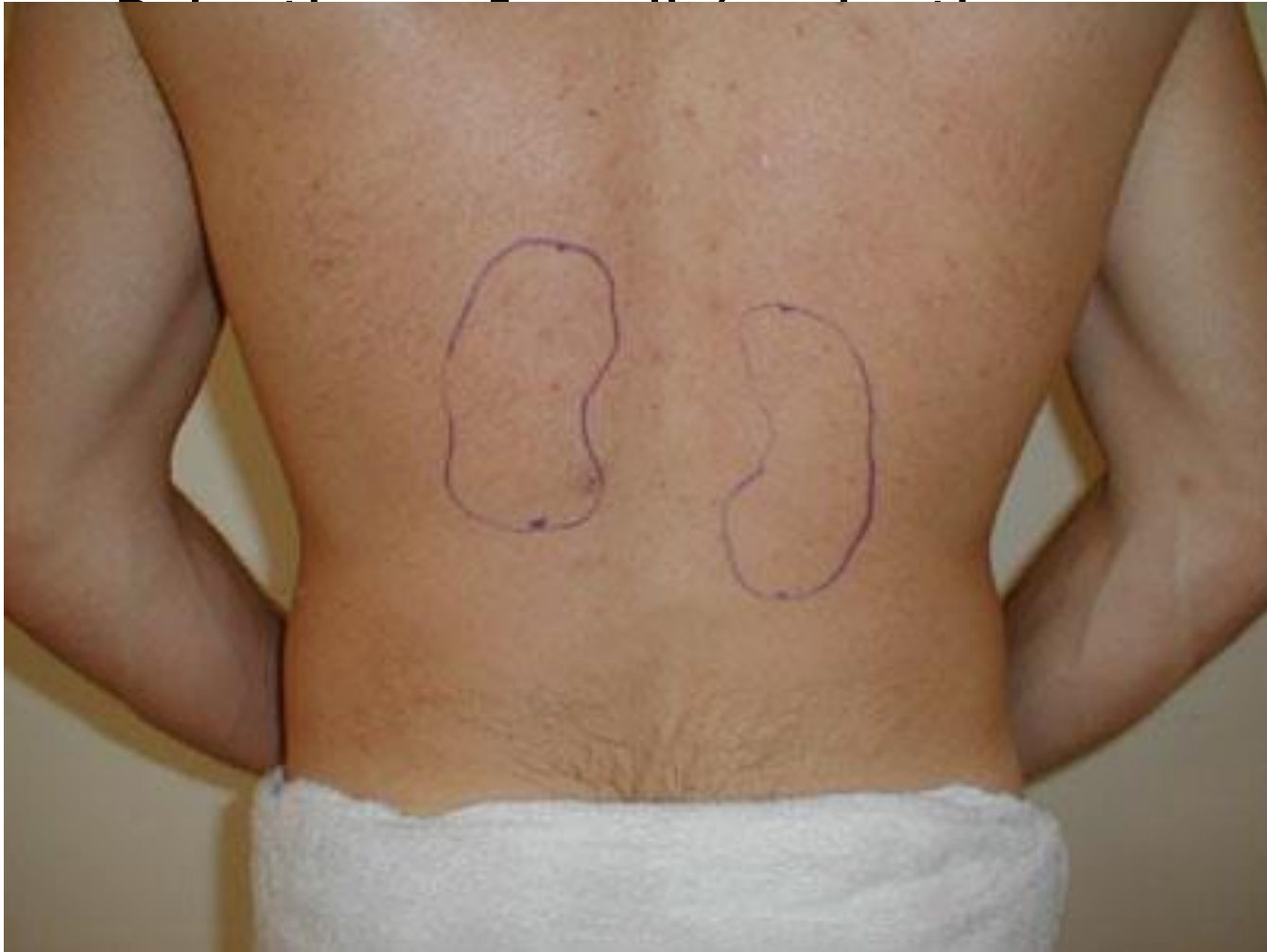SPLEEN

- Palpation

- in the supine position
- in the right oblique position



KIDNEY



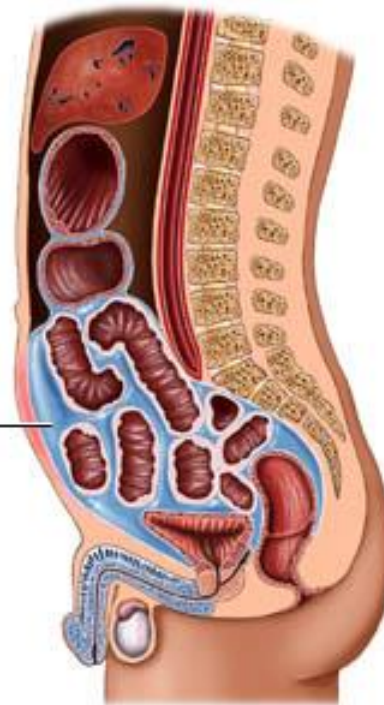
cyst,

osis of

ASCITES

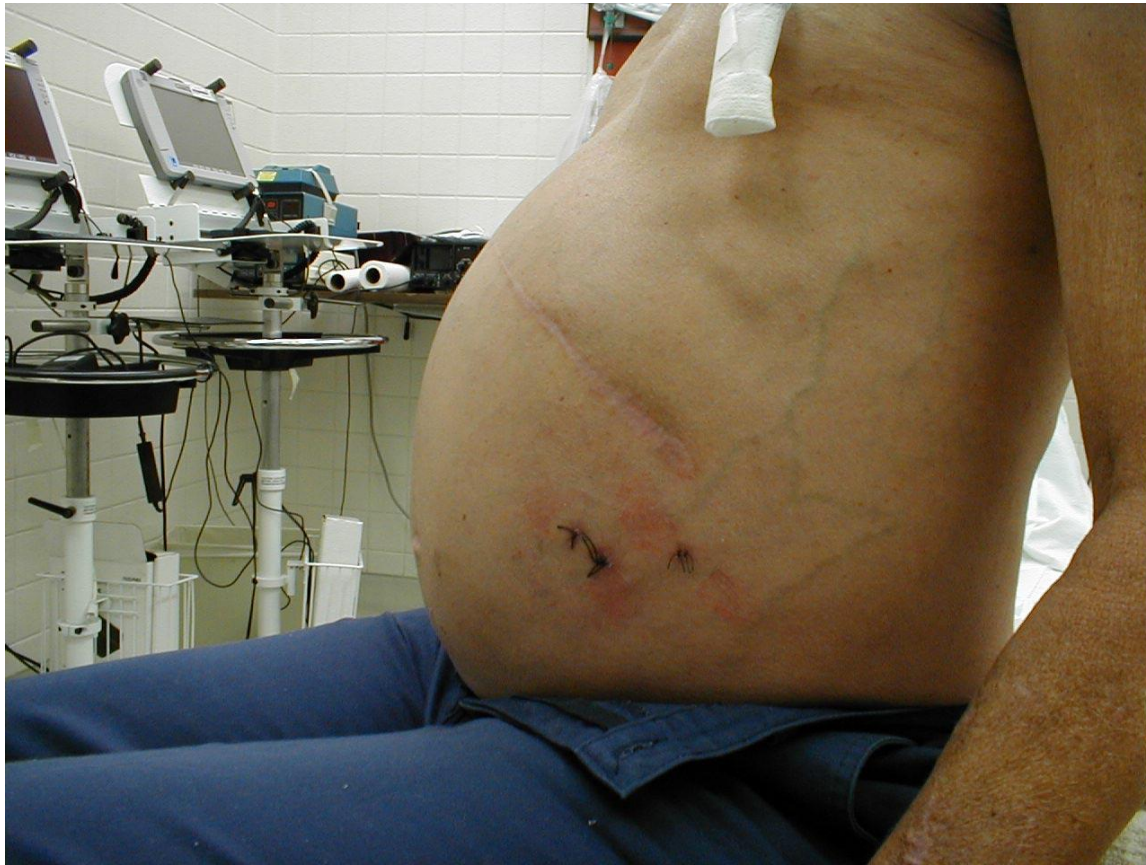- FLUID in the cavity of abdomen
- Physically can be find: 1-2 litr

Increased amount of fluid
between abdominal structures



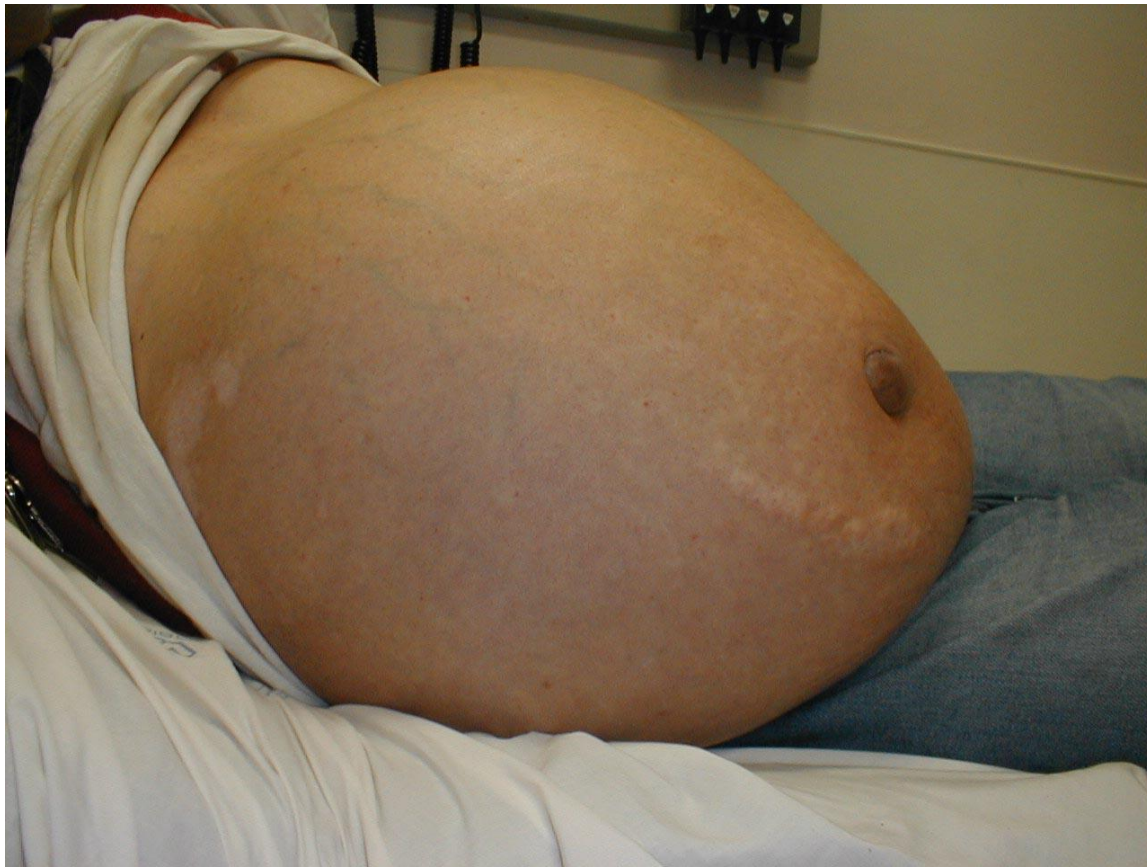
ASCITES

- Inspection



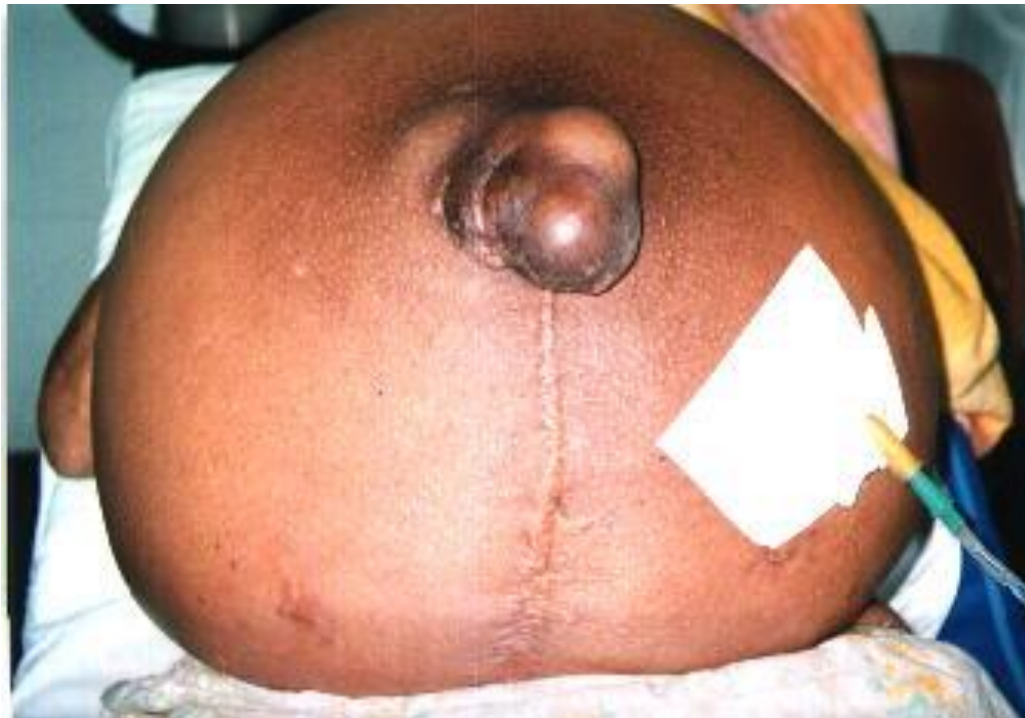ASCITES

- Inspection

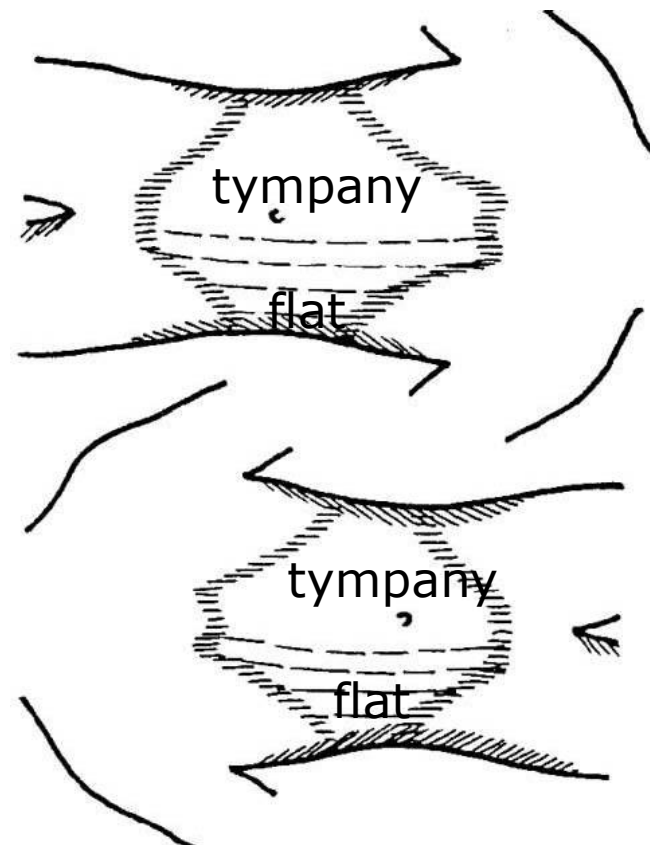
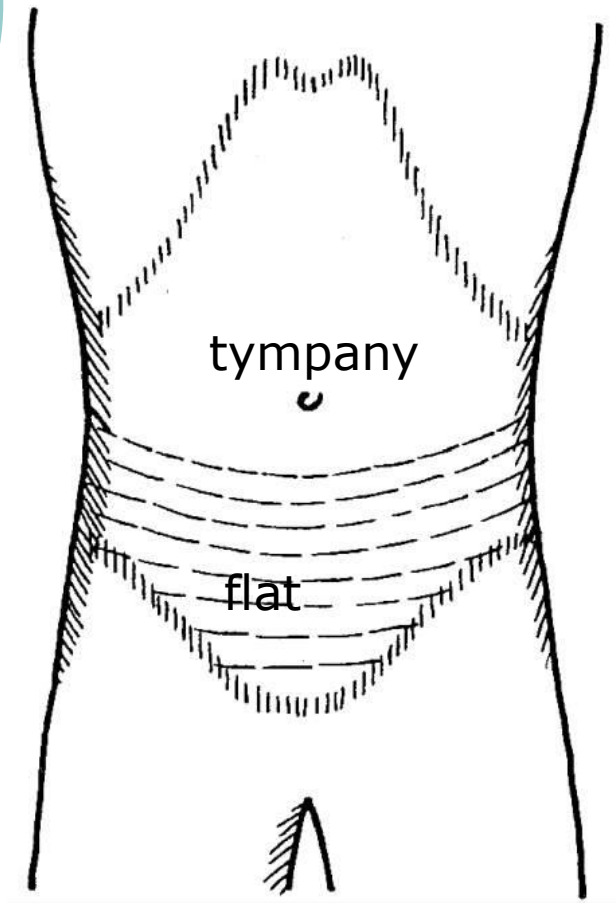


ASCITES

- Inspection



ASCITES -percussion



ASCITES

- Percussion – we can touch the undulation (fluid wave) or transmitted shaking of the abdominal wall

