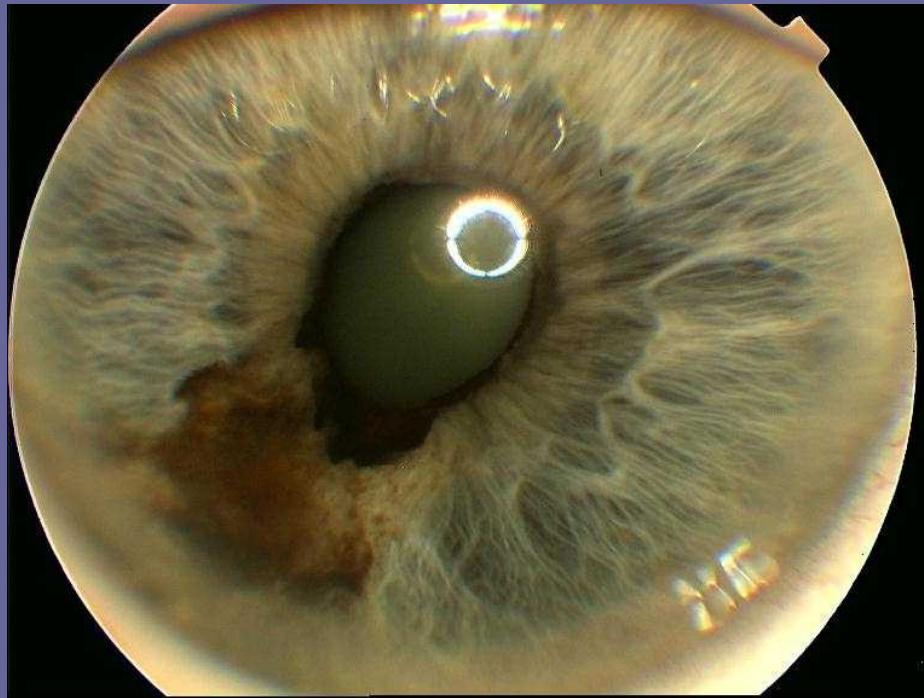


Neoplastic diseases of the eye and adnexa



MUDr. Michala Karkanová, MUDr. Radoslava Uhmánová

MUDr. Igor Vícha, MUDr. Radek Girgle, MUDr. Elena Tokošová

Ophthalmology clinic FN Brno, přednostka prof. MUDr. Eva Vlková, CSc

Tumor tissue change, which is a result of the locally noncontrolable growth of autonomous nature.

The biological nature of the tumor:

benign

malignant

Separation of eye tumors according to anatomic localization:

eyelid tumors

tumors of the eye

orbital tumors

Eyelids tumors

Location:

anywhere on the cap

mainly a cosmetic problem

fault status and function lids with symptoms of dry eye syndrome (burning, cutting, more frequent sec. infections, xerosis of the conjunctiva, exposure keratopathy a reduction or even loss of the eye ZO)

Treatment:

(Depending on size, location and nature of the changes)

Early excision with a sufficiently large safety rim

histological verification

Benign eyelids tumors

Location:

anywhere on the lid, without age limitation

mostly a cosmetic problem

Retention cysts sebaceous glands (milia, atheroma)

Papilloma - cutaneous horns

Verruca, verruca senile

Hemangioma

Xantelasma

Nevus

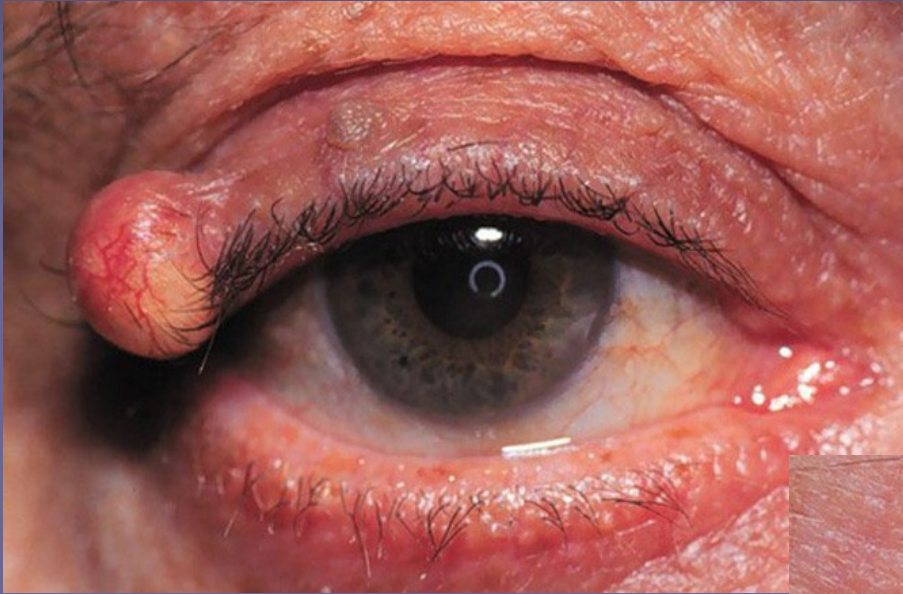Treatment:

Observation (nevi)

Surgery - cautery, simple excision, laser therapy
(CO2 laser), cryo

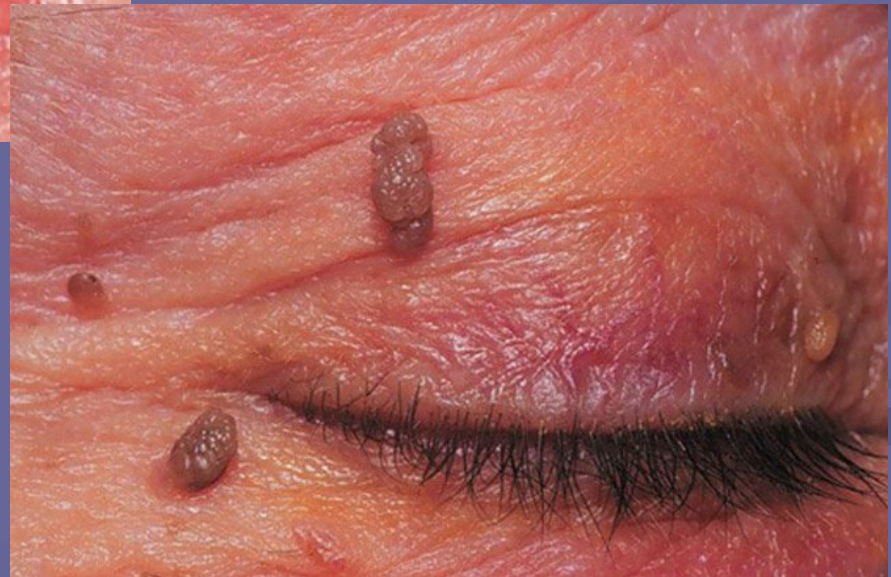Histological examination !!!

Benign eyelids tumors



Retention cyst

Eyelids papiloma



Malignant eyelid tumors

Location:

predilectively lower lid, 6.-7. decade of life

basal cell carcinoma (invasion only local)

squamous cell carcinoma (metastasizes)

malignant melanoma

Meibom glands carcinoma

Treatment:

surgical excision - simple

- with plastic finish

radiotherapy

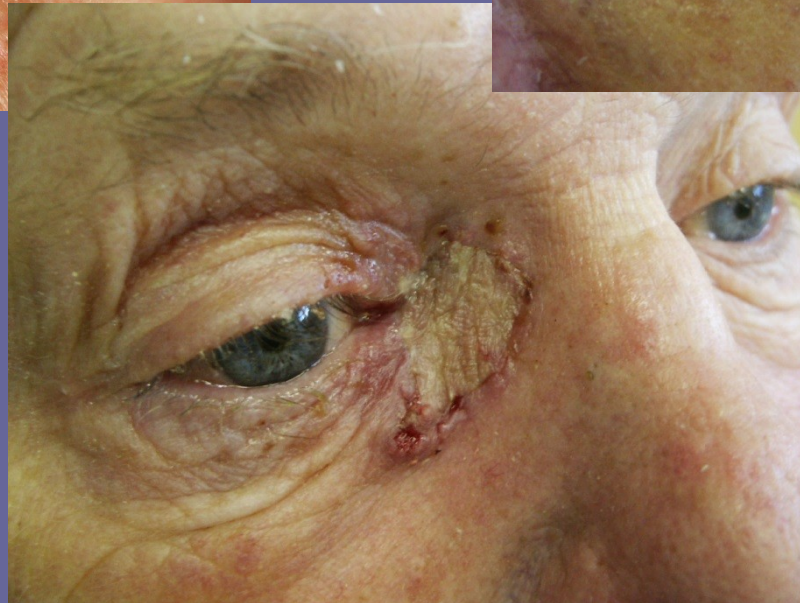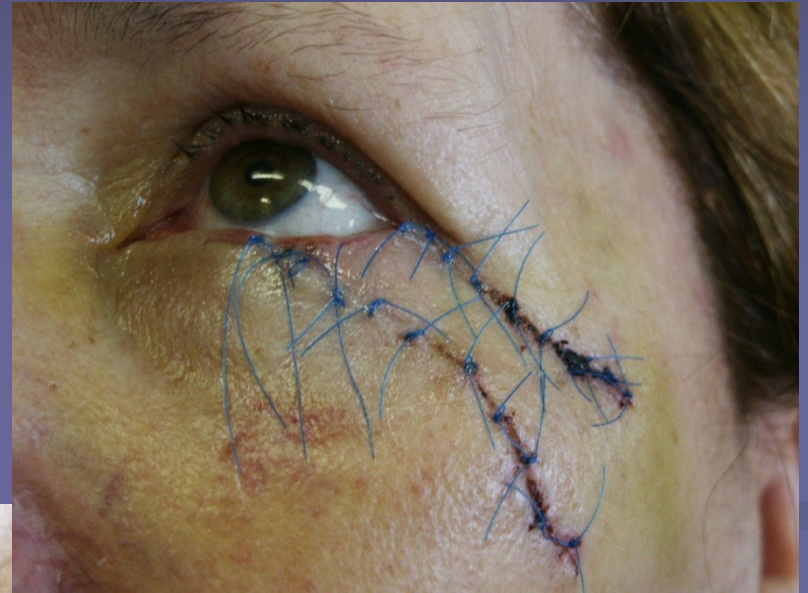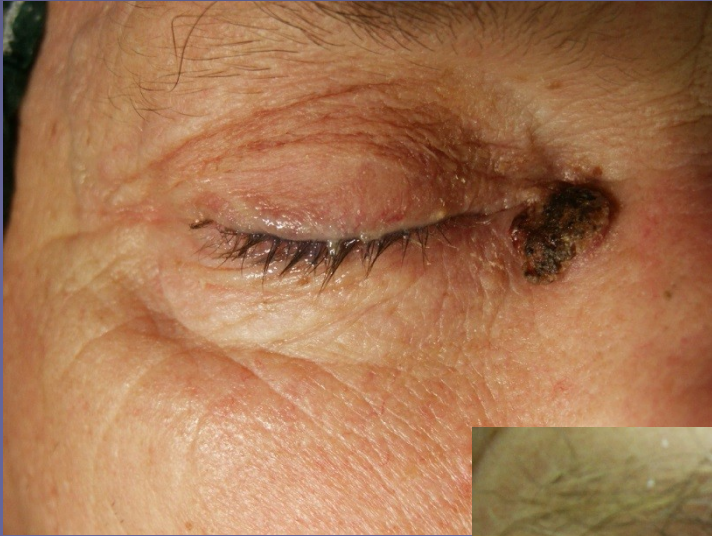surgery followed by radiotherapy

local application IL

Oncologic dispensary!

Malignant eyelid tumors

Basal cell carcinoma



Tumors of the conjunctiva and cornea

Location:

predilectively range of eye slits, all ages,
a shift to a higher age

Treatment:

dispensary congenital change without progression -
photographs (cosmetic point of view)

surgical - block excision, lamellar keratectomy,
in malignancies completed with cryotherapy
- radical excision (up orbit exenteration)

additional local radiotherapy

local application of antimetabolites

Histological examination!

Oncological dispensary in melanoma and cancer!

Benign tumors of the conjunctiva and cornea

Congenital:

Choristoma - dermoid, lipodermoid

Hemangioma

Epithelial:

Hyperplasia

Epithelioma (carcinoma in situ, Bowen's disease)

Melanotic:

Melanosis

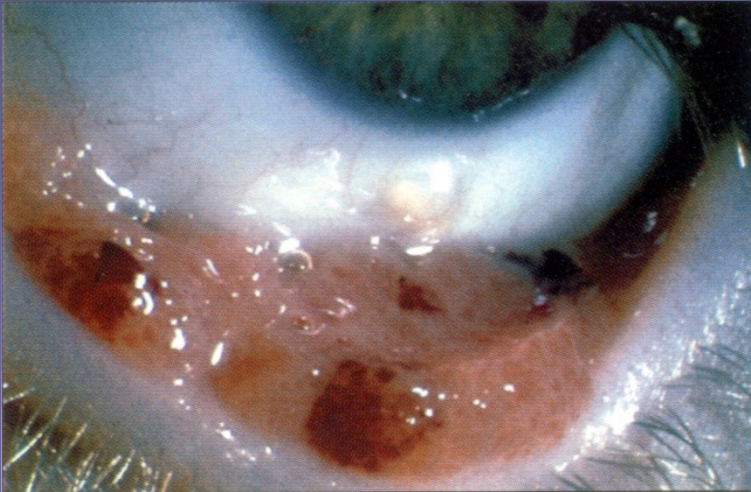
- congenital

- acquired (with or without atypia atypical)

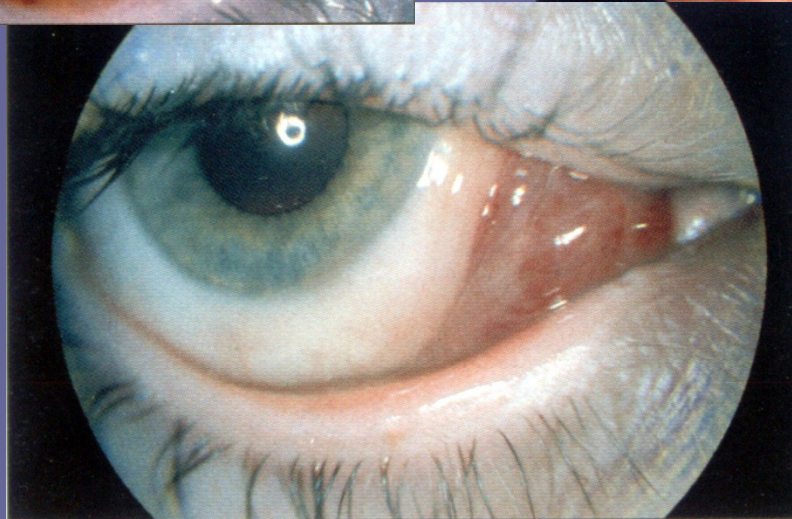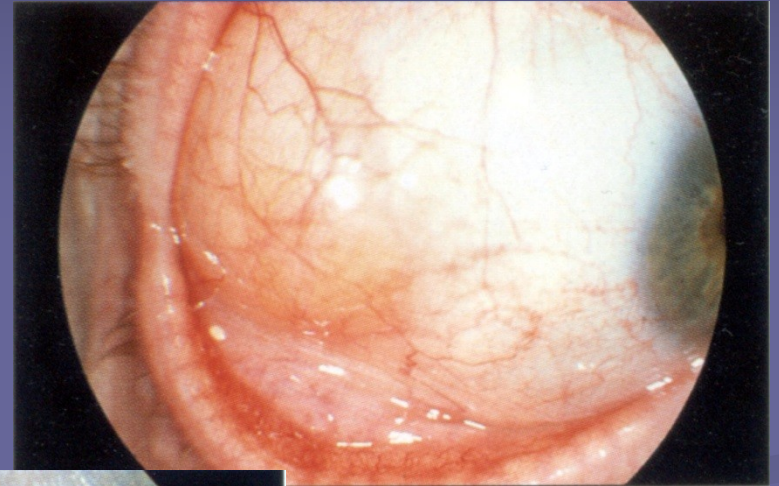
Nevus, Melanocytoma (kong. based)

Benign tumors of the conjunctiva and cornea

conjunctival papiloma



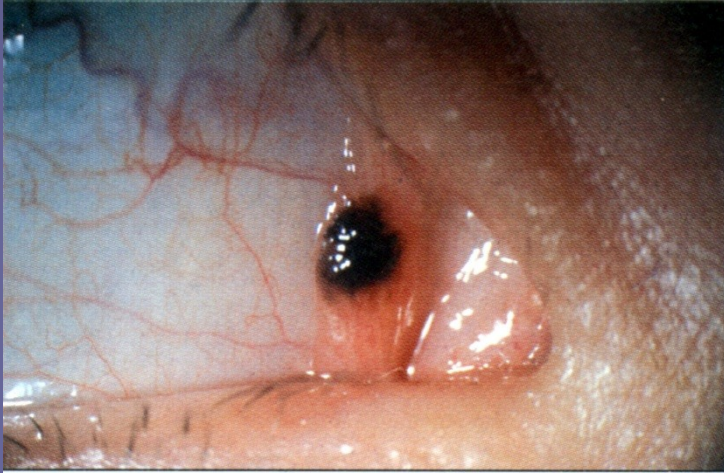
conjunctival lipodermoid



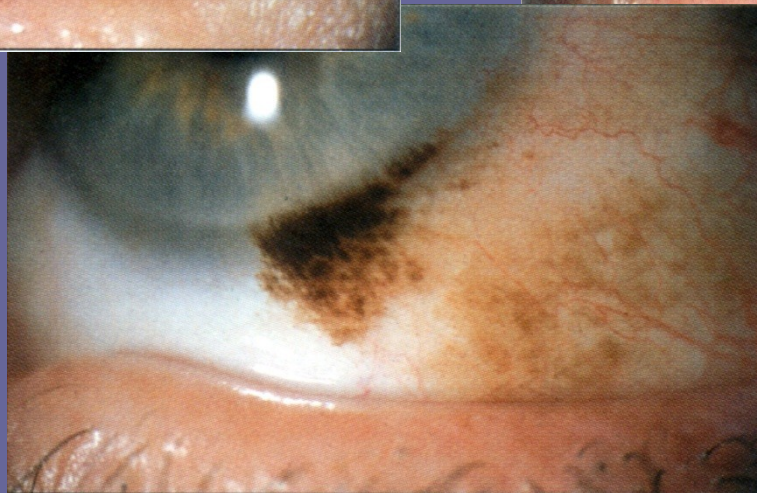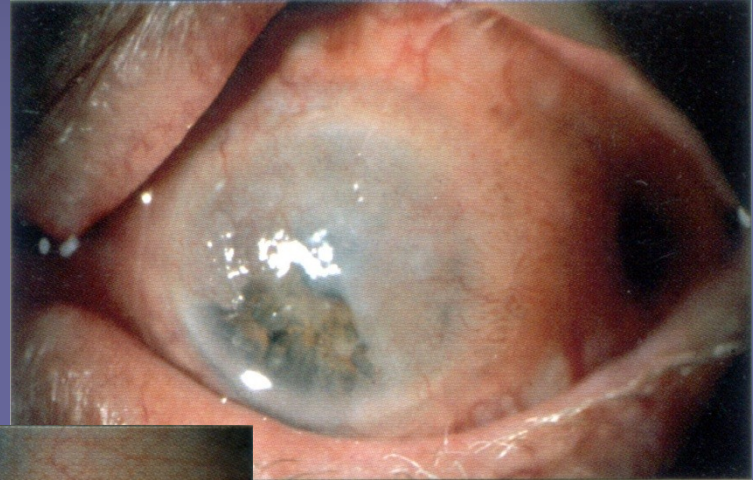
*conjunctival
lymfangioma*

Benign tumors of the conjunctiva and cornea

conjunctival nevus



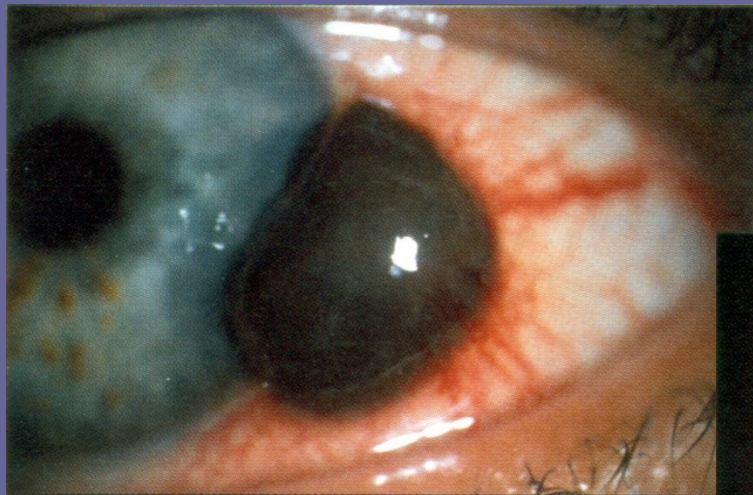
carcinoma in situ



*conjunctival
melanosis*

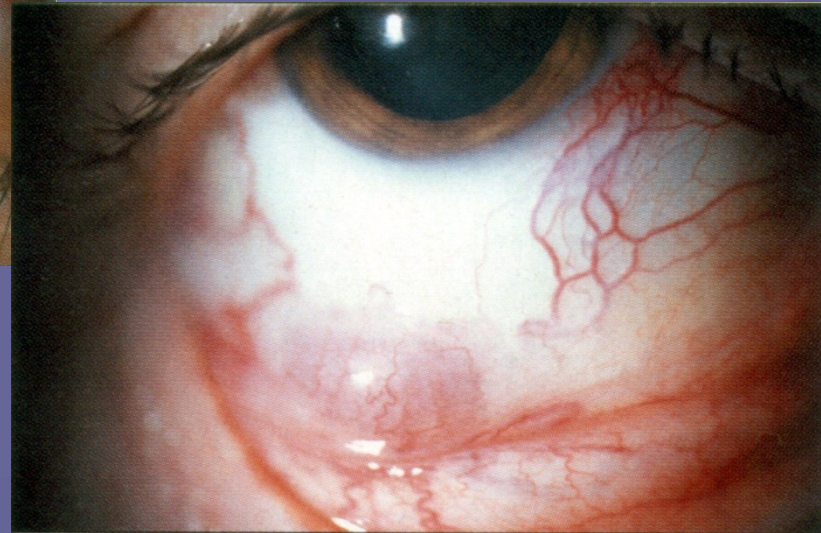
Malignant tumors of the conjunctiva and cornea

- Malignant melanoma of the conjunctiva
- Carcinoma of the conjunctiva (rare disease))
- Lymfoma of the conjunctiva (Non – Hodgkin type)



conjunctival malignant melanoma

conjunctival lymfoma



Intraocular tumors

Primary:

the origin of the uvea (iris, ciliary body, choroid)
originate in the retina (exceptionally on adults)

Secondary:

infiltrative growth of surrounding tissue

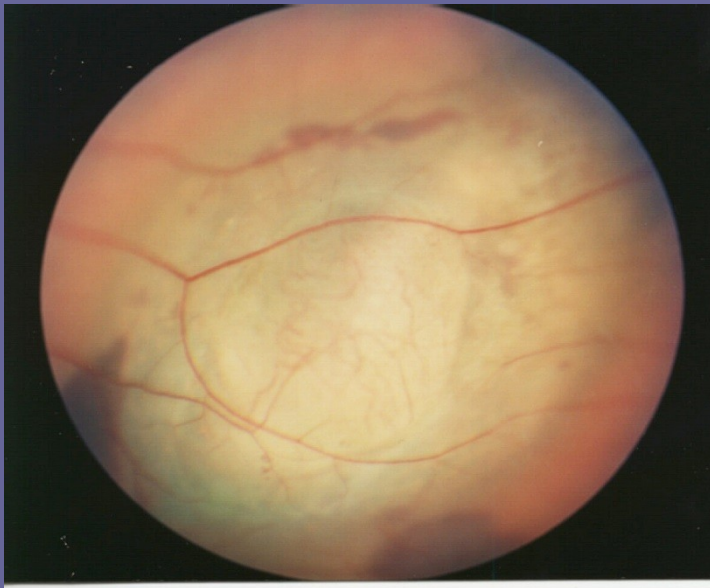
Metastatic:

following generalization of the malignancy
most common in the choroid (often the first symptom of malignancy)

Metastases - women breast carcinoma 85%, bronchi 8%
- male lung carcinoma 38%, GIT 20%

Malignant melanoma of the uvea(MMU)

- Iris 8%
- Ciliary body 12%
- Chorioid 80%



- the most common primary intraocular tumor of adults
- incidence between 50-70 years
- featured mortality 30 -70% most often
- unilateral

MMU Diagnostics

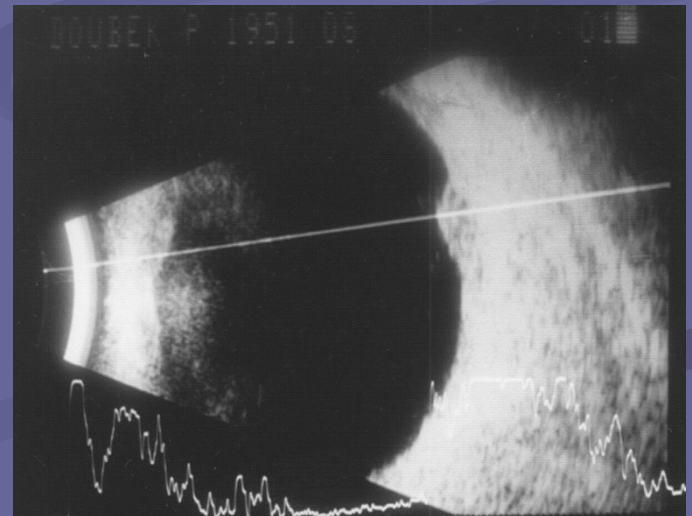
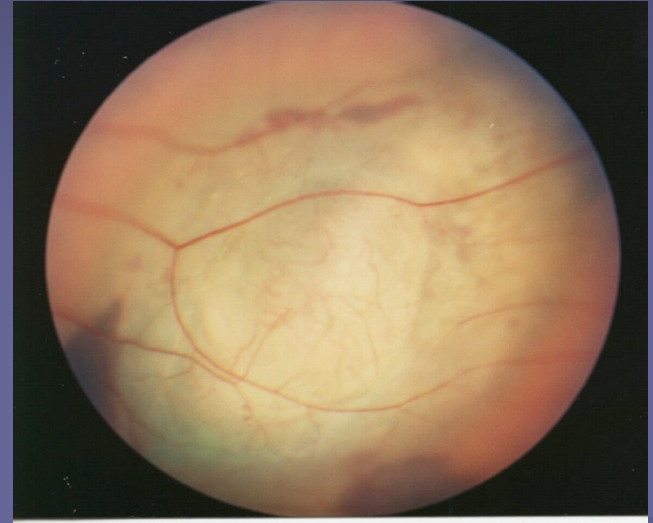
Examination on the slit lamp

Ophthalmoscopy

- direct
- indirect
- biomicroskopie
- gonioscopy

Sonography

- B scan
- standard. echography
- UBM

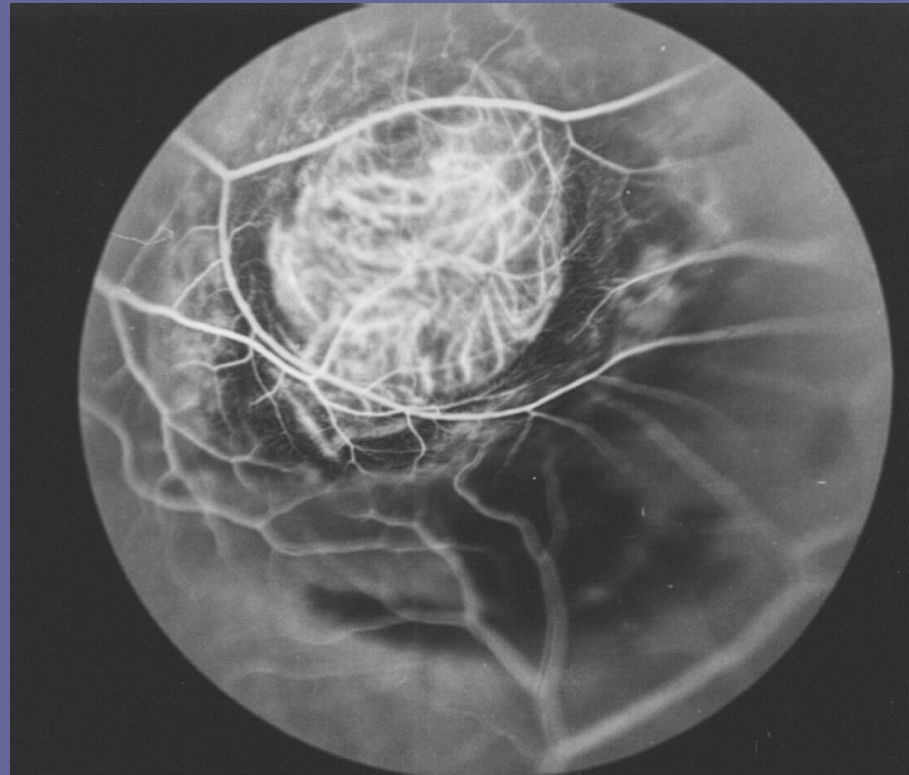


MMU Diagnostics

FAG (fluorescein angiography)

ICG (indocyanin angiography)

NMR, PET



Examinations performed in determining the MMU diagnosis

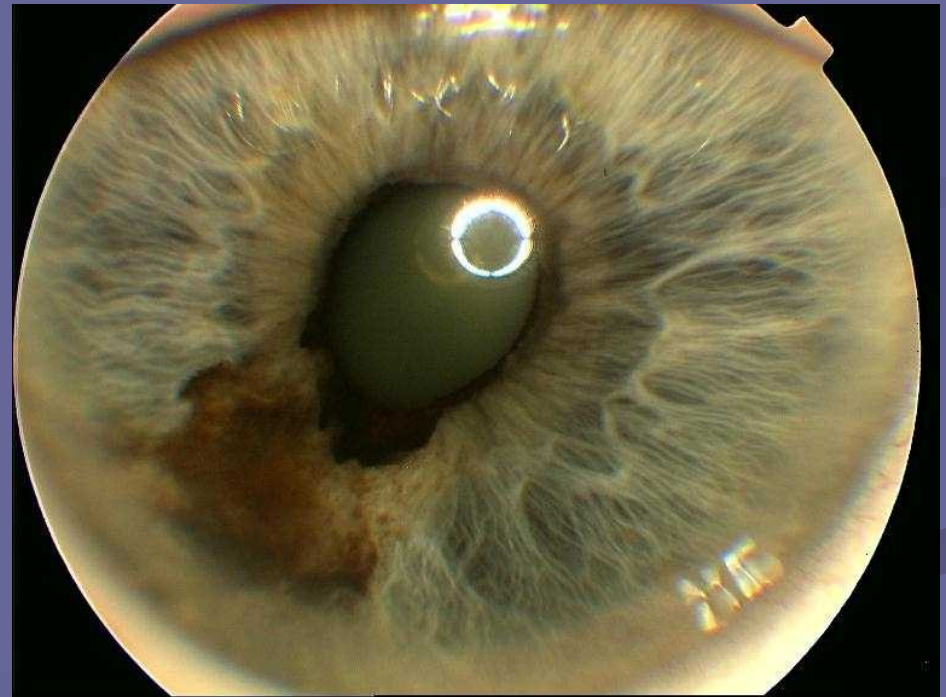
- Complet laboratory examinations including oncomarkers
- Lungs radiology
- Echography of parenchymatous organs of the abdomen
- Sceleton scintigraphy
- Brain NMR
- Complet inner examinatin
- Oncological examinatin
- (PET)

Criteria for selecting therapeutic approach

- individual
- vision, intraocular tension, status of the affected eye
- **size of the tumor**, signs of its activities
- localization, shape
- other eye condition, patients general state
- age of the patient at the time of detection

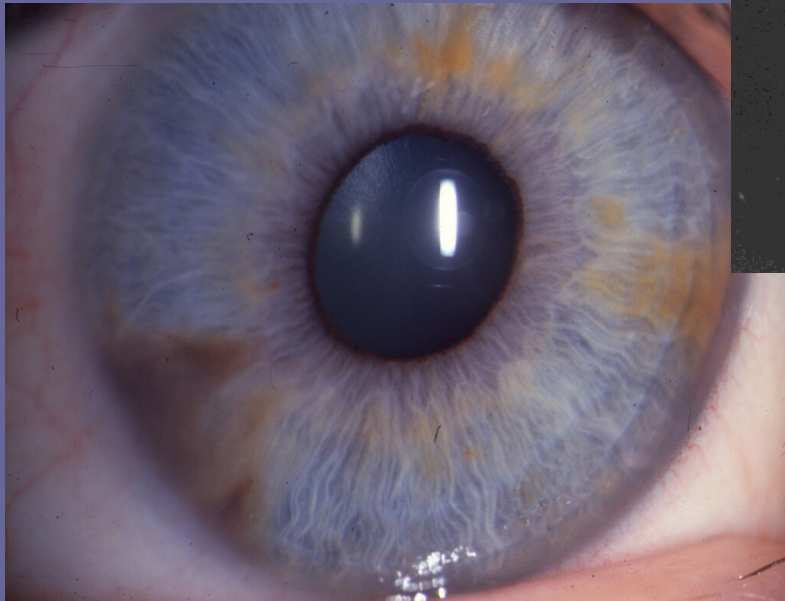Iris malignant melanoma

- most common occurrence in the lower half of the iris
- various pigment
- distortion of the pupil
- ectopia of pigmented sheet
- partial cataract

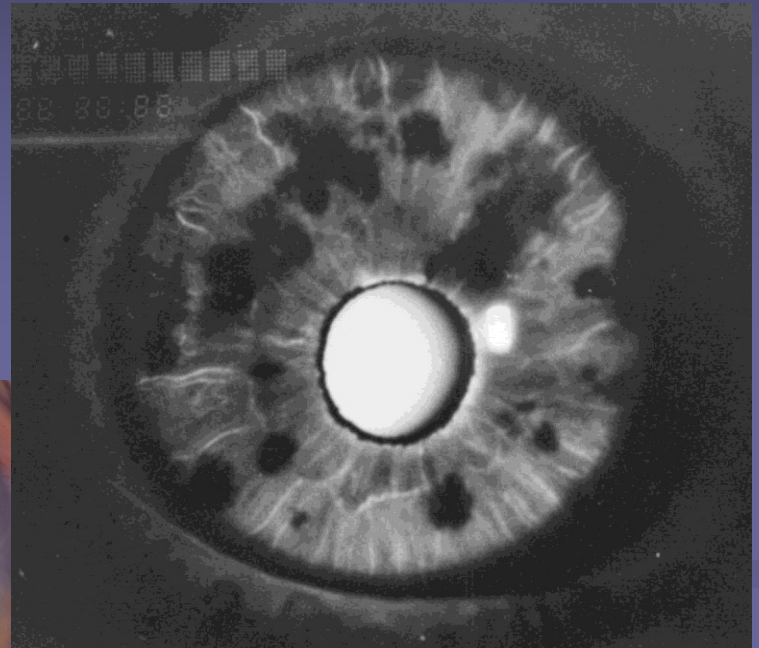


Diferencial diagnosis of the iris tumors

- nevus
- cyst
- leiomyoma
- leaf pigment hyperplasia



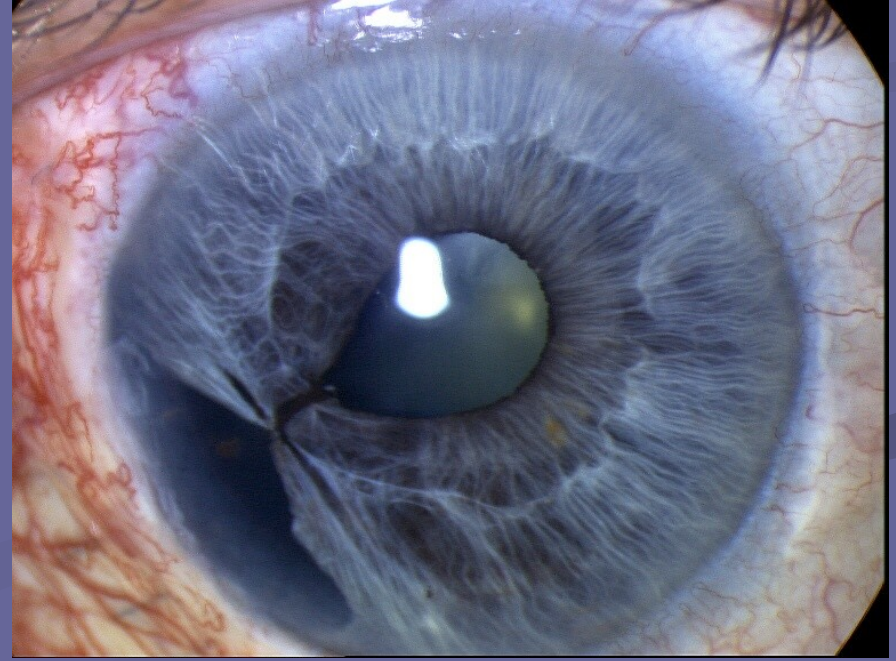
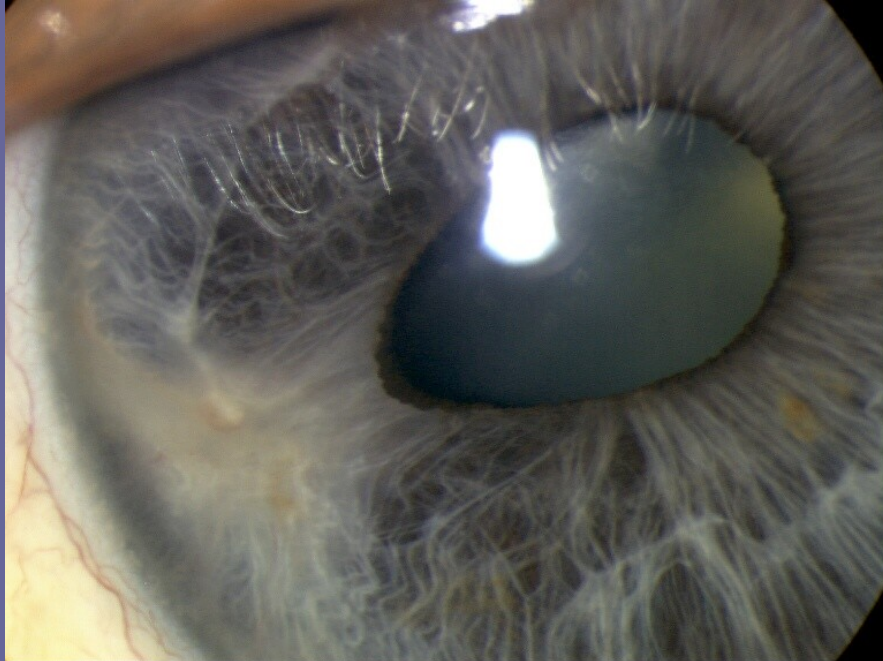nevus of the iris



iris like the tiger

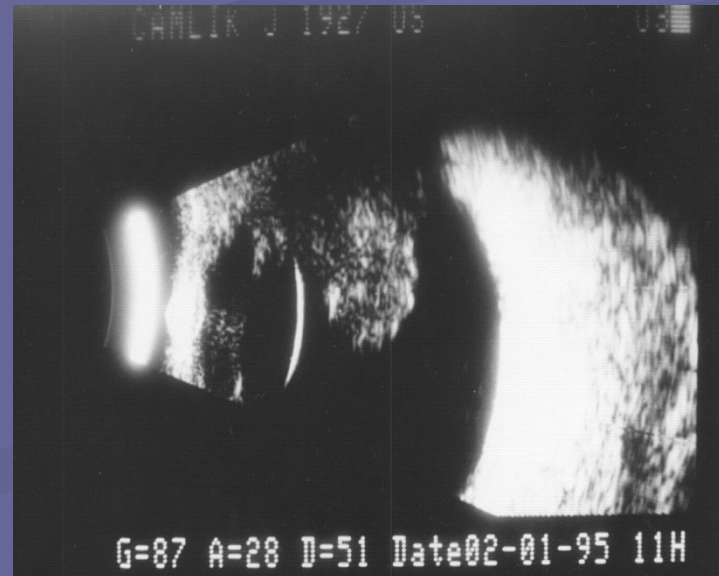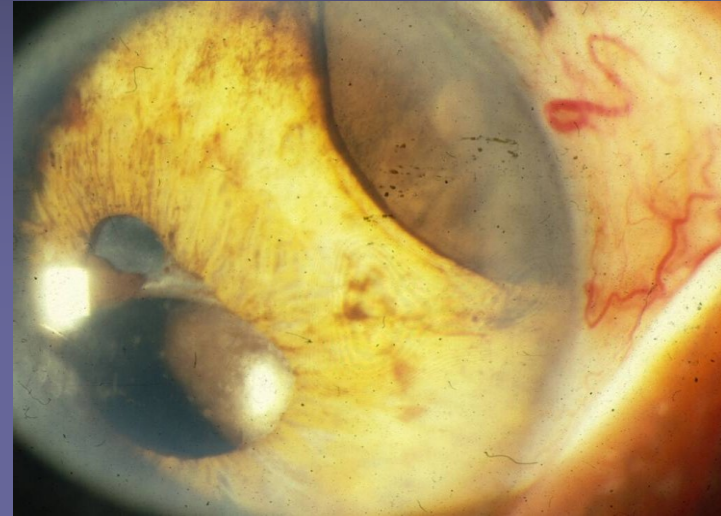
Treatment of benign and malignant lesions of the iris

- monitoring borderline findings (photographs)
- excision - in suspected lesions not overlapping 4 hours
- enucleation of the globe - susp. malignant lesions over 1/2 of the iris, blind bulb, noncorrected secondary glaucoma



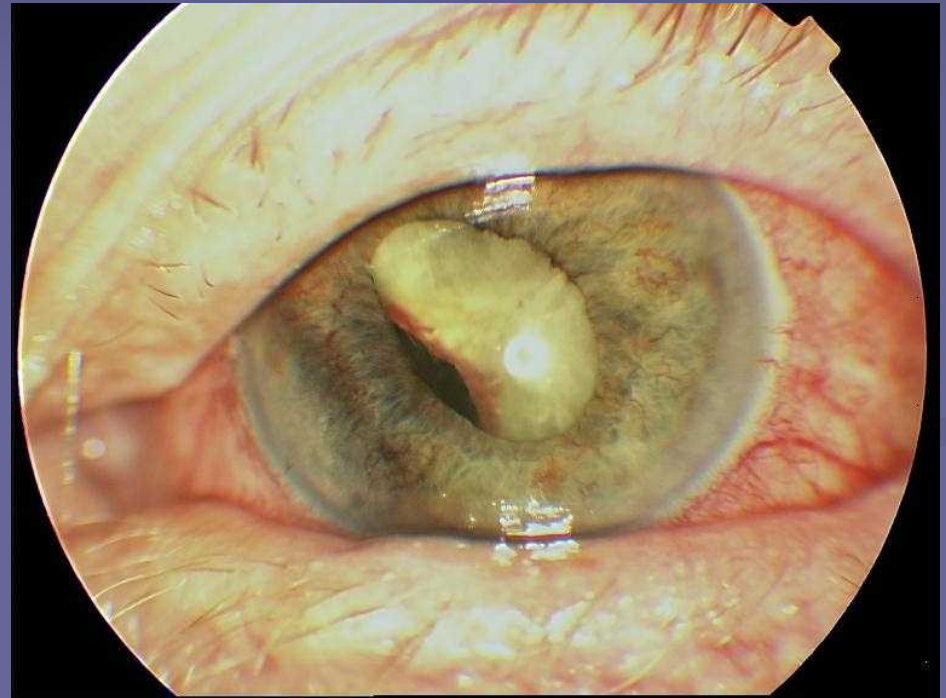
Ciliary body malignant melanoma

- long asymptomatic
- extension episcleral vessels
- pressure on the lens
(astigmatism, partial cataract, subluxation)
- secondary retinal detachment
- iris root erosion
- secondary glaucoma after initial hypotension
- epibulbar meat in place of extrabulbar extension



Diferencial diagnosis of ciliary body tumors

- tumors from the pigment and nonpigment epithelium
- cysts
- clinical indistinguishable

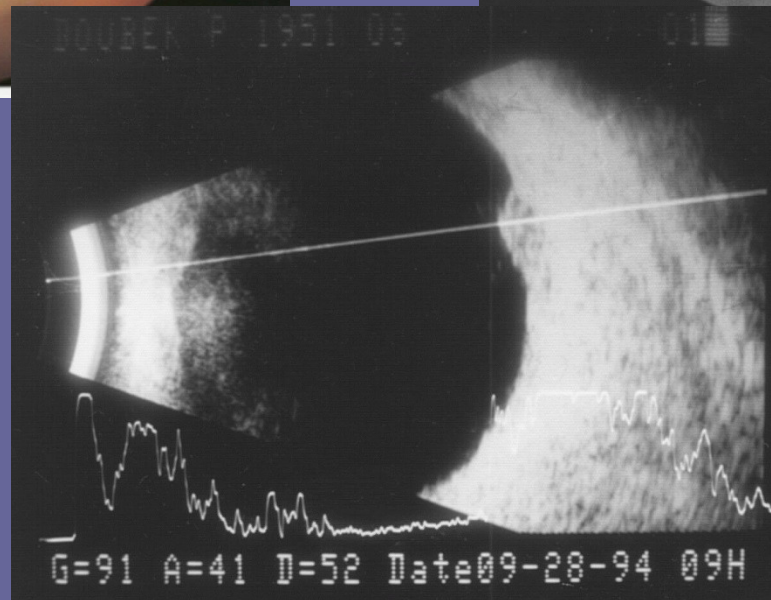
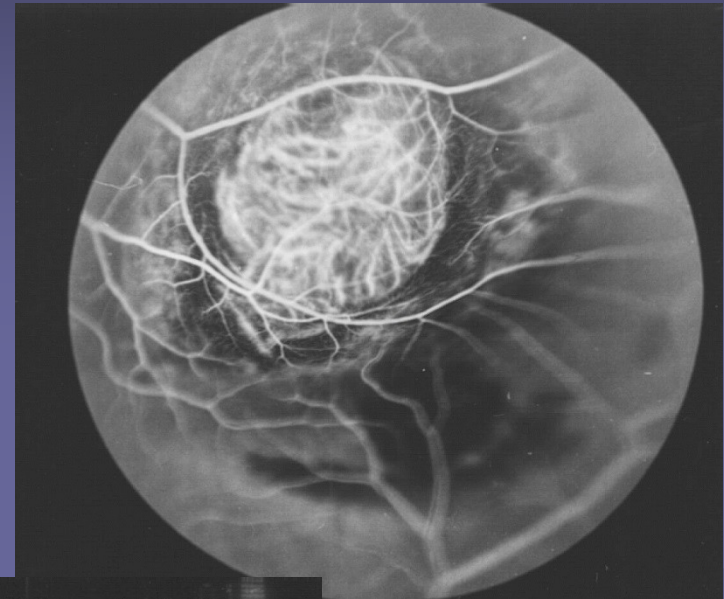
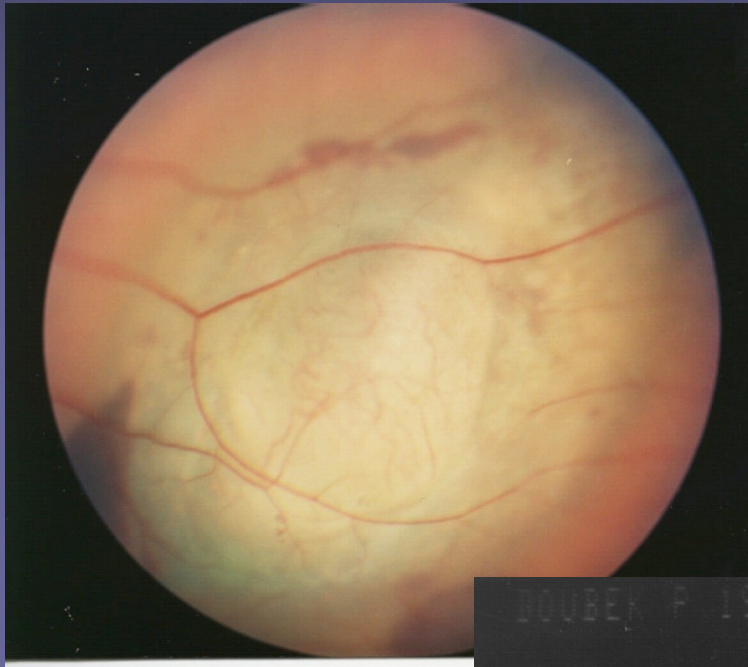


cyst of ciliary body

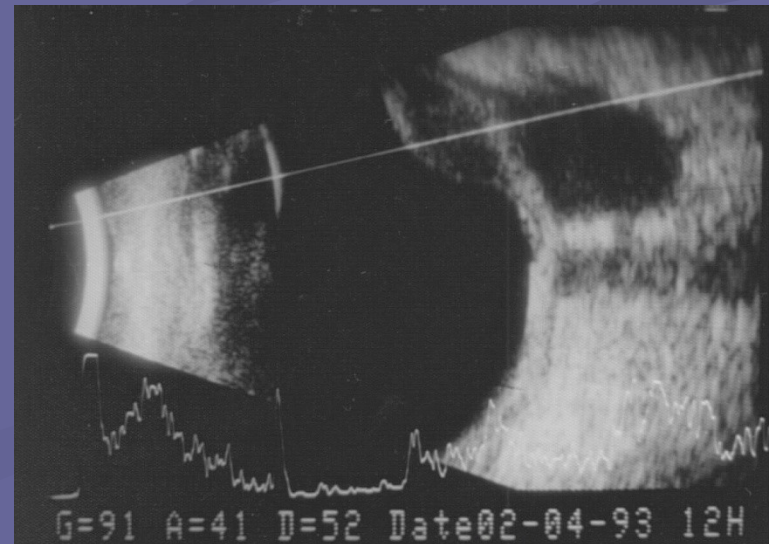
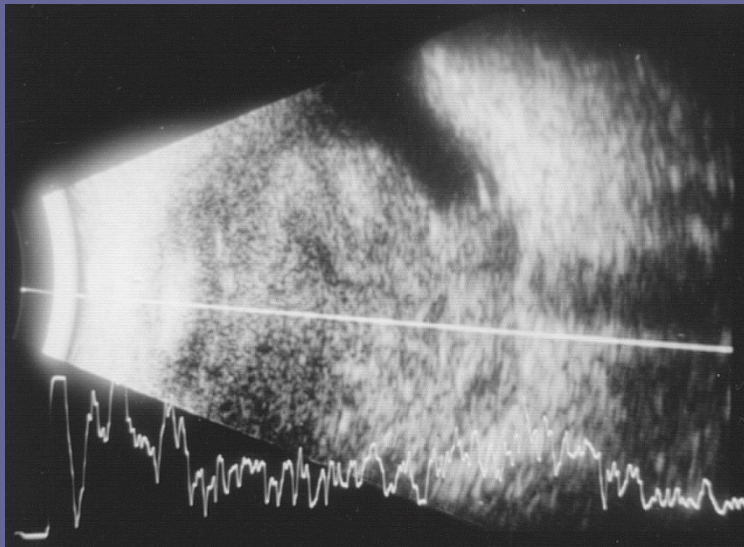
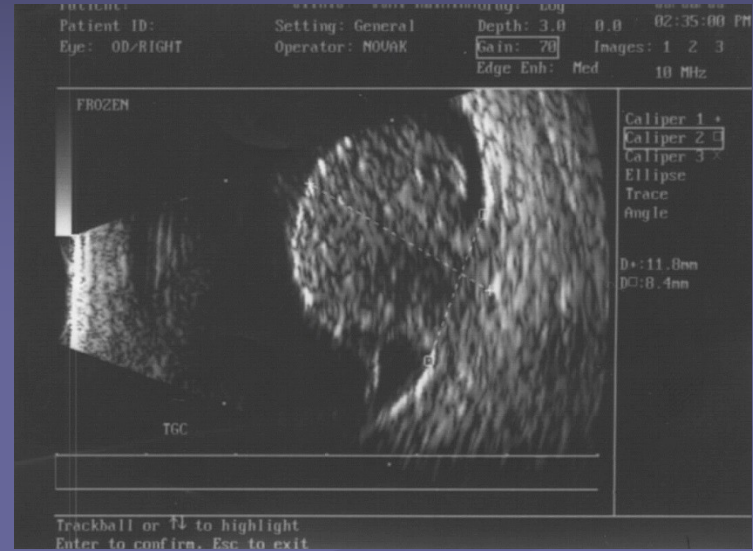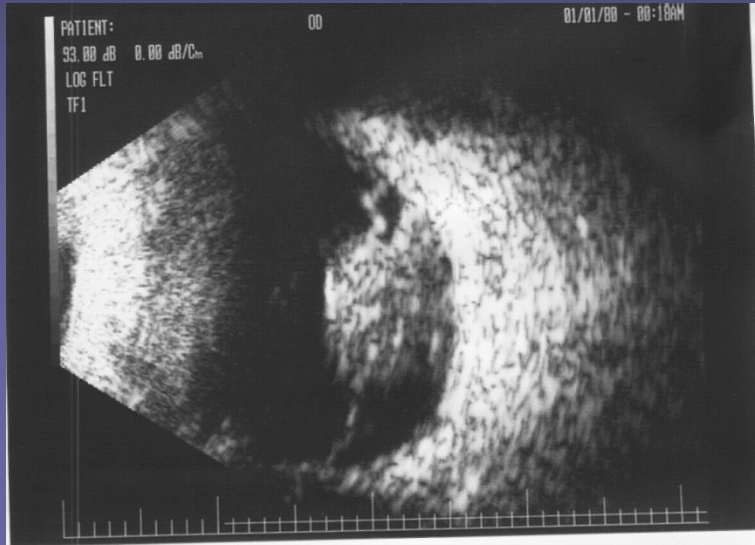Therapy of ciliary body melanomas

- cyclectomy
- iridocyclectomy
- radiotherapy - brachytherapy
 - Lexell gama knife
- enucleation

Choroidal malignant melanoma



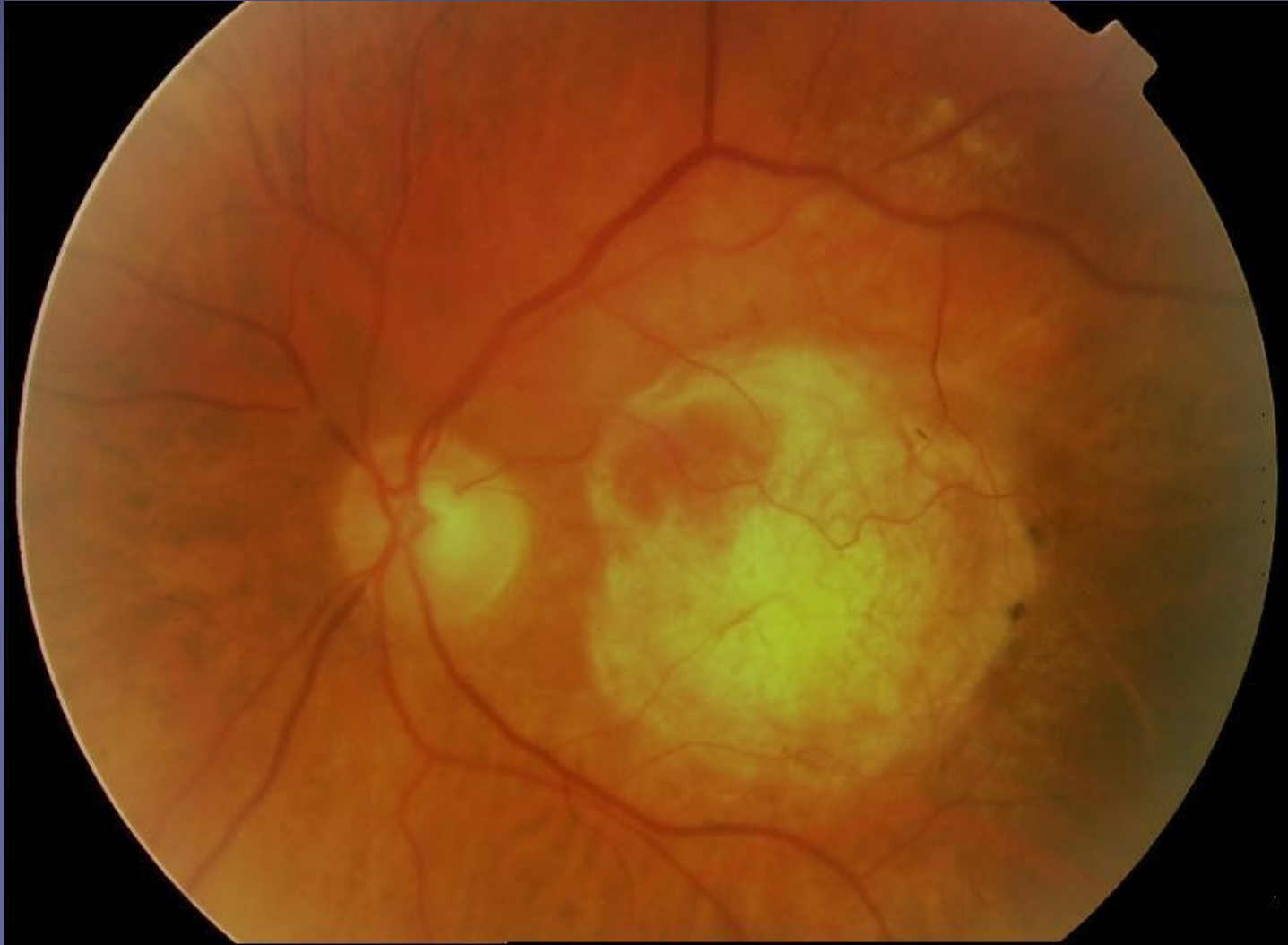
Choroidal malignant melanoma - sonography



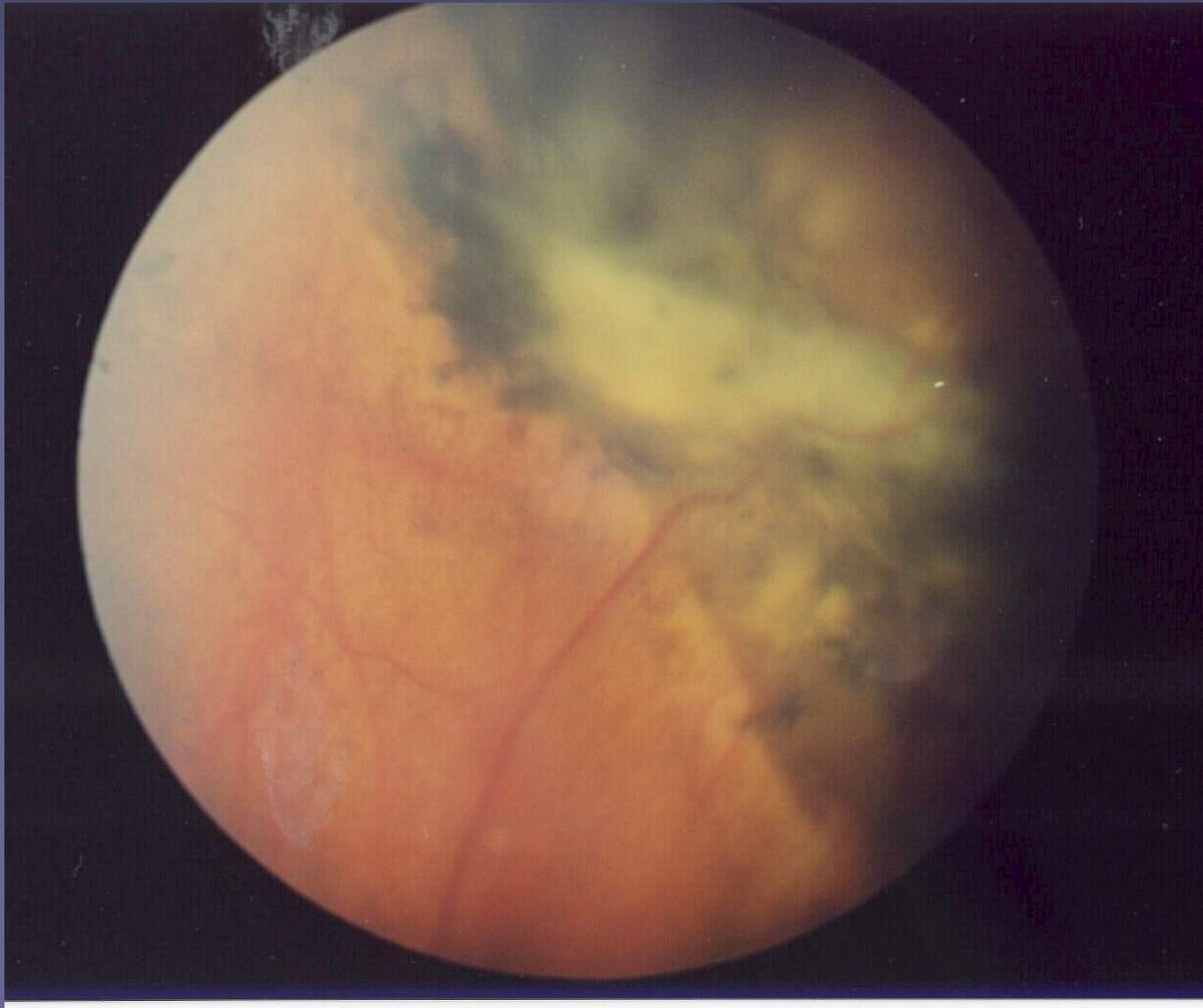
Diferencial diagnosis of choroidal lesions

- exudative form of ARMD
- chorioidal granulomatous scars
- subretinal haemorrhage
- big prominent nevi
- hyperplasia of RPE
- ablation of the choroid
- metastases
- cavernous hemangioma
- rear scleritis
- melanocytoma
- retinoblastoma

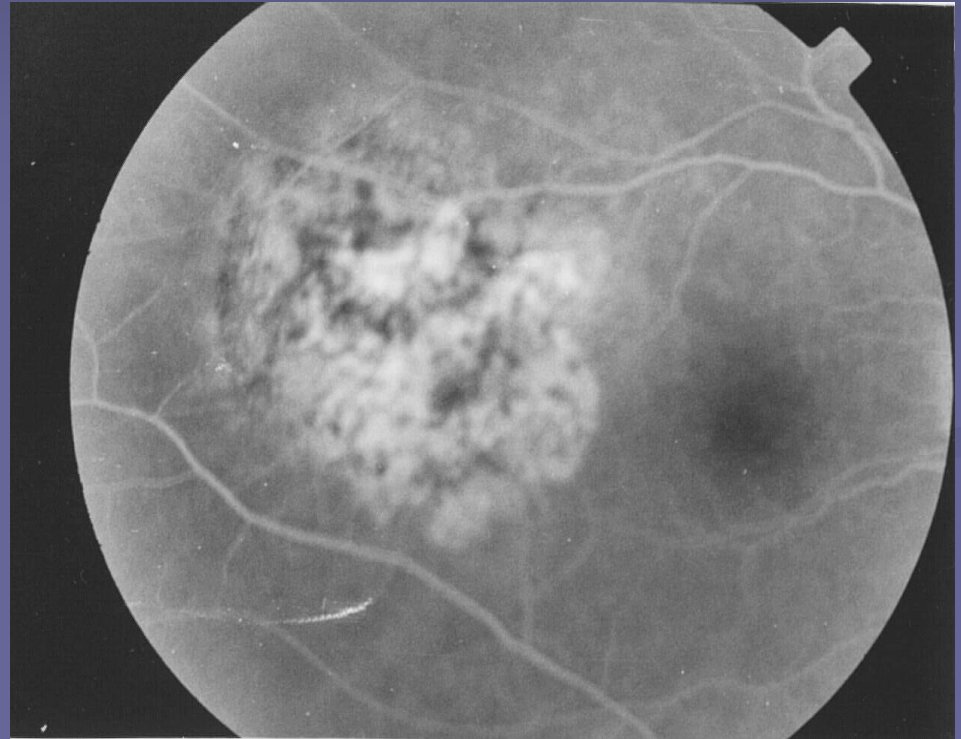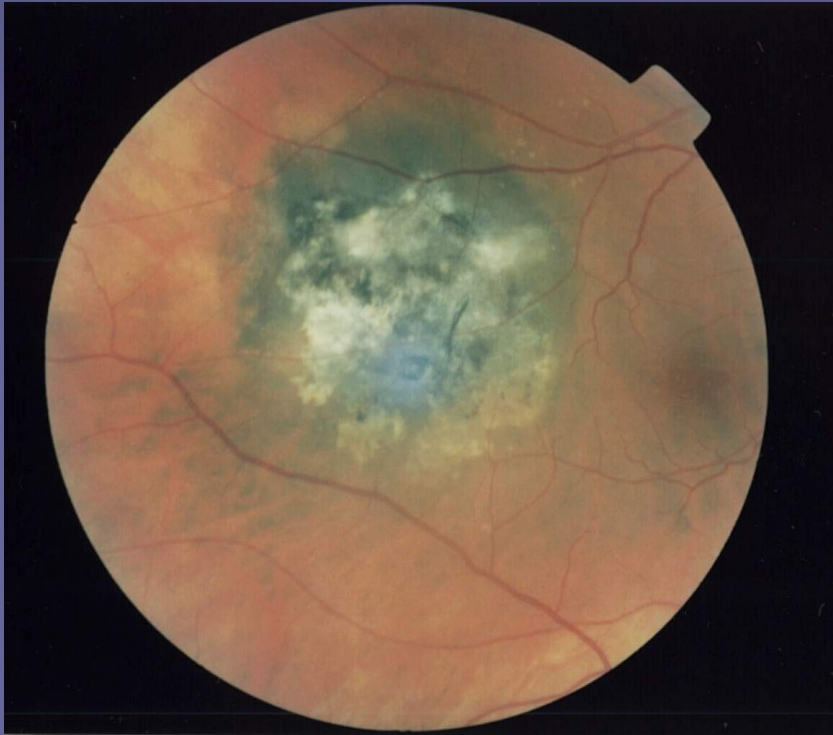Age related macular degeneration



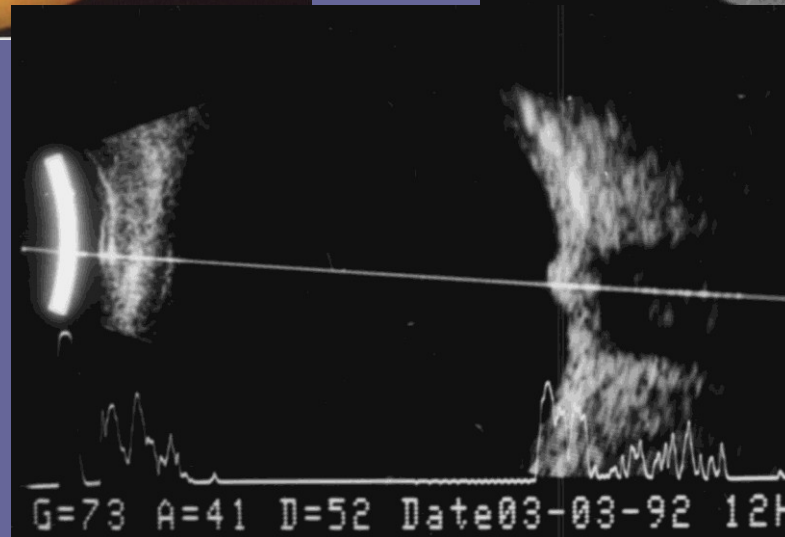
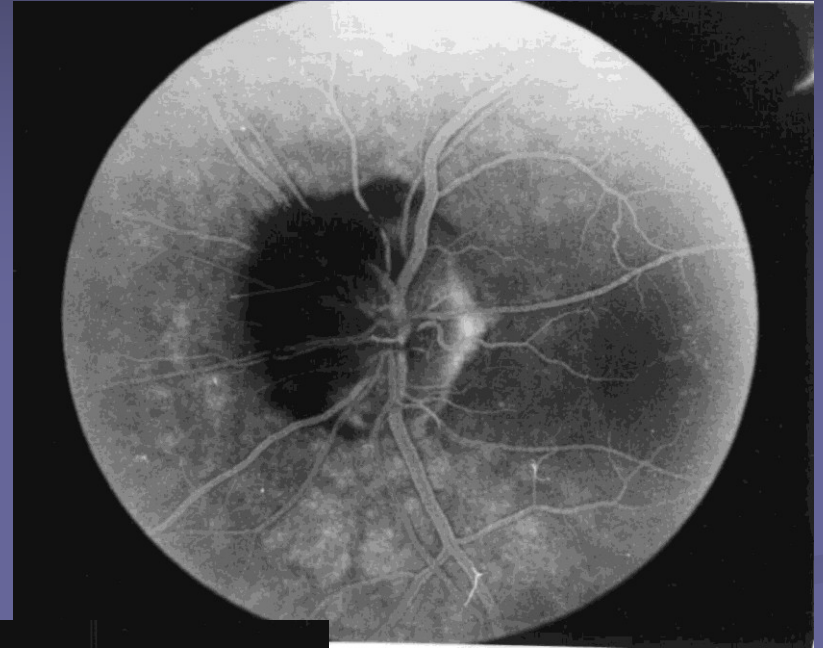
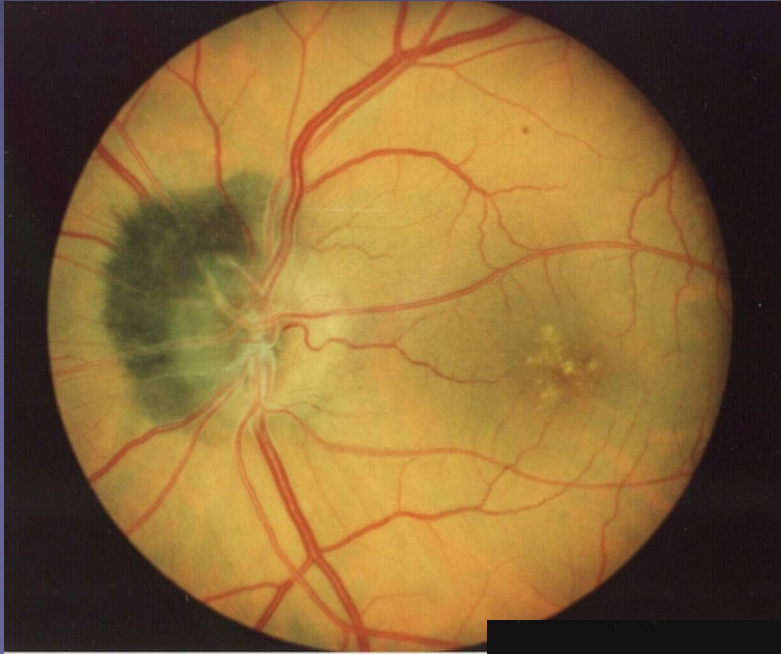Chorioidal exudative scar



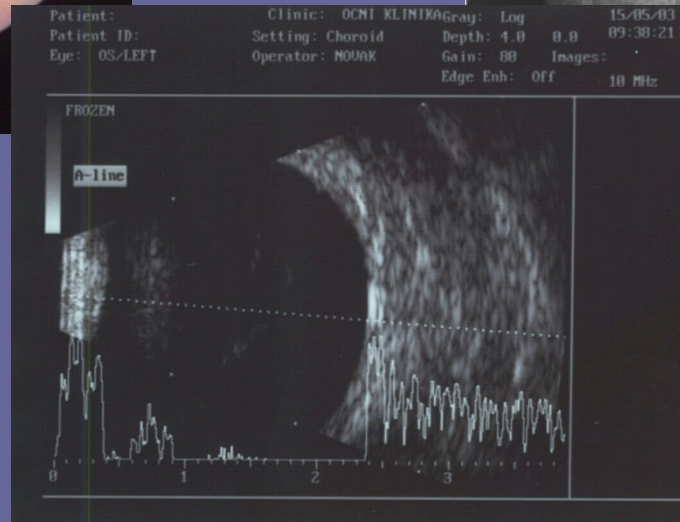
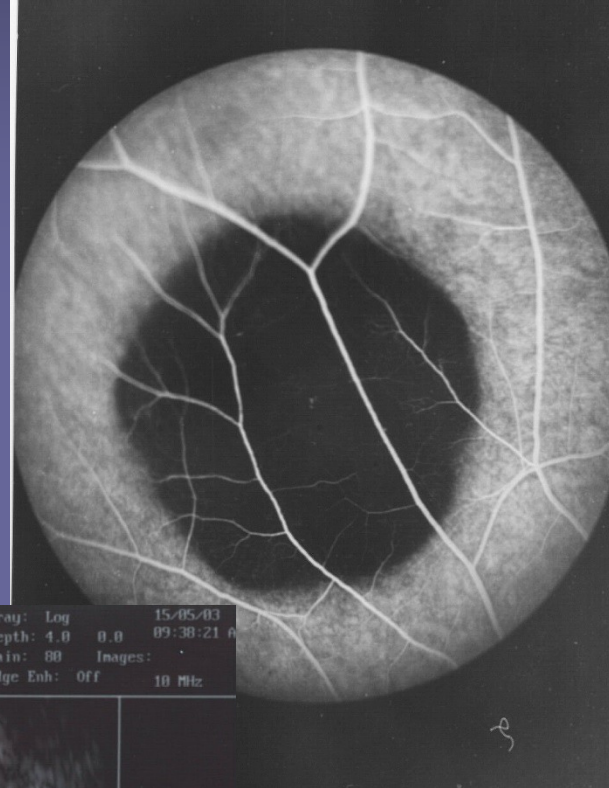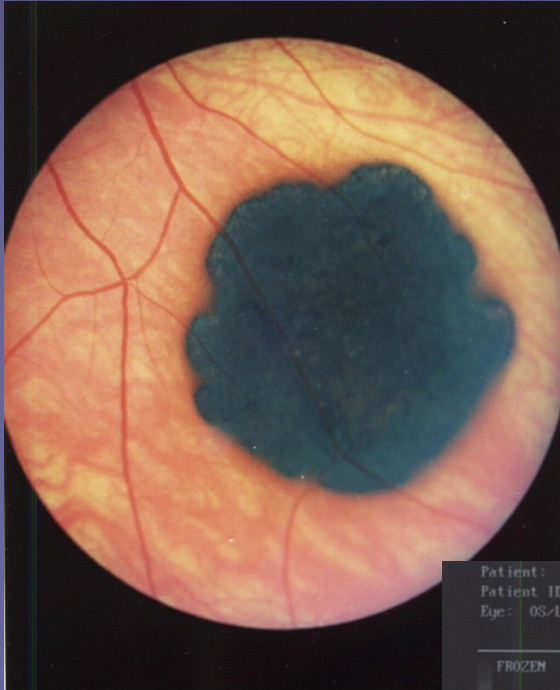
Choroidal Névi



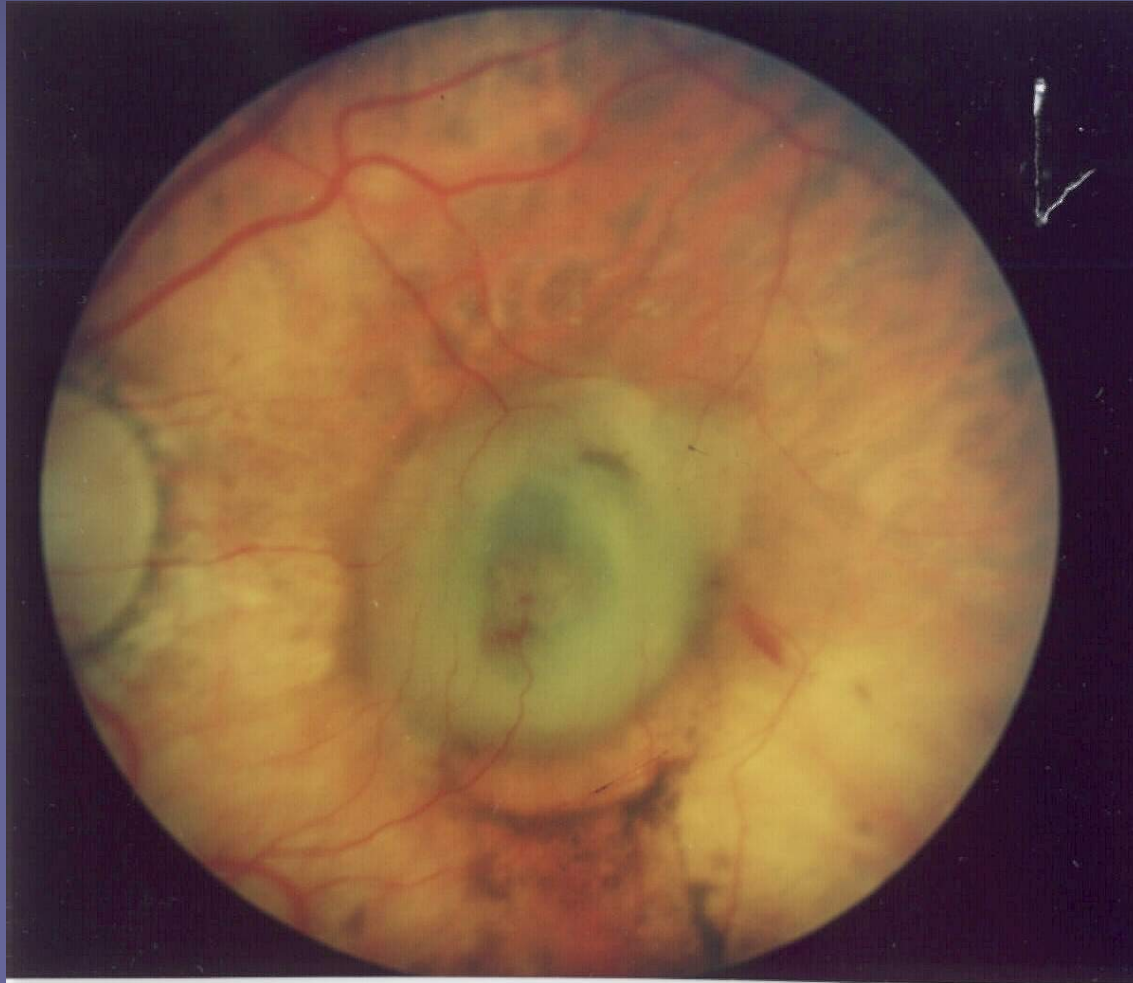
Melanocytoma



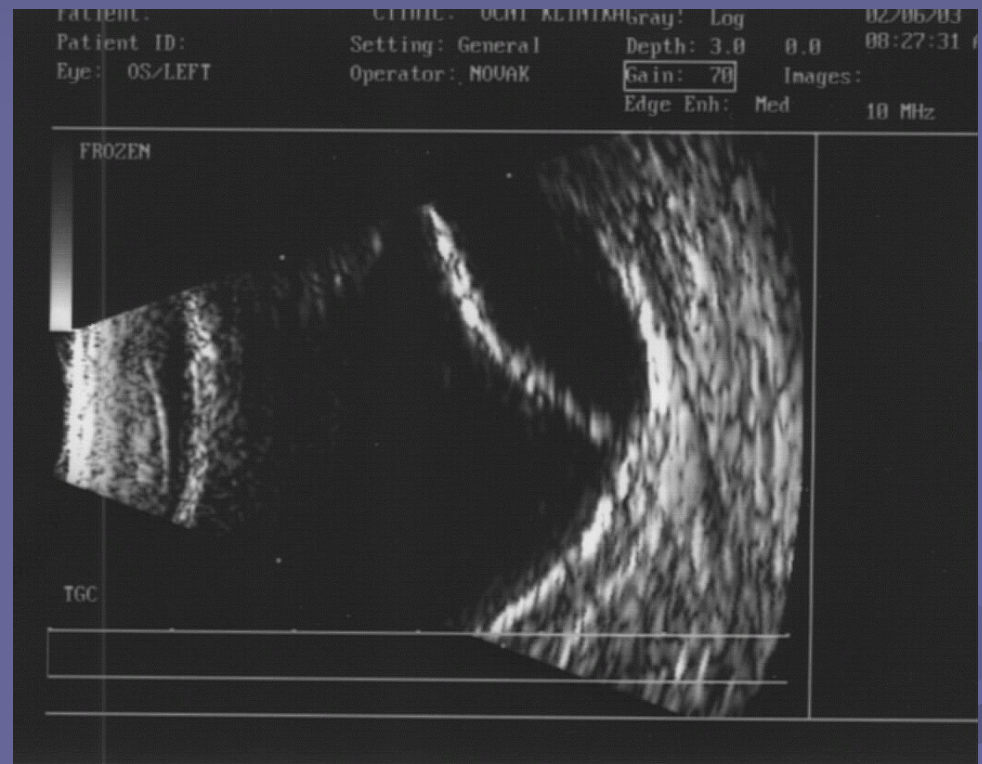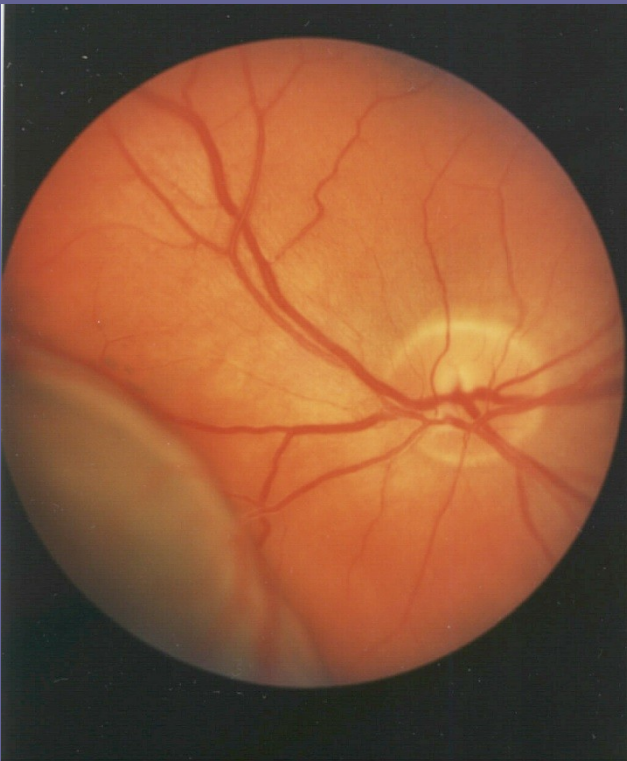
RPE congenital hyperplasia



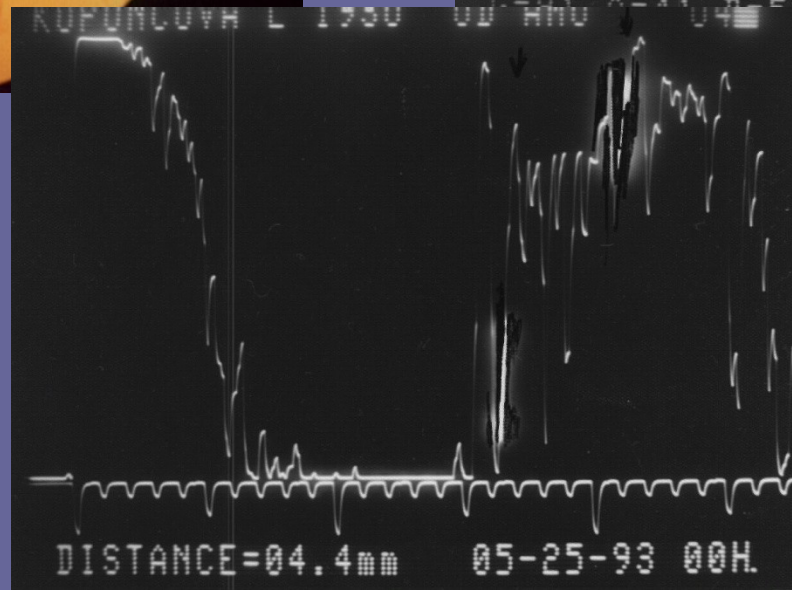
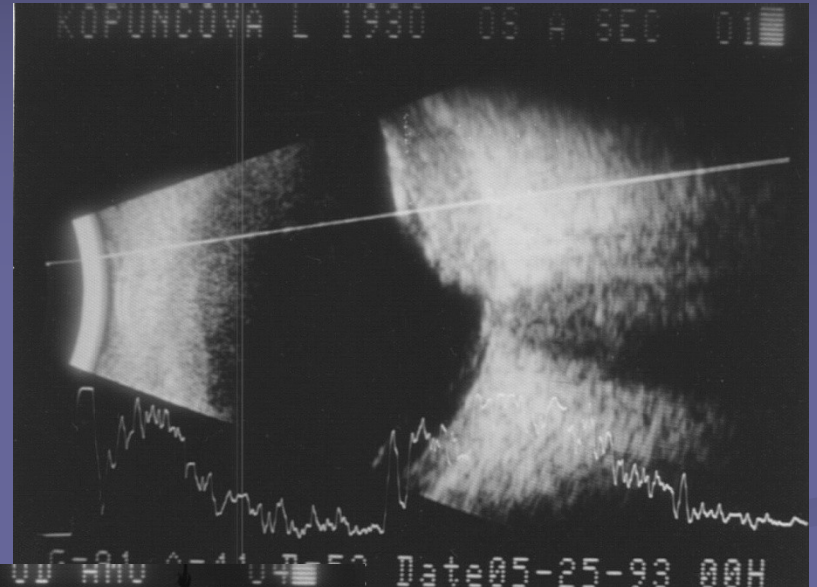
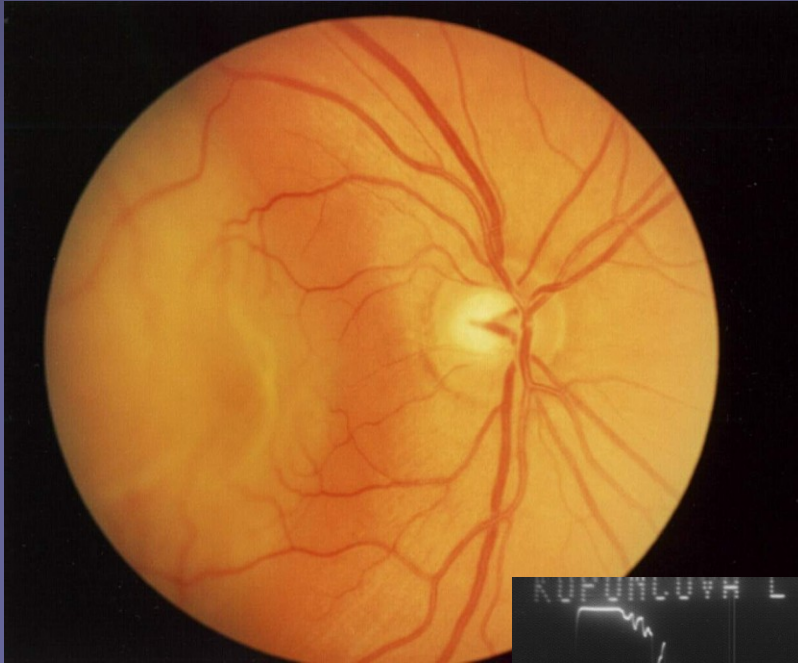
Organization of subretinal haemorrhage



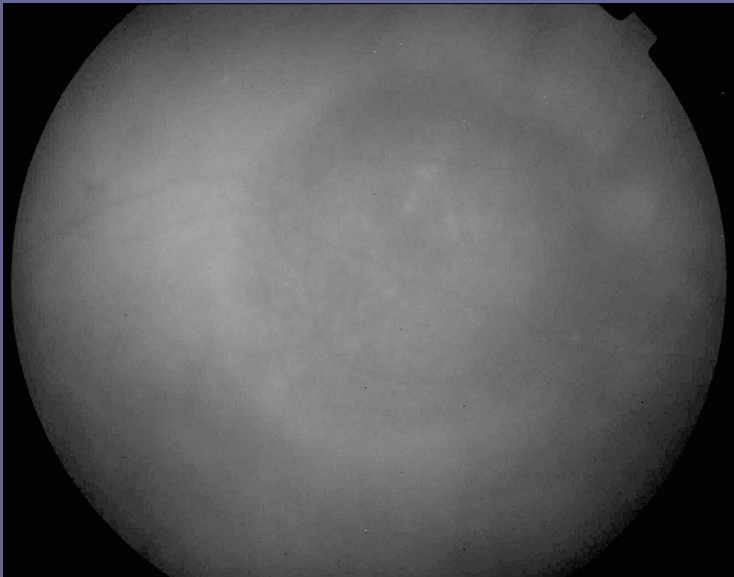
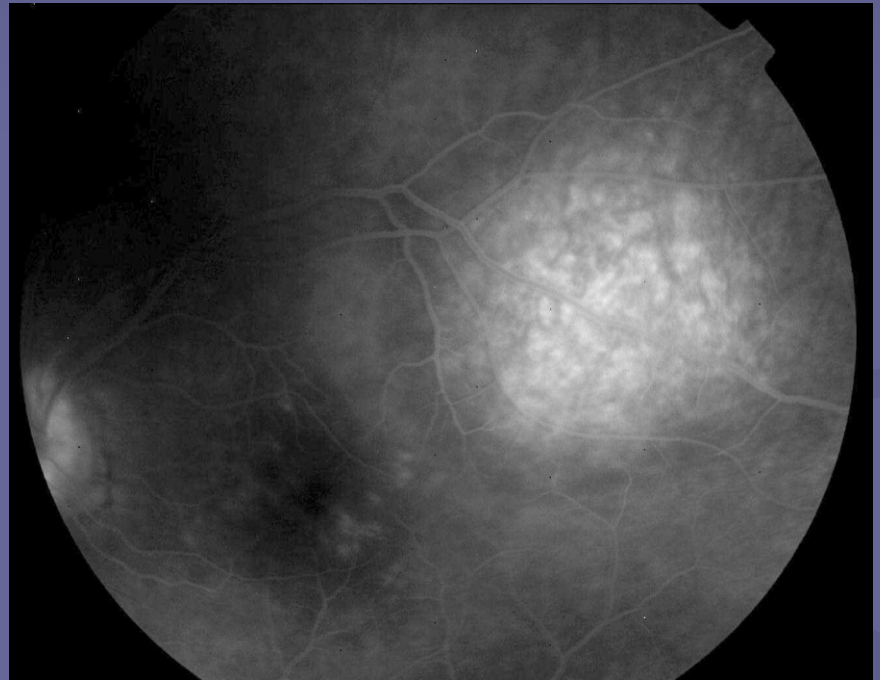
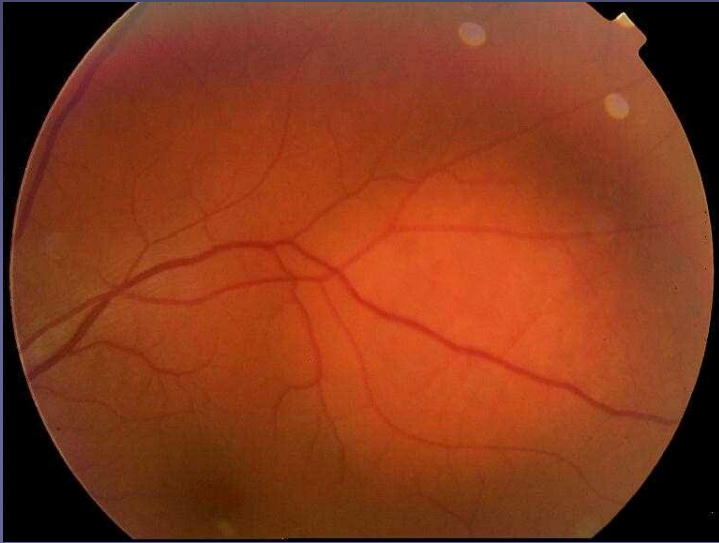
Ablation of the choroid



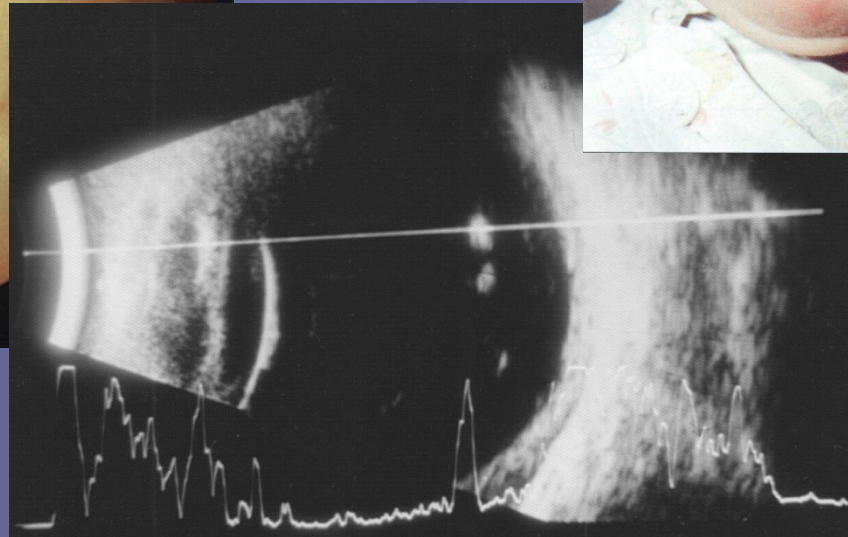
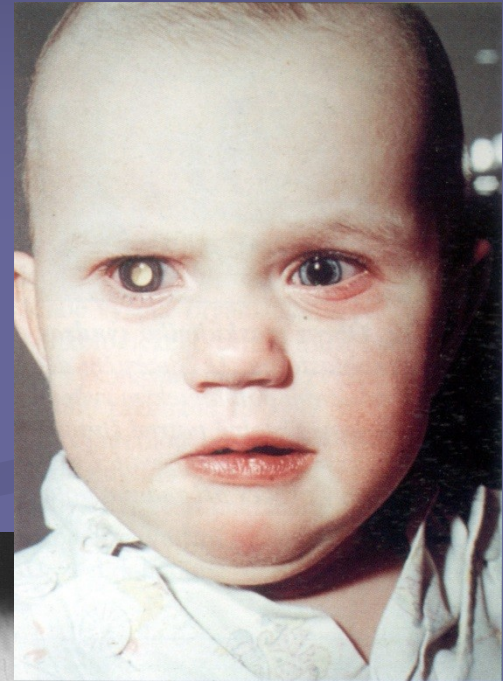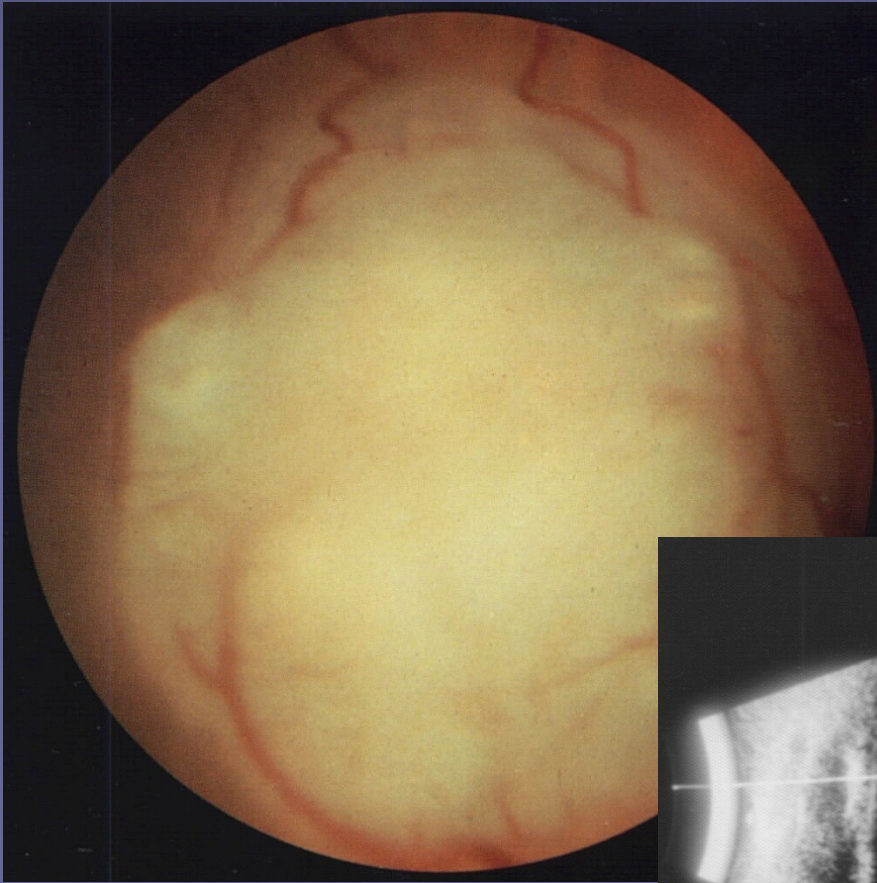
Choroidal metastasis



Choroidal hemangioma



Retinoblastoma – most common intraocular tumor in childhood



Histological classification according Callender

- spindle type A
- spindle type B
- epithelioid
- mixed
- fascicular

Prognosis quad vitam according histological type of the tumor:

- Spindle type A: mortality 5% in 5 years
- Spindle type B: 14% in 5 years
- Epithelioid type: 69% in 5 years
- Necrotic type: until 50% in 5 years

Prognostic factors MM

- cell type
- size
- localization
- Bruch membrane state
- extrabulbar extension

Metastases

At the time of finding the MMU has about 11% of metastases simultaneously.

Most common localization and % behalf:

- liver 60-70
- subcutaneus 24
- lungs 7
- spine 7
- CNS 2

Signs of tumor activity

Nonactive lesions

- inaccurately bounded
- occurrence of drusen on the surface

Active lesions

- documented growth
(measured by ultrasound)
- bounded elevation
- breaking Bruchs membrane
- production of SRF
- occurrence of lipofuscin on surface of the tumor

Size of the tumor – classification by Shields

- melanomas to 3mm
- melanomas to 5mm
- melanomas to 10mm
- melanomas above 10mm

Therapy of choroidal MM

- Photocoagulation
- TTT
- Photodynamic therapy
- Radiotherapy
- Brachytherapy
- Lexell gama knife
- Parcial resection of the tumor
- Enucleation of the bulb
- Exenteration of the orbit

Brachytherapy

Indication

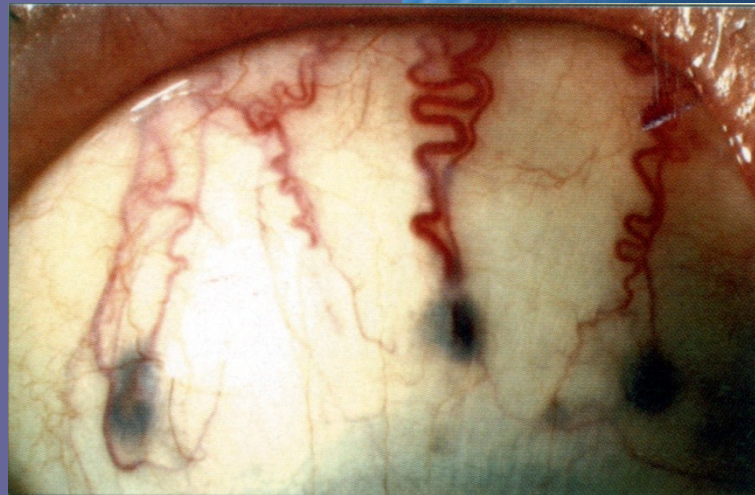
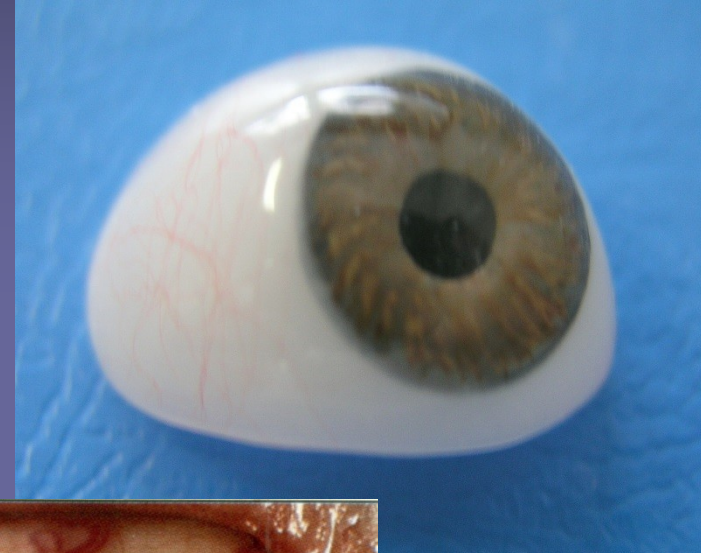- Height to 10 mm
- Bases to 15 mm

radioactive source ^{106}Ru




Enucleation of the bulb

- height above 8-10 mm
- bases above 15 mm
- small range extrabulbar extension
- blind and painfull bulbs with secondary glaucoma




Enucleation of the bulb



Exenteration of the orbit

Indications:

- retrobulbar extension of the tumor
- significant peribulbar extension of the tumor



Dispensary

In a subsequent patient care is extremely important collaboration between an ophthalmologist, internal physician and oncologist who will decide on possible further therapy (cytostatics, interferon ...).

Conclusion

The aim of all us ophthalmologists is that intraocular tumor was detected in time.

Tumors of the orbit

A separate group of cancers with similar ocular manifestations.

Symptoms:

- changes in the position of the eye - the eye protrusion or deviations
- double vision (binocular diplopia)
- eyelid symptoms - edema of the eyelids, drooping of the eyelid
- swelling and redness of the conjunctiva
- pain - a frequent symptom! (from oppression, sec. glaucoma)
- decrease in visual acuity from the oppression of the optic nerve
- visual field changes

Tumors of the orbit - distribution

Primary – primary formation in orbit tissues

- **Benign** - inflammation pseudotumor, vascular – **hemangioma**, lacrimal gland adenoma
- **Malignant** - **primary lymphoma, rhabdomyosarcoma**, meningioma of the optic nerve, lacrimal gland and sac adenocarcinoma

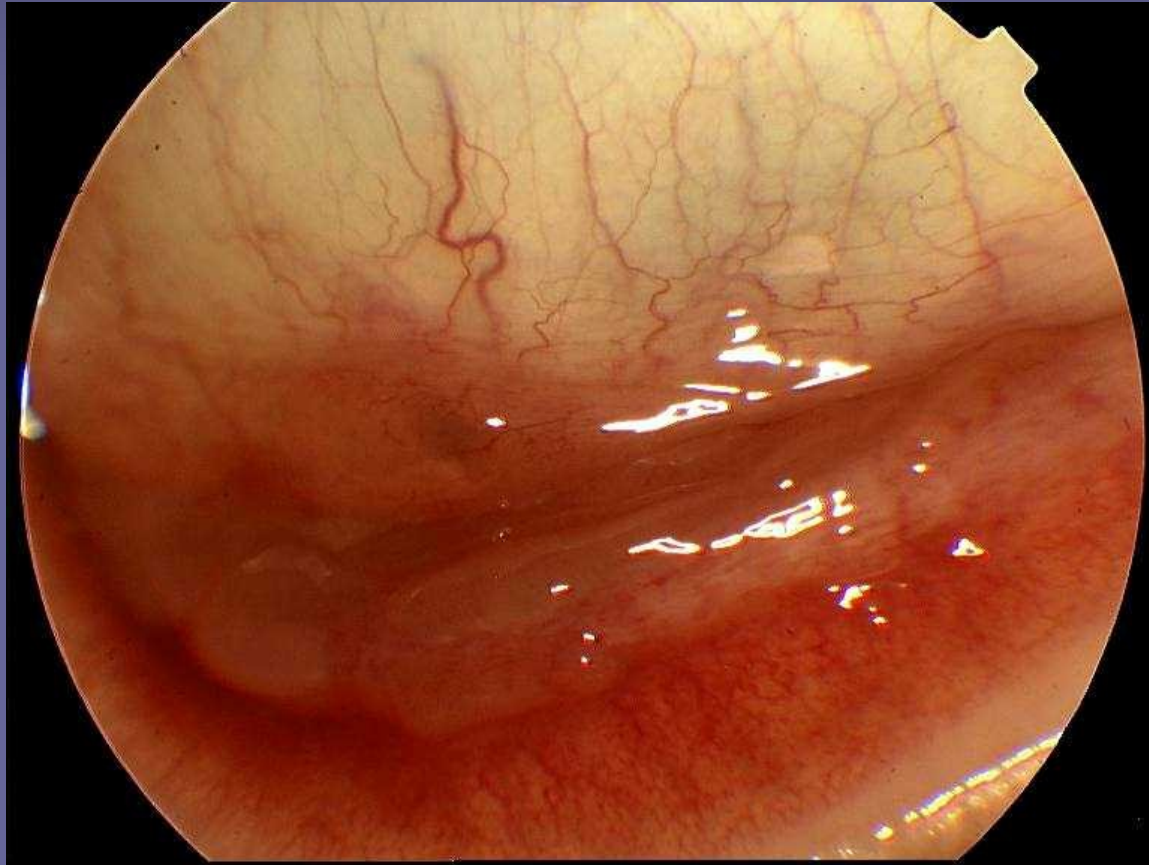
Secondary – ingrowth from sinuses and CNS

- **Benign** - dermoid cysta, mucocele and pyocele
- **Malignant** – sinuses carcinoma , wedge bone meningioma, conjunctival and uveal malignant melanoma, eyelids carcinoma

Metastatic – blood or lymphatic vessels

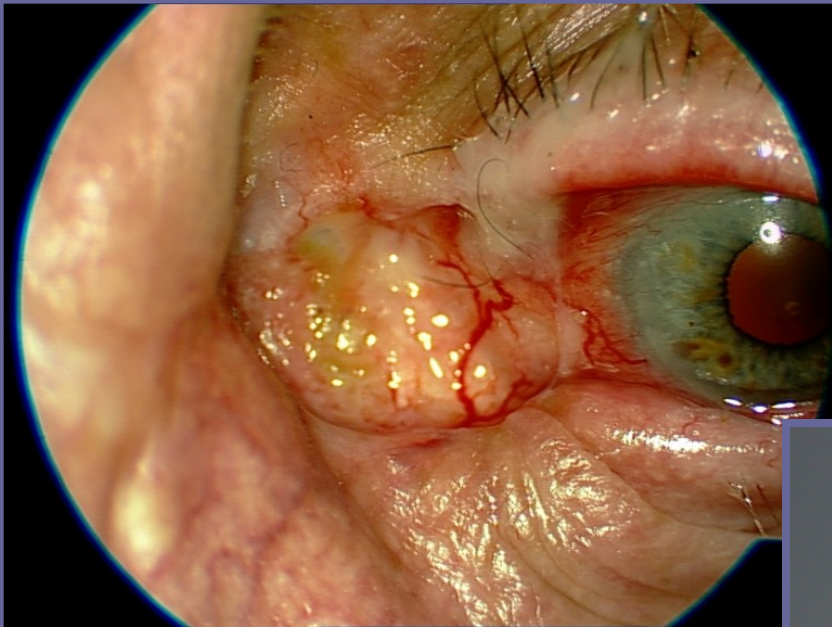
- **always malignant** – bronchogenic carcinoma, breast carcinoma, GIS carcinoma, haemoblastoma

Primary tumors of the orbit



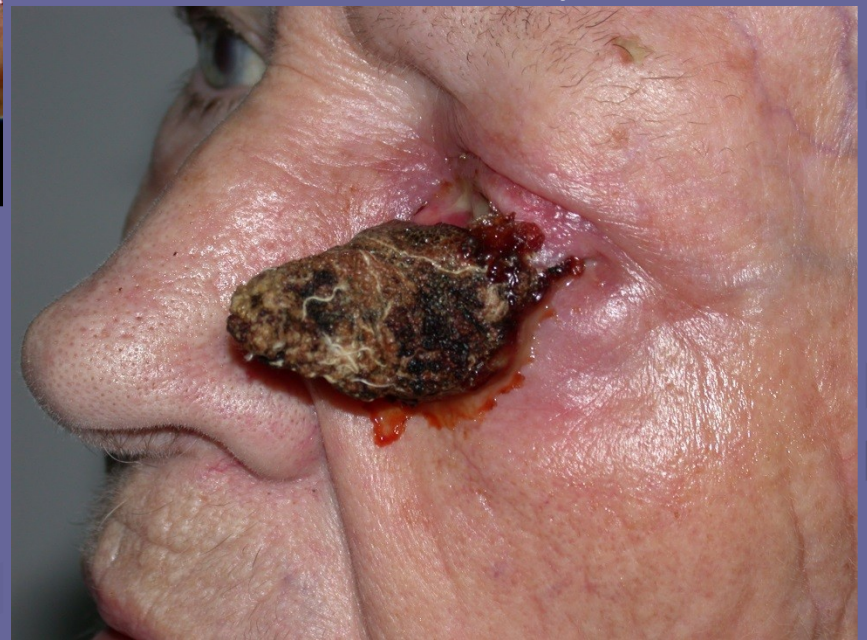lymfoma of the orbit

secondary tumors of the orbit

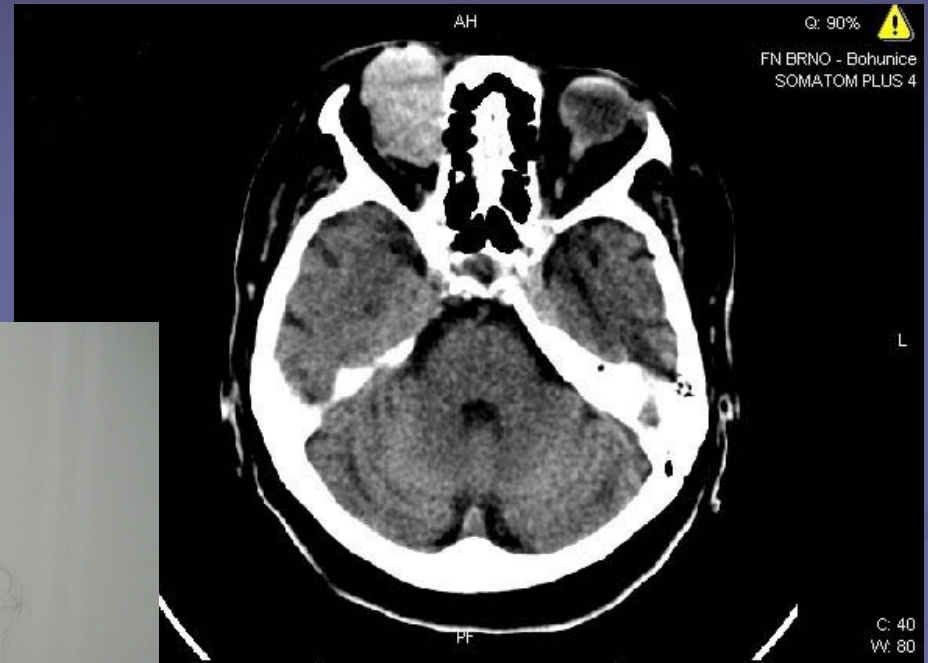
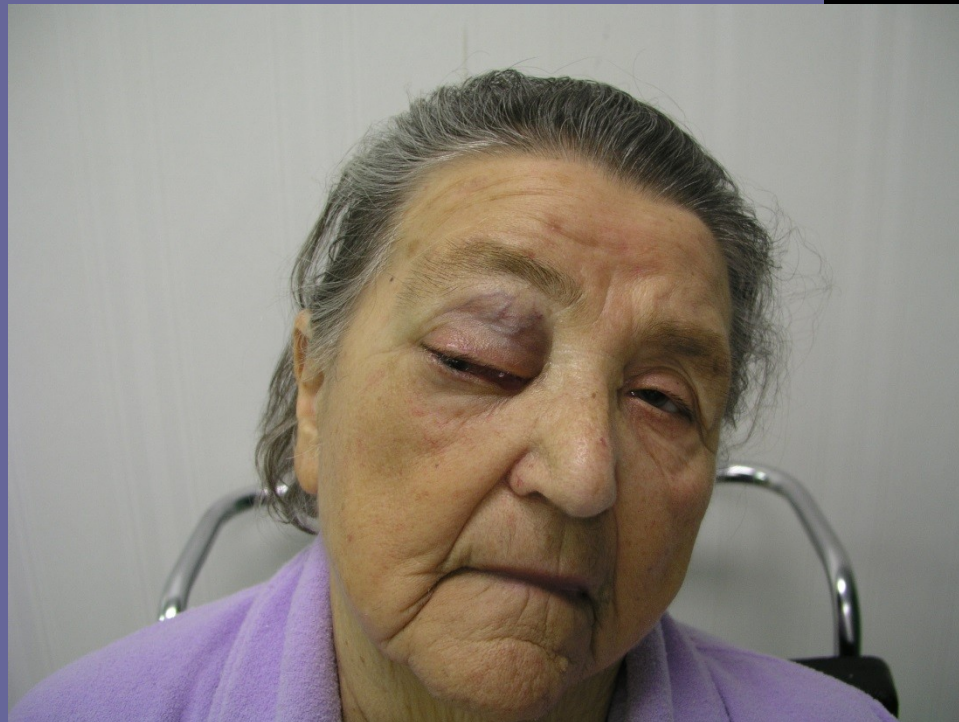
adenocarcinoma of the orbit

bazalioma of the orbit



Metastatic tumors of the orbit



Diagnostics of orbit tumors

- **Complet ophtalmological examinatin**
- **Radiodiagnostic methods** - RTG, CT, NMR,
Digit. substr. angiografie
(morphology of the lesion in PNS or CNS)
- Biopsy**
- **Interdisciplinary cooperation**

Treatment of oncological diseases of the orbit

Surgery (interdisciplinary cooperation)

- extirpation (boundad lesions)
- extirpation with resection of surrounding structur
- exenteration of the orbit without or with resection of PND

Radiotherapy

- primary (lymfoma of the orbit, pseudotumors)
- aditiv

Combined

- surgery with radiotherapy or chemotherapy

Conclusion

Early diagnostics of cancer, using modern diagnostic procedures and treatments, will allow patients to survive without abusive surgical procedures while retaining their eye and maintaining useful visual acuity.

Závěr

V přednášce byly použity materiály a obrazová dokumentace z následujících knih a sdělení:

- **Nádory oka a očních adnex u dospělých, MUDr. Radoslava Uhmannová, *III. celostátní sjezd oftalmologické sekce České asociace sester, 10/ 2006, Brno***
- **Nádory oka, Prof. MUDr. Drahomíra Baráková, CSc. a kol., Praha 2002**
- **Maligní melanom uvey (současná diagnostika a léčba), MUDr. R. Girgle, MUDr. Radoslava Uhmannová, MUDr. Igor Vícha**
- **Enukleace bulbu, Eviscerace bulbu, Exenterace očnice, MUDr. Igor Vícha, MUDr. Radoslava Uhmannová, MUDr. Michala Karkanová**

Závěrem děkuji všem zmíněným autorům za poskytnutí jejich materiálů a všem lékařům Oční kliniky FN Brno za poskytnutí obrazové dokumentace.