

Genitourinary Tract Tumours case studies

Radek Lakomy, MD, PhD

Alexandr Poprach, MD, PhD

Ivo Kocak, MD, PhD

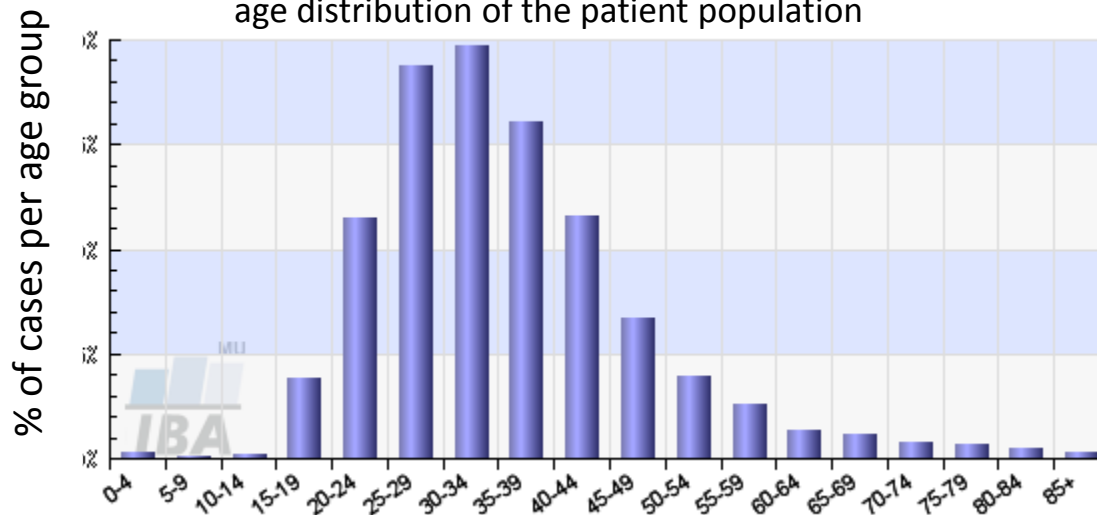
Genitourinary Tract Tumours

- Tumours of the kidney
- Tumours of the urinary bladder
- Tumours of the prostate
- Tumours of the testis
- *Tumours of the penis*

Age distribution of the genitourinary tract tumours

C62 – testis – incidence – male

age distribution of the patient population



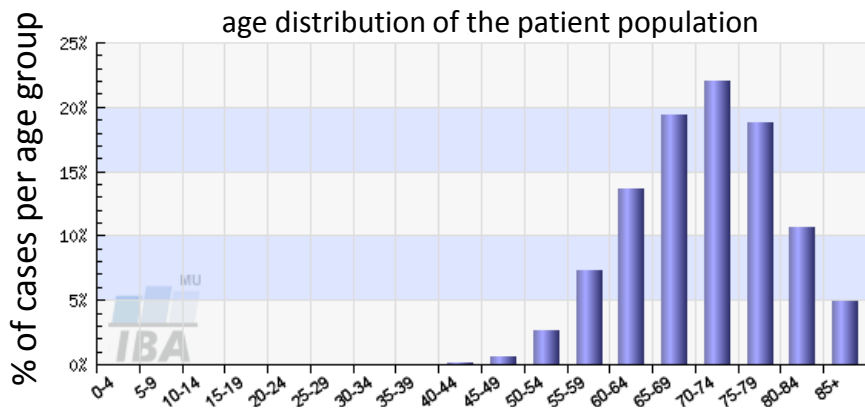
Sample size: N = 11910

<http://www.svod.cz>

Data source: UZIS CR

C61 – prostate – incidence – male

age distribution of the patient population



Sample size: N = 106410

<http://www.svod.cz>

Data source: UZIS CR

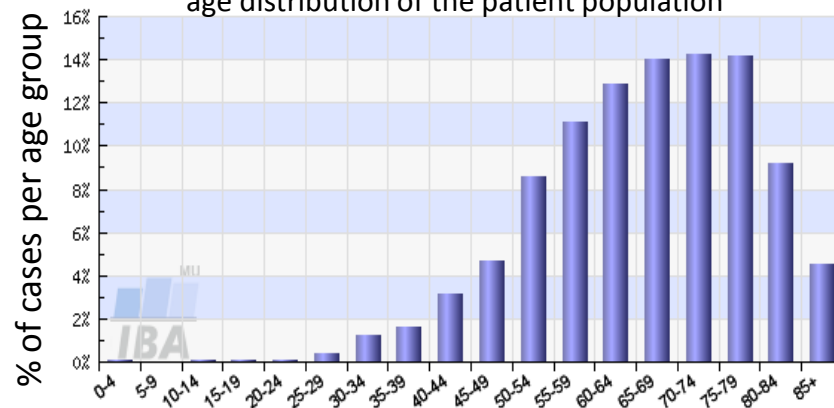
Analýzovaná data: N=69280

<http://www.svod.cz>

Zdroj dat: ÚZIS ČR

C60 – penis – incidence – male

age distribution of the patient population



Sample size: N = 106410

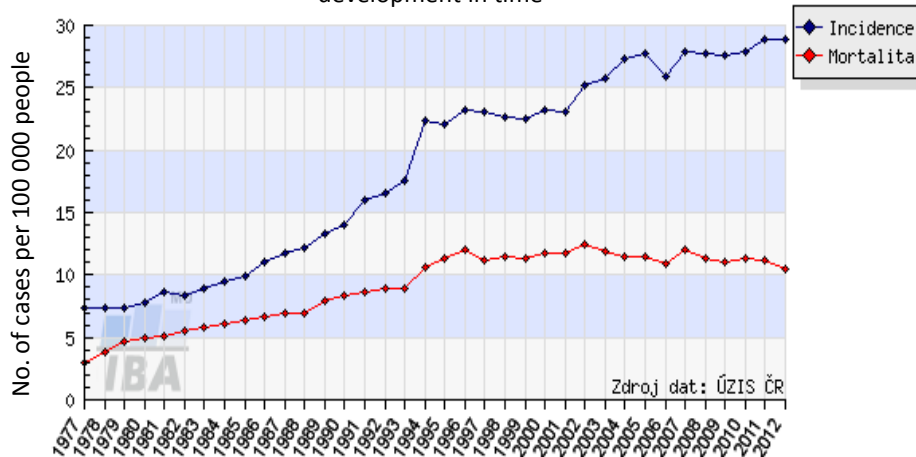
<http://www.svod.cz>

Data source: UZIS CR

Tumours of the kidney

Epidemiology and aetiology

C64 – kidney other than renal pelvis
development in time



Sample size: N (inc.) = 69280 N (mor.) = 33620

<http://www.svod.cz>

- **Sporadic forms**

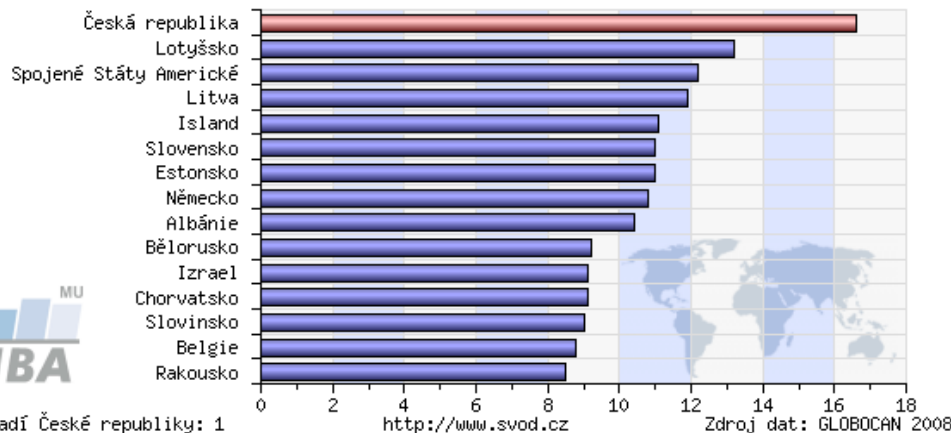
- Smoking, polycyclic aromatic carbohydrates, heavy metals, polycystic kidney, obesity, DM, hypertension

➤ 50-80 % von Hippel-Lindau tumour suppressor gene mutation

- **Hereditary forms (2-3%)**

- von Hippel-Lindau disease
 - VHL suppressor gene mutation (3p)
- Hereditary papillary renal cell carcinoma
 - MET proto-oncogene mutation (7q)
- Hereditary leiomyomatosis and renal cell carcinoma
 - FH (fumarate-hydratase) gene mutation
 - Birt-Hogg-Dubé syndrome
 - FLCN – folliculin protein gene mutation (17p)

C64 – C66 – kidney, renal pelvis and...
Comparison of incidence in CZ and other countries, ASR – global standard



Pořadí České republiky: 1

<http://www.svod.cz>

Zdroj dat: GLOBOCAN 2008

Tumours of the kidney – histological types

- **Benign tumours**

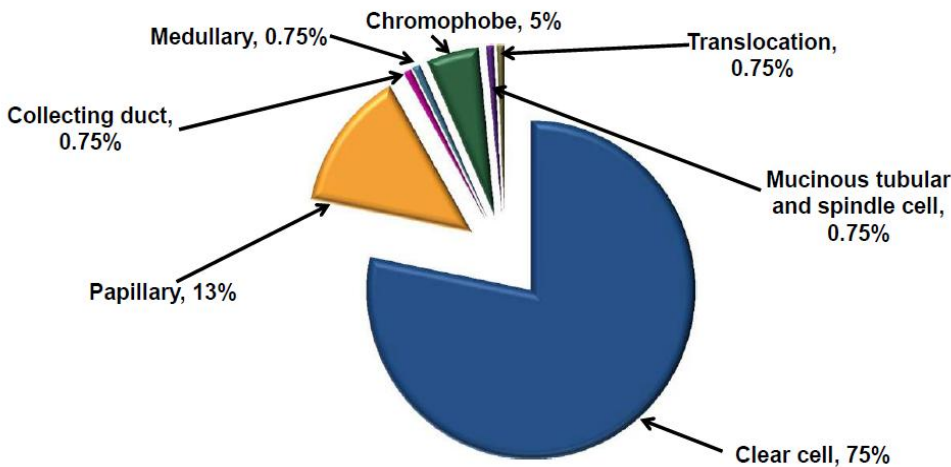
- oncocytoma, adenoma, angiomyolipoma

- **Malignant tumours**

(2% of all adult malignancies)

- Adenocarcinoma (90%)
 - clear cell carcinoma (75 %)
 - papillary Ca (10-15%)
 - chromophobe Ca (5%)
- Sarcoma
- Lymphoma
- Foetal renal tumours – nephroblastoma (Wilms tumour) – in children

☐ **Kidney tumours – often accidental finding on an ultrasound or CT scan**



1. Albiges L et al. *Oncologist*. 2012;17:1051-62.
2. Lopez-Beltran A et al. *Eur Oncol*. 2006;49:798-805.

Localized disease

- ***Surgical treatment***
 - Radical nephrectomy
 - Partial nephrectomy – preferred (pole tumours, single kidney, CRI)
- **Adjuvant treatment – none**
 - Radiotherapy, chemotherapy, immunotherapy – failure in adjuvant setting
 - Clinical studies with biological treatment (sunitinib, sorafenib, pazopanib) – also no effect on OS

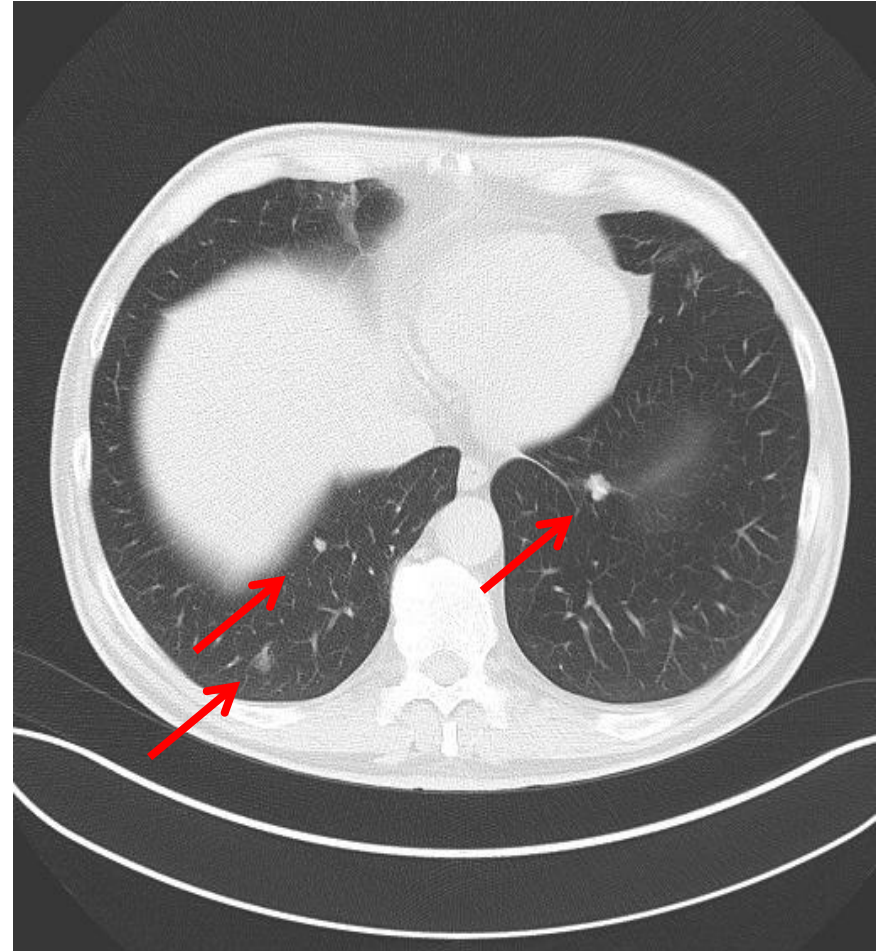
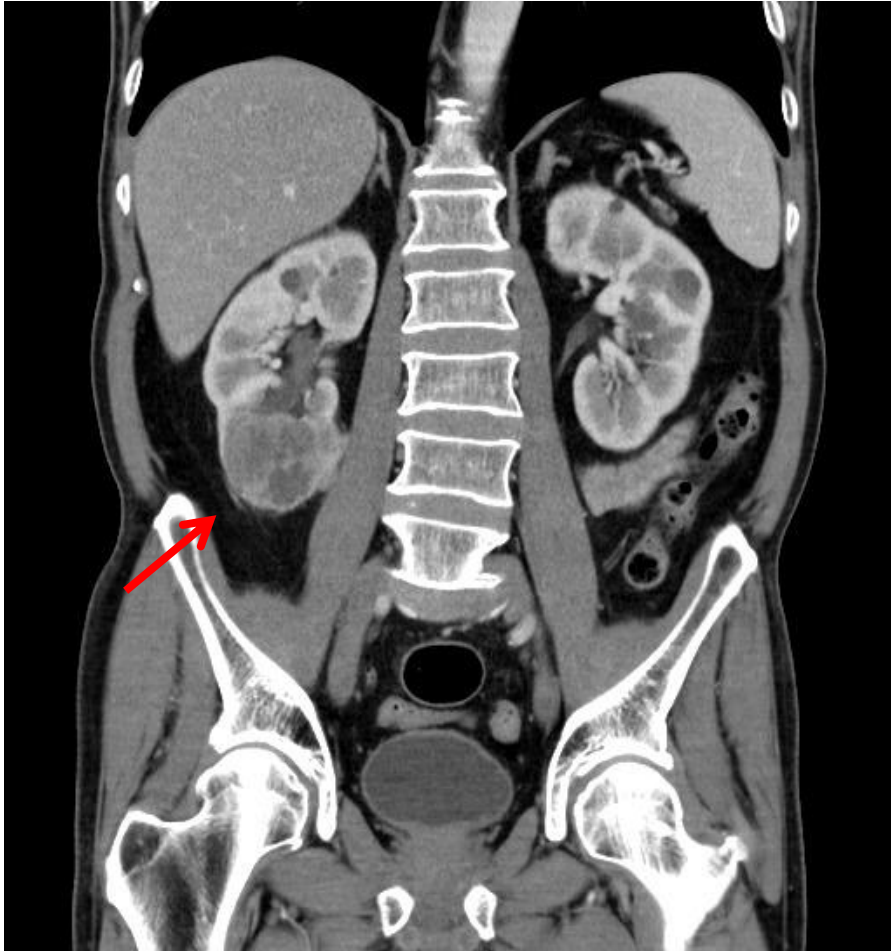
Disseminated disease

- **Targeted treatment = currently the most effective systemic treatment**
 - **tyrosine kinase inhibitors** (PDGFR alfa a beta, VEGFR 1,2,3), c-kit, Flt, RET etc.
 - angiogenesis and tumour proliferation inhibition
 - **sunitinib, sorafenib, pazopanib, axitinib**
 - **m-TOR inhibitors**
 - **temsirolimus, everolimus**
 - **monoclonal anti-VEGF antibodies** – angiogenesis inhibition, effective combination with INF alfa
 - **bevacizumab**
- **Research: modern immunotherapy with checkpoint inhibitors**
 - *Anti-CTLA-4 antibody: ipilimumab*
 - *Anti-PD-1 antibodies: nivolumab, pembrolizumab, pidilizumab*
 - *Anti-PD-L1 antibodies: atezolizumab*

Case study

- 60 years old patient, male
- FH: father died of kidney ca aged 65, mother died of stomach ca aged 82
- PH: 6/2011 haemorrhoid surgery, hypertension from 2008, otherwise healthy
- Treatments: lisinopril tablets 5mg 1-0-0
- Allergies: 0
- Social history: married, 2 children
- Occupational history: managerial position Tesco United Kingdom, currently unemployed
- Abuses: smokes 20 cig/day/40 years, currently in the process of stopping, black coffee 3/day, alcohol 0
- Symptoms – pain in the right lumbar region in 1/2012
- Ultrasound => right kidney tumour
- Staging
 - CT scan of the lungs, abdomen, pelvis in 2/2012 – tumour of the inferior pole of the right kidney 80 x 66 mm, RCC-like, small metastases in the lungs bilaterally 3 – 20 mm
 - Skeletal scintigraphy 6. 2. 2012 Faculty Hospital Motol in Prague – no evident metastases of the bones

CT before the treatment in 2/2012



Surgical treatment

- 8.2.2012 – laparoscopic radical NE I. dx., peri-surgically extensive tumour of the inferior pole of the left kidney, Faculty Hospital Motol Prague
- Histology - adenoCa renis, clear cell Ca, pT1, G 2-3
- TNM classification – pT1bNXM1 (pulm.), st. IV

Treatment in MOU

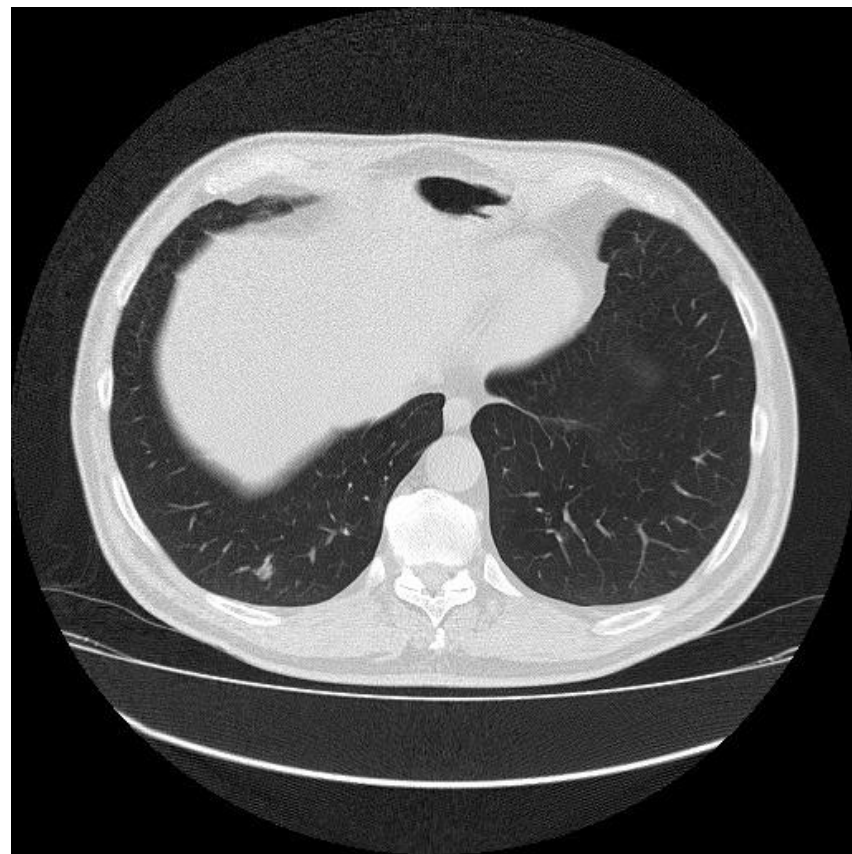
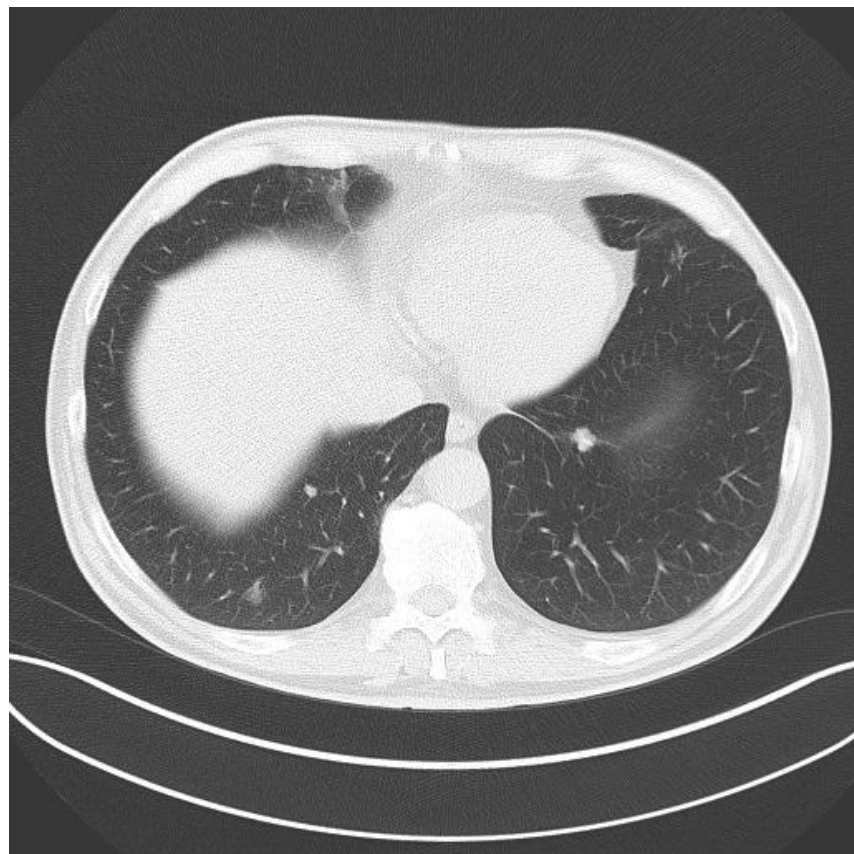
- Outpatient consultation 20.2.2012
- KI 100%, asymptomatic, surgical wound healed, laboratory investigations normal
- **MSKCC – medium prognosis**
 - **1 criterion: diagnosis < 1 year from treatment initiation**

MSKCC scoring system of 2002: valid for TKI and bevacizumab treatment
LDH > 1.5 times upper limit of normal
Haemoglobin < lower limit of normal
Corrected plasma calcium > 2.5 mmol/L
Karnofsky index ≤ 70 %
Time from diagnosis to systemic treatment initiation < 1 year

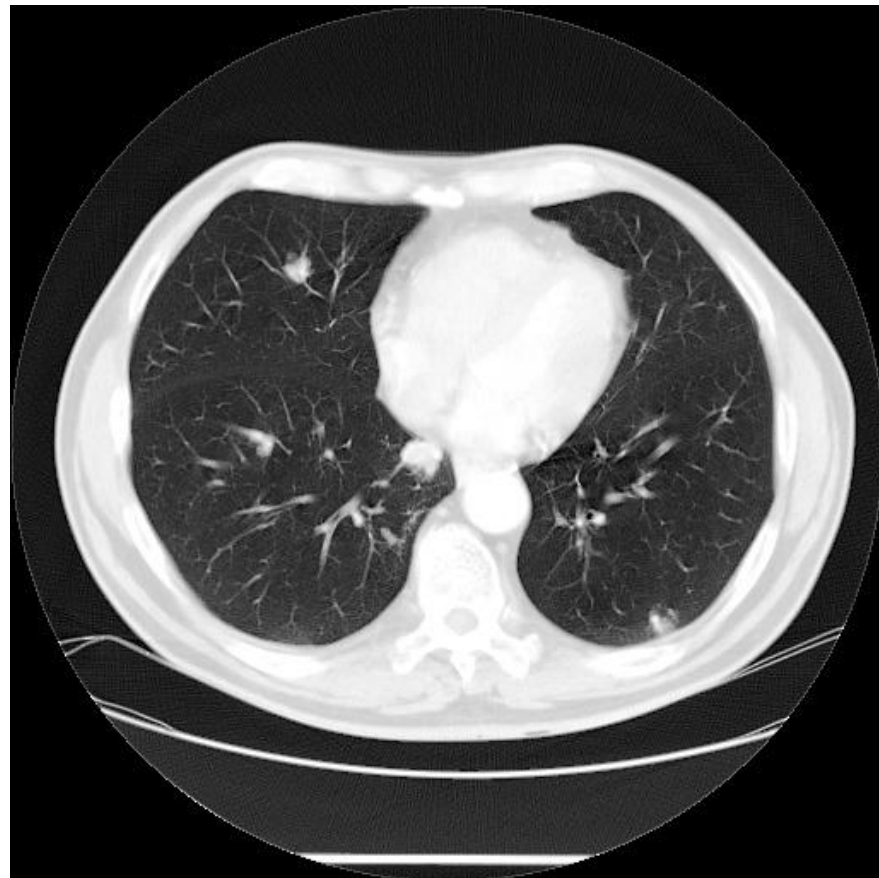
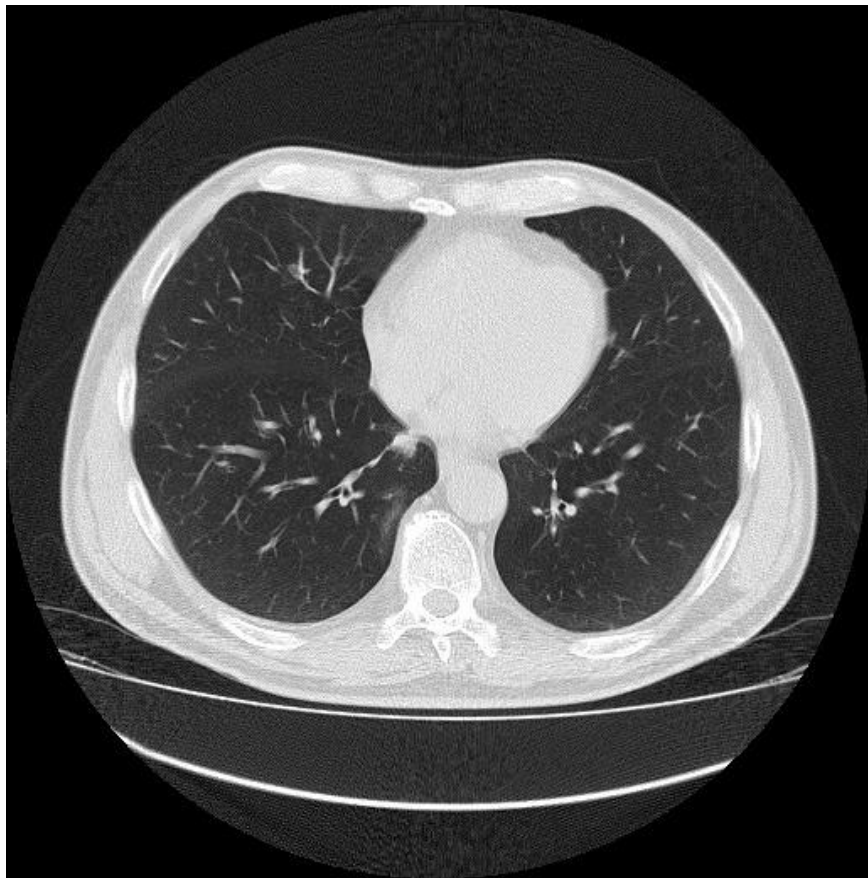
1st line treatment

- **sunitinib 50 mg/day, D1-28, every 6 weeks**
 - start day: 24. 2. 2012
- Well tolerated, no myelotoxicity
 - Only arthralgia G1, fatigue G1, hand-foot sy. G1 (from 4th cycle), hair and eyebrows going grey (from 5th cycle), hypertension corrected with 2-combination

**1st line treatment (sunitinib) – rescan after
3 cycles – partial regression of lung meta**



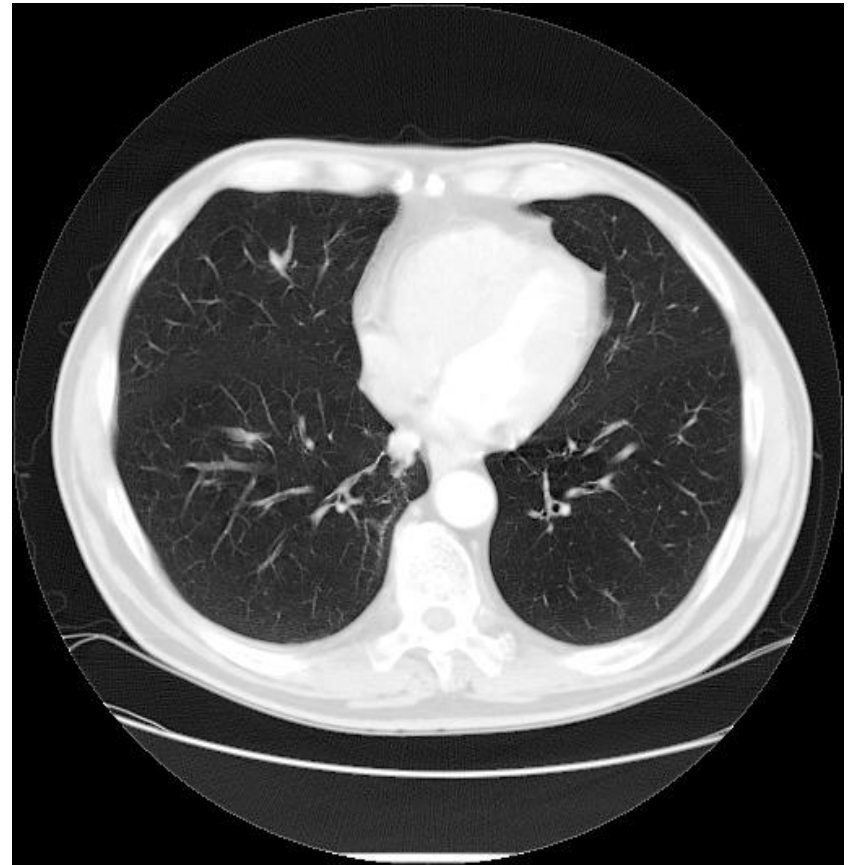
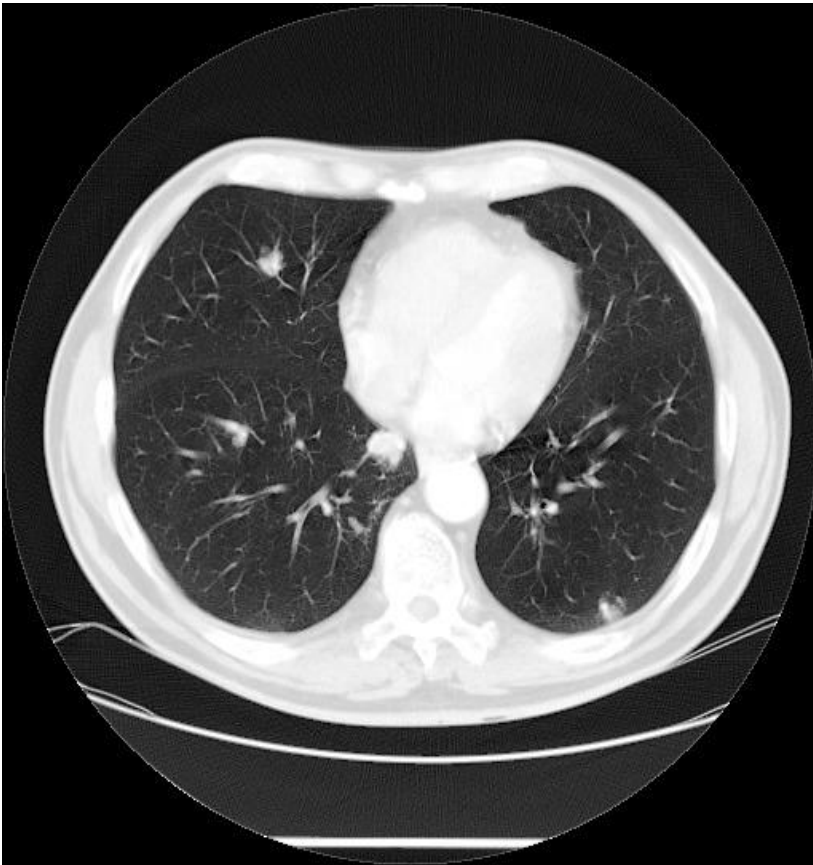
**1st line treatment (sunitinib) - rescan after 6 cycles -
progression of lung meta
(number and size – 1. 11. 2012)**



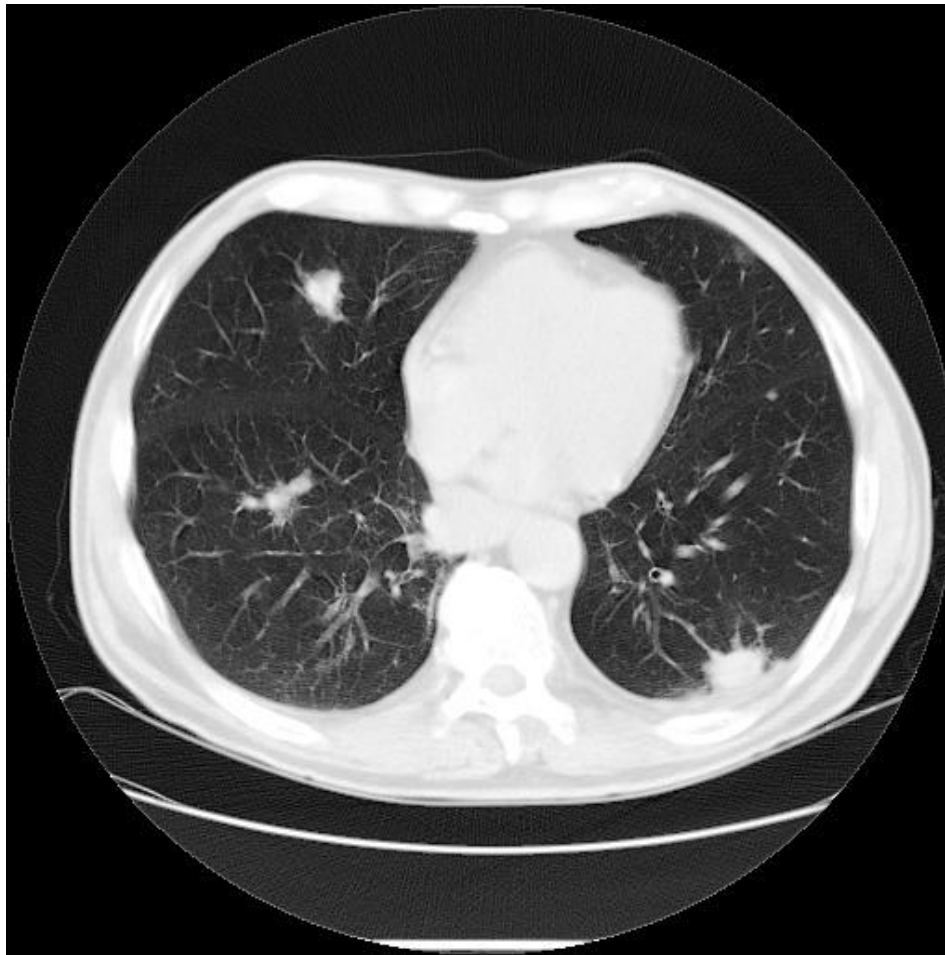2nd line treatment

- **afinitor 10 mg/day, D1-28**
 - start on 3. 12. 2012, KI 100%, labs normal
- well tolerated, no myelotoxicity, no pulmonary toxicity, no mucositis
 - nausea G1, acneiform exanthema and pruritus G1 (treated with antihistamines - levocetirizine), higher plasma glucose (7-9 mmol/L)

2nd line treatment (afinitor) – rescan after 3 cycles – partial regression of lung meta with subsequent long-term stabilization



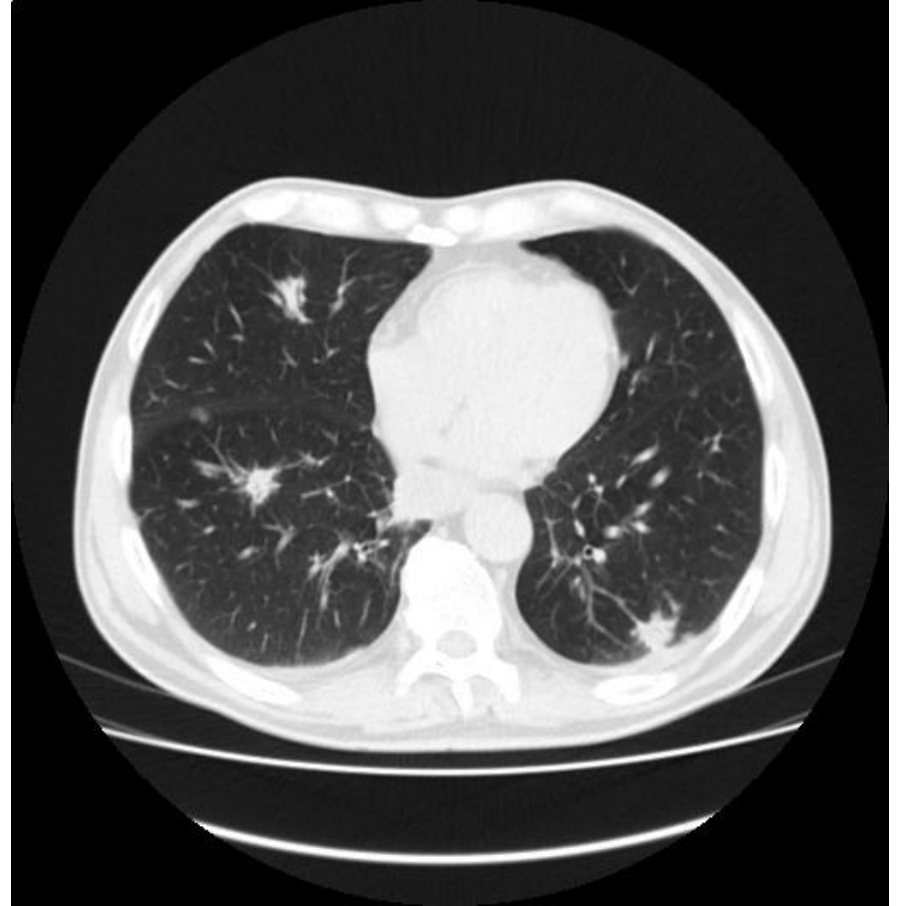
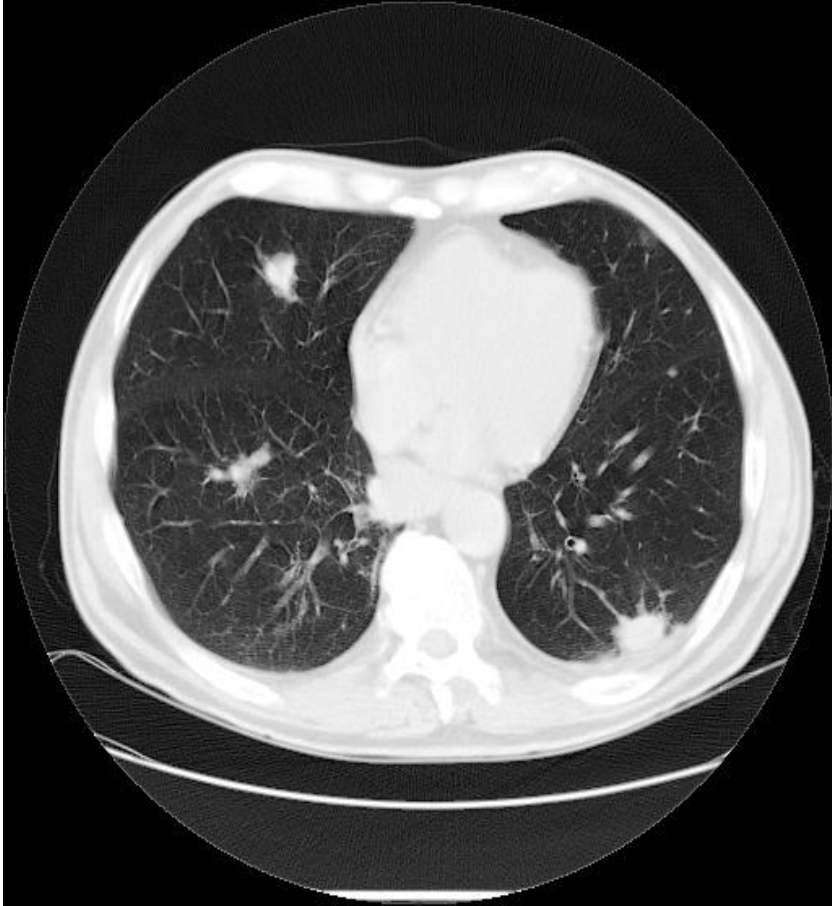
2nd line treatment (afinitor) – rescan after 19 cycles – progression of lung meta (30.4.2014)



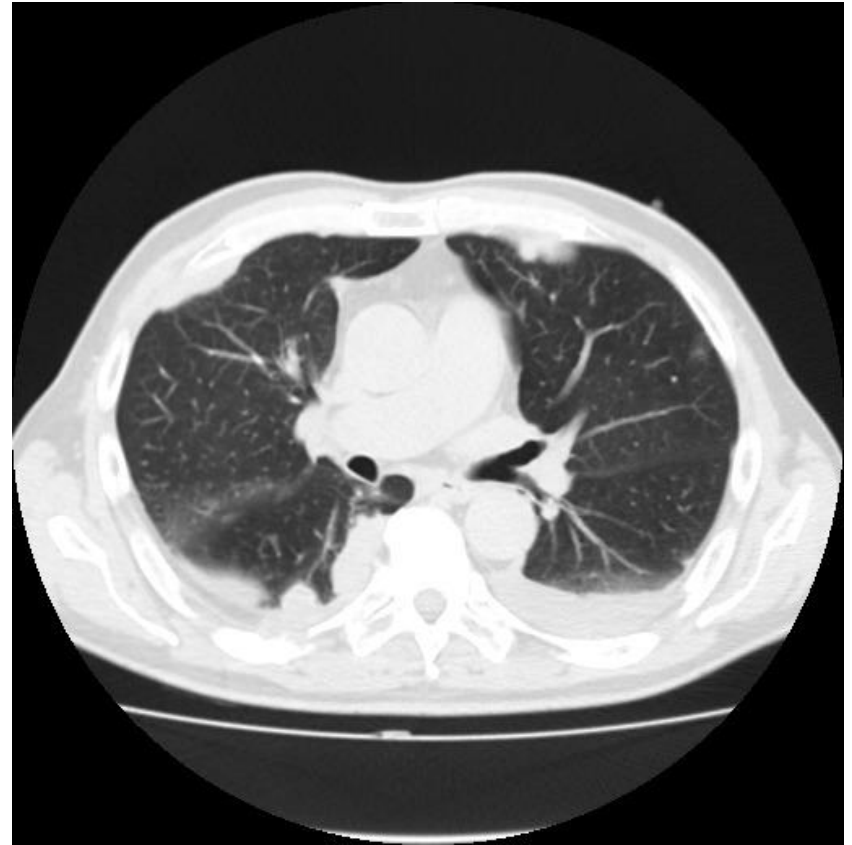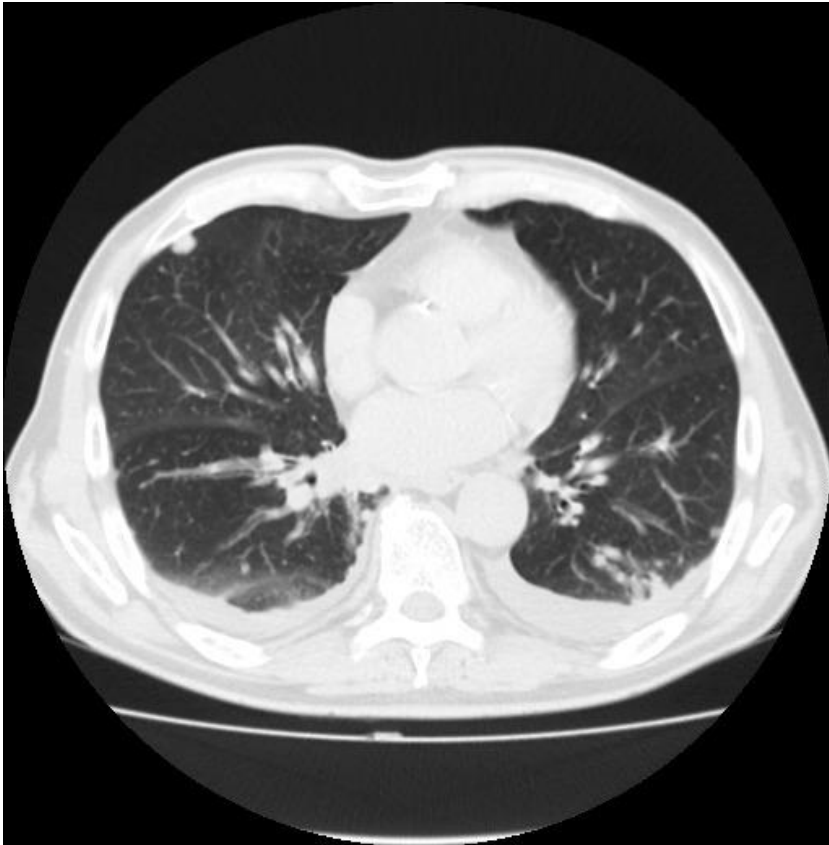
3rd line treatment

- **sorafenib 800 mg/day (2-0-2 / 200 mg)**
 - start on 23. 6. 2014, KI 90%
- relatively well tolerated at the start, just slight nausea, light exanthema and skin itching G1 (antihistamines)
 - from 3rd cycle: exanthema in progression G2 (local steroids by a dermatologist + levocetirizine), diarrhoea G1-2, loss of appetite G1, fatigue G2, hand-foot sy. G1

3rd line treatment (sorafenib) – rescan after 2 cycles – slight size regression of lung meta (SD)



3rd line treatment (sorafenib) – rescan after 8 cycles – progression of lung meta and pleura with effusion (13.4.2015) – treatment discontinuation followed by symptomatic treatment



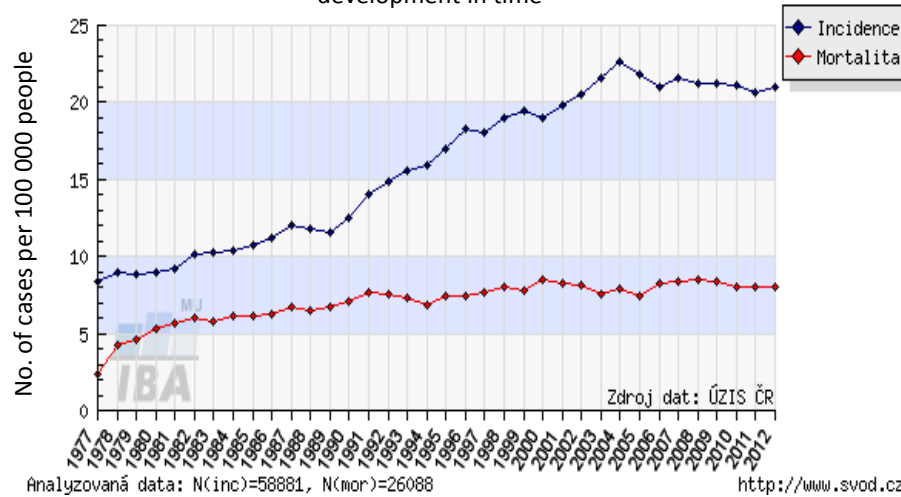
Summary

- Targeted treatment has prolonged survival of mRCC patients
 - our patient was treated for just under 38 months (24.2.2012 – 13.4.2015)
- Development of resistance to TKIs and mTOR inhibitors continues to limit therapy => palliative treatment
- Quality of life – important treatment success factor
- High hopes in modern immunotherapy with checkpoint inhibitors (long-term disease control)
- Future – new combinations, targeted treatment sequencing and immunotherapy

Tumours of the urinary bladder

Epidemiology and aetiology

C67 – urinary bladder – vesicae...
development in time



Aetiology

➤ Smoking, polycyclic aromatic amines, dietary factors, medicines, chronic infections

C67 – urinary bladder

Comparison of incidence in CZ and other countries, ASR – global standard



➤ Genetic predispositions – can be up to 10%, familial occurrence in association with the LYNCH II syndrome as well as exclusive entities with autosomal dominant inheritance – genetically determined higher sensitivity to some carcinogens

Tumours of the urinary bladder – most frequent histology types

- **urothelial carcinoma: 90%**
- **epidermoid carcinoma: 6% - 7%**
- **adenokarcinoma: 1-2%**

Localized disease

1. superficial (non-muscle invasive) - Tis, Ta, T1

- Preferred surgical treatment (TURBT) + local...intravesical BCG or CHT mitomycin administration

2. Invasive (muscle invasive) - T2-4a N0

- Newly treatment with neoadjuvant cisplatin-based chemotherapy, than radical surgery (RACE) and possibly ambiguous adjuvant chemotherapy
- Rarely other modalities: radiotherapy, primary surgery, ...

Disseminated disease

- **metastatic Ca - T4b / N+ / M+...palliative cisplatin, gemcitabin, taxan, vinflavin or doxorubicin-based chemotherapy**

Case study - B.J.; 1954

- FH: father + Ca kidneys, mother CRI, brother brain Tu
- Social history: married
- Occupational history: logistics, no contact with chemicals
- Personal history: HLPP, smoker
- Surgeries: 0
- Treatments: fenofibrate (Lipanthyl Supra 160mg 0-0-1)
- allergies: negates
- abuses: **quitted smoking 11/2013, 15 c/day - from 18 years of age**, alcohol ad hoc, coffee sometimes
- Subjective: no complaints, accidental finding during prostate ultrasound

B.J.; 1954

- 11/13 flexible cystoscopy - susp. Tumourous changes under the left urethral opening
- Kidney ultrasound 10/2013 no finding, Chest X-Ray normal, blood count + biochemistry normal
- 11/2013 surgery: **TURT**
- Description: Bipolar endorectometer Ch 26 introduced into the bladder: field coloured with pink urine, rinsing required, 4 tumours identified, some solid with papillary surface, other form a spruce growth, size 1x1 to 3x3 cm. TUR performed of all identified tumours: 1. above the left ureteral opening, 2. base – sample 1, 3. meatus of the bladder – sample 7, 4. right wall, 5. base – sample 5, 6. posterior wall, 7. base - sample 6. Careful electrocoagulation, three-way catheter F 18 Ch, balloon 10 ml, lavage - light pink liquid.
- **After surgery: intravesical MMC administration.**

B.J.; 1954

- Histology
- 1) tu above the left urethral opening : high-grade papillary urothelial carcinoma **with sub-epithelial connective tissue invasion**
- 2) sample No. 1 base: negative
- 3) tu in the urinary meatus on No. 7: high-grade papillary urothelial carcinoma **with sub-epithelial connective tissue invasion**
- 4) tu of the right wall: high-grade papillary urothelial carcinoma **with sub-epithelial connective tissue invasion**
- 5) sample No. 5 base: negative
- 6) tu of the dorsal wall: high-grade papillary urothelial carcinoma **with sub-epithelial connective tissue invasion**
- 7) sample No. 5 base: negative

- **CLASSIFICATION: pTNM(7): pT1**

- **.....reTURB necessary due to the positive base**

Therapeutic classification of urinary bladder CAs:

1. superficial (non-muscle invasive) - Tis, Ta, T1
2. invasive (muscle invasive) - T2-4a N0
3. metastatic - T4b / N+ / M+

B.J.; 1954

- 01/2014 reTURT... Tis only here (base negative)... followed by intravesical BCG
- 04/2014...recurrence according to cytology and cytoscopy....further reTURT

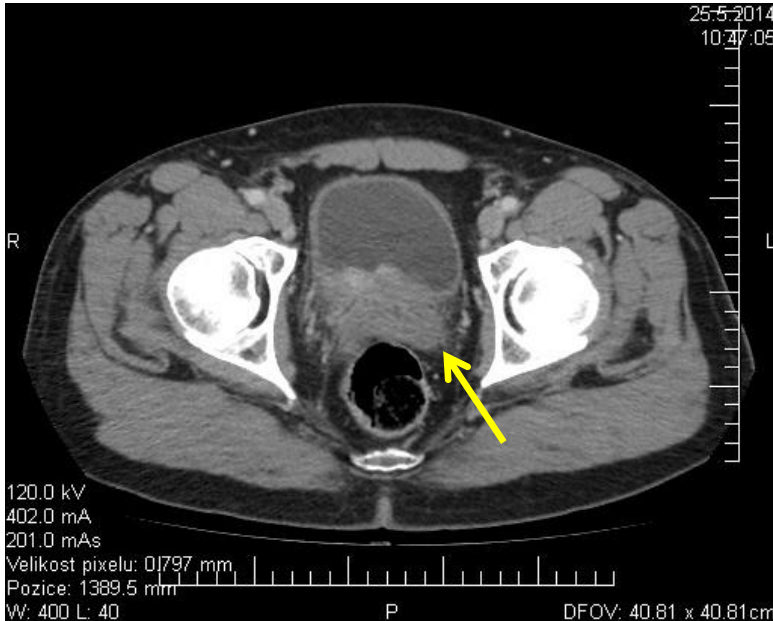B.J.; 1954

- 04/2014: re-resection of all areas after TURT
- histology:
- 1,2) Medial from the left opening a focus of invasively spreading **high-grade urothelial carcinoma**, negative base. **Recurrence!!**
- **3,4) No. 7-9 in the meatus - high-grade urothelial carcinoma with minimal invasion into the muscle base.** **Recurrence!!**
- 5,6) Chronic inflammation and granulation tissue lateral from the right opening, no malignity, including the base.
- 7) Sample of the mucosa of prostatic urethra with chronic inflammation and surface erosions with granulation tissue, no malignity.
- **CLASSIFICATION: pTNM(7): high-grade CARCINOMA, pT2....restaging necessary!!!**

Therapeutic classification of urinary bladder CAs:

1. superficial (non-muscle invasive) - Tis, Ta, T1
2. invasive (muscle invasive) - T2-4a N0
3. metastatic - T4b / N+ / M+

B.J.;1954

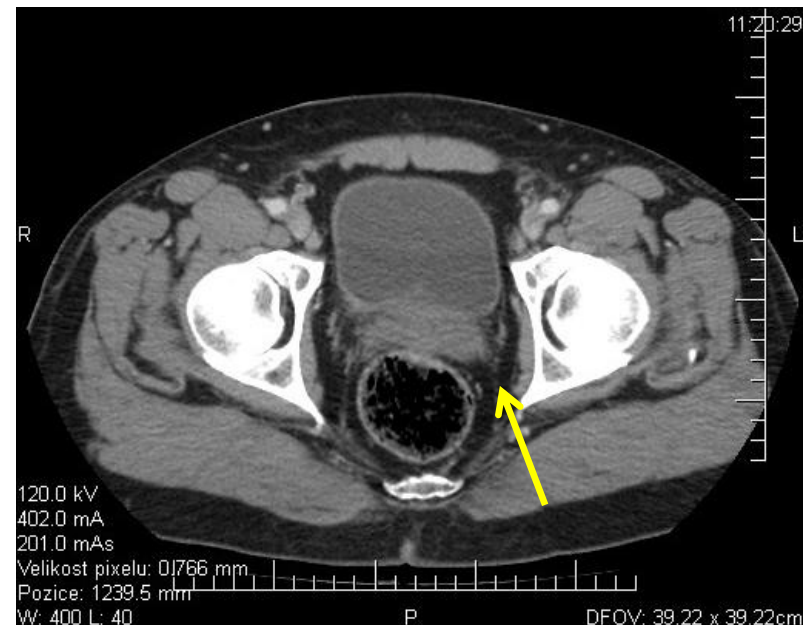
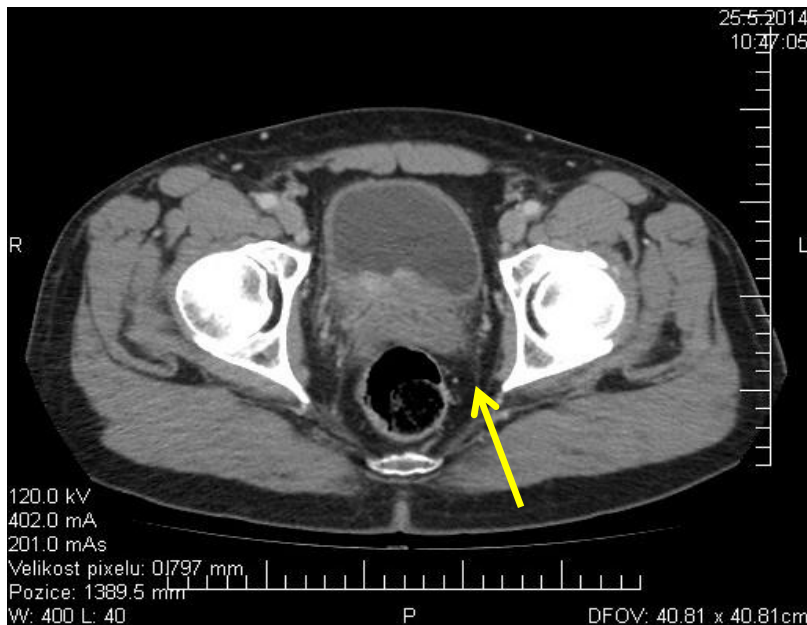

- Skeletal scintigraphy (negative), chest X-ray (negative), labs - normal
- CT of the abdomen and pelvis
 - Tu of the bladder
 - Pathologically enlarged para-aortic nodules in the pelvis and RP.

TNM and stage: at minimum pT2cN3MX - stage IV.

B.J.;1954

- 4 cycles of neoadjuvant chemotherapy cisplatin + gemcitabine, leading to regression - 80%



B.J.; 1954

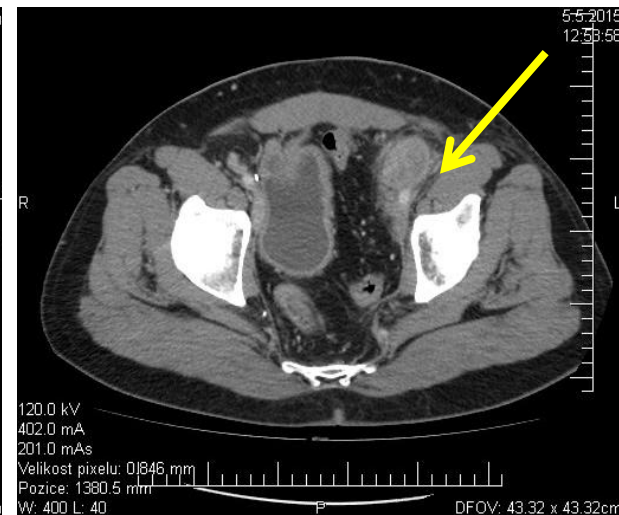
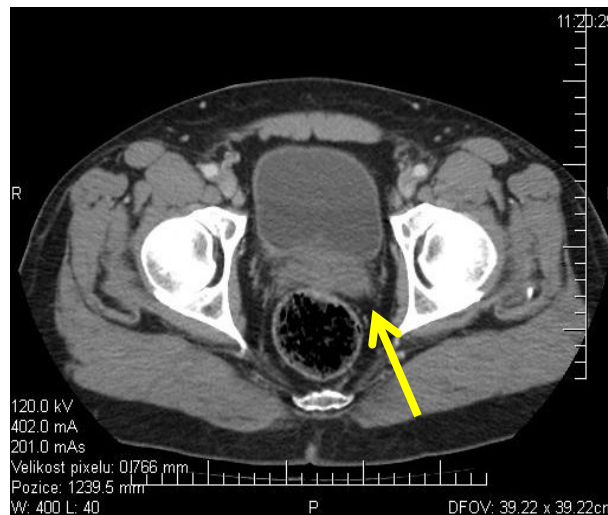
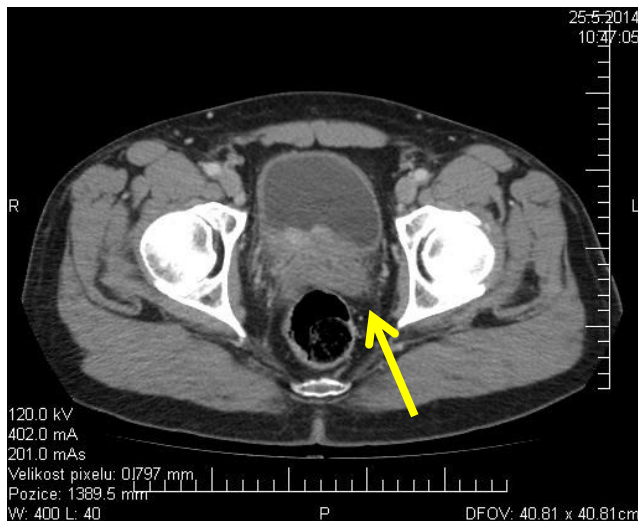
- **10.09.2014 - radical cystektomy** (def: usual RACE: complete resection of the bladder, with prostate and seminal vesicles in male and with uterus, adnexa and the frontal wall of the vagina in female, and including nodules in some cases (according to peri-surgical finding and previous abdominal and pelvic CT)).
- **Histologically: Urinary bladder without an evidence of residual carcinoma following neoadjuvant therapy. Resection margins including urethra negative for both urethras. A micrometastasis of a higher grade carcinoma (1 mm) in 1 of 40 lymphatic nodes.** Prostate gland with predominance of glandular atrophy, a focus of chronic inflammation, granulomatous reaction after endoresection. Regular appendix.
- **CLASSIFICATION: pTNM(7): ypT0 pN1(nodes[posit./exam.]: 1/40), L0 V0 R0....i.e. significant regression, almost complete remission....VERY GOOD PROGNOSIS**

B.J.; 1954

- **05/2015: However, CT scan:** Conclusion: patient after radical cystectomy with ileal ureteral substitution, **progression with pathological lymphadenopathy** in the left groin and by the outer iliac ligament, **new enlarged node in posterior mediastinum**, the currently observed nodes had previously regressed

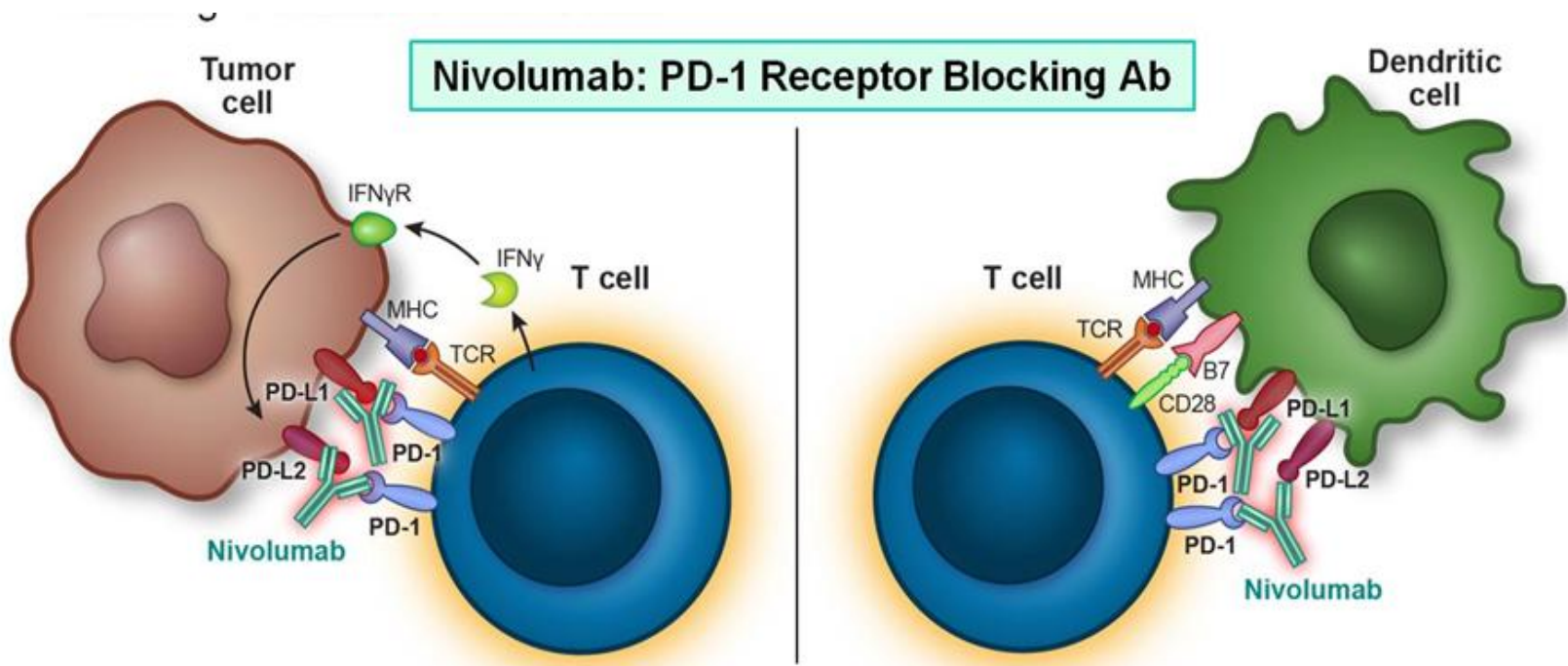
Therapeutic classification of urinary bladder CAs:

1. superficial (non-muscle invasive) - Tis, Ta, T1
2. invasive (muscle invasive) - T2-4a N0
3. metastatic - T4b / N+ / M+



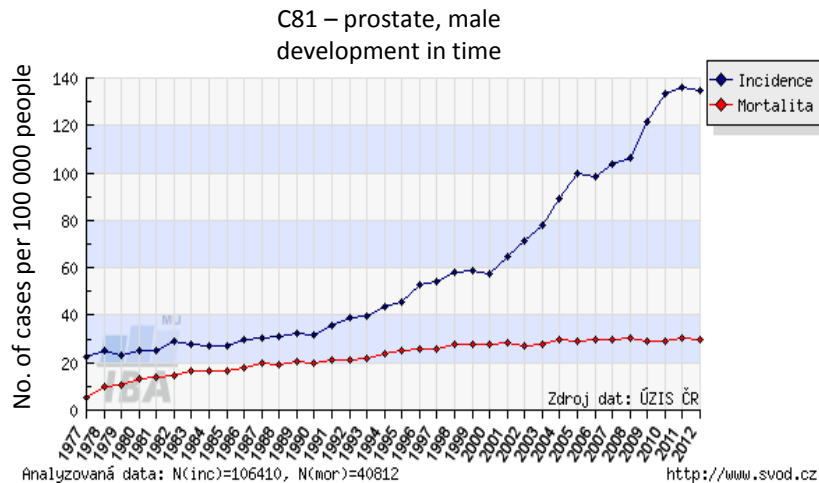
B.J.; 1954

- Therefore: **3rd metastatic** - T4b / N+ / M+...palliative cisplatin, gemcitabine, taxan, vinflavin, doxorubicin-based chemotherapy
- **a study became available with „check-point inhibitors“: nivolumab – first line palliative immunotherapy**



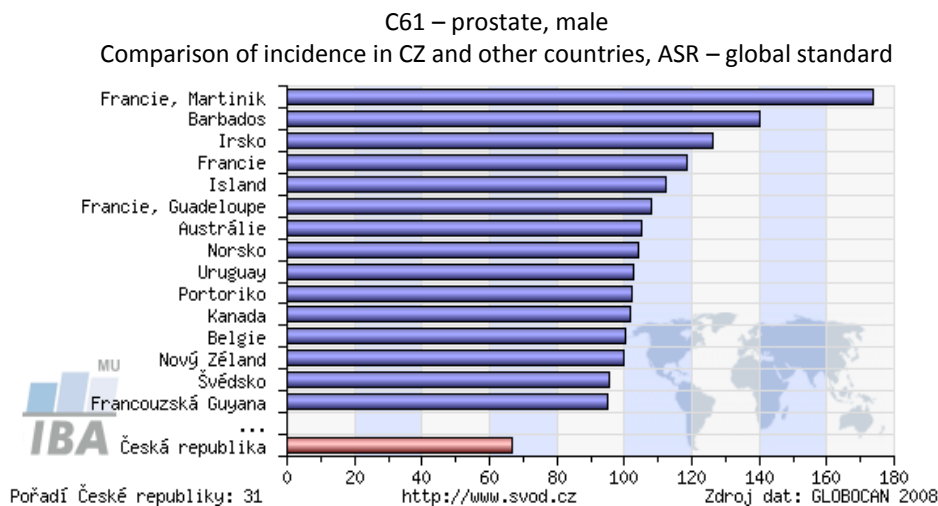
Tumours of the prostate

Epidemiology a aetiology



Aetiology and risk factors

- Genetic predispositions – familial 5 %, p53, Bcl-2
- Age – steep rise post 6th decade
- Dietary habits – increased intake of saturated fatty acids, low intake of vegetables, obesity
- Professional exposition – aromatic carbohydrates, heavy metals
- Ethnic effects – highest in Afro-Caribbean, lowest in Asians



Localized disease

- RAPE ± pelvic lymphadenectomy (according to nomogram – Partin, Briganti, MSKCC),
 - Curative radiotherapy ± hormone therapy neoadjuvant/concomitant/adjuvant
 - active surveillance or watchful waiting
- **Modality selection according to the risk (low, medium, high – as per the T, PSA and Gleason score), overall health status, comorbidities, patient attitude towards treatment (age, sexual activity)**

Disseminated disease

- Hormone therapy
 - Chemotherapy
 - Immunotherapy
 - Radioisotopes
-
- Bisphosphonates, denosumab

Phases of the disease development

Primary hormone-sensitive disease

Androgen deprivation therapy

Hormone-sensitive disease for 2-3 years

Need to establish permanent castration

Development of castration-resistant disease

CRPC systemic treatment modalities

Systemic chemotherapy

Androgen-deprivation therapy

Inclusion of immunotherapy

Supportive treatment of bone metastases

Antiresorptive agents

Radionuclide therapy

Palliative radiotherapy

Bone metastases

Antiresorptive agents:

bisphosphonates

RANKL inhibitor – denosumab

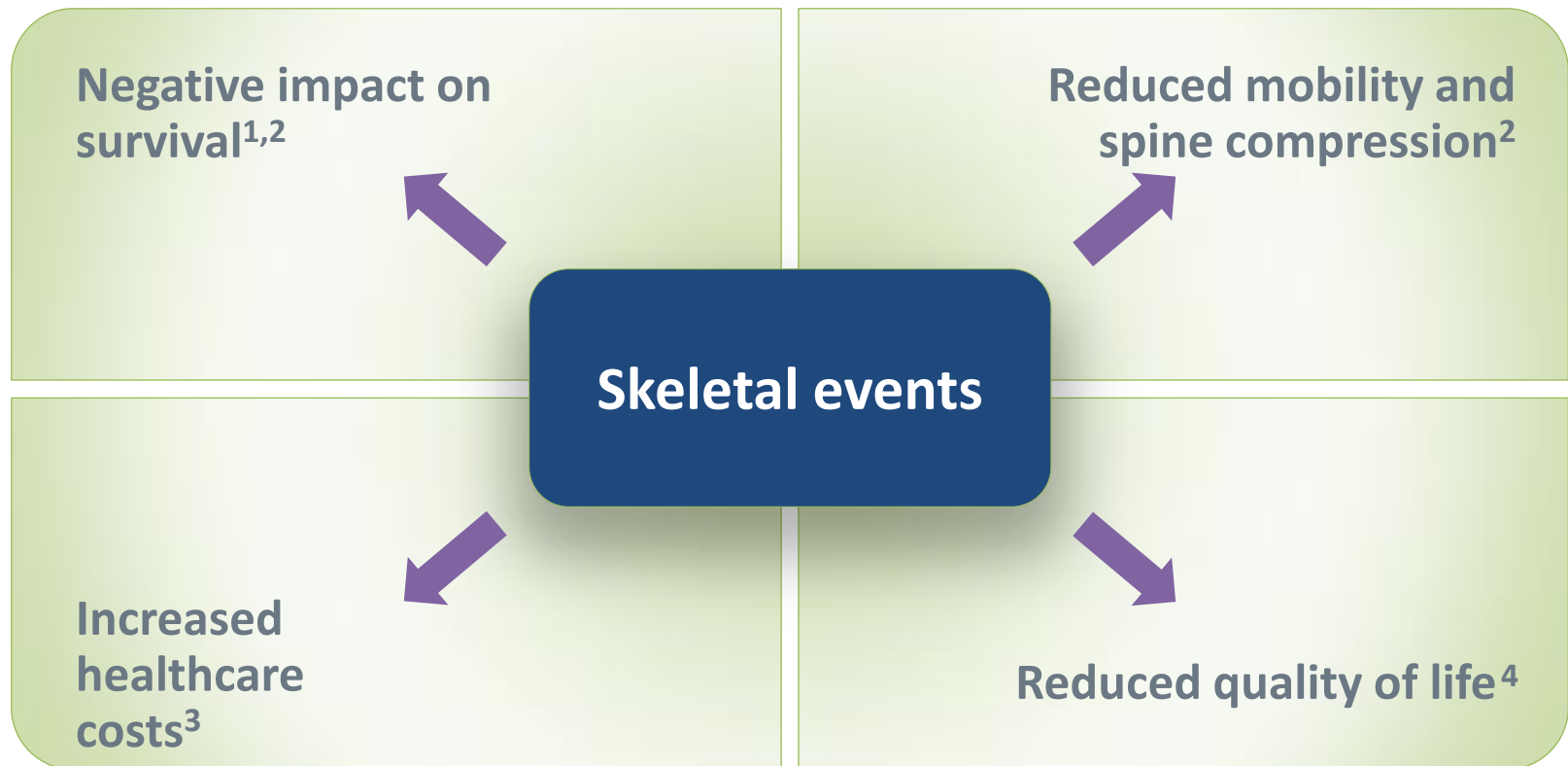
Radionuclide therapy

samarium-153

radium-223

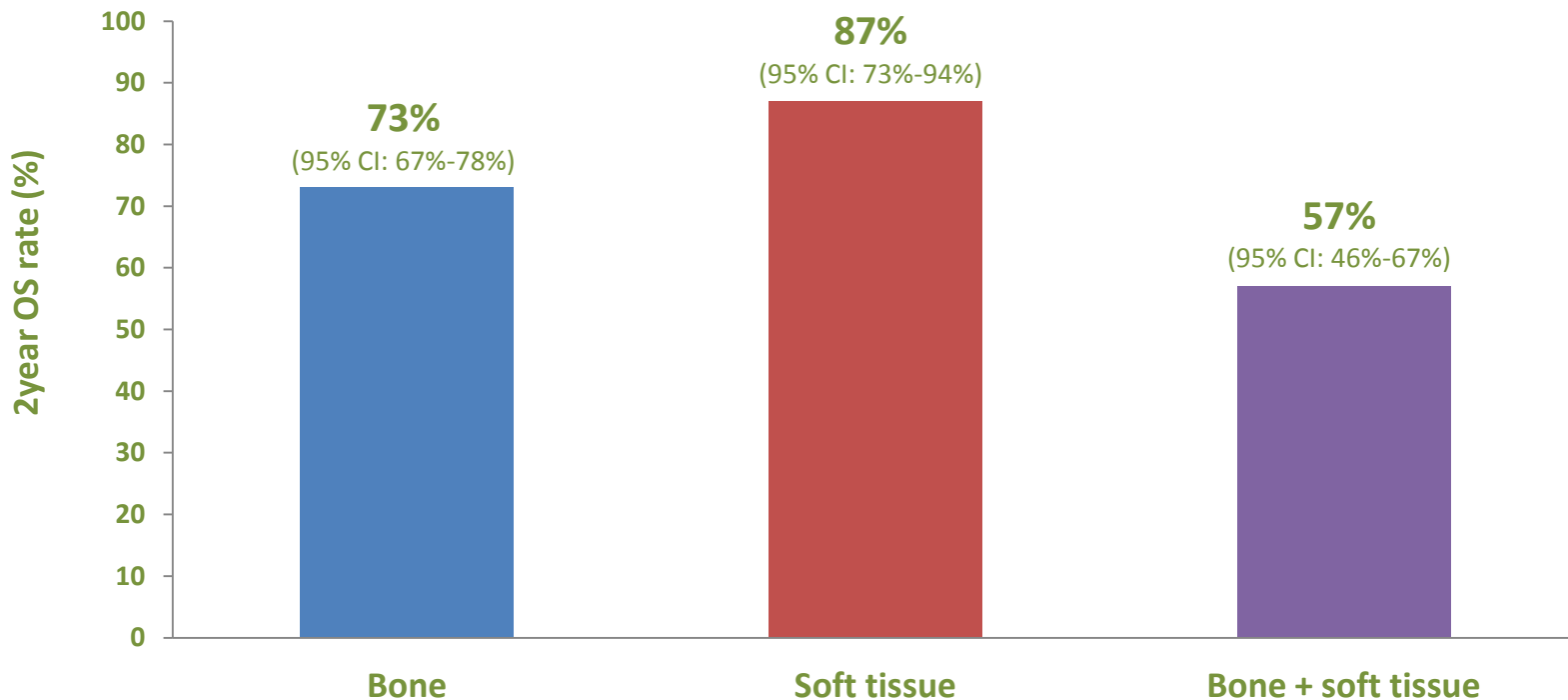
Bone metastases in advanced prostate cancer: related consequences

SRE are associated with higher morbidity^{1,2}, higher treatment cost³ and lower quality of life⁴



Impact of bone metastases on overall survival in patients with mCRPC

- Patients with bone disease at the time of diagnosis have significantly poorer OS than those with lymph node disease



2012

Radium 223

Enzalutamide

Denosumab

Cabazitaxel

Sipuleucel-T

Abiraterone
pre & post-doc

Zoledronic acid

Docetaxel

ADT

2010

Denosumab

Cabazitaxel

Sipuleucel-T

Abiraterone
Post-doc

Zoledronic acid

Docetaxel

ADT

2004

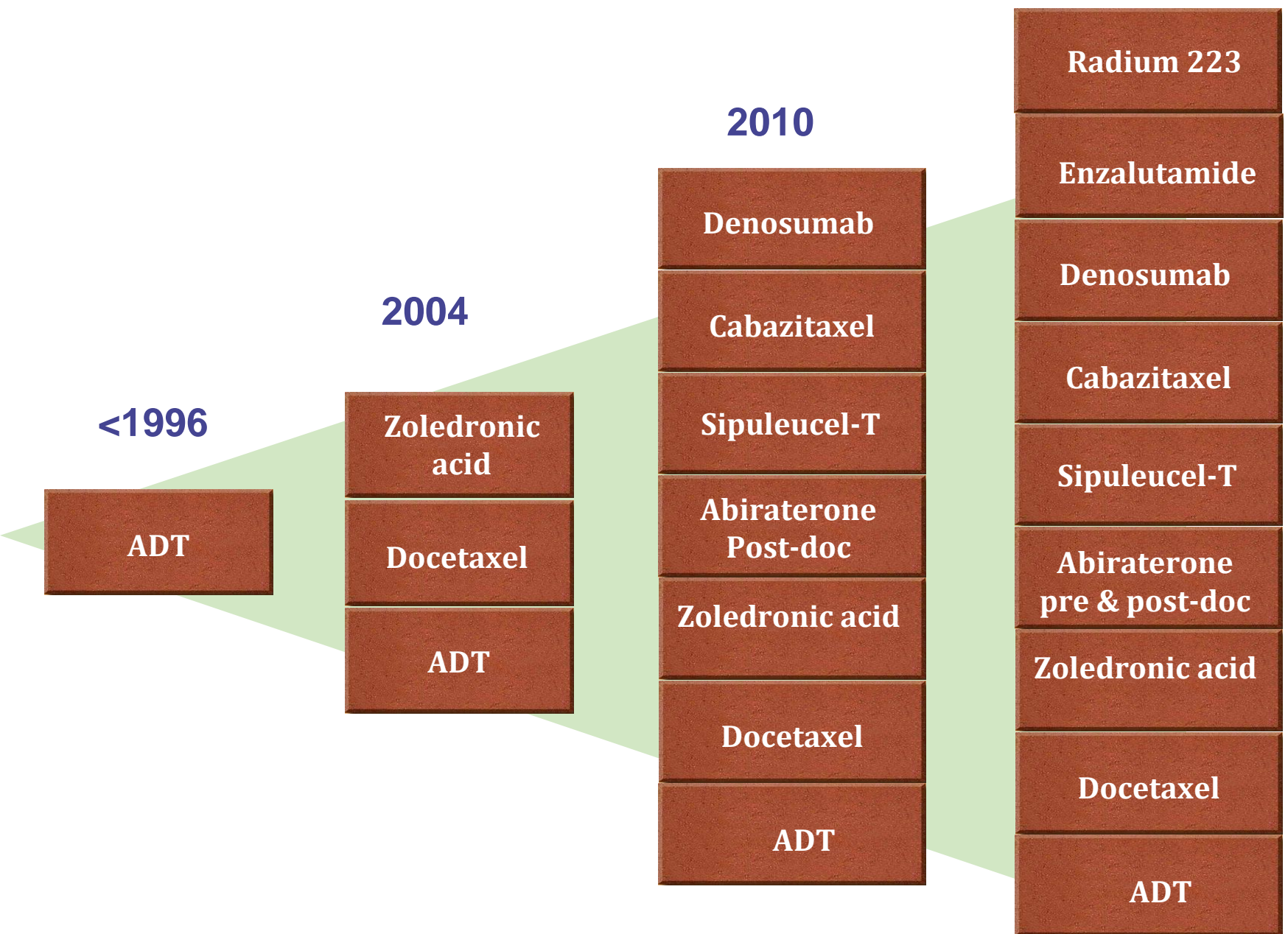
Zoledronic acid

Docetaxel

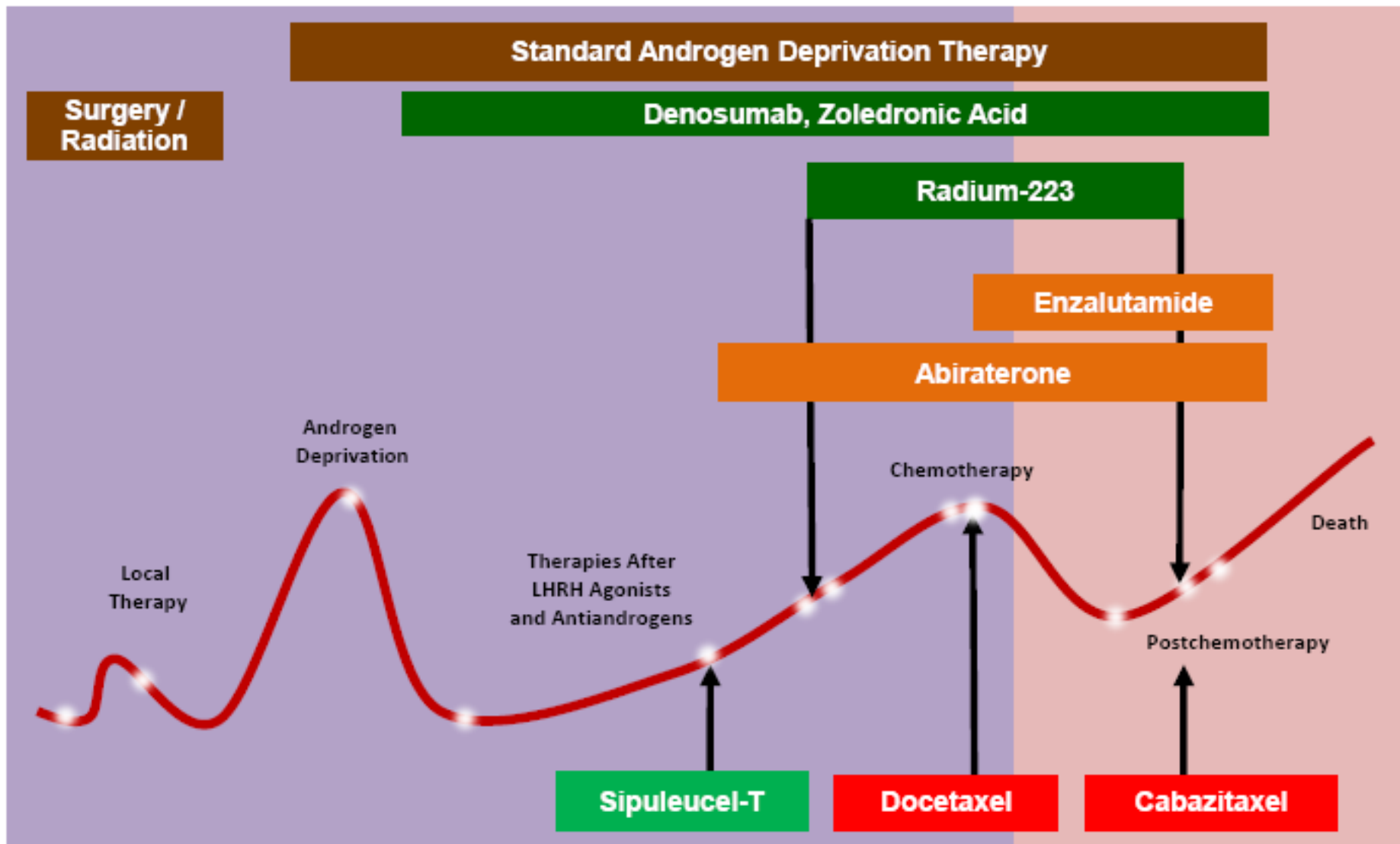
ADT

<1996

ADT



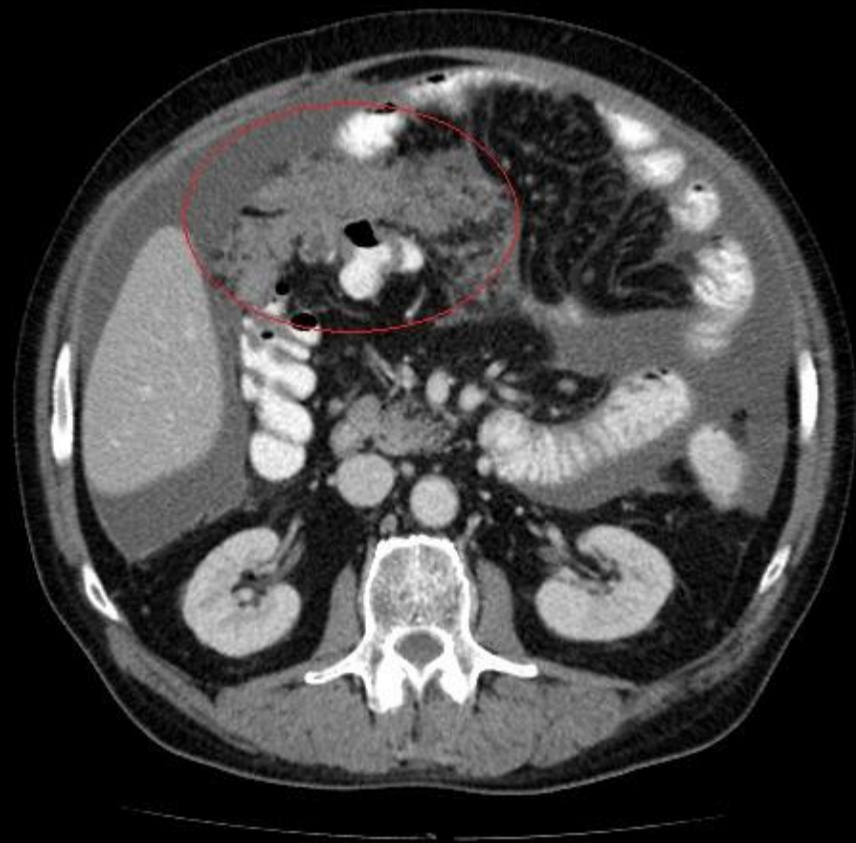
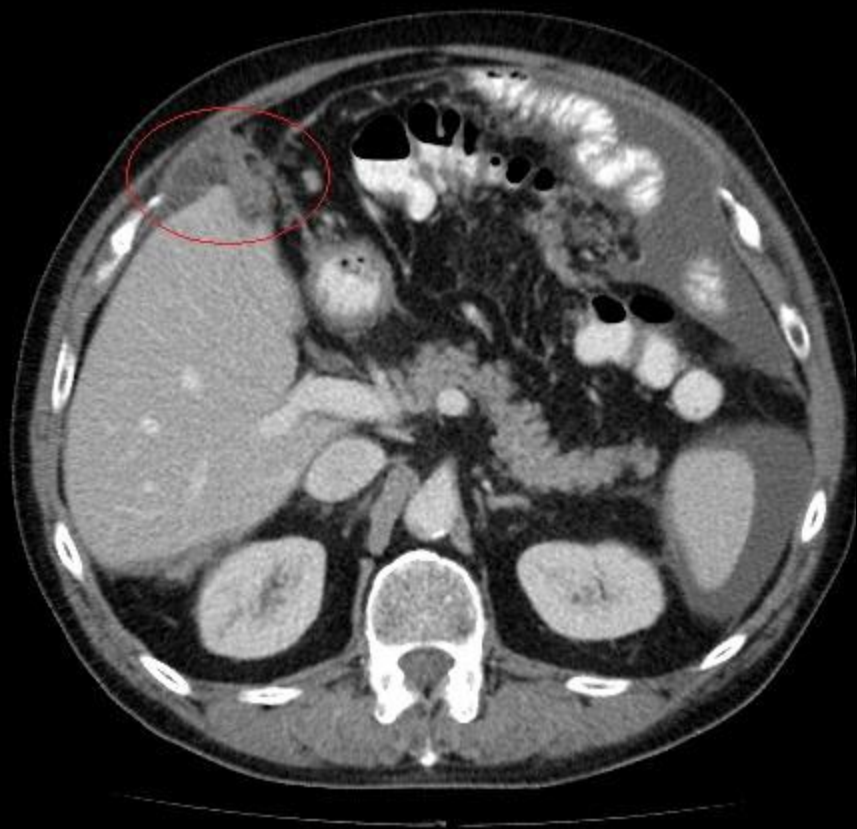
Treatment algorithm



- Patient diagnosed with: Ca prostatae, dg. 1/07, histol.: prostate adenocarcinoma in both lobes, Gleason 3+3, margin affected, significant perineural invasion, pT3a pN0 M0, clin st III, initial PSA 5,6
 - patient after RAPE 5/07.
 - curative RT of the prostate bed due to positive resection margins
- Patient then observed based on the PSA levels during the hormone-sensitive phase of the disease, bilateral OE performed on 17.9.2010; anti-androgenic treatment involved bicalutamid, flutamid.
- CRPC (castration-resistant prostate carcinoma) diagnosed in 4.2011 based on PSA elevation and CT scan. Peritoneal excision due to the atypical finding in the abdominal cavity revealed infiltrations with prostatic adenocarcinoma structures.
The disease was asymptomatic at the time of CRPC diagnosis

- To address the visceral generalization and the risk of symptom manifestation, first line palliative CHT with docetaxel was administered from 18.4.11 to 6.1.12. A total of 13 cycles administered, initial PSA: 82.6.
- Cont. decline in PSA during the docetaxel treatment; docetaxel discontinued at PSA 0,151. PR on CT also achieved.
- Docetaxel discontinuation led to gradual increase in PSA, asymptomatic disease, CT in 5/2012 described regression. Patient offered treatment with abirateron on 24.7.2012.
- Treatment with abirateron very well tolerated no haematol. or biochemical toxicity. Treatment with abirateron resulted in significant decline in PSA, with minimal values.
- PSA values:
 - 17. 7. 2012: 7.26 – initial value before abirateron initiation
 - 12. 11. 2012: 0.192 - nadir in PSA decline
- The treatment aimed to maintain very good health status for as long as possible. Therefore, treatment continued until clinical progression.

- Clinical progression leading to treatment discontinuation identified on 19.5.2014 with symptoms corresponding to disease generalization in the abdominal cavity:
 - feeling of full stomach, burning sensation or cramps in the abdominal wall, no nausea, normal urination, obstipation – used laxatives, observed enlargement of the abdominal volume, flatus reduced
- Physical examination of the ascites revealed less palpable abdominal wall, impaired peristalsis.
- CT on 6.2014:
 - Patient after RAPE – no signs of tumour recurrence.
 - Ascites – the entire abdominal cavity and pelvis – new.
 - Diffuse MTS of the omentum and peritoneum – significant progression.



- Patient with good biochemical and haematological parameters with PS 2 offered subsequent treatment – re-challenge docetaxel from 6.6.2014, with initial PSA: 82.7.
- Subsequent treatment led to fast reduction or even elimination of the abdominal symptomatology, elimination of the ascites according to a physical examination and re-establishment of PSA decline.
- PSA values:
 - 27. 6. 14: 61.3
 - 18. 7. 14: 33.5
 - 8. 8. 14: 19.9
 - 19. 9. 14: 12.0
 - 15. 5. 15: 20.3
- 15.5.2015 clinical disease progression occurs after 15 cycles of docetaxel re-challenge – tense ascites, impaired peristalsis. Anti-tumour treatment discontinued, the patient referred to palliative care.

Conclusion

**Prostate cancer is becoming easier to manage
due to the availability of new data from clinical trials
and availability of further treatment modalities.**

Tumours of the testis

Epidemiology a aetiology

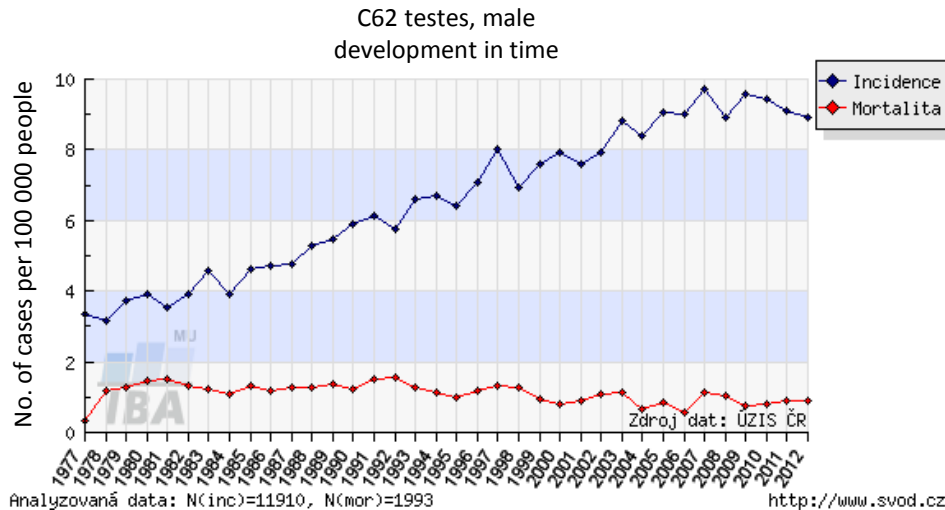
One of the most frequent malignancies in young men aged 20-40 years

Rising incidence – white race, developed countries (North America and Europe)

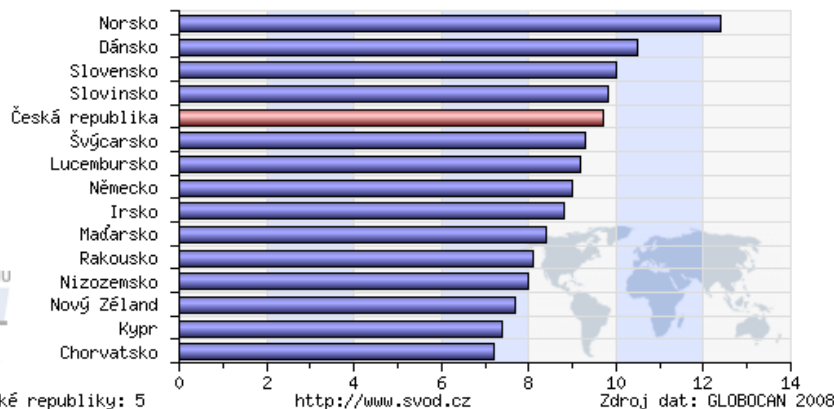
Aetiology – unknown

Risk factors

- Familial occurrence
- Cryptorchidism – increased temperature, endocrine disorders, orchidopexy needed before 1-2 years of age
- Urogenital tract abnormalities
- Discussed: inguinal hernias, orchitis, scrotal trauma



C62 - testes, male
Comparison of incidence in CZ and other countries, ASR – global standard



Testicular tumours – histological types

- ***Germ cell tumours*** – germ cells origin – 95% of all testicular tumours
 - ***Seminomas*** – classic, anaplastic, spermatocytic
 - ***Nonseminomas*** - embryonal carcinoma, choriocarcinoma, yolk sac tumour, teratoma/teratocarcinoma

- ***Non-germ cell tumours*** – lymphomas, sarcomas, Leydig and Sertoli cell tumours

Localised diseases – stage IA,B

- **Surgical treatment** – inguinal orchiectomy in all stages
- **Adjuvant treatment**
 - as per the risk factors – tumour size (> 4cm) and rete testis invasion in seminomas, angioinvasion in nonseminomas
 - **Seminomas** – **surveillance or chemotherapy**
(carboplatin monotherapy, 1-2 cycles)
 - **Nonseminomas** – **surveillance or chemotherapy**
(BEP regimen, 1-2 cycles)

Disseminated disease – stage IS, IIA,B,C and IIIA,B,C (treatment after orchiectomy)

- **Stage IS (tumour marker elevation only) and stage II (retroperitoneal node involvement)**
 - **Seminomas** – curative chemotherapy with the BEP regimen (preferred) or curative radiotherapy in stage IIA,B (cave late toxicity)
 - Residuum after therapy with negative PET - surveillance
 - **Nonseminomas** – curative chemotherapy with the BEP regimen (preferred) or primary RPLND in teratomas
 - Residuum after cytostatic treatment over 1cm – retroperitoneal lymphadenectomy, and followed by chemotherapy if viable tumour
- **Stage III (distant metastases)**
 - **Seminomas and nonseminomas** – curative chemotherapy with the BEP regimen, surgery of residual metastases in nonseminomas and according to PET in seminomas

Case study

- Patient **(18 years)**
- 11/2006 referred by an urologist due to a resistance in the left testicle
- FH: negative
- PH: **orchidopexy of the left testicle aged 11 years (risk factor)**
- Treatments: sine medication, Allergies:0
- Social history: lives with parents
- Occupational history: student
- Abuses: non-smoker, alcohol occasionally, coffee 0

Initial investigations

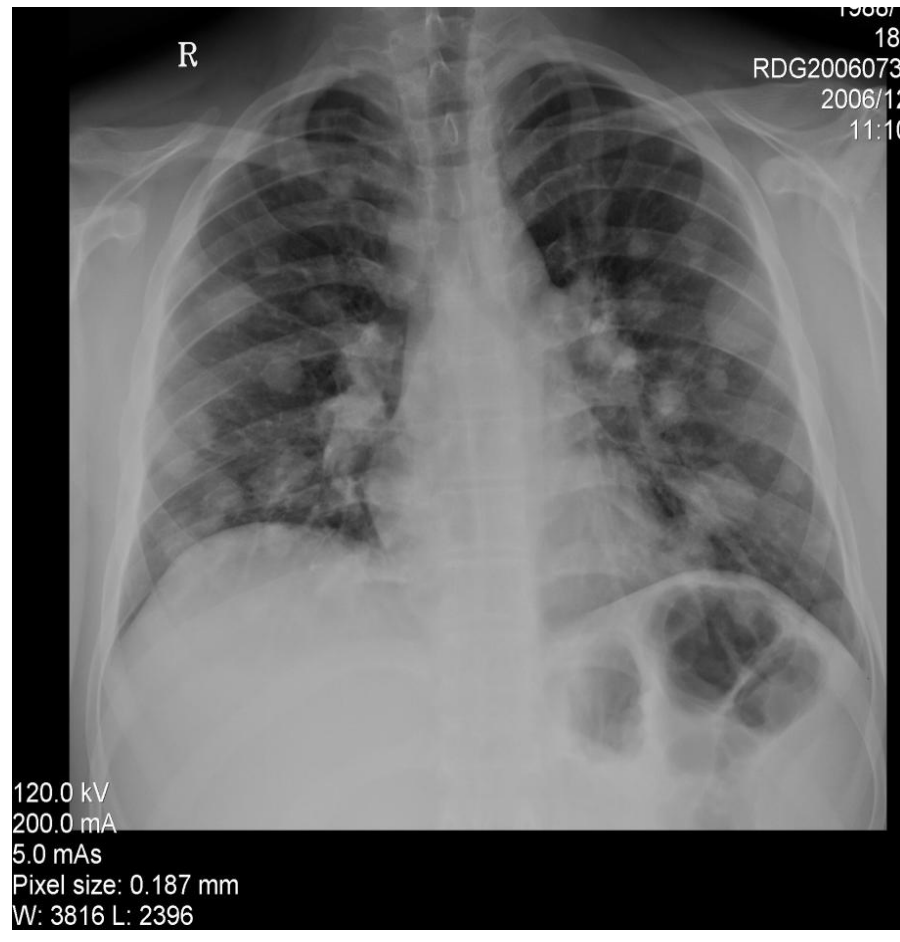
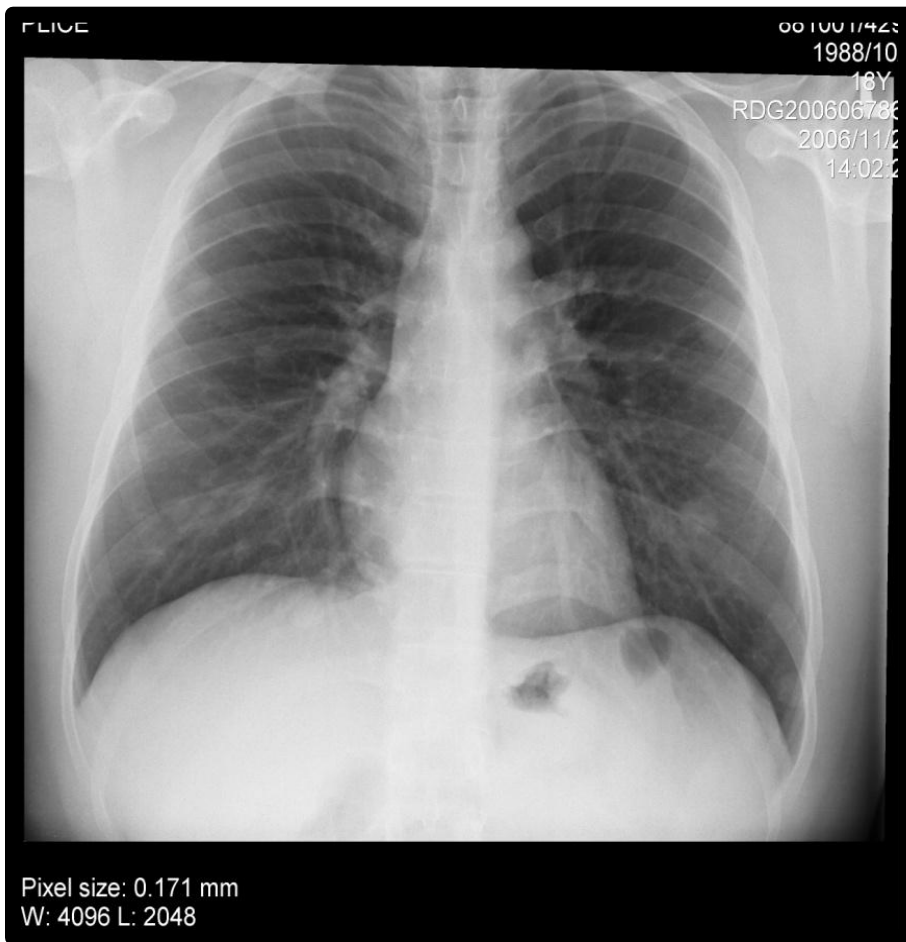- **Current disease:** 1 year pain in the left testicle and 3 weeks palpable resistance
- **Clinical investigation and + ultrasound of the testis:** confirmed tumour of the testis
- **Laboratory:** FW 4/7, CRP 16, blood count+diff. and biochemistry normal
- **Tumour markers:** AFP 17.8 ug/L, HCG 30 360 IU/L, LDH normal
- **Chest X-ray – metastases in both lungs, PET – multiple lung, mediastinum, liver and retroperitoneum metastases**
- **Surgery: left inguinal orchiectomy**
 - **Histology:** mixed germ cell tumour of the testis with predominant embryocarcinoma, minor choriocarcinoma component, invasion into seminal ligament, lymphangi invasion, pT3, C62.9, M 9085/39
- **Refused immediate initiation of systemic treatment (Christmas)**

Fast disease progression!!!

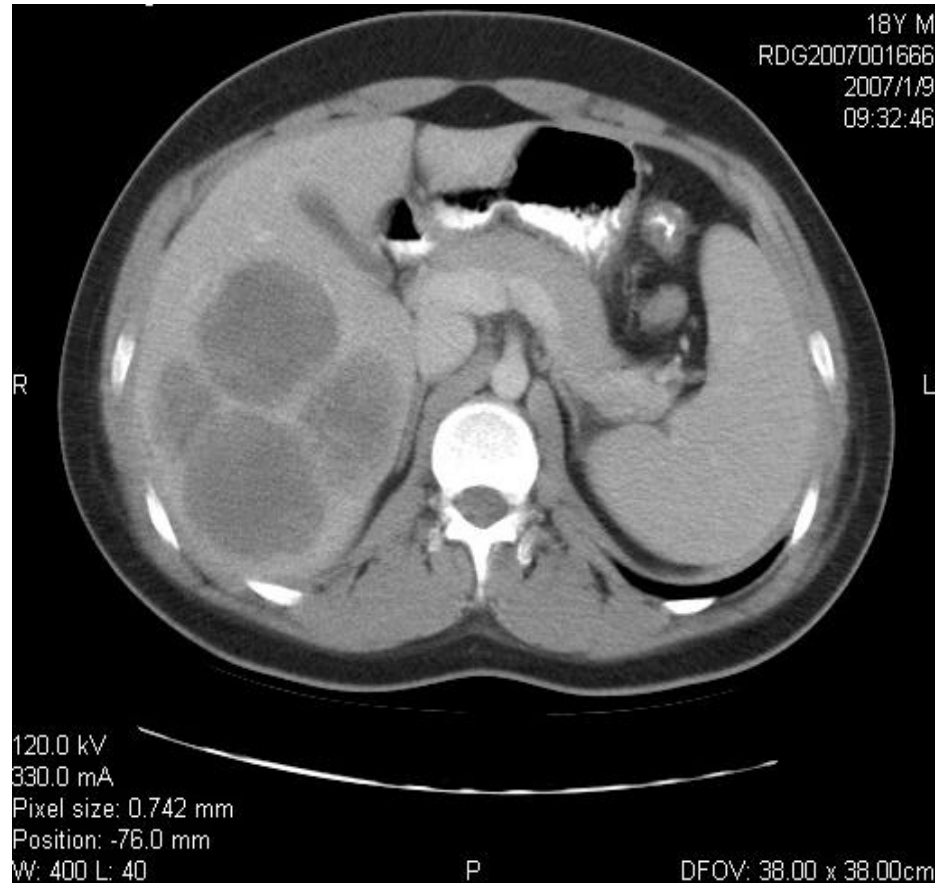
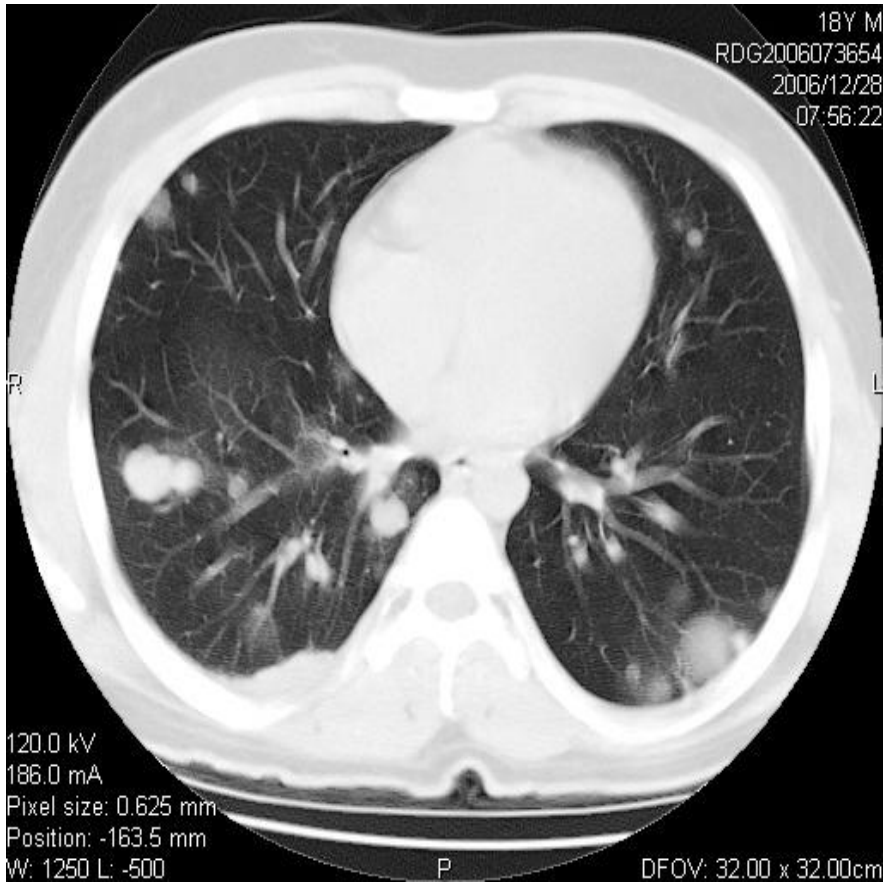
**Acute admission for breathlessness 4 weeks after the surgery
(27.12.2006)**

- **Chest X-ray:** size and numerical **progression by more than 100%**
- **Laboratory:** FW 42/79, CRP 168, blood count + diff. normal, biochemistry – total bilirubin 42, AST 1.11, GMT 3.46, ALP 3.16
- **Tumour markers:** **AFP 128ug/L (17.8), HCG >200 000IU/L (30 360), LDH 34.05 (off norm)**
- **Clinical:** breathlessness at rest, sat. O₂ – 88%

Chest X-ray before the surgery and 4 weeks later



CT of the lungs, abdomen and pelvis at the treatment initiation

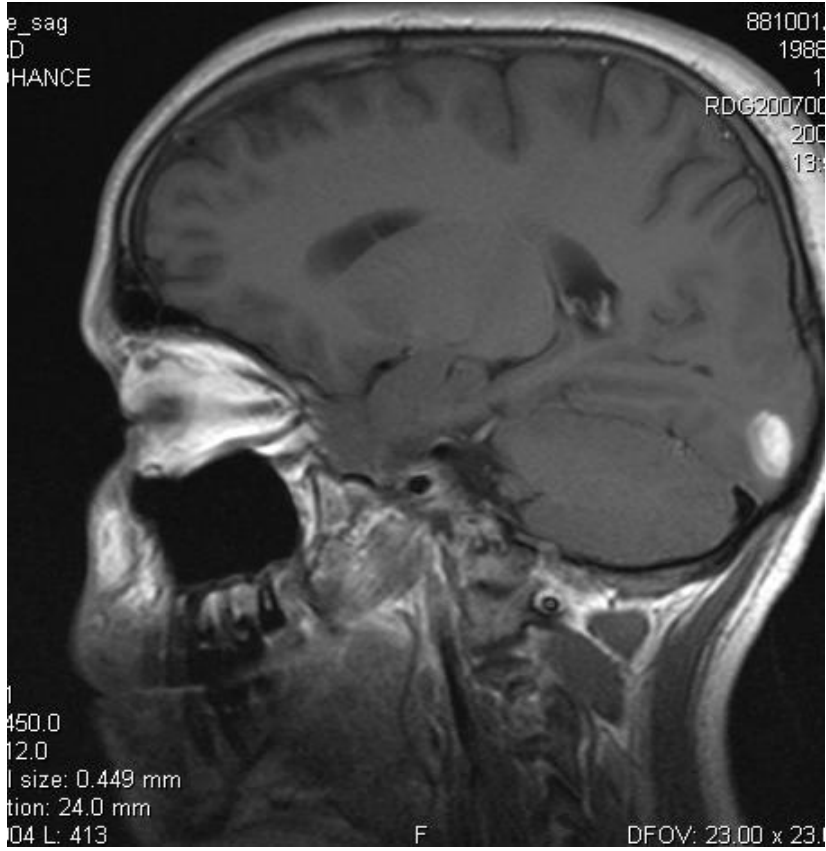
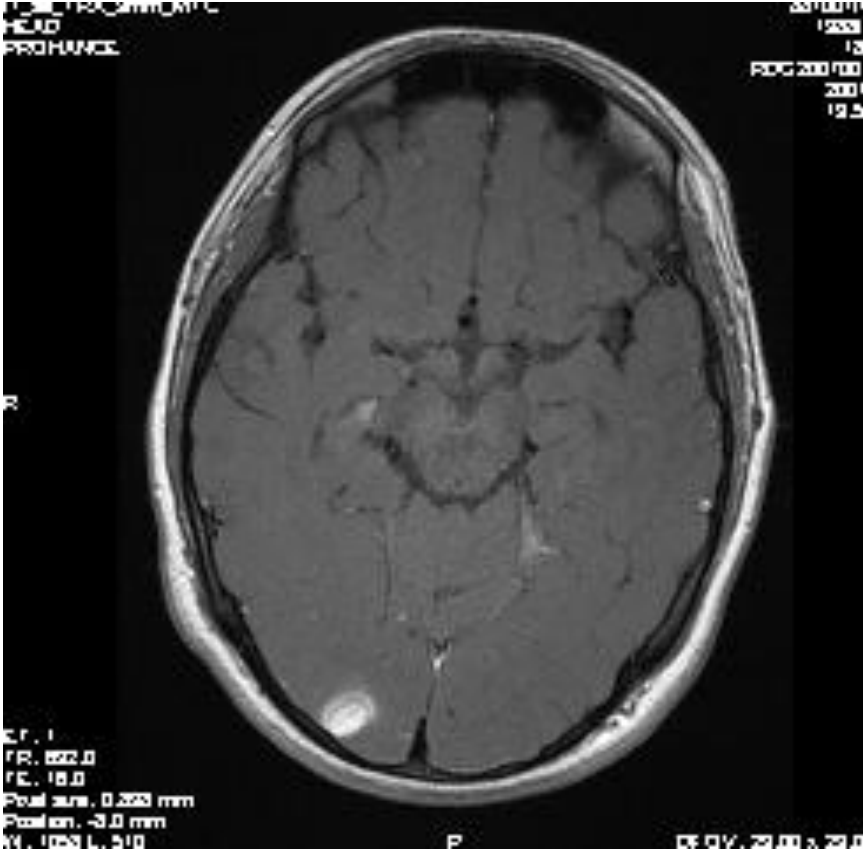


Curative chemotherapy - BEP

TNM classification – pT3N2M1b S3, stage IIIC, poor risk according to IGCCCG => curative chemotherapy indicated 4x BEP (bleomycin, etoposide, cisplatin)

- **Chemotherapy initiated for vital indication at an ICU**
 - Hydration, allopurinol, tumour lysis syndrome prevention, Neulasta (G-CSF)
- **A week from treatment initiation (4.1.2007) – generalized epileptiform activity, CT of the brain – metastasis in the right occipital lobe**
- **Brain MRI on 9.1.2007 – solitary MTS occipital l. dx. 10x10x18mm => stereotactic radiotherapy of a solit. meta of the brain (25Gy) and continuing curative chemotherapy**

Brain MRI on 9.1.2007

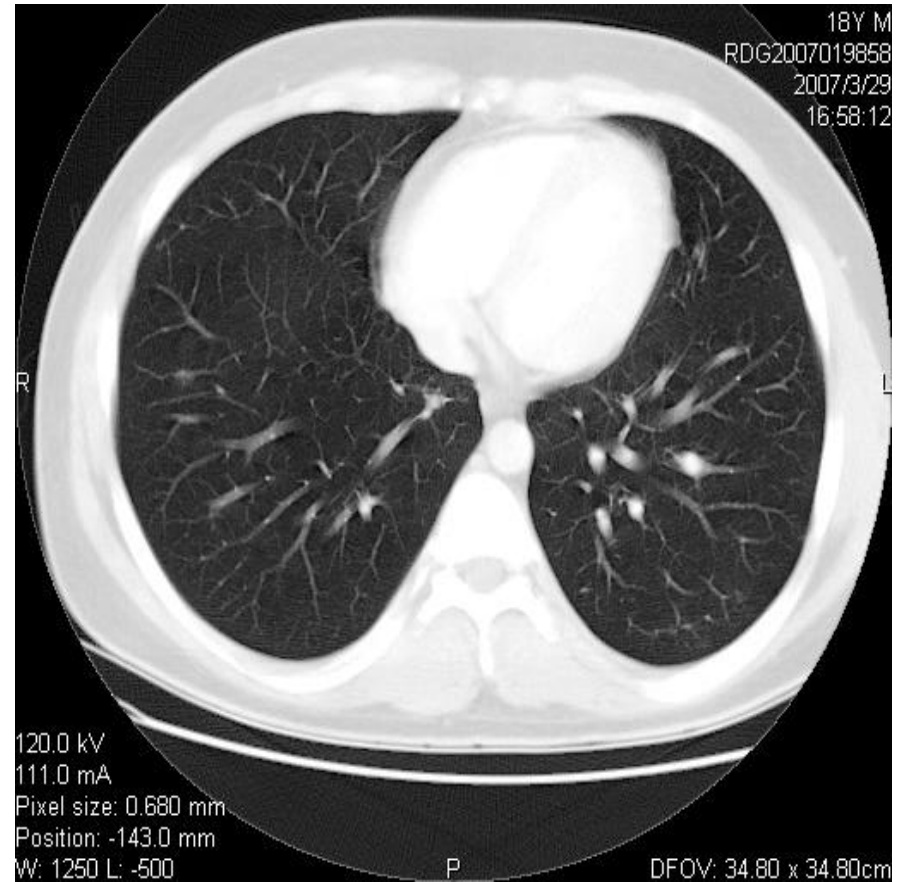
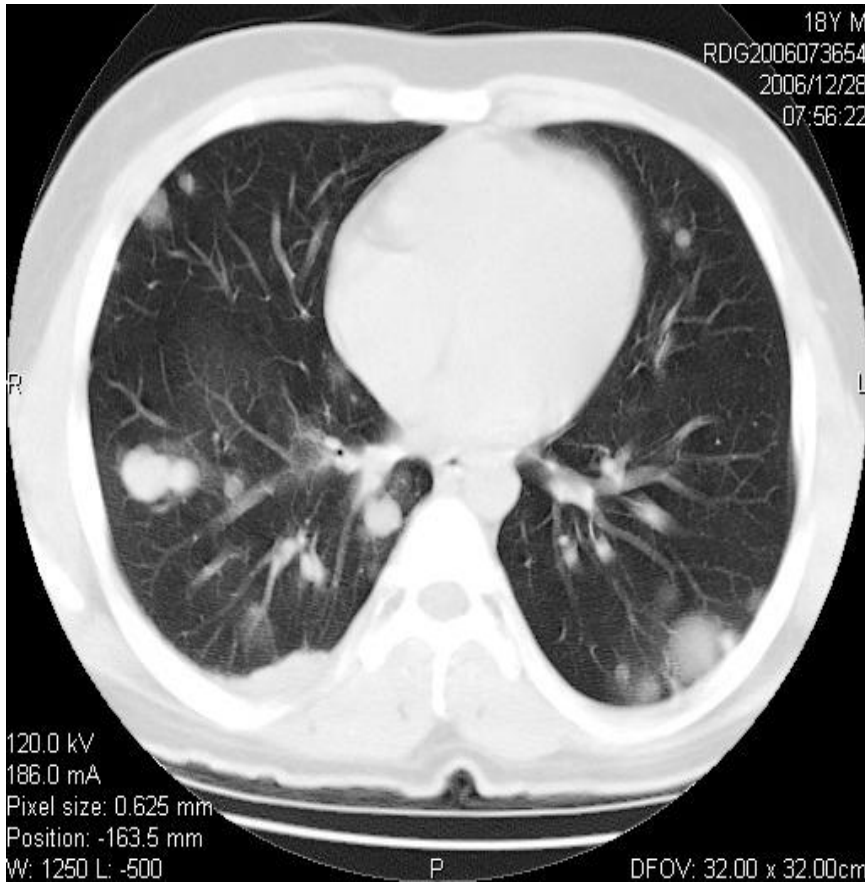


Reinvestigation after 4 cycles of chemotherapy

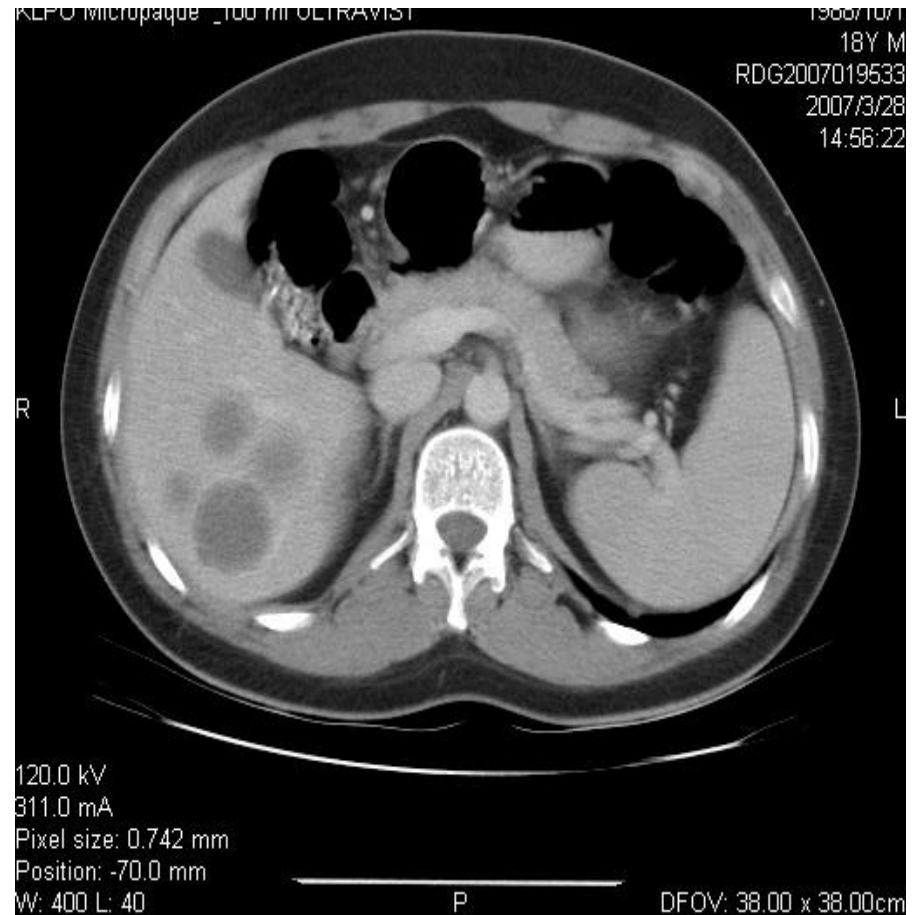
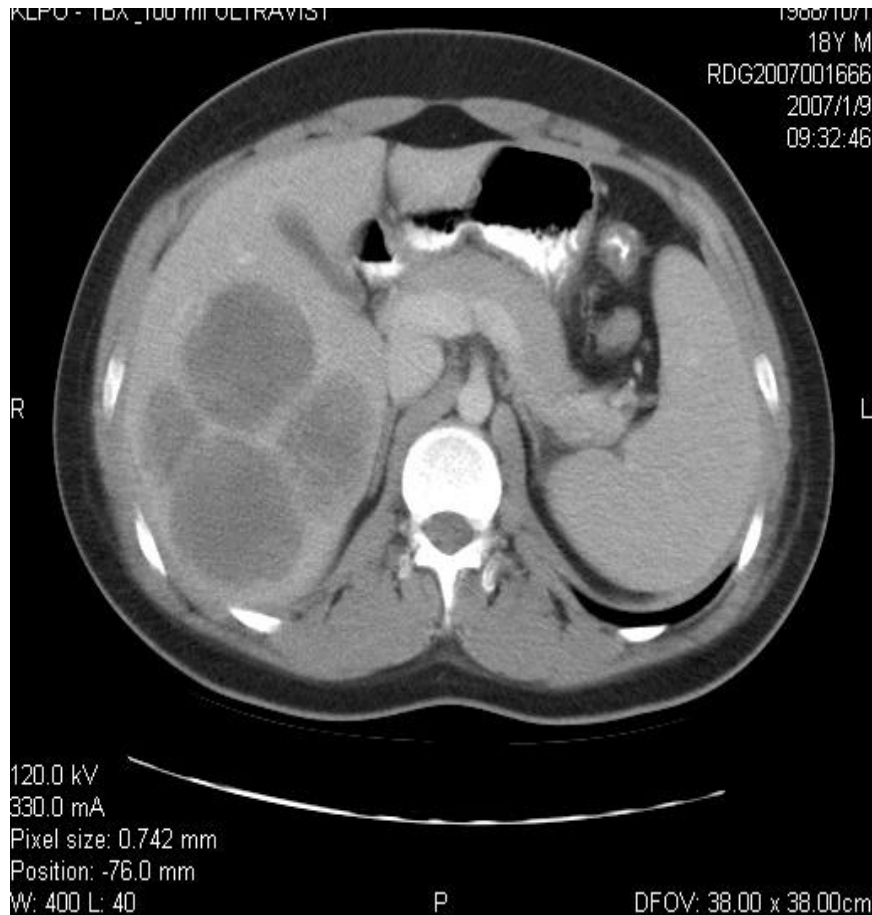
BEP: 28.3.-30.3.2007

- **CT of the lungs, abdomen and pelvis:** significant regression of lung, liver and retroperitoneal metastases, elimination of mediastinal metastases
- **Brain MRI:** post-radiotherapy scar only
- **Tumour markers:** AFP - 128...3.6, HCG - >200 000...19.1, LDH – 34.05...3.46
- **Clinical:** no signs of the disease, no breathlessness

Lung CT before and after 4 cycles of CHT - BEP



CT of the abdomen and pelvis before and after 4 cycles of CHT - BEP



Salvage chemotherapy - VeIP

- **Indication – when a patient does not achieve complete remission on curative 1st line chemotherapy (or surgery)**
- **Administered a total of 3 cycles (2.4. – 27.5.2007)**
 - TM after 3rd cycle - AFP 3.7, HCG 3.6, LDH 3.35 – normalization
- **4th cycle not administered – deteriorated hearing (cisplatin toxicity)**
- **Follow up surveillance, repeated follow ups show complete remission (calcification of necrotic liver metastases)**
- **Complete remission – continues at present**

Thank you for your attention