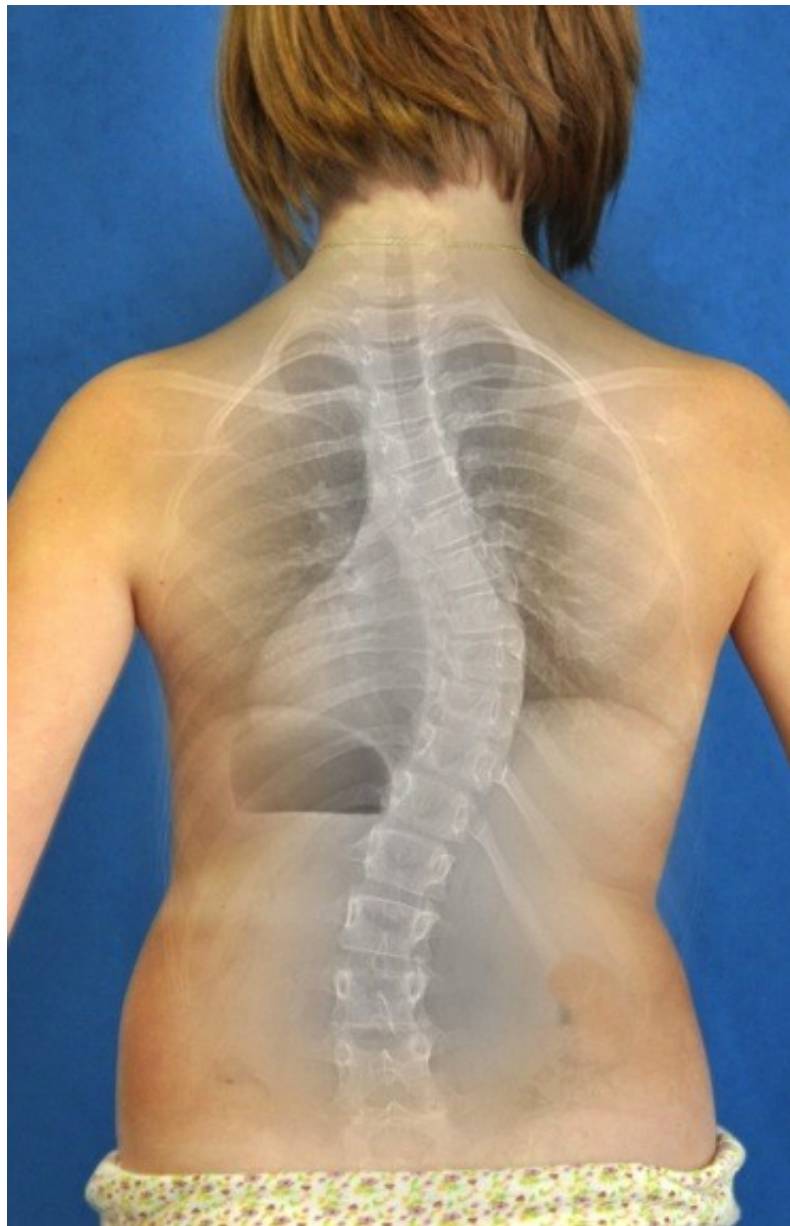




Scoliosis

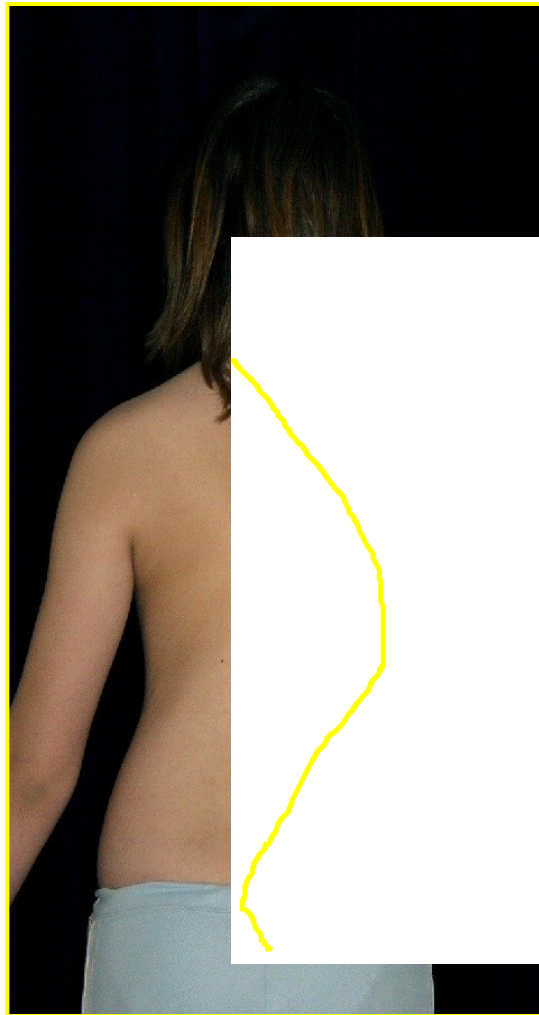
Prýmek M., Repko M.,
Filipovič M., Leznar M.

Department of Orthopedic Surgery – Faculty of Medicine –
Ass. Martin Prýmek


MUNI




Scoliosis = 3 D deformity




Frontální rovina




Sagitální rovina



Axiální rovina






Shoulder height disbalance


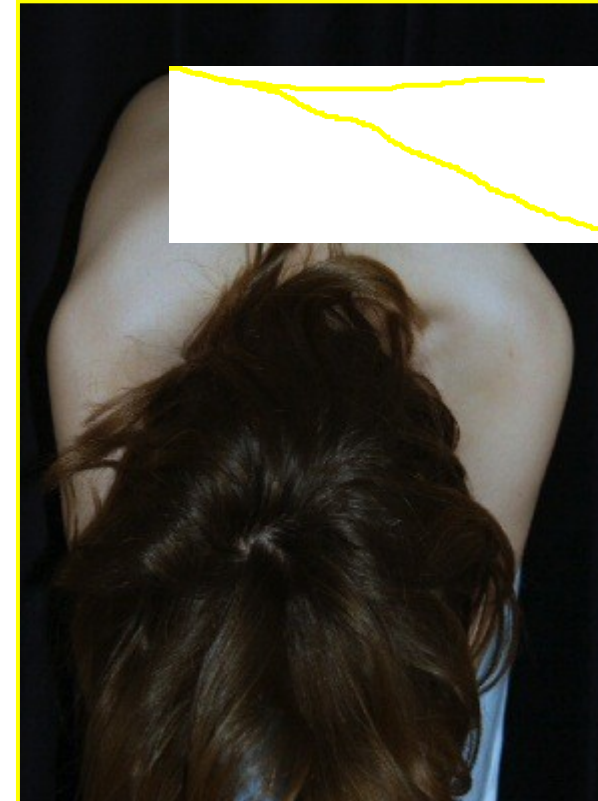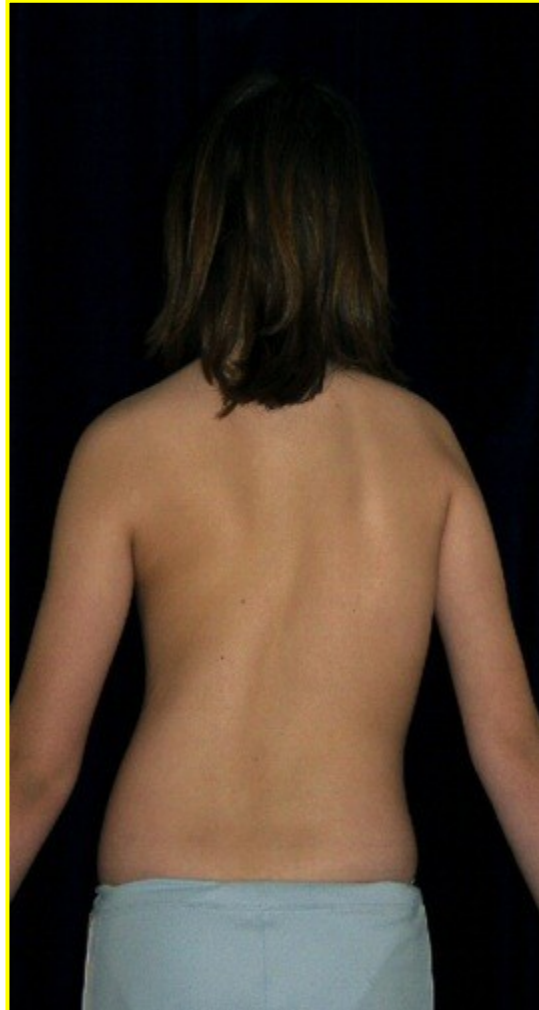
Gibbus – paravertebral prominence

Waist asymetry

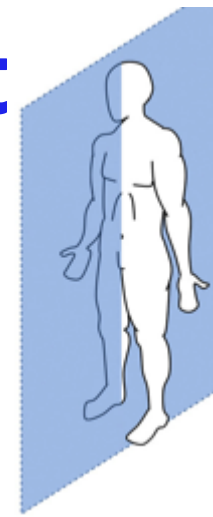Trunk decompensation - frontal plane , C7 plumb line



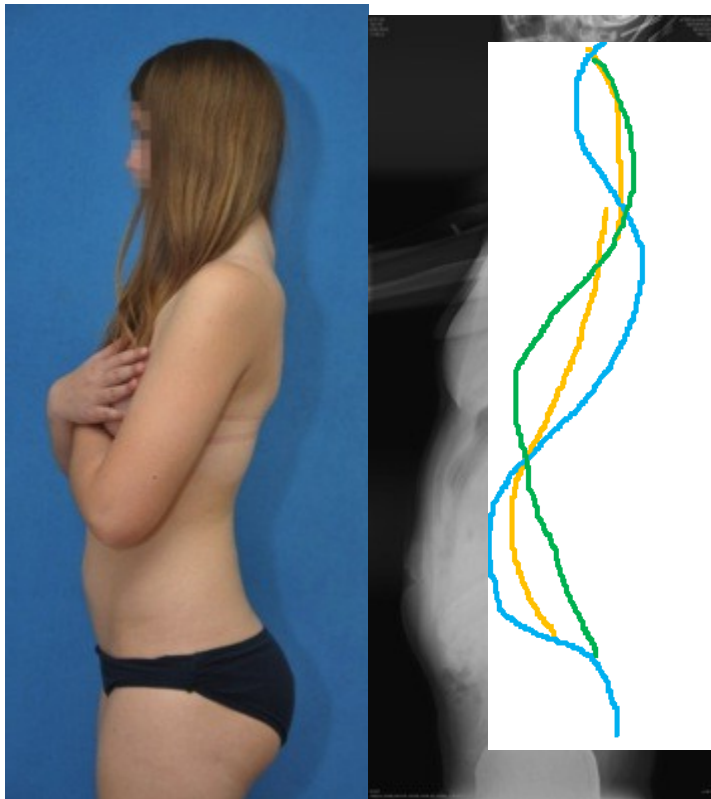
Bending forward! = Adams test





SAGITTAL aspect




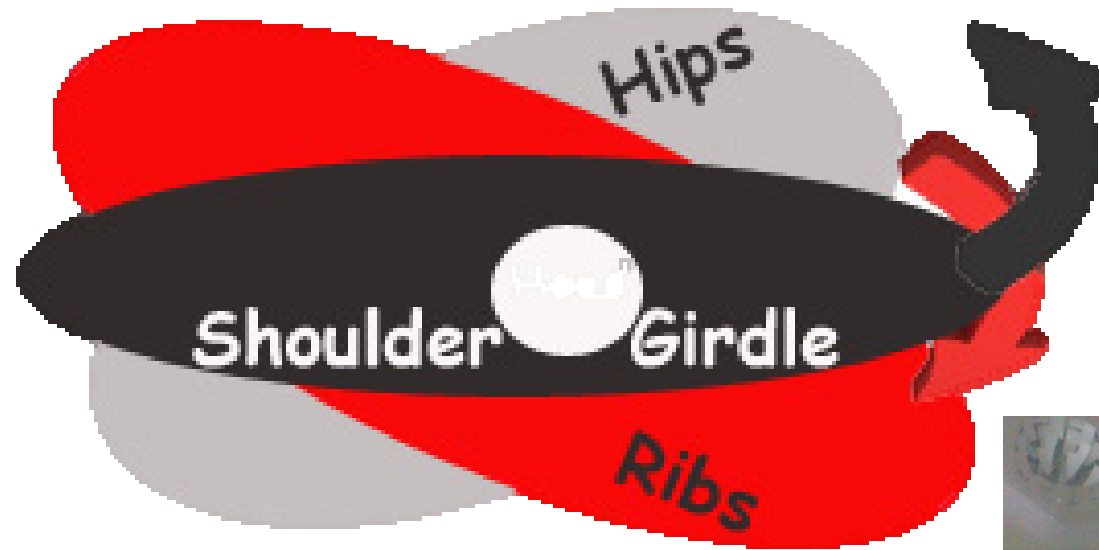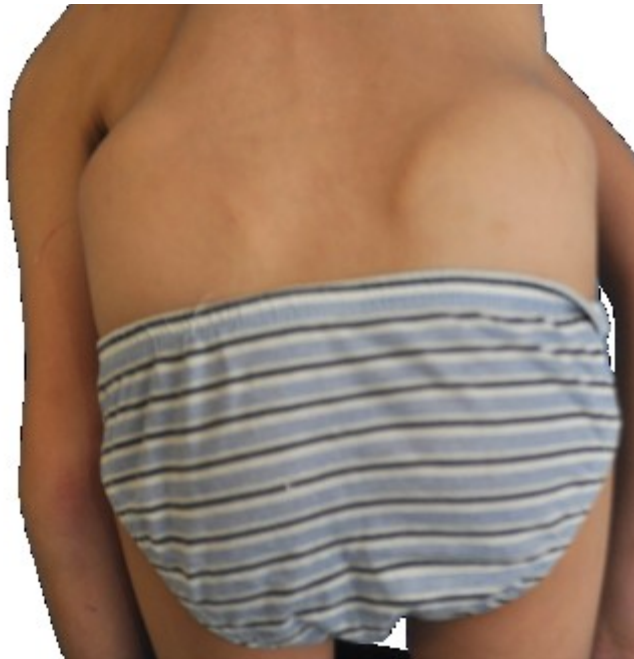
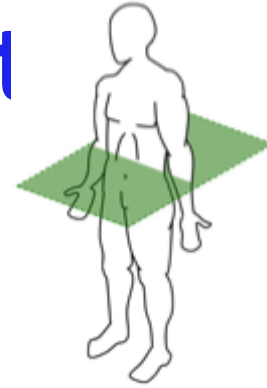
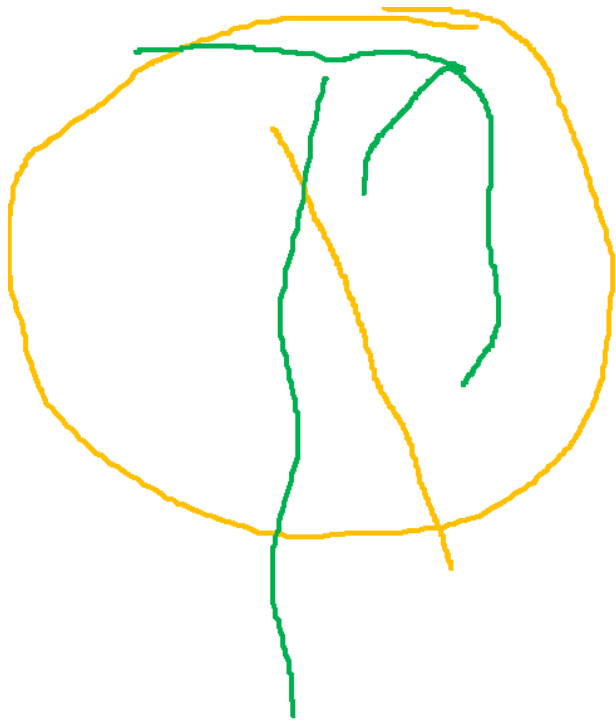HYPOkyphosis




HYPERkyphosis

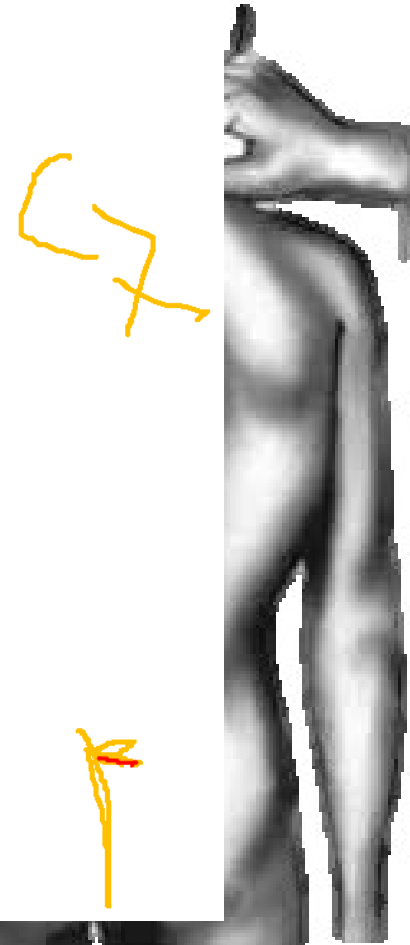


TRANSVERSE aspect

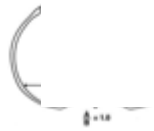




tient
ON



n



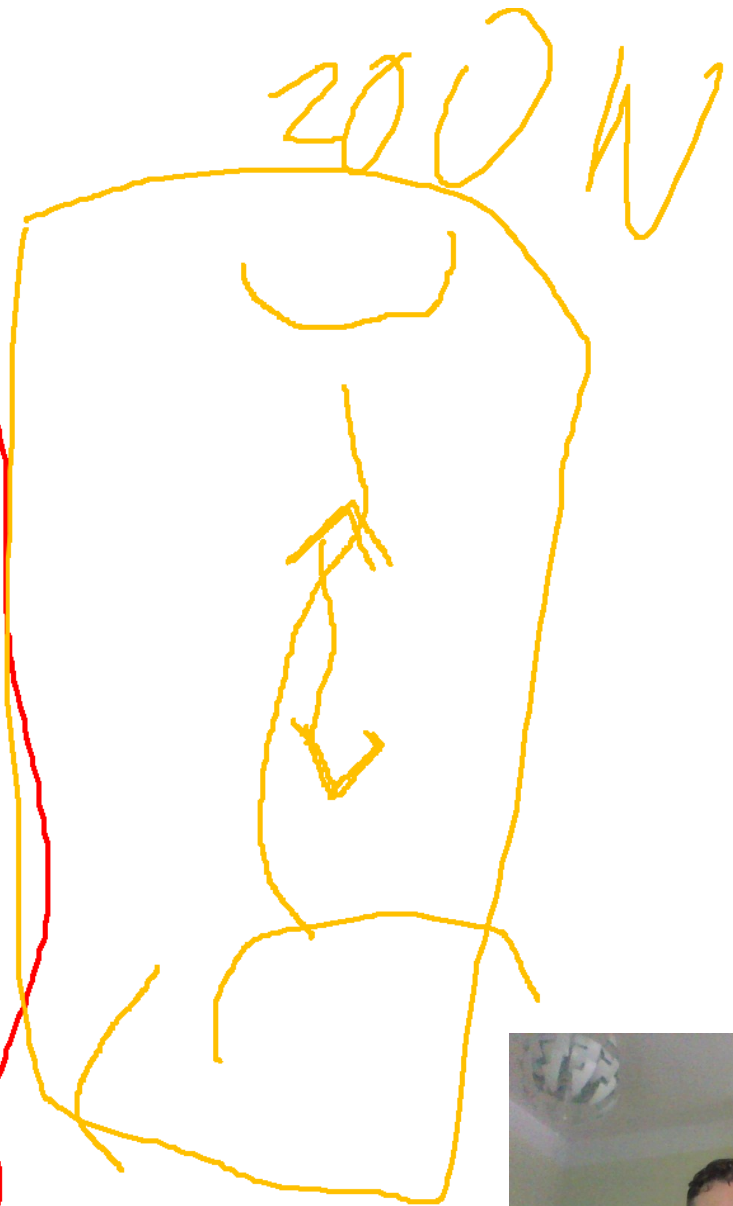

AP


lateral




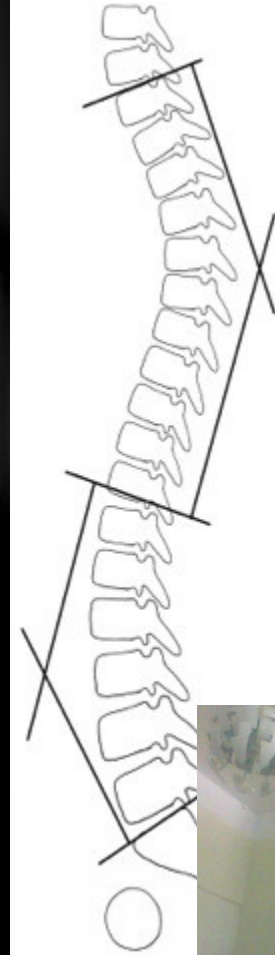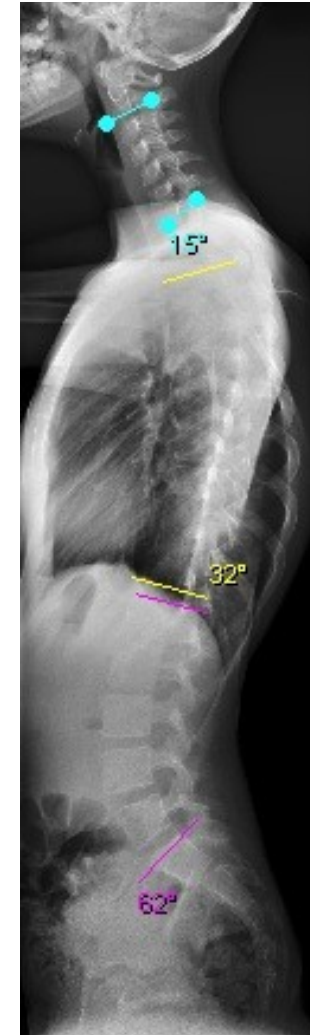
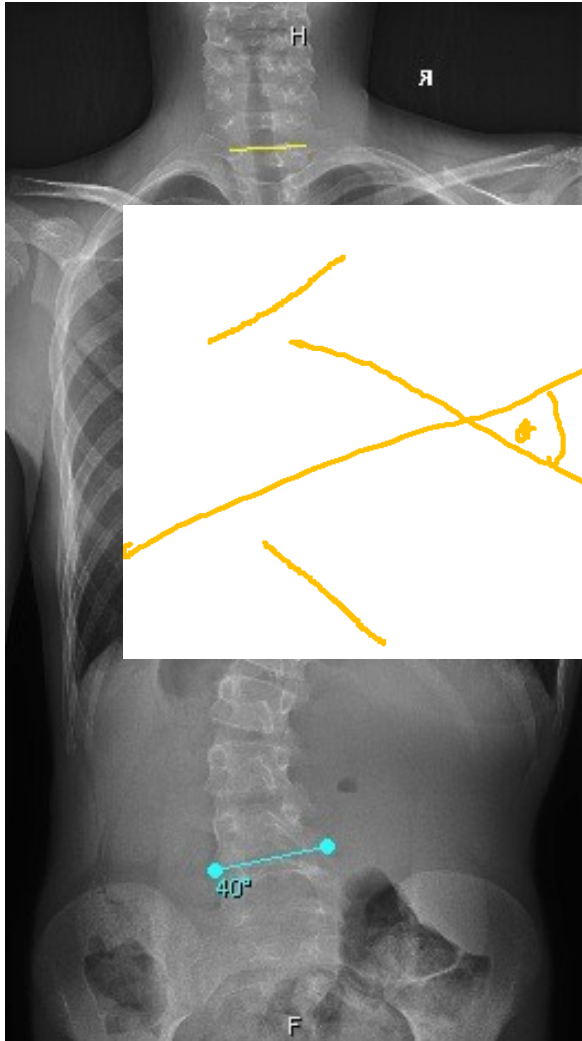
bending




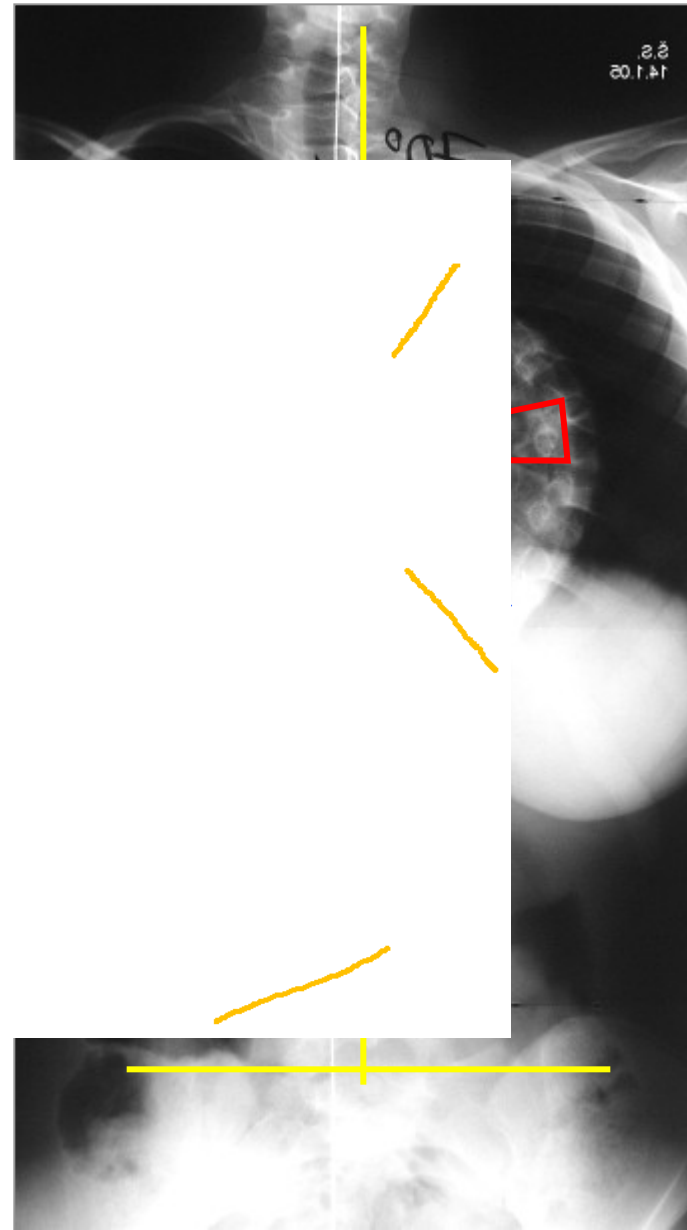
traction

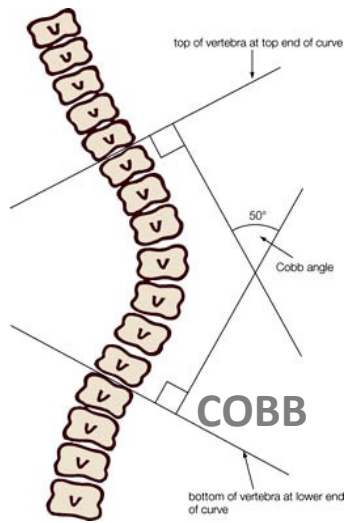


COBB'S angle


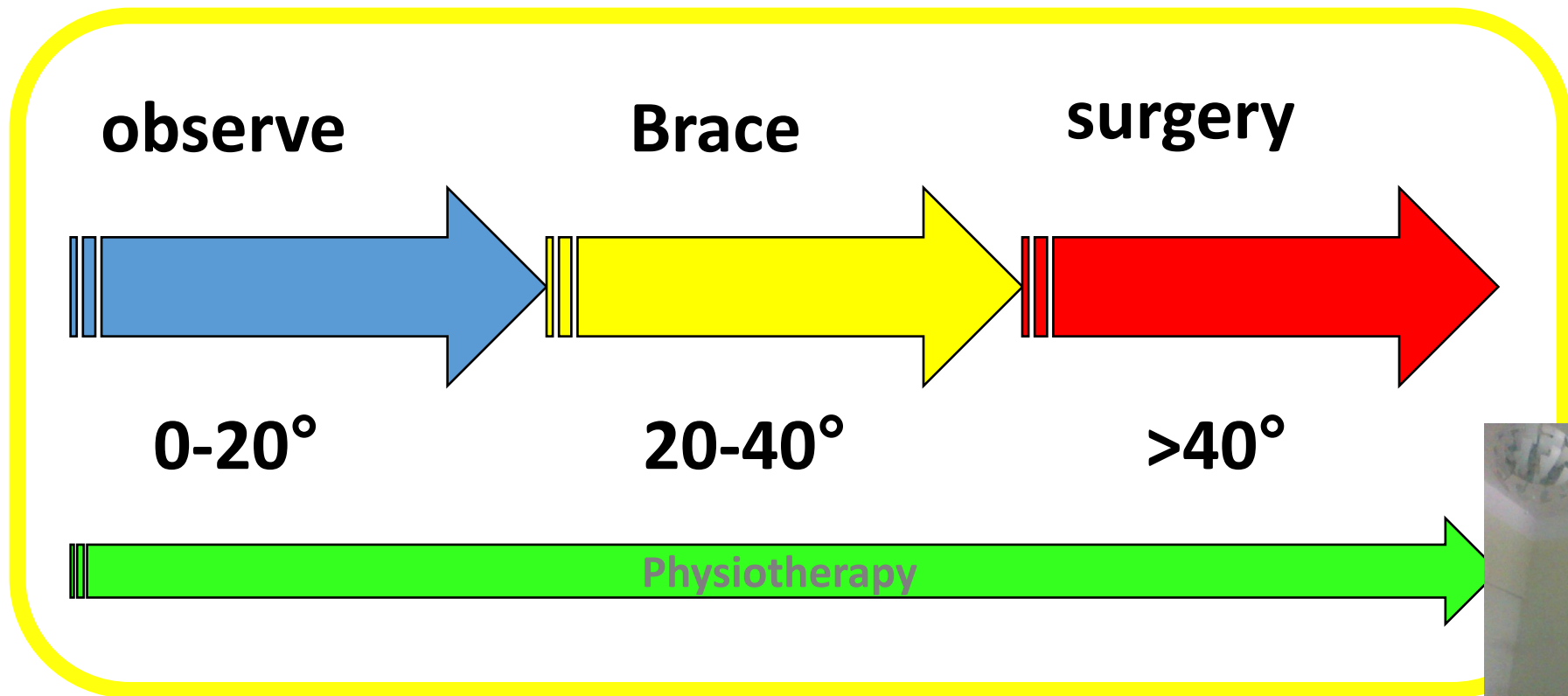


Descriptive terminology







Therapeutic scheme



Natural evolution of untreated juvenile idiopathic scoliosis




Deformity worsening



ad progresion even in adult age !



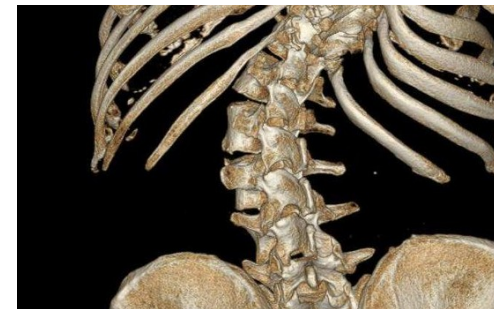
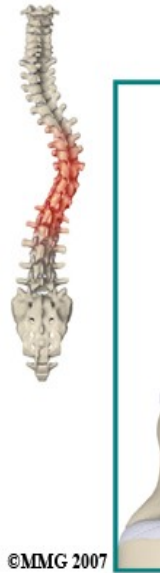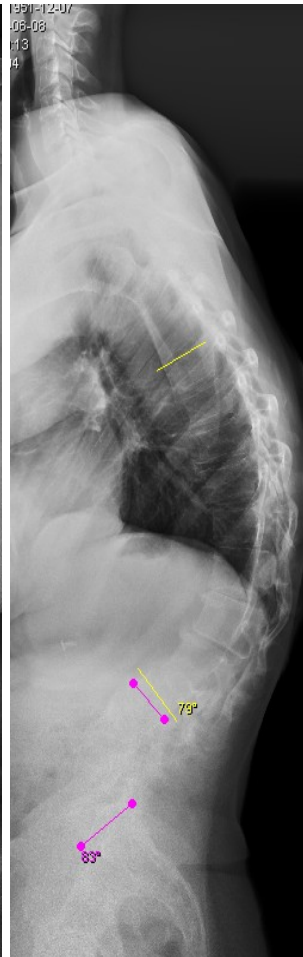
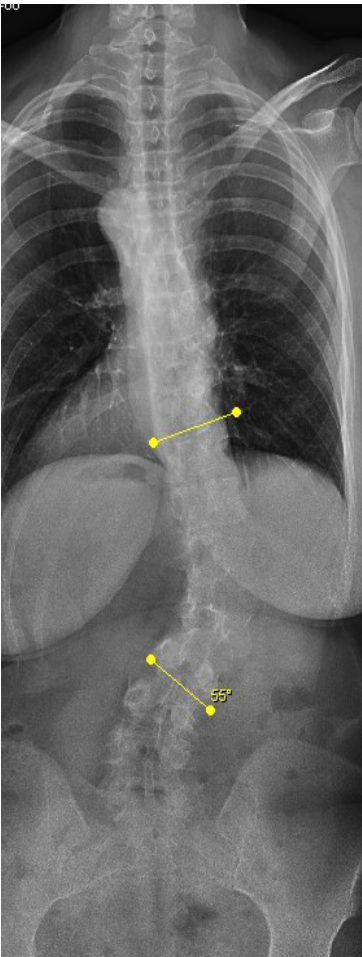
- Thoracic curves - 1 dg./year
- Thoracolumbar curves - 0,5 dg./year
- Lumbar curves - 0,24 dg./year



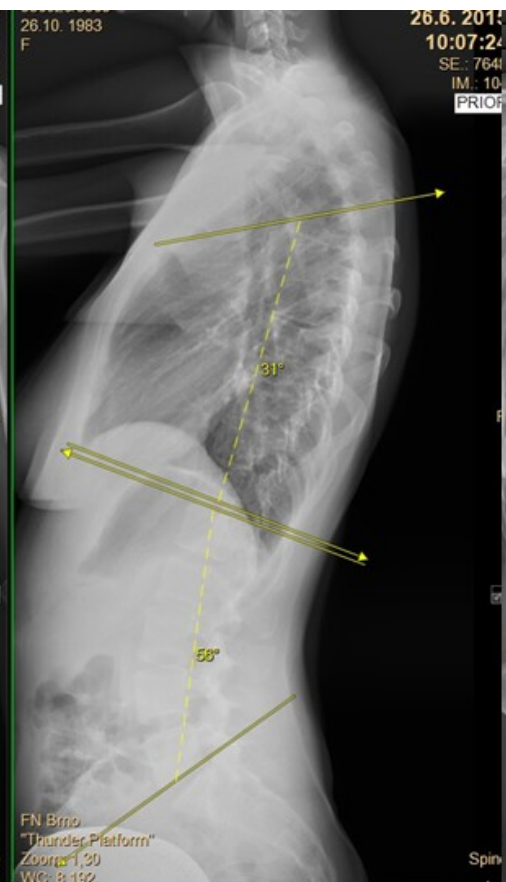
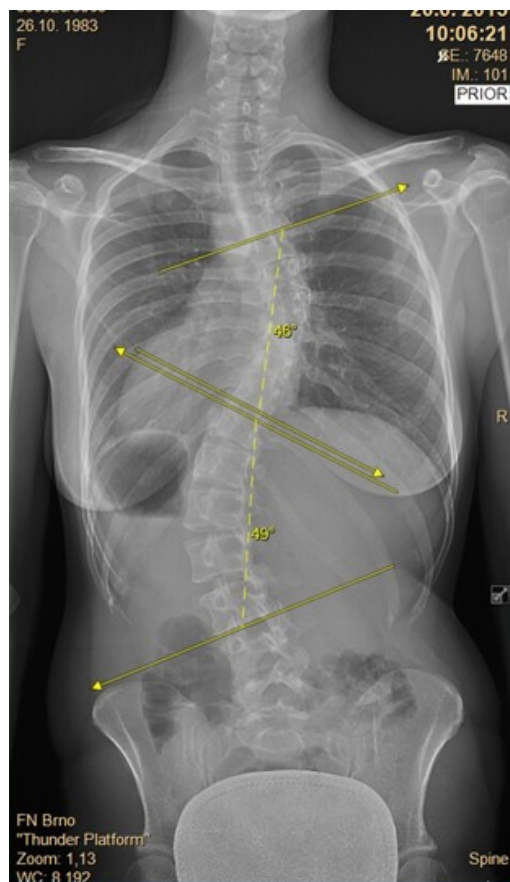
Sever complication of untreated scoliosis in childhood

=

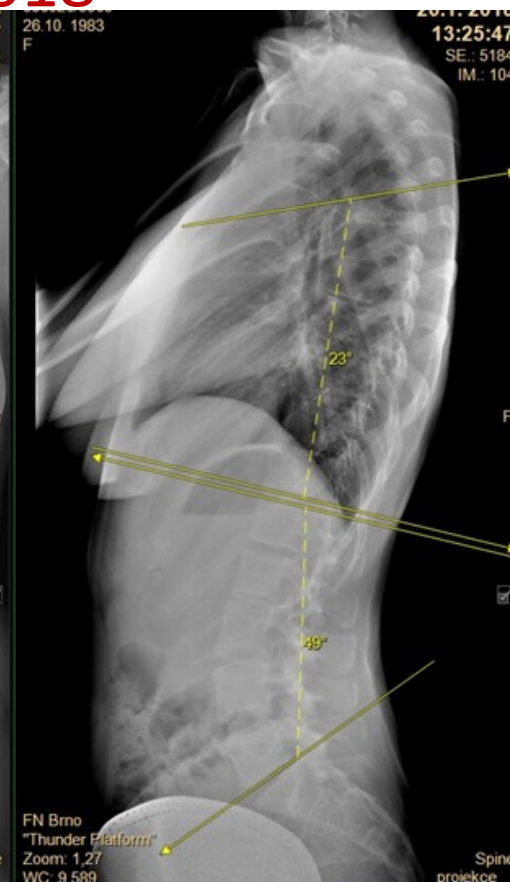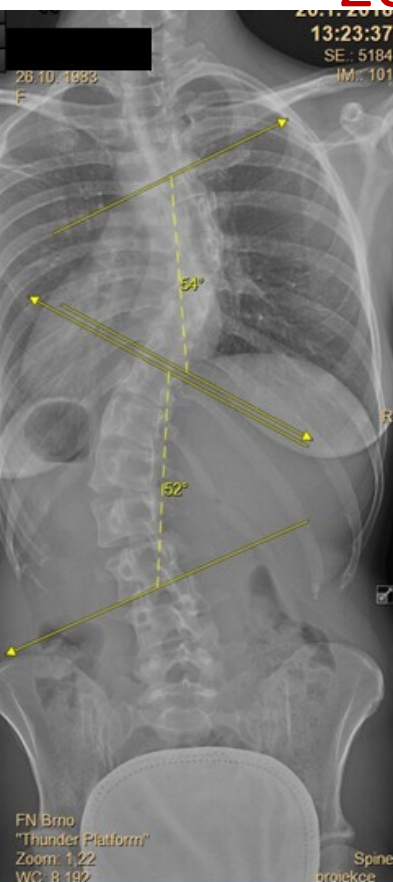
Degenerative changes and cardiopulmonary insufficiency



2015




2018




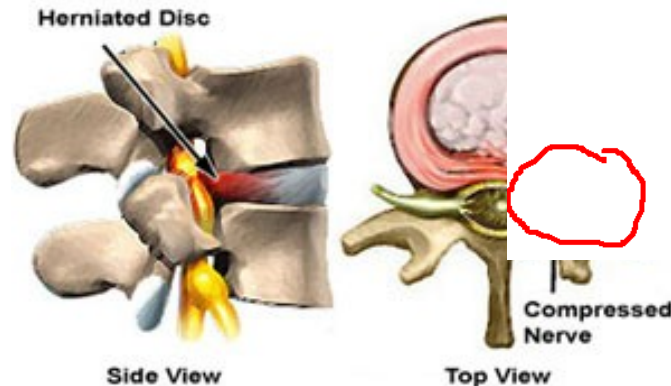
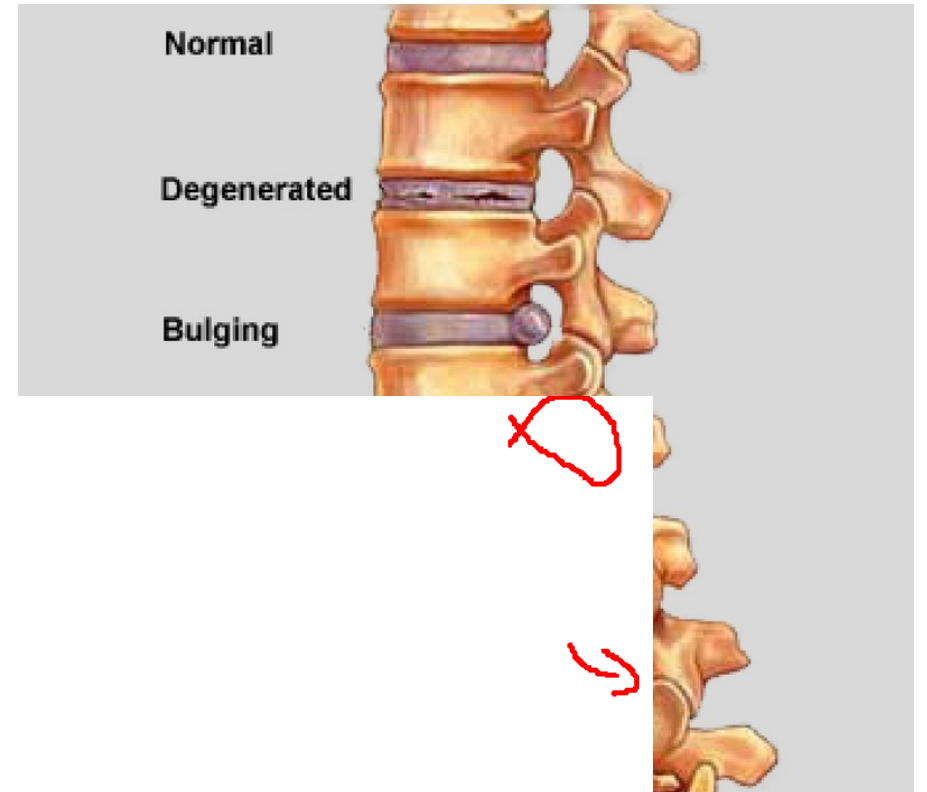
32 let

35 let




Risks of curve progression

- Progressive oppression of intra-abdominal organs
 - Heart + Lungs
 - Indigestion
- **Degeneration of spine structures**
 - Intervertebral joints
 - Intervertebral disc->
production of osteophytes with possible nerve compression !




Goals of scoliosis surgery in childhood

- 1 Stop deformity progression
- 2 Correction of deformity
- 3 Improvement of cardiopulmonary functions
- 4 Prevention of degenerative spine changes




Scoliosis surgery in adult age

- ~~Higher surgery risks with lower rates of deformity correction~~
- Often associated with nerve impairment
- Difficult tolerance of corrected torso and spine position
- Slow postoperative convalescence (pain)
- long-term rehabilitation care is required




Surgical risks in general



1 \downarrow 30%

2

rhythm disorders,
etc.




Surgical risks specific for scoliosis surgery

- Increased postoperative pain due to stretching of shortened muscles - in each patient

1-2%

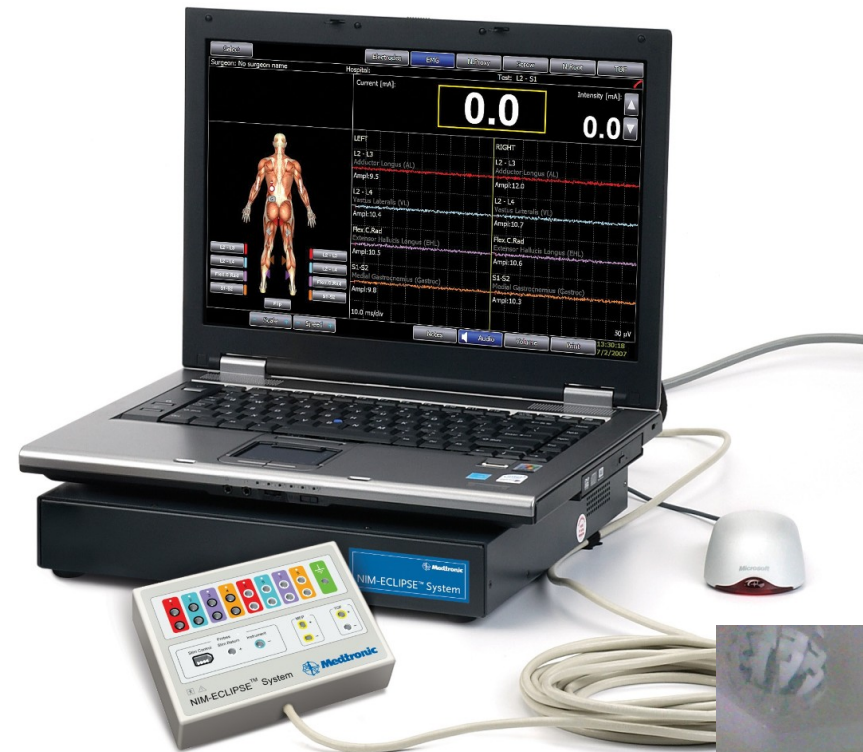
- Paralysis due to surgery
 - For thoracic and lumbar curves it refers to the lower limbs
Very rare complication, but very serious as a result.




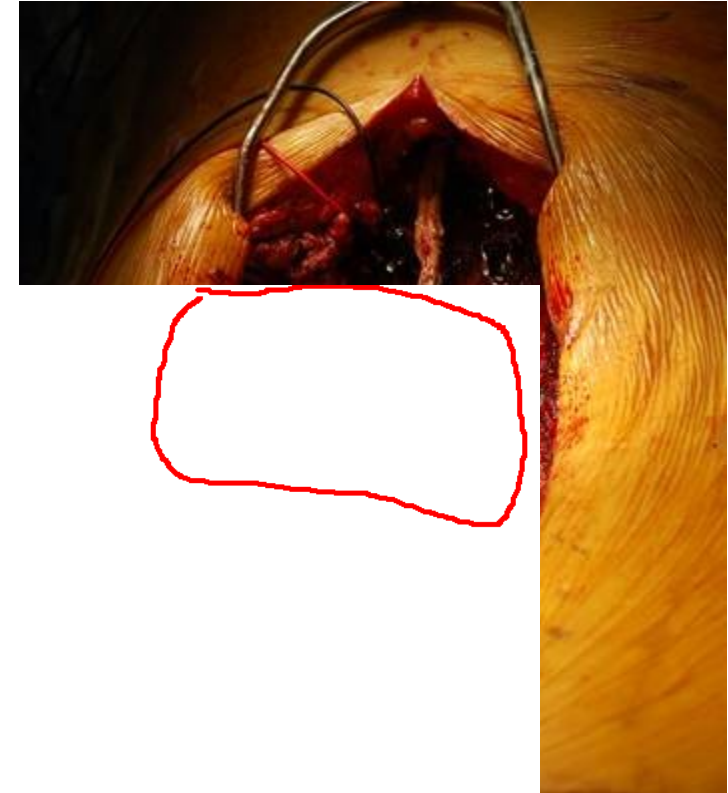
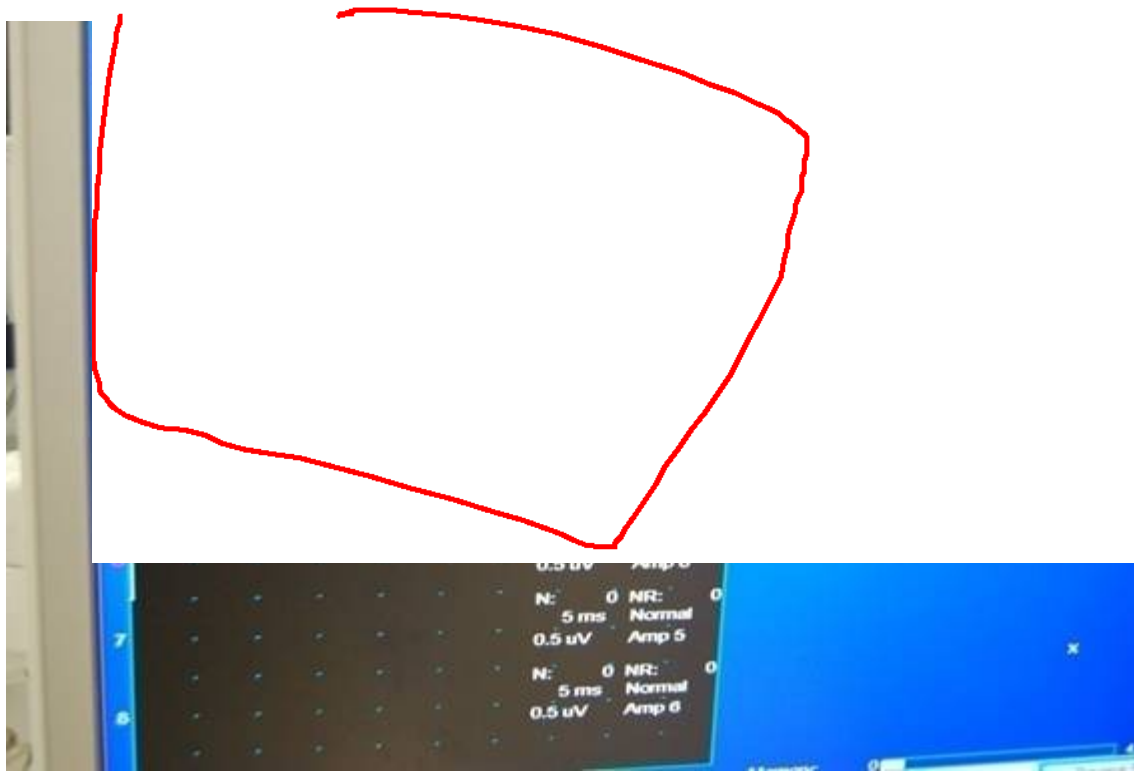
MEP – motor evoked potentials



- Monitoring of nervous system functionality during surgery
- It enables immediate reaction to the problem and thus minimizes the risk of permanent nervous disability






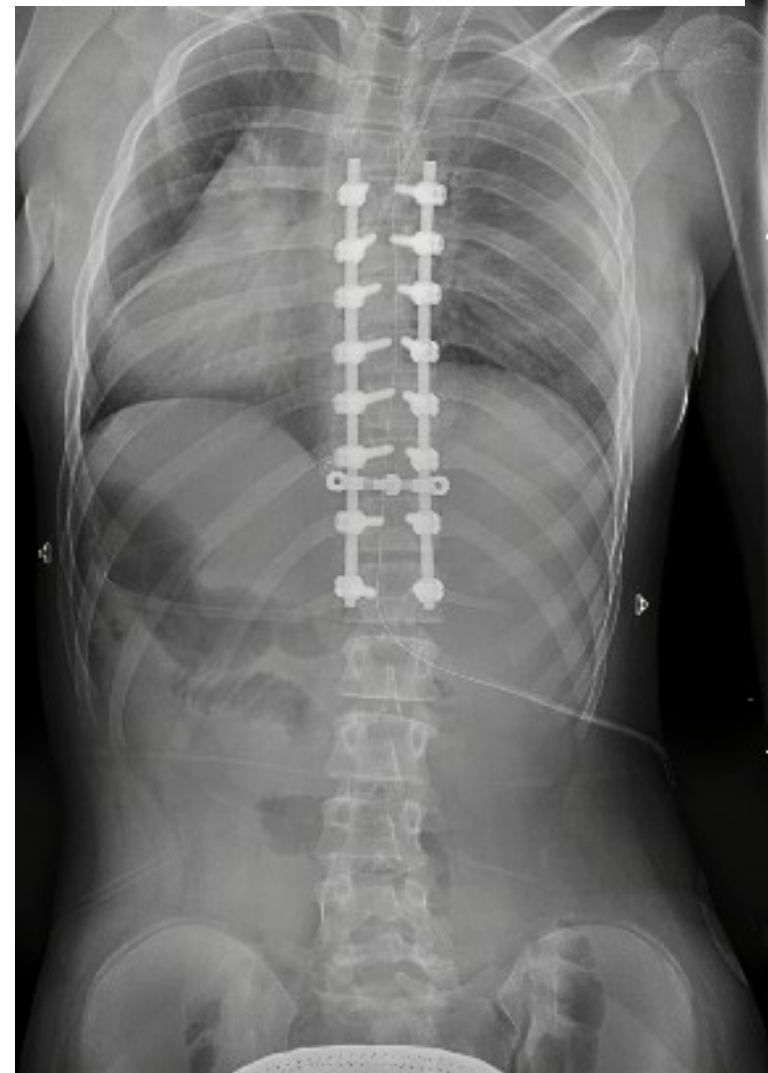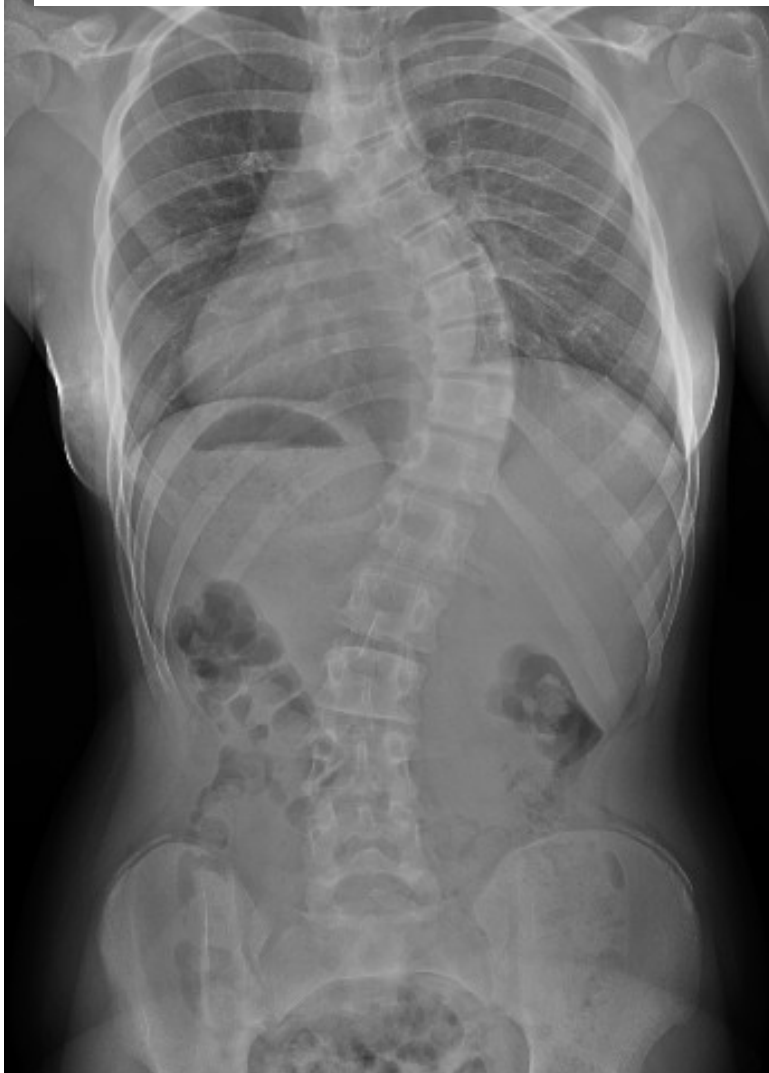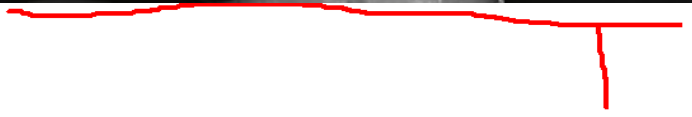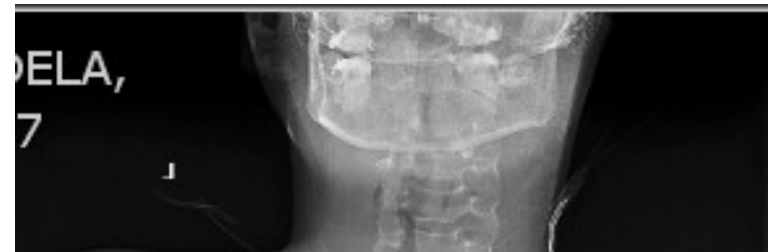
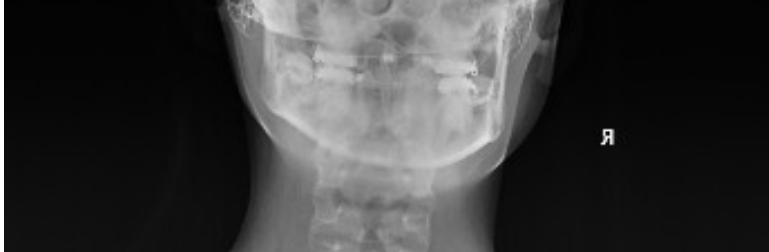MEP – motor evoked potentials (SSEP) SEP a MEP


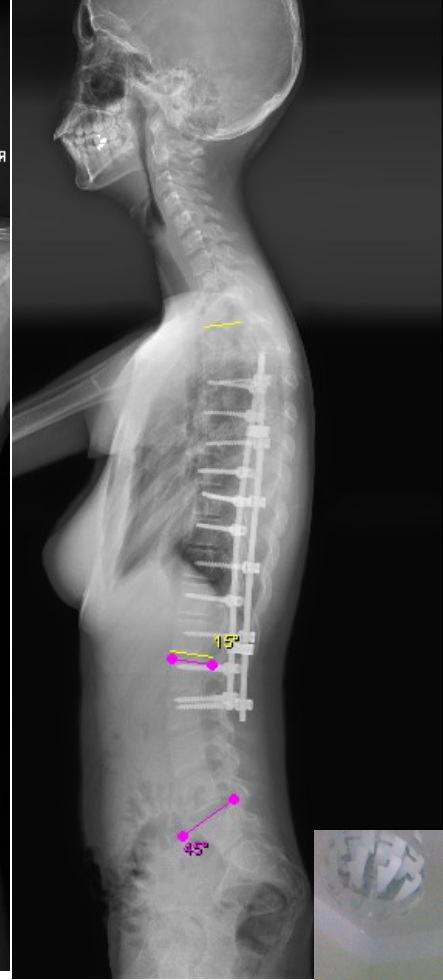
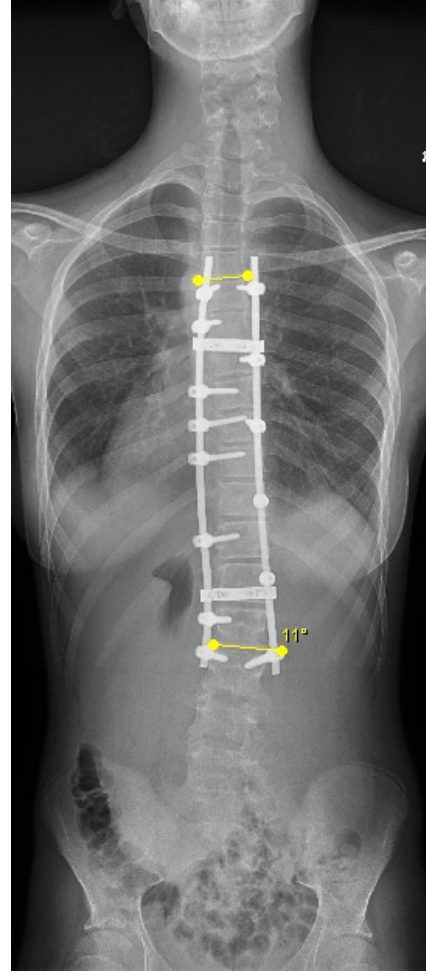
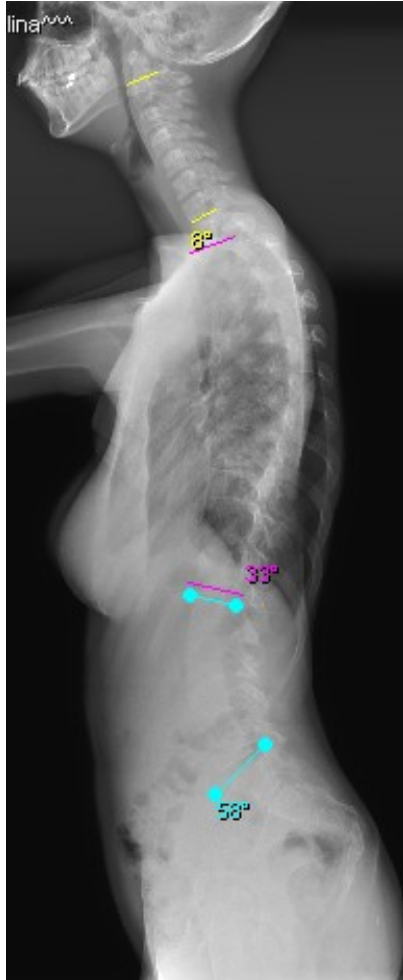
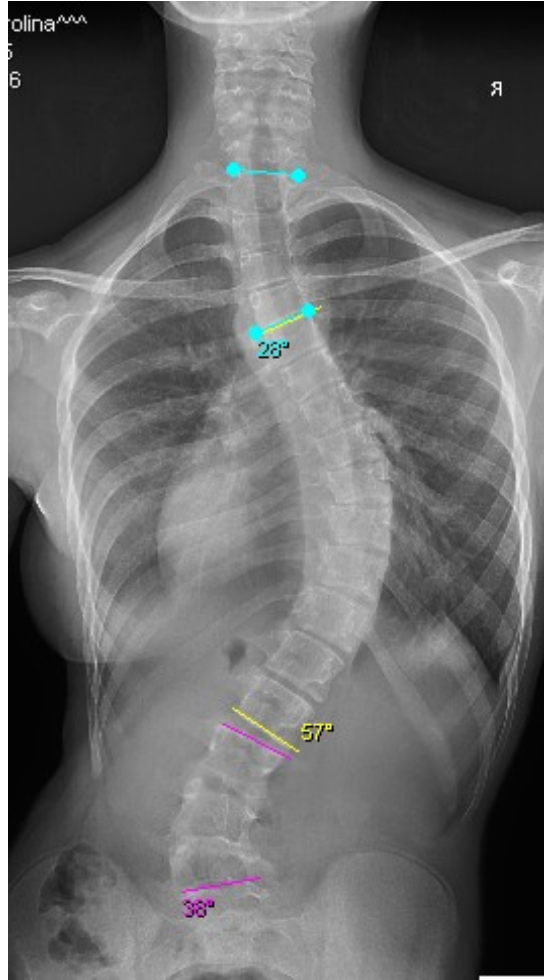

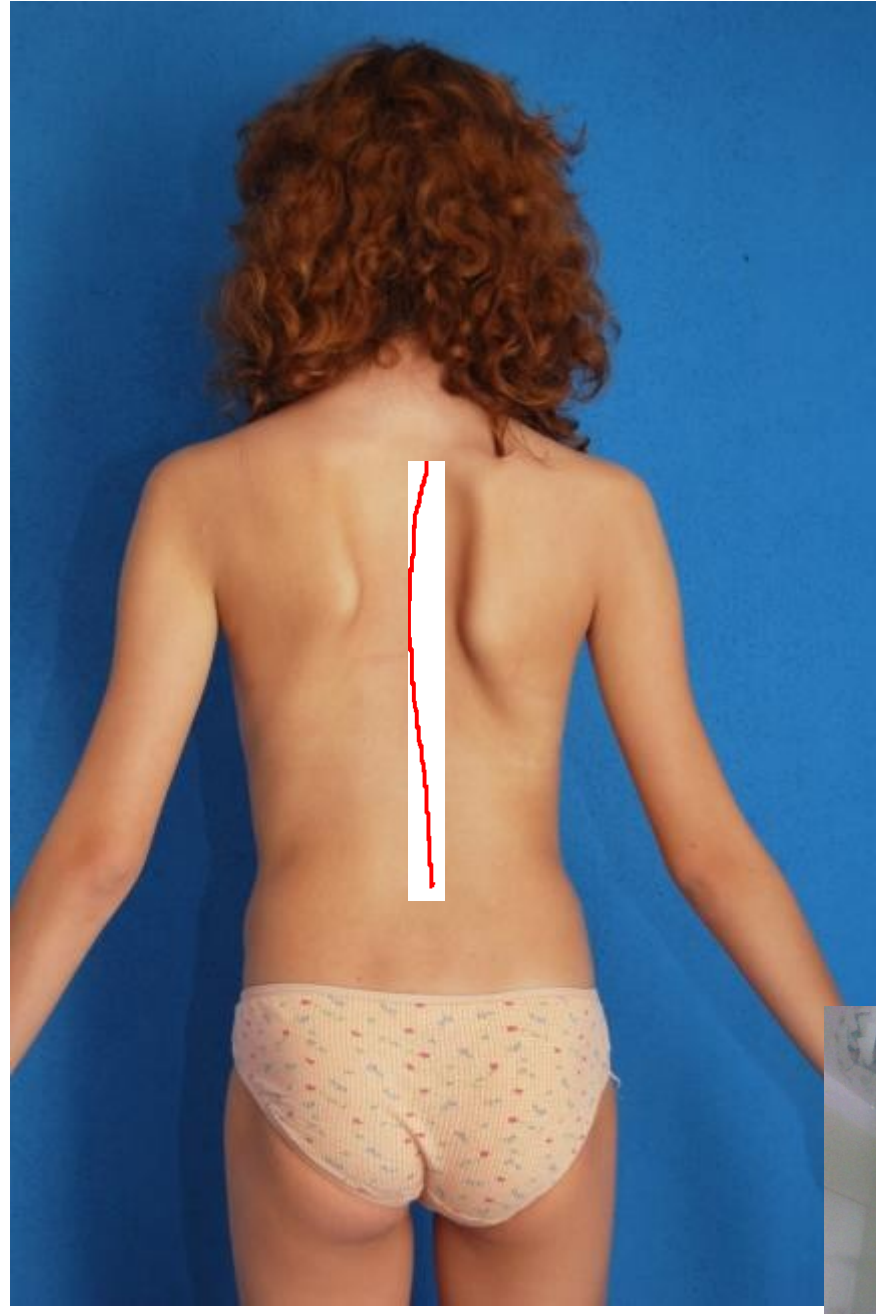

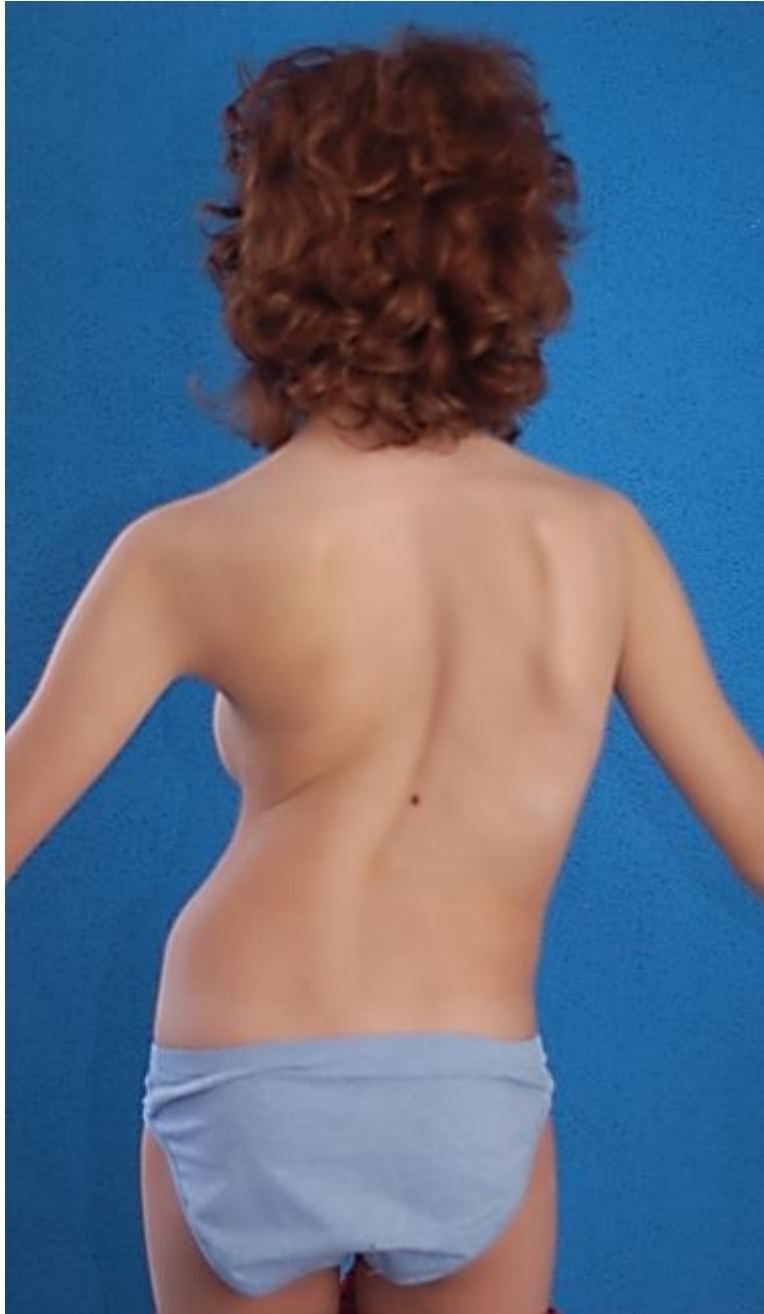
Method of surgical scoliosis treatment.

- Transpedicular screws
- Bended rods
- Bone grafts (autograft)
- = INTERVERTEBRA









Základní pojmy popisné


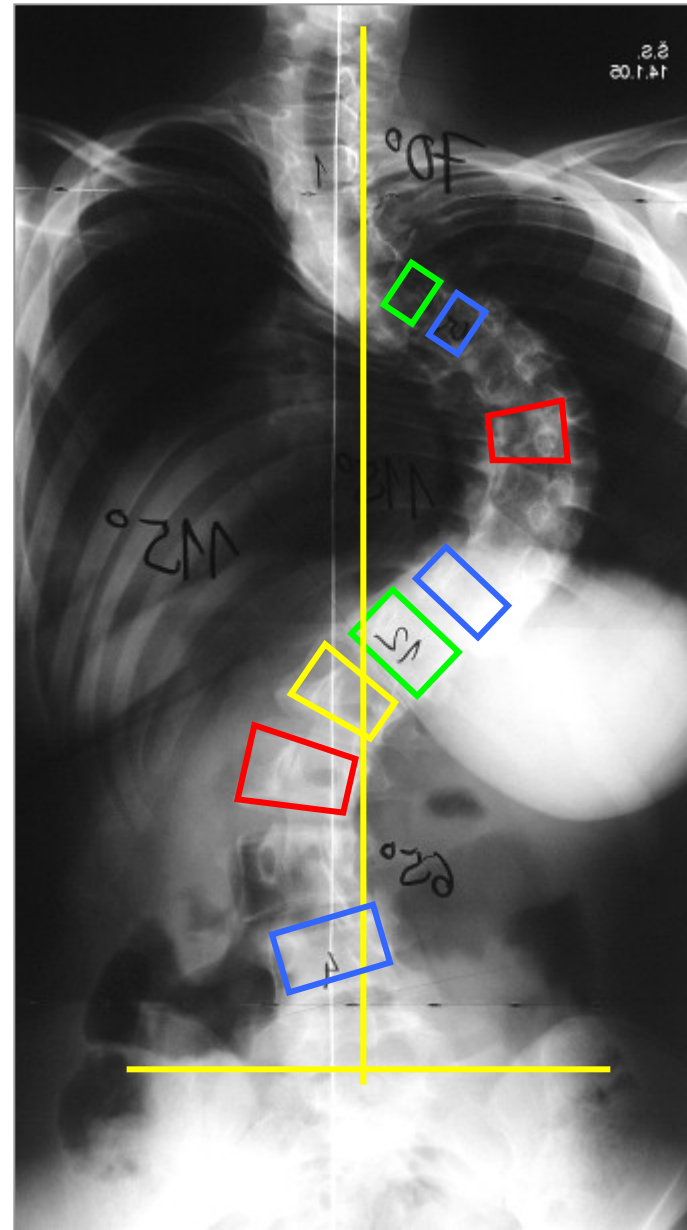
Apical vertebra

End vertebra

Neutral vertebra

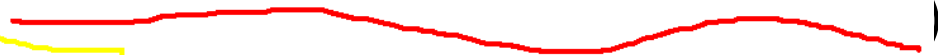
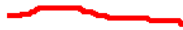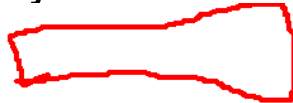CSVL

Stabile vertebra




Scoliosis types due to ethiology

- Idiopathic.....4/5 **80%**
 - infantile
 - juvenile



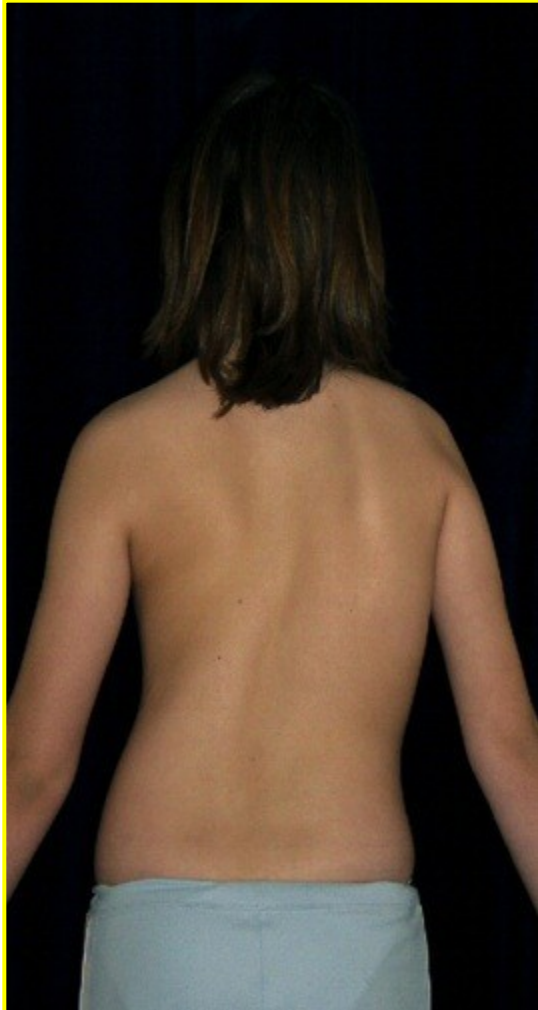Scoliosis types due to ethiology

Deformity type	Age
• <u>Idiopathic</u>	• Infantile < 3 y
• Congenital	• Juvenile 4-10 y
• Neuromuscular	• Adolescent 11-17 y • Adult > 17 y

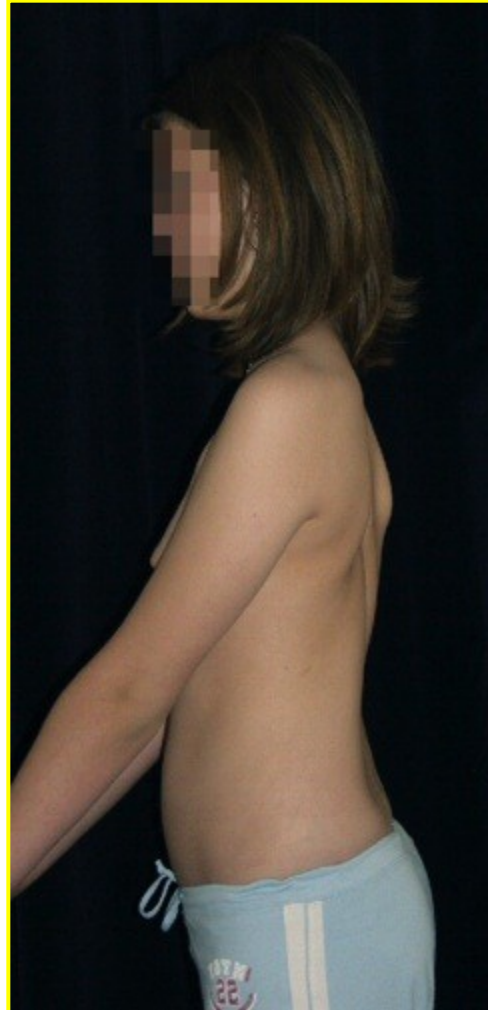

SCOLIOSIS

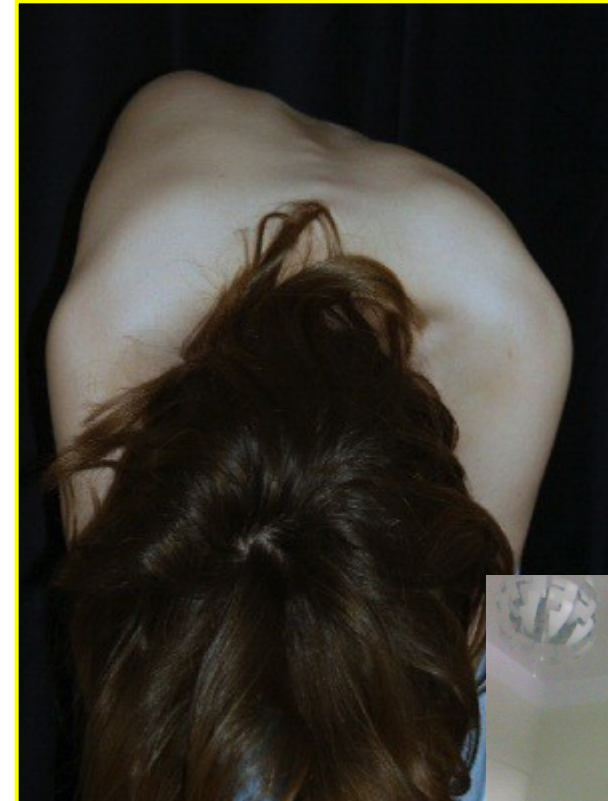
= 3 dimensional deformity



Coronal plane




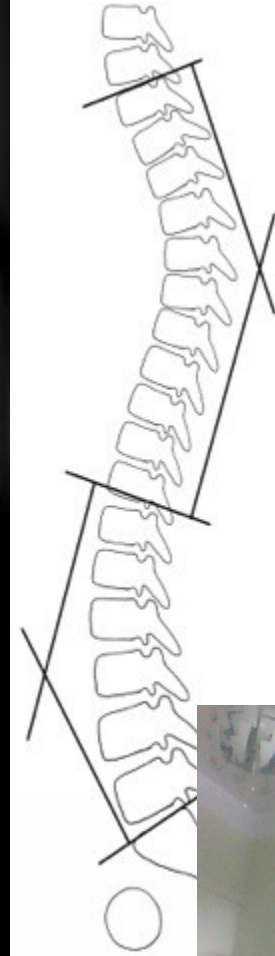
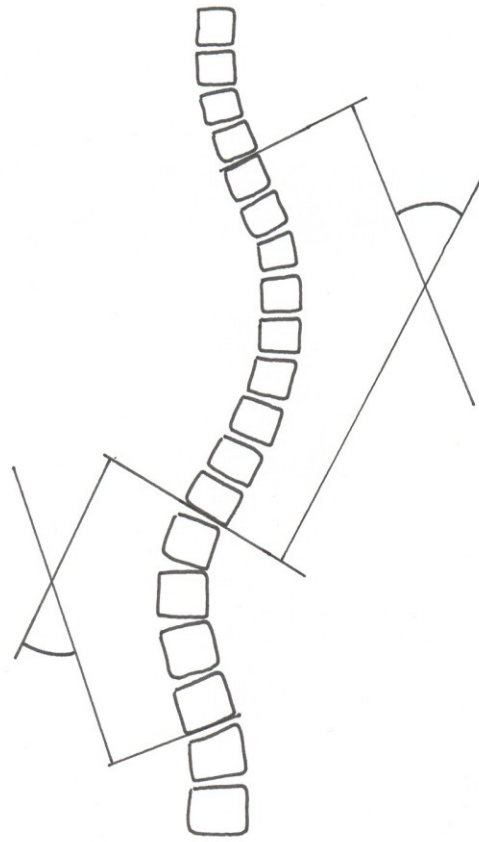
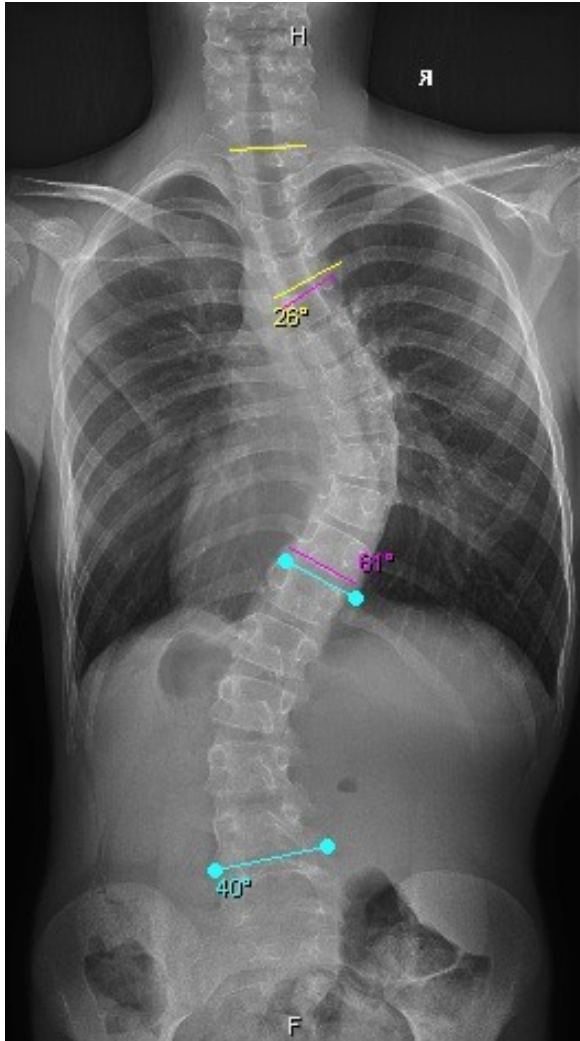
Sagittal plane



Transverse plane



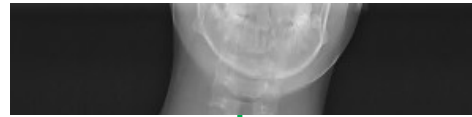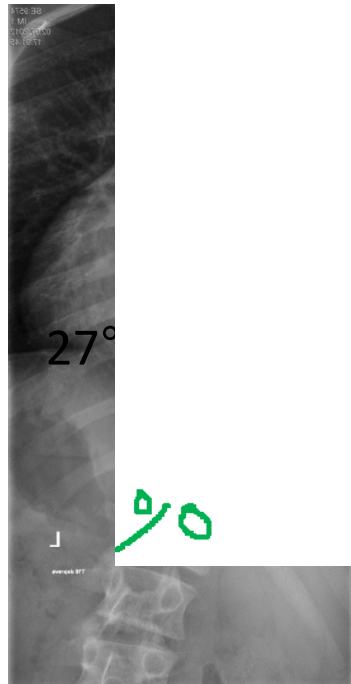COBB'S angle



Essentially distinguish between:


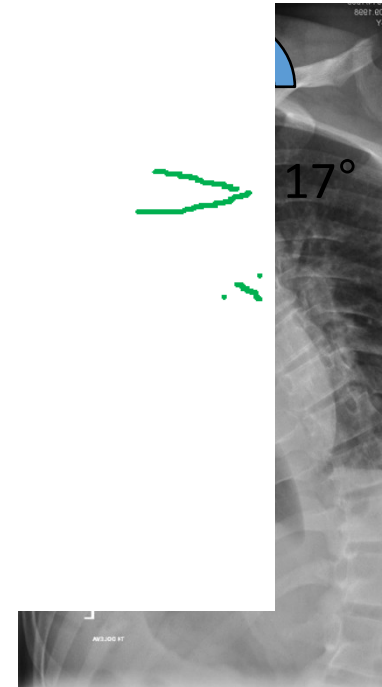
Structural
curve

beno



Non-structural
curve

25

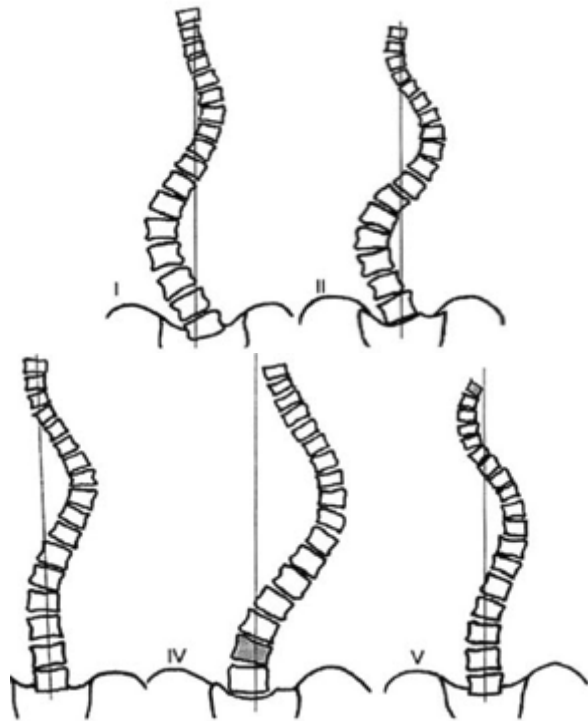


EVOLUTION in scoliotic classifications

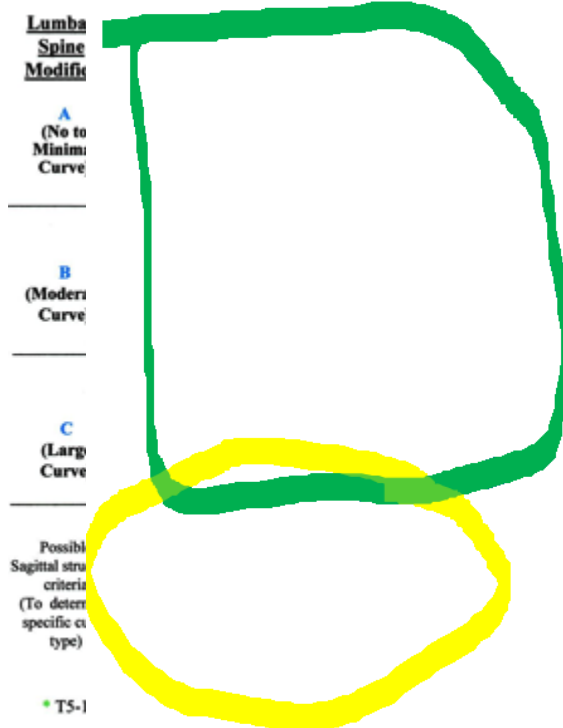
KING-MOE →

1D

frontal



frontal



Lumbar Spine Modification

A
(No to Minimal Curve)

B
(Moderate Curve)

C
(Large Curve)

Possible Sagittal structural criteria
(To determine specific curve type)


• TS-1





LENKE's classification

- **Curve type**
- **Lumbar spine modifier**
- **Thoracic sagittal profile**





LENKE's classification

- Curve type




(Minor Curves)

- Proximal Thoracic - Side Bending Cobb $\geq 25^\circ$
- T2-T5 Kyphosis $\geq +20^\circ$
- Main Thoracic - Side Bending Cobb $\geq 25^\circ$
- T10-L2 Kyphosis $\geq +20^\circ$
- Thoracolumbar/Lumbar - Side Bending Cobb $\geq 25^\circ$
- T10-L2 Kyphosis $\geq +20^\circ$



Minor = All other curves with structural criteria applied
³Type 4 - MT or TL/L can be major curve

**LOCATION OF APEX
(SRS Definition)**

<u>CURVE</u>	<u>APEX</u>
Thoracic	T2-T11/12 Disc
Thoracolumbar	T12-L1
Thoracolumbar/Lumbar	L1/2 Disc-L4







Lenke's classification curve types







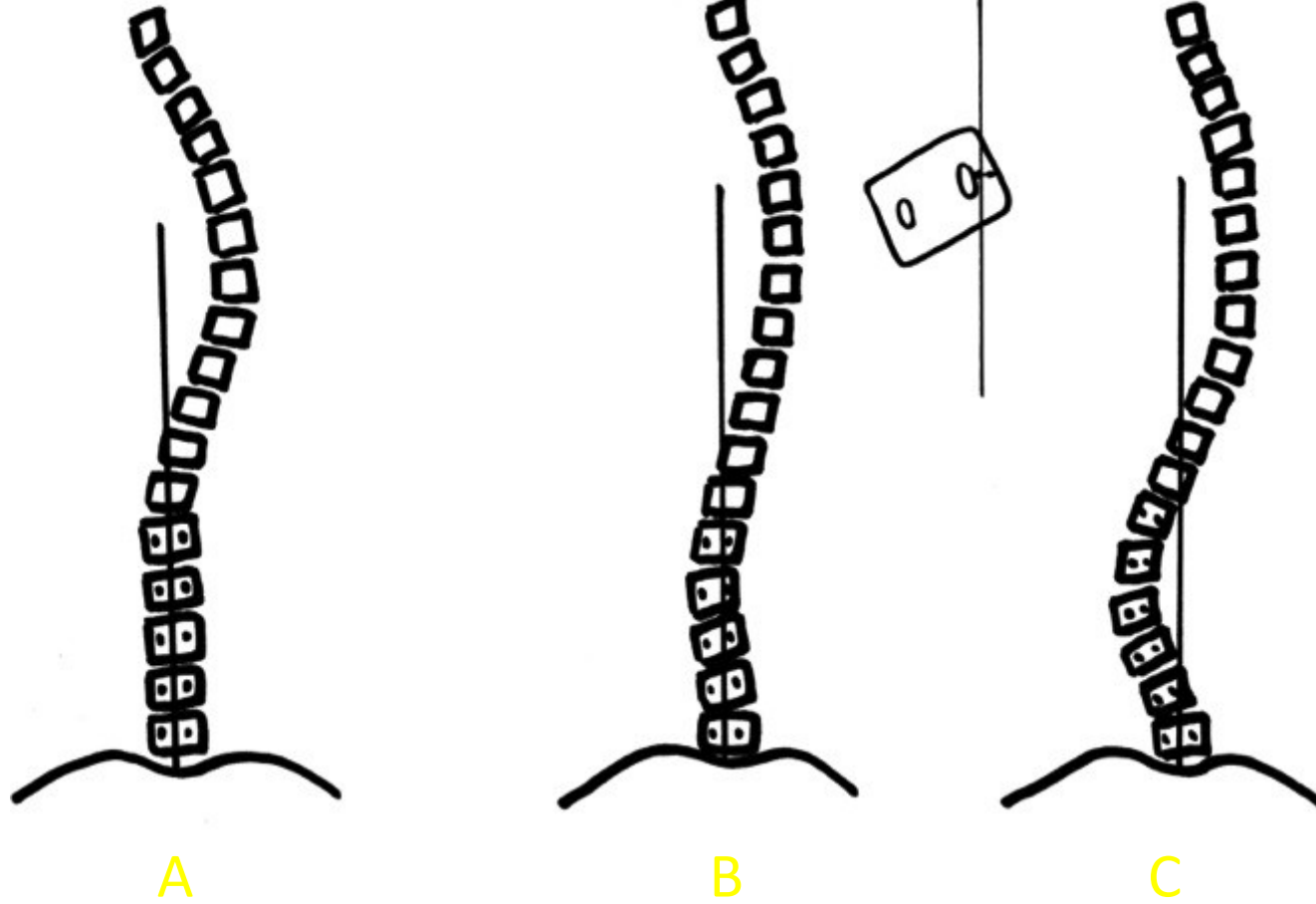
LENKE's classification

- Lumbar spine modifier

Lumbar Spine Modifier				
A				
B				
C				




Lenke's classification lumbar parameter


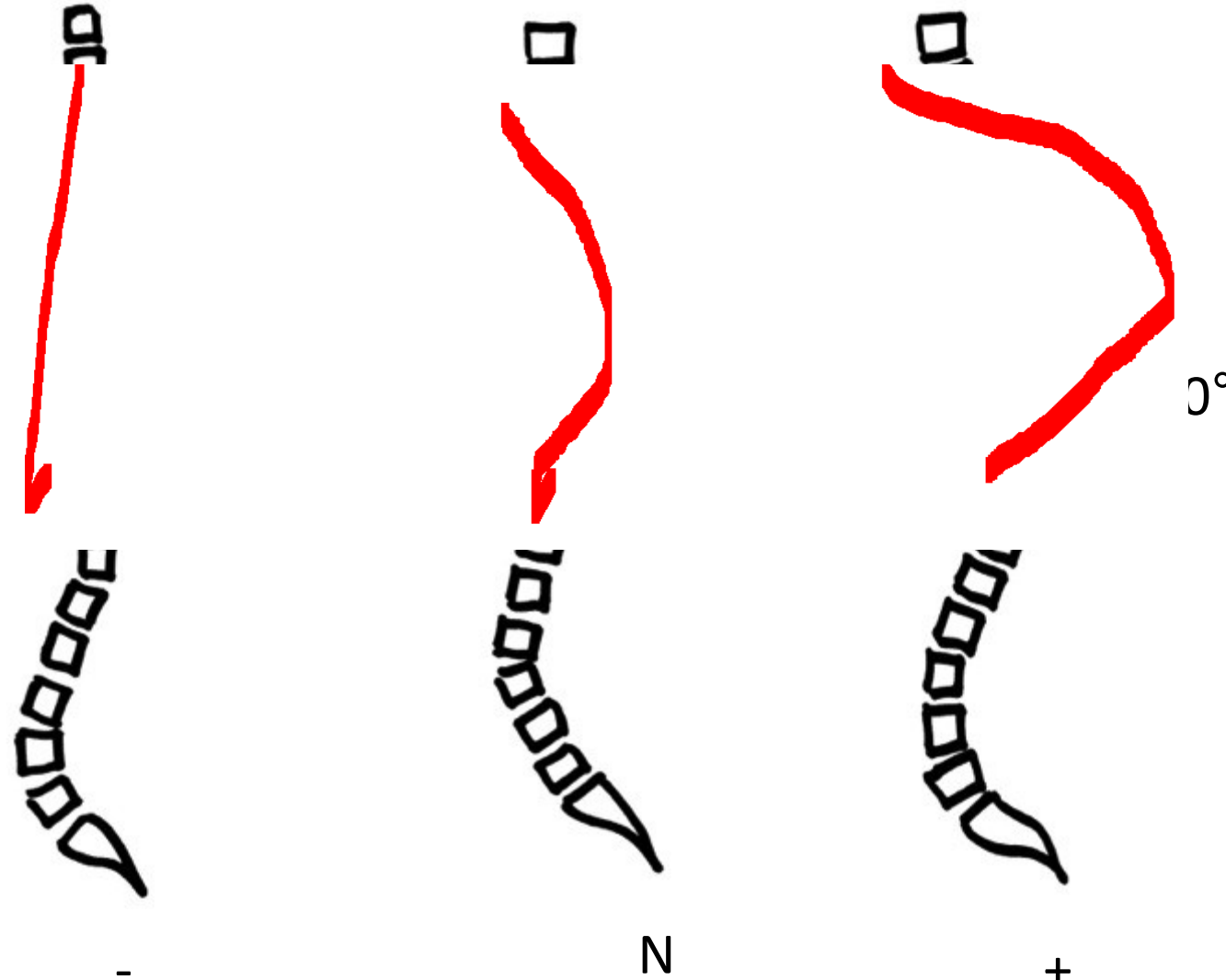




LENKE's classification




Lenke's classification sagittal parameter



Lenke's classification

EXAMPLES

> 40°


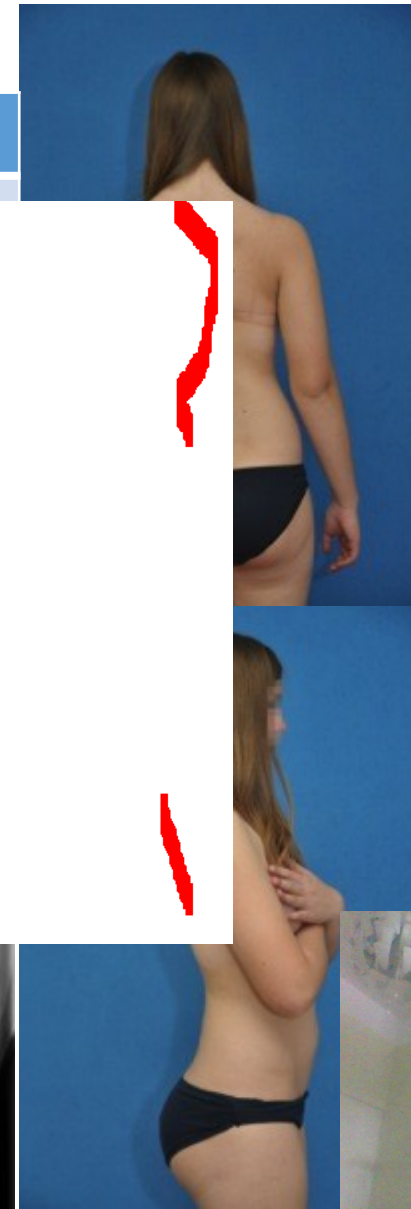
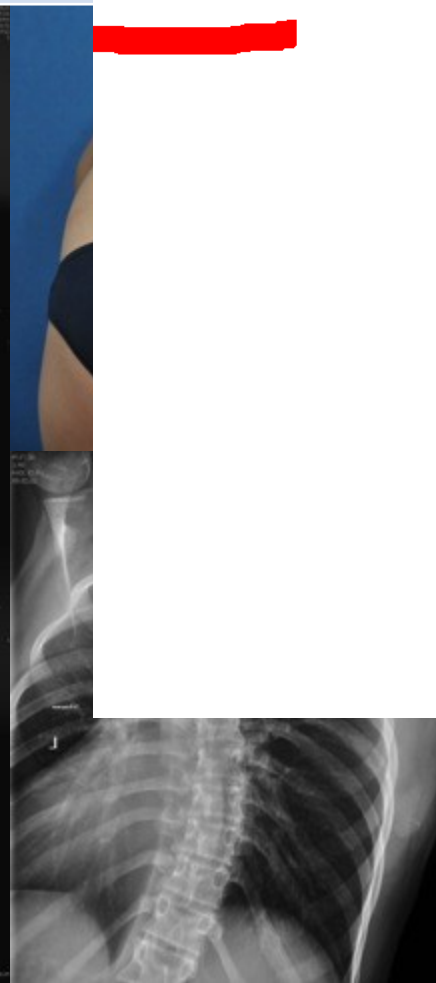
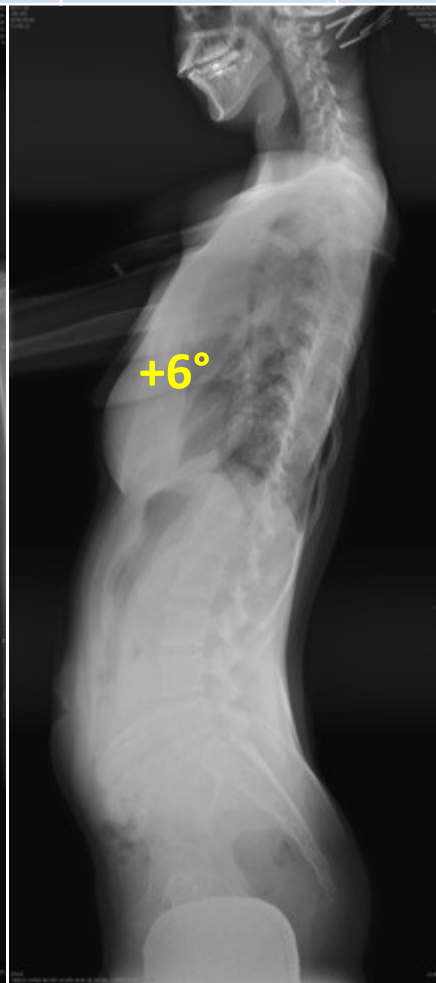
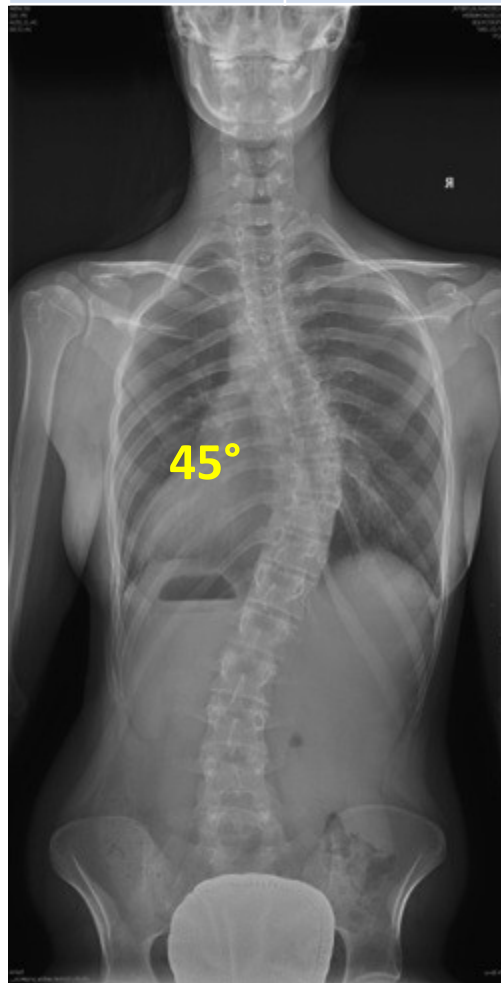


Lenke 1

Lenke 1A-

Girl 13+9

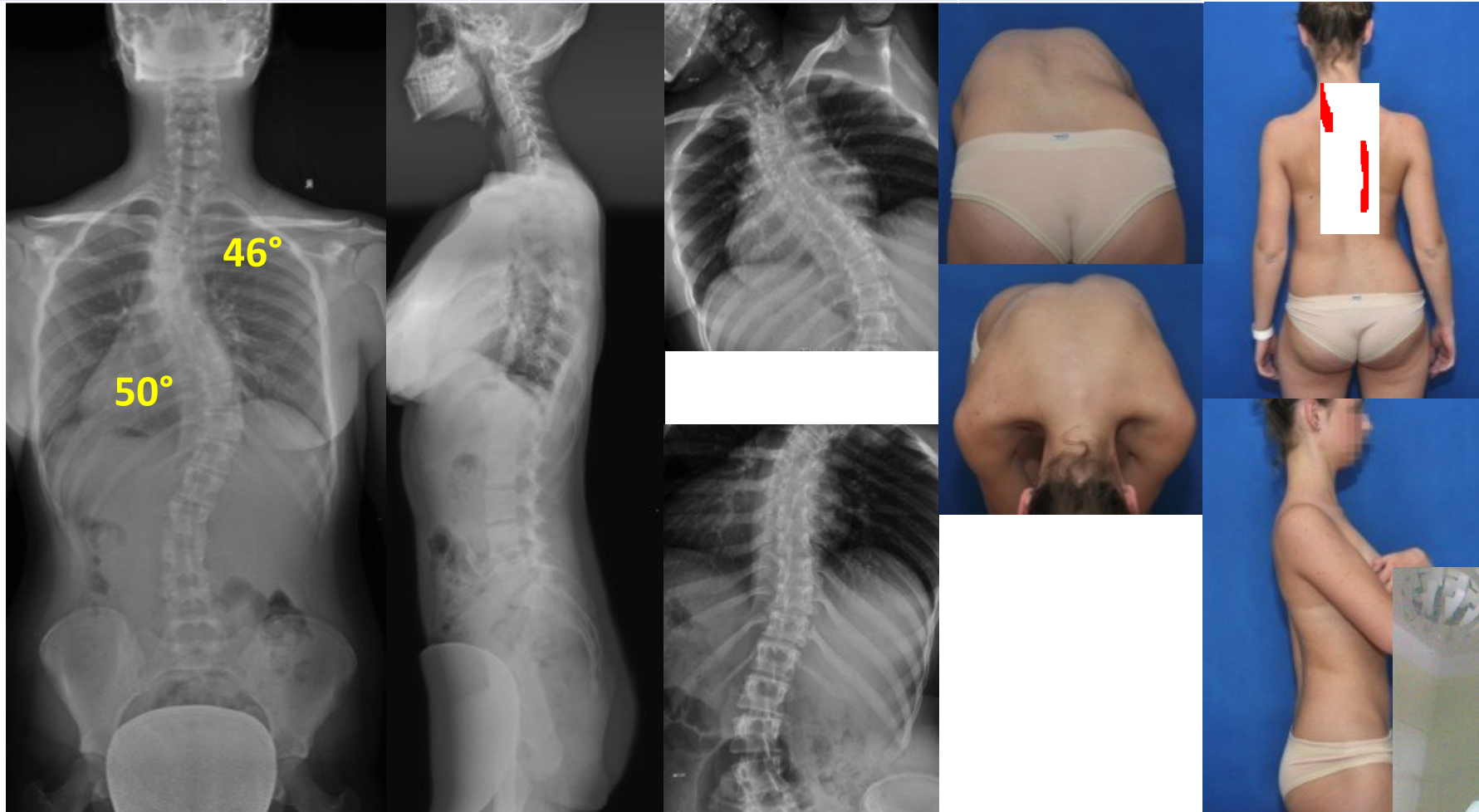
type	Proximal thoracic	Main thoracic	Thoracolumbar/lumbar	Description
1	Non-Structural	Structural (Major)	Non-Structural	MT (Main Thoracic)



Lenke 2

Girl 14+1

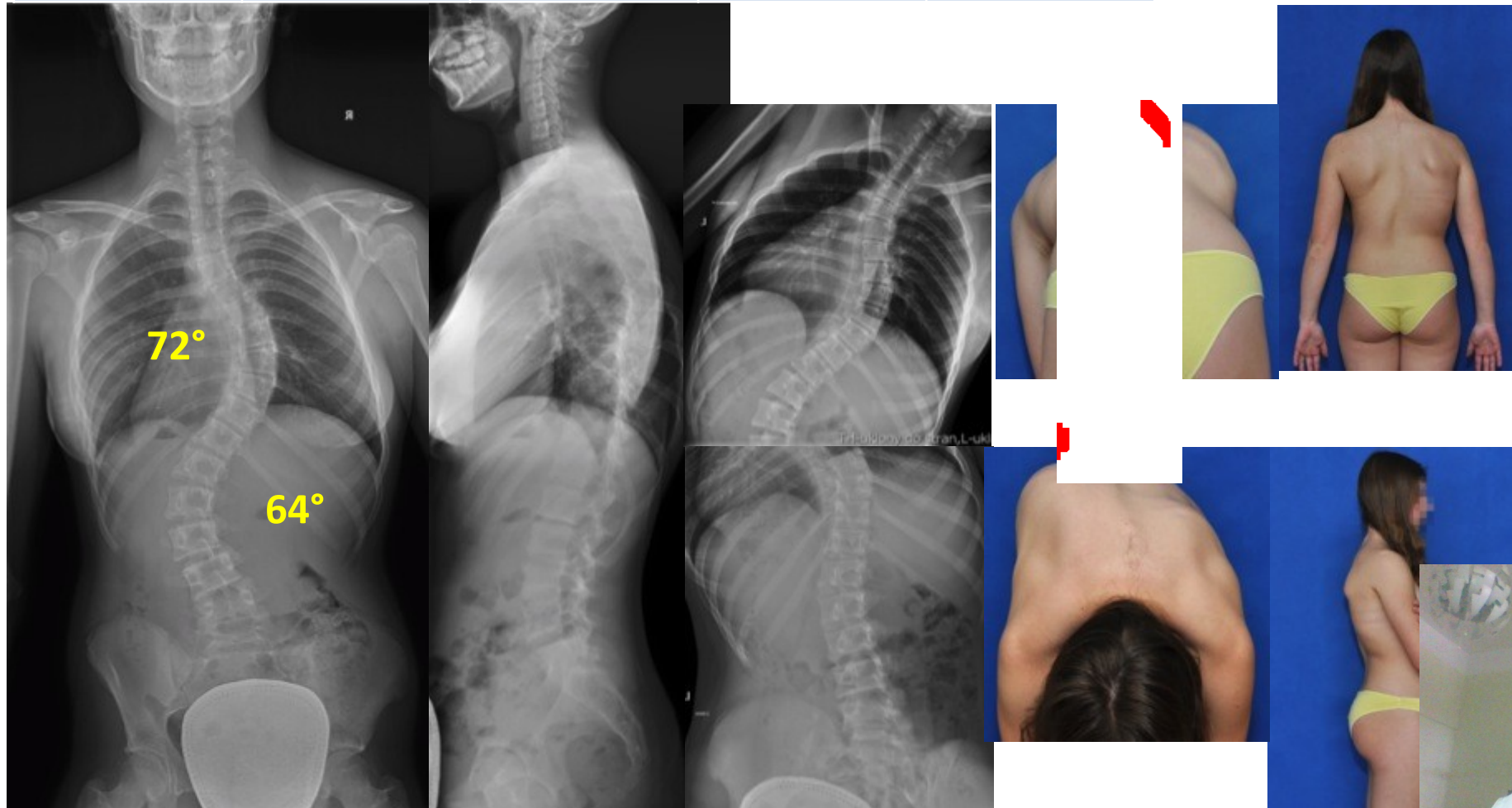
type	Proximal thoracic	Main thoracic	Thoracolumbar/lumbar	Description
2	Structural	Structural (Major)	Non-Structural	DT (Double Thoracic)



Lenke 3

Girl 14+2


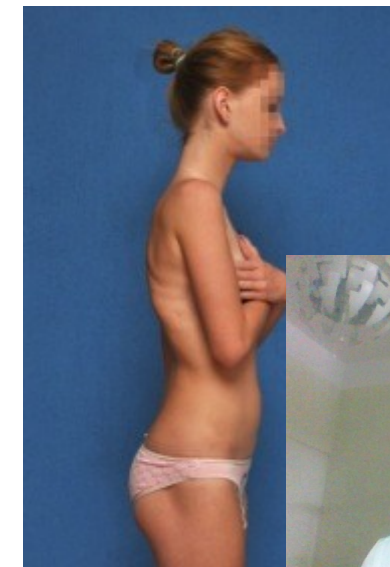
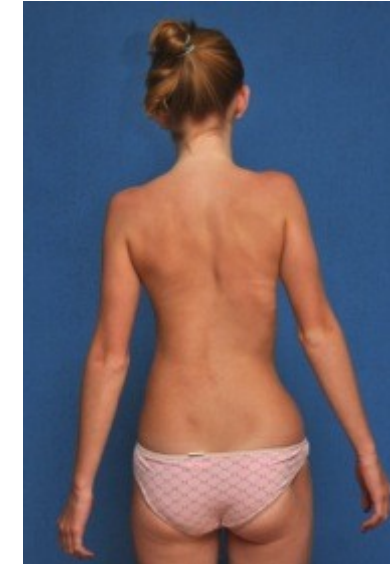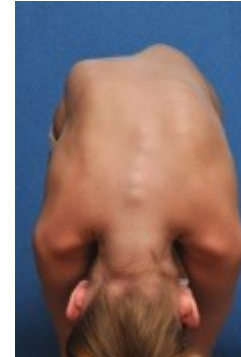
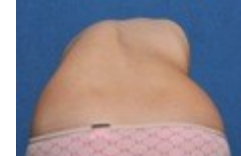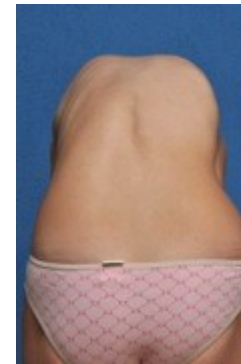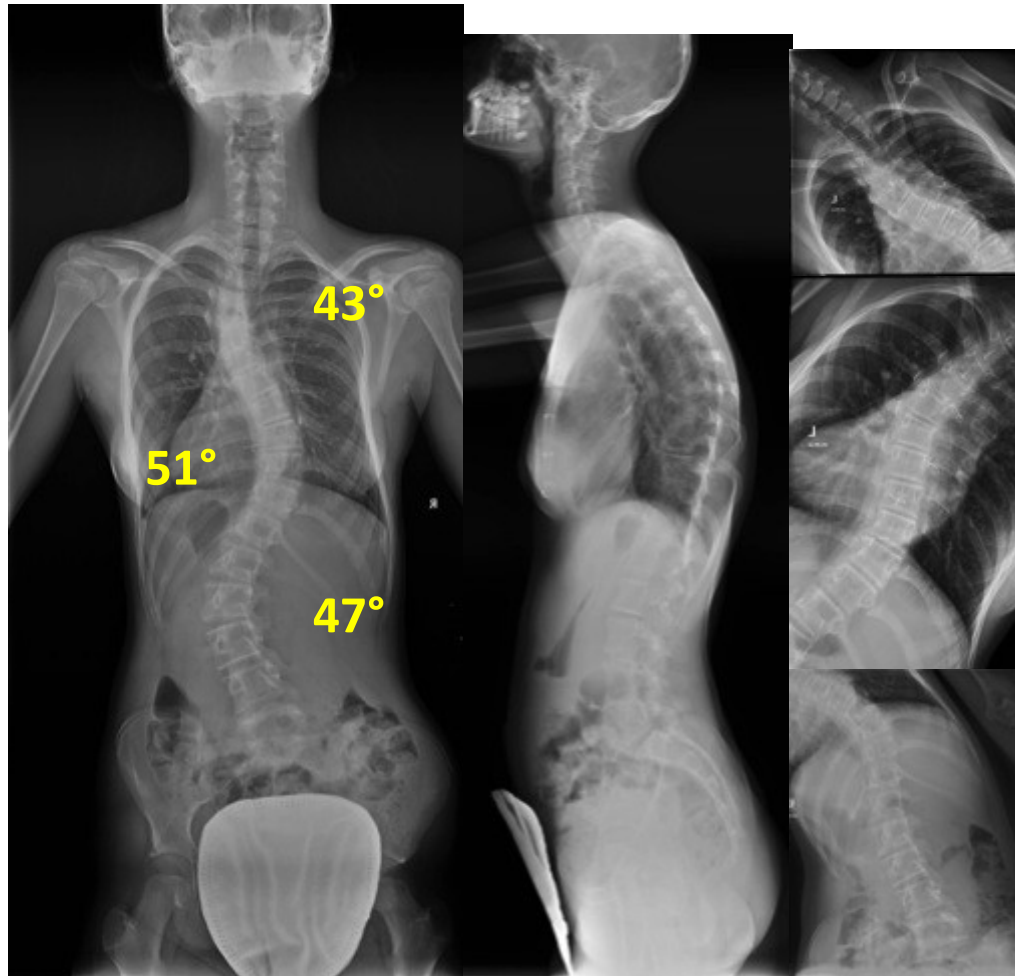type	Proximal thoracic	Main thoracic	Thoracolumbar/lumbar	Description
3	Non-Structural	Structural (Major)	Structural	DM (Double Major)



Lenke 4

Girl 12+9

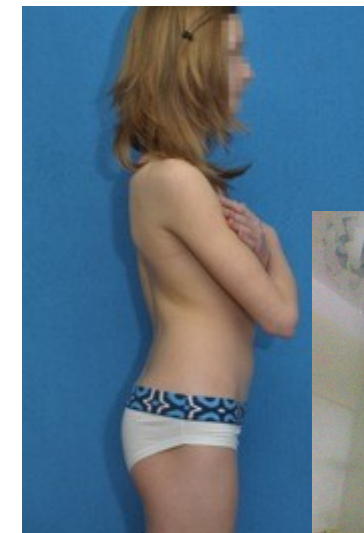

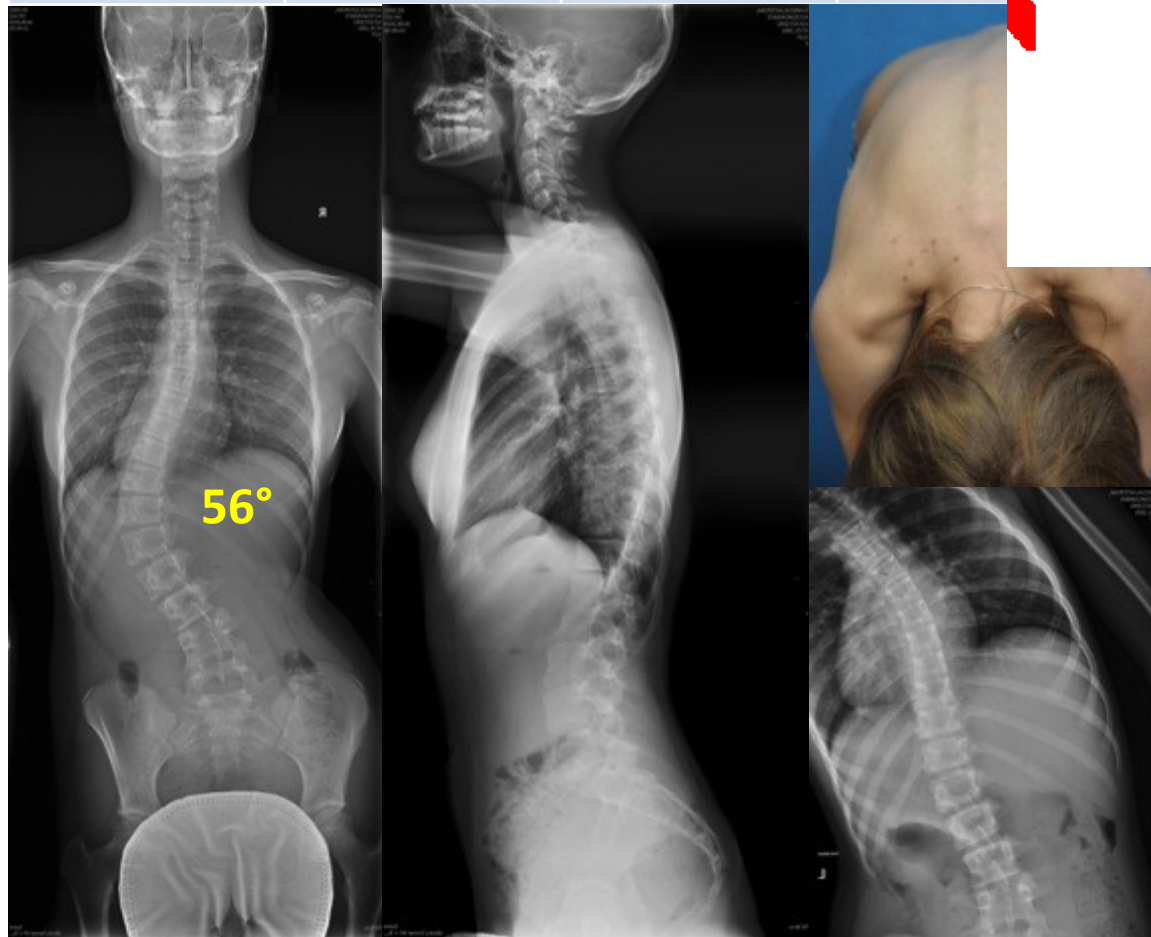
type	Proximal thoracic	Main thoracic	Thoracolumbar/lumbar	Description
4	Structural	Structural (Major)	Structural (Major)	TM (Triple Major)



Lenke 5

Girl 12+5

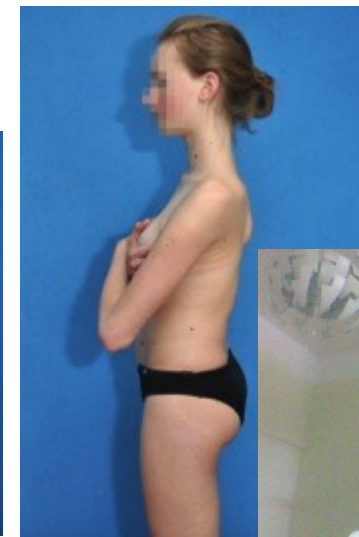
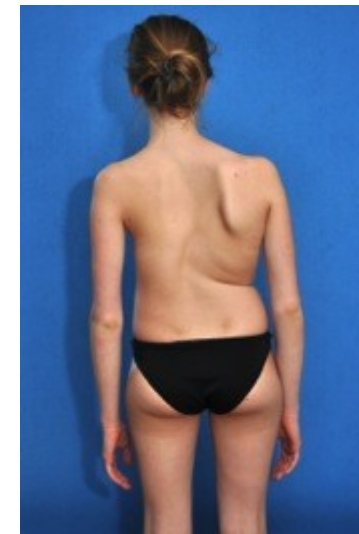
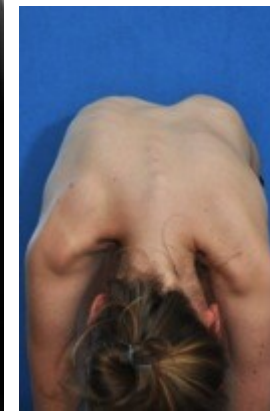
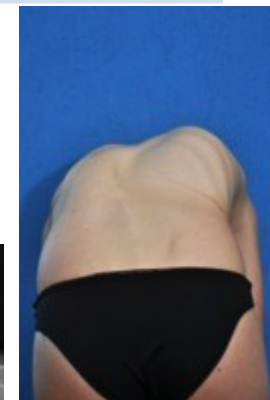
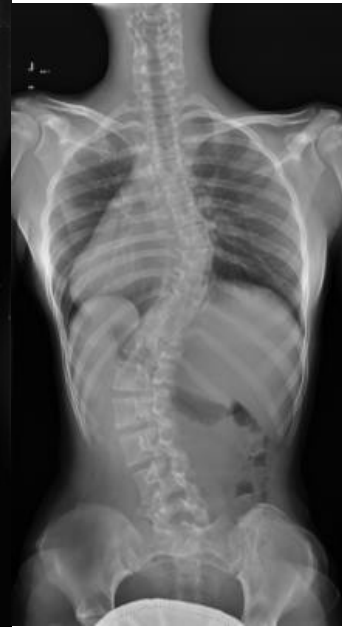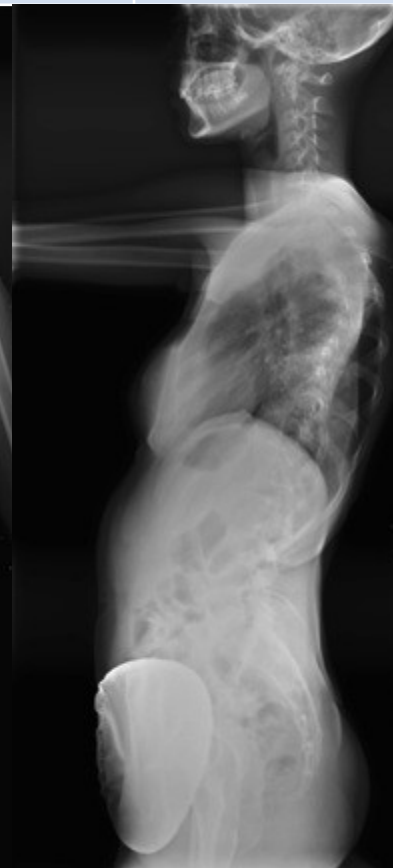
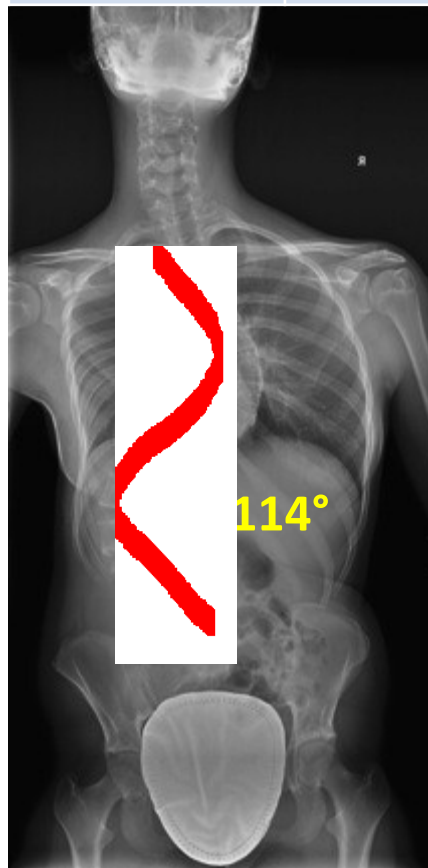
type	Proximal thoracic	Main thoracic	Thoracolumbar/lumbar	Description
4	Non-Structural	Non-Structural	Structural (Major)	TL/T (Thoracolumbar/Lumbar)

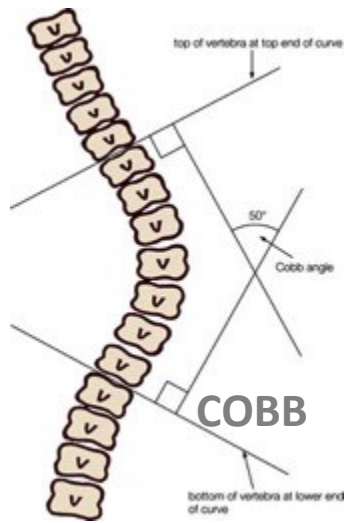


Lenke 6

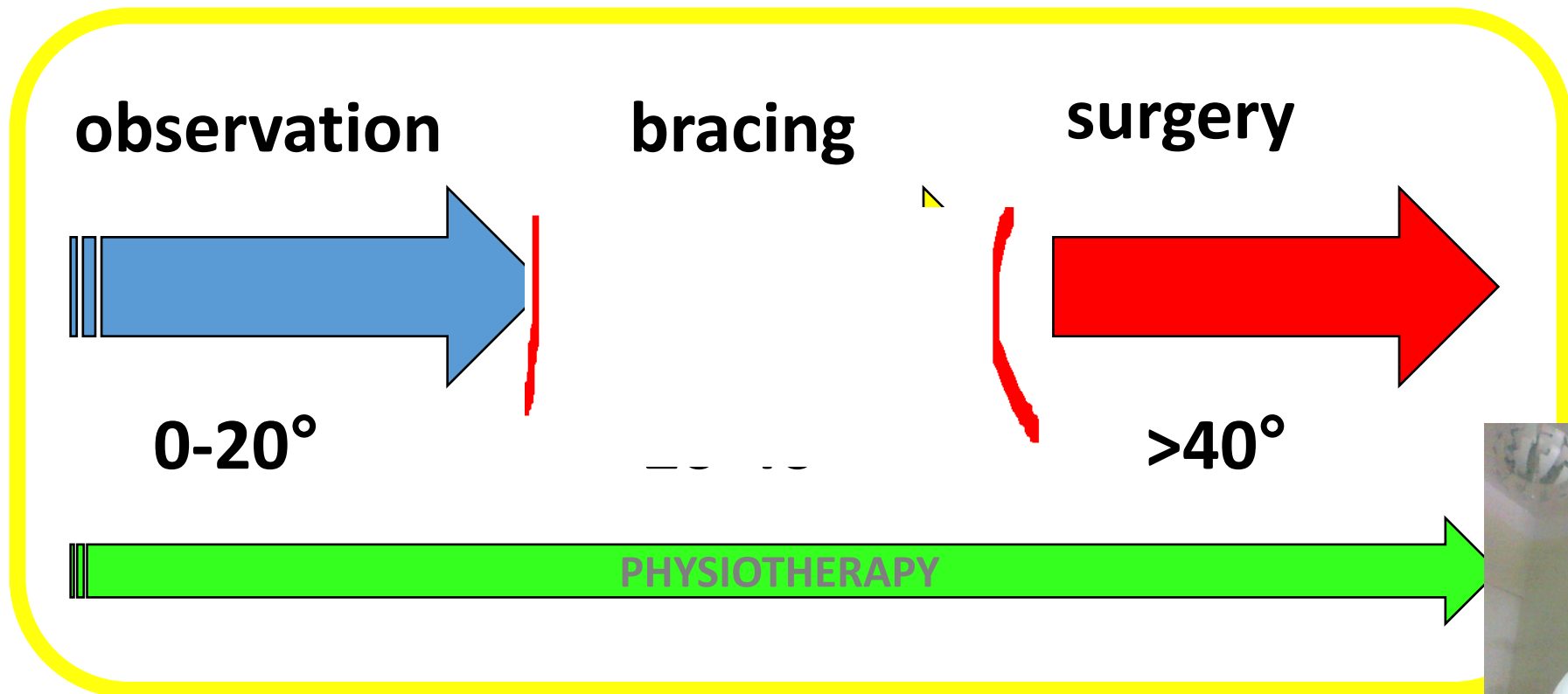
Girl 16+9

type	Proximal thoracic	Main thoracic	Thoracolumbar/lumbar	Description
4	Non-Structural	Structural	Structural (Major)	TL/T-MT (Thoracolumbar/Lumbar-Main Thoracic)





Therapeutic chart




Non-operative treatment

physiotherapy

casting

bracing

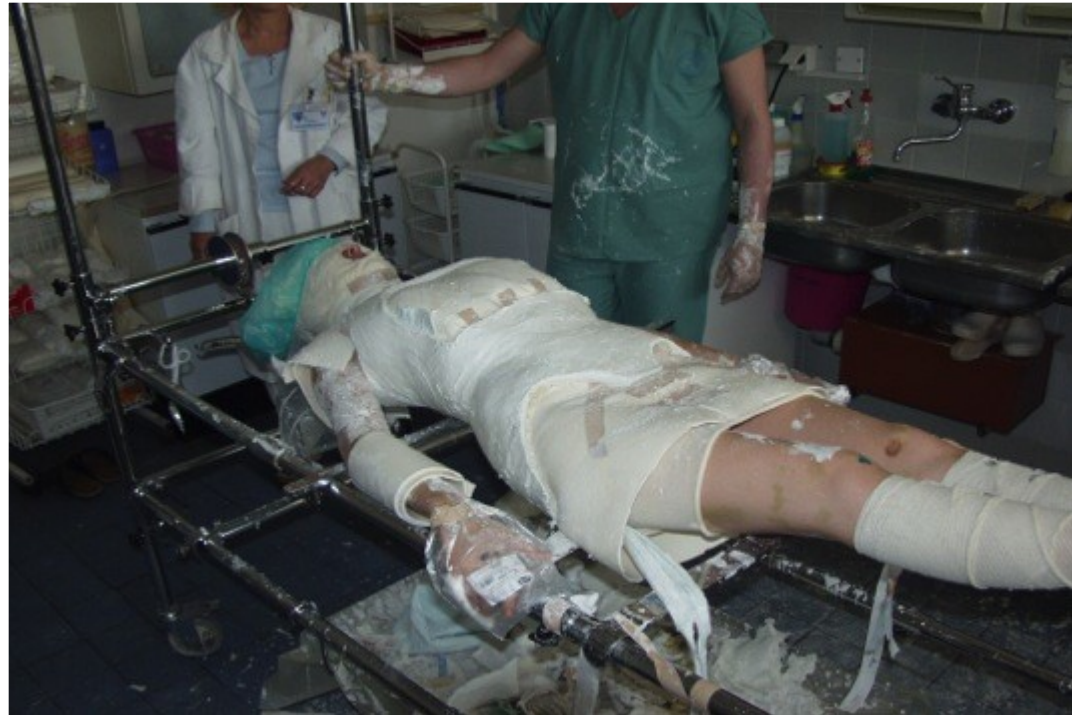


CASTING

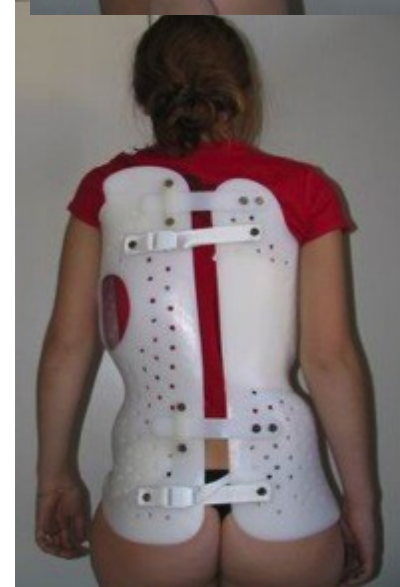
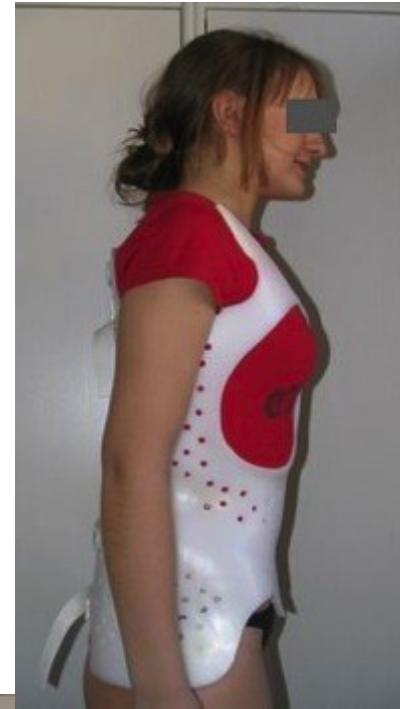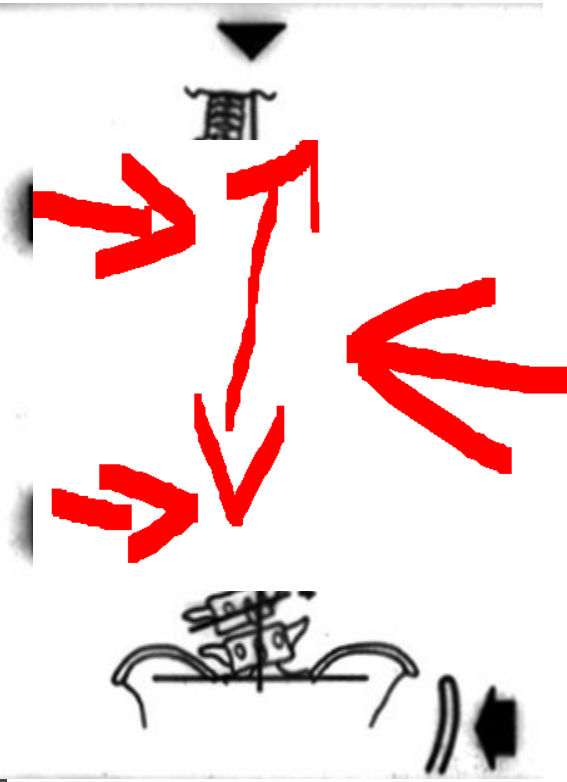
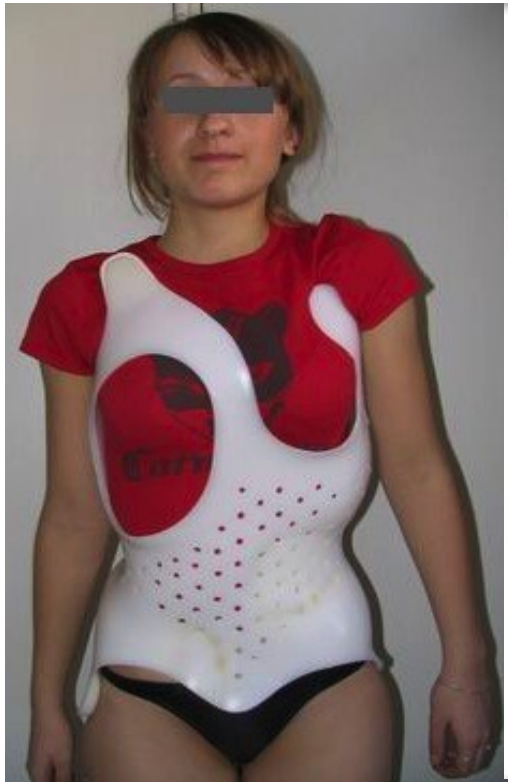Indication: INFANTILE scoliosis

Applying under the general anesthesia

Changing each and every 2 month




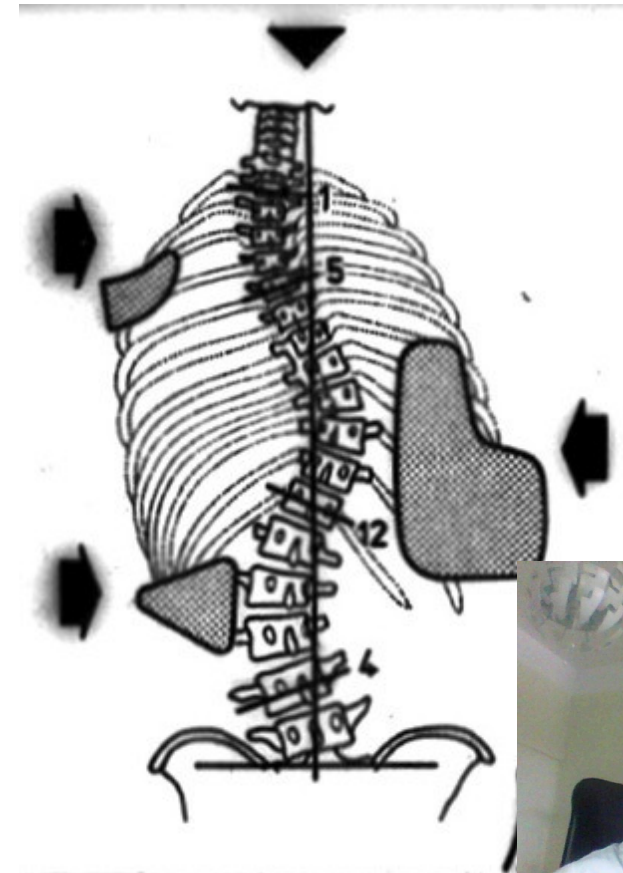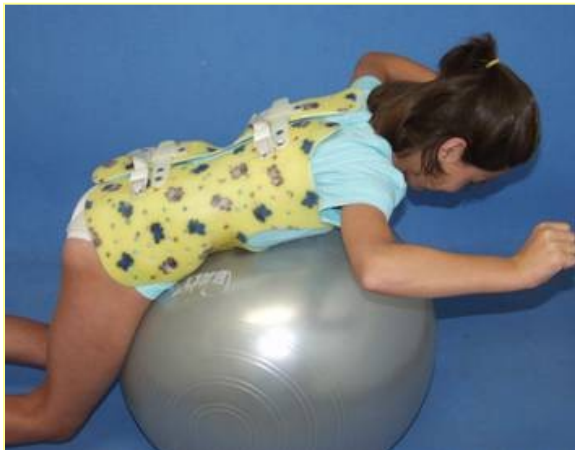
BRACING



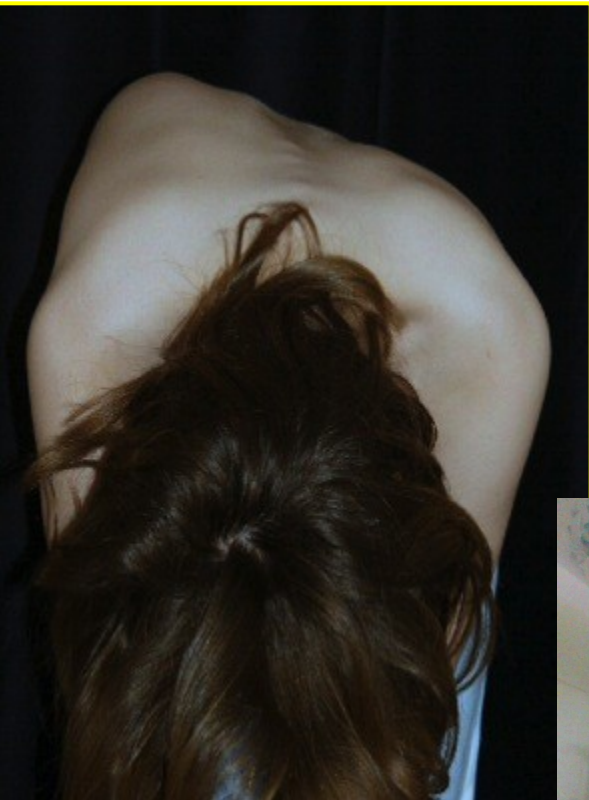
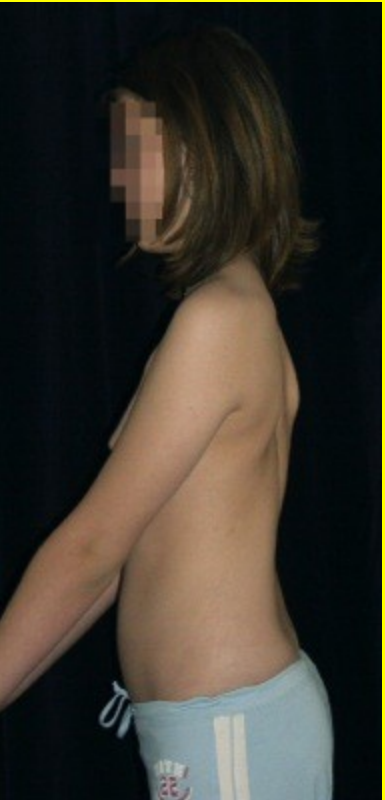
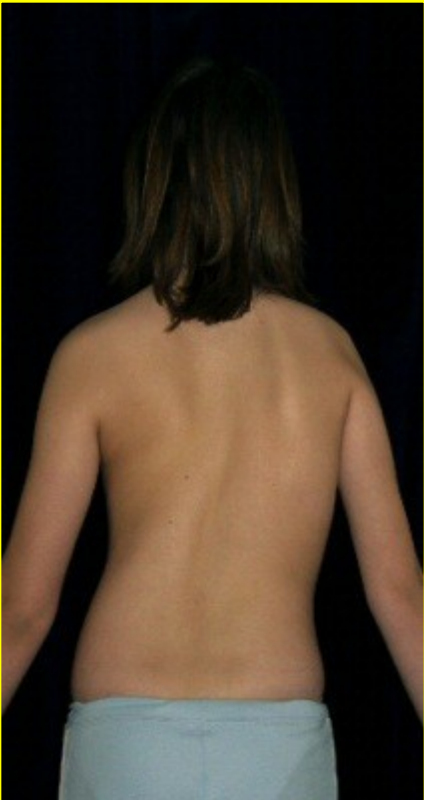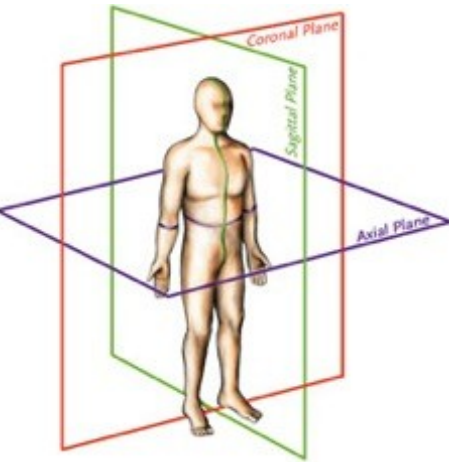
BRACING

Indication for bracing:

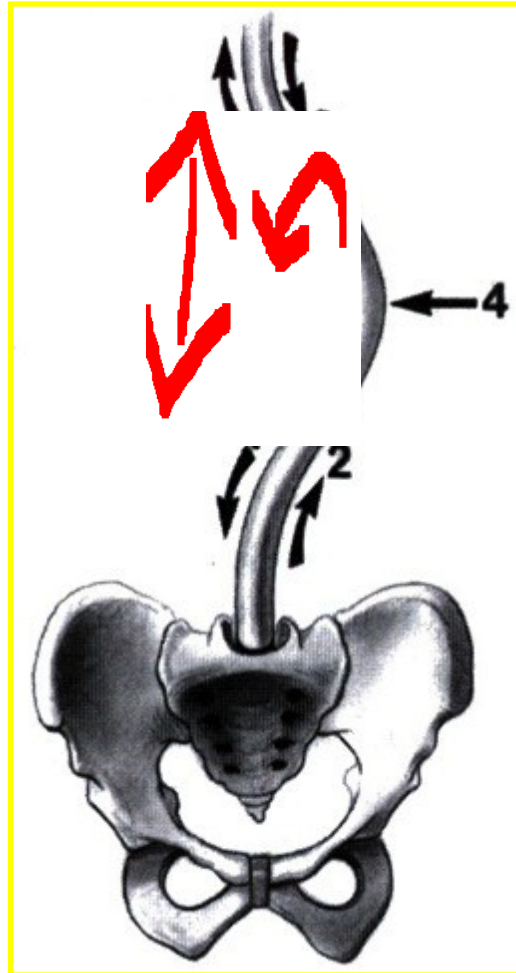
progressive scoliosis
poor or no casting toleration
unable to undergo surgery



3D scoliotic correction



Corrective methods





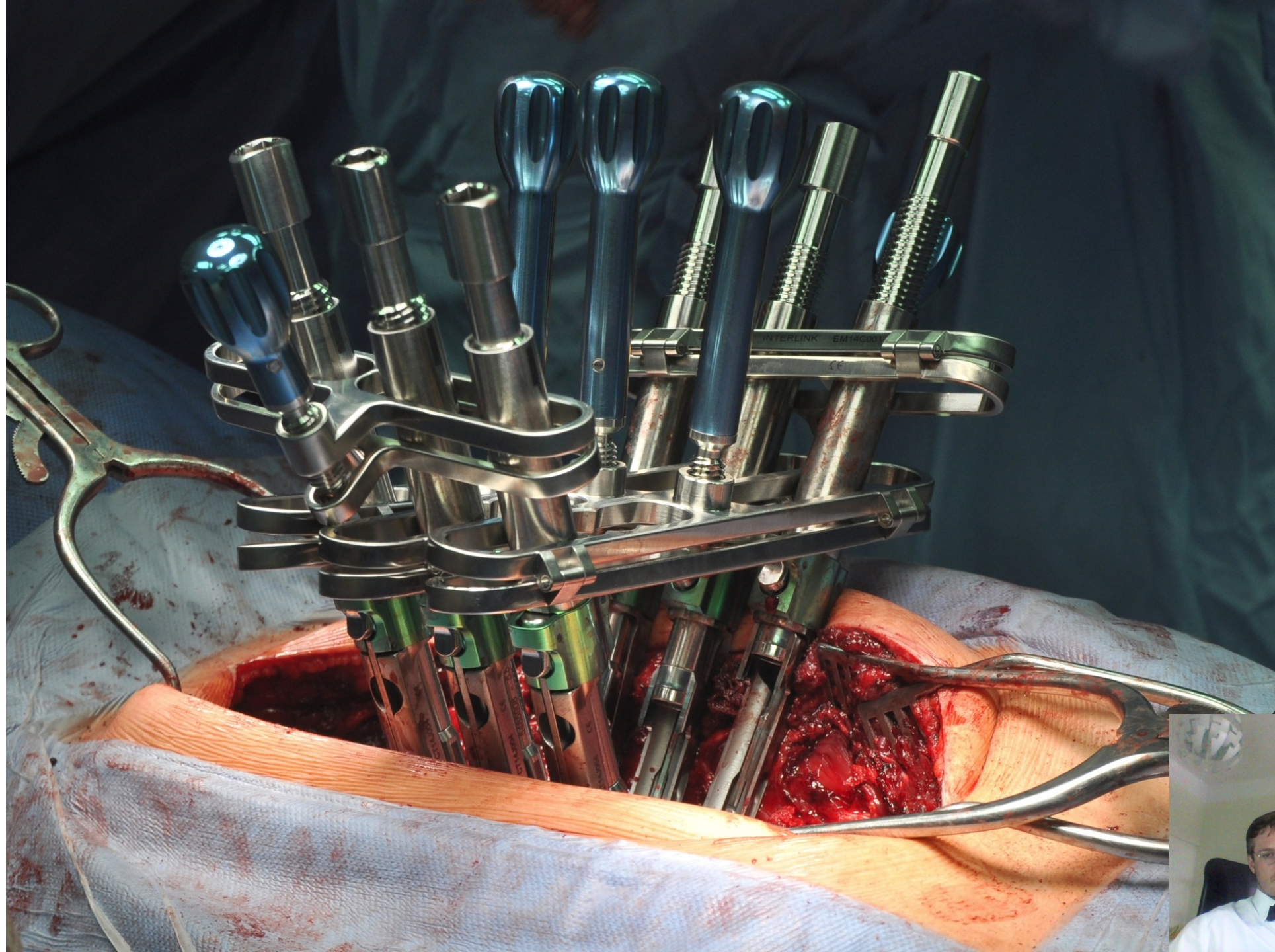
1-distracton

2-compression

3,4-translation

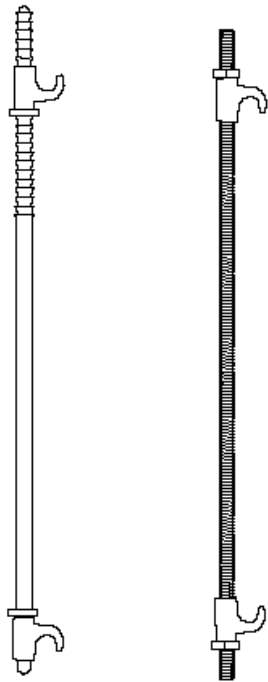
5-derotation



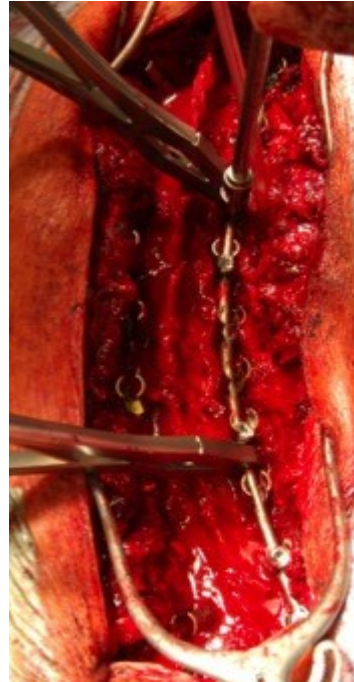


EVOLUTION in corrective maneuvers

DISTRACTION → TRANSLATION → ~~YOU~~ → ~~Red Reduction~~




1D
frontal




1D
frontal



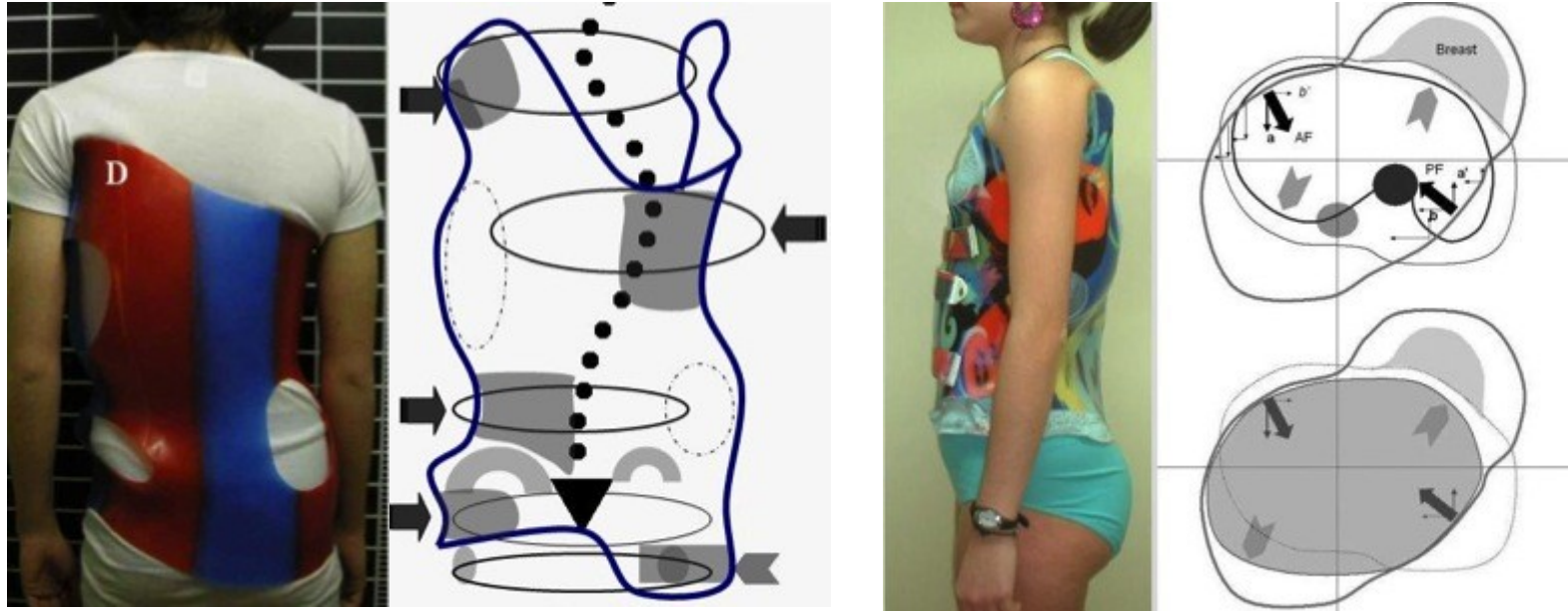
2D
frontal, axial




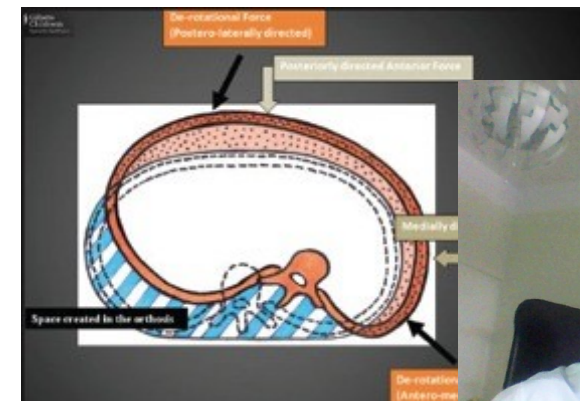
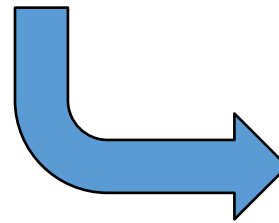
3D
frontal, axial, sagittal



BRACING



Source: Rigo et al, Scoliosis 2010




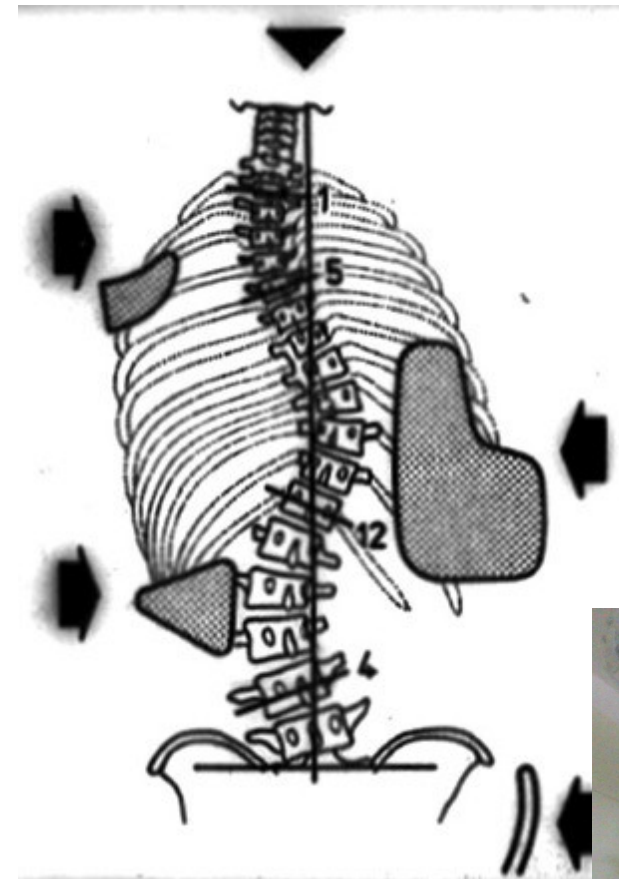
BRACING

Advantages:




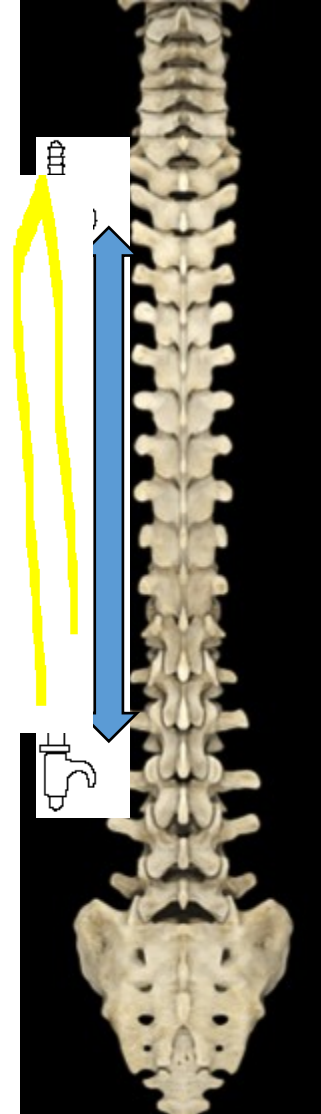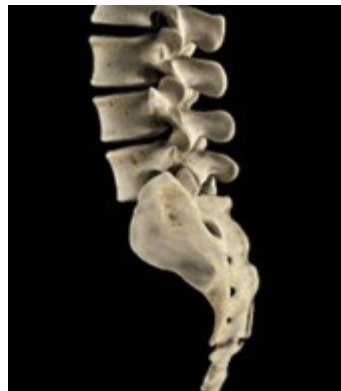
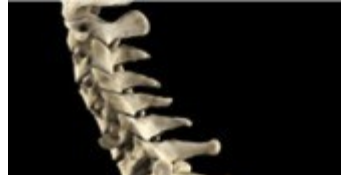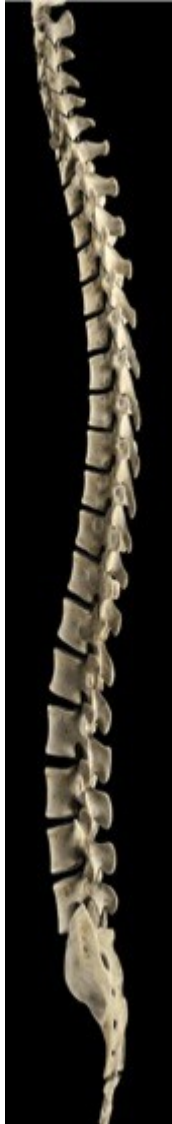Problems:

- HYPOKYPHOSIS
- POOR DEROTATION



DISTRACTION

EVOLUTION
in corrective maneuvers



DISTRACTION

Advantages:


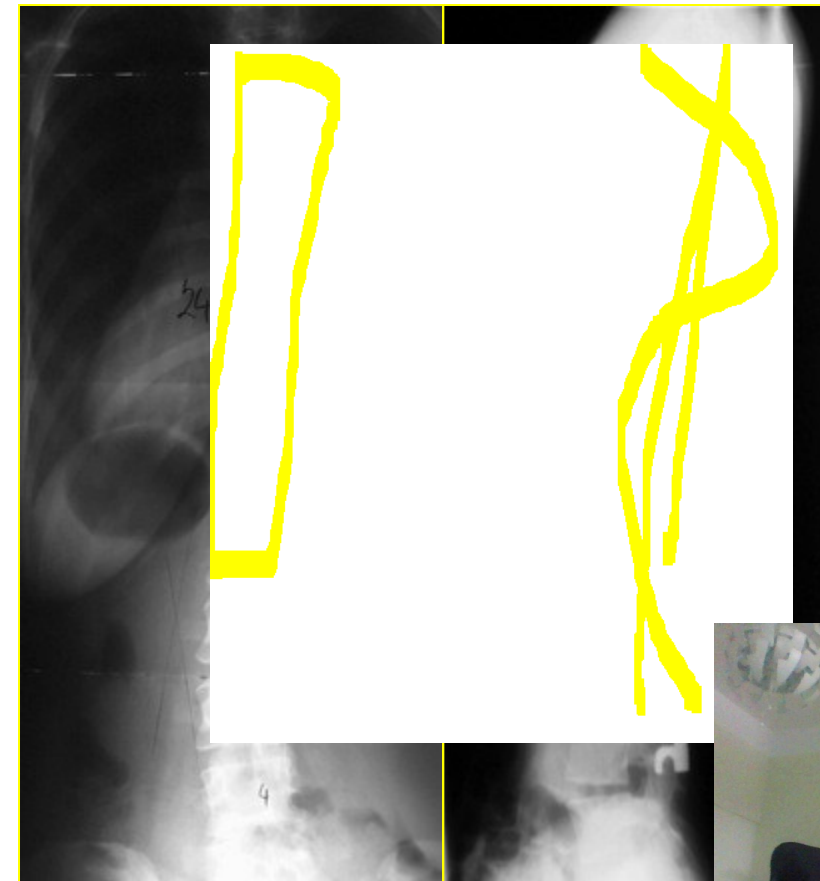
- Simple implantation
- Possibility of spine growth
- Miniinvasive approach

Disadvantages:

- Uniplanar correction (frontal)
- High rate of complications

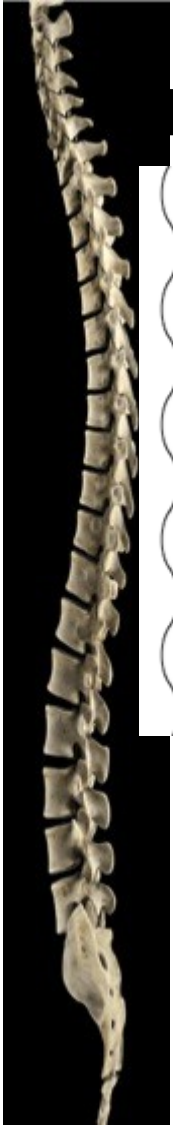Problems:

- **HYPOKYPHOSIS**
- **NO DEROTATION**

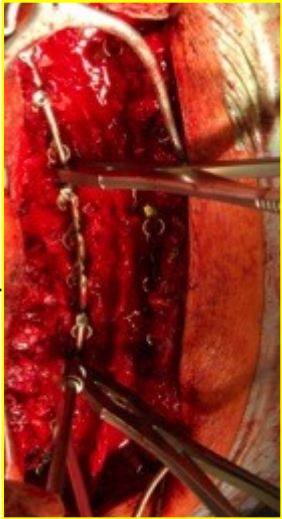

TRANSLATION

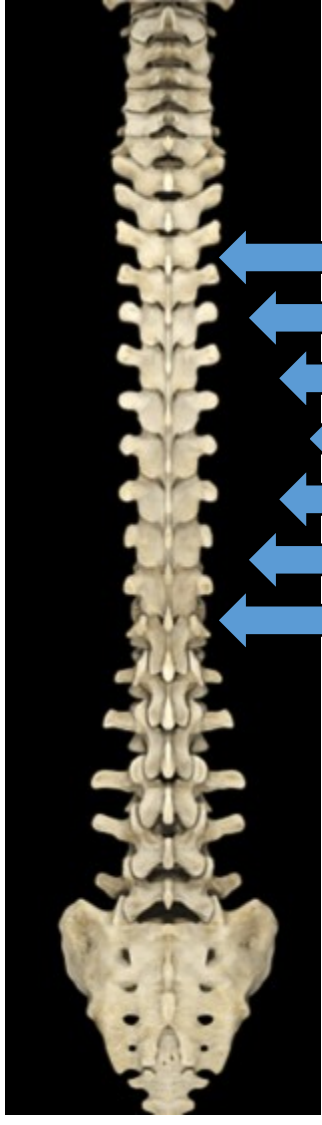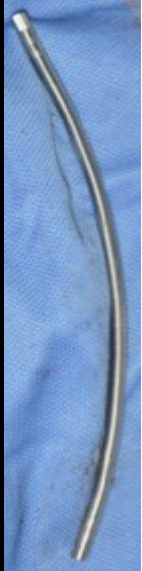
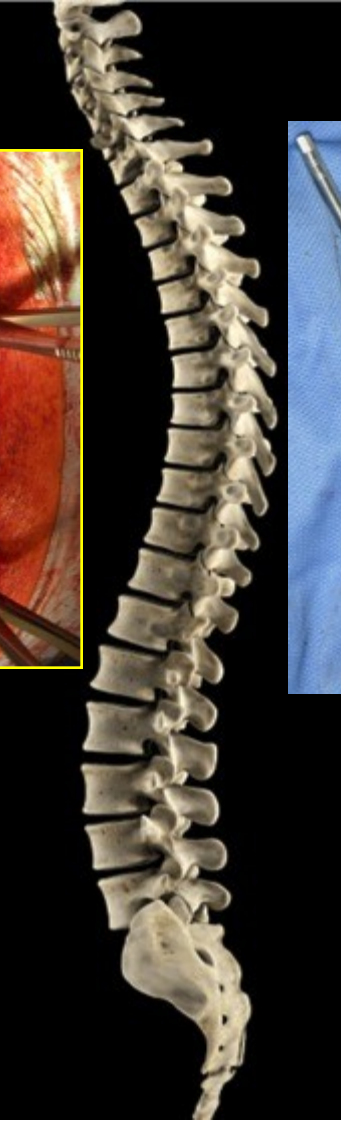EVOLUTION
in corrective maneuvers



kyphosis



rod
derotatic



TRANSLATION

Advantages:

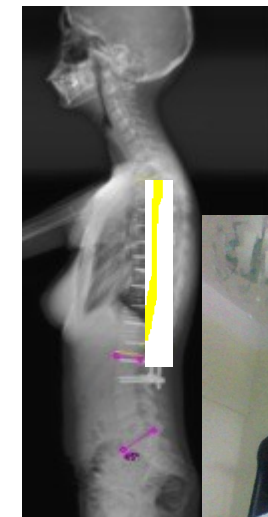
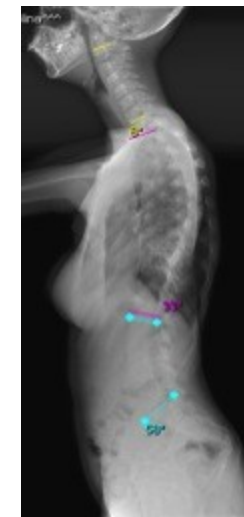
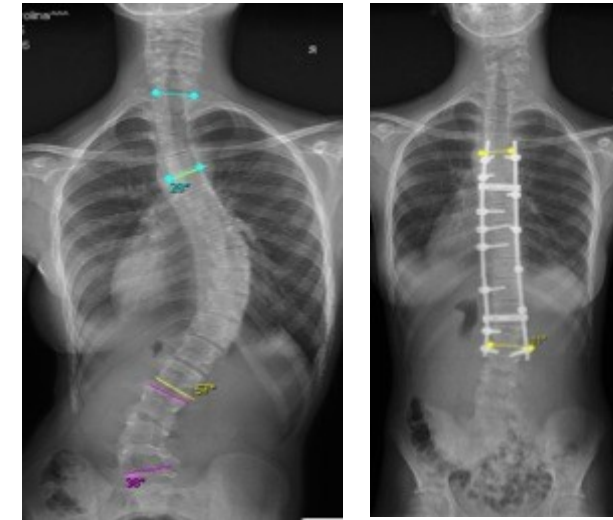
- Good frontal correction

Disadvantages:

- Uniplanar correction (frontal)

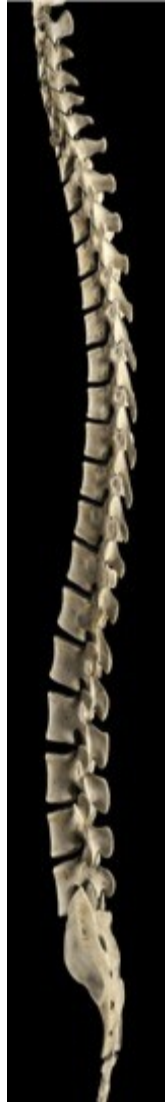Problems:

- **HYPOKYPHOSIS**
- **NO DEROTATION**


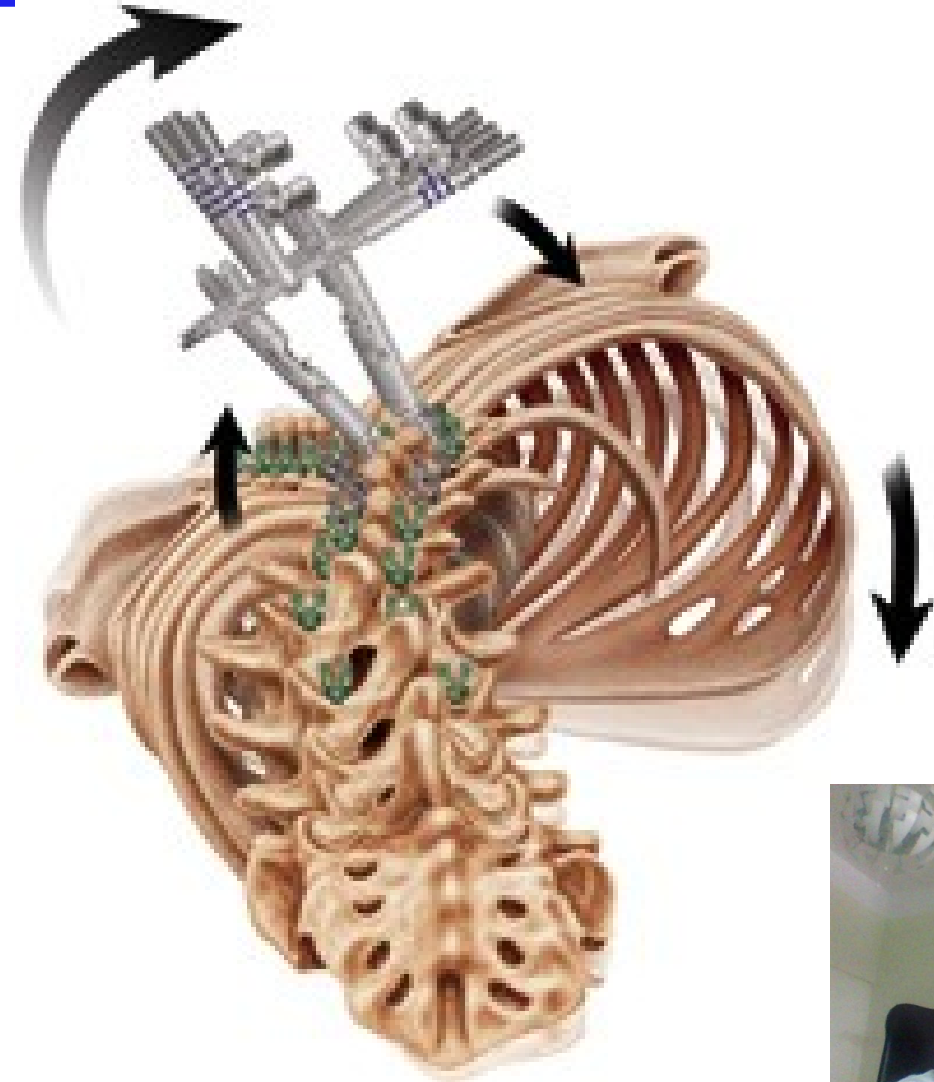
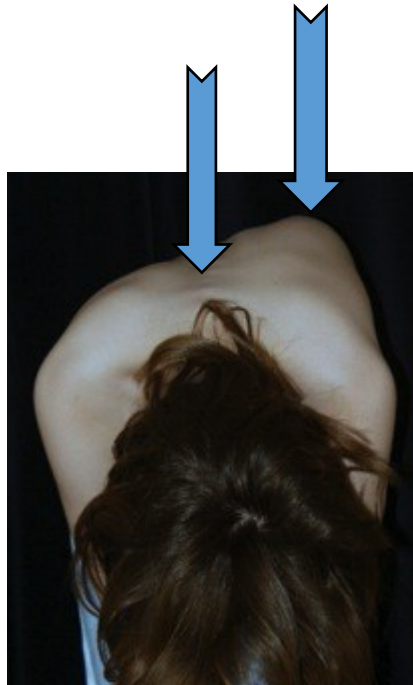


VCM VERTEBRAL COLUMN MANIPULATION

EVOLUTION
in corrective maneuvers



hypokyphosis




Derotation

WHY derotation?

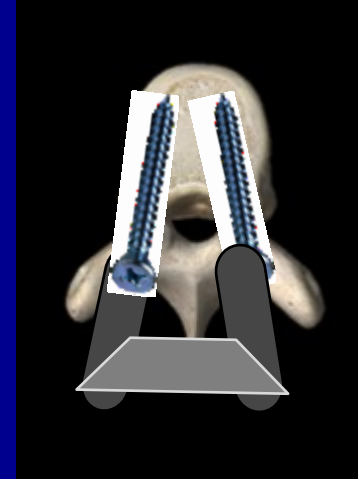
- 3D scoliotic correction
- Correction of Rib Hump prominence
- Secondary curve correction in selective fusion

Balanced spine




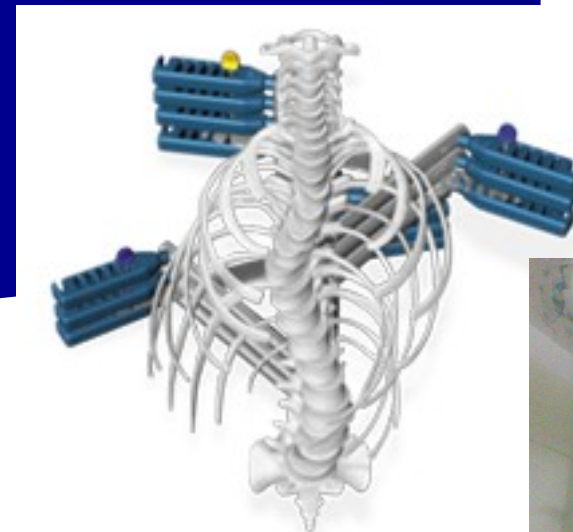
Transpedicular screw constructs

- Allows effective derotation of single vertebra



Derotation instruments

- Allows safe and effective derotation of single vertebra as well as the whole apical area.



VCM

Vertebral column manipulation

Advantages:


- Good frontal and axial correction

Disadvantage:

- little too forced isolated technique


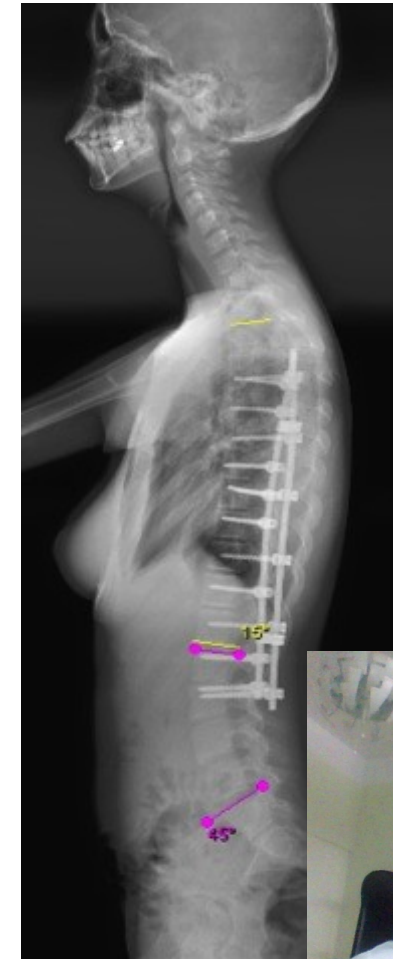
Problem:

- **HYPOKYPHOSIS**




RESULT of most correction maneuvers


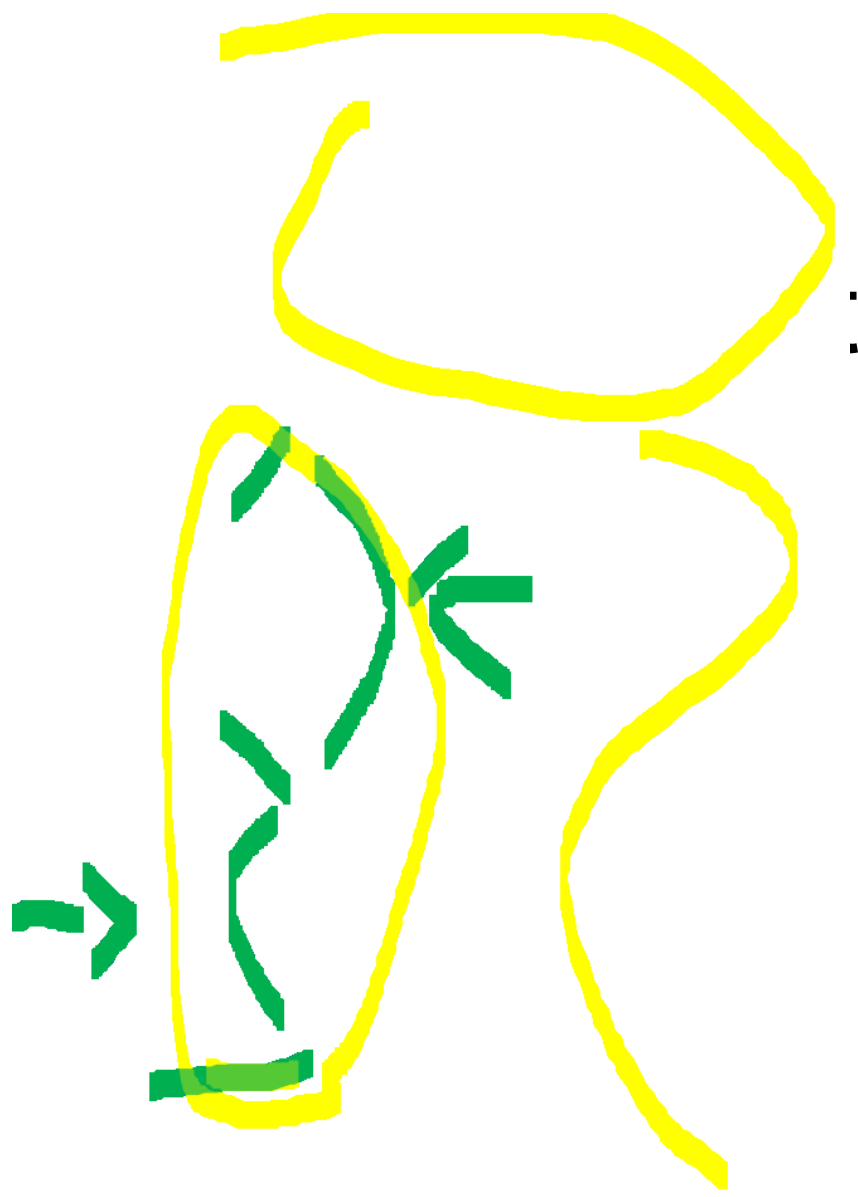
- **HYPOKYPHOSIS**
- **ABSENCE or RESTRICTIVE DEROTATION**

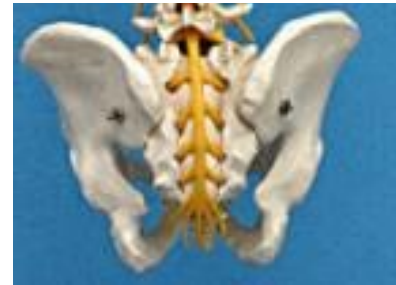
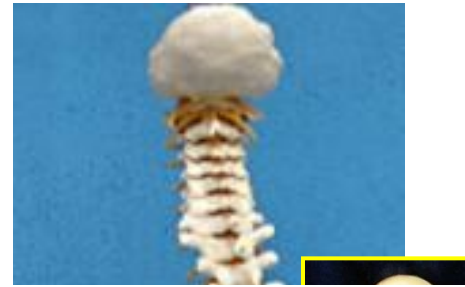
DEROTATION


Transversal plane










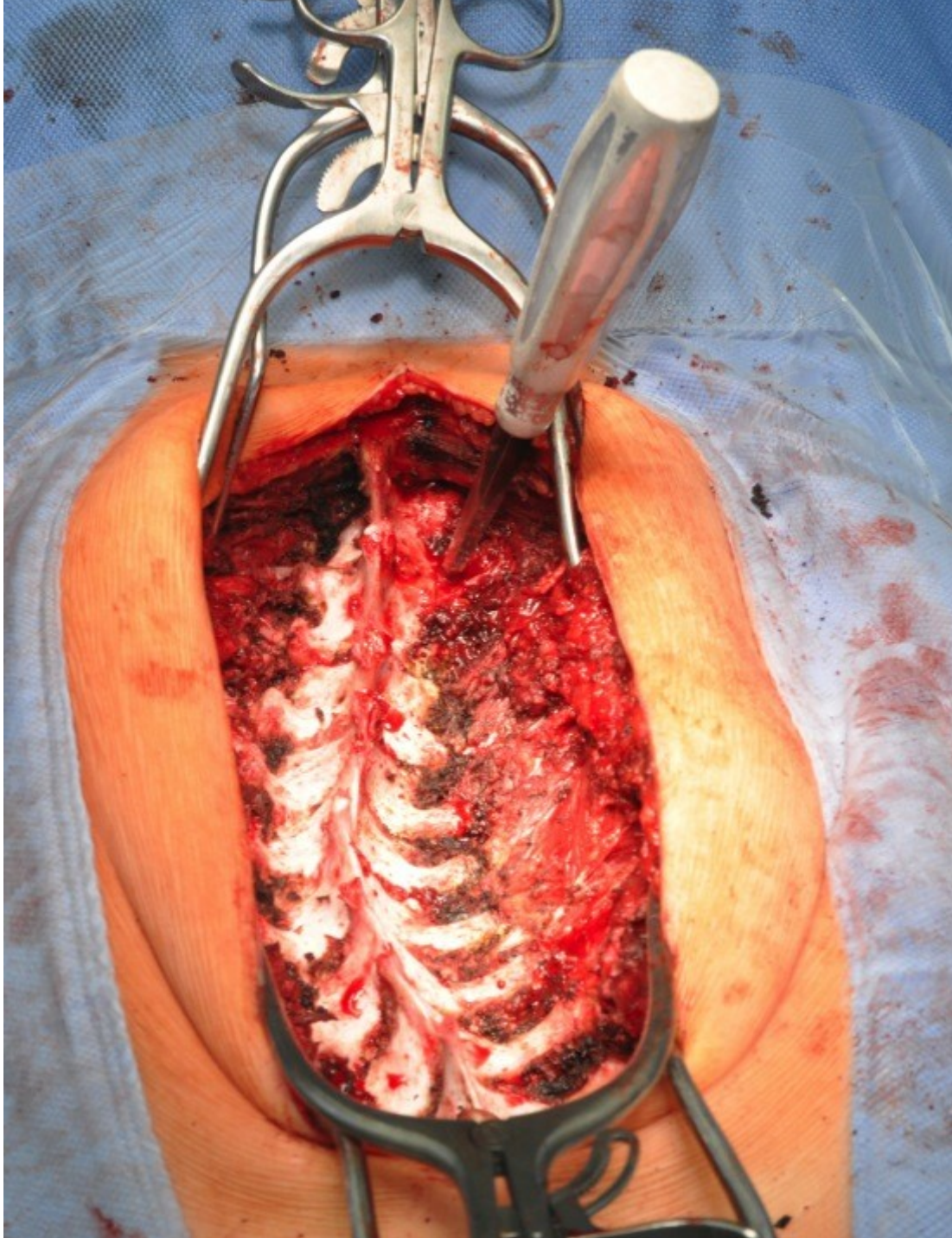
3D geometrical changes




Caudal Δ

Surgical
posterior
approach



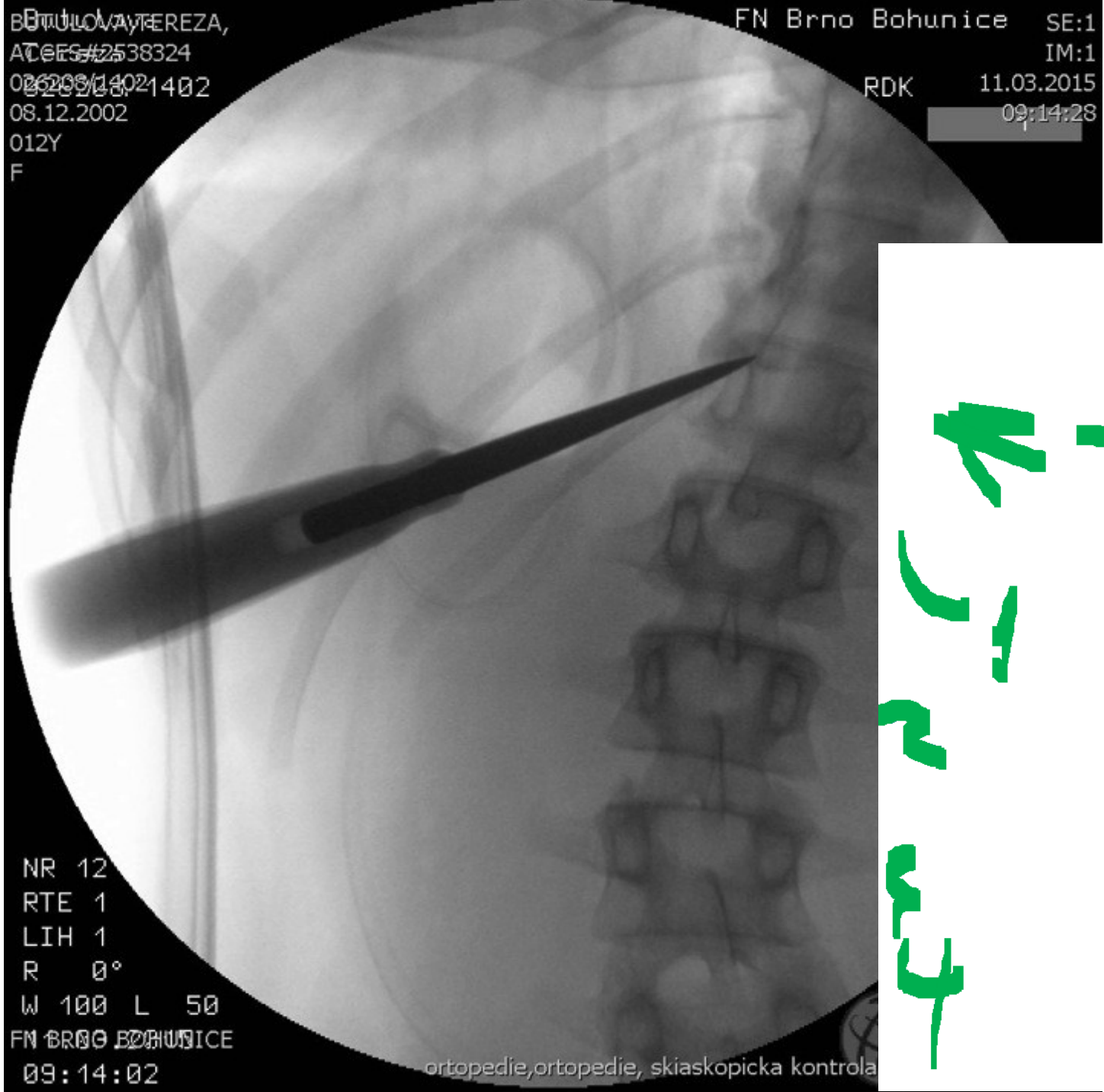


**level
checking**





BUTULOVÁ, TEREZA,
ATCS #2538324
026209/14021402
026209/14021402
08.12.2002
012Y
F

FN Brno Bohunice SE:1
IM:1
RDK 11.03.2015
09:14:28


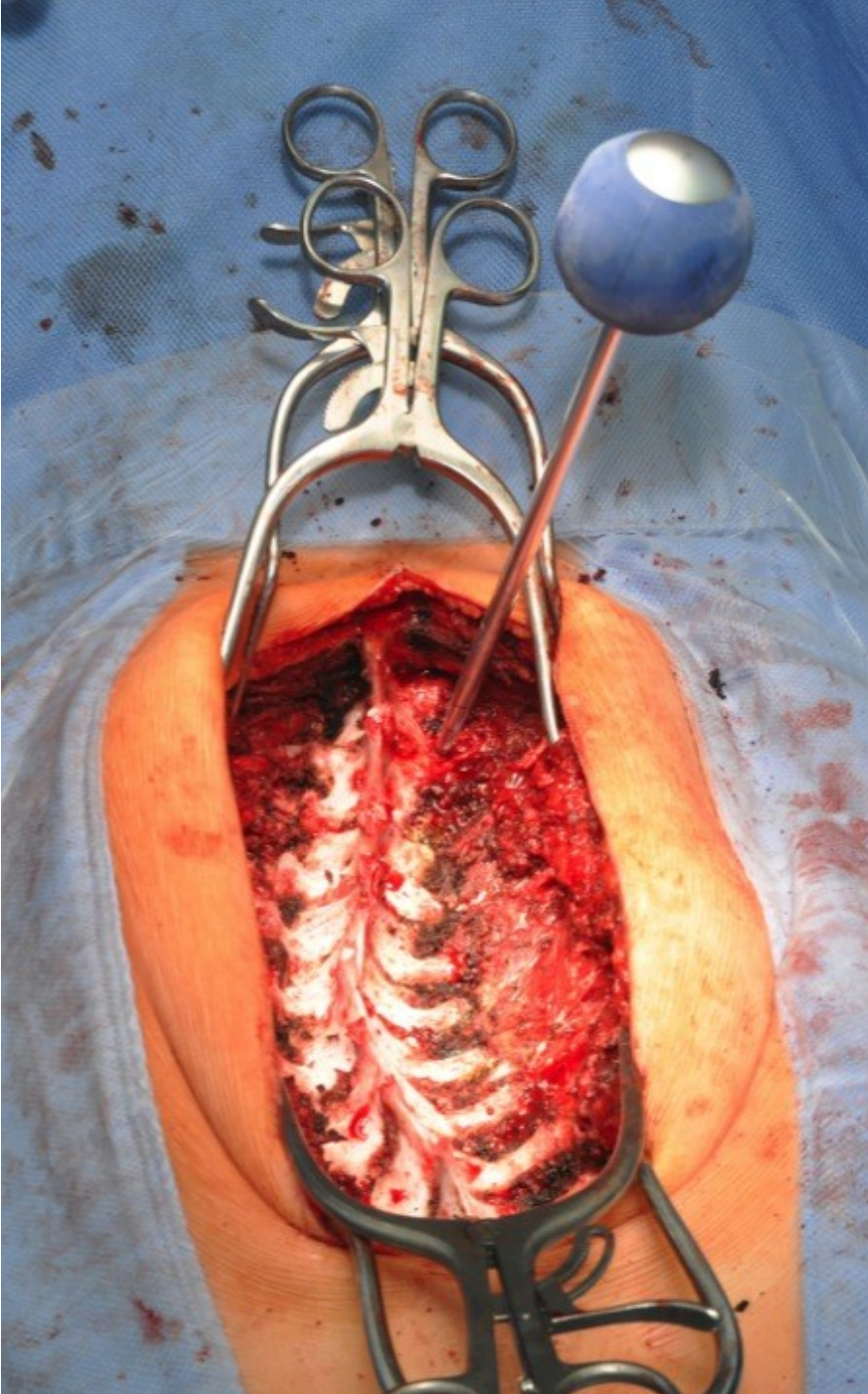


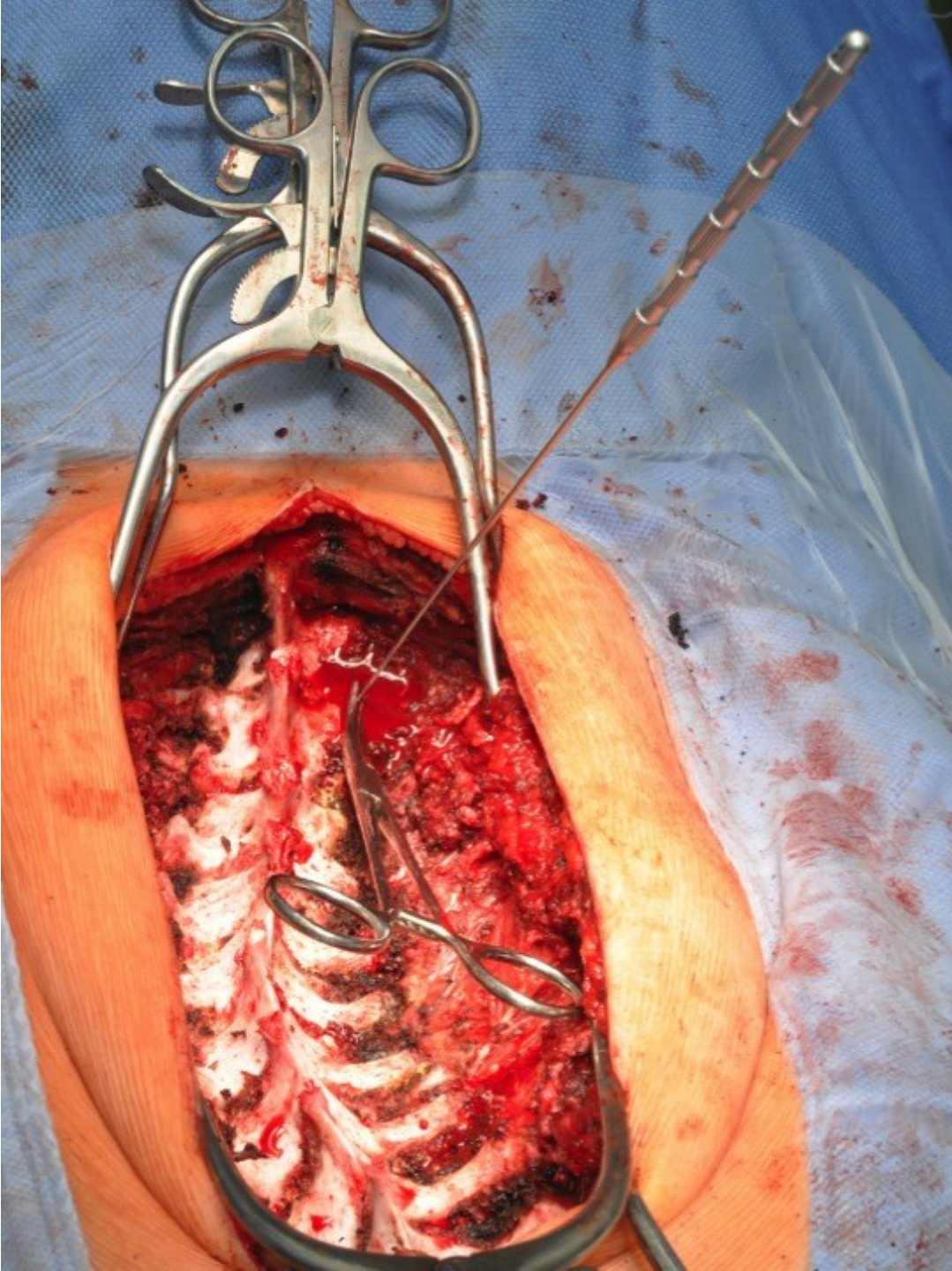
NR 12
RTE 1
LIH 1
R 0°
W 100 L 50
FN BRNO BOHUNICE
09:14:02

ortopedie, ortopedie, skiaskopicka kontrola




Probe - pedikle finding


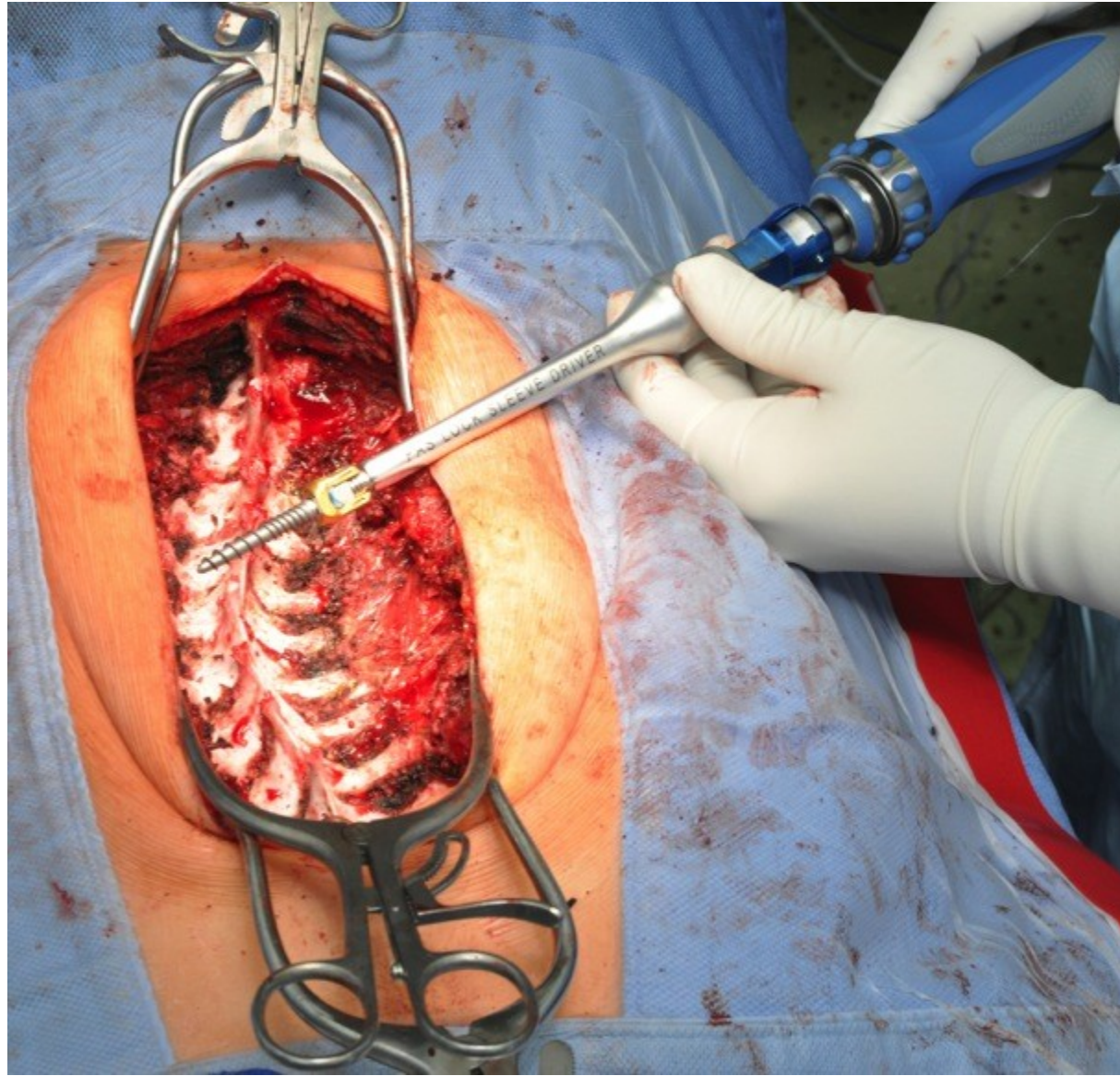





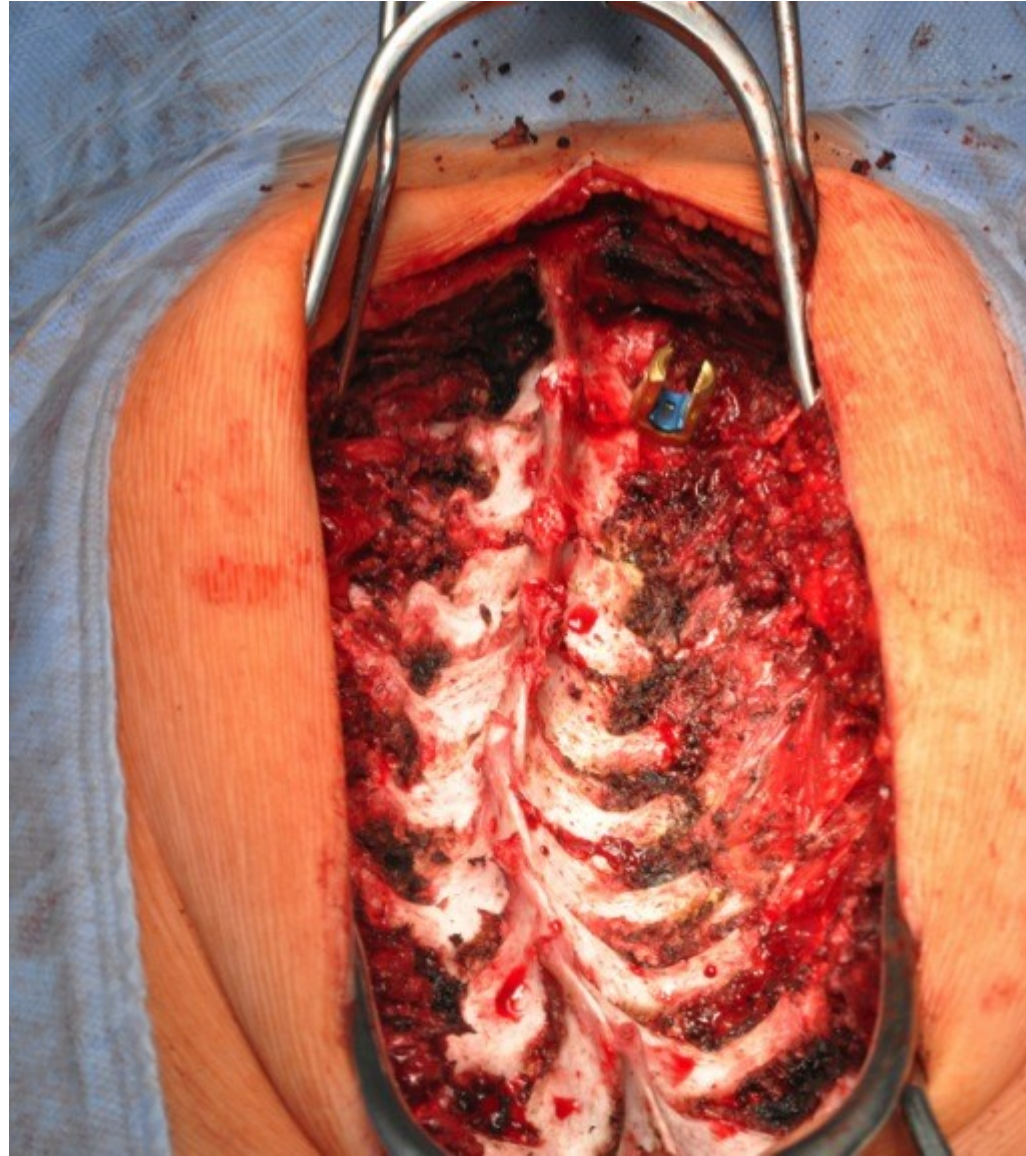
Sound
-
pedicle hole checking
-
screw length measuring




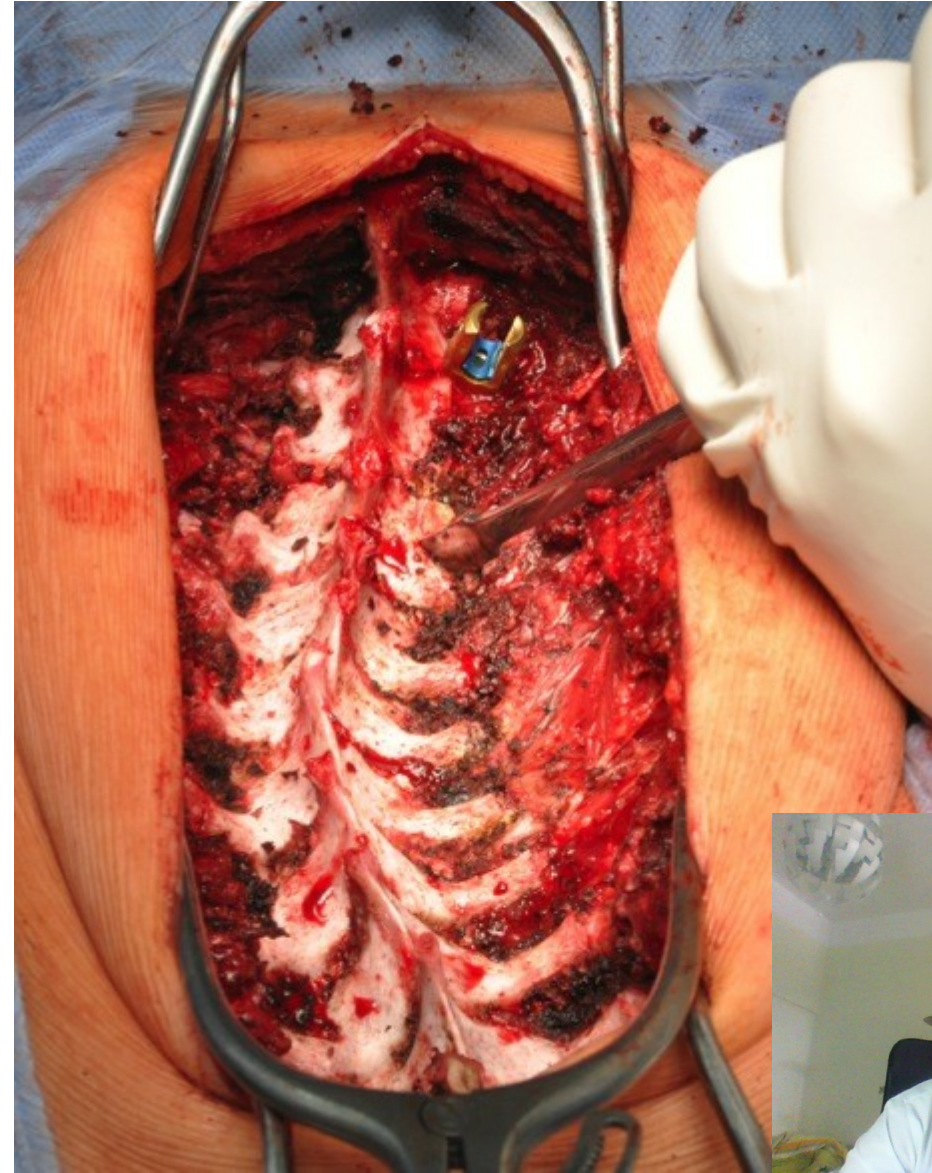
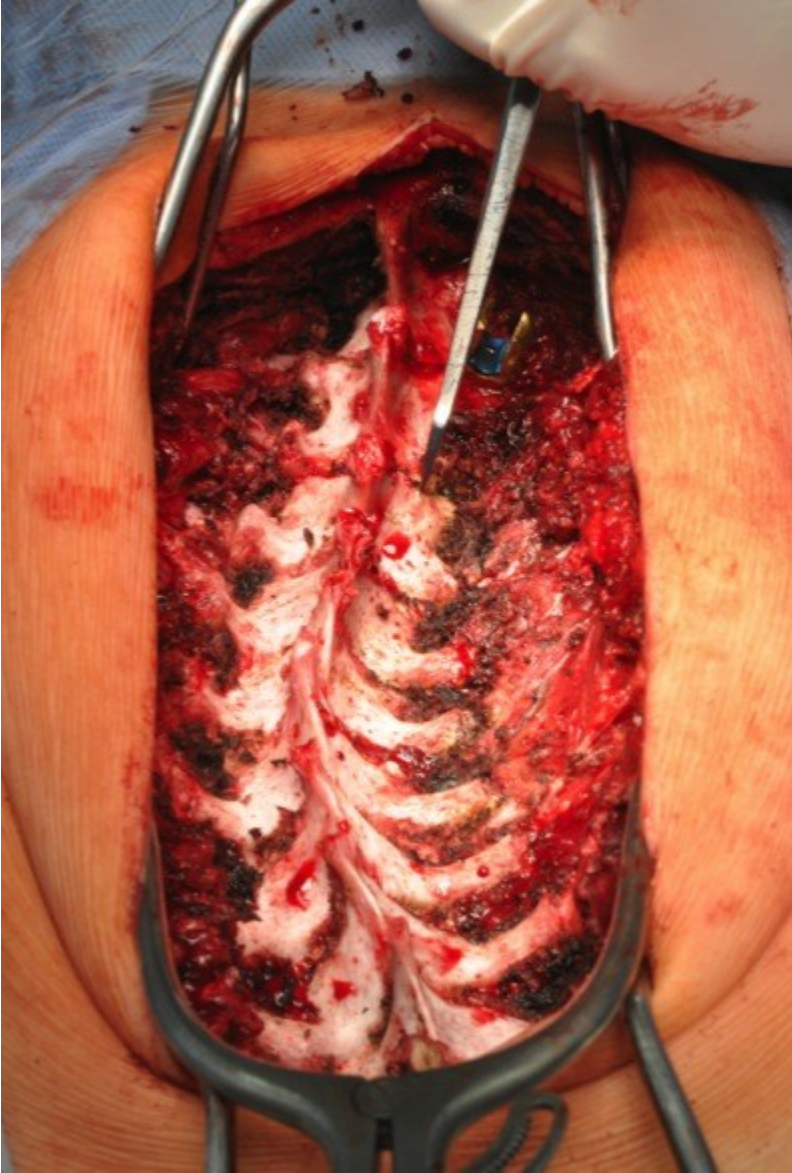
Screwdriver - screw insertion




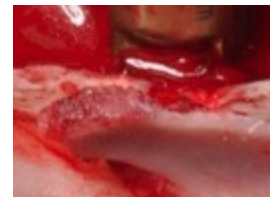

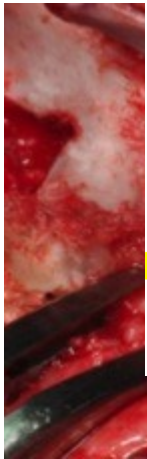
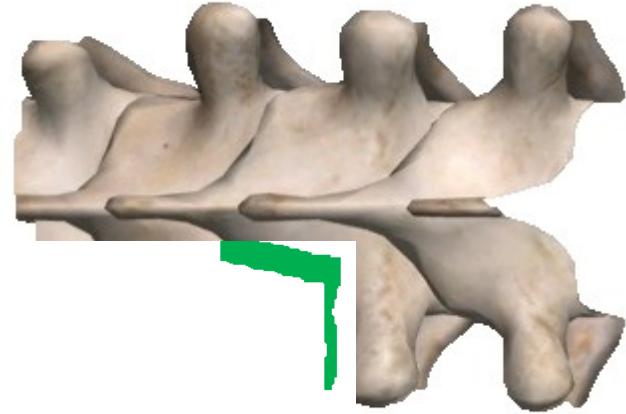
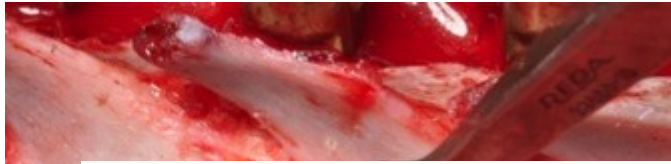
Screwdriver - screw insertion



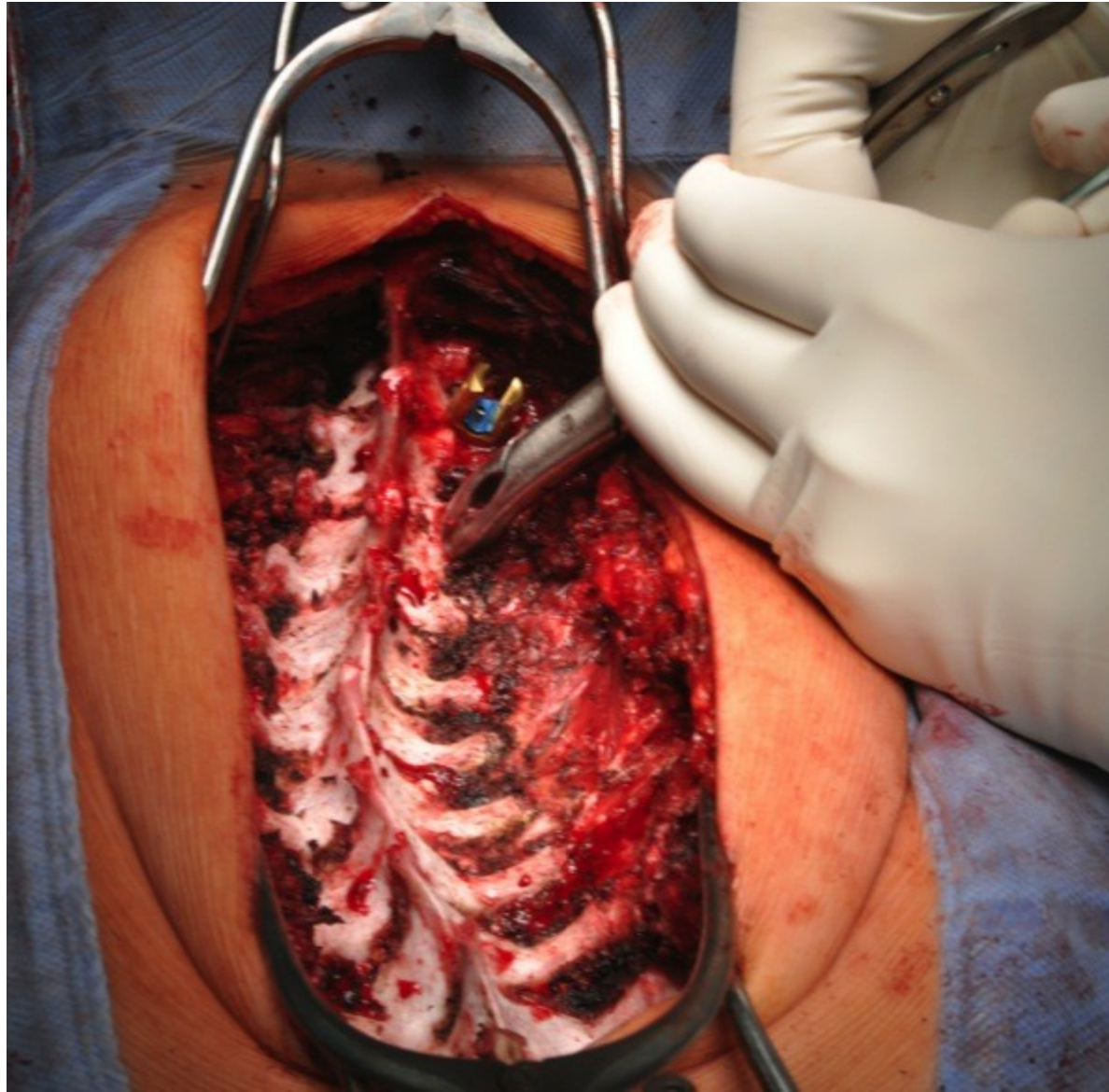Chisel – facet resection


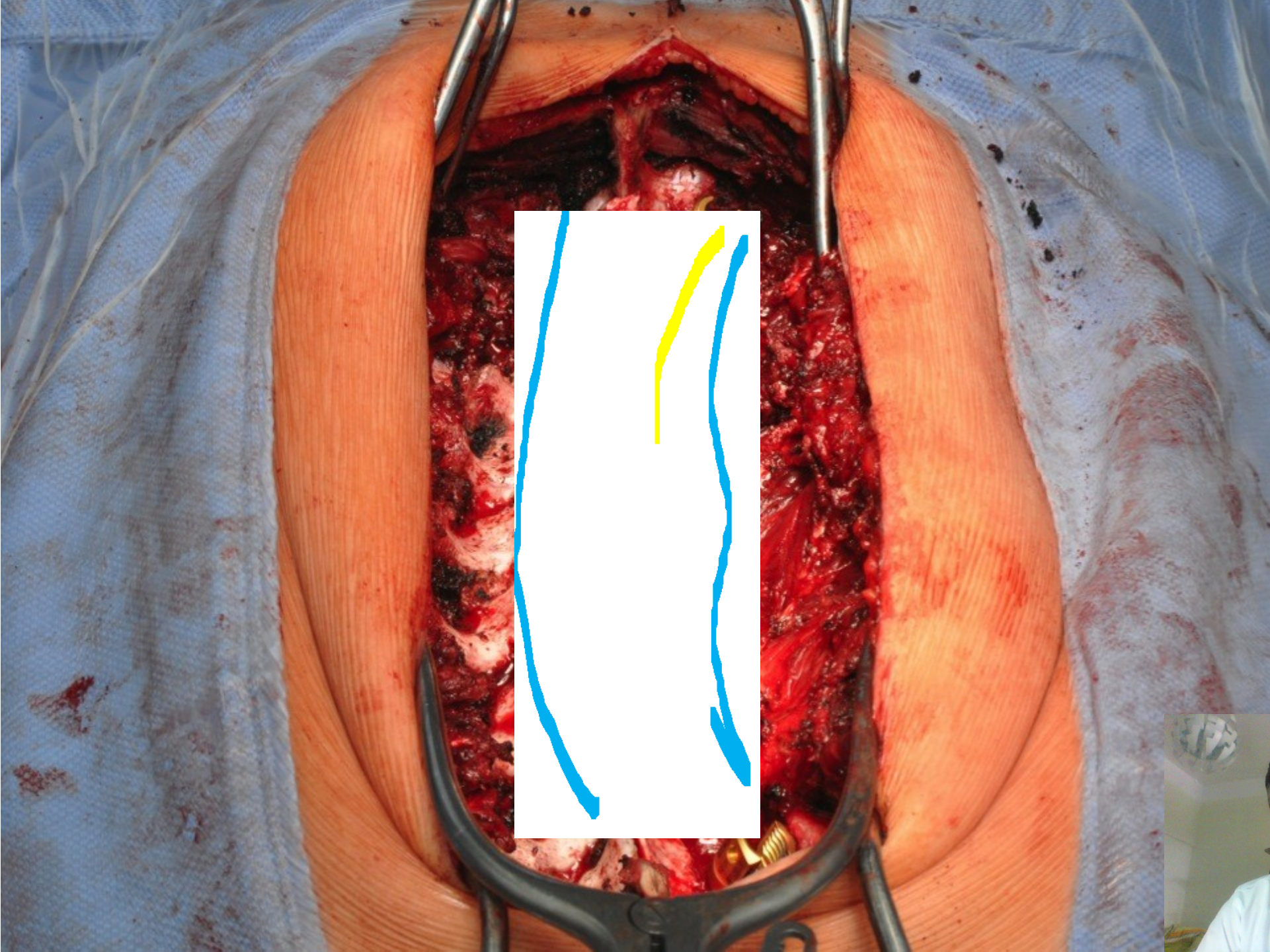



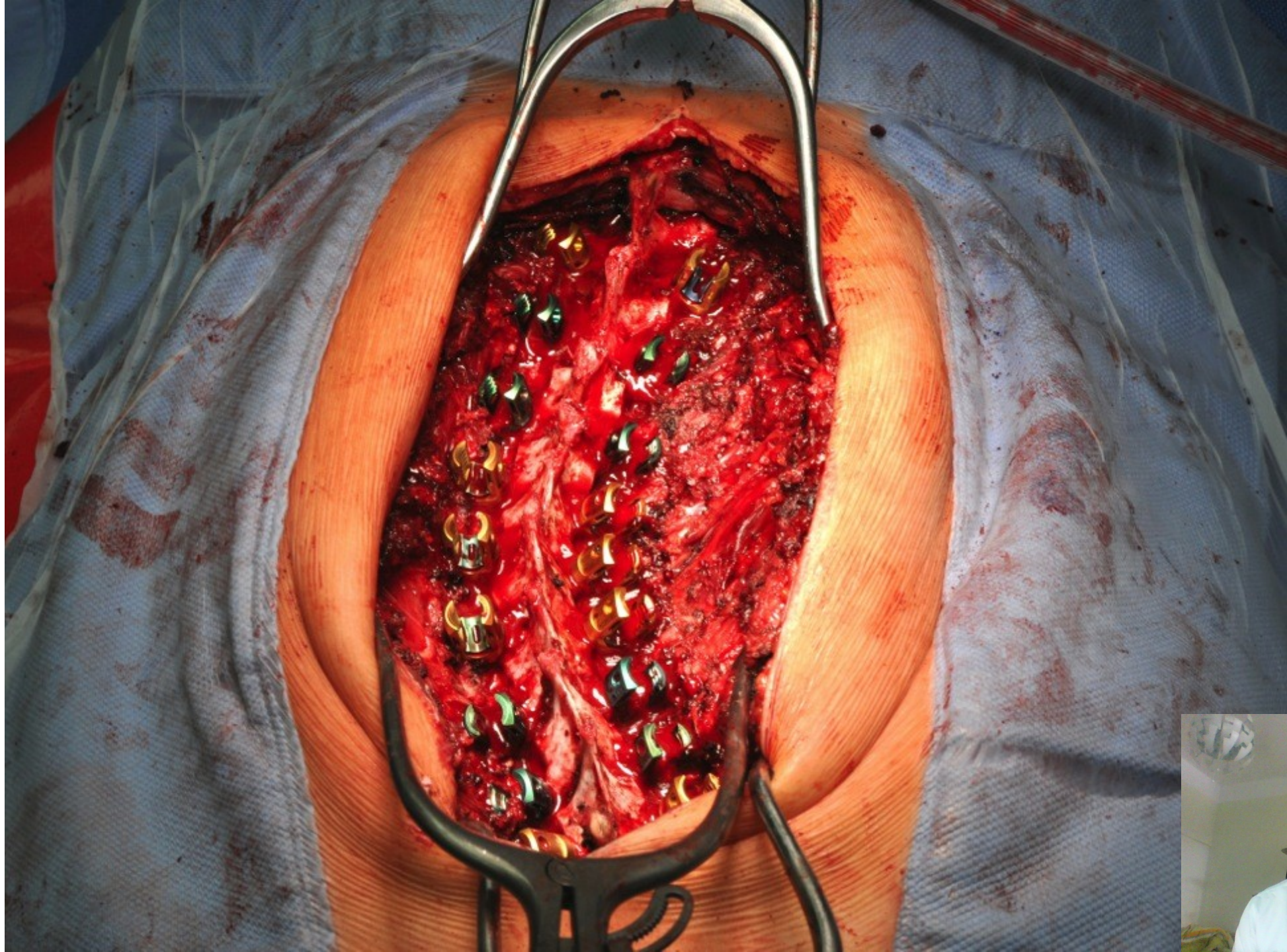
Chisel – facet resection



Luer – cortex resection

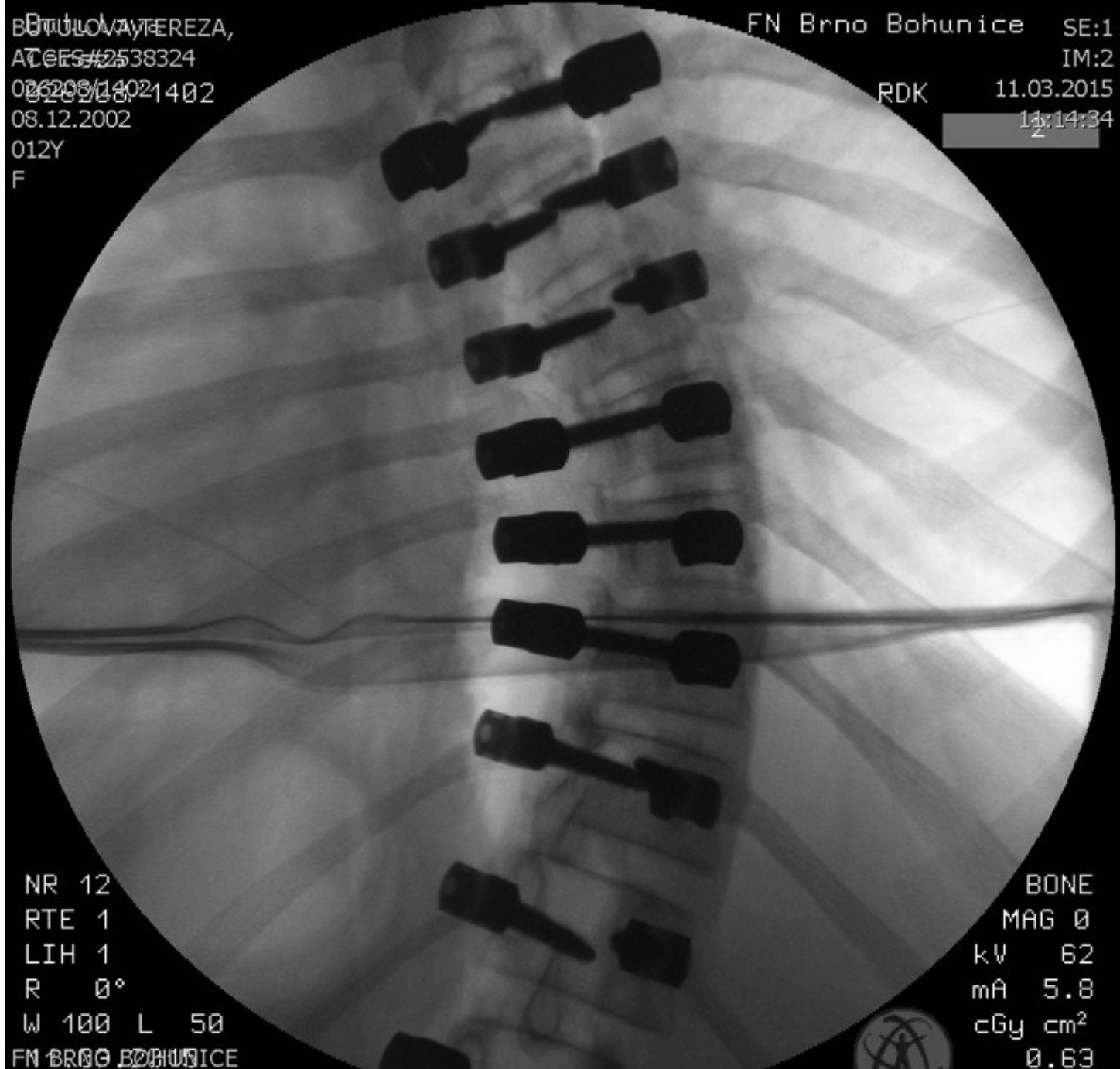





BUTULOVÁ, TEREZA,
ACEF#2538324
026208/14021402
08.12.2002
012Y
F


FN Brno Bohunice SE:1
IM:2
RDK 11.03.2015
11:14:34

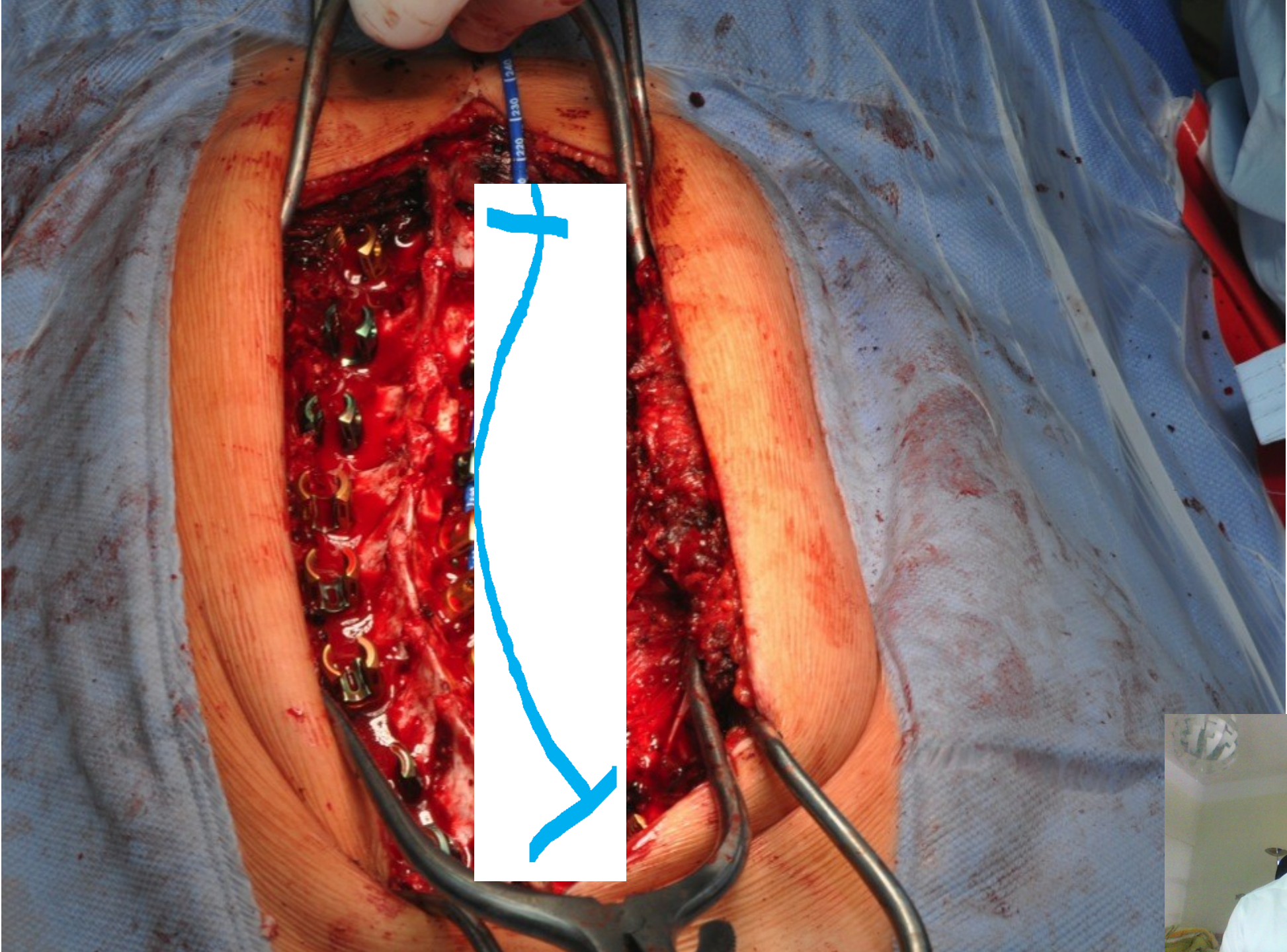



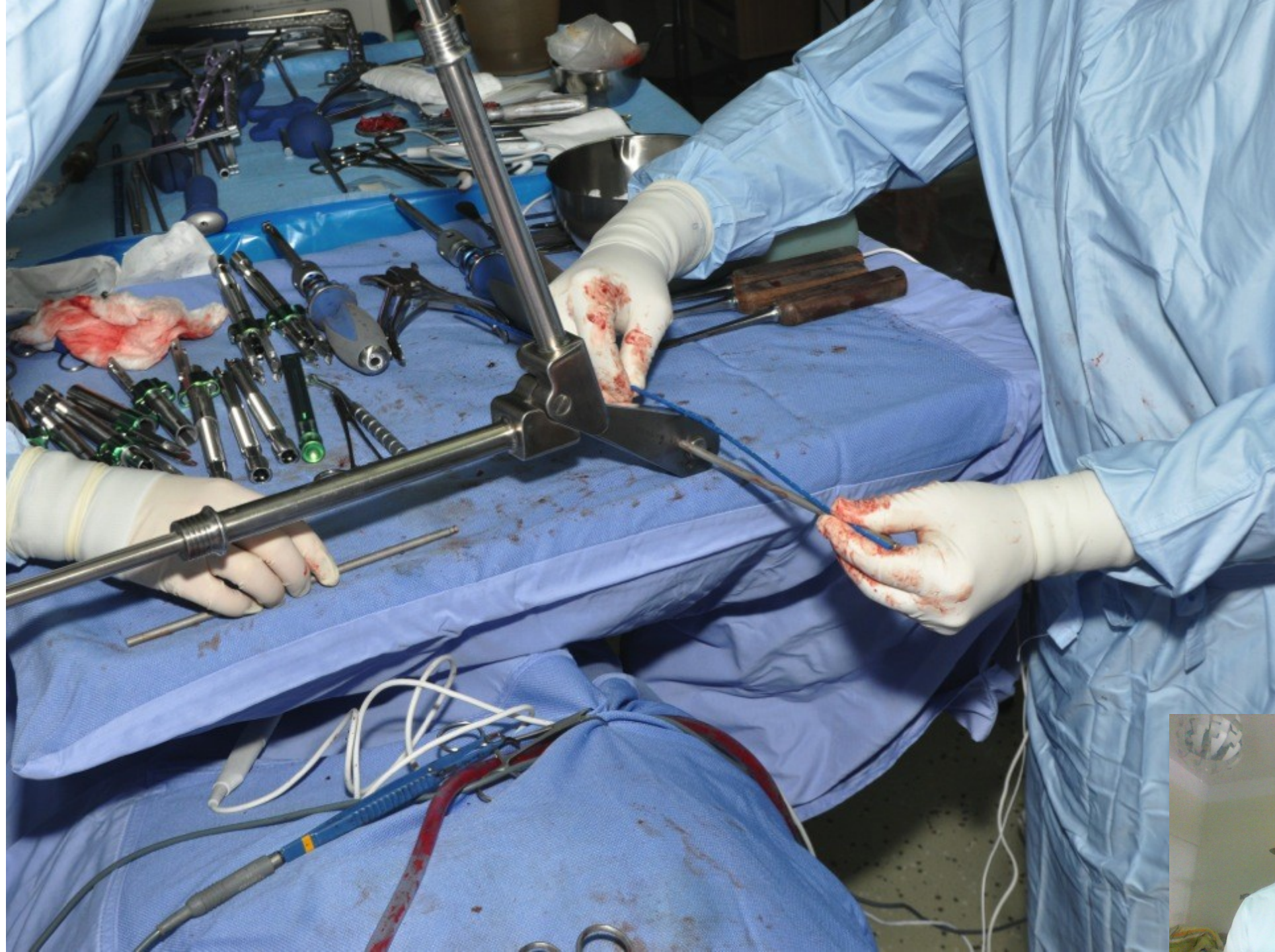
NR 12
RTE 1
LIH 1
R 0°
W 100 L 50
FN BRNO BOHUNICE
11:14:30

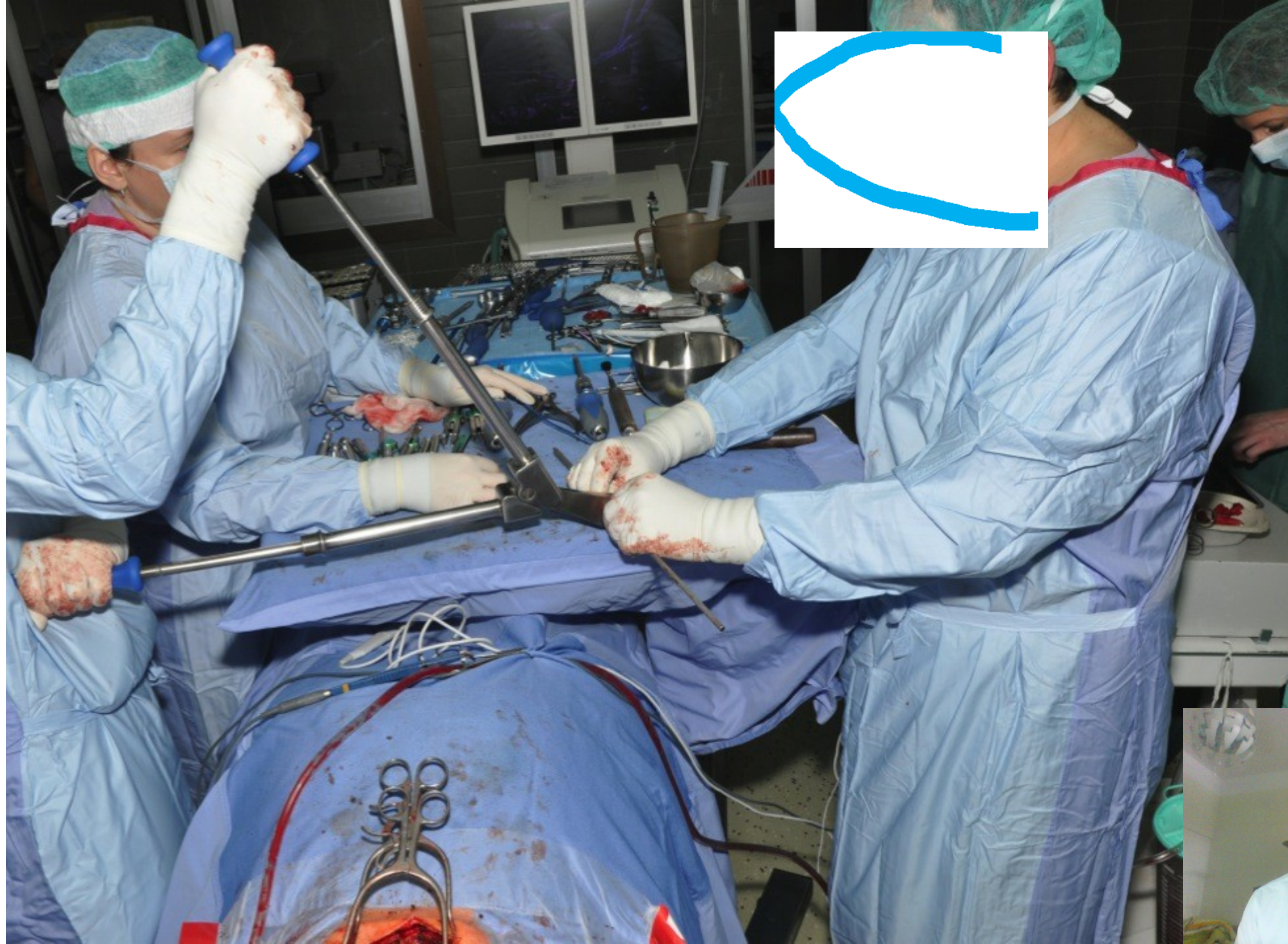
BONE
MAG 0
kV 62
mA 5.8
cGy cm²
0.63


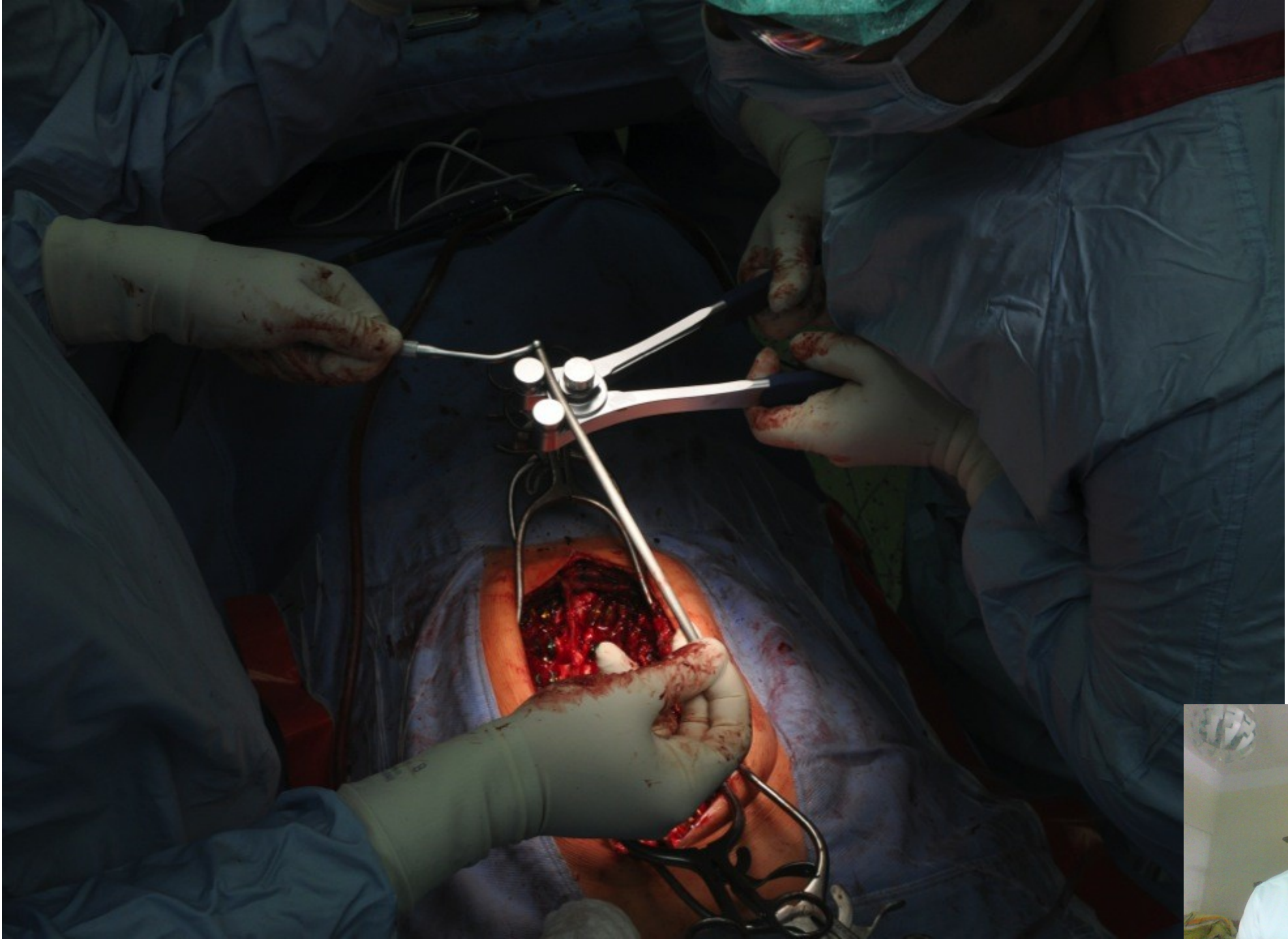
ortopedie, ortopedie, skiaskopicka kontrola radiodiagnostikem,


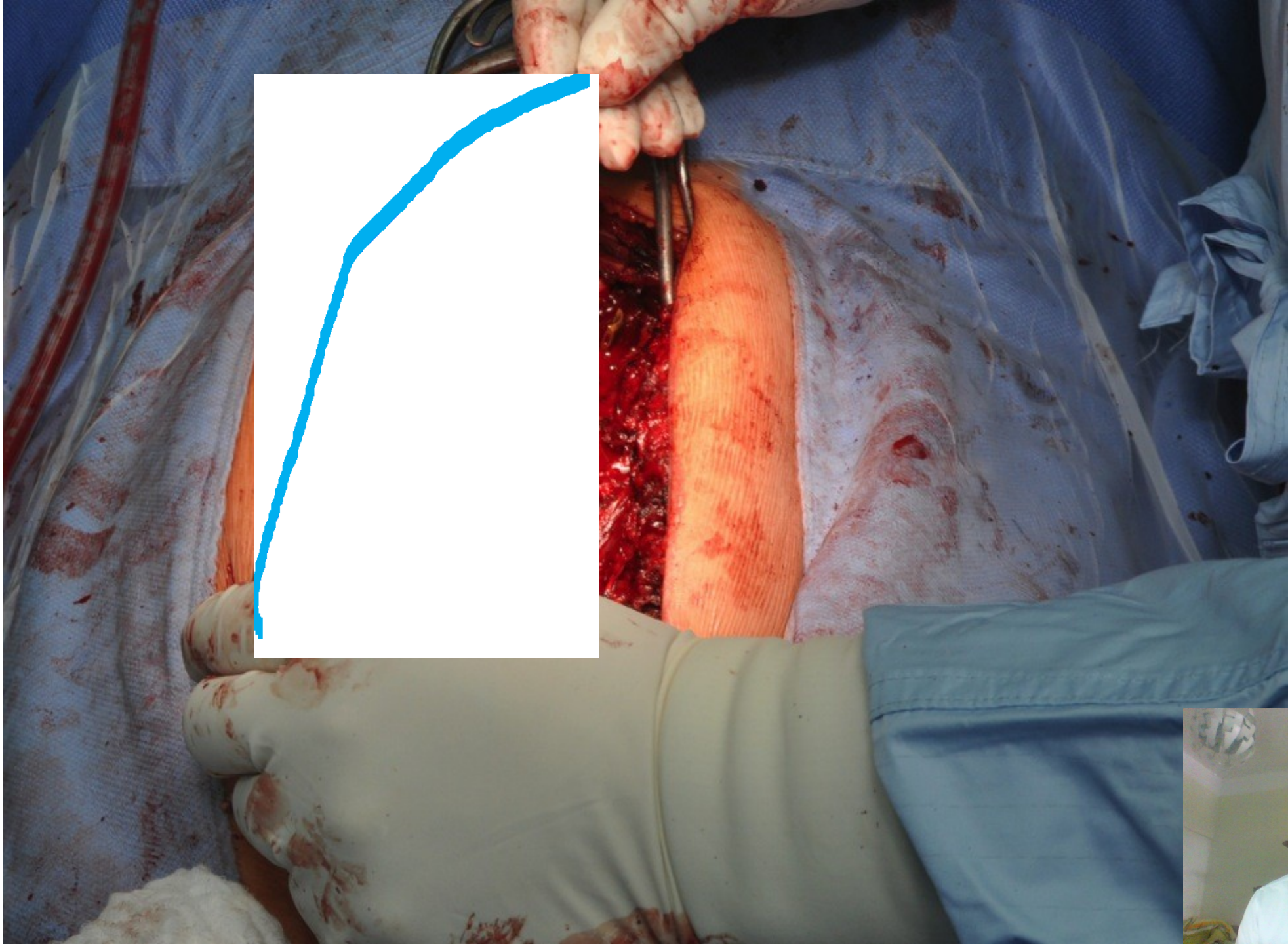



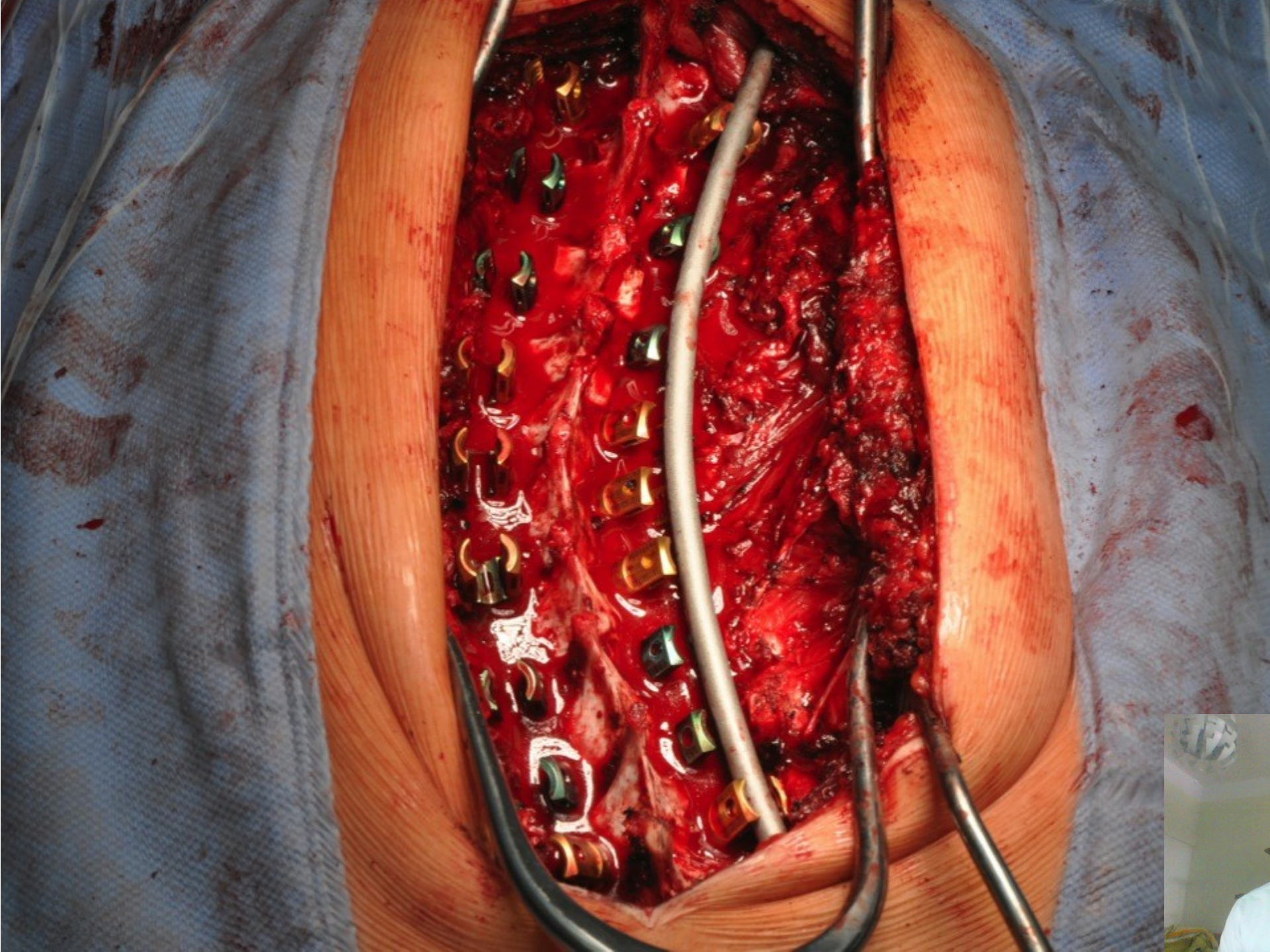


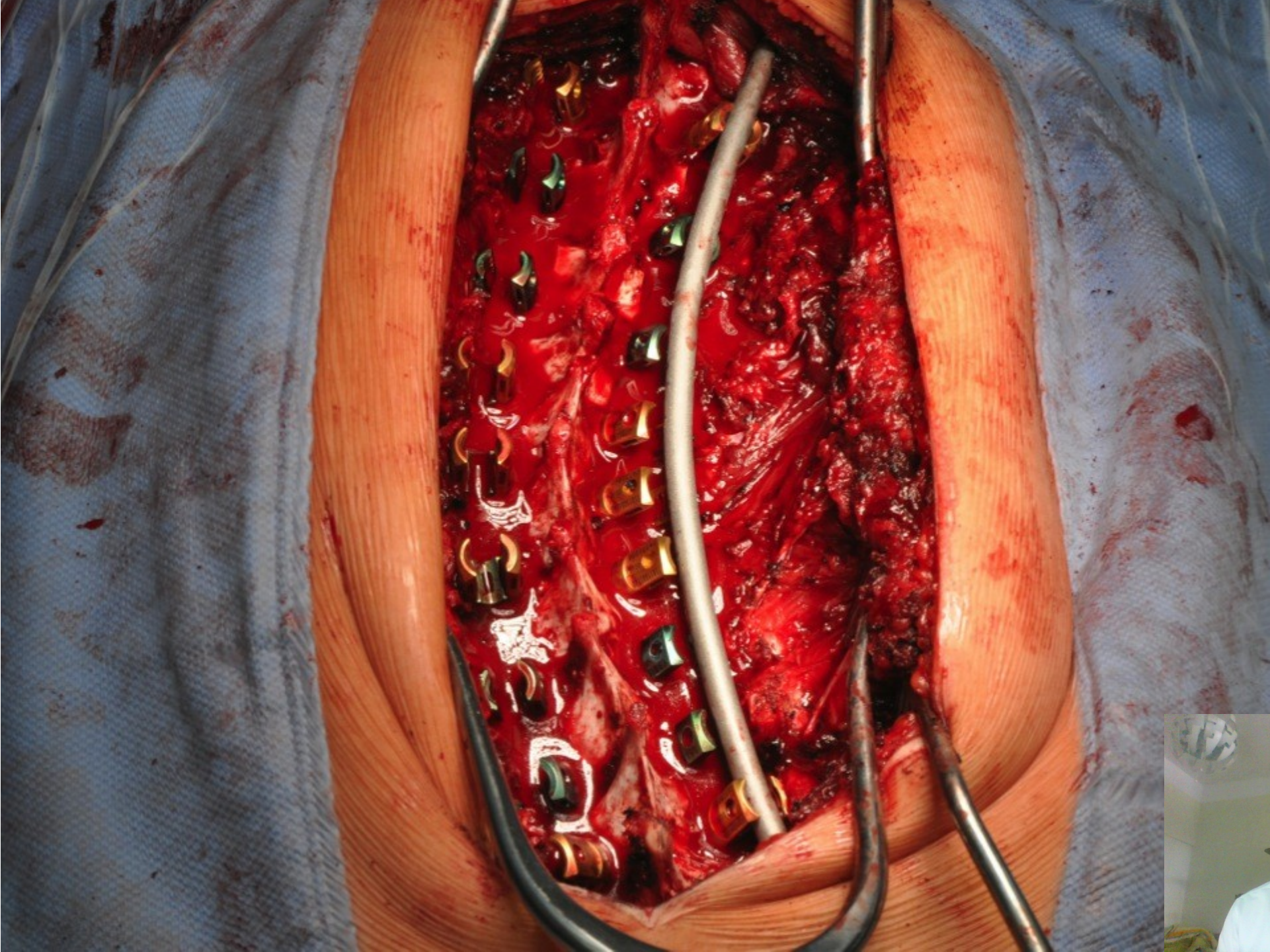



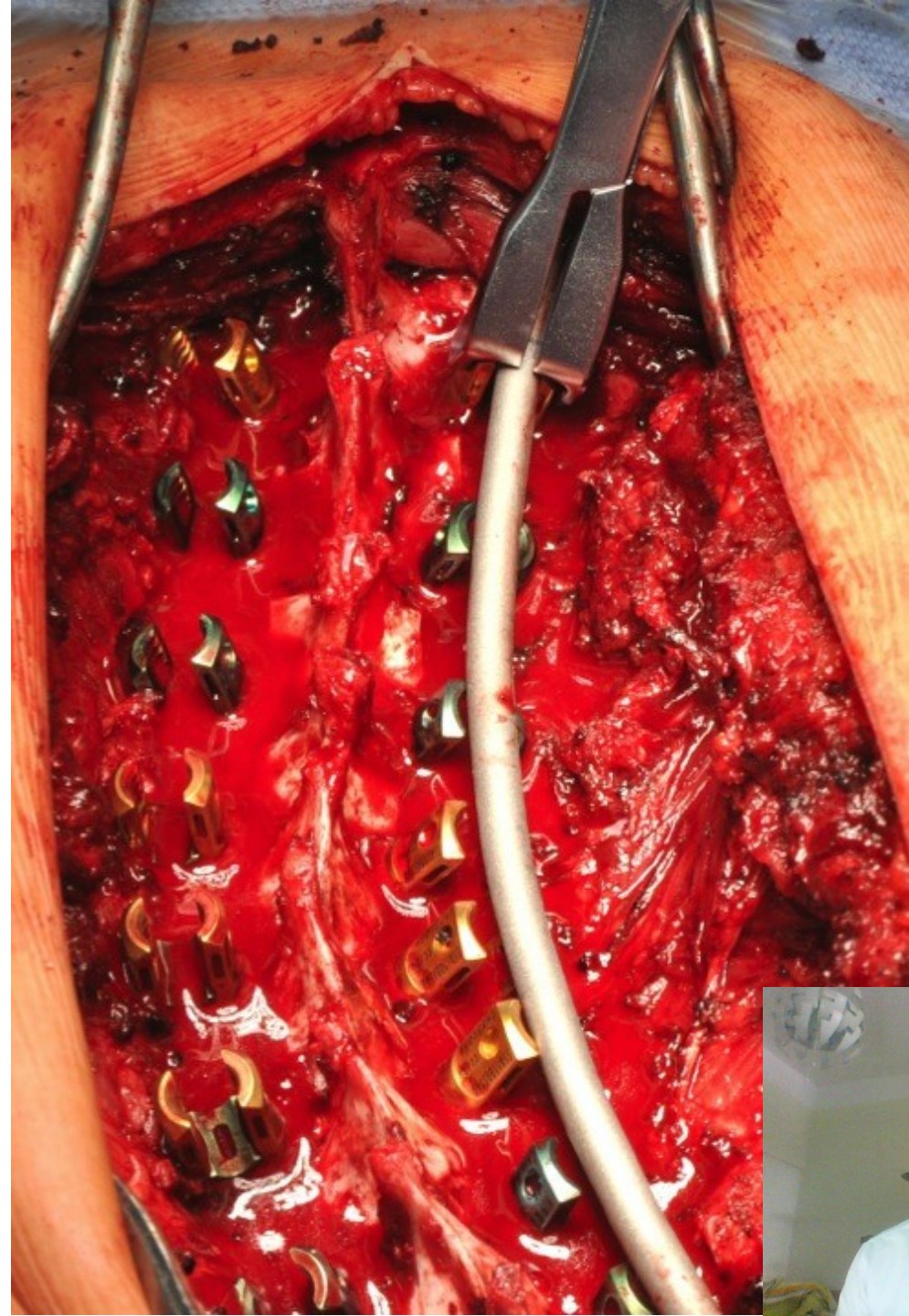
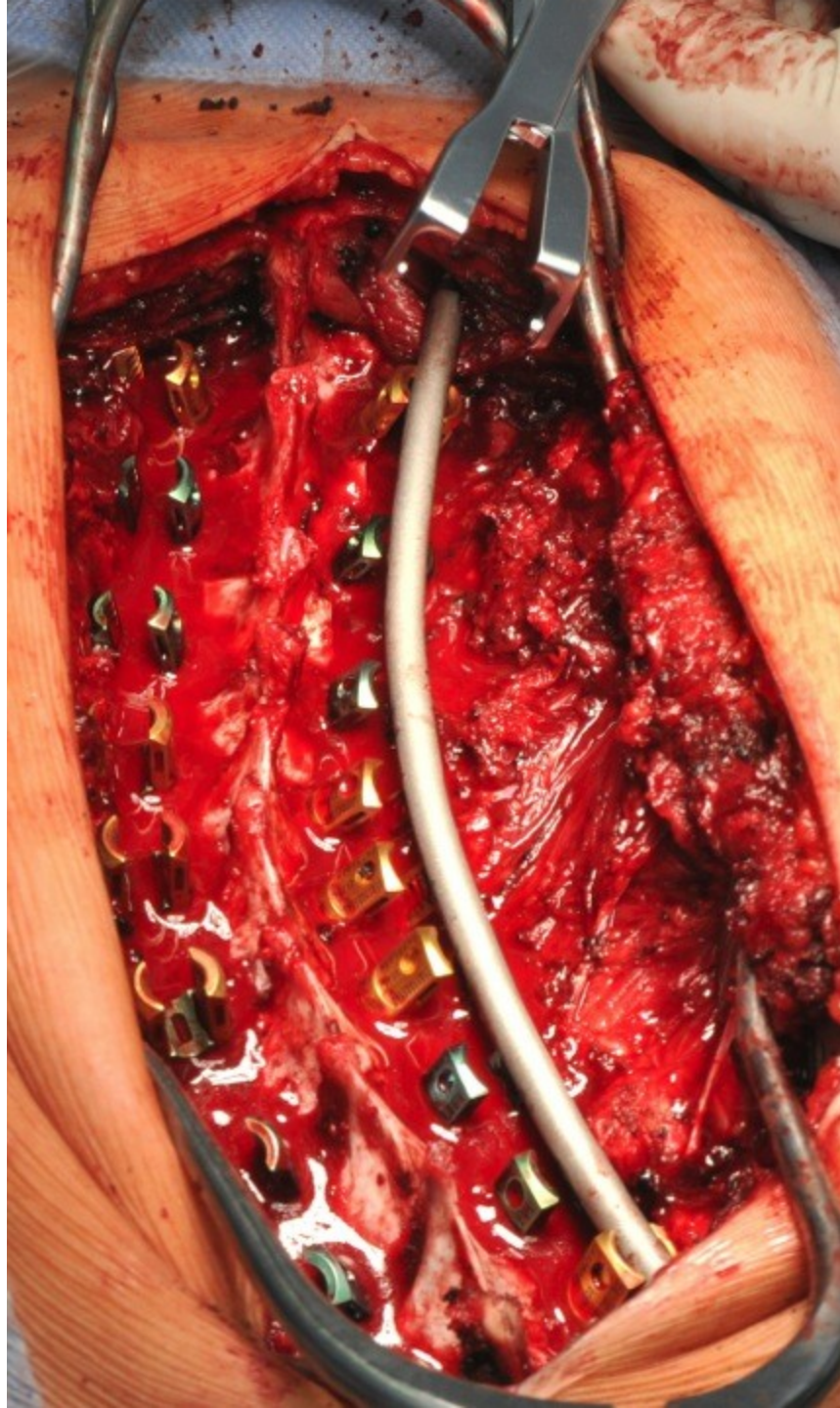


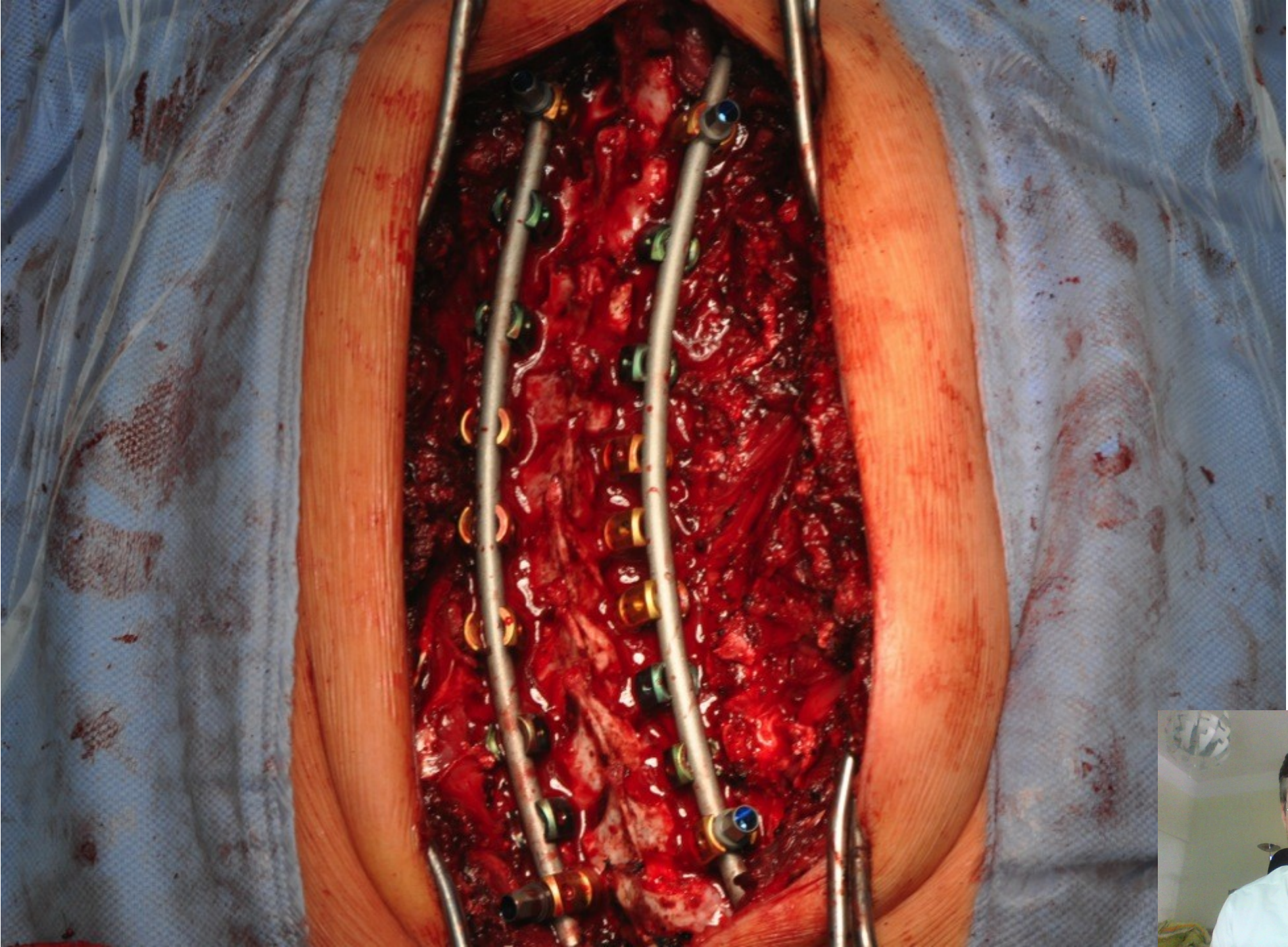



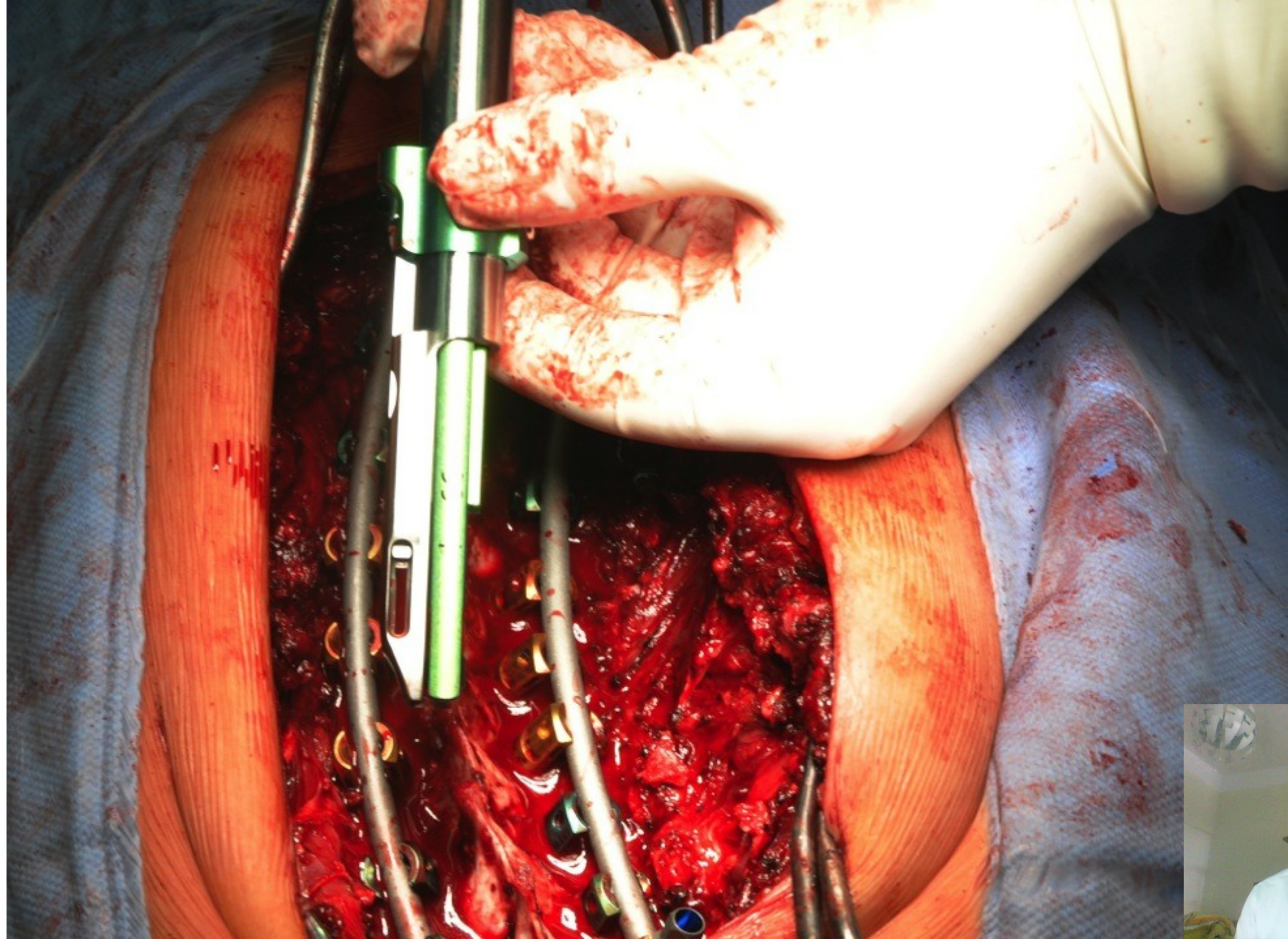



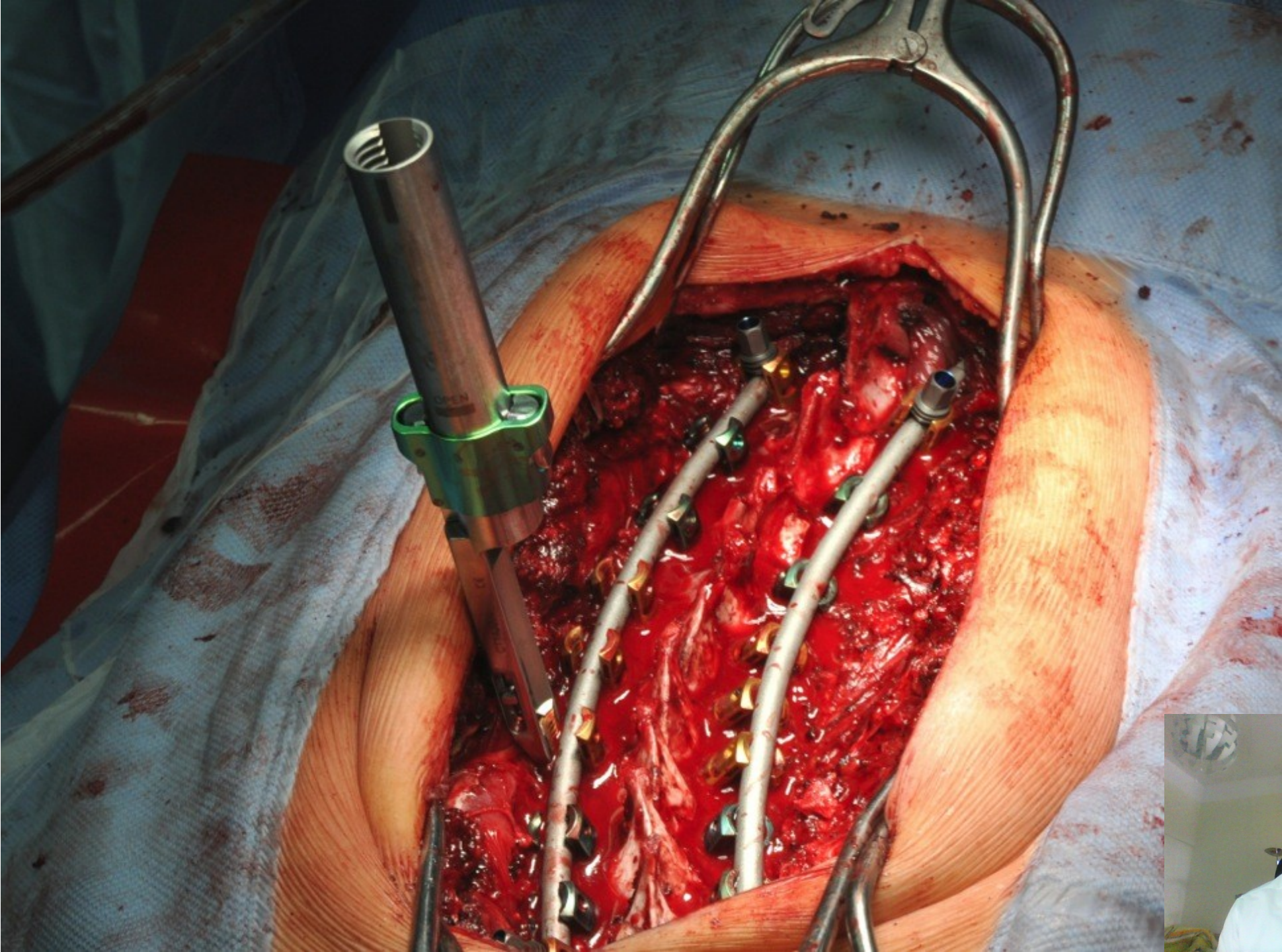



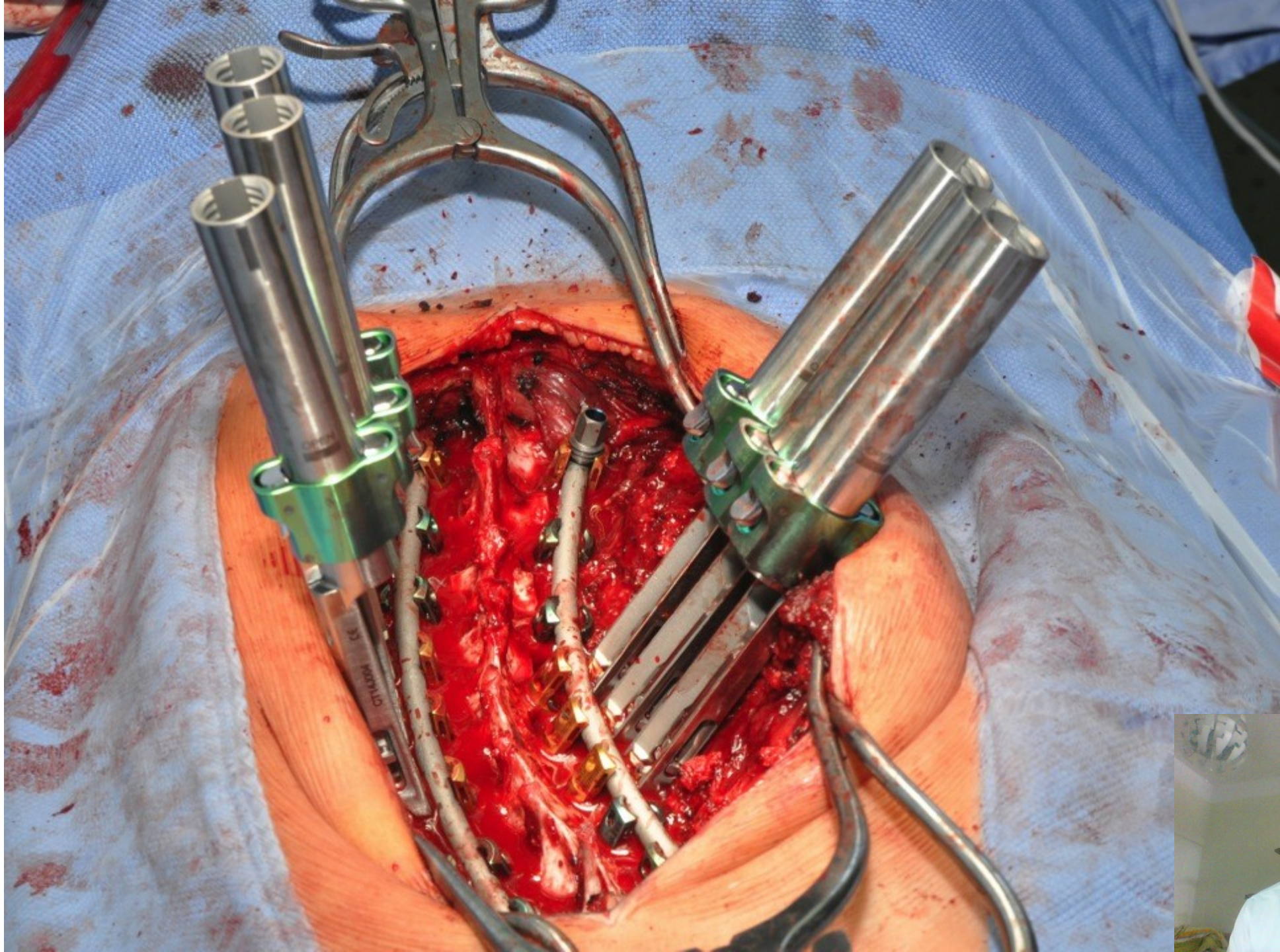



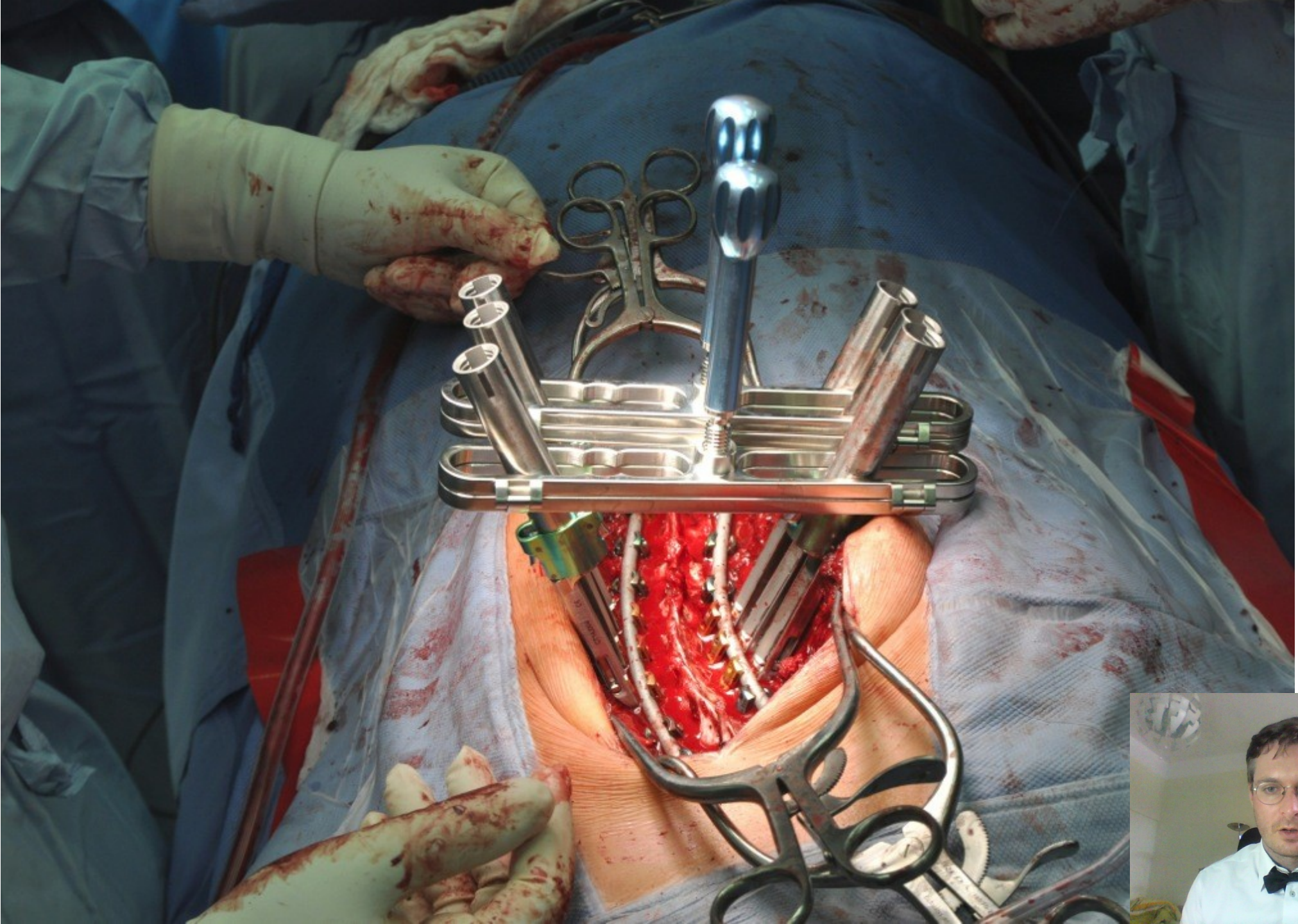


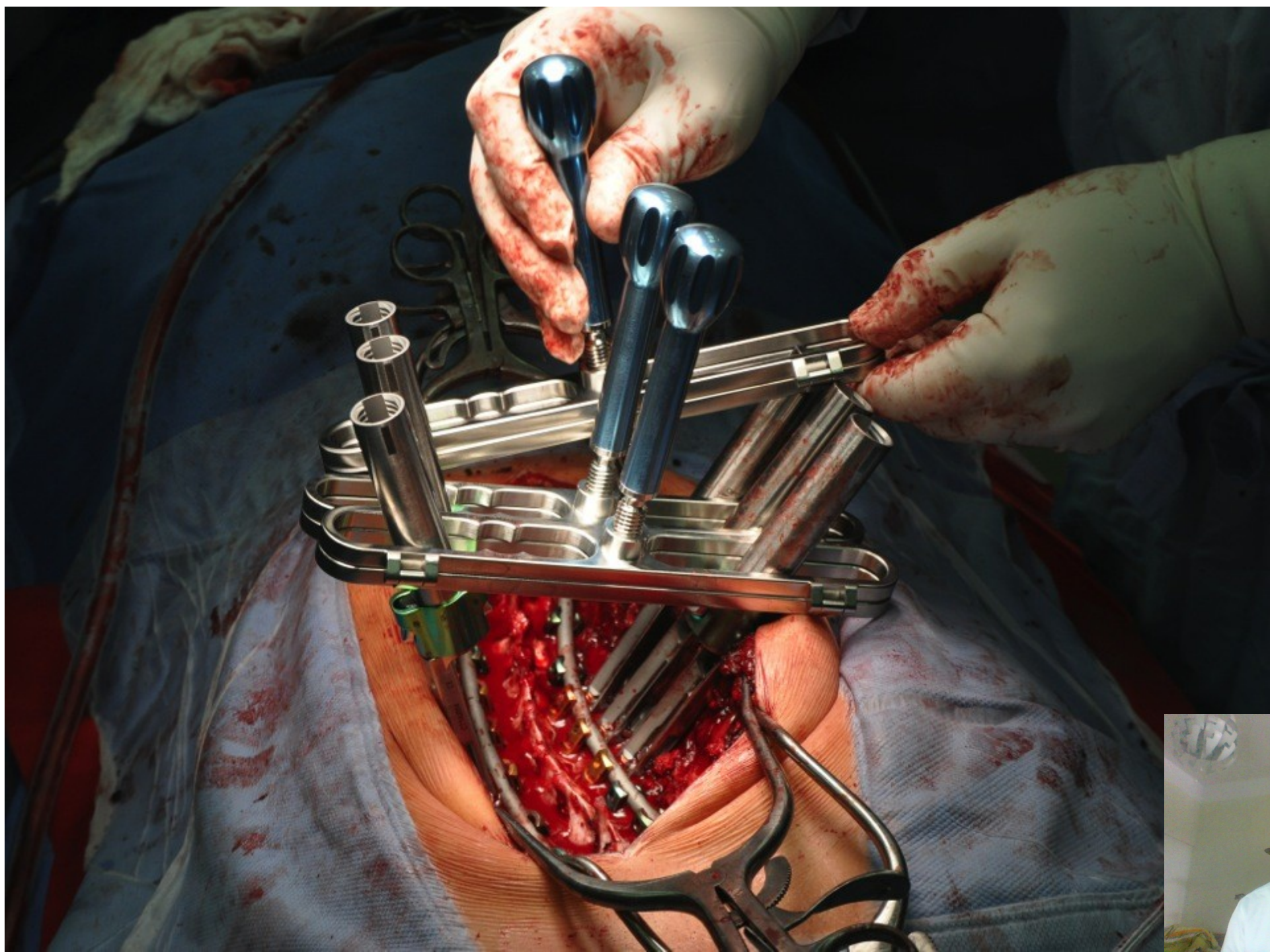



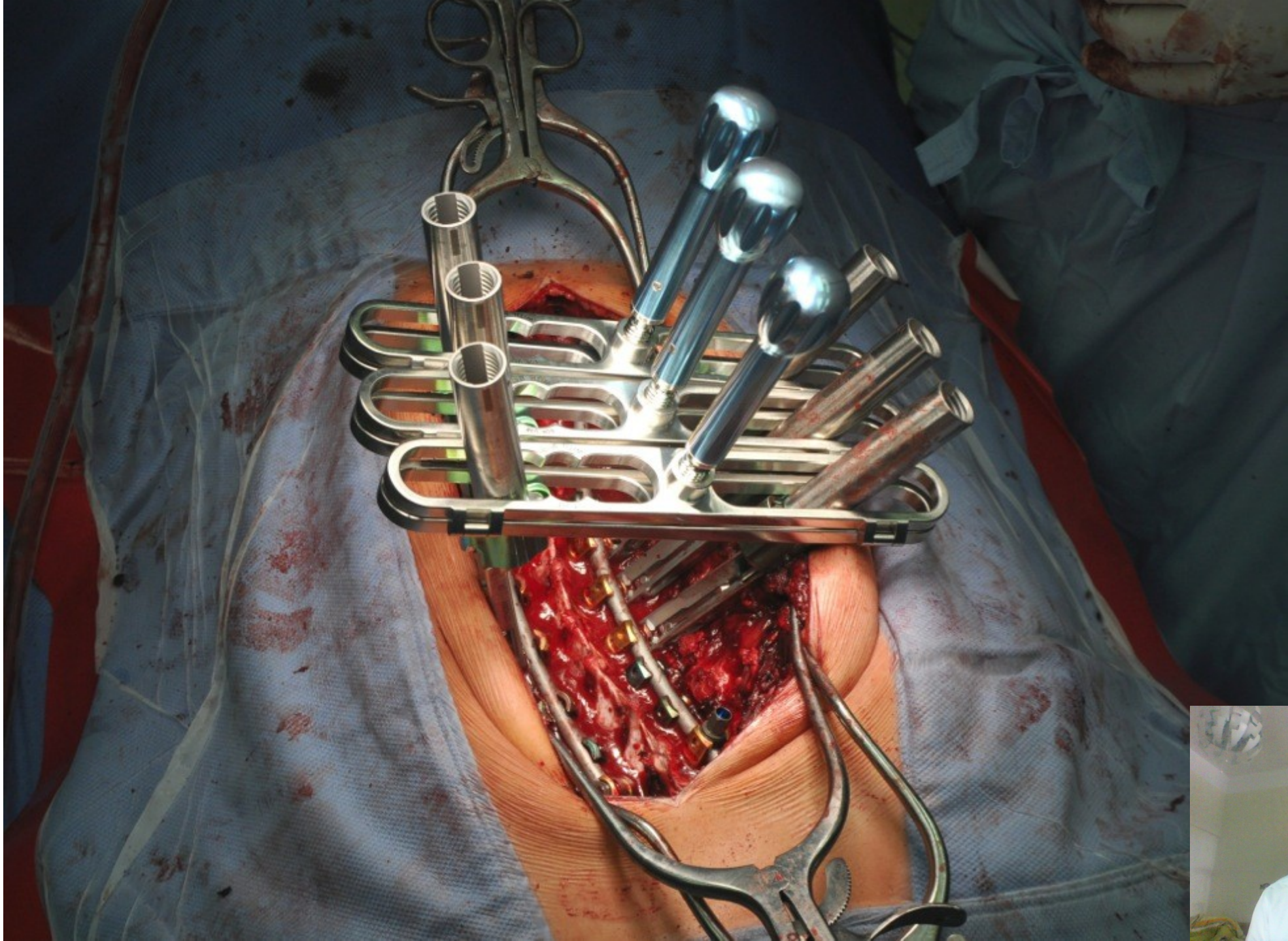


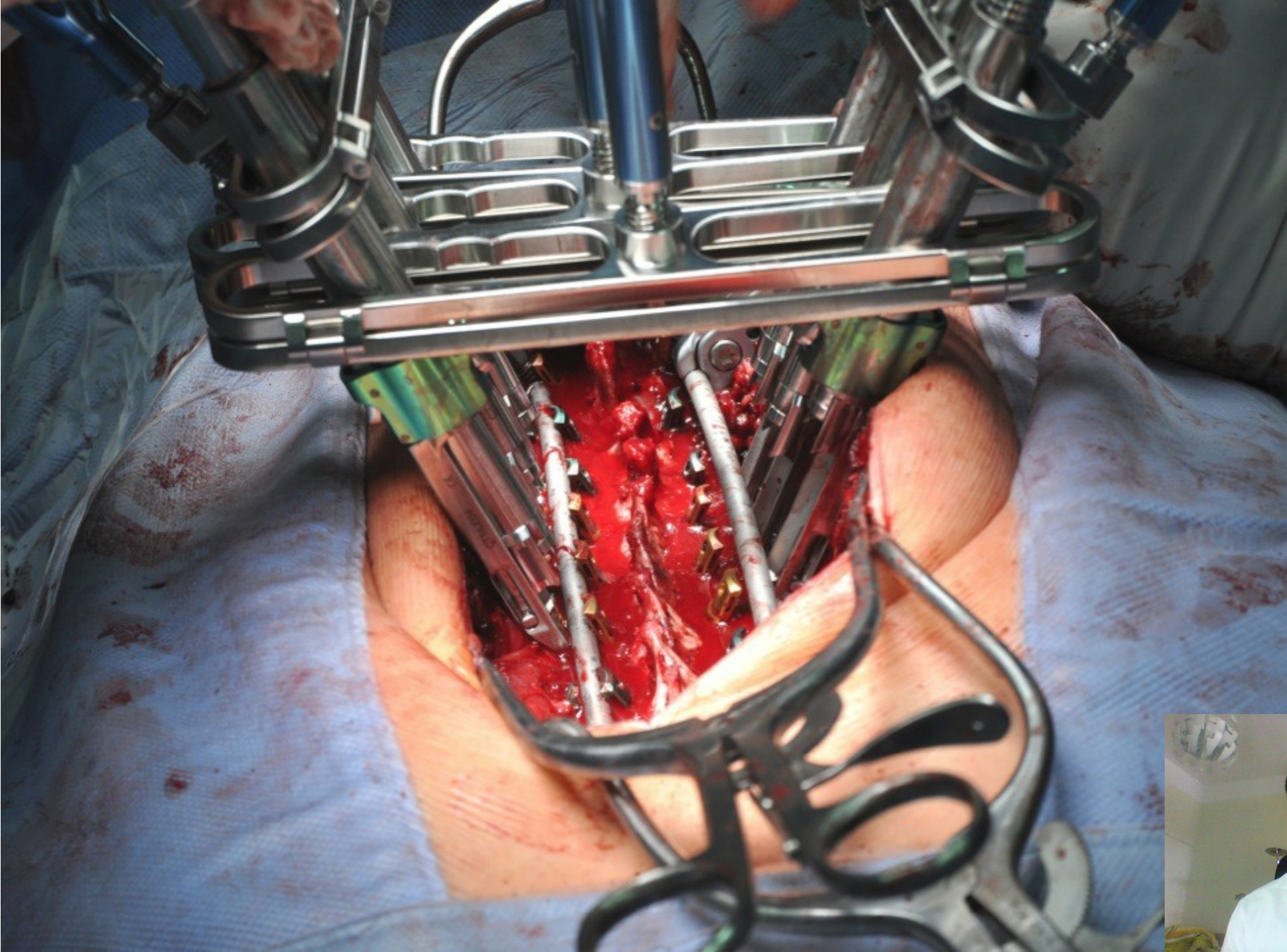


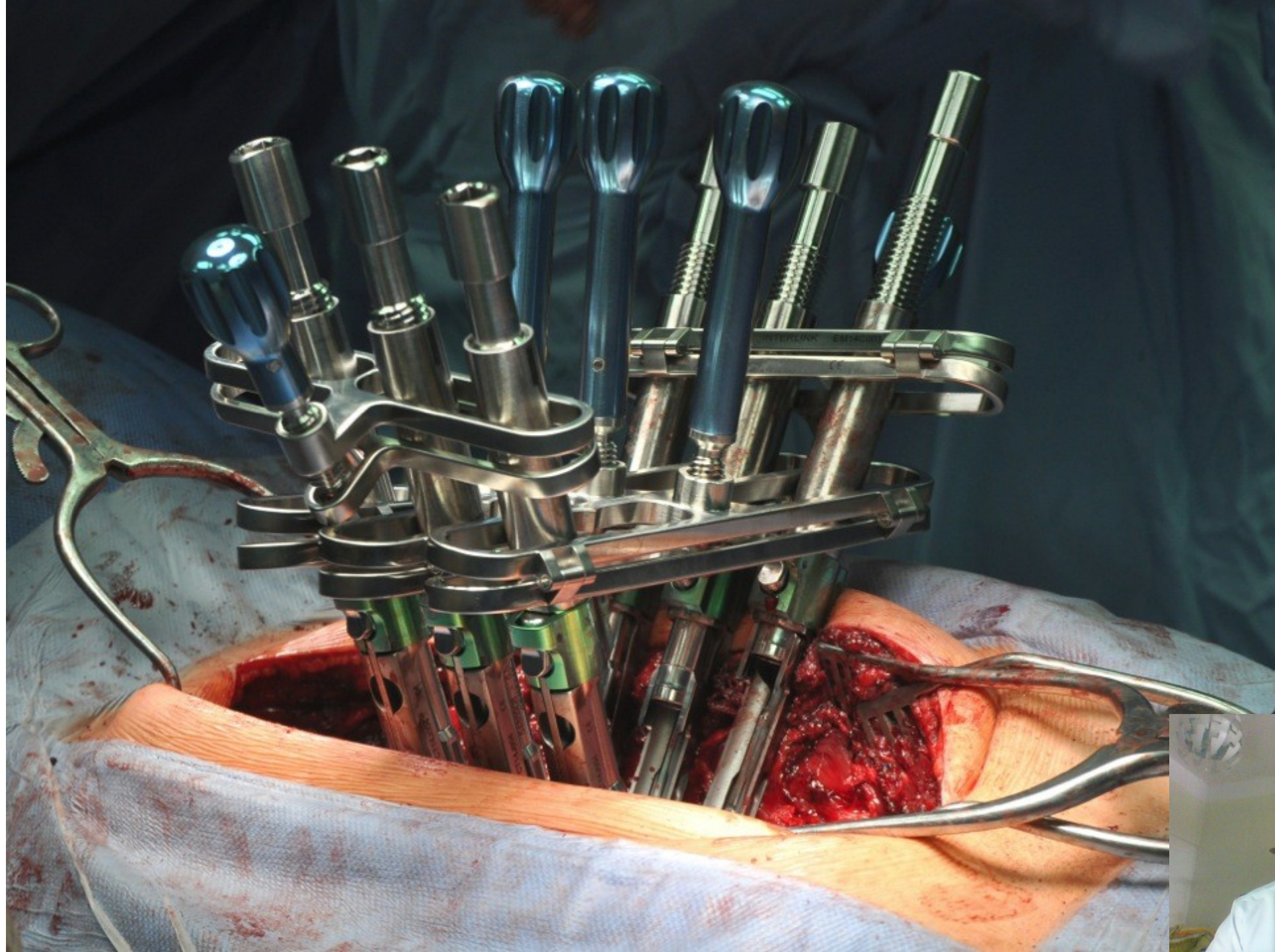






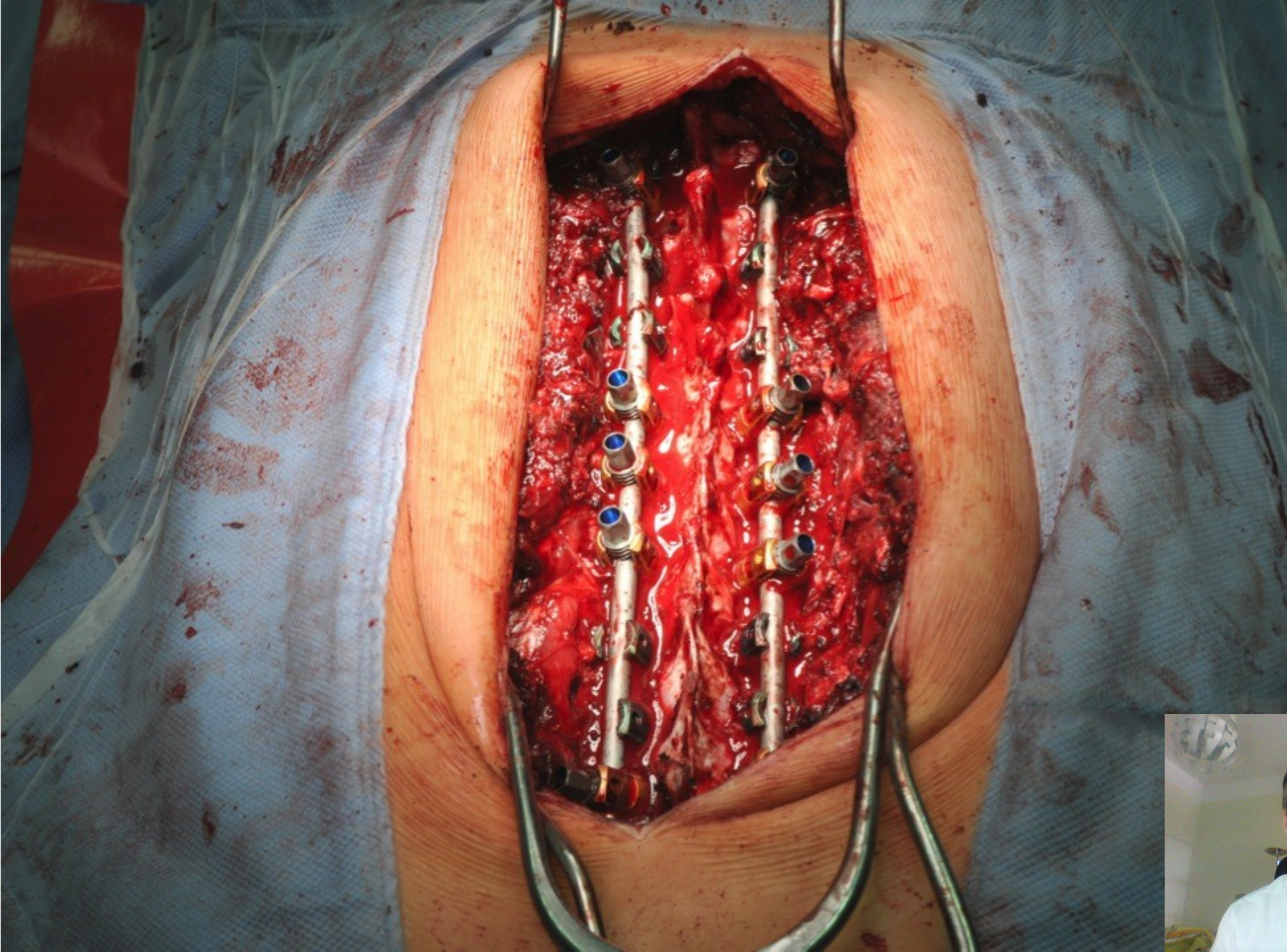


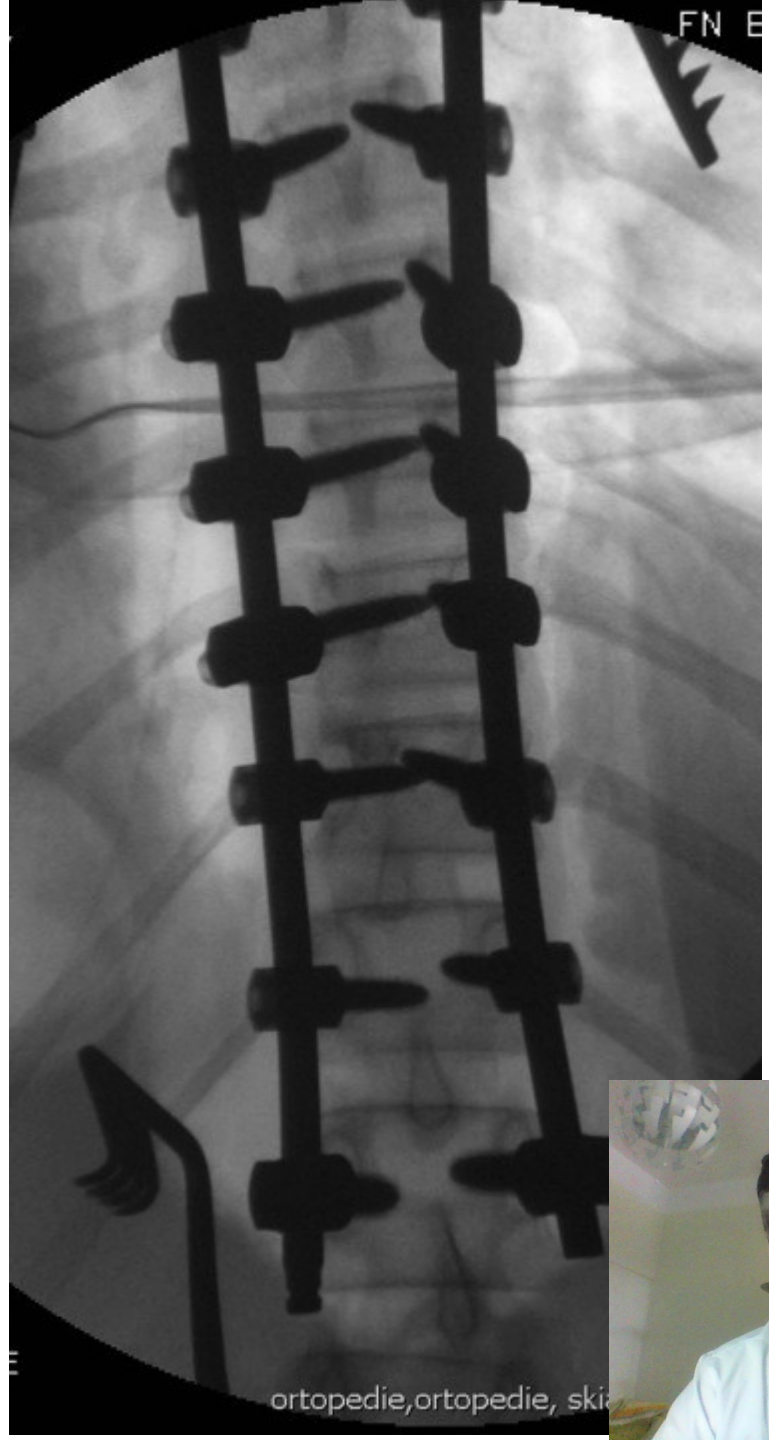
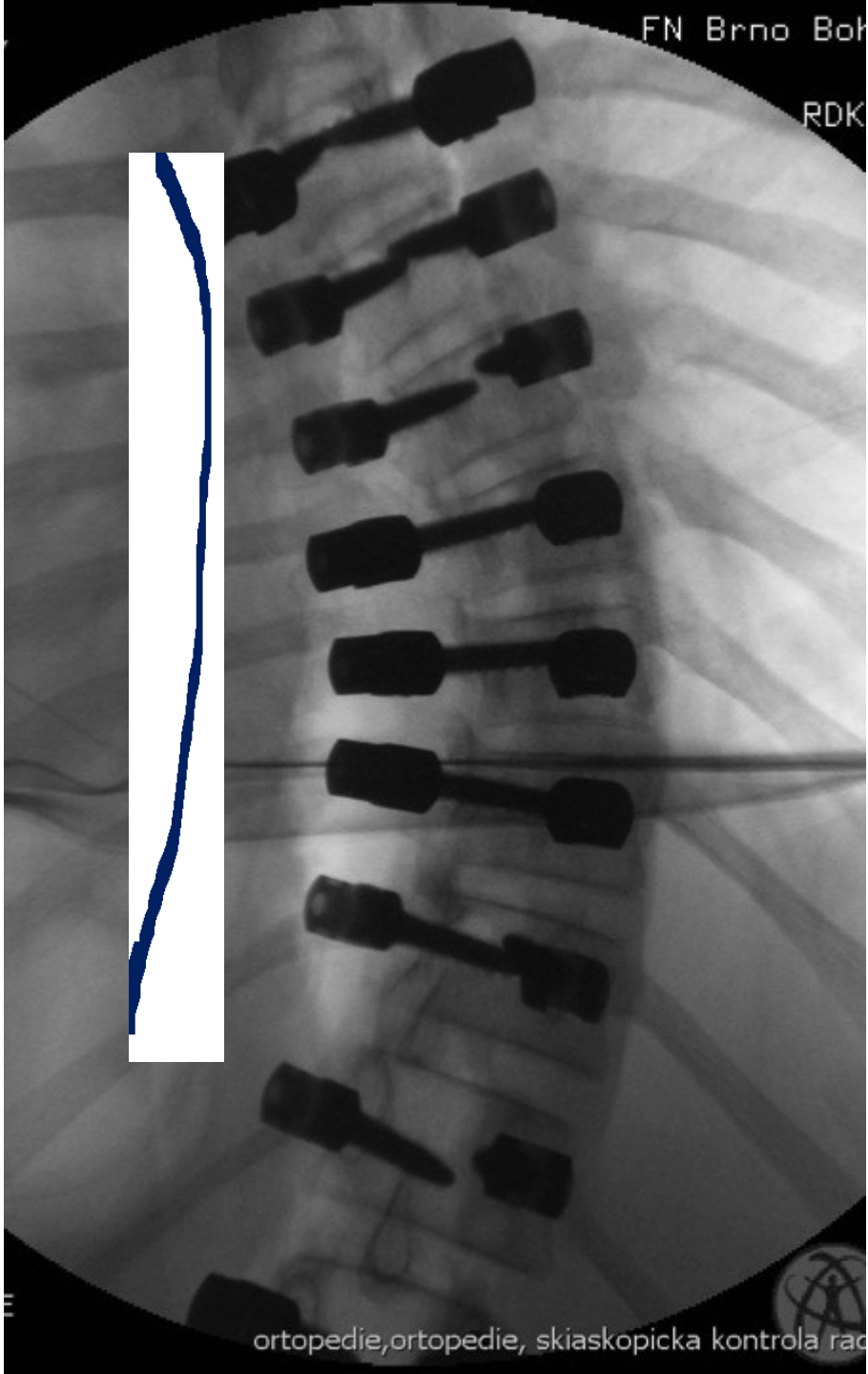


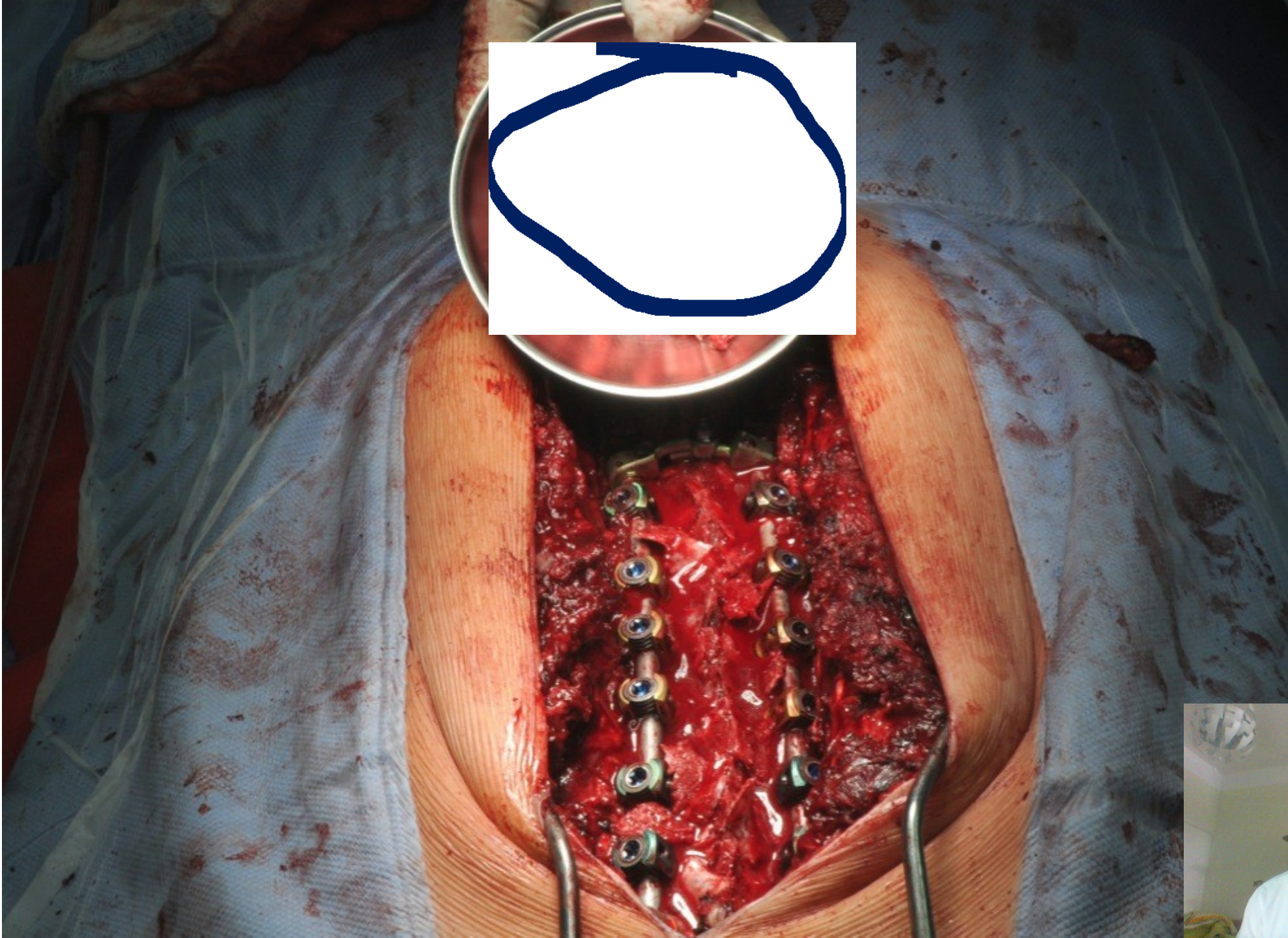



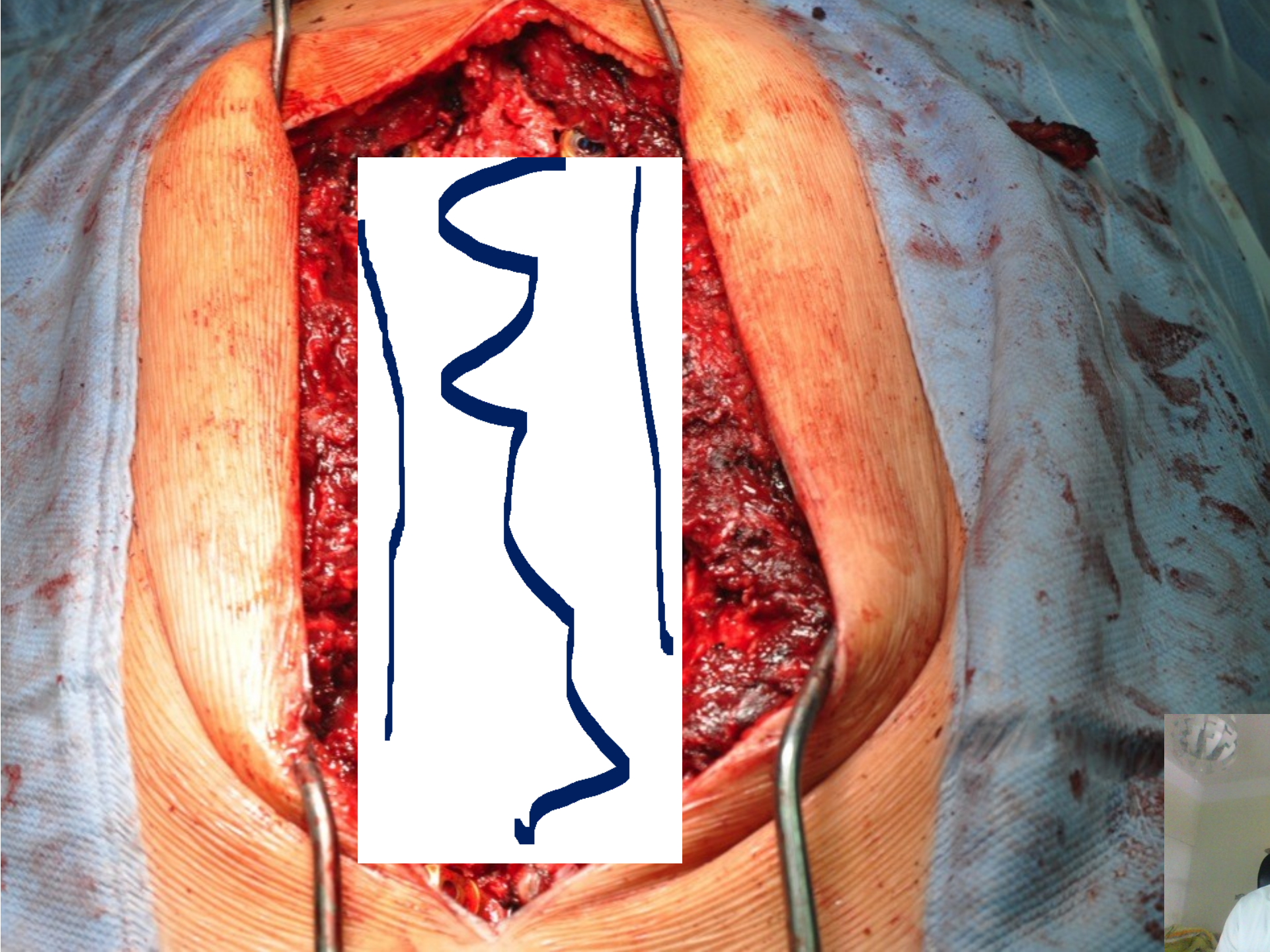













Nonfusion surgery methods

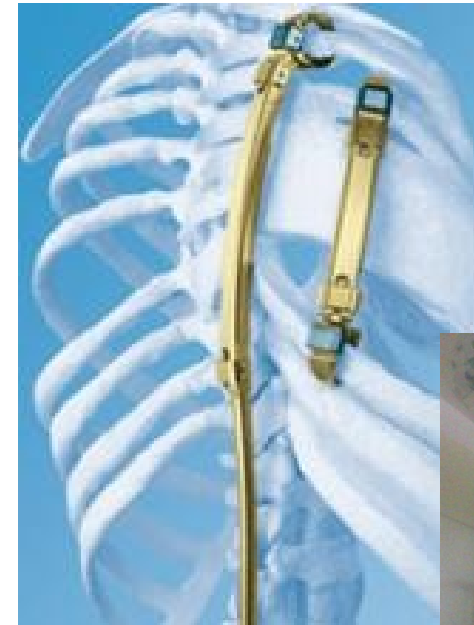


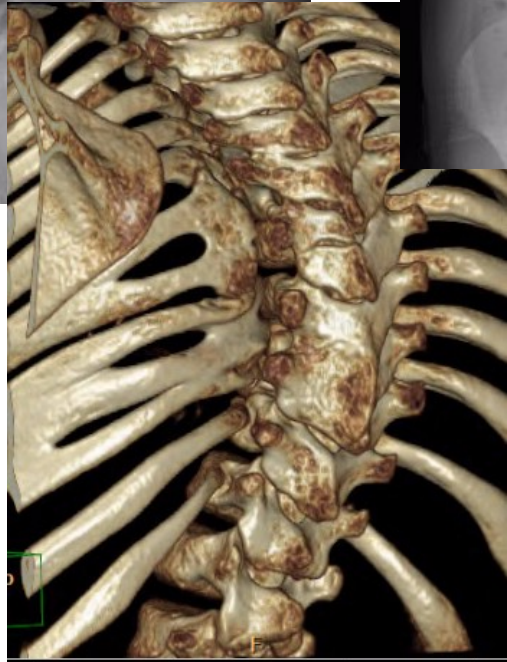
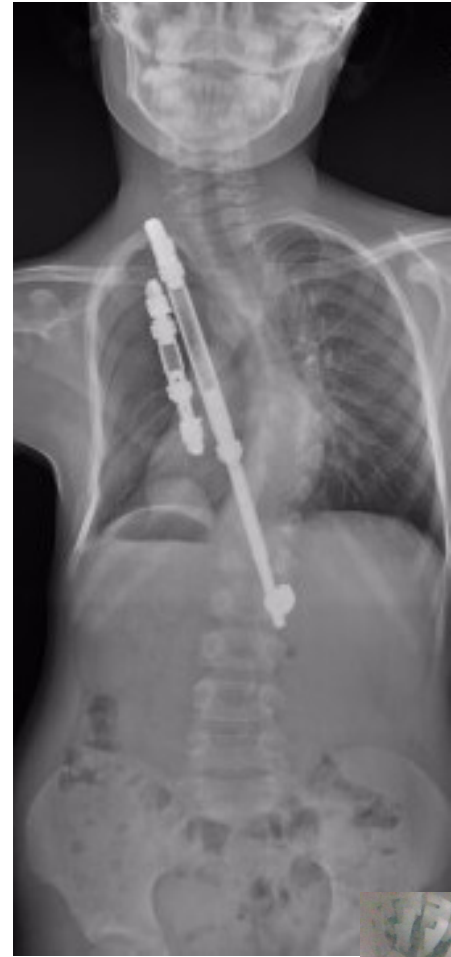
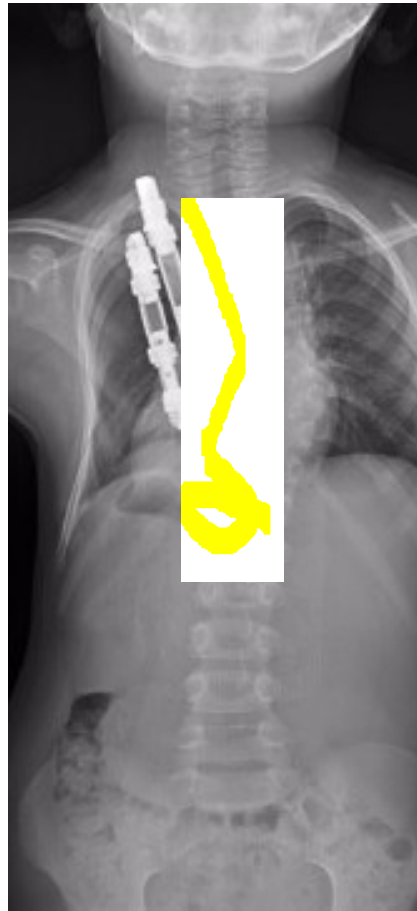
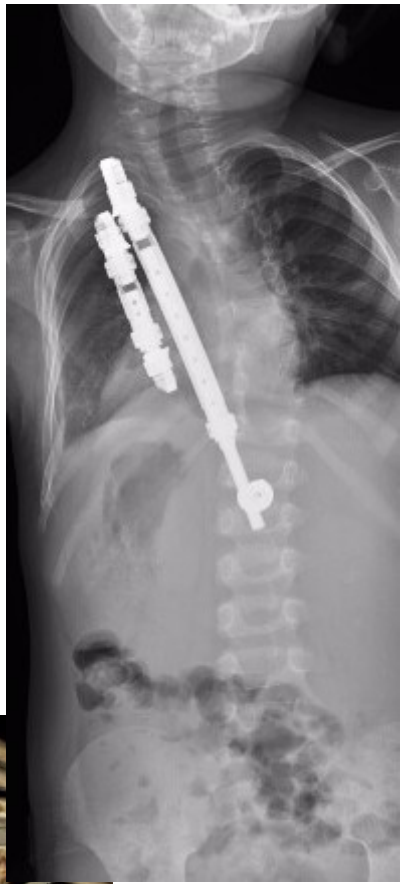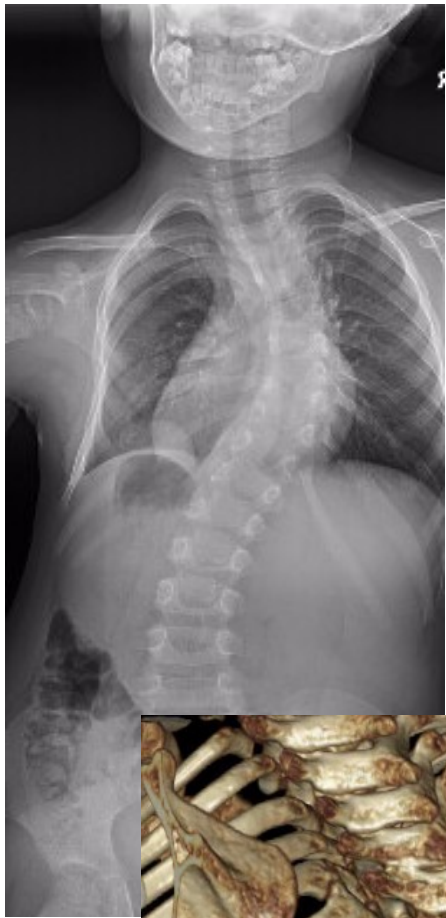VEPTR

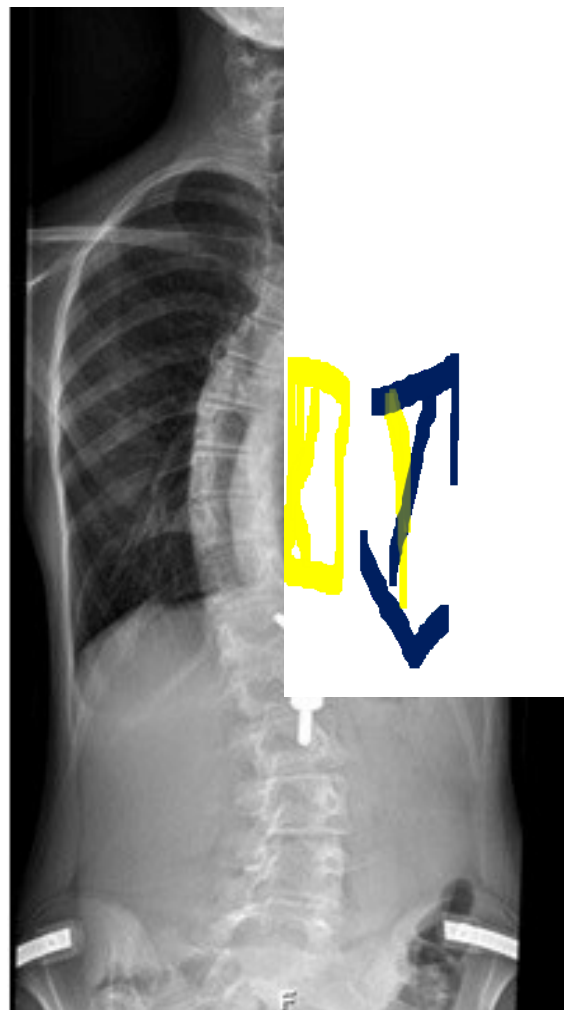

= **vertical expandable prosthetic titanium rib**

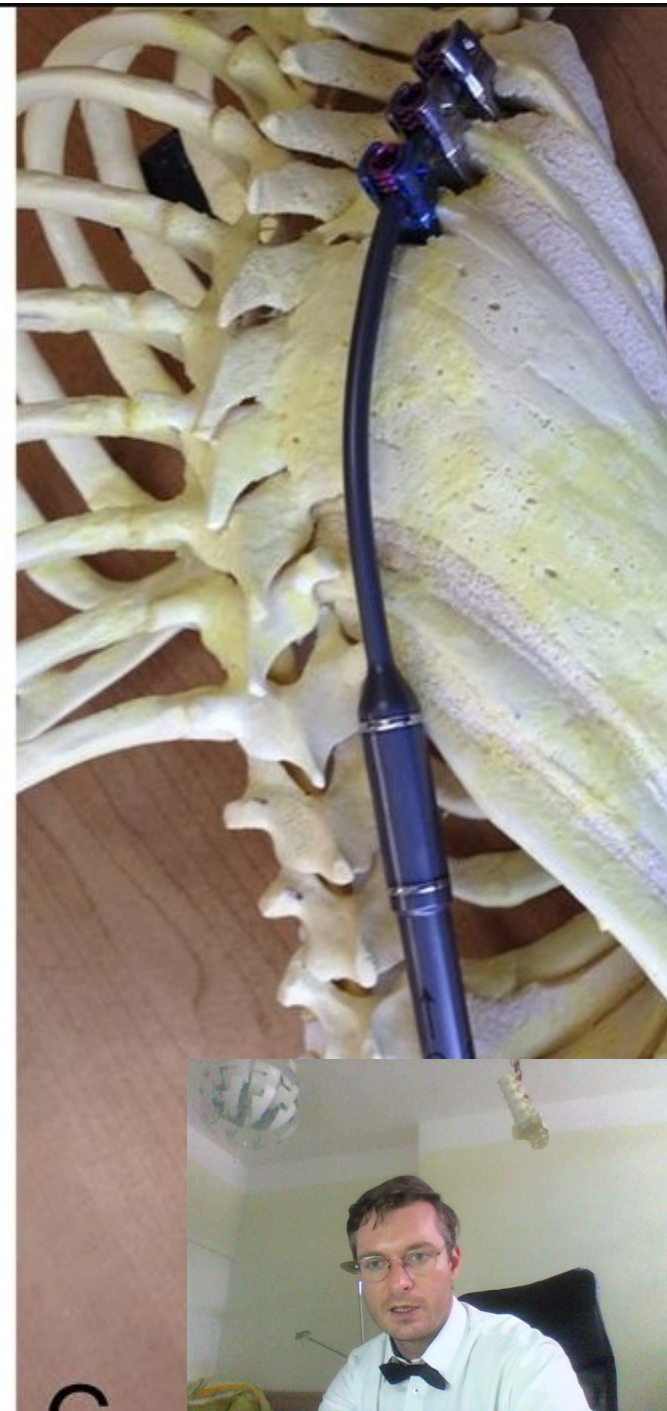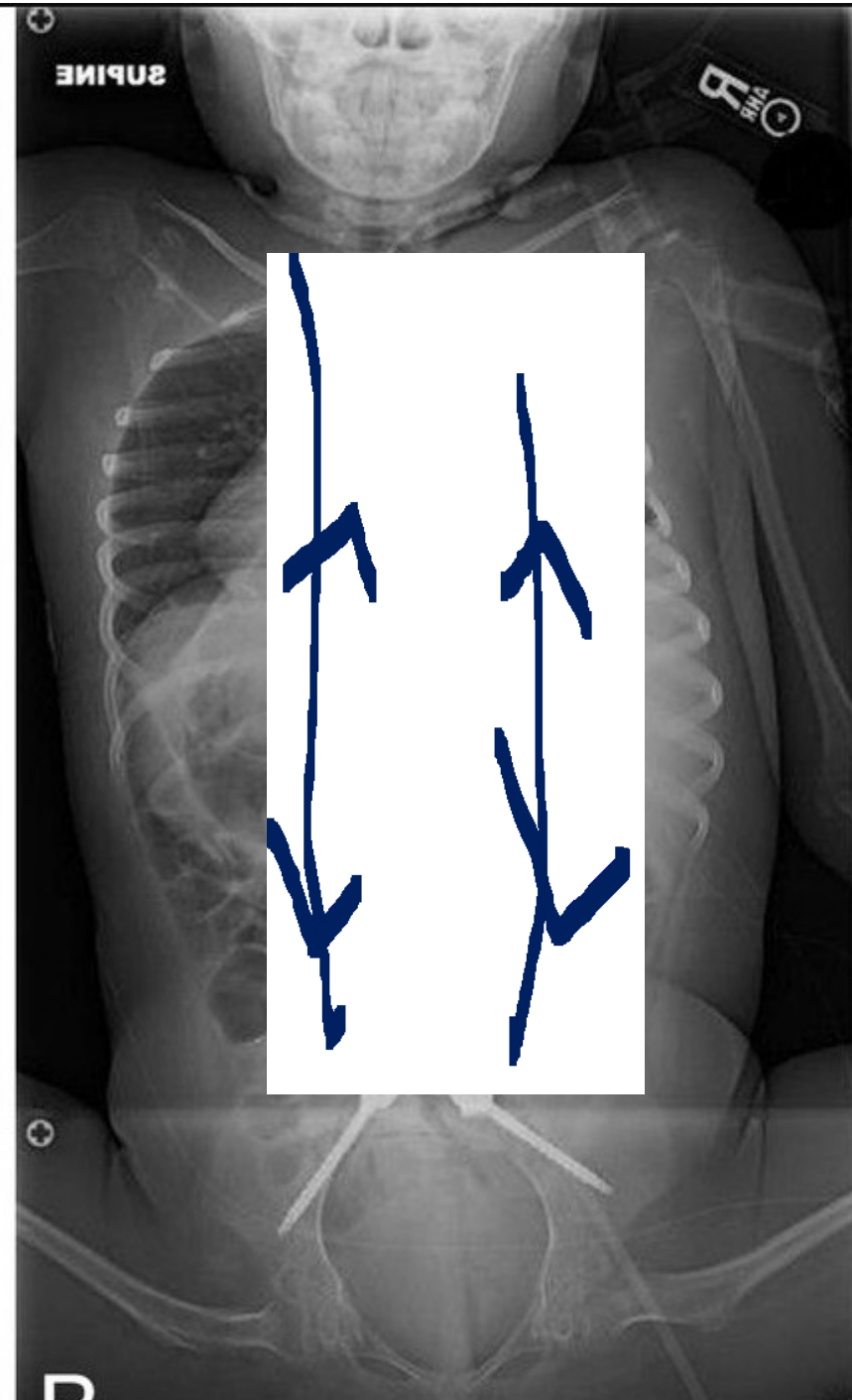
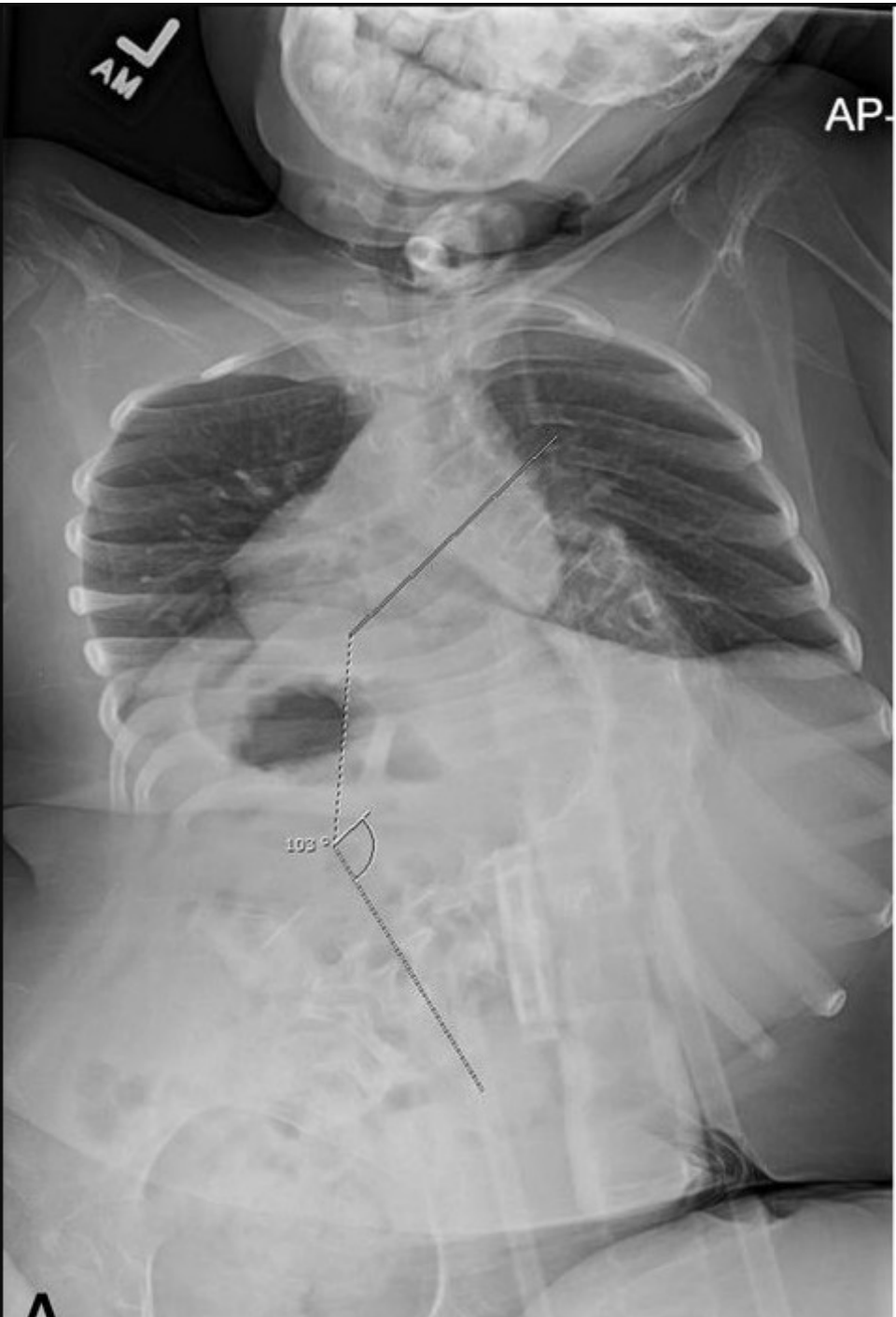- Indikace: kong. def. + thoracic insufficiency syndrom + kostní nezralost
- Cíl: zvětšení objemu hrudníku + korekce deformity
- Nutné opakované redistrakce






Magnetické tyče (Magnetic rods)


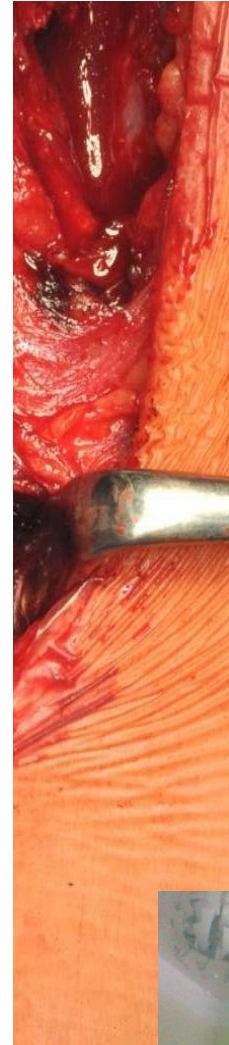


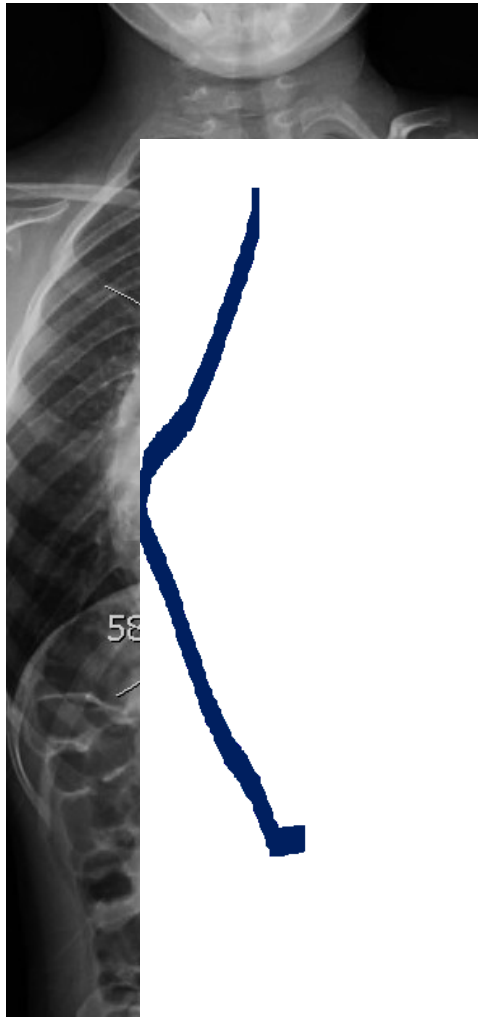


Growth Guided System

- Deformity correction + growth enabled
- Fusion of the apex of the curve
- The rest of spine grows guided along the rods








3+9




3+10

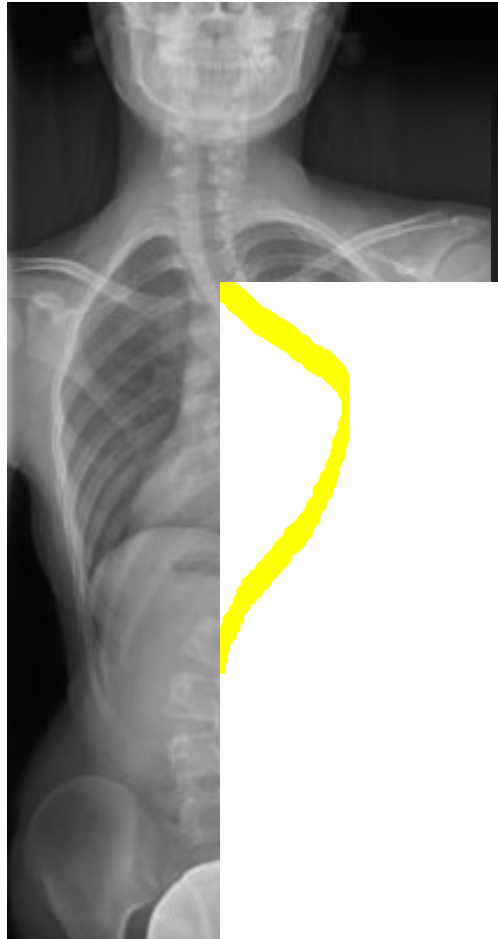

5+10

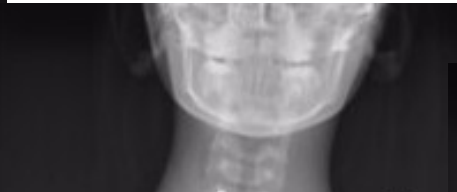

7+5

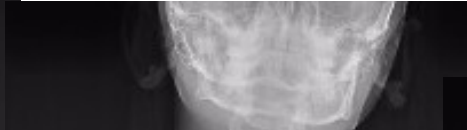



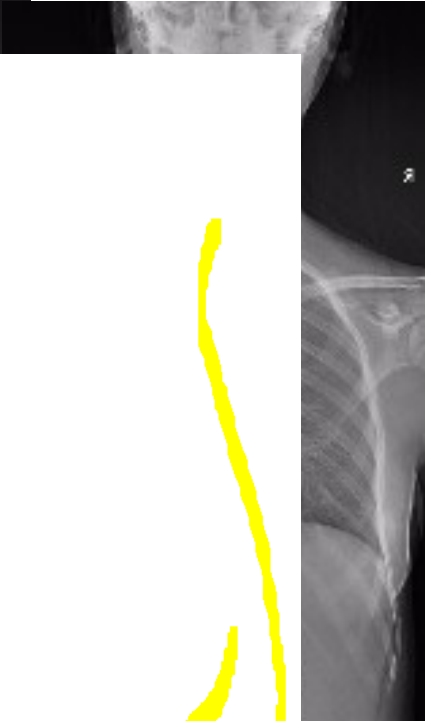10 +9




poop



13+8



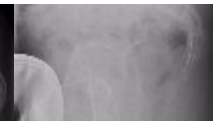
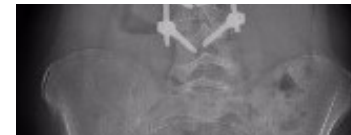
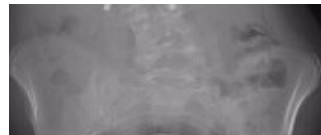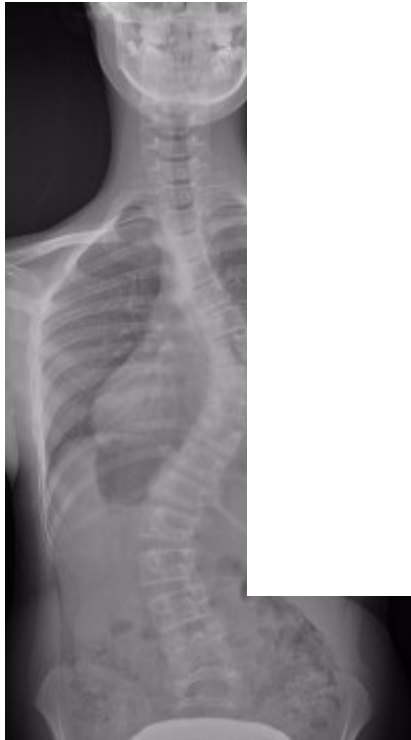15+1



GGG requires definitive fusion !

Pts need ~~_____~~


Convertic



Scoliosis types due to ethiology

Deformity type


- **Idiopathic**



- **Neuromuscular**


Age

- **Infantile**
< 3 y
- **Juvenile**
4-10 y
- **Adolescent**
11-17 y
- **Adult**
> 17 y




Congenital scoliosis

- Congenital Scoliosis- inborn spine deformity due to imperfect formation of vertebrae and their association.
- Hard to predict development and deformity progression ...




Congenital scoliosis

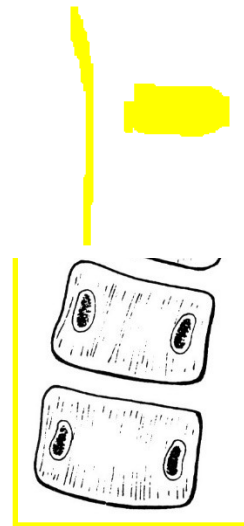
- deformity occurs during the first 6 weeks of embryonic development without hereditary burden, it is not hereditary
- wide diversity of severity of disability
- dg. newborns / toddlers, can occur at any time during growth




CONGENITAL scoliosis



Hemivertebra




Unsegmented bar





Congenital scoliosis



- Failure of SEGMENTATION- failure of the connection of one or more vertebrae on one side
- Failure of FORMATION- most often, disorder of vertebra formation, shape anomalies
- COMBINED failure



Failure of segmentation






Failure of segmentation



Failure of segmentation

-



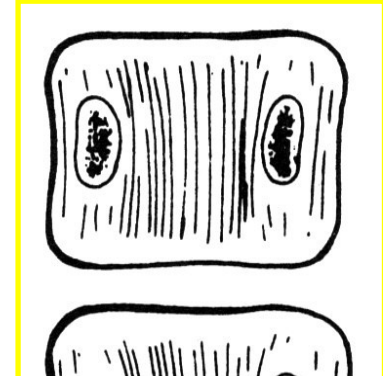


Failure of segmentation

Usually asymptomatic

Can lead to relative shortening of spine

“
”



Failure of formation

- anterior

Could affect just part of vertebra / all structures

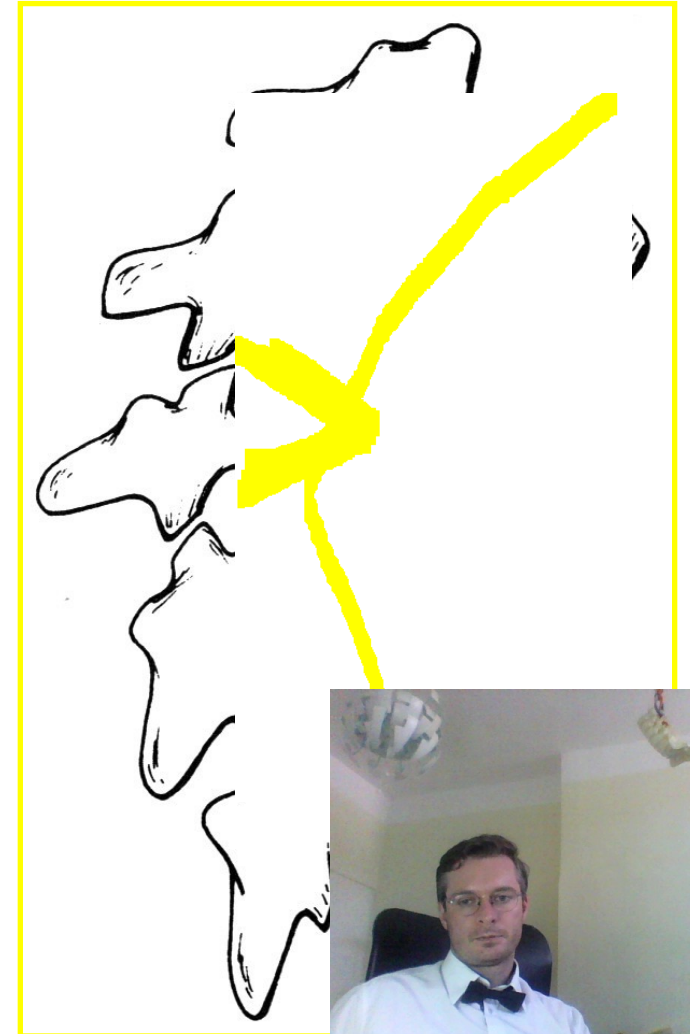
Solitary or multiple changes

„posterior hemivertebra“

-> kyphosis


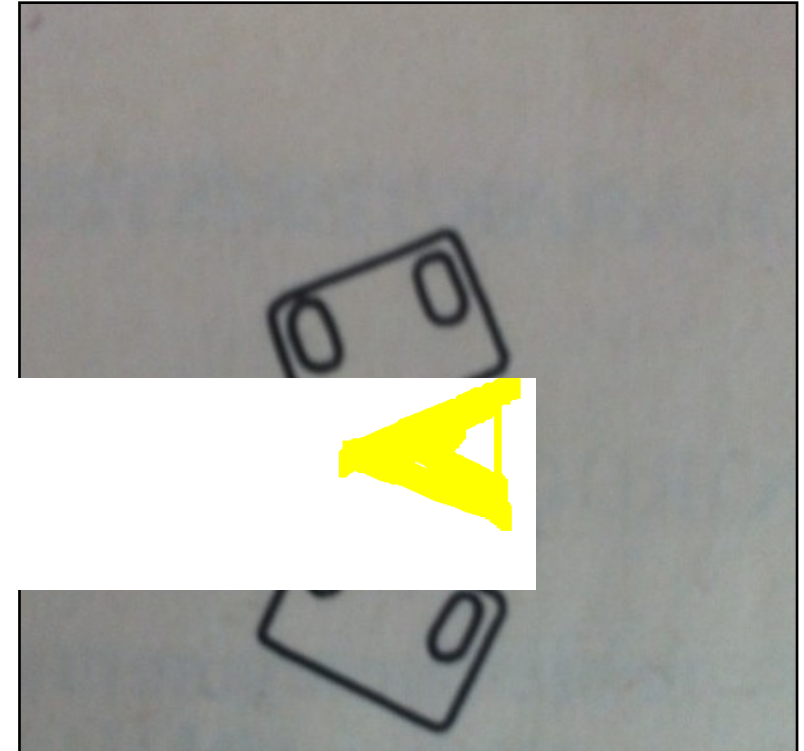

- posterior – much less common

- > lordosis



Failure of formation


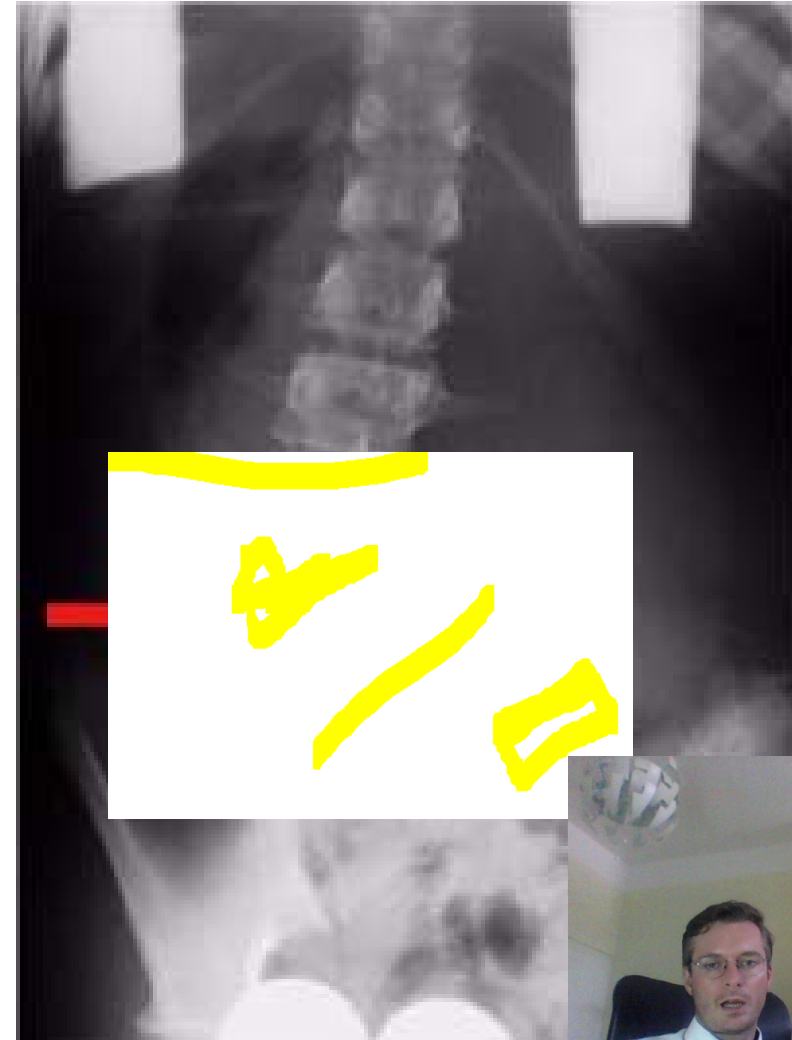
- Lateral
 - Hemivertebra
- > scoliosis deformity



Failure of formation


Postižení solitární až mnohočetné

Postižení sousedních obratlů nebo
v různých úsecích páteře




Hemivertebra types

closed type / neuzavřený poloobratel



bez progrese / progrese deformity




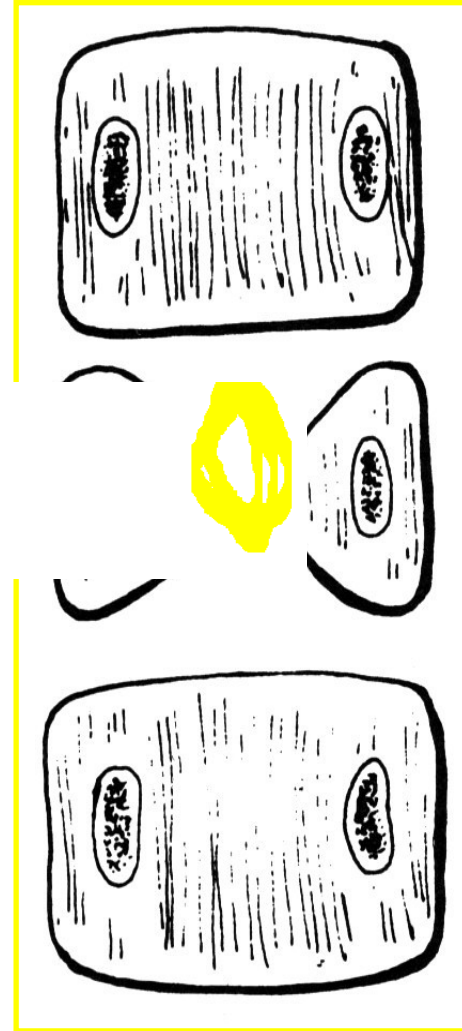
Failure of formation

- Anterior central defect

The two parts of vert. are not connected together



- According to severity of the anterior defect can lead to kyphosis or is completely asymptomatic

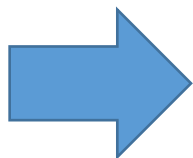


Combined failure


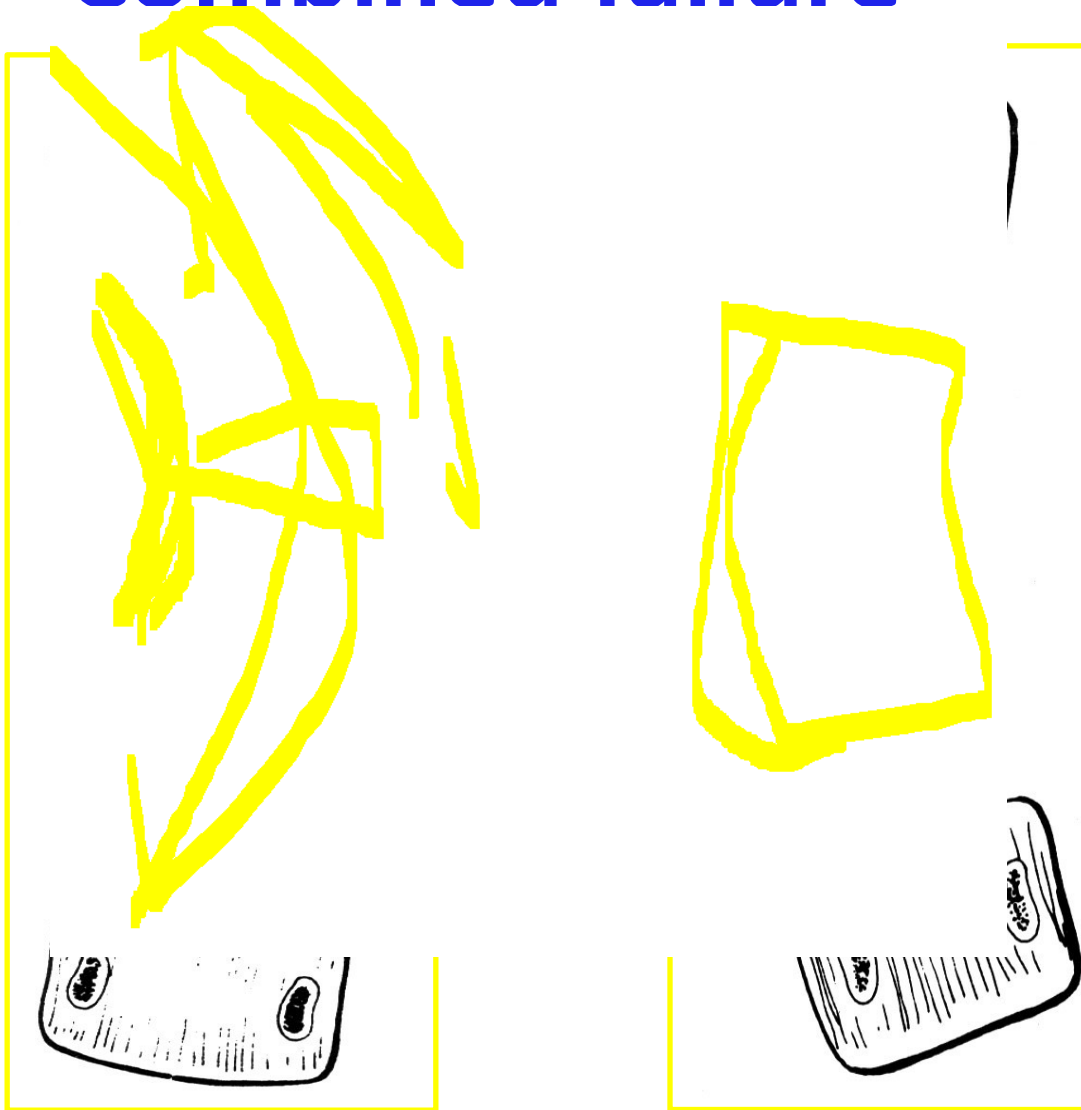
- Very common
- Multiple changes
- Very individual
- Hard to predict progression in multiple changes, observation is the key.


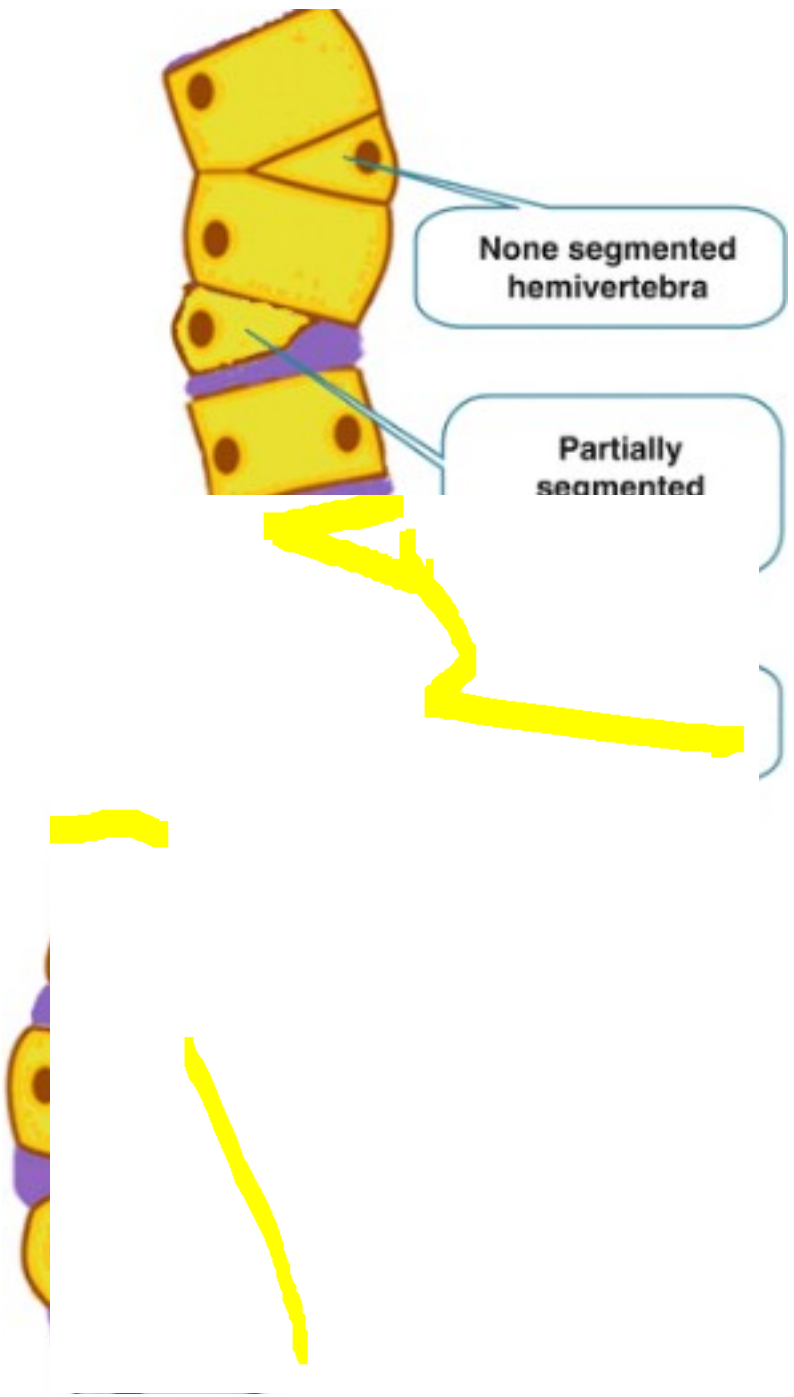


The highest risk of progression = Fully segmented hemivertebra + contralateral unsegmented bar !!



Combined failure





Congenital scoliosis - therapy

Main rule – STOP the progression !


Observation – X-ray á 6months

if there is progression of deformity -> surgery


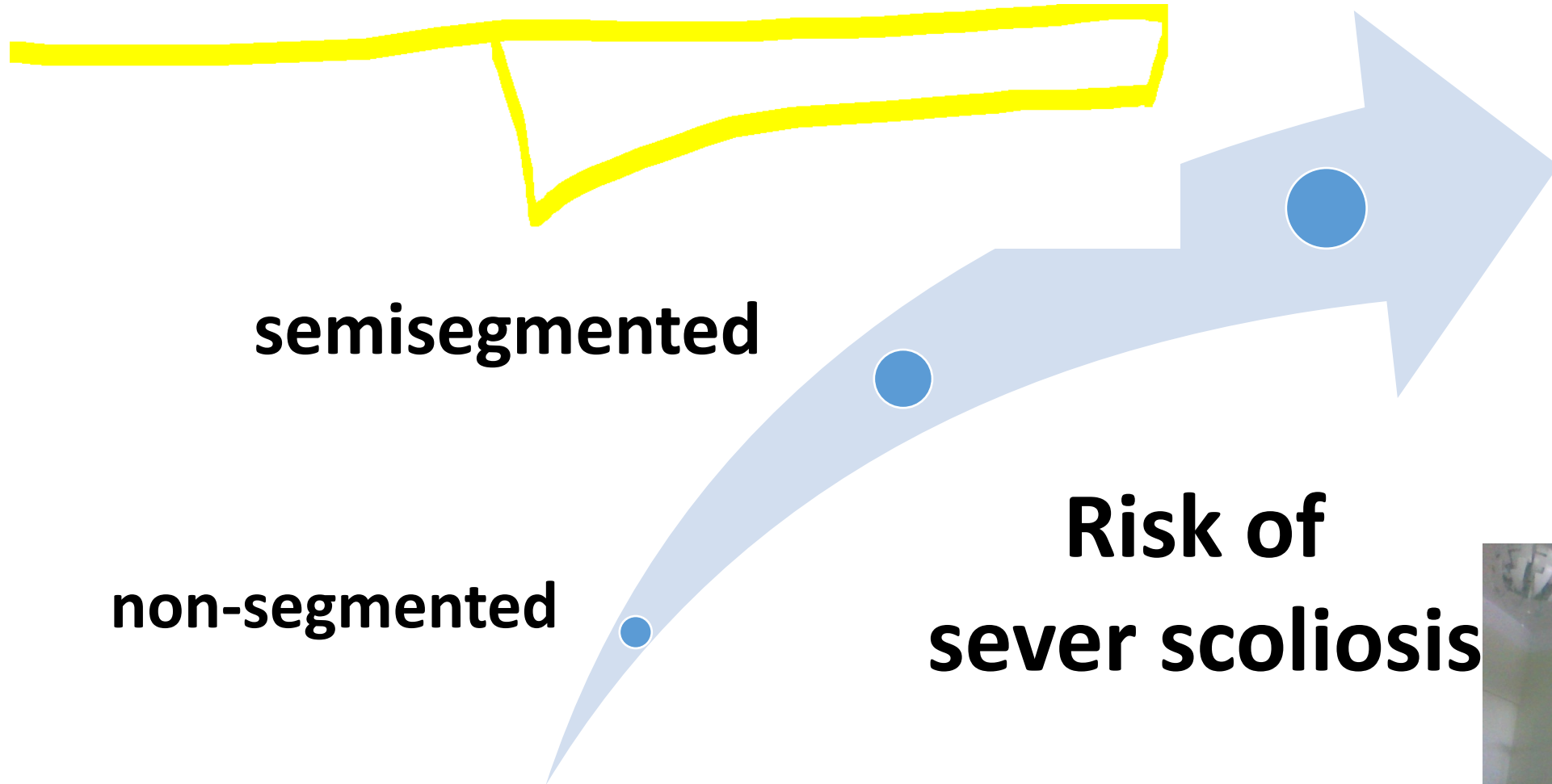
fastest growth– frist 5y of age

+ adolescent growth spurt


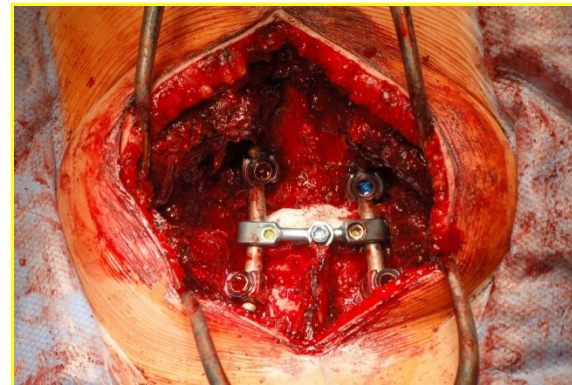
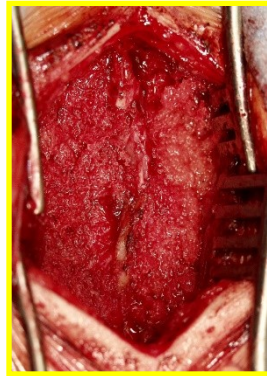
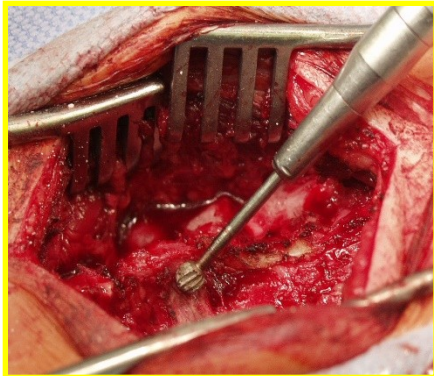
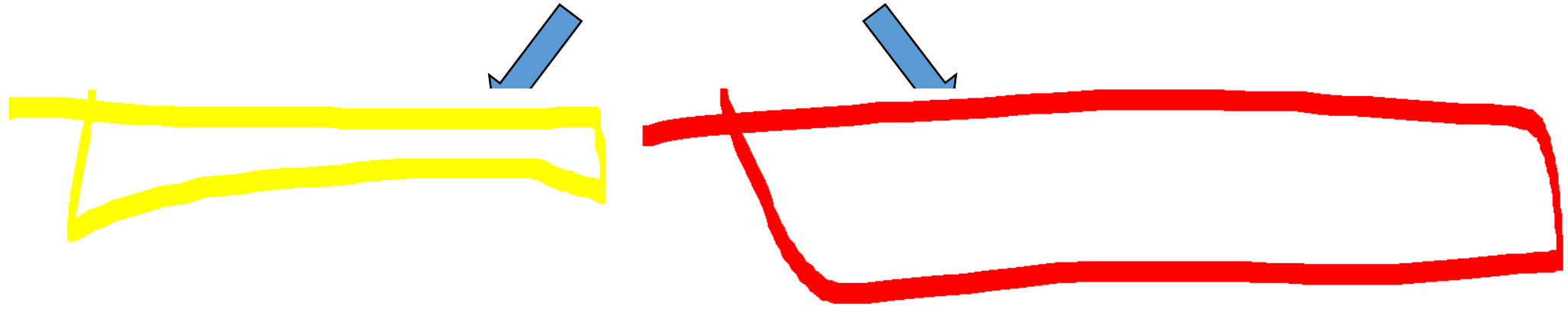
-> highest risk of progression !!!



Hemivertebra

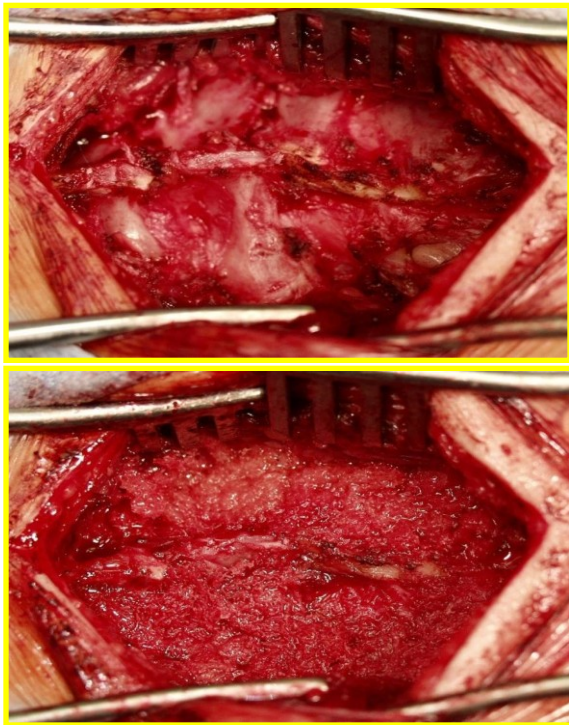


2 main used surgical techniques



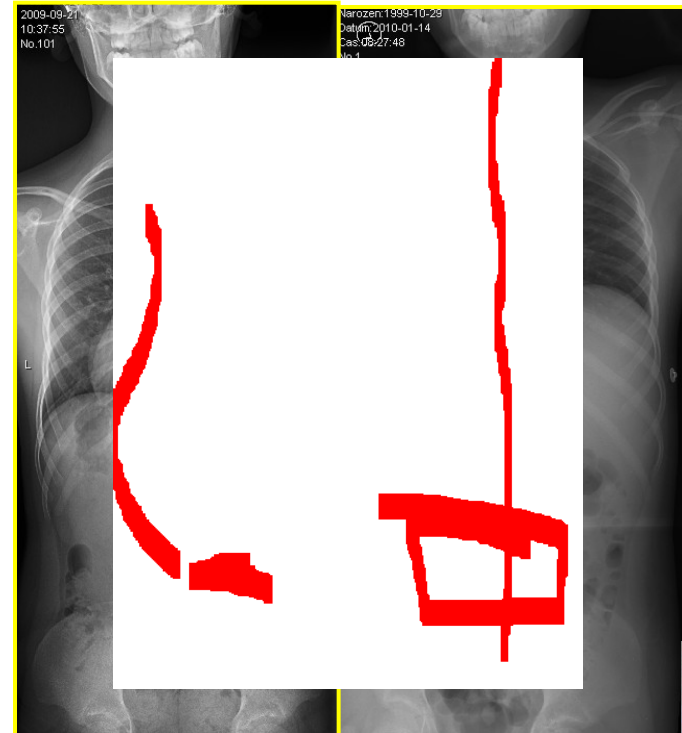
Surgery of hemivertebra

Simple fusion




- Small deformities
- Blockage of worsening
- Without correction possibility

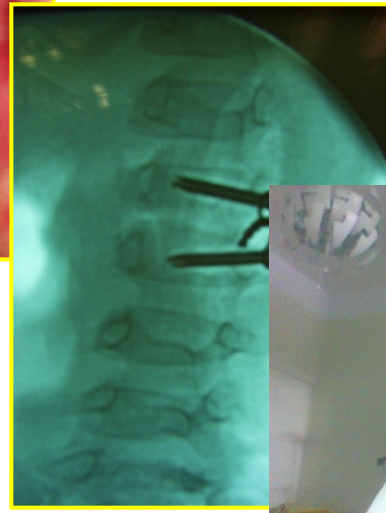
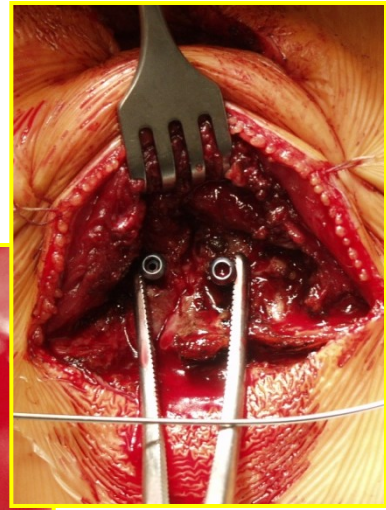

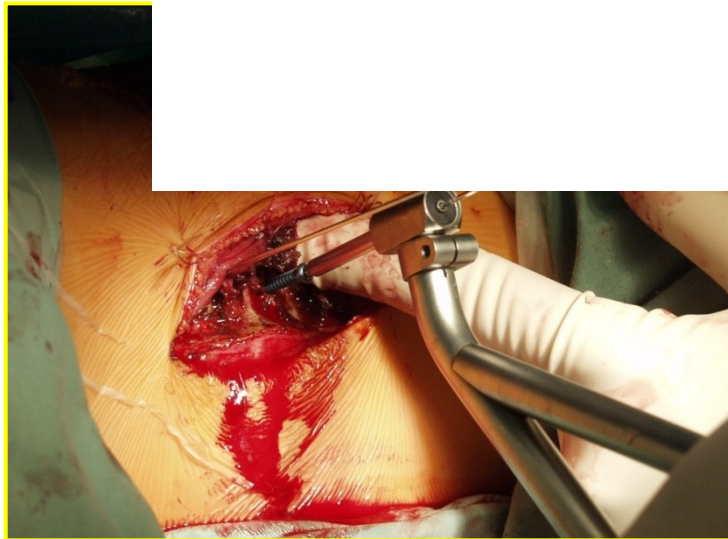
Hemivertebrectomy

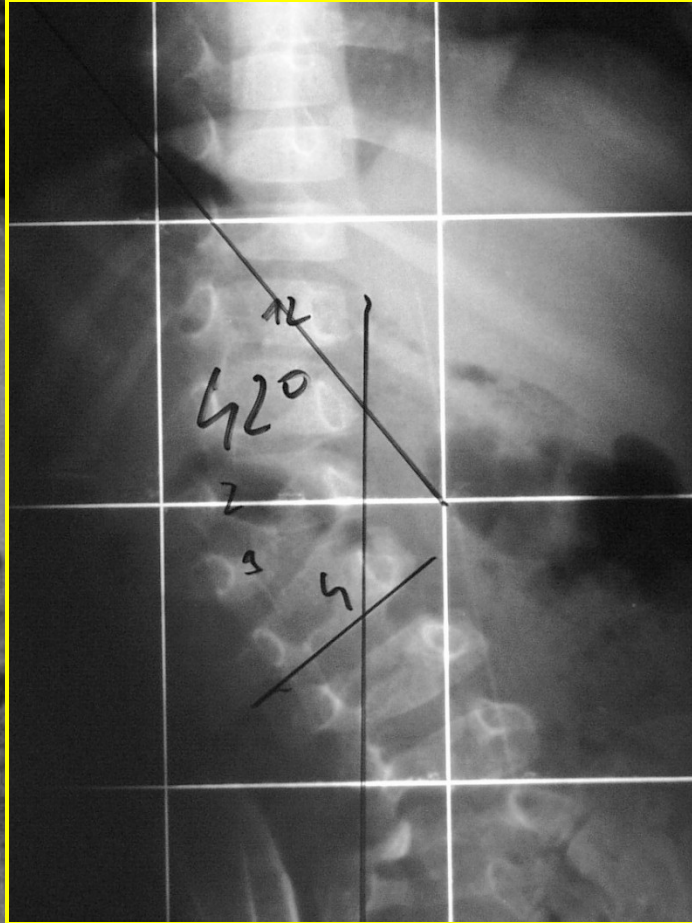
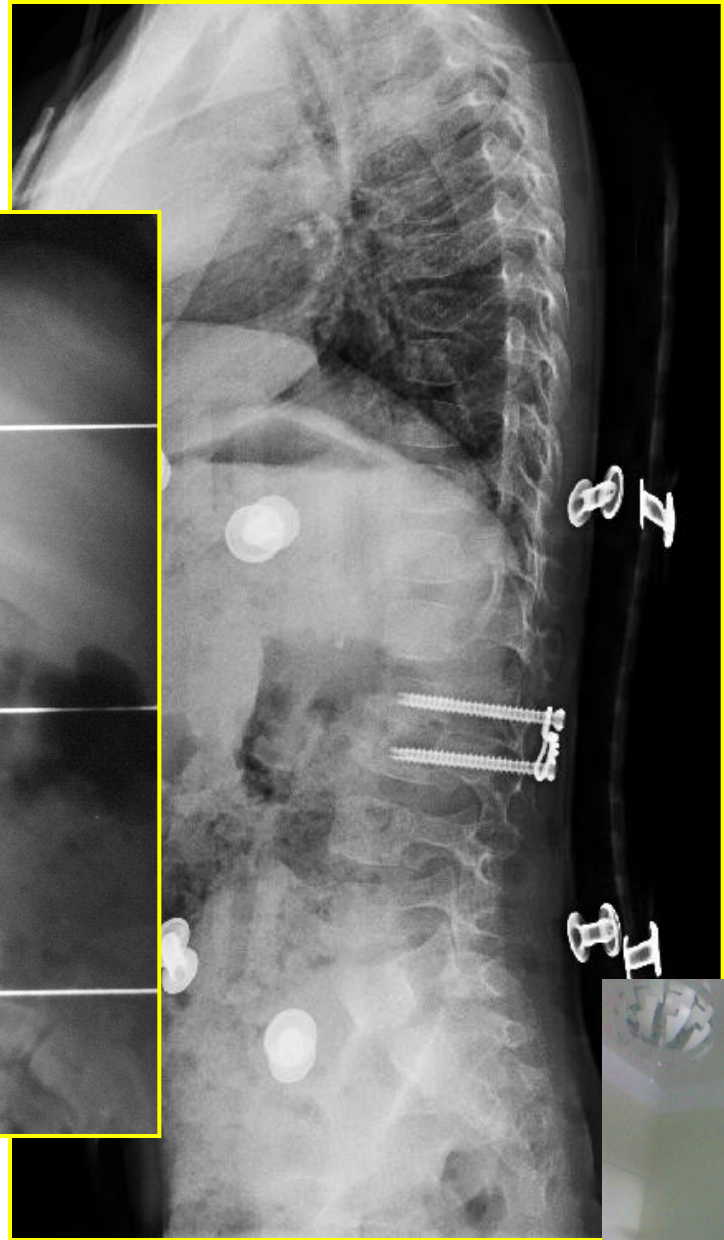
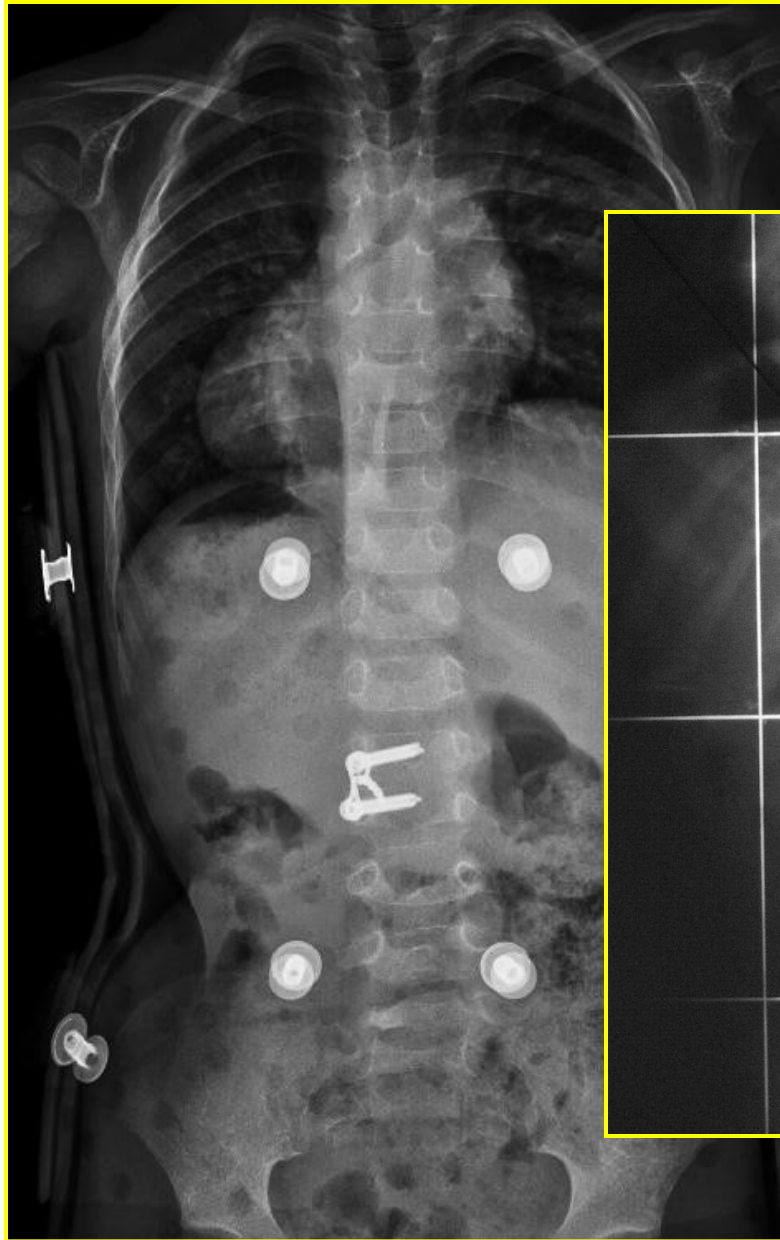


- Larger deformities
- Curve correction
- Prevention of secondary curves


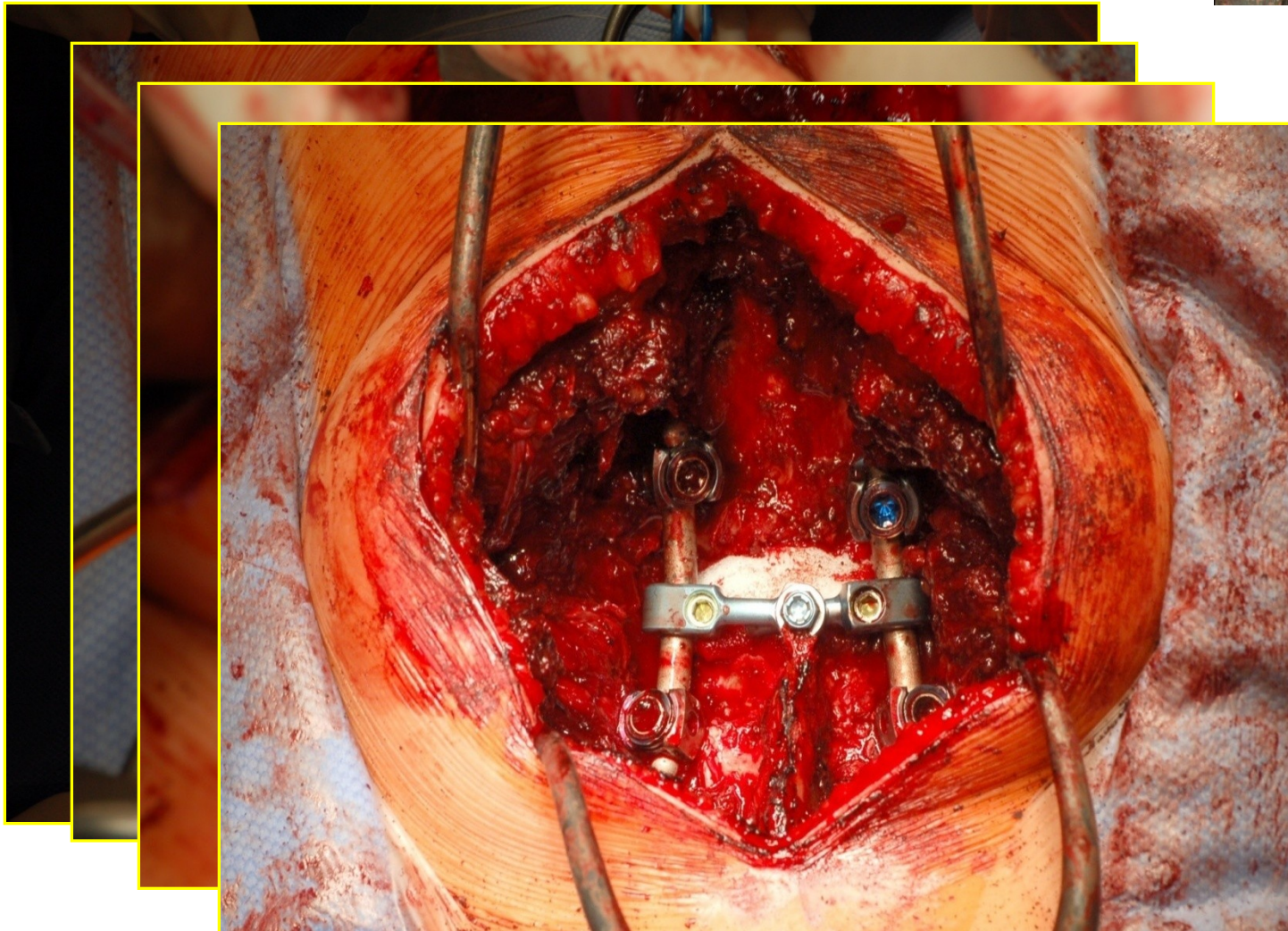

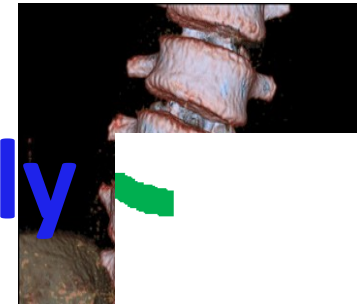
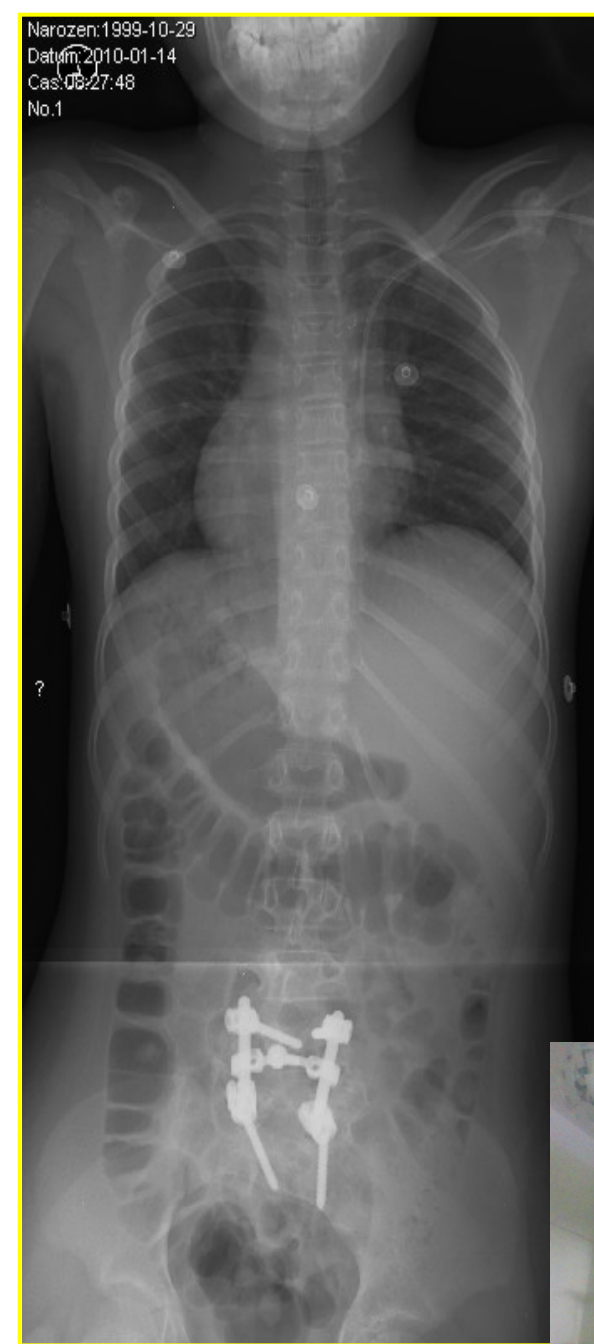

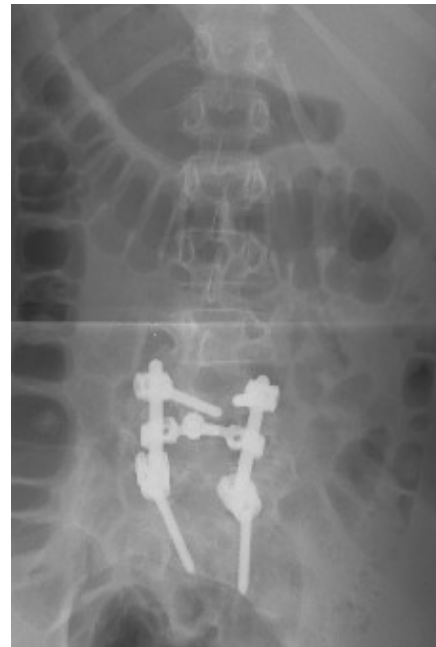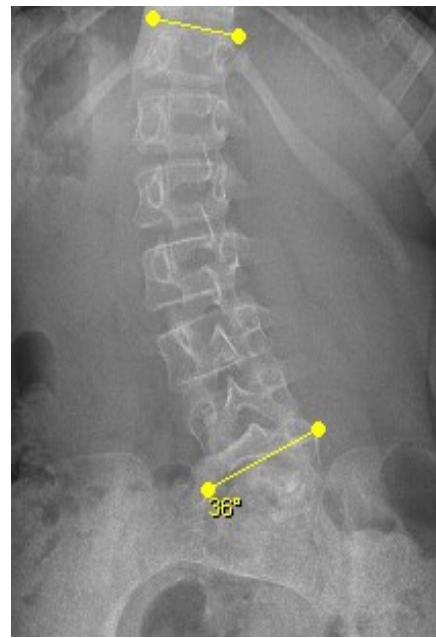
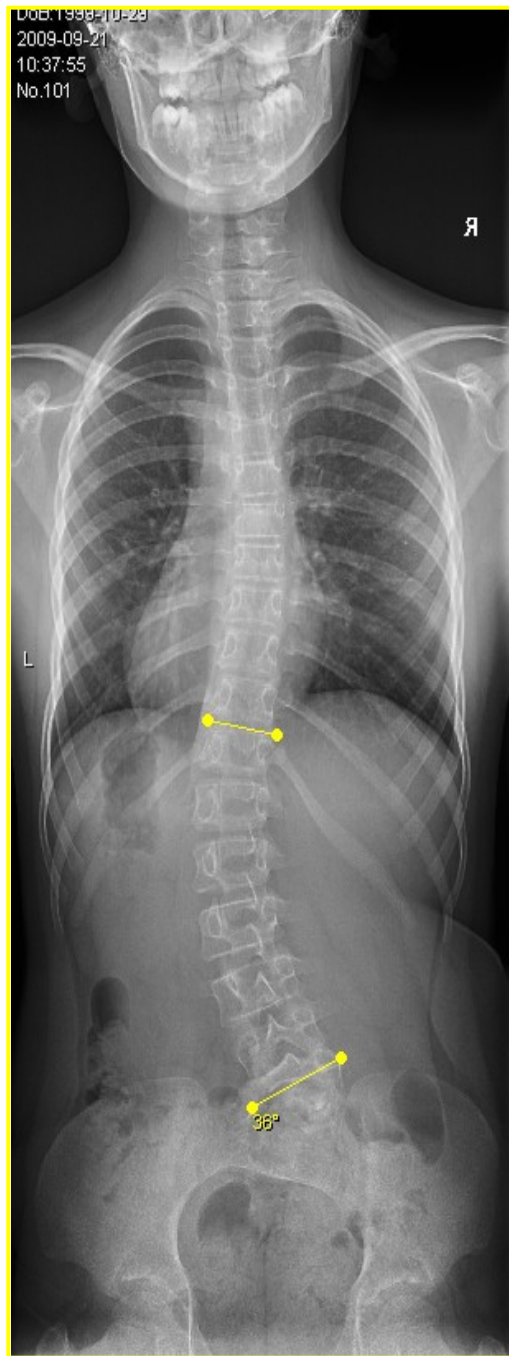
Hemivertebrectomy combined approach





Hemivertebrectomy posterior approach only





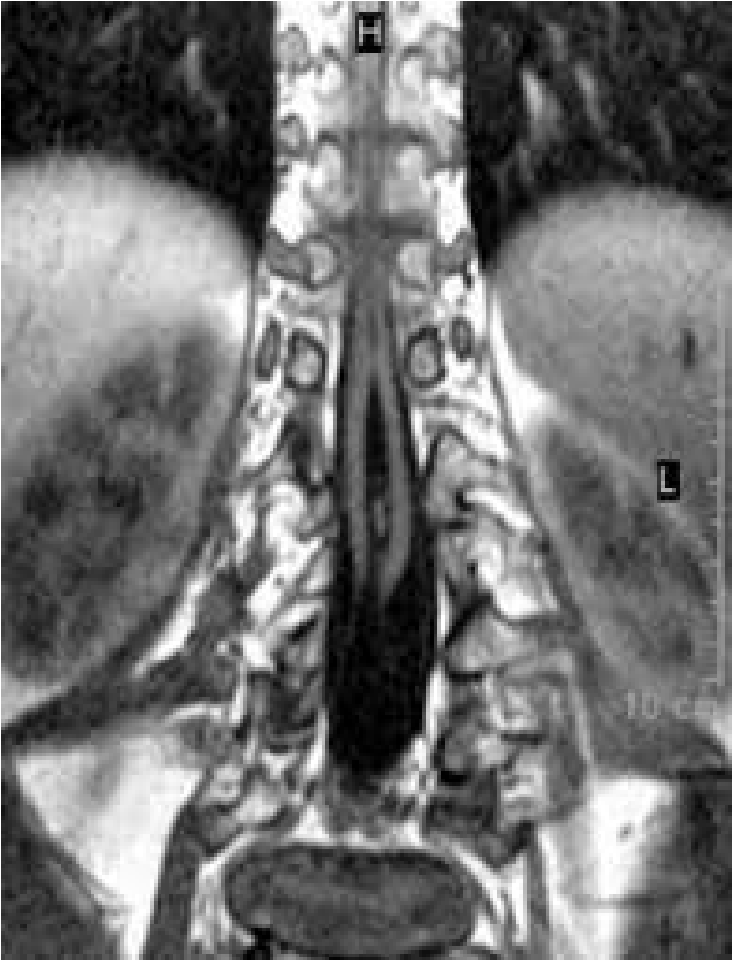
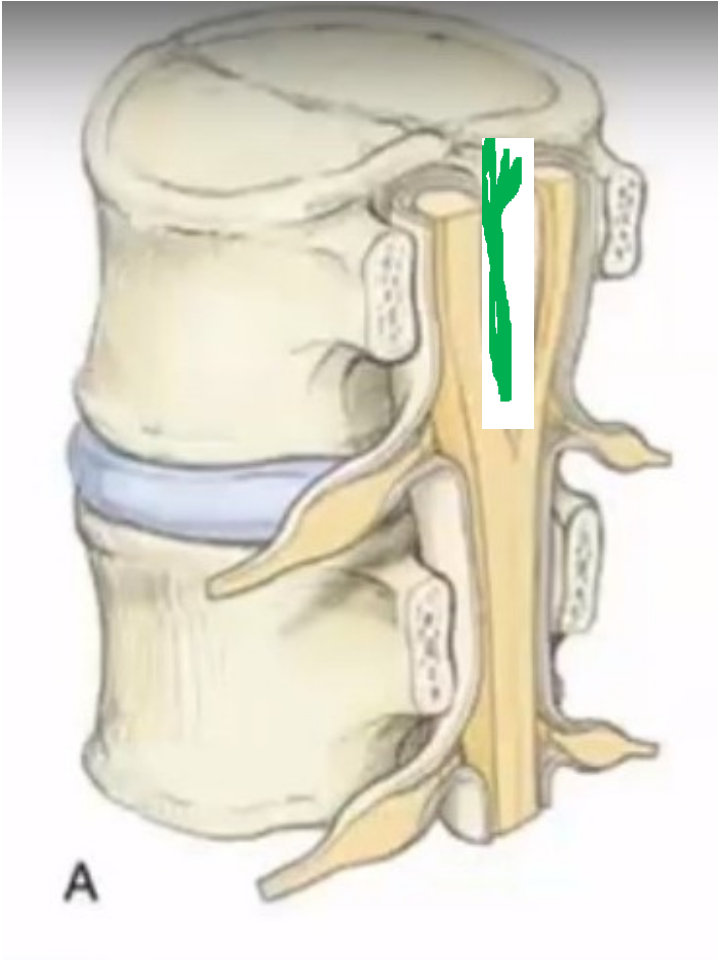
Conclusion

The main factors of successful treatment of congenital scoliosis

- **early detection**
- **good timing**
- **adequate surgical approach**

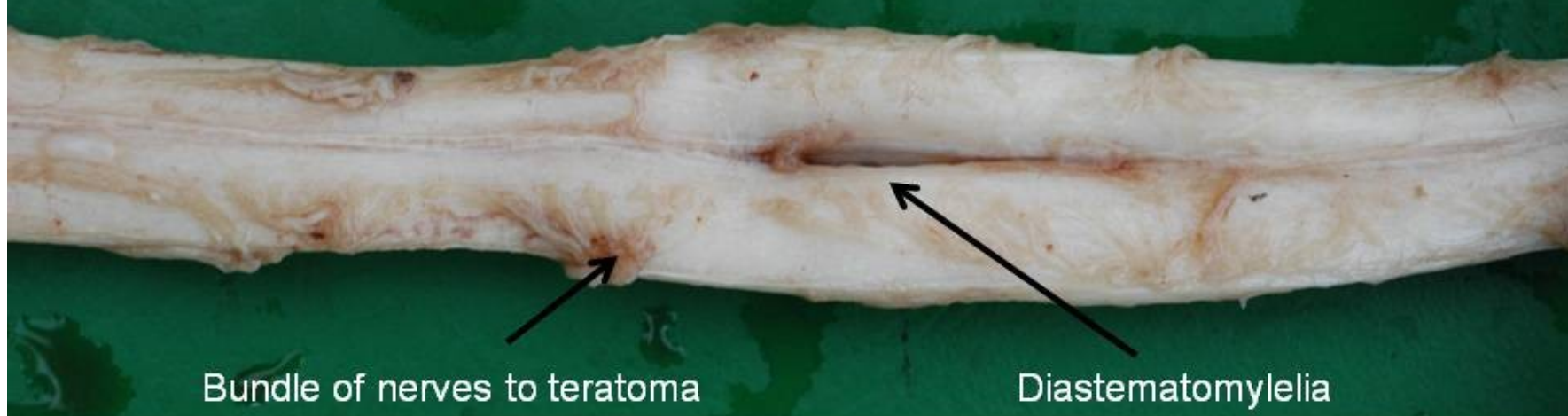

Diastematomyelie




Ski, M

Thoracolumbar Spinal Cord


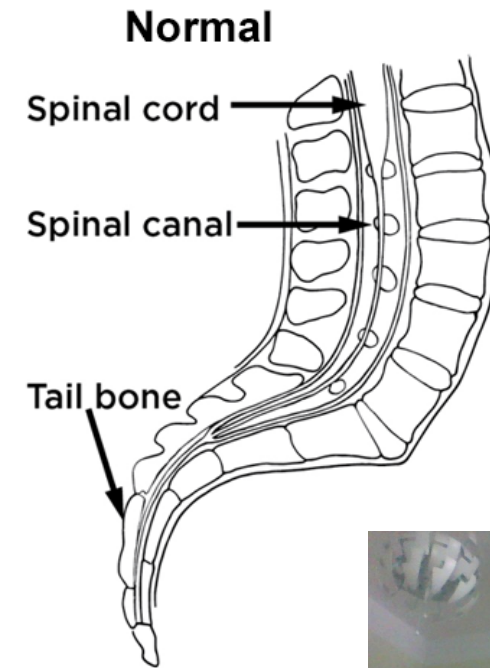
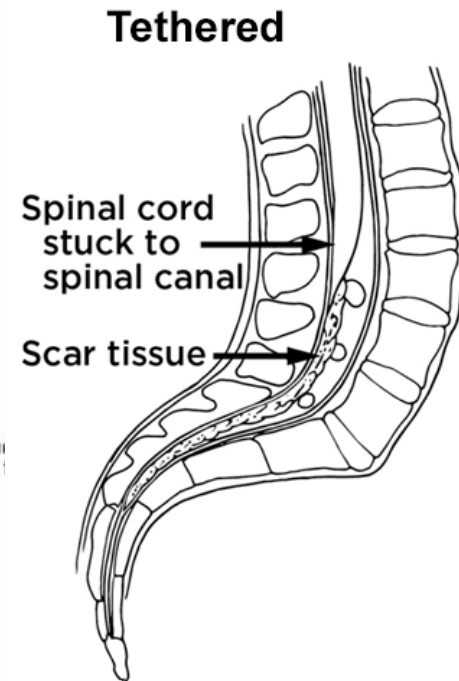
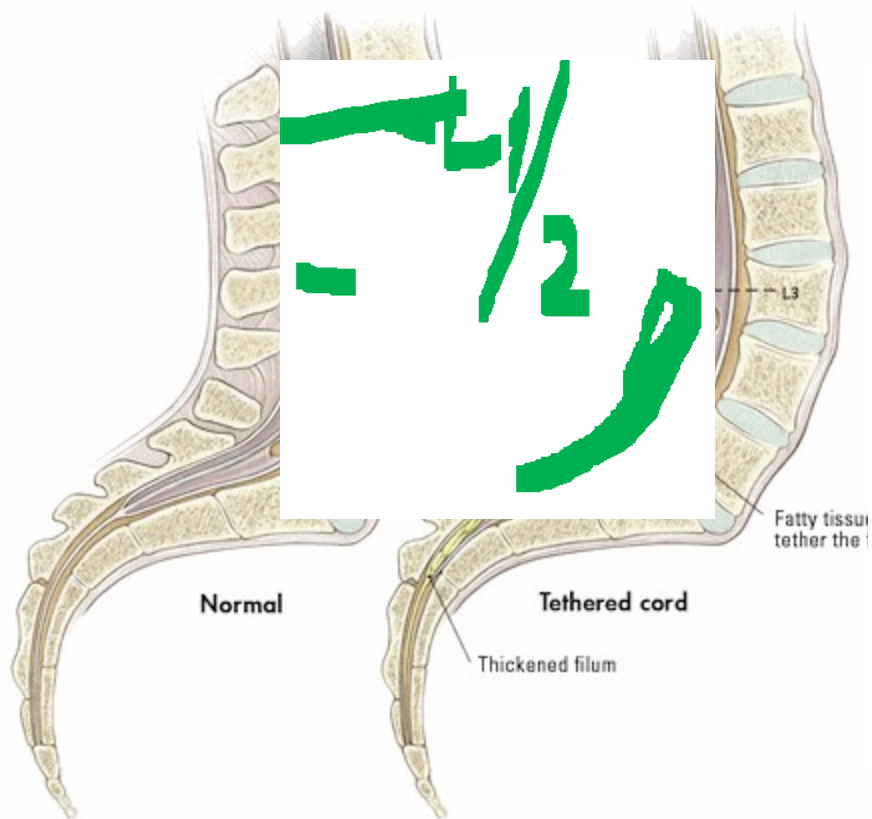


Bundle of nerves to teratoma


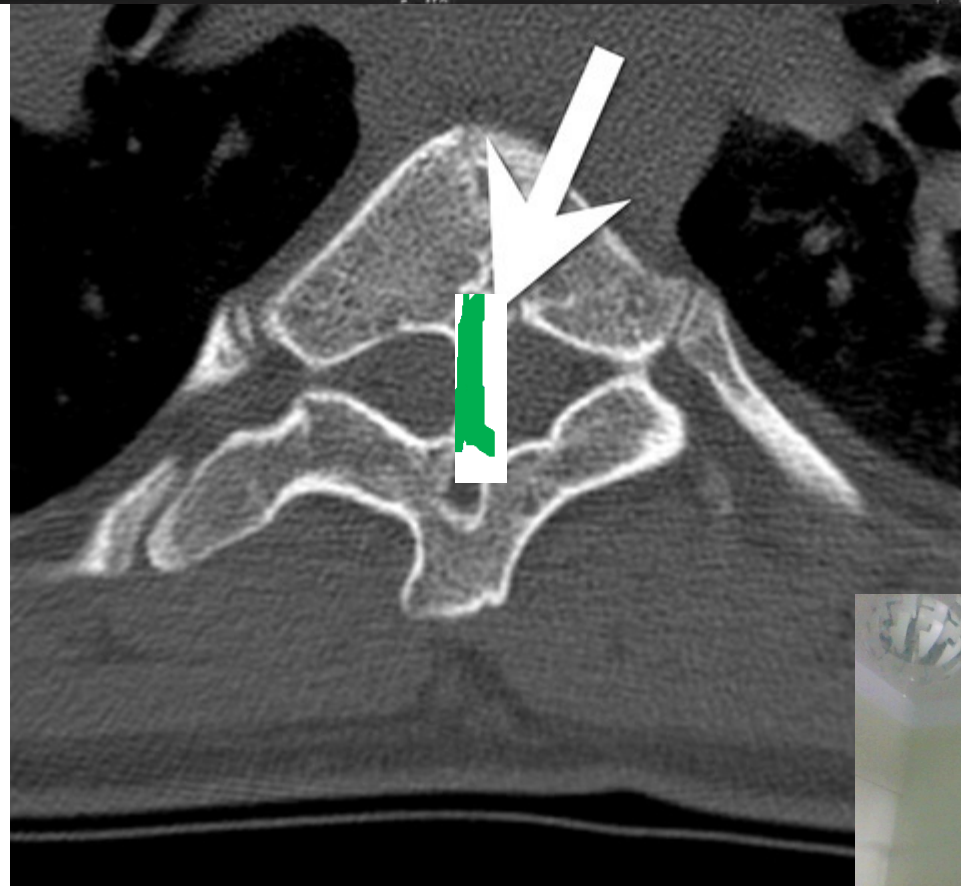
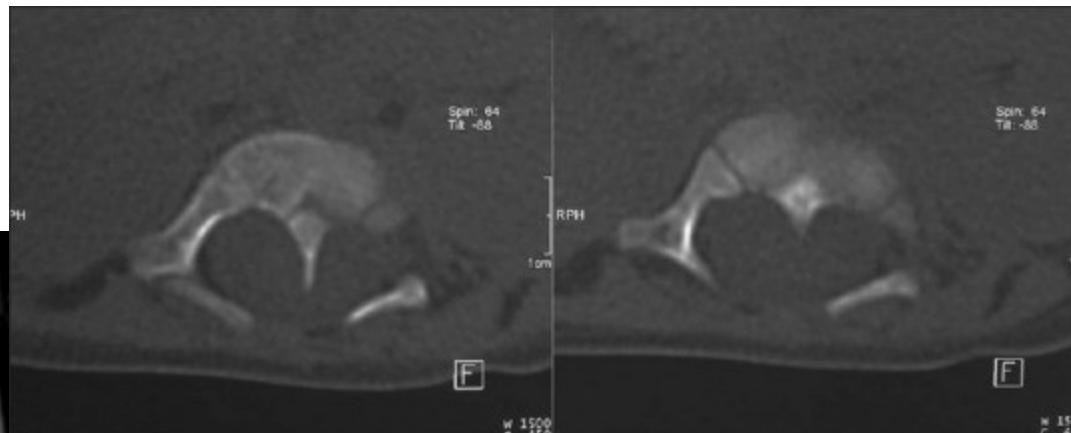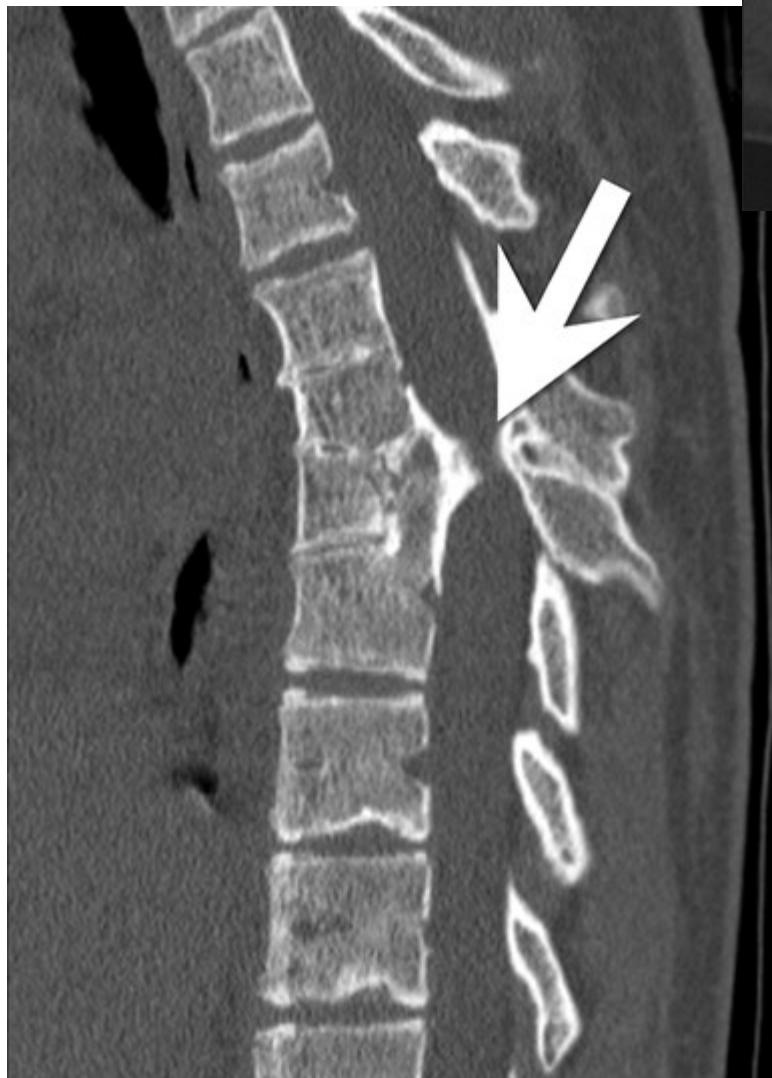
Diastematomyelia




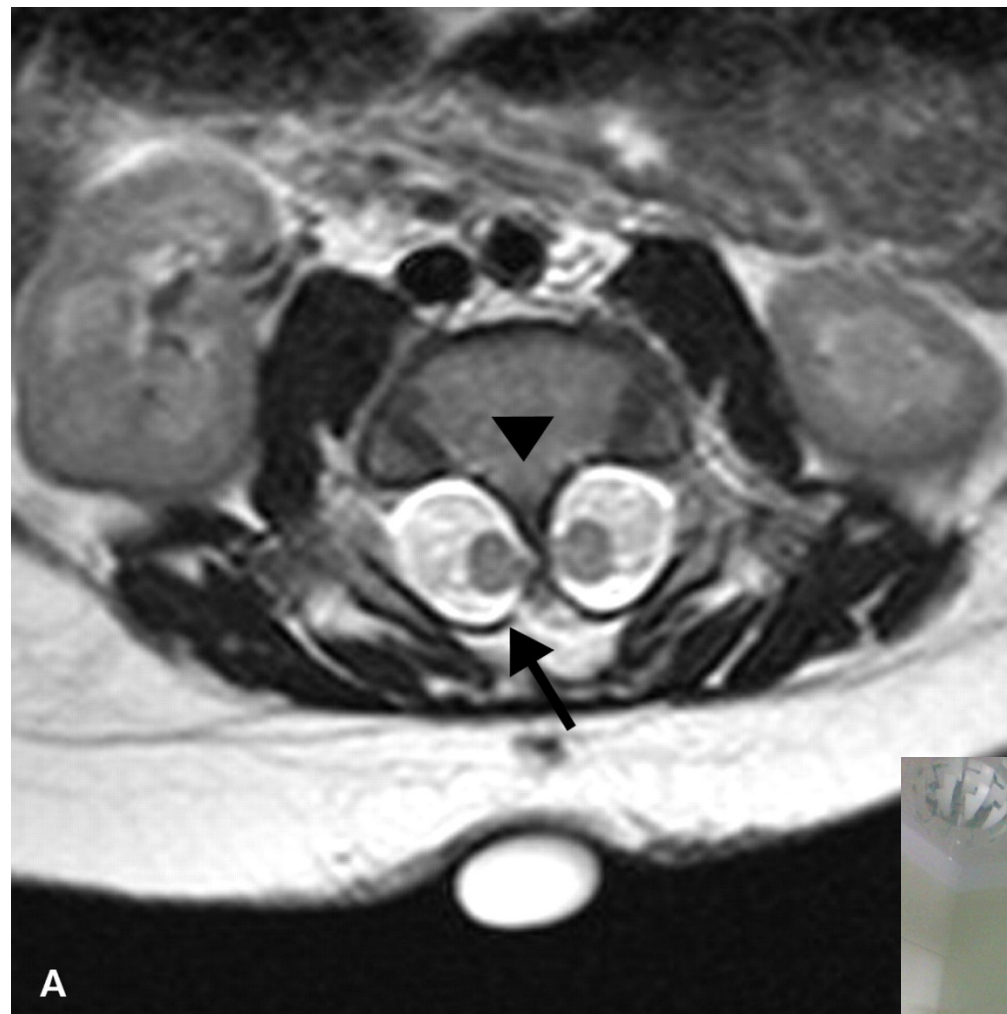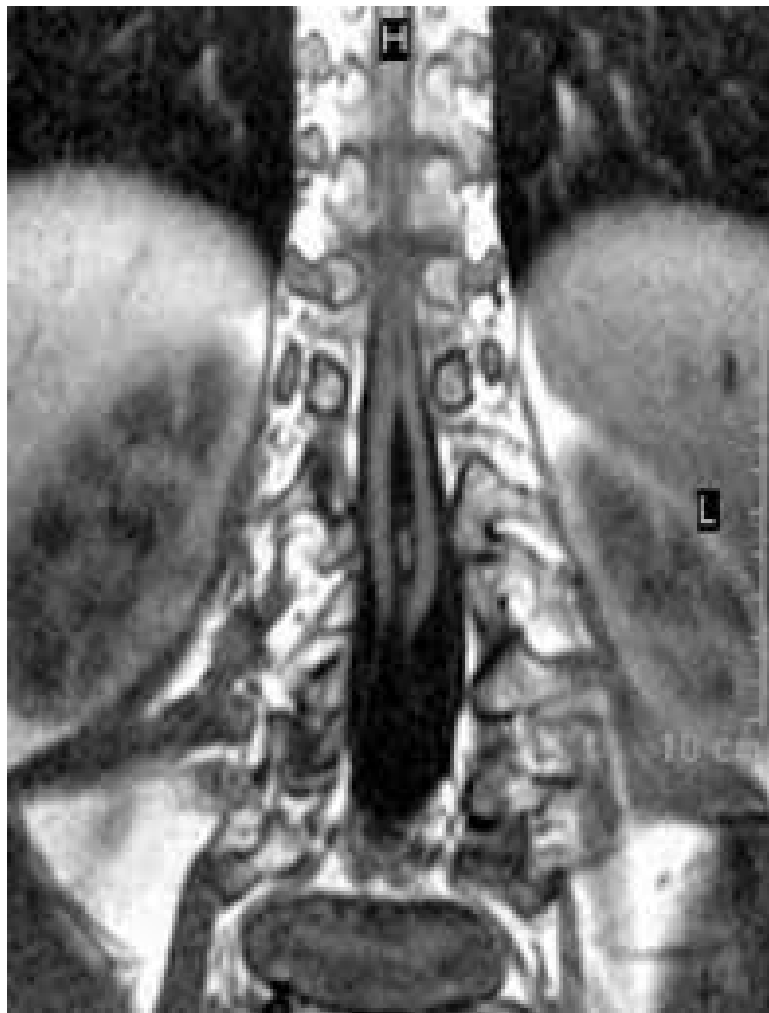
Tethered cord syndrome



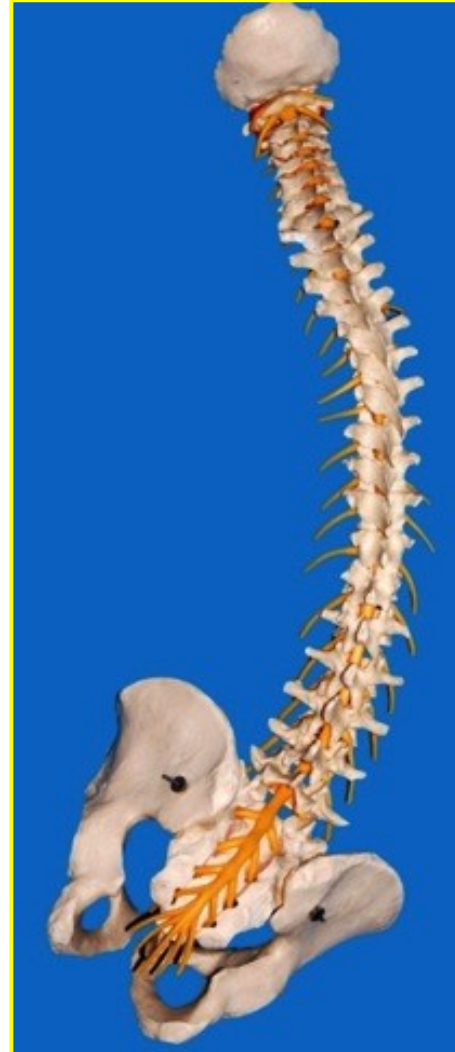
CT



MRI



Neuromuscular scoliosis



Scoliosis types due to ethiology

Deformity type	Age
• Idiopathic	• Infantile < 3 y
• Congenital	• Juvenile 4-10 y
• <u>Neuromuscular</u>	• Adolescent 11-17 y • Adult > 17 y



Neuromuscular scoliosis

- Significant progression (even after growth)


- severe deformities
- combined with pelvic and hip deformities
- high degree of associated dysfunction

-  y




- 

- 


- osteoporosis



Conservative treatment



Léčebné postupy

1. Conservative treatment


disadvantages :

- [redacted]
- [redacted]
- [redacted]
- [redacted]

2. surgery


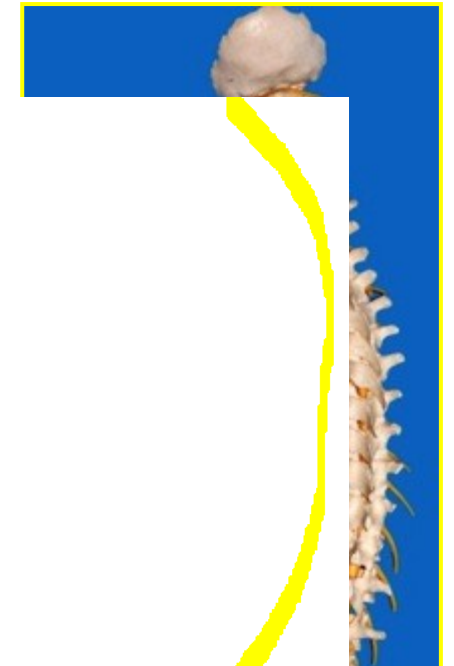

indication:

- [redacted]
- [redacted]
- back pain
- the tendency to pressure sores

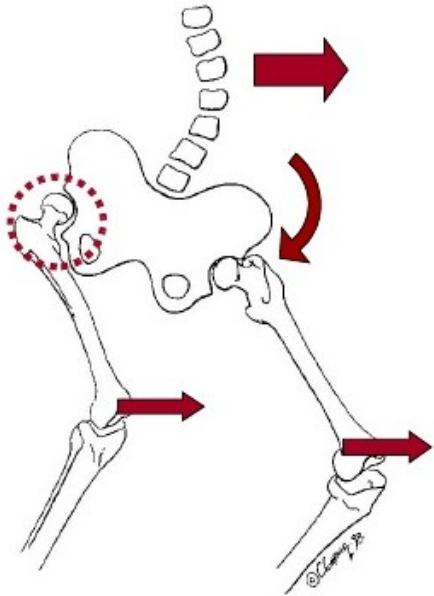


Neuromuscular spine deformity = complex deformity

- Long thoracolumbar dx convex curve
- kyphoscoliosis
- hyperlordosis
- Hip anomaly
- Pelvic obliquity



Postural Management



- Scolio
- Pelvic
- Winds
- Hip Di

Madigan & Wa



Letts et al 198

Lonstein & Be

Young et al 1998

(29 participants)

(26 participants)



Basic NM scoliosis types



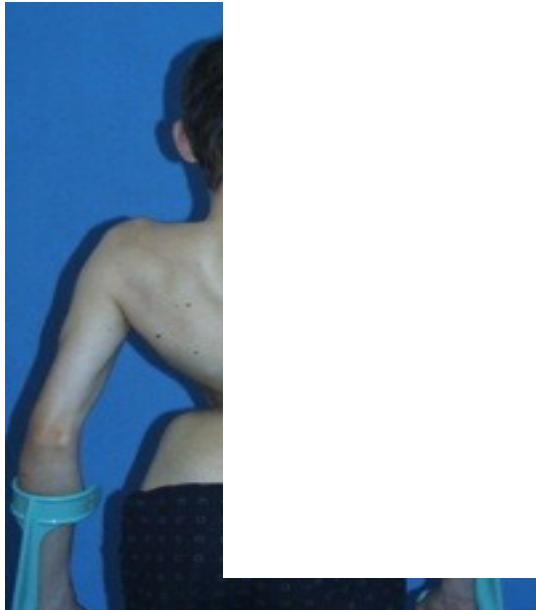

SPASTIC

FLACCID

- brain

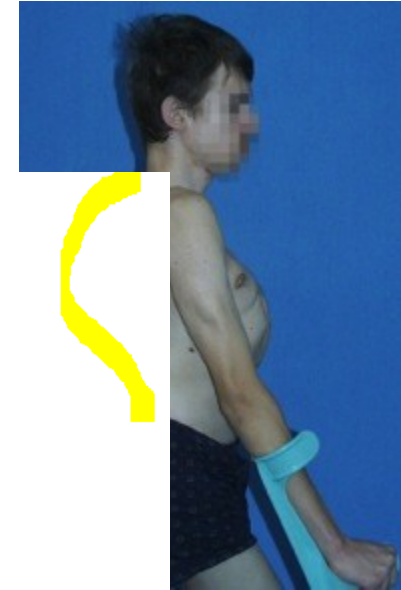
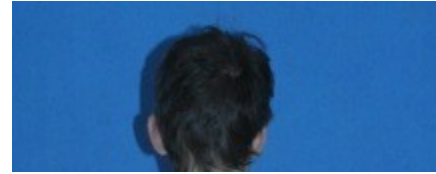-

-

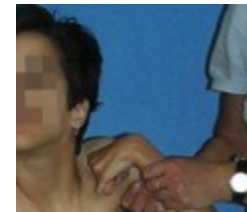



NM spine deformities

1. Spastic forms

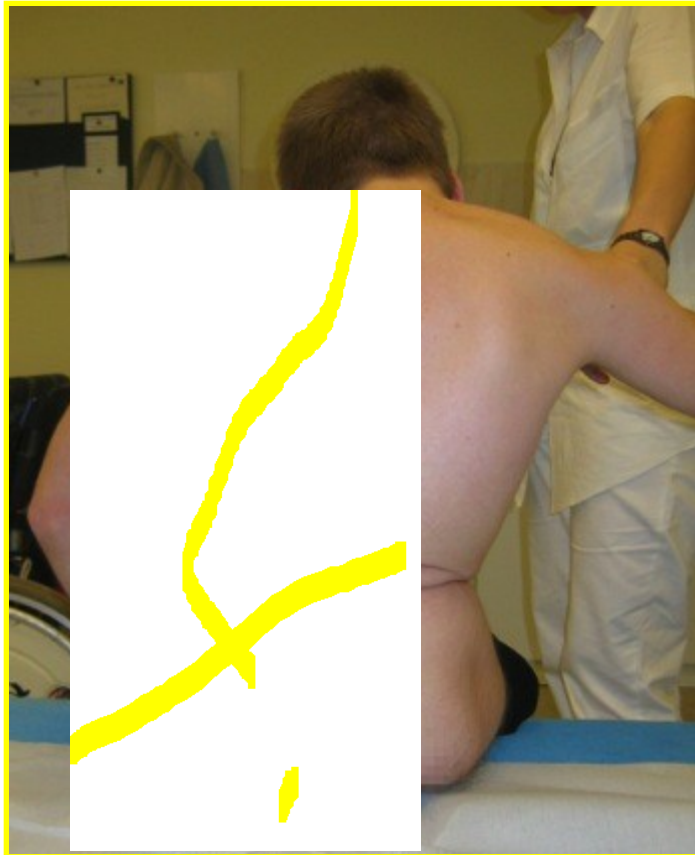


2.f

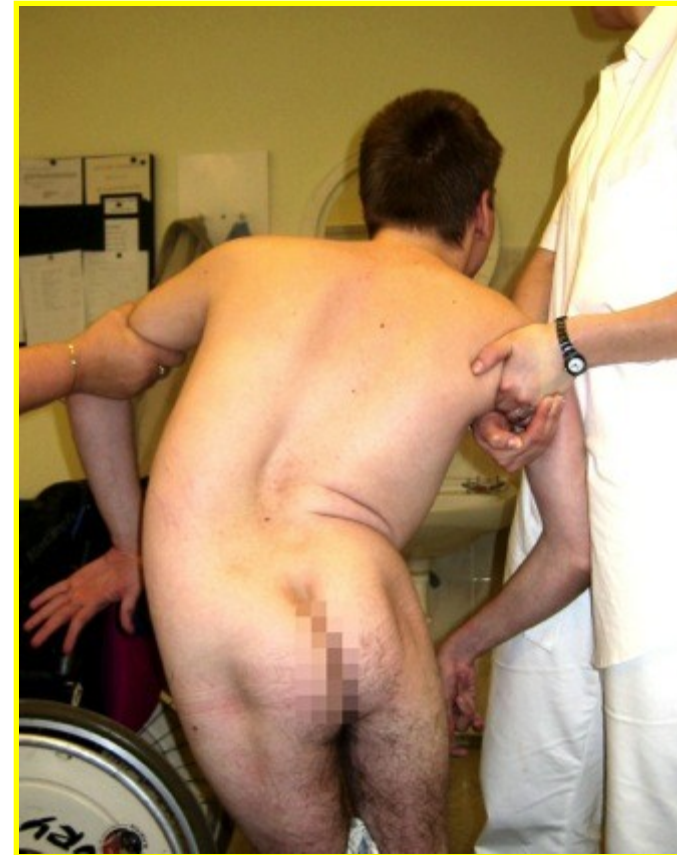


NM spine deformities

Sitting instability




Standing instability



Clinical examination of NM deformities

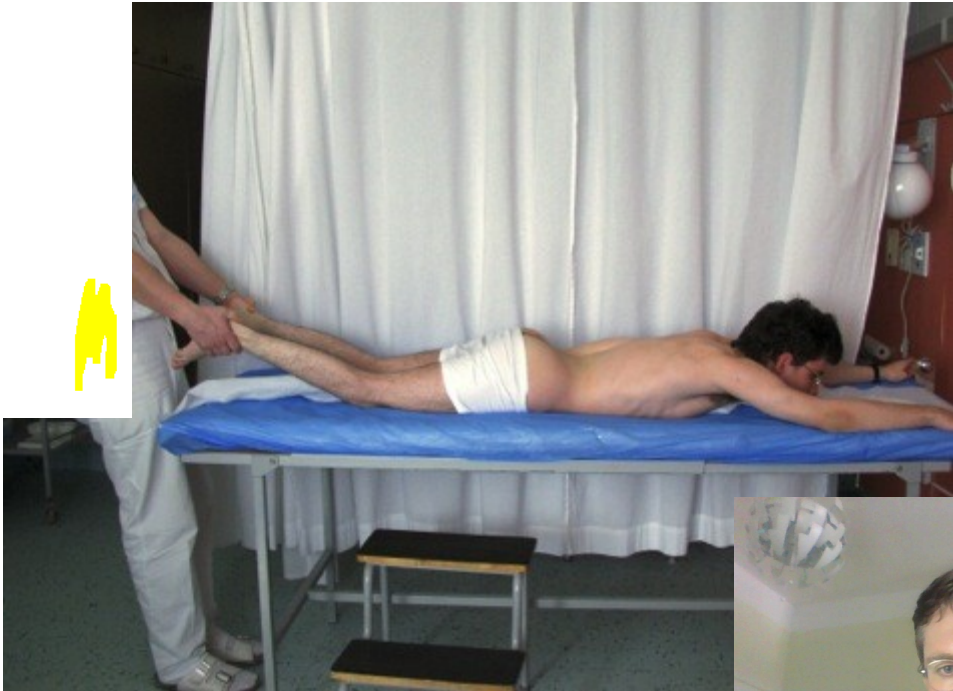Gibbus



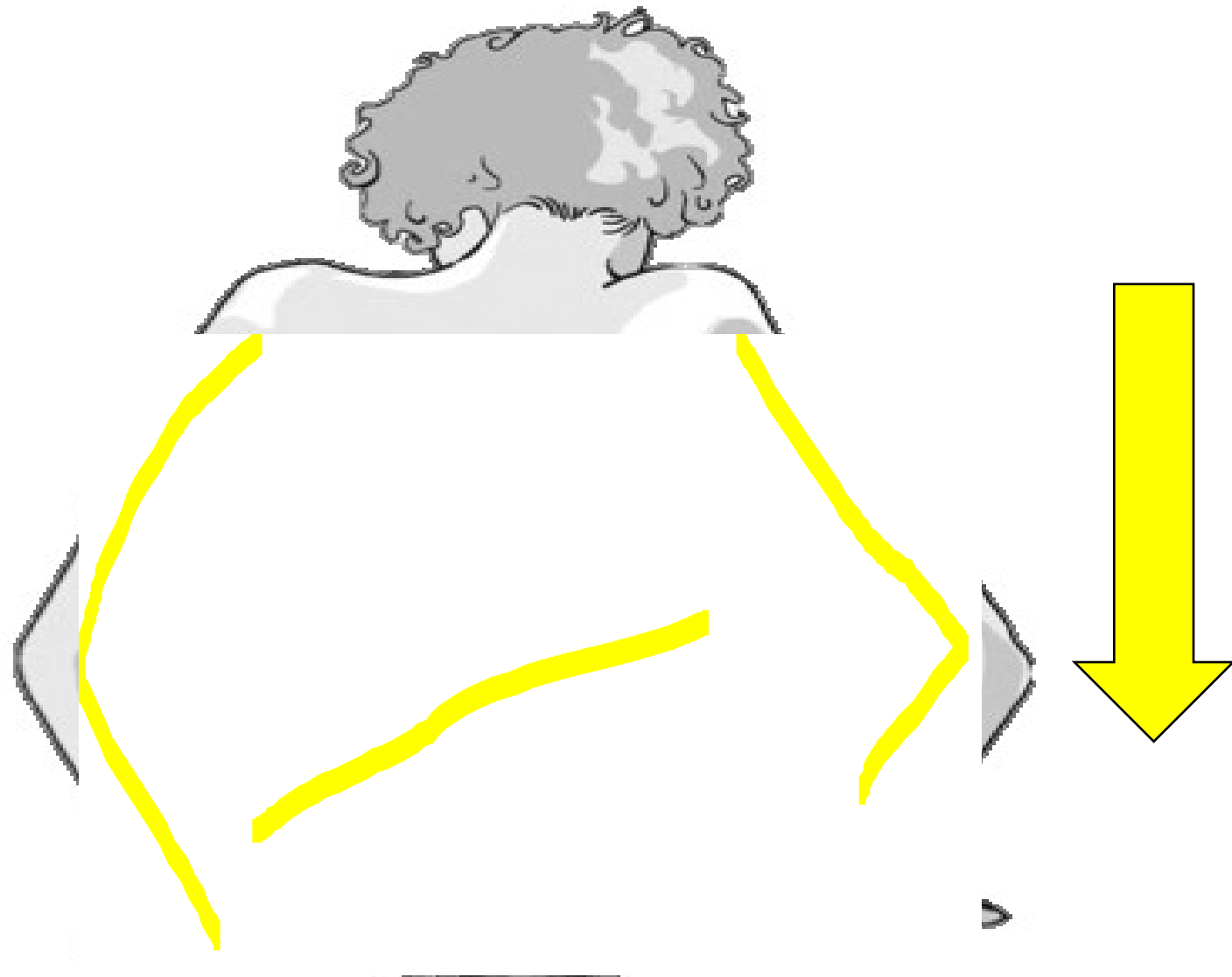
Blump



Correction in traction



FLACCID deformity



gravity

Trunk co



TYPES

A. Neuropathic

I. upper motoneuron failure

- cerebral palsy

n
(Huntington-Horsley syndrome)

- syringomyelia

- spinal tumors

- spinal cord injury



A. Neuropathic

II. lower motoneuron failure

- Poliomyelitis


[Redacted]

- [Redacted]

- [Redacted]

- [Redacted] ar atrophy

Werdnig-Hoffman, Kugelberger-Welander



B . Myopathic curves



- (fascioscapulohumeral syndrome, belt-girdle syndrome)
- fiber type disproportion syndrome
- congenital hypotonia
- dystrophic myotonia



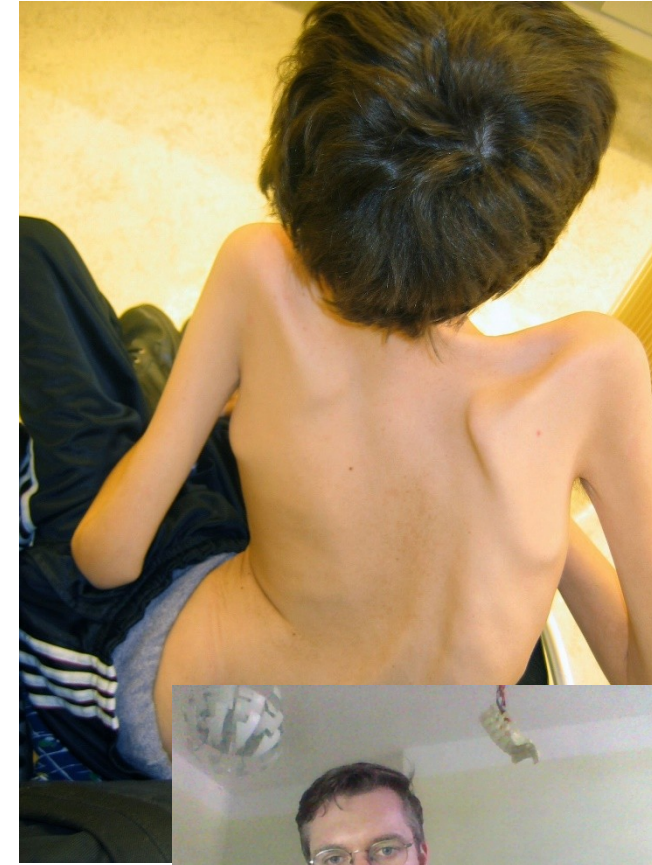SMA Infantile

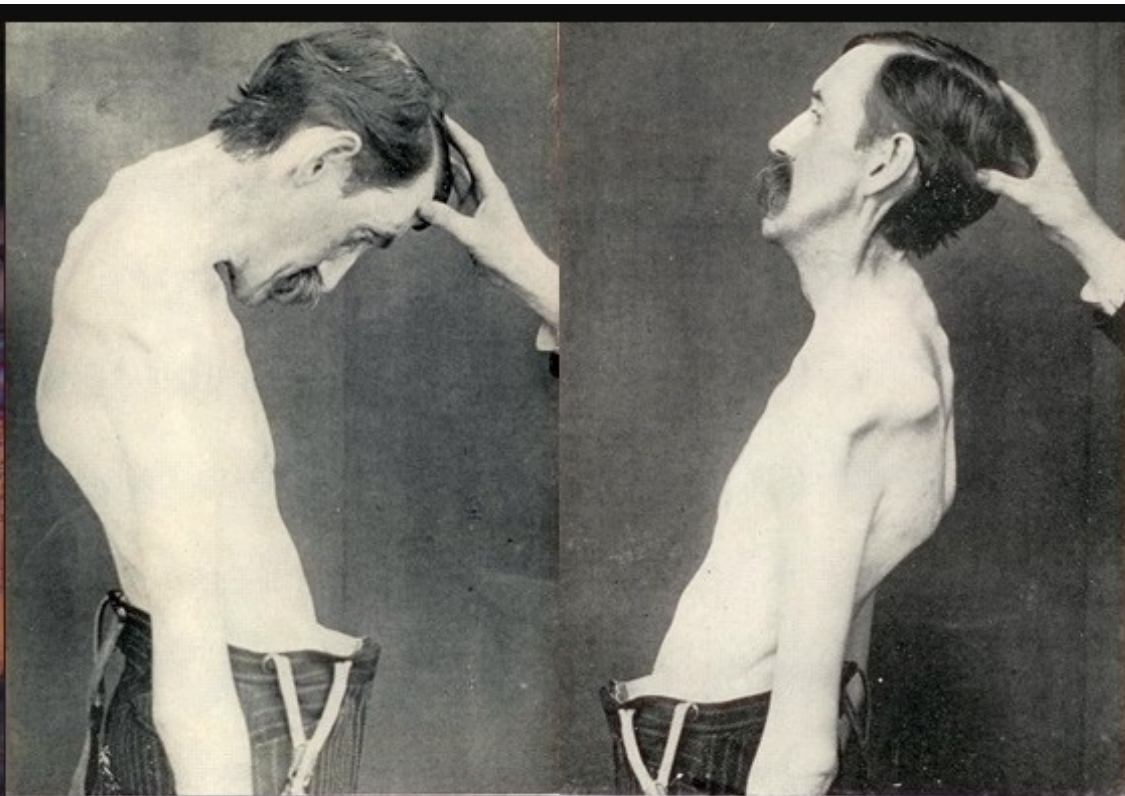
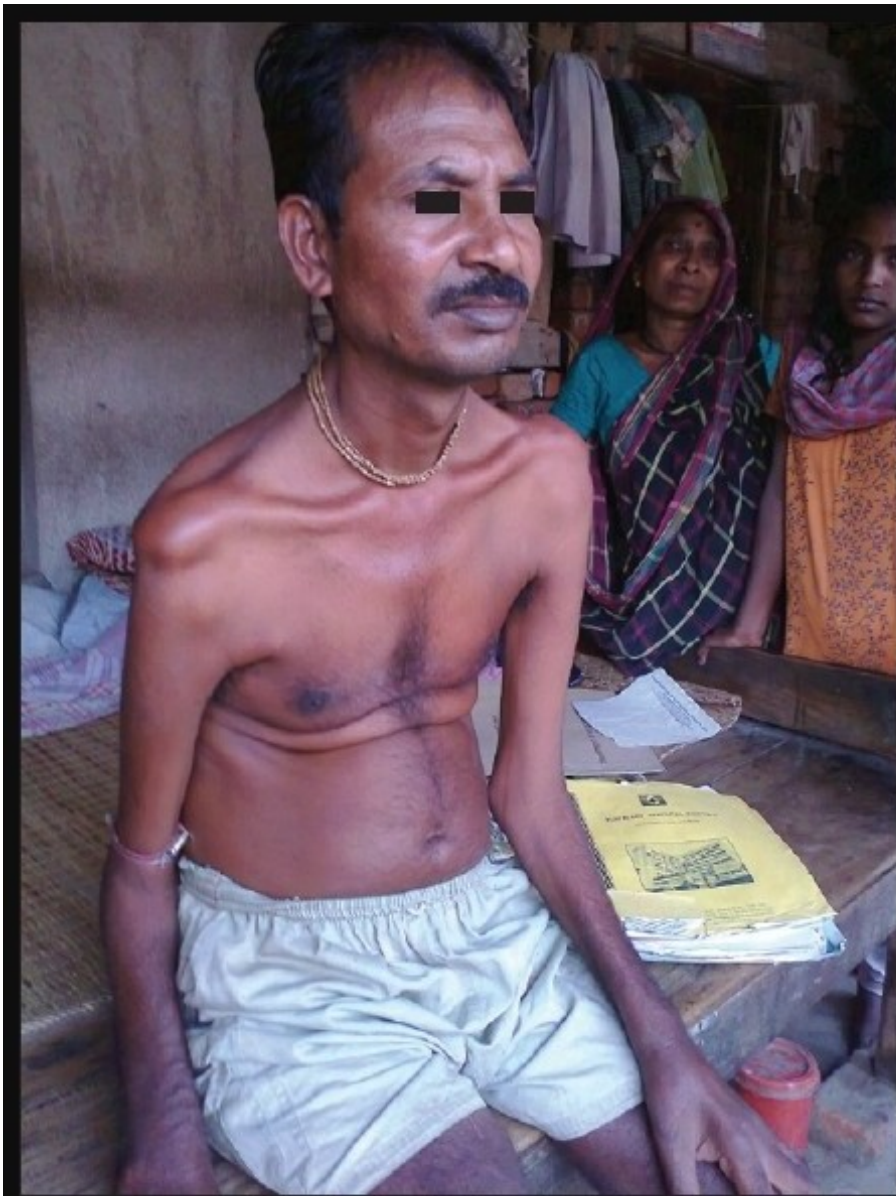

- 
- 

- Disability of the hips


- Scoliosis: paralytic curves, progression









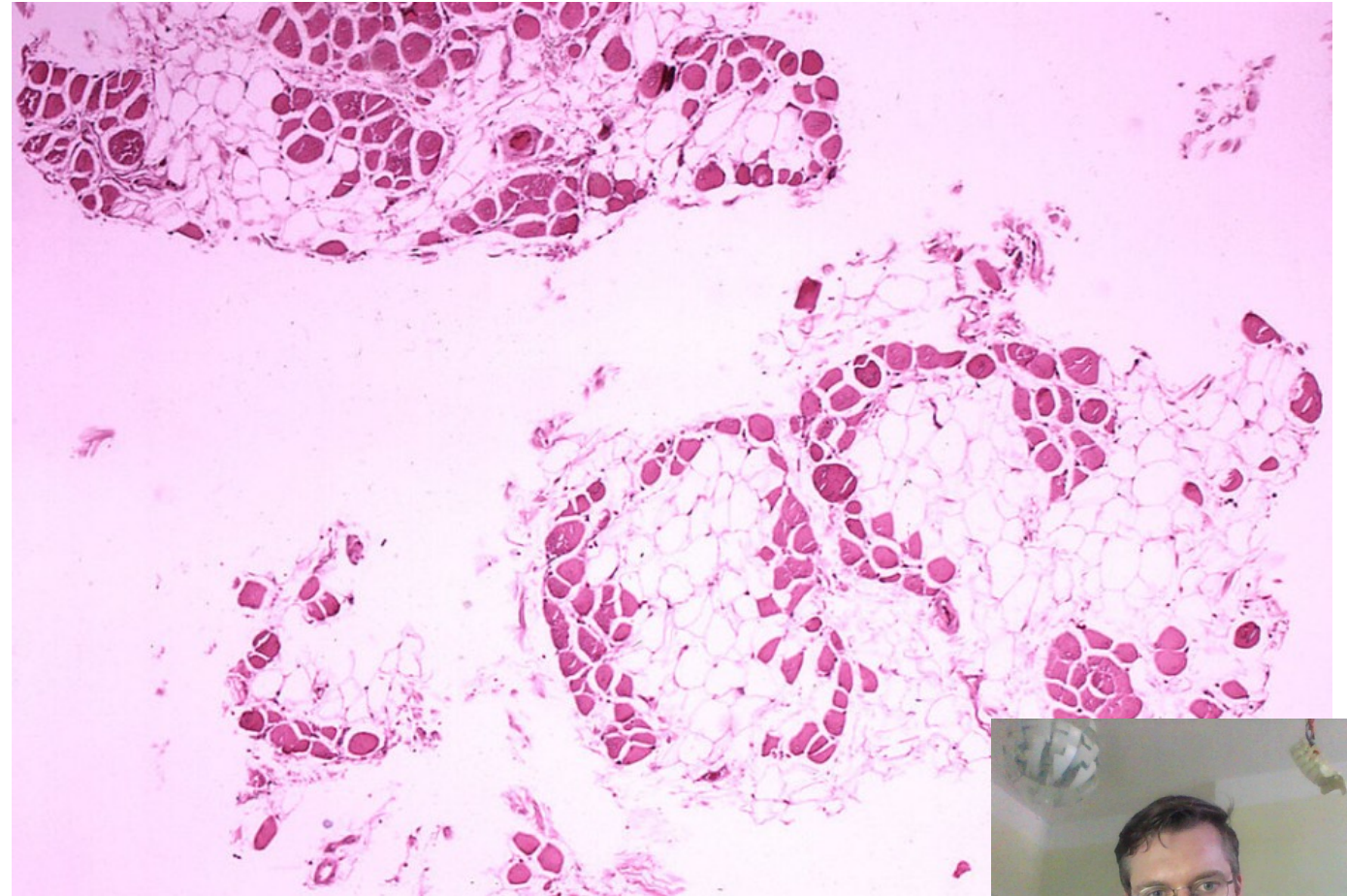
*Progresivní svalová
atrofie PMA,*

*(Duchen–Aranova mu
atrofie)*




Duchene muscular dystrophy

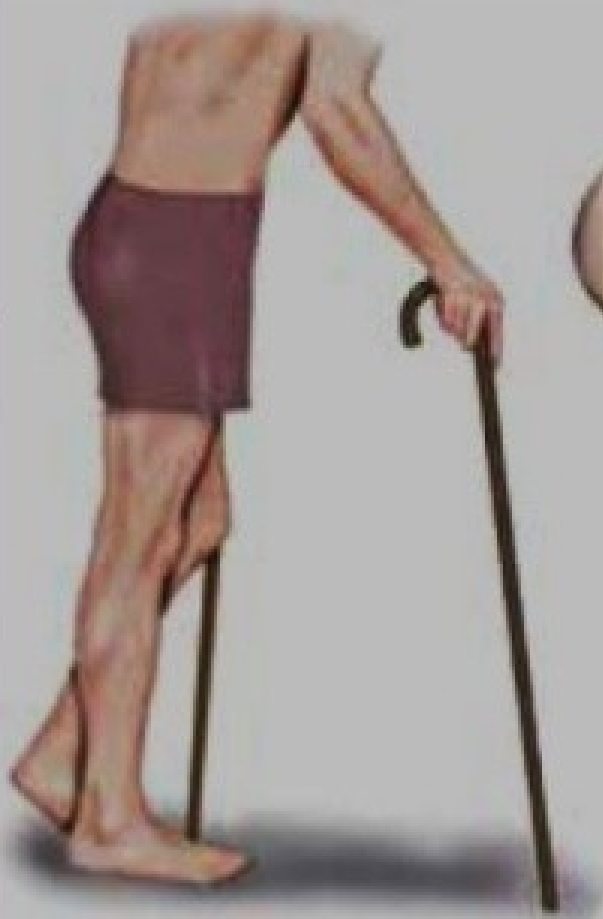- 
- 
- 
- Gradual replacement of muscles by fibrous tissue.



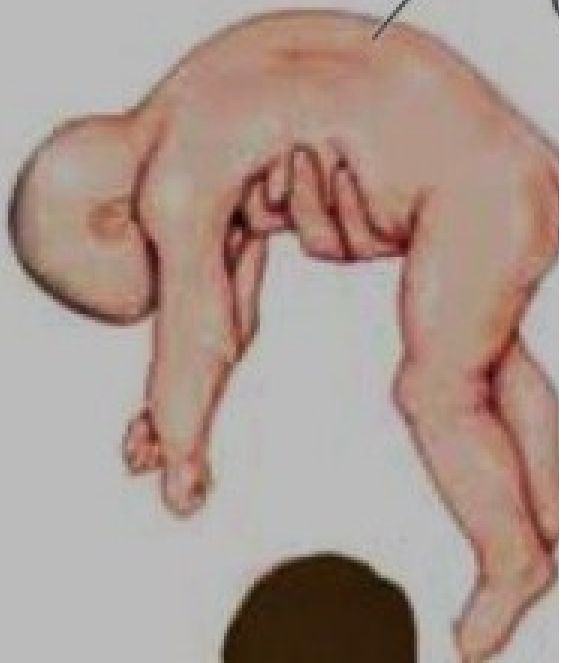Duchene muscular dystrophy

- [redacted] ome,
as a consequence, dying muscle fibers are
ligaments.
- [redacted] ig, getting up from a lying or sitting position
- [redacted]
- [redacted]
- [redacted]

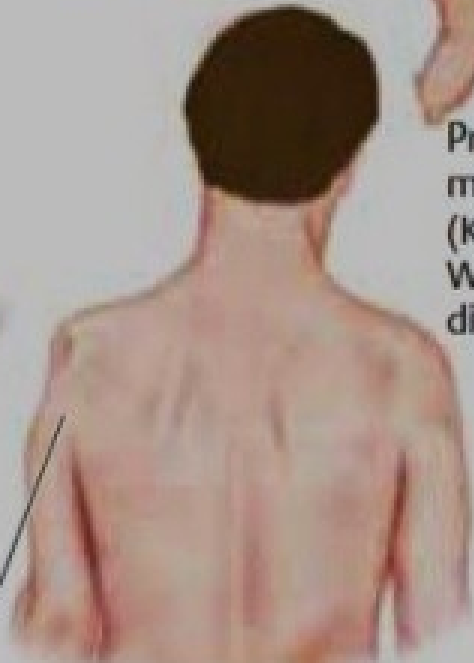




First motor neuron lesion (spastic paraparesis)

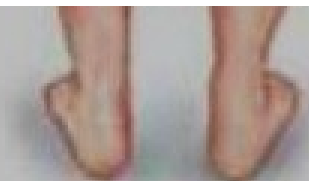

Flaccid quadriplegia



Localized atrophy (shoulder, scapula)

Proximal muscle (Kugelwaller disease)



Calf hypertrophy

Second motor neuron lesion

Dr. Juan C. Salazar Peñares




Therapeutic approach

• A. Muscular dishalalance of the lower
lin

B.

C.




Surgical treatment

INDICATION

- Paralytic curves
collapse and instability of the spine
- Progressive deformity
- Sitting instability
- Impairment of cardiopulmonary functions
by orthosis
- Back pain
- Tendency to pressure ulcers


CONTRAINDICATION

- Poor overall internal condition



General or local infection

Significant non-cooperati




Surgical treatment

Goals




Complication



injury
massive loss

infection
complications

failure





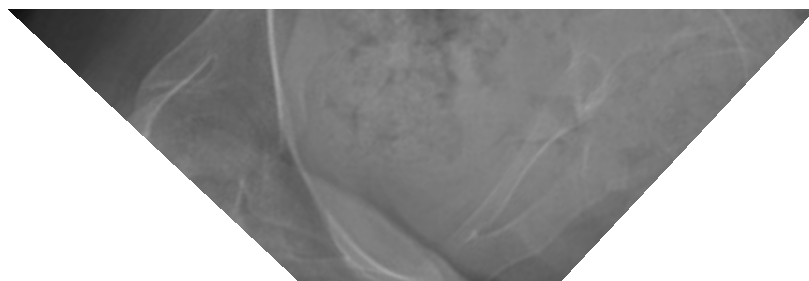




Pelvic fixation

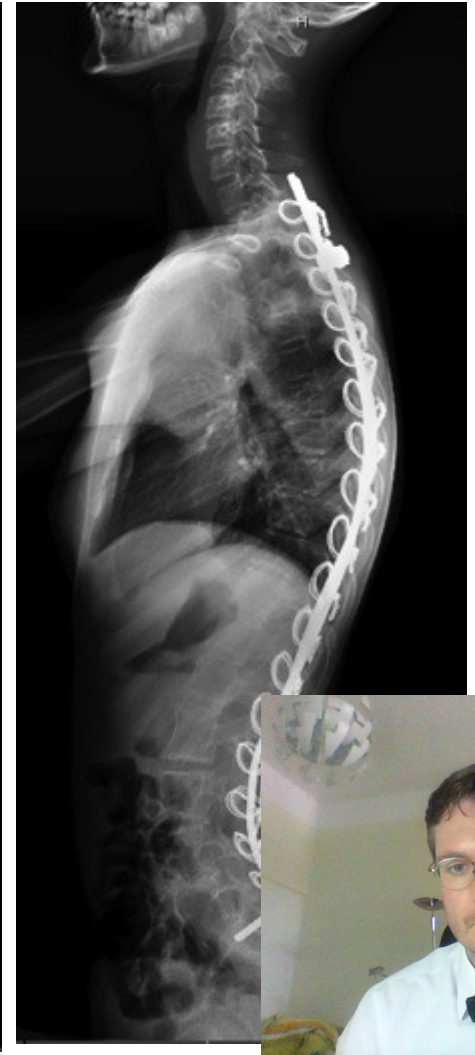
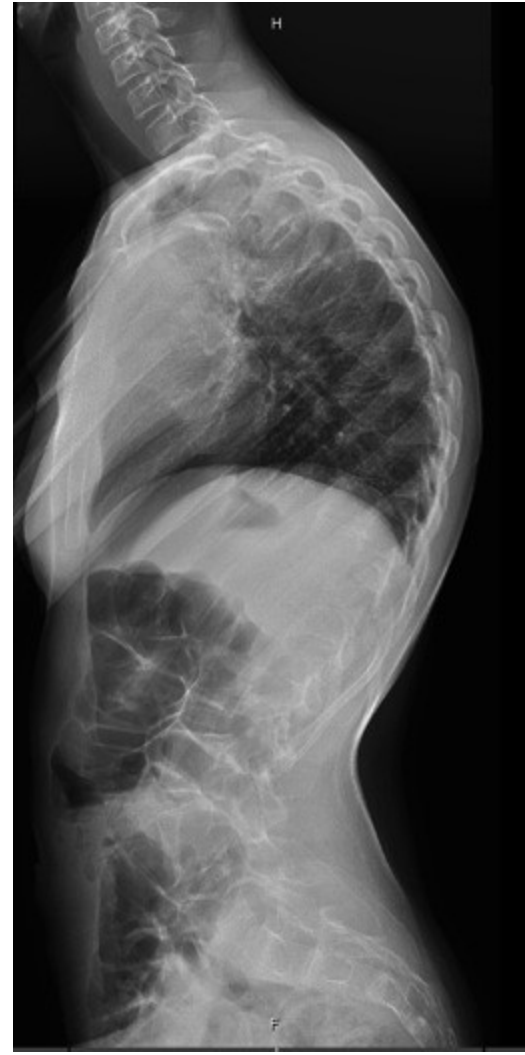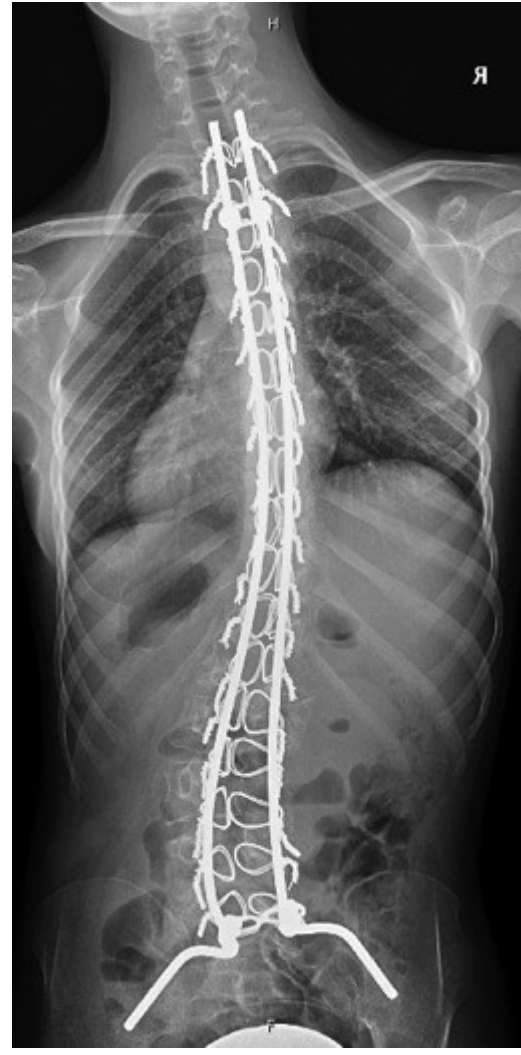
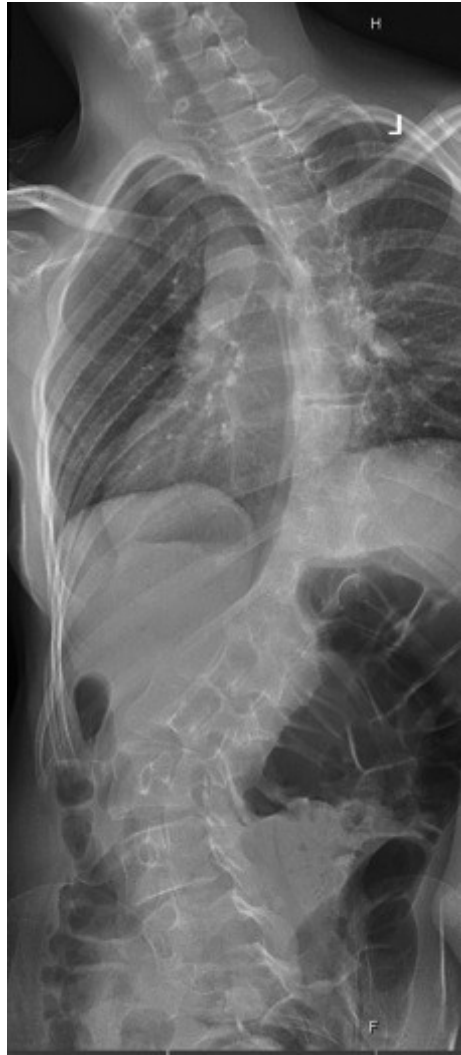Gal...

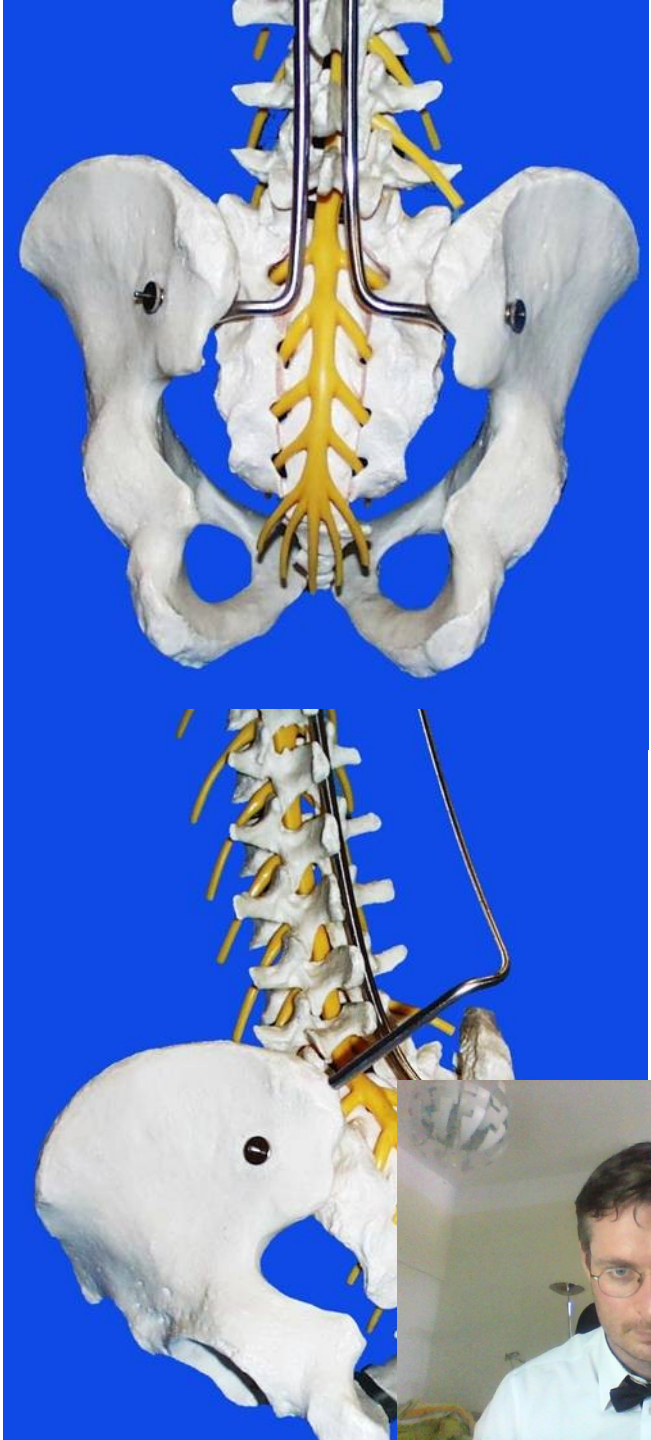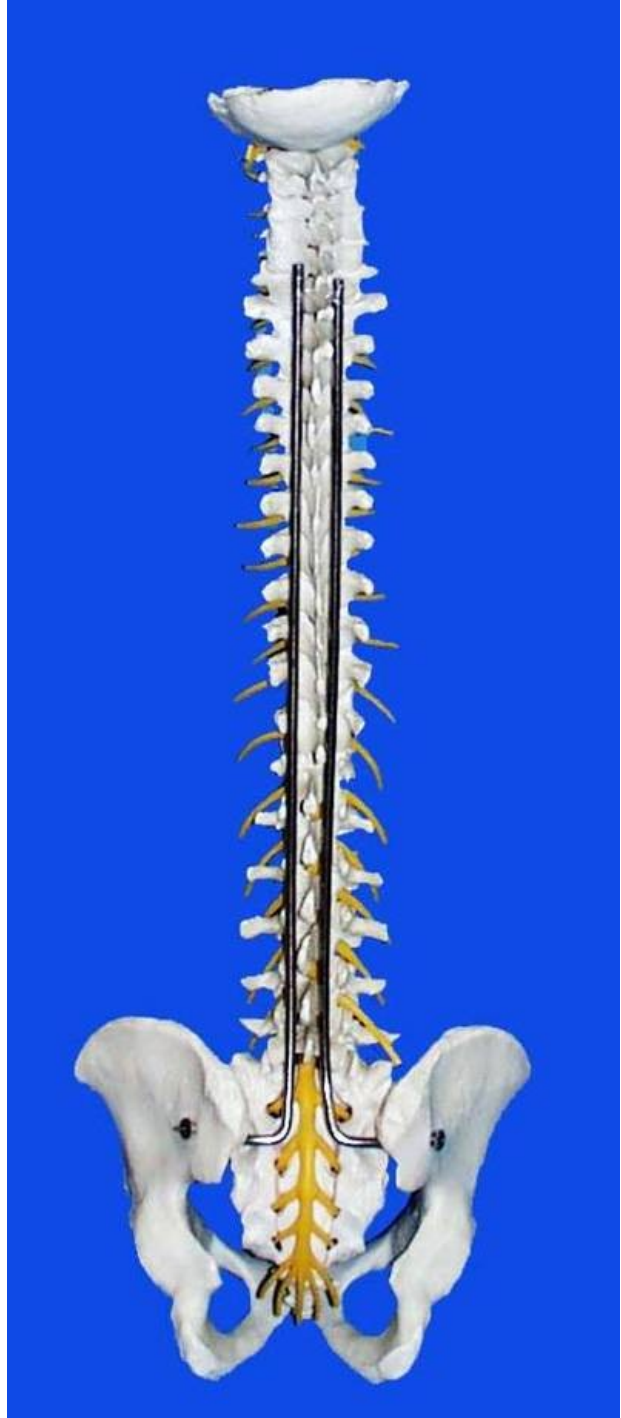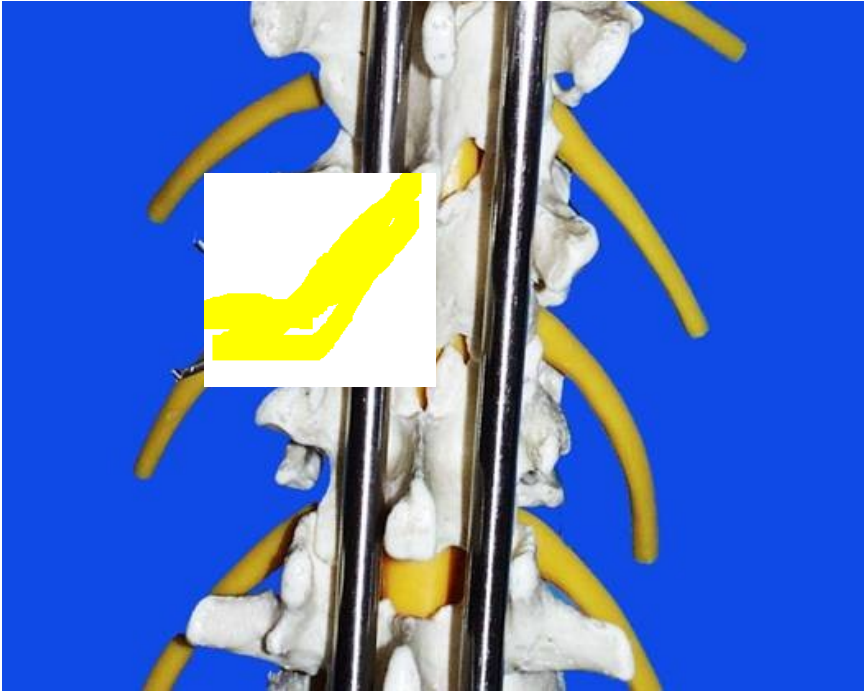
.....

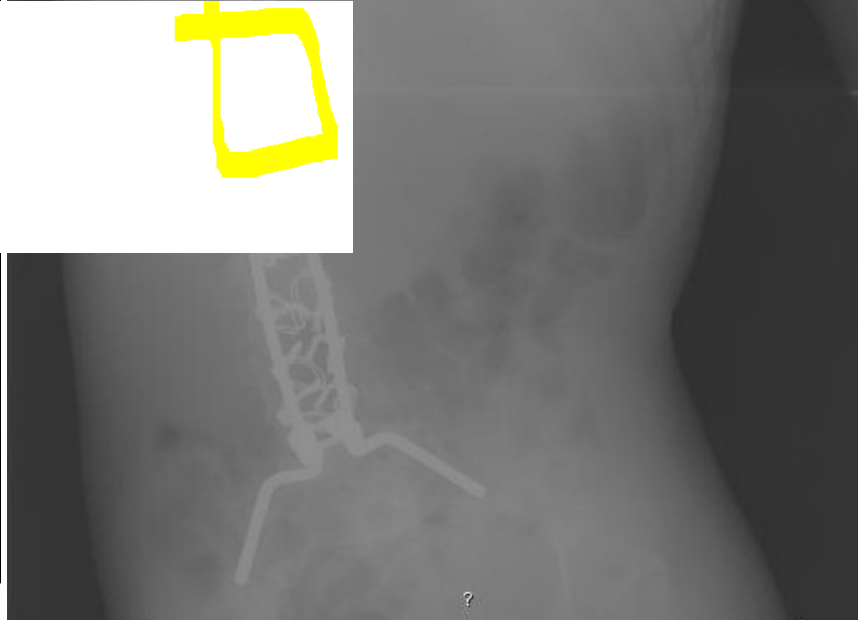
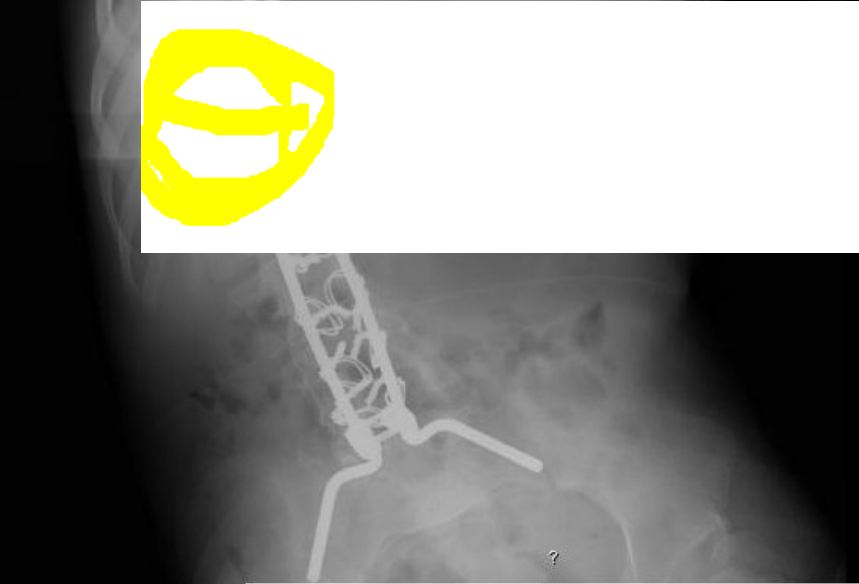
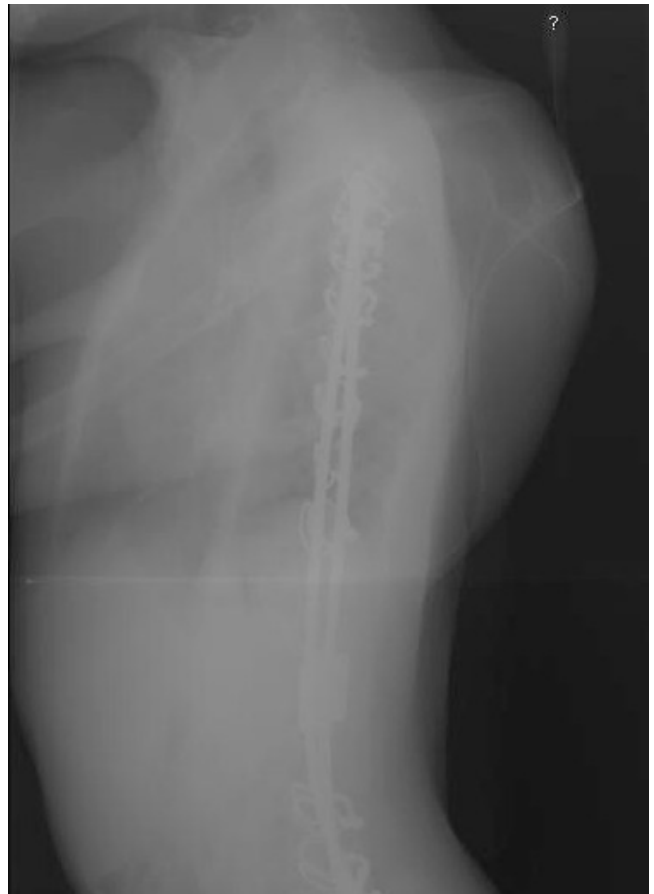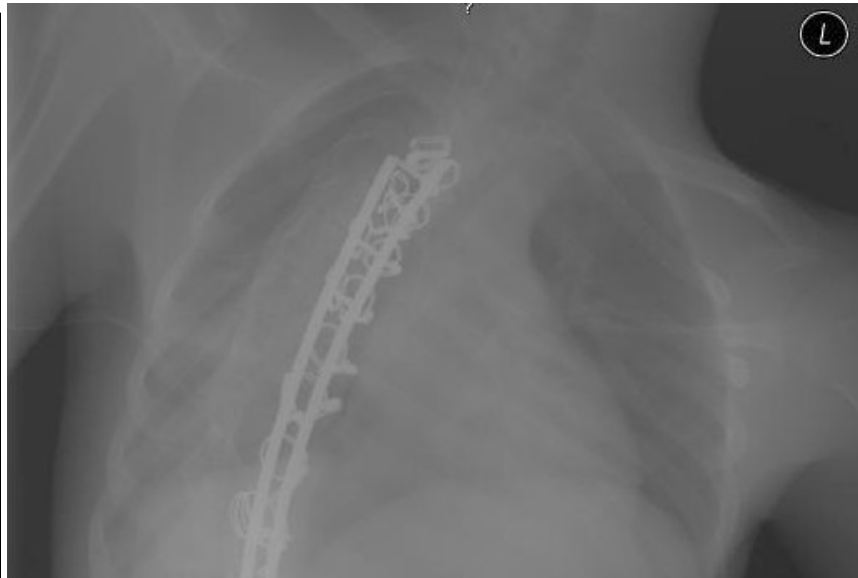
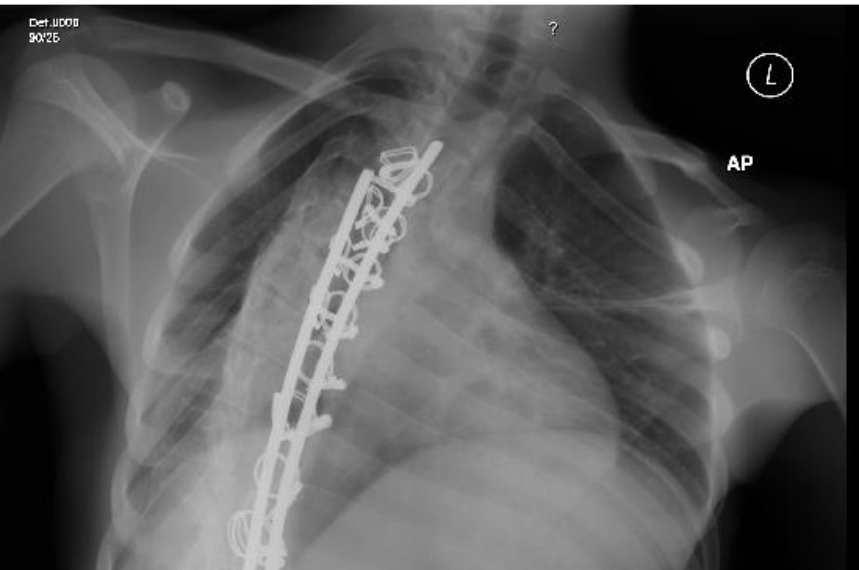
.....

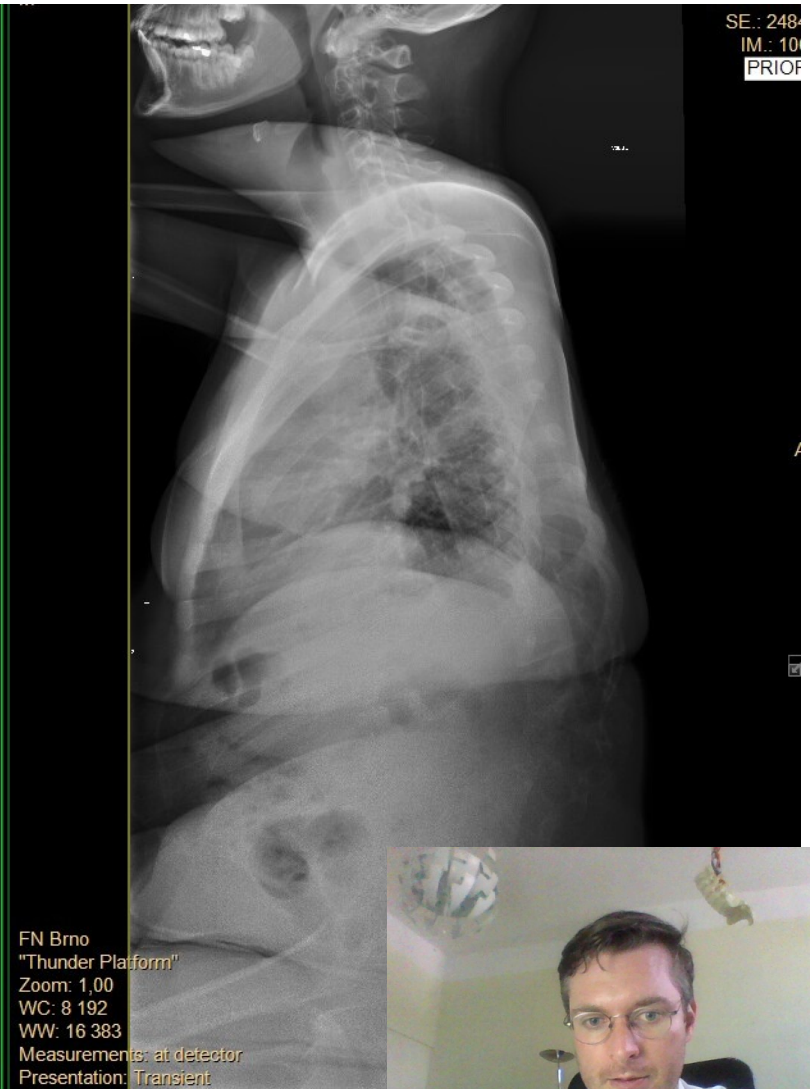
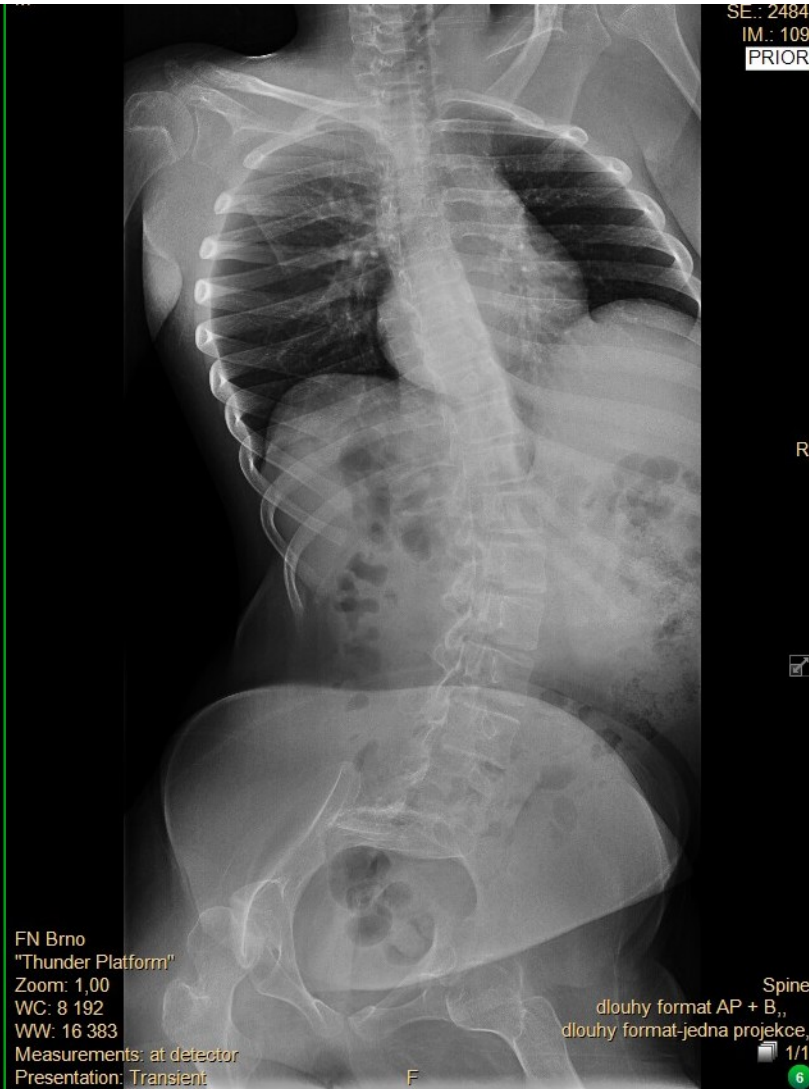
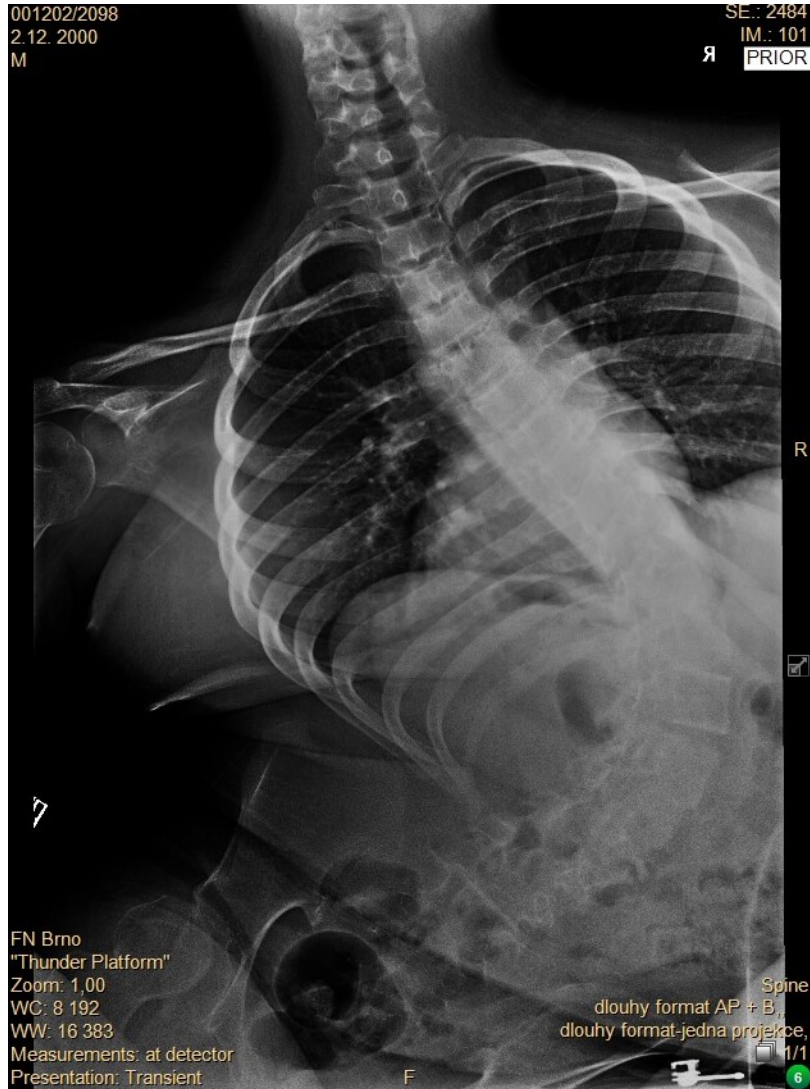
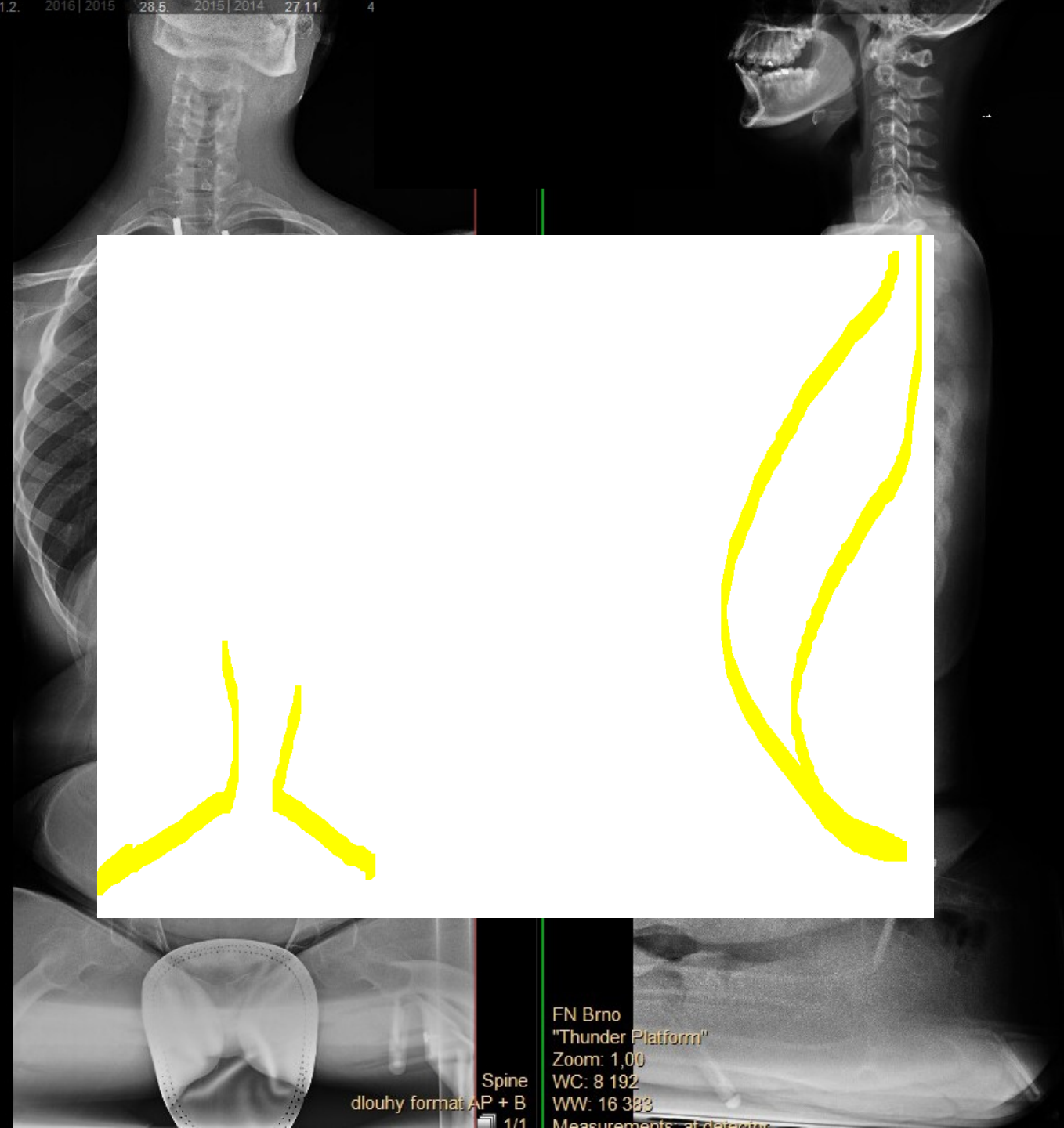
Luque Galveston technique







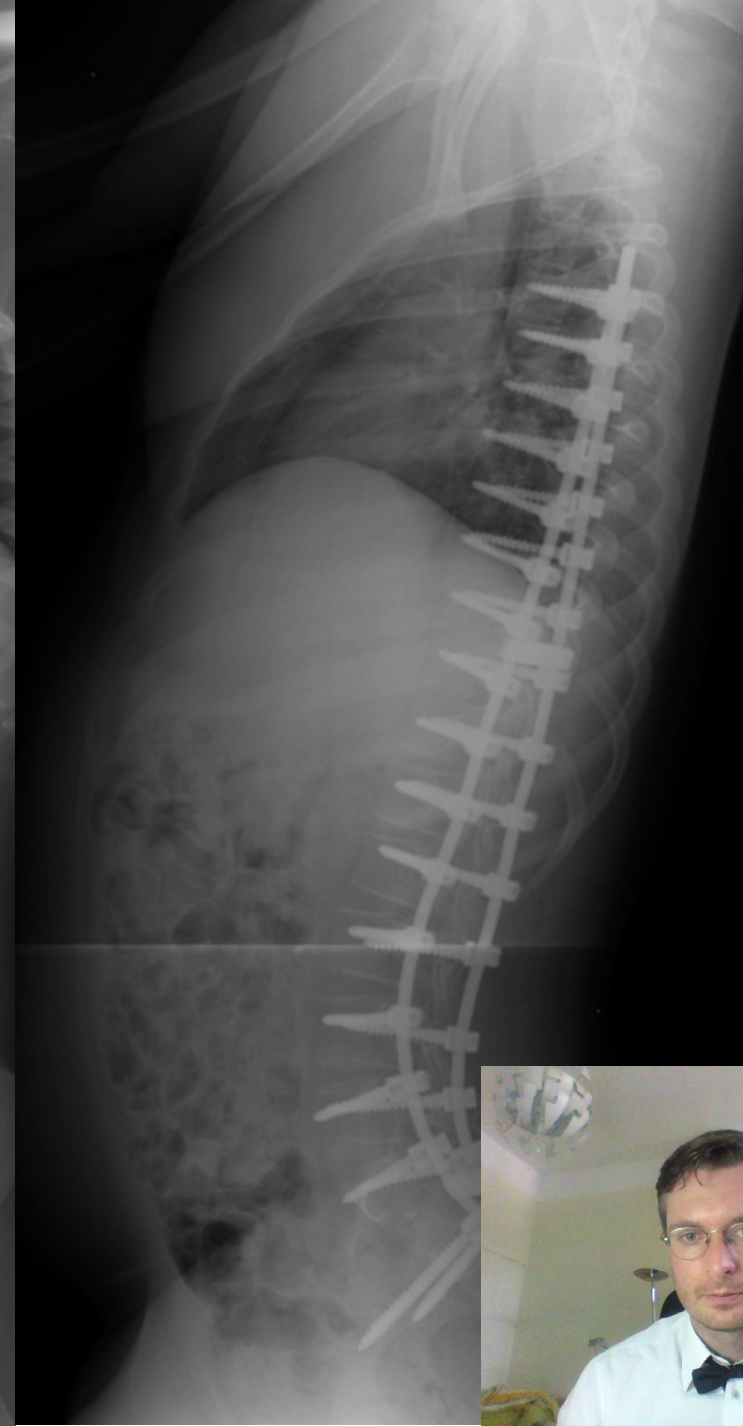
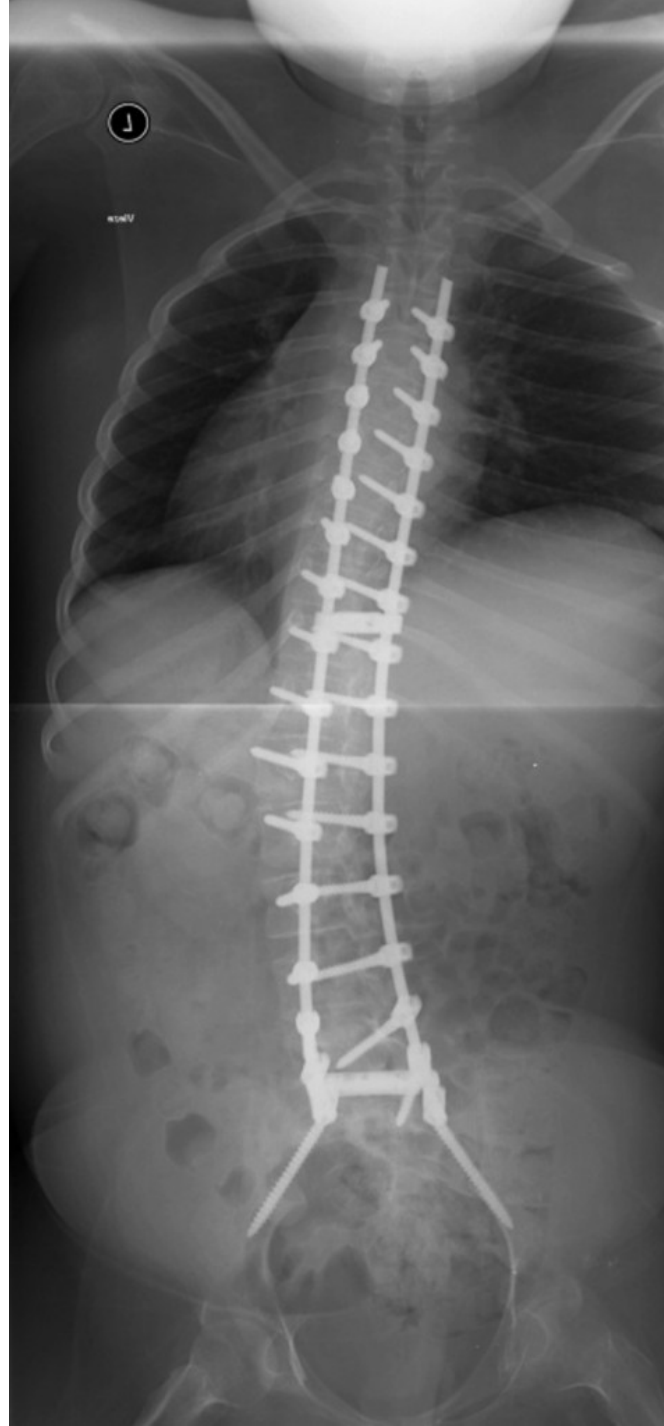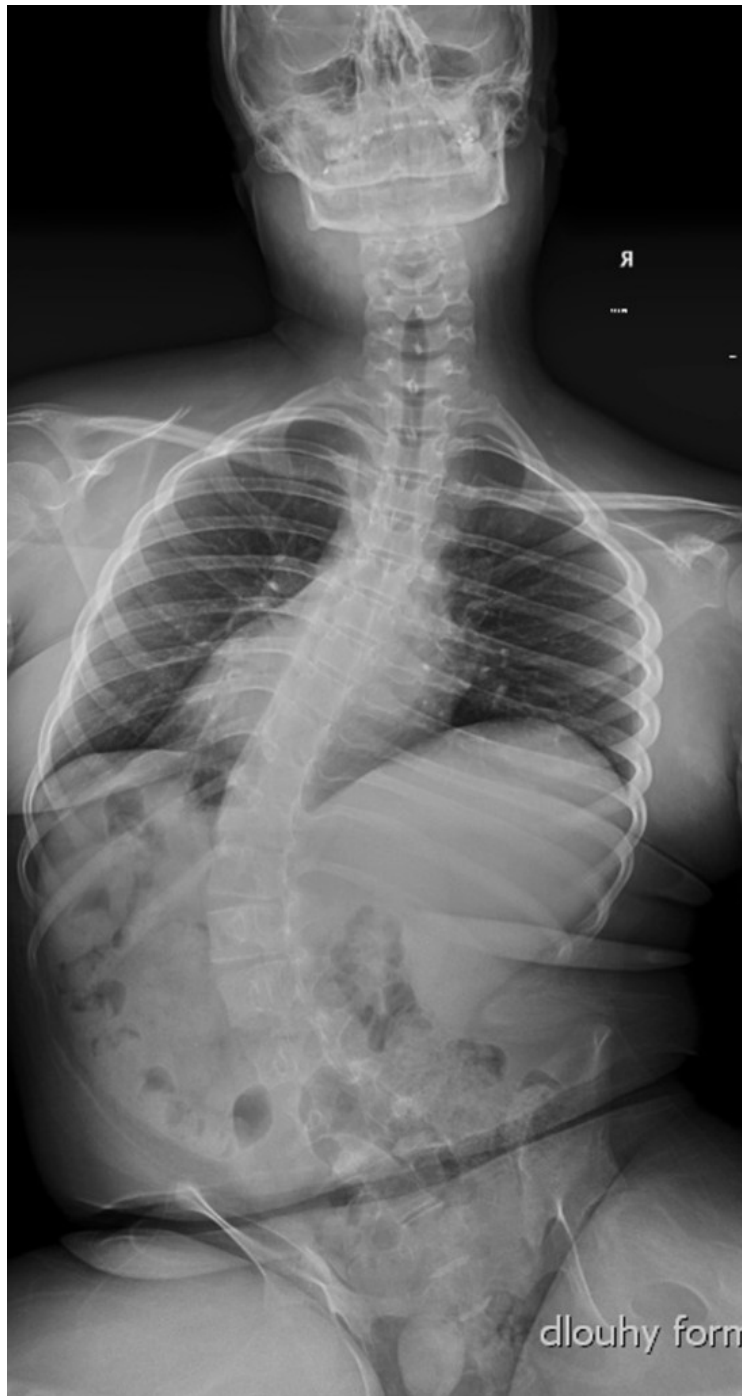

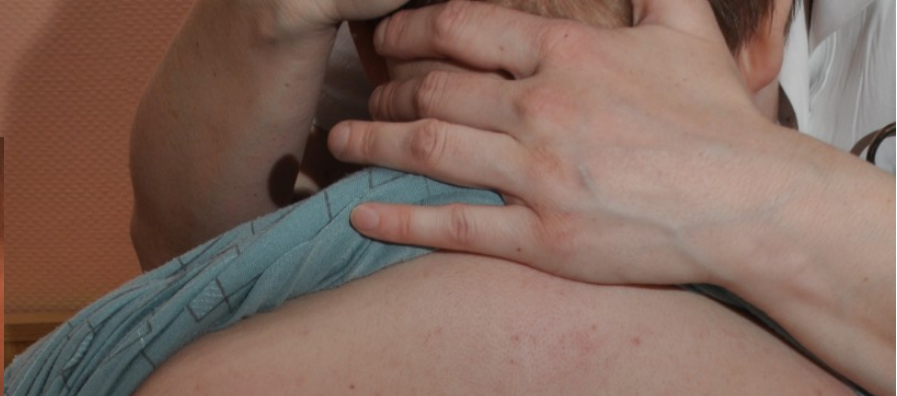
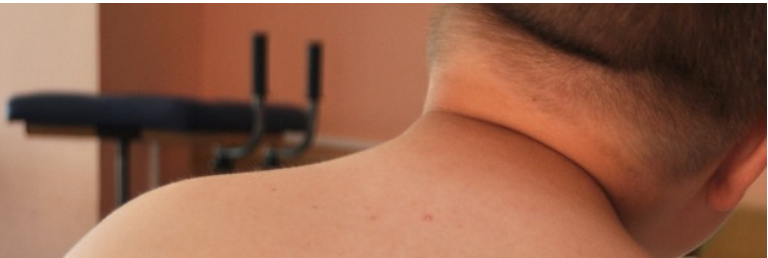






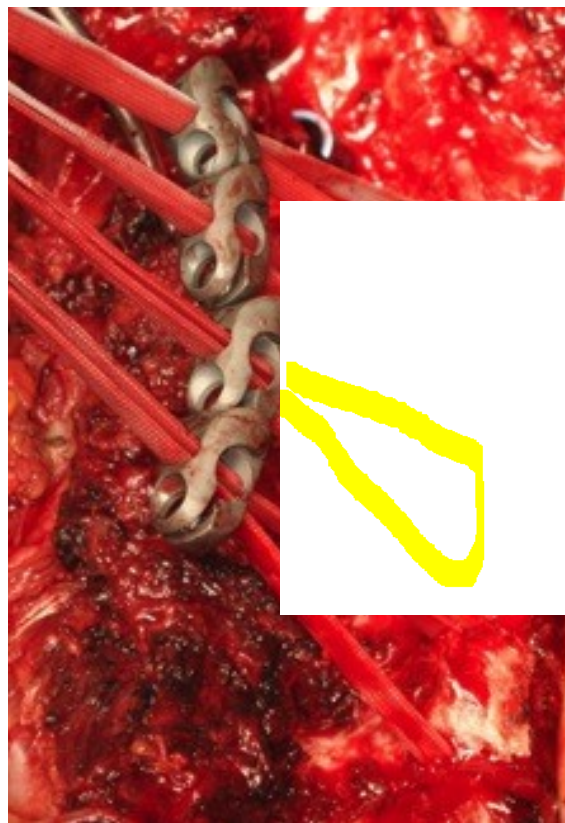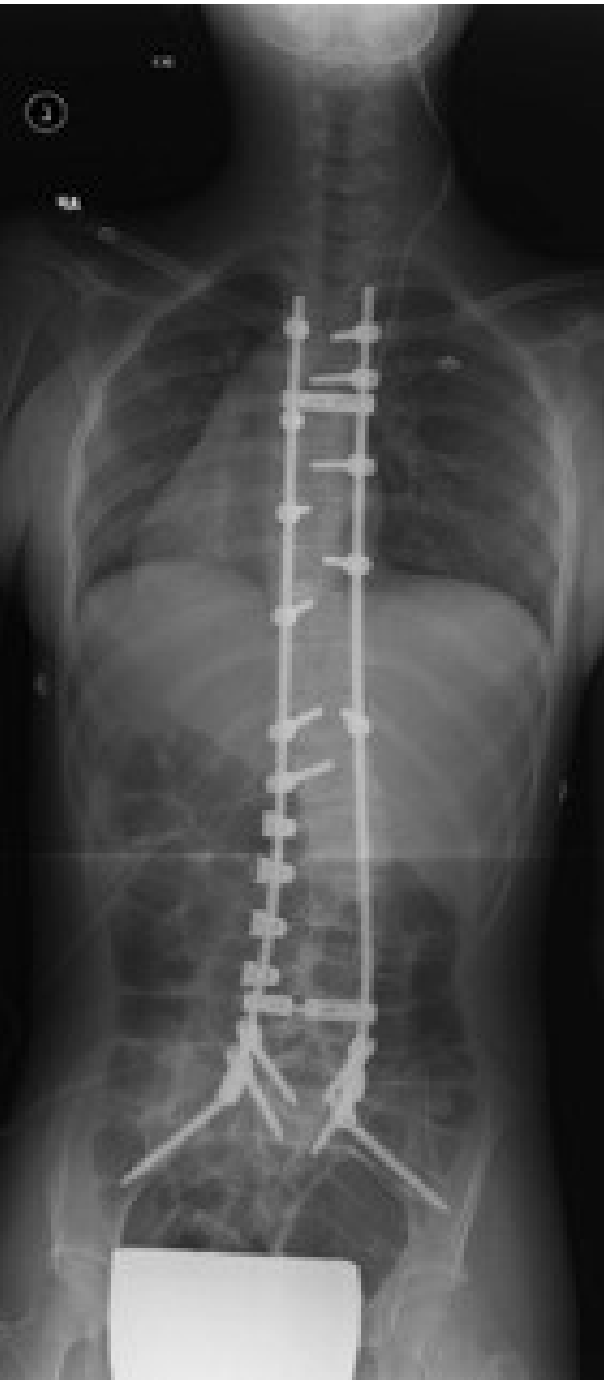
FN Brno
"Thunder Platform"
Zoom: 1,00
WC: 8 192
WW: 16 388
Measurements: at detector
Spine
dlouhy format AP + B
1/1

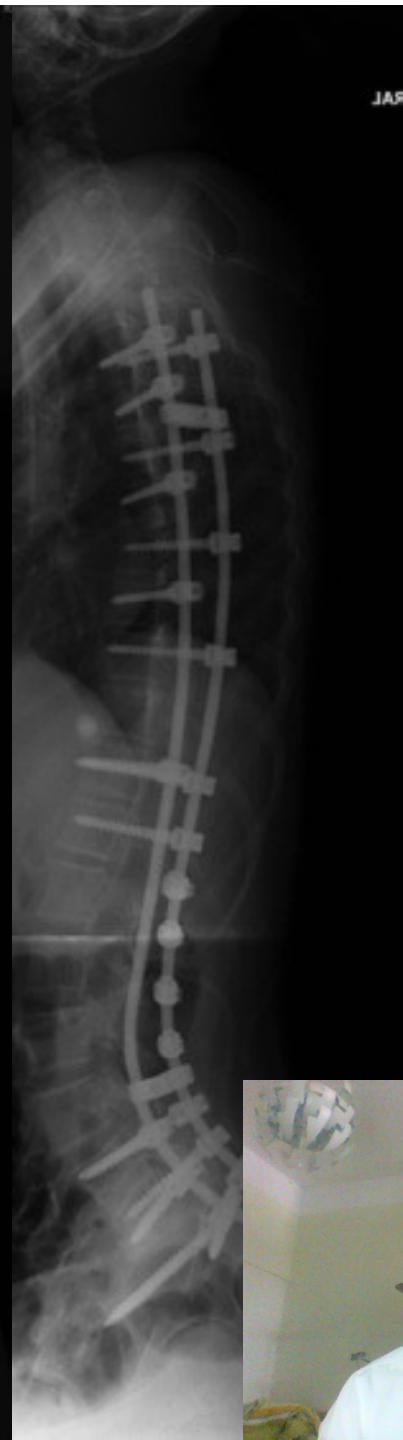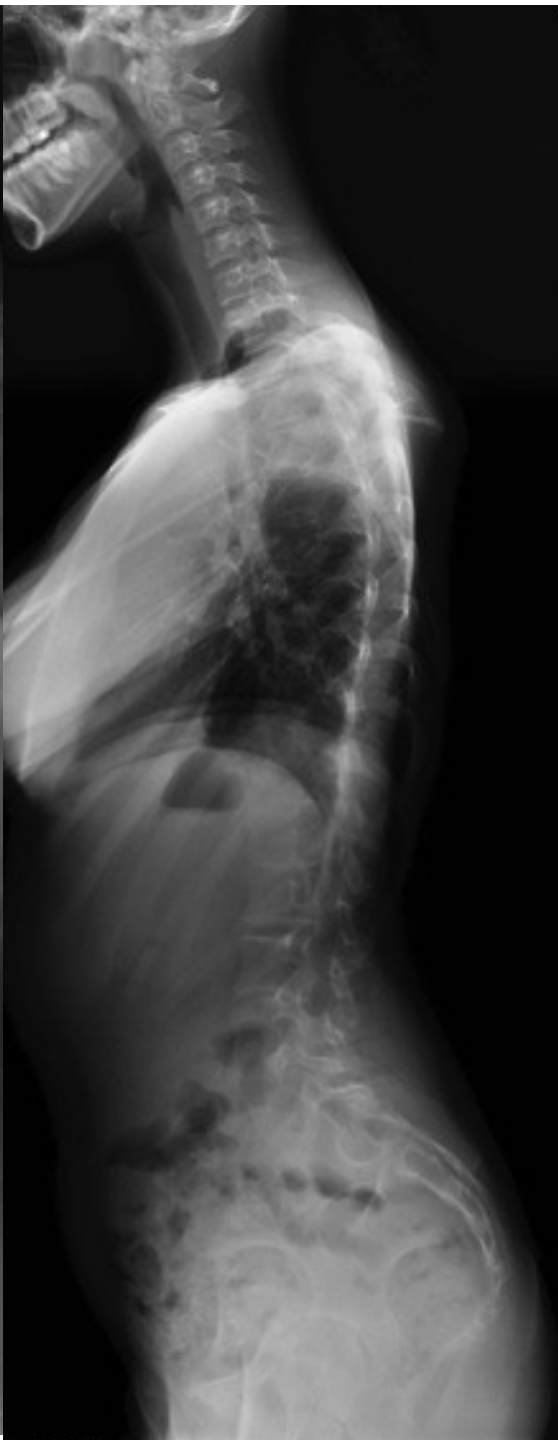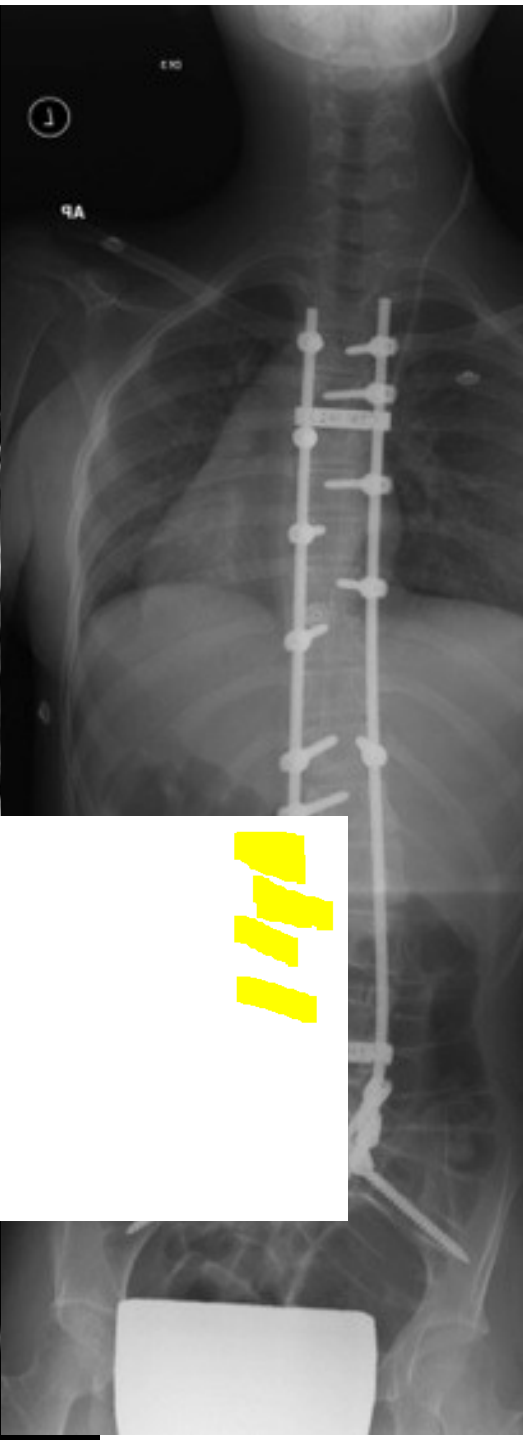
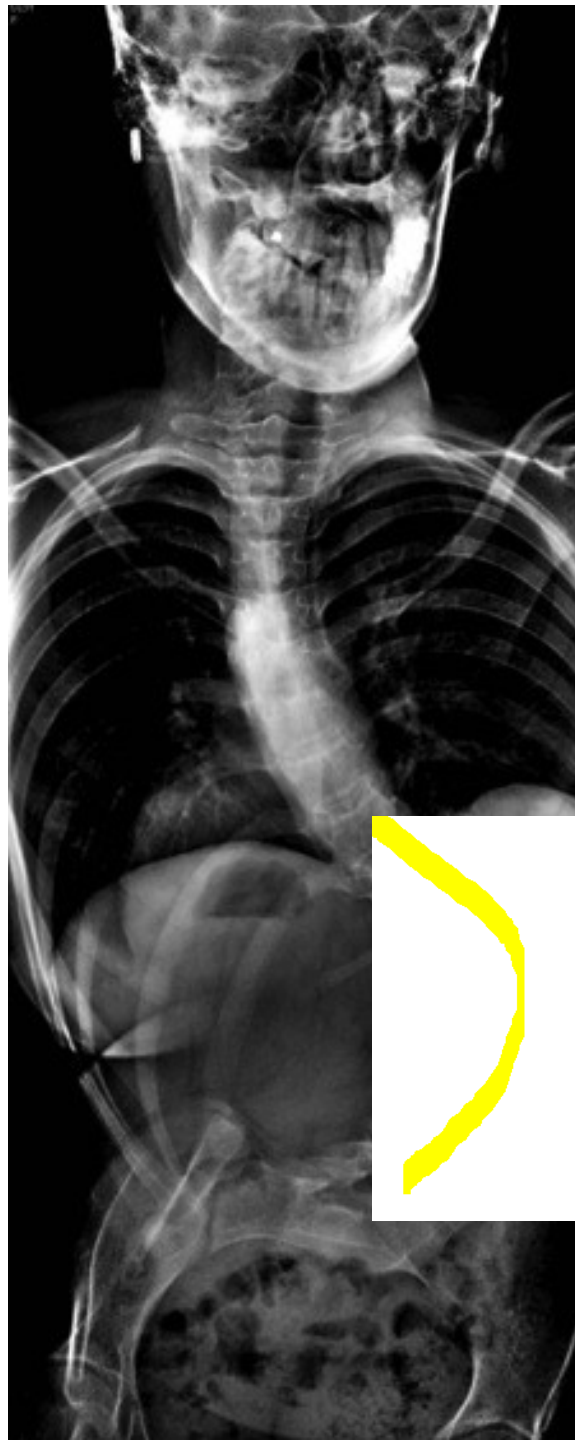






Universal Clamp





NM scoliosis – take home



raction deformities



Scoliosis in general-take home message

- 3D deformity !
- AIS 80% of all deformities
- Physiotherapy does not stop progression in AIS !
- Brace from 20° Cobb to stop progression in growing patient
- Surgery above 40° Cobb angle

