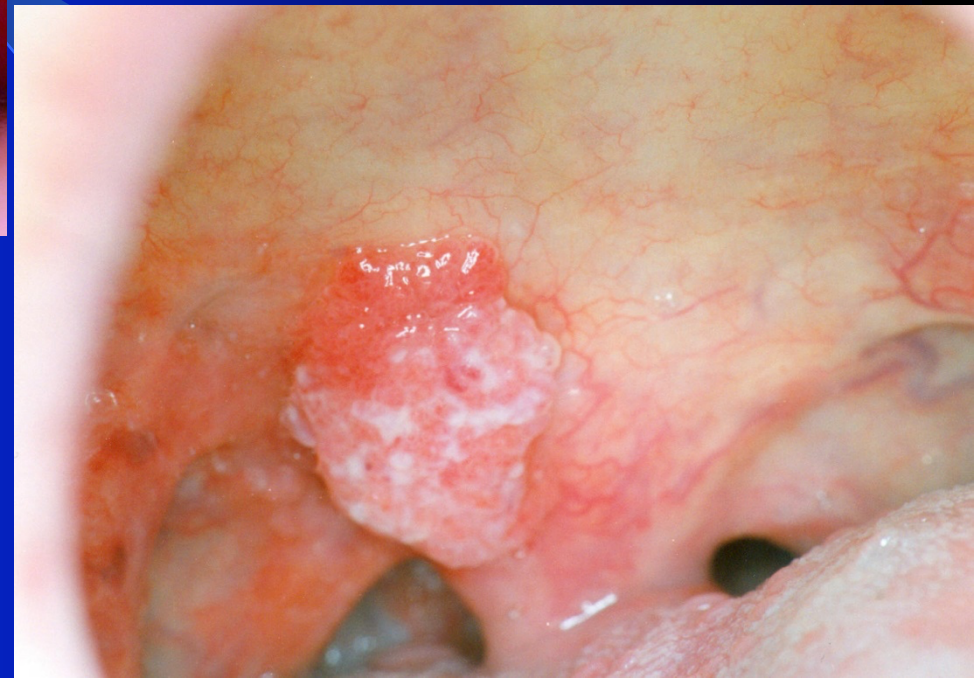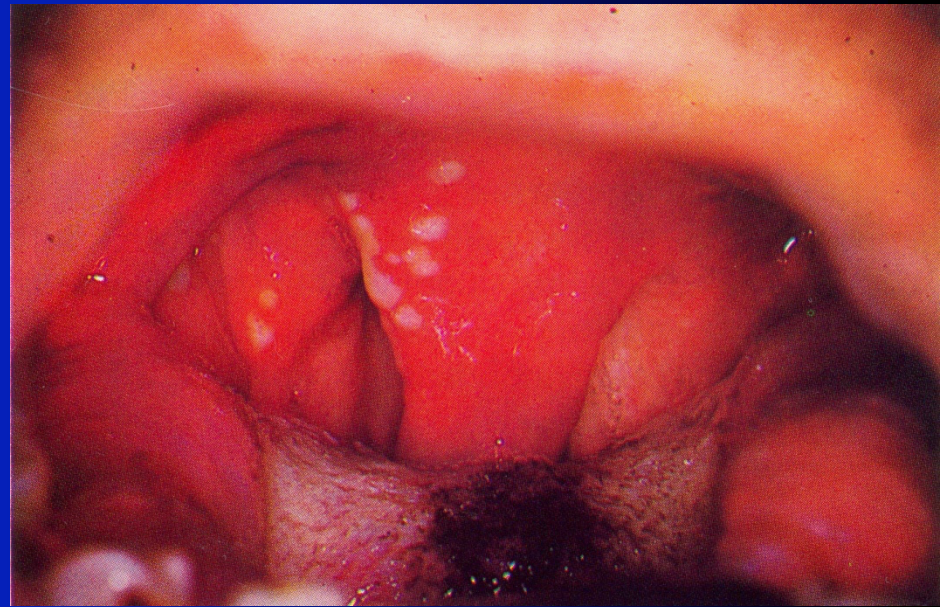
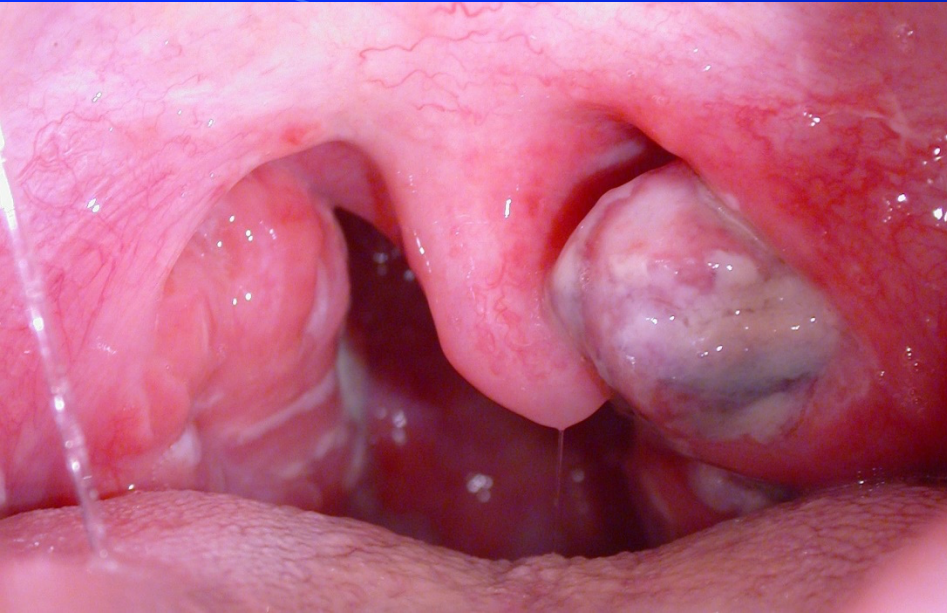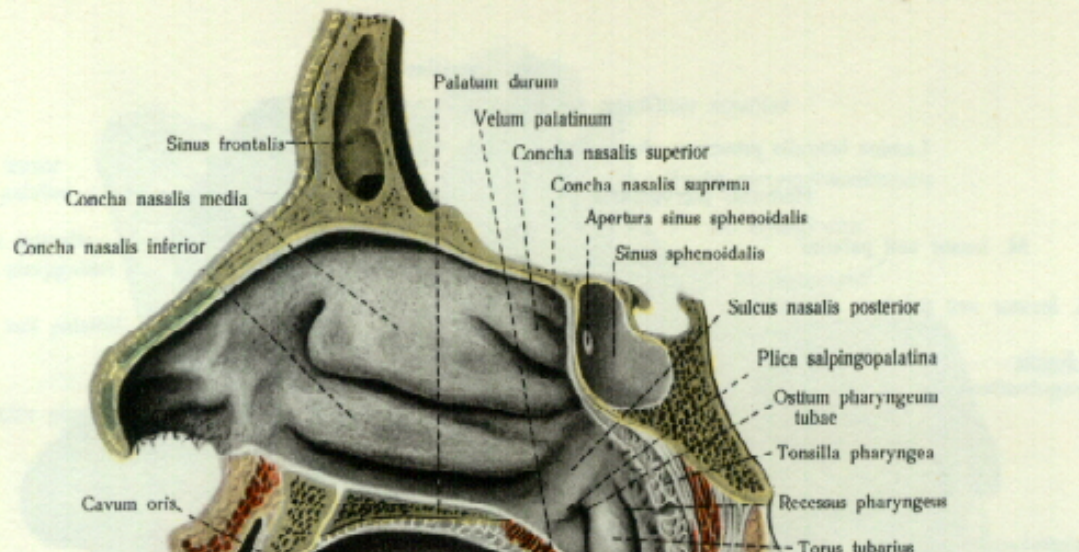


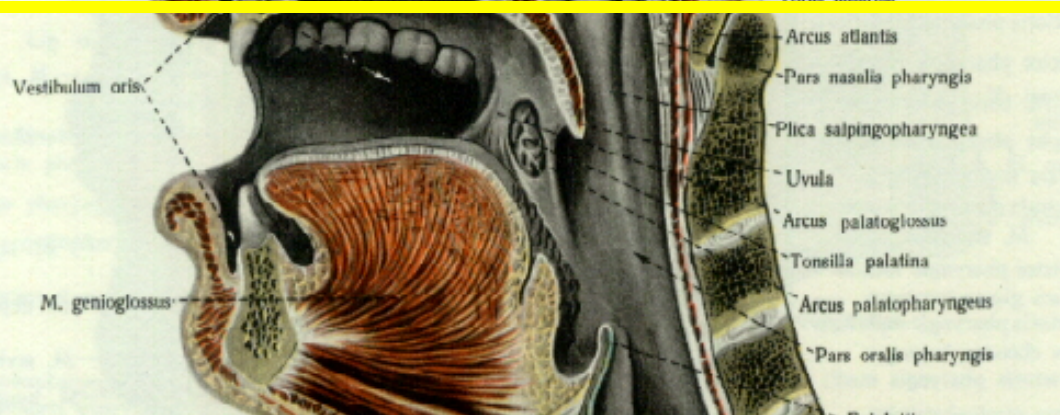
Pharynx, nasopharynx



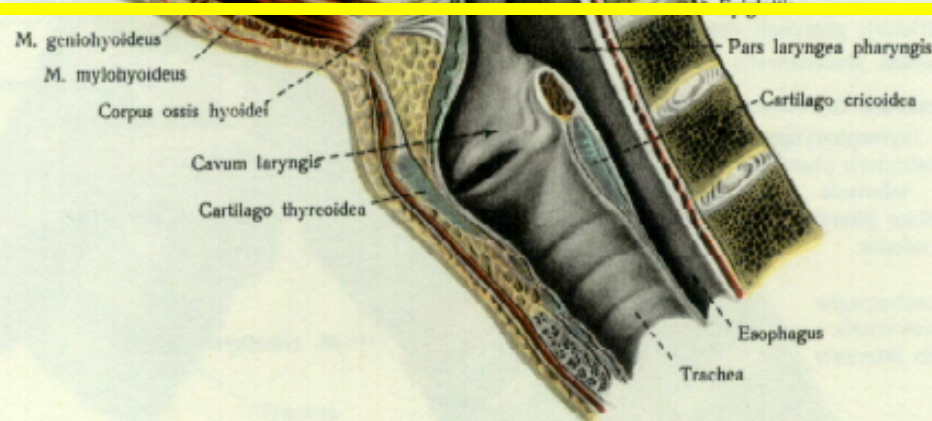
Epipharynx

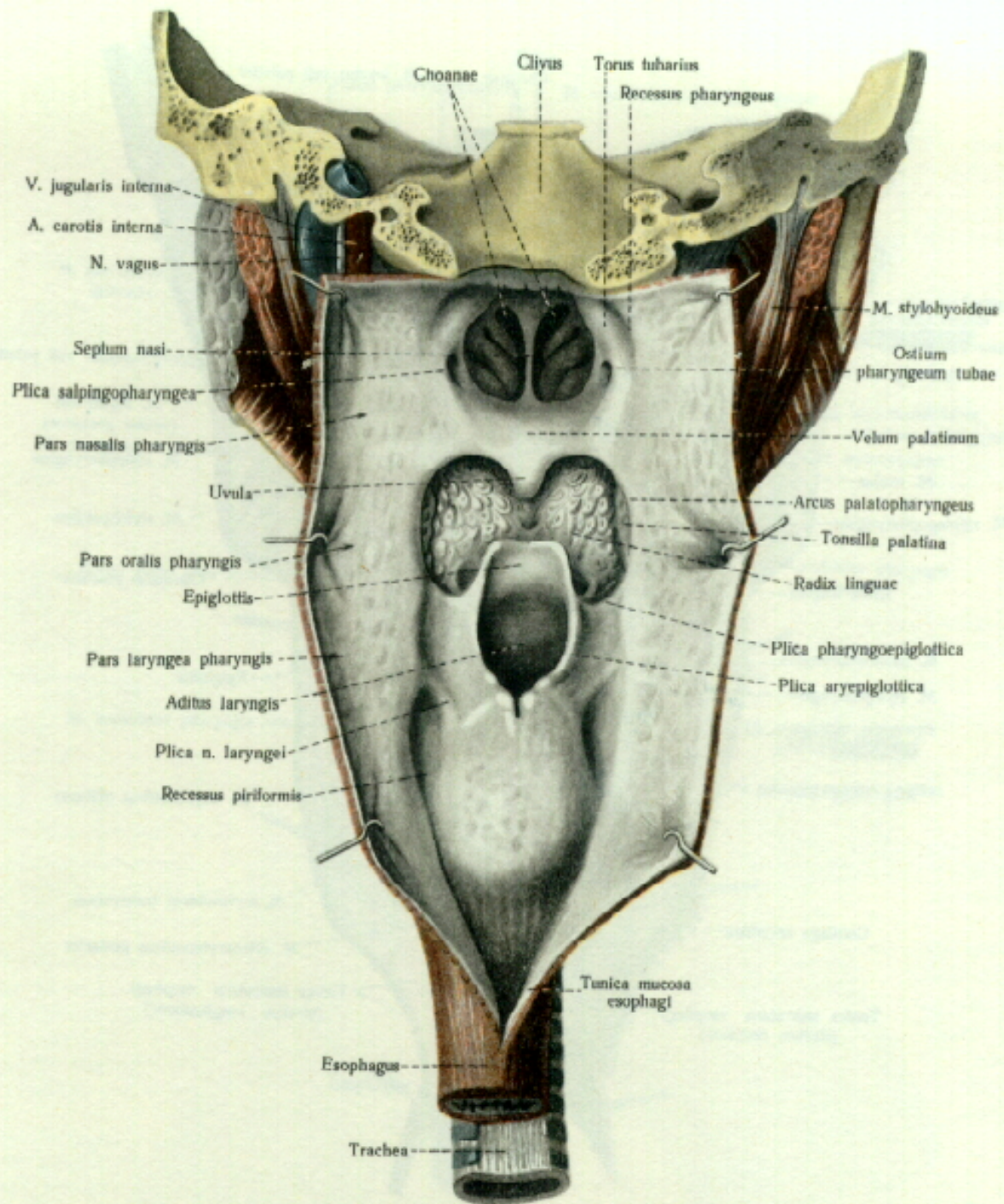


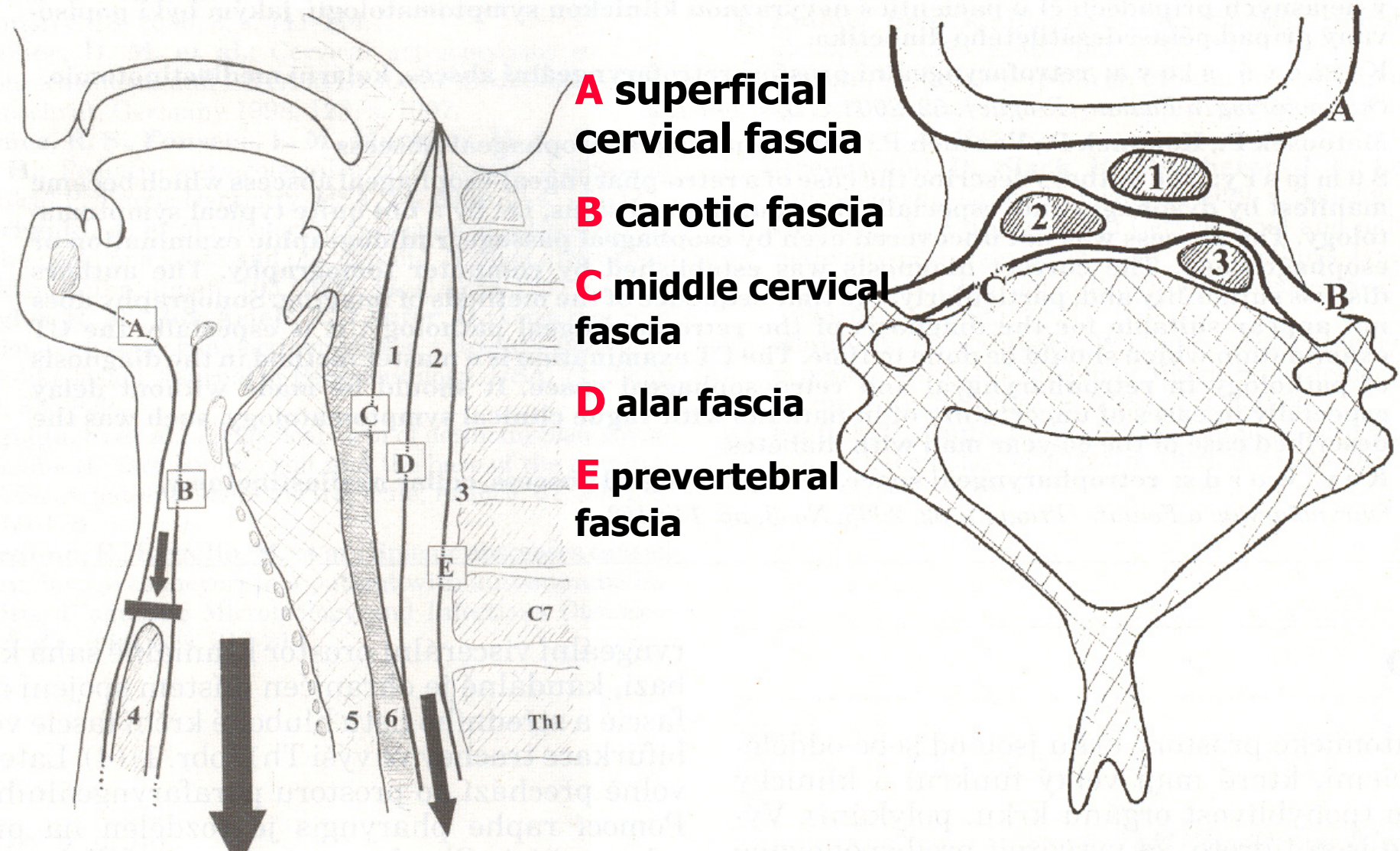
Oropharynx



Hypopharynx



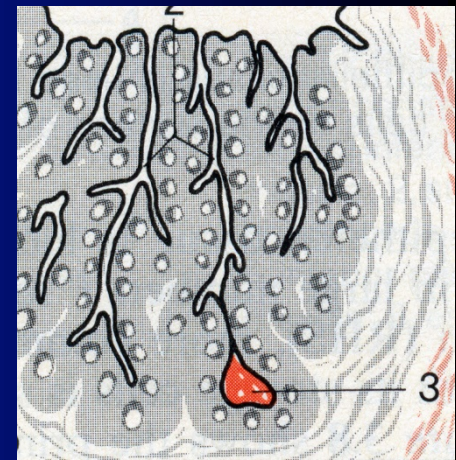




Cervical interfascial spaces

1. abscessus in retropharyng. space, 2. v „dangerous space, 3. v prevertebral space.

Immune-specific function of Waldeyer's Ring



Palatine tonsil:

- The tonsils ensure controlled and protected contact of the organism with environment, immunologic surveillance
- The tonsils produce lymphocytes
- The tonsils expose B- and T-lymphocytes to current antigens
- The tonsils produce specific antibodies after the production of the appropriate plasma cells.
- All types of immunoglobulins occur in tonsillar tissue.

Main symptoms indicating disease of the mouth and pharynx I:

Pain on eating, chewing, or swallowing

Frequent cause: inflammations, tumors, foreign bodies

Dysphagia

inflammations (glossitis, abscesy, angionerutický edém, edém vchodu do hrtanu)

Neurogenic aetiology (disorder of n vagus a glossopharyngeus, amyotrophic lateral sclerosis, bulbar and pseudobulbar paralysis, sclerosis multiplex, diabetic and alcoholic neuropathy)

Mechanical obstruction (f.b., diverticulosis, striktury, tumor)

Miscelanea (epithelitis post actinotherapiam, xerostomy, fractures of mandibule and maxilla, disorder of chewing muscles)

Burning of the tongue

toxic stomatitis, various diseases of GIT, xerostomy, syndroma Plummer-Vinson, Diabetes mellitus, food allergy, mukoviscidosis, psychogenic glossodyna

Main symptoms indicating disease of the mouth and pharynx II: - superficialis laesions of the tongue

Red tongue (anemia, scarlett fever, hepatic cirrhosis, hypertension, allergy, Sjögren's syndrome)

Gray smooth tongue (st.p. radiotherapiam, vitamin A deficiency, lichen planus)

Black hairy tongue (antibiotics, mycosis)

Fissured tongue (lingua plicata, Melkersson-Rosenthal syndrome)

Coated tongue (mycosis, non-specific inflammation, reduced food intake, fever, malhygiene of oral cavity)

Brownish plaques (uremy in renal insufficiency)

Presence of blood in saliva, sputum

Bleeding in parodontosis, injury, foreign bodies, varices in base of the tongue, tumors.

Differential diagnosis: epistaxis, hemoptysis (coughing of blood from lower airways, hematemesis (bleeding from swallowing ways))

Foetor ex cavo oris (Oral Fetor)

teeth, gingiva- caries dentium, parodontosis, stomatitis, exulcerated tumors

Pharynx - inflammation (acute, chronic, specific), foreign bodies, tumors

Airway – atrophis rhinitis, ozaena, purulent rhinosinusitis, bronchiectasies

Digestive tract – esophageal diverticulum, disorder of stomach etc.

Metabolic cause- diabetes mellitus (acetone), renální insufficiency (urine), liver coma (sweet aromatic smell)

- **Trismus**

Inflammation of the teeth or mandible, temporomandibular joint, oropharynx (peritonsillar abscess) infection, muscle spasm from neurologic origin, tumors of oropharynx and around the temporomandibular joint, congenital ankylosis of temporomandibular joint

- **Disorder of salivary secretion**

xerostomy -dehydration, st.p.RT, Sjögren's syndrome, sialadenosis, sialorrhea - psychogenic factors, gravidity; ...

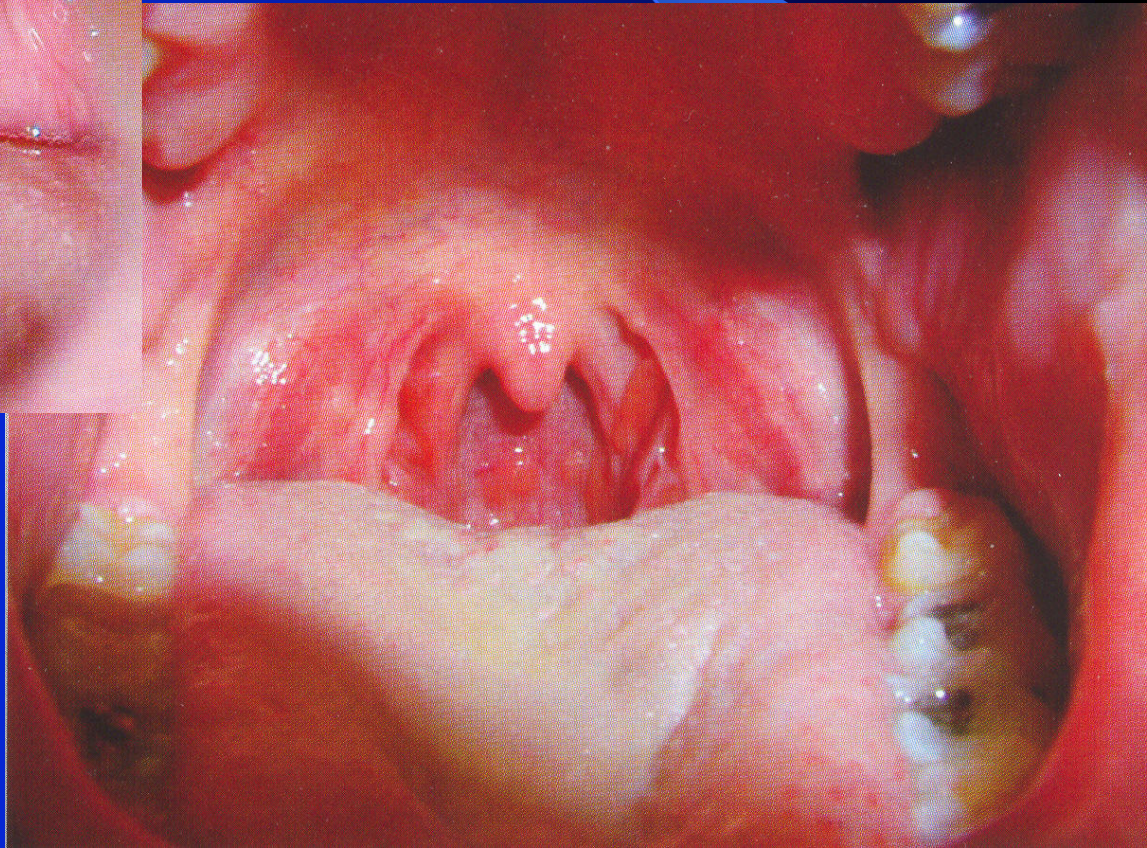
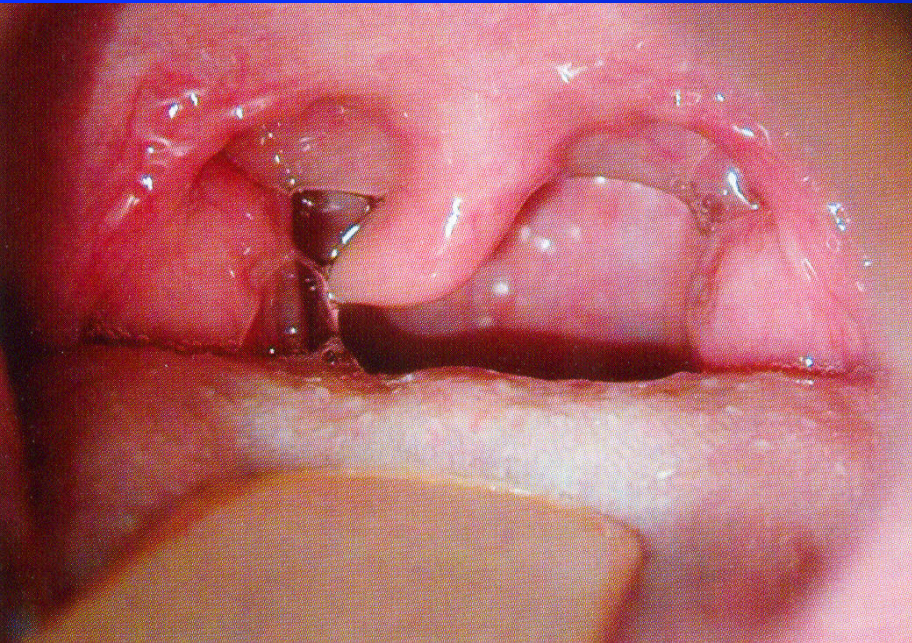
- **Disorder of speech**

dysarthry - bulbar and pseudobulbar palsy, ...etc

Methods of investigation

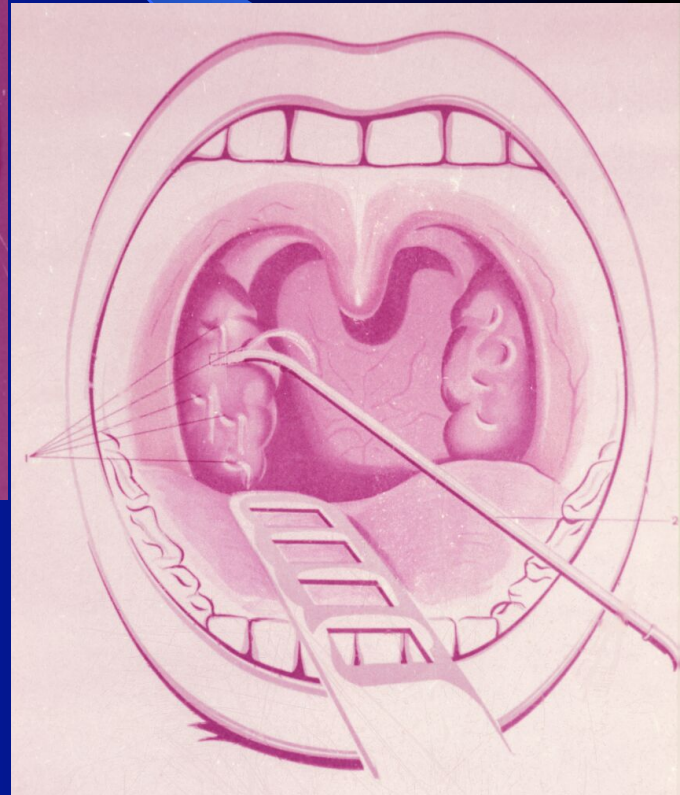
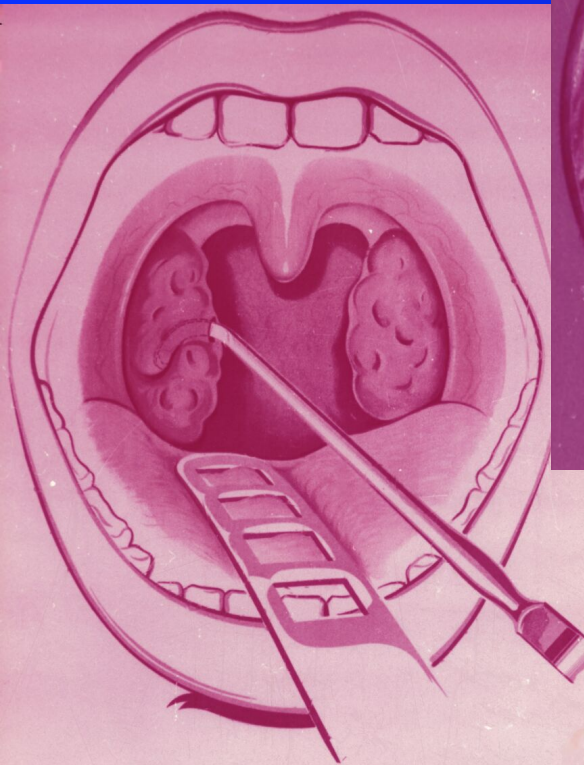
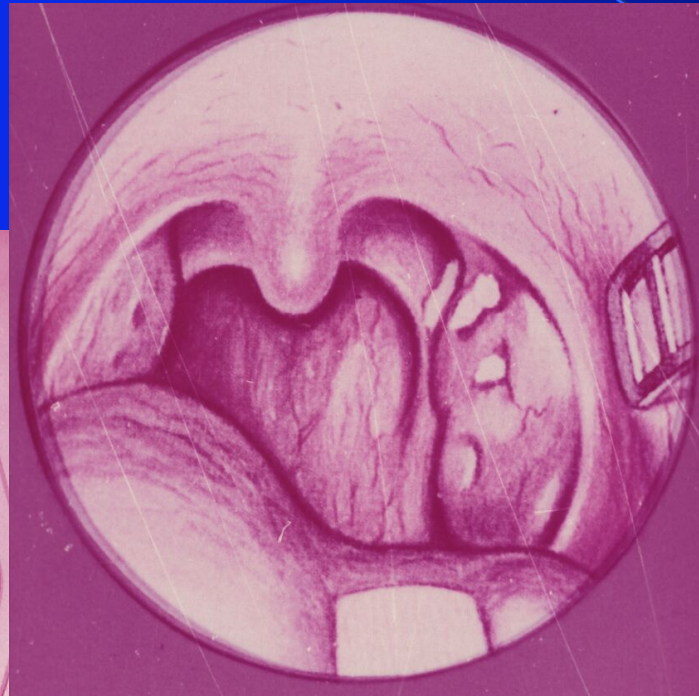
- **Inspection - indirect, direct endoscopy**
- **Palpation**
- **Investigation of innervation**
 - **tongue** motoric innervation (n. hypoglossus – lying tongue -the tip to the sound side, tongue out – to the disease side)
 - **Sensitive**
 - **Sensoric (anterior 2/3 n. V., posterior 1/3 n. IX), elektrogustometry**

Oropharynx- normal finding



Tonsillar pin

the crypts usually contain cell debris, bacteria, lymphocytes - that smell extremely foul when released and can cause bad breath.

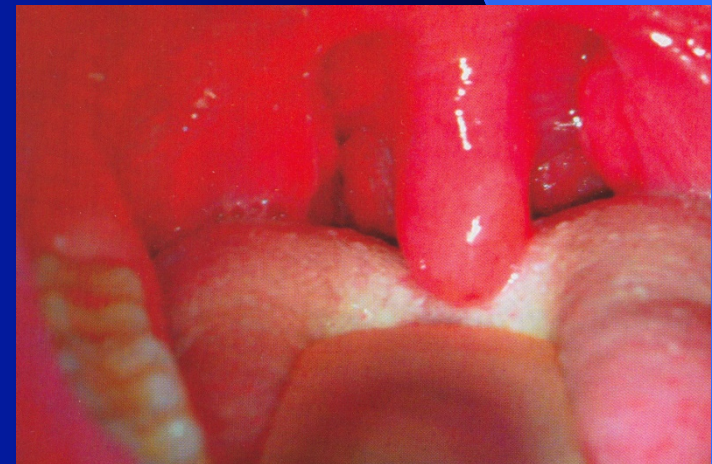

Inflammation of pharynx

- division according to site of disorder
 - **Tonzillitis** inflammation of lymphoepithelial tissue of pharynx.
 - **Pharyngitis** inflammation of mucose membrane of pharynx.
 - **Tonsillo-pharyngitis** inflammation of mucose membrane of pharynx and also lymphoepithelial tissue.

According to course

- **acute**
- **chronic**



Types of tonsillitis according to various criterion

- **Anatomic (site)**
- **Microbiologic**
- **Patogenetic**
- **Pathology- anatomy**

Site of disorder – acute tonsillitis

- **angina palatina**
- **angina retronasalis**
- **angina pharyngis lateralis**
- **angina lingualis**

Microbiology

- **bacterial infection** : 30-40 % of all infections, Streptococcus pyogenes **90%** of bacterial origin, Haemophilus influenzae, Staphylococcus aureus, Mycoplasma pneumoniae
- **viruses** – adenoviruses, parainfluenza, enterovirus, coxsackie, etc.
- **mycosis** – rarely in immunocompromised patients (immunosuppression, HIV, tumors)

Patogenetic division

Acute tonsillitis

- **suppurative**
- **symptomatic – local symptom of general disease with bacteriemia or viremia**
- **Secondary in immunodeficiency (agranulocytosis, leukemia etc.)**

Pathology-anatomy

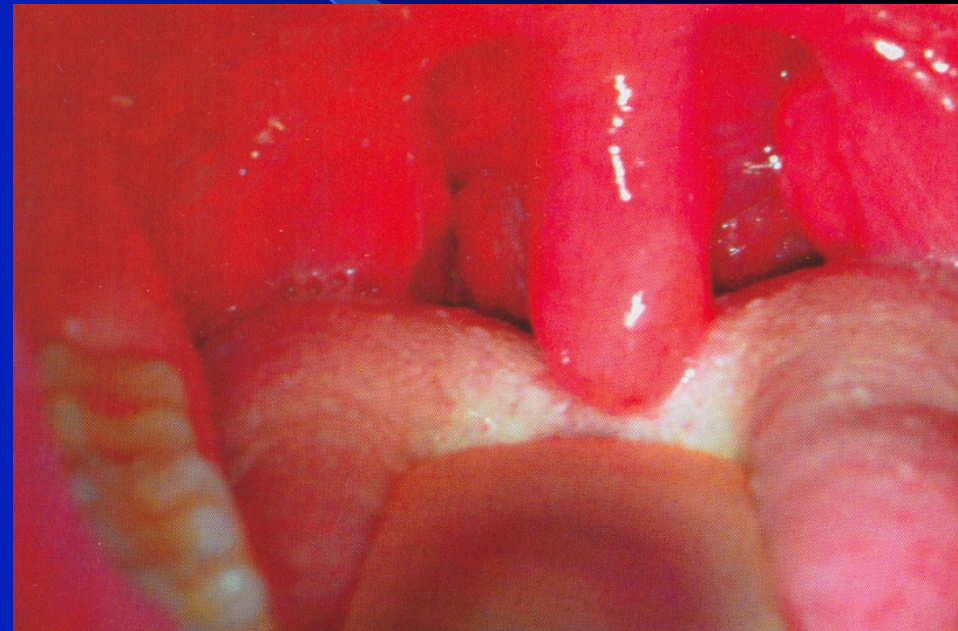Acute tonsillitis

- **catarrhal**
- **lakunar**
- **Follicular**
- **Vesiculous**
- **Pseudomembranous
ulceromembranous**
- **Phlegmonous and gangrenous**

Tonsillitis ac. catarrhal

Bilateral odynophagy

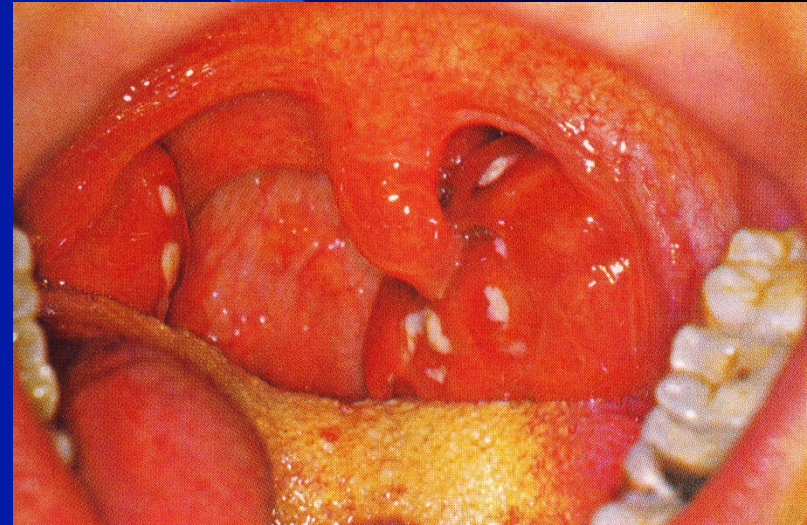
redness, swelling of
tonsils, febris



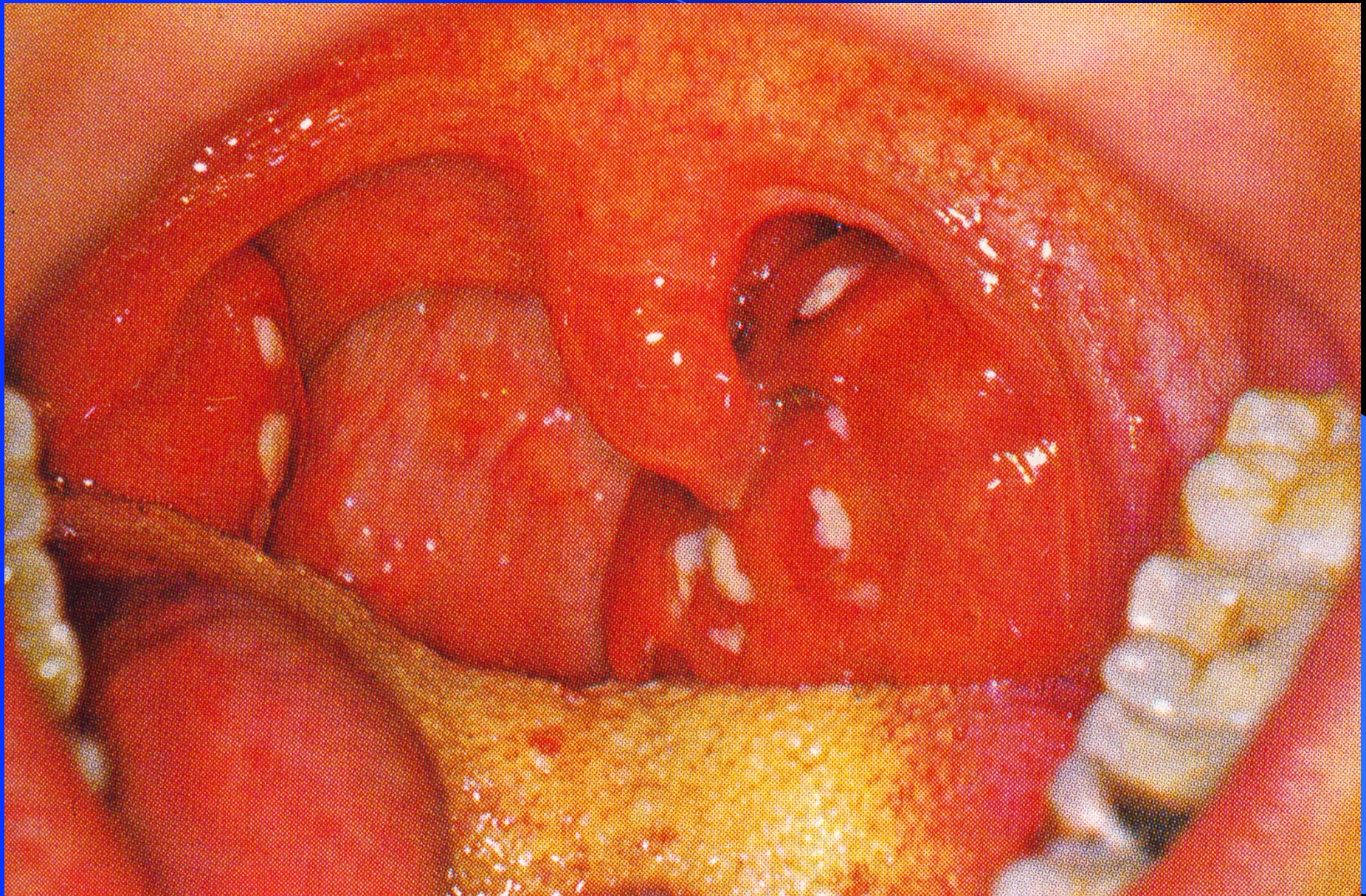
Tonsillitis ac. lacunar

Bilateral odynophagy,
increasing in swallowing,
irradiated into ears

infiltrated, reddened,
enlarged tonsills with
plagues in opening of
tonsillar crypts,
sometime confluenting
(*angina confluens*), not
spreading to tonsillar
pillars, fever

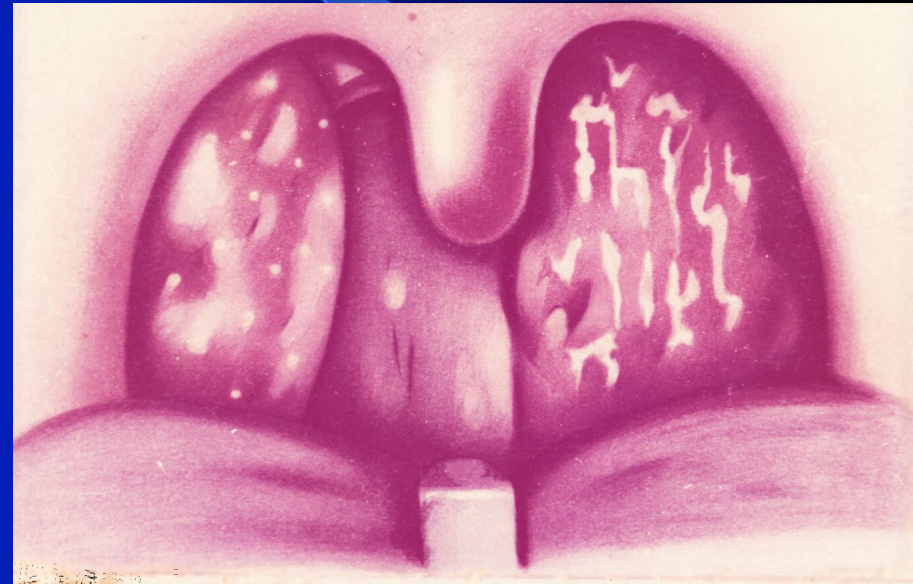


Tonsillitis ac. lacunaris



Tonsillitis ac. follicular

Bilateral odynophagy,
increasing in
swallowing,
irradiated into ears
microabscessus in
follicles visible
through mucosa
membrane on the
tonsillar surface

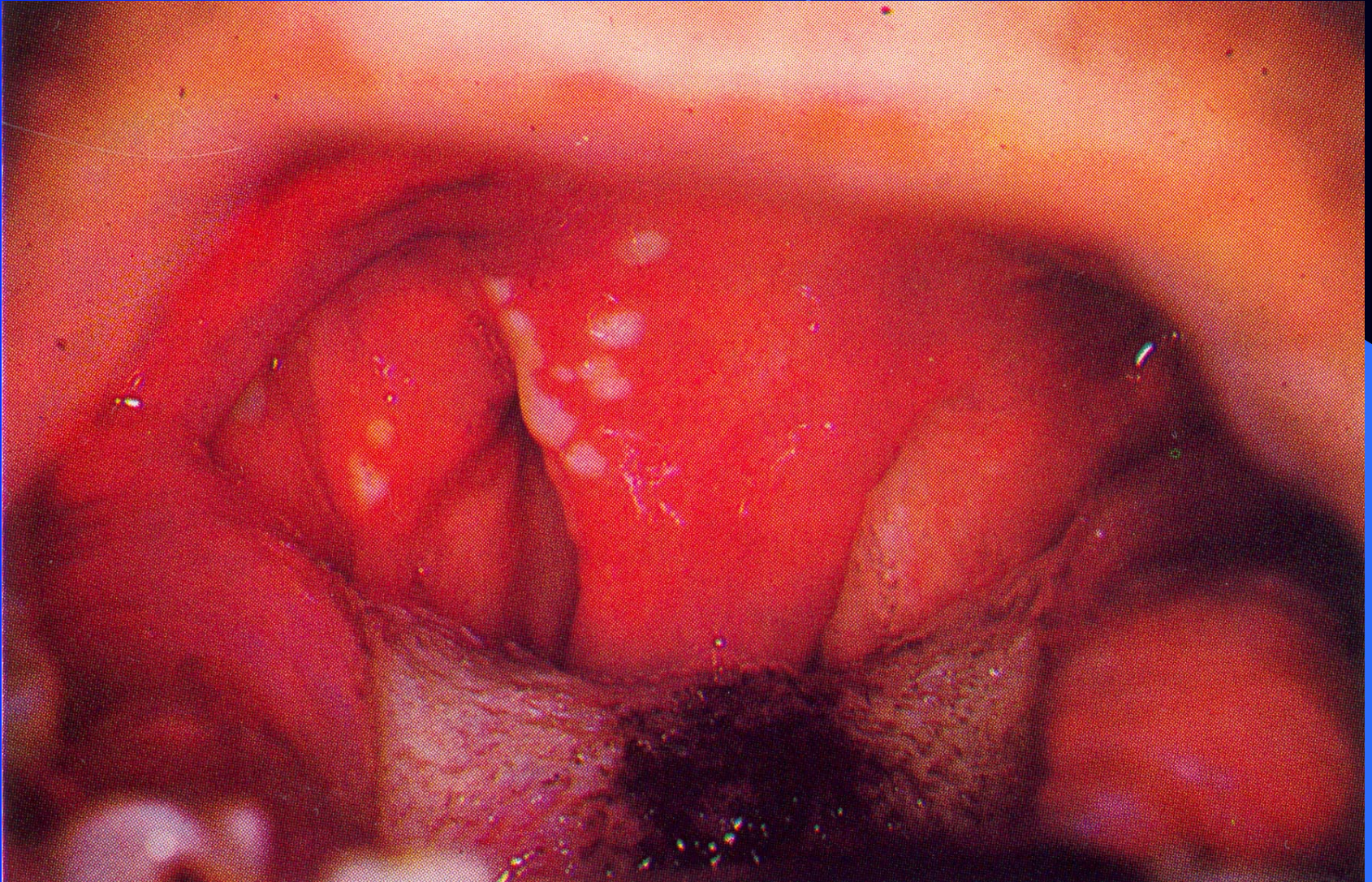


Herpangina (angina vesiculosa) - Coxsackie virus

Marked generalized symptoms, such as high fever, headache, pains in the neck, loss of appetite, stomatitis, vomiting

Vesicles form initially, particularly on the anterior faucial pillar, then small flat ulceration covered in milky white plaques,

Herpangina



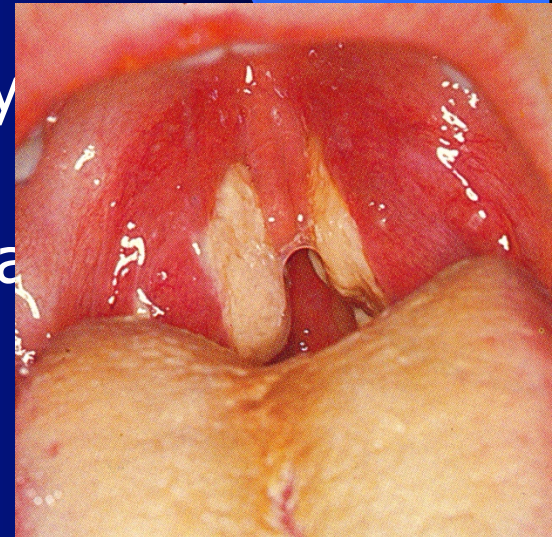
Pseudomembranous tonsillitis (in mononucleosis infectiosa)

Epstein-Barr virosis

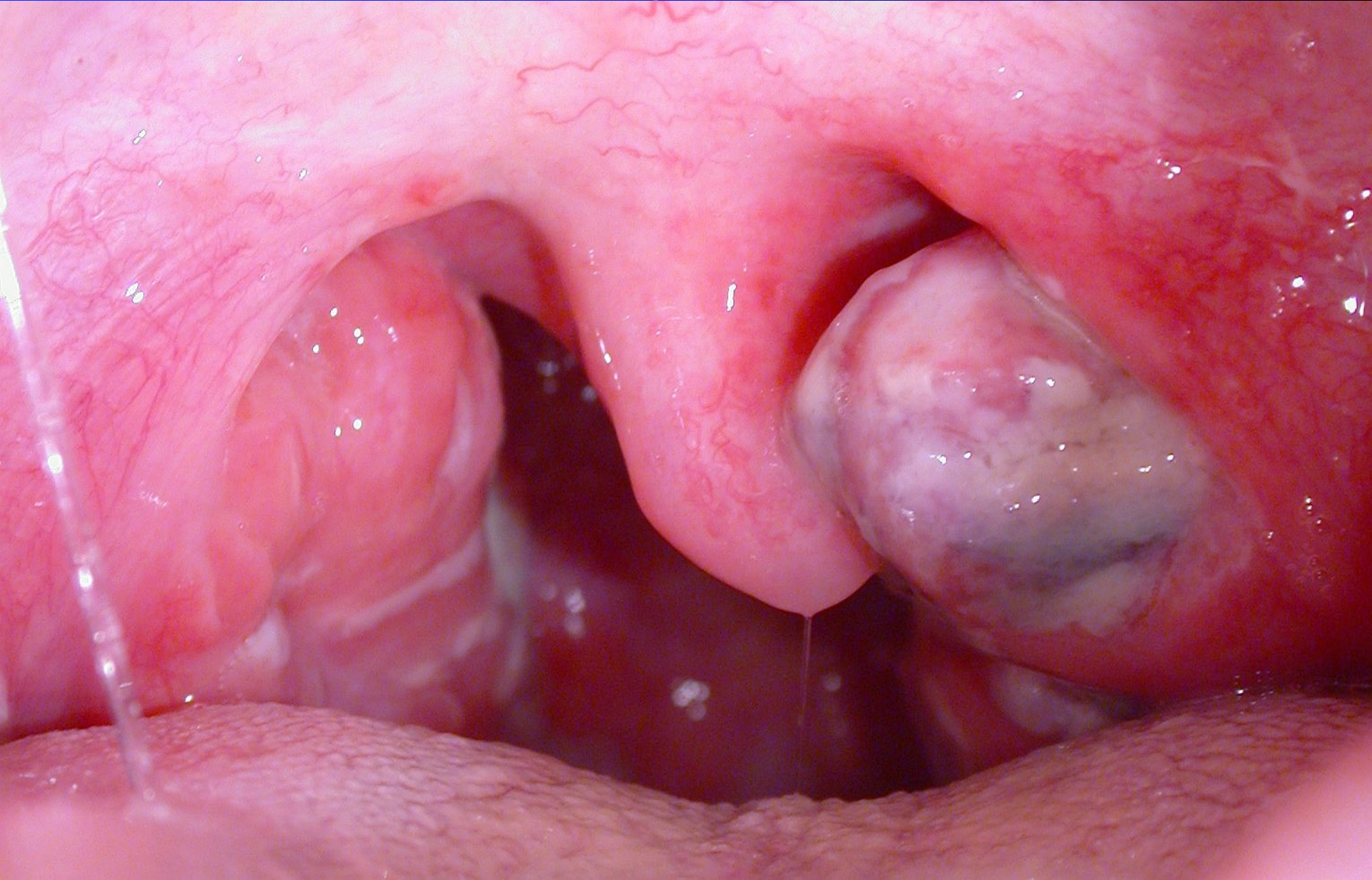
Bilateral odynophagy, headache

fever 38-39, marked lymphadenopathy, tonsil is swollen, covered with a fibrinous exudate or membrane, hepatosplenomegaly, marked feeling of being unwell, leukocytosis, mononuclear cells and atypical lymphocytes

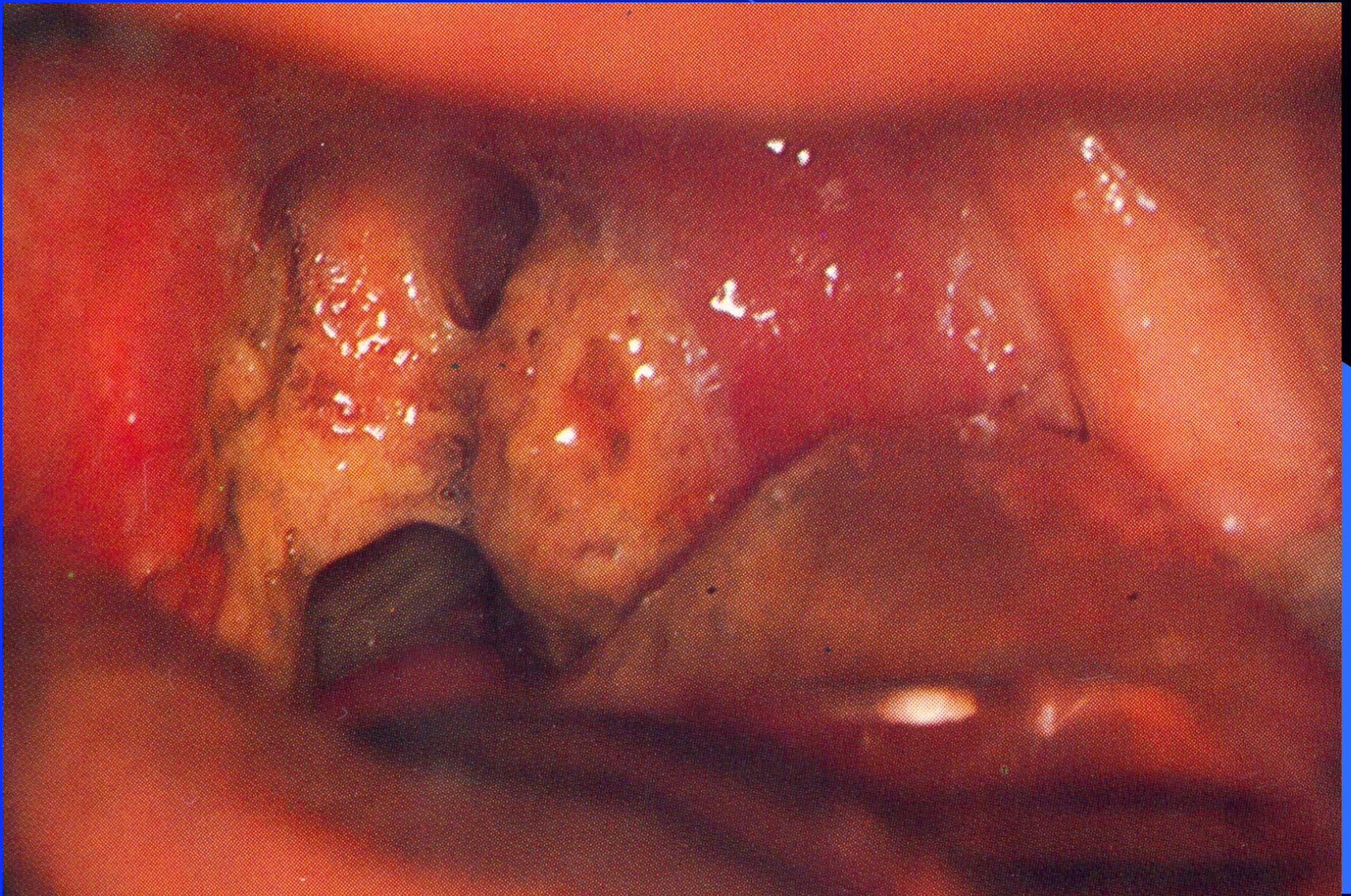
Higher transaminasis (ALT,AST), positive antibody against EB virus and positive Paul Bunnell reaction.



Pseudomembranos tonsillitis



Pseudomembranos tonsillitis



Tonsillitis ac. retranasal

Pain feeled in depth behind the nose,
blocked nose, running nose

Closed mumbleness, hearing disorder
(bad functio of Eustachian tube), pus
in posterior wall of oropharynx

Tonsillitis ac. of the tongue

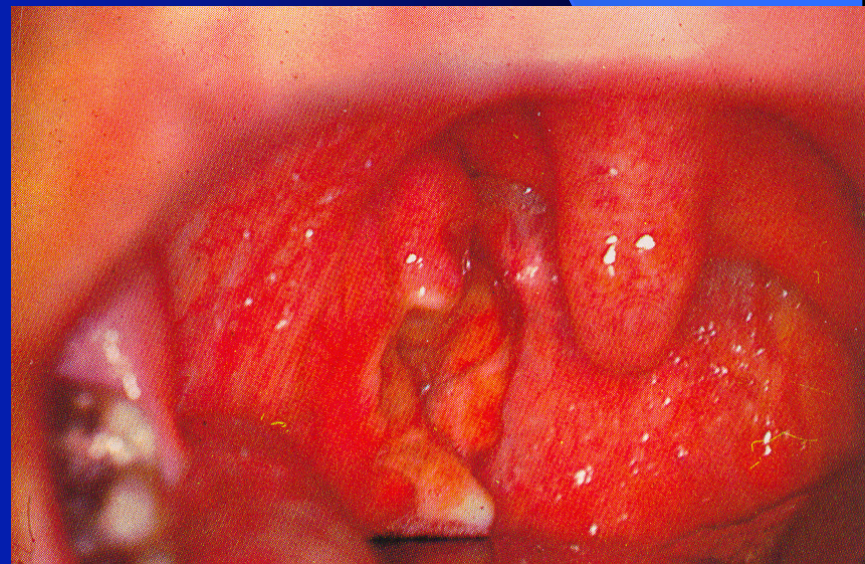
odynophagy increasing with movement of tongue

in laryngeal mirror- the finding as in tonsillitis ac. lacunaris

Plaut-Vincent angina

feeling of foreign body, scratching, no general symptoms

in superior part of one tonsill ulceration covered with a gray membrane, halitosis (foetor ex ore), bad teeth bakteriologi: *Bacillus fusiformis* and *Spirocheta buccalis*,



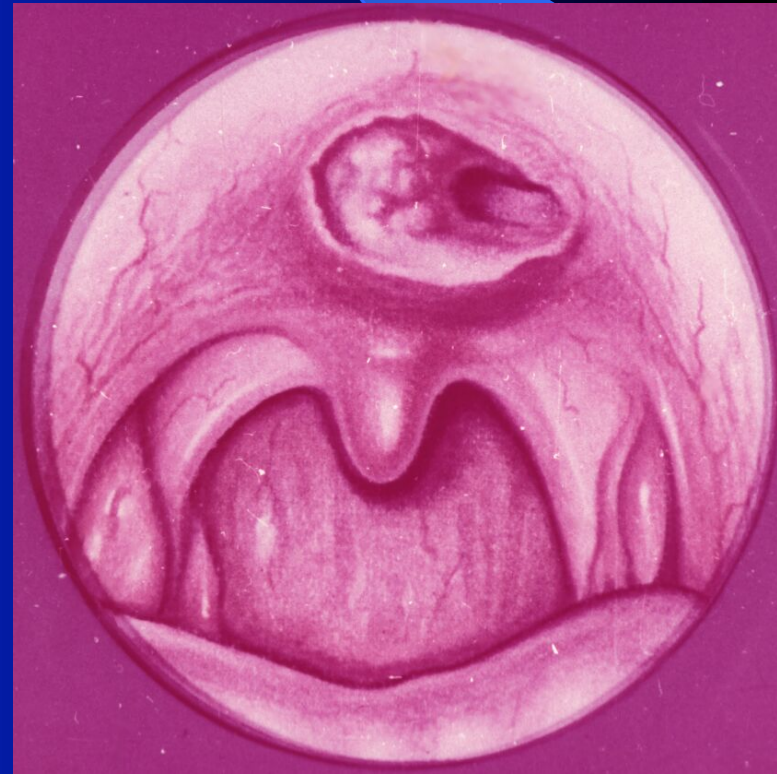Syphilis, Lues

primary ulcer gray coated

syphilitic angina mucous plaques or hazy, smoke-colored mucosal lesions

gummose stage swelling with ulceration

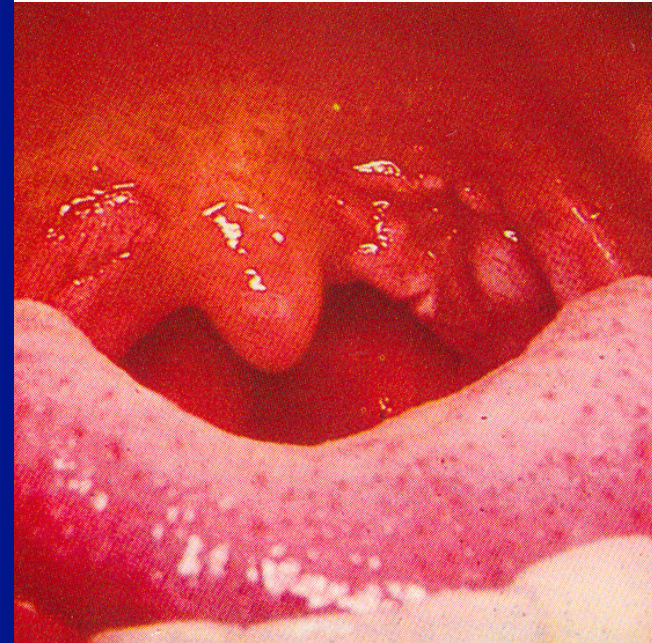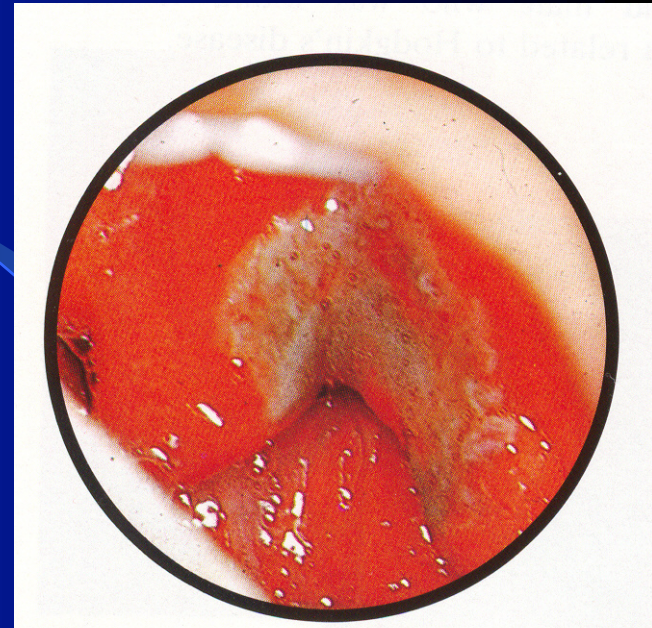
typical bacteriology, serology
and histology evaluation



Lues

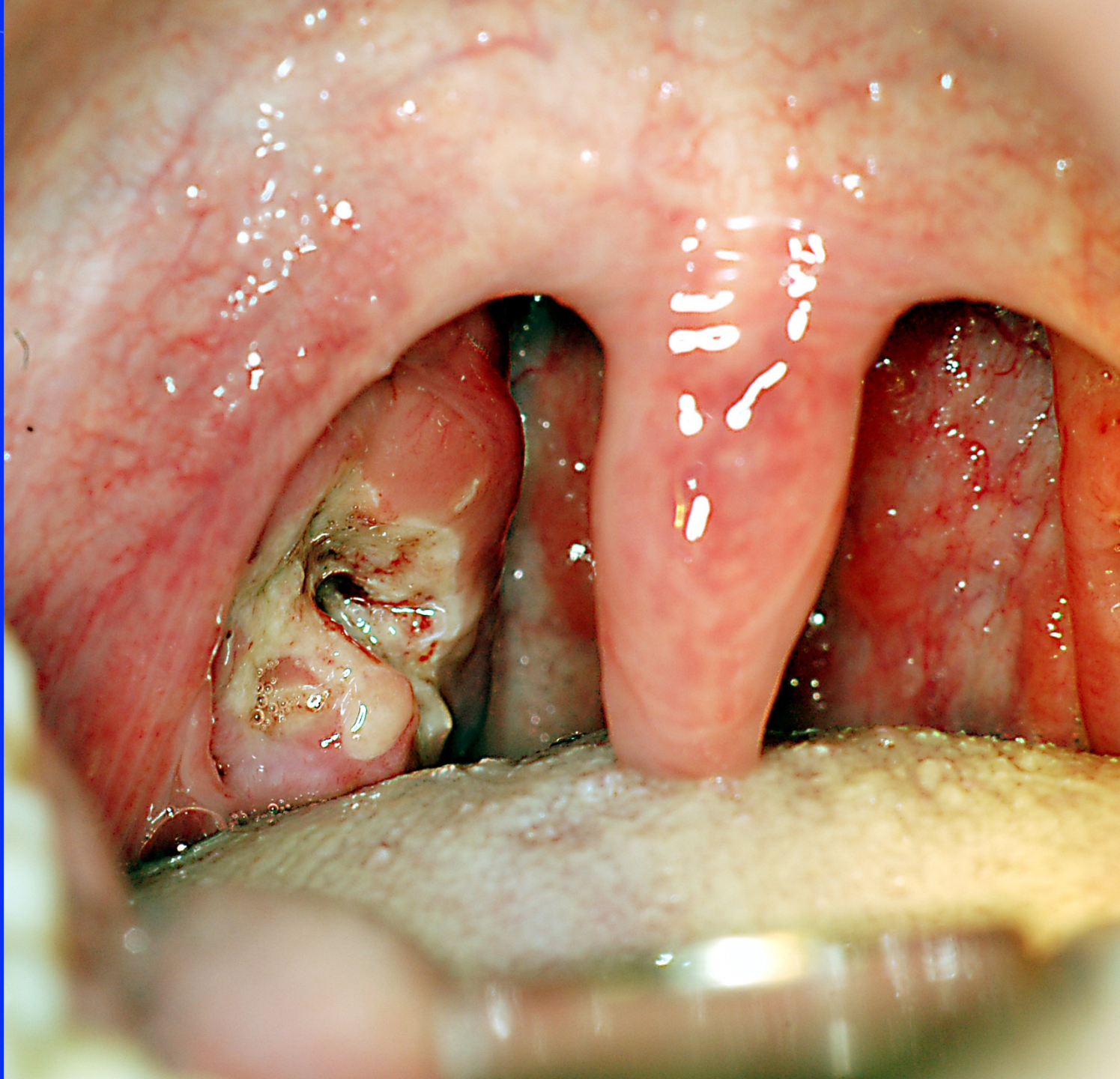primary ulcer on soft palate in 21
old male

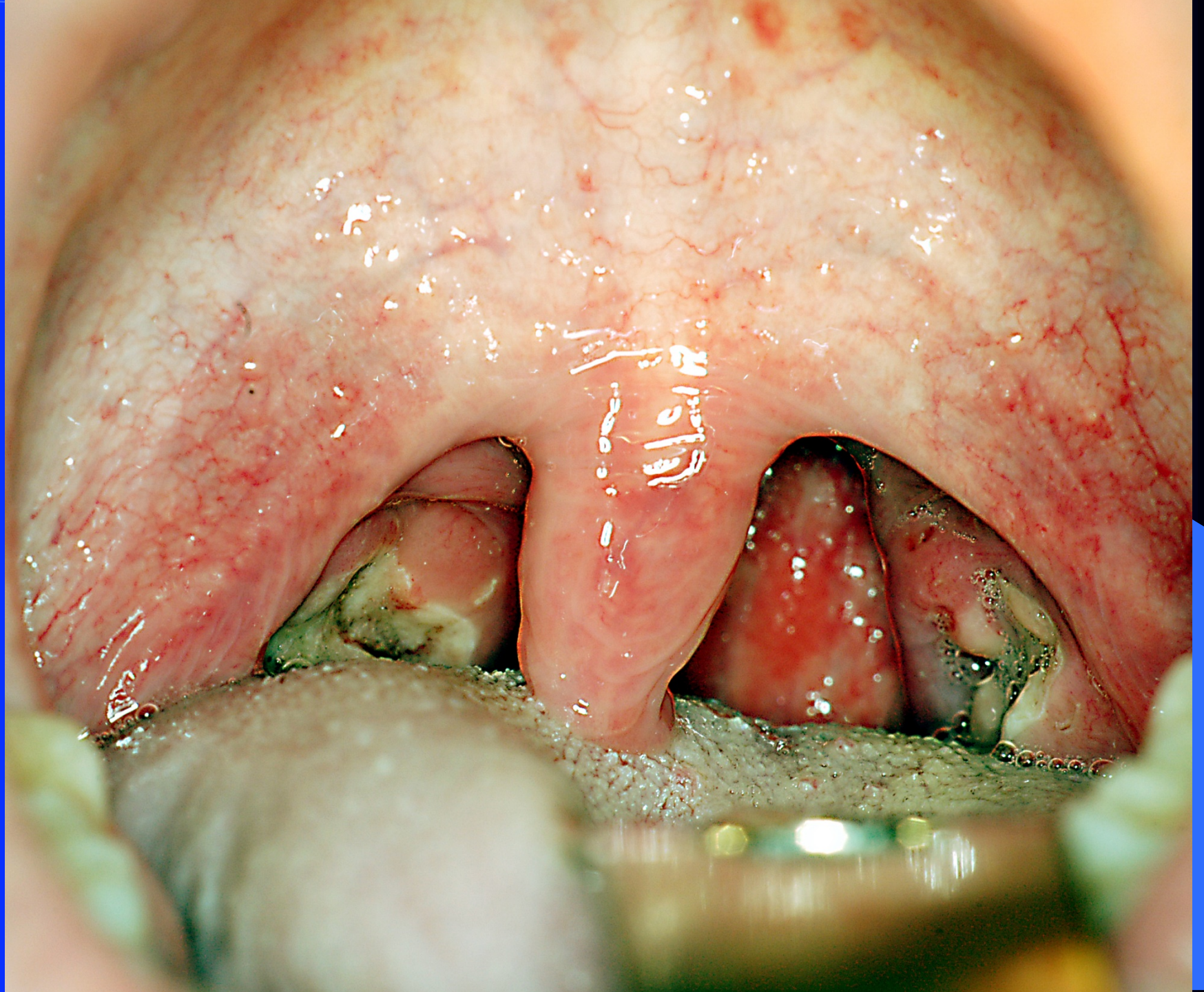syphilitic angina mucous
plaques



**Syphilis
II. st.
pharynx
male
29 let**

**cook in
public
catering**



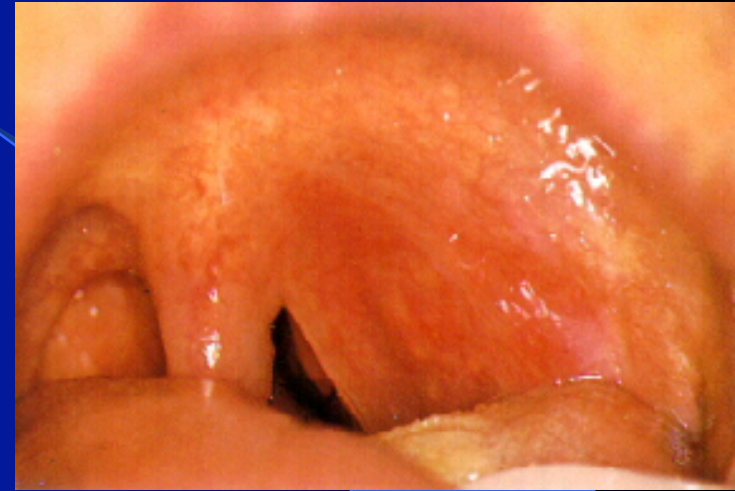

Primary source: pharynx

Abscessus et phlegmona peritonsillaris

Abscessus et phlegmona parapharyngealis

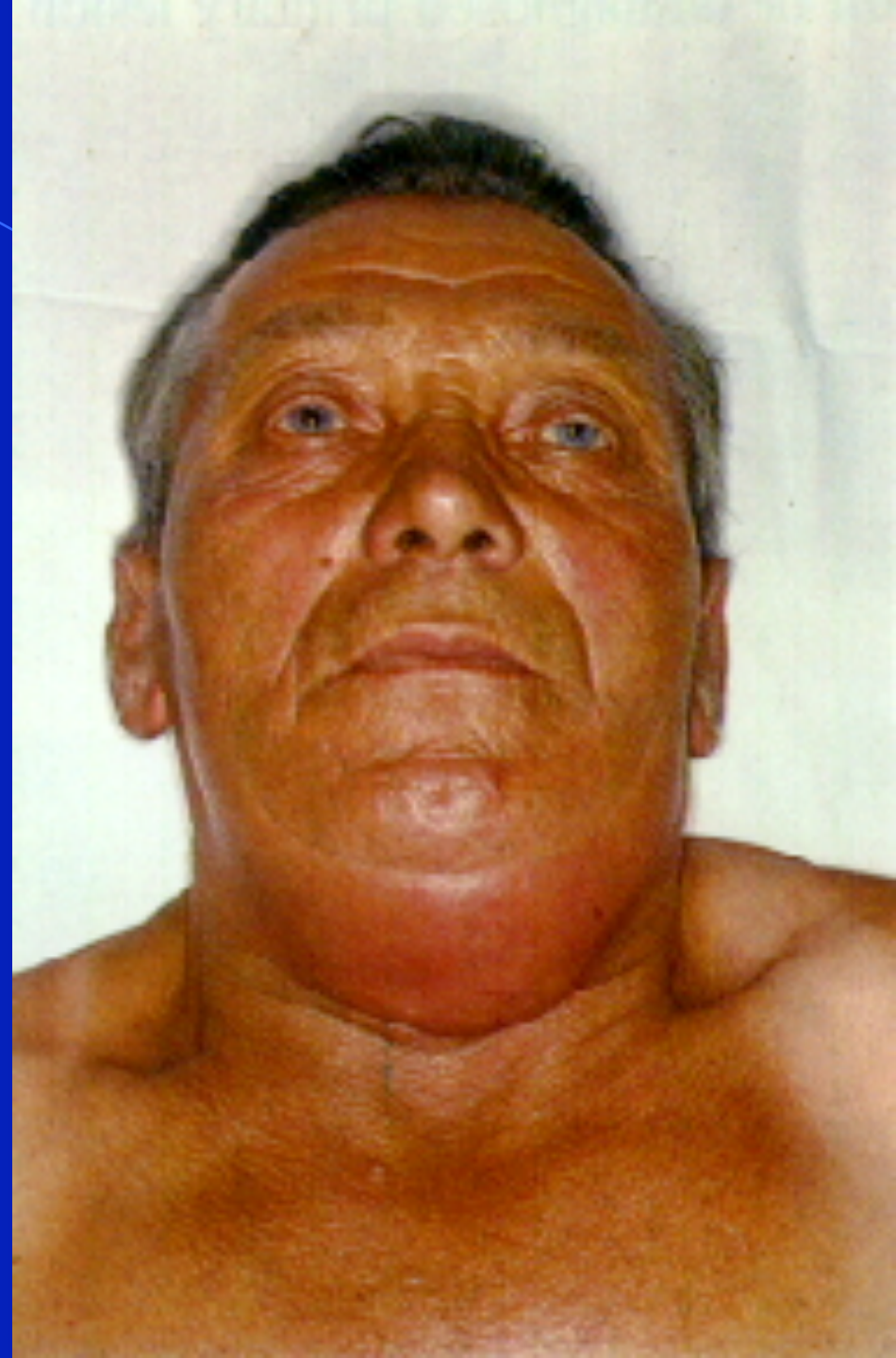Sepsis tonsillogenes (angina septica, sepsis post anginam, trombophlebitis v. jug. int.)



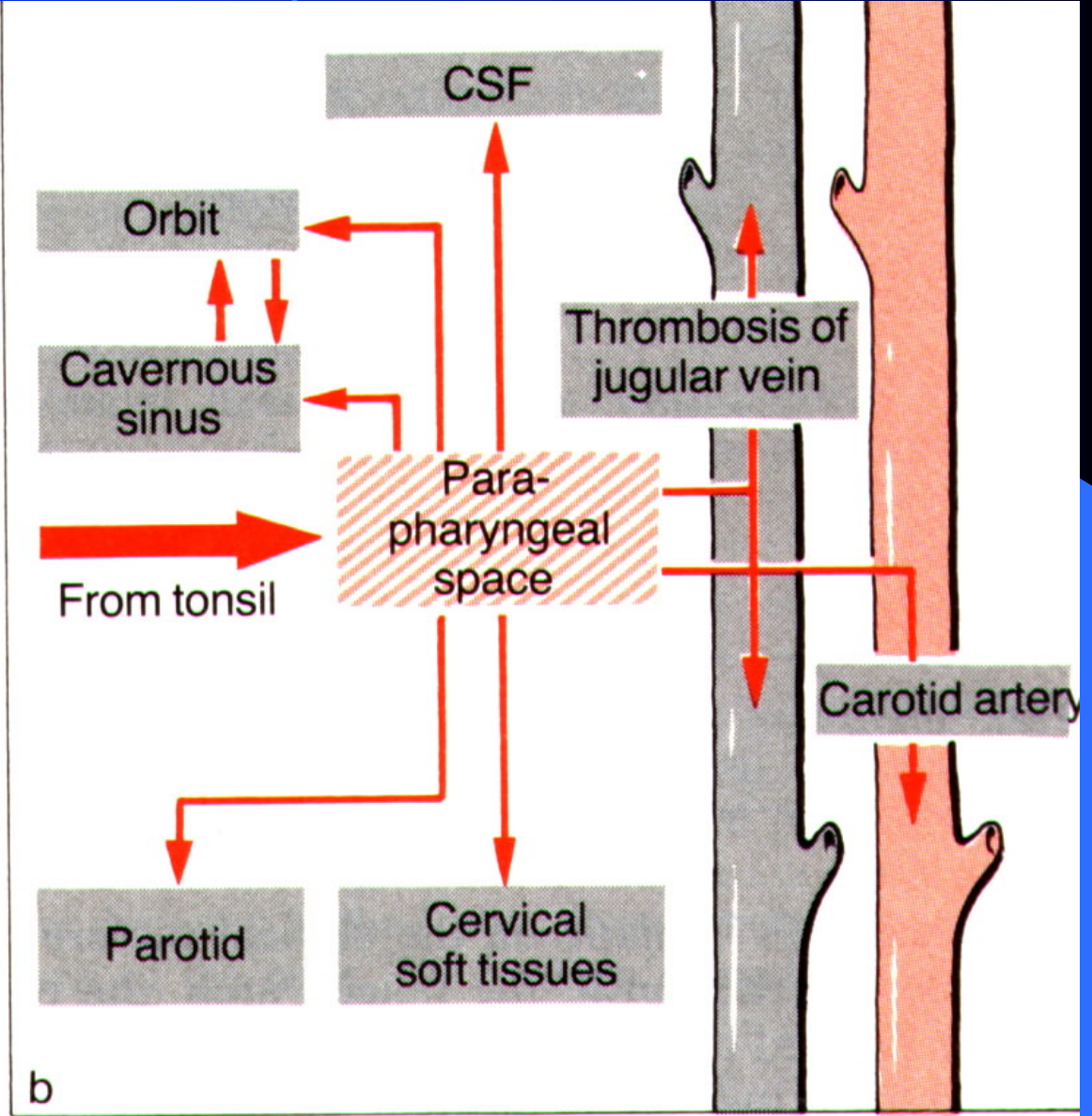
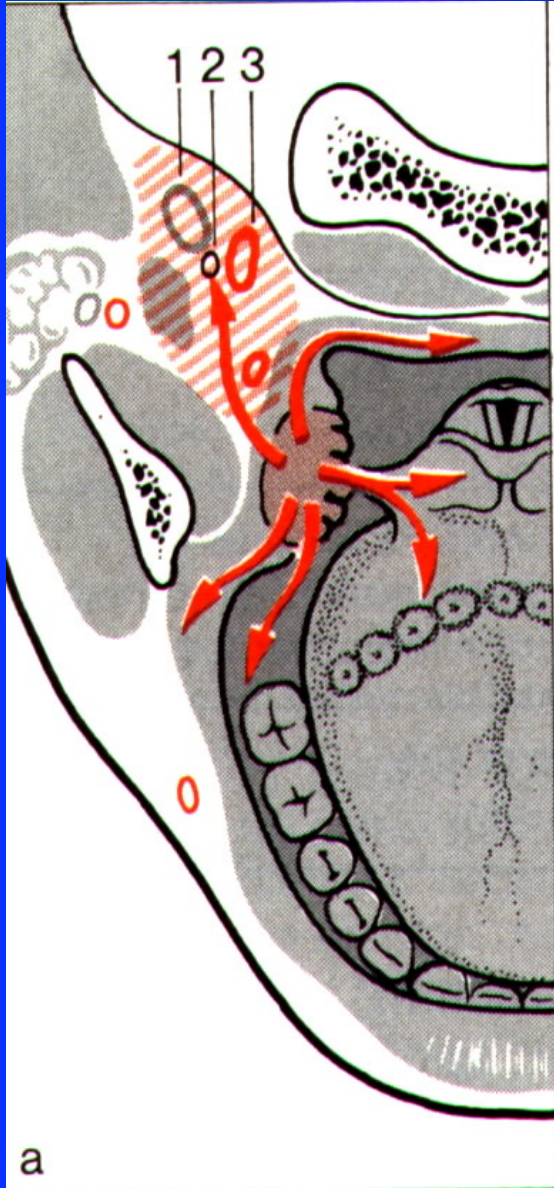
Phlegmona base of the oral cavity „Angina Ludowici“

tongue pain, odynophagy,
fever with shivering fit,
symptoms of sepsis

elevation of base of oral
cavity, tongue not moving,
infiltration in submandibular
region



Complications during and after tonsillitis



Phlegmona et abscessus peritonsillaris

- Localisation - supratonsillar, retrotonsillar, infratonsillar, lateral
- Increasing difficulty in swallowing occurs after a symptomfree interl of a few days after tonsillitis
- Fever not too high
- Sever pain to to diseased side, spreading to the ear, patient refuses to eat,
- Differentila diagnossis :tonsilogenic sepsis, dentitio diffitilis tertii mollaris inferioris
- Treatment- punctio, incisio, dilatation, antibiotics

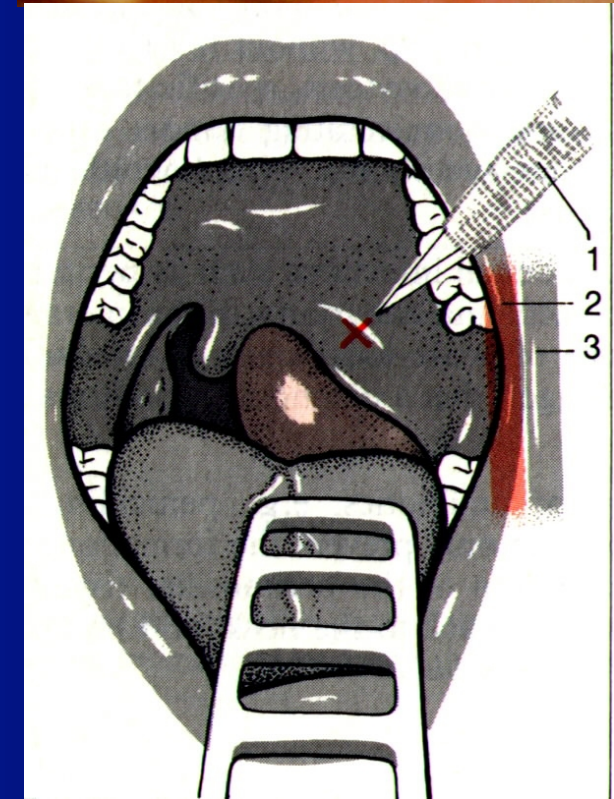
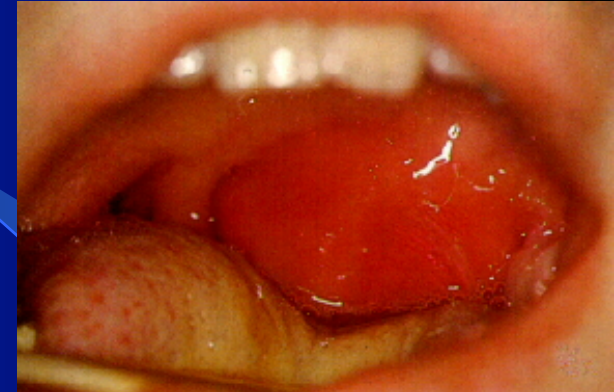Peritonsillar phlegmon and abscess

Clinical picture of swelling, redness and protrusion of the tonsil, faucial arch, the palate and the uvula, marked tenderness of the tonsillar area, trismus

Typical side for incision:

X midpoint between the uvula and the last molar

- 2) Arteria carotis interna
- 3) Vena jugularis int.



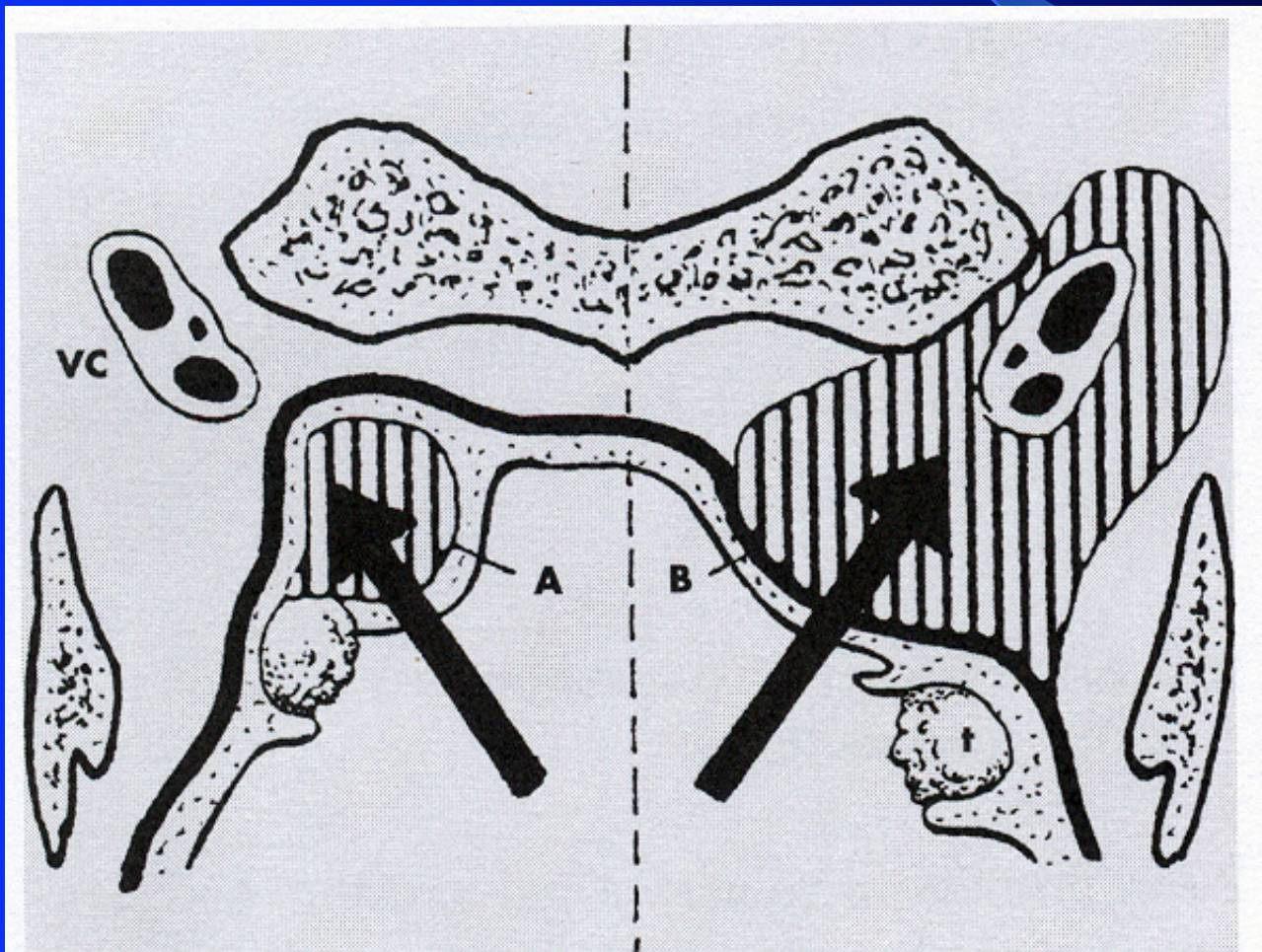
Phlegmona and parapharyngeal abscess

- Spreading infection from tonsill into the parapharyngeal space
- Fever, pain, trismus, torticollis, swelling of external neck, swallowing of hypopharynx
- Risk of infection spreading into the mediastinum
- treatment – incision, drainage of infection focuses, antibiotics – broad spectrum in sufficient dosage

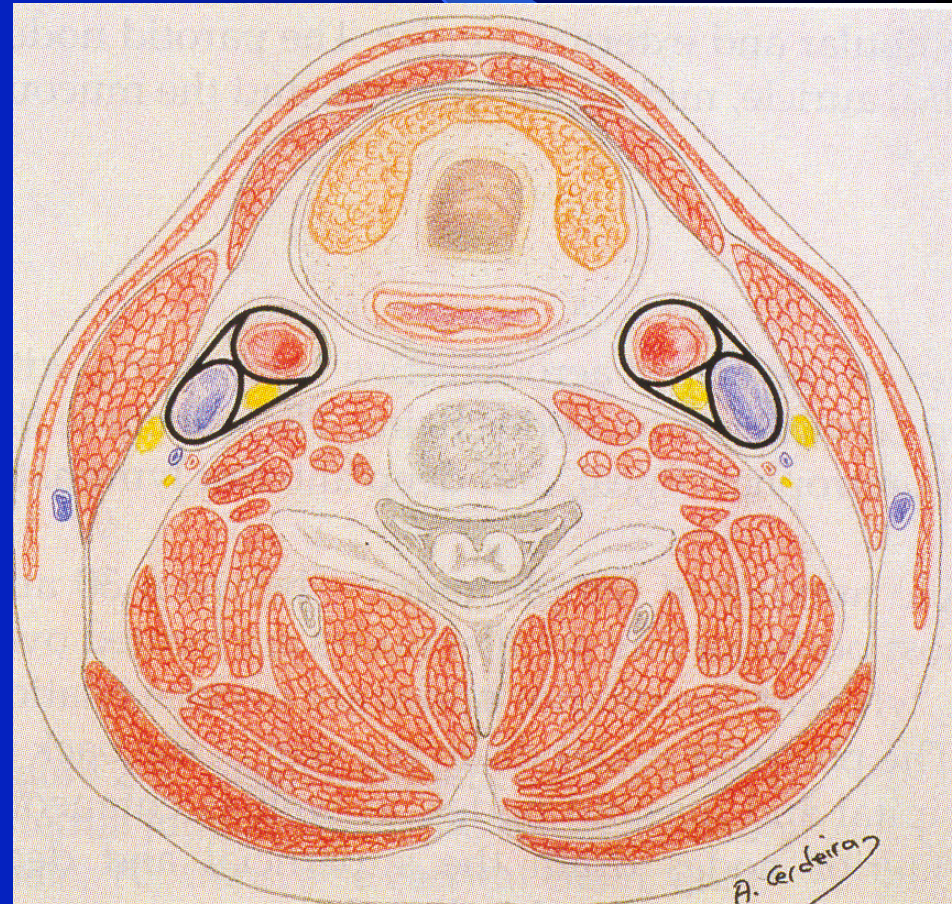
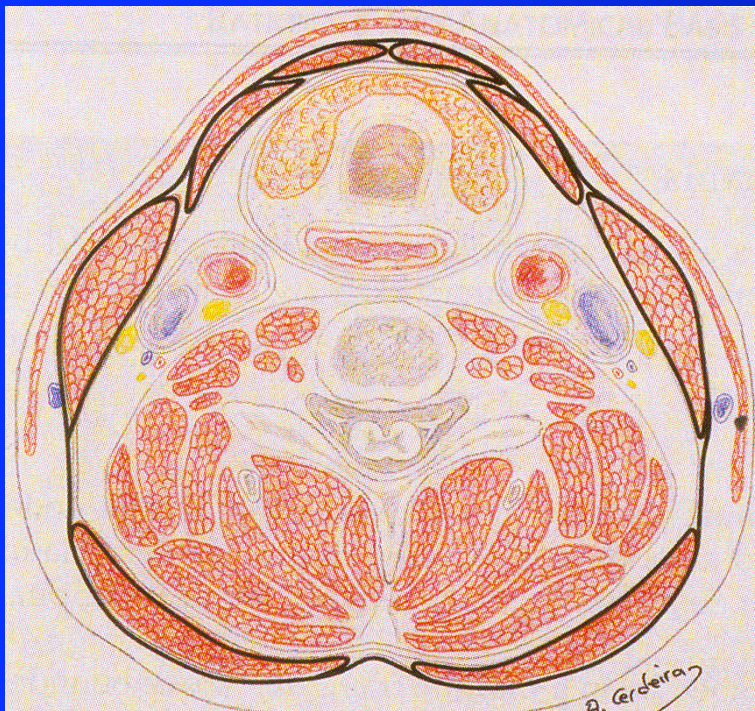
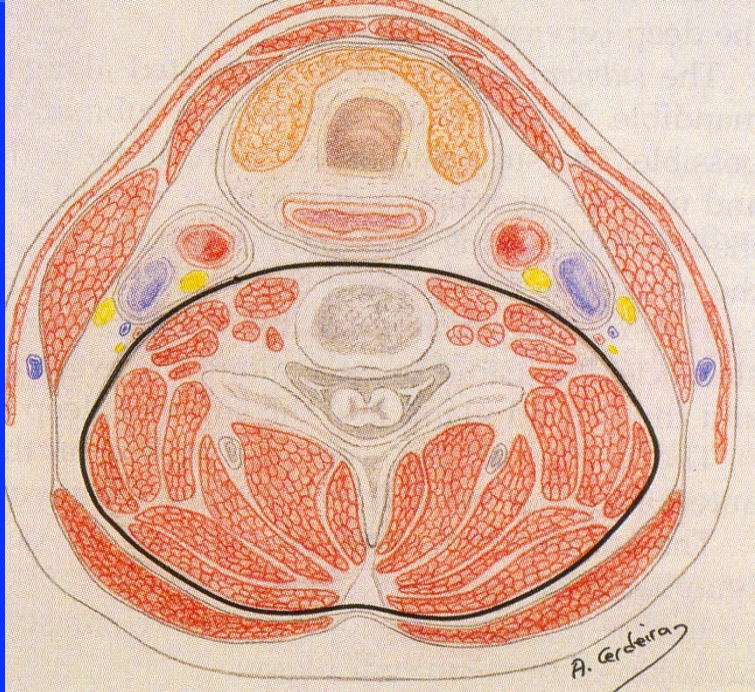
A. Retrotonsilar abscess

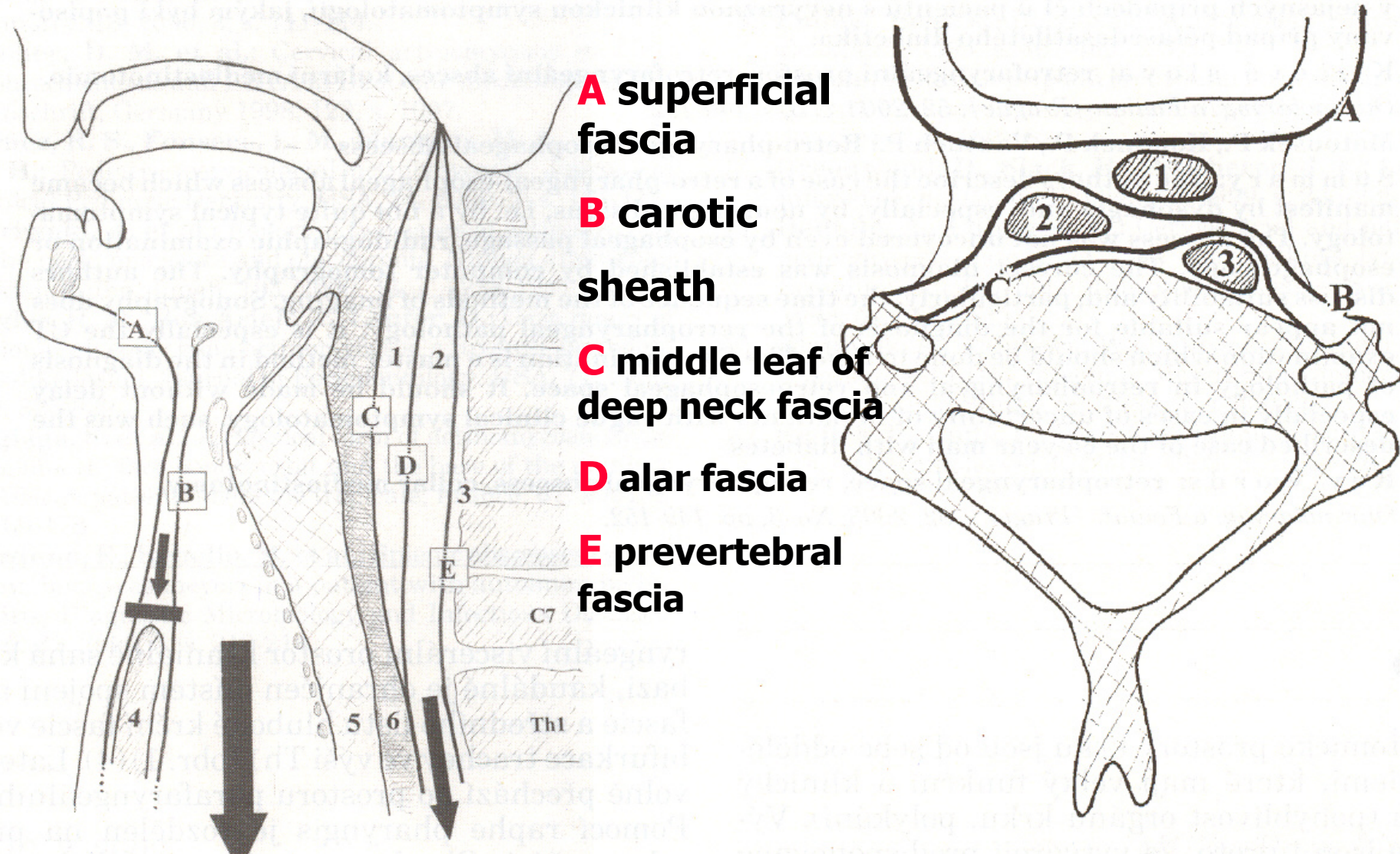
B. peripharyngeal abscess

VC = great vessels



Carotid sheath between deep and superficial cervical fascia



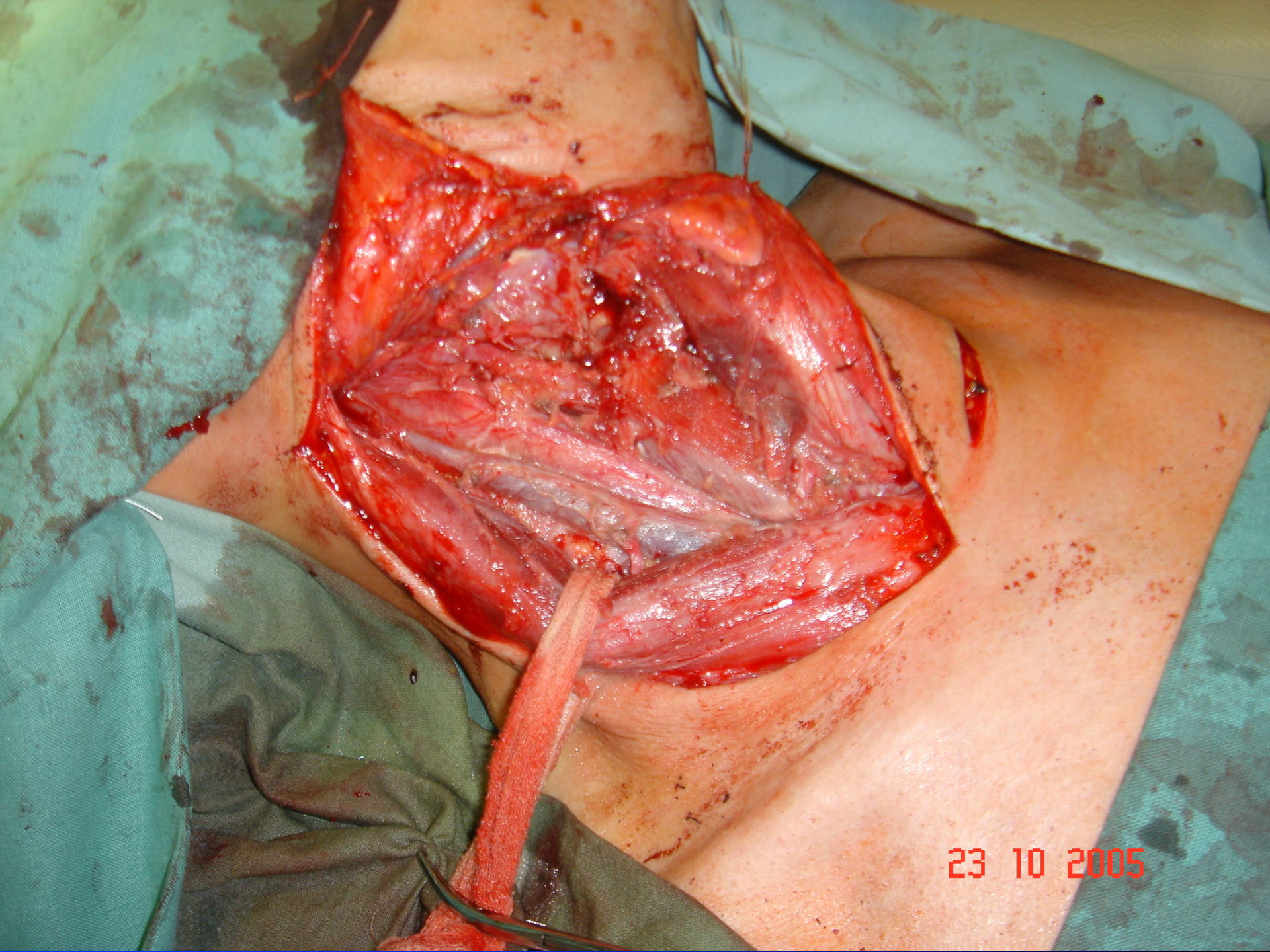


Neck fascial spaces

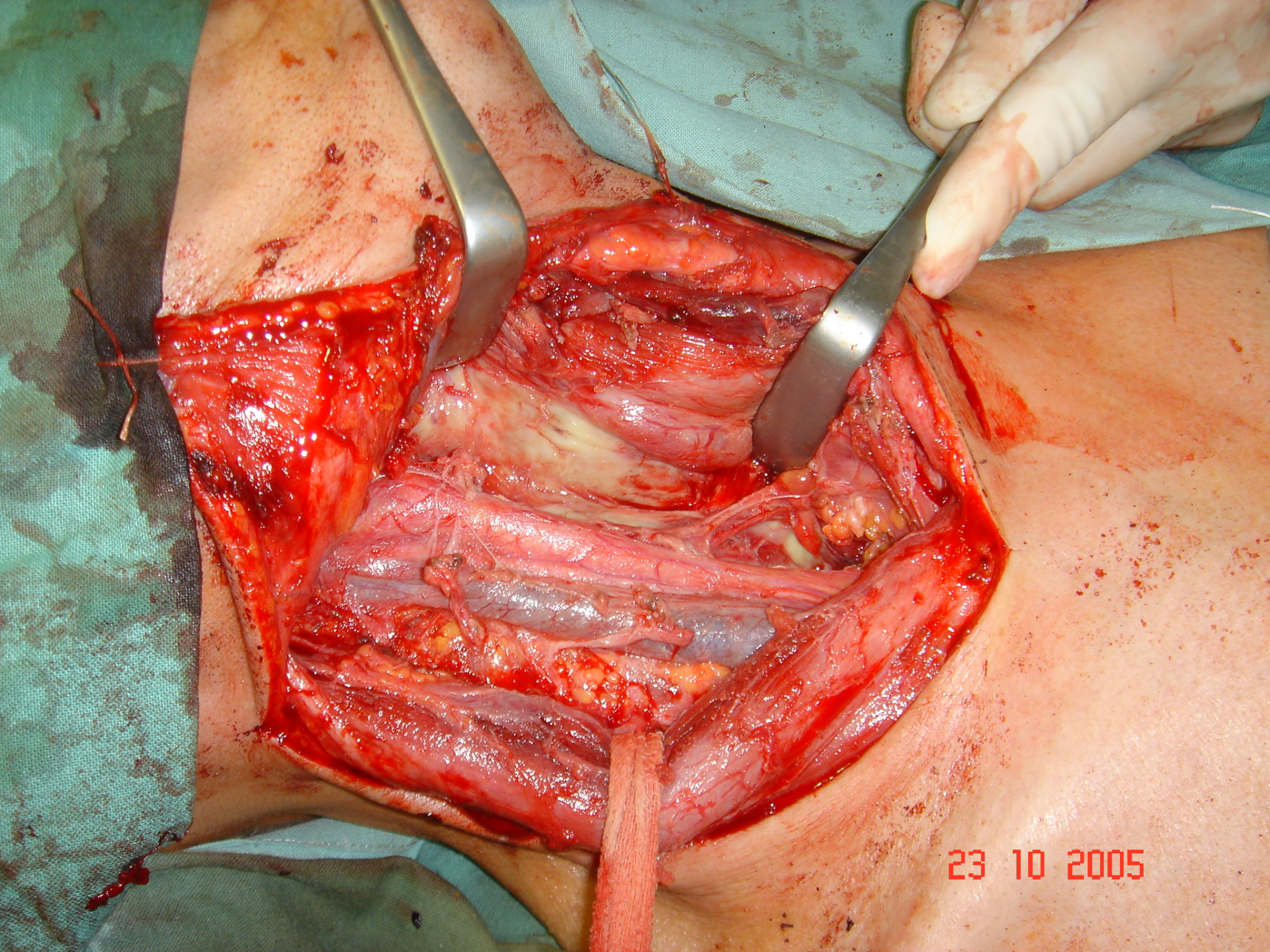
1. abscess in retropharyngeal space, 2. in „dangerous space, 3. in prevertebral space.

Phlegmona colli, Mediastinitis

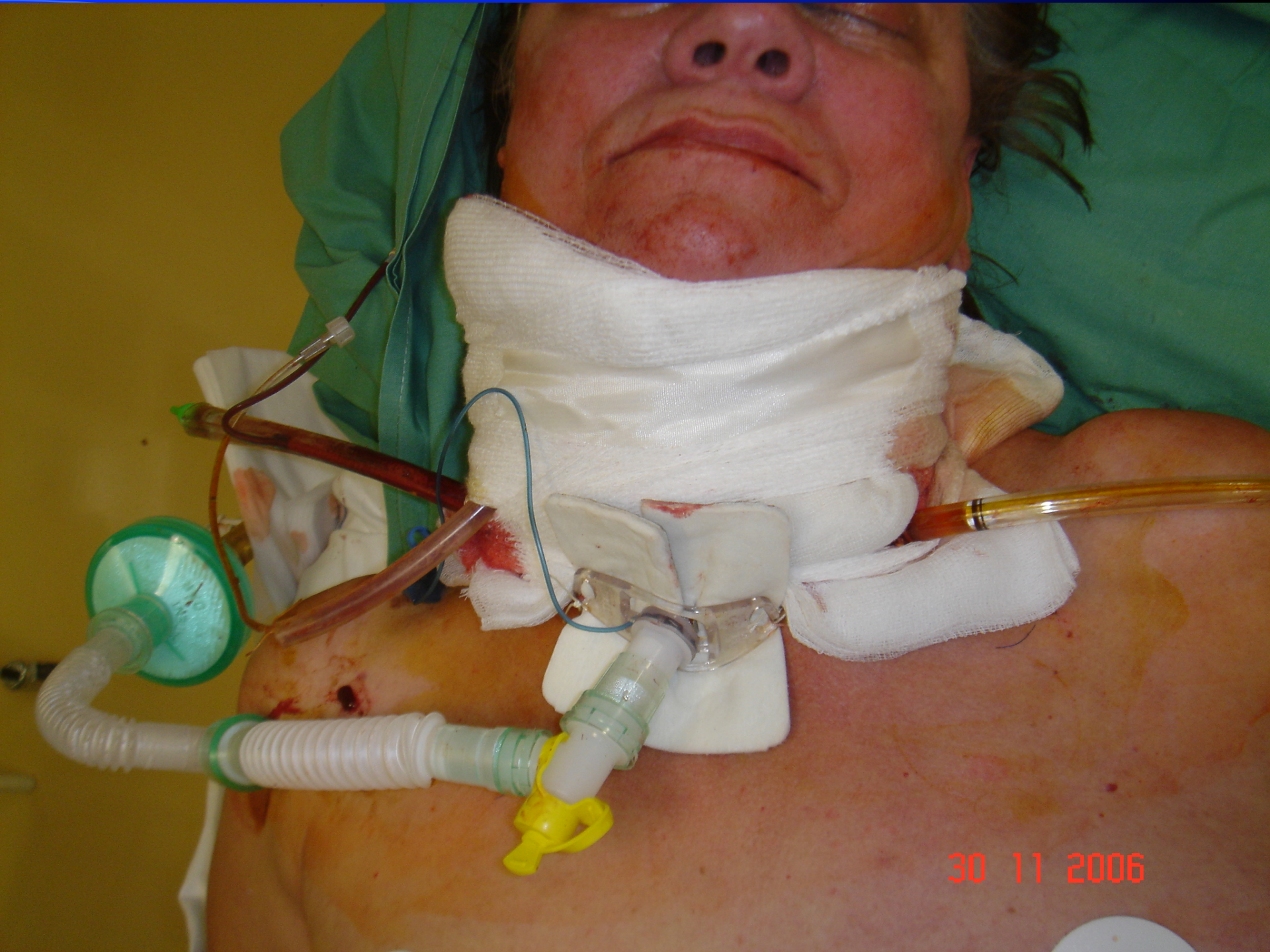- ➔ **Source** –infection of paratonsillar a retromoral region, injury of oral cavity base, pharynx or cervical oesophagus. Visceral spaces of the neck have no distal boundary with mediastinum.
- ➔ **Clinical picture** – fever, usually septic, dysphagia, pain in the back (intrascapular), retrosternal pain
- ➔ **Inflammatory infiltration of the neck without boundary, fluctuation, speciall palpation feeling; by spread into the mediastinum – dysphagia and even dyspnoe**
- ➔ **Treatment** – surgical opening of space surrounding great neck vessels, collateral mediastinotomy, treatment of primary source, general treatment aimed against sepsis, thrombosis, kidney failure etc.
- ➔ **Bad prognosis, high mortality**



23 10 2005



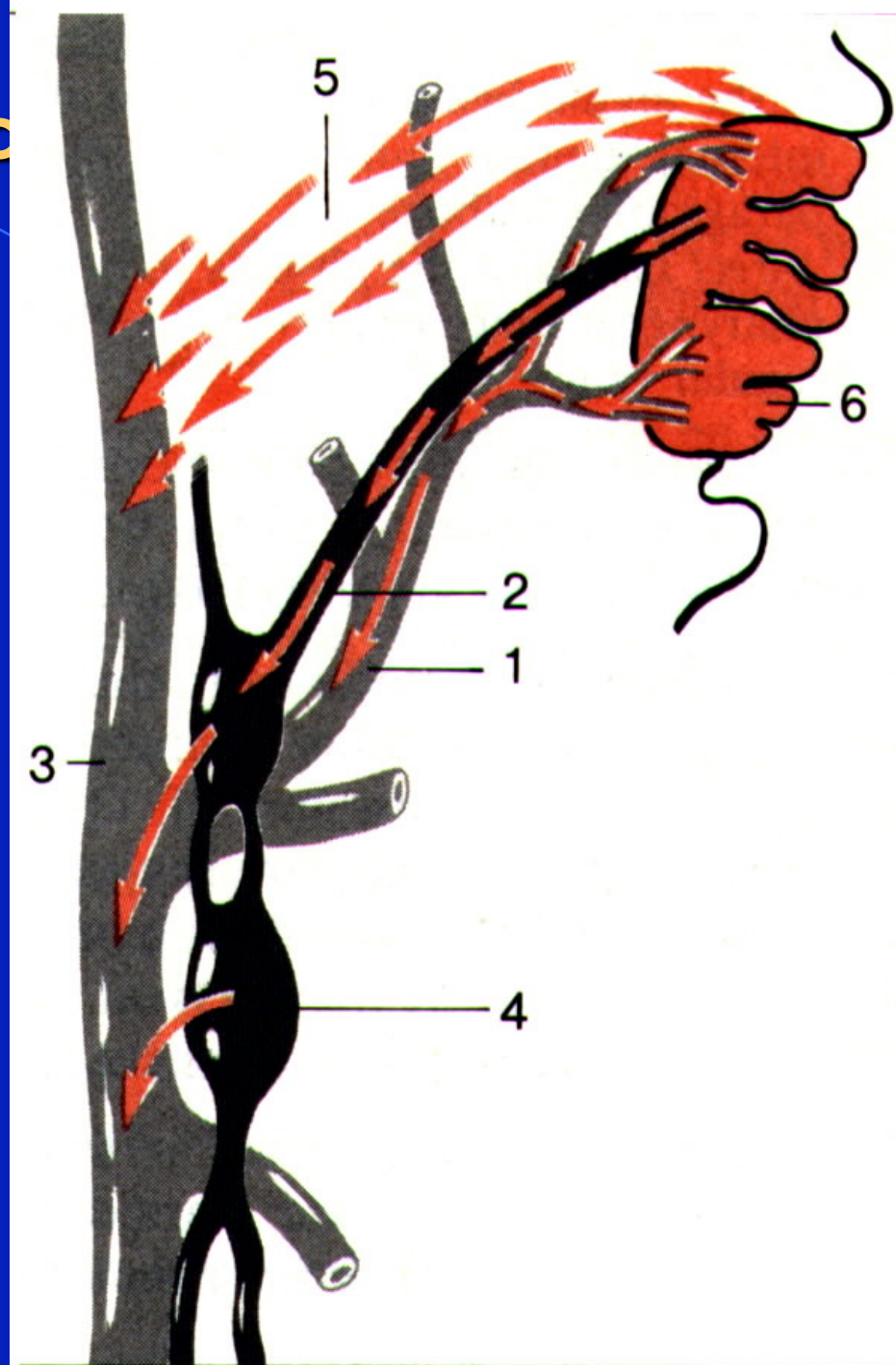
23 10 2005



30 11 2006

Genesis of tonsillogenic sepsis

- 1) Extention by **veins**
- 2) Extention by **lymph vessels**
- 3) Internal jugular vein
- 4) Regional lymph nodes around the VJI
- 5) Extention in continuity via the **cervical soft tissue**



Sepsis tonsillogenes

Angina septica – trombophlebitis of small veins occurring during tonsillitis – spreading into internal jugular vein, and . Symptoms: fever, shivering fit, palpation pain before anterior edge of sternocleidomastoid muscle. Possibility of spreading into the intracranium

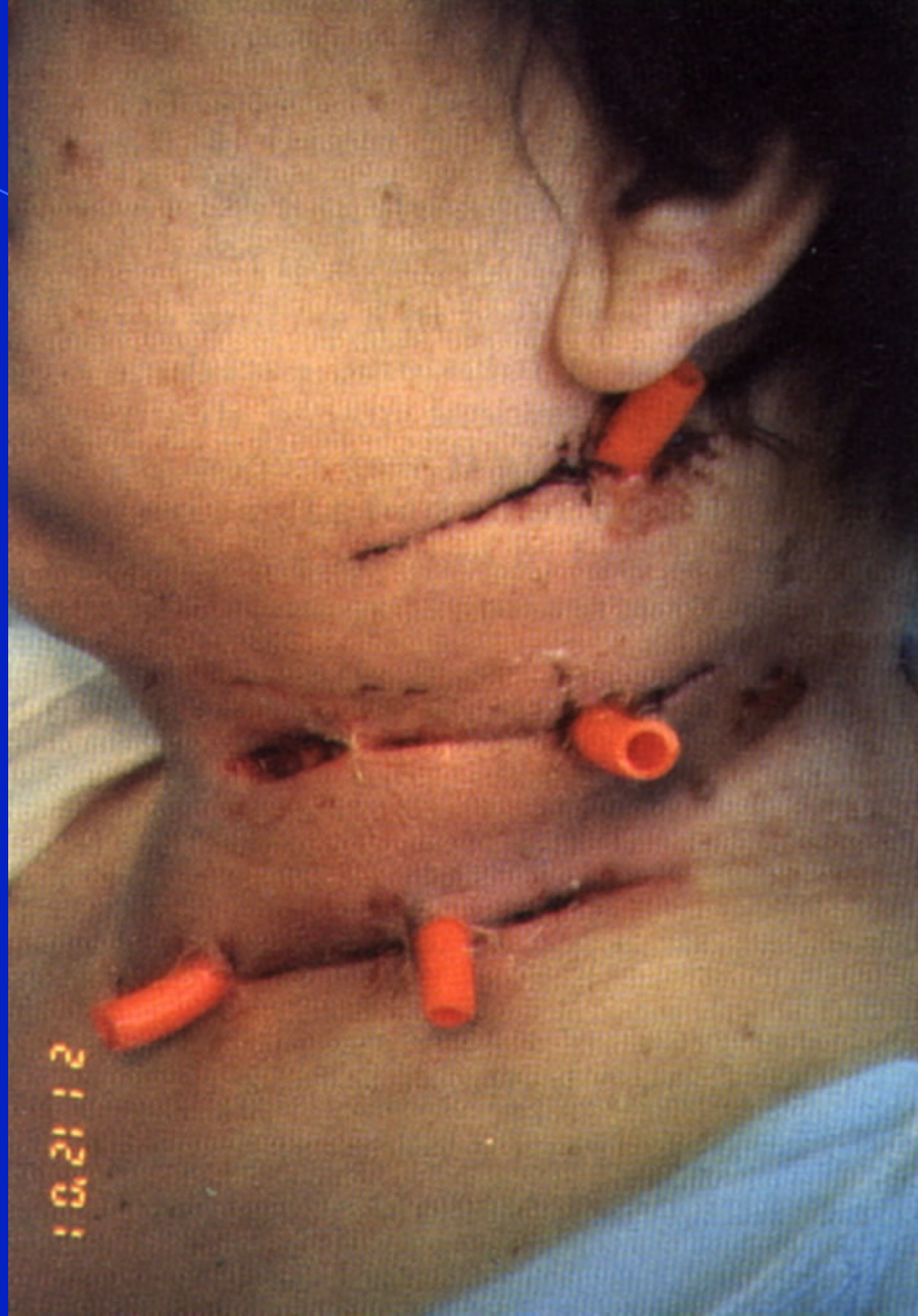Sepsis post anginam – symptoms free interval of a few days after tonsillitis, normal finding on tonsils; Lymphatic way: lymphnode -periadnitis-periphlebitis-trombophlebitis VJI

Trombophlebitis v. jug. int. – treatment :surgery, removal of inflam. focus, suture of VJI and resection in extention of thrombosis, antibiotics

Fasciitis necrotisans

**inflammation of soft
tissues of the neck
with fast spreading
in fascial
compartments
without borders,
with necroses**

Incision, drainage

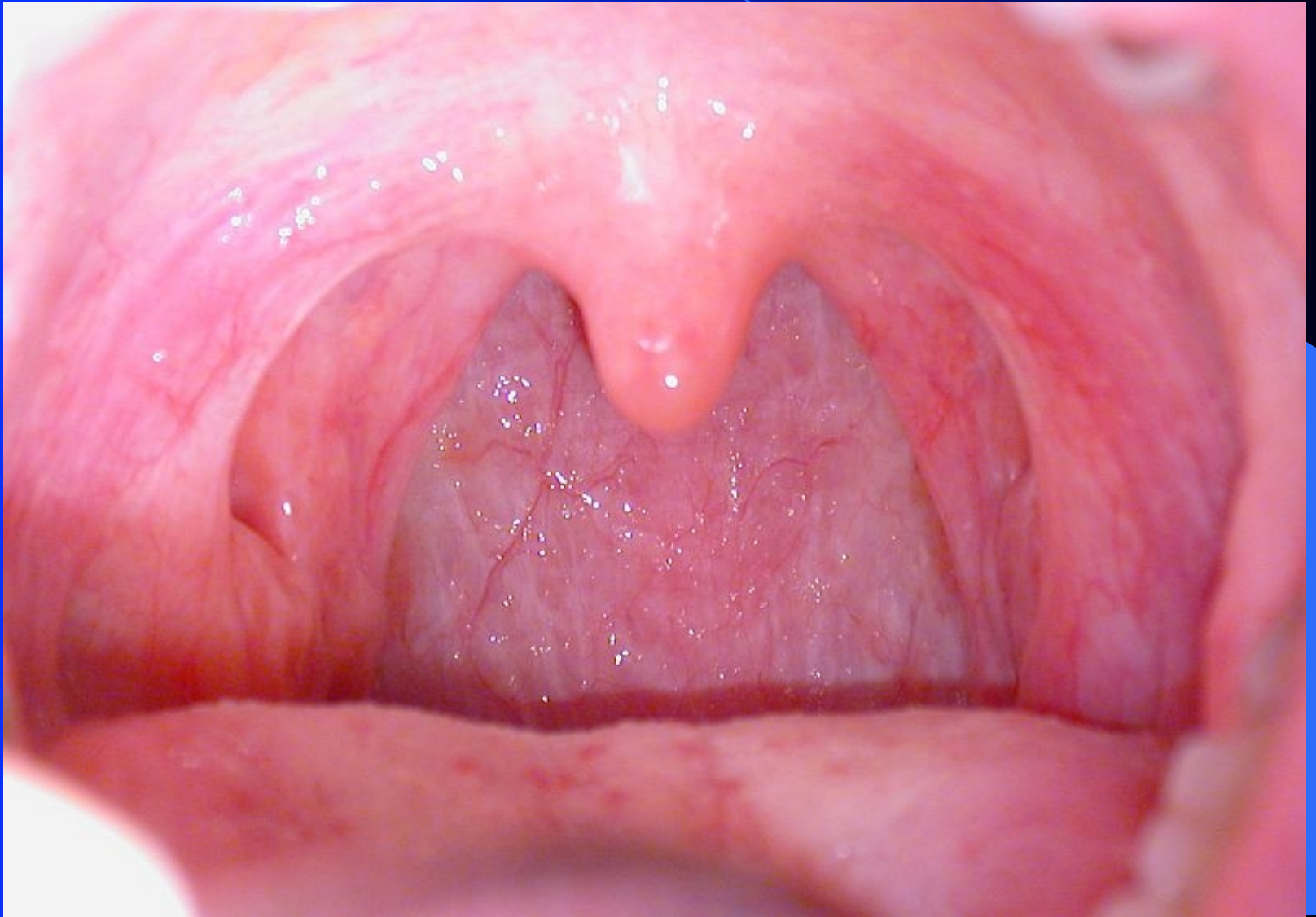

Chronic pharyngitis

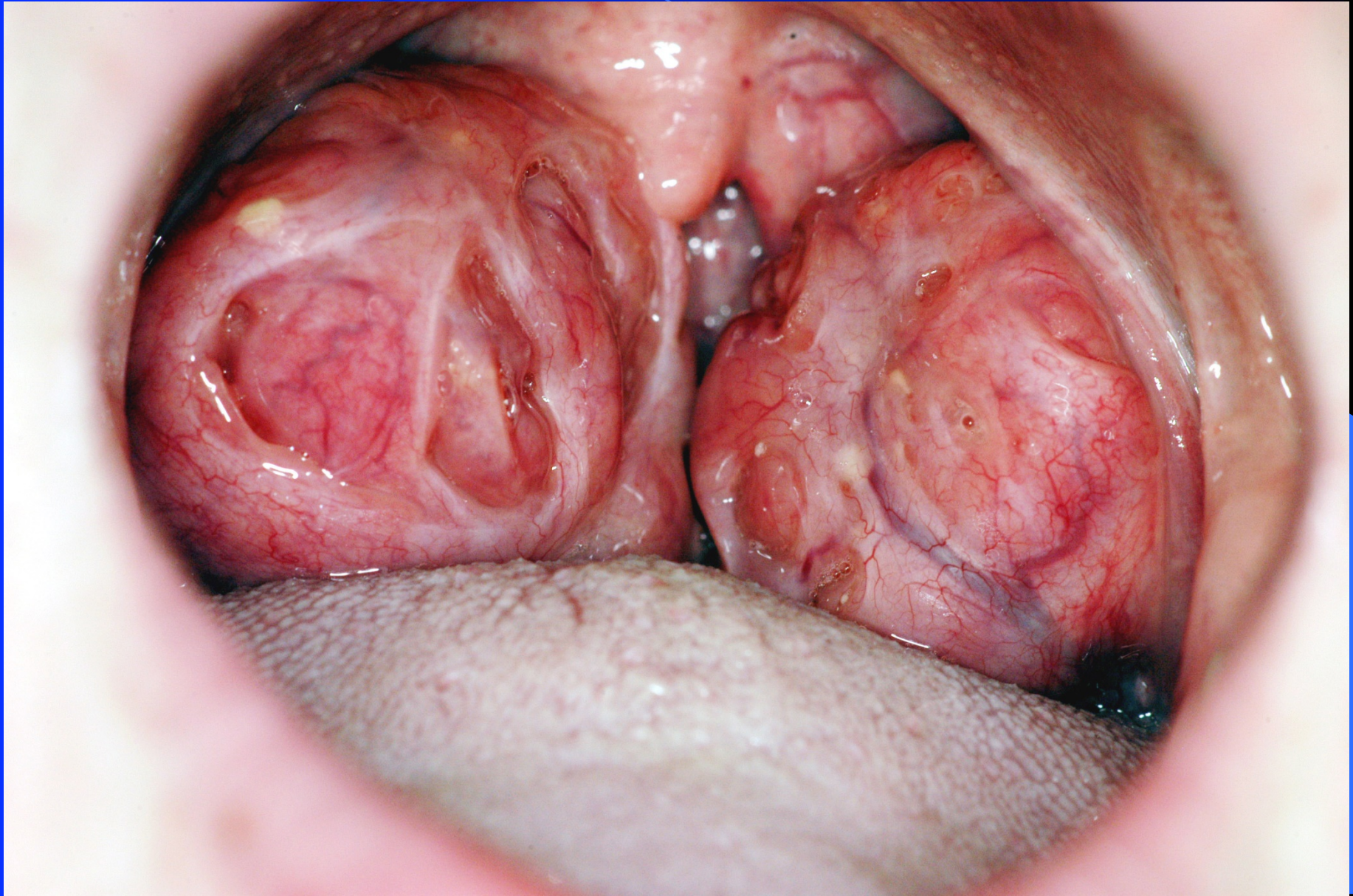
Hypertrophic – pharyngeal paresthesia, increasing in swallowing, hypertrophic changes of subepithelial tissue

Atrophic - feeling of foreign body, burning and dryness feeling; pharyngeal mucous membrane is thin, dry, glossy, sometimes covered with secretion

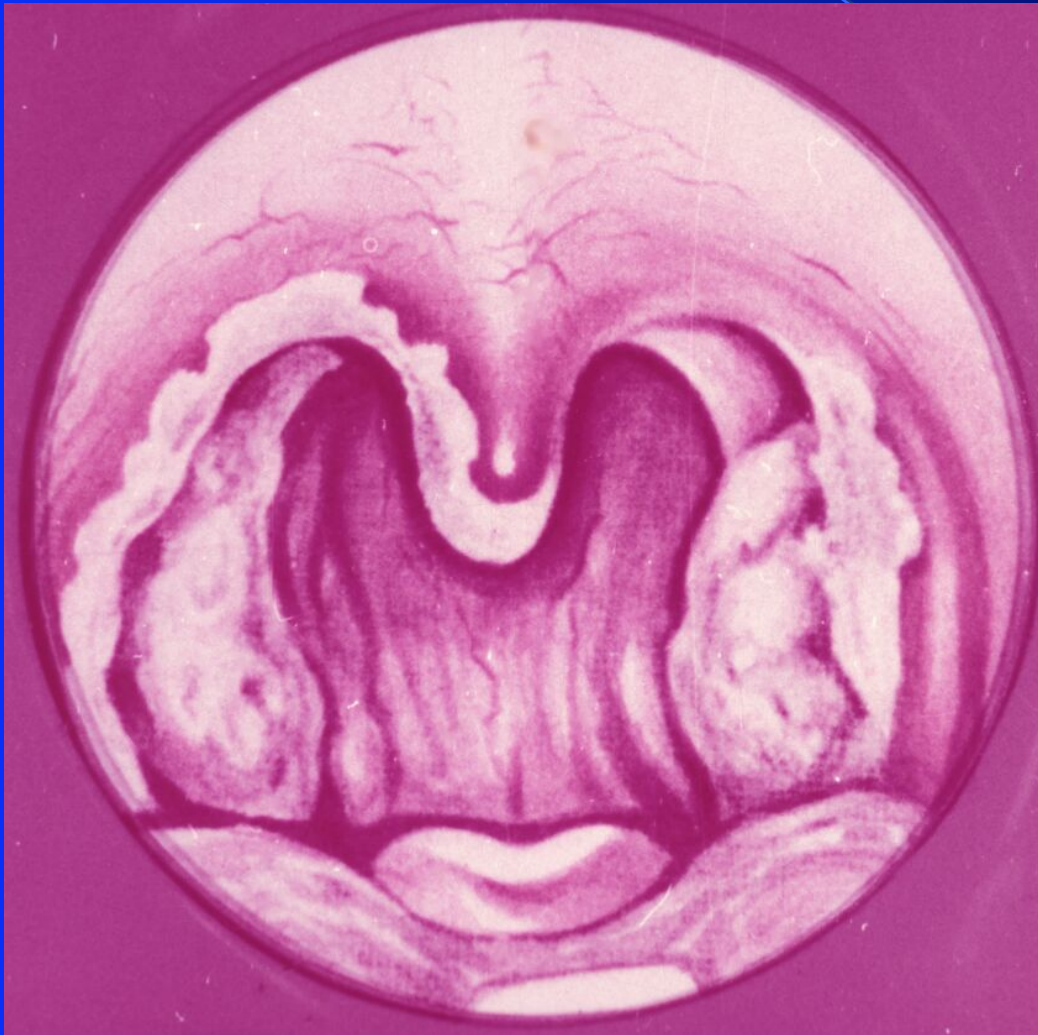Chronic pharyngitis



Hypertrophy of palatinal tonsils (indication to TE)



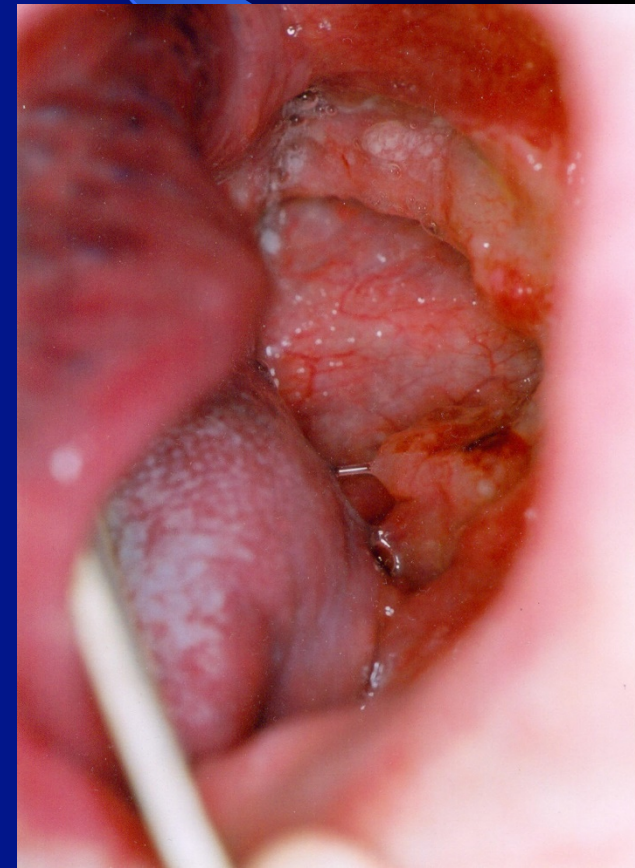Diphtheria



tumors of oropharynx

history – long lasting: pain,
feeling of foreign body,
bleeding, halitosis

asymmetric changes in isthmus
facium, ulceration,
hyperkeratosis, bleeding,
tough tonsil, exofytic growth –
histology !



foreign bodies

onside pain, feeling of foreign body

History- sudden onset during eating,
finding of foreign body.

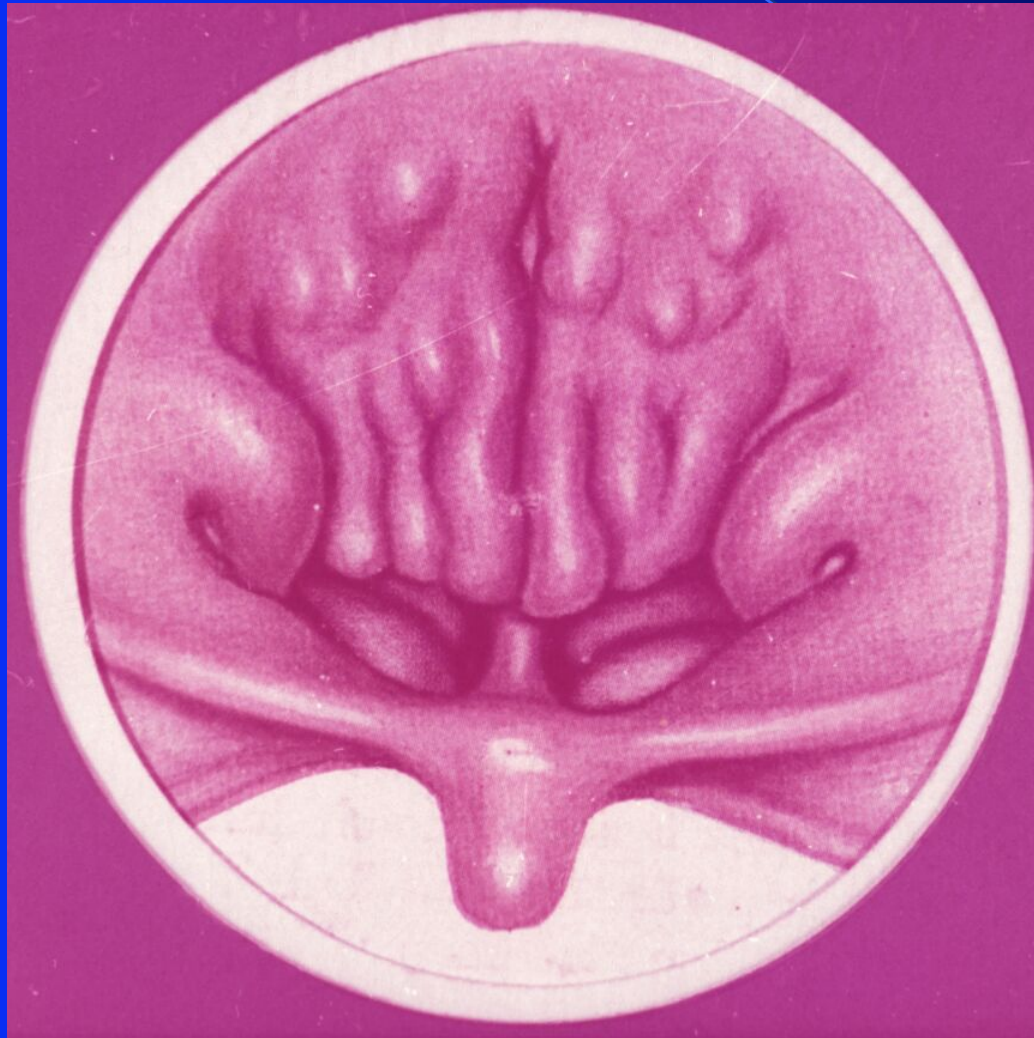evaluation of epipharynx

- **posterior rhinoscopy**
- **Palpation**
- **Direct epipharyngoscopy**
- **Rtg, CT**

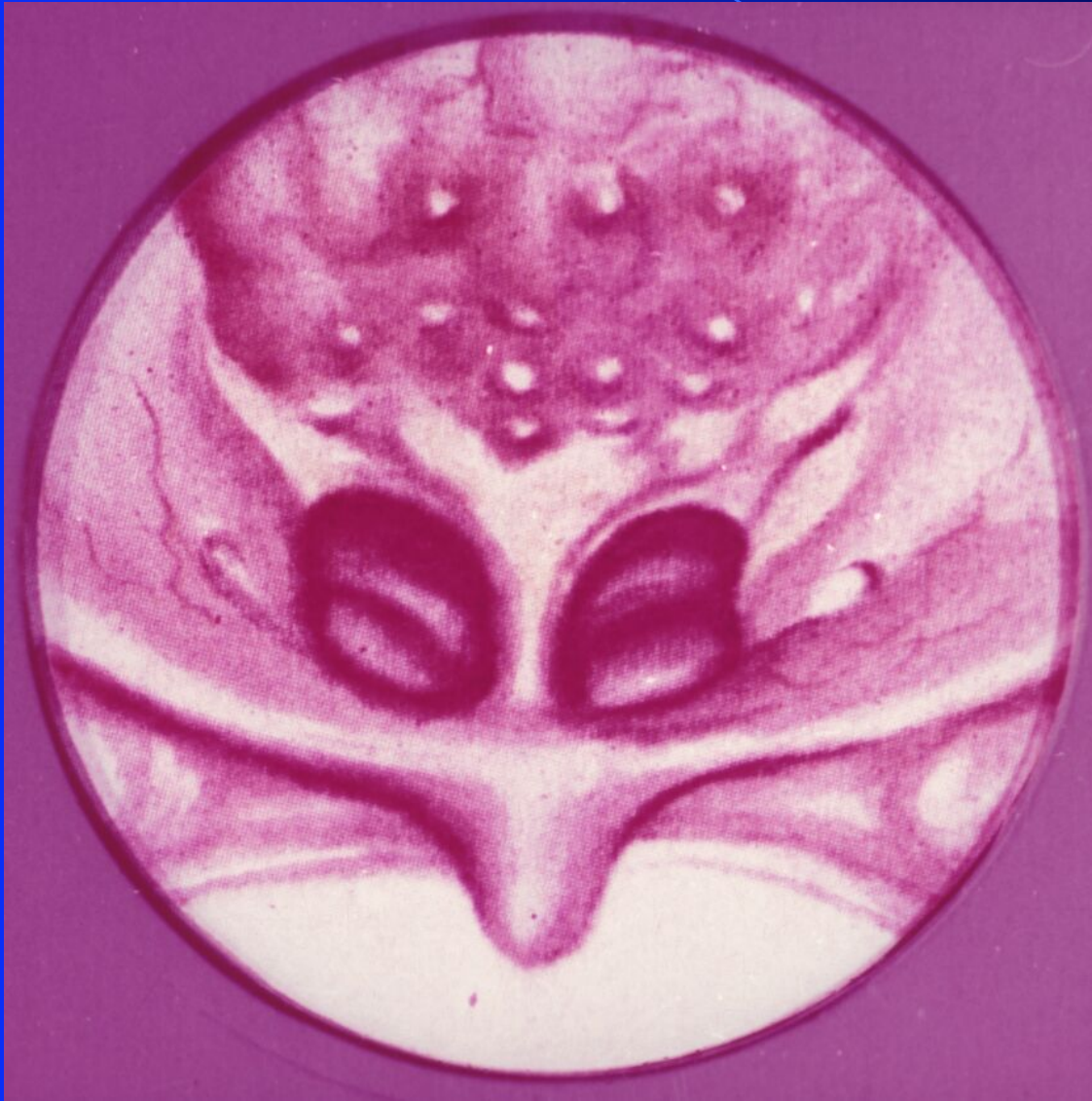
Evaluation of Eustachian tube

- Epipharyngoscopy
- Politzeration
- Cathetrisation
 - **Normal** rustle dry, filled
 - In **stenosis** – discontinuous, abrupt
 - In **liquid** in middle ear cavity – moist fenomens
 - In **perforation** of ear drum – high,
- Tubometry – even in perforated ear drum (Valsalva, Toynbee),

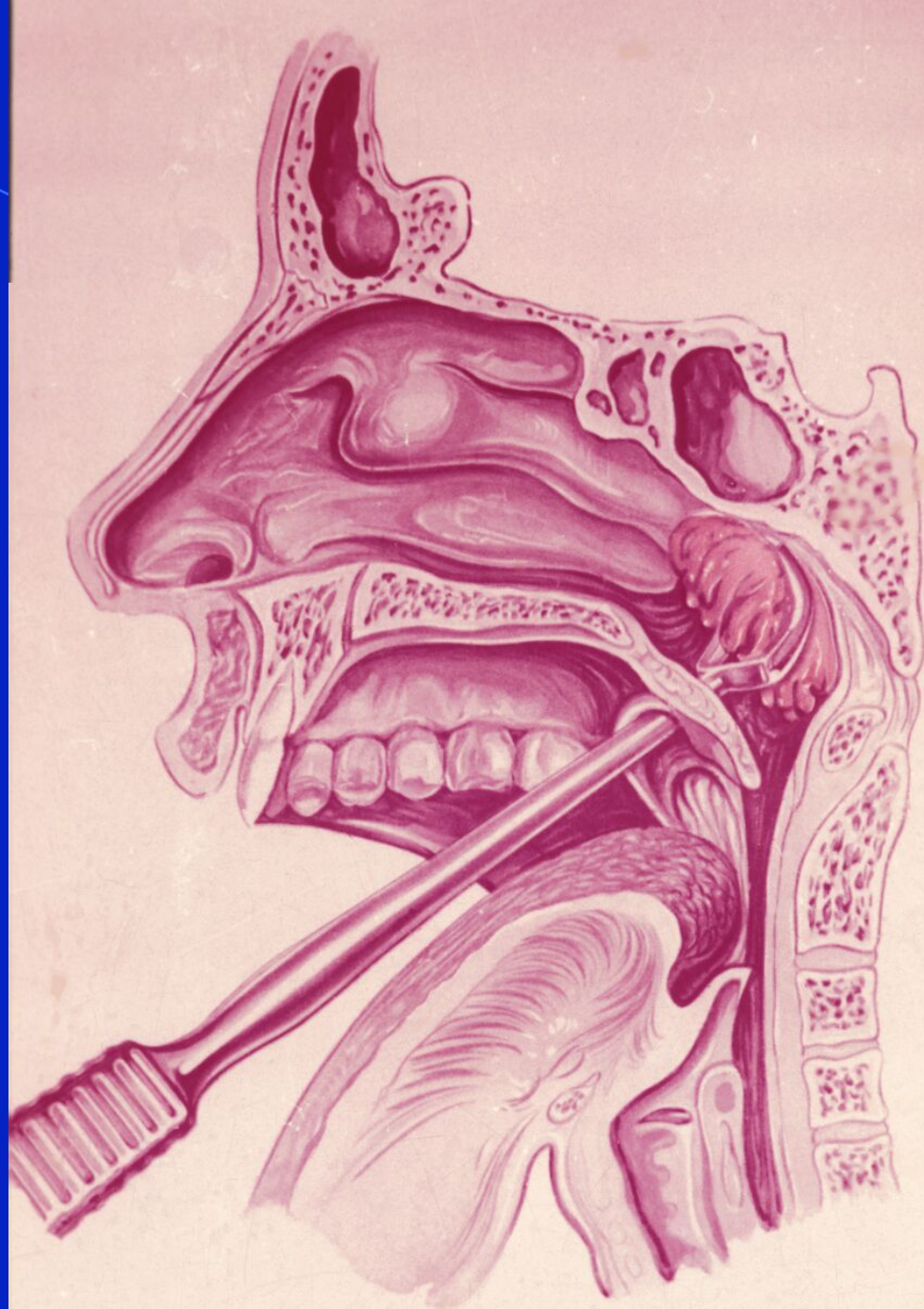
Vegetationes adenoideae (tonsila pharyngea)



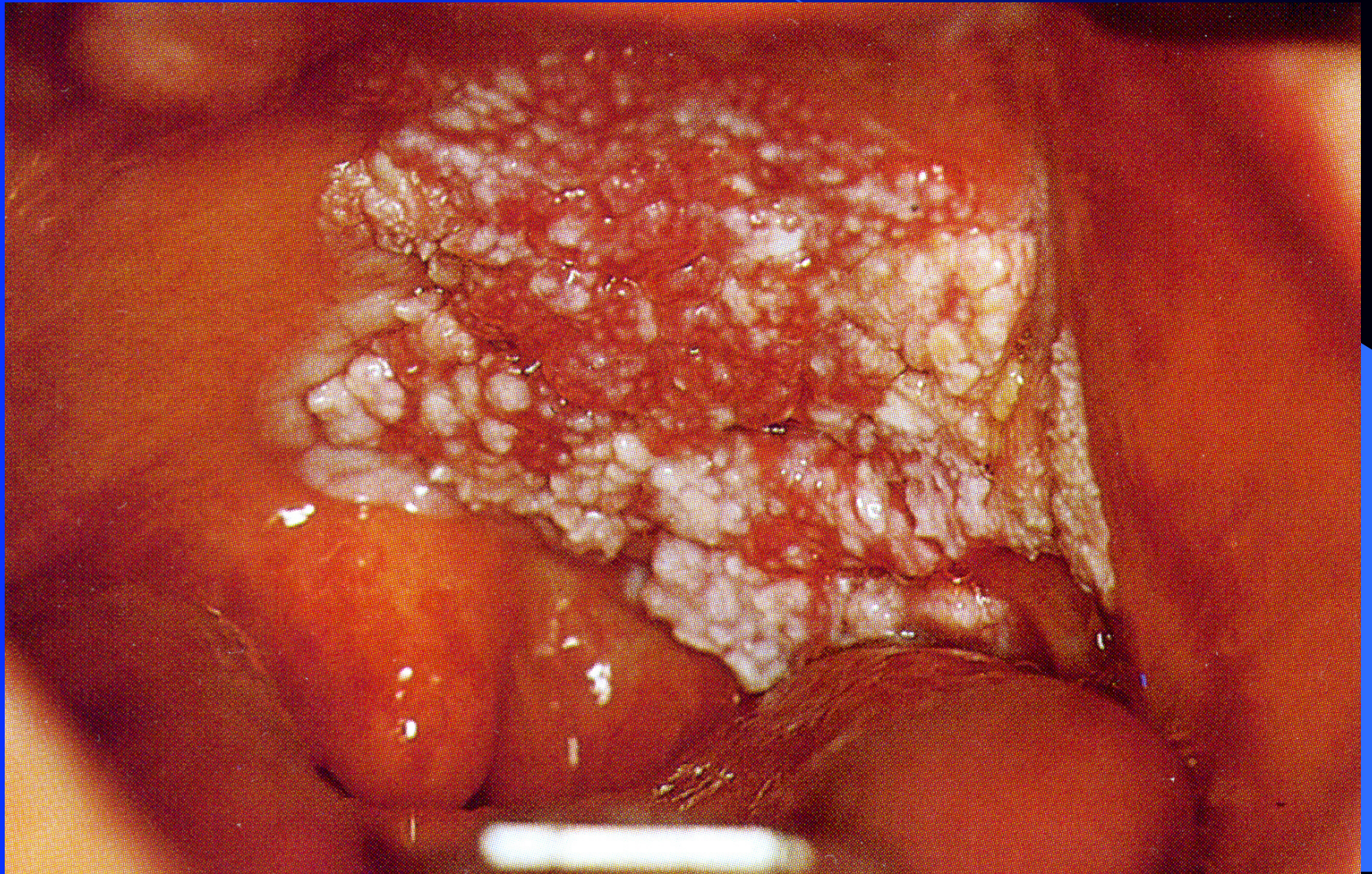
Tonsillitis ac. retronasalis



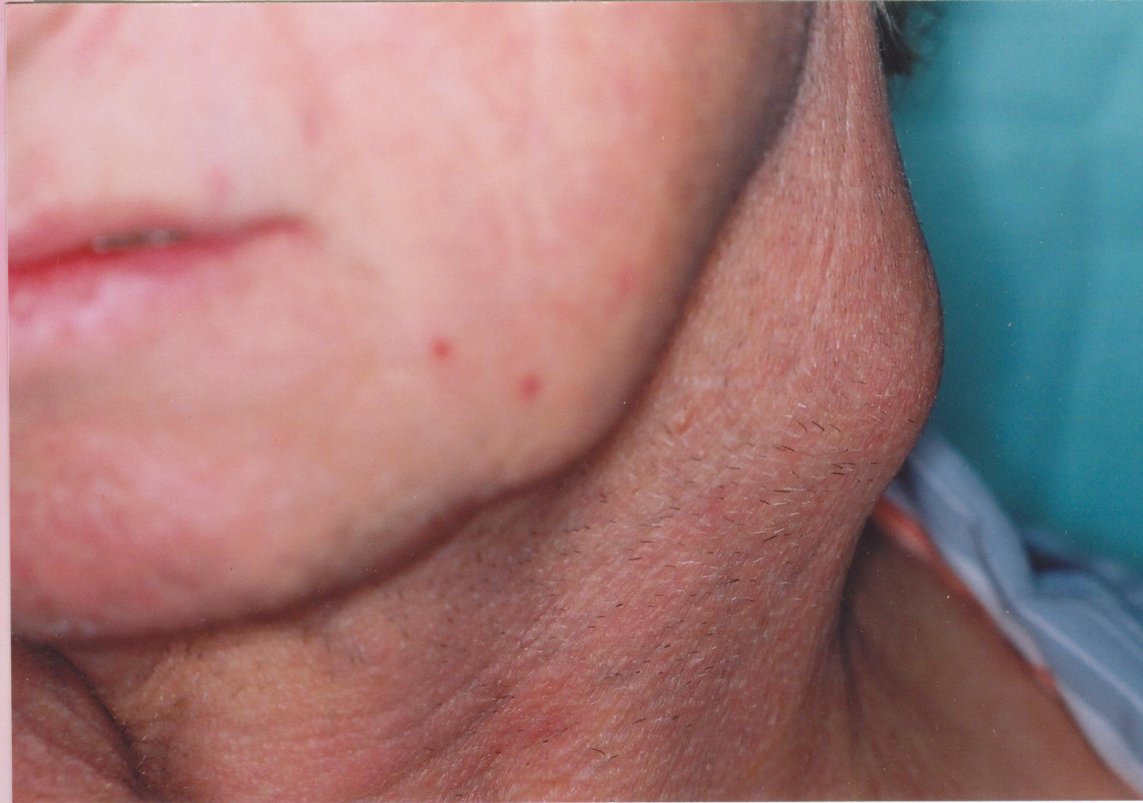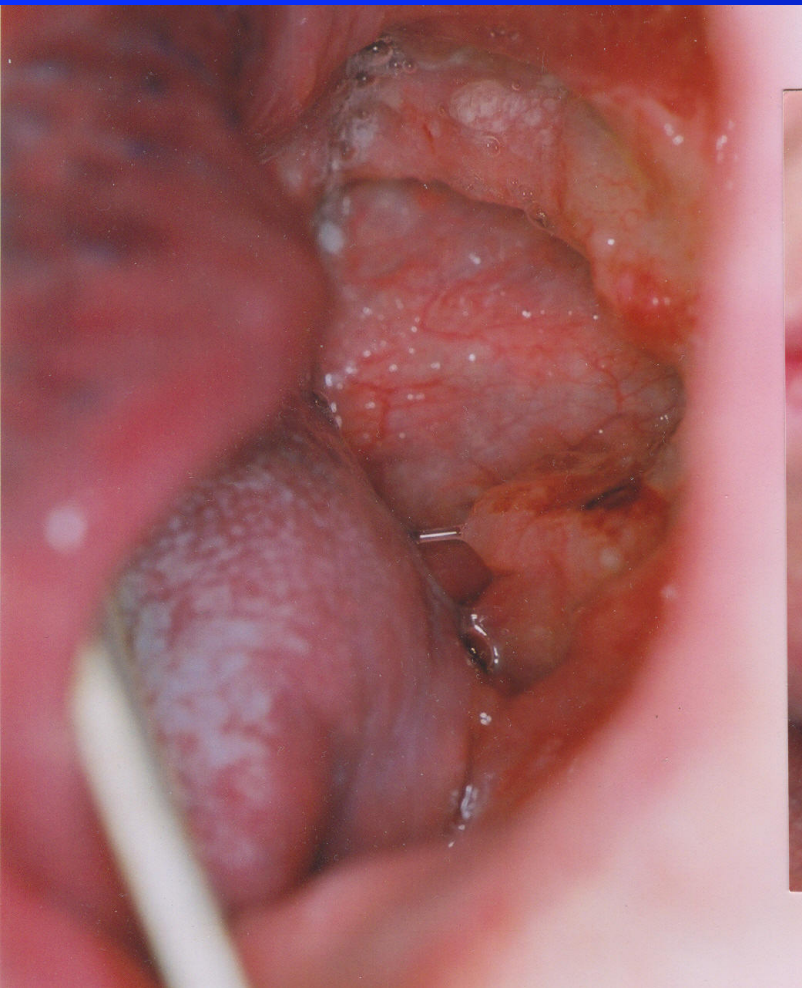
Adenotomy



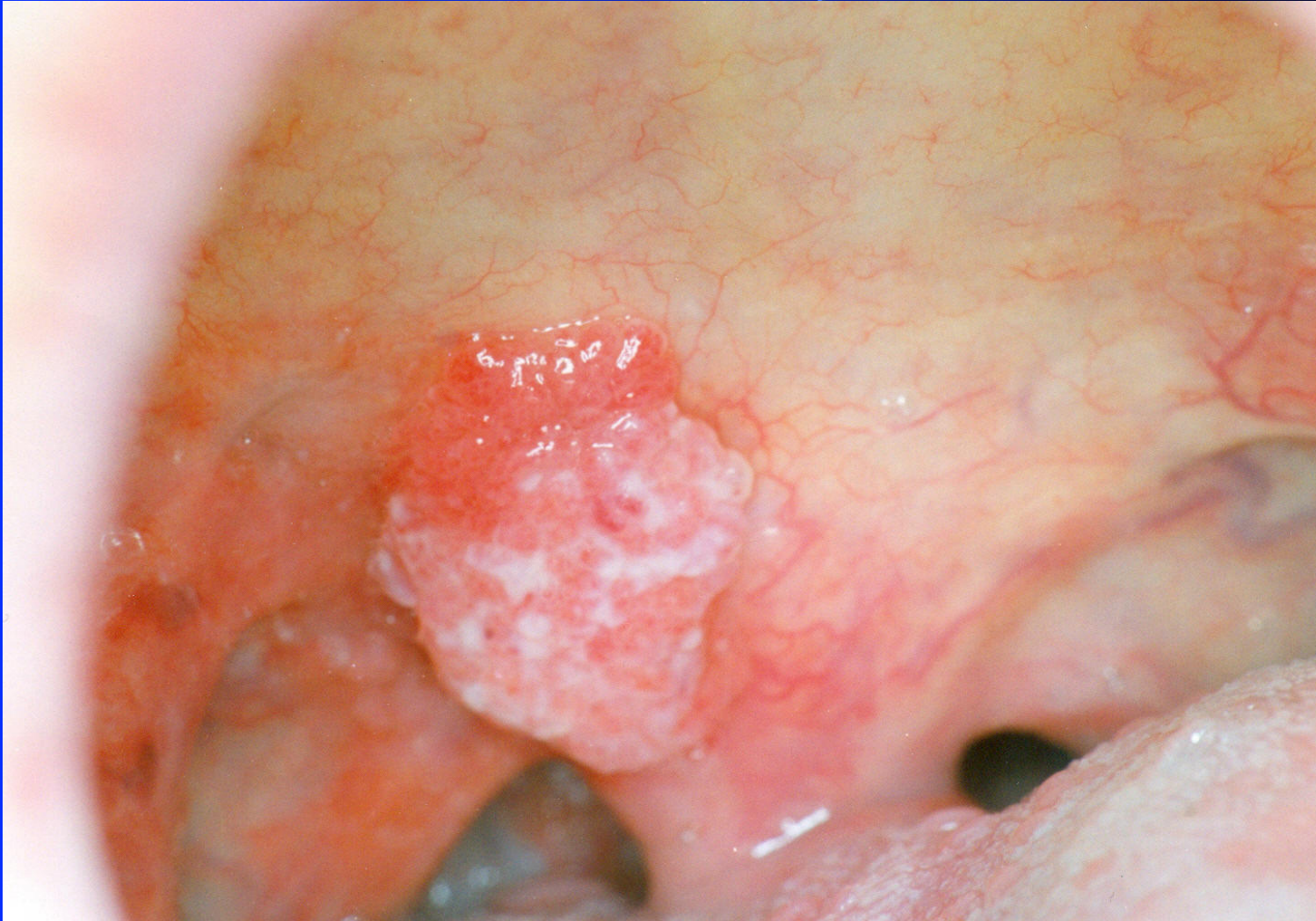soft palate carcinoma



oropharyngeal cancer with metastasis on the neck



oropharyngeal cancer



Evaluation of salivary glands

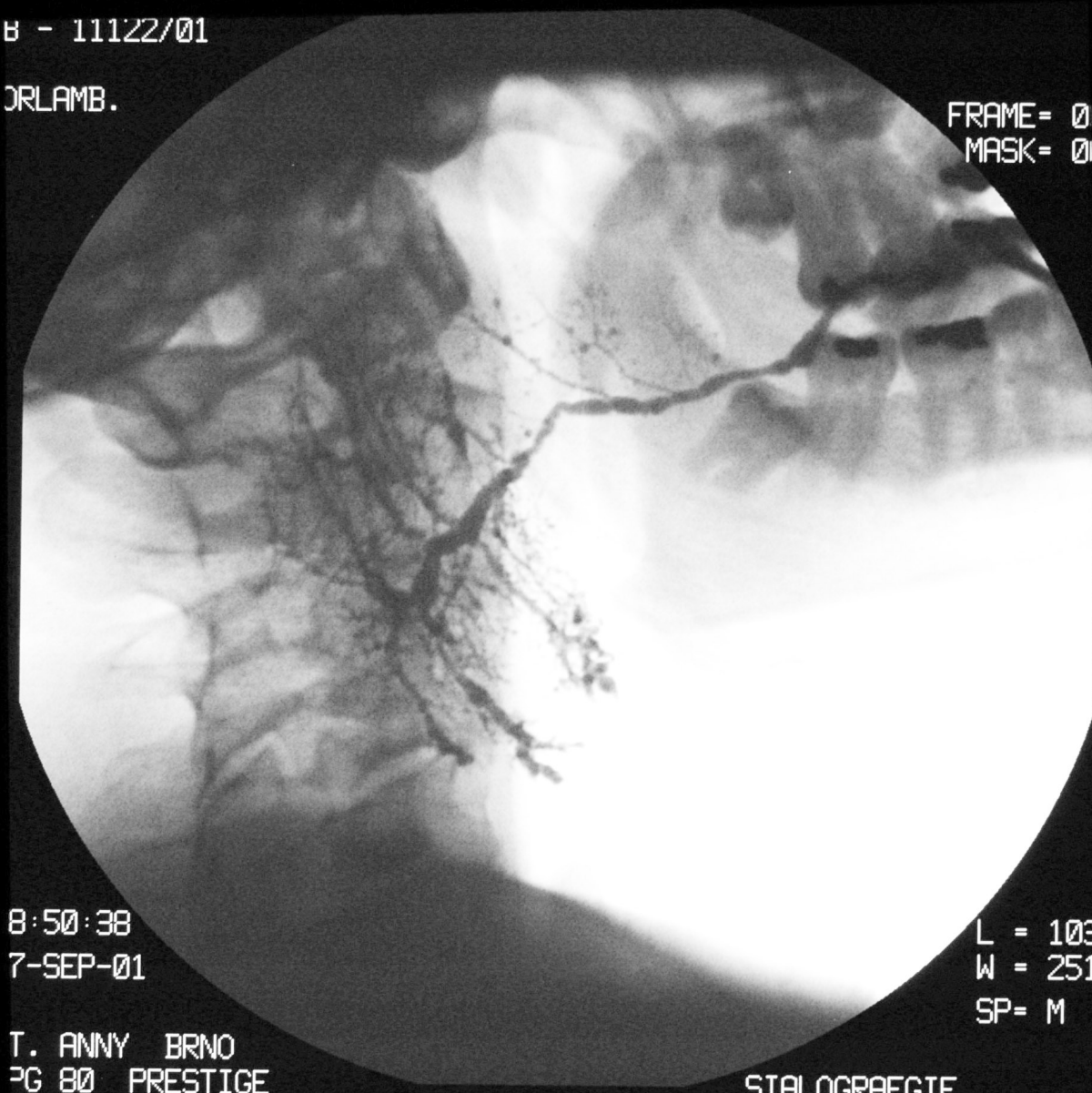
- **Inspection**
- **Palpation**
- **Ultrasound**
- **Sialography, CT, NMR**
- **FNB = fine needle biopsy**
- **Endoscopy of drainage system**

Sialography

B - 11122/01

ORLAMB.

FRAME = 0
MASK = 01



8:50:38
7-SEP-01

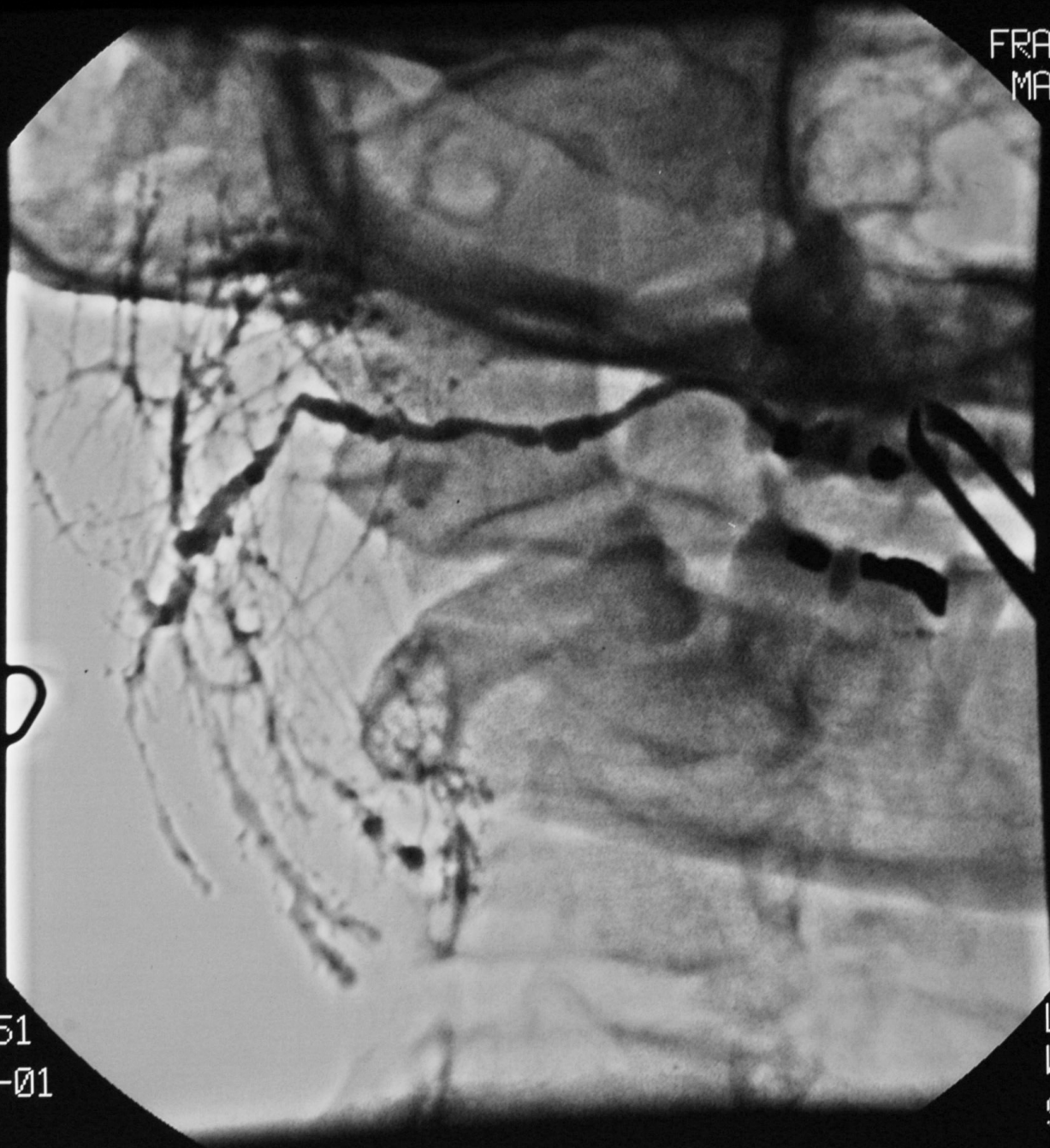
L = 103
W = 251
SP = M

T. ANNY BRNO
PG 80 PRESTIGE

SIALOGRAFIE

3.

FRAI
MA:



51
-01

MIV DOMO



