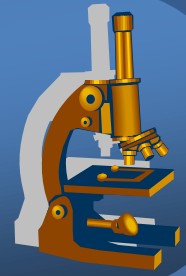


Systemic Pathology



Hepatobiliary, pancreas, diabetes mellitus, endocrine system

Morphology of hepatic injury



- ✘ hepatocyte degeneration and/or pathologic intracellular accumulation (i. e. fatty liver, pigment, ...)
- ✘ hepatocyte necrosis, apoptosis
- ✘ inflammation
- ✘ regeneration
- ✘ fibrosis

Fatty liver disease - steatosis



✗ gross:

⇒ *enlarged, paler, in extreme cases yellow, softer consistency*

✗ micro:

⇒ *small or confluent droplets in cytoplasm*

✗ causes:

⇒ *alcohol*

⇒ *other toxins (drugs, organic substances)*

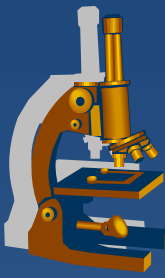
⇒ *diabetes mellitus + metabolic syndrome*

⇒ *excessive fat intake*

⇒ *infection (hepatitis C, ...)*

⇒ *hypoxia*

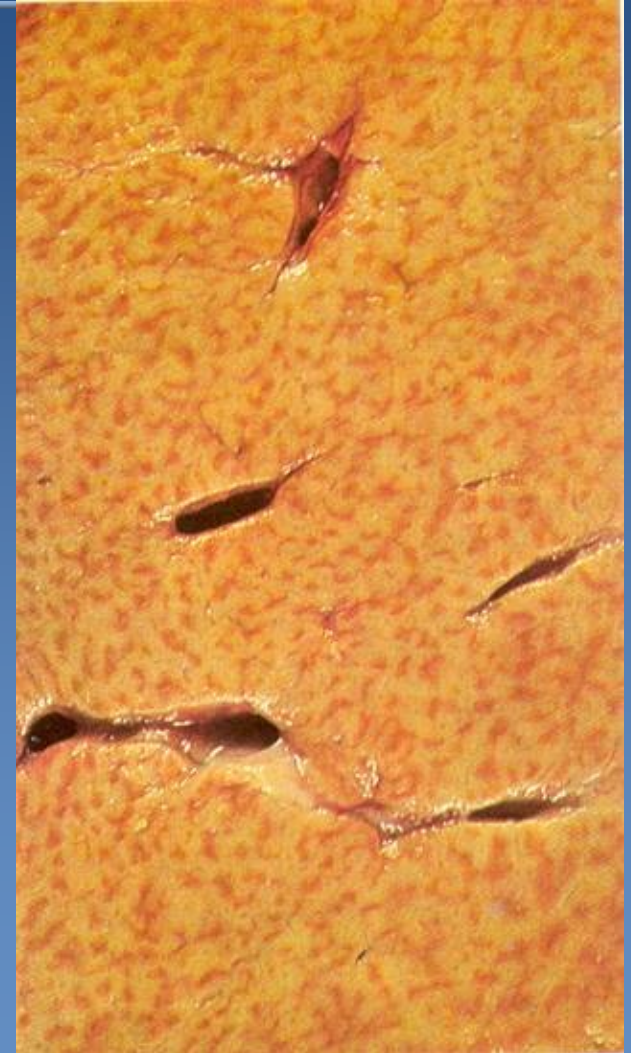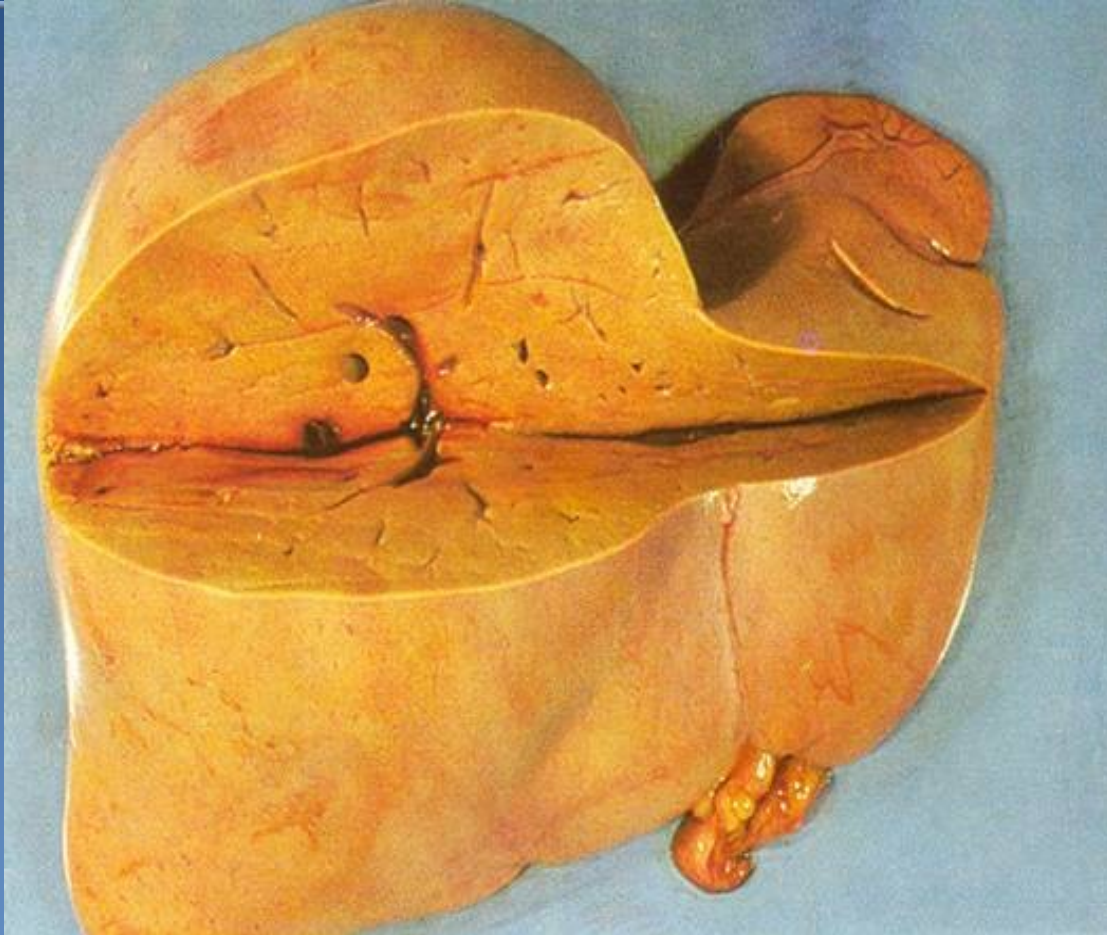
Fatty liver - steatosis



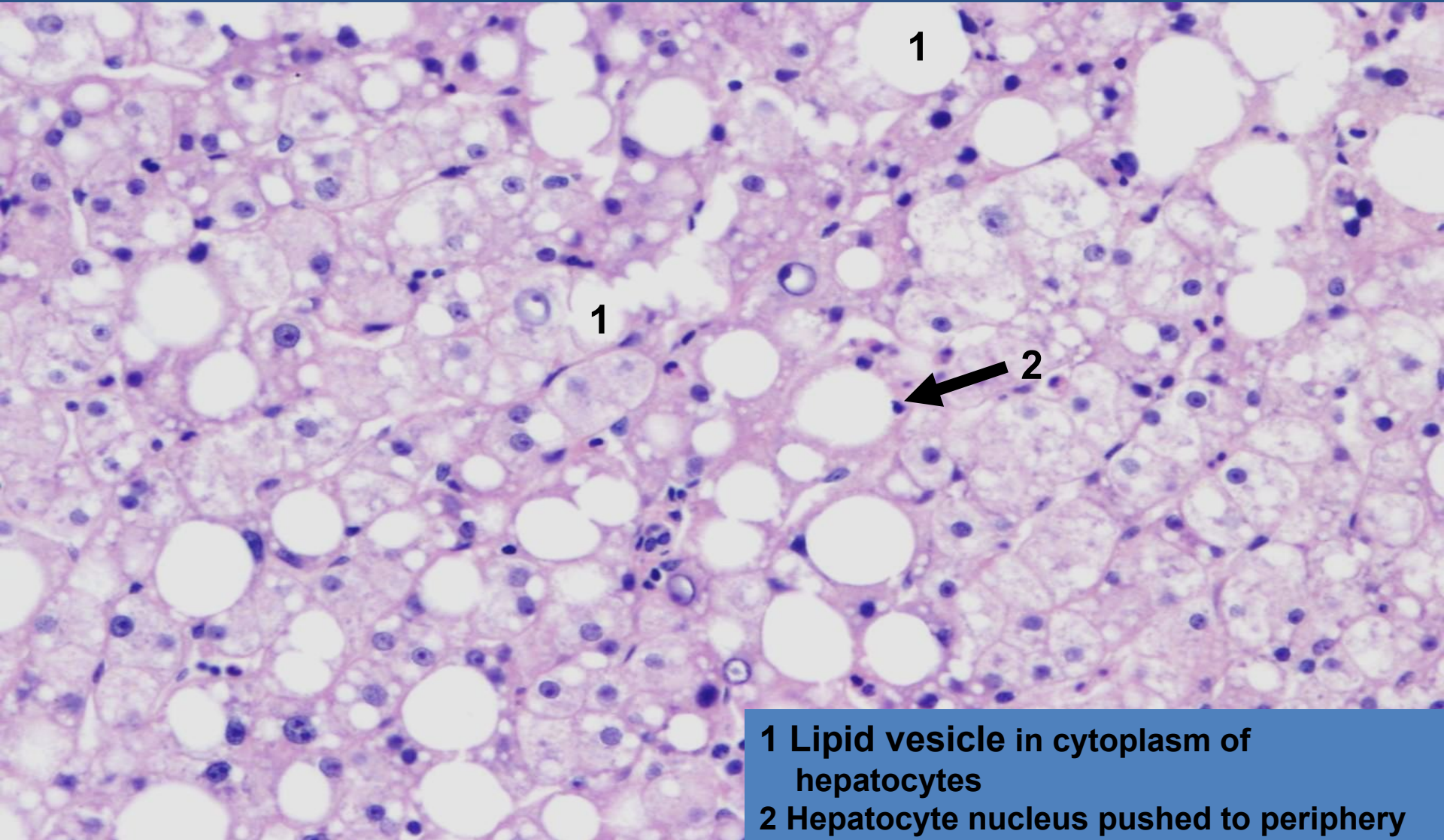
= pathological accumulation of lipids in form of intracytoplasmatic vesicles

- ✗ without inflammatory reaction reversible process
- ✗ with inflammation (steatohepatitis) – possible progression to cirrhosis
- ✗ microvesicular x macrovesicular
 - ⇒ *vesicle < or > than hepatocyte nucleus*
 - ⇒ *variable distribution (diffuse, zonal, focal), may help to the etiological diagnosis*

Fatty liver disease - steatosis



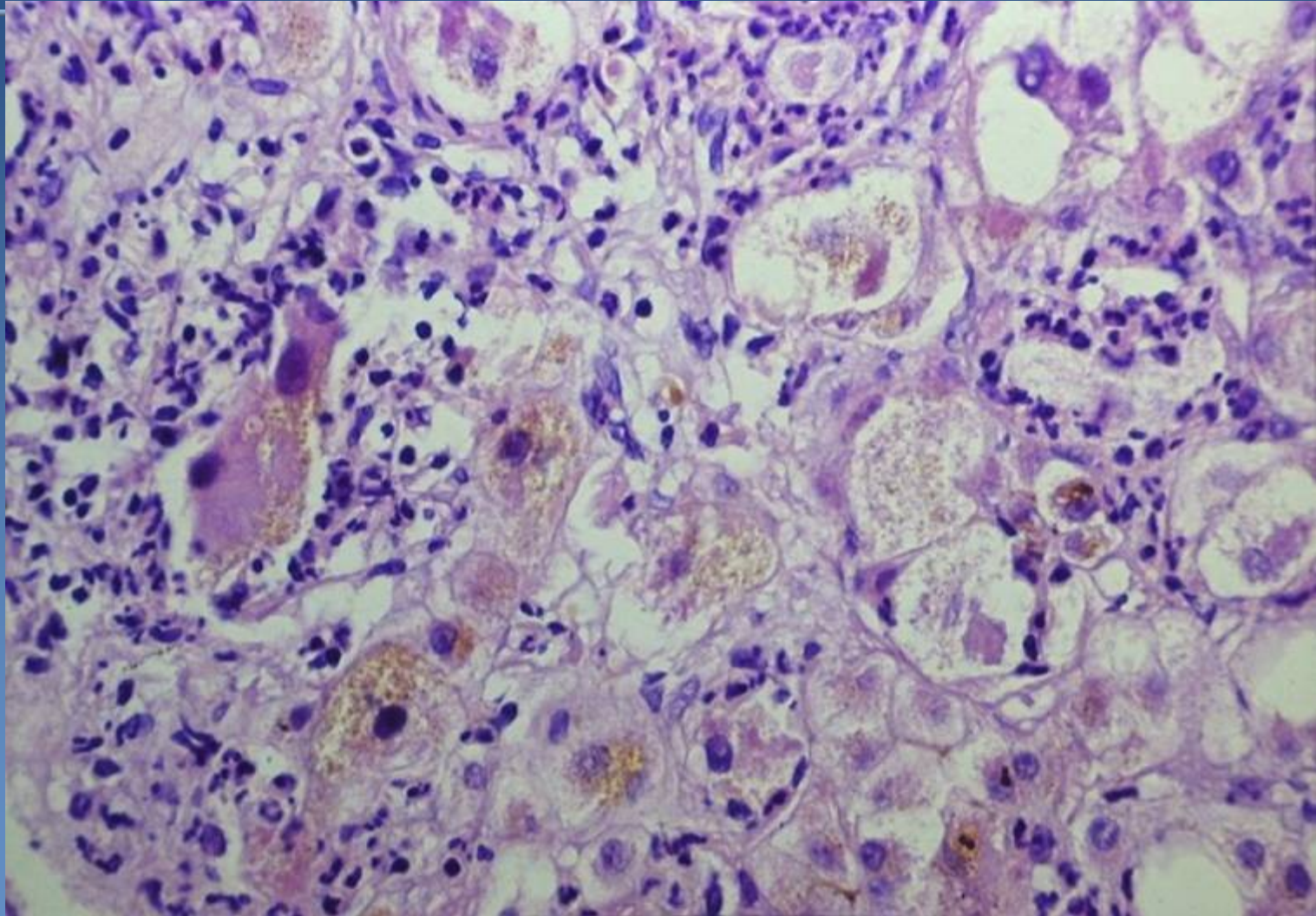
Alcoholic fatty liver



1 Lipid vesicle in cytoplasm of hepatocytes

2 Hepatocyte nucleus pushed to periphery

***Alcoholic hepatitis : steatohepatitis,
cholestasis, Mallory hyaline***



Cholestasis



× Causes:

- ⇒ *hepatocellular dysfunction (inborn, acquired)*
- ⇒ *biliary obstruction (intra-, extrahepatic)*

× Signs:

- ⇒ *pruritus - itching (↑ serum bile acids)*
- ⇒ *hyperlipidemia → skin xanthomas (focal cholesterol accumulation)*
- ⇒ *malabsorption → ↓ fat soluble vitamins (A; D; K)*
- ⇒ *↑ ALP (serum alkaline phosphatase)*

Cholestasis

MORPHOLOGY



xGross:

⇒ *green-brown (olive) discoloration*

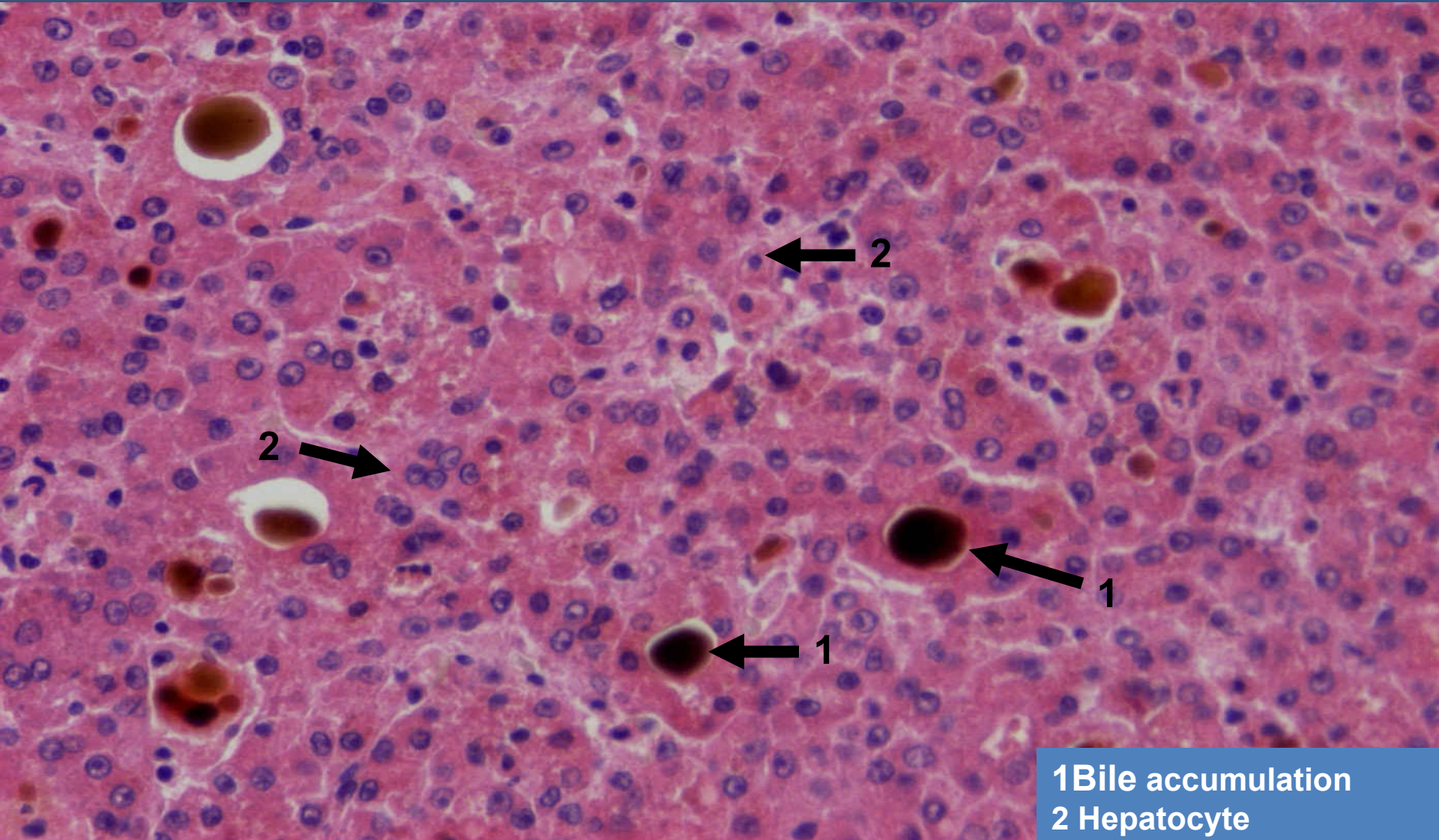
xMicro:

⇒ *bile pigment accumulation in hepatocytes / canaliculi („bile plugs“)*

⇒ *edema, periductal neutrophilic infiltrates in portal spaces*

⇒ *chronic obstruction → portal fibrosis → biliary cirrhosis*

Cholestasis in HCC



1 Bile accumulation
2 Hepatocyte

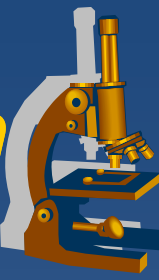
Hepatic venous congestion



x GROSS:

- ⇒ *enlarged, heavy liver*
- ⇒ *dark – reddish brown color*
- ⇒ *cardiac fibrosis (induration)*
- ⇒ *combination with chronic hypoxemic steatosis –
nutmeg liver*

Hepatic venous congestion ***("nutmeg" liver)***



Hepatic venous congestion



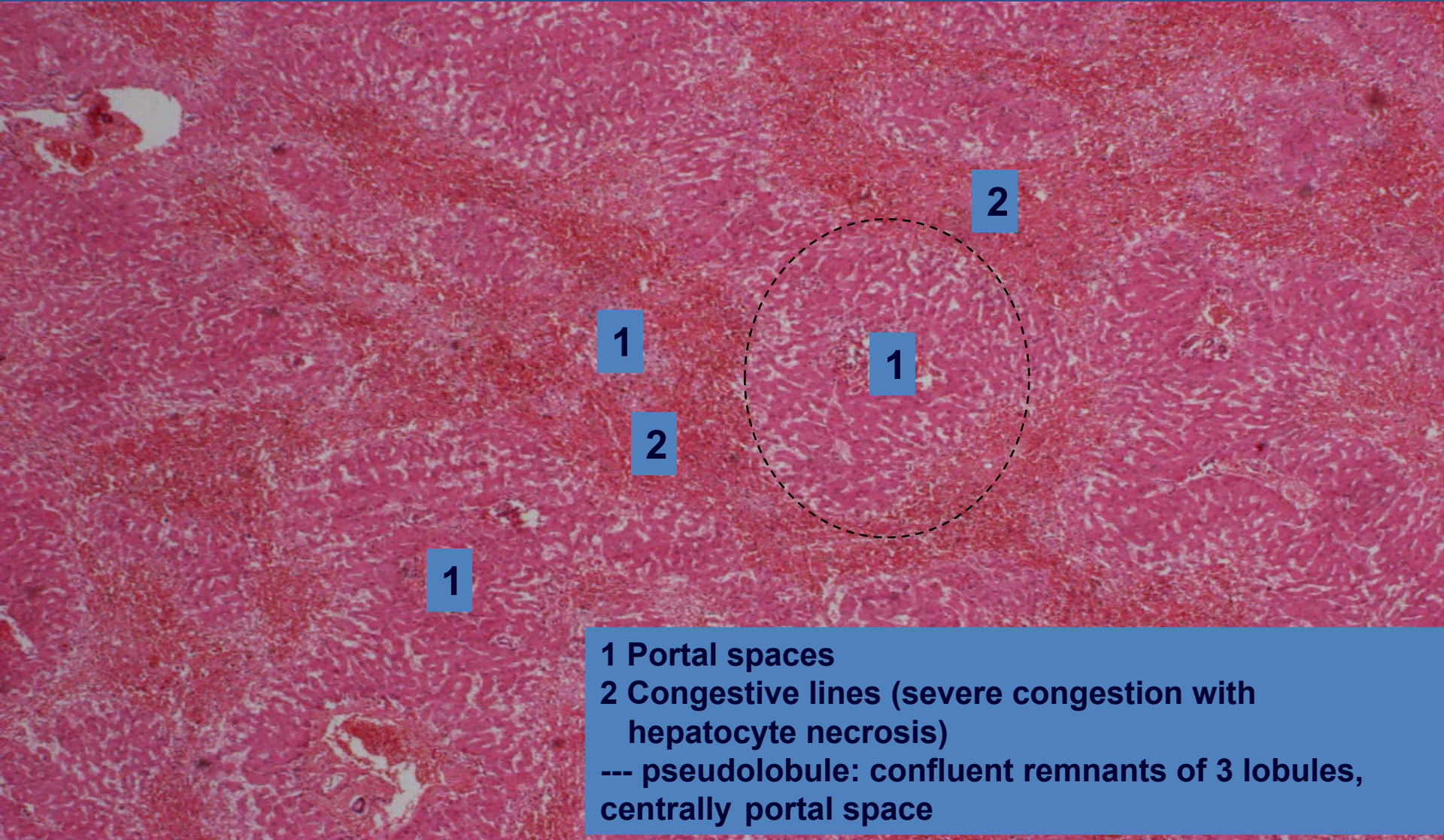
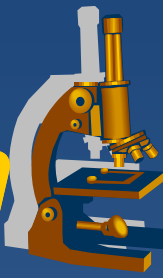x MICRO:

⇒ *central veins and sinusoidal dilatation*

⇒ *centrolobular hepatocytic atrophy, necrosis*

⇒ *„lines“ of congestion*

Hepatic venous congestion



1 Portal spaces

2 Congestive lines (severe congestion with hepatocyte necrosis)

--- pseudolobule: confluent remnants of 3 lobules, centrally portal space

Hepatitis



xinfectious

⇒ *acute, chronic*

⇒ *viral*

- most common
- primary hepatotropic - hepatitis viruses
- systemic – EBV, CMV, HSV, yellow fever, enteroviruses, ...

⇒ *bacterial*

- pyogenic bacteria, TBC, salmonella – typhoid fever, leptospirosis, ...

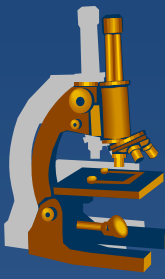⇒ *parasitic*

- echinococcus, schistosoma, ...

⇒ *protozoal*

- amebiasis

Hepatitis



Non-infectious

(acute, chronic)

- ⇒ *autoimmune (AIH)*
- ⇒ *metabolic*
 - hemochromatosis, NASH
- ⇒ *toxic/drug induced*
- ⇒ *cryptogenic*

Chronic hepatitis



- ✗ Asymptomatic / clinical symptoms
- ✗ Laboratory signs of progressive/relapsing liver disease (> 6 months, 12 months in HCV)
- ✗ Etiology:
 - ⇒ *Viruses*
 - HBV, HBV+HDV, HCV
 - ⇒ *AIH*
 - ⇒ *metabolic (inborn, NASH)*
 - ⇒ *toxic/ drug induced (alcoholic)*
 - ⇒ *cryptogenic*

Chronic hepatitis - pathology



x Gross:

⇒ *non-characteristic, commonly enlarged liver of firmer consistency*

x Micro:

⇒ *Disease activity: grade of necroinflammatory changes in portal spaces and lobules (interface activity; type, grade and localisation of necrosis; grade of inflammatory infiltrate)*

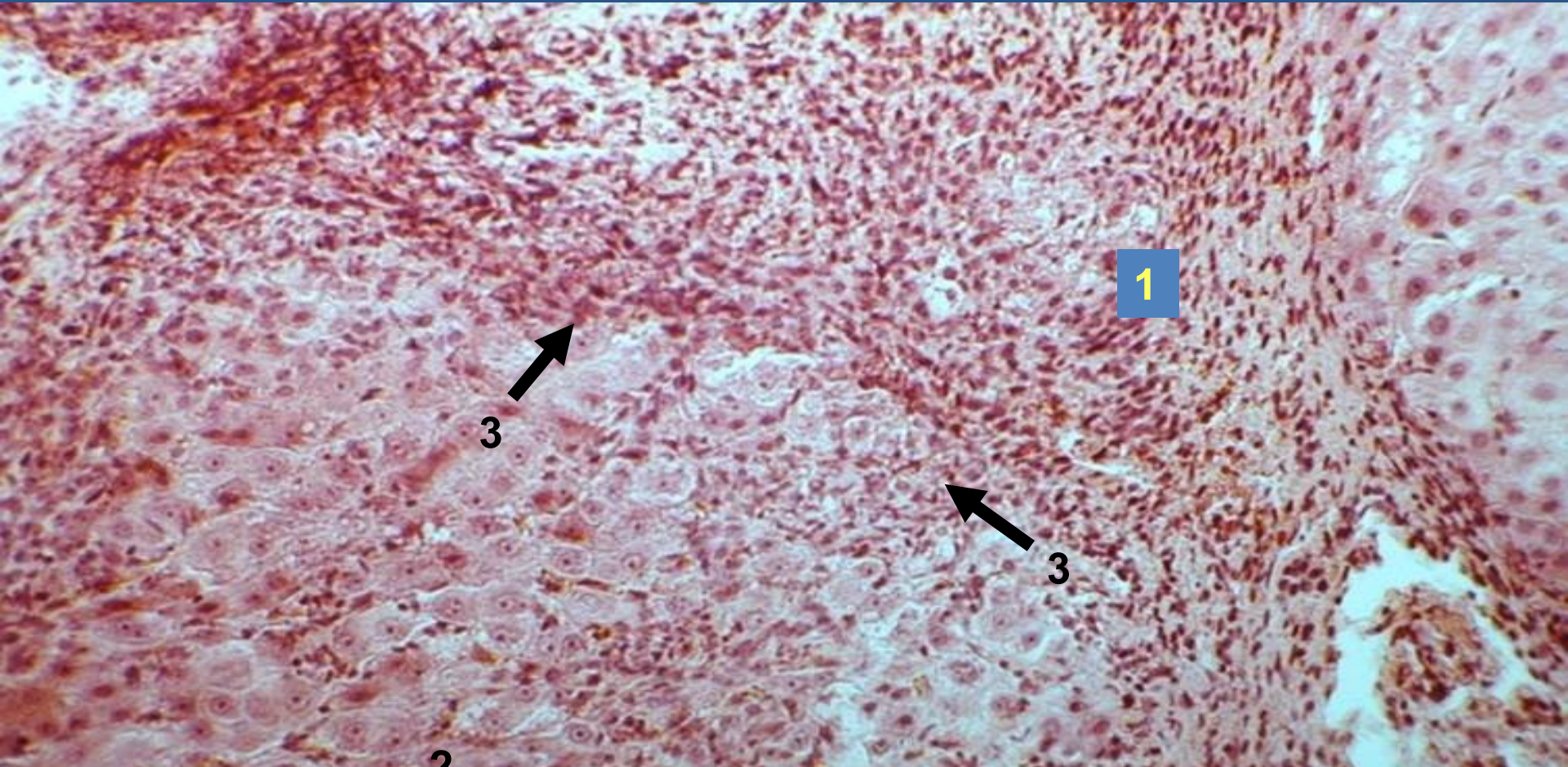
Chronic hepatitis - pathology



x Disease stage:

⇒ stage of fibrosis and architectural changes (portal fibrotic expansion, bridging fibrosis, nodularity → cirrhosis)

Chronic hepatitis



- 1 Portal spaces with inflammatory infiltrate
- 2 Hepatocytes
- 3 Interface activity

NASH: non-alcoholic steatohepatitis



x Spreading silent epidemics:

Patients with metabolic syndrome:

„male-type“ obesity (intraabdominal fat
accumulation – waist size)

hyperlipidemia

DM of II type, hyperglycaemia

Liver fibrosis



- × Response to inflammation
- × Mostly irreversible
 - ⇒ *(under favorable conditions reversible to some extent)*
- × Deposition of collagen
 - ⇒ → *effects on hepatic metabolism and blood flow*
- × Begins around portal tracts or central veins → spreads → links other regions (bridging fibrosis)
- × Basic lobular architecture partially preserved

Advanced liver disease (cirrhosis)



- ✘ Complete loss of original architecture
 - ⇒ *Regenerating groups of hepatocytes surrounded by fibrotic scar tissue*
 - ⇒ *Reorganisation of vascular architecture*
 - ⇒ *Intrahepatic biliary tract changes, incl. ductular hyperplasia*

- ✘ Due to continued parenchymal injury and fibrosis
- ✘ Advanced stage of liver disease, may be partially reversible

Advanced liver disease (cirrhosis)



x Etiology:

⇒ *massive acute necrosis*

⇒ *chronic hepatitis*

⇒ *biliary diseases:*

- inborn (atresia)

- acquired:

- autoimmune (primary biliary cirrhosis, prim. sclerosing cholangitis),
secondary biliary cirrhosis (chronic obstruction)

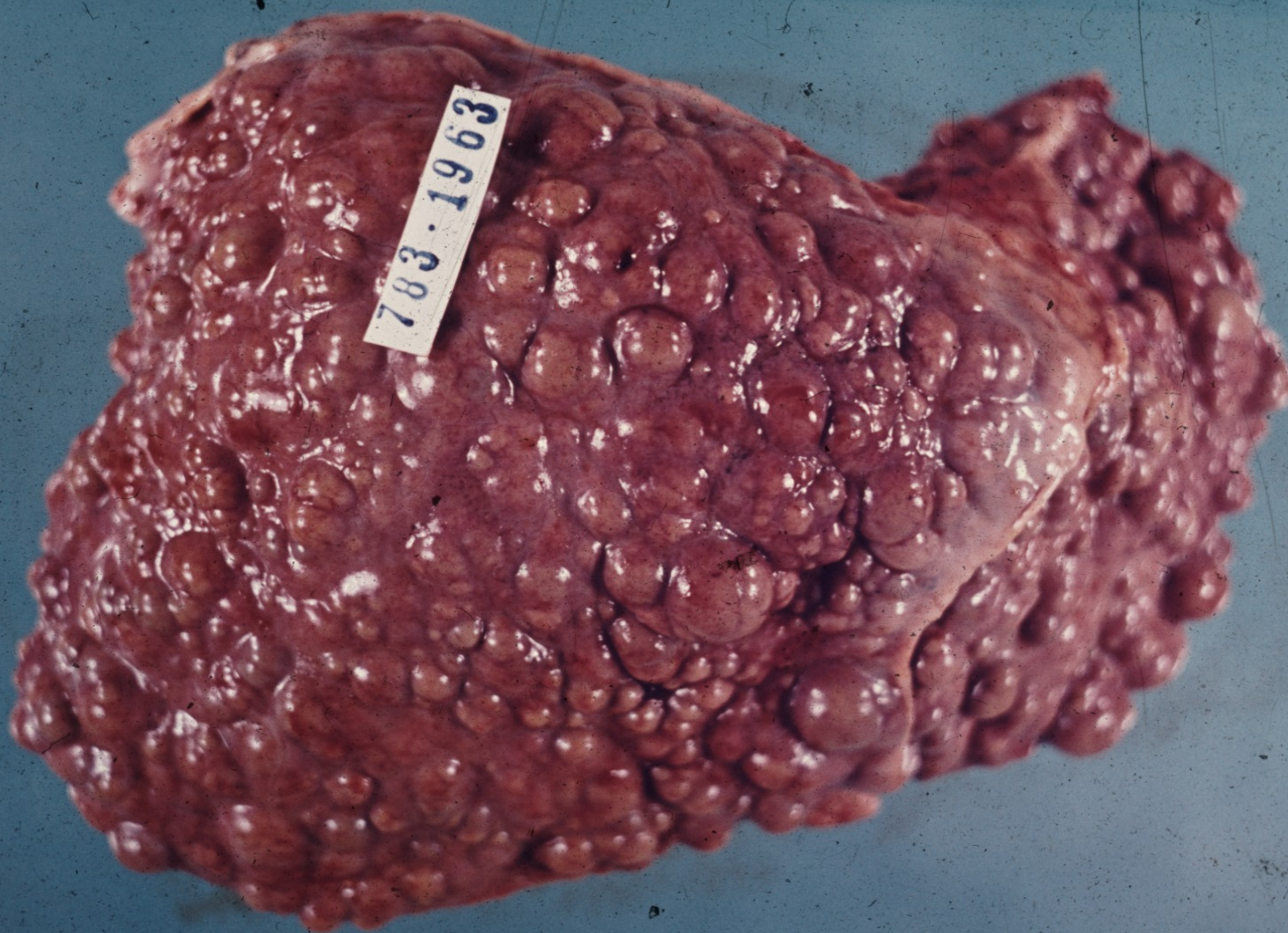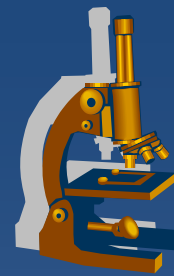
⇒ *cryptogenic cirrhosis*

x Gross: liver usually diminished in size

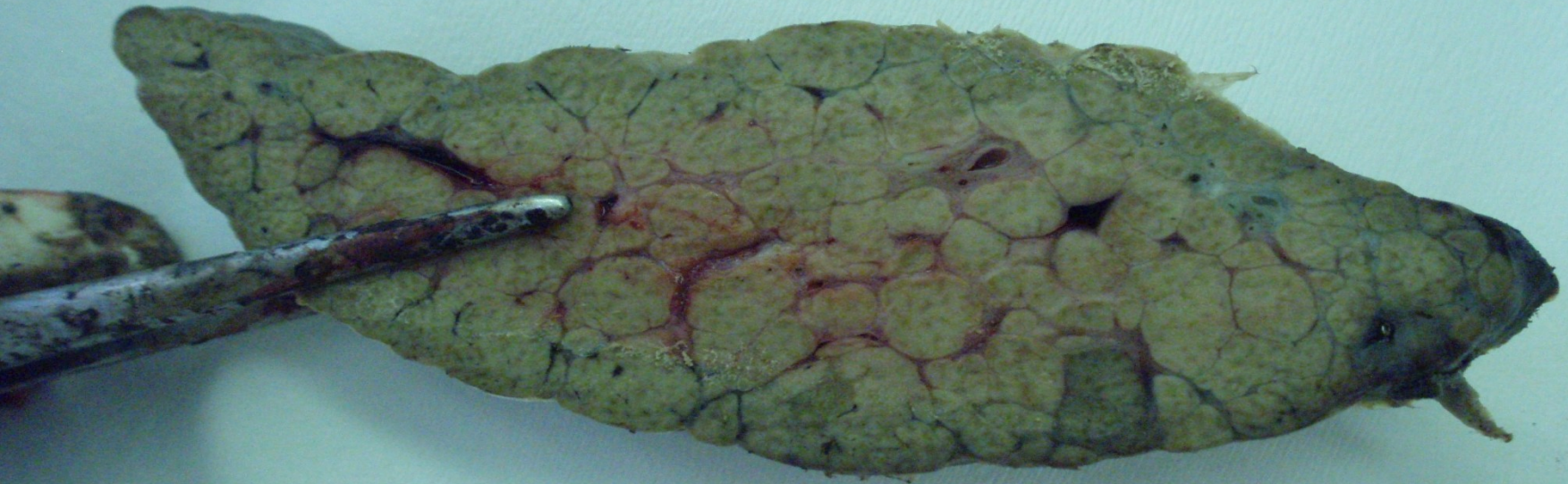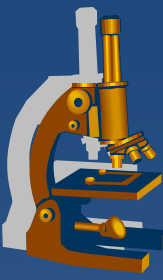
⇒ *micronodular*

⇒ *macronodular*

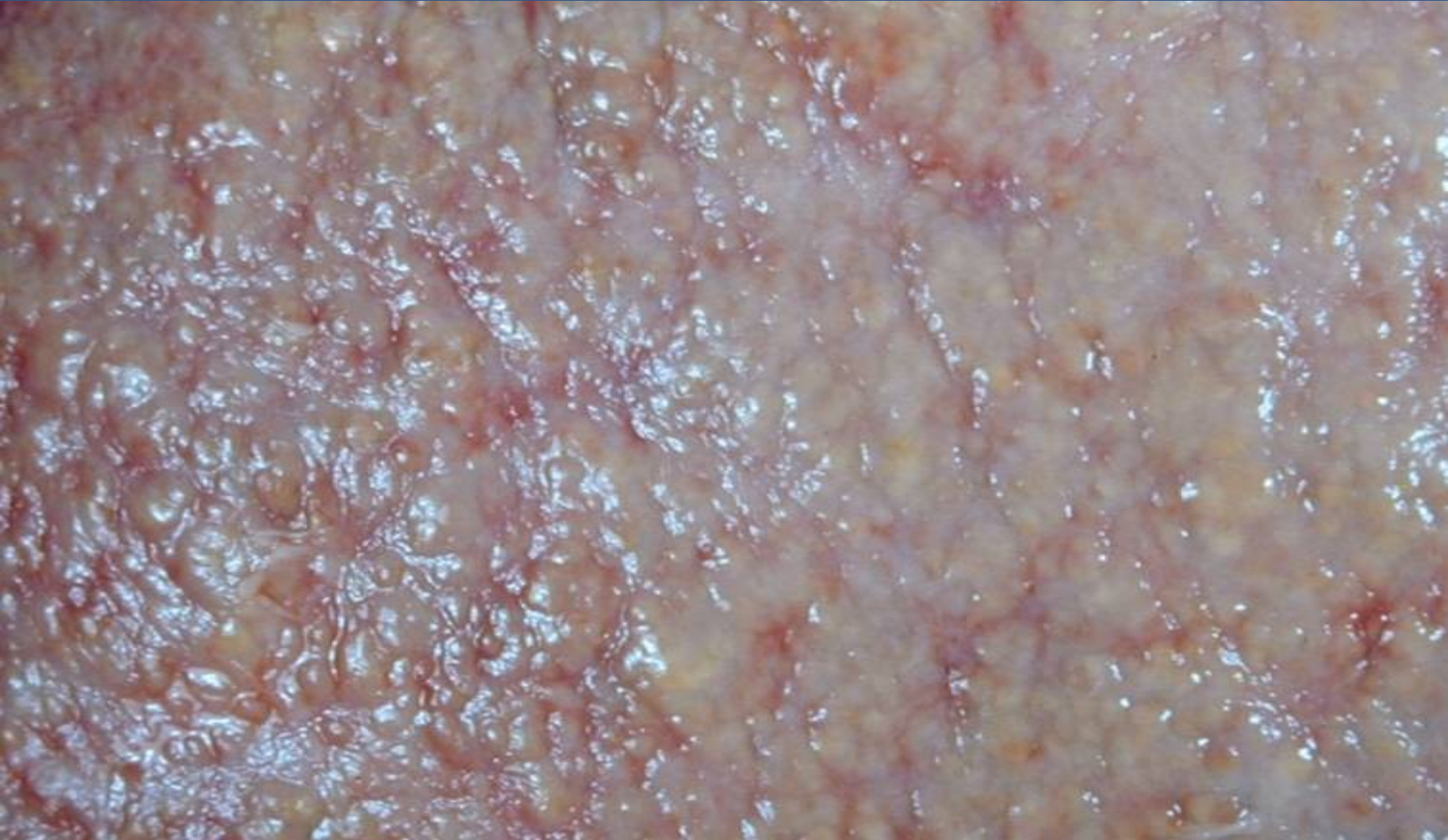Cirrhosis - macronodular



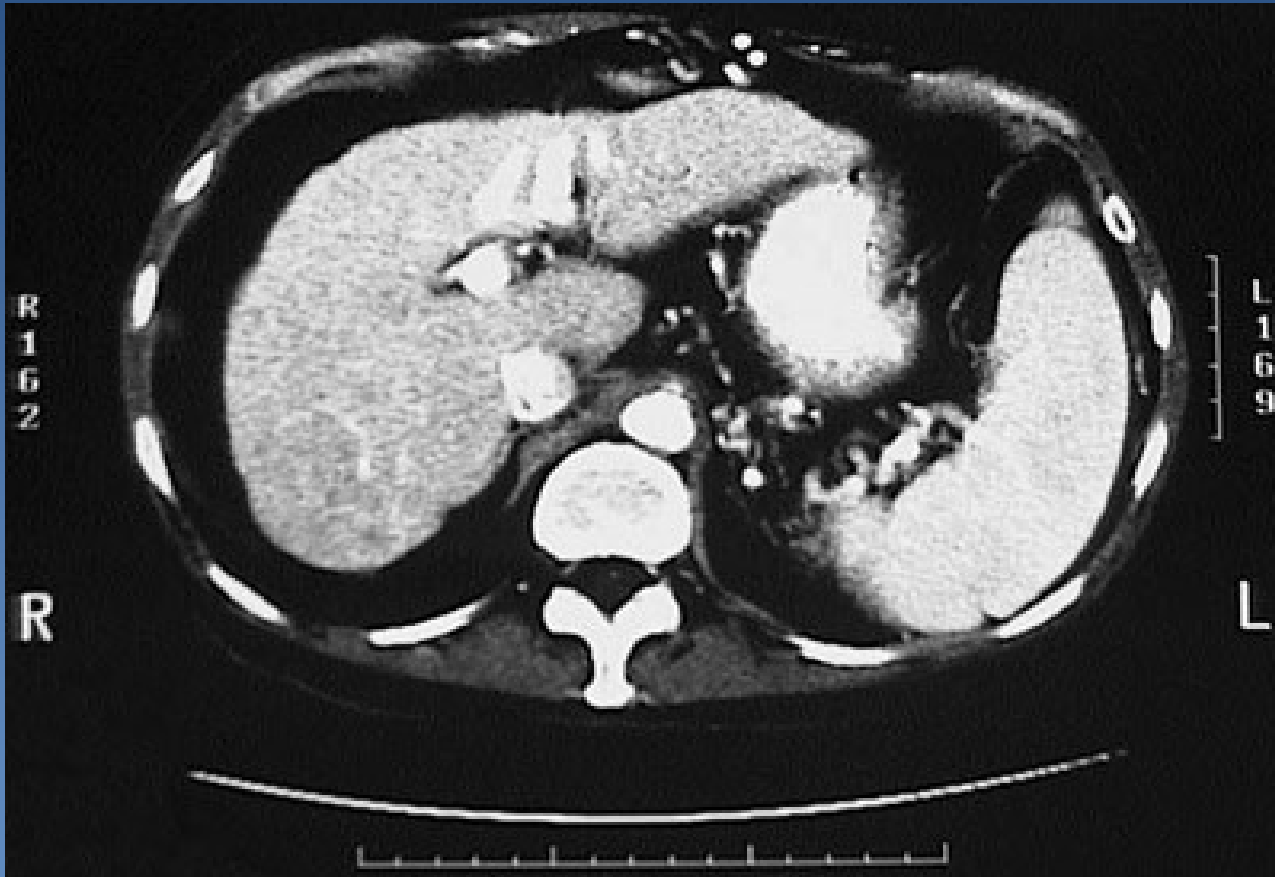
Cirrhosis - micronodular



Advanced liver disease (cirrhosis)

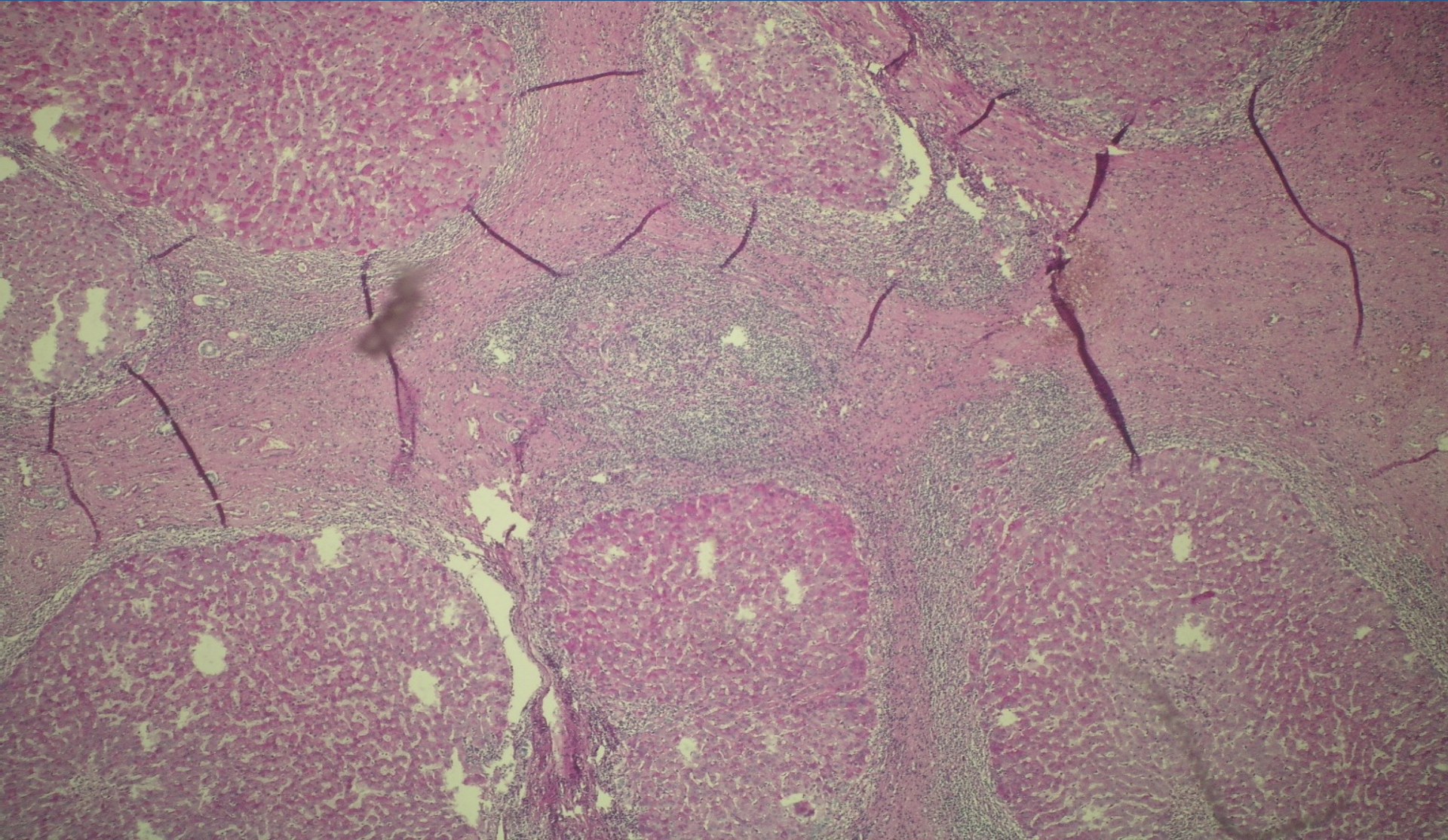


Advanced liver disease (cirrhosis)

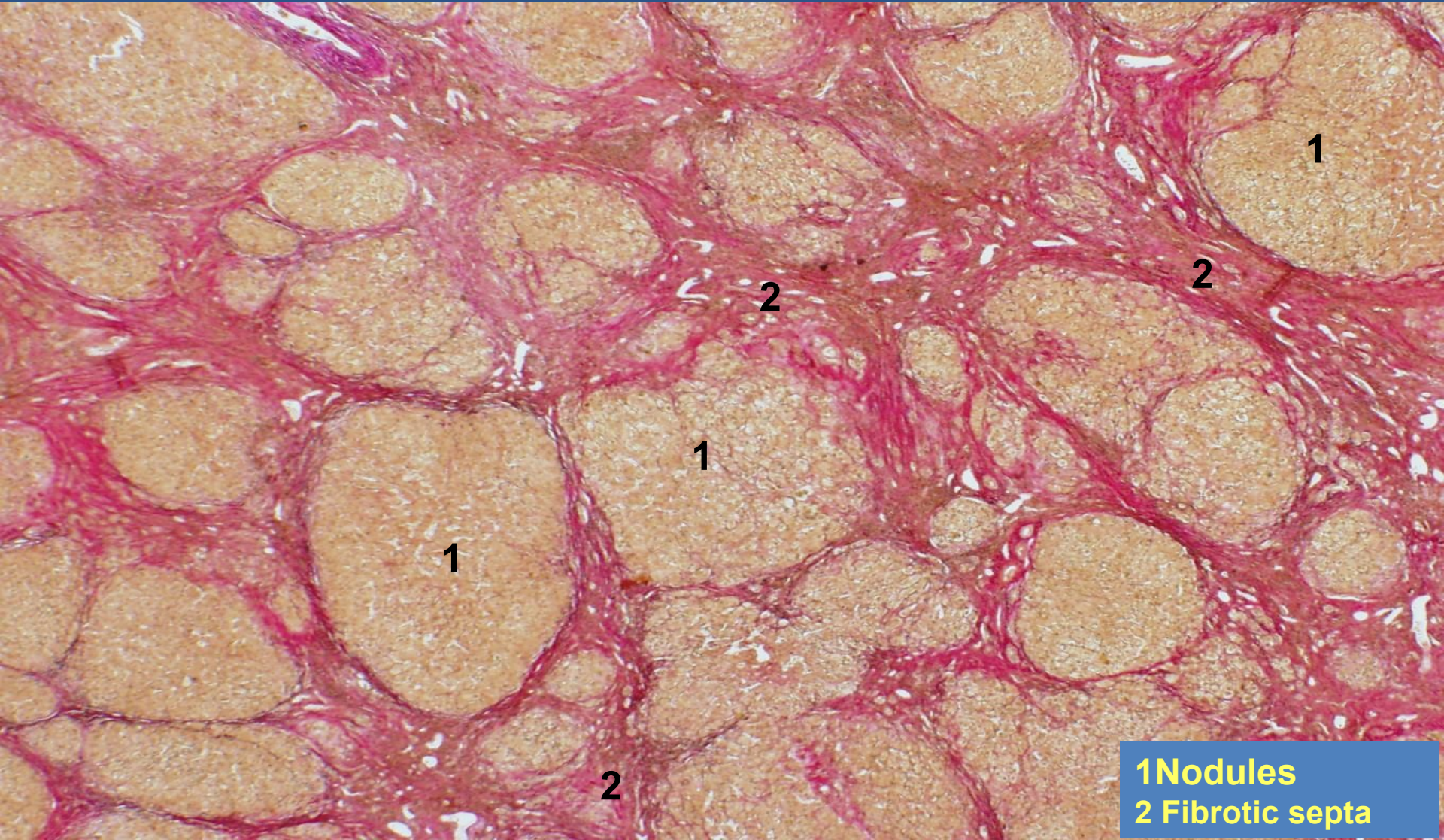


CT scan with contrast of the abdomen in transverse view demonstrates a **small liver with cirrhosis**. The spleen is enlarged from portal hypertension

Advanced liver disease (cirrhosis)

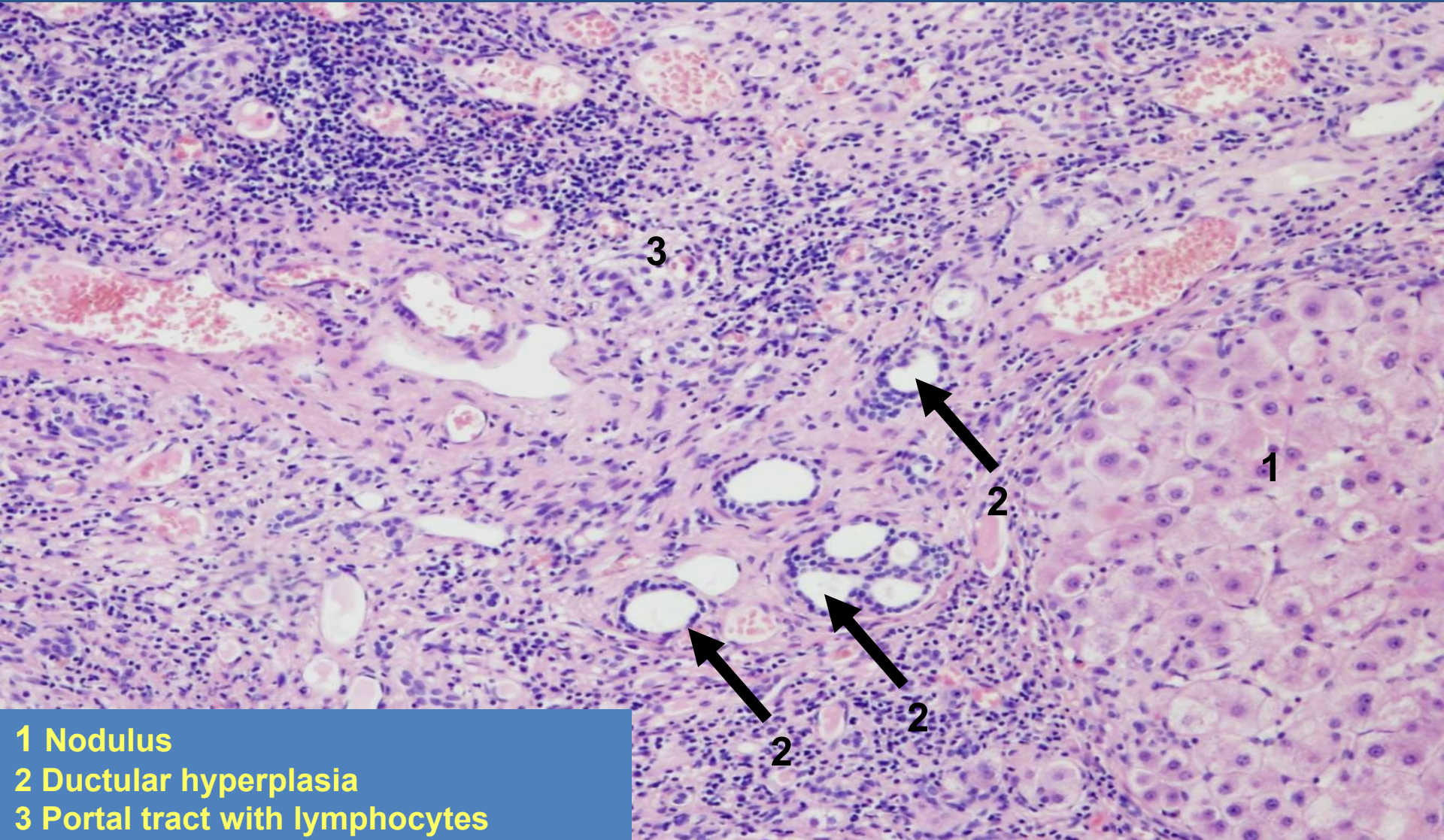


Cirrhosis – fibrotic septa ***(Van Gieson staining)***

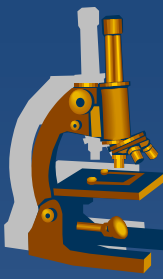


1 Nodules
2 Fibrotic septa

Cirrhosis - ductules



1 Nodulus
2 Ductular hyperplasia
3 Portal tract with lymphocytes



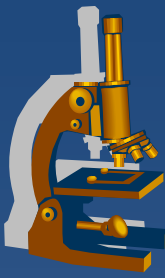
Complications of cirrhosis

- ✘ Insufficiency of liver functions:
 - ⇒ ↓ *synthesis (proteins incl. clotting factors etc.)*
 - ⇒ ↓ *detoxication – hepatic coma*
 - ⇒ ↓ *Kupffer cells function*

- ✘ Portal hypertension:
 - ⇒ *splenomegaly, intestinal venous congestion (! infarsation, inflammation)*
 - ⇒ *ascites (! peritonitis)*
 - ⇒ *portocaval anastomoses (oesophageal varices)*

- ✘ Carcinoma
 - ⇒ *mostly hepatocellular*

Focal lesions and tumors

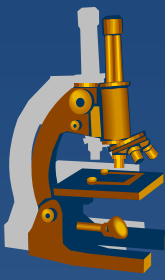


- x Tumor-like lesions**
- x Benign tumors**
- x Malignant tumors:**
 - ⇒ *primary, secondary*

Tumor-like lesions



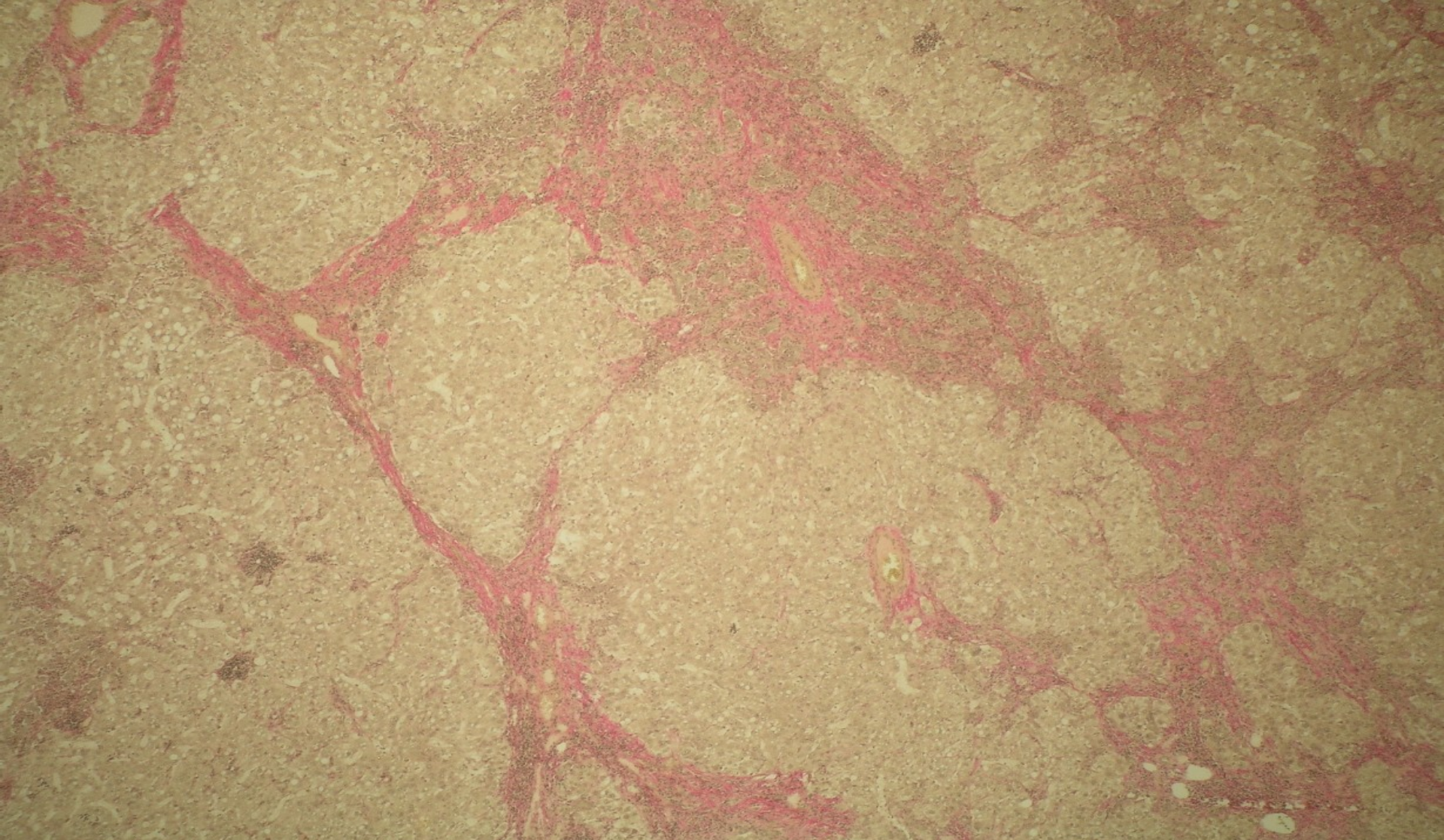
- x Focal nodular hyperplasia**
- x Nodular regenerative hyperplasia
(lack of fibrosis)**
- x Cysts**
- x Biliary hamartoma (von Meyenburg
complex)**



Focal nodular hyperplasia

- ✘ Localized benign hepatocellular nodules with central stellate fibrous scar
- ✘ Single or multiple
- ✘ More common in females, oral contraceptives – estrogens
- ✘ Diff. dg. x tumors

FNH – fibrotic scar



Benign tumors



Adenoma

×hepatocellular

⇒ *lack of portal tracts, regular trabeculae*

×cholangiocellular

⇒ *biliary, accumulation of regular ducts, lack of bile production, less than 1cm, subcapsular*

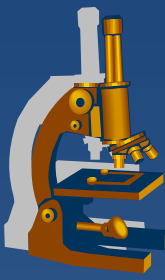
×cystadenoma

⇒ *mucinous, rare*

Haemangioma

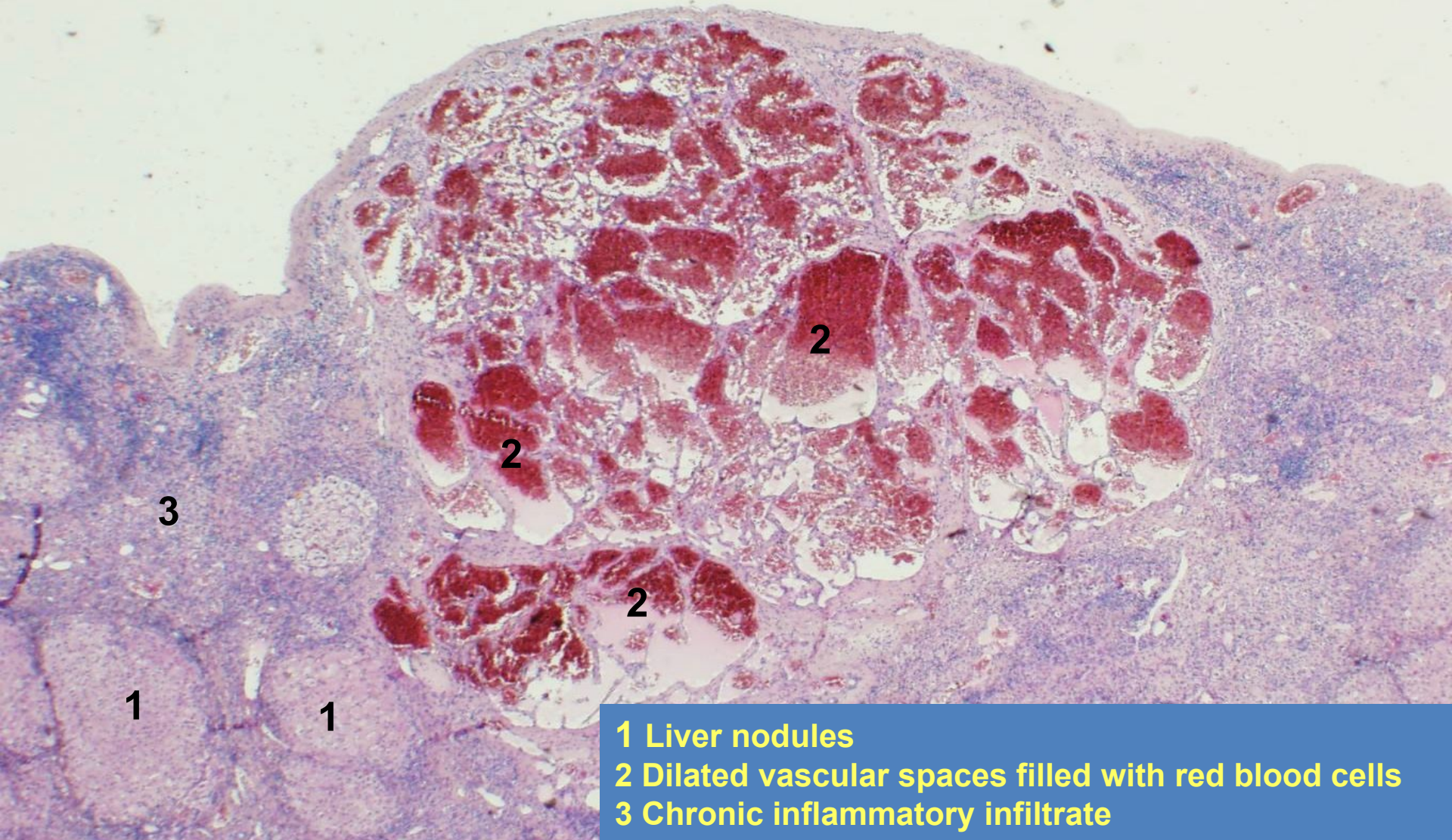
×cavernous

Cavernous haemangioma



- ✗ hamartoma, commonly multiple
- ✗ 2 mm – 15 cm
- ✗ risk of rupture + bleeding, consumption coagulopathy
- ✗ common regressive changes – atypical US, CT, dif. dg. x malignancy
- ✗ dark spongiotic demarcated focus
- ✗ fibrous septa + vascular spaces

Cavernous haemangioma (in micronodular liver cirrhosis)

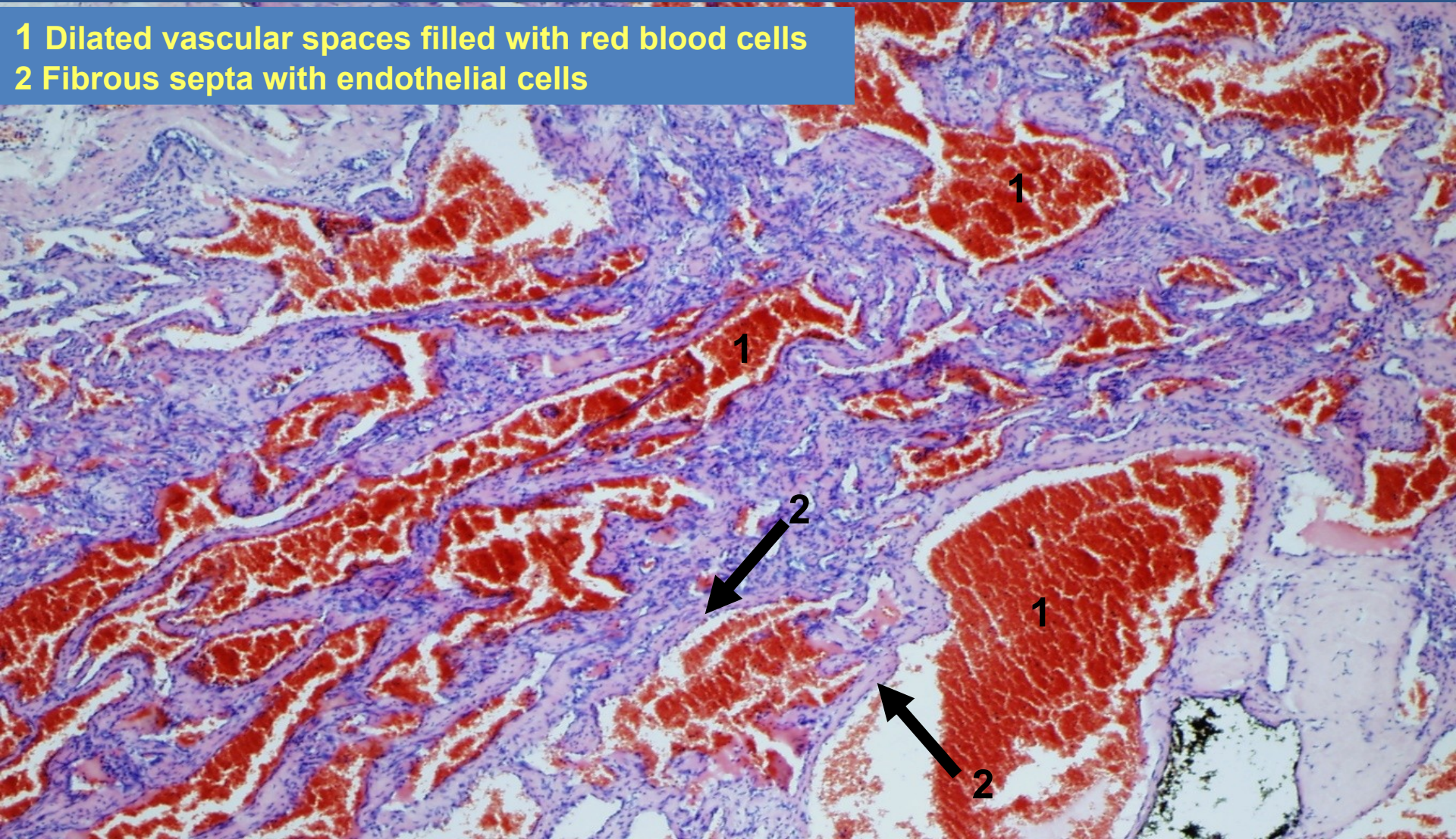


- 1 Liver nodules**
- 2 Dilated vascular spaces filled with red blood cells**
- 3 Chronic inflammatory infiltrate**

Cavernous haemangioma



1 Dilated vascular spaces filled with red blood cells
2 Fibrous septa with endothelial cells



Malignant tumors



x Primary

⇒ *Hepatocellular carcinoma (90%)*

⇒ *Cholangiocarcinoma*

⇒ *Hepatoblastoma*

- children

⇒ *Angiosarcoma*

- associated with vinyl chloride, arsenic, or Thorotrast exposure

Malignant tumors



xSecondary

⇒ ***Metastatic carcinomas***

- most common liver malignancy (GIT, lung, breast, kidney,...)

⇒ ***Direct spread of adjacent malignant tumors***

- gall bladder, pancreas

⇒ ***Other metastasing tumors***

- melanoma, sarcomas etc.

⇒ ***Haemopoetic neoplasms***

- leukemia infiltrates, lymphomas

Preneoplastic changes



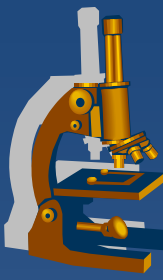
x Liver cell dysplasia

⇒ *low grade, high grade*

⇒ *usually in cirrhosis*

⇒ *small foci or nodules, microcellular – smaller cells with less cytoplasm + bigger nuclei*

Diff. dg. x well diff. HCC

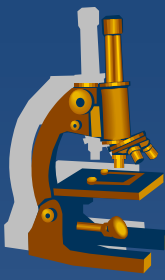


Hepatocellular carcinoma

- ✗ World-wide 5th most common malignancy in males, 8th in females
- ✗ Possible primary prevention
- ✗ Different incidence due to geography / cause

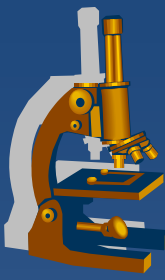
High-income countries: now lower incidence, usually in cirrhosis (alcohol), ↑ (NASH, HCV)

Eastern Asia (HBV) + Africa (aflatoxin) – 80% of cases



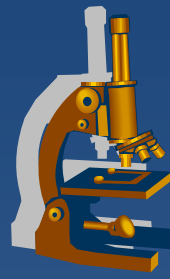
Hepatocellular carcinoma

- x** Single or more nodules different from adjacent tissue
 - ⇒ *multifocal start or intrahepatic metastases*
- x** Micro
 - ⇒ *trabecular, acinar +/- pseudoglandular, solid*
 - ⇒ *enlarged nuclei + nucleoli, ↑ mitotic activity, atypias; eosinophilic – pale cytoplasm*
- x** Possible steatosis, bile production

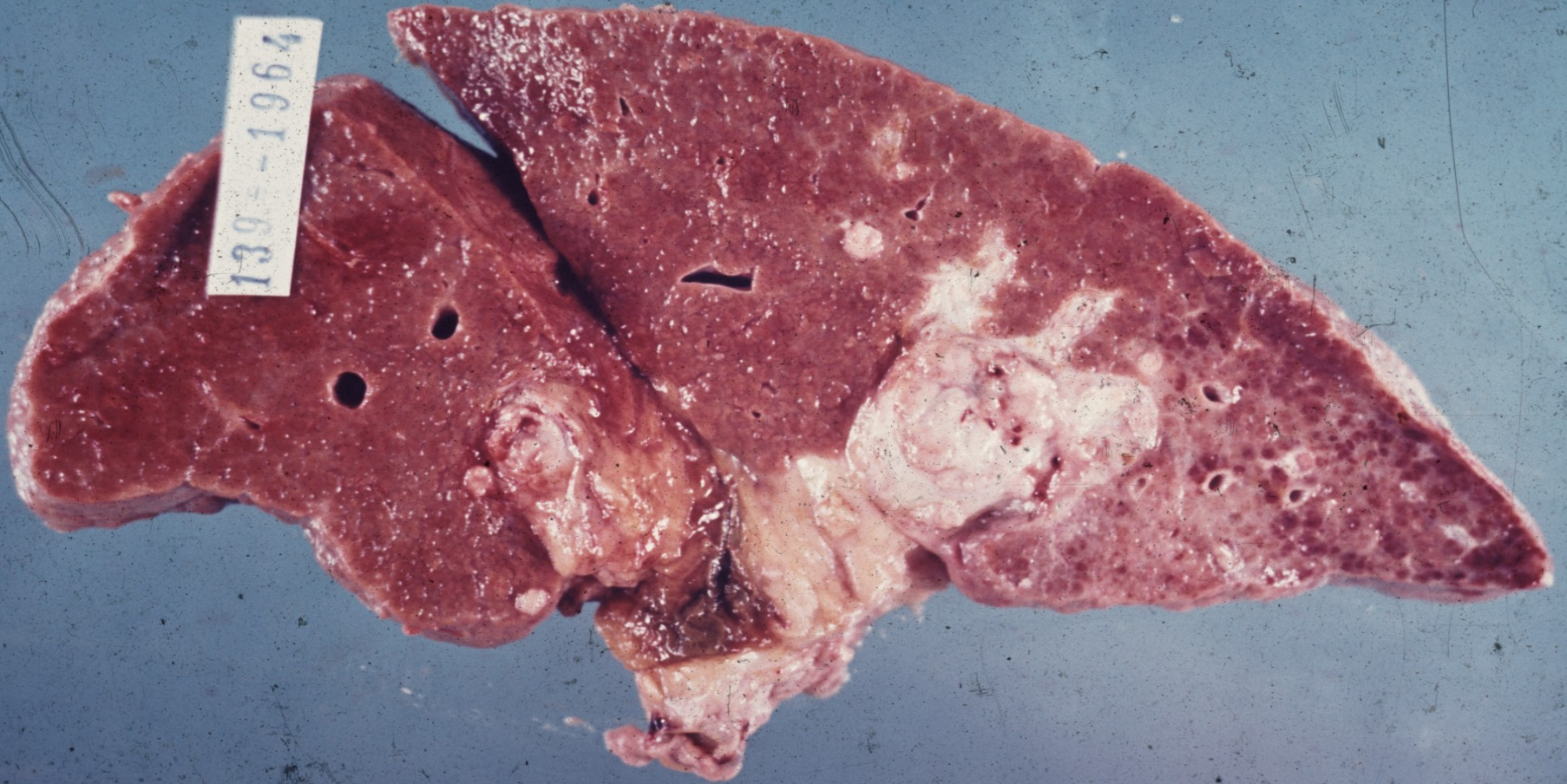


Hepatocellular carcinoma

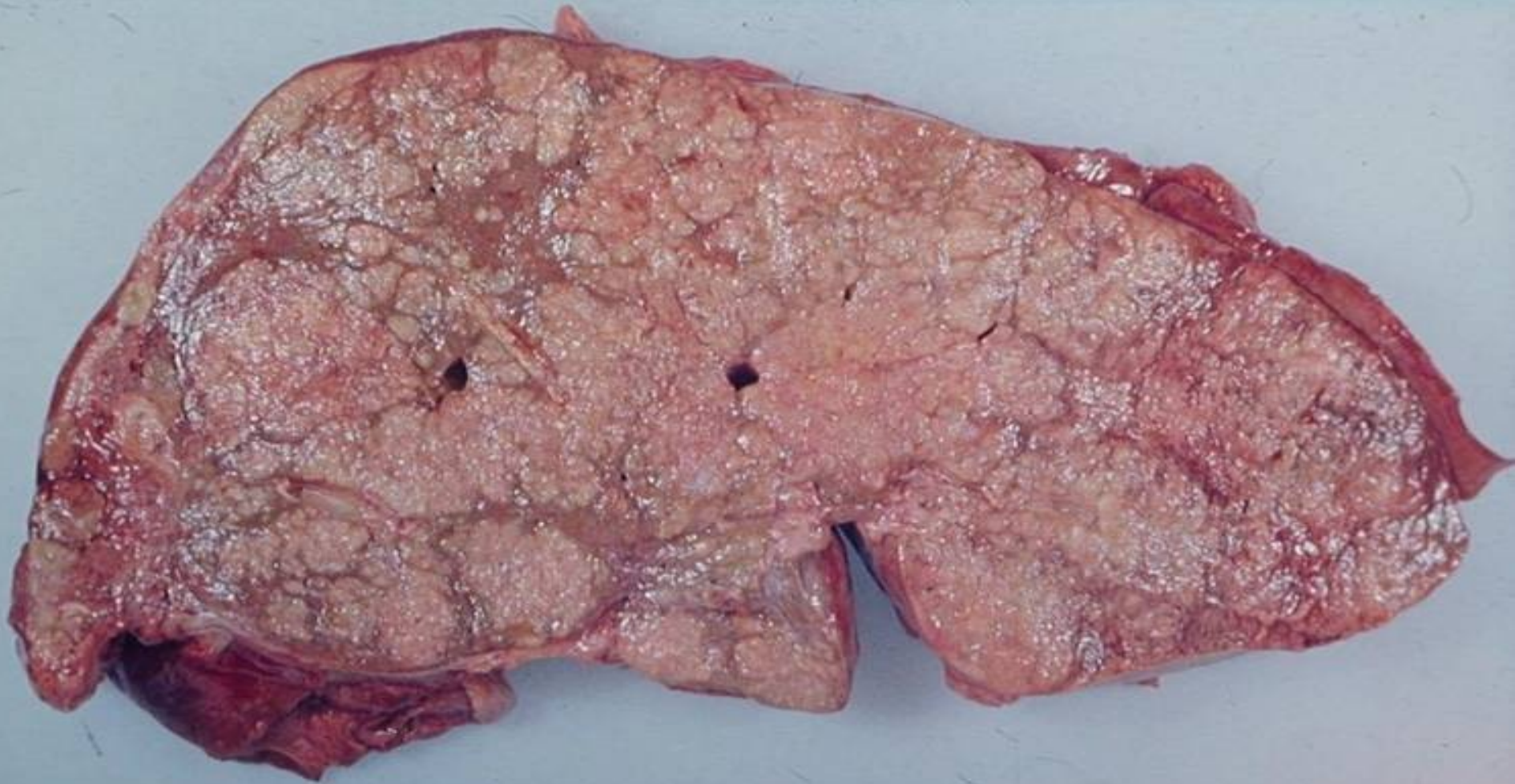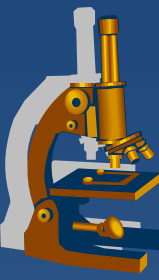
- x** angioinvasion
 - ⇒ *mostly venous*
- x** metastases
 - ⇒ *lung, bones, LN*
- x** small solitary (→3) focus
 - ⇒ *excision, transplantation*
- x** large, multiple
 - ⇒ *ablation, bad prognosis*
- x** secondary prevention
 - ⇒ *regular check-up of cirrhotic patients*



Hepatocellular carcinoma

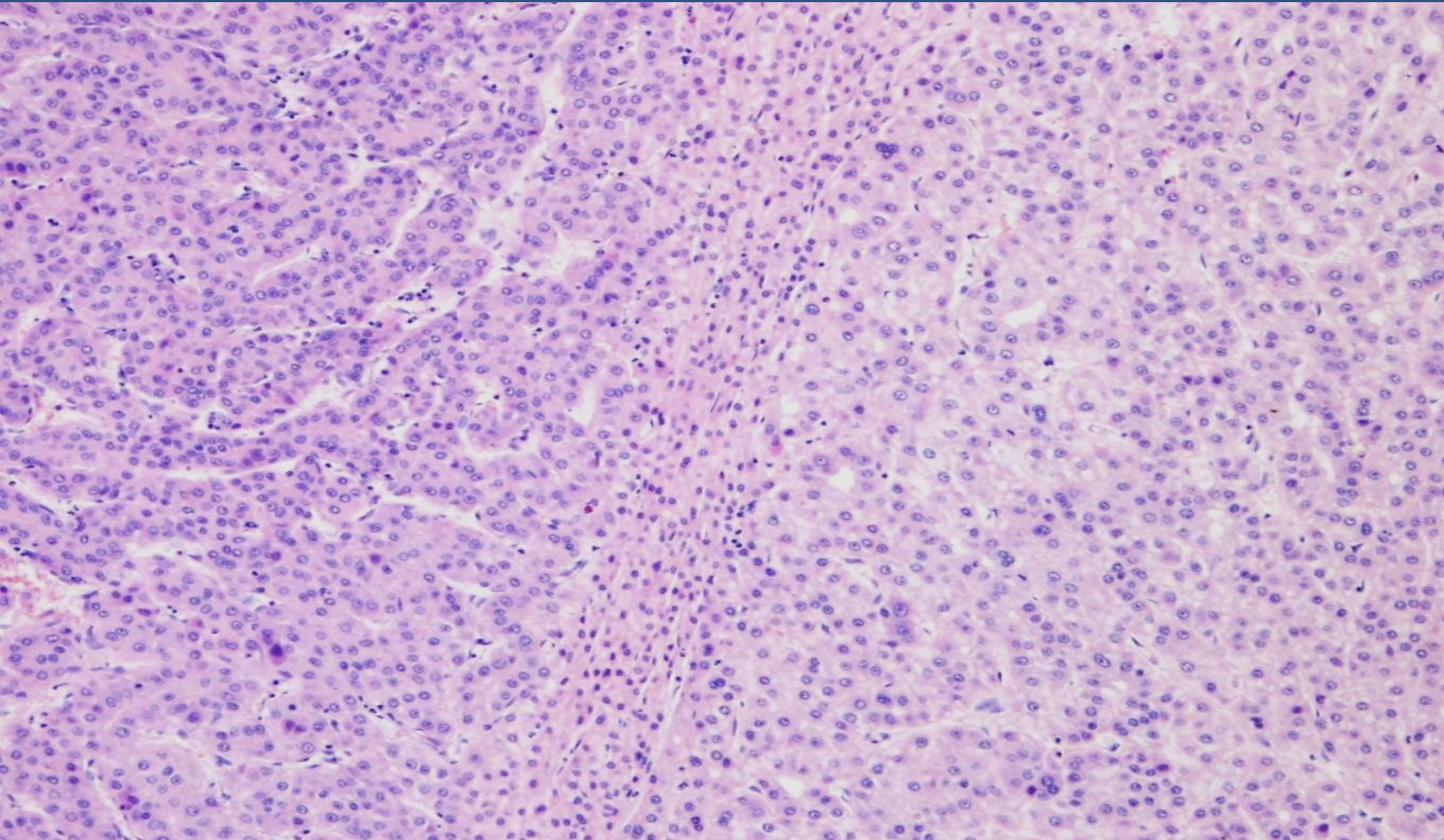
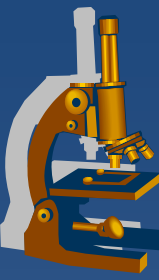


HCC

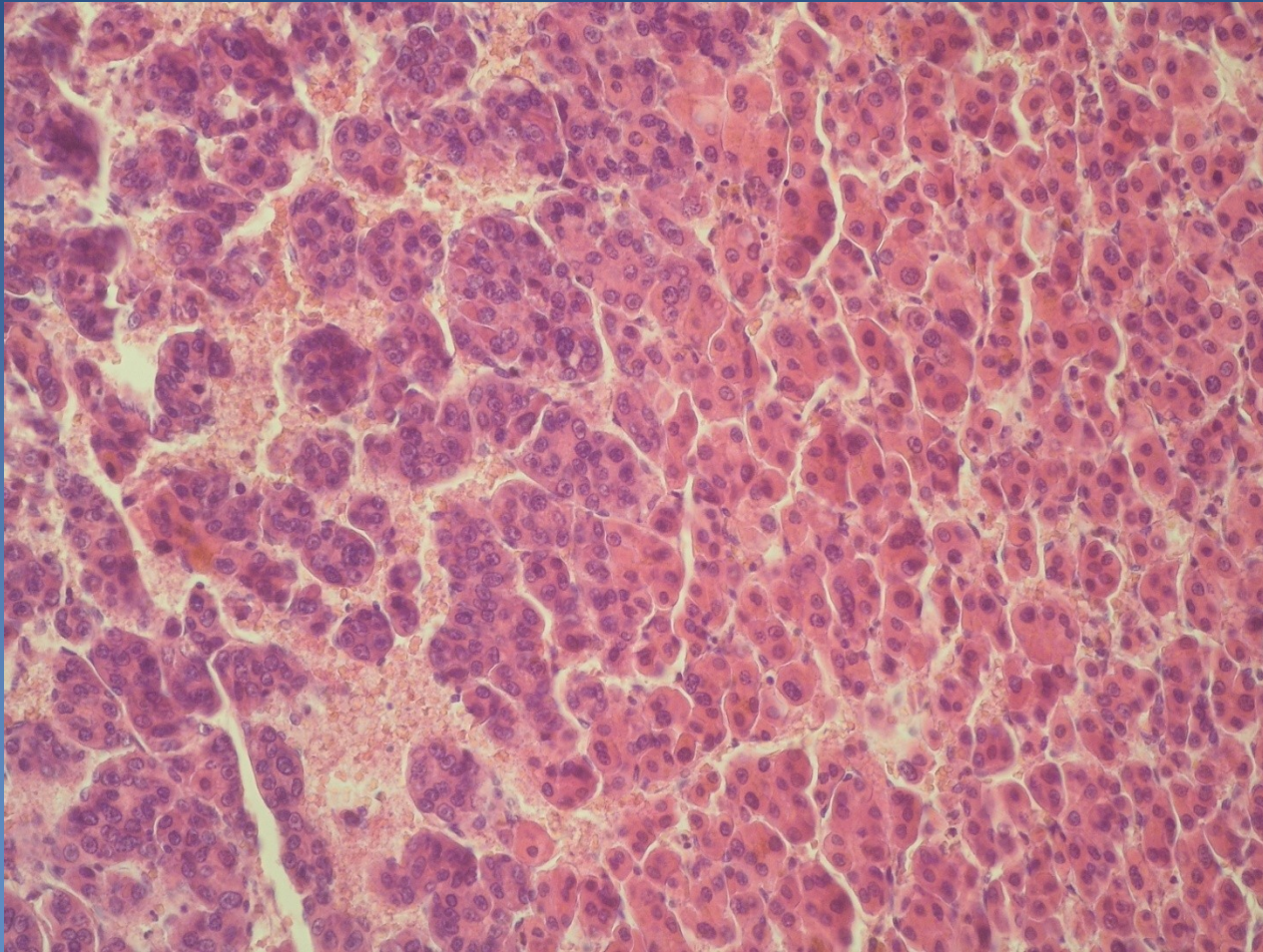
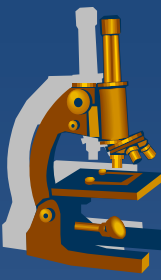


P 400/72

HCC



HCC

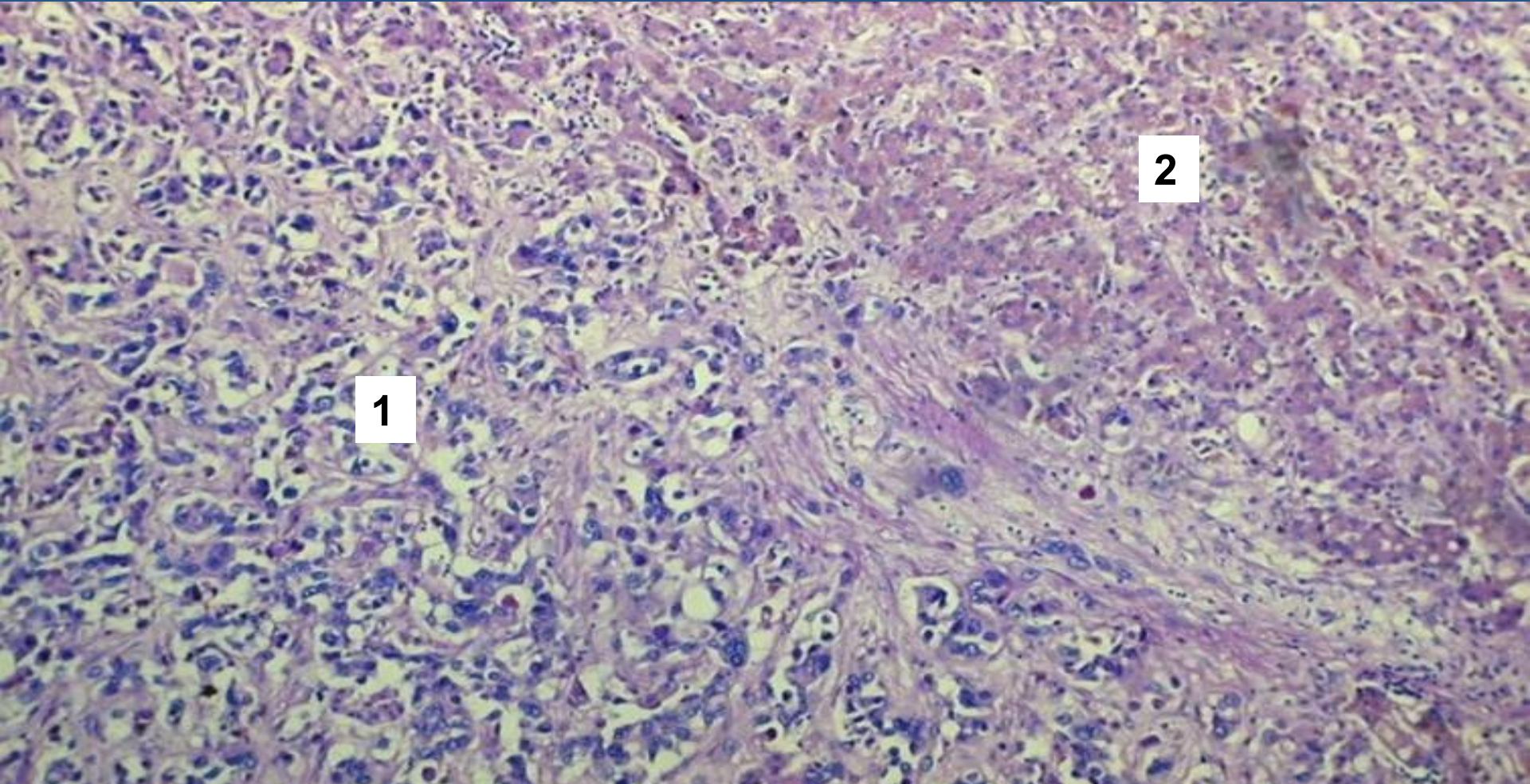


Cholangiocarcinoma



- × From intrahepatic biliary ducts
- × ↑ risk in PSC, HCV cirrhosis, ...
- × mucin secretion, no bilirubin pigment
- × irregular ducts, strands of cells
- × diff. dg. × metastatic or direct spread –
gallbladder, pancreas, colorectal ca
- × mostly bad prognosis

Cholangiocarcinoma

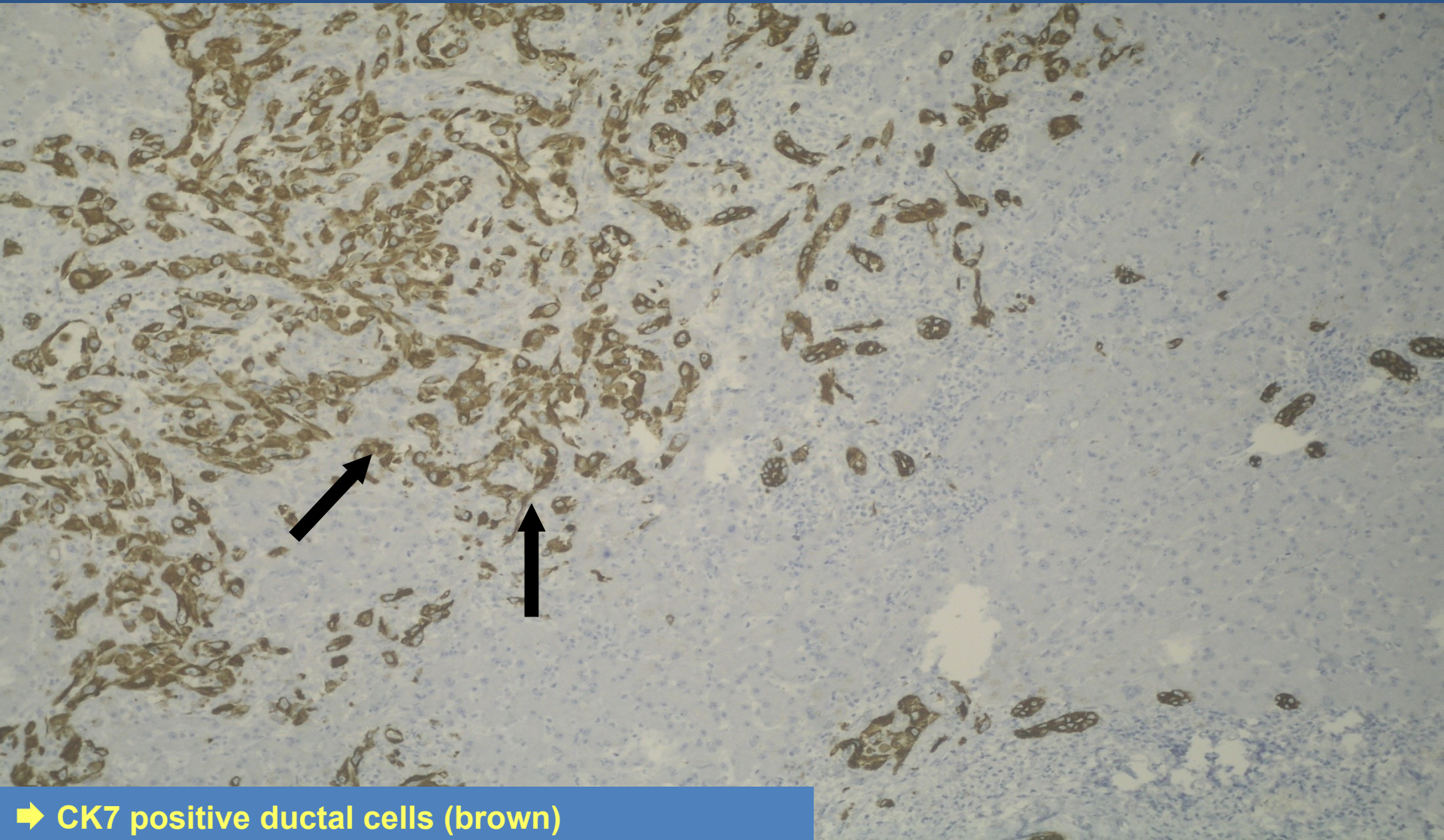
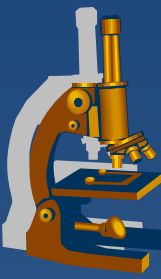


1

2

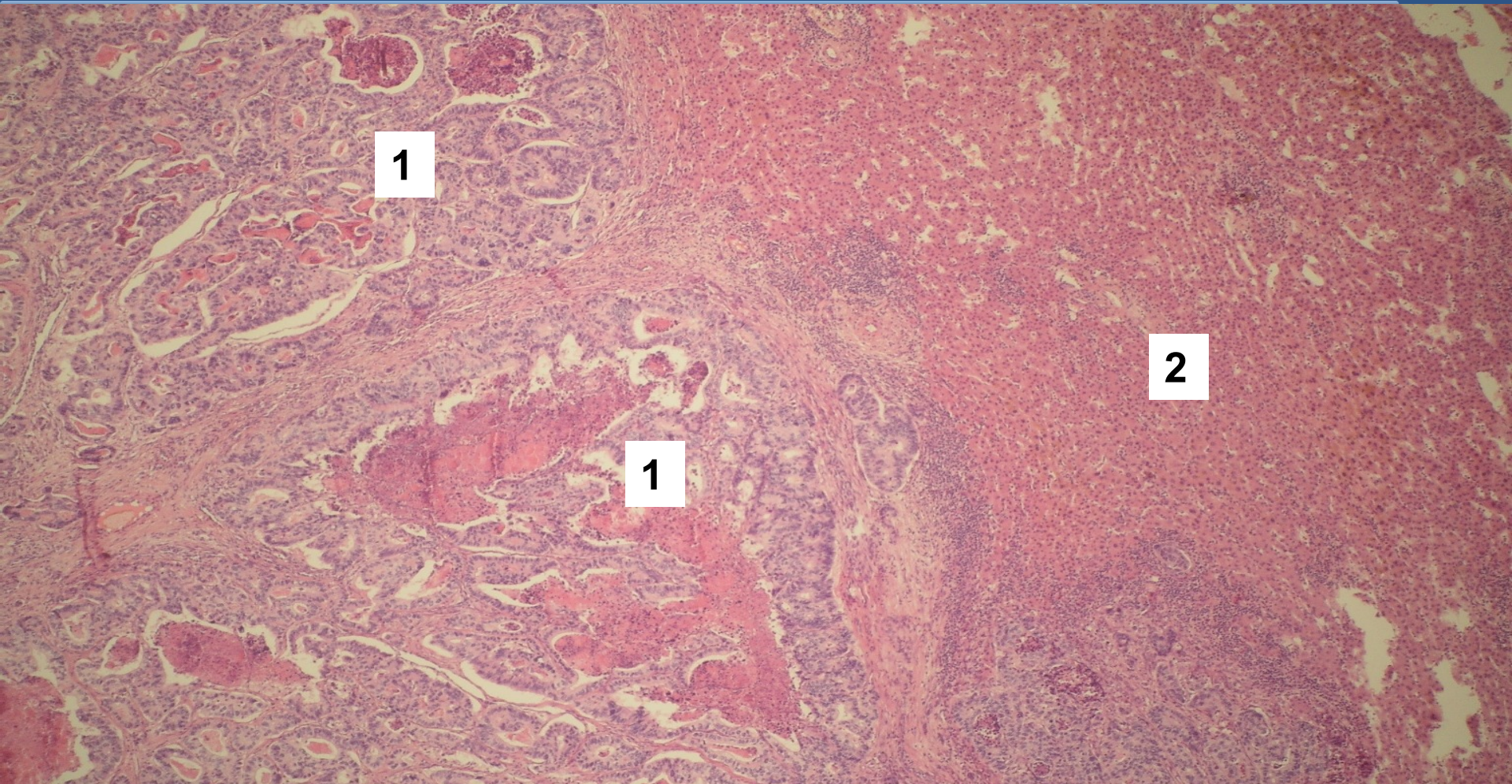
1 Cholangiocarcinoma
2 Liver parenchyma

Cholangiocarcinoma ***(IHC CK7)***



➡ CK7 positive ductal cells (brown)

Colorectal ca metastasis



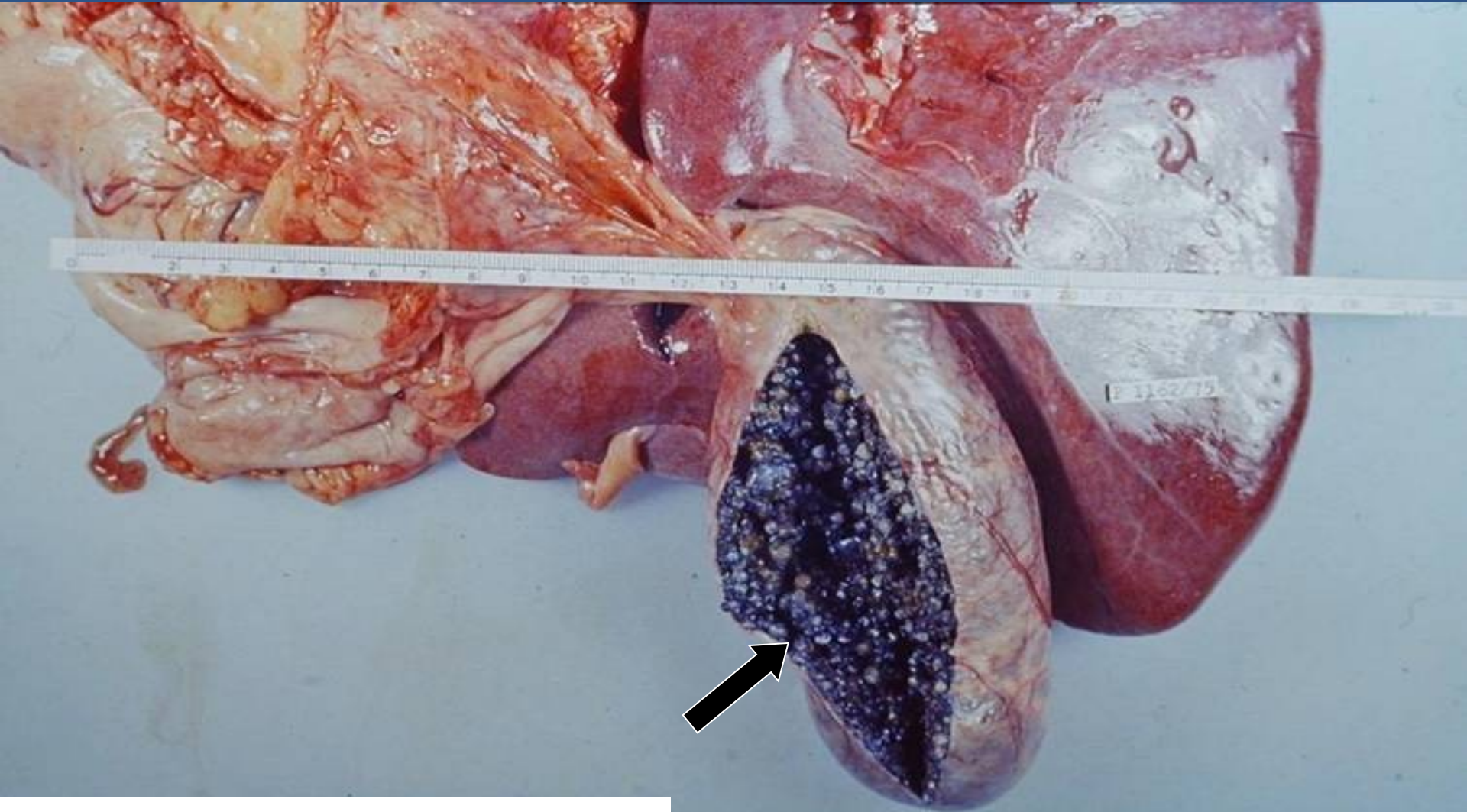
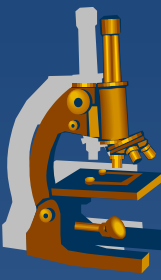
1

1

2

1 Tubular formations of colorectal adenocarcinoma
2 Liver parenchyma

Cholecystolithiasis



➡ Gallbladder filled with stones

Cholecystitis



x Acute calculous

- ⇒ *Obstruction of GB neck or cystic duct*
- ⇒ *Local pain radiating to right shoulder*
- ⇒ *Fever, nausea, leukocytosis*
- ⇒ *Potential surgical emergency*

empyema of gallbladder

gangrenous cholecystitis

Cholecystitis



x Acute acalculous

⇒ *less common, ischemic (postoperative, trauma, burns, sepsis,...)*

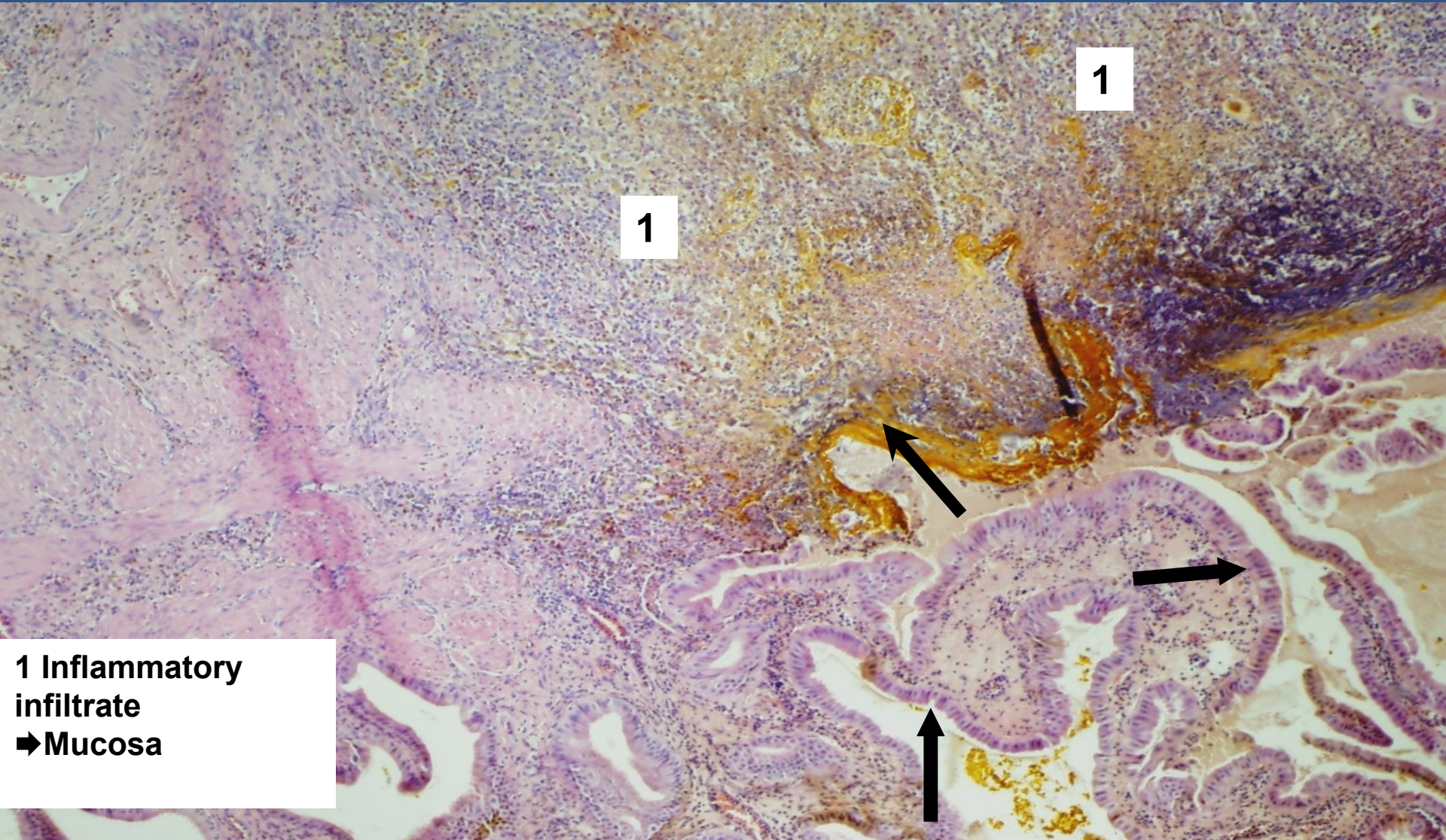
x Chronic

⇒ *Recurrent attacks of pain*

⇒ *Nausea and vomiting*

⇒ *Associated with fatty meals*

Cholecystitis

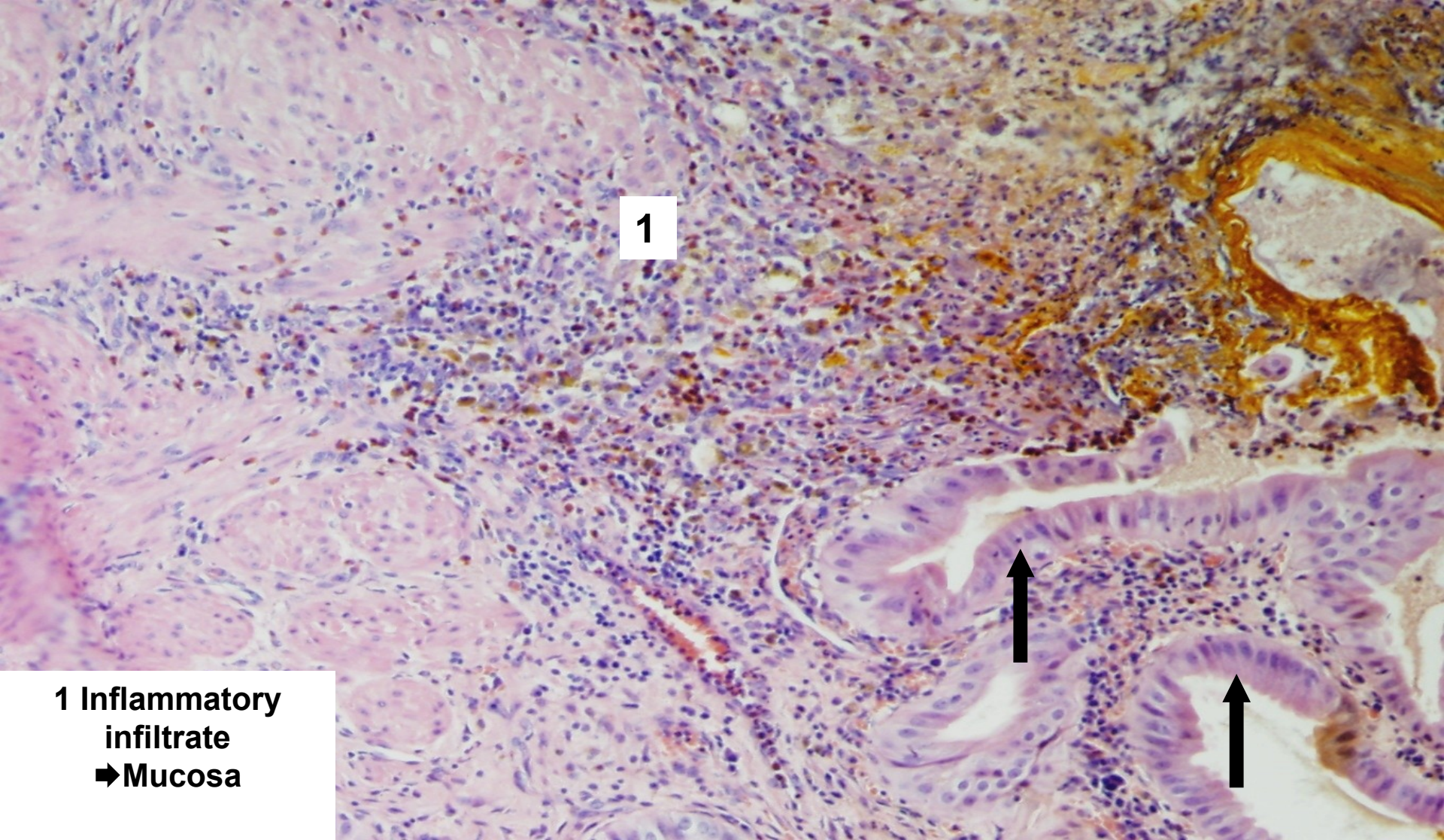


1

1

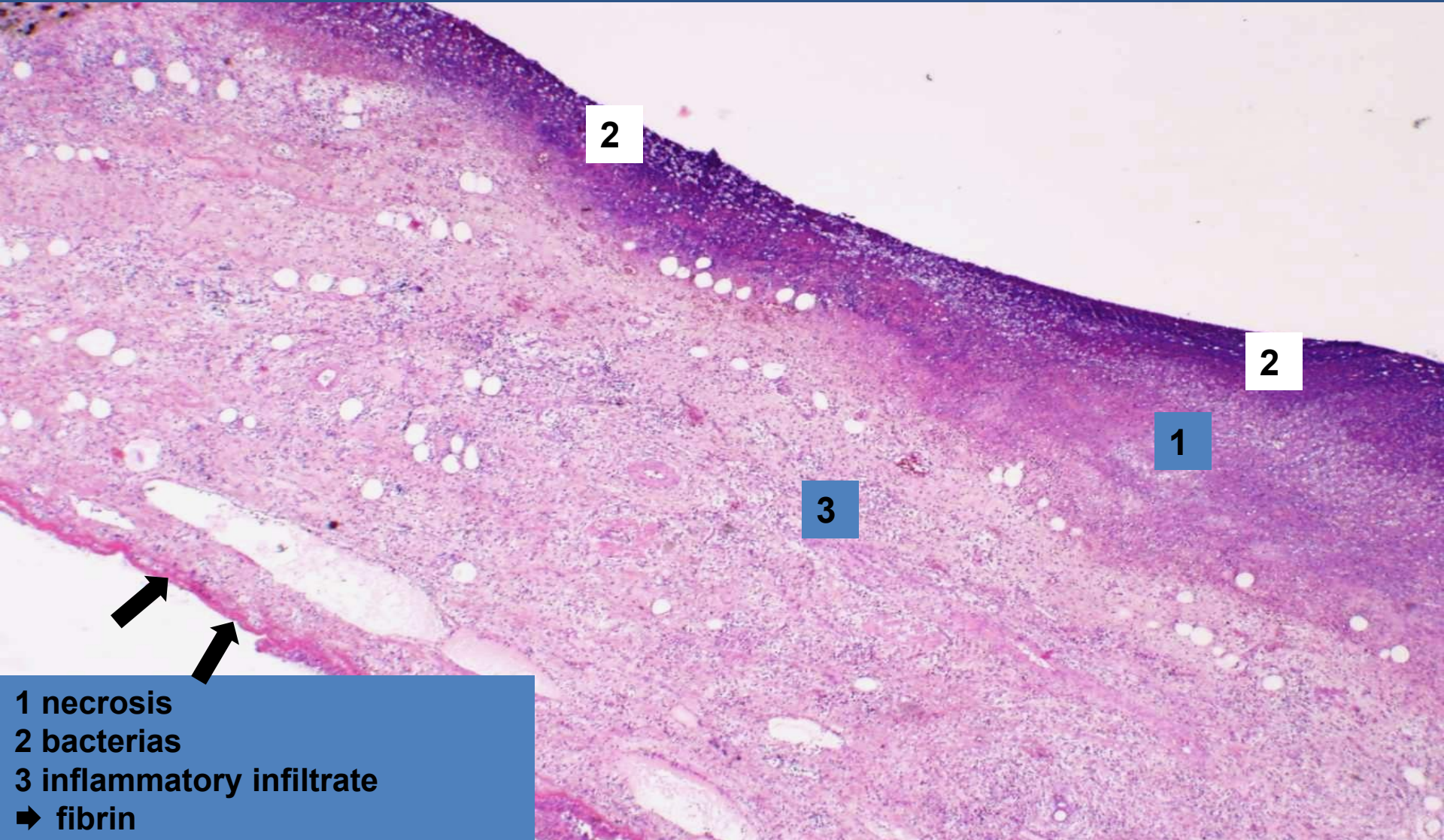
1 Inflammatory infiltrate
➔ Mucosa

Cholecystitis



**1 Inflammatory
infiltrate
➔ Mucosa**

Gangrenous cholecystitis



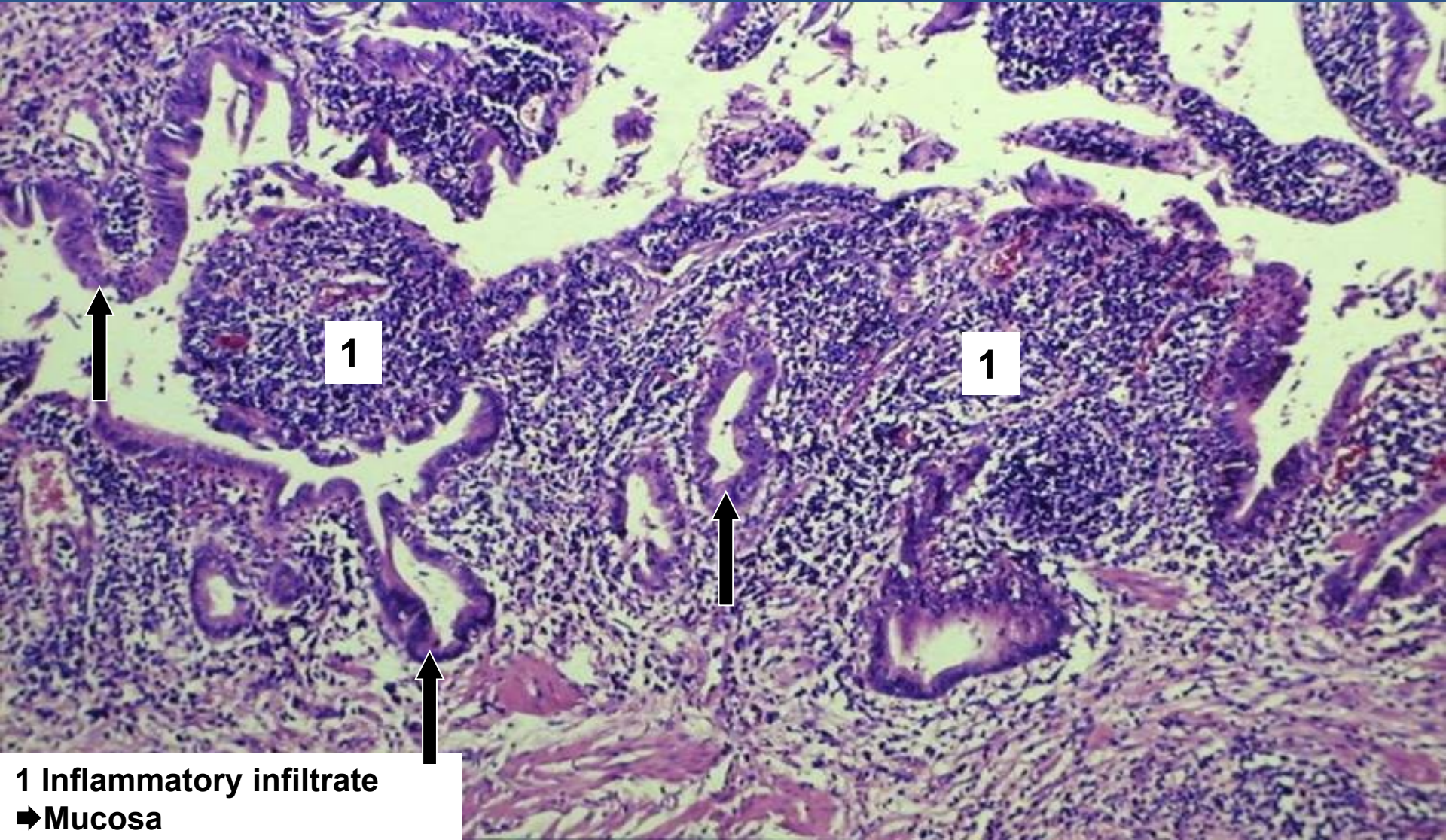
1 necrosis
2 bacterias
3 inflammatory infiltrate
➔ fibrin

Chronic cholecystitis



- ✗ Fibroproduction
 - ⇒ *thickening of the wall, adhesion, diff. dg. x ca*
- ✗ Chronic inflammation
- ✗ Reactive epithelial atypias and metaplasia
 - Possible dysplasia
 - ⇒ ↑ *ca risk*
- ✗ Dystrophic calcification
- ✗ Gallbladder hydrops

Chronic cholecystitis



1

1

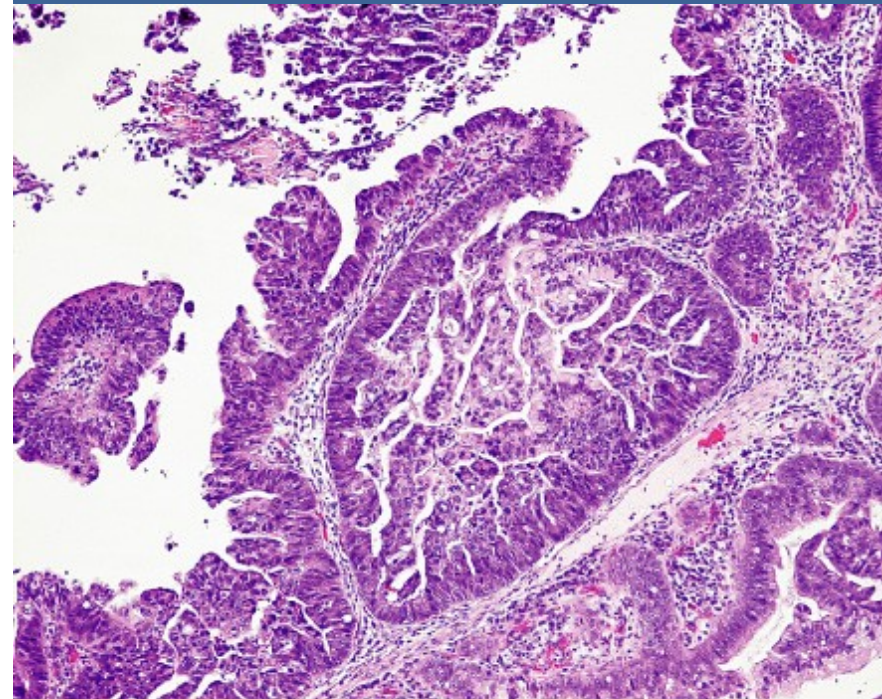
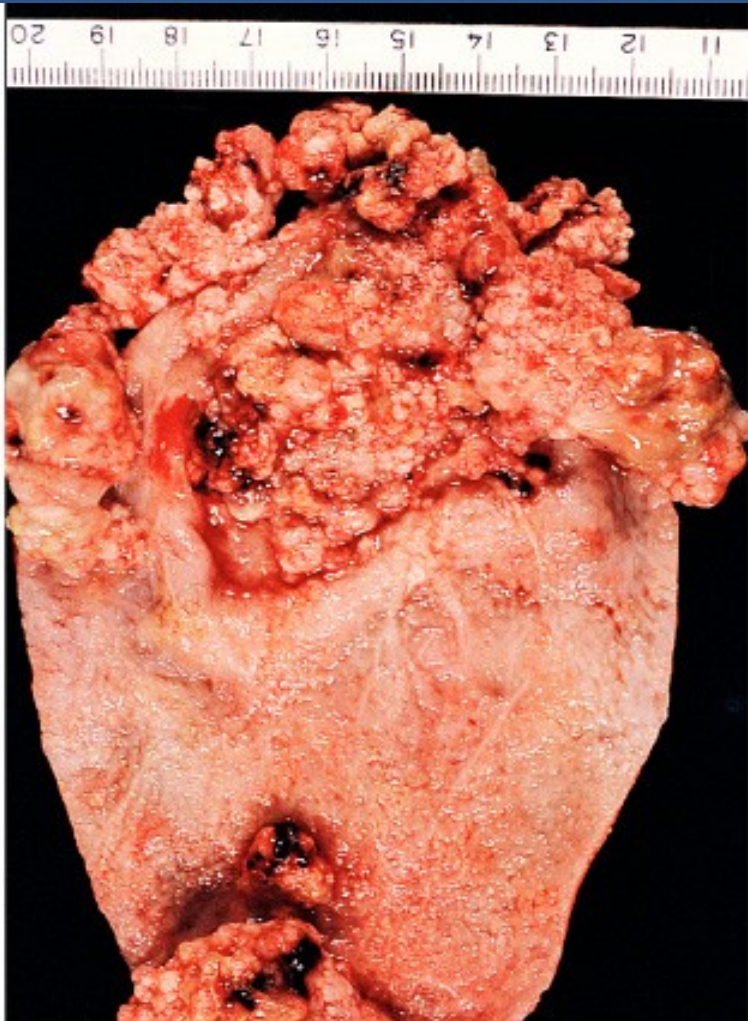1 Inflammatory infiltrate
➔ Mucosa

Gallbladder carcinoma



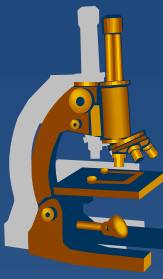
- ✘ Seventh decade
- ✘ F > M
- ✘ Discovered at late stage, usually accidental
- ✘ Adenocarcinoma, other types
- ✘ Local extension into liver, cystic duct, portal LN
- ✘ Mean 5 yrs survival 1%
 - ⇒ *better prognosis if accidental finding in CHCE in incipient stage*

Gallbladder carcinoma

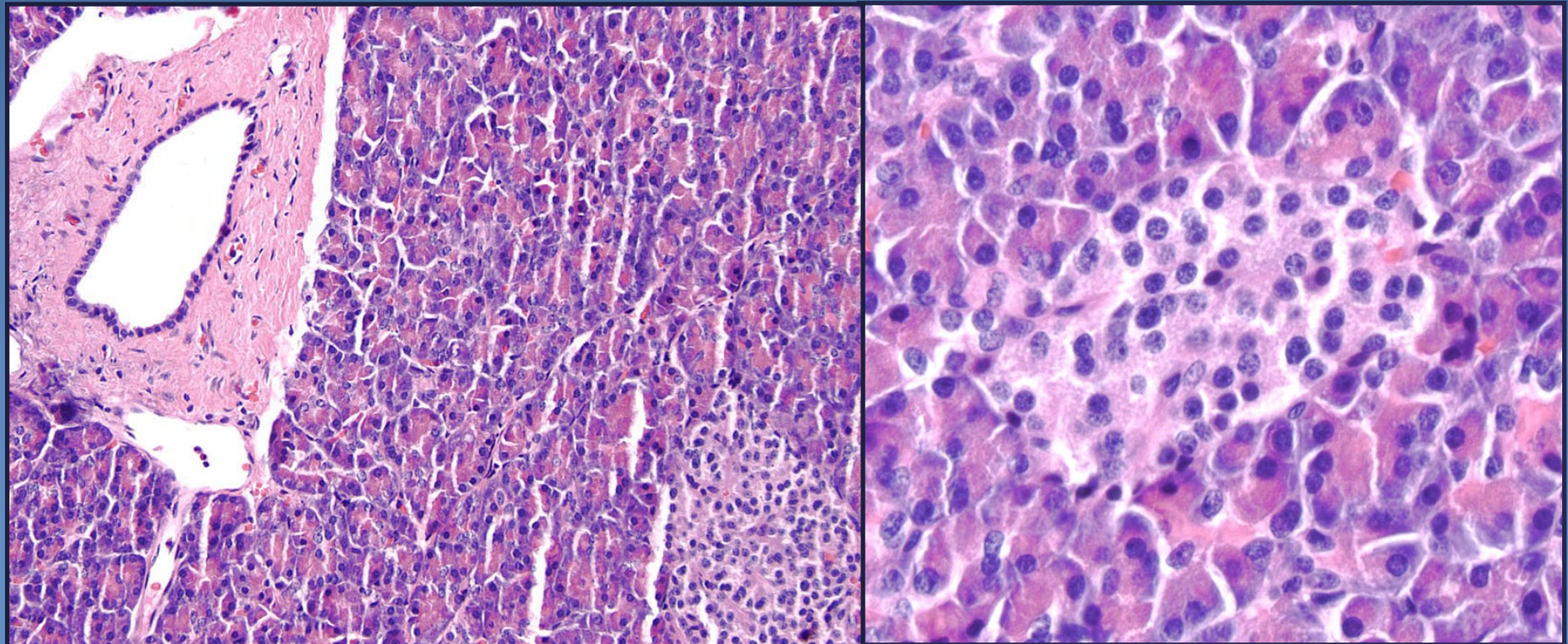


© Elsevier Inc 2004 Rosai and Ackerman's Surgical Pathology 9e

Pathology of pancreas



- ✘ Exocrine
- ✘ Endocrine



Acute pancreatitis



× etiological factors:

⇒ **Metabolic**

- Alcohol
- Hyperlipoproteinemia (type I and V)
- Hypercalcemia (hyperparathyroidism)
- Drugs
- Genetics

⇒ **Mechanic**

- Obstruction (lithiasis), spasms
- Iatrogenic damage (ERCP, perioperative)

⇒ **Vascular, ischemic**

- Shock, thrombosis, embolia
- Vasculitis – polyarteriitis nodosa

⇒ **Infections**

- mumps
- Coxsackieviruses
- Mycoplasma pneumoniae

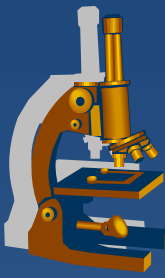
Acute pancreatitis



x clinical features:

- ⇒ *severe abdominal (epigastric) pain, nausea and vomiting – acute abdomen*
- ⇒ *DIC*
- ⇒ *shock, multiorgan failure, ARDS, renal failure*
- ⇒ *elevation of serum amylases, lipases, hypocalcaemia*
- ⇒ *infective complications*
- ⇒ *pseudocysts*

Acute pancreatitis



x Morphology:

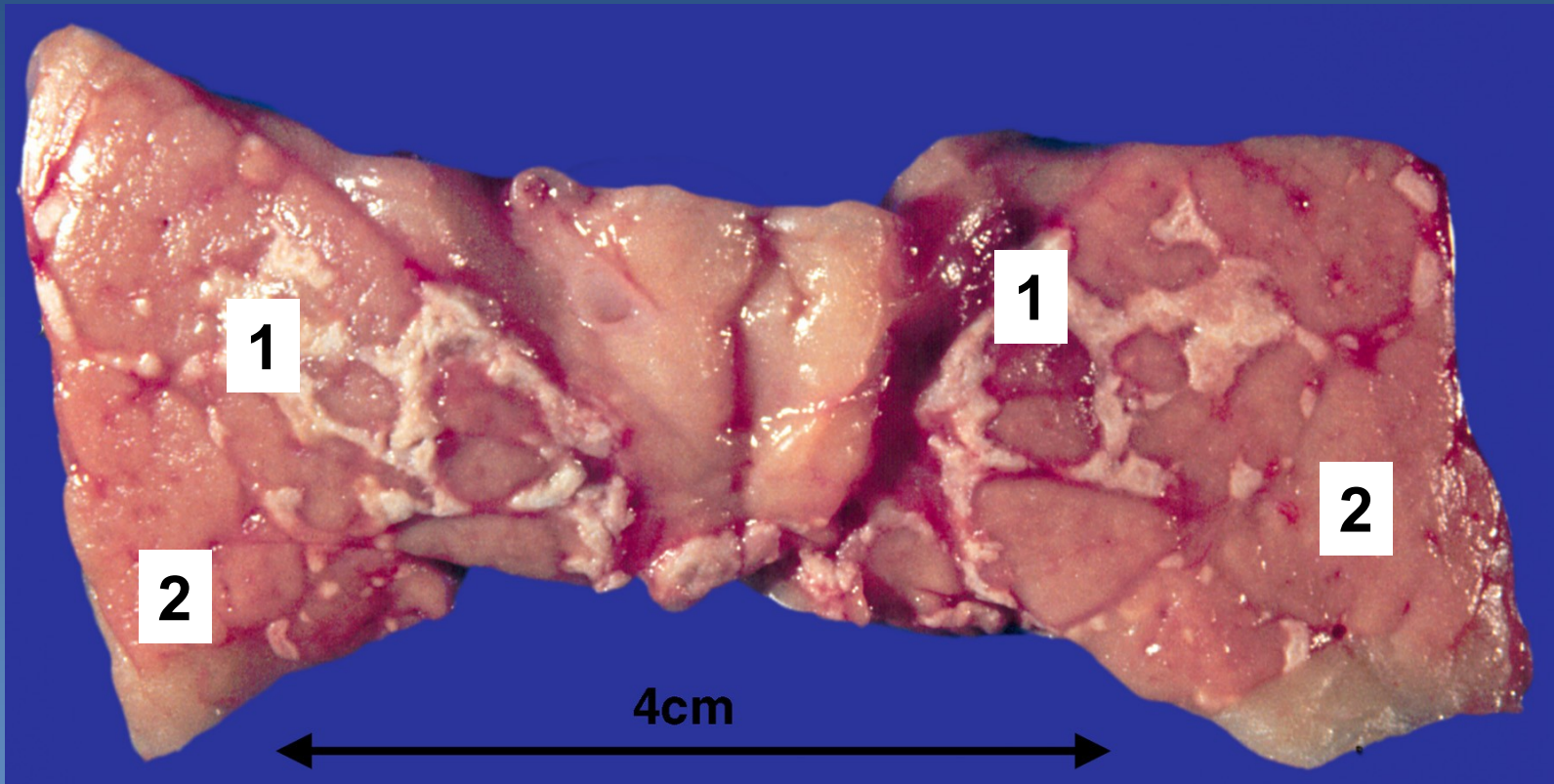
⇒ *serous and haemorrhagic exsudate in the peritoneal cavity*

⇒ *swollen pancreas*

⇒ *necroses, colliquation, haemorrhages*

⇒ *Balzer's fat necroses*

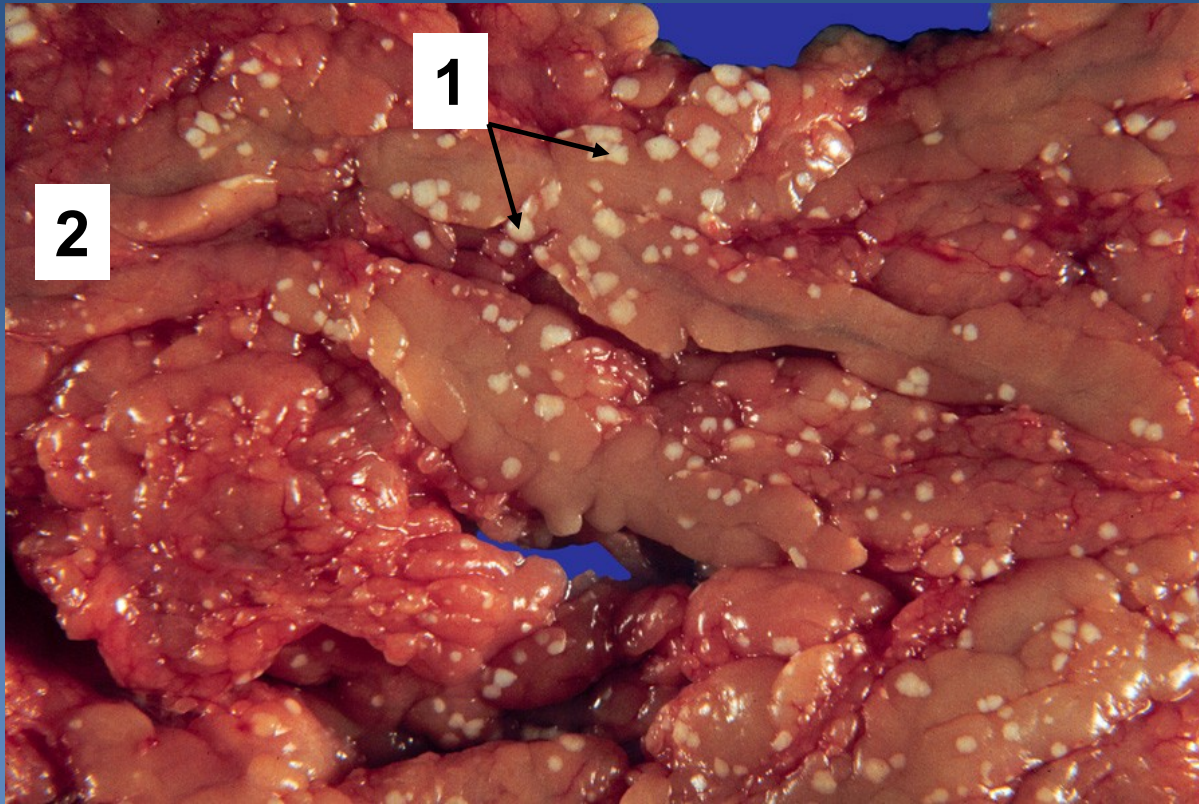
Acute pancreatitis



1. Fatty necroses with haemorrhagic rim

2. Adjacent pancreatic parenchyma

Balzer's fat necroses



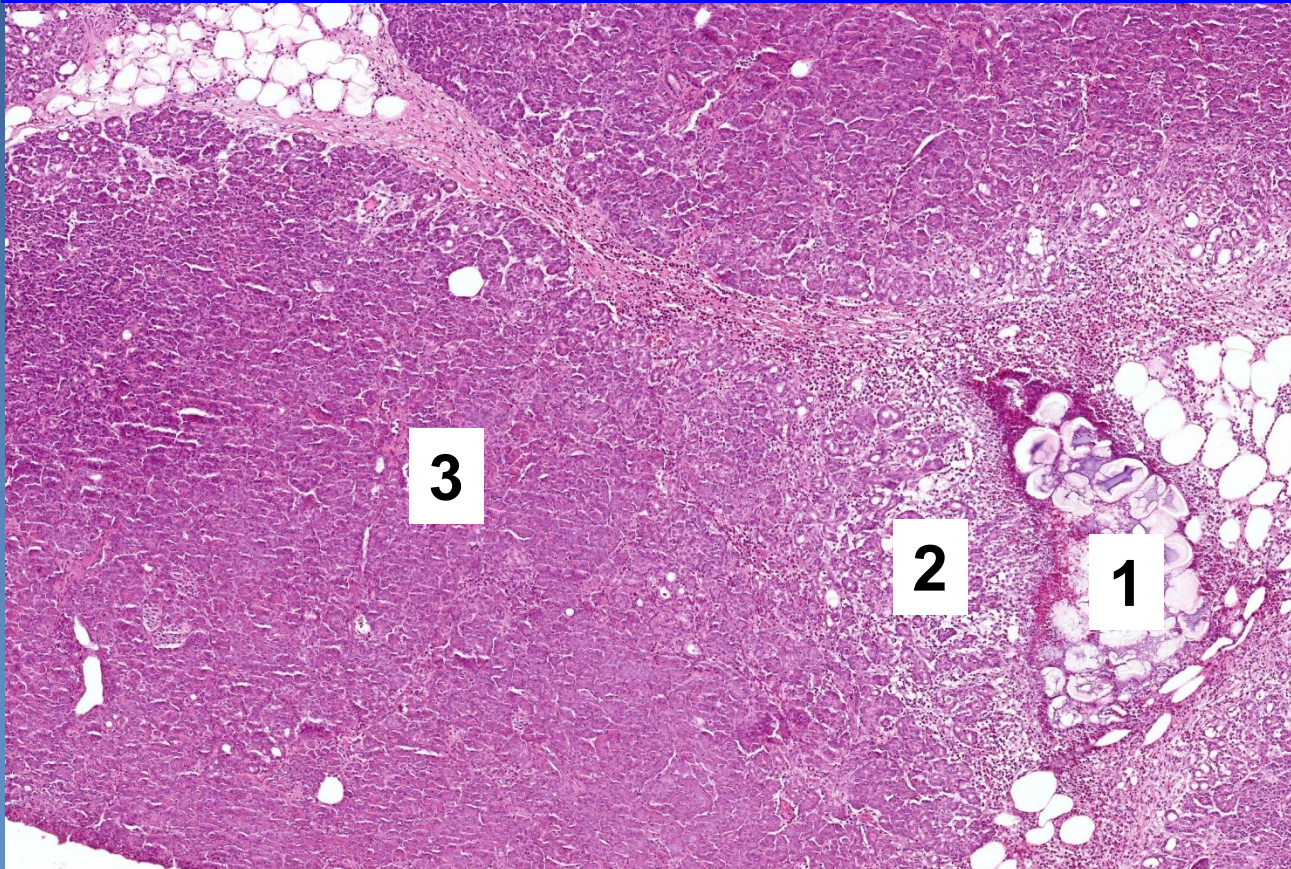
1. Balzer's fat necrosis in the omentum

2. Surrounding fatty tissue

Acute pancreatitis



- 1. Necrosis*
- 2. Demarcation/leucocytes*
- 3. Adjacent pancreatic tissue*

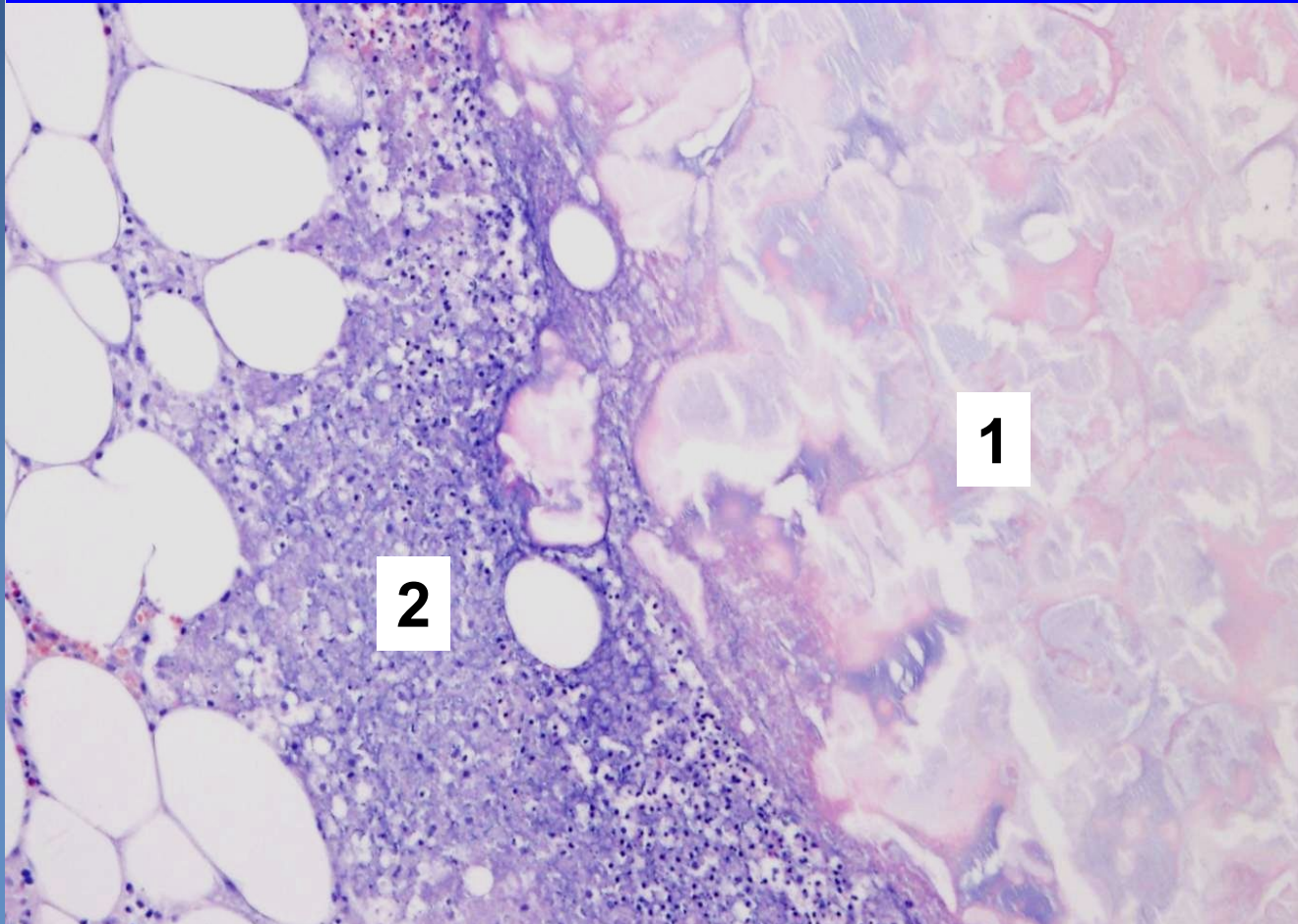


Acute pancreatitis

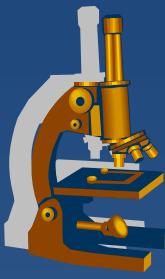


1. Necrosis

2. Demarcation/leucocytes



Chronic pancreatitis



- × TIGAR-O classification (2001):

- ⇒ *Toxic/metabolic (alcohol, uremia, drugs)*

- ⇒ *Idiopathic*

- ⇒ *Genetic (hereditary)*

- ⇒ *Autoimmune*

- ⇒ *Recurrent acute*

- ⇒ *Obstructive*

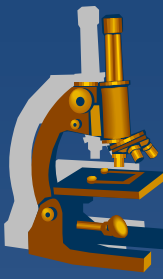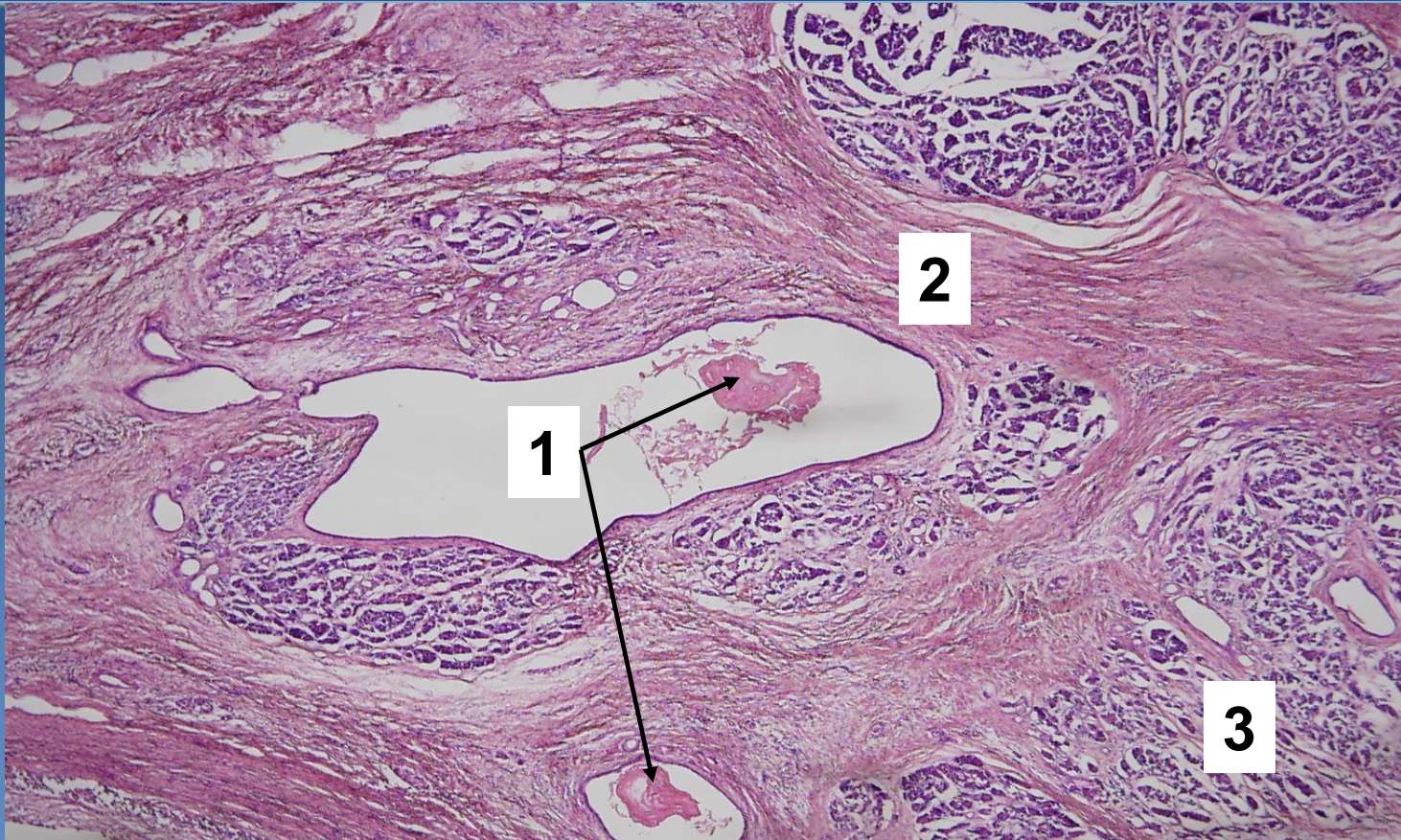
Alcoholic pancreatitis



× histologic features:

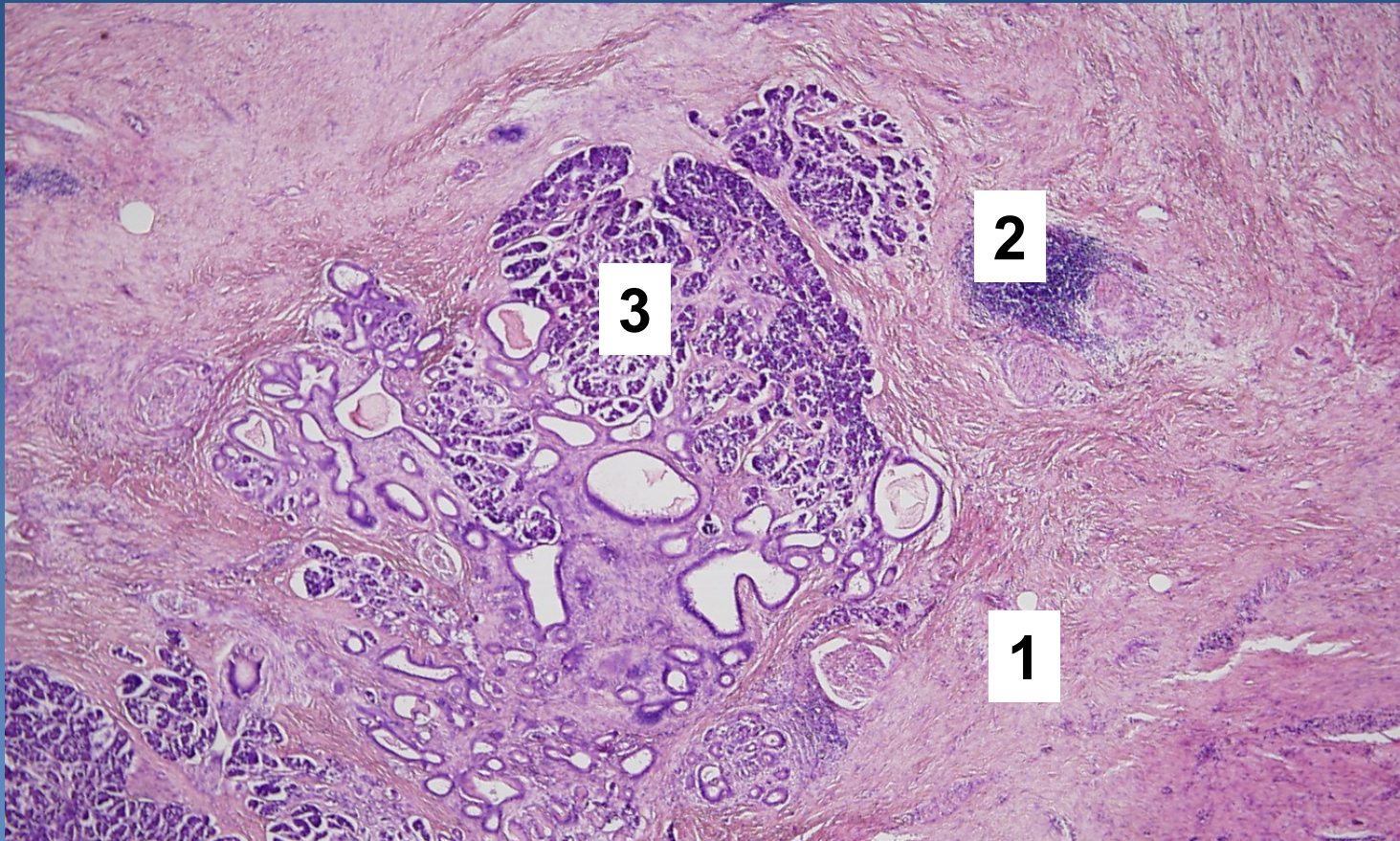
- ⇒ *chronic calcifying pancreatitis*
- ⇒ *fibrotisation of pancreas, mostly perilobular*
- ⇒ *autodigestive necroses and postmaltatic pseudocysts*
- ⇒ *dilated and irregular ducts*
- ⇒ *protein plugs in ducts, calcifications*
- ⇒ *hyperplasia and metaplasia of ductal epithelium*
- ⇒ *increased risk of pancreatic cancer in chronic pancreatitis*

Alcoholic pancreatitis



- 1. Dilated ducts, protein plugs in ducts*
- 2. Perilobular fibrotisation*
- 3. Lobular architecture of pancreas*

Alcoholic pancreatitis



- 1. Perilobular fibrotisation*
- 2. lympho-plasmocellular inflammatory infiltration*
- 3. Lobular architecture of the pancreas*

Autoimmune pancreatitis



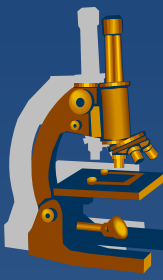
x adults affected

⇒ *rare in 2nd and 3rd decade*

x M>F

x clinical and radiological features mimic pancreatic cancer

x associated with other autoimmune disorders



Obstructive pancreatitis

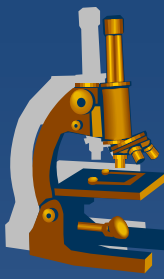
- x** Obstructive pancreatitis – histological features:
 - ⇒ *diffuse perilobular and intralobular fibrosis*
 - ⇒ *dilated ducts without obstruction, irregularities or signs of destruction of ductal epithelium*
 - ⇒ *no protein plugs or calcifications in ducts*
 - ⇒ *hyperplasia of ductal epithelium*
 - ⇒ *necroses and pseudocysts absent*

Tumours of the pancreas



- x epithelial
- x non-epithelial
- x secondary - metastatic

Epithelial tumours



× *classified according to biological behavior:*

⇒ **benign:**

- serous cystadenoma
- acinar cell cystadenoma

⇒ **Premalignant lesion:**

- pancreatic intraepithelial neoplasia grade 3 (PanIN-3)
- mucinous cystic neoplasm with low- or intermediate grade dysplasia
- mucinous cystic neoplasm with high grade dysplasia
- intraductal papillary mucinous neoplasm with low- or intermediate grade dysplasia
- intraductal papillary mucinous neoplasm with high grade dysplasia
- intraductal tubulopapillary neoplasm

⇒ **malignant:**

- **Ductal adenocarcinoma !! (PDAC)**
- mucinous cystic neoplasm associated with invasive carcinoma
- intraductal papillary mucinous neoplasm associated with invasive carcinoma
- acinar cell carcinoma
- acinar cell cystadenocarcinoma
- serous cystadenocarcinoma
- pancreatoblastoma
- solid-pseudopapillary neoplasm
- mixed acinar-ductal carcinoma
- mixed acinar-neuroendocrine carcinoma
- mixed acinar-neuroendocrine-ductal carcinoma
- mixed neuroendocrine-ductal carcinoma

Precursor lesions of invasive pancreatic cancer

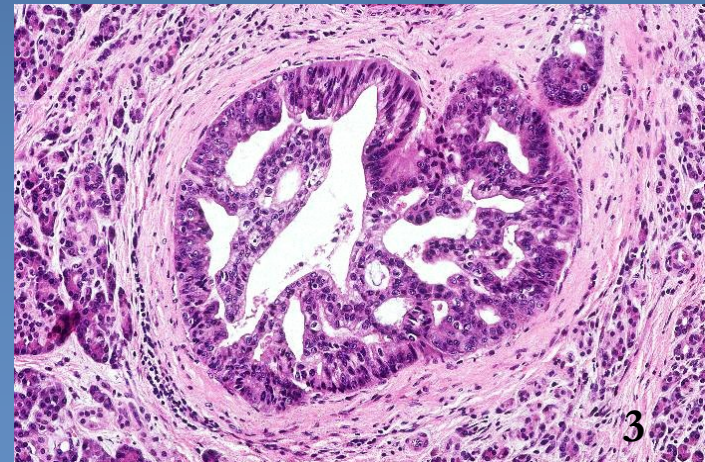
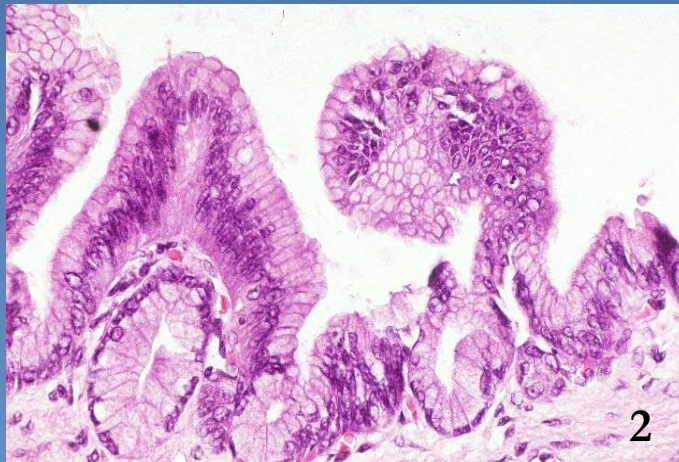
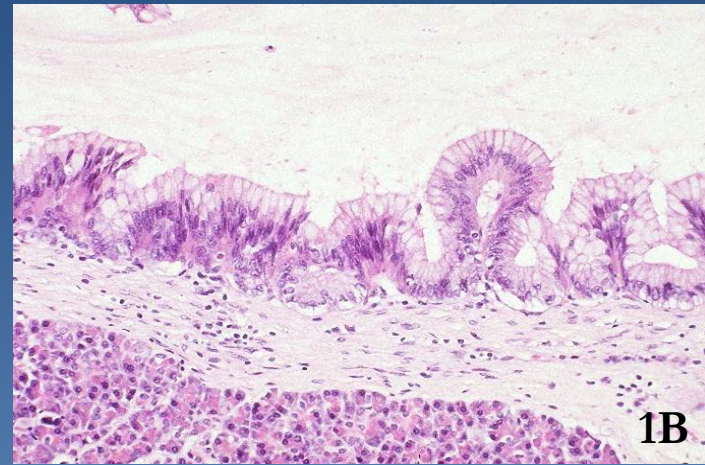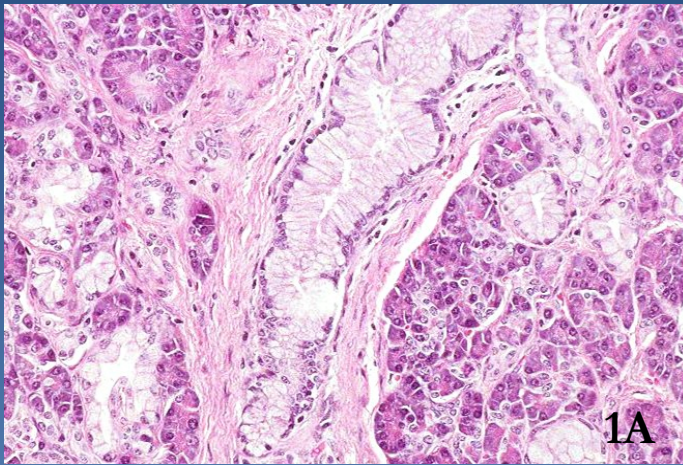


- x Pancreatic intraepithelial neoplasia (PanIN)**
 - ⇒ *microscopic precursor of PDAC*

- x Mucinous cystic neoplasm (MCN)**

- x Intraductal papillary mucinous neoplasm (IPMN)**
 - ⇒ *gross cystic precursor lesions*

Pancreatic intraepithelial neoplasia (PanIN)



Ductal adenocarcinoma



- × *ductal adenocarcinoma* - 85-90% of all pancreatic neoplasias

- × 5th most frequent cancer-related death
 - ⇒ *in GIT 2nd after colorectal cancer*

- × risk factors:
 - ⇒ *higher age*
 - ⇒ *genetic factors*
 - ⇒ *environmental factors:*
 - **smoking, high fat diet, obesity and low physical activity, chemicals**
 - ⇒ *chronic pancreatitis (both hereditary and sporadic); (CP)*
 - ⇒ *diabetes mellitus*
 - ⇒ *alcohol (indirectly, induces CP)*

Ductal adenocarcinoma



x Clinical features:

⇒ ***60-70 % in the pancreatic head***

⇒ ***abdominal and back pain***

⇒ ***weight loss***

⇒ ***icterus, pruritus, diabetes mellitus***

⇒ ***migratory thrombophlebitis***

⇒ ***symptoms related to liver metastasis and/or invasion of adjacent organs***

Ductal adenocarcinoma



- × biological behavior

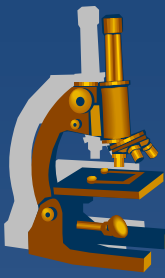
- ⇒ *lymphogenous metastasis (regional lymph nodes)*

- ⇒ *haematogenous metastasis (liver, lungs, bones)*

- ⇒ *carcinomatosis of peritoneum*

- ⇒ *perineural spreading*

Ductal adenocarcinoma



x Gross:

- ⇒ *usually solid mass in the pancreatic head*
- ⇒ *mean diameter 2-3 cm*
- ⇒ *common bile duct and/or main pancreatic duct stenosis*
- ⇒ *necrosis rare*
- ⇒ *absence of calcifications and pseudocysts*

Ductal adenocarcinoma

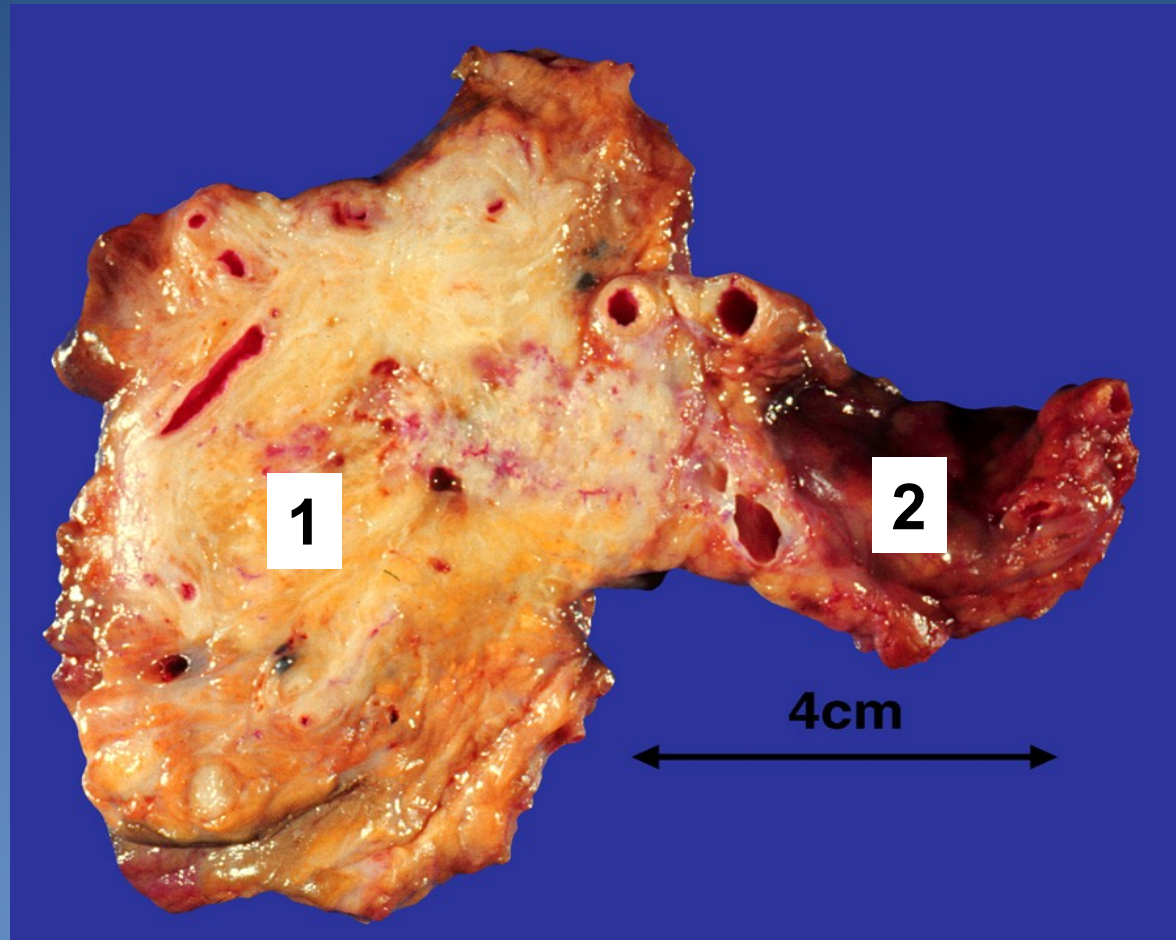
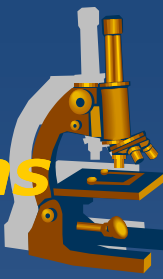


× Micro:

⇒ *grade of differentiation:*

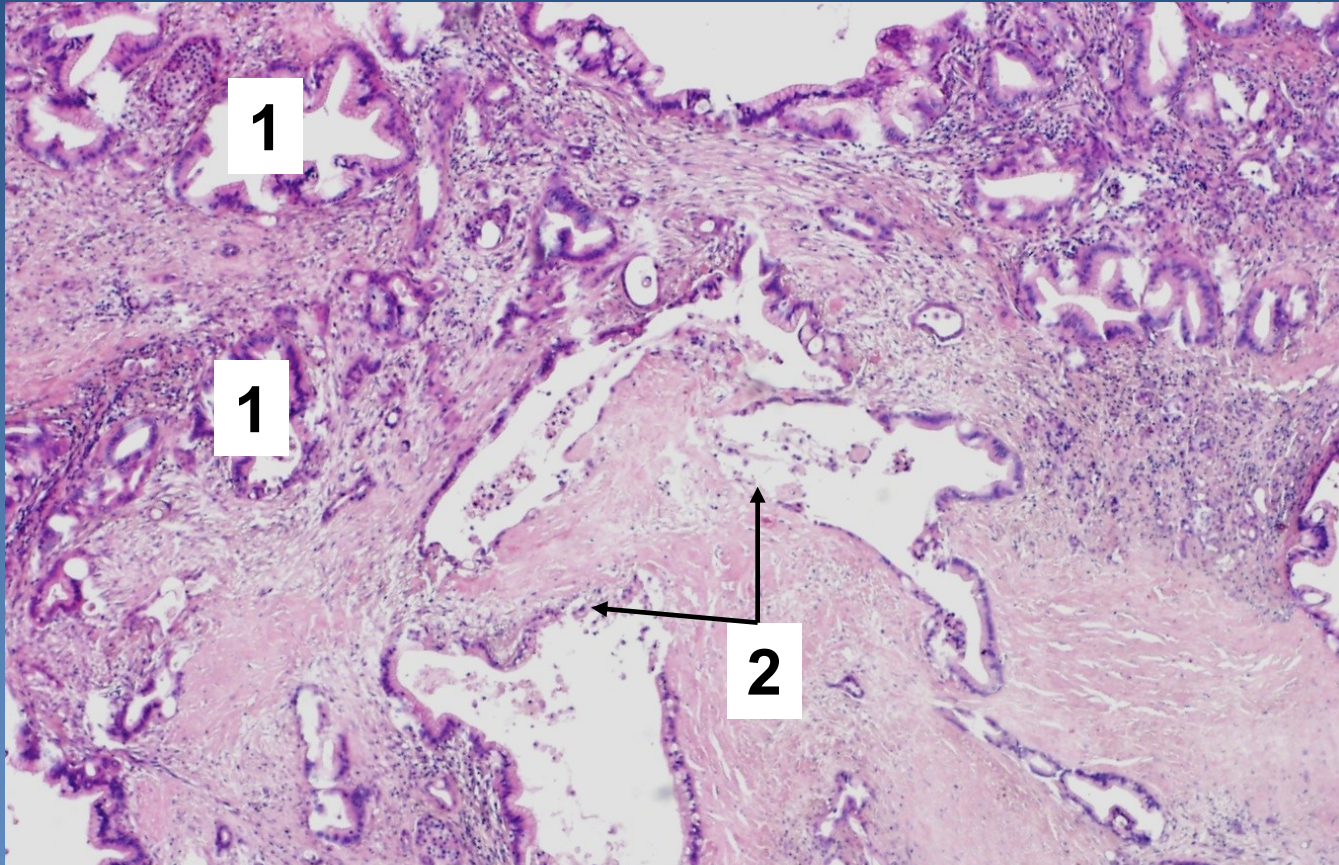
- **grade 1: well differentiated**
 - ductal and tubular formation in desmoplastic stroma, columnar mucin producing cell, distinct small nucleoli, low mitotic activity, low degree of pleomorphism/atypia
- **grade 2: moderately differentiated**
 - ductal, tubular, microglandular, cribriform formation, desmoplasia, irregular mucin production, prominent nucleoli, higher pleomorphism
- **grade 3: poorly differentiated**
 - irregular glandular structure, solid aggregates, squamoid foci, spindle cells, anaplastic, pleomorphic structures, mitotic activity

Ductal adenocarcinoma in the head of pancreas



- 1. Carcinoma of pancreatic head*
- 2. Pancreatic body and tail*

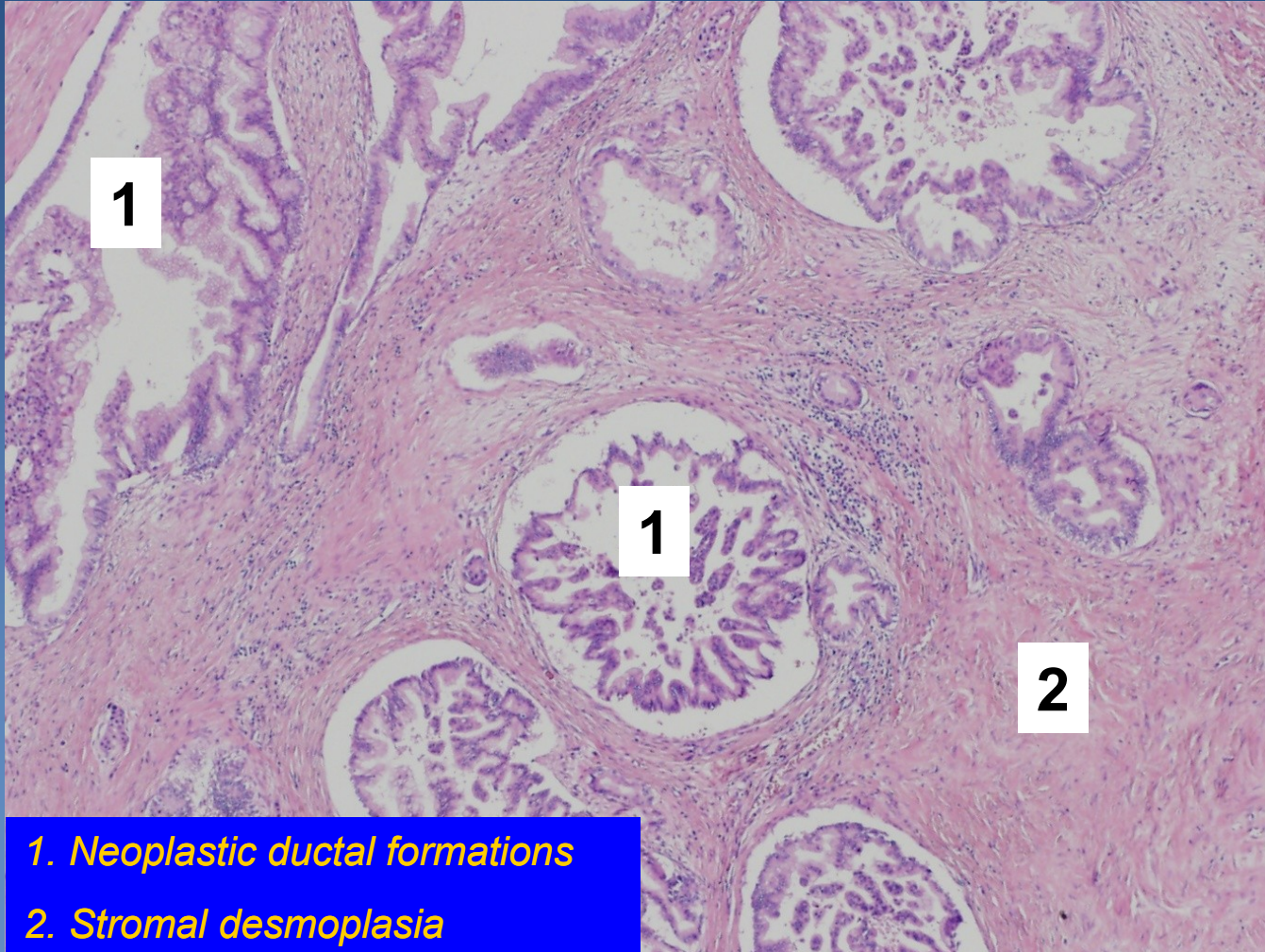
Ductal adenocarcinoma



1. Neoplastic ductal formations

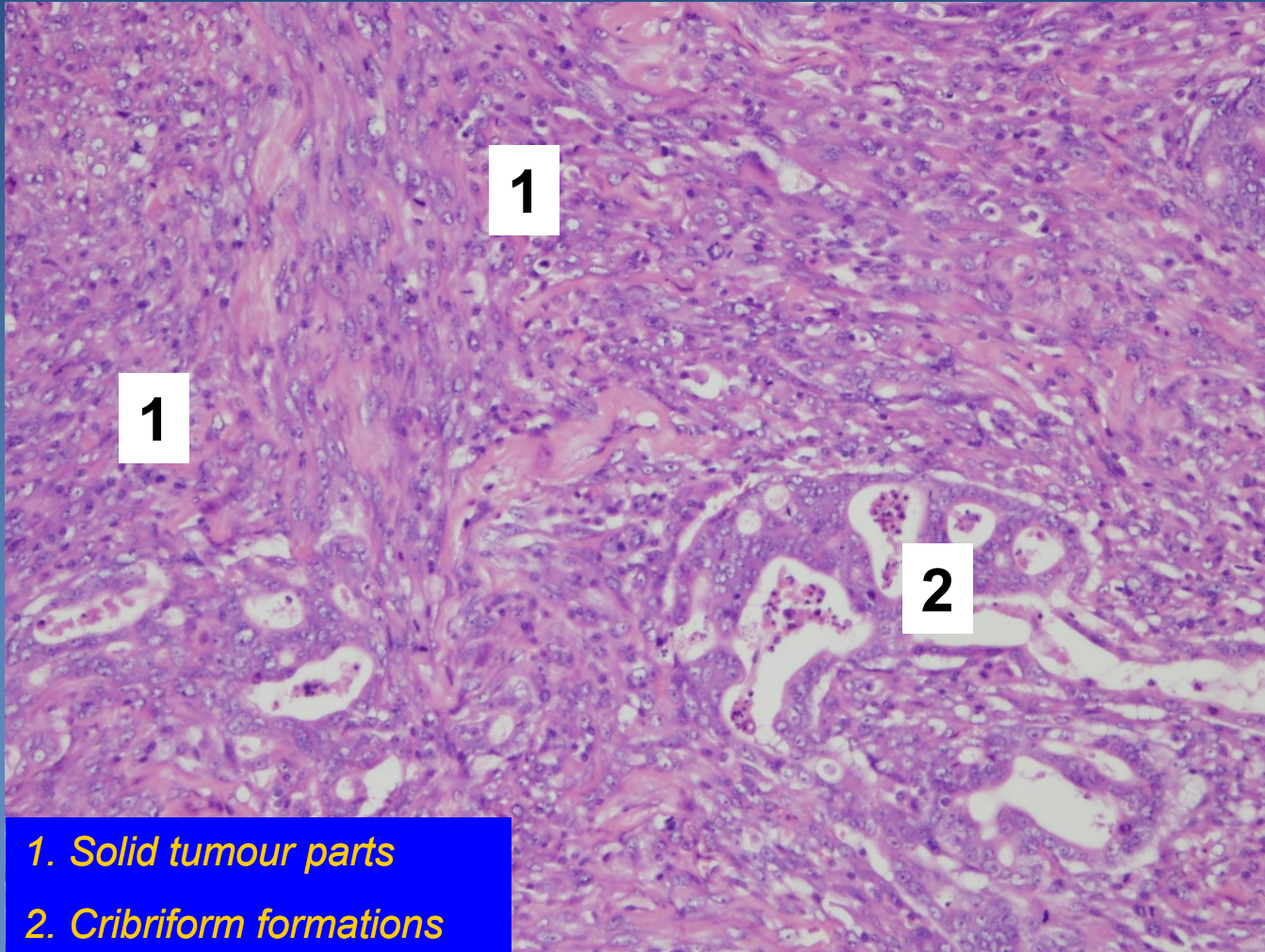
2. Focal duct ruptures with macrophages and detritus intraluminally

Ductal adenocarcinoma – well differentiated (G1)



- 1. Neoplastic ductal formations*
- 2. Stromal desmoplasia*

Ductal adenocarcinoma – poorly differentiated (G3)



- 1. Solid tumour parts*
- 2. Cribriform formations*

Differential diagnosis of ductal adenocarcinoma and chronic pancreatitis – clinical features



x Adenocarcinoma:

⇒ *older patients*

- rare under 40

⇒ *no pancreatitis and alcoholism in medical history*

⇒ *sudden painless icterus*

x Chronic pancreatitis:

⇒ *often in younger patients*

⇒ *medical history:*

- long term
 - recurrent acute pancreatitis
- alcohol abuse

⇒ *icterus after long term duration of disease*

Differential diagnosis of ductal adenocarcinoma and chronic pancreatitis – gross features



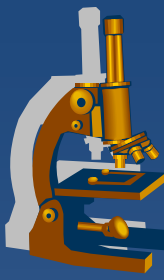
x Adenocarcinoma:

- ⇒ *solid mass in the pancreatic head, mean diameter 2-3 cm*
- ⇒ *common bile duct stenosis*
- ⇒ *usually without necrosis, calcifications, pseudocysts*

x Chronic pancreatitis:

- ⇒ *more diffuse*
- ⇒ *Alternation of lobular parenchyma and areas of fibrosis*
- ⇒ *protein plugs and calcifications in ducts*
- ⇒ *extrapancreatic pseudocysts*

Differential diagnosis of ductal adenocarcinoma and chronic pancreatitis – microscopic features

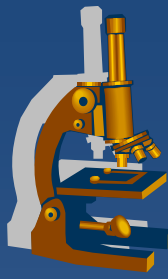


× Adenocarcinoma:

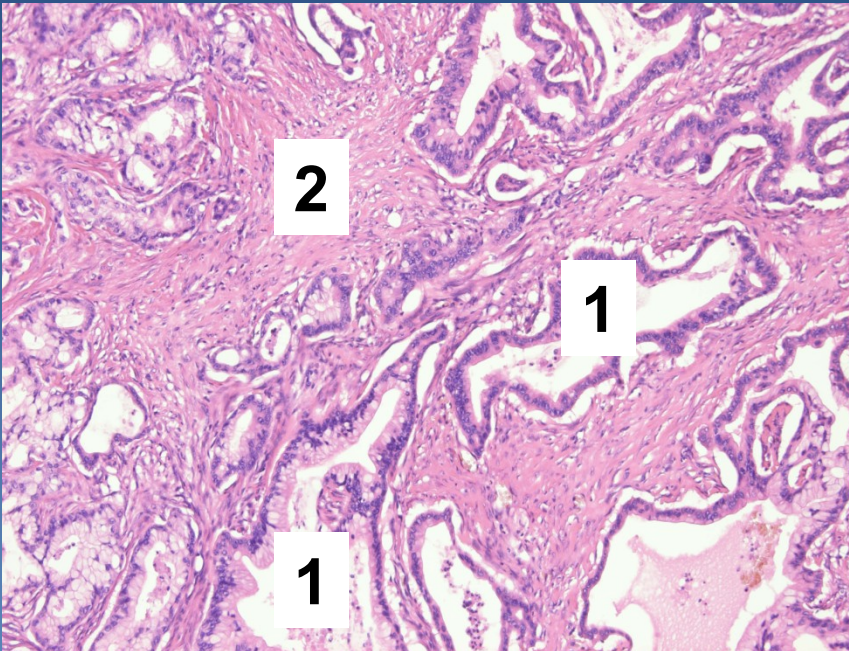
- ⇒ haphazard distribution of irregular ductal structures
- ⇒ ducts perineurally, in extrapancreatic fatty tissue
- ⇒ hypercellular condensation of stroma around neoplastic ducts, stromal desmoplasia
- ⇒ enlarged nuclei, pleomorphism, hyperchromasia, mitoses, prominent nucleoli, loss of nuclear polarity
- ⇒ dense acidophilic cytoplasm, apical condensation of cytoplasm

× Chronic pancreatitis

- ⇒ (organoid) lobular arrangement
- ⇒ ducts intrapancreatically
- ⇒ smooth contours of the ducts, round/oval lumens
- ⇒ dense hyalinized stroma
- ⇒ uniform nuclei, inconspicuous nucleoli, no mitoses
- ⇒ cytoplasm normochromophilic, absence of apical condensation



Differential diagnosis of ductal adenocarcinoma and chronic pancreatitis – microscopic features

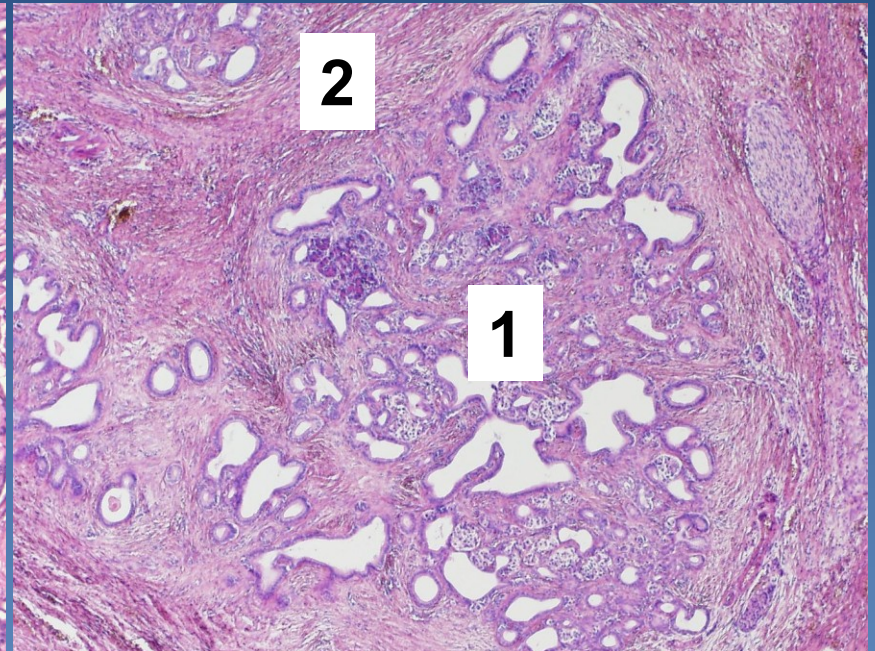


2

1

1

- 1. Haphazard distribution of irregular ducts**
- 2. Stromal desmoplasia**



2

1

- 1. Lobular arrangement**
- 2. Dense hyalinized stroma**

Neuroendocrine neoplasms of the pancreas



- ✘ synonyms: pancreatic NETs, islet cell tumor, APUDoma
- ✘ 1 – 2 % of all pancreatic tumors
- ✘ 3rd-6th decade
- ✘ classification:
 - ⇒ *neuroendocrine tumour (NET)*
 - nonfunctional NET (NET G1, G2)
 - NET G1
 - NET G2

 - ⇒ *neuroendocrine carcinoma (NEC)*
 - large cell NEC
 - small cell NEC

Neuroendocrine neoplasms of pancreas



- × Functional (hormonally active)
 - ⇒ *insulinoma*
 - ⇒ *glucagonoma*
 - ⇒ *somatostatinoma*
 - ⇒ *gastrinoma*
 - ⇒ *VIPoma*
 - ⇒ *serotonin producing NET*
 - ⇒ *others – with ectopic hormone production (ACTH, calcitonin,...)*

- × Nonfunctional (with no association with hormonal syndrome)

- × Pancreatic neuroendocrine microadenomas
 - ⇒ *<0,5 cm*
 - ⇒ *usually clinically silent*

Neuroendocrine neoplasms of pancreas



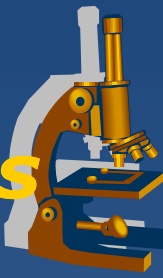xGross:

⇒ *partially or totally circumscribed/encapsulated; usually solitary*

⇒ *white, yellow or pink-brown*

⇒ *haemorrhages, necrosis can occur; cystic tumors rare*

Neuroendocrine neoplasms of pancreas



x Micro:

⇒ *nesting, trabecular, glandular, acinar, tubuloacinar, pseudorosette, ...arrangements of their cells*

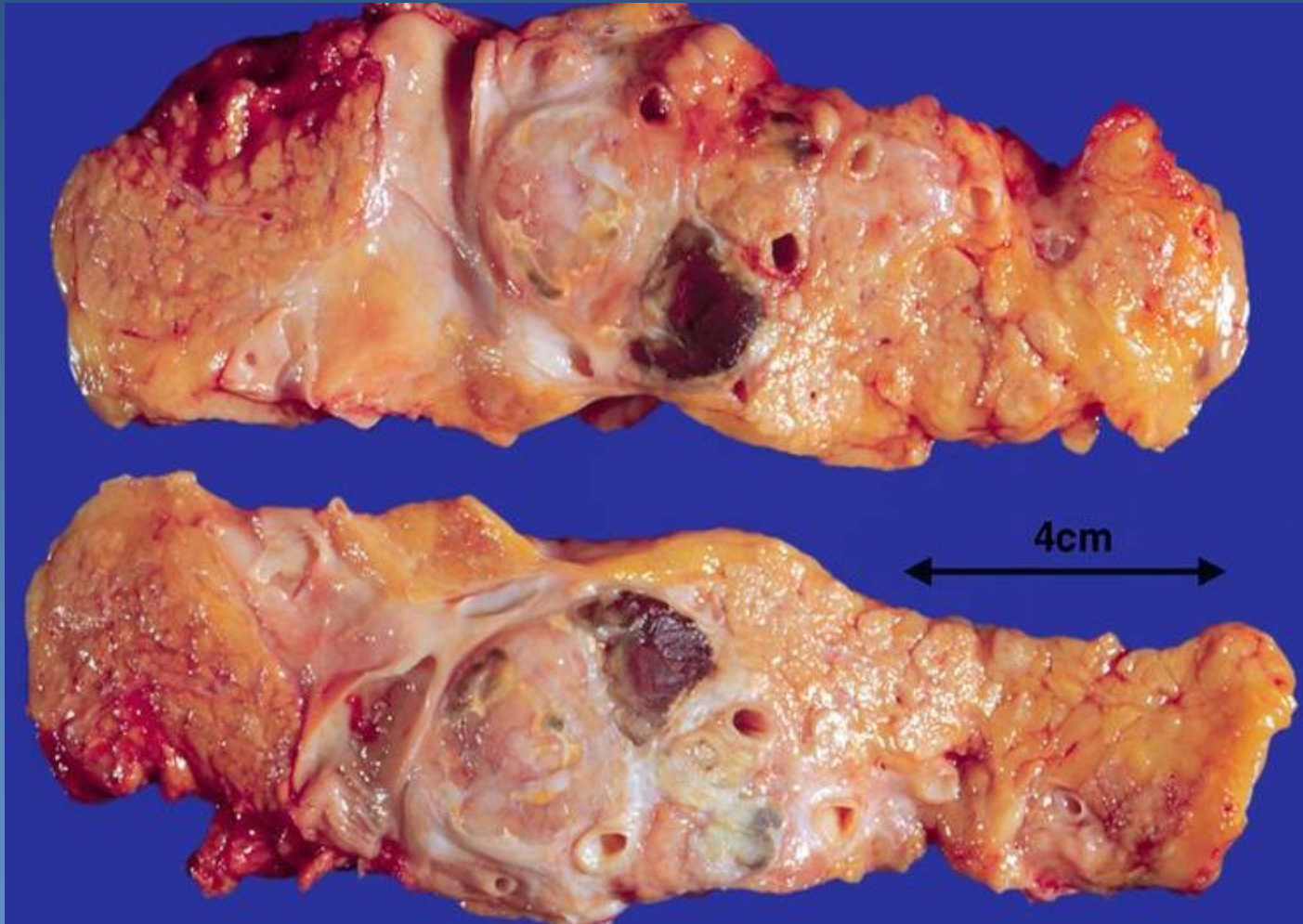
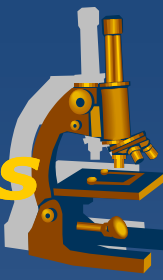⇒ *cells uniform, round, finely granular amphophilic to eosinophilic cytoplasm, coarsely clump chromatin („salt and pepper“)*

⇒ *Variable amount of stroma*

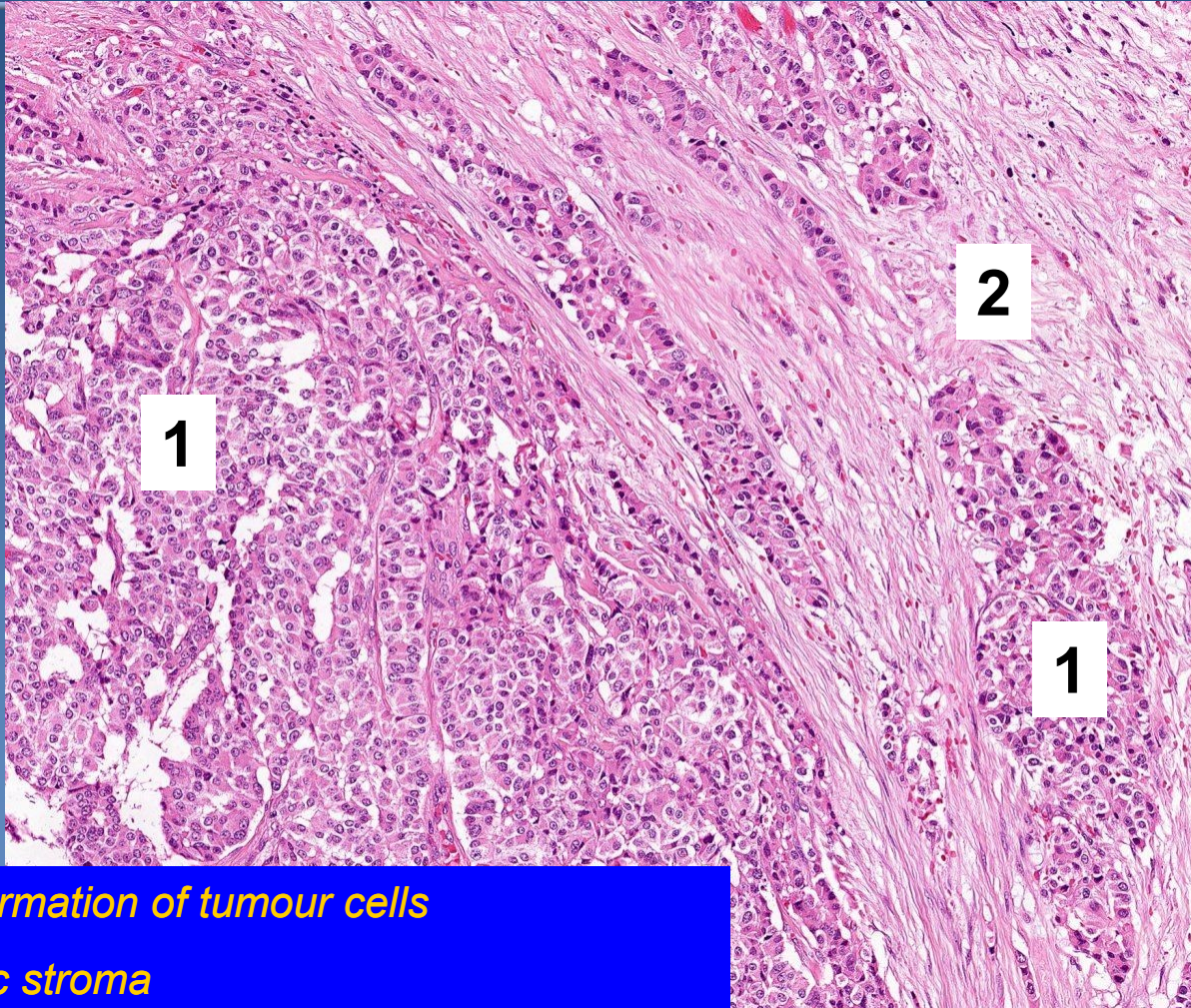
⇒ **IHC:**

- CEA, synaptophysin, chromogranin, NSE, CD56
- peptide hormones:
 - insulin, glucagon, serotonin, somatostatin, gastrin

Neuroendocrine neoplasms of pancreas



Neuroendocrine neoplasms of pancreas



- 1. Trabecular formation of tumour cells*
- 2. Dense fibrotic stroma*

Diabetes mellitus



- ✗ Group of complex metabolic lesions
- ✗ Multifactorial etiology
- ✗ Common sign:
 - ⇒ *glucose metabolism dysregulation* → *glucose intolerance* - **hyperglycaemia**
- ✗ Causes:
 - ⇒ *insulin secretion disorders*
 - ⇒ *disorders of insulin action / response to insulin*
 - ⇒ *combination of both*

Diabetes mellitus



x Other metabolic disorders:

⇒ *lipolysis*

- hyperlipidaemia (loss of weight), ketoacidosis

⇒ *hyperglycaemia*

- osmotic diuresis (polyuria, dehydration, thirst)

⇒ *diminished protein synthesis*

Diabetes mellitus - classification



x Primary DM:

⇒ *DM type 1*

- insulin-dependent
- destruction of β -cells, autoimmune, idiopathic

⇒ *DM type 2*

- non-insulin dependent

⇒ *Genetic defects of β -cells function*

- MODY – maturity-onset diabetes of the young, etc.

x Now possible 5 DM types

Diabetes mellitus - classification



× Secondary DM:

⇒ *Exocrine pancreas defects*

- (chron. pancreatitis, cystic fibrosis, hemochromatosis, tumor)

⇒ *Endocrinopathies*

- (Cushing sy, hyperthyreosis, acromegaly, etc.)

⇒ *Infections*

- (CMV, coxsackie B, congenital rubella)

⇒ *Drugs*

- (glucocorticoids, proteases inhibitors, ...)

× Gestational DM

Diabetes mellitus



- ✘ Atypical glucose bond on proteins
 - ⇒ *glycation* → *change of normal characteristics/functions, i.e. in vessels BM; monitoring - glycosylated hemoglobin HbA1c*

- ✘ Polyol pathways
 - ⇒ *atypical metabolism* of glucose by reductases to *sorbitol + fructose i.e. in kidneys, nerves, eye lens* → *oedema and cell damage*

- ✘ Free radicals formation
 - ⇒ *oxidative stress*

Diabetes mellitus - complications



Long-term consequences similar in all types:

- ⇒ *microangiopathy (neuropathy, retinopathy)*
- ⇒ *diabetic glomerulosclerosis*
- ⇒ *accelerated atherosclerosis*
- ⇒ *immune defect, mostly nonspecific (bacterias, fungi)*
- ⇒ *diabetic ketoacidosis, hyperosmolar coma*
- ⇒ *hypoglycaemia/coma due to insulin overdose*

Diabetes mellitus – morphology



Pancreas

x DM type 1

⇒ *more specific changes*

⇒ *insulinitis with lymphocytic infiltration of islets + ↓ of their size and number*

x DM type 2

⇒ *possible amyloid deposition or islet fibrotisation*

Diabetes mellitus – morphology



Large vessels

- ✗ AS, changes non-specific
- ✗ AS complications (MI, gangrene) sooner and more often
- ✗ accelerated hyaline arteriolosclerosis and hypertension → intracerebral haemorrhage, nephrosclerosis

Diabetes mellitus – morphology



Small vessels

- ✘ Microangiopathy

 - ⇒ *diffuse thickening of BM, but BM more leaky for proteins*

- ✘ Nephropathy

- ✘ Retinopathy

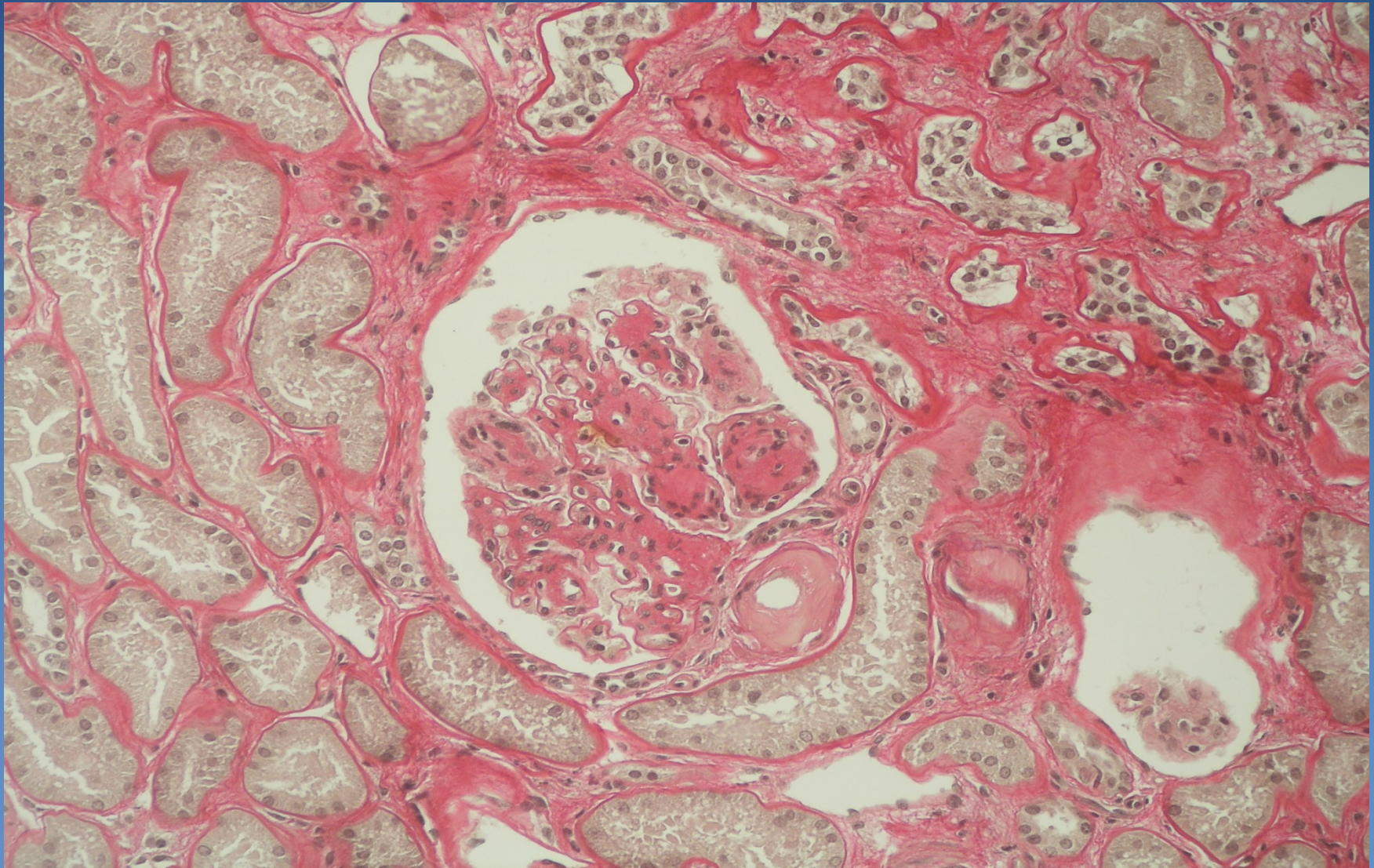
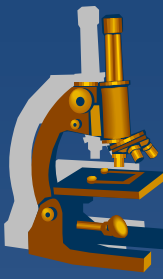
- ✘ Neuropathy

Diabetic nephropathy

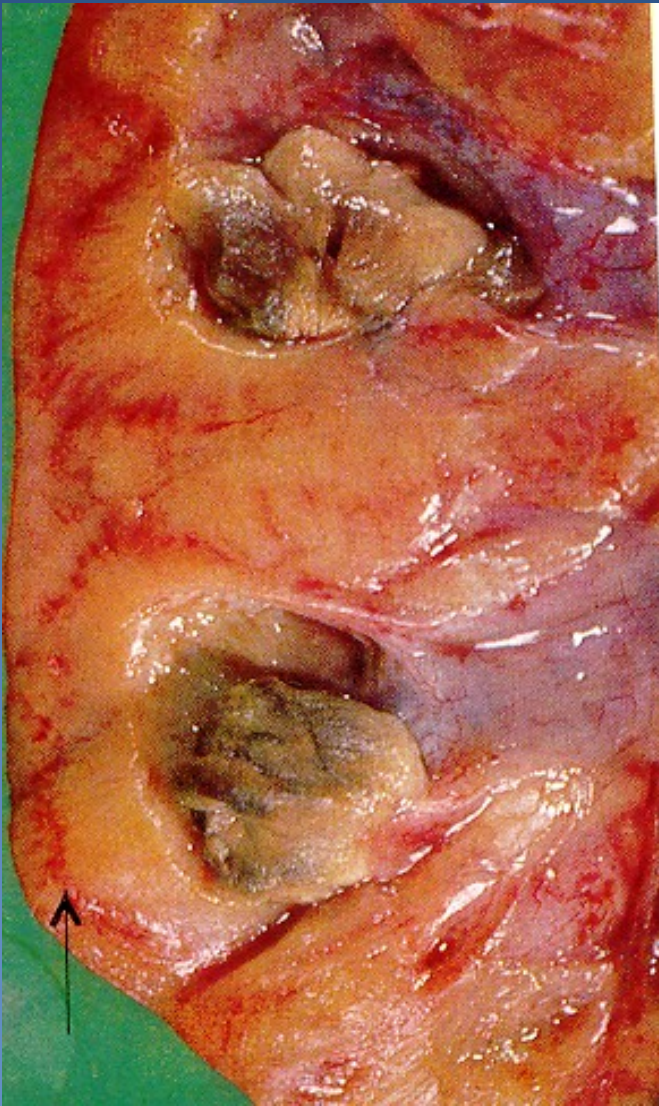


- ✘ Diabetic glomerulosclerosis
 - ⇒ *diffuse x nodular*
- ✘ Renal vascular lesions
 - ⇒ *arteriolosclerosis*
- ✘ Pyelonephritis incl. papillary necrosis
- ✘ Common progression to renal insufficiency

Glomerulosclerosis + arteriolosclerosis



Papillary necrosis



- ✘ Acute necrotizing papillitis in the setting of focal ischaemia

Diabetes mellitus – morphology



- x** Ocular lesions:
 - ⇒ *retinopathy (neovascularization)*
 - ⇒ *cataract formation (opaque lens)*
 - ⇒ *glaucoma (intra-ocular hypertension)*

Diabetes mellitus – morphology



x Neuropathy

segmental demyelination

⇒ ***distal polyneuropathy***

- mostly motoric + sensitive in lower extremities – incl. ↓ pain perception (→ ulceration)

⇒ ***autonomic neuropathy***

- functional disorders of intestines, bladder, sexual

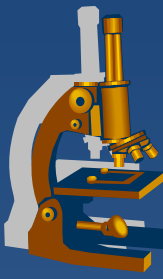
Diabetes mellitus – morphology



x Skin

- ⇒ *increased susceptibility to infections incl. protracted mycotic i., gangrene*
- ⇒ *granuloma annulare (foci of collagen degeneration + inflammatory infiltrate)*
- ⇒ *necrobiosis lipoidica*

Diabetes mellitus – morphology



x Pregnancy

⇒ *pre-eclampsia*

⇒ *large babies (already in utero)*

⇒ *neonatal hypoglycaemia*

Metabolic syndrome

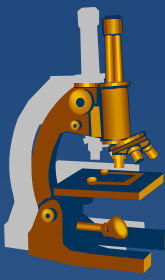


- x abdominal obesity („male type“)
- x insulin resistance
- x hyperlipidemia + abnormal lipid spectrum

Consequences

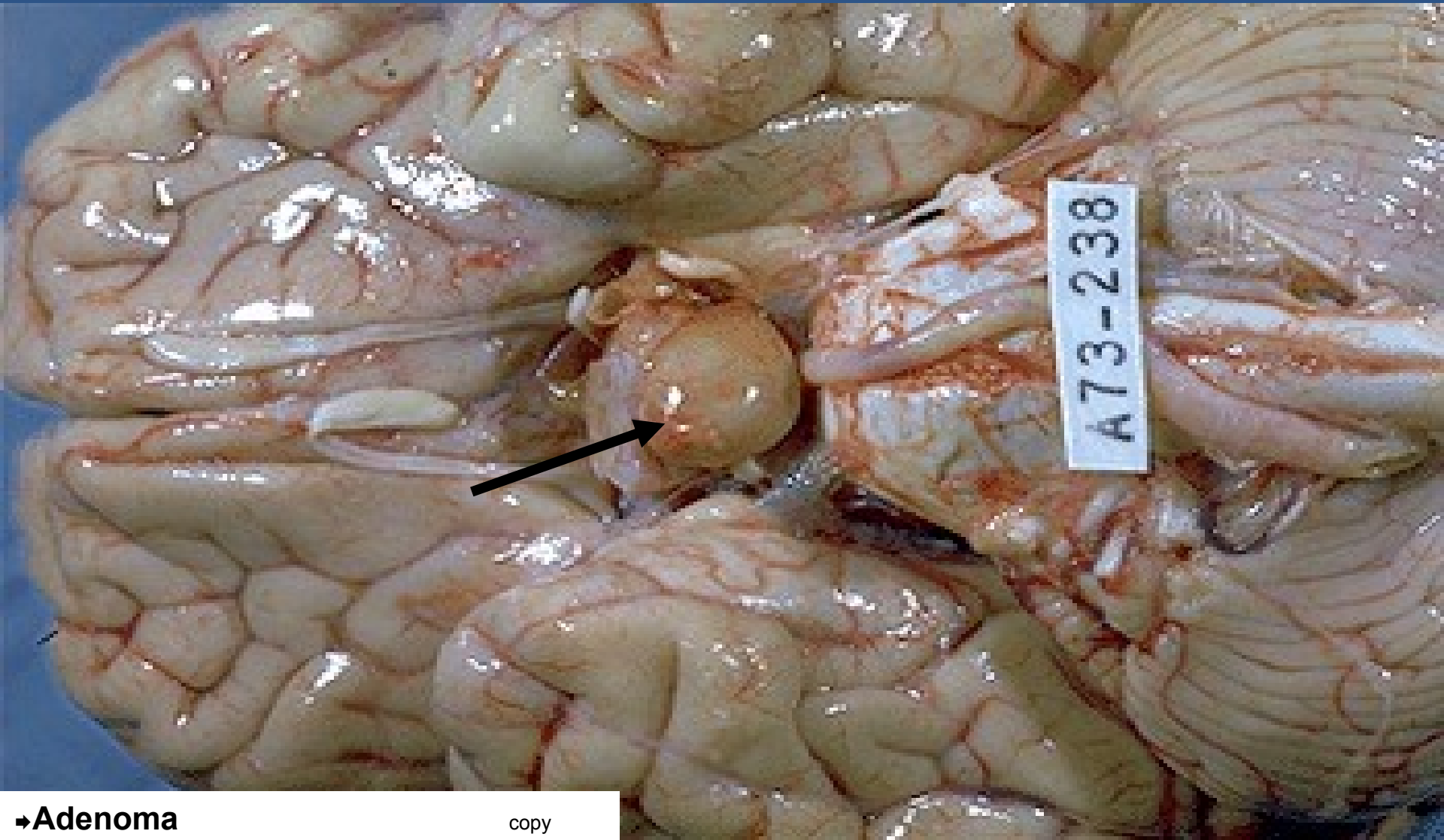
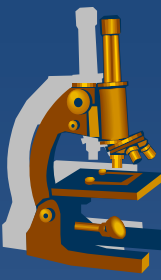
- x cardiovascular lesions
- x non-alcoholic steatohepatitis

Pathology of other endocrine organs (selected)



- x Hyperfunction
- x Hypofunction
- x Neoplasia (+ event. functional changes)

Pituitary adenoma



→ Adenoma copy

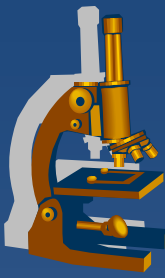
Thyroid gland



HYPERTHYROIDISM - thyrotoxicosis

- ✗ overproduction, ↑ release into the blood, extrathyroidal secretion
- ✗ hyperplasia
 - ⇒ *Graves-Basedow disease, nodular goitre*
- ✗ hyperfunctional tumor
 - ⇒ *adenoma, ca*
- ✗ incipient autoimmune thyroiditis
- ✗ endocrine axis dysregulation

Thyroid gland



Thyrotoxicosis

hypermetabolic state + overactivity of sympathetic nervous system

- ✗ Exophthalmos
- ✗ Weight loss, diarrhoea, tremor, anxiety, insomnia
- ✗ Tachycardia, palpitations, arrhythmia - atrial fibrillation → thyrotoxic cardiomyopathy, hypertension
- ✗ Sweating, heat intolerance
- ✗ Osteoporosis
- ✗ Possible thyroid storm, heart failure

Thyroid gland



HYPOTHYROIDISM

✗ congenital (cretinism),

- ⇒ *geographic iodine deficiency (endemic cretinism), individual factors (hypoplasia, ectopy, genetic /metabolic defects)*
- ⇒ *thyroid hormones necessary to fetal brain development
→ severe neurologic defects incl. mental retardation*
- ⇒ *coarse facial features + hypomimia, protruding tongue, disorders of dentition + growth, sexual retardation*


Thyroid gland



MYXEDEMA

- ✗ hypothyroidism developing in older child/adult
- ✗ **M:F 1:10**
- ✗ slowing of physical/mental activity
- ✗ accumulation of mucoid matrix substances in dermis, myocardium, vessels, ...), hypercholesterolemia, AS acceleration
- ✗ cool skin, cold intolerance, constipation + overweight, fatigue, dyspnoea, decreased exercise capacity
- ✗ secondary oligo- amenorrhoea
- ✗ cardiovascular insufficiency

Thyroid gland - scintigraphy



radioactive iodine uptake

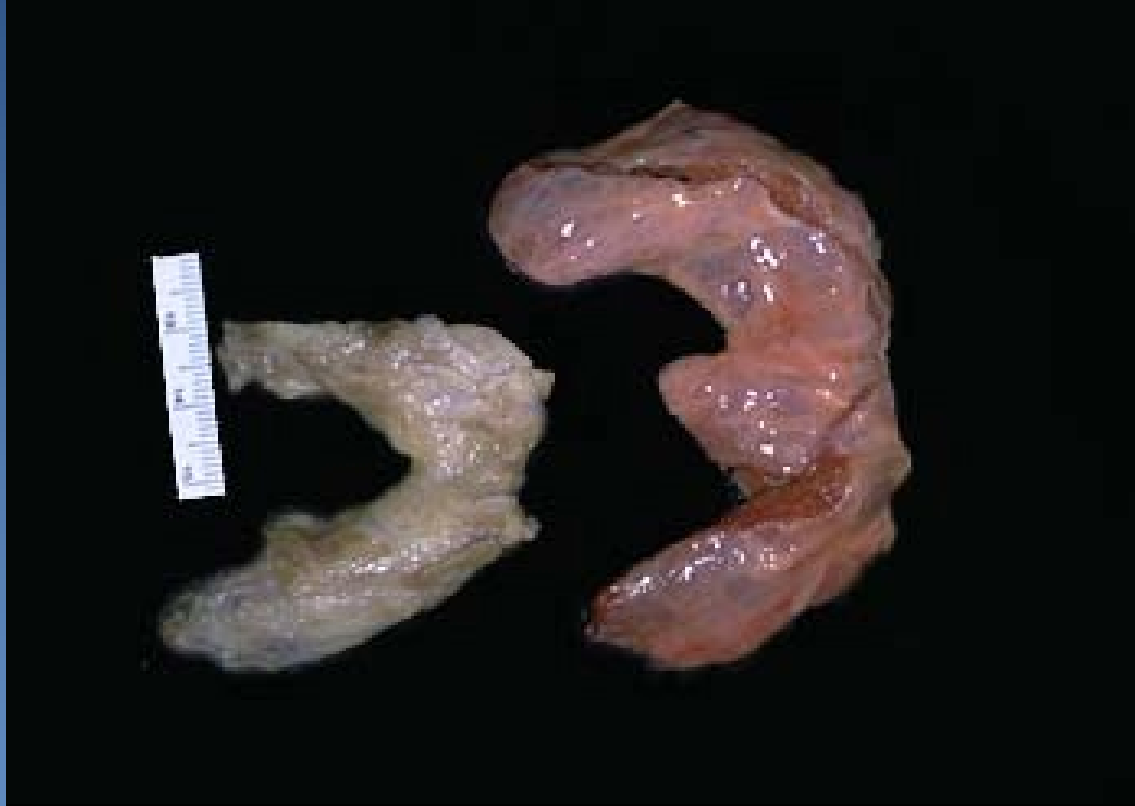1. norm
2. diffuse hyperplasia
3. „hot“ nodule – usually adenoma
4. „cold“ nodule - ca

Thyroiditis



- × Acute inflammations uncommon
 - purulent bacterial (abscess), tbc*
- × Subacute granulomatous – giant cell thyroiditis (de Quervain's) ?viral
 - ⇒ *painful enlargement, micro mixed inflammatory infiltrate + giant cell reaction*
- × Chronic sclerosing t. (Riedel's)
 - ⇒ *dense fibrotisatin, diff. dg. x ca*

Chronic thyroiditis



Hashimoto's thyroiditis



- ✗ organ-specific autoimmune inflammation
- ✗ variable auto-antibodies
 - ⇒ *x peroxidase, thyroglobulin, etc.*
- ✗ early stage - enlargement + hyperfunction
- ✗ later hypofunction
- ✗ ↑ risk of other autoimmune diseases (DM, SLE,..)
- ✗ ↑ risk of malignancies
 - ⇒ *MALT lymphomas, papillary thyroid carcinoma*

Hashimoto's thyroiditis



× Gross:

⇒ *non-homogenous, firm, small paler foci*

× Micro:

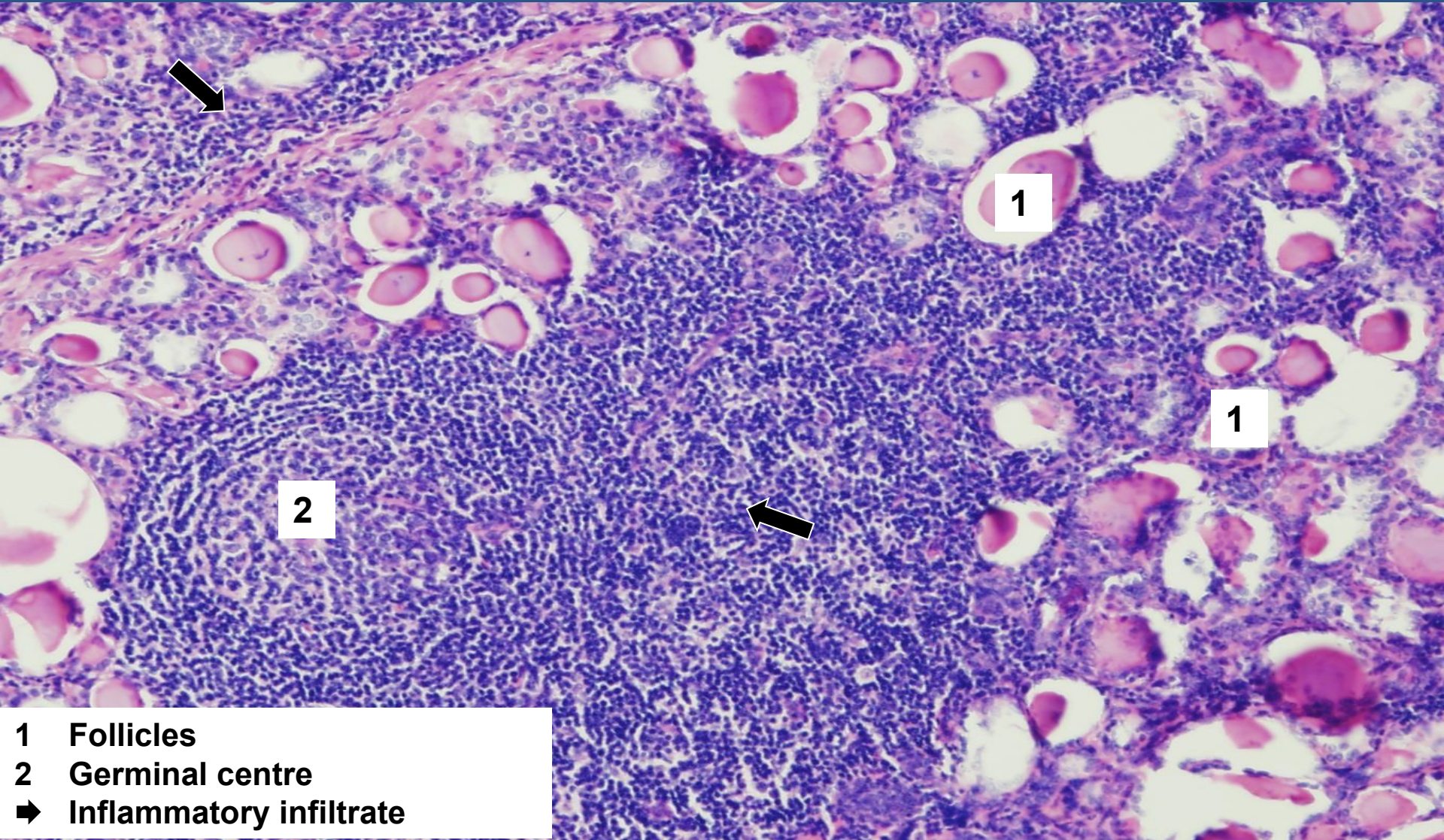
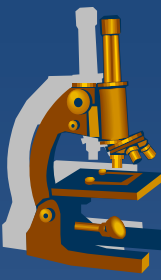
⇒ *dense lymphoplasmocellular infiltrate, incl. germinal centres*

⇒ *thyroid follicles atrophy, onkocytic transformation of follicular epithelium (Hürtle cells)*

- eosinophilic cytoplasm, enlarged nucleus, distinctive nucleolus

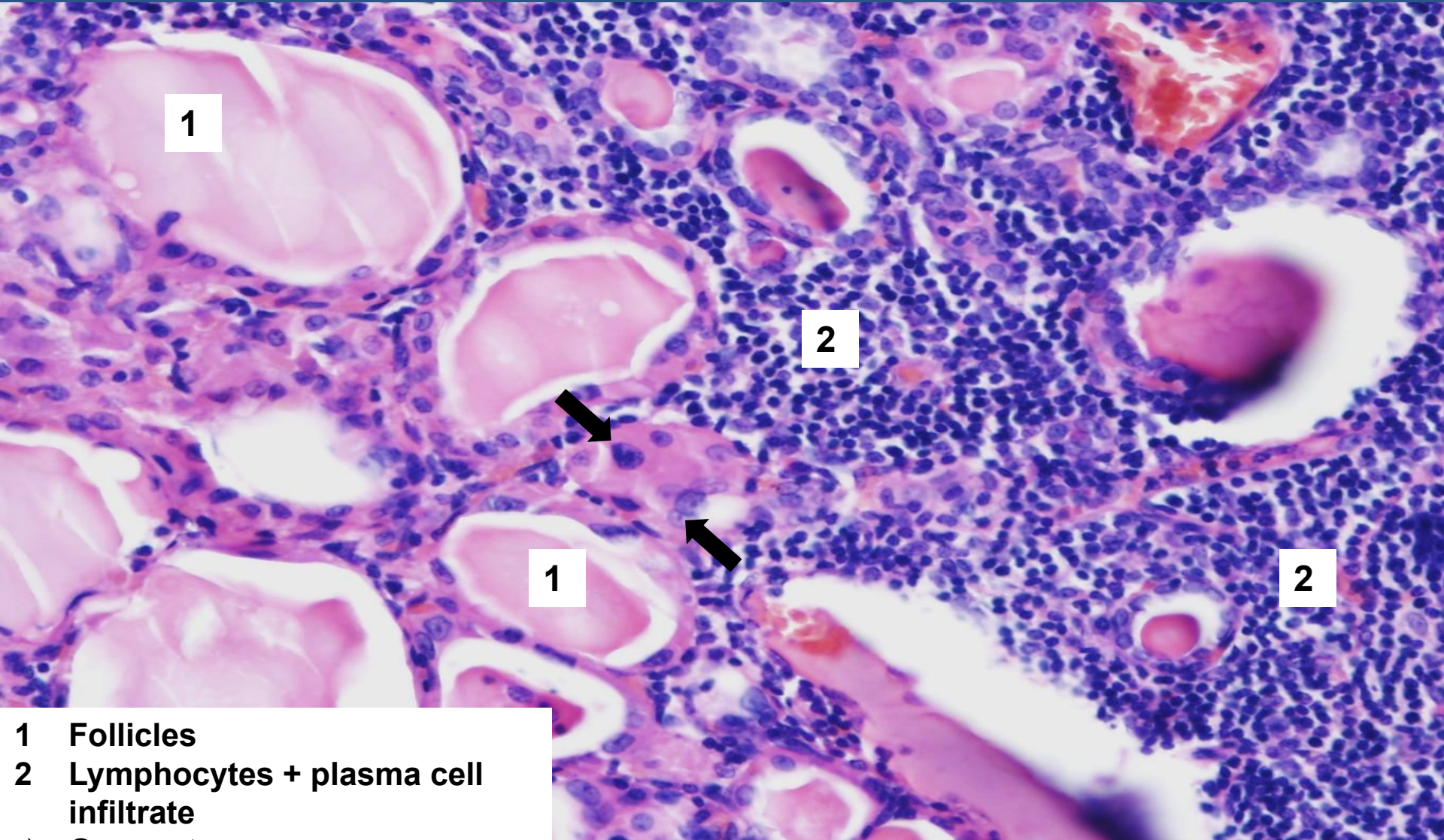
⇒ *variable grade of fibrosis*

Hashimoto's thyroiditis



- 1 Follicles
- 2 Germinal centre
- ➔ Inflammatory infiltrate

Hashimoto's thyroiditis



1

2

1

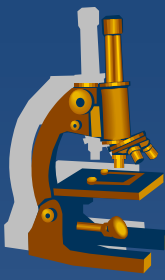
2

- 1 Follicles
- 2 Lymphocytes + plasma cell infiltrate



Thyroid gland hyperplasia

- x** Autoimmune Graves-Basedow disease
- x** Diffuse parenchymatous thyrotoxic goiter (> 60g)
+ exophthalmos
- x** IgG auto-antibody to the TSH receptor – LATS
(long-acting thyroid stimulator)
- x** Adenomatoid nodules
 - ⇒ *in the setting of nodular goiter, unencapsulated, diff. dg. x true adenoma may be difficult*



Thyroid gland hyperplasia

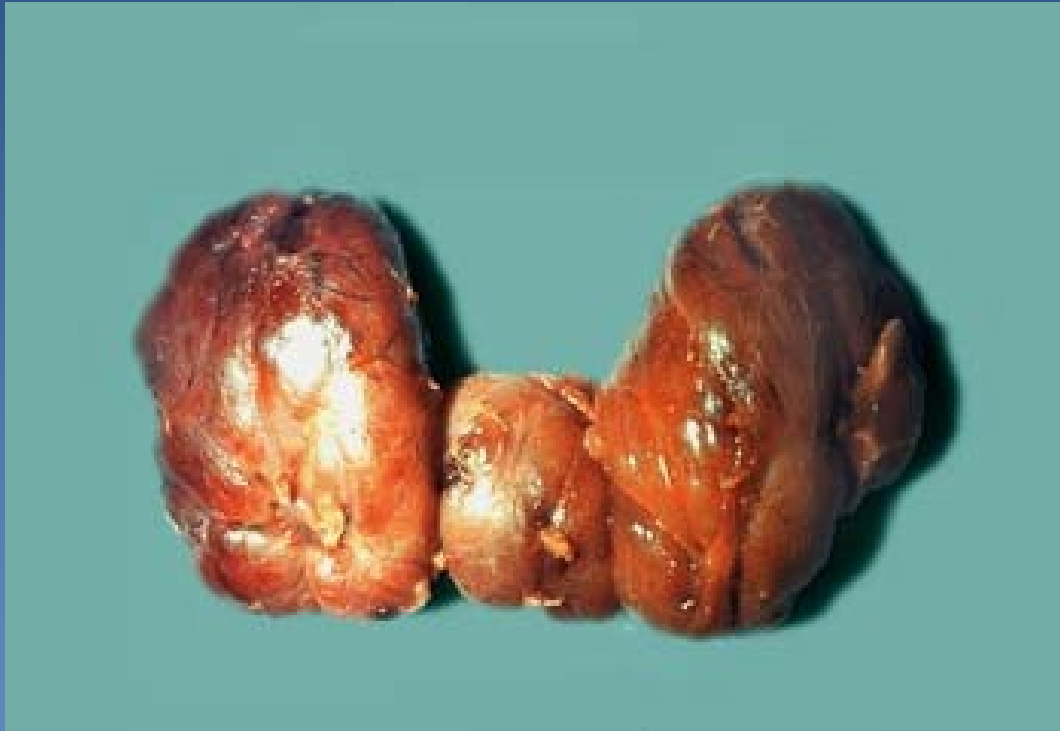x Gross:

⇒ *symmetric diffuse enlargement, red-brown, „fleshy“*

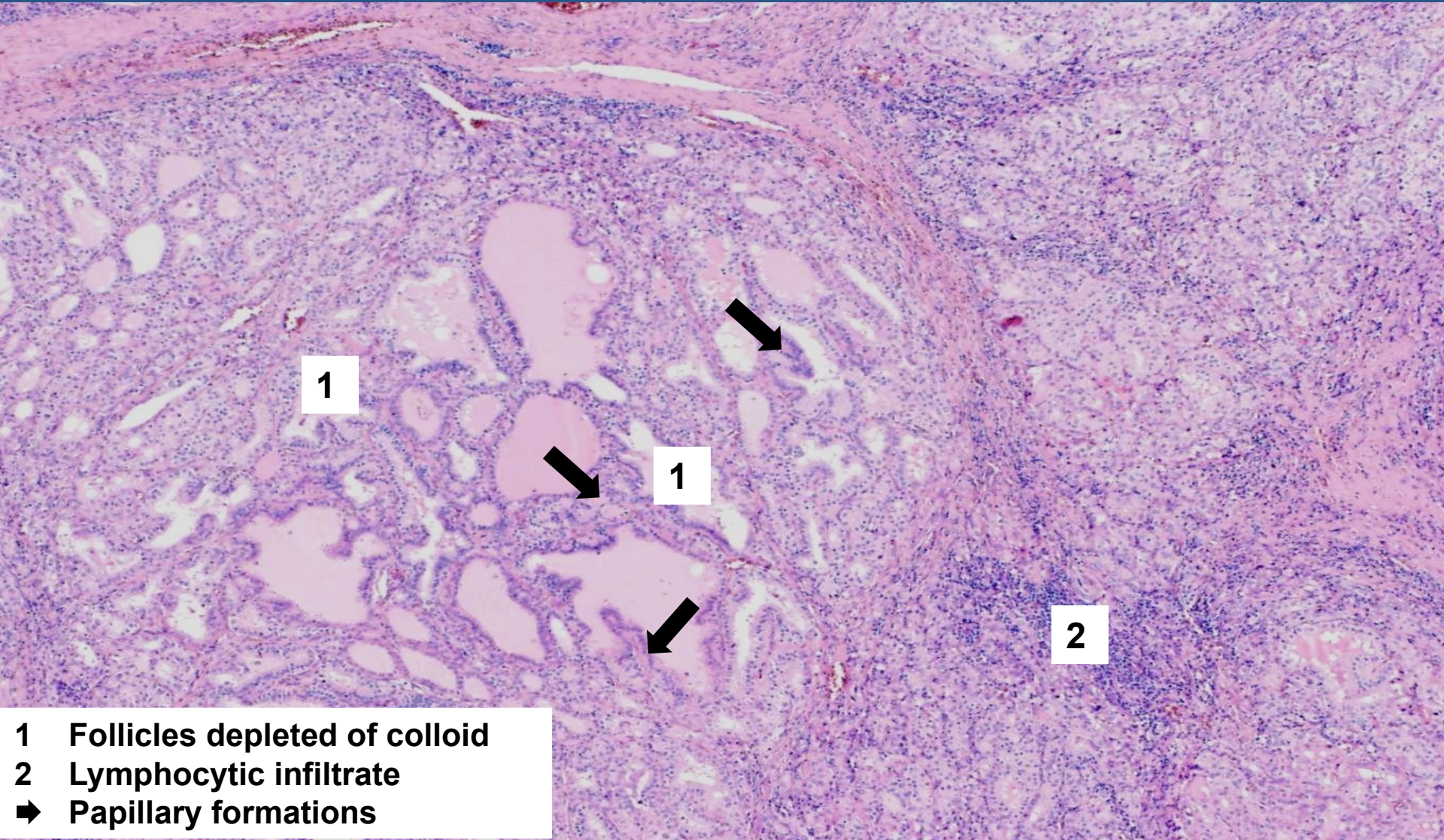
x Micro:

⇒ *tall hyperplastic follicular cells, papillary formations, ↓ amount of colloid, numerous resorptive vacuoles, focal lymphocytic infiltration*

Thyroid hyperplasia



Thyroid hyperplasia



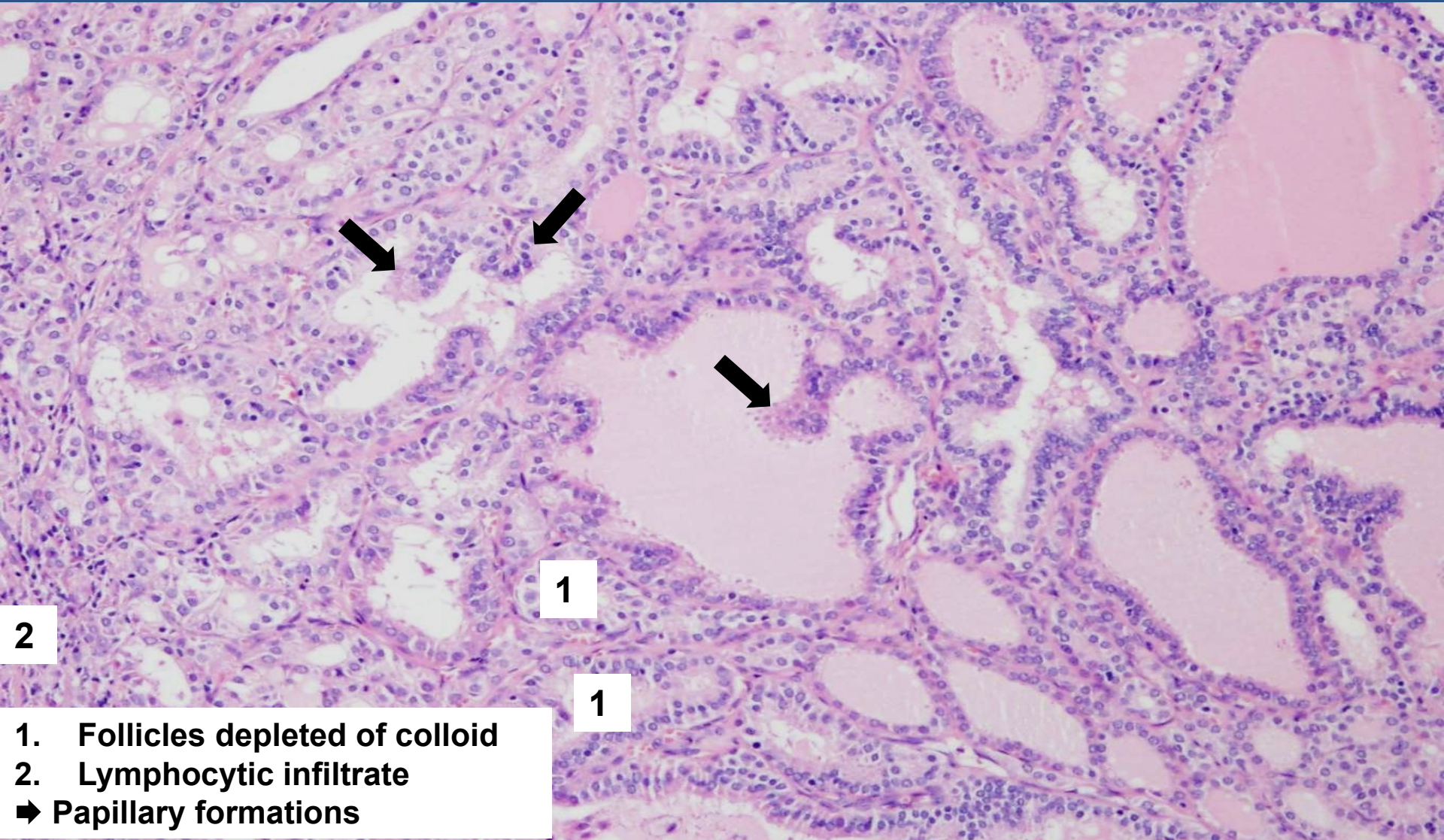
1

1

2

- 1 Follicles depleted of colloid
- 2 Lymphocytic infiltrate
- ➔ Papillary formations

Thyroid hyperplasia



1

1

2

1. Follicles depleted of colloid
 2. Lymphocytic infiltrate
- ➔ Papillary formations

Nontoxic goitre



- ✘ Iodine deficiency, goitrogens etc. → impaired synthesis of thyroid hormones → activation of hypothalamus-pituitary-thyroidal axis - ↑TSH
- ✘ Irregular activation, hyperplastic phase, colloid involution, reactive and regressive changes
- ✘ Nodular transformation – multinodular goitre
- ✘ Mostly euthyroid or low-level of hypothyroidism

Multinodular goitre



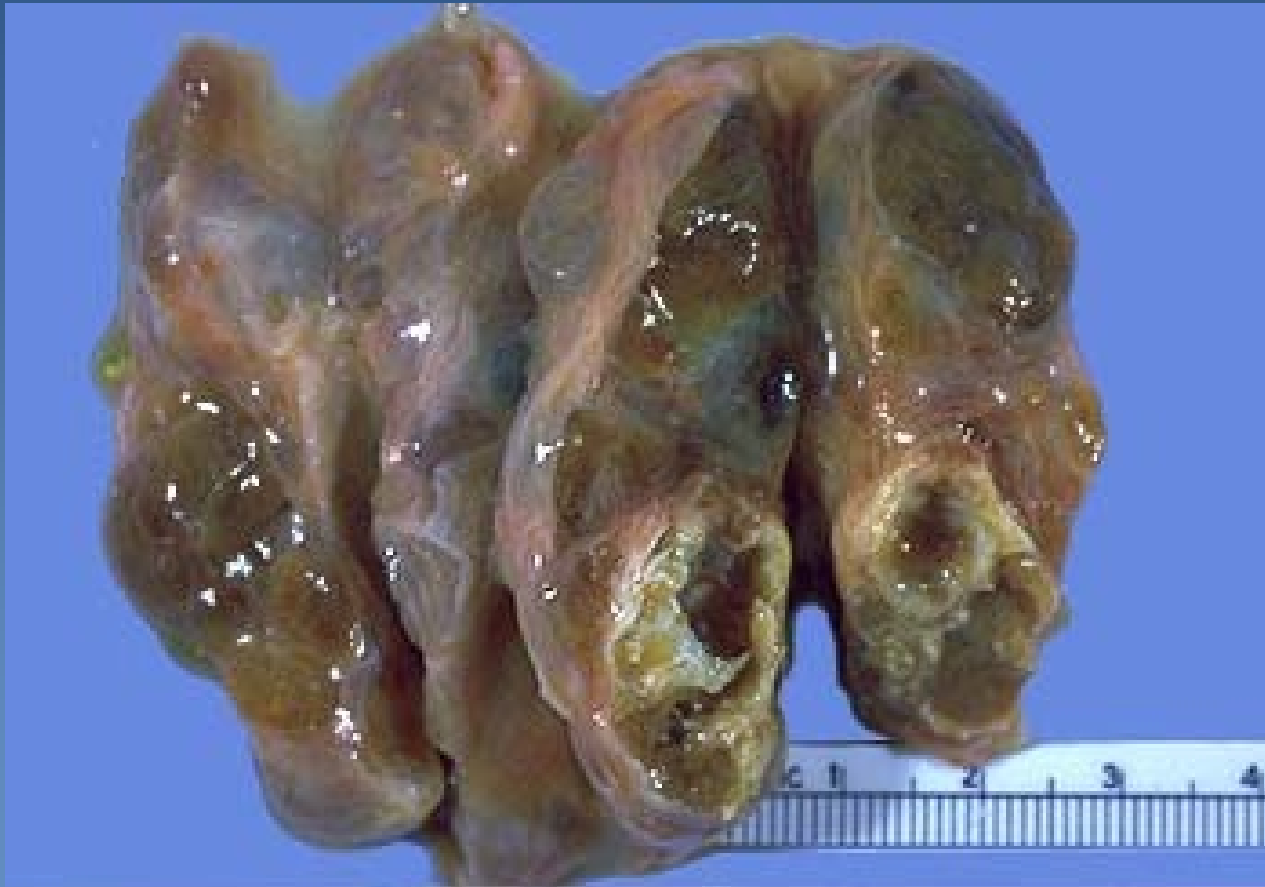x Gross:

- ⇒ irregular nodules, granular, yellow-brown (colloid goitre)*
- ⇒ common regressive changes – haemorrhage, cysts, fibrosis, calcification*

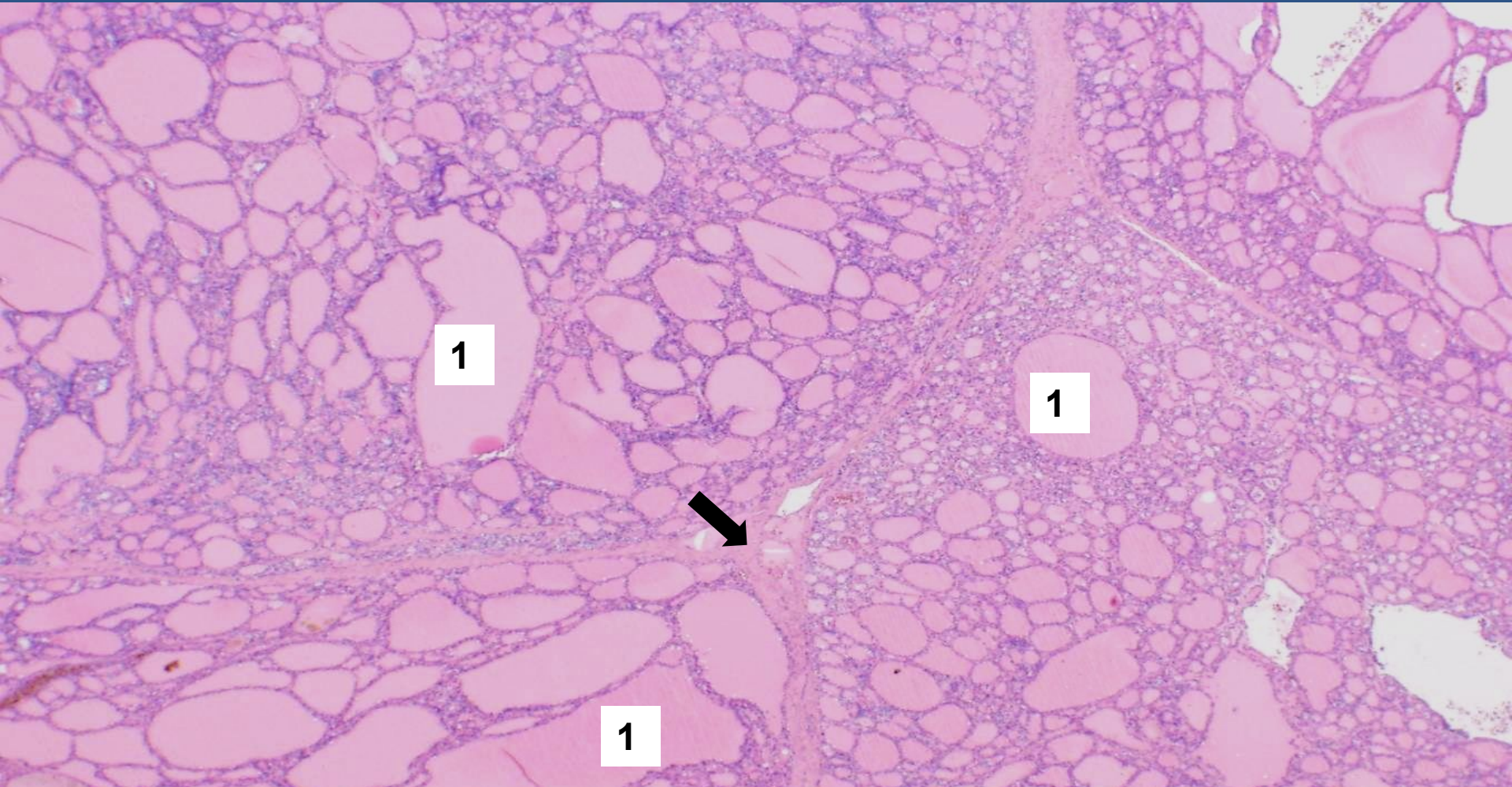
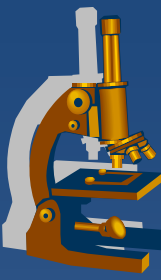
x Micro:

- ⇒ dilated follicles filled with colloid, sparse resorptive vacuoles, flat epithelial cells*

Multinodular goitre



Multinodular goitre



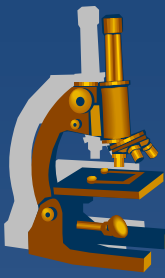
1 Follicles
➡ Fibrous septa

Thyroid tumors



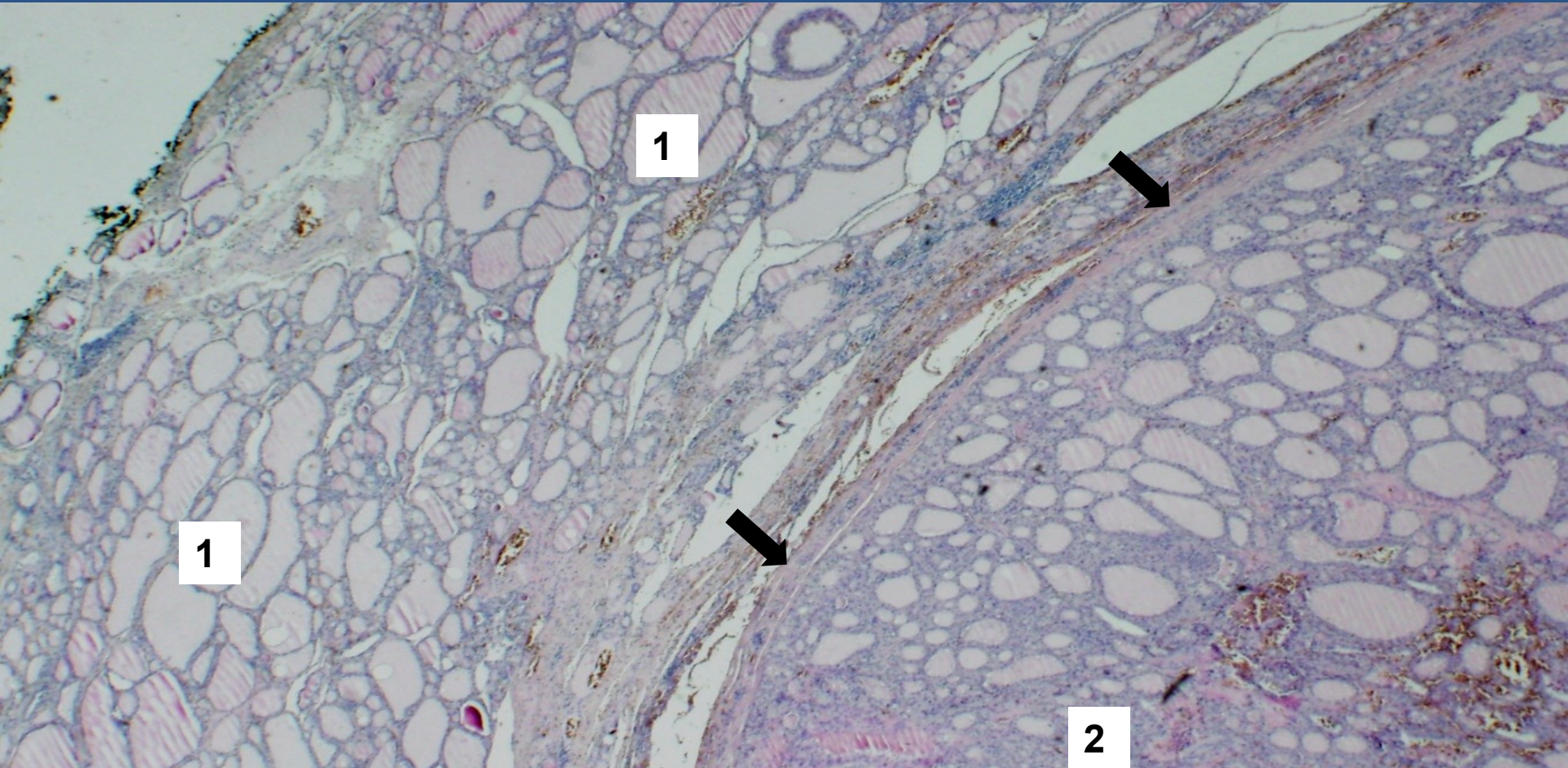
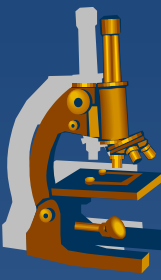
- ✘ Adenomas with variable structure
 - ⇒ *follicular, oncocytic, etc.*
- ✘ Carcinomas
 - ⇒ *papillary, follicular, medullary – parafollicular C-cells, anaplastic*
- ✘ Malignant lymphomas, secondary tu, etc.

Follicular adenoma



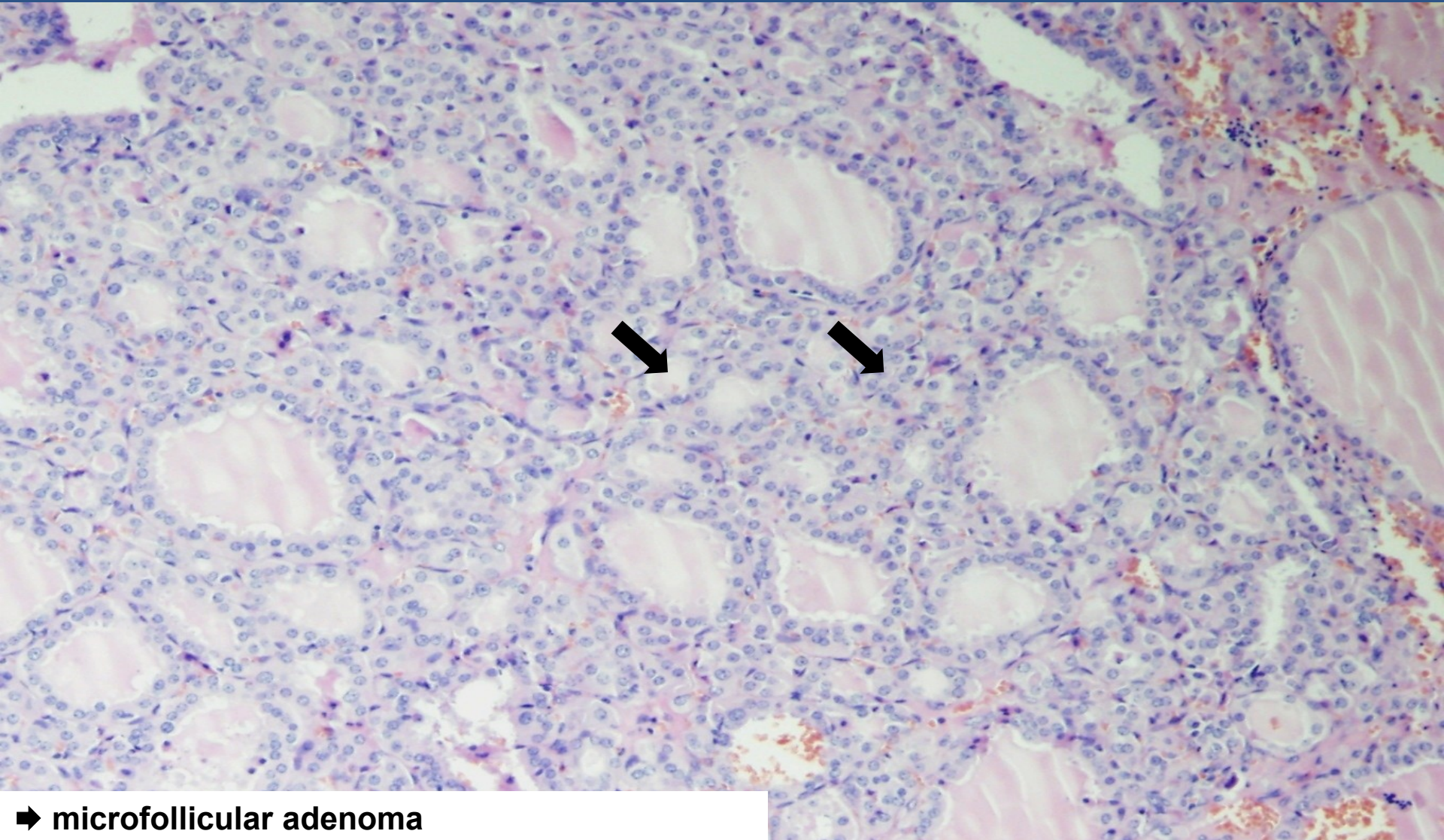
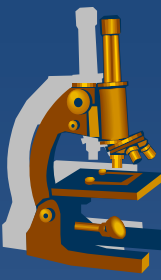
- ✗ Mostly solitary
- ✗ Encapsulated
- ✗ Pressure atrophy of adjacent parenchyma
- ✗ Diff. dg. ✗ follicular carcinoma
 - ⇒ *similar histologic structure, transcapsular invasion into surrounding thyroid tissue and/or angioinvasion necessary for ca diagnosis*
- ✗ Diagnosis possible only with complete biopsy
- ✗ Cytology – well differentiated follicular neoplasia

Follicular adenoma

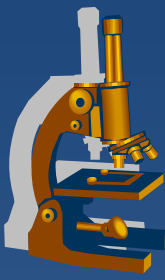


- 1 Thyroid parenchyma with follicles
- 2 Adenoma
- ➔ Fibrotic capsule (adenoma demarcation)

Follicular adenoma

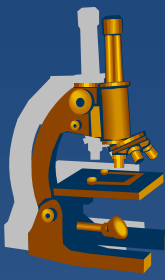


➡ microfollicular adenoma



Papillary adenocarcinoma

- ✗ Most common thyroid malignancy
- ✗ F 25-50 yrs, M less common, possible in children, adolescent
- ✗ ↑ incidence (better diagnostics)
- ✗ Solitary / multifocal
- ✗ Subtypes according histological structure
 - ⇒ *papillary, follicular, diffuse sclerosing, etc.*
- ✗ Diagnosis based on cytologic morphology



Papillary adenocarcinoma

x Gross:

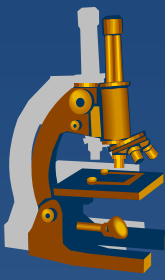
⇒ *pale focus*

x Micro:

⇒ *ground-glass nuclei*

- clear nuclei, grooved nuclei, excentric nucleolus („Orphan Annie“), nuclear superposition

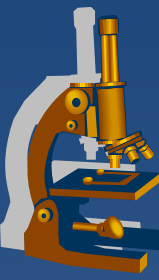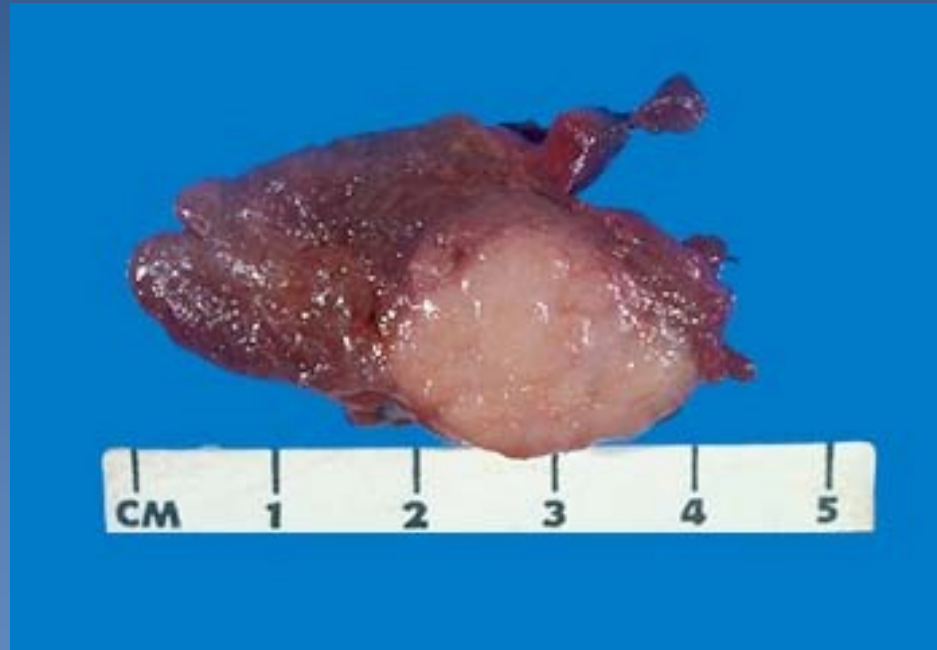
⇒ *papillary formations with disp. microcalcification*

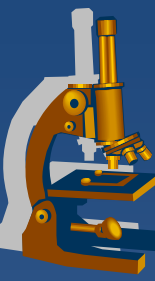


Papillary adenocarcinoma

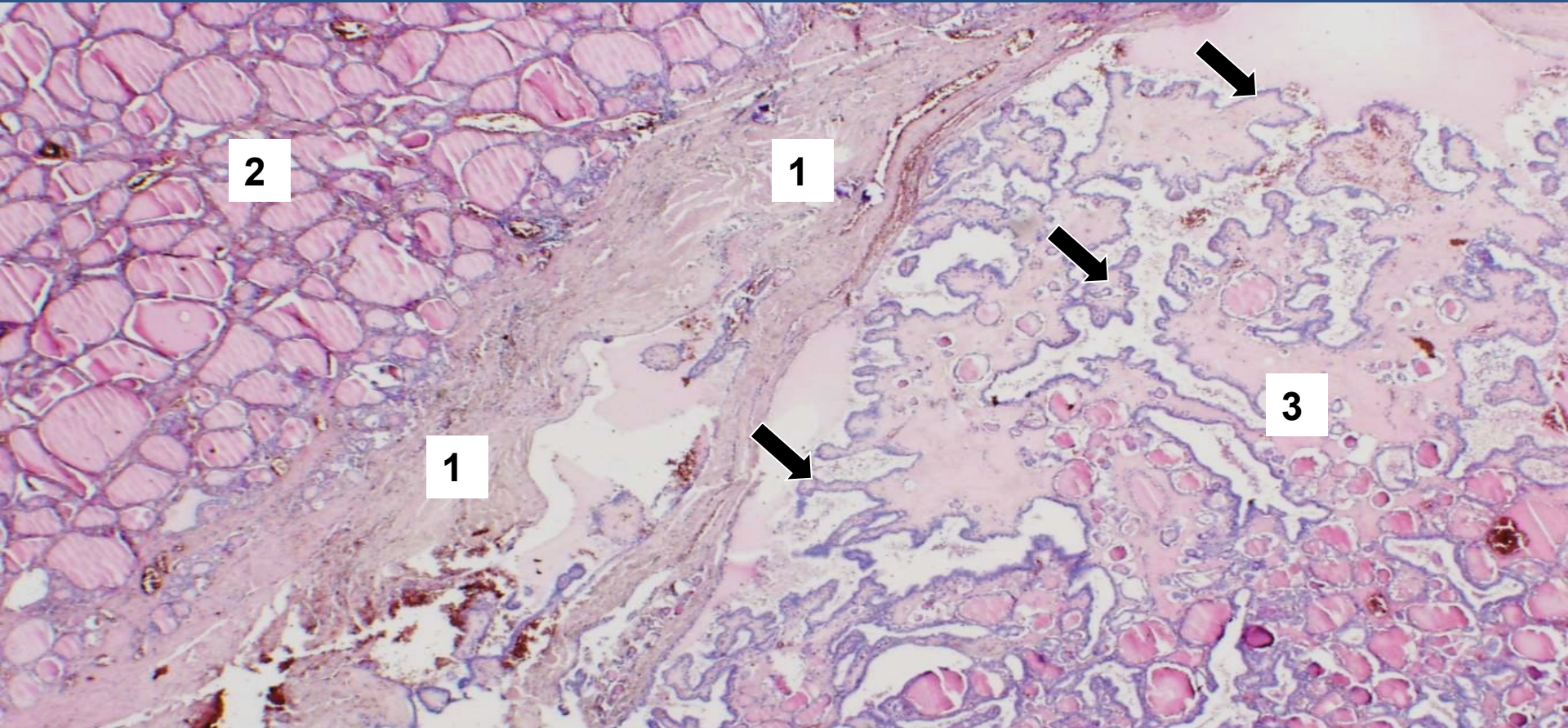
- ✘ Microcarcinoma
 - ⇒ *incidental finding, < 1 cm, very good prognosis*
- ✘ Worse prognosis in males, older people, ca with extrathyroidal extension
- ✘ Metastases into regional LN, lungs

Papillary adenocarcinoma

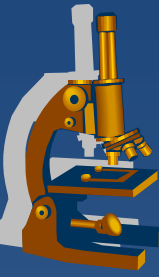




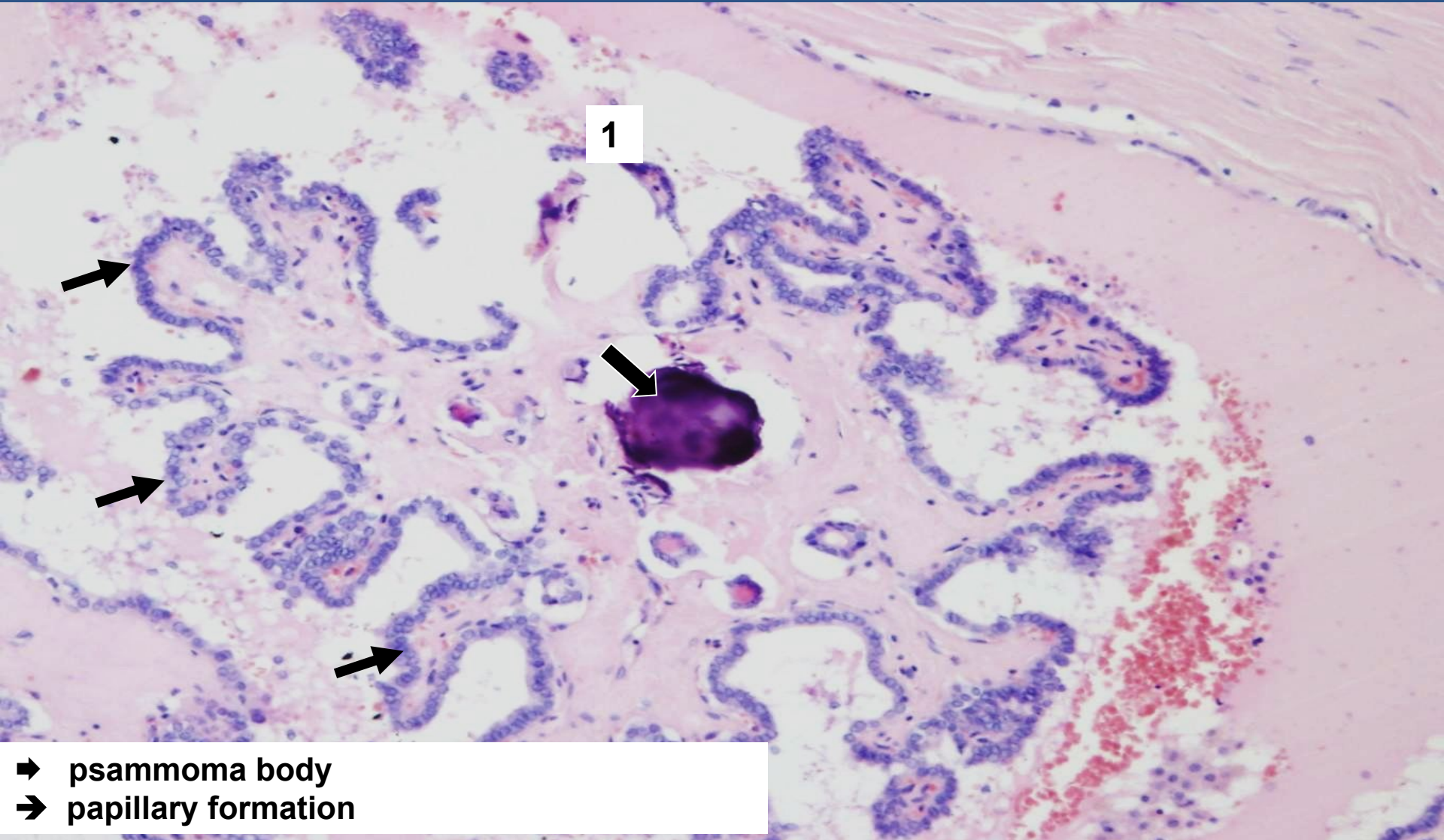
Papillary adenocarcinoma



- 1 fibrotic capsule
- 2 normal thyroid parenchyma
- 3 adenocarcinoma
- ➔ papillary formations

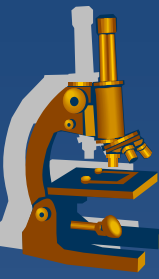


Papillary adenocarcinoma

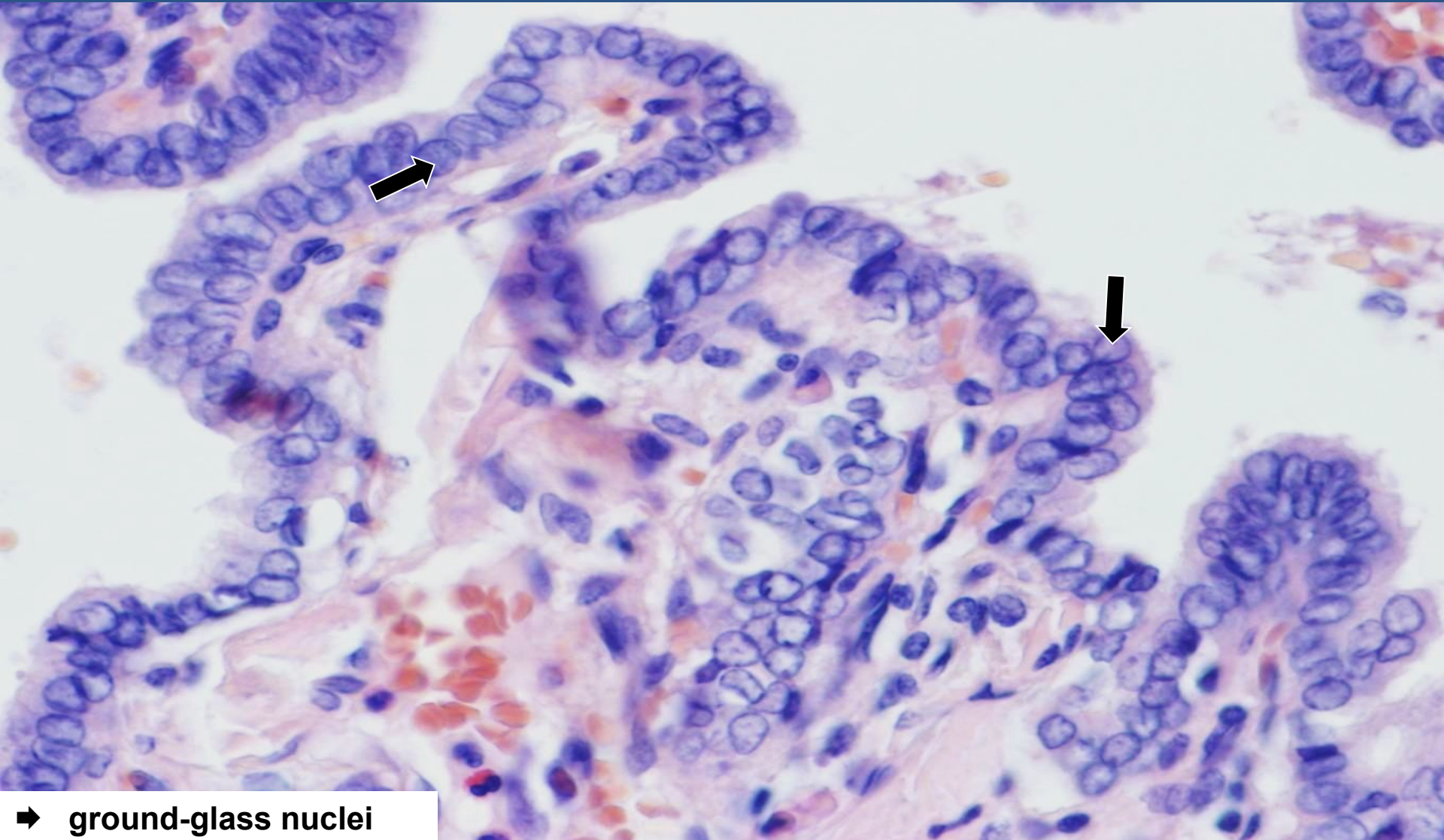


1

- ➔ psammoma body
- ➔ papillary formation



Papillary adenocarcinoma



➔ ground-glass nuclei

Pathology of adrenals



x Adrenal medulla pathology

⇒ *Hyperplasia (MEN sy)*

⇒ *Tumors*

- Neuroblastoma
- Ganglioneuroma
- Pheochromocytoma

Pheochromocytoma



- ✘ Chromaffin cells of adrenal medulla (paraganglioma), extraadrenal site possible
- ✘ Catecholamines synthesis
- ✘ Hypertension (incl. paroxysmal), tachycardia, sweating, tremor, headache
- ✘ Risk of brain haemorrhage
- ✘ More common 4.-5. decade, possible in children
- ✘ 90% benign behaviour

Pheochromocytoma



× Gross:

⇒ *demarcated paler lesion of variable size (g-kg), possible regressive changes (haemorrhage, necrosis)*

× Micro:

⇒ *fine capillarized stroma*

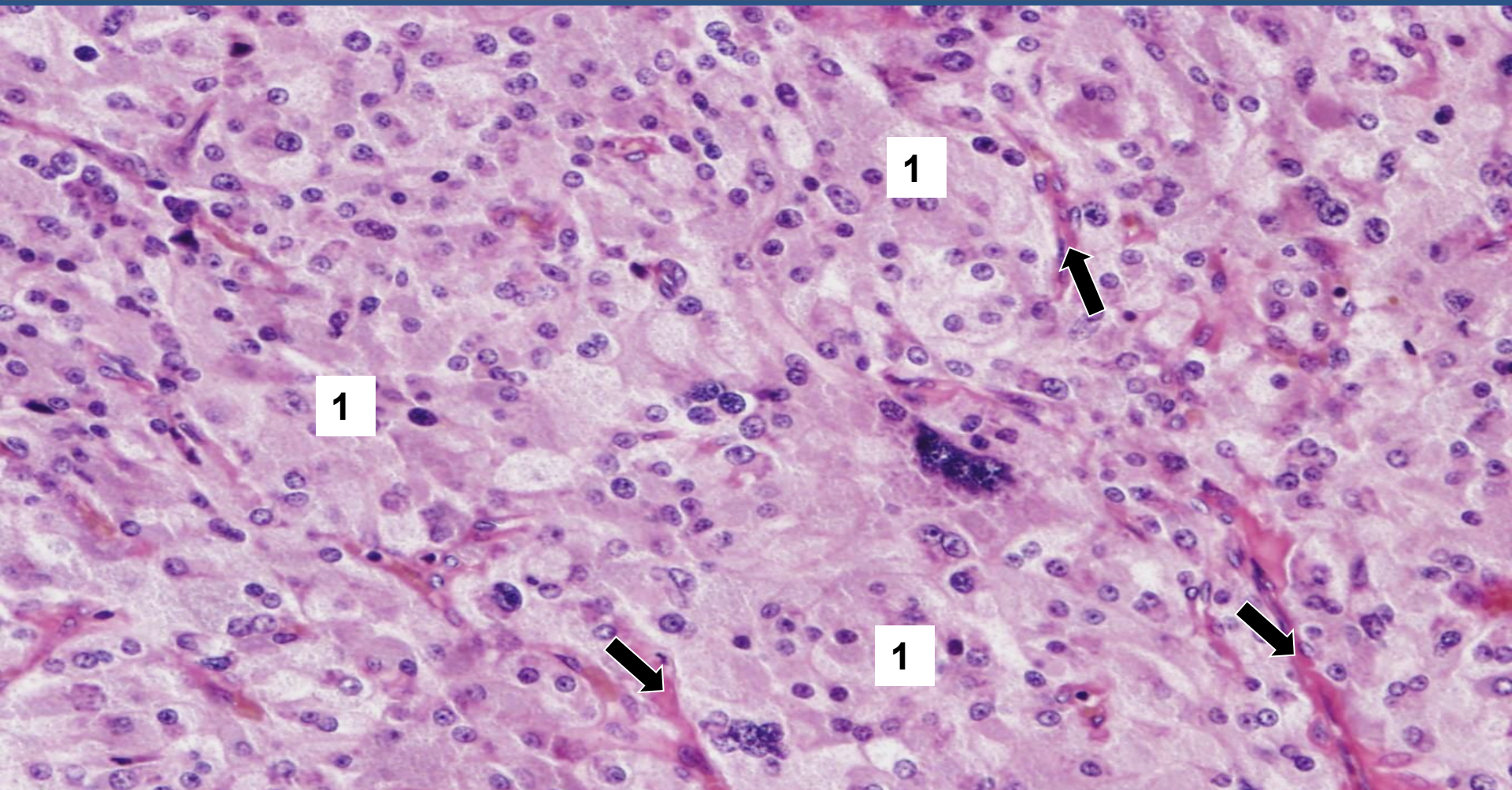
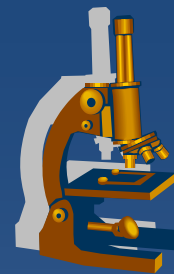
⇒ *trabeculae, solid alveoli*

⇒ *large cells, granulated cytoplasm, neurosecretory granules*

⇒ *nuclear atypias are not a sign of malignancy*

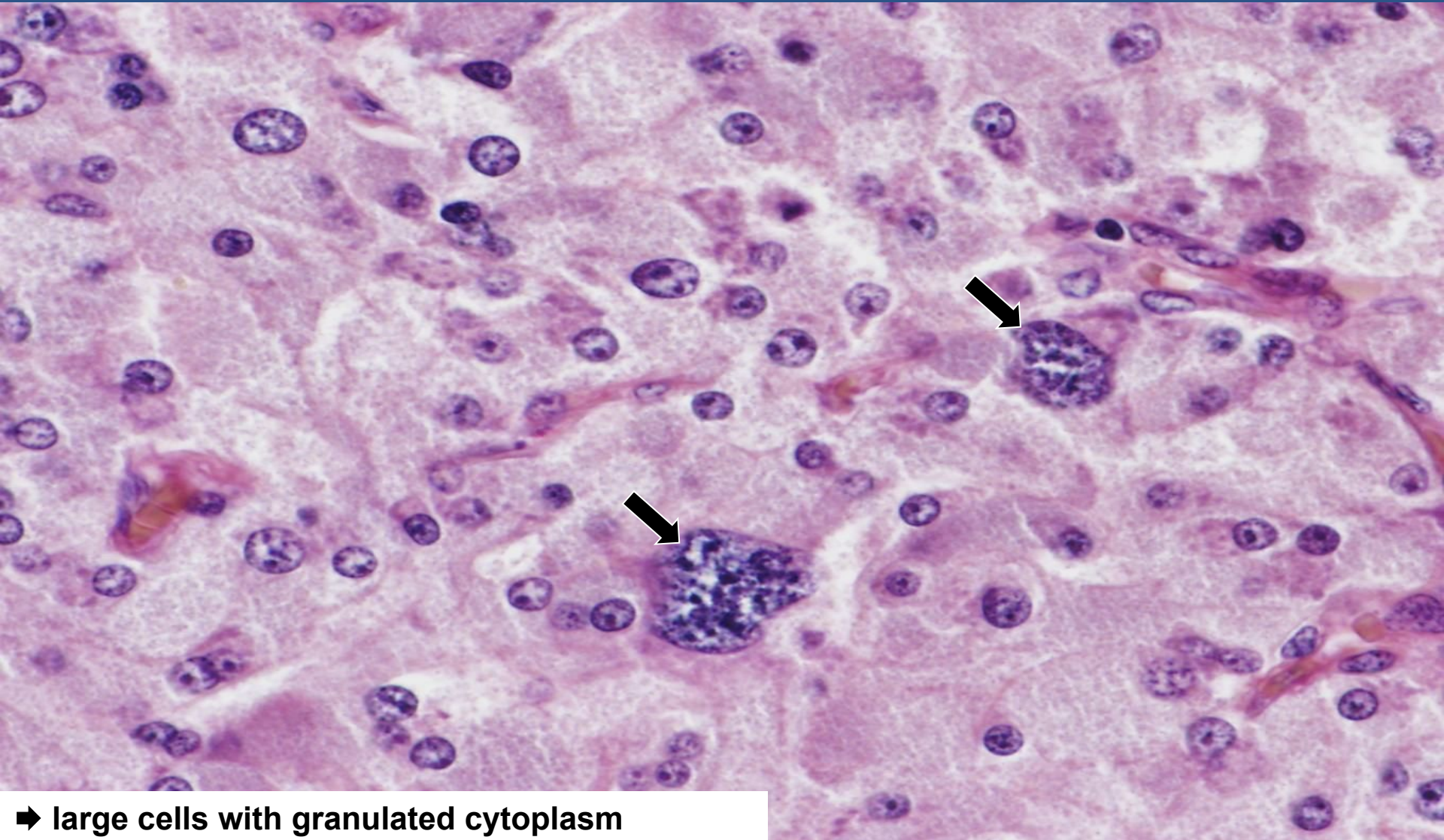
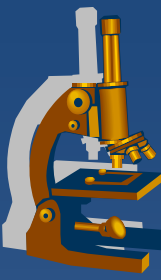
× Definitive diagnosis of malignancy based exclusively on finding of metastases

Pheochromocytoma



1 solid alveoli
➔ capillarized stroma

Pheochromocytoma



➔ large cells with granulated cytoplasm