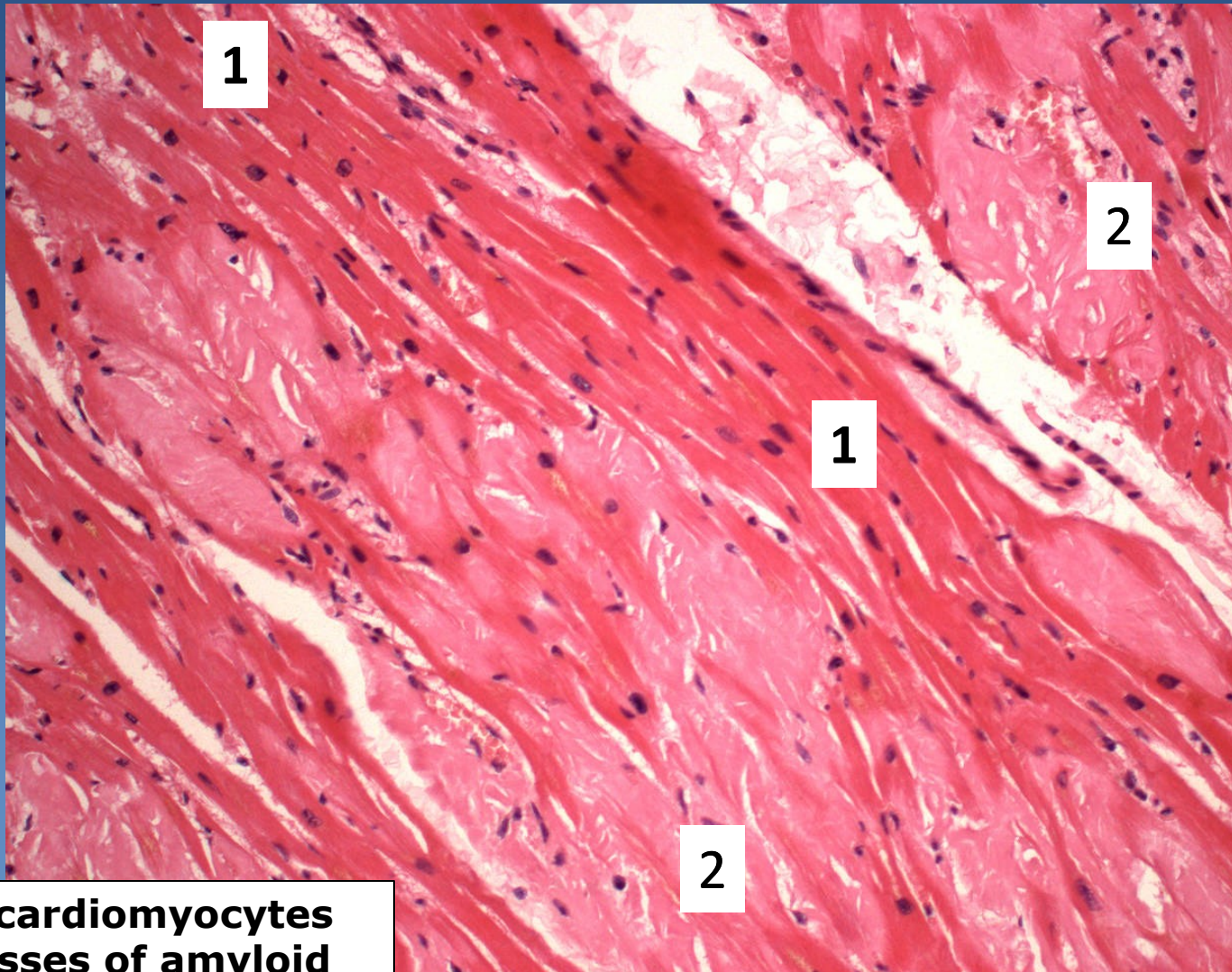
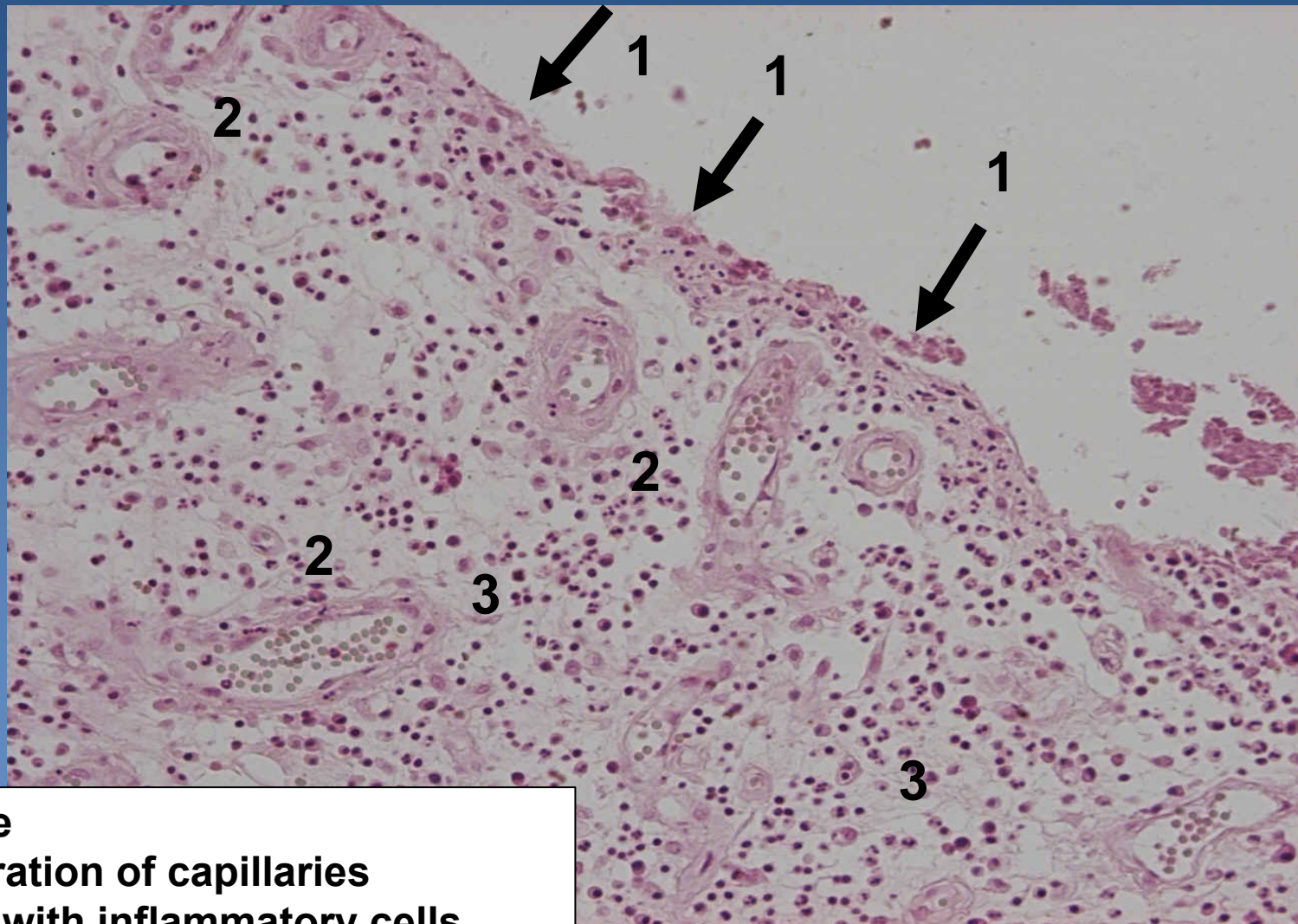
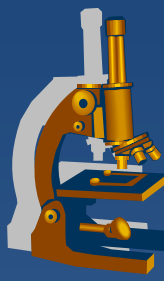


1. Myocardial amyloidosis



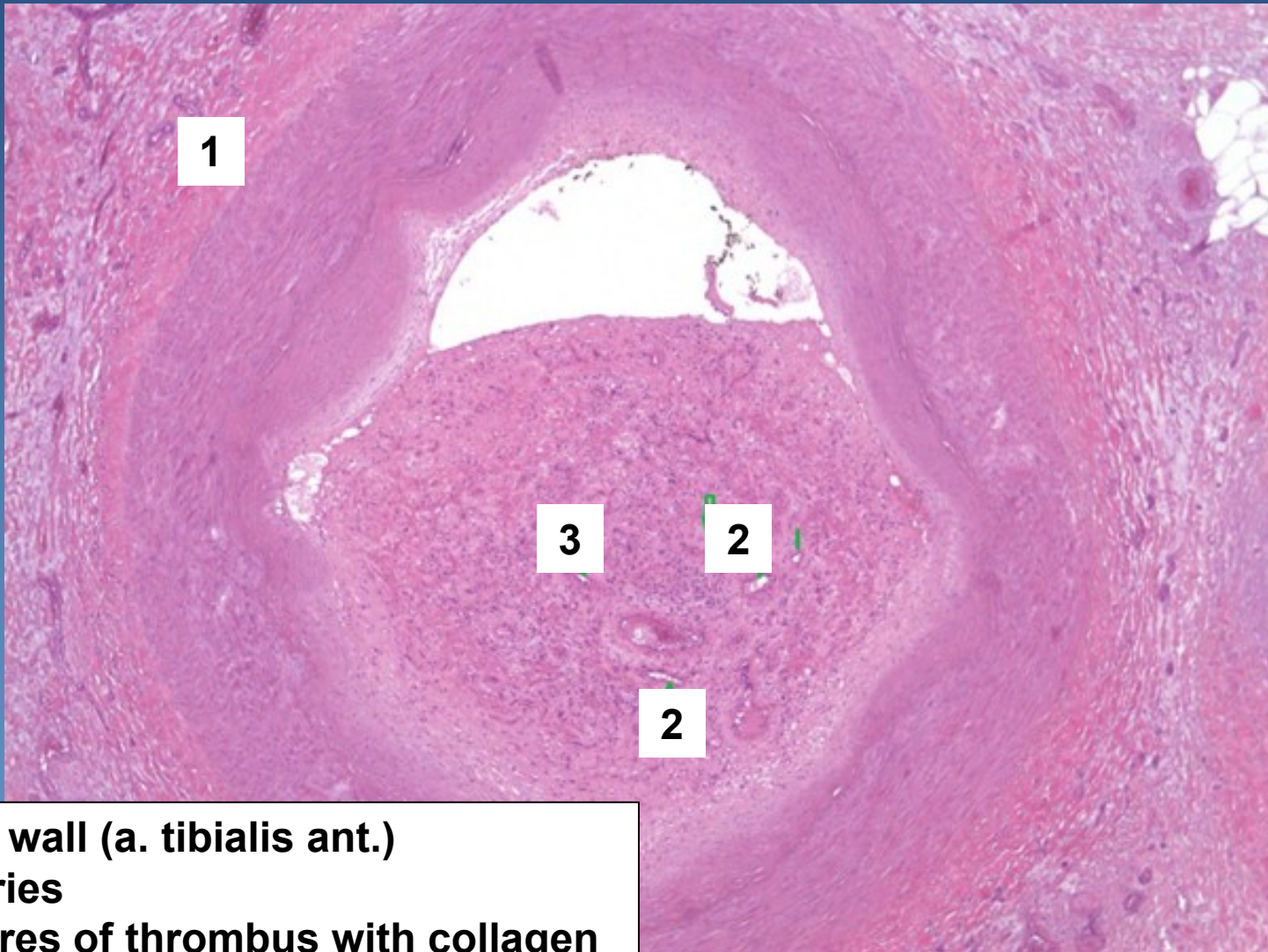
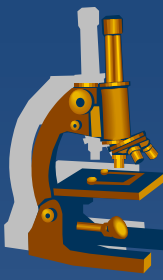
1 Normal cardiomyocytes
2 Pink masses of amyloid

2. Granulation tissue



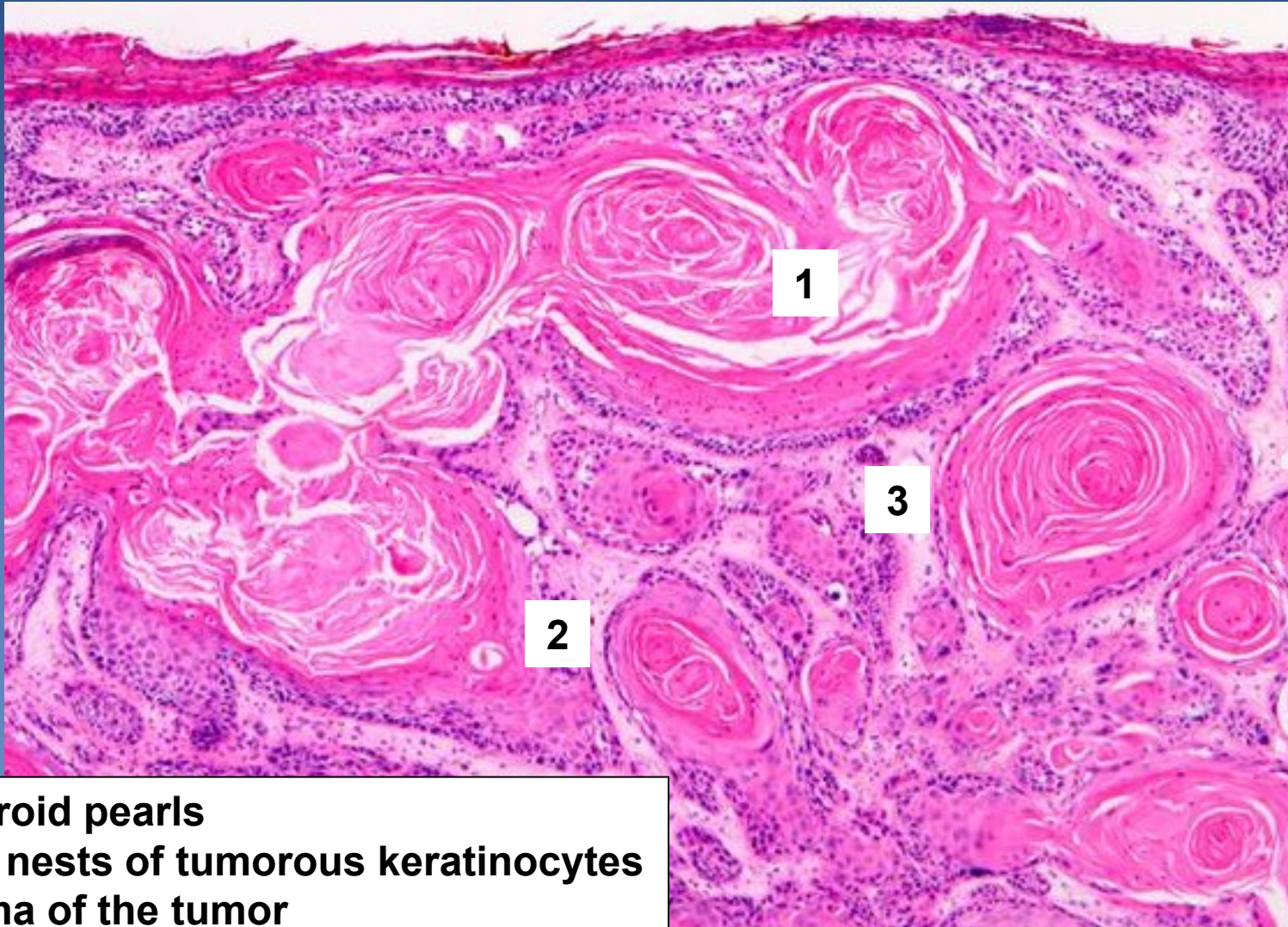
- 1 Surface
- 2 Proliferation of capillaries
- 3 Tissue with inflammatory cells

3. Organized thrombus



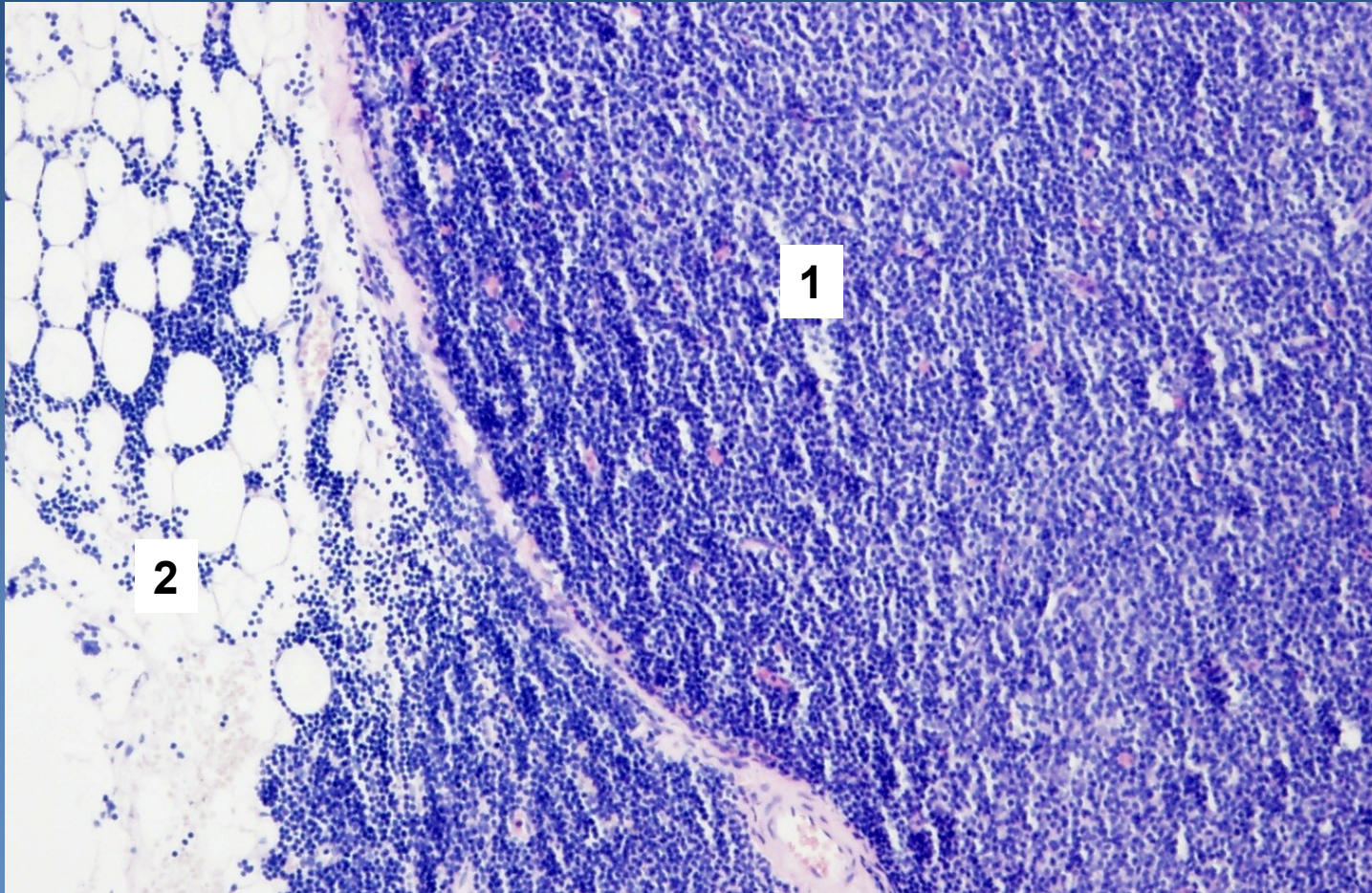
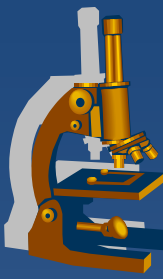
1 Arterial wall (a. tibialis ant.)
2 Capillaries
3 Structures of thrombus with collagen

4. Squamous cell carcinoma



- 1 Cancroid pearls
- 2 Solid nests of tumorous keratinocytes
- 3 Stroma of the tumor

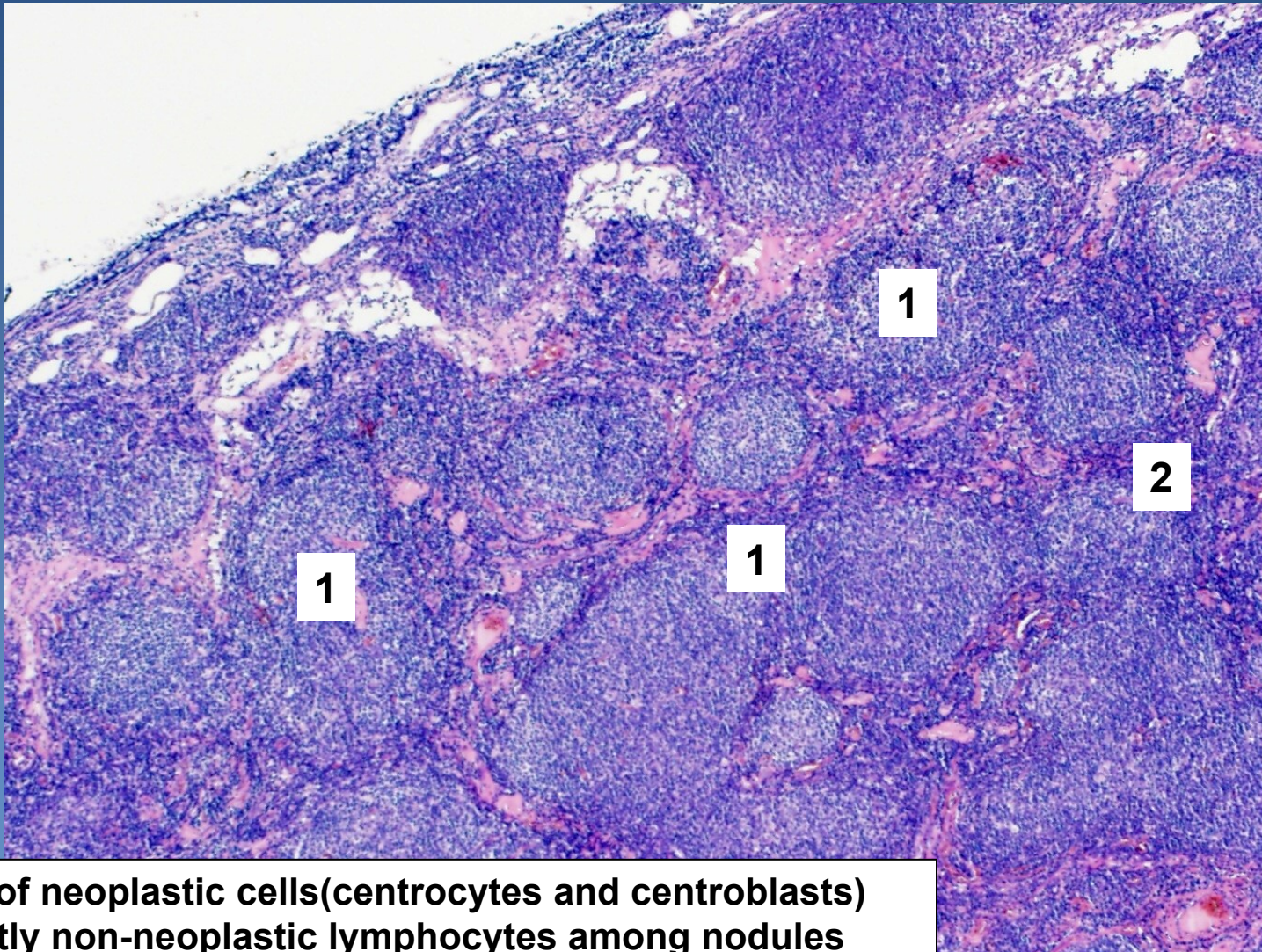
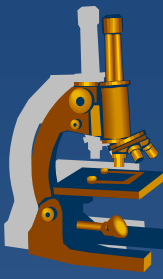
5. CLL/SLL



1 Diffuse infiltration in lymph node (mostly prolymphocytes and small lymphocytes – focally with pseudofollicles)

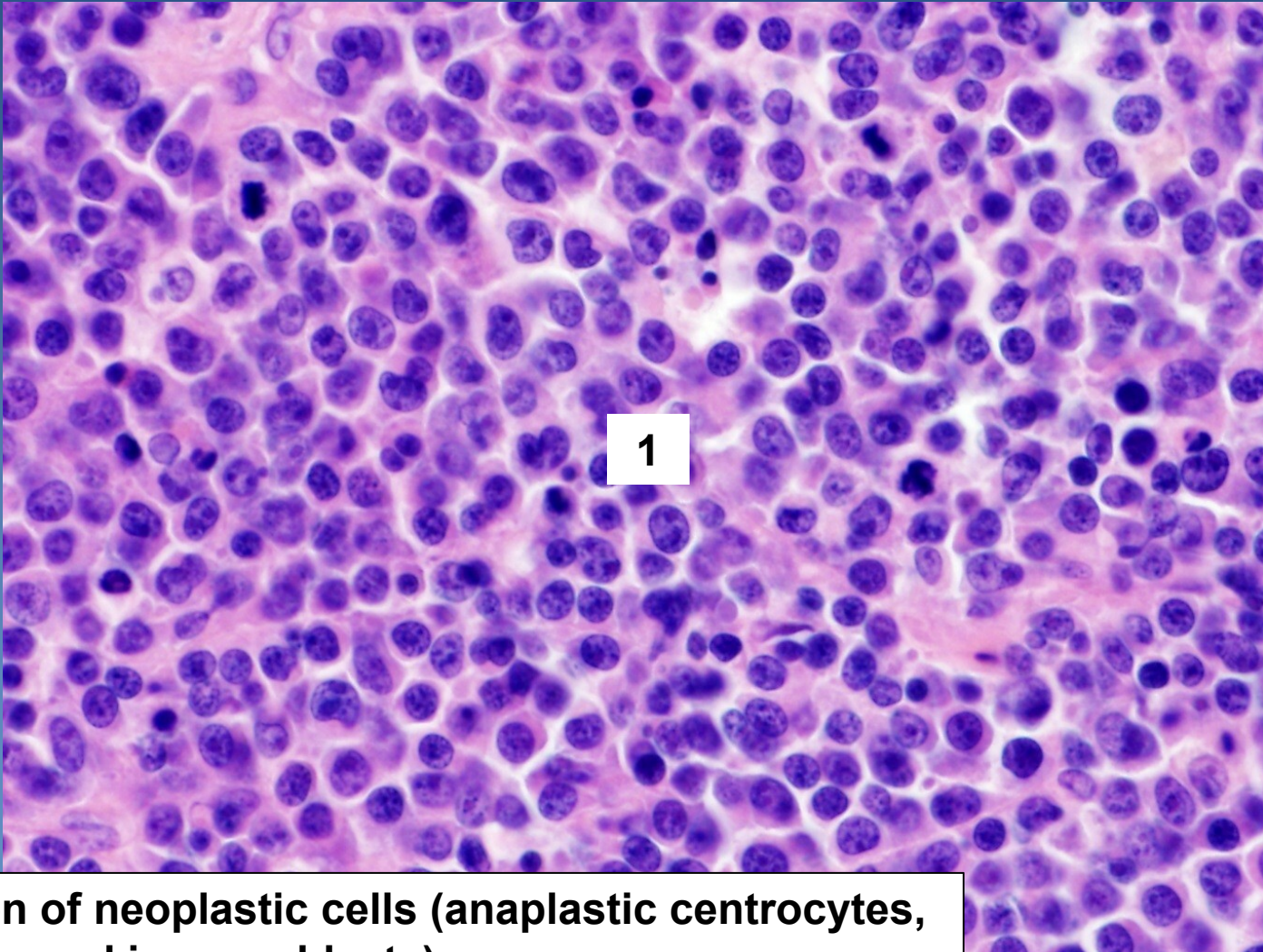
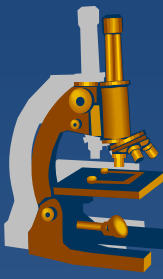
2 Infiltration of perinodal adipose tissue

6. Follicular lymphoma



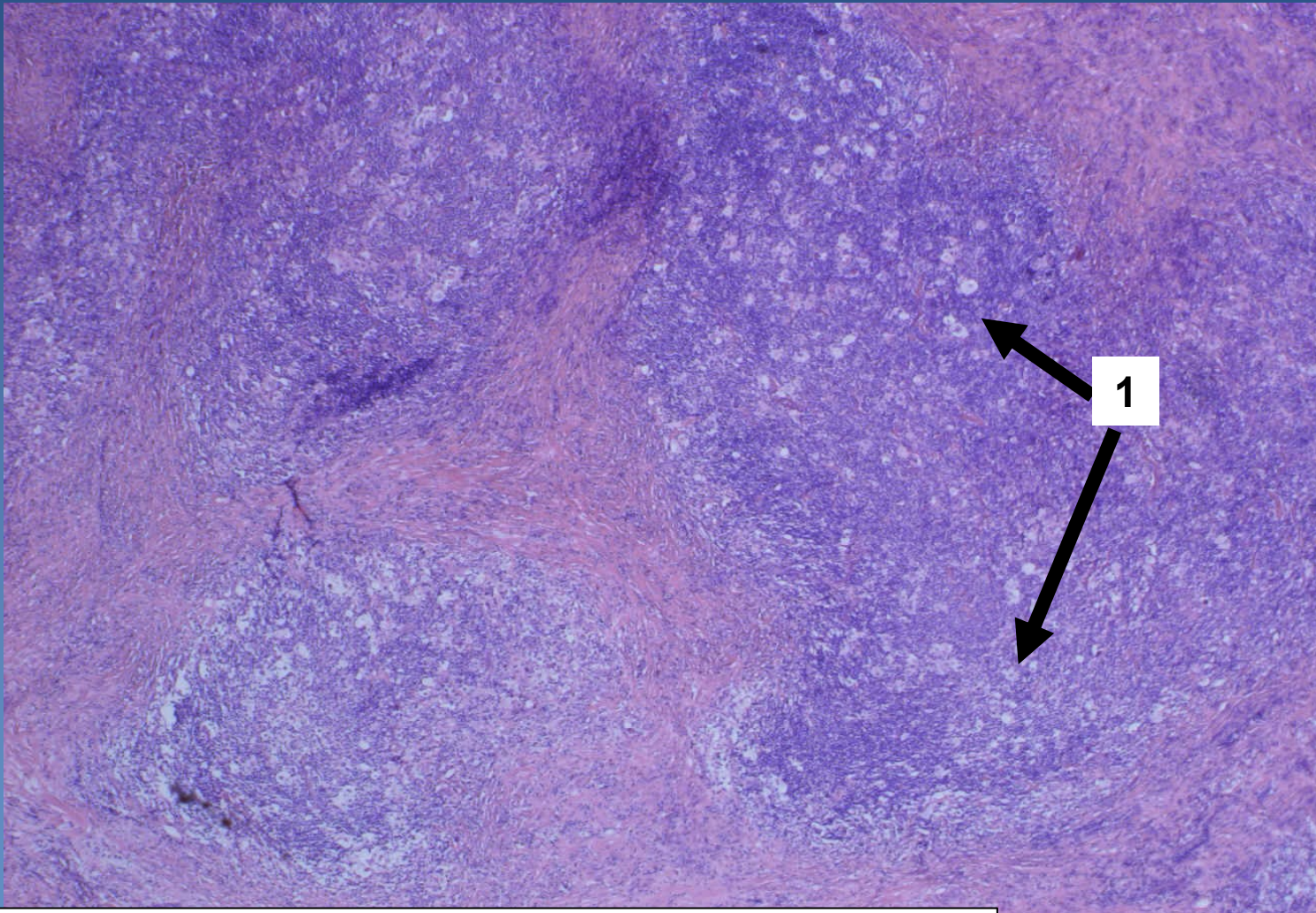
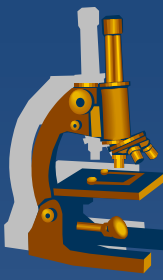
- 1 Nodules of neoplastic cells(centrocytes and centroblasts)
- 2 Dominantly non-neoplastic lymphocytes among nodules

7. Diffuse large B-cell lymphoma (DLBCL)



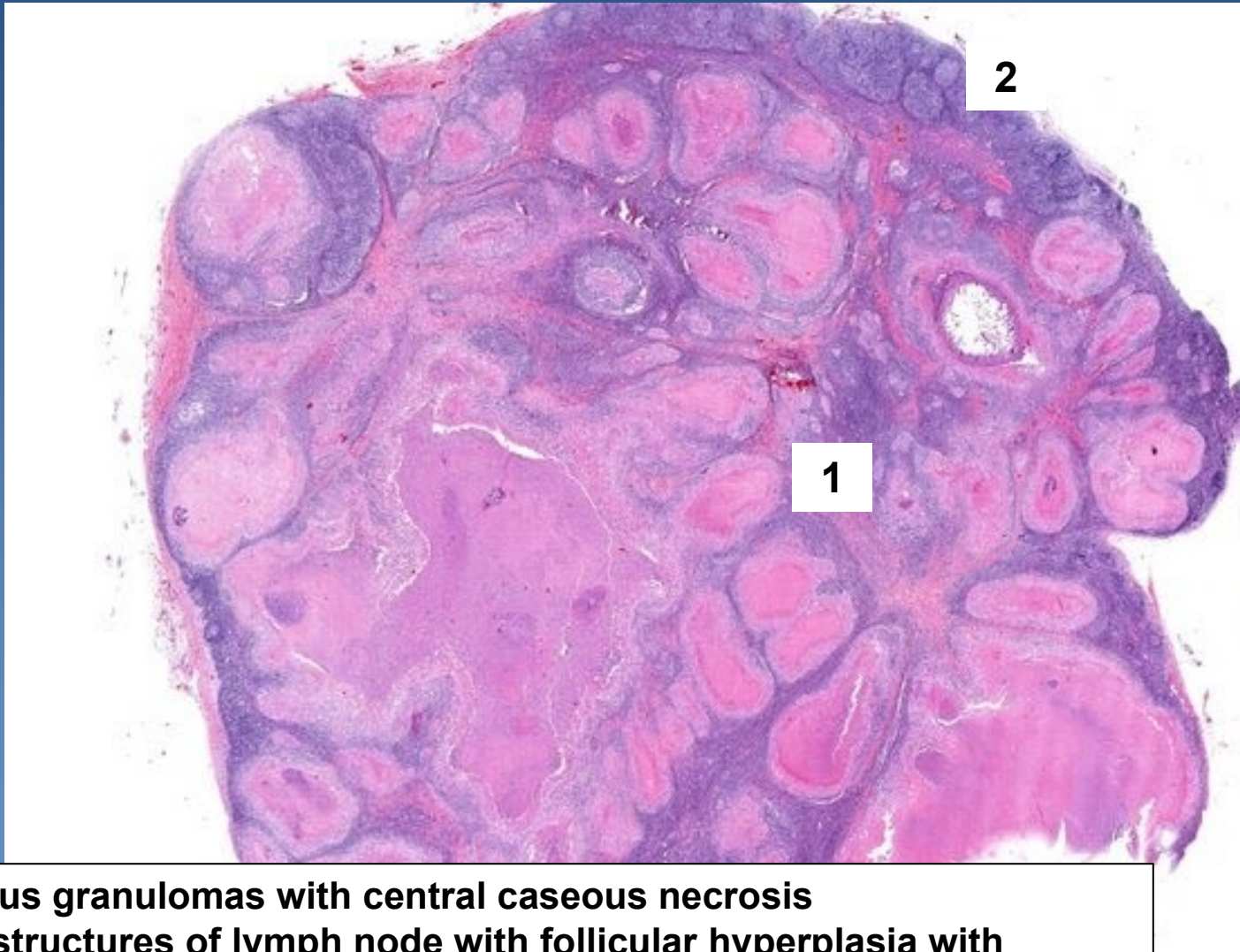
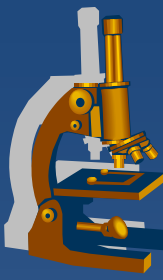
1 Population of neoplastic cells (anaplastic centrocytes, centroblasts and immunoblasts)

8. Hodgkin lymphoma, classical, nodular sclerosis

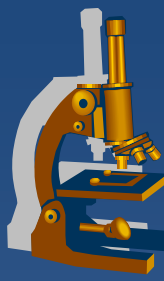


1 Lacunar cells in reactive non-neoplastic background

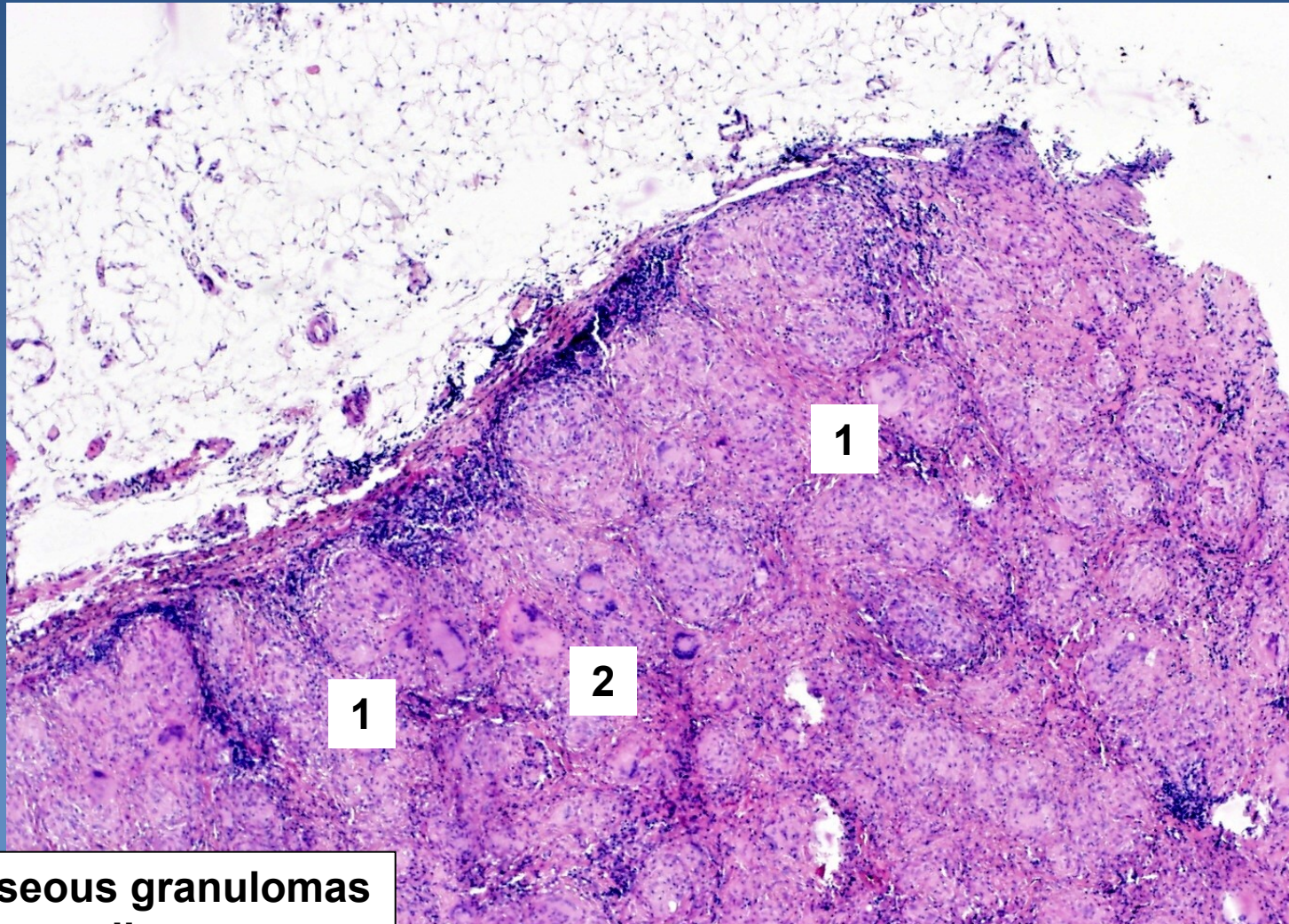
9. TBC lymphadenopathy



- 1 Tuberculous granulomas with central caseous necrosis
- 2 Remnant structures of lymph node with follicular hyperplasia with

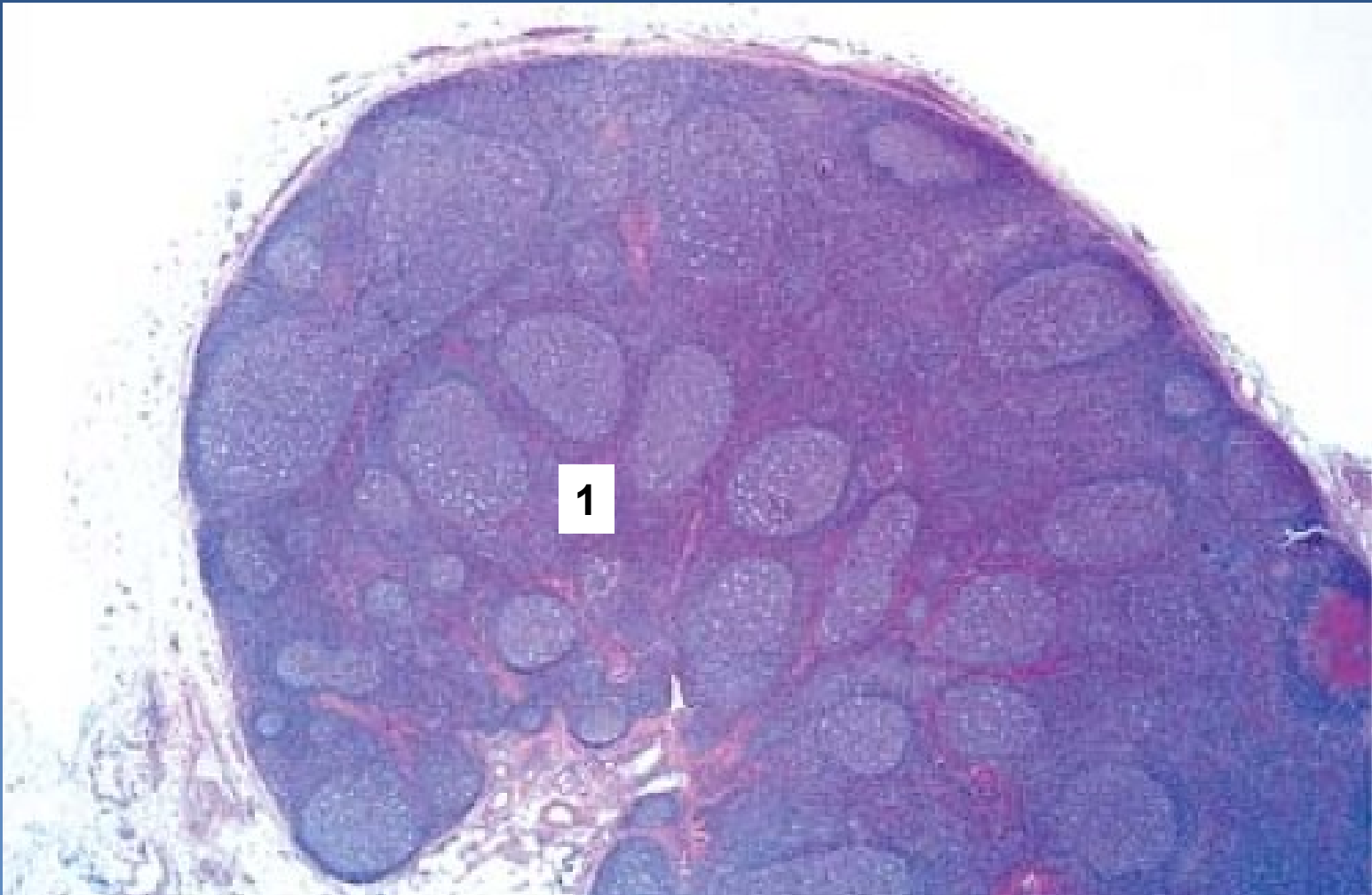
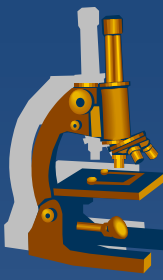


10. Sarcoidosis of lymph node



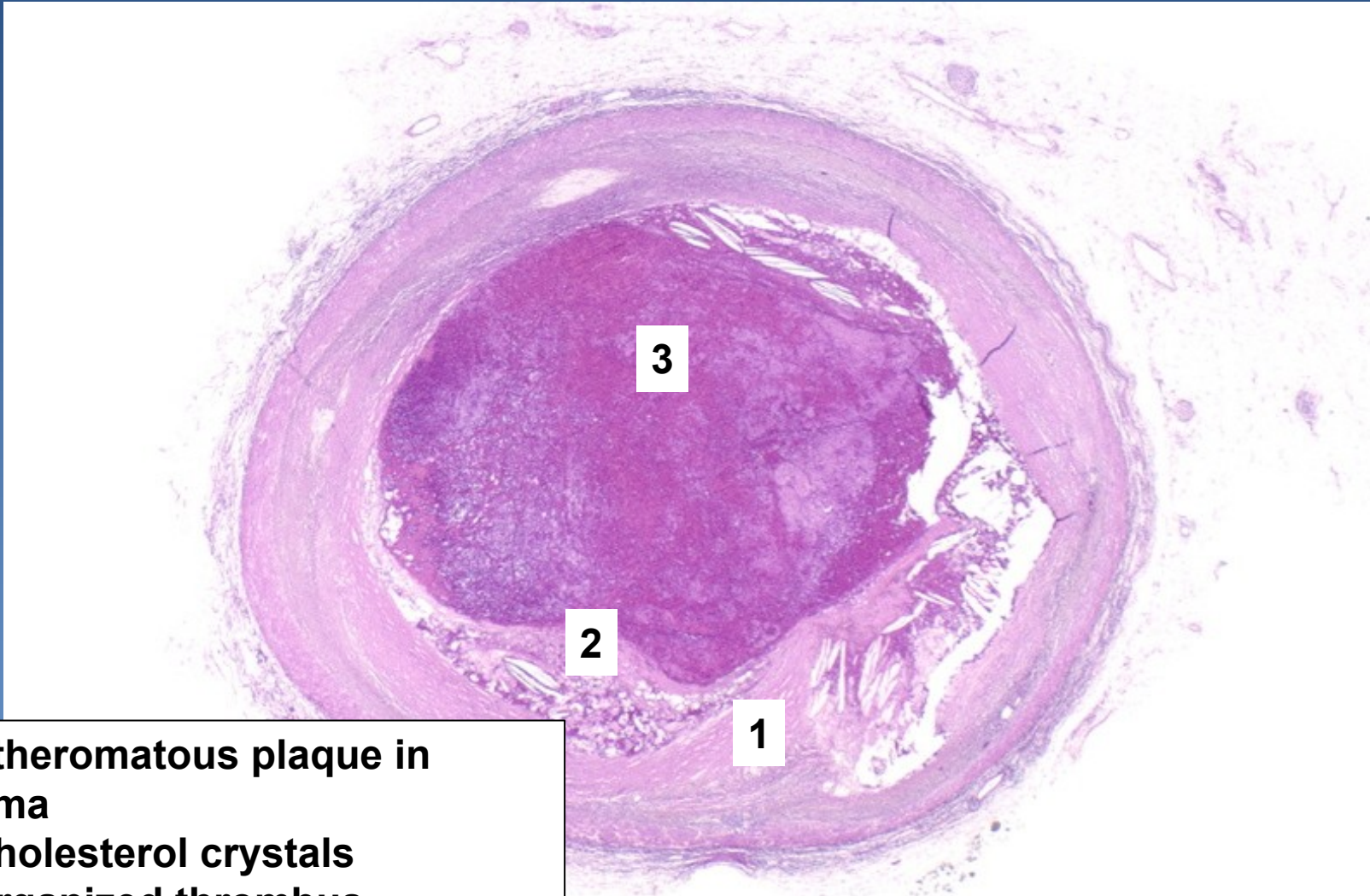
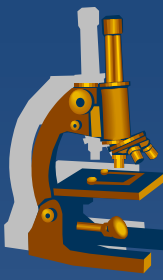
1 Non-caseous granulomas
2 Langhans cells

11. Reactive lymphadenopathy



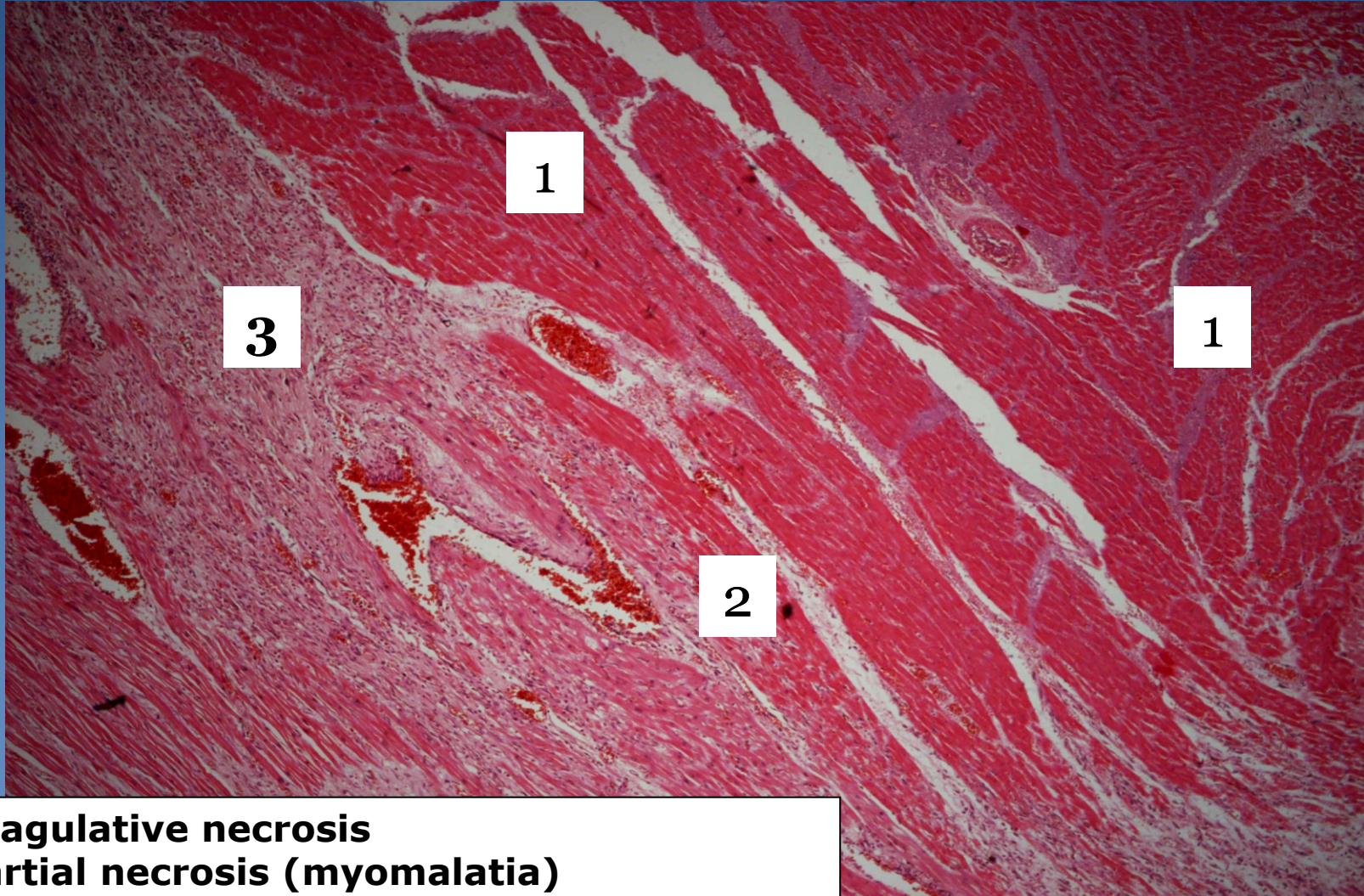
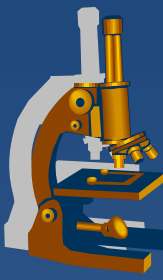
1 Structures of lymph node with follicular hyperplasia with germinal centers

12. Atherosclerosis with mural thrombosis

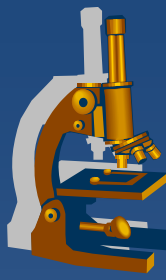


- 1 Atheromatous plaque in intima
- 2 Cholesterol crystals
- 3 Organized thrombus

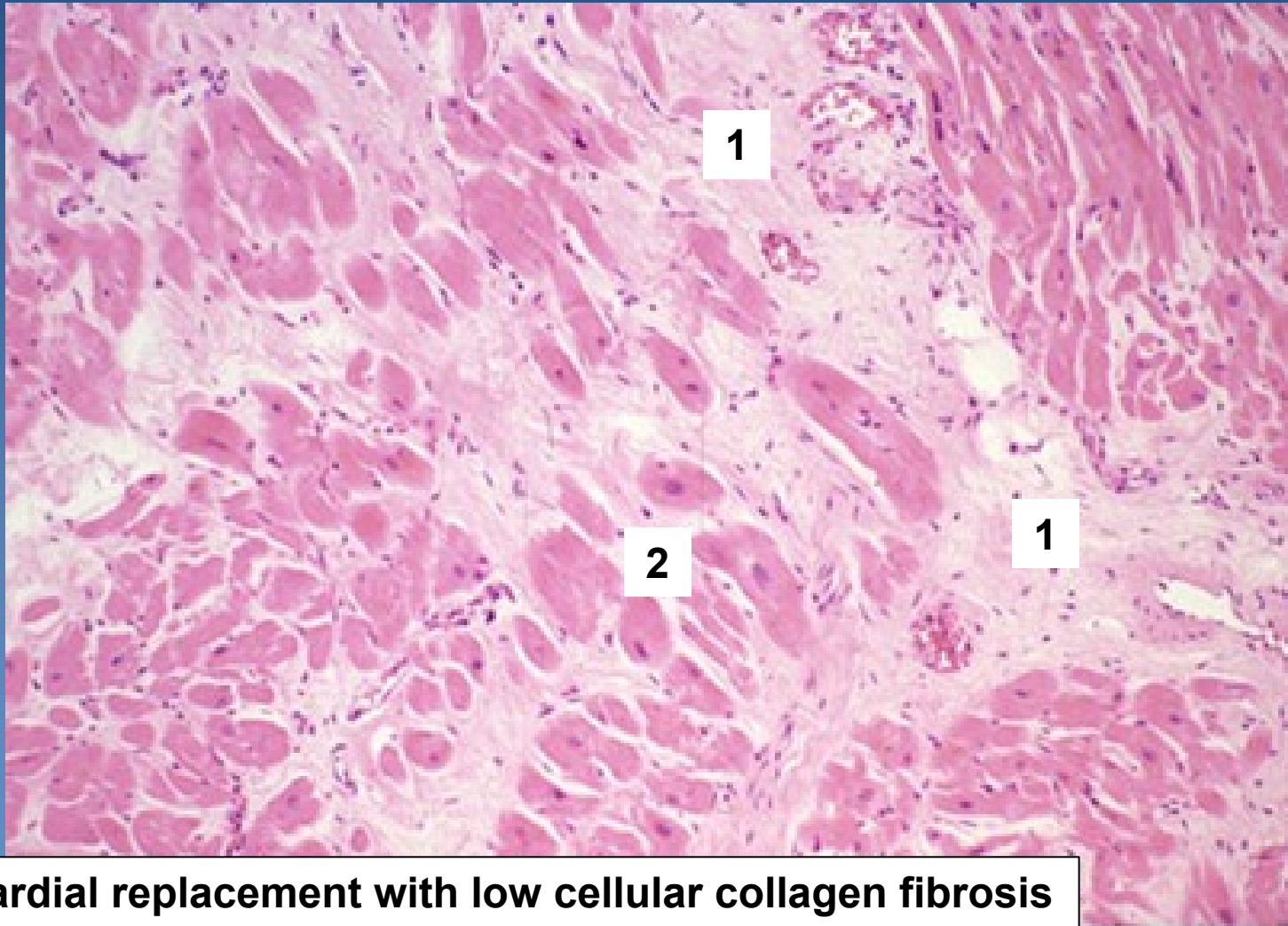
13. Myocardial infarction



- 1 coagulative necrosis**
- 2 partial necrosis (myomalatia)**
- 3 granulation tissue, inflammatory infiltrate**

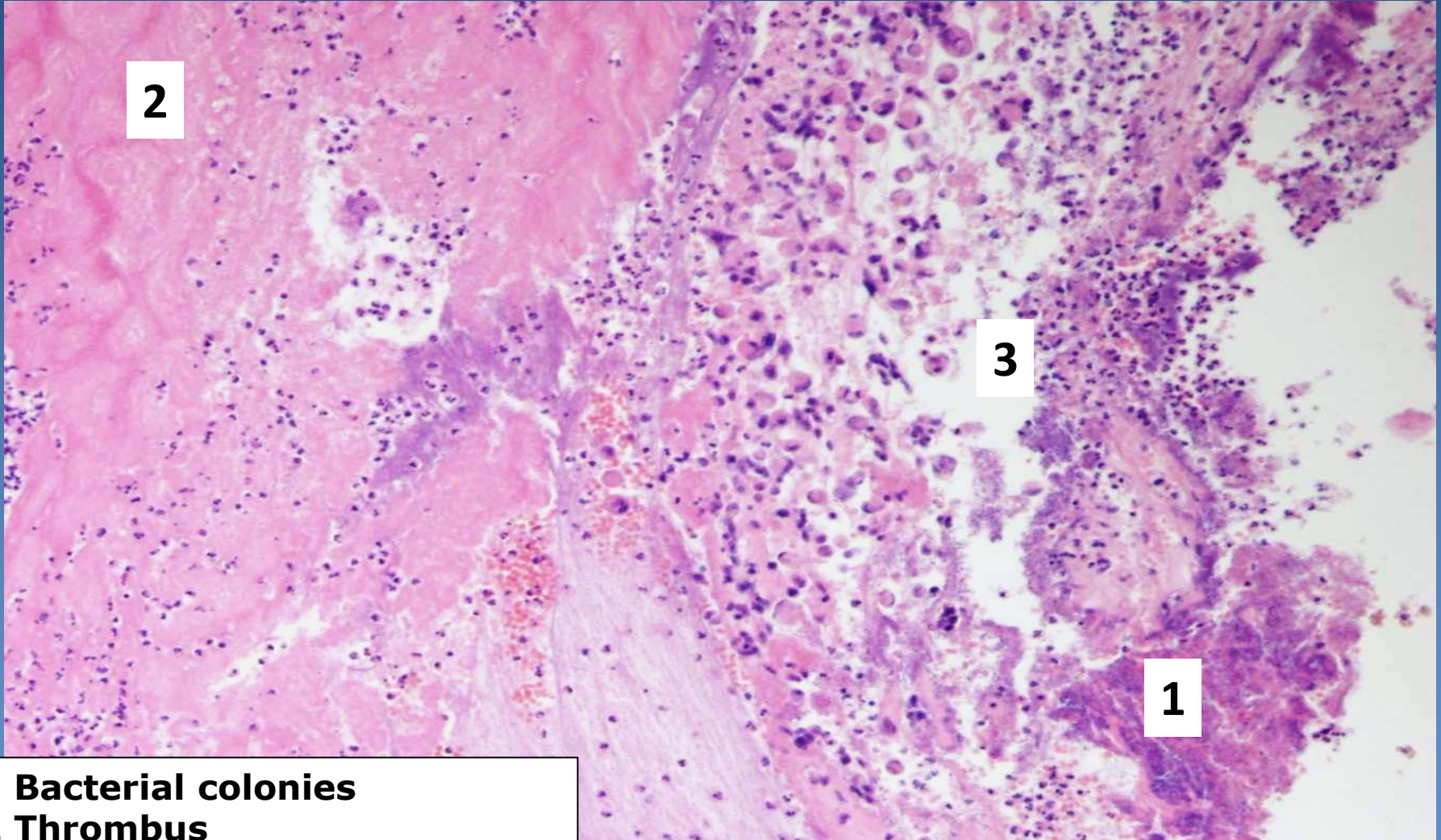
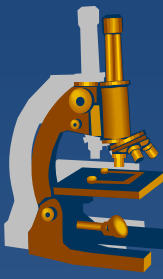


14. Dispersive myocardial myofibrosis



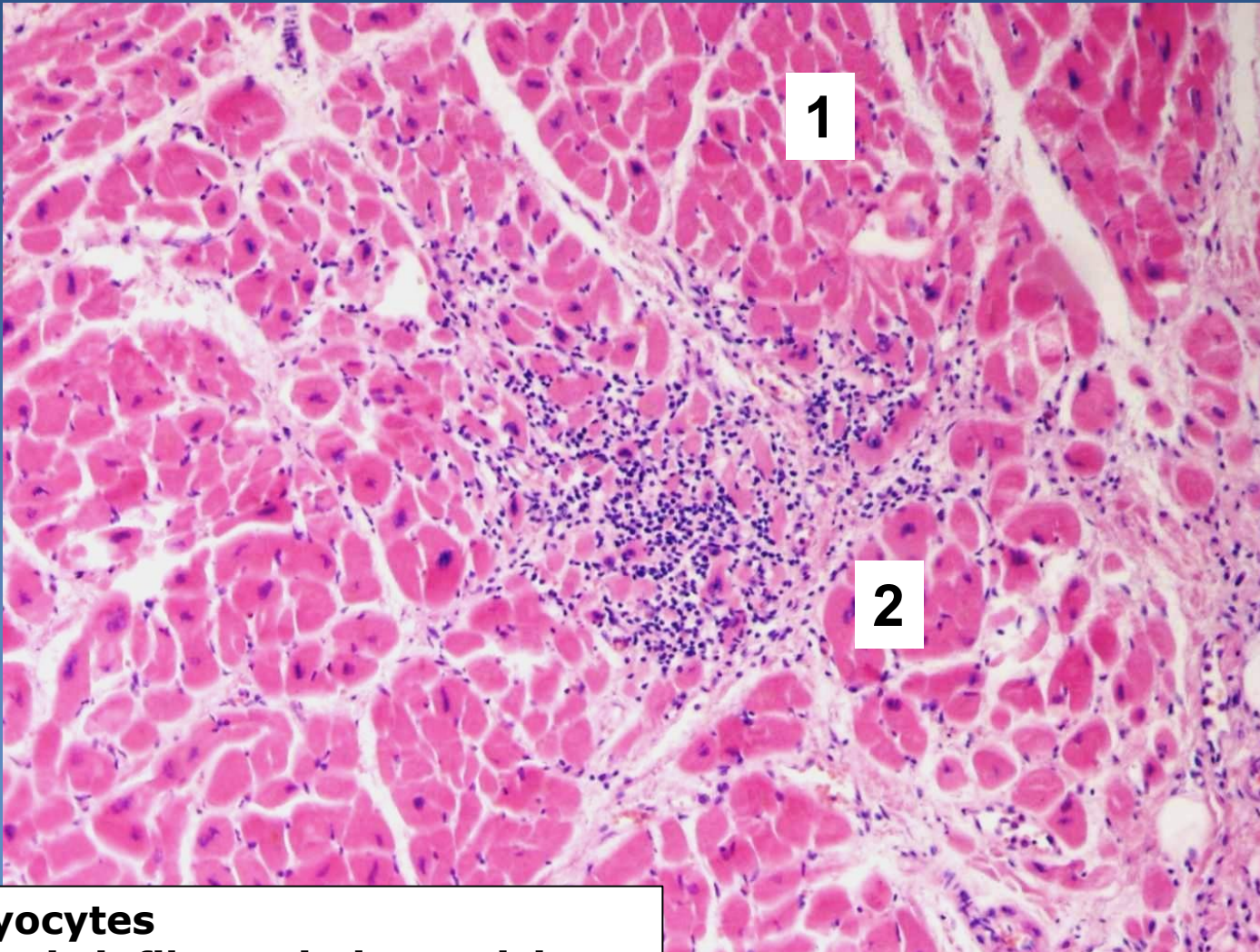
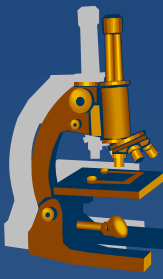
1 Myocardial replacement with low cellular collagen fibrosis
2 Hypertrophic cardiomyocytes

15. *Acute infective endocarditis*



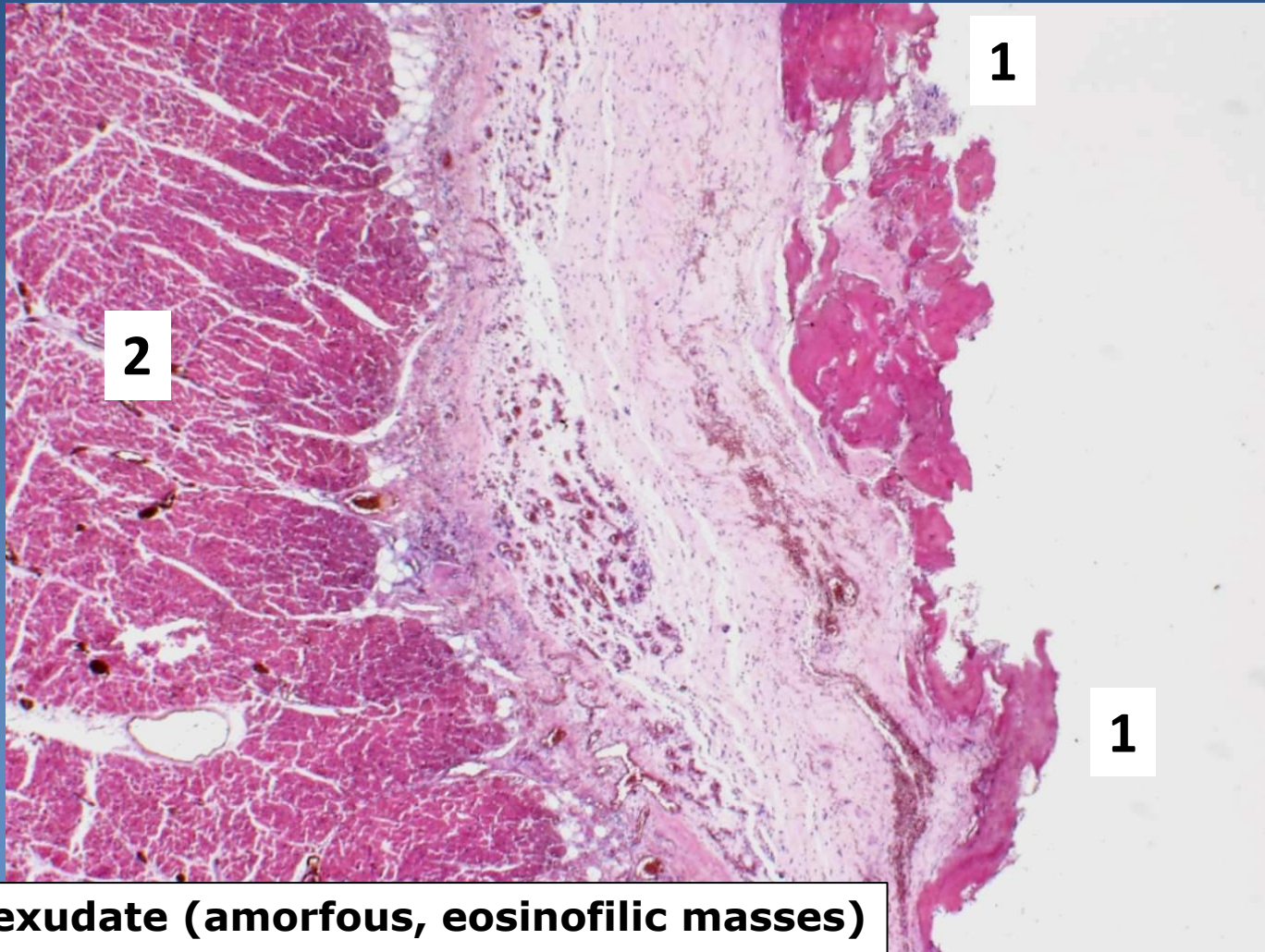
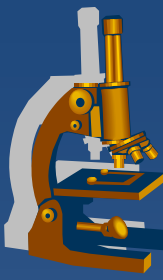
1 Bacterial colonies
2 Thrombus
3 inflammatory infiltrate

16. Viral myocarditis



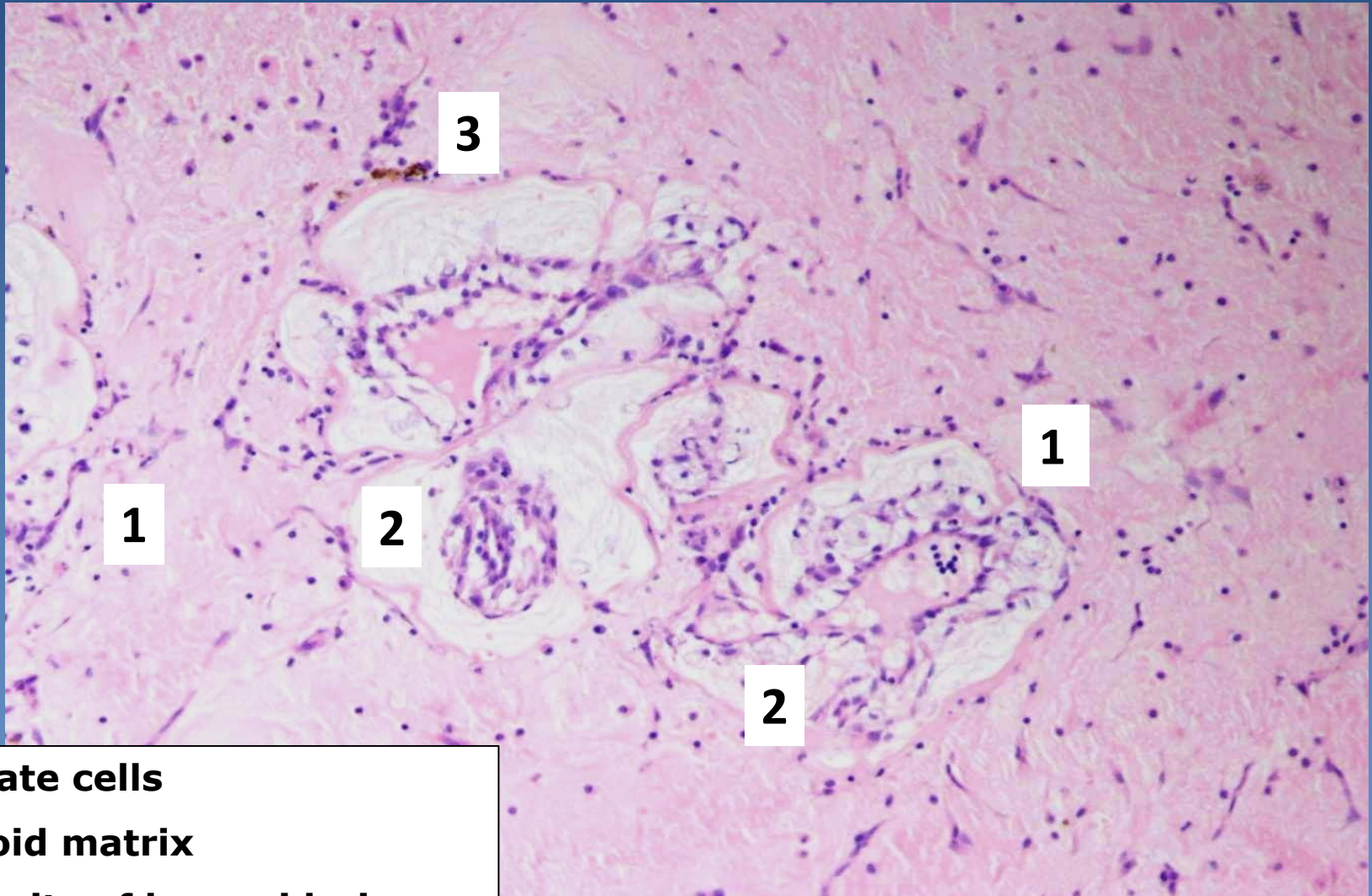
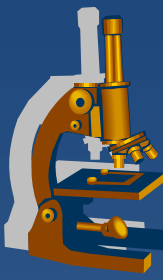
- 1 Cardiomyocytes**
- 2 Lymphocytic infiltrate in interstitium**

17. Fibrinous pericarditis



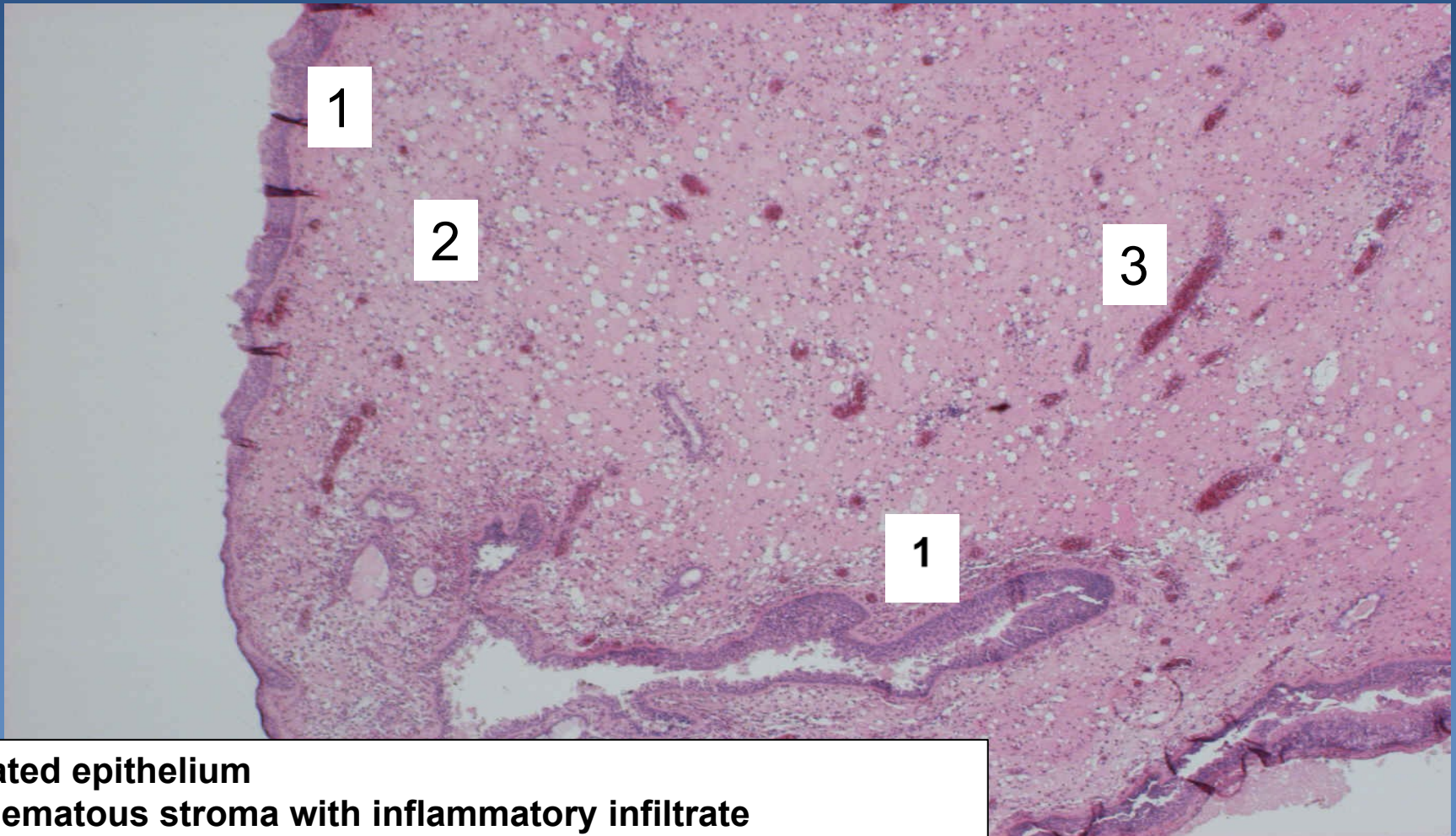
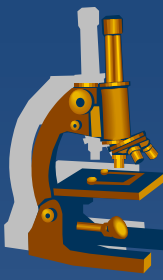
1 Fibrinous exudate (amorphous, eosinophilic masses)
2 Myocardium

18. Myxoma of the left atrium



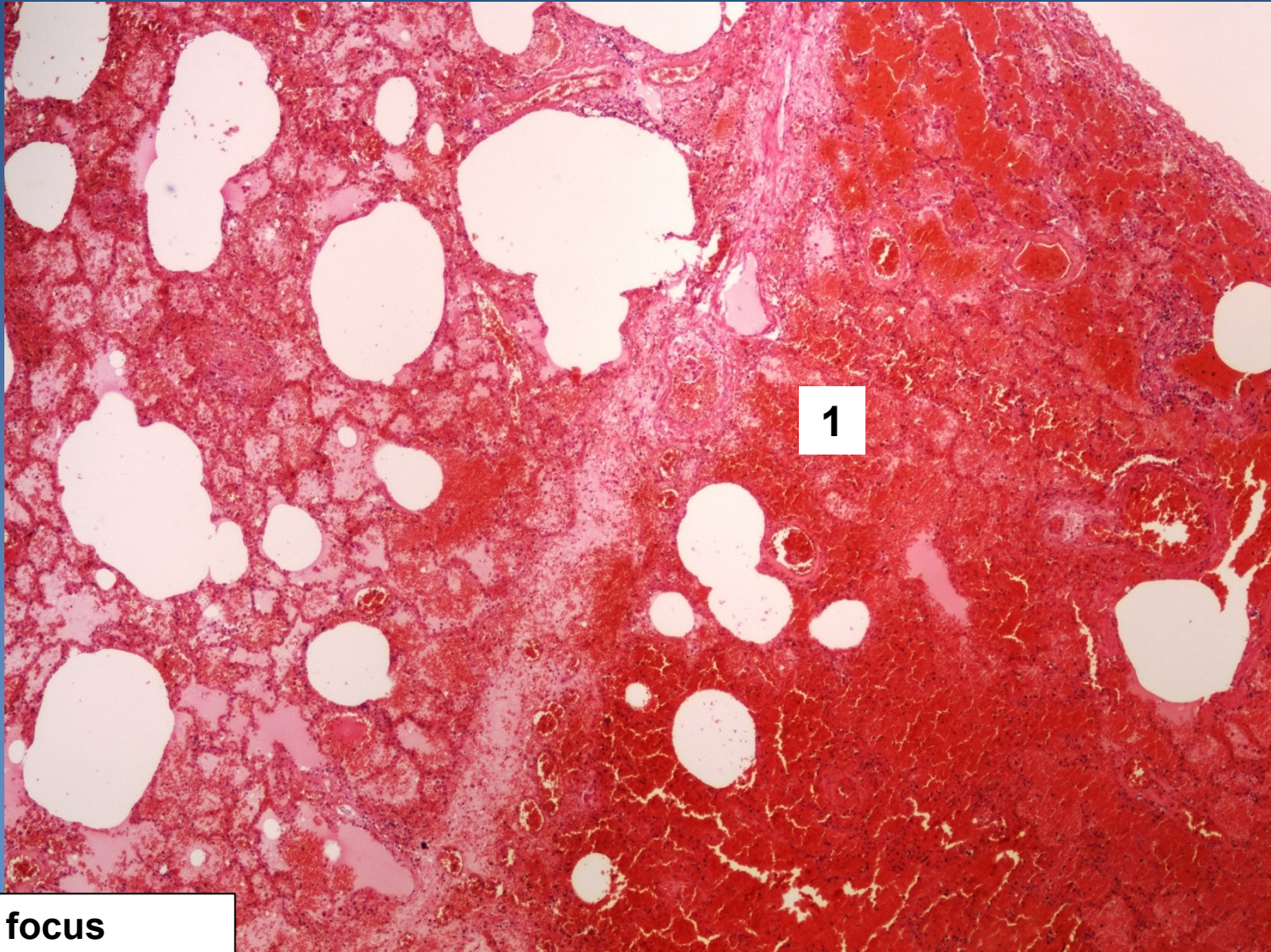
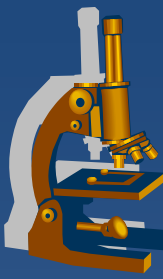
- 1 Stellate cells**
- 2 Myxoid matrix**
- 3 Deposits of hemosiderin**

19. *Polypous chronic rhinitis*



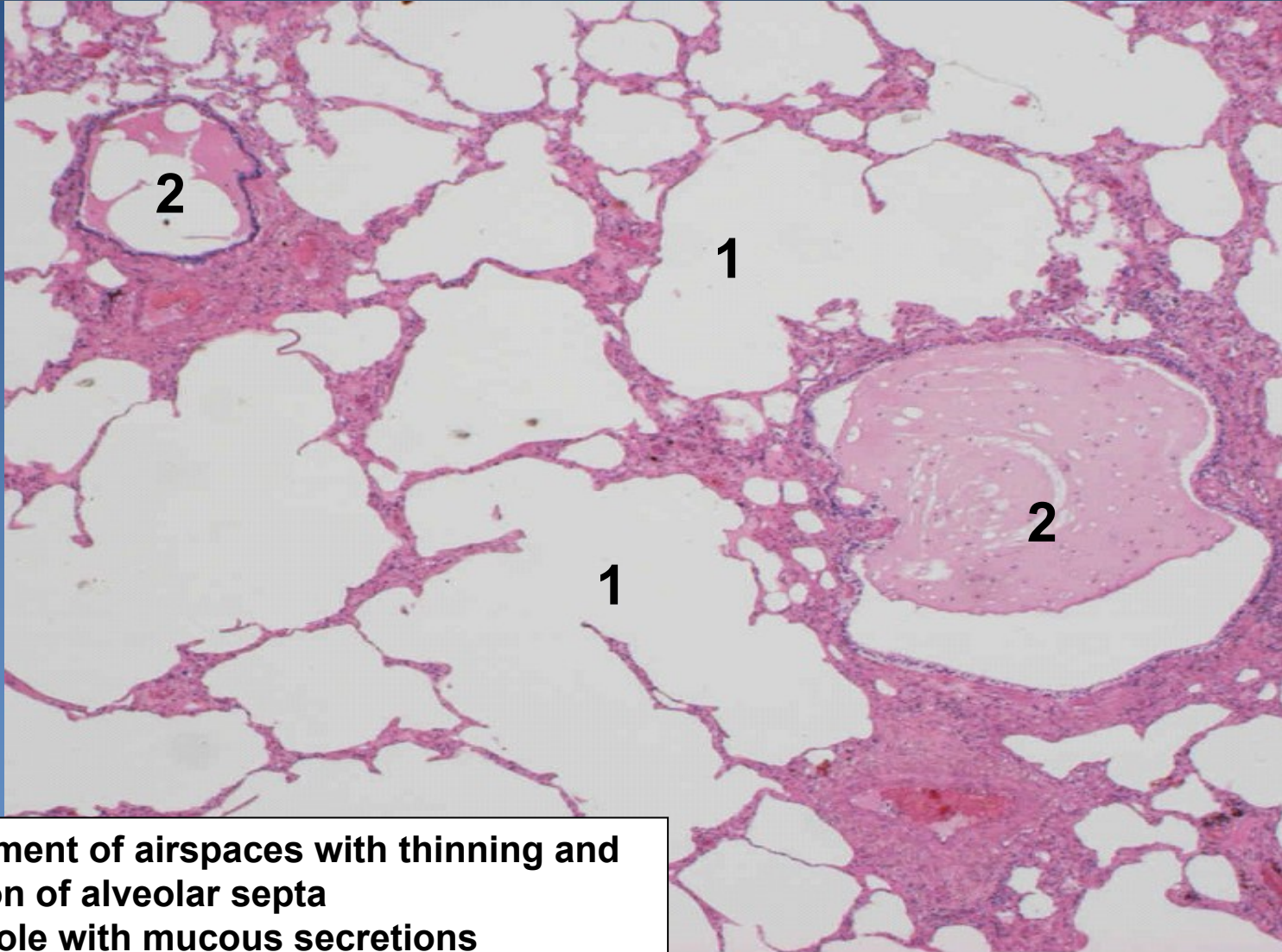
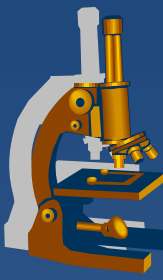
- 1 Ciliated epithelium
- 2 Oedematous stroma with inflammatory infiltrate
- 3 Capillary

20. Hemorrhagic pulmonary infarction



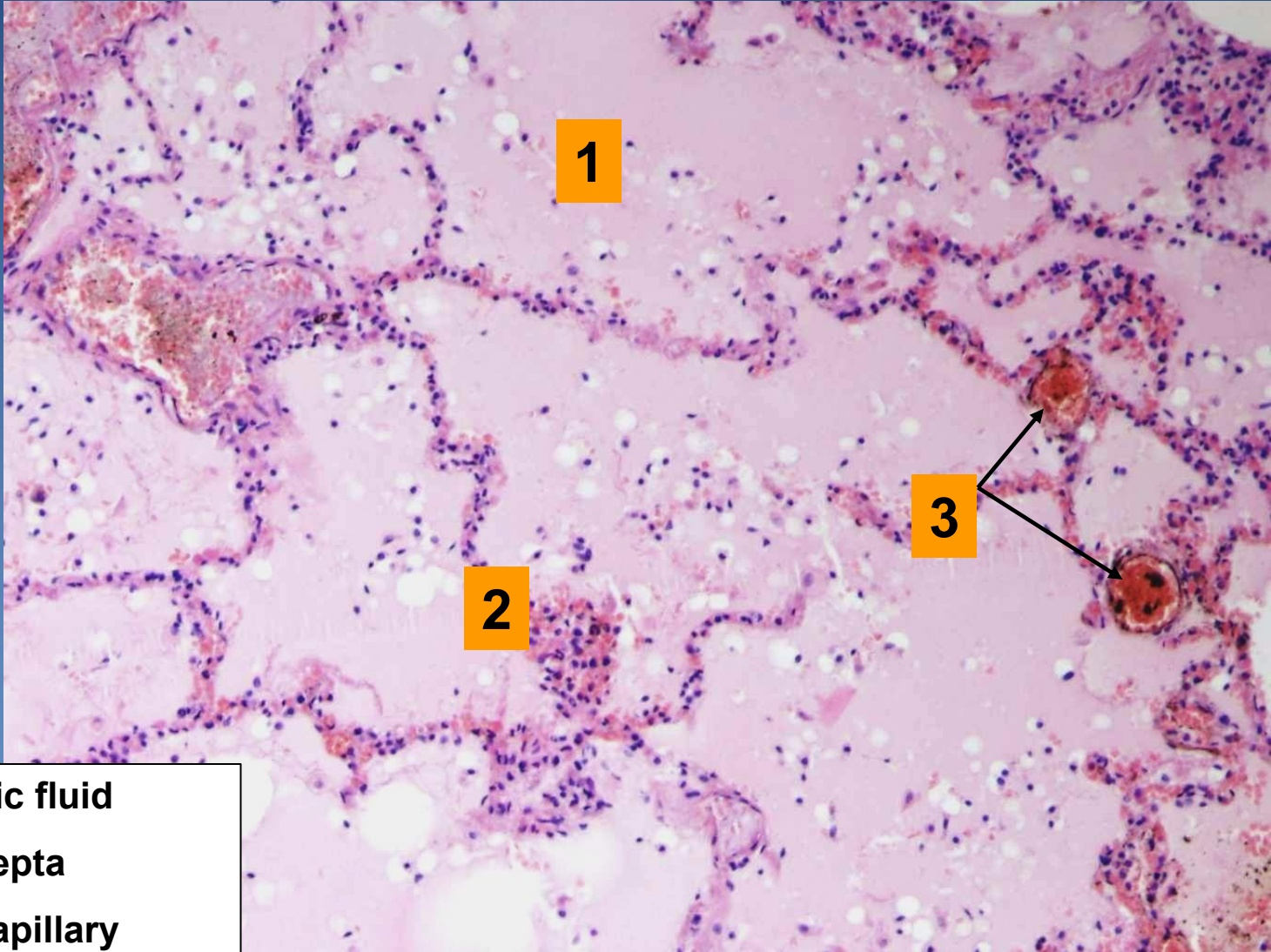
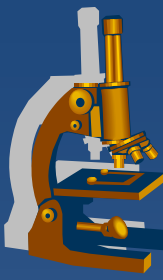
1 Necrotic focus

21. Alveolar emphysema



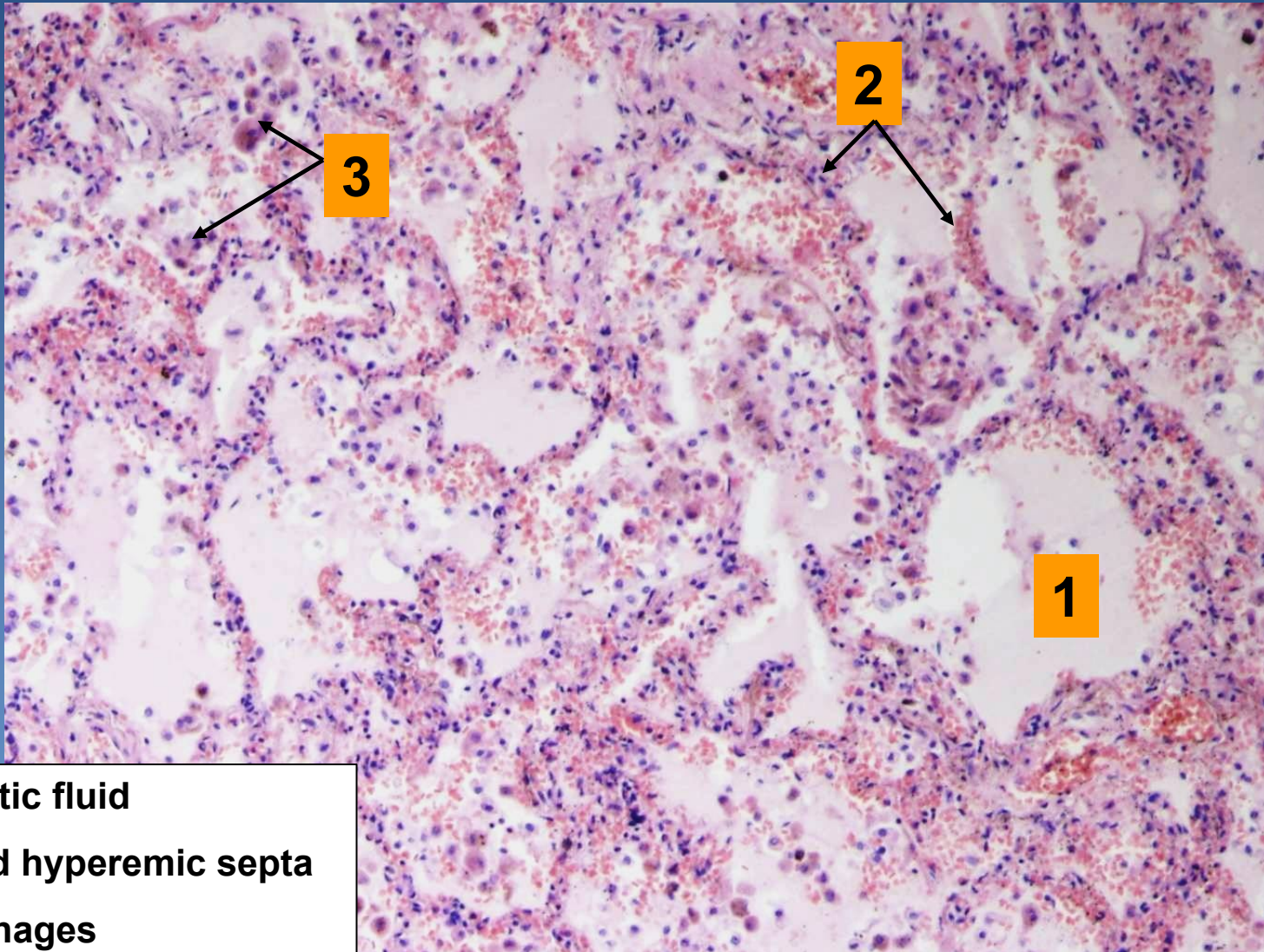
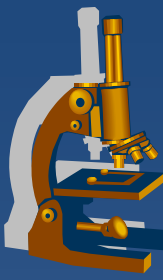
- 1 Enlargement of airspaces with thinning and destruction of alveolar septa
- 2 Bronchiole with mucous secretions

22. Alveolar oedema



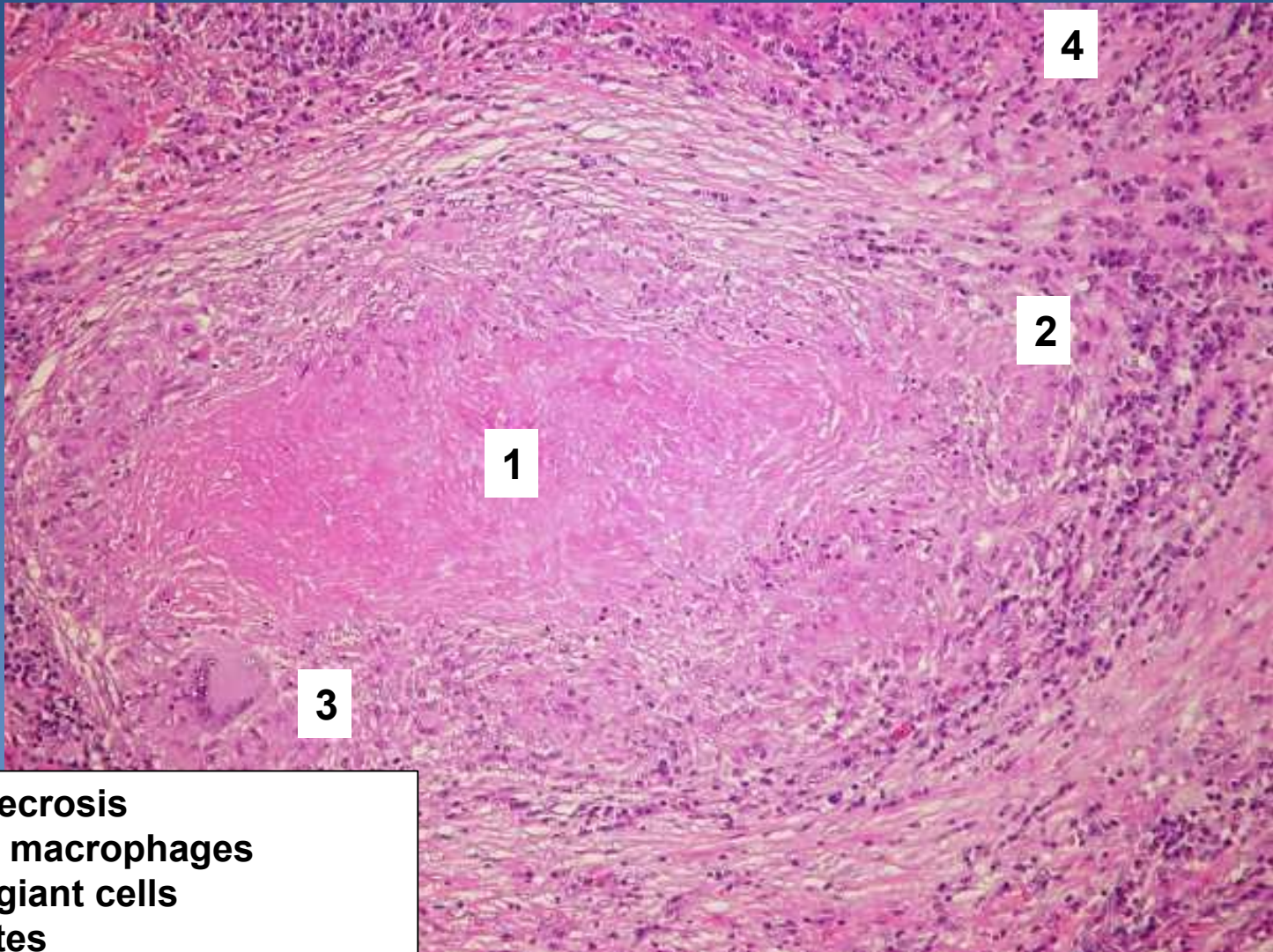
- 1 Oedematic fluid
- 2 Dilated septa
- 3 Dilated capillary

23. Chronic pulmonary venous congestion



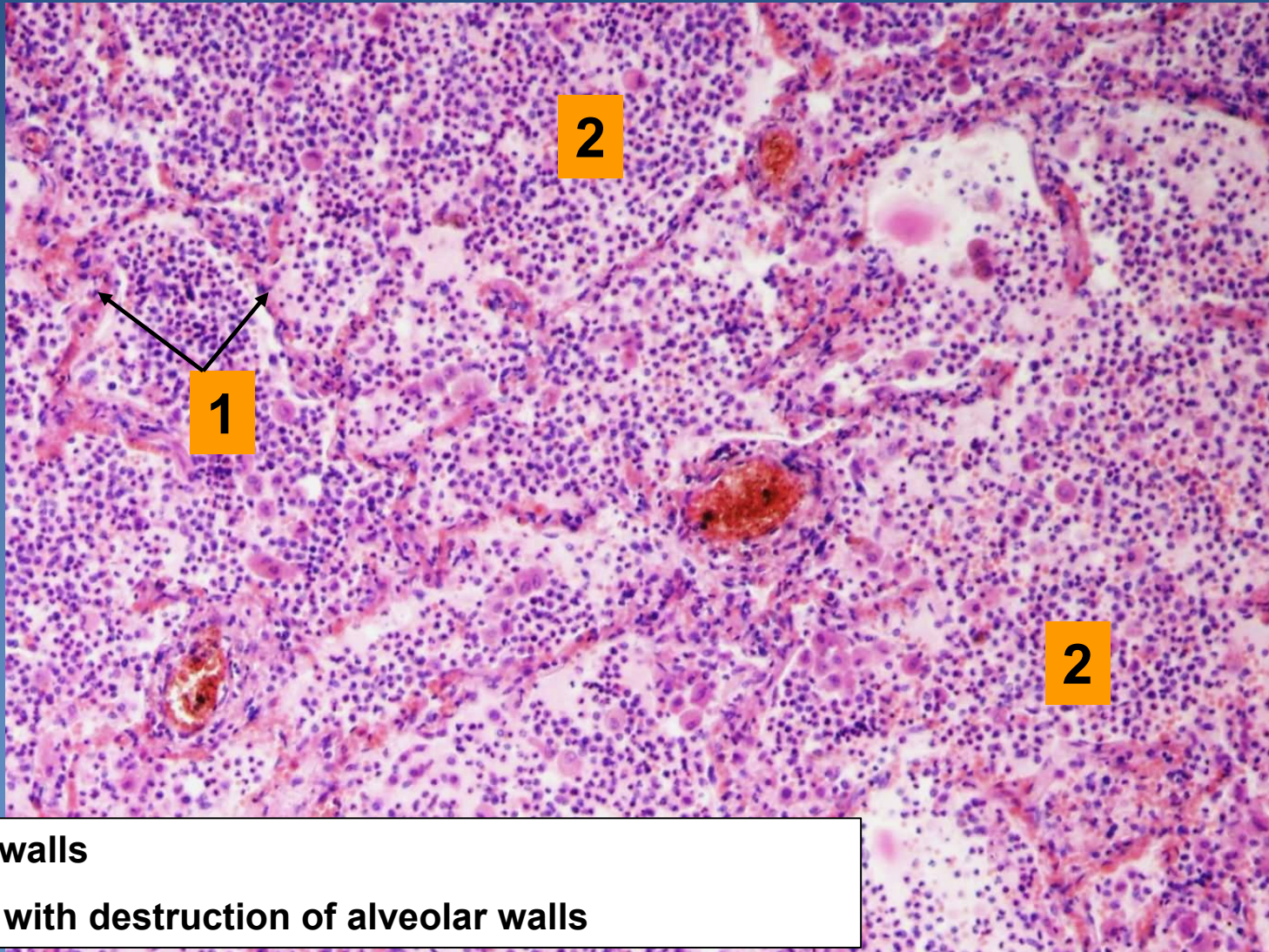
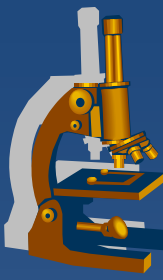
- 1 Oedematic fluid
- 2 Enlarged hyperemic septa
- 3 Siderophages

24. TBC granuloma of lungs



- 1 Caseous necrosis
- 2 Epithelioid macrophages
- 3 Langhans giant cells
- 4 Lymphocytes

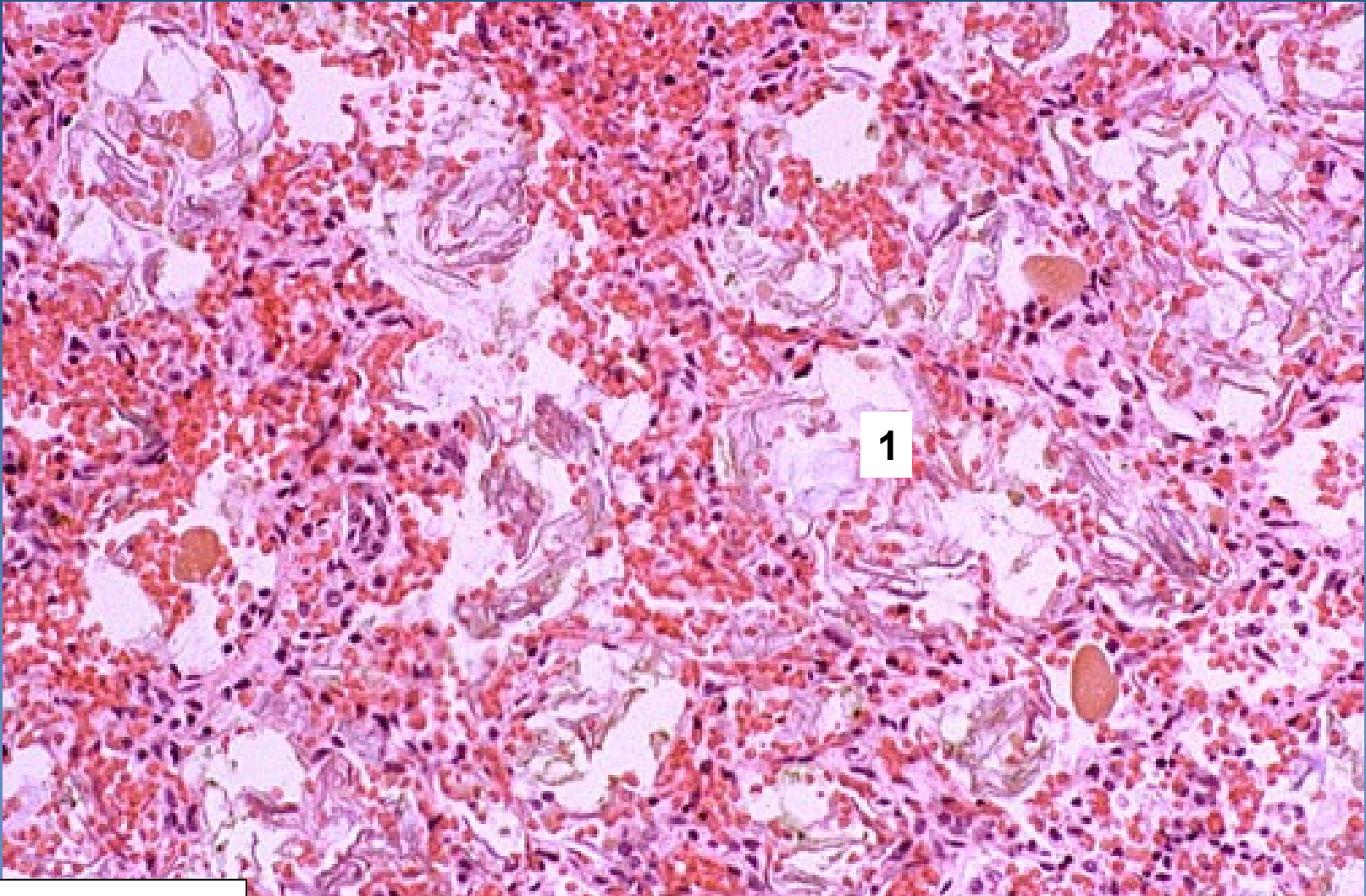
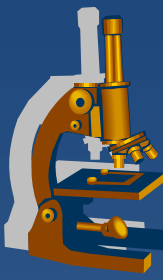
25. Purulent (abscessing) bronchopneumonia



1 Alveolar walls

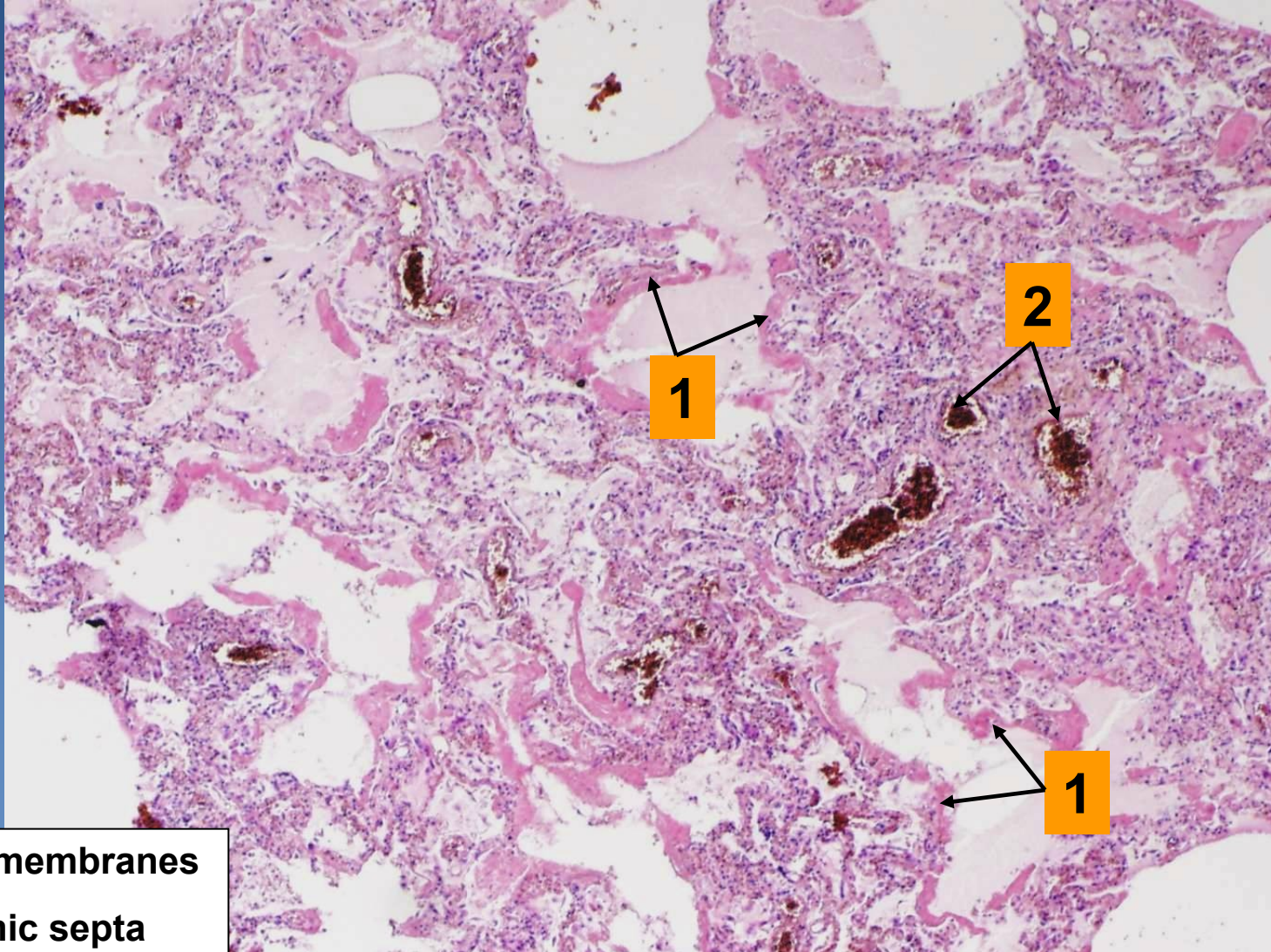
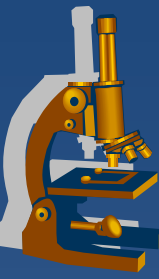
2 Abscess with destruction of alveolar walls

26. Amniotic fluid aspiration



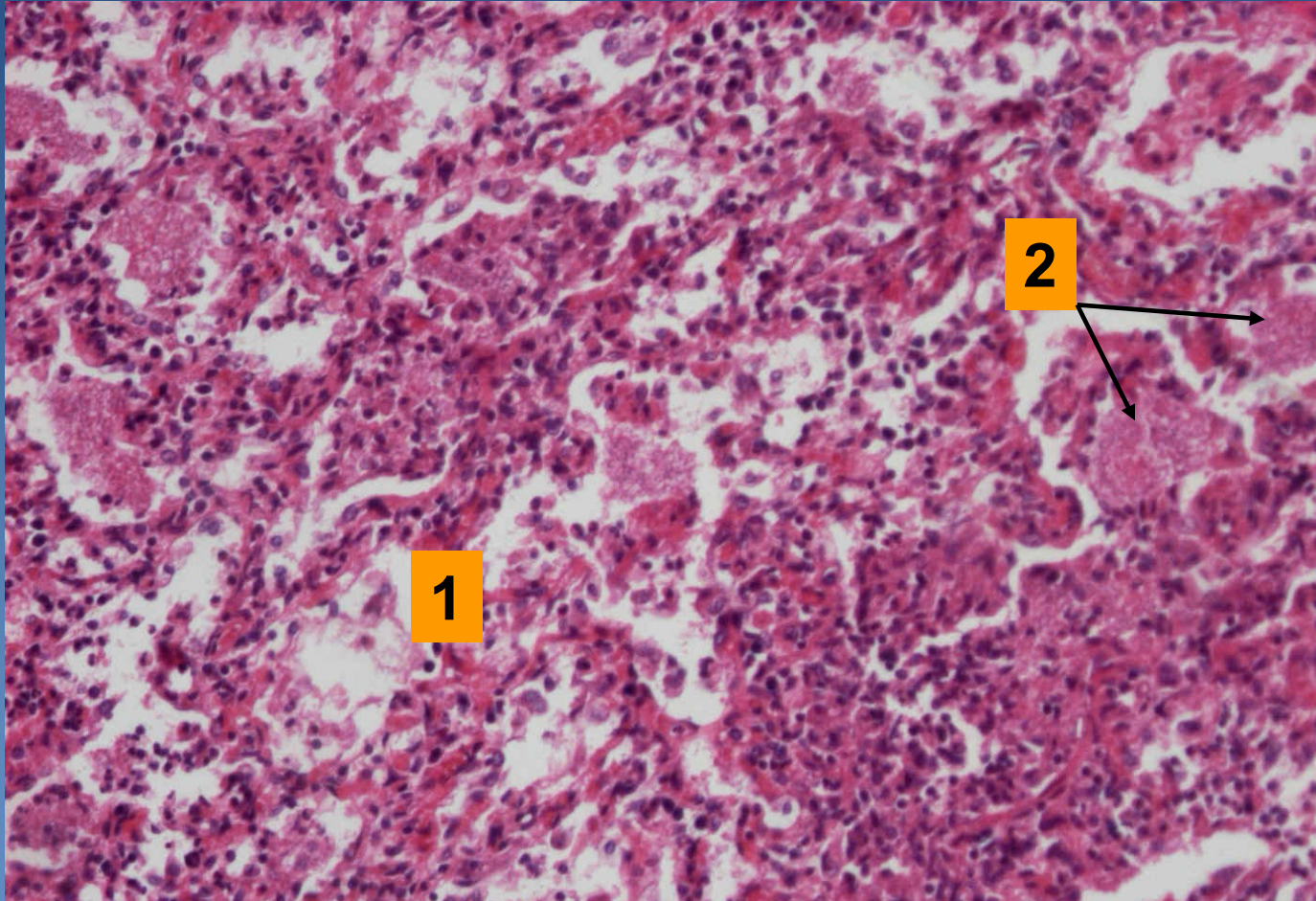
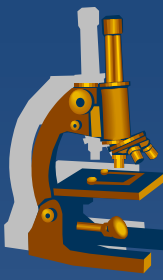
1 Masses of keratin

27. Diffuse alveolar damage (DAD/ARDS)



1 Hyaline membranes
2 Hyperemic septa

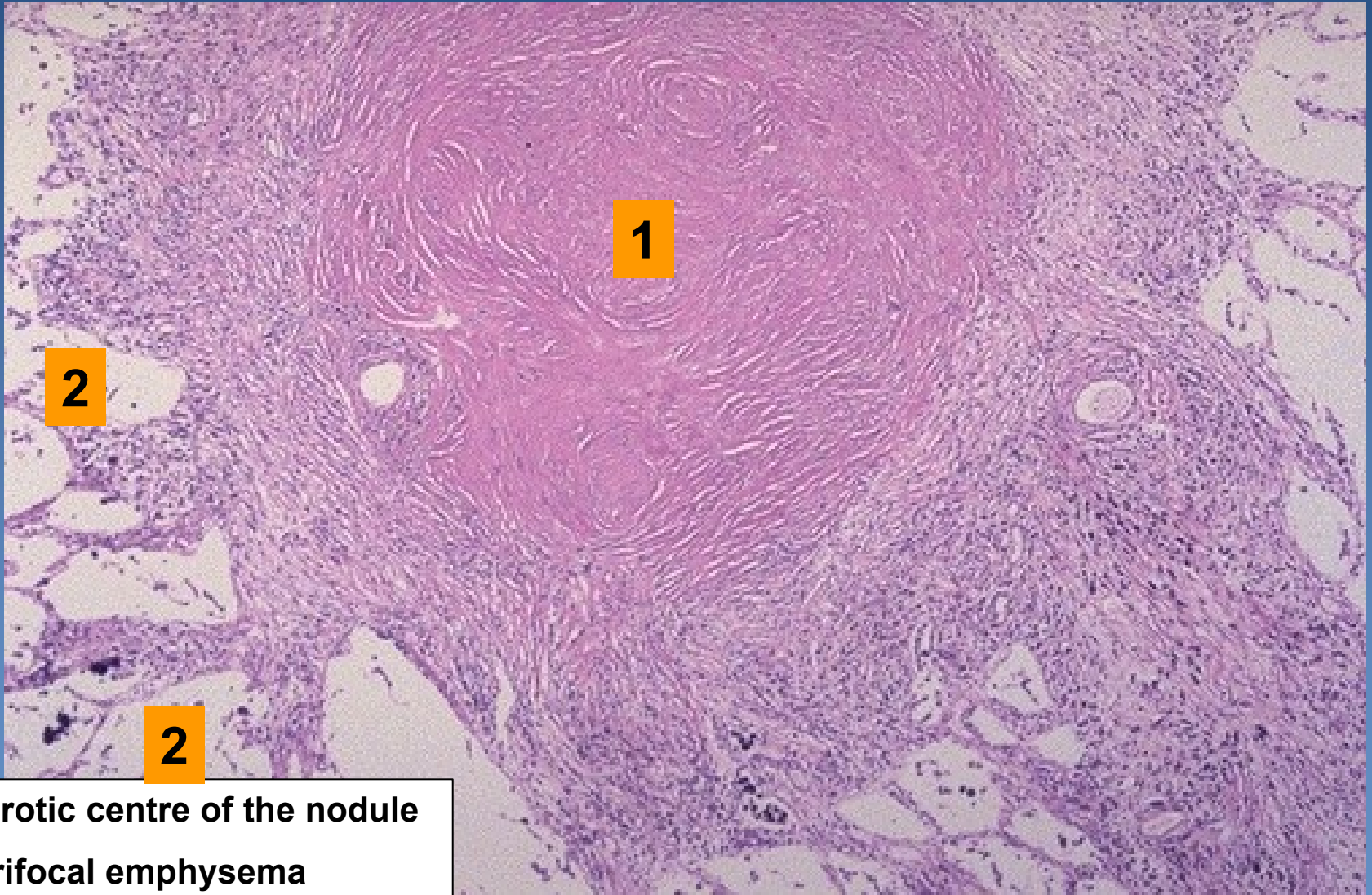
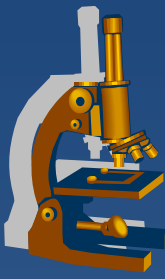28. *Pneumocystis pneumonia*



1 Alveolar walls filled with monocellular infiltration

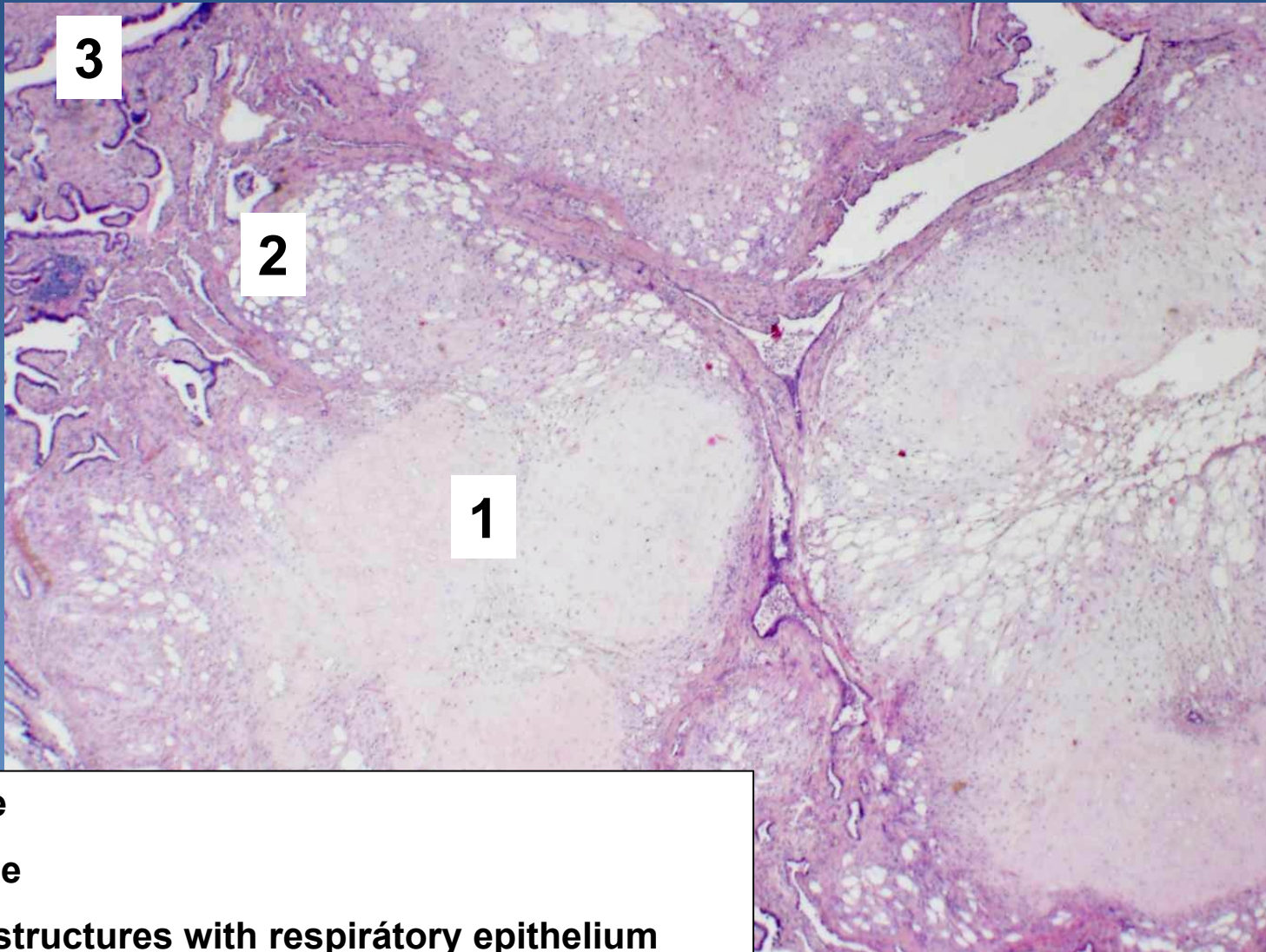
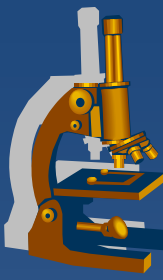
2 Bubbly eosinophilic material

29. Silicosis of lungs



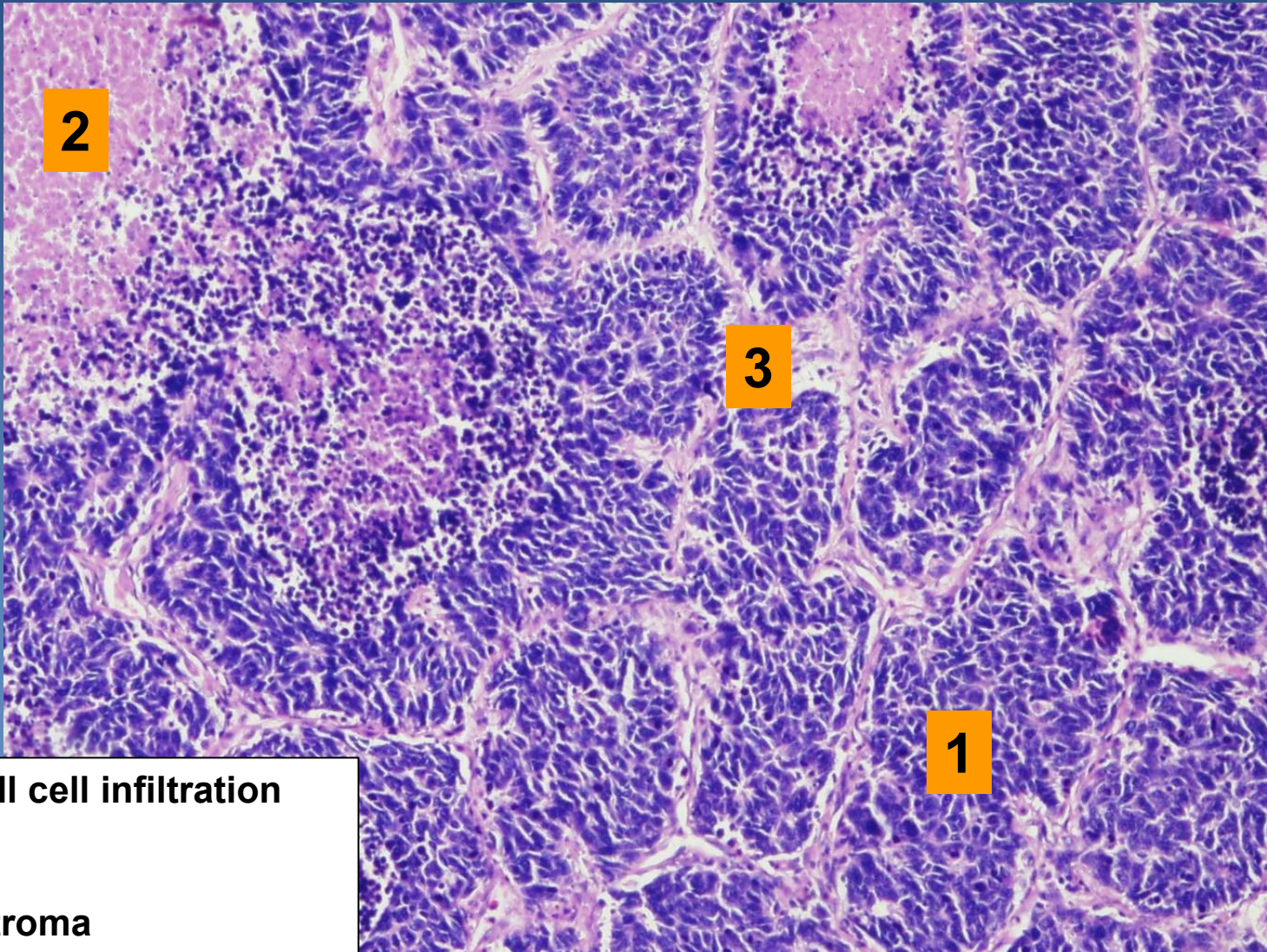
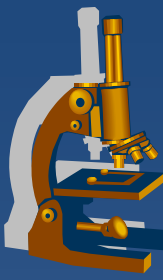
- 1 Fibrotic centre of the nodule
- 2 Perifocal emphysema

30. Pulmonary chondrohamartoma



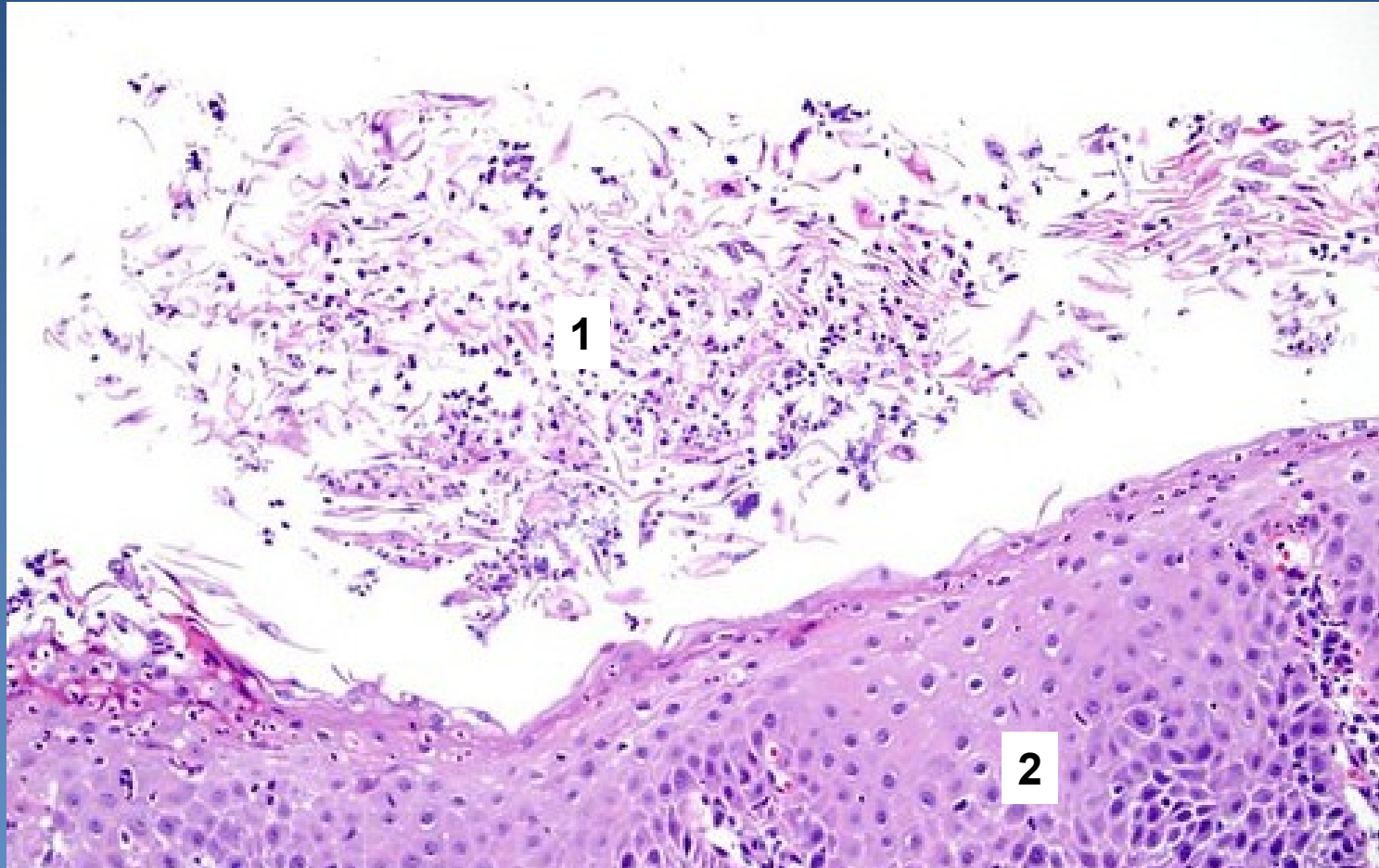
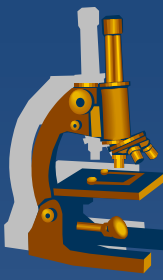
- 1 Cartilage
- 2 Fat tissue
- 3 Tubular structures with respiratory epithelium

31. *Small-cell lung carcinoma*



- 1 Solid small cell infiltration
- 2 Necrosis
- 3 Fibrous stroma

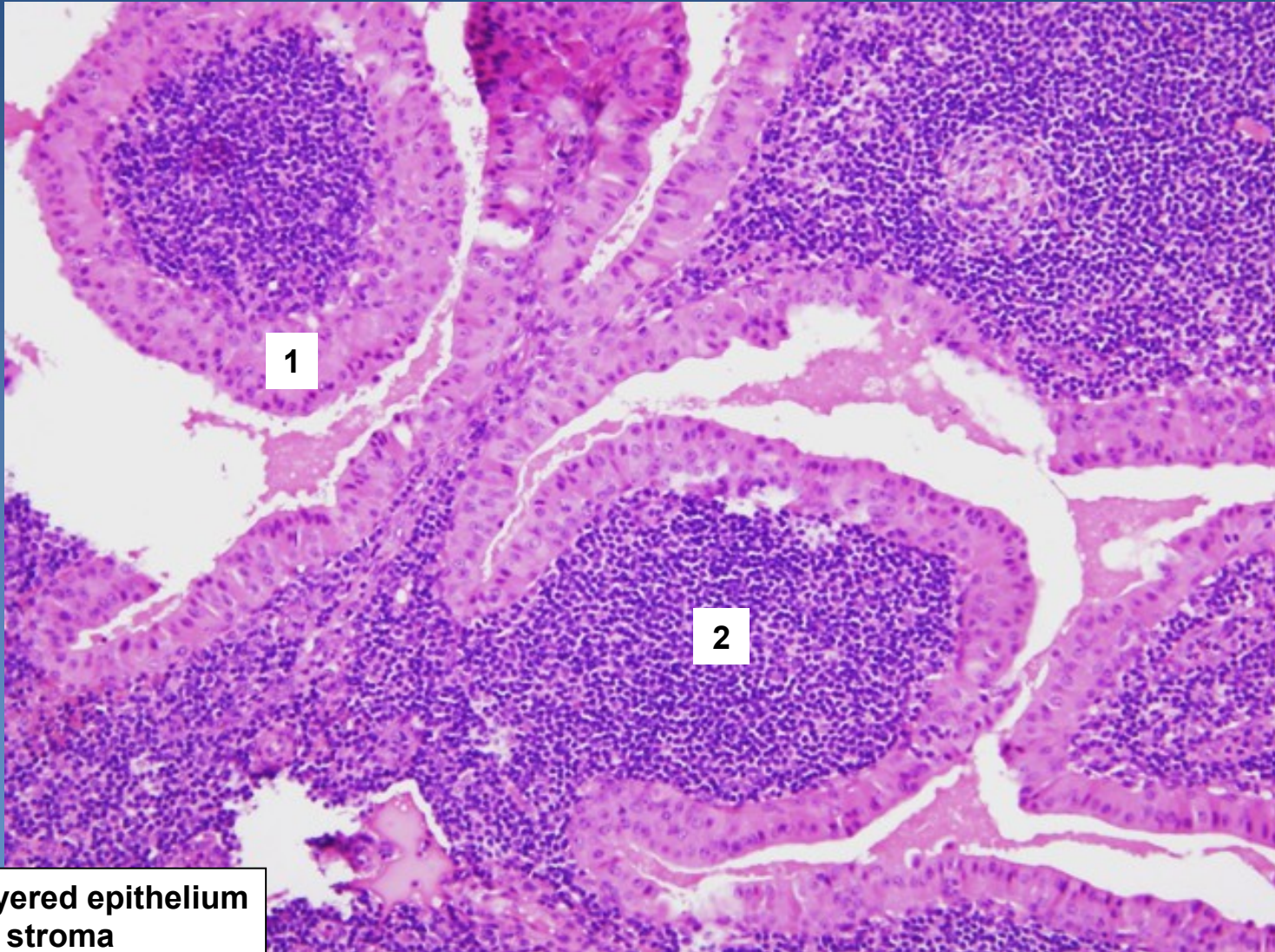
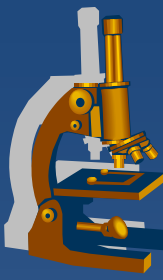
32. Mycotic oesophagitis



1 Superficial necrotic mucosa (mixed inflammatory infiltrate with a fungal hyphae)

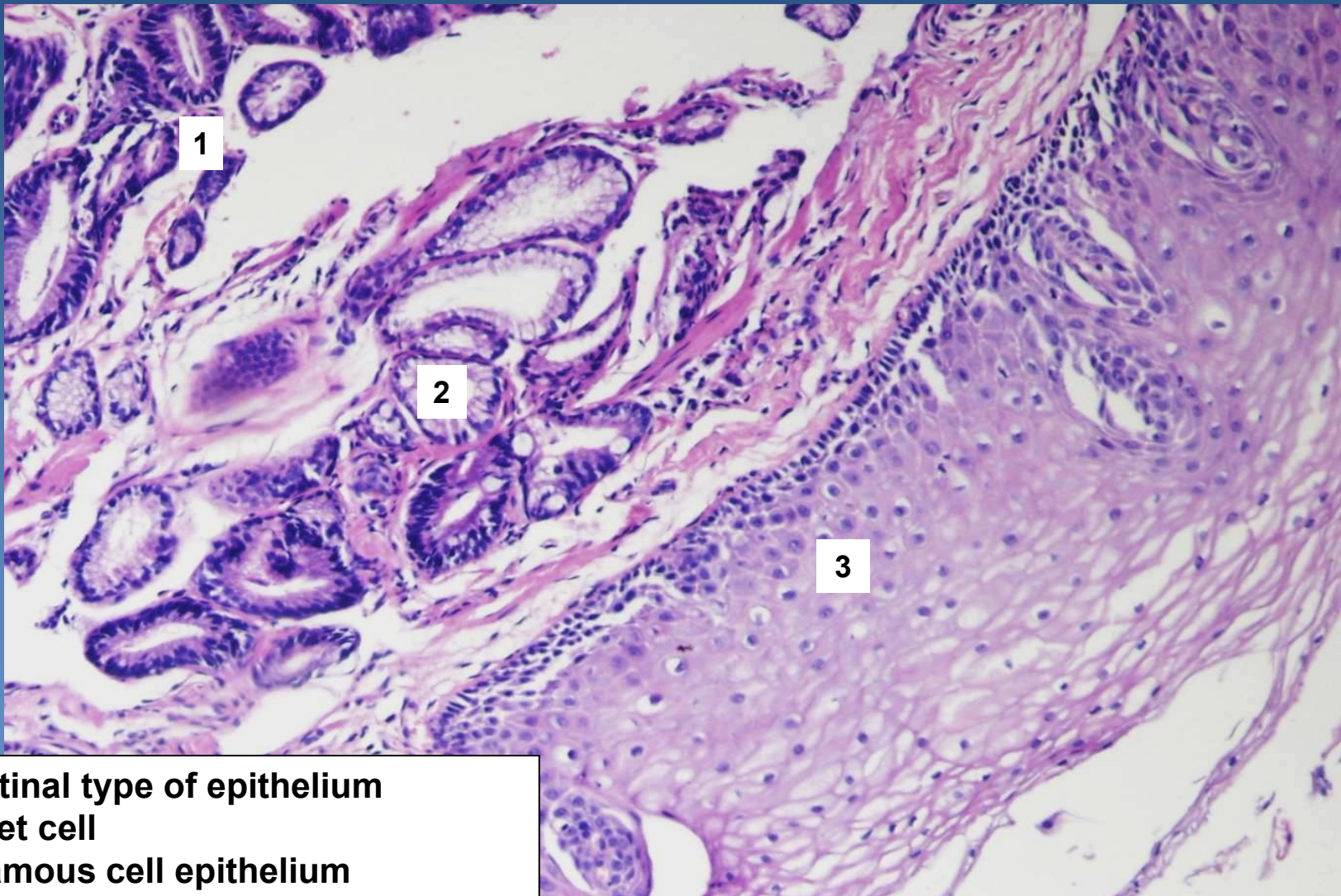
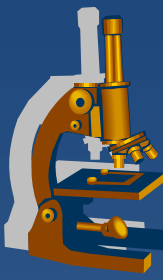
2 Squamous epithelium of the esophagus

33. Warthin's tumor (cystadenolymphoma)



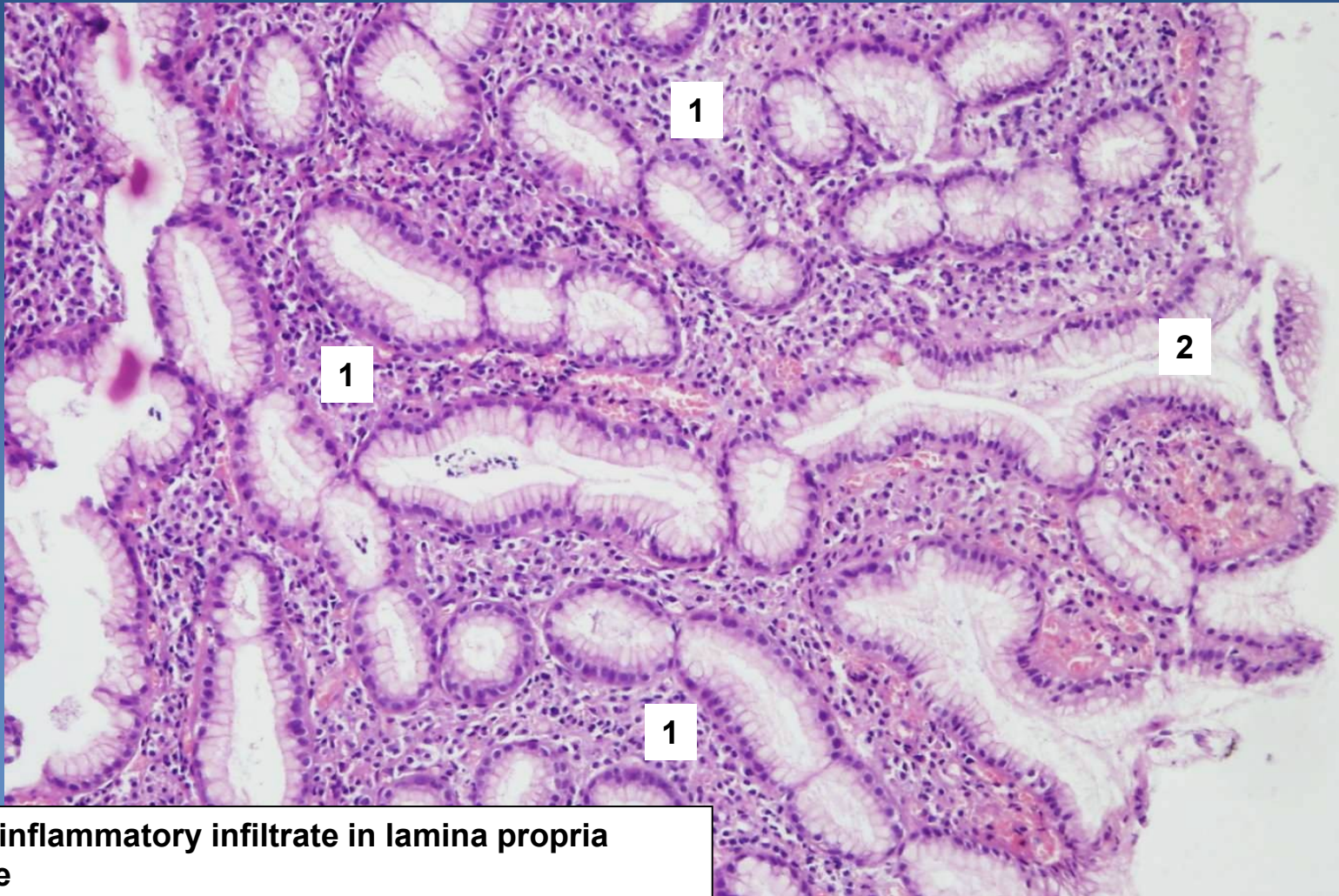
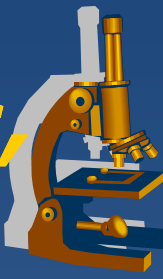1 Double-layered epithelium
2 Lymphoid stroma

34. Barrett's oesophagus



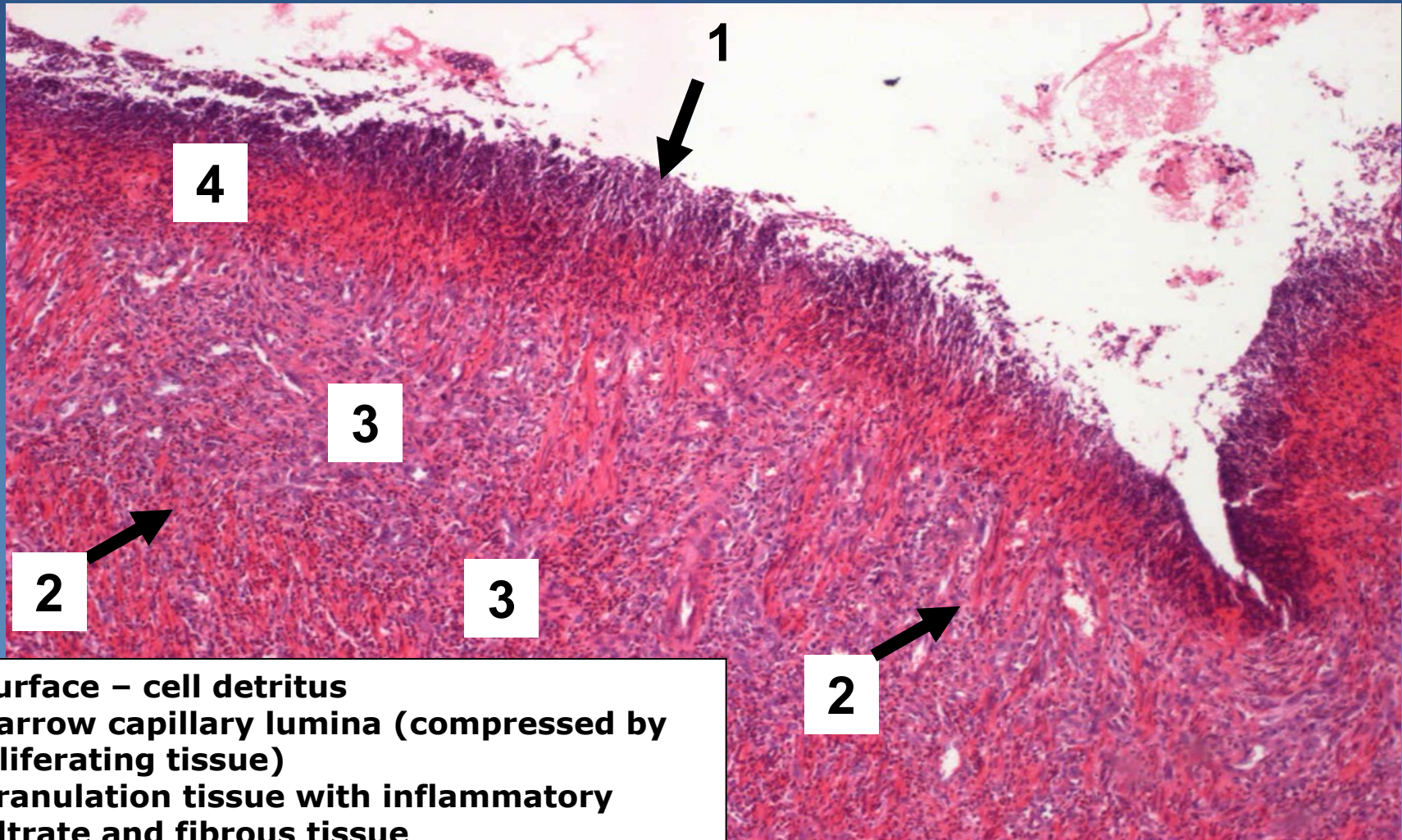
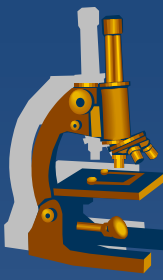
1 Intestinal type of epithelium
2 Goblet cell
3 Squamous cell epithelium

35. Chronic non-atrophic gastritis, associated with HP



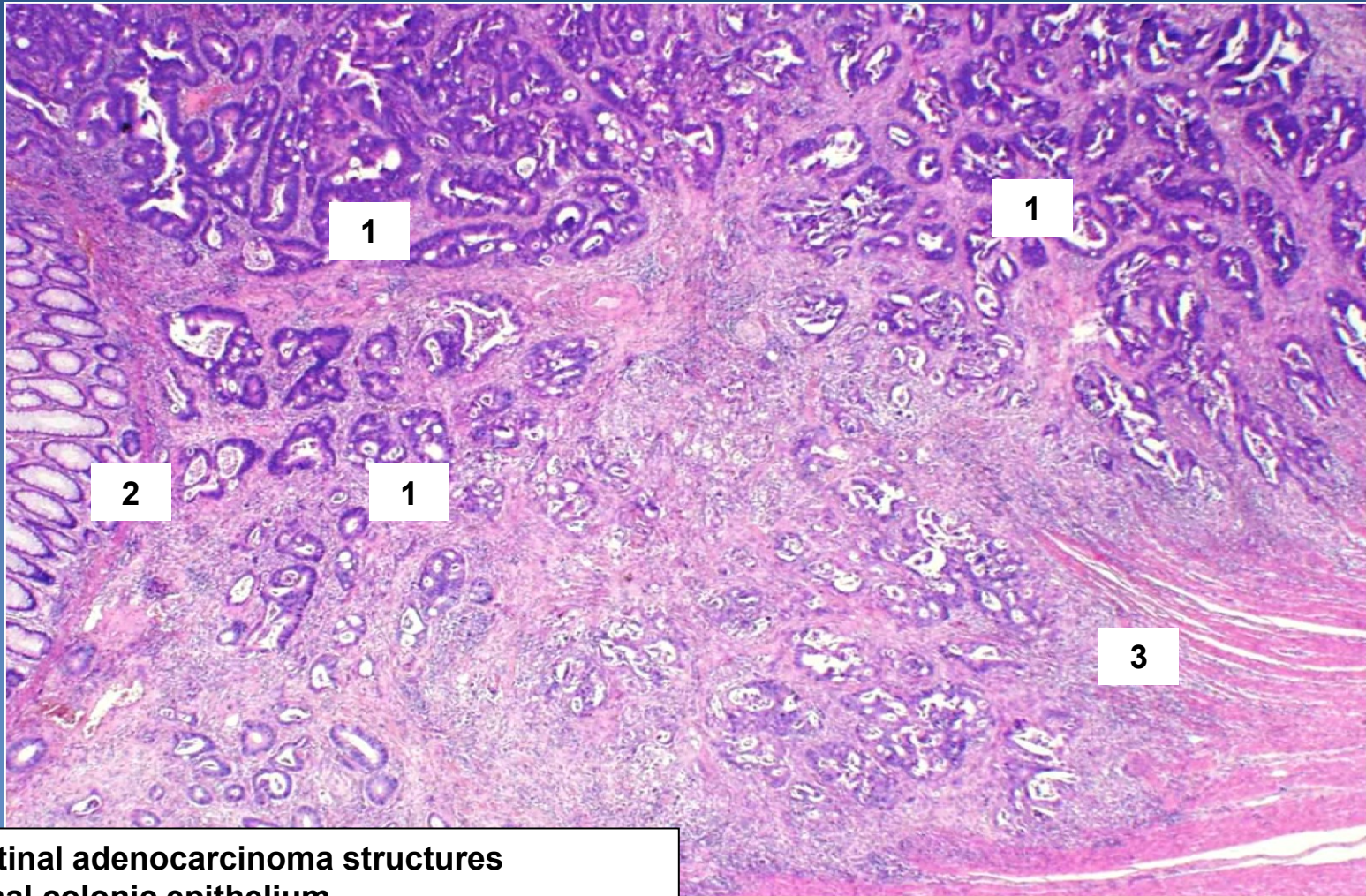
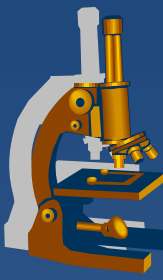
1 Mixed inflammatory infiltrate in lamina propria mucosae
2 Gastric pit

36. Chronic peptic ulcer of the stomach



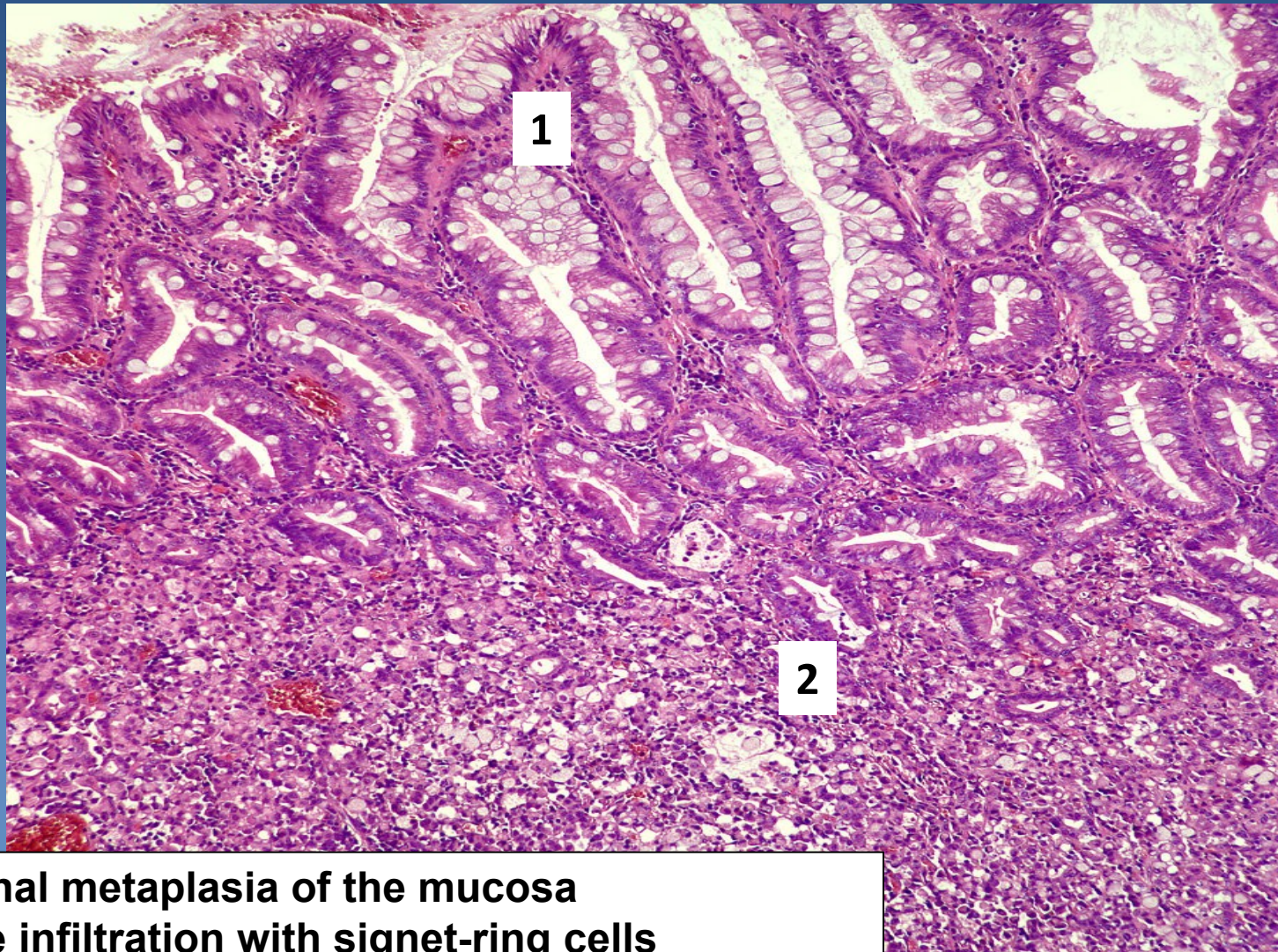
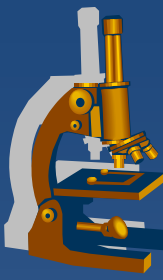
1 surface - cell detritus
2 narrow capillary lumina (compressed by proliferating tissue)
3 granulation tissue with inflammatory infiltrate and fibrous tissue
4 fibrinoid necrosis

37. Adenocarcinoma of the colon (intestinal type)



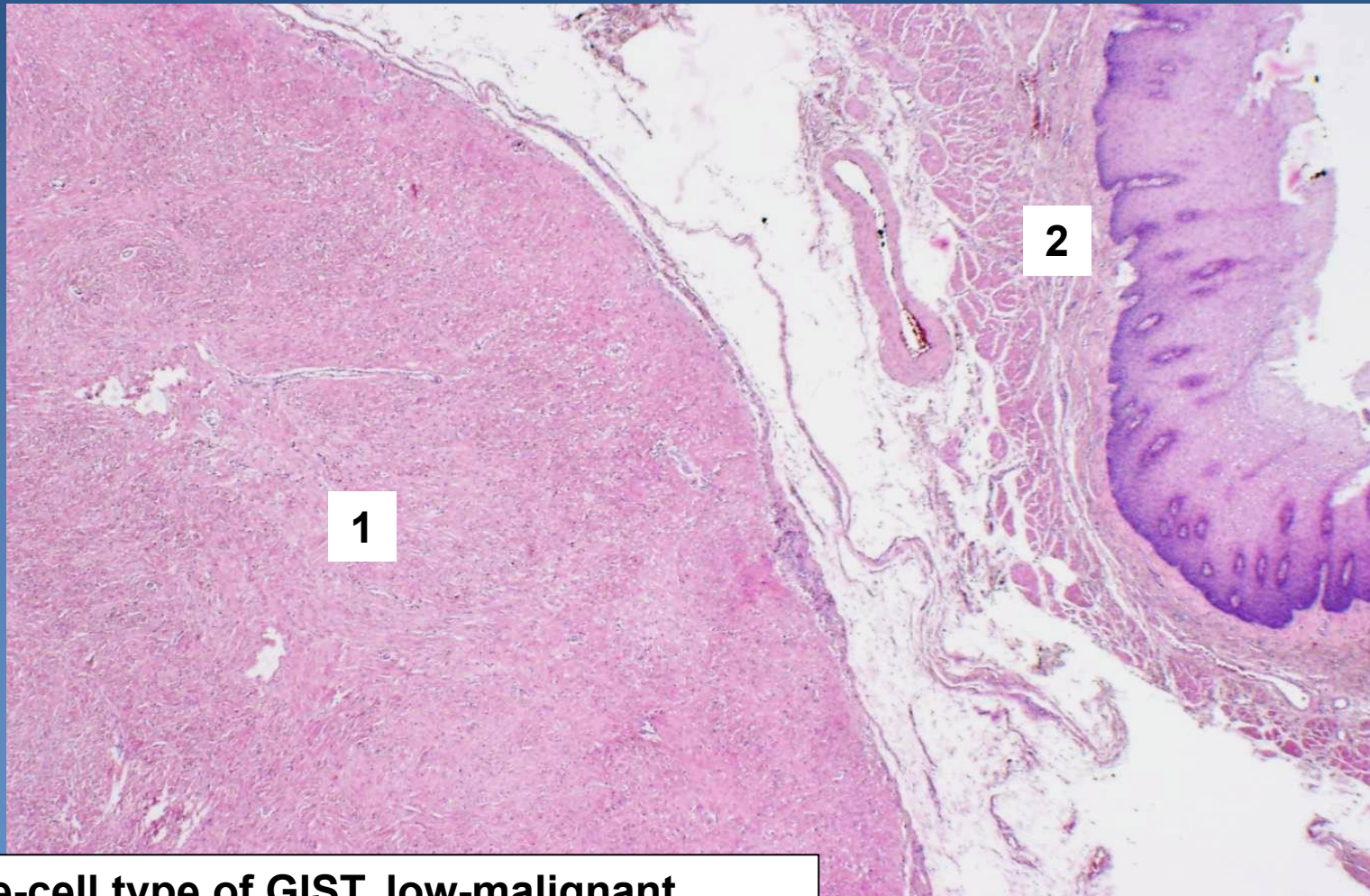
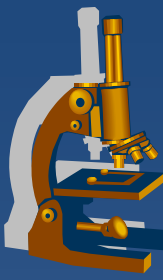
- 1 Intestinal adenocarcinoma structures
- 2 Normal colonic epithelium
- 3 Muscularis propria

38. Gastric adenocarcinoma (diffuse type)



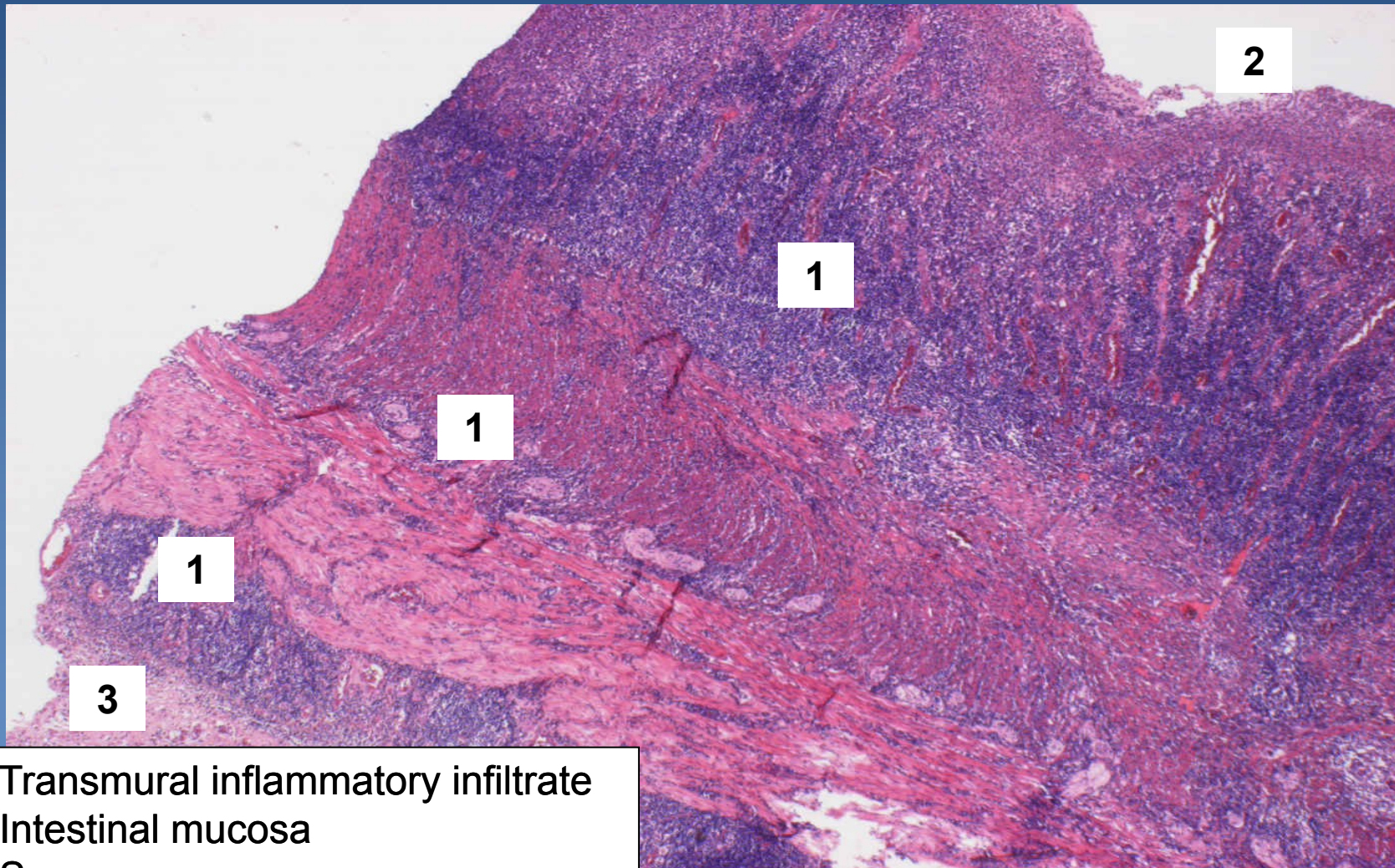
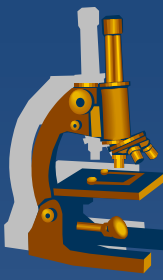
- 1 Intestinal metaplasia of the mucosa
- 2 Diffuse infiltration with signet-ring cells

39. GIST



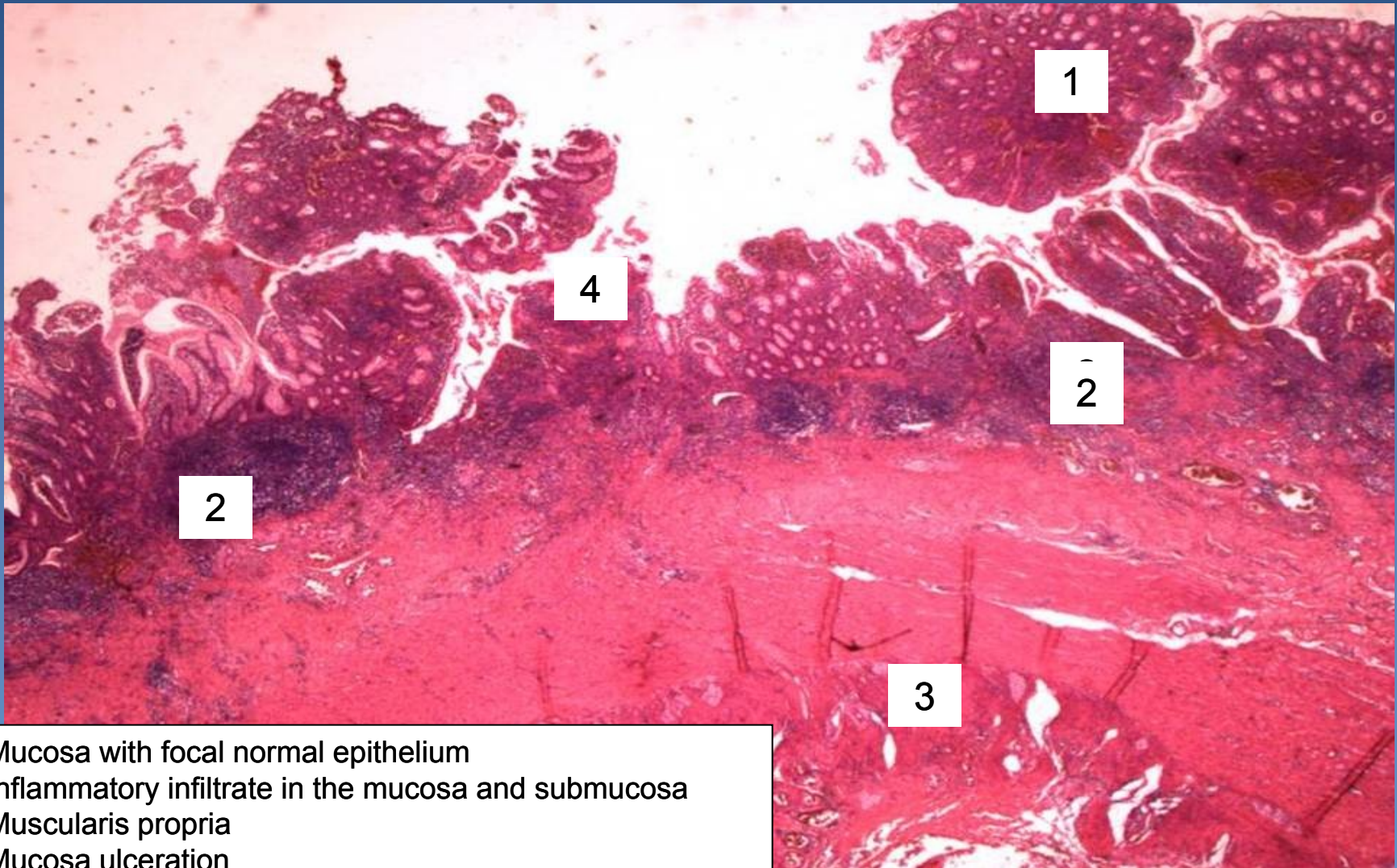
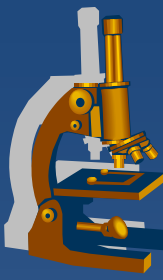
1 Spindle-cell type of GIST, low-malignant
2 Oesophageal wall

40. Crohn's disease



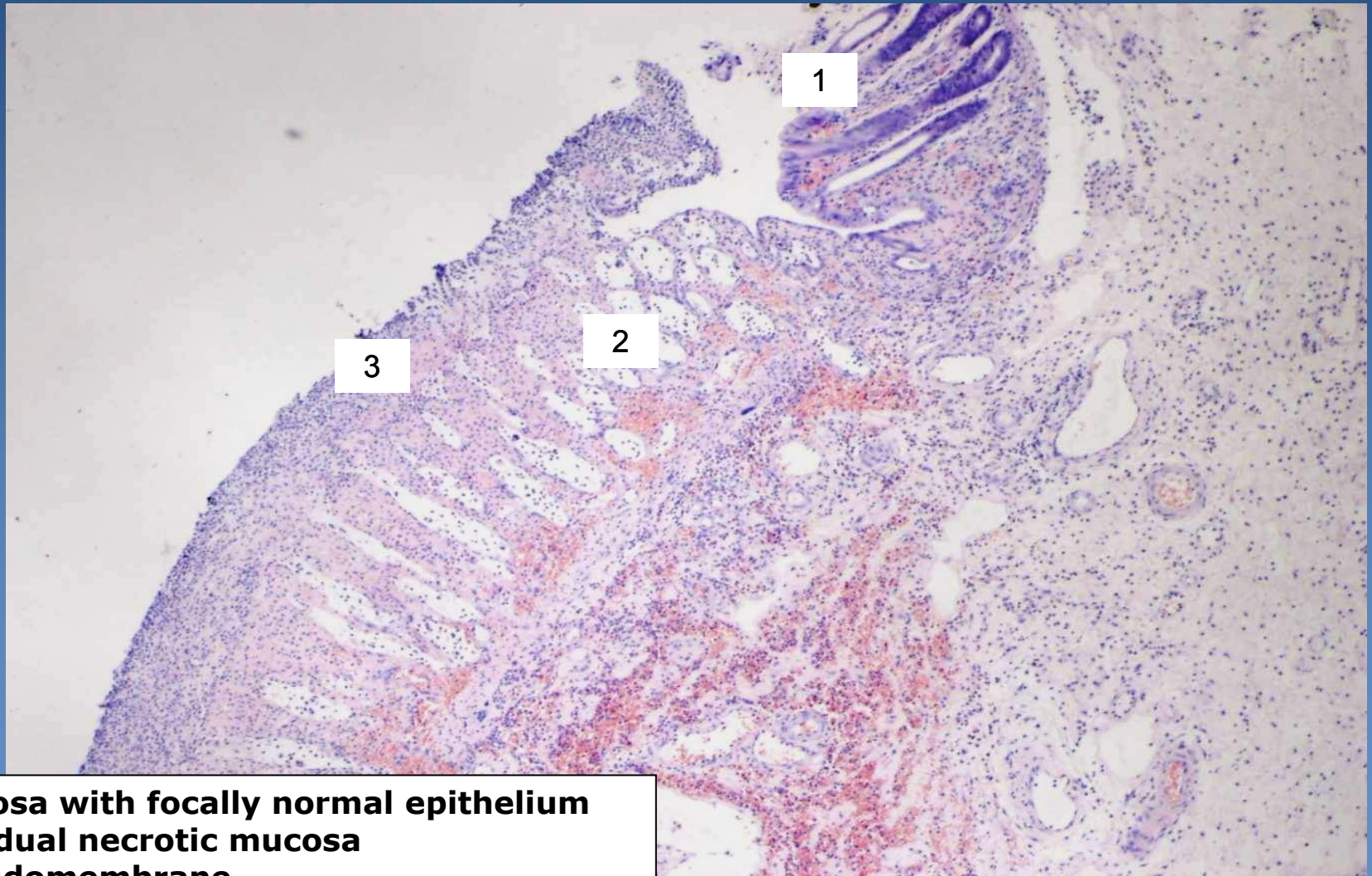
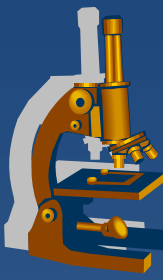
- 1 Transmural inflammatory infiltrate
- 2 Intestinal mucosa
- 3 Serosa

41. *Ulcerative colitis* (*superficial inflammatory infiltrate*)



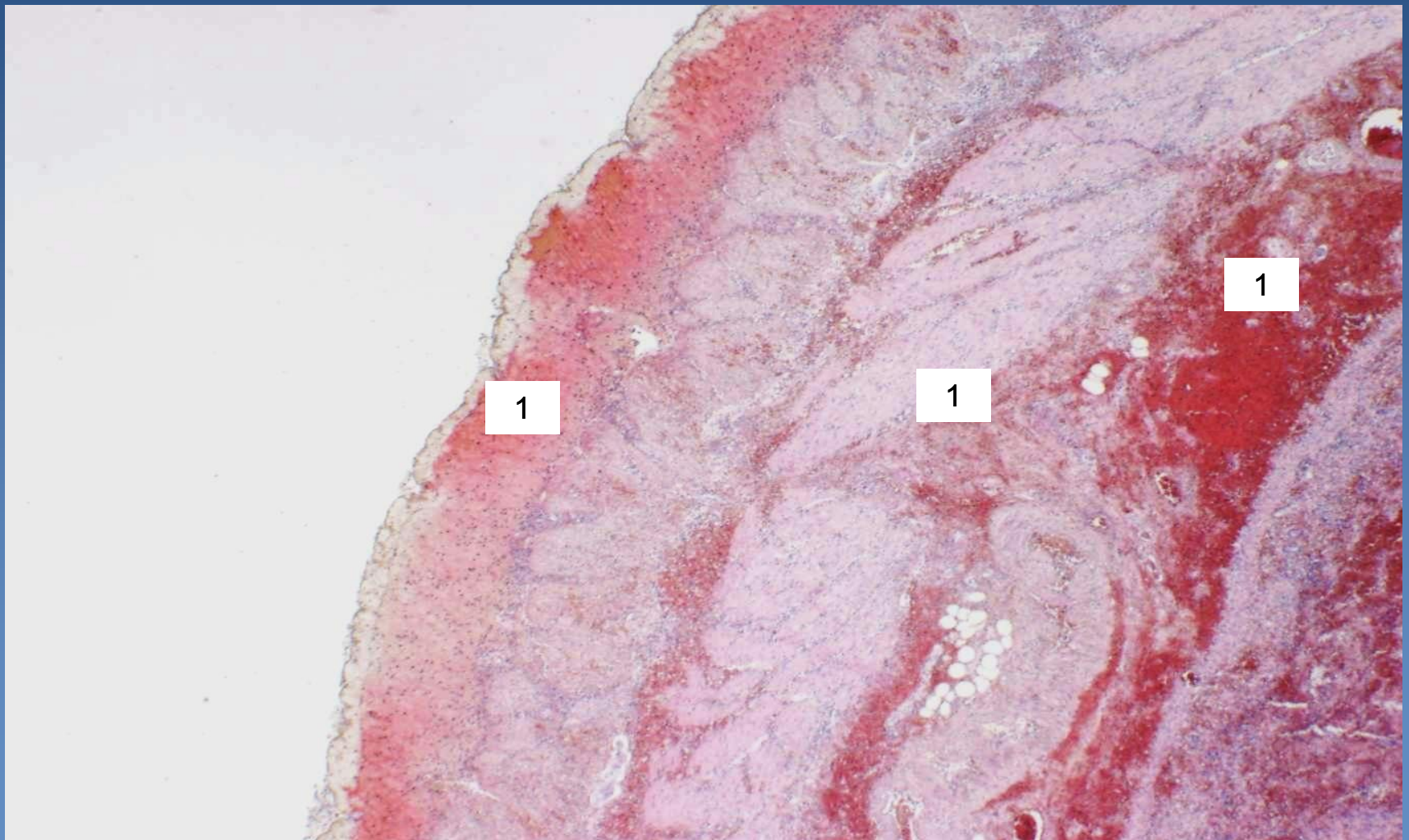
- 1 Mucosa with focal normal epithelium
- 2 Inflammatory infiltrate in the mucosa and submucosa
- 3 Muscularis propria
- 4 Mucosa ulceration

42. Pseudomembranous colitis



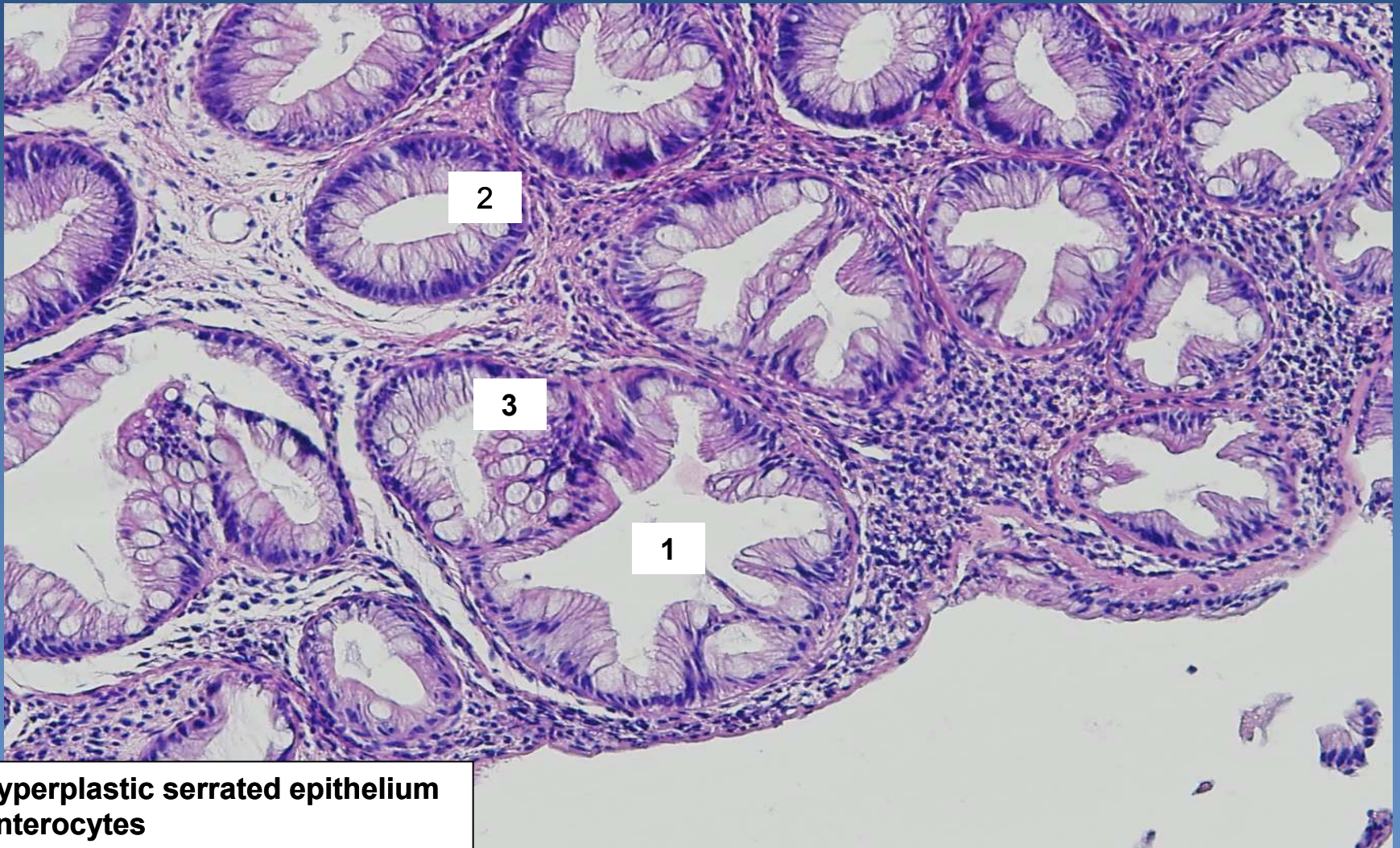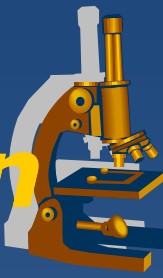1 Mucosa with focally normal epithelium
2 Residual necrotic mucosa
3 Pseudomembrane

43. Hemorrhagic infarction of the intestine



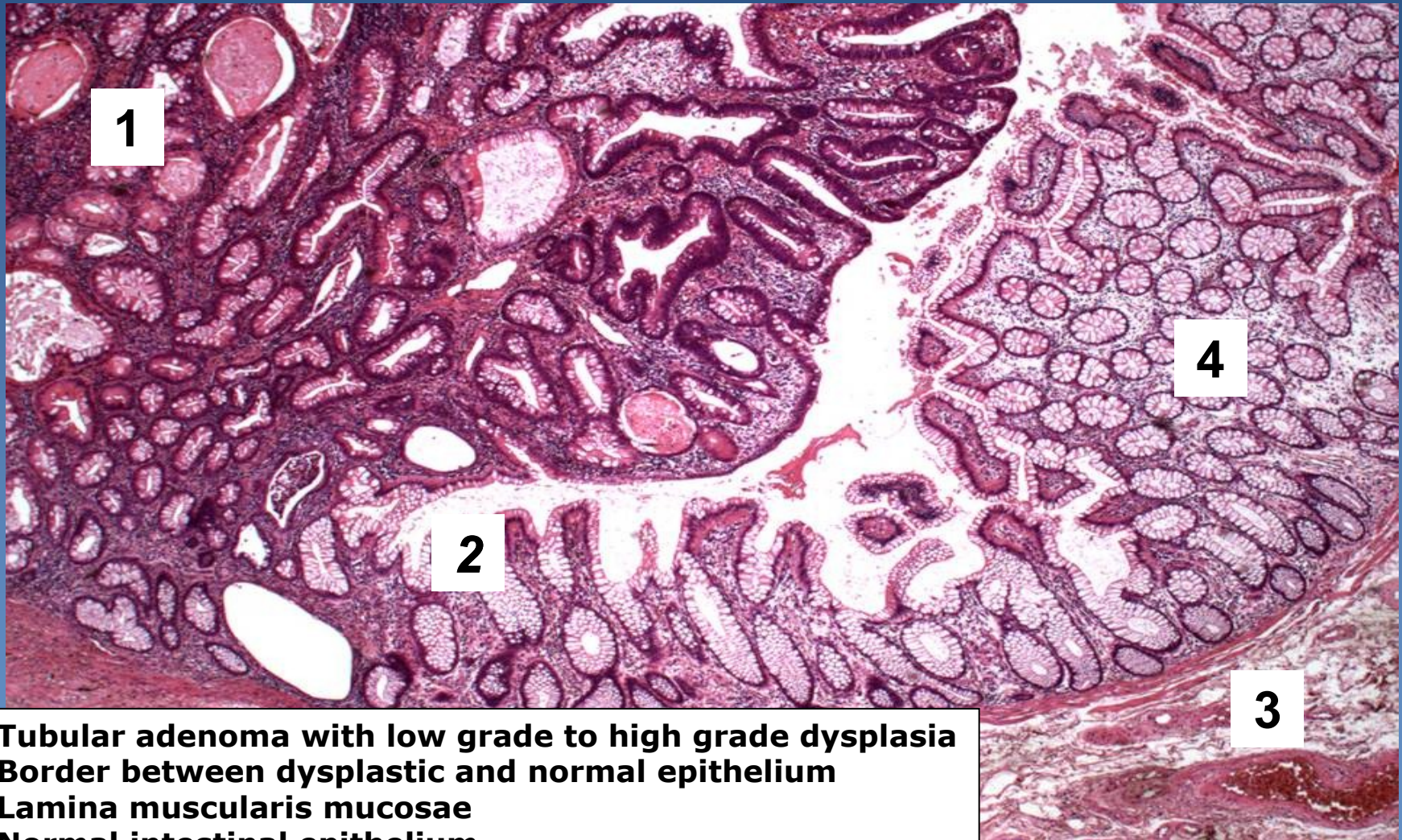
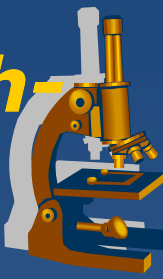1 Complete transmural hemorrhagic necrosis of the intestinal wall

44. Hyperplastic polyp of colon



- 1 Hyperplastic serrated epithelium
- 2 Enterocytes
- 3 Goblet cells

45. Tubular adenoma of colon with high-grade epithelial dysplasia



1

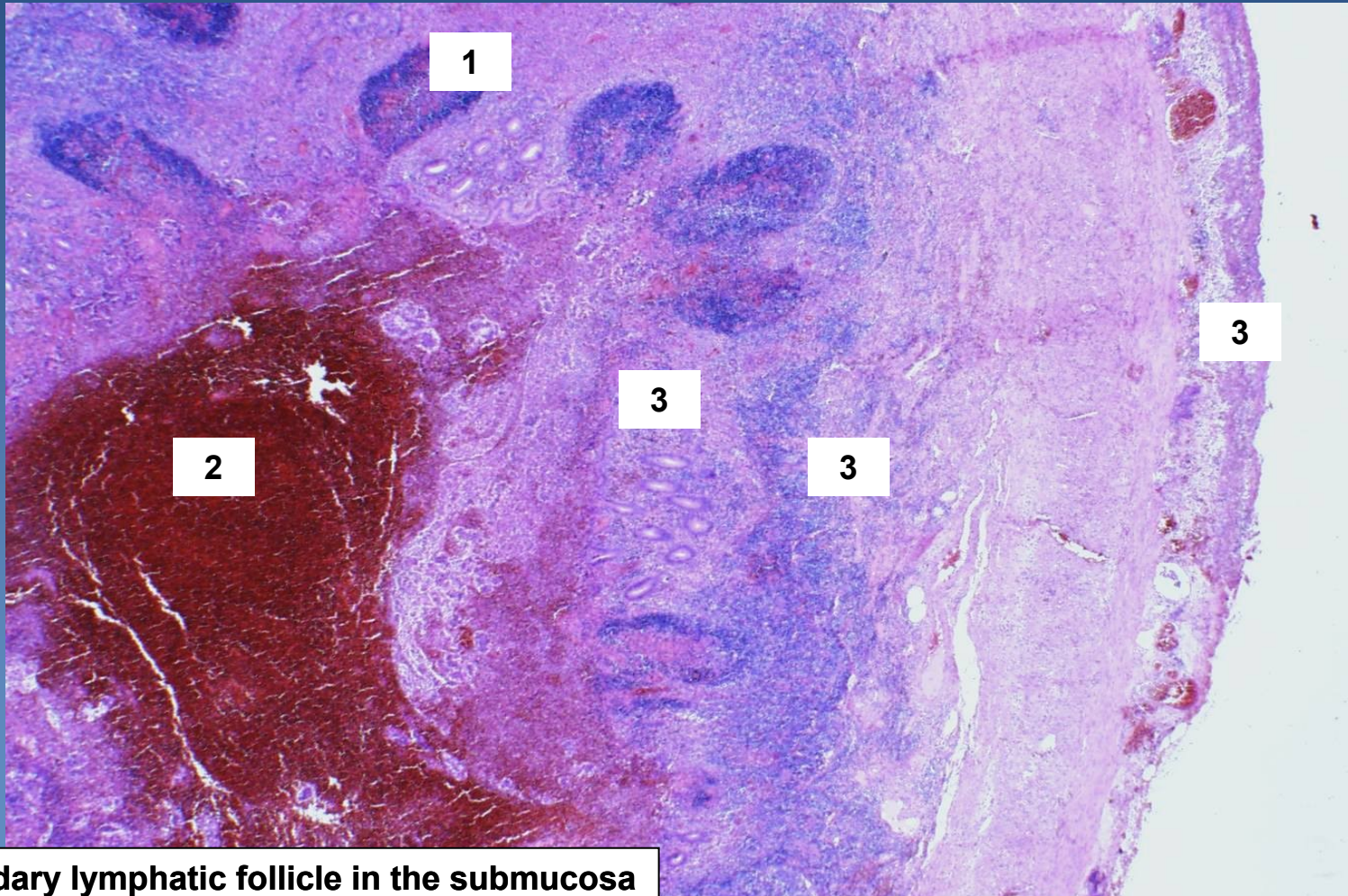
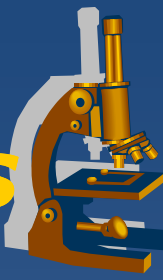2

4

3

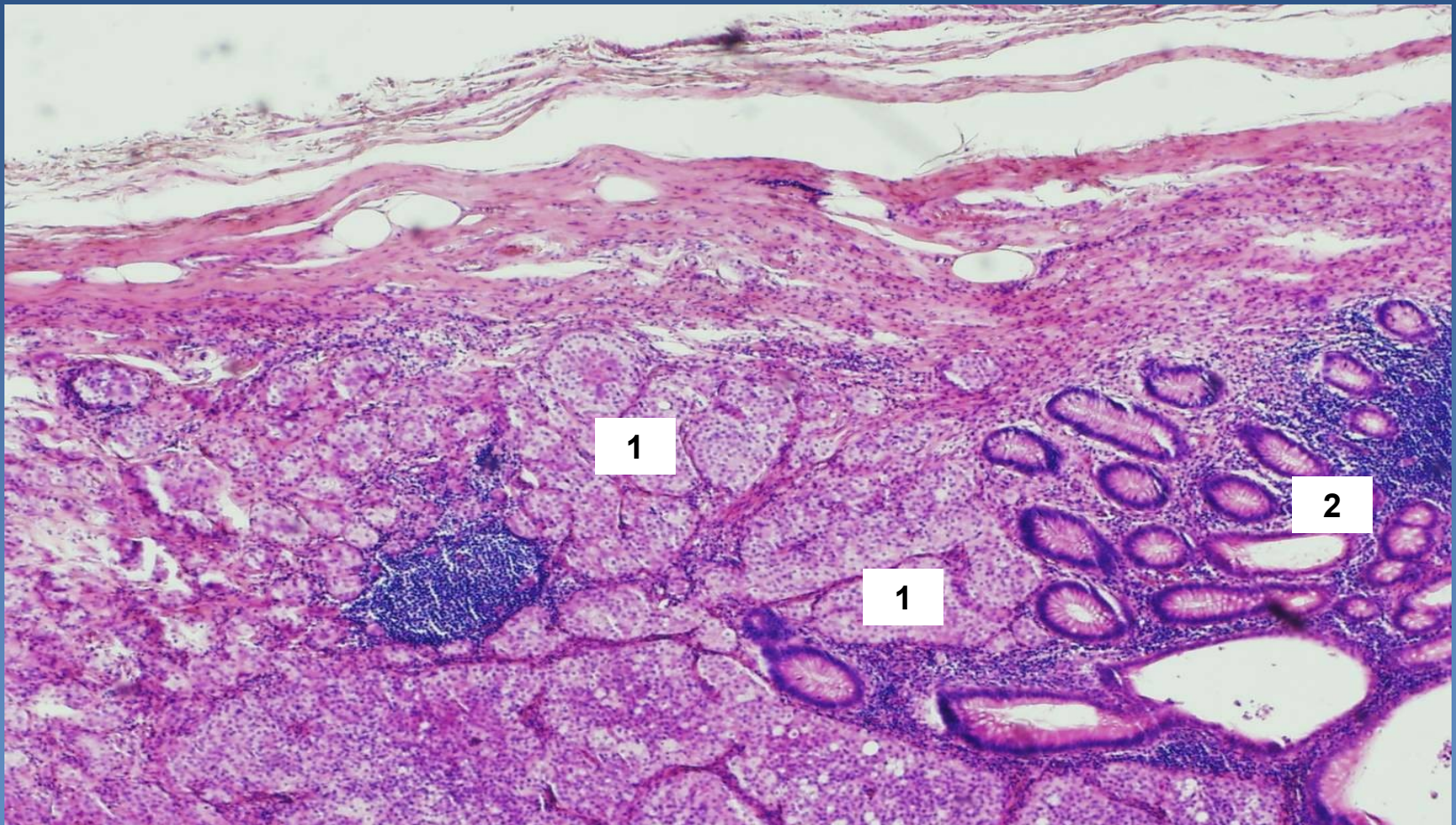
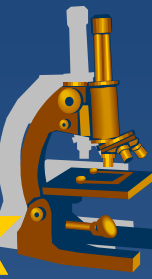
- 1 Tubular adenoma with low grade to high grade dysplasia
- 2 Border between dysplastic and normal epithelium
- 3 Lamina muscularis mucosae
- 4 Normal intestinal epithelium

46. *Phlegmonous appendicitis*



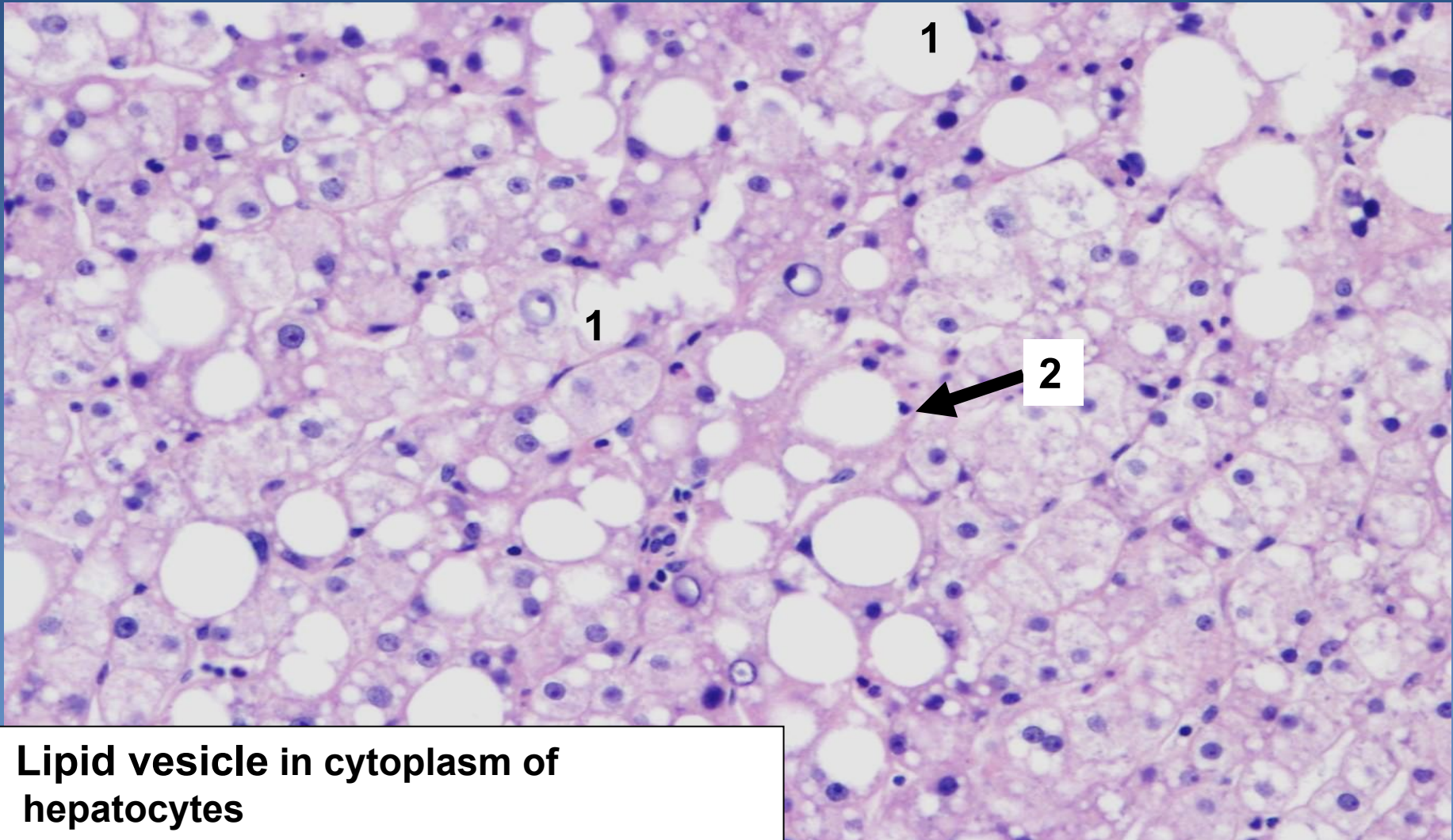
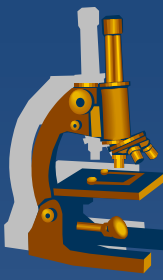
- 1 Secondary lymphatic follicle in the submucosa
- 2 Intraluminal hemorrhage
- 3 Inflammatory infiltrate

47. Neuroendocrine tumor (carcinoid) of the appendix



- 1 Trabecular/glandular neoplastic structures, cells with clear cytoplasm and round/oval-shaped nuclei
- 2 Appendiceal mucosa

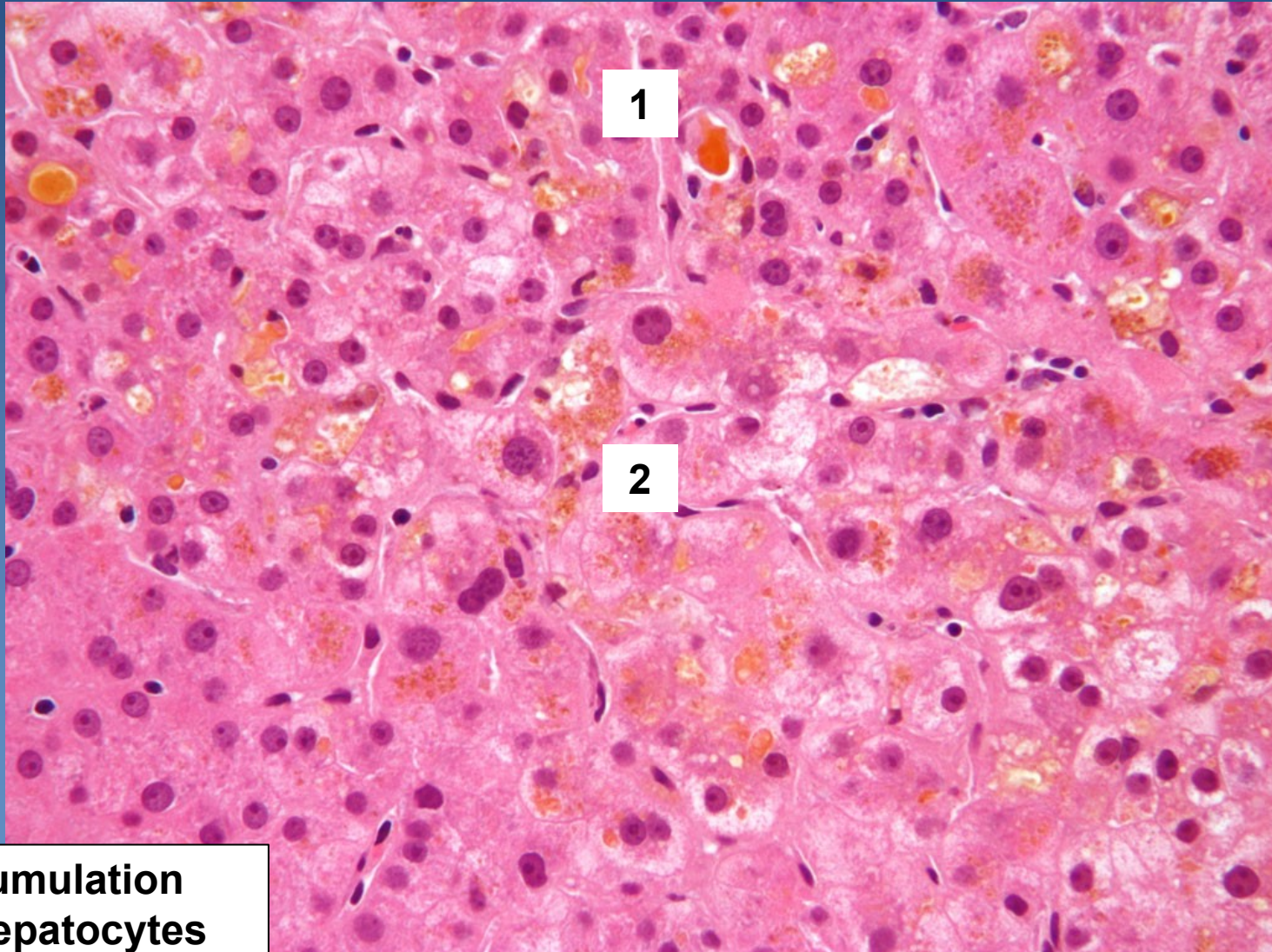
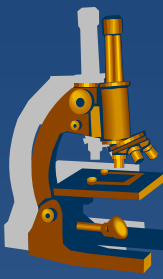
48. Steatosis of liver



1 Lipid vesicle in cytoplasm of hepatocytes

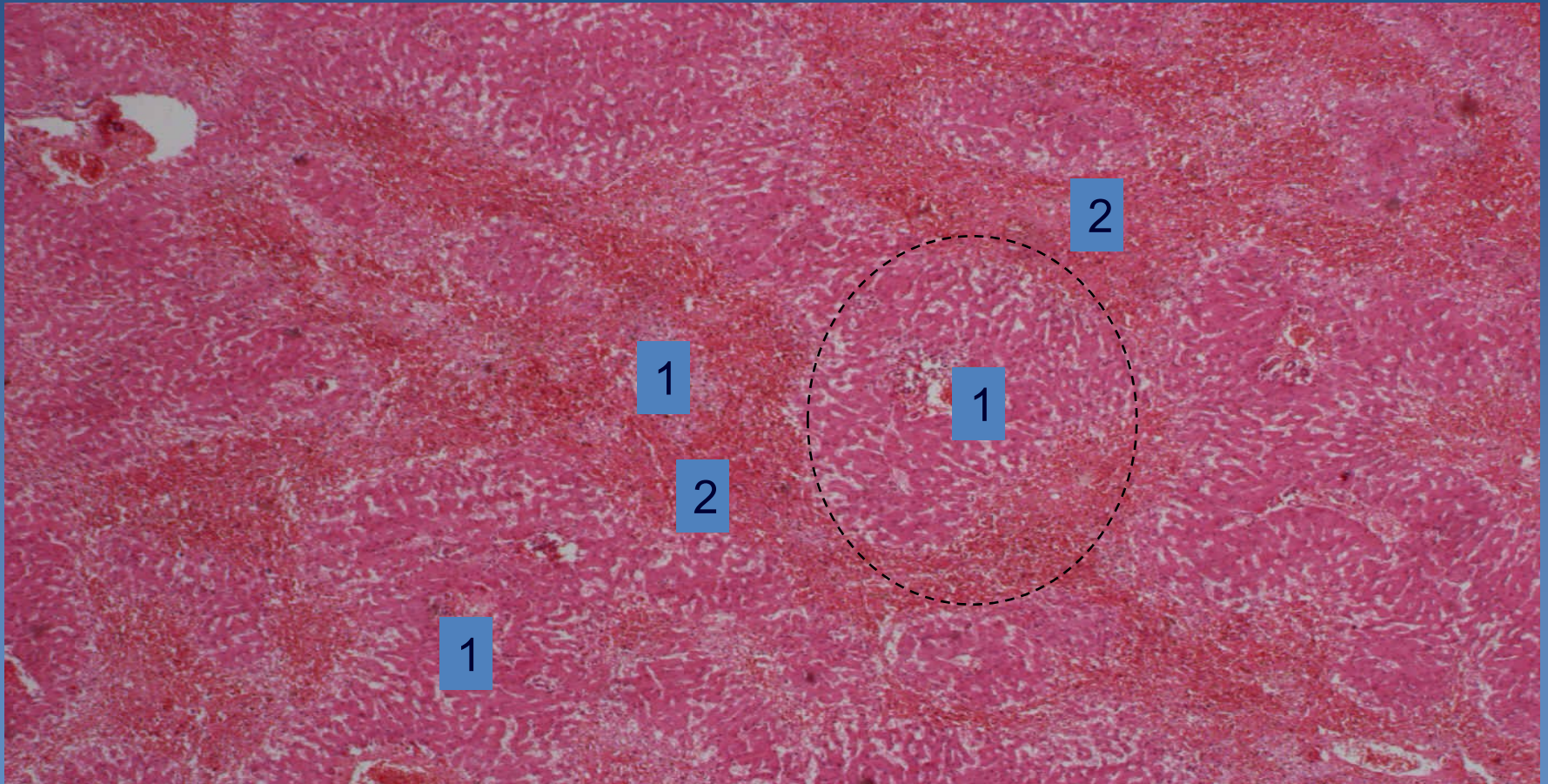
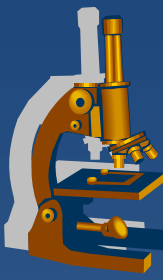
2 Hepatocyte nucleus pushed to periphery

49. Cholestasis of liver



1 Bile accumulation
2 Bile in hepatocytes

50. Hepatic venous congestion

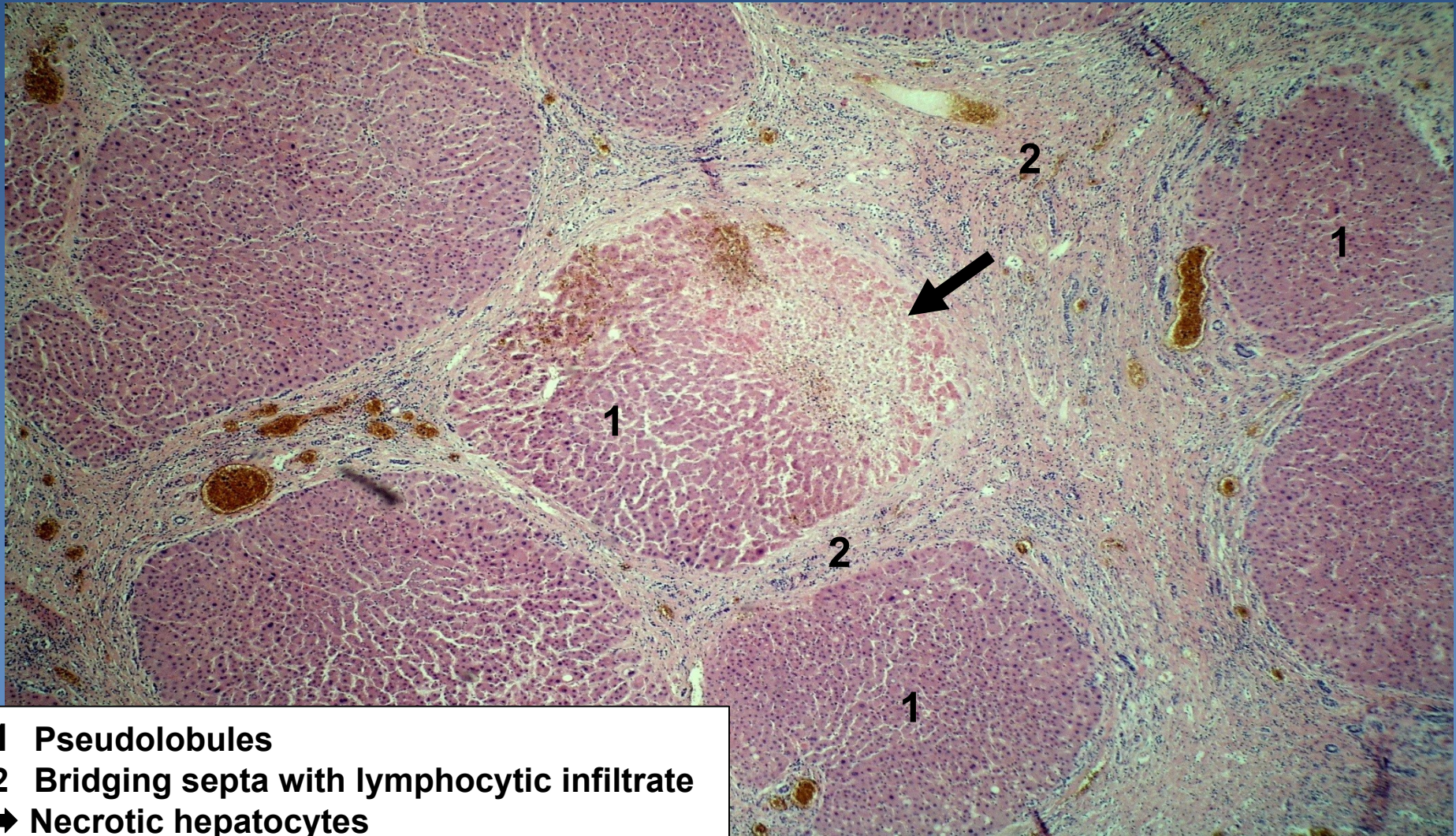
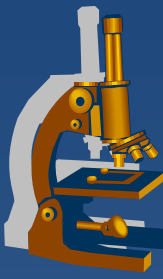


1 Portal spaces

2 Congestive lines (severe congestion with hepatocyte necrosis)

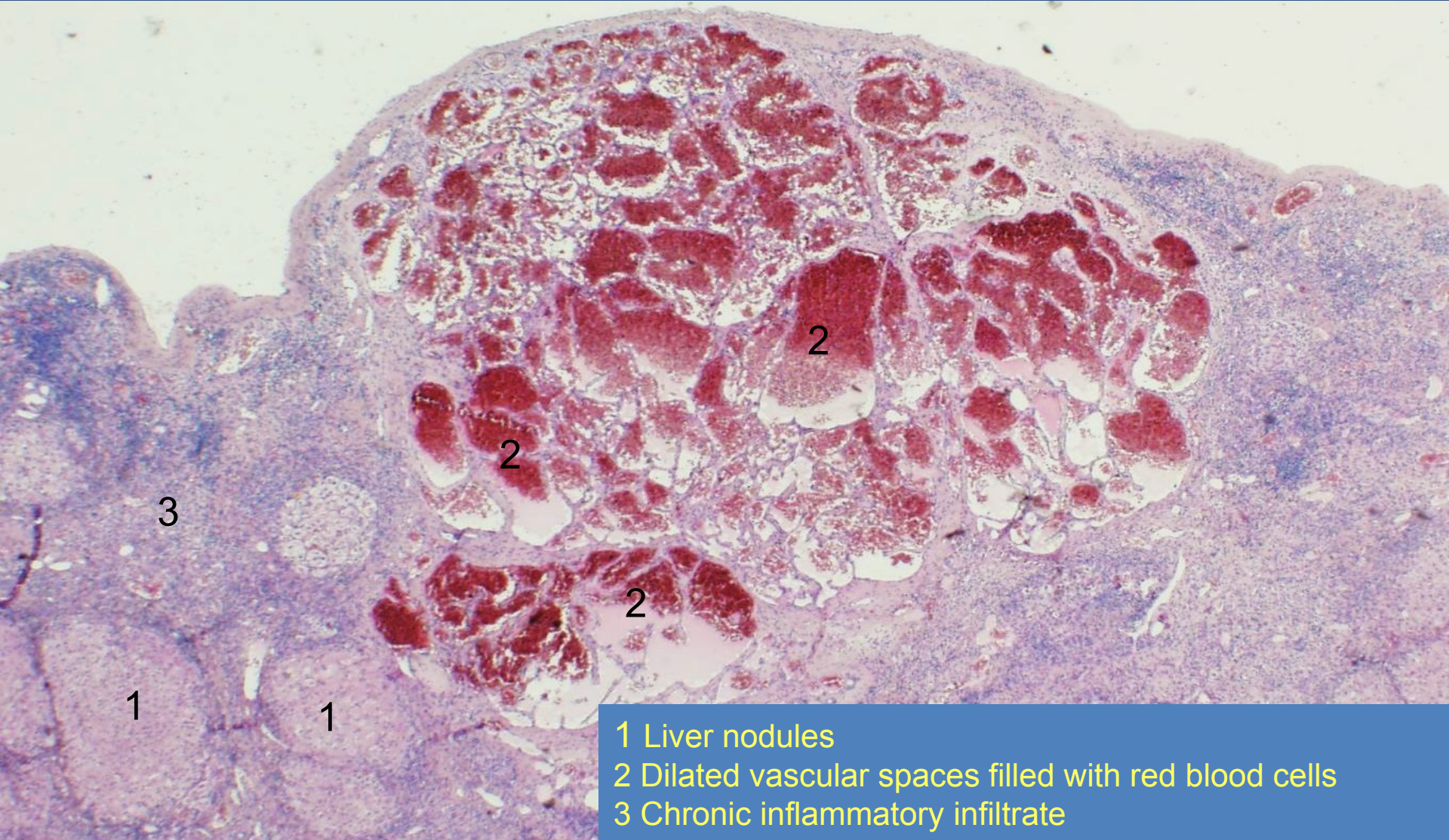
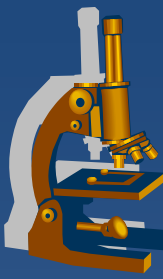
„---“ pseudolobule: confluent remnants of 3 lobules, centrally portal space

51. Cirrhosis of liver



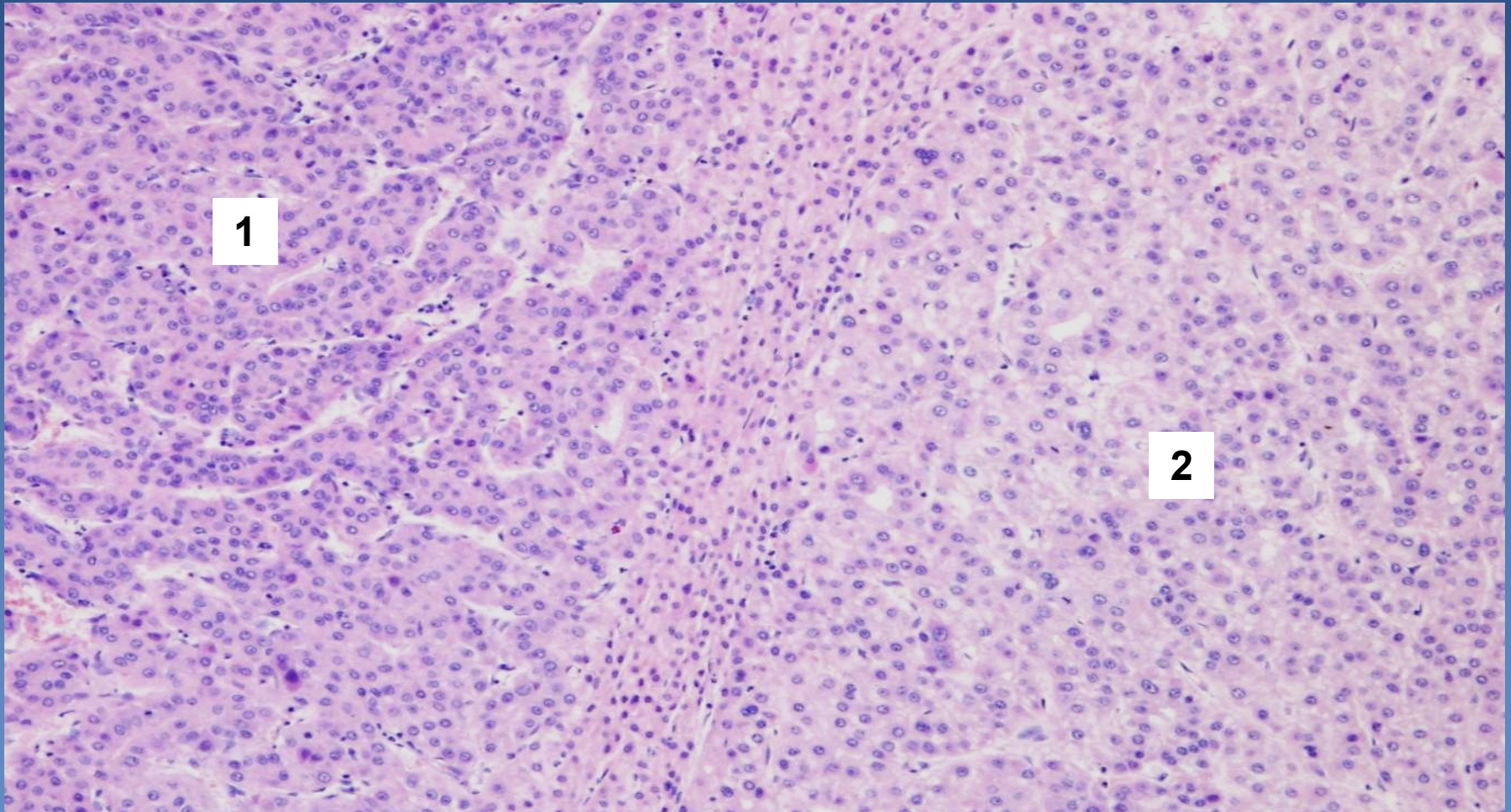
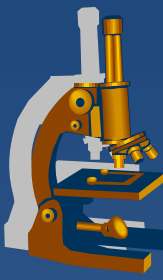
- 1 Pseudolobules
- 2 Bridging septa with lymphocytic infiltrate
- ➔ Necrotic hepatocytes

52. Cavernous haemangioma (in micronodular liver cirrhosis)



- 1 Liver nodules
- 2 Dilated vascular spaces filled with red blood cells
- 3 Chronic inflammatory infiltrate

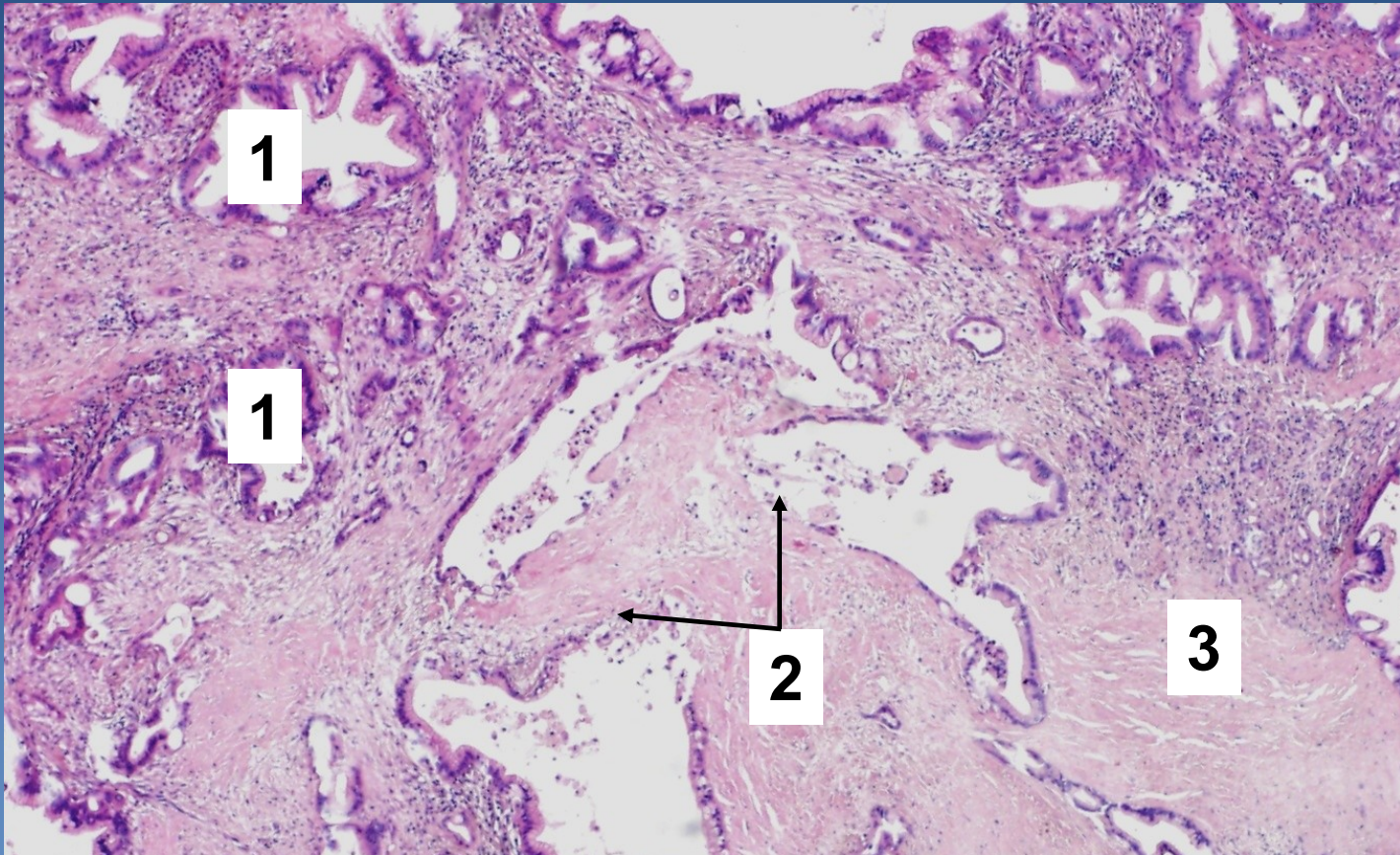
53. Hepatocellular carcinoma



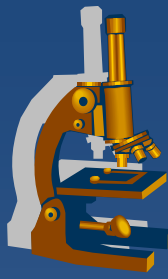
1 Normal liver parenchyma

2 Cells of hepatocellular carcinoma – in here with pale cytoplasm, trabecular structure, with atypias and increased mitotic activity

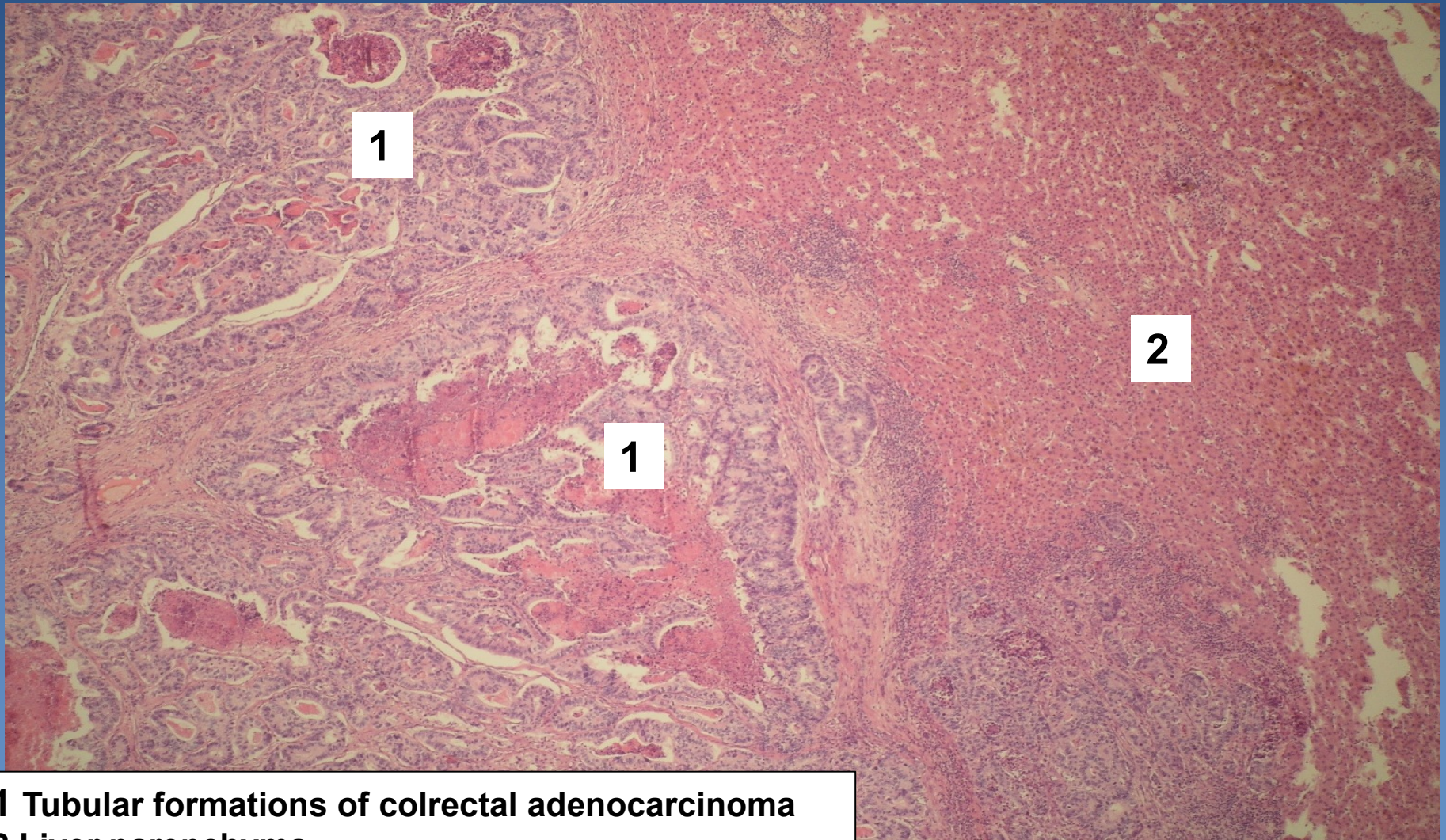
54. Ductal adenocarcinoma of pancreas



- 1 Neoplastic ductal formations
- 2 Focal duct ruptures with macrophages and detritus in the lumen
- 3 Stromal desmoplasia

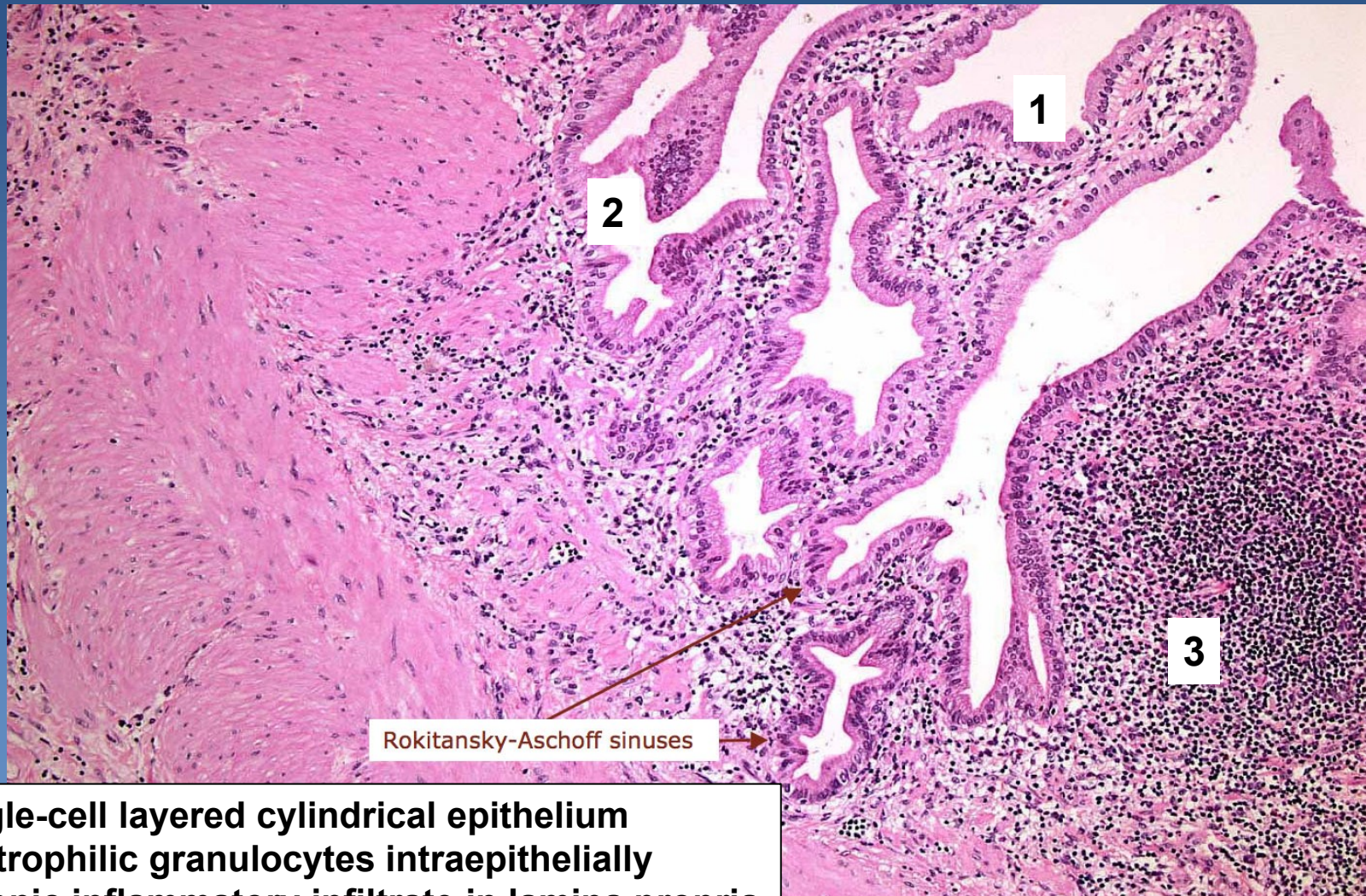
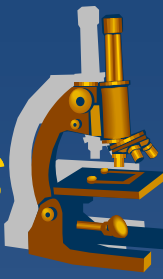


55. Colorectal adenocarcinoma metastasis into hepatic parenchyma



1 Tubular formations of colorectal adenocarcinoma
2 Liver parenchyma

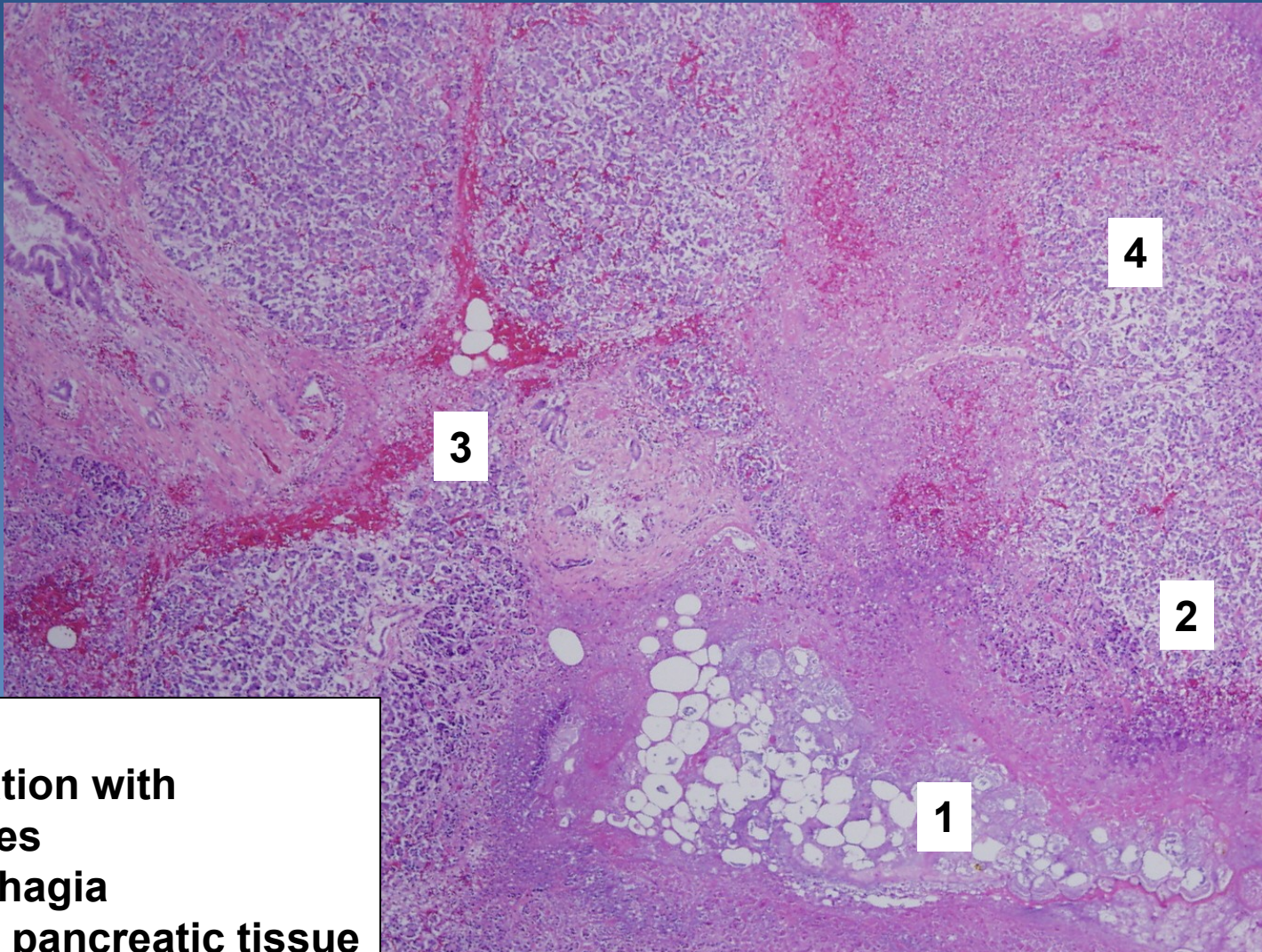
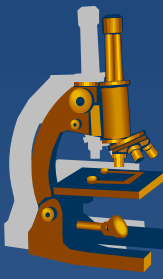
56. Chronic active cholecystitis



Rokitansky-Aschoff sinuses

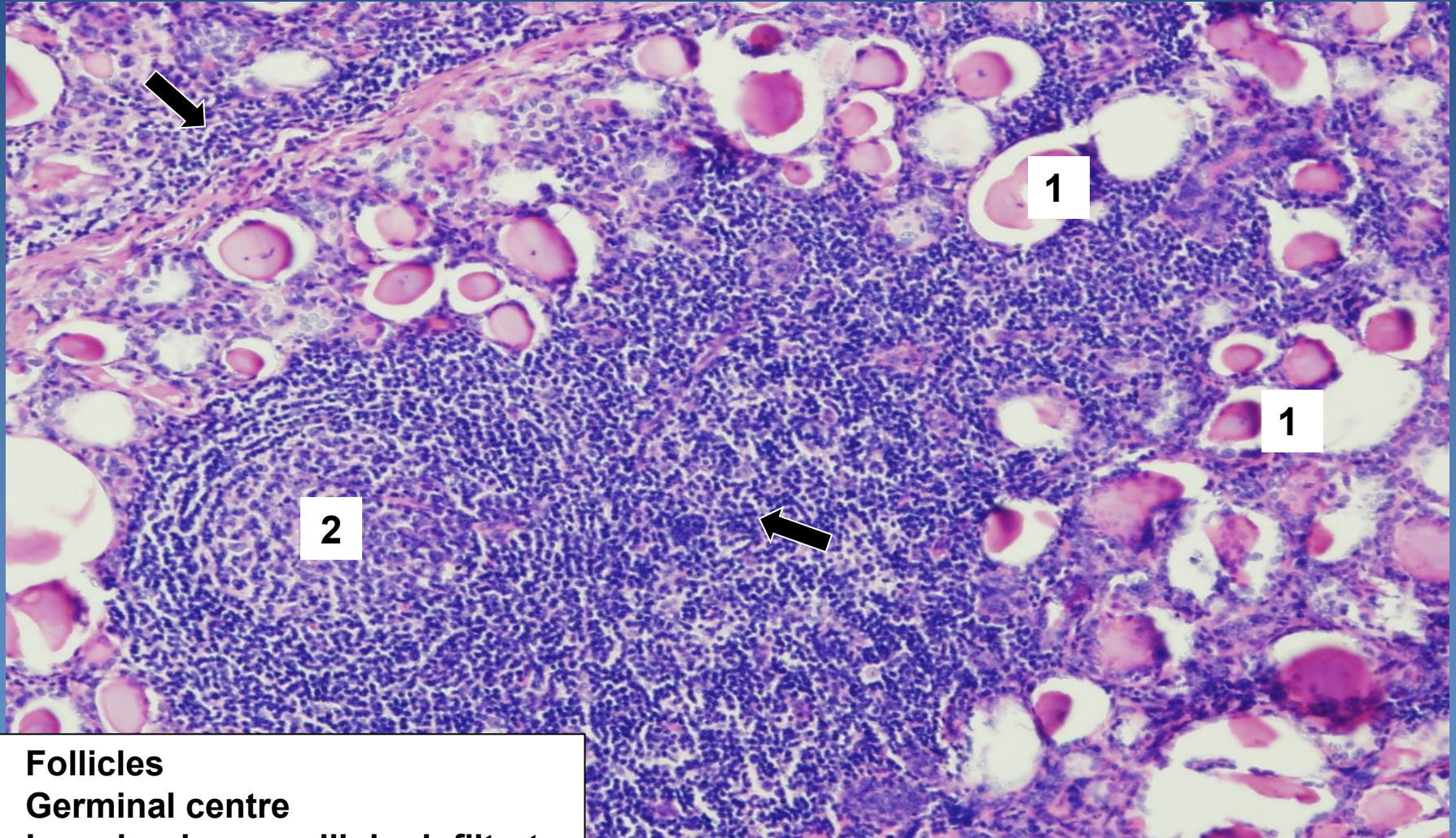
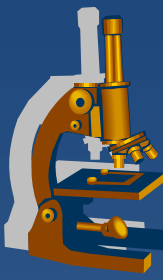
- 1 single-cell layered cylindrical epithelium
- 2 neutrophilic granulocytes intraepithelially
- 3 chronic inflammatory infiltrate in lamina propria

57. Acute haemorrhagic pancreatitis



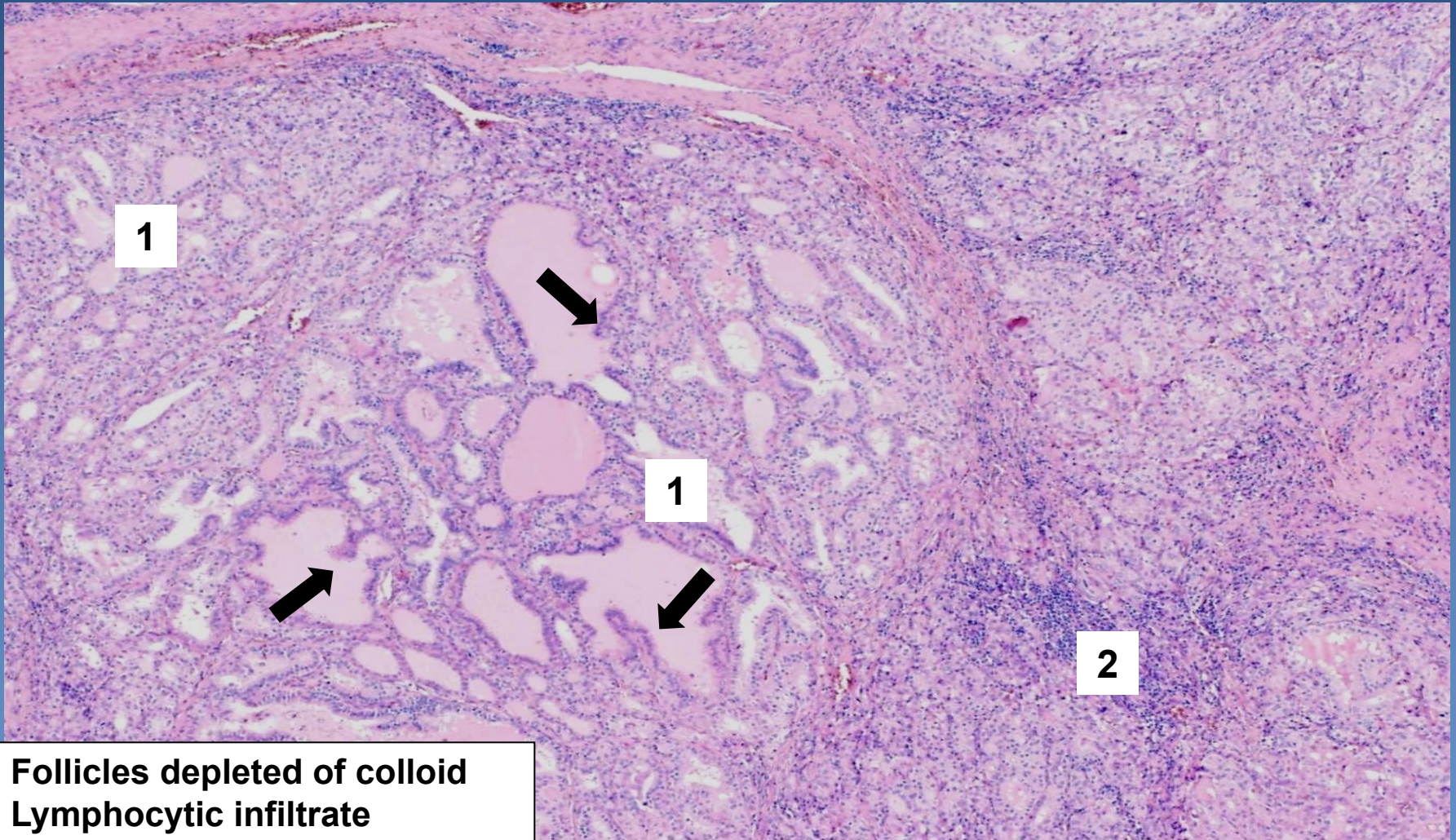
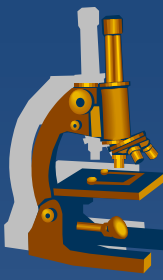
- 1 Necrosis
- 2 Demarcation with neutrophils
- 3 Haemorrhagia
- 4 Adjacent pancreatic tissue

58. Hashimoto's thyroiditis



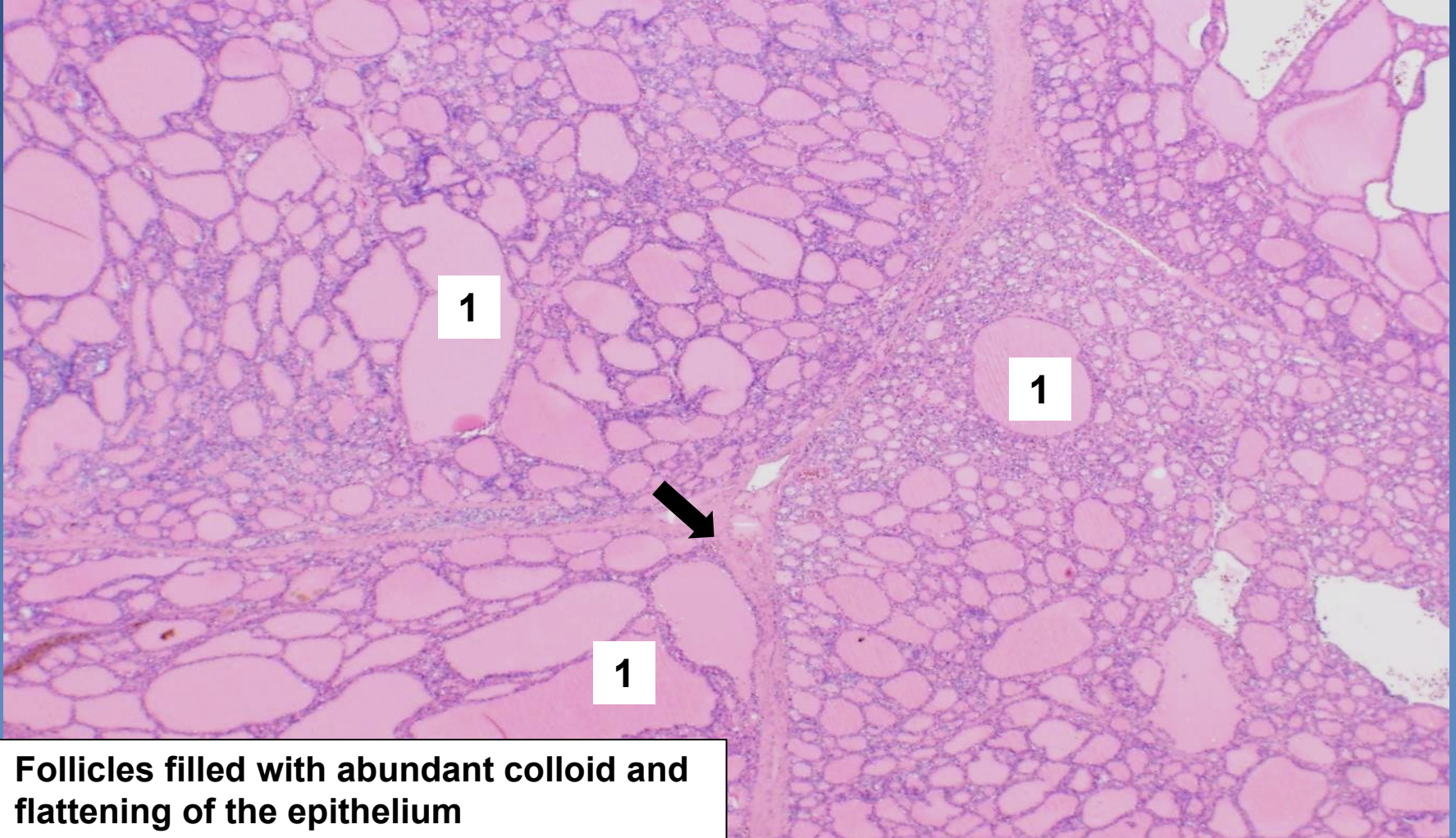
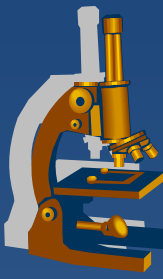
- 1 Follicles
- 2 Germinal centre
- ➔ Lymphoplasmocellular infiltrate

59. Thyroid gland hyperplasia (Graves-Basedow disease)



- 1 Follicles depleted of colloid
- 2 Lymphocytic infiltrate
- ➔ Papillary formations

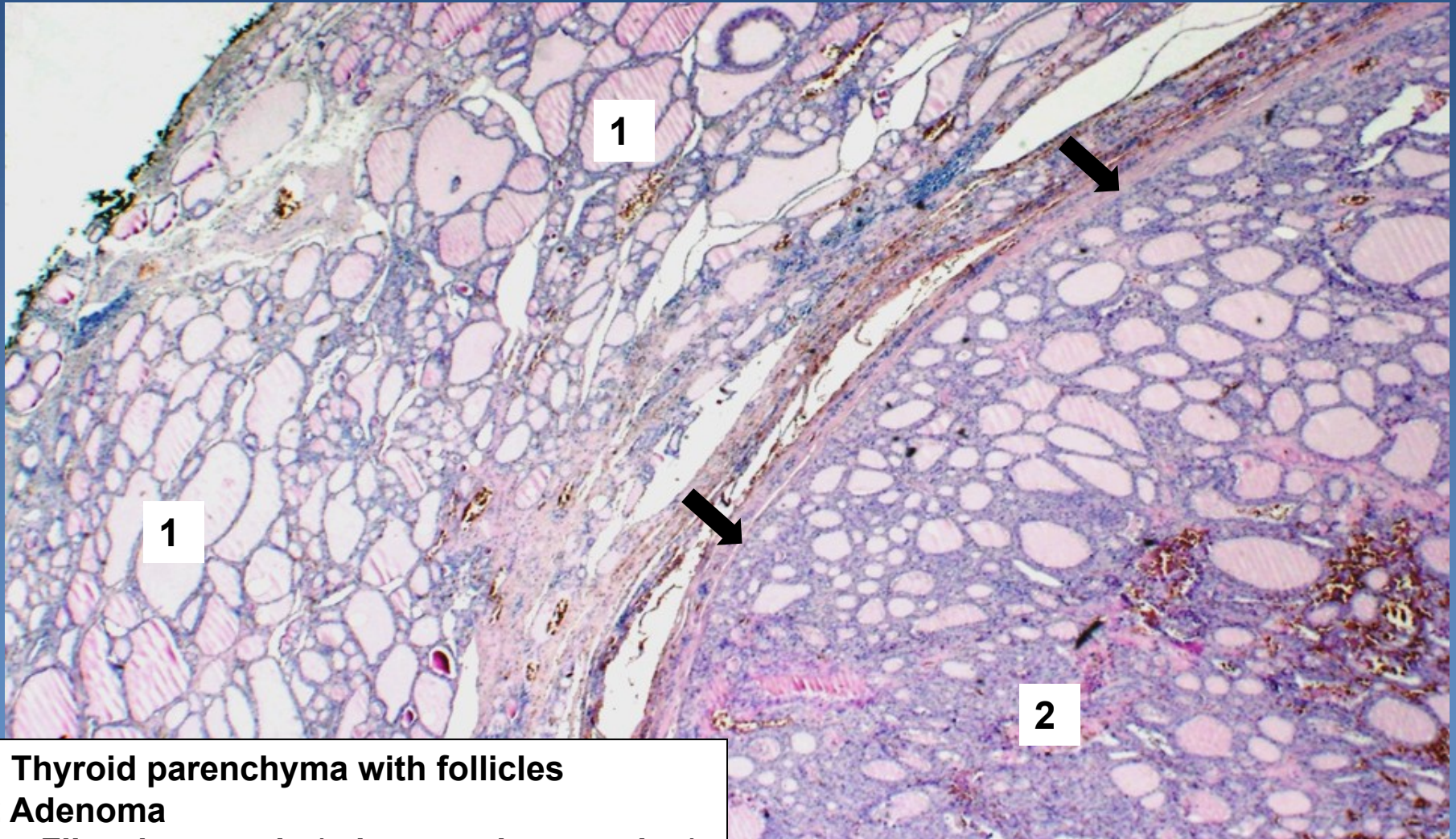
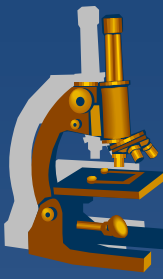
60. Multinodular goitre



1 Follicles filled with abundant colloid and flattening of the epithelium

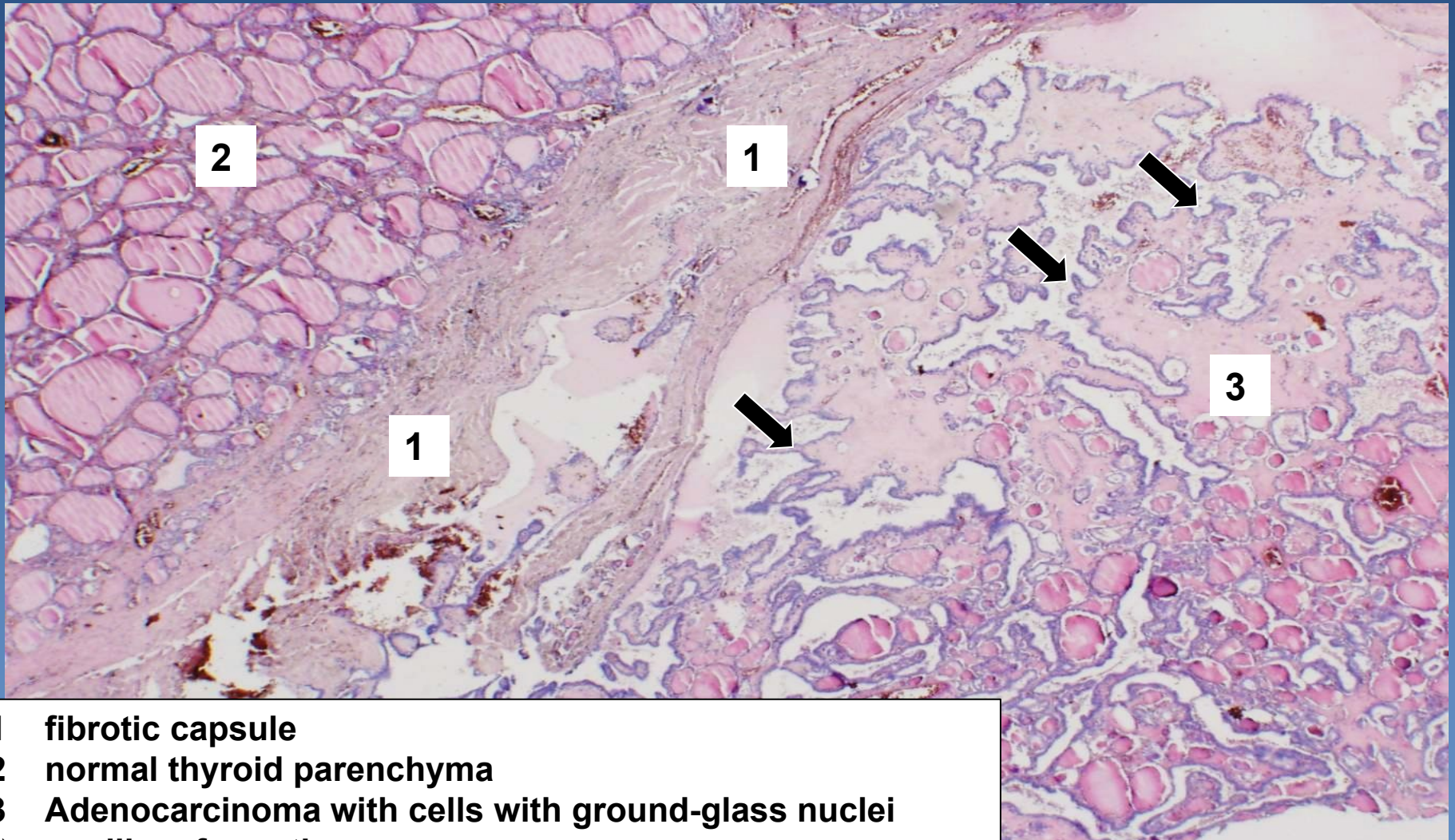
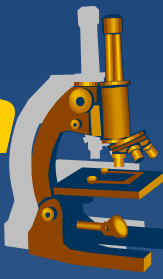➔ **Fibrous septa**

61. Follicular thyroid adenoma

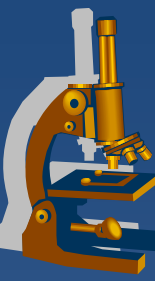


1 Thyroid parenchyma with follicles
2 Adenoma
➔ Fibrotic capsule (adenoma demarcation)

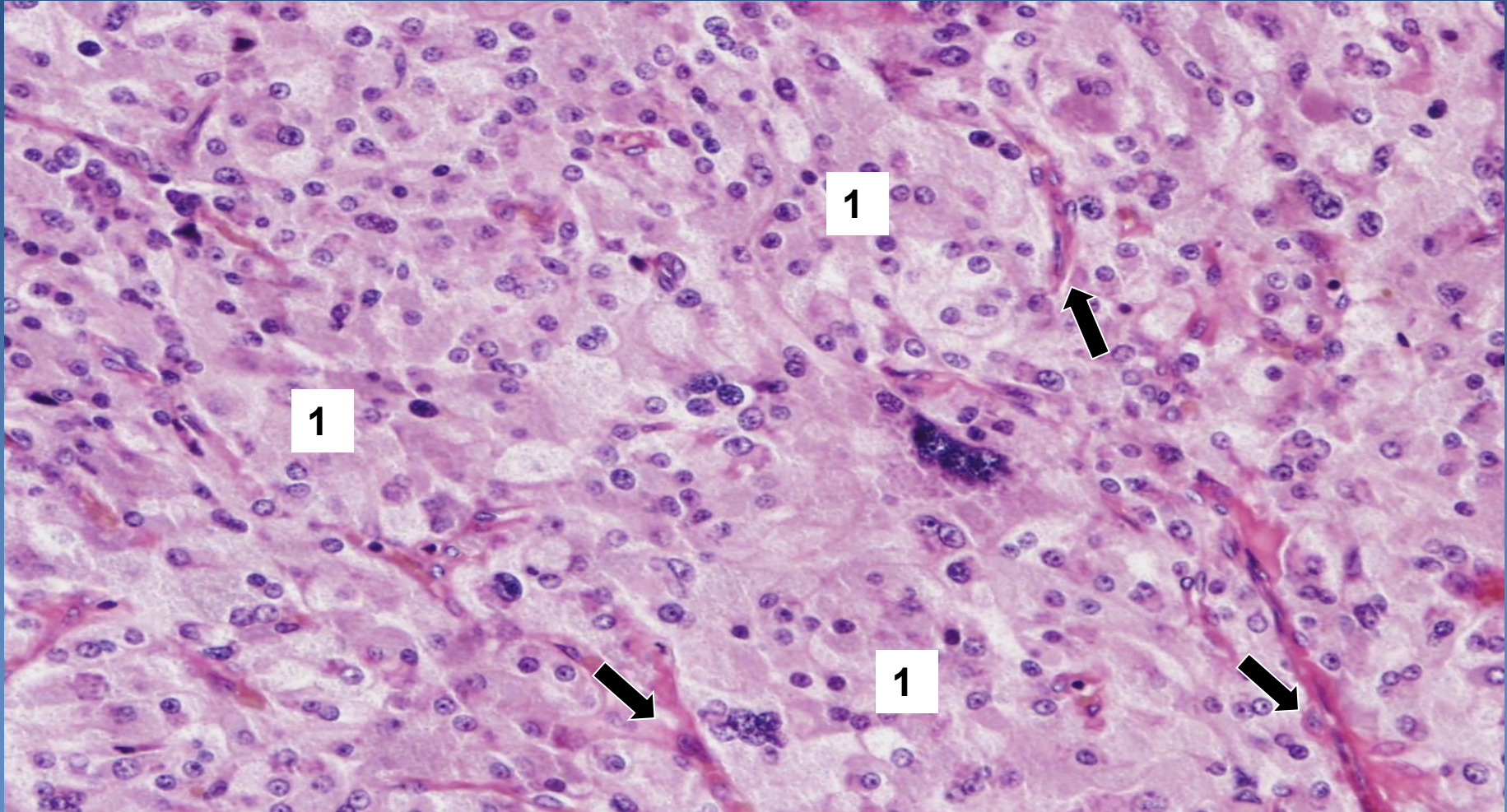
62. Papillary adenocarcinoma of thyroid gland



- 1 fibrotic capsule
- 2 normal thyroid parenchyma
- 3 Adenocarcinoma with cells with ground-glass nuclei
- ➔ papillary formations

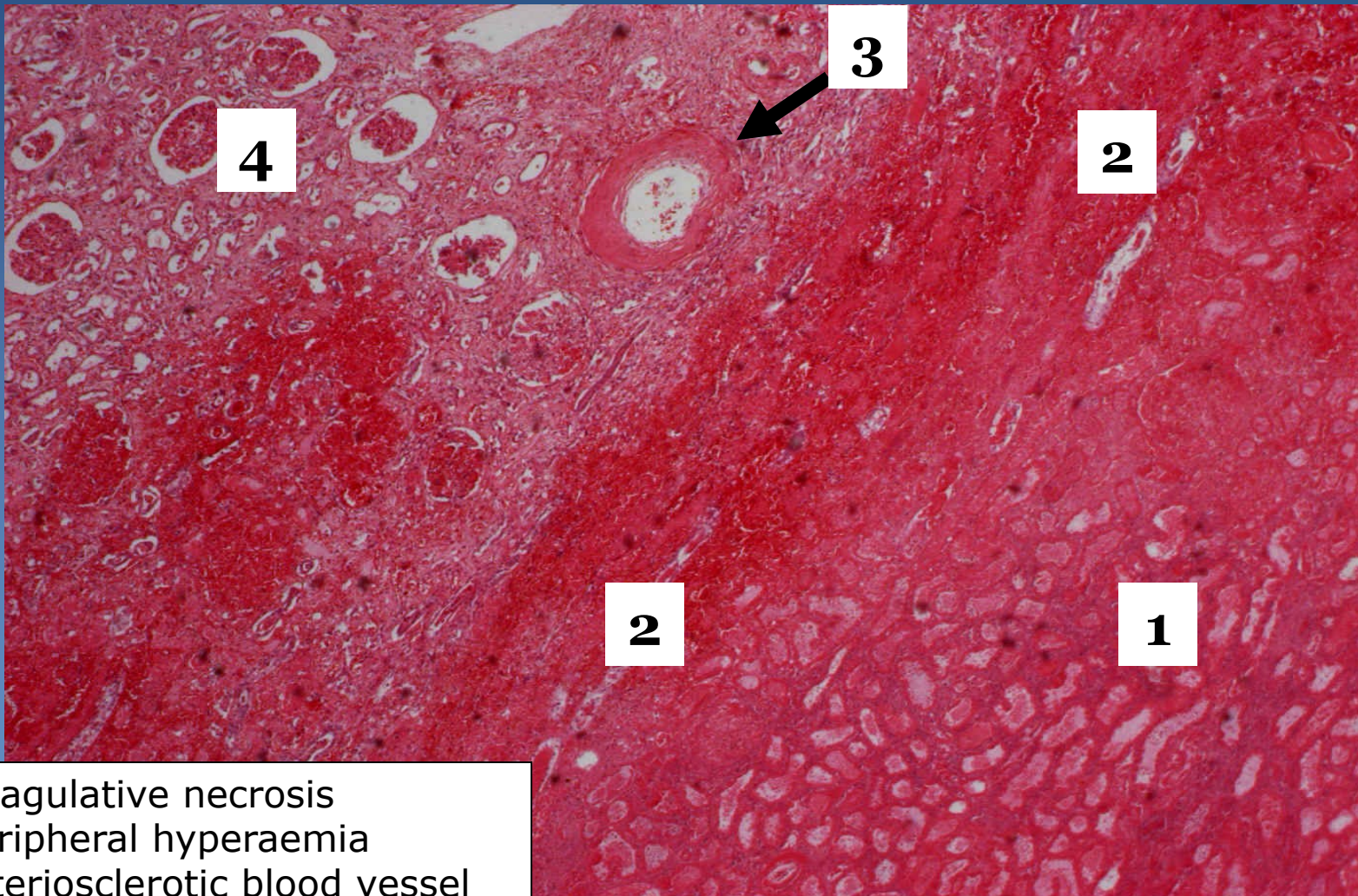
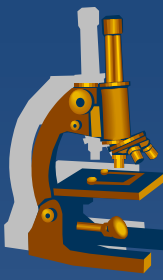


63. Pheochromocytoma

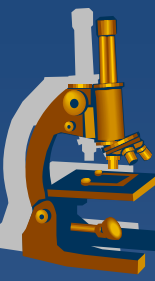


1 Solid alveoli (large cells with granulated cytoplasm)
➡ capillarized stroma

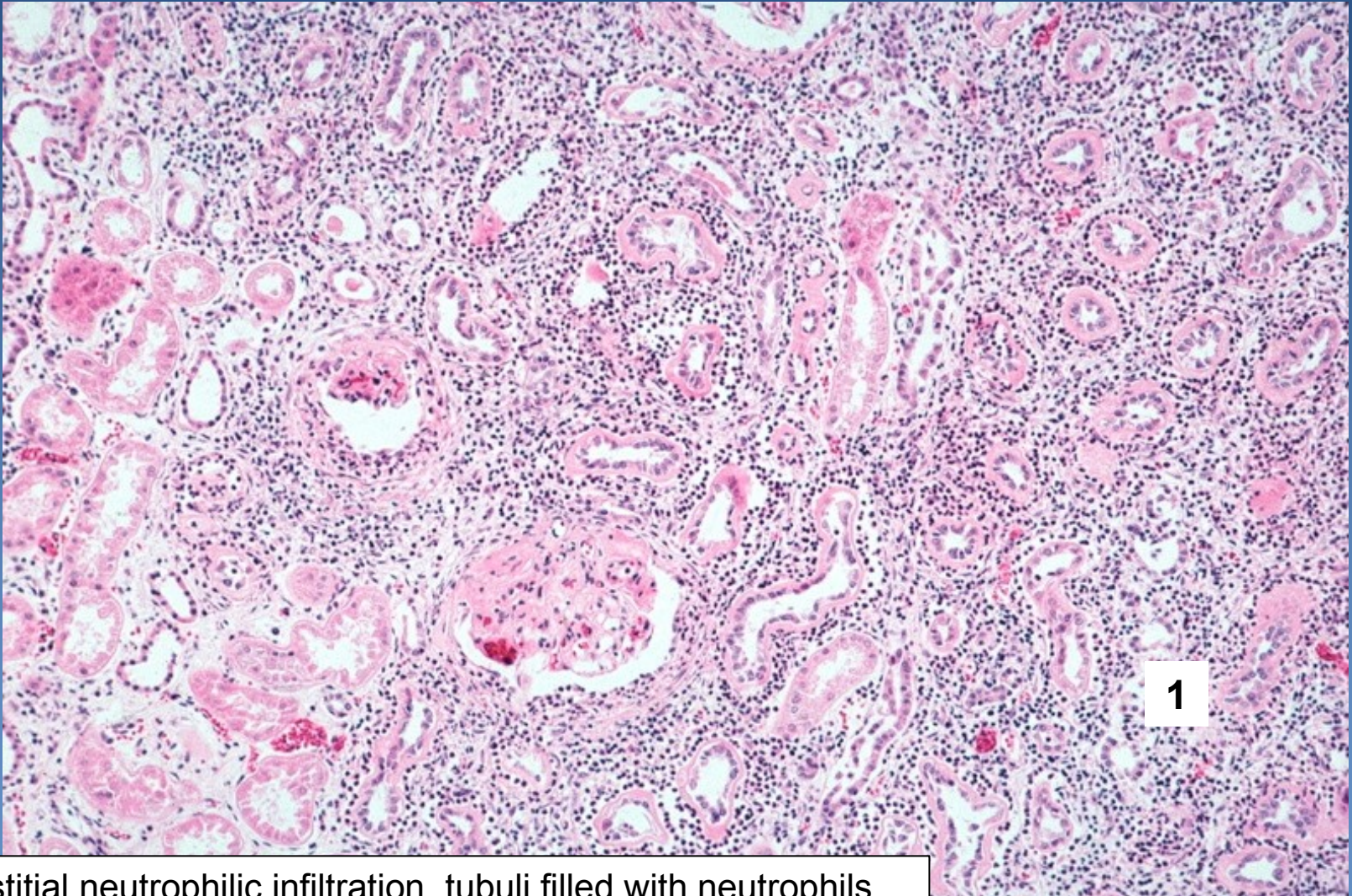
64. Renal infarction



- 1 - coagulative necrosis
- 2 - peripheral hyperaemia
- 3 - arteriosclerotic blood vessel
- 4 - normal tissue

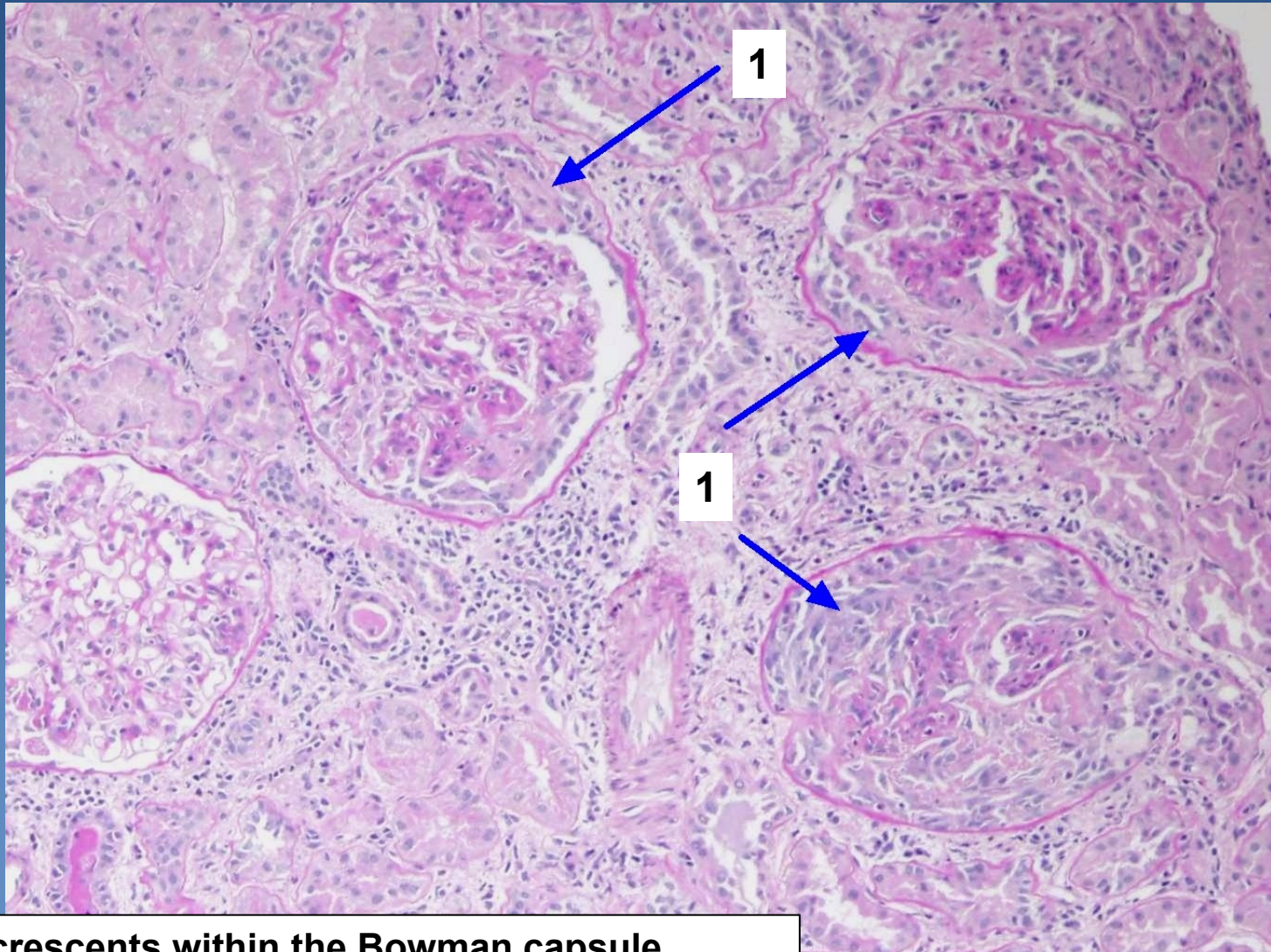
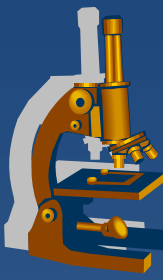


65. *Pyelonefritida purulentní*



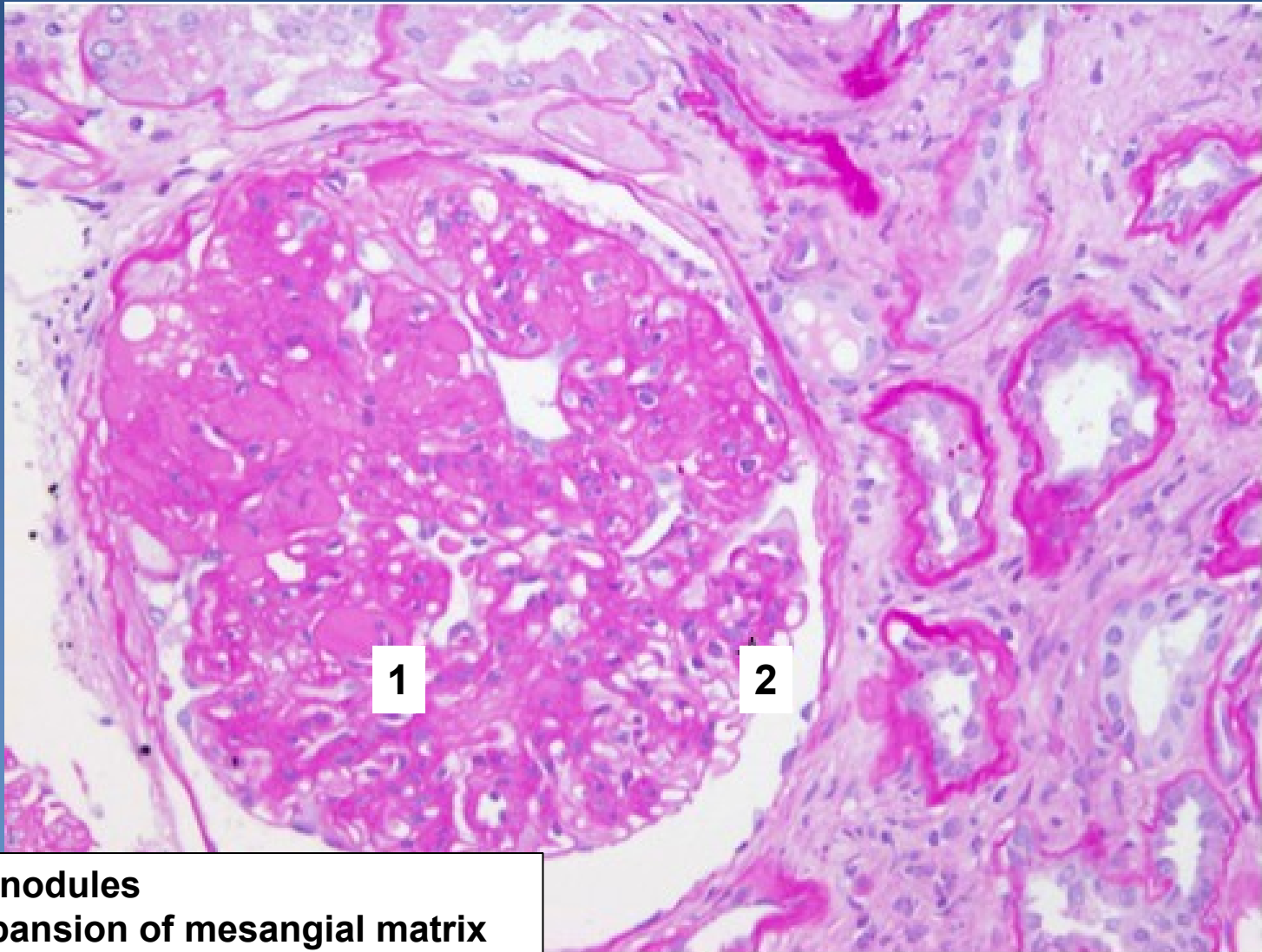
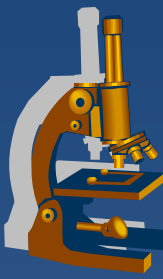
1 Interstitial neutrophilic infiltration, tubuli filled with neutrophils

66. Acute glomerulonephritis (proliferative or crescentic)



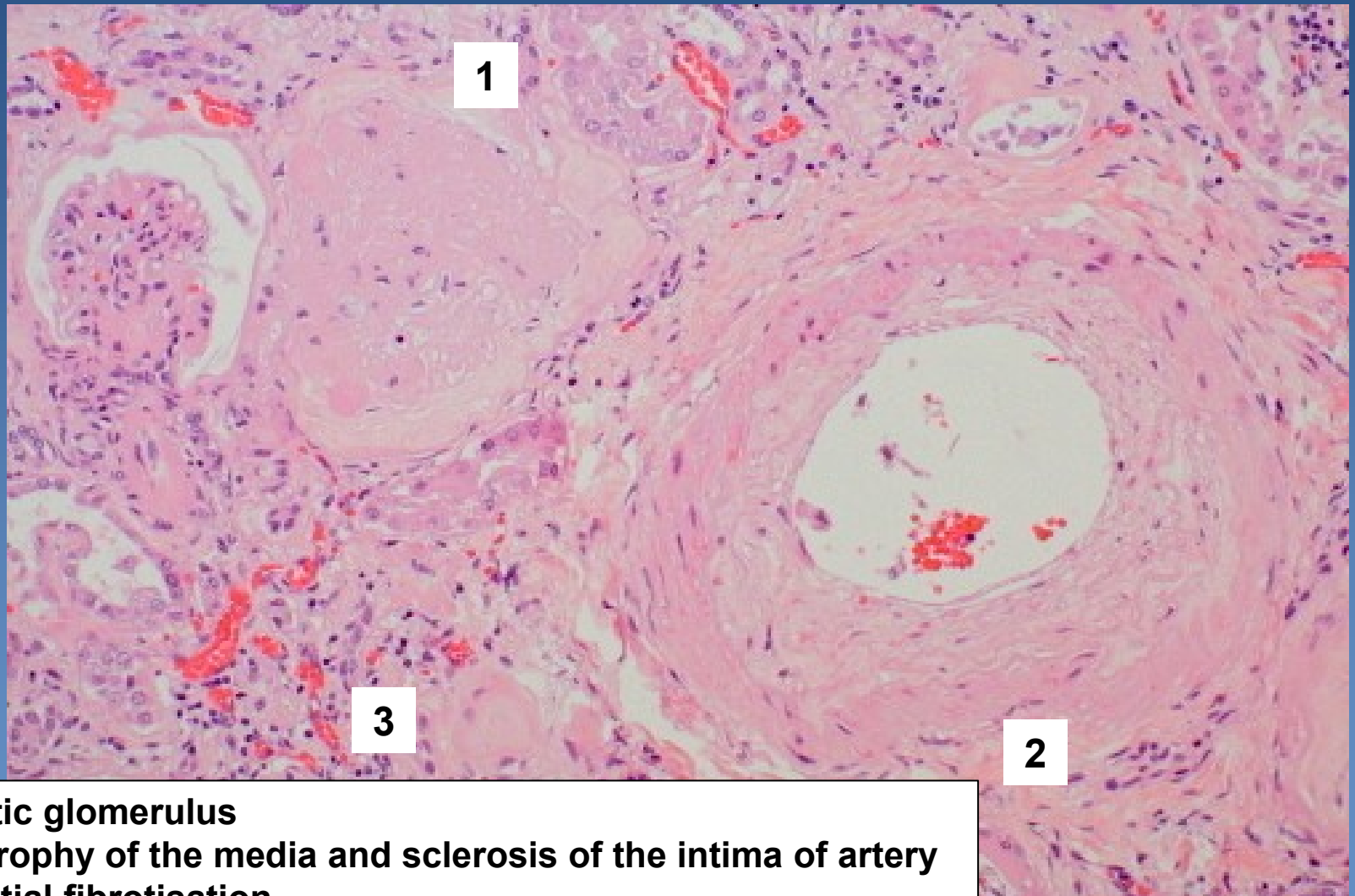
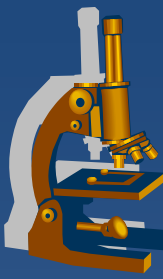
1 Cellular crescents within the Bowman capsule

67. Diabetic glomerulopathy



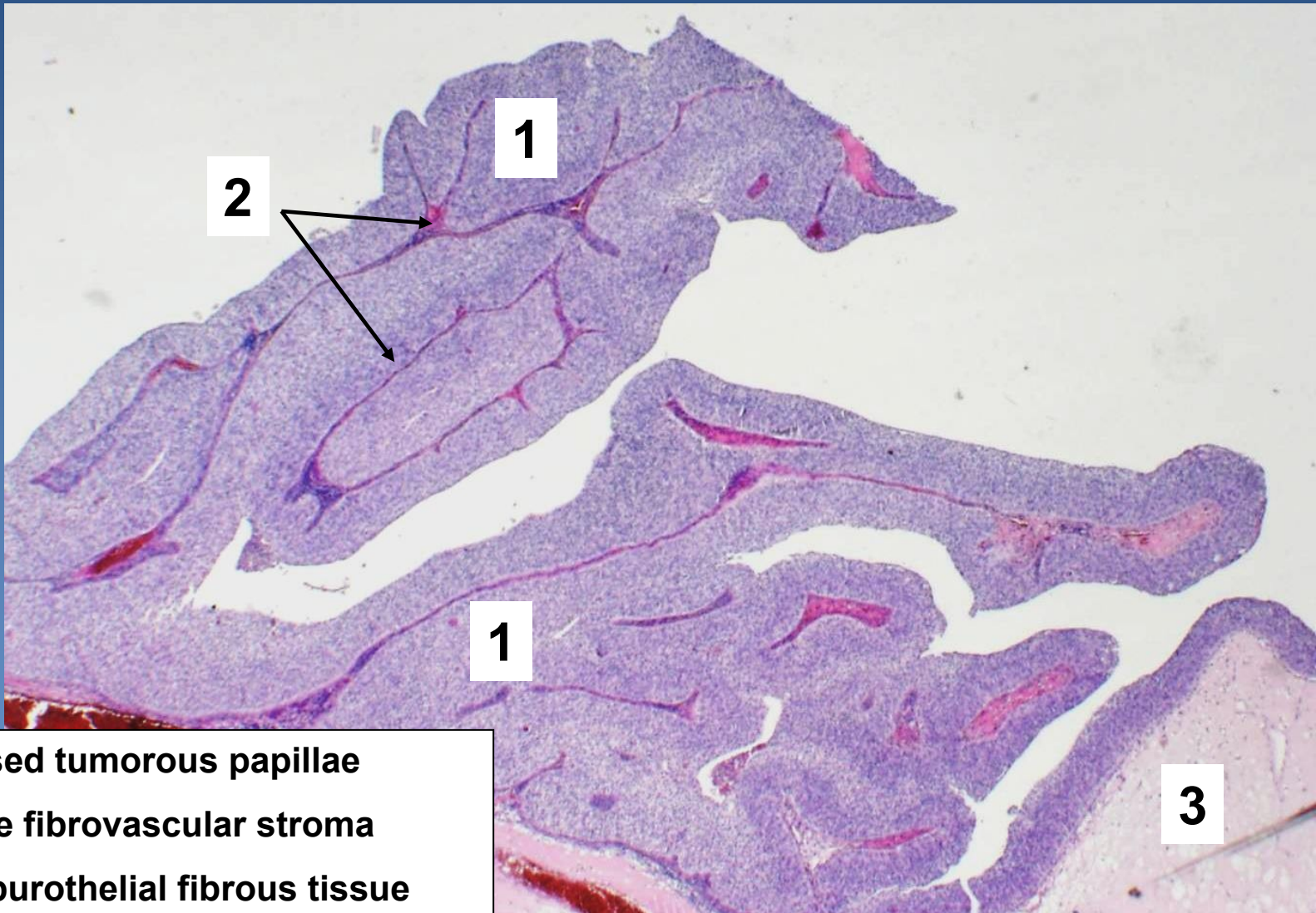
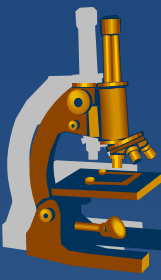
1 Mesangial nodules
2 Diffuse expansion of mesangial matrix

68. *Benign nephrosclerosis*



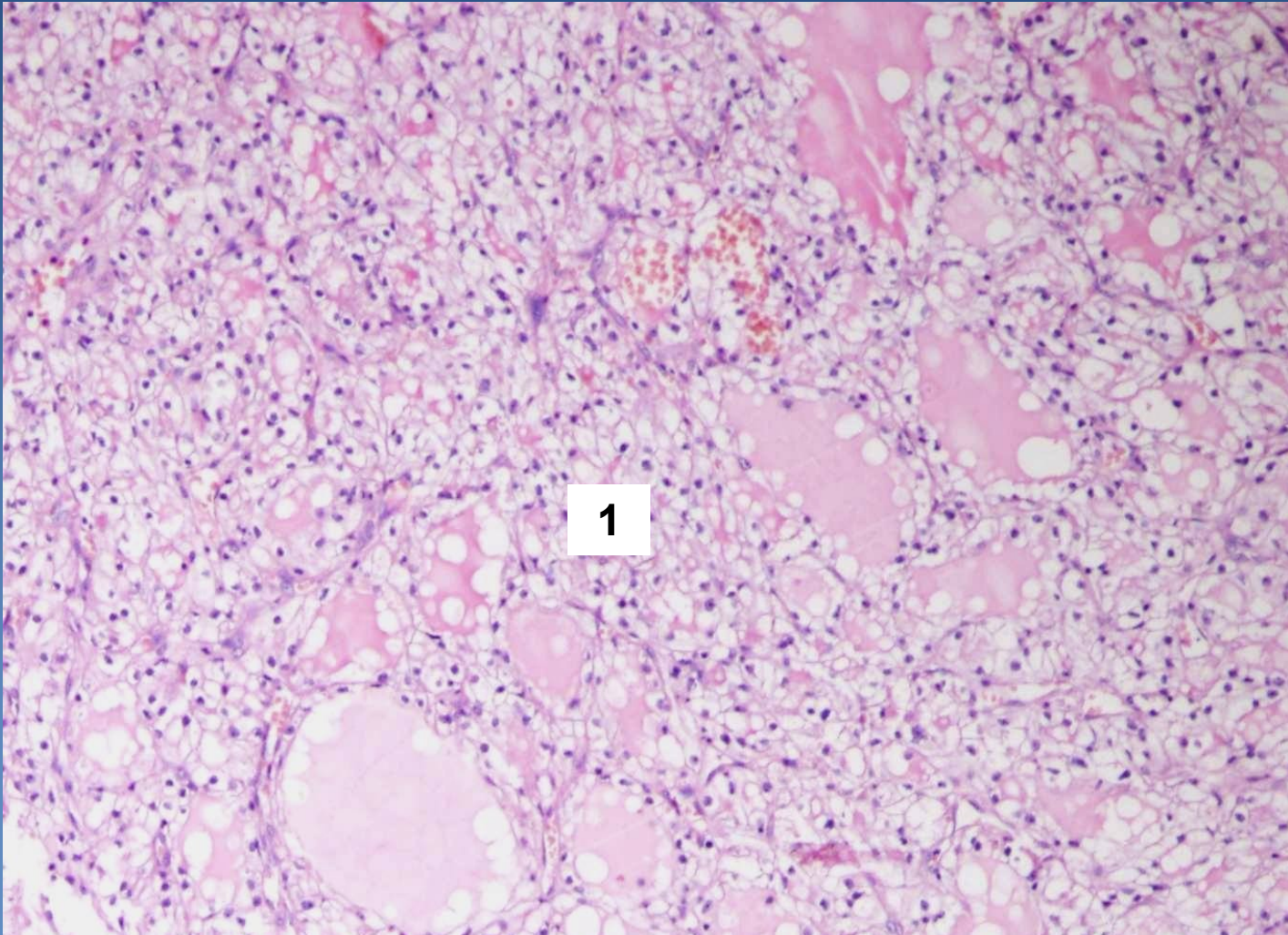
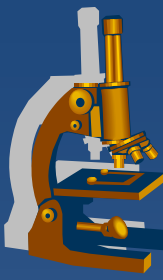
1 Sclerotic glomerulus
2 Hypertrophy of the media and sclerosis of the intima of artery
3 Interstitial fibrotisation

69. Papillary urothelial carcinoma, low grade



1. Fused tumorous papillae
2. Fine fibrovascular stroma
3. Suburothelial fibrous tissue

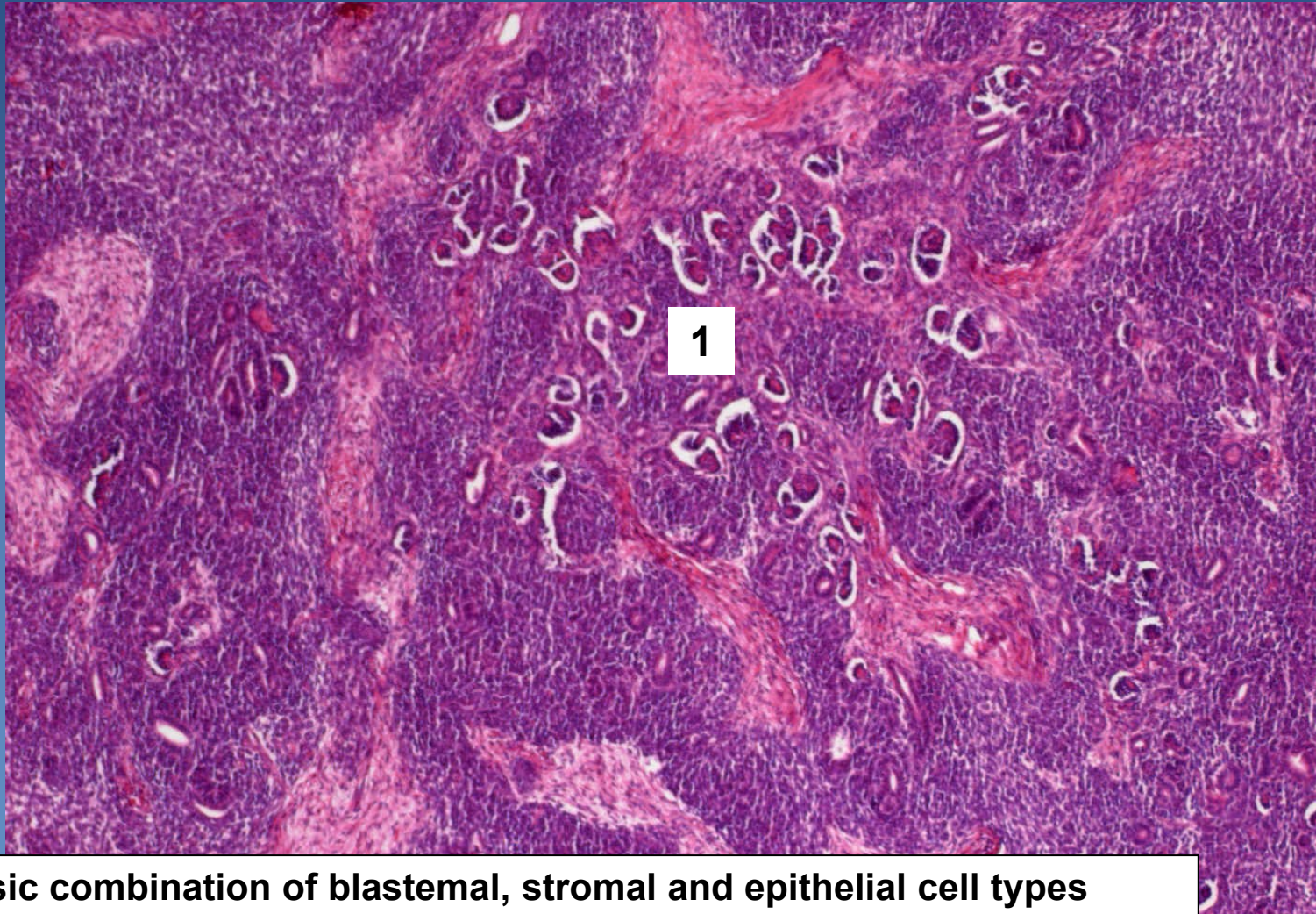
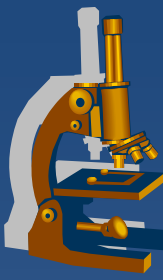
70. Clear cell renal cell carcinoma (Grawitz tumor)



1

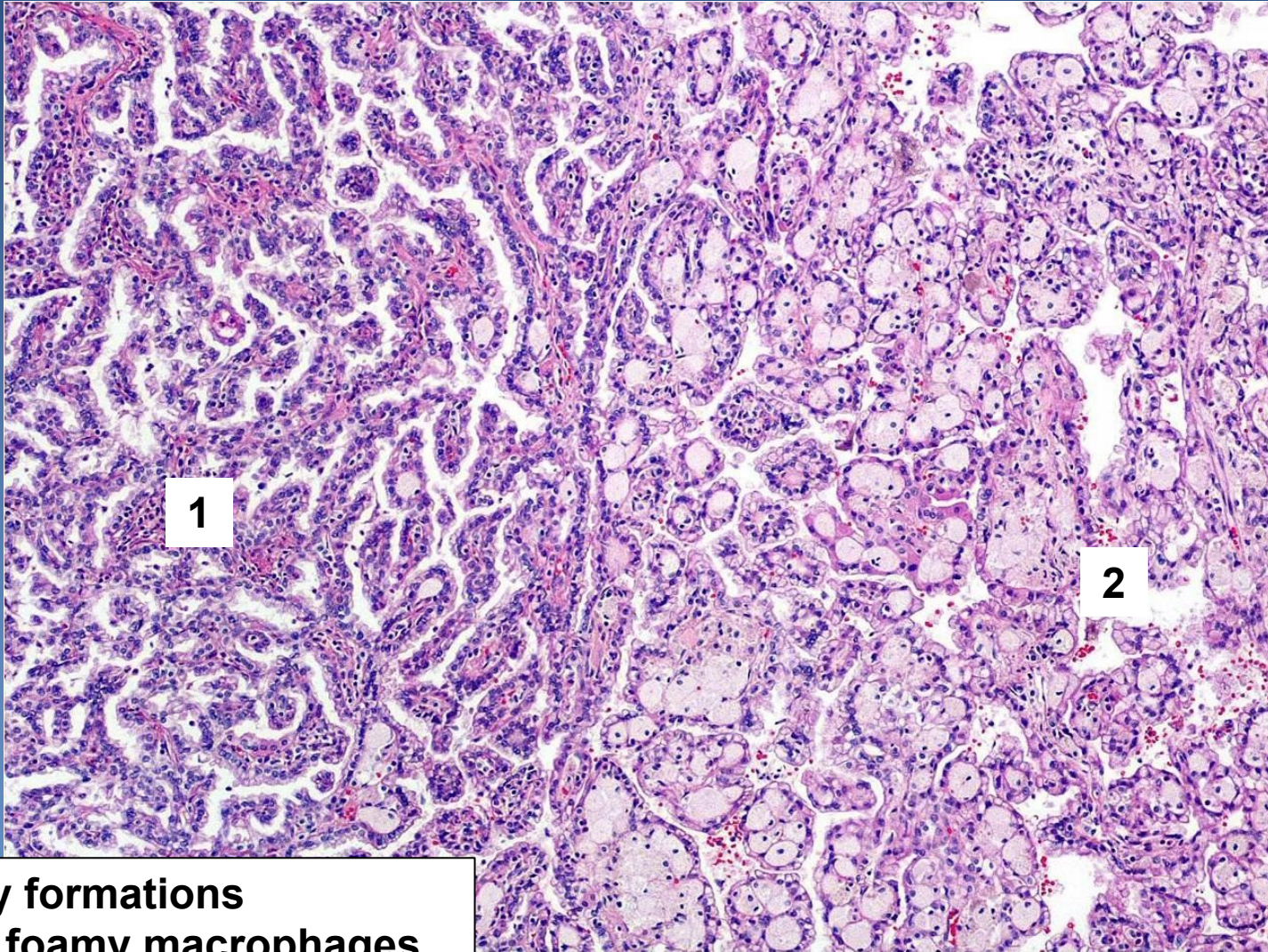
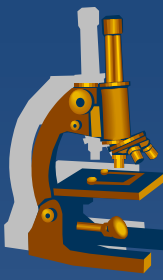
1 Large cells with clear granular cytoplasm (glycogen and lipid deposits)

71. Nephroblastoma (Wilms' tumor)



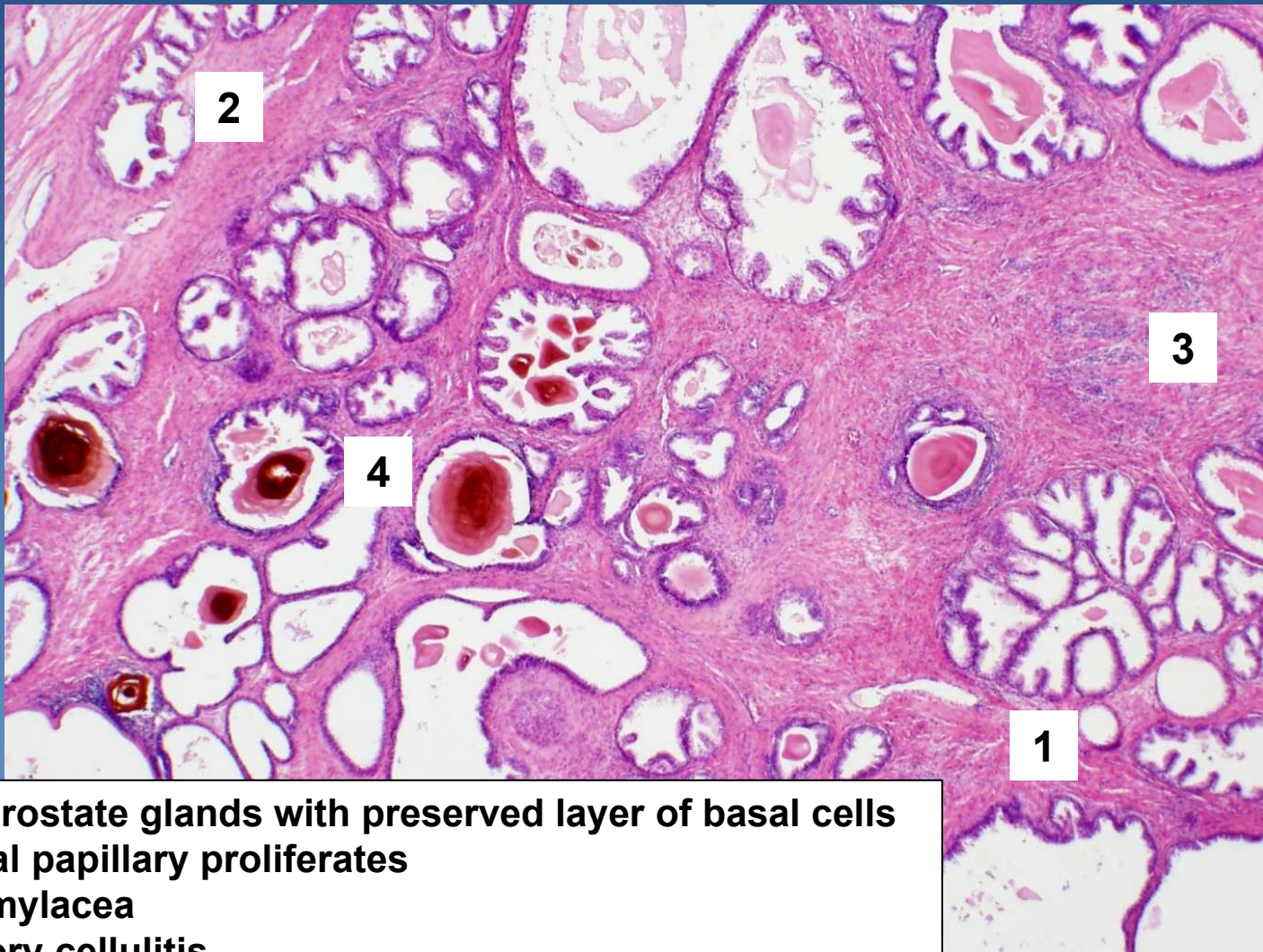
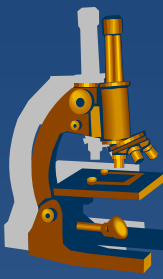
1 Triphasic combination of blastemal, stromal and epithelial cell types

72. Papillary renal cell carcinoma



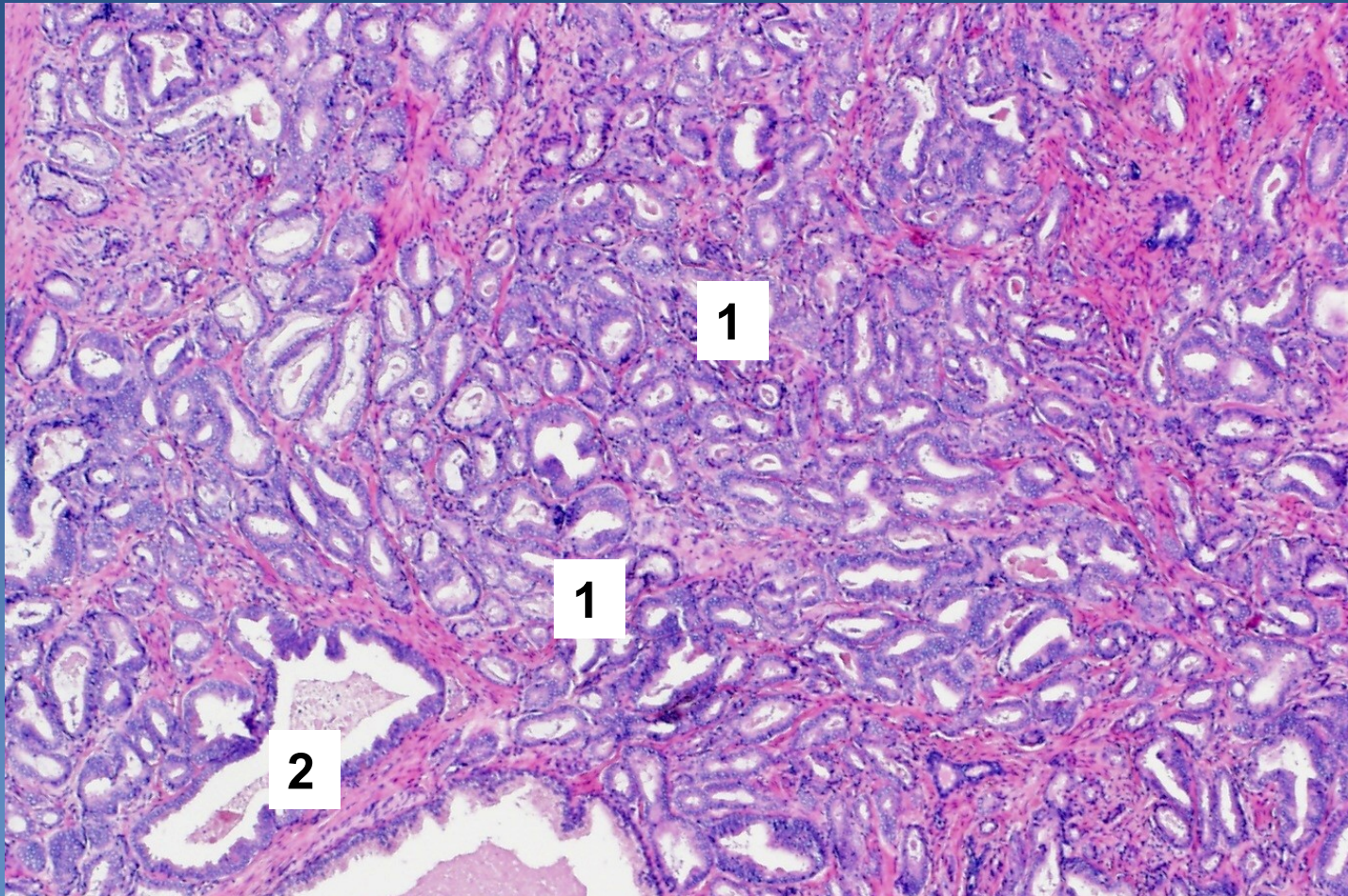
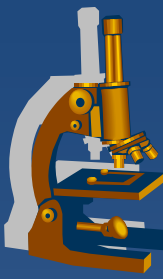
1 Papillary formations
2 Stromal foamy macrophages

73. Benign prostatic hyperplasia



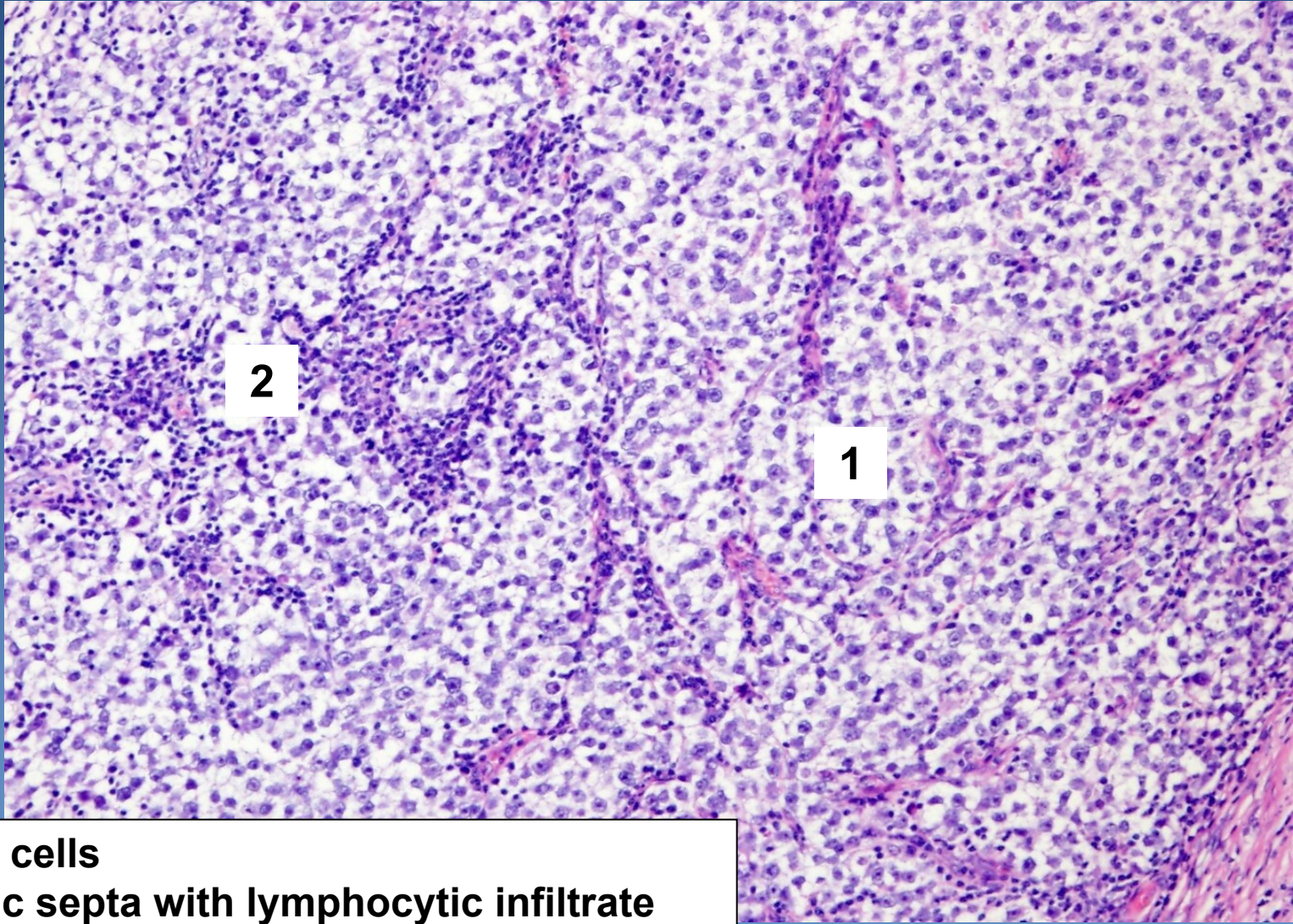
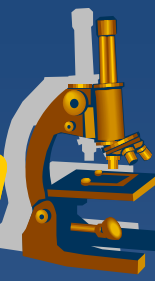- 1 Enlarged prostate glands with preserved layer of basal cells
- 2 Intraluminal papillary proliferates
- 3 Corpora amylacea
- 4 Inflammatory cellulitis

74. Acinar prostatic adenocarcinoma



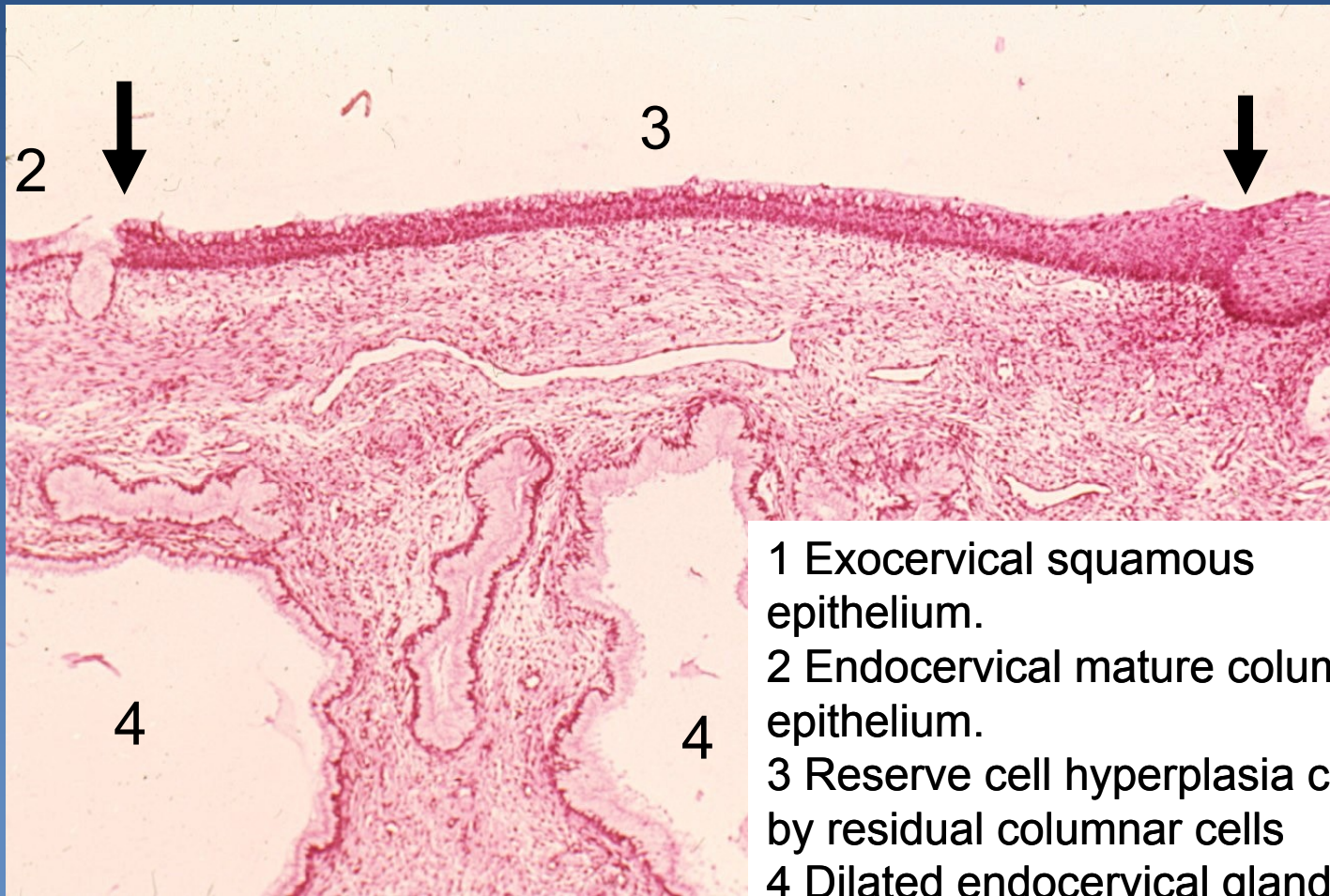
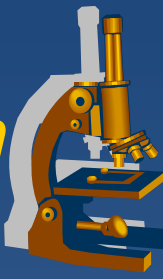- 1 Small neoplastic glands without preserved layer of basal cells
- 2 Neoplastic acini growing between prostatic glands

75. Testicular seminoma



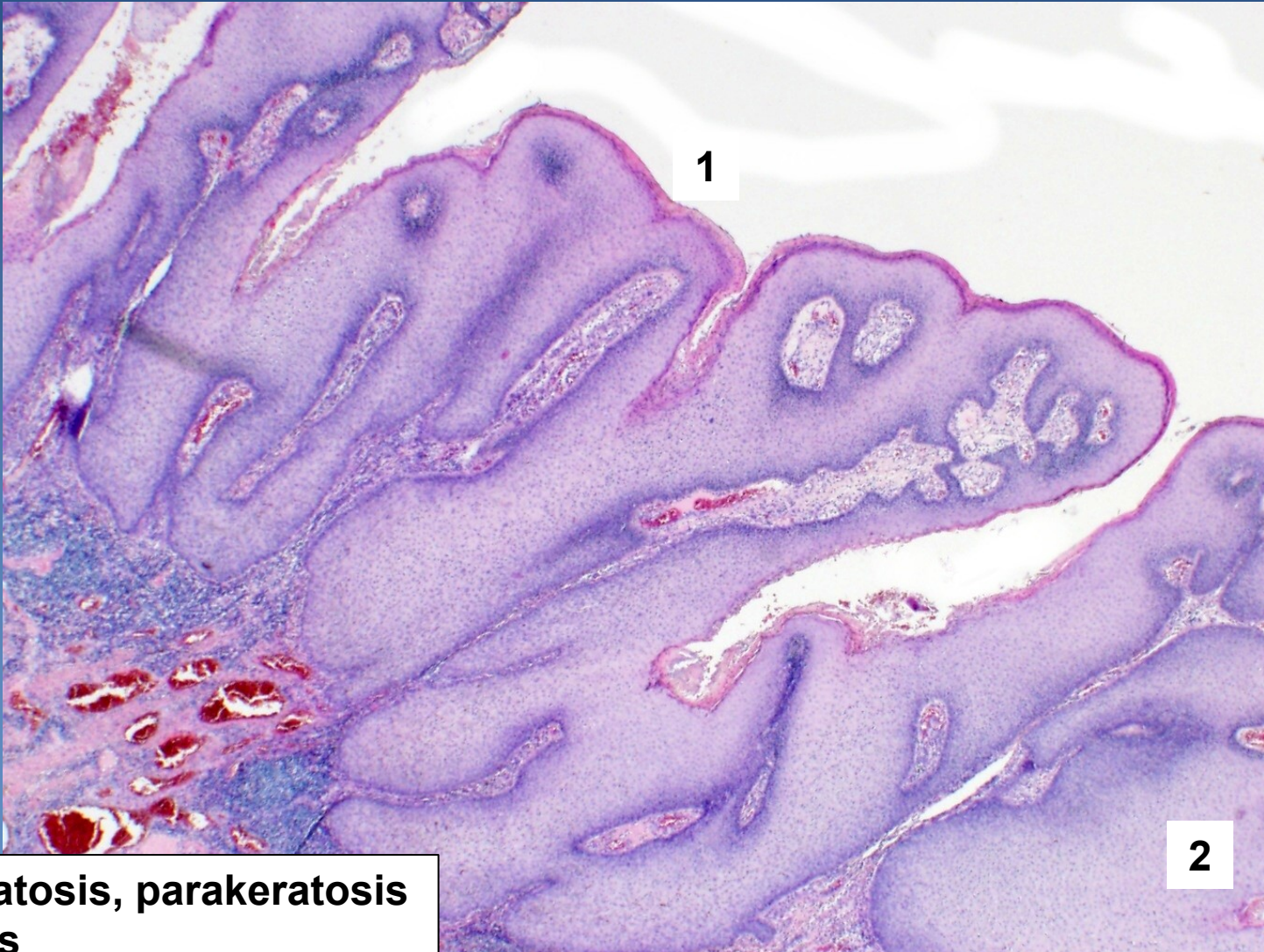
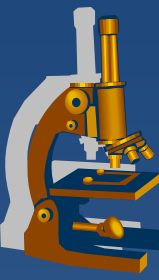
1 Tumor cells
2 Fibrotic septa with lymphocytic infiltrate

76. Squamous metaplasia with Nabothian cysts



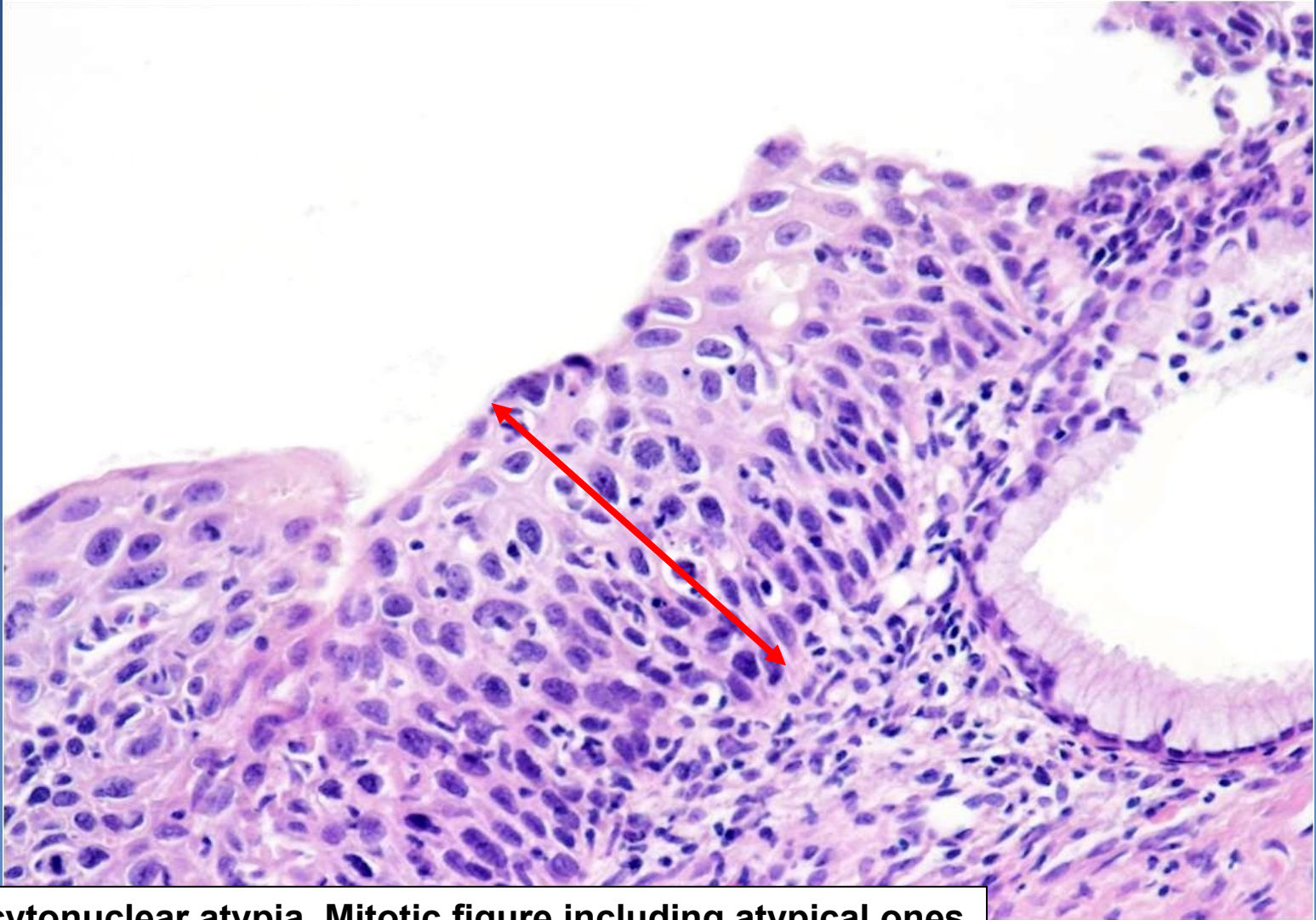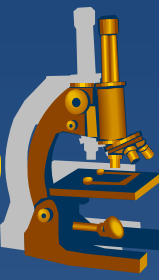
- 1 Exocervical squamous epithelium.
- 2 Endocervical mature columnar epithelium.
- 3 Reserve cell hyperplasia covered by residual columnar cells
- 4 Dilated endocervical glands (Nabothian cysts)

77. *Condyloma accuminatum*



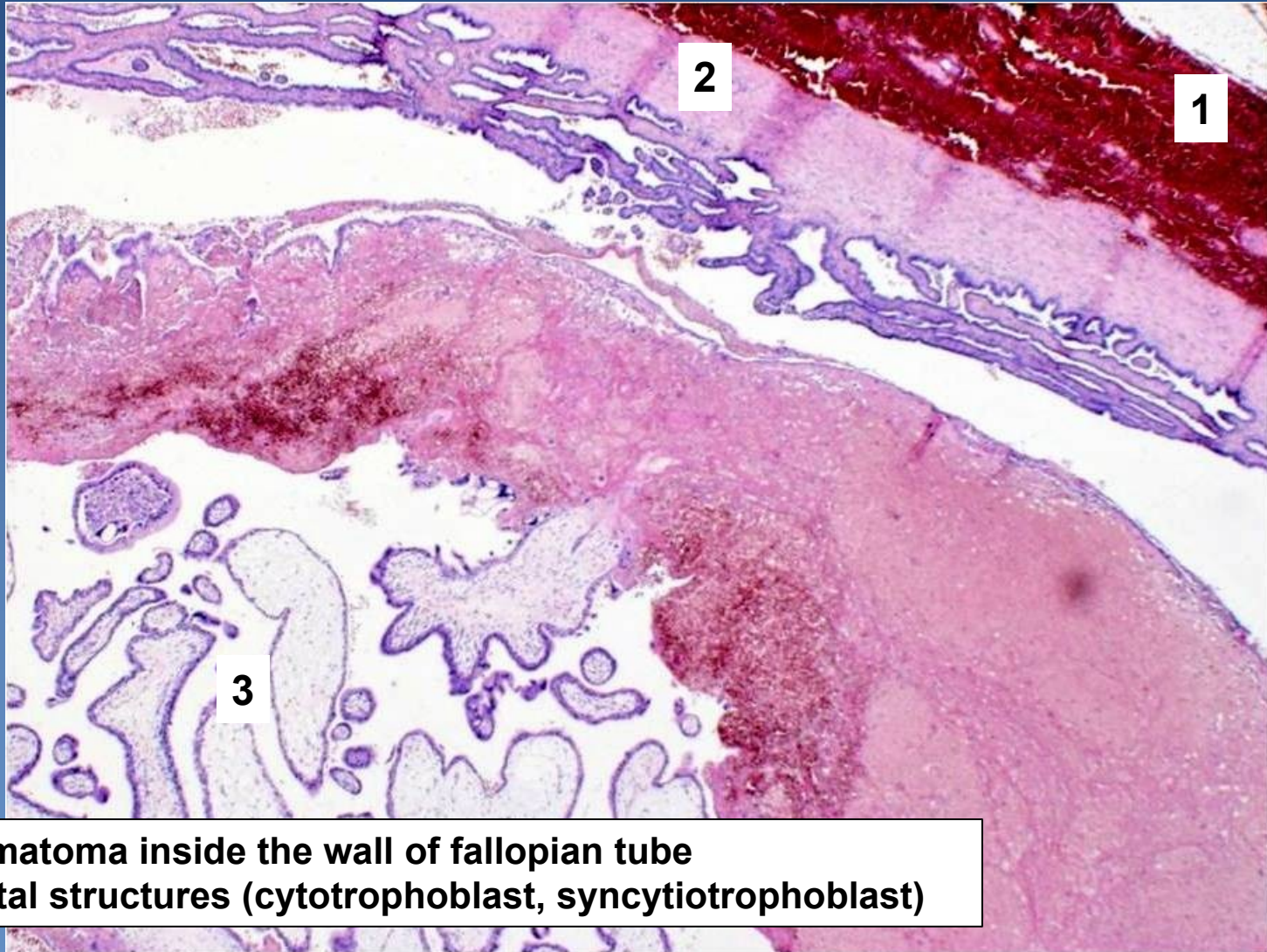
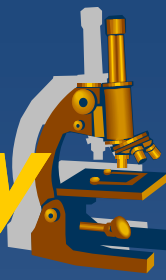
1 Hyperkeratosis, parakeratosis
2 Koilocytes

78. HSIL (High-grade CIN)



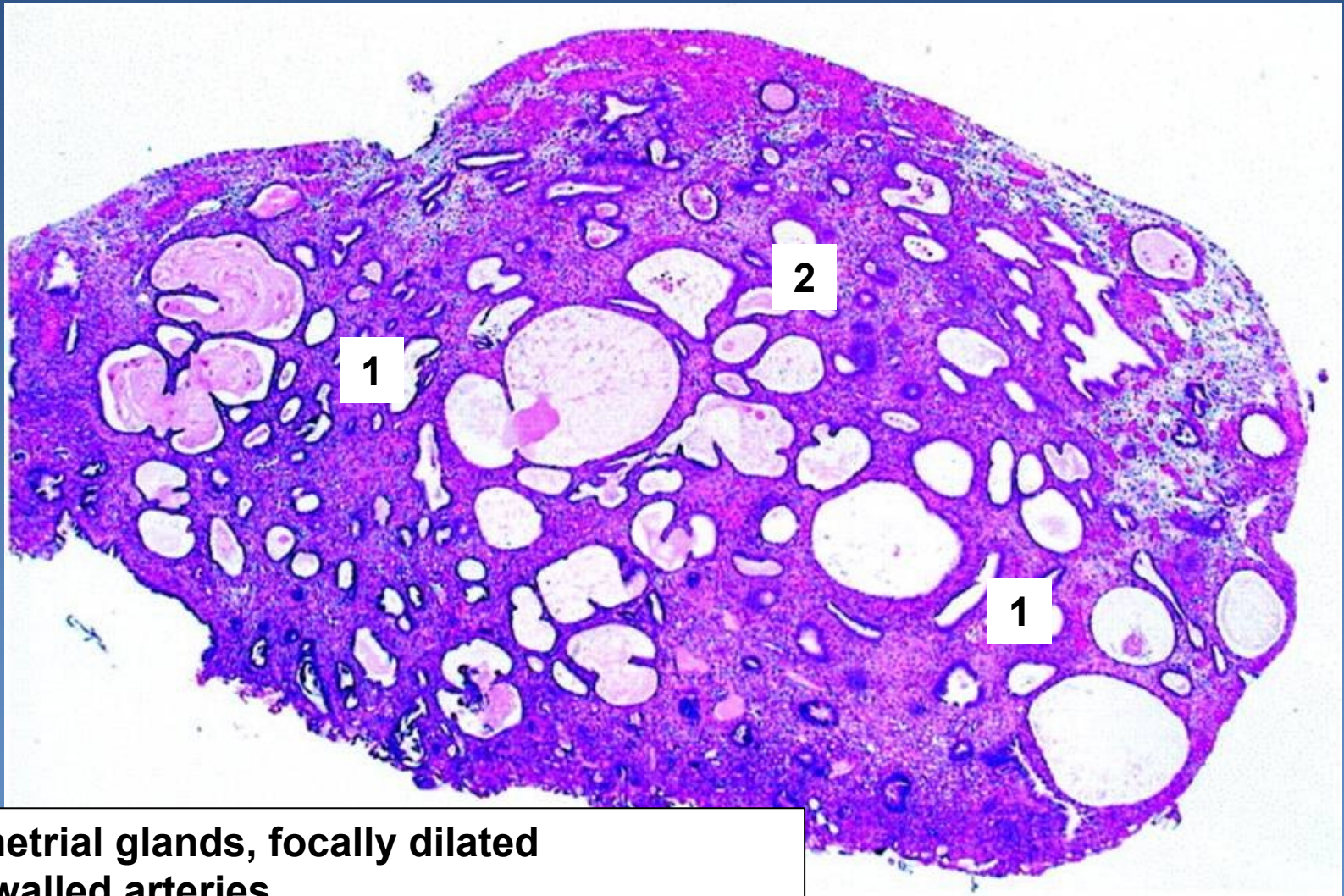
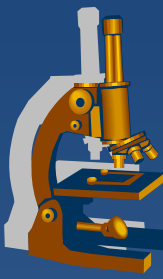
Diffuse cytonuclear atypia. Mitotic figure including atypical ones

79. Ectopic tubal pregnancy



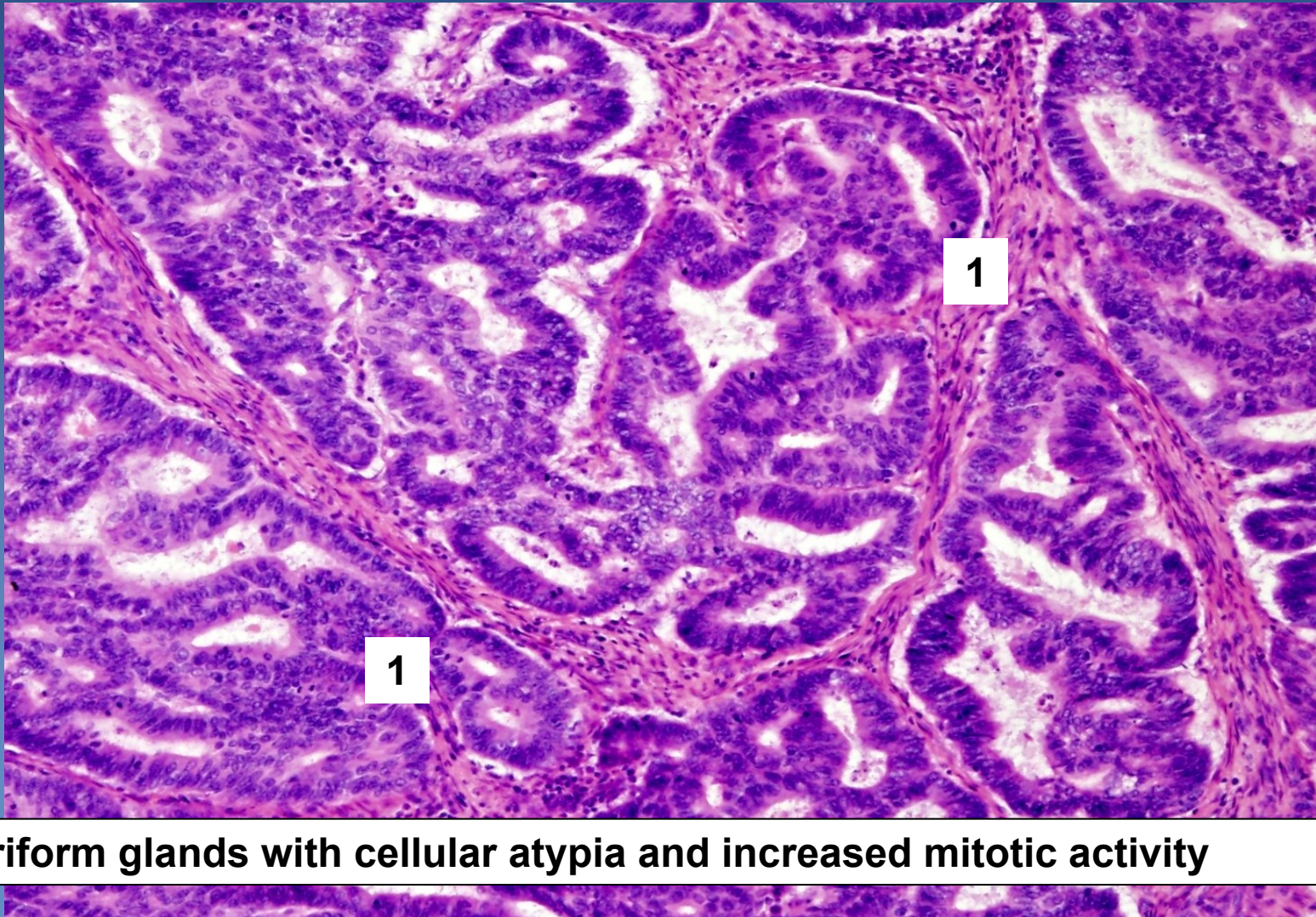
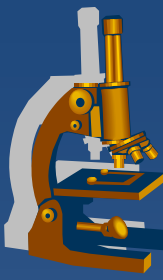
1+2 Haematoma inside the wall of fallopian tube
3 Placental structures (cytotrophoblast, syncytiotrophoblast)

80. Endometrial polyp



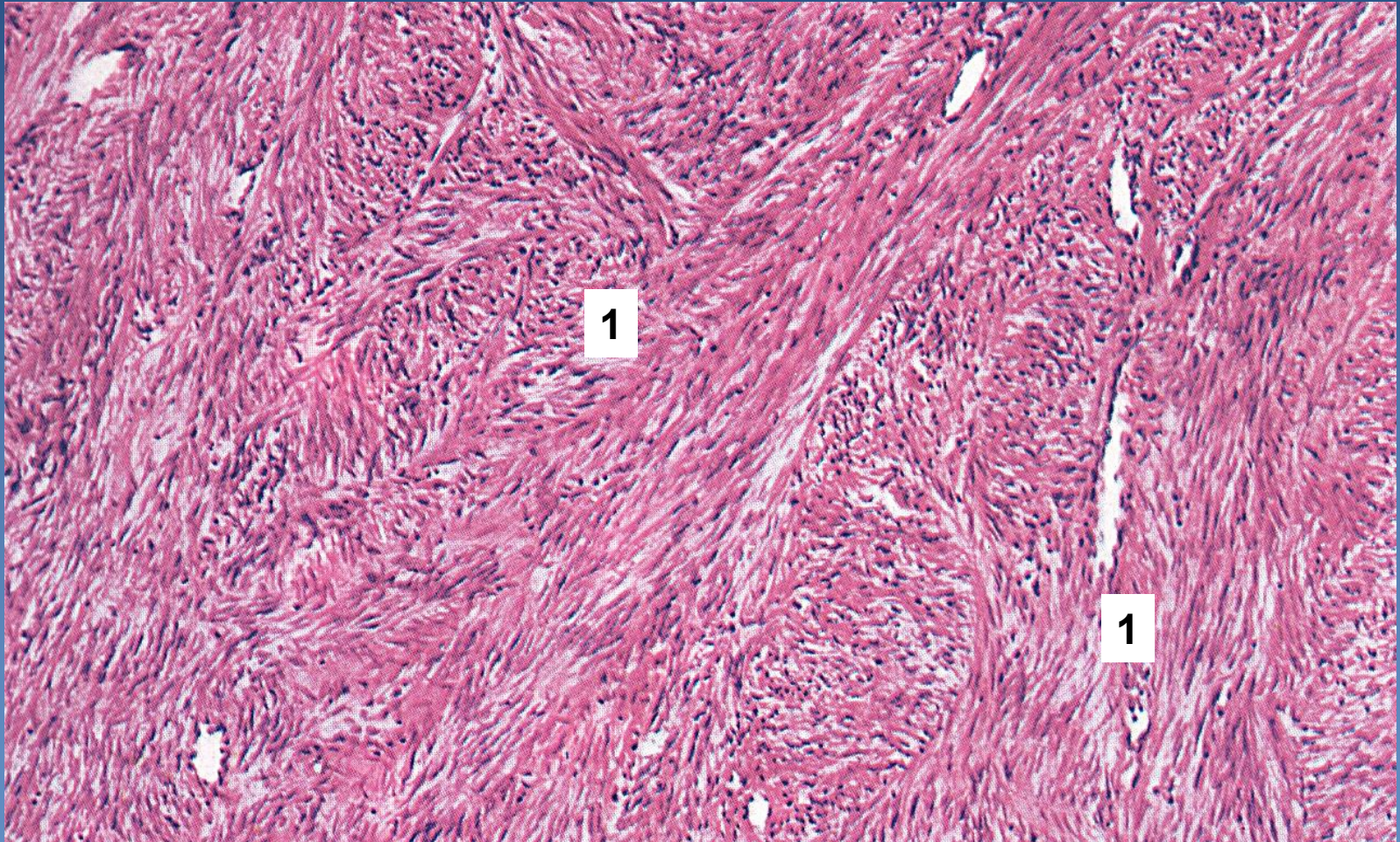
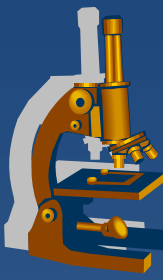
- 1 Endometrial glands, focally dilated
- 2 Thick-walled arteries

81. Endometrioid adenocarcinoma



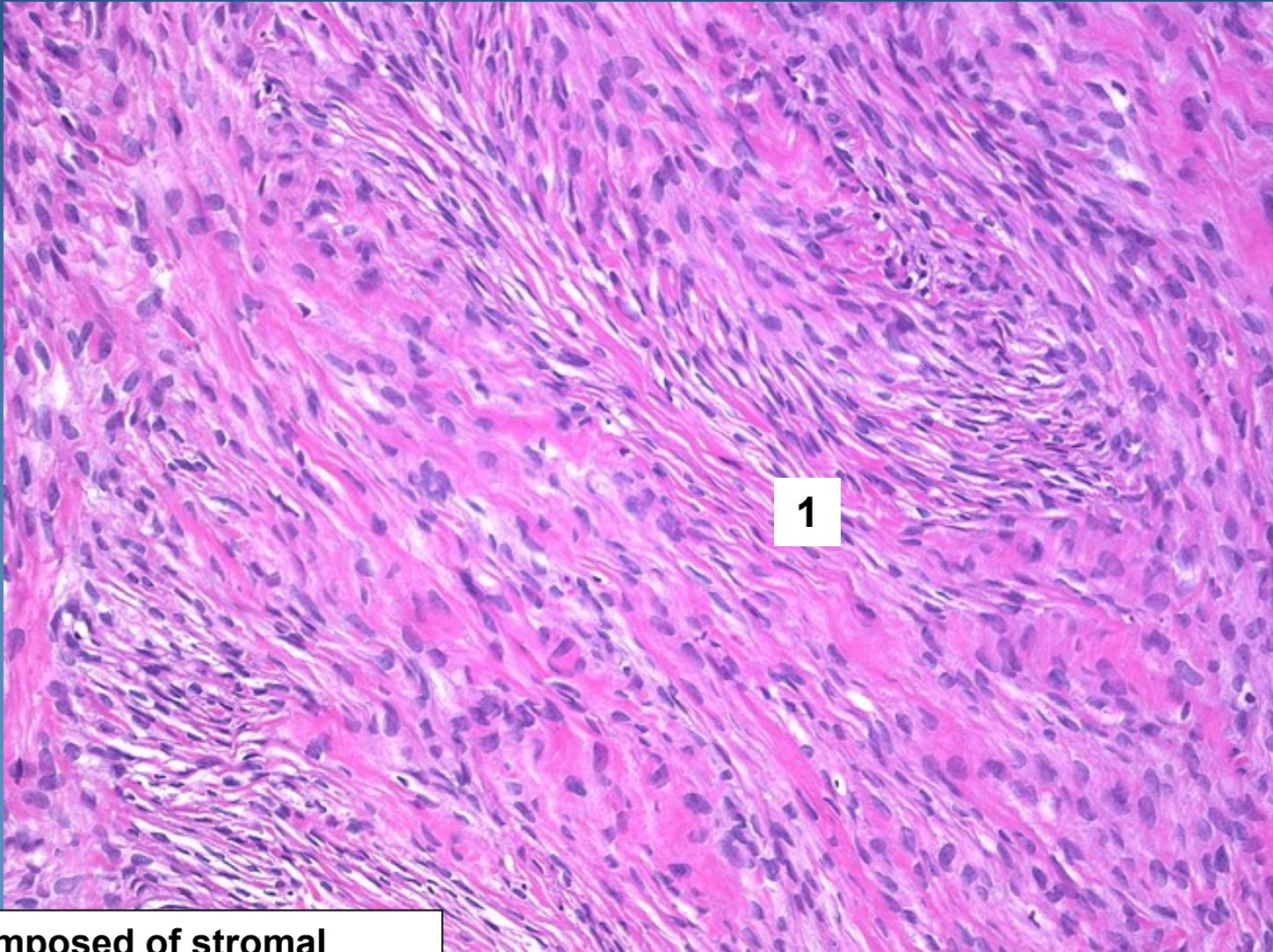
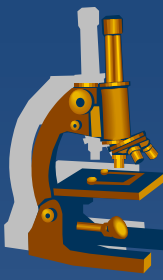
1 Cribriform glands with cellular atypia and increased mitotic activity

82. *Leiomyoma uteri*



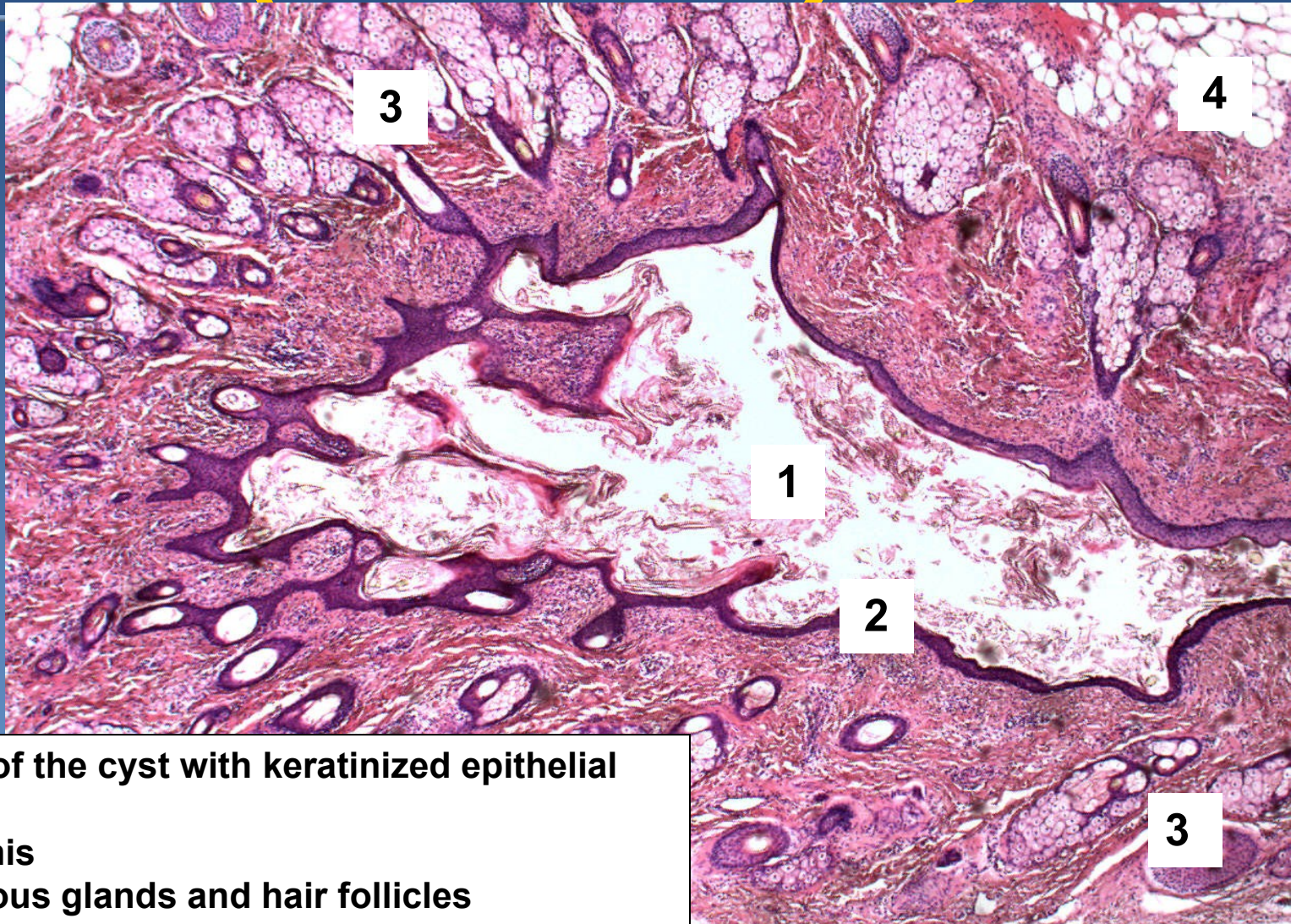
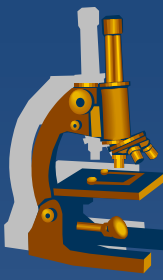
1 Spindle smooth muscle cells, elongated nuclei with rounded ends („cigar shaped nuclei“), fascicular structure. No atypia/necrosis/mitosis.

83. Ovarian fibroma



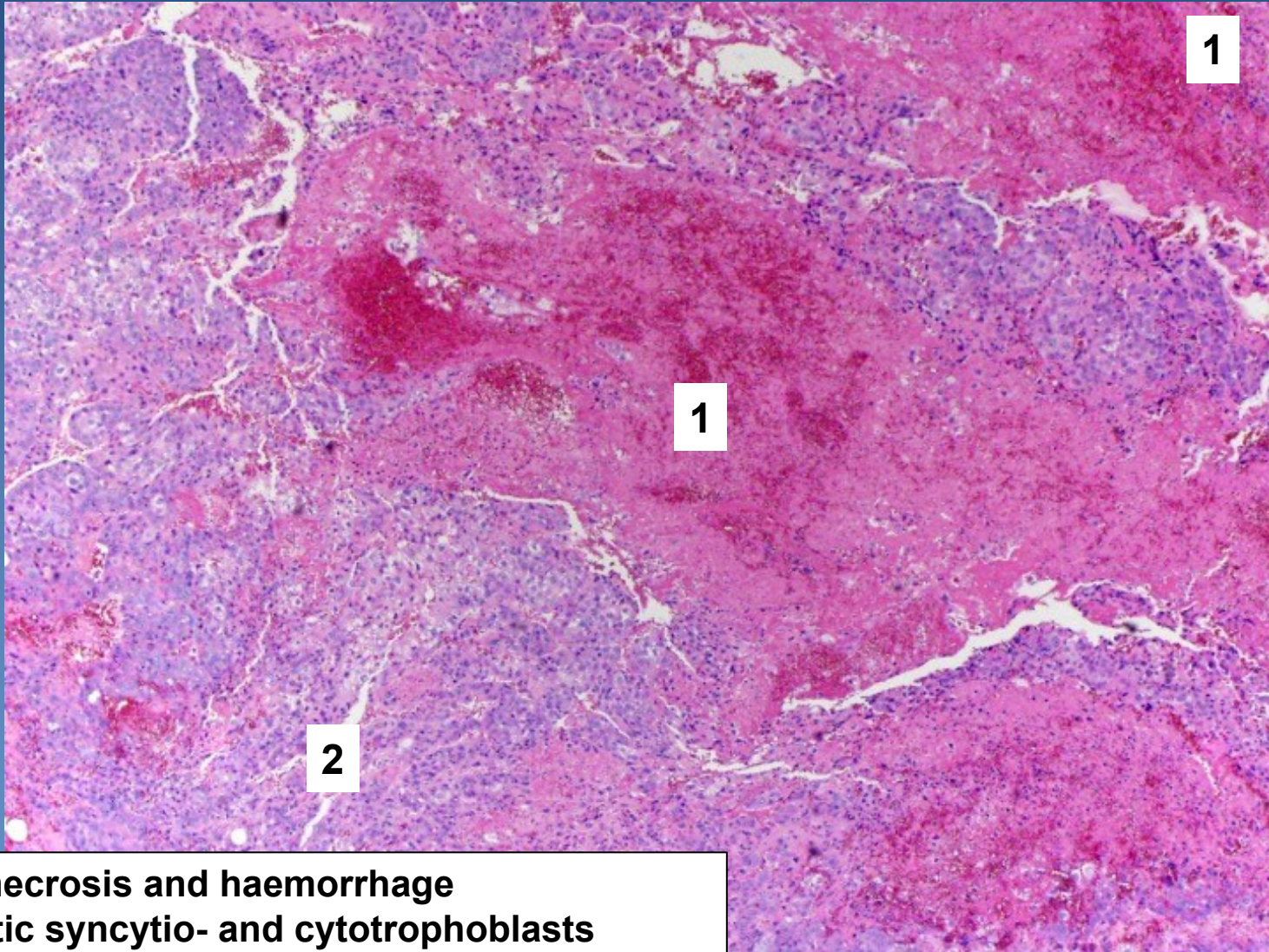
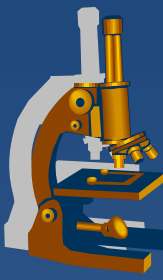
1 Tumor composed of stromal

84. Mature teratoma (dermoid cyst)



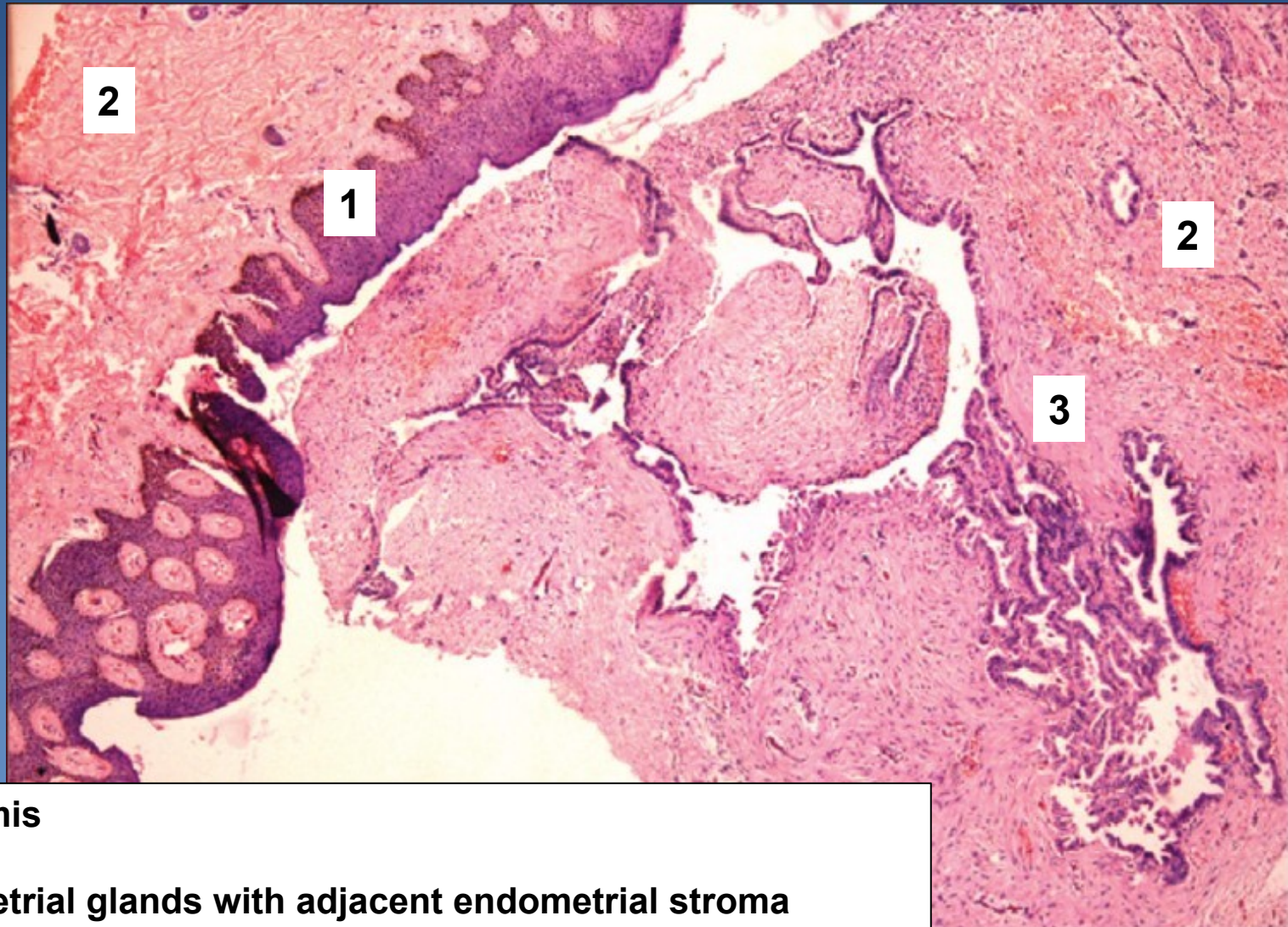
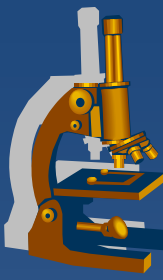
- 1 Lumen of the cyst with keratinized epithelial cells
- 2 Epidermis
- 3 Sebaceous glands and hair follicles
- 4 Adipose tissue

85. Choriocarcinoma – metastasis in skin



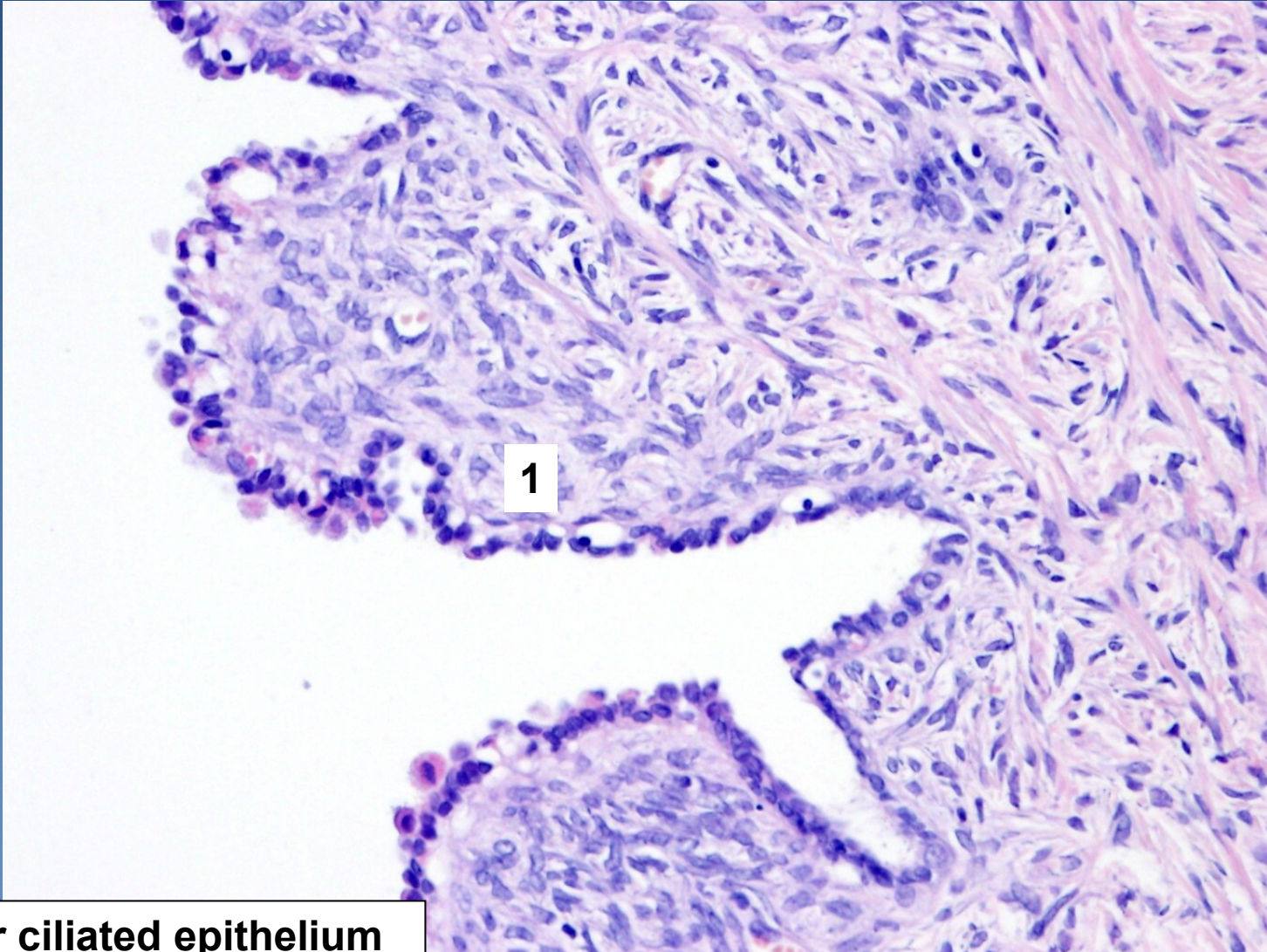
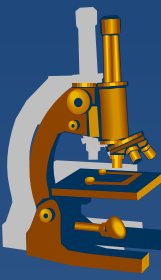
1 Foci of necrosis and haemorrhage
2 Anaplastic syncytio- and cytotrophoblasts

86. Endometriosis (in navel)



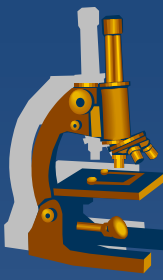
1 Epidermis
2 Dermis
3 Endometrial glands with adjacent endometrial stroma

87. Ovarian serous cystadenoma

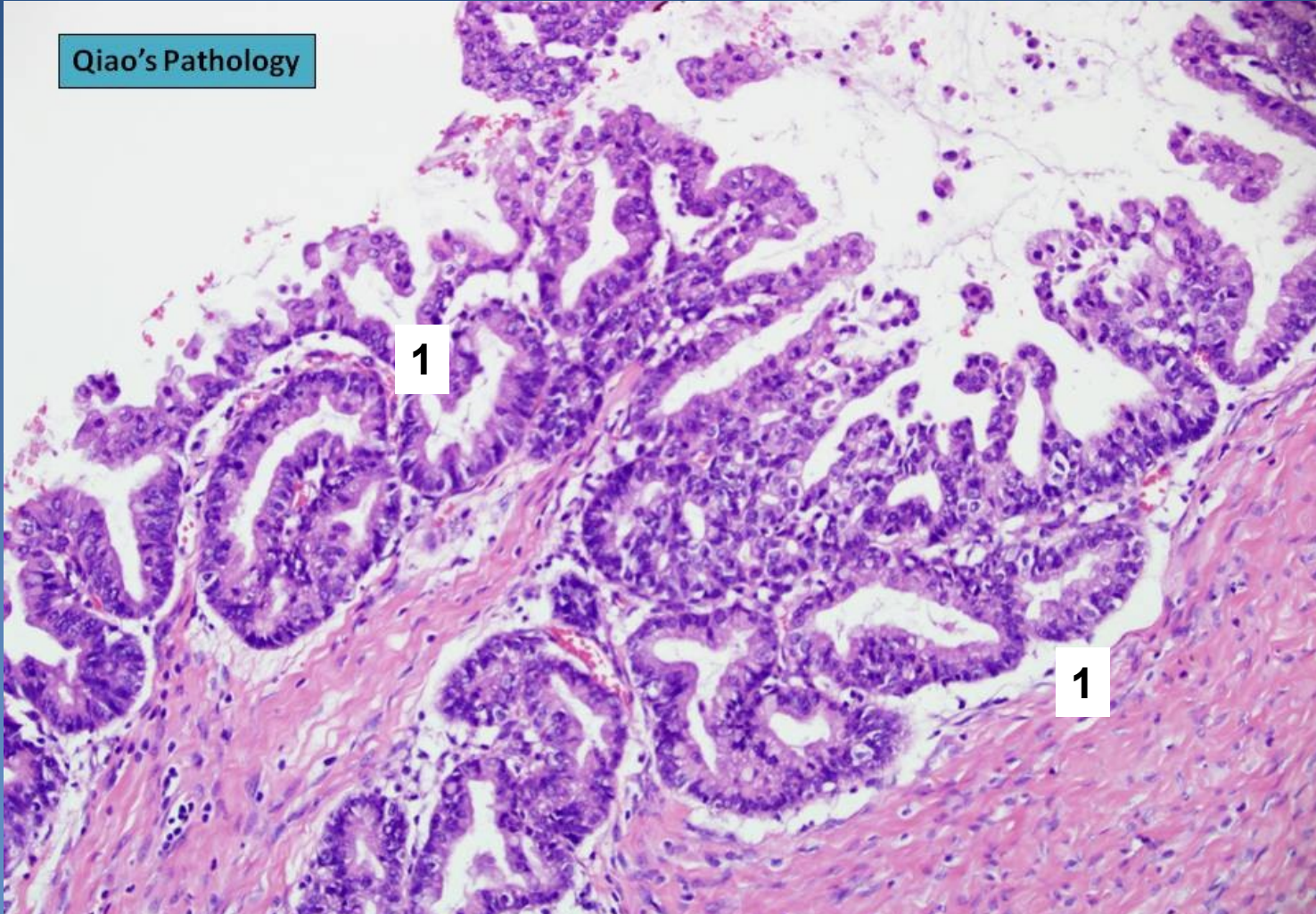


1 Columnar ciliated epithelium

88. Ovarian mucinous cystadenocarcinoma

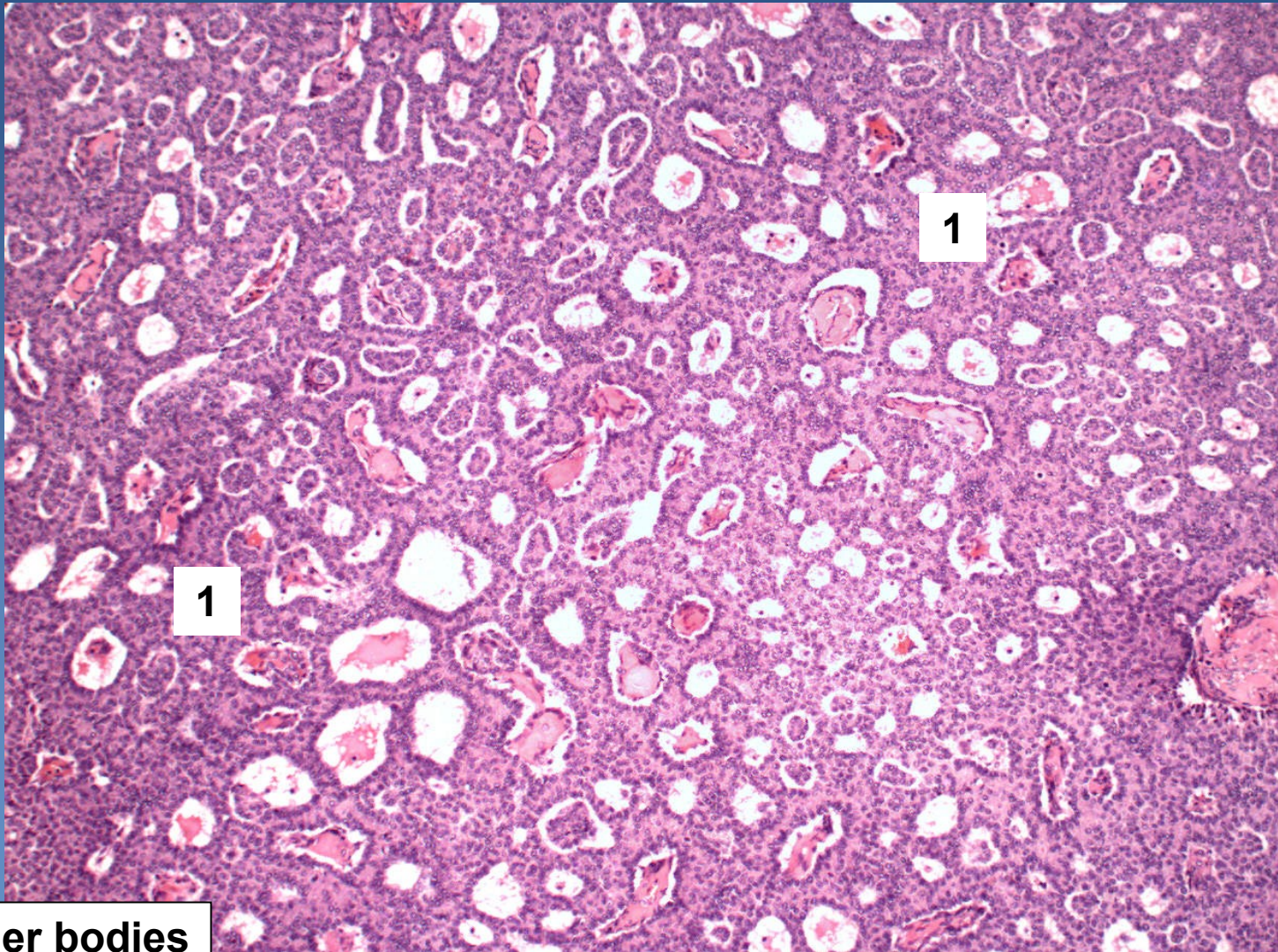
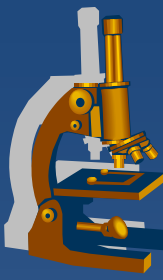


Qiao's Pathology



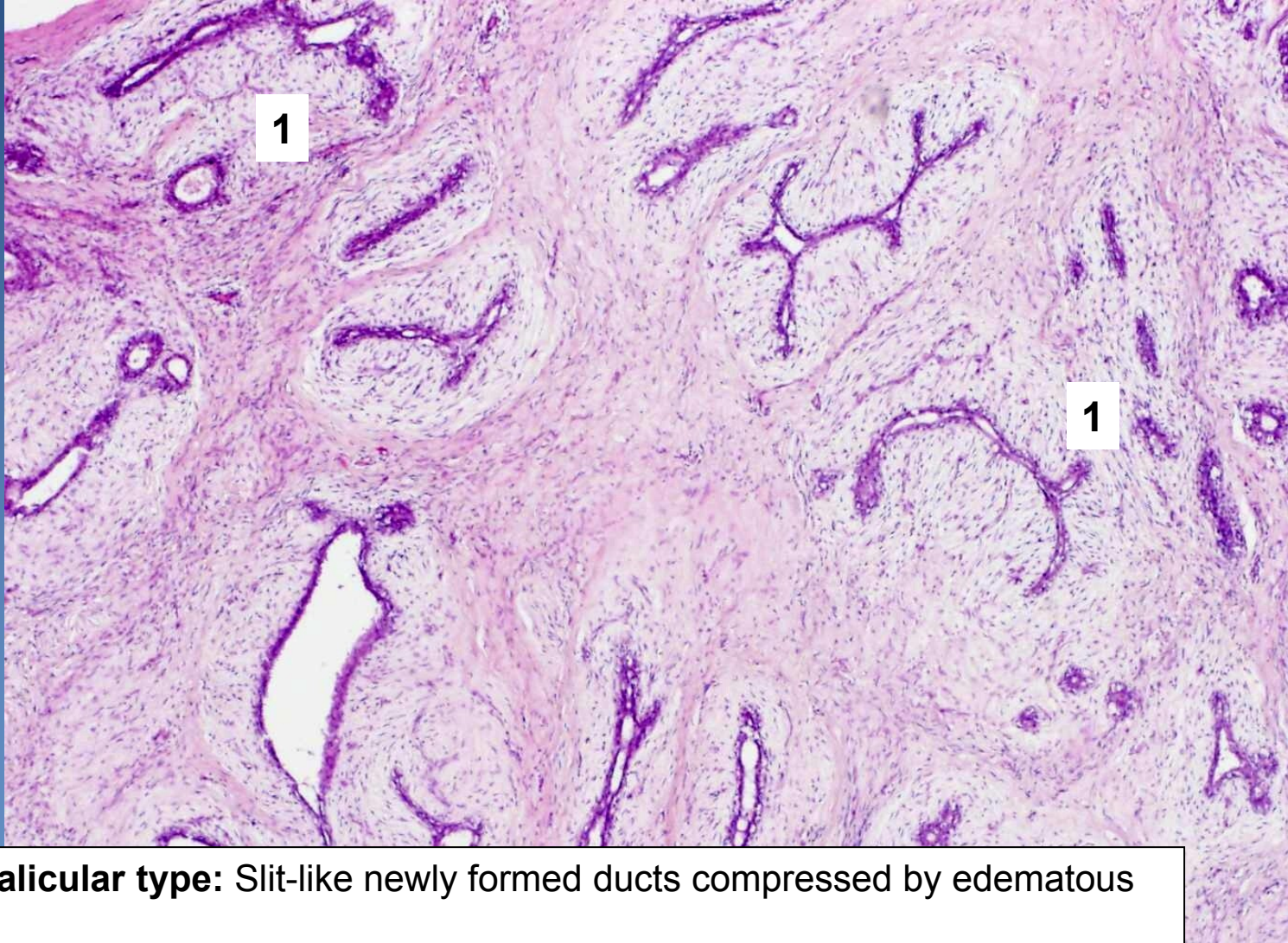
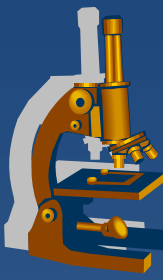
1 Columnar mucinous epithelium with cytonuclear atypia and mitoses

89. Granulosa cell tumor



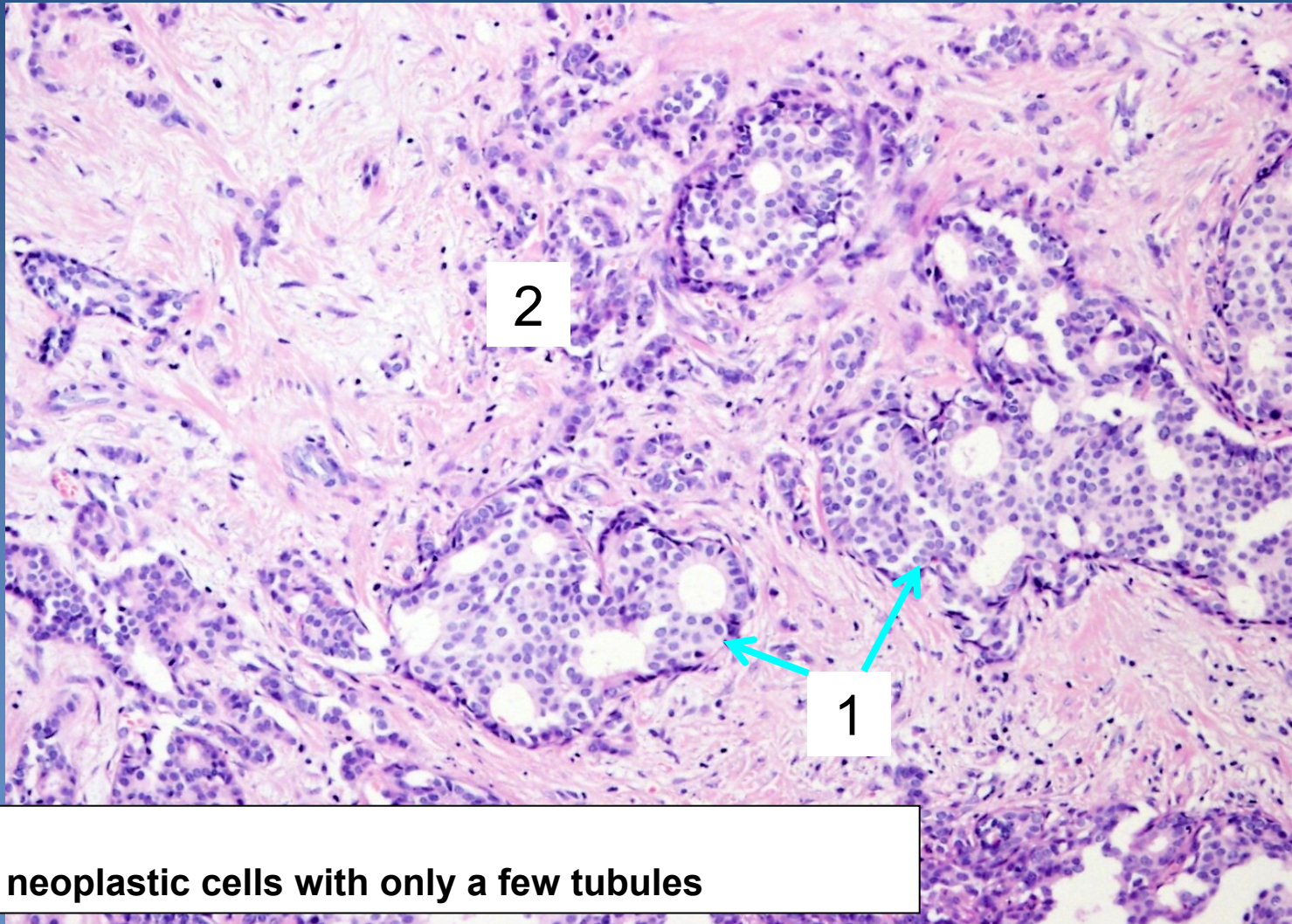
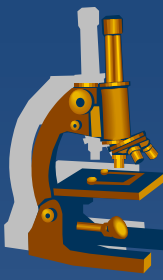
1 Call-Exner bodies

90. Fibroadenoma of mammary



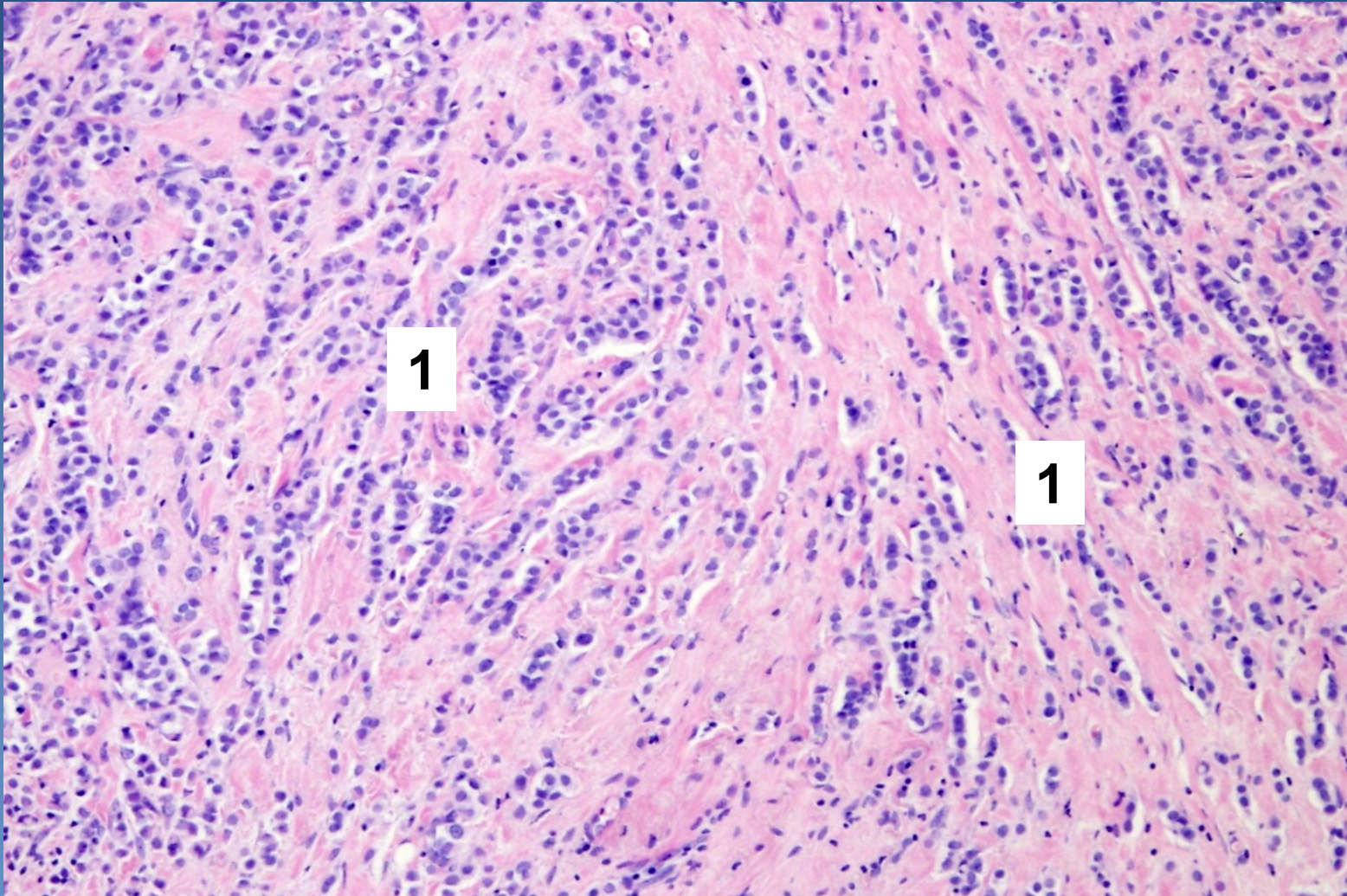
1 Intracanalicular type: Slit-like newly formed ducts compressed by edematous stroma

91. *Invazive carcinoma, NOS, of mamma (formerly known as invasive ductal cacrinoma)*



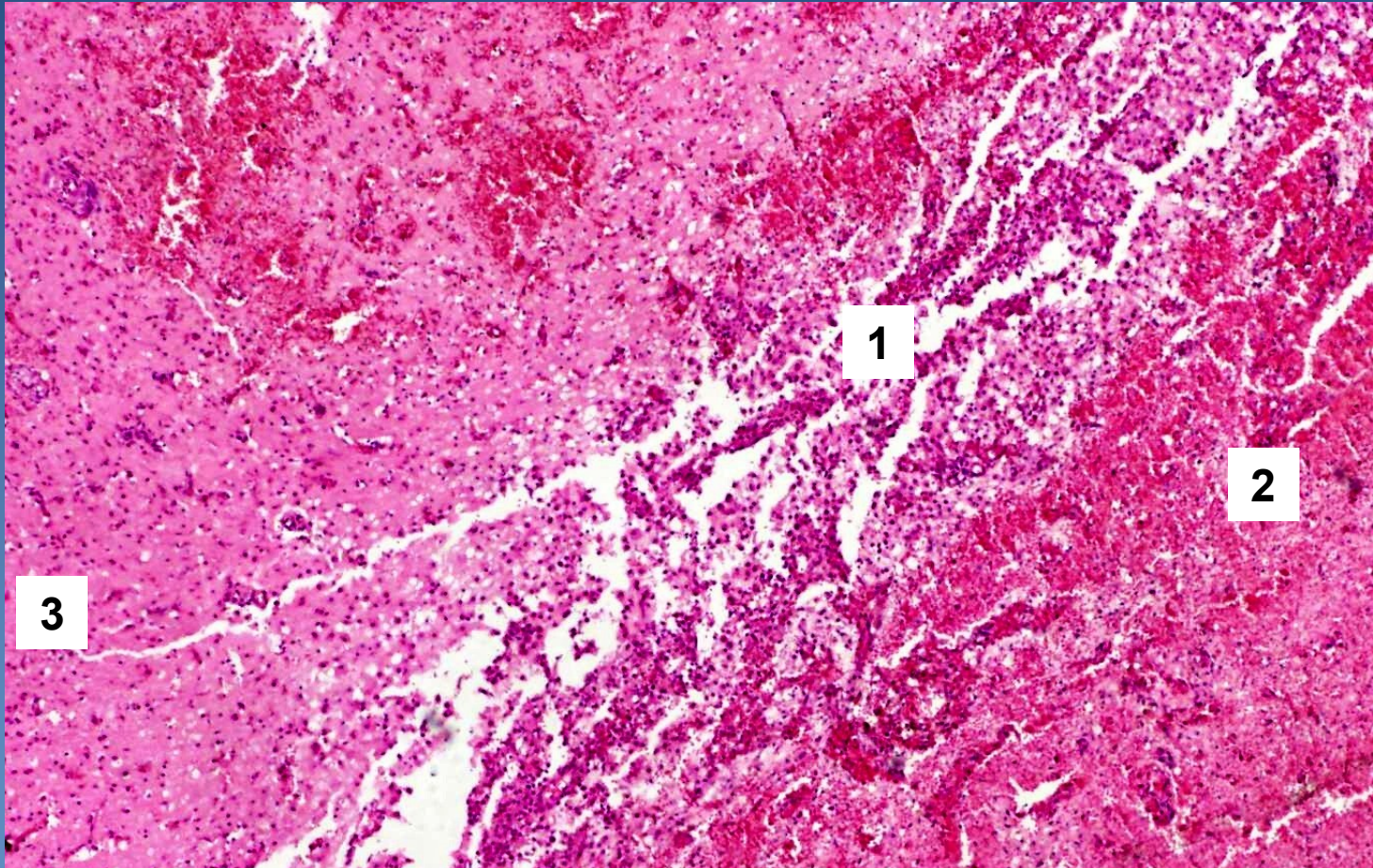
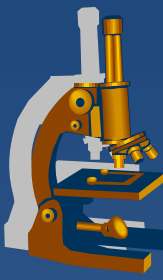
- 1 DCIS
- 2 Cohesive neoplastic cells with only a few tubules

92. *Invasive lobular carcinoma of mamma*

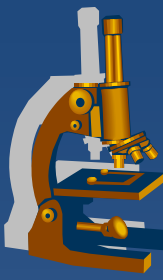


1 Dyscohesive tumor cells forming single linear files („Indian file“)

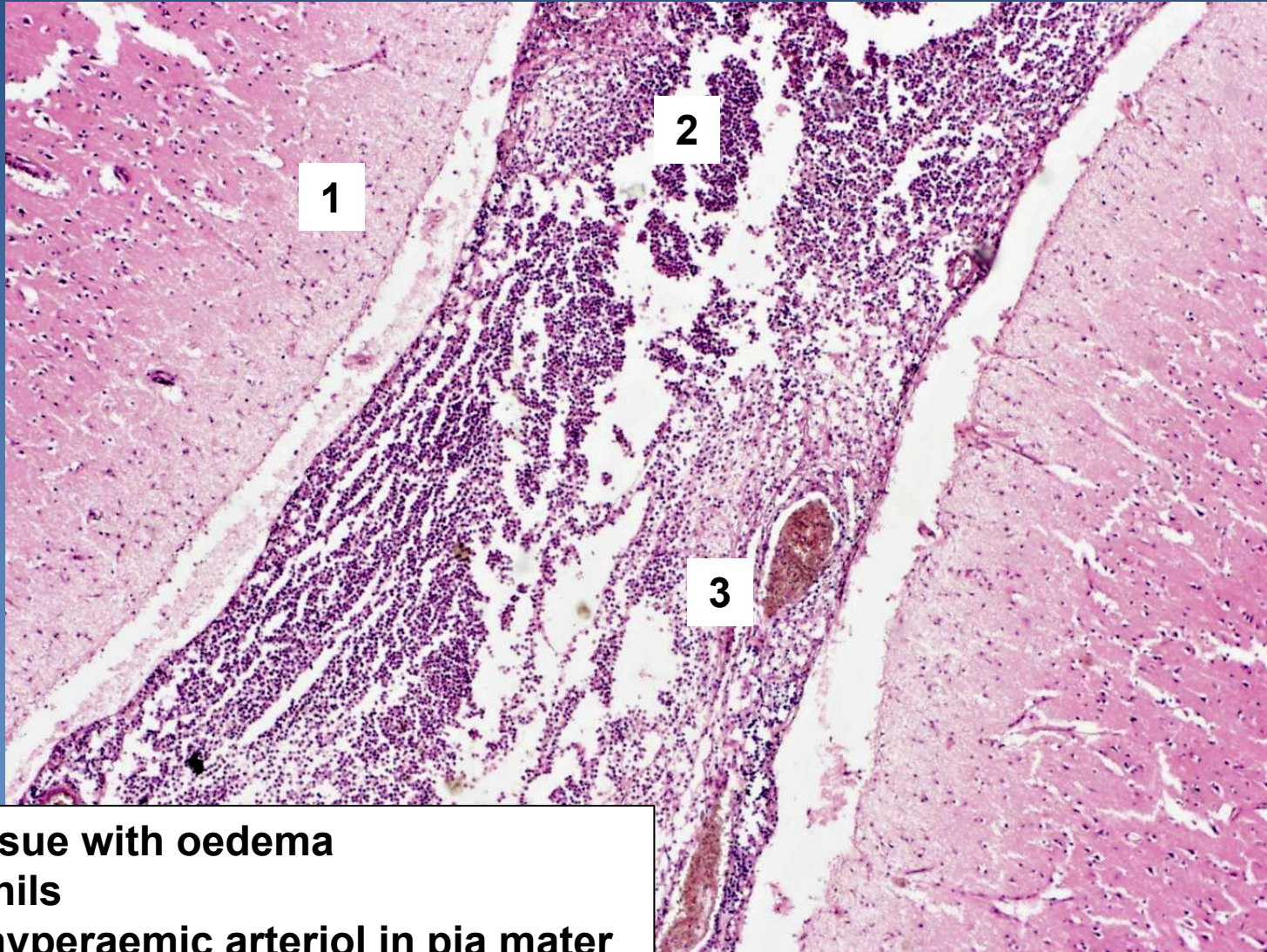
93. *Encefalomalatia* (of older date)



- 1 Macrophages with intracytoplasmic deposits of lipid products of myelin breakdown
- 2 Haemorrhagic infarction

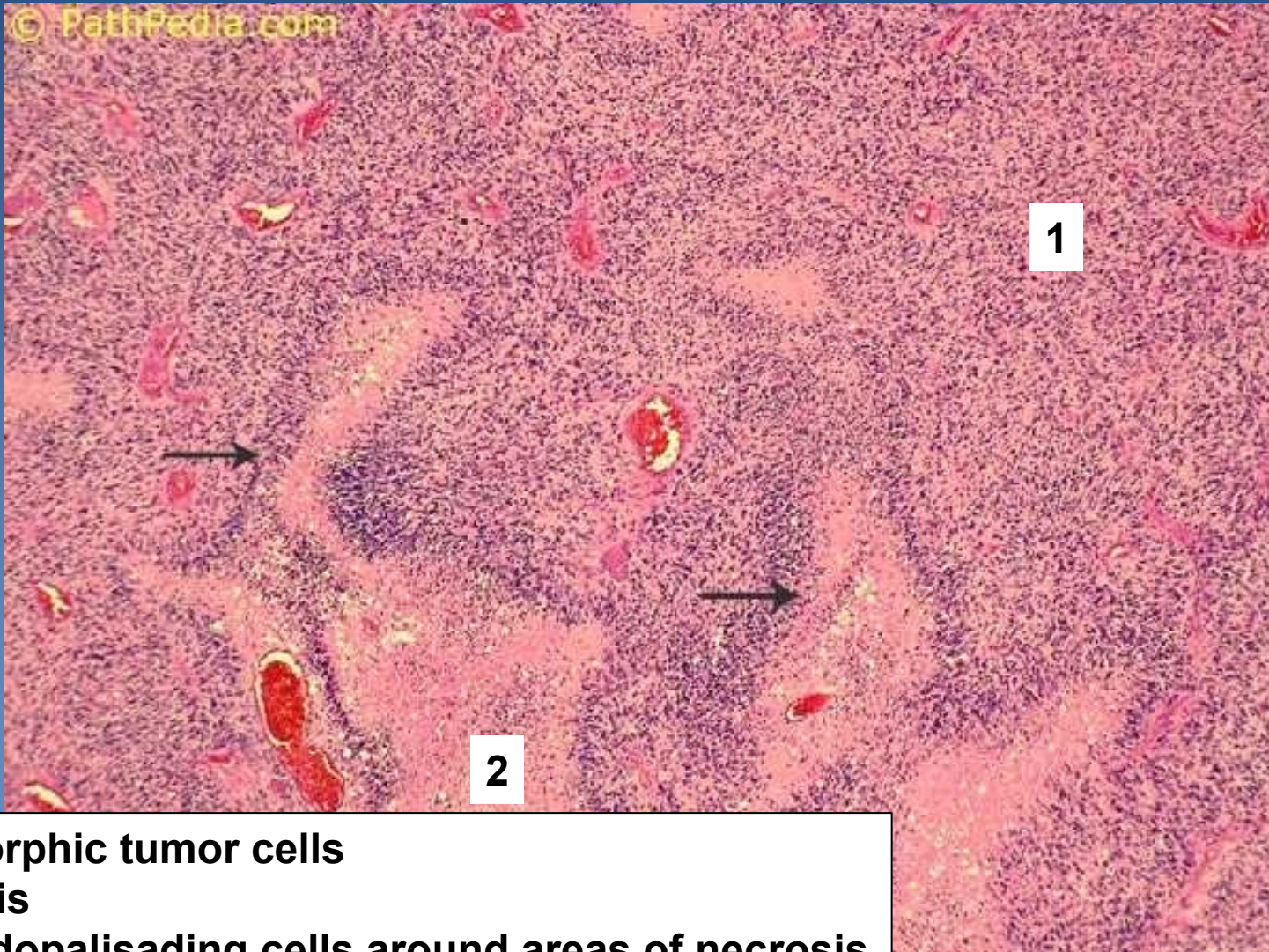
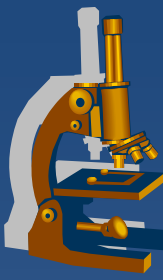


94. Purulent leptomeningitis



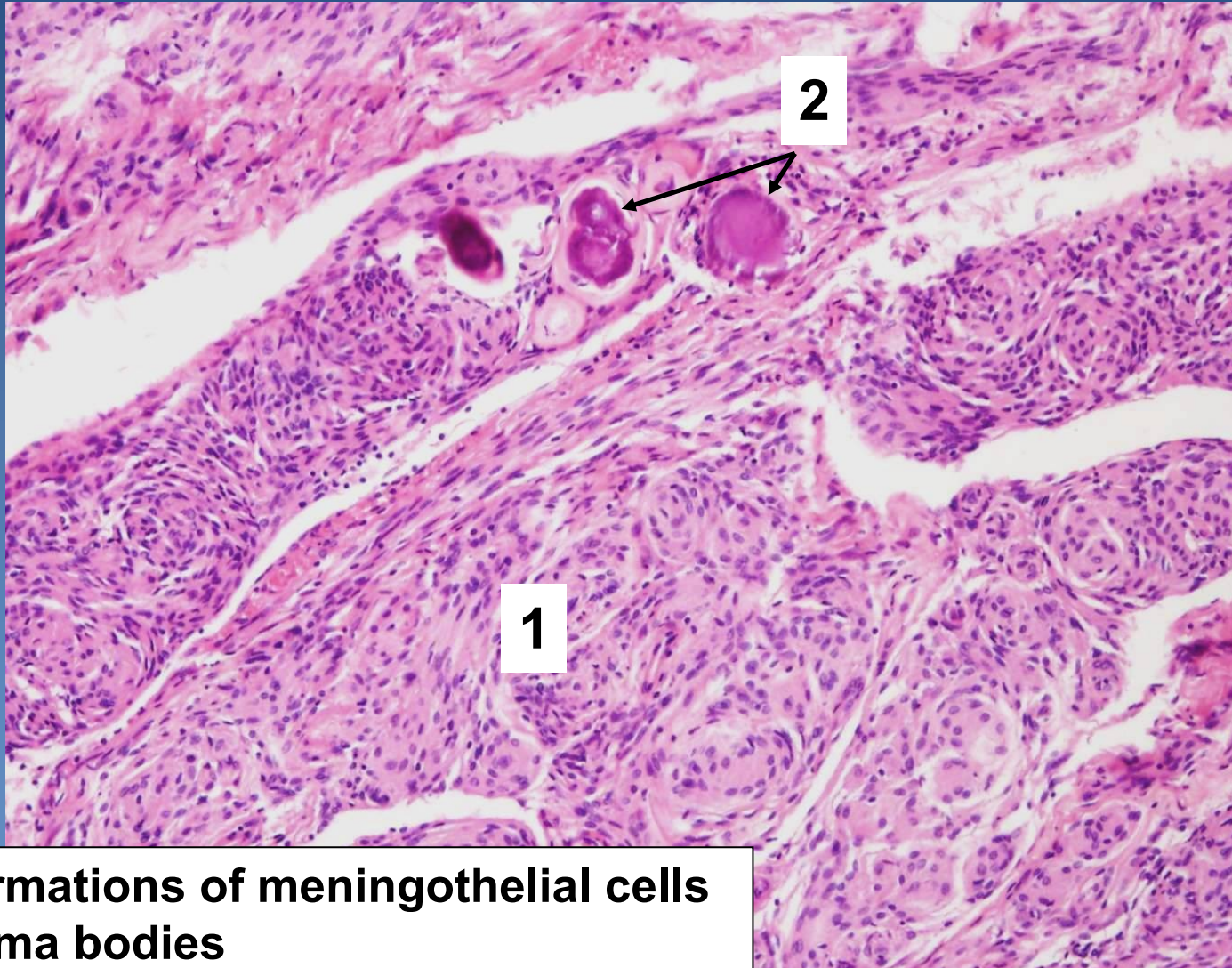
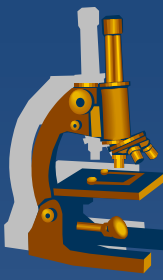
- 1 Brain tissue with oedema
- 2 Neutrophils
- 3 Dilated hyperaemic arteriolar in pia mater

95. Glioblastoma multiforme



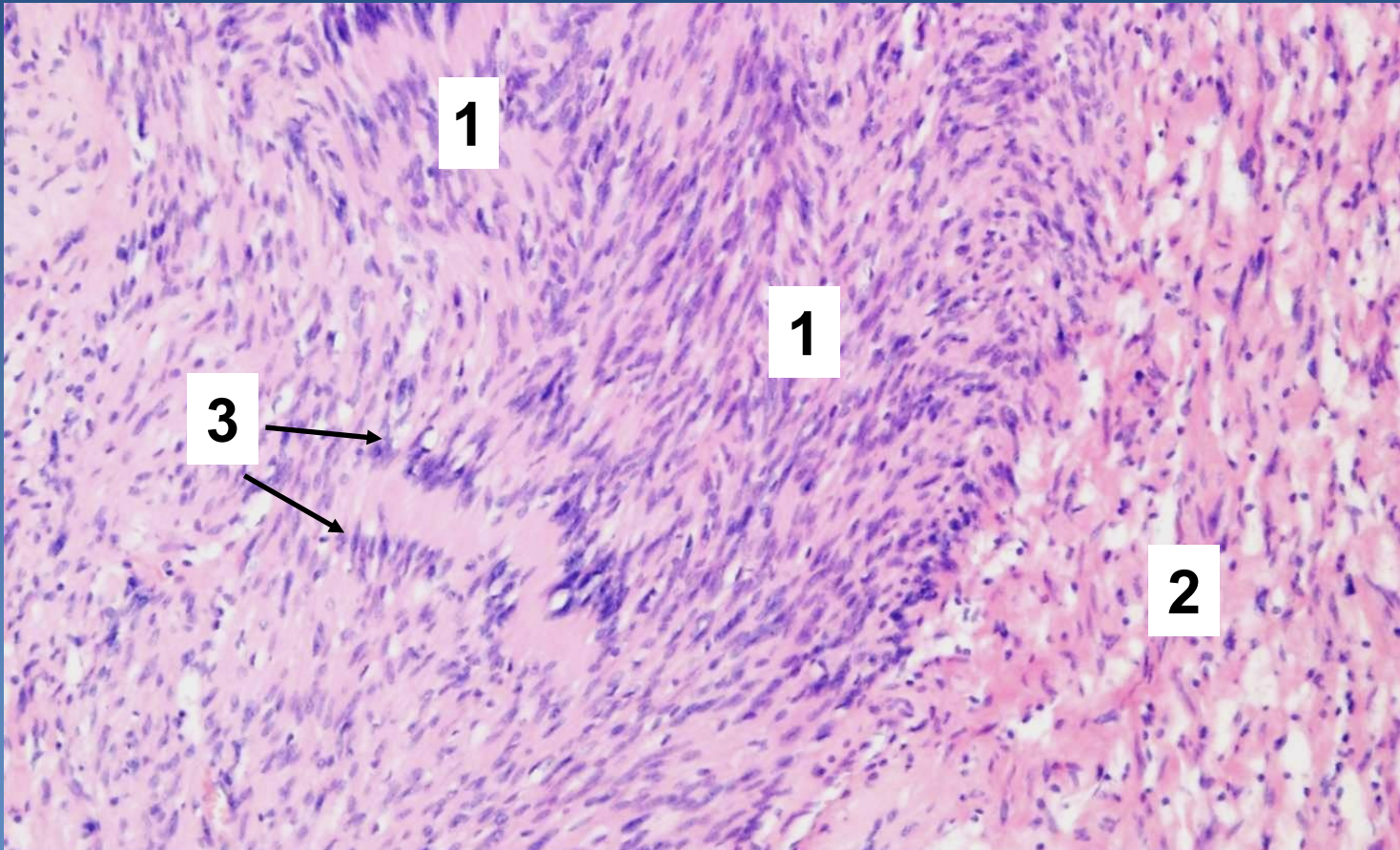
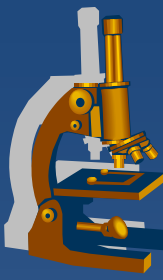
1 Pleomorphic tumor cells
2 Necrosis
—> **Pseudopalisading cells around areas of necrosis**

96. Meningeoma



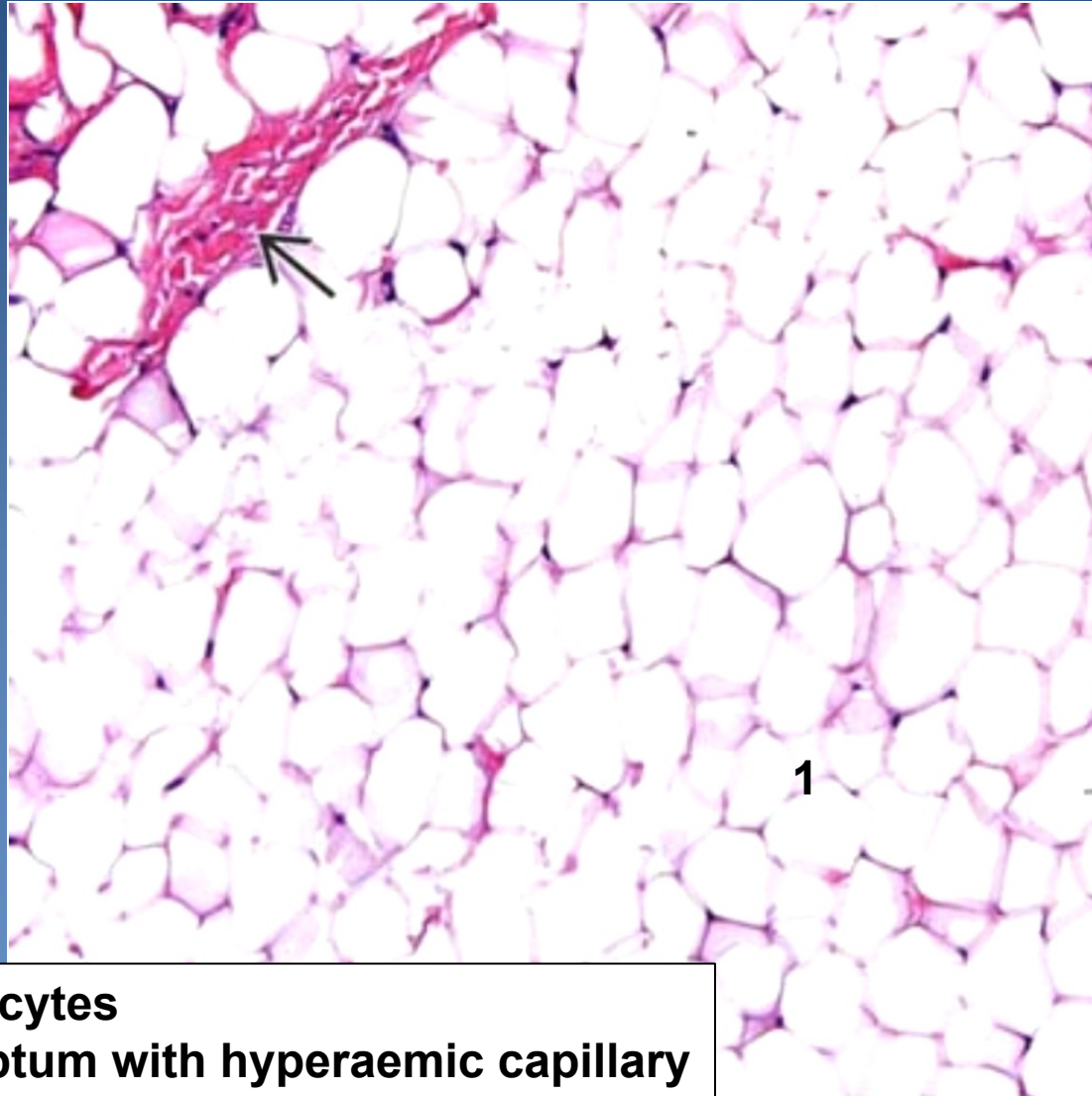
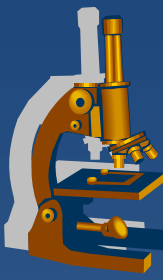
1 Whorl formations of meningothelial cells
2 Psammoma bodies

97. *Neurinoma/ Schwannoma*



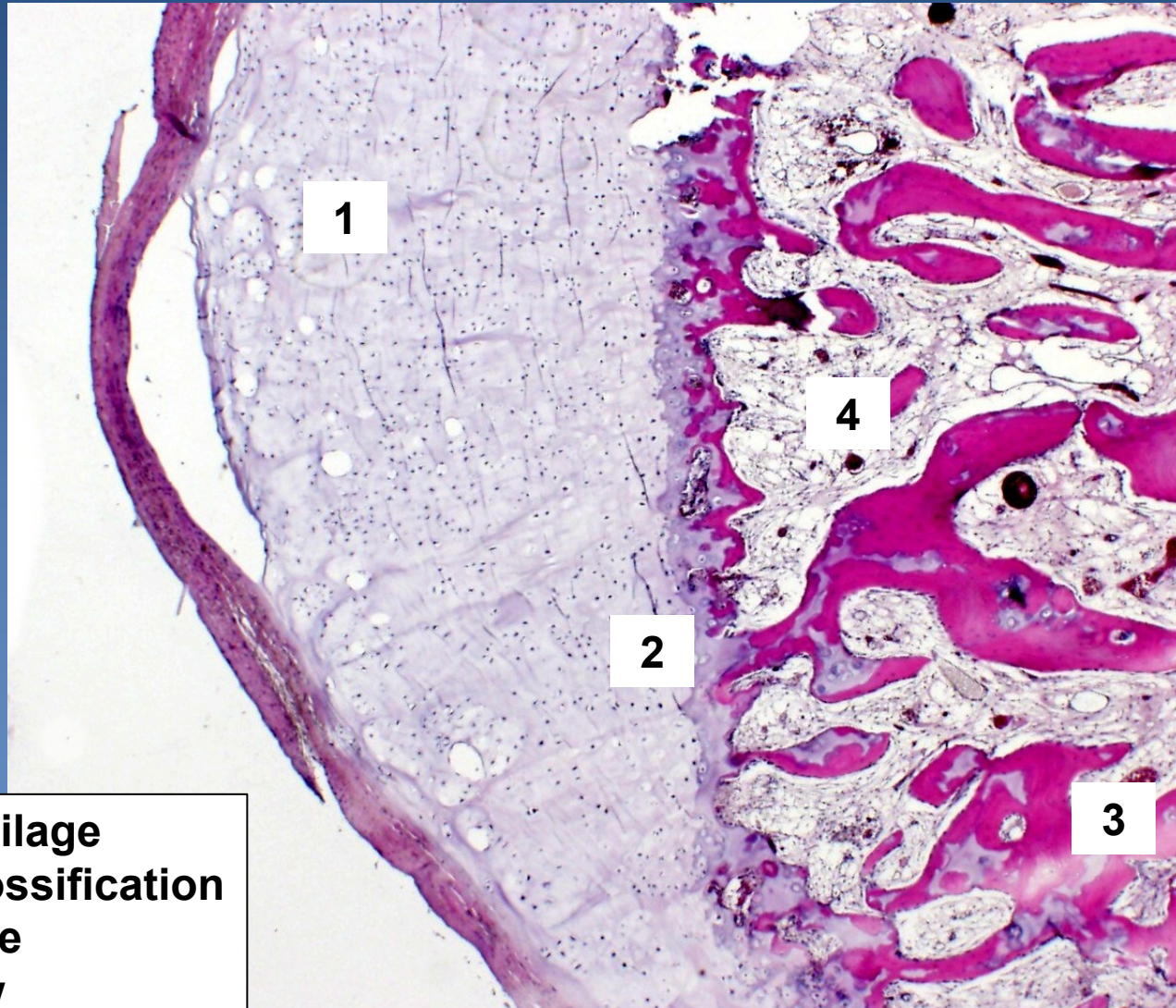
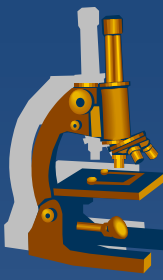
- 1 Antoni A
- 2 Antoni B (hypocellular, with myxoid degeneration)
- 3 Nuclear palisading

98. Lipoma



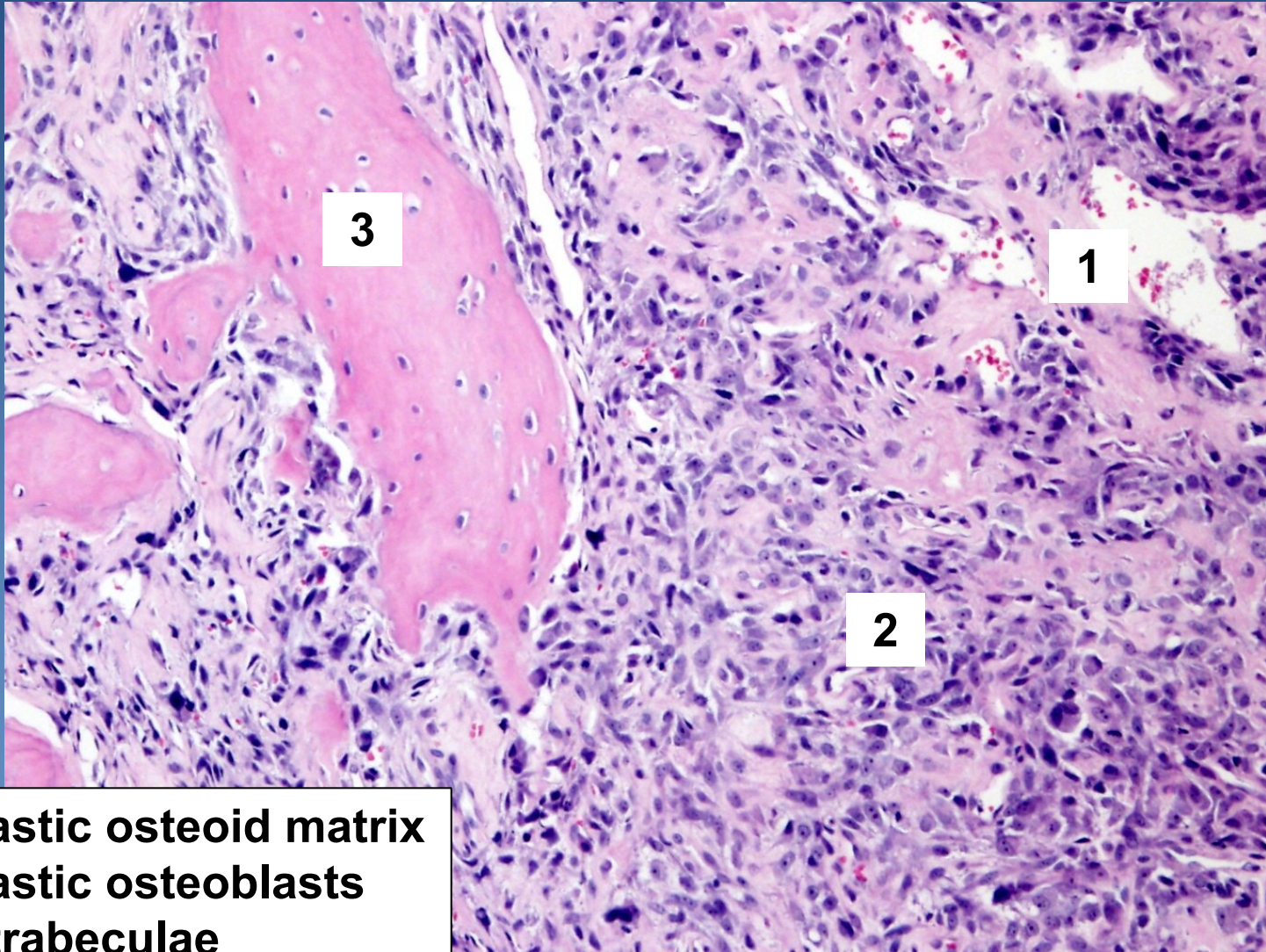
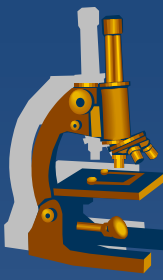
1 Mature adipocytes
➔ fibrotic septum with hyperaemic capillary

99. Osteochondroma



- 1 Hyaline cartilage
- 2 Enchondral ossification
- 3 Lamellar bone
- 4 Bone marrow

100. High-grade osteosarcoma

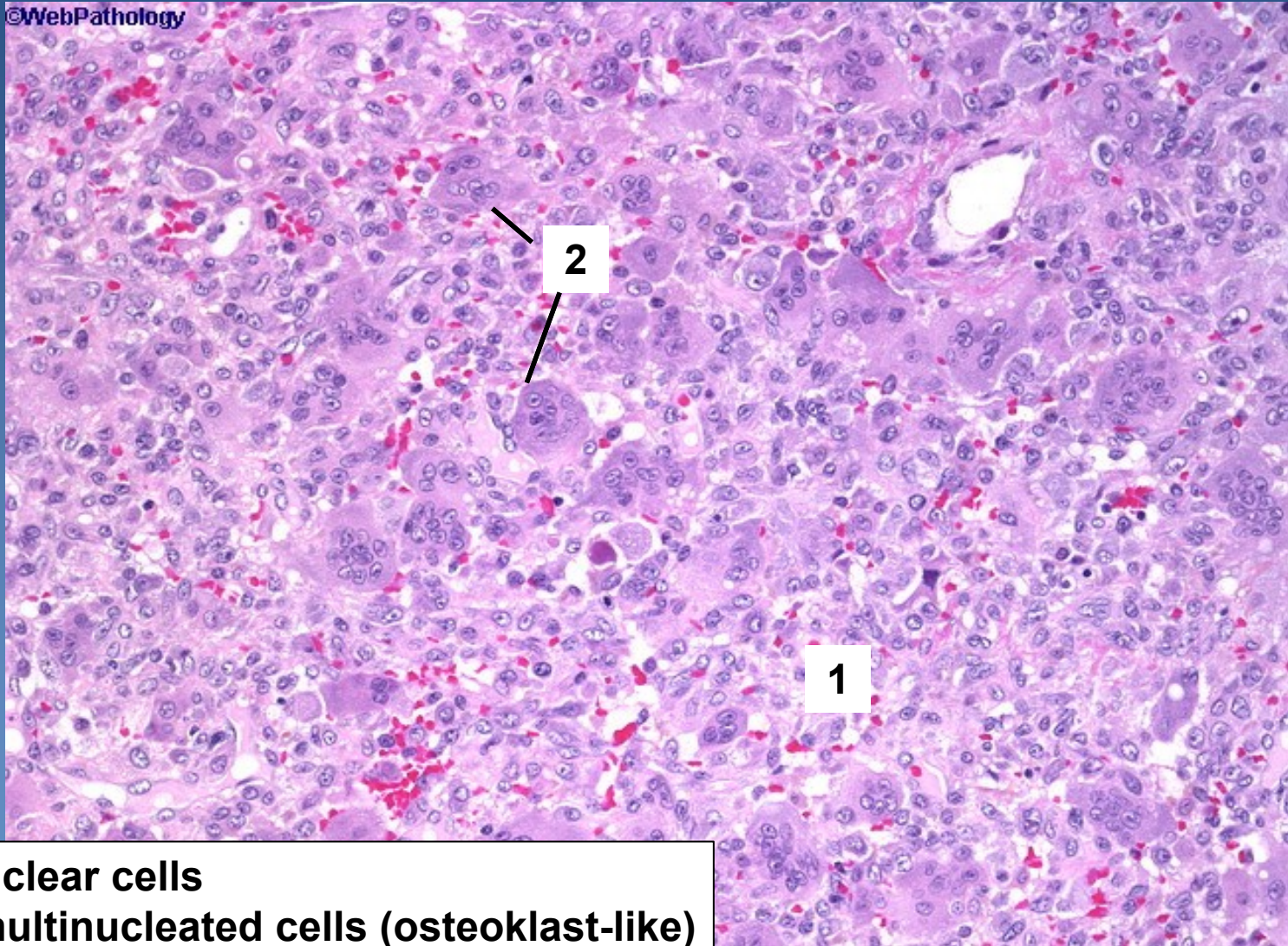


- 1 Neoplastic osteoid matrix
- 2 Neoplastic osteoblasts
- 3 Bone trabeculae

101. Giant-cell tumor of the bone

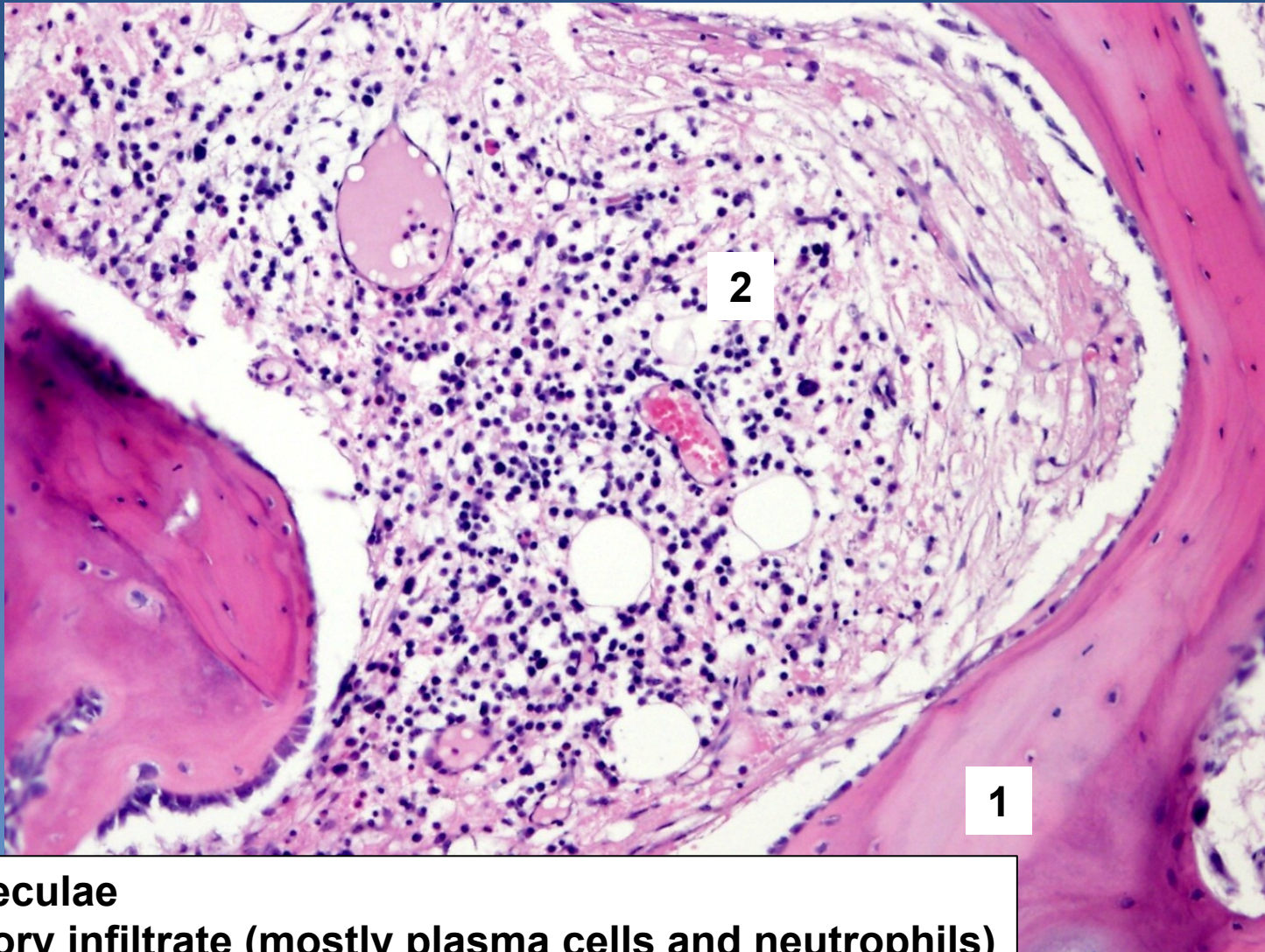
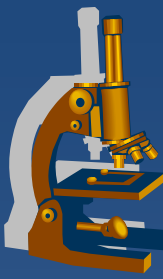


©WebPathology



- 1 Mononuclear cells
- 2 Giant multinucleated cells (osteoclast-like)

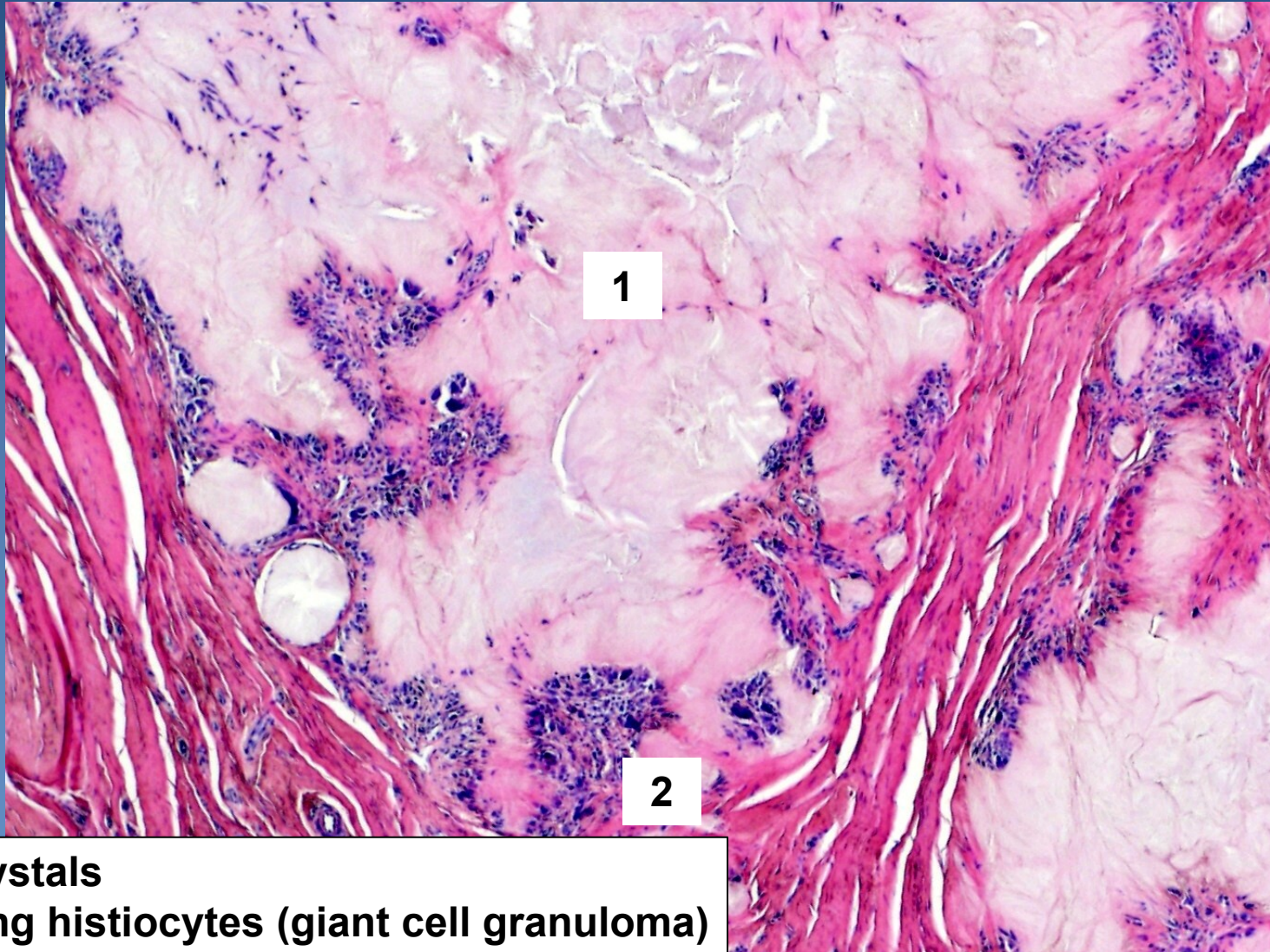
102. Chronic purulent osteomyelitis



1 Bone trabeculae

2 Inflammatory infiltrate (mostly plasma cells and neutrophils)

103. *Tophus in arthritis uratica*

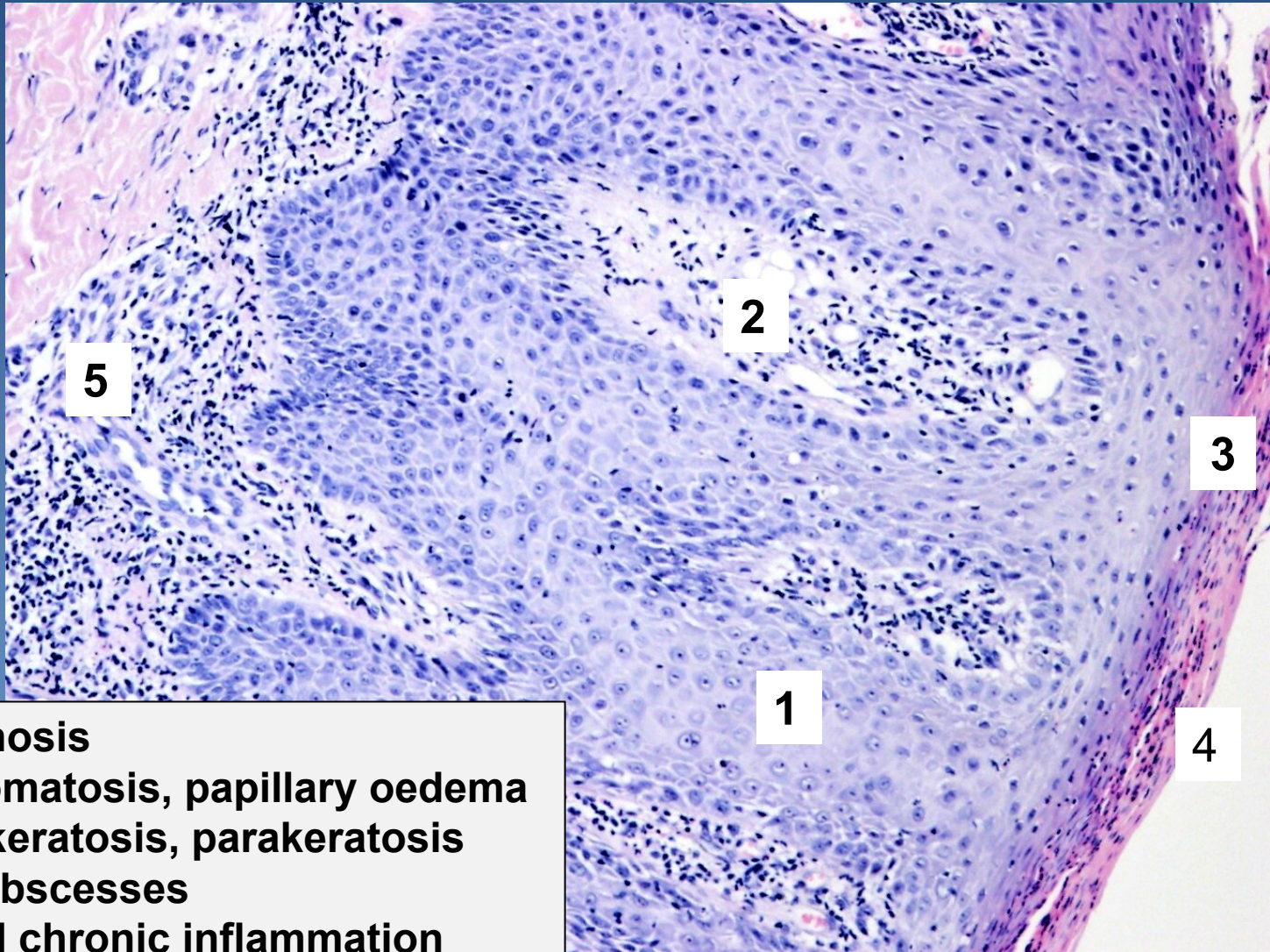
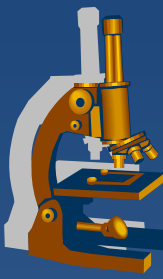


1

2

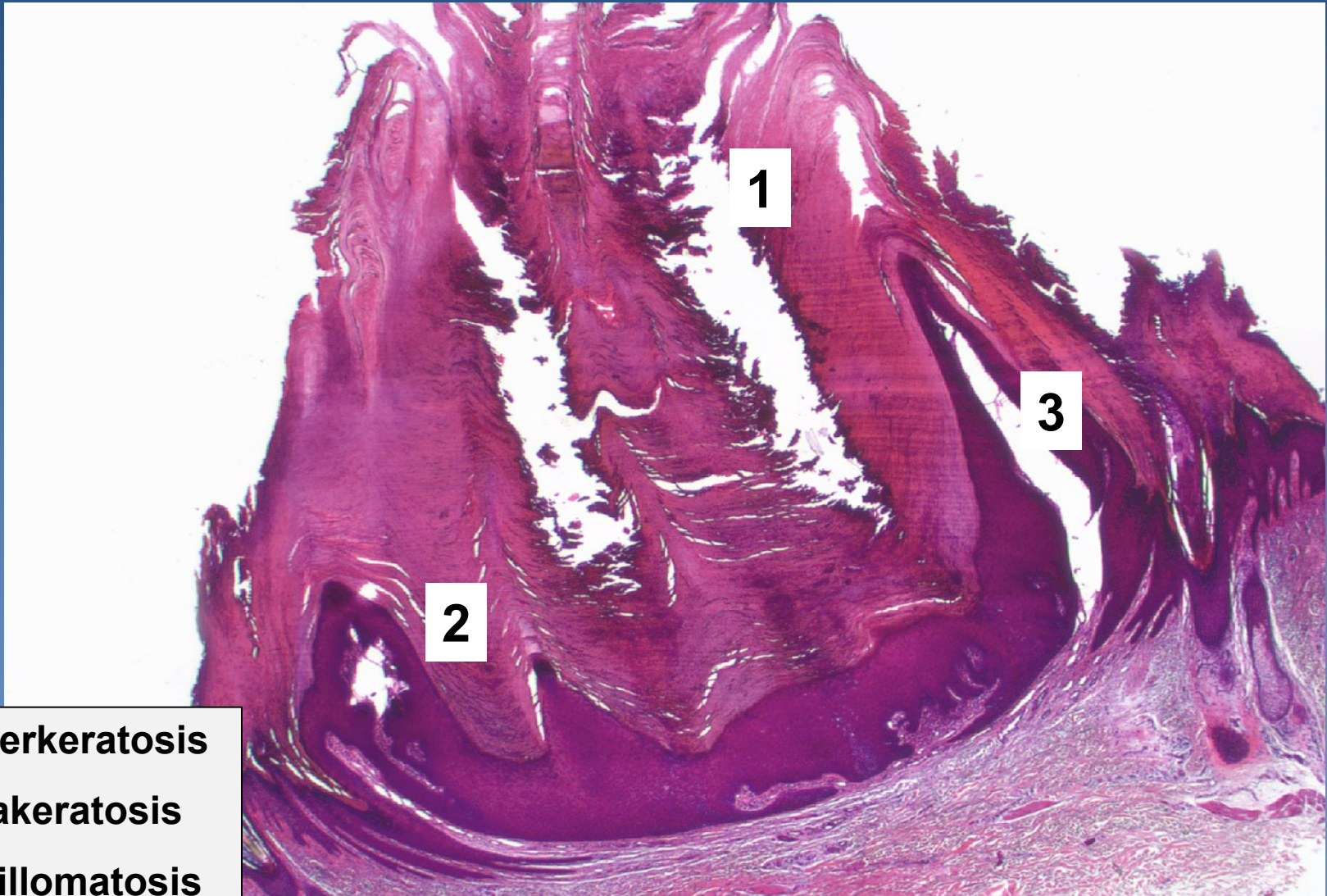
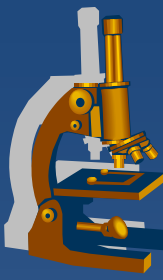
1 Urate crystals
2 Palisading histiocytes (giant cell granuloma)

104. Psoriasis



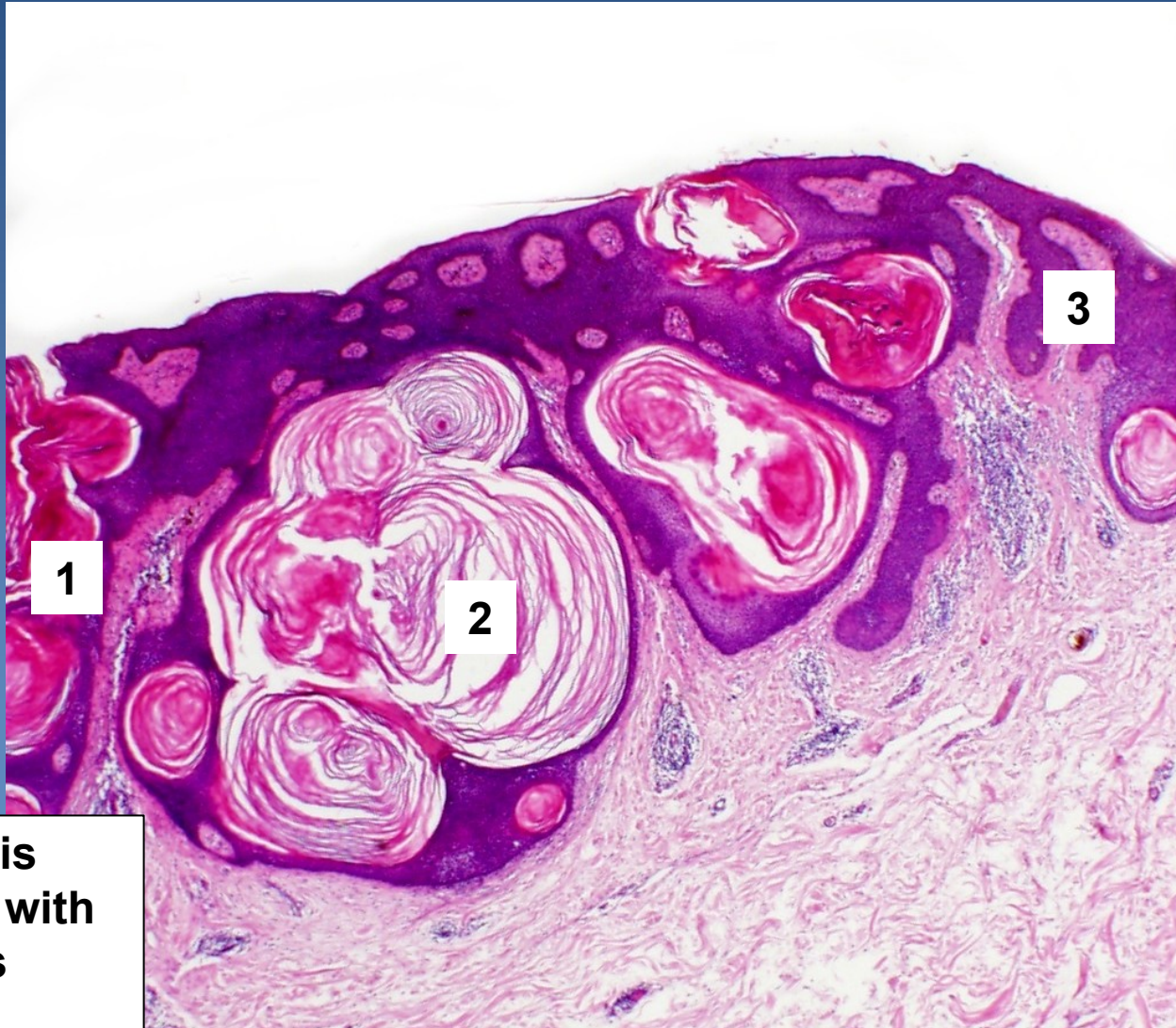
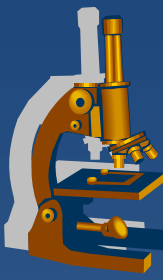
- 1 Acanthosis
- 2 Papillomatosis, papillary oedema
- 3 Hyperkeratosis, parakeratosis
- 4 Microabscesses
- 5 Dermal chronic inflammation

105. *Verruca vulgaris*



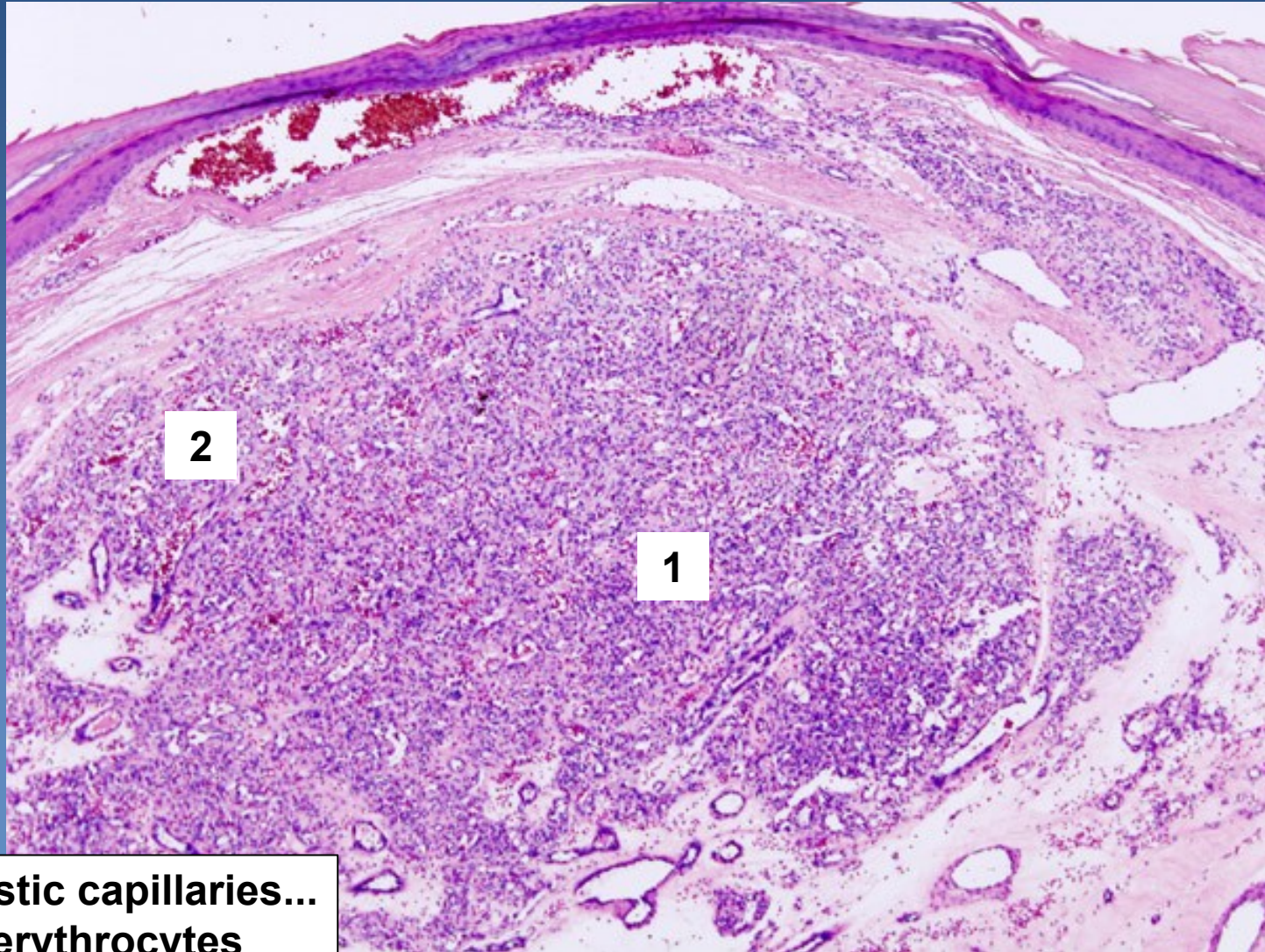
- 1 Hyperkeratosis
- 2 Parakeratosis
- 3 Papillomatosis

106. Seborrheic keratosis



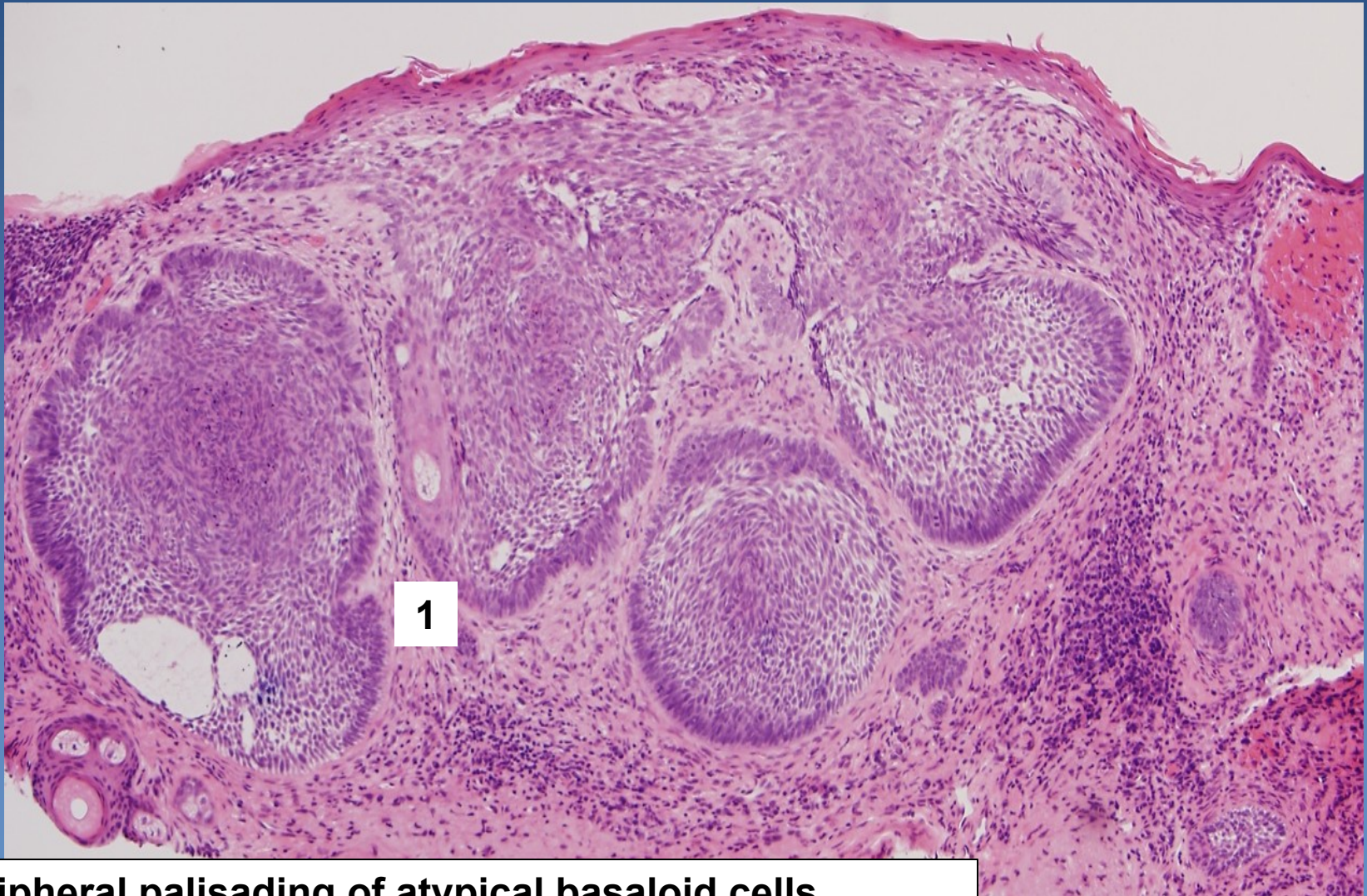- 1 Papillomatosis
- 2 "horn" cysts with keratin masses
- 3 Acanthosis

107. Capillary hemangioma of the skin



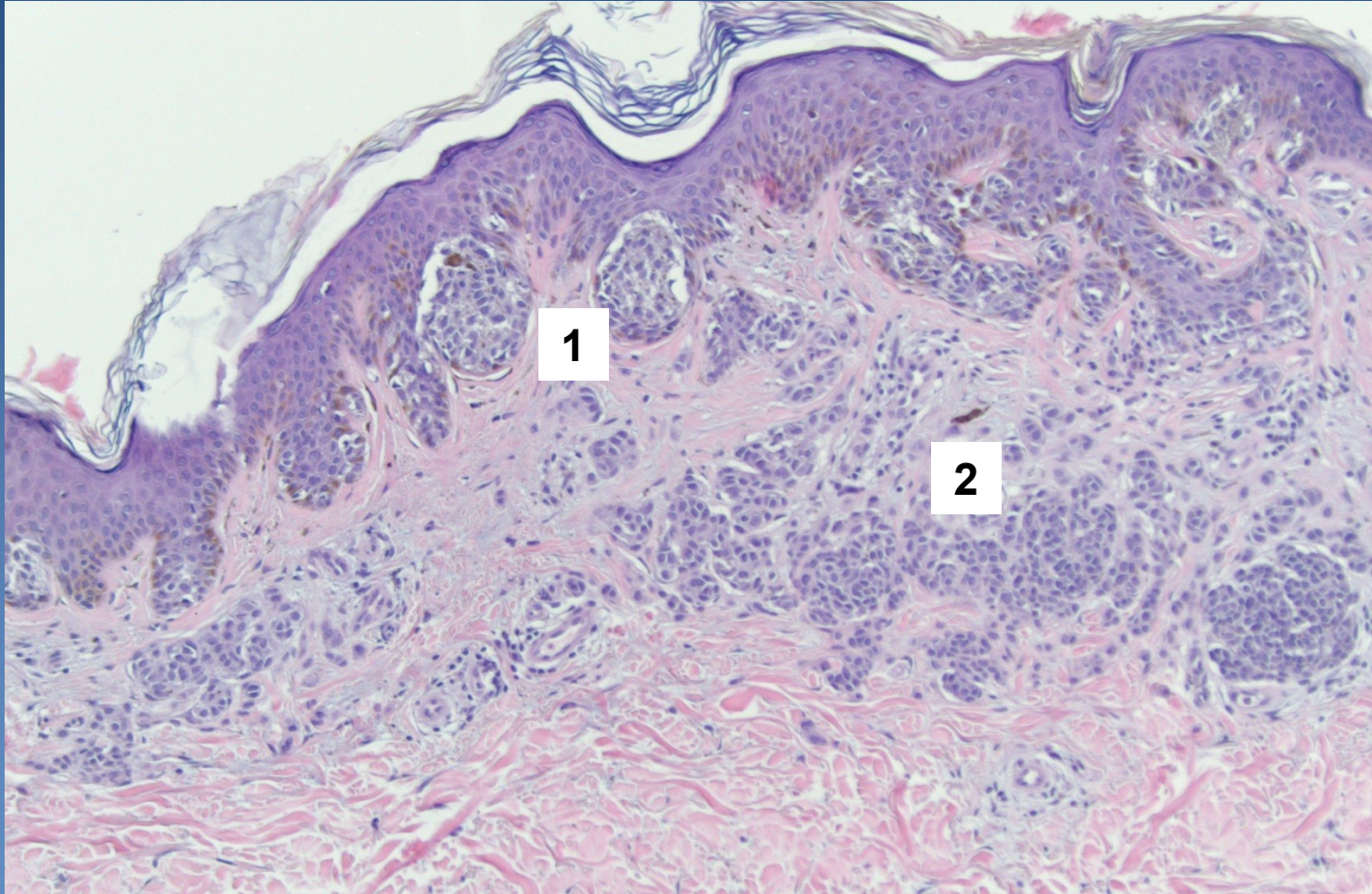
1 Neoplastic capillaries...
2 ...with erythrocytes

108. Basal cell carcinoma of the skin

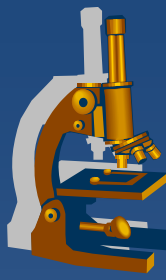


1 Peripheral palisading of atypical basaloid cells

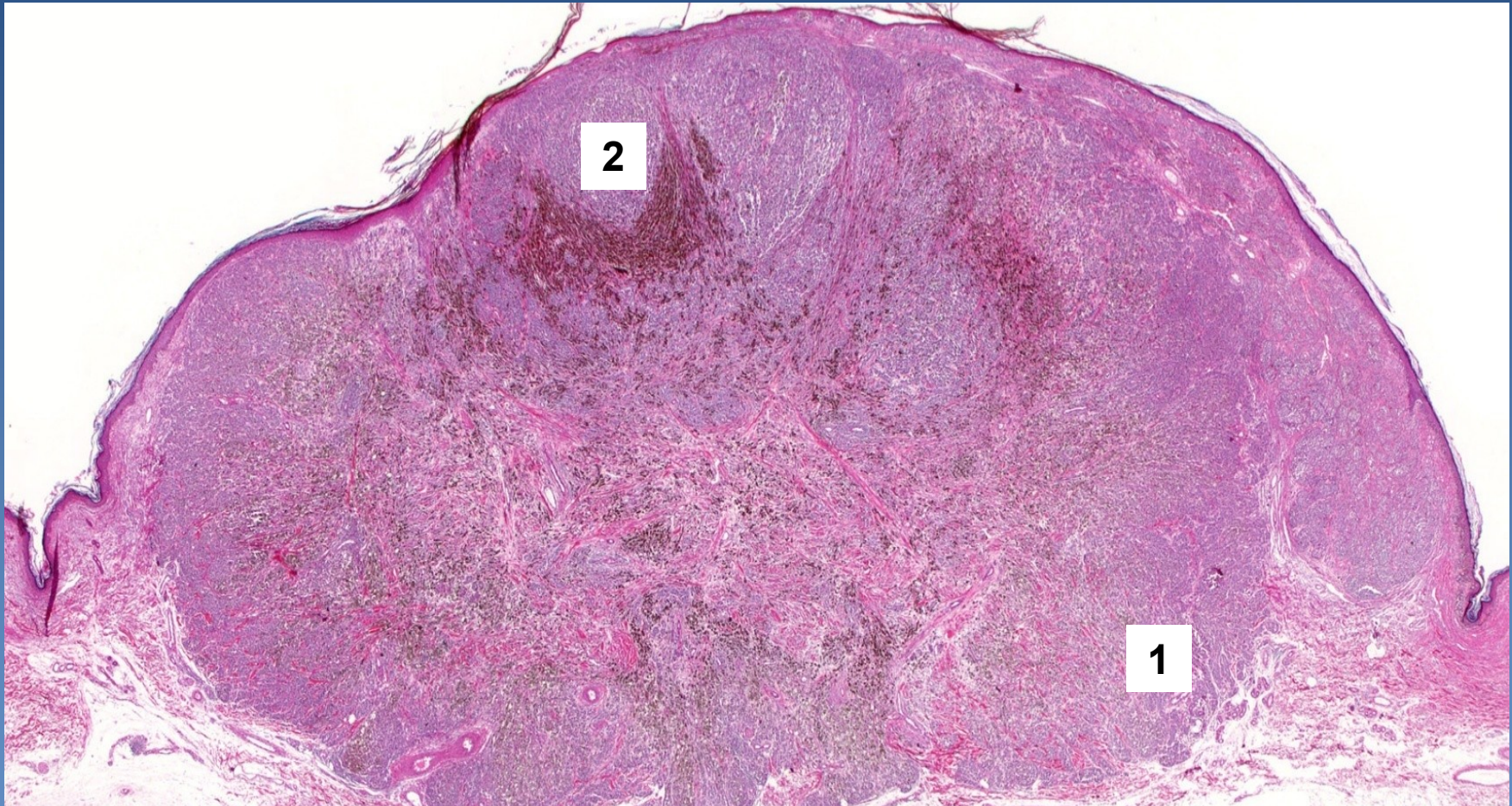
109. Compound pigmented naevus



- 1 Nests of melanocytes in dermoepidermal junction
- 2 Nests of melanocytes in the dermis



110. Malignant melanoma



- 1 Neoplastic melanocytes in the dermis with infiltration of adipose tissue**
- 2 Focally increased melanin production**