

Epithelial tissue

Petr Vaňhara, PhD

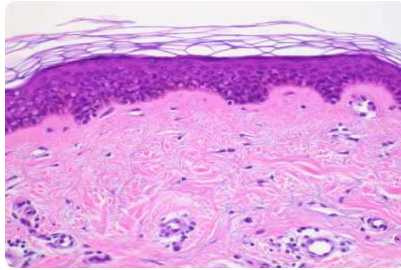
Dept. Histology & Embryology,
Faculty of Medicine MU

pvanhara@med.muni.cz

CONTEMPORARY TISSUE CLASSIFICATION

Based on morphology and function:


Epithelium



Continual, avascular layers of cells with different function, oriented to open space, with specific junctions and minimum of ECM and intercellular space.

Derivates of all three germ layers

Muscle



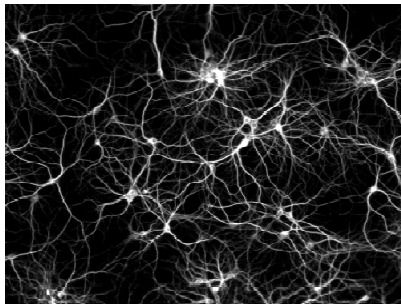
Myofibrils → contraction

Mesoderm – skeletal muscle, myocard, mesenchyme

– smooth muscles

Rarely ectoderm (eg. m. sphincter a m. dilatator pupillae)

Nerve

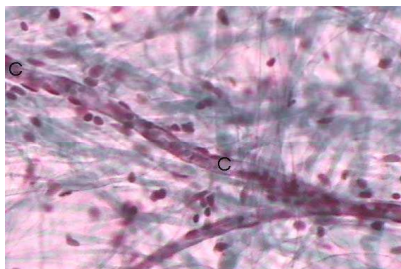


Neurons and neuroglia

Reception and transmission of electric signals

Ectoderm, rarely mesoderm (microglia)

Connective



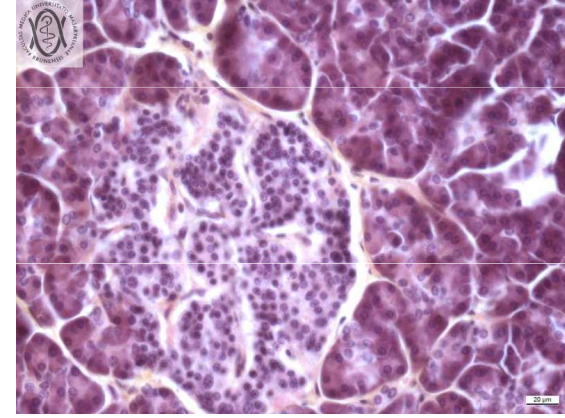
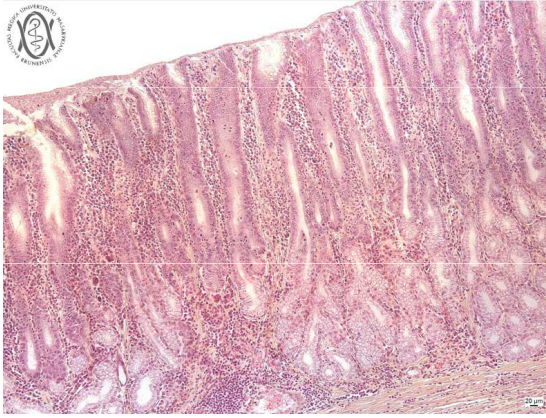
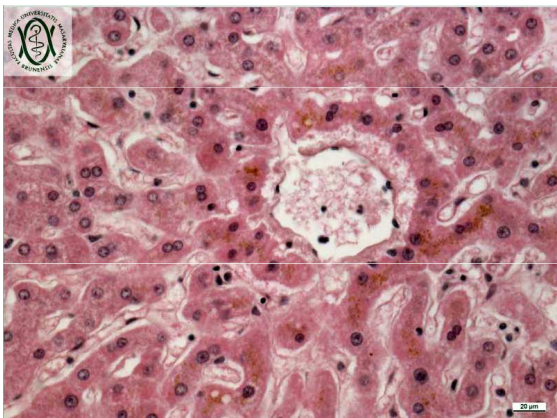
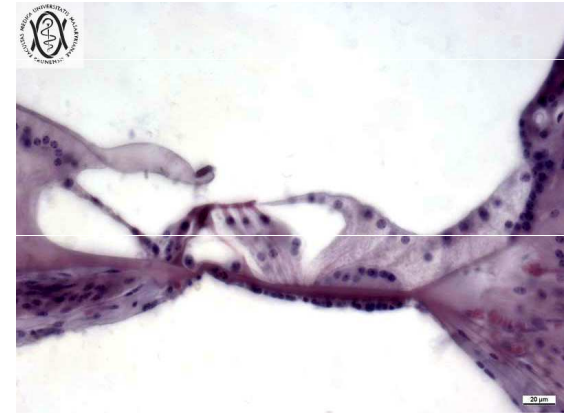
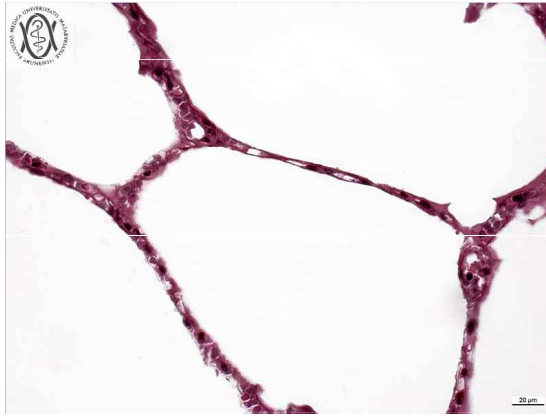
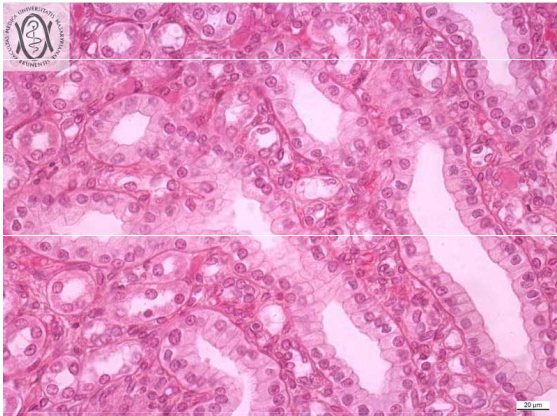
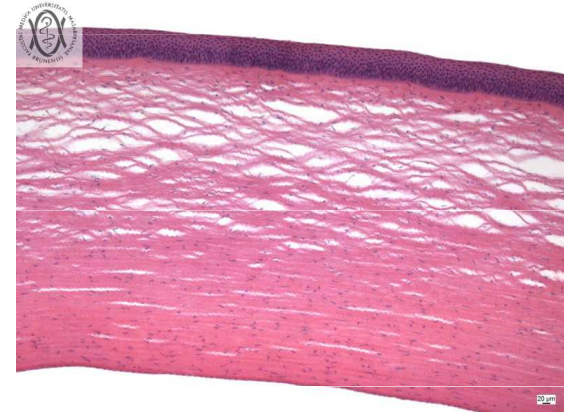
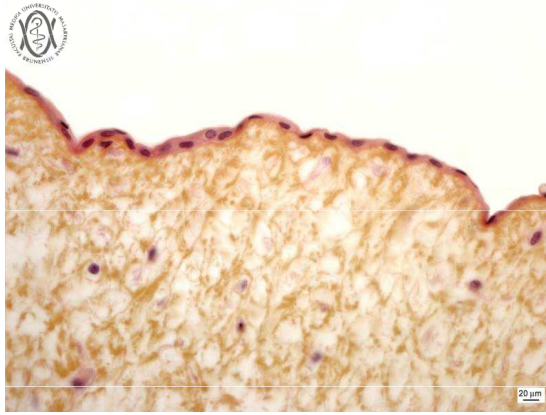
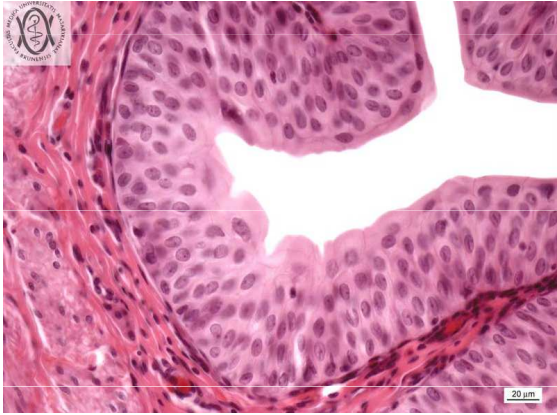Dominant extracellular matrix

Connective tissue, cartilage, bone...

Mesenchyme

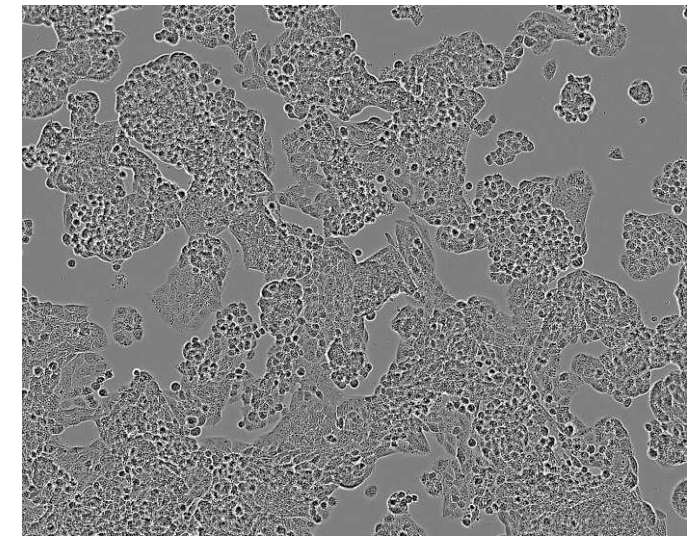
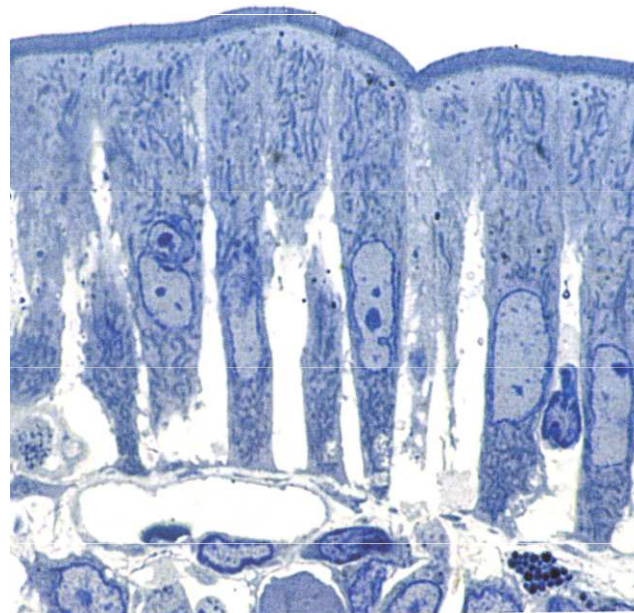
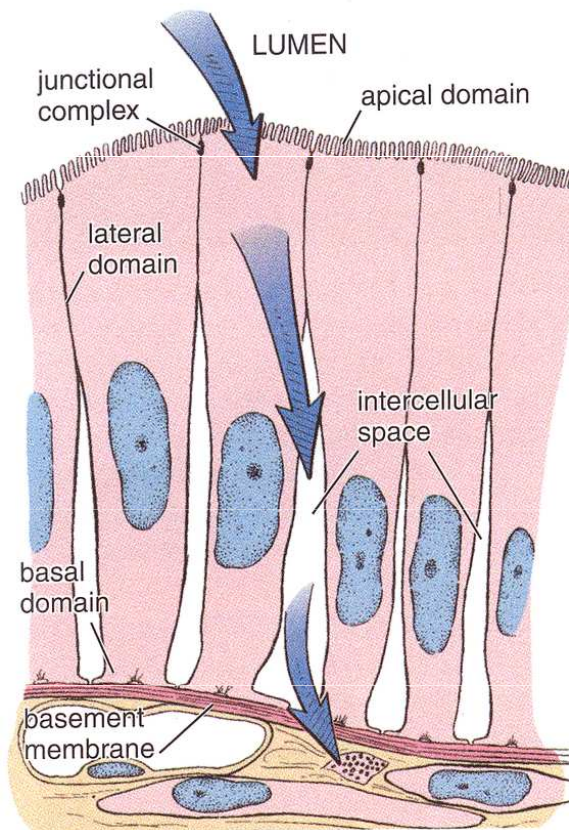
General characteristics

EPITHELIAL VARIABILITY IN HUMANS

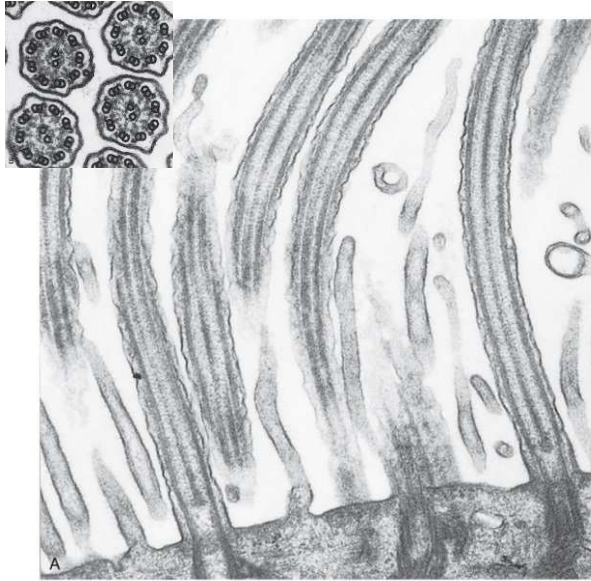


GENERAL CHARACTERISTICS OF EPITHELIAL TISSUE

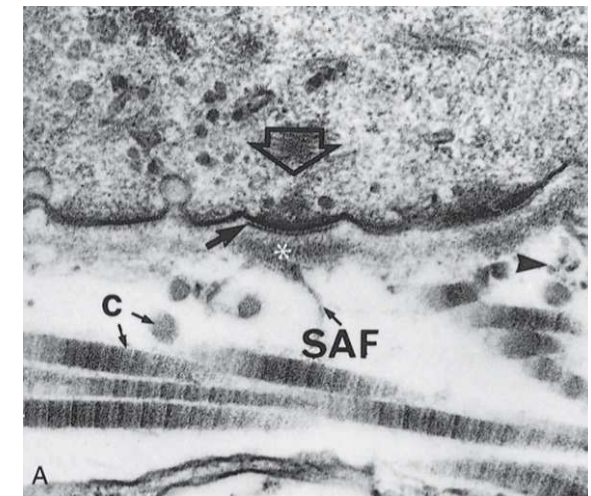
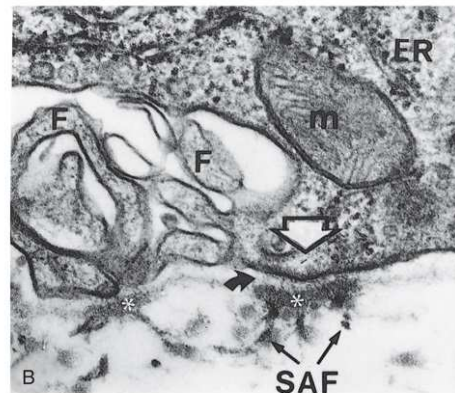
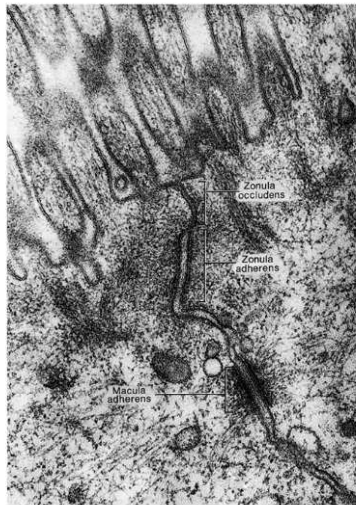
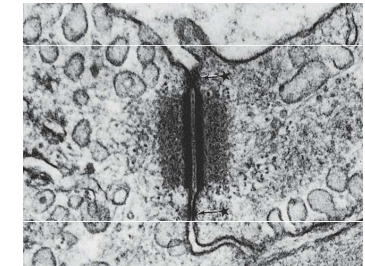
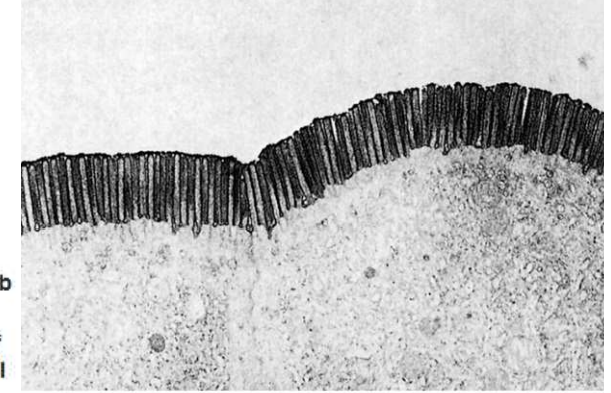
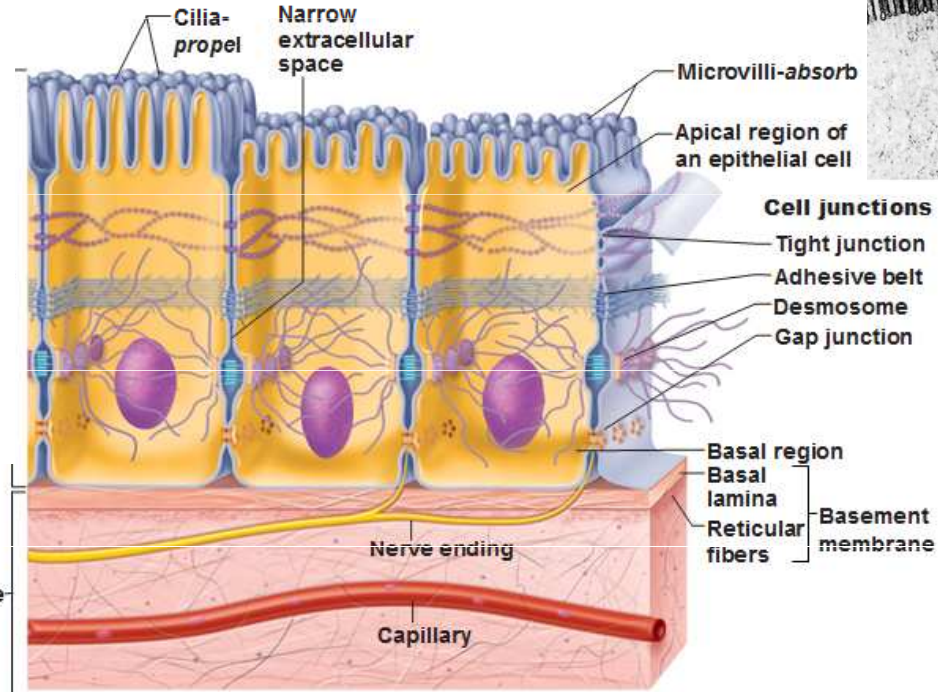
- **Avascular** (without blood supply) – in covering epithelia, nutrition by diffusion from a highly vascular and innervated area of loose connective tissue (*lamina propria*) just below the basement membrane
- **Highly cellular** – cohesive sheet or groups of cells with no or little extracellular matrix
- Typical **morphology** and **cell connections**



HALLMARKS OF A TYPICAL EPITHELIAL CELL

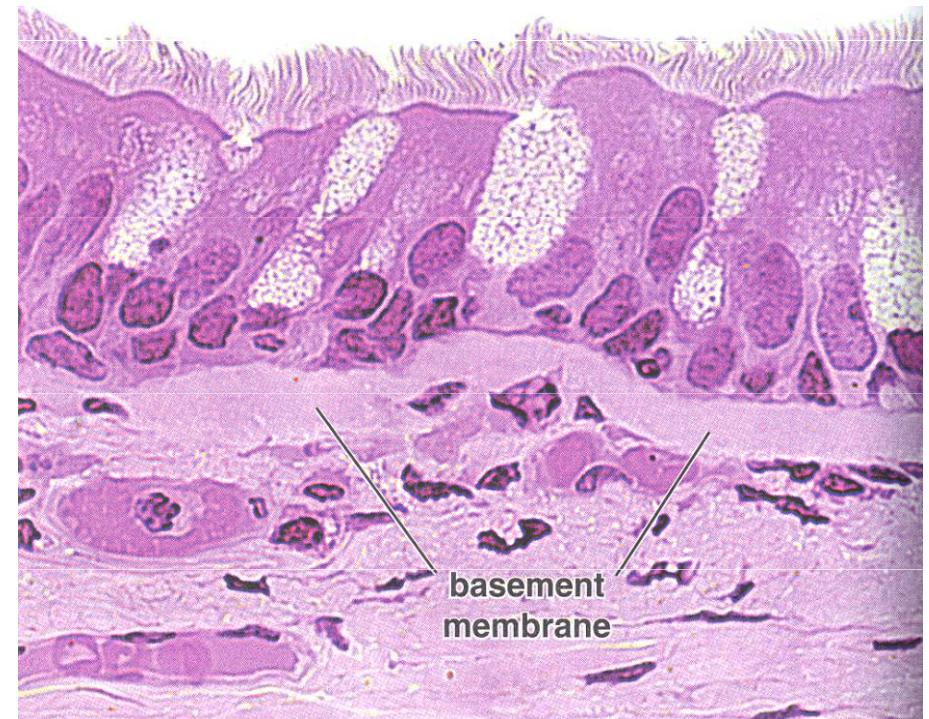
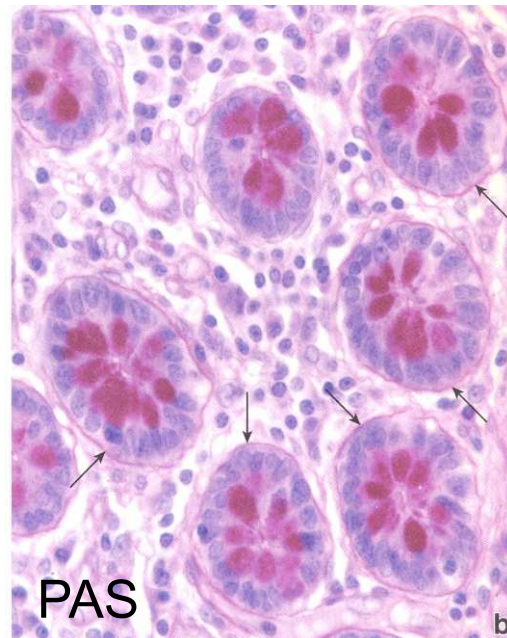
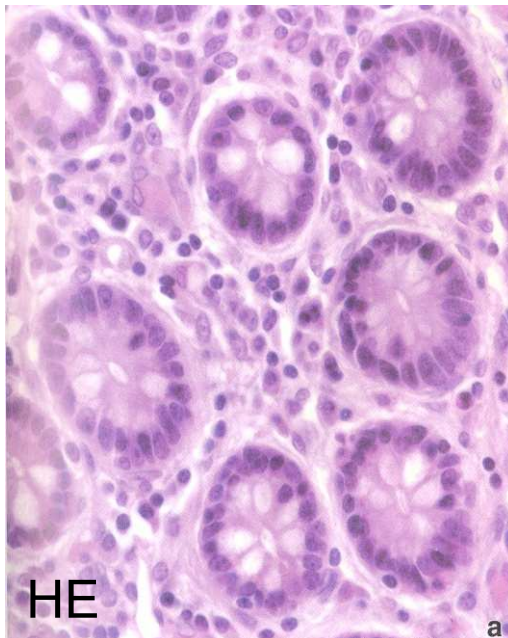
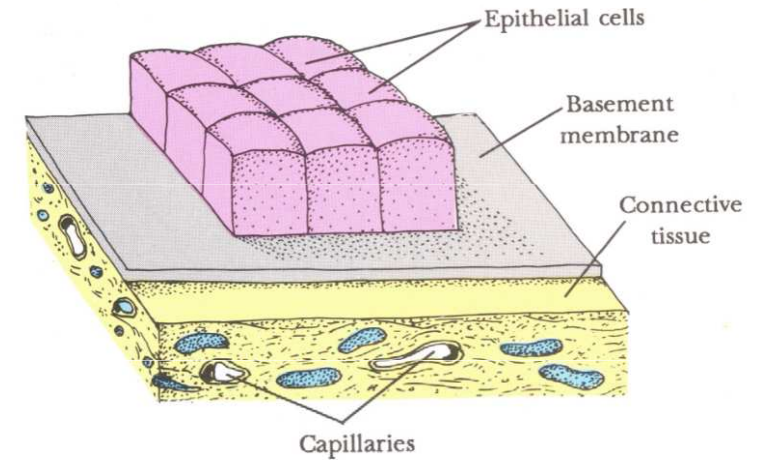


From Lesson TS, Leeson CR, Paparo AA. *Text Atlas of Histology*. Philadelphia: WB Saunders; 1988.



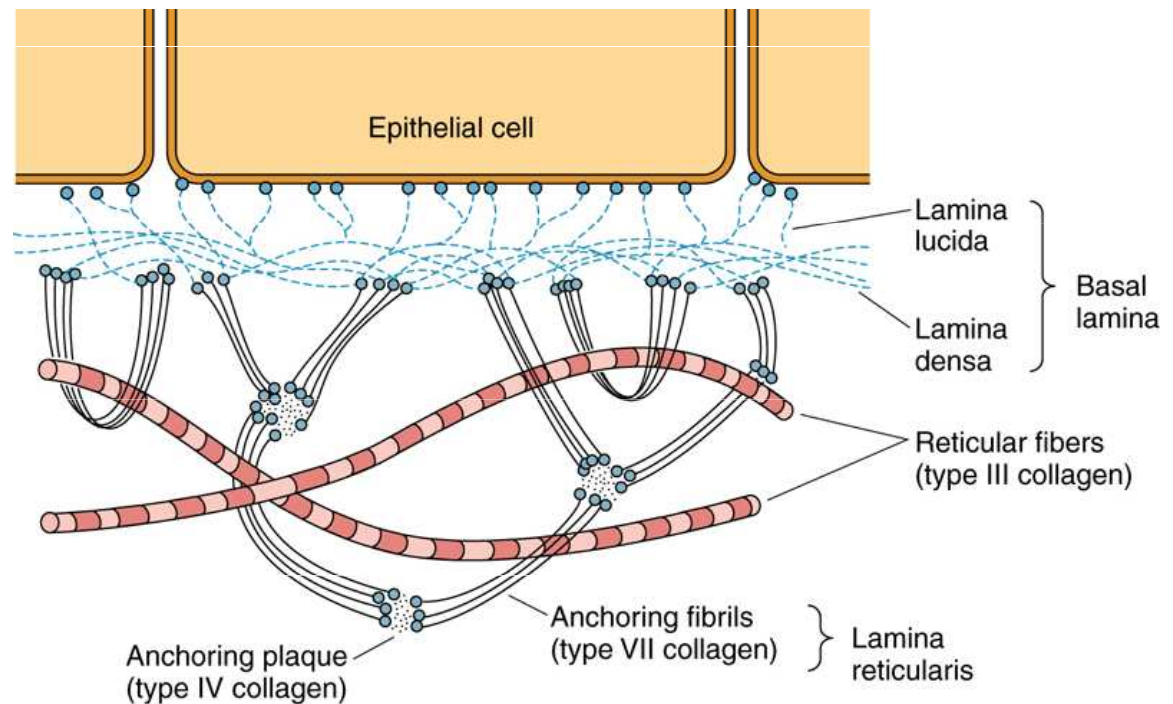
BASEMENT MEMBRANE

- Attachment of epithelium to underlying tissues
- Selective filter barrier between epithelial and connective tissue
- Communication, differentiation
- Term from light microscopy
- Basement membrane = lamina basalis + lamina (fibro)reticularis



BASAL LAMINA vs. BASEMENT MEMBRANE

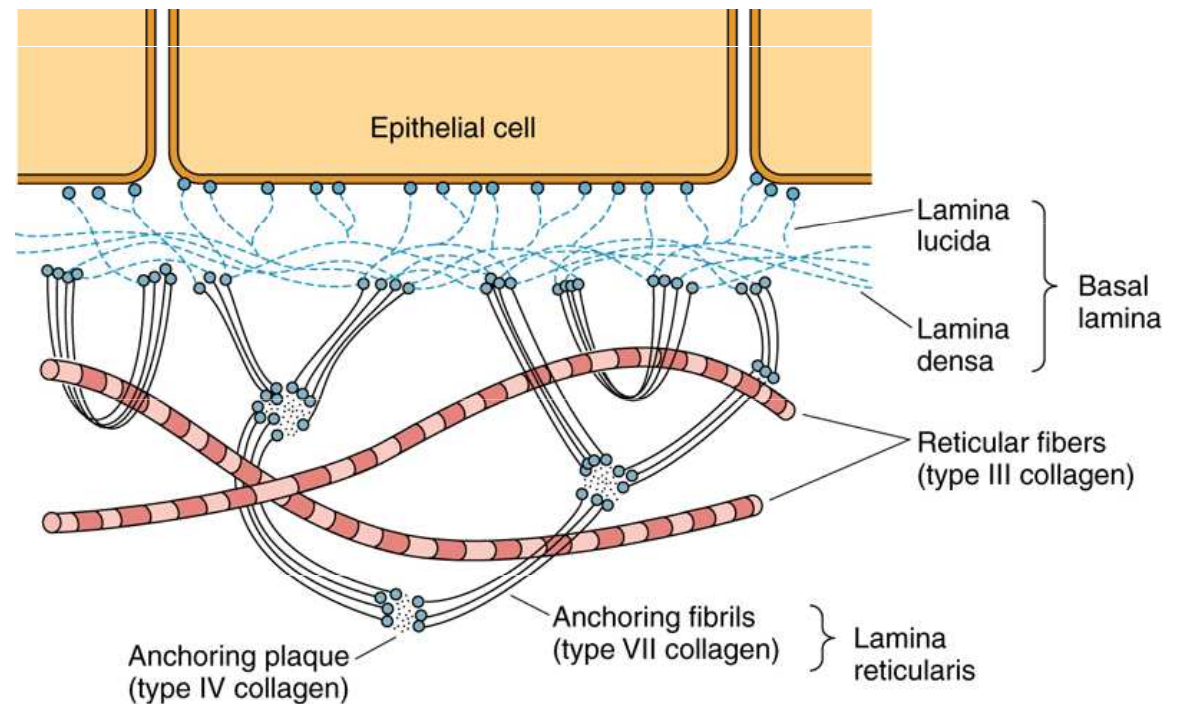
- **Basal lamina (lamina basalis)**
- term of electron microscopy
- two layers: lamina densa and lamina rara
 - lamina rara (lucida) - GAGs (visualized by PAS reaction) - attachment of hemidesmosomes, light
 - lamina densa - collagens (IV), dark
- product of epithelial cells
- 50 - 100nm



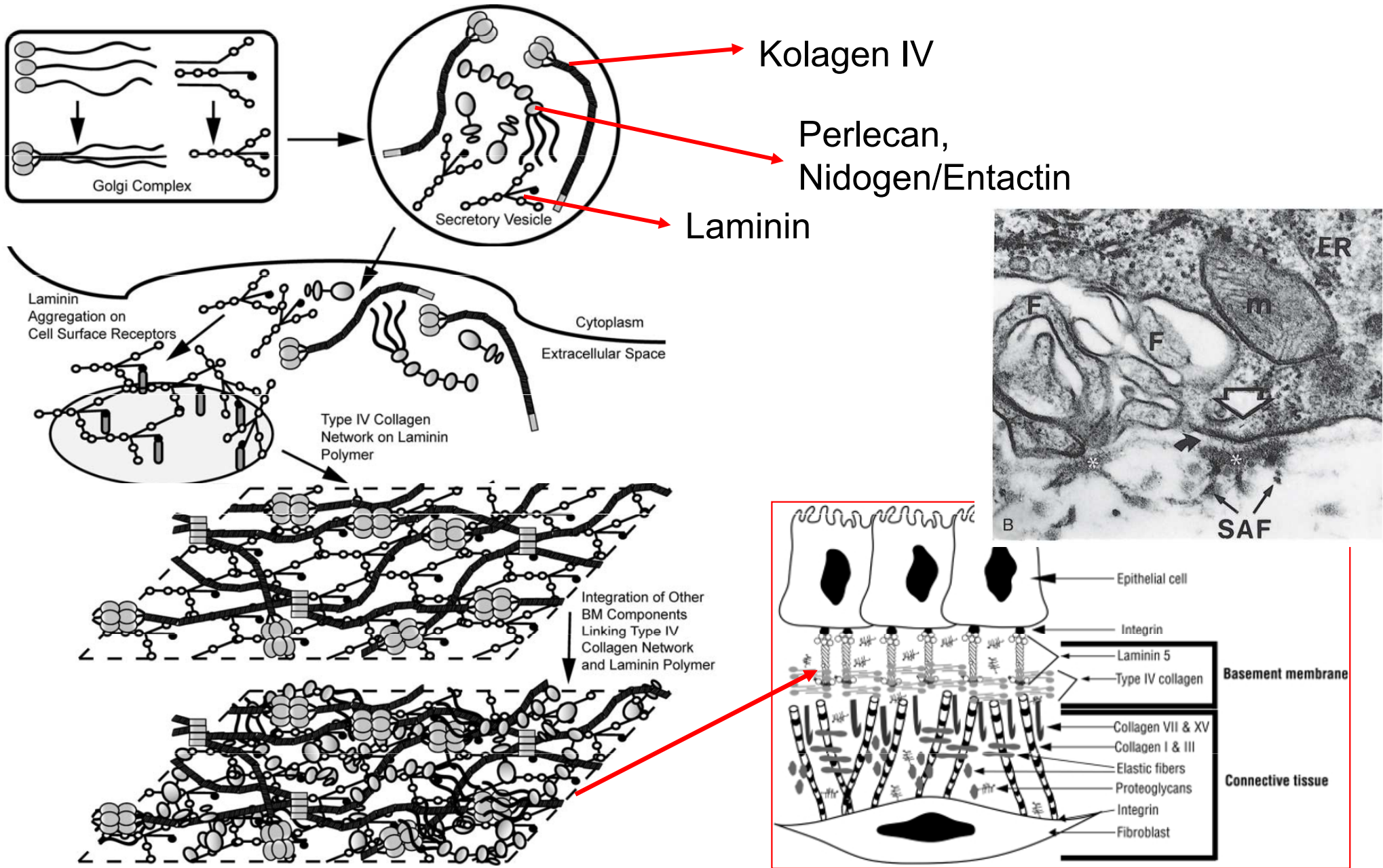
BASAL LAMINA vs. BASEMENT MEMBRANE

Lamina (fibro)reticularis

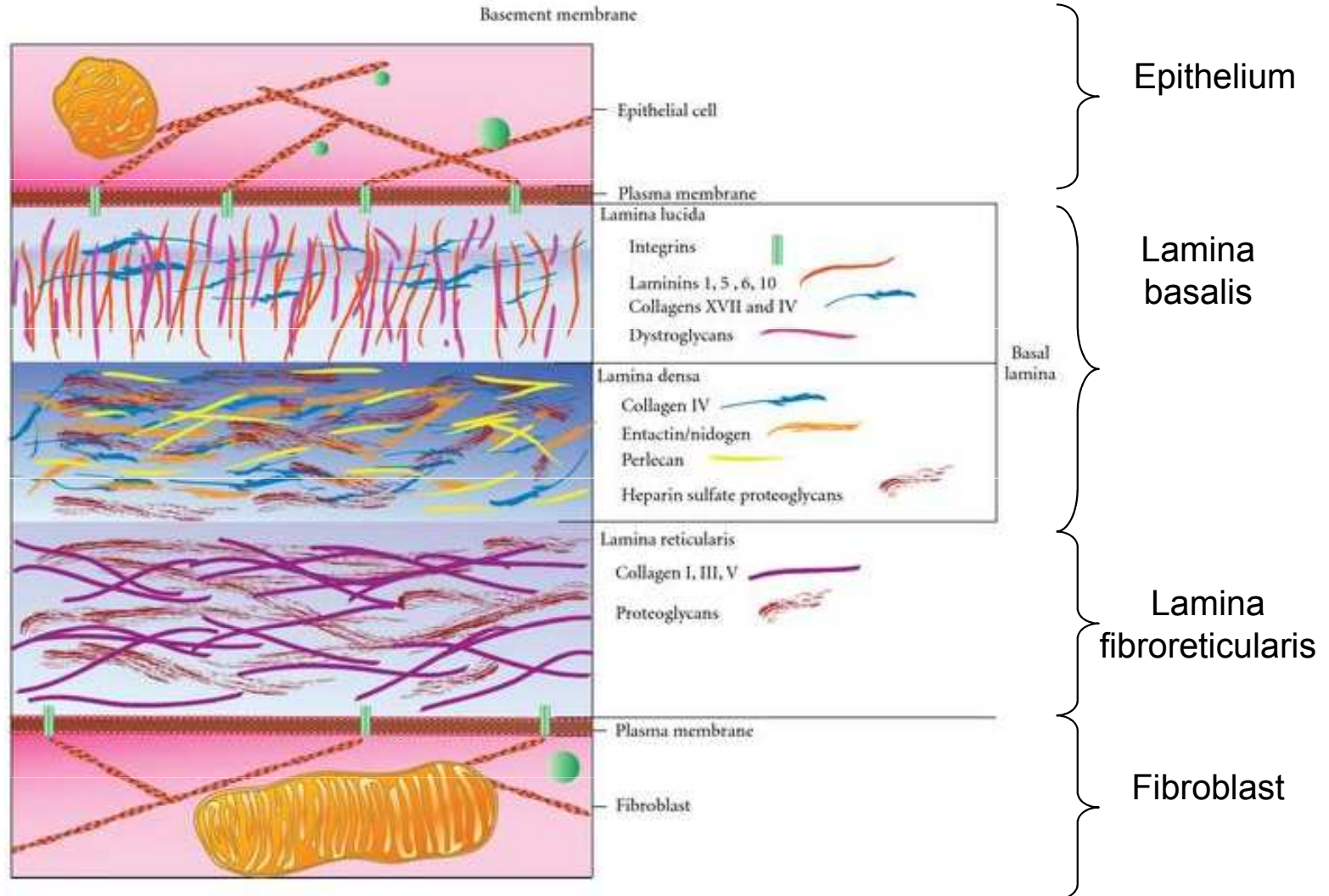
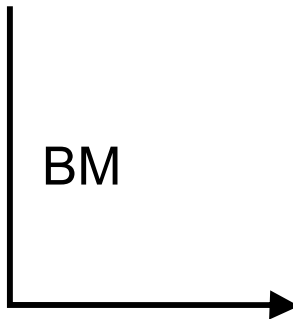
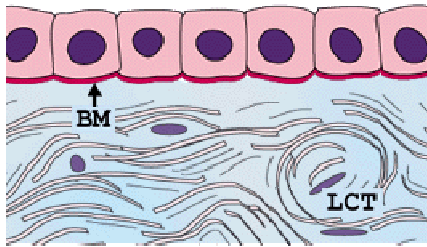
- term of electron microscopy
- collagen III and other collagens (IV, VI)
- fibrilin
- product of connective tissue cells



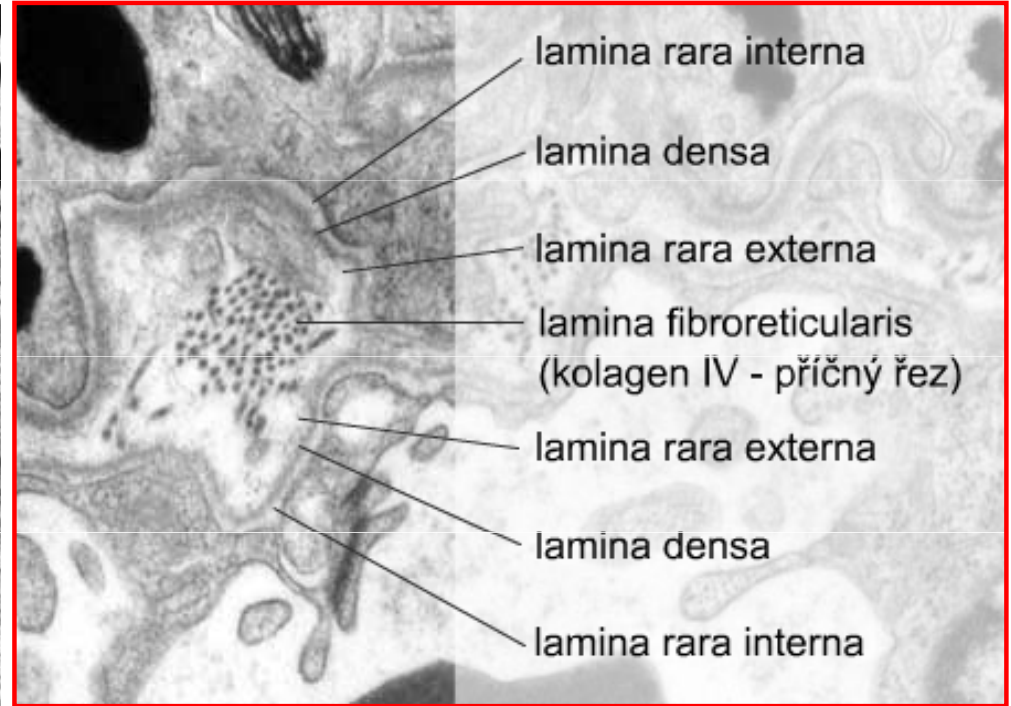
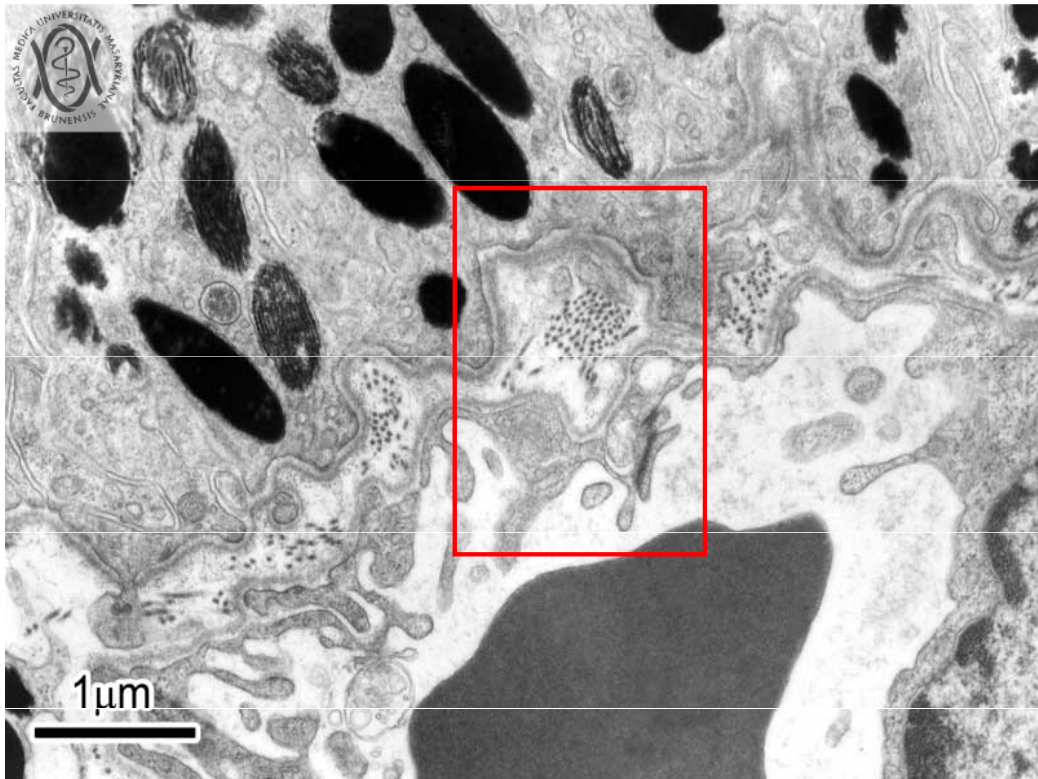
BASEMENT MEMBRANE



ARCHITECTURE OF BASEMENT MEMBRANE



MODIFICATIONS OF BASEMENT MEMBRANE



- **Two basic layers**

- lamina basalis

- lamina densa,
- lamina rara

if two epithelium and endothelium meet, laminae basalis may fuse. Then there is common lamina densa and lamina rara ext. and int.

- lamina fibroreticularis

- **Tissue specific modifications**

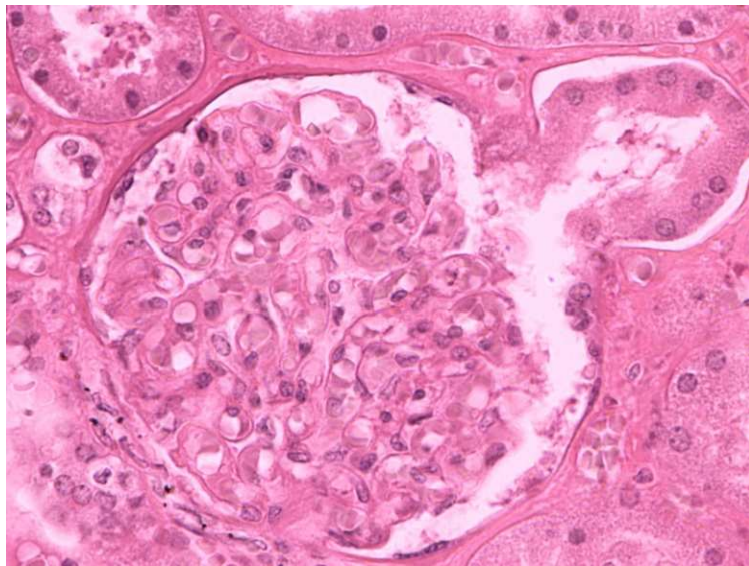
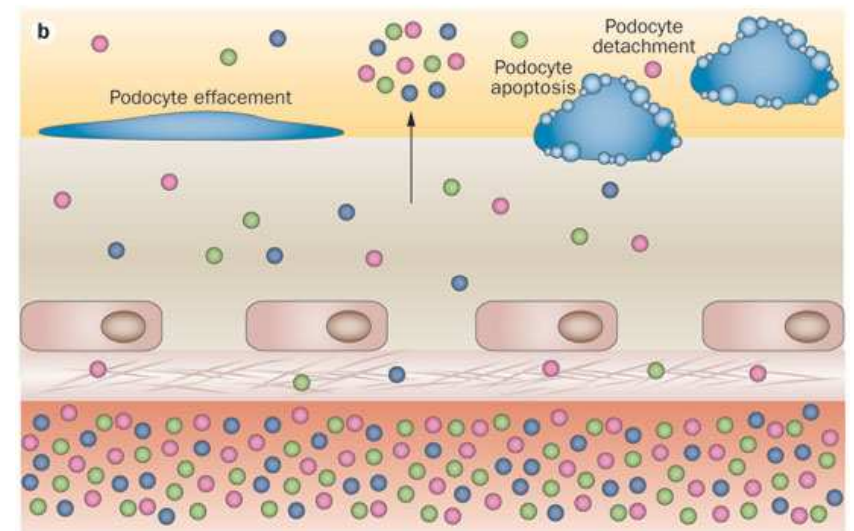
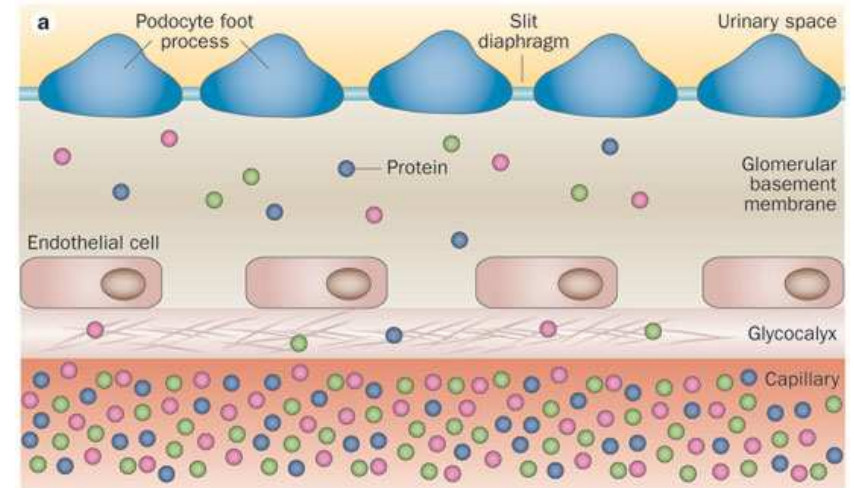
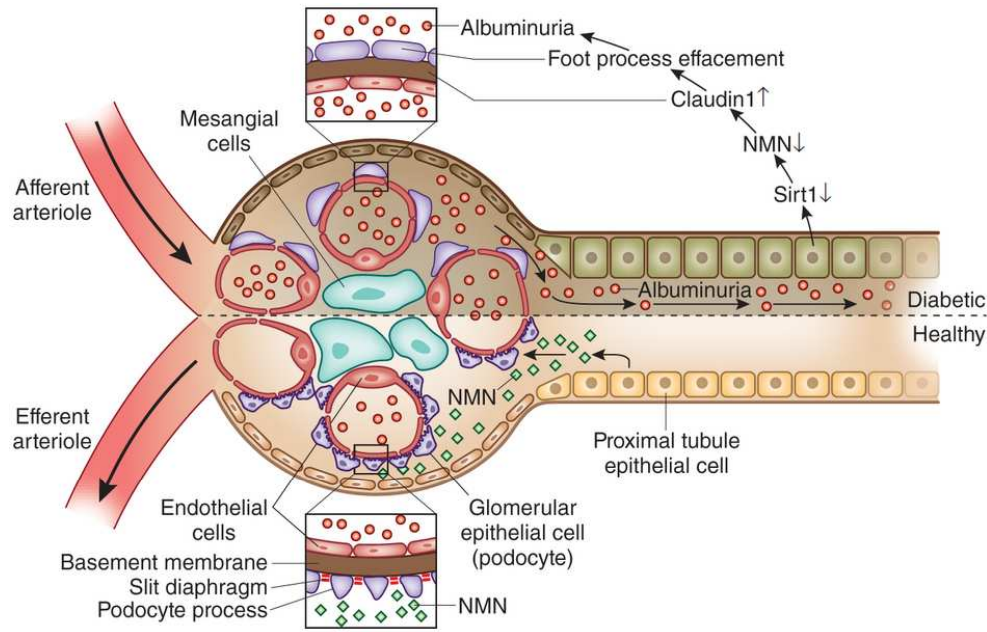
- Descemet membrane (cornea)

- Glomerular BM (Bowman's capsule)

- Part of Bruch's membran of retina

- ...

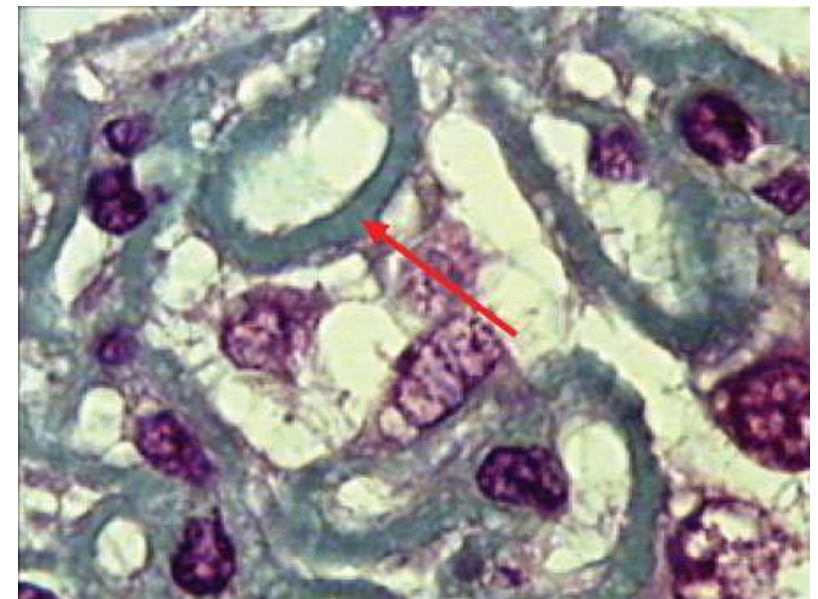
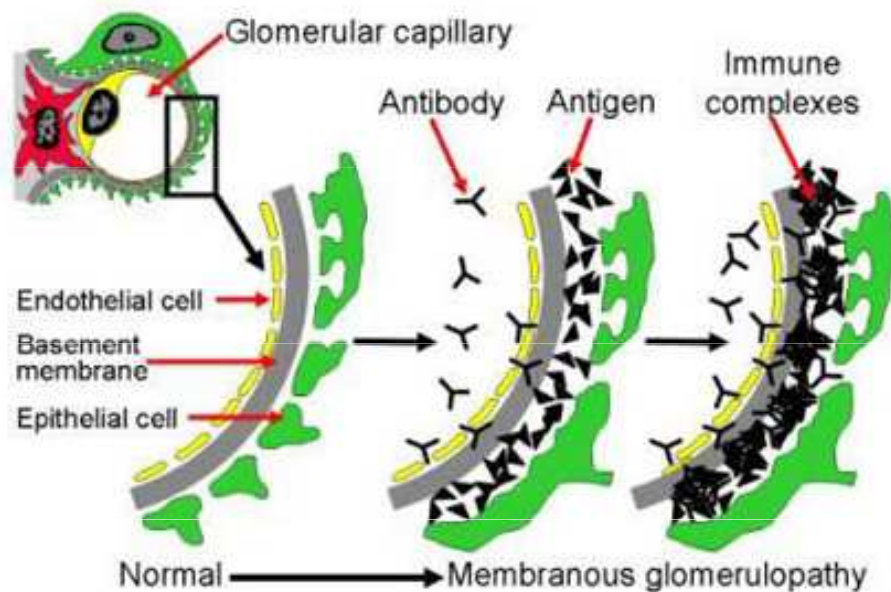
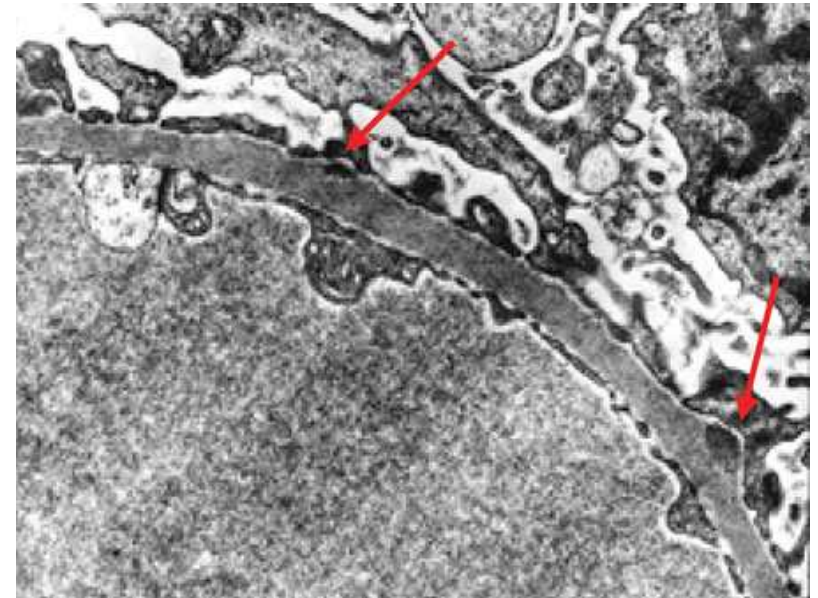
BASEMENT MEMBRANE IN CORPUSCULUM RENIS



BASEMENT MEMBRANE IN CORPUSCULUM RENIS

- **Clinical correlations – *membranous glomerulonephritis***

- circulating Abs bind to BM of capillary wall
- complement (C5b-C9) attacks glomerular endothelial cells
- filtration barrier compromised
- proteinuria, edema, hematuria, renal failure



EMBRYONIC ORIGIN OF EPITHELIAL TISSUE

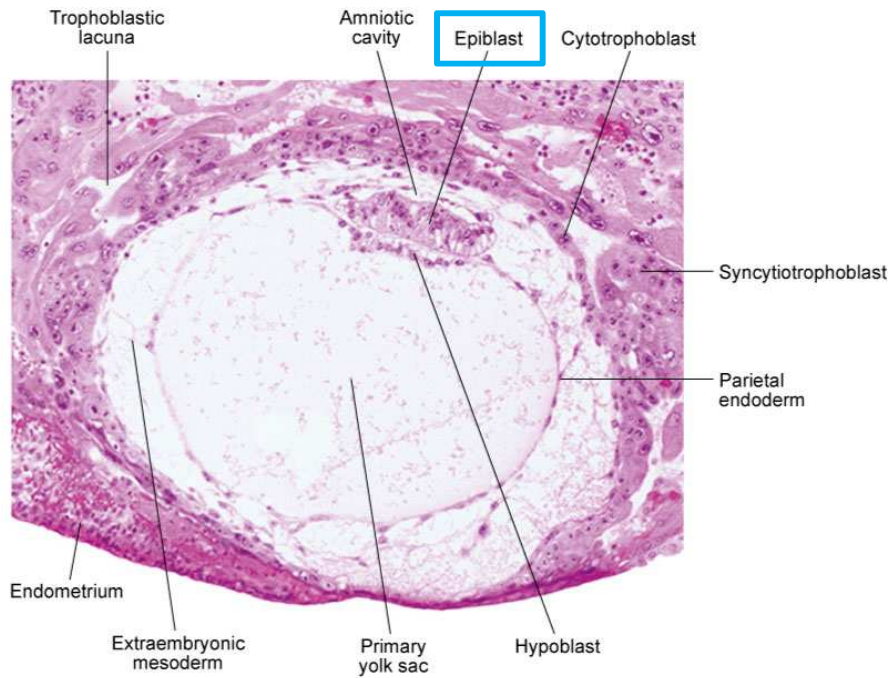


Fig. 5-3. Digital photomicrograph of a 12-day human embryo (Carnegie No. 7700) taken just as implantation within the endometrium is completed.

Courtesy of Dr. Ray Gasser.

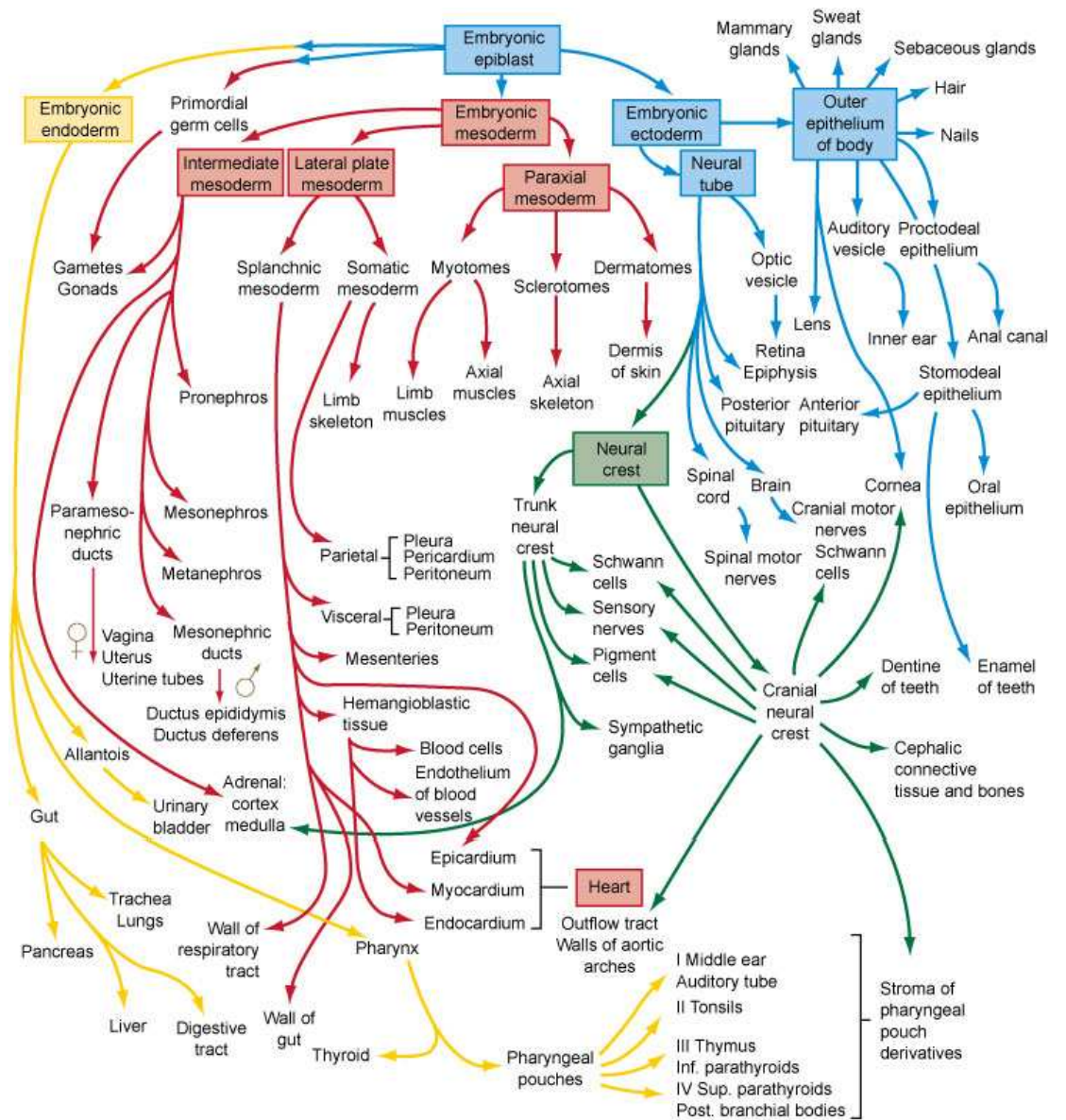


Fig. 6-27. Flow chart showing the formation of the organs and tissues of the embryo from the fundamental germ layers. The arrows are color-coded according to the germ layer of origin of the structure (see Fig. 4-1 for color code).

EMBRYONIC ORIGIN OF EPITHELIAL TISSUE

- derived from all three germ layers

Germ layer	Epithelial derivatives
Ectoderm	<ol style="list-style-type: none">1. Epidermis (stratified squamous keratinized epithelium)2. Sweat glands and ducts (simple and stratified cuboidal epithelium)3. Oral cavity, vagina, anal canal (stratified squamous non-keratinized epithelium)
Mesoderm	<ol style="list-style-type: none">1. Endothelium of blood vessels (simple squamous epithelium)2. Mesothelium of body cavities (simple squamous epithelium)3. Urinary and reproductive passages (transitional, pseudostratified and stratified columnar epithelium, simple cuboidal and columnar epithelium)
Endoderm	<ol style="list-style-type: none">1. Esophagus (stratified squamous non-keratinized epithelium)2. GIT (simple columnar epithelium)3. Gall bladder (simple columnar epithelium)4. Solid glands (liver, pankreas)5. Respiratory passages (ciliated pseudostratified columnar epithelium, ciliated simple columnar epithelium, cuboidal, squamous epithelium)

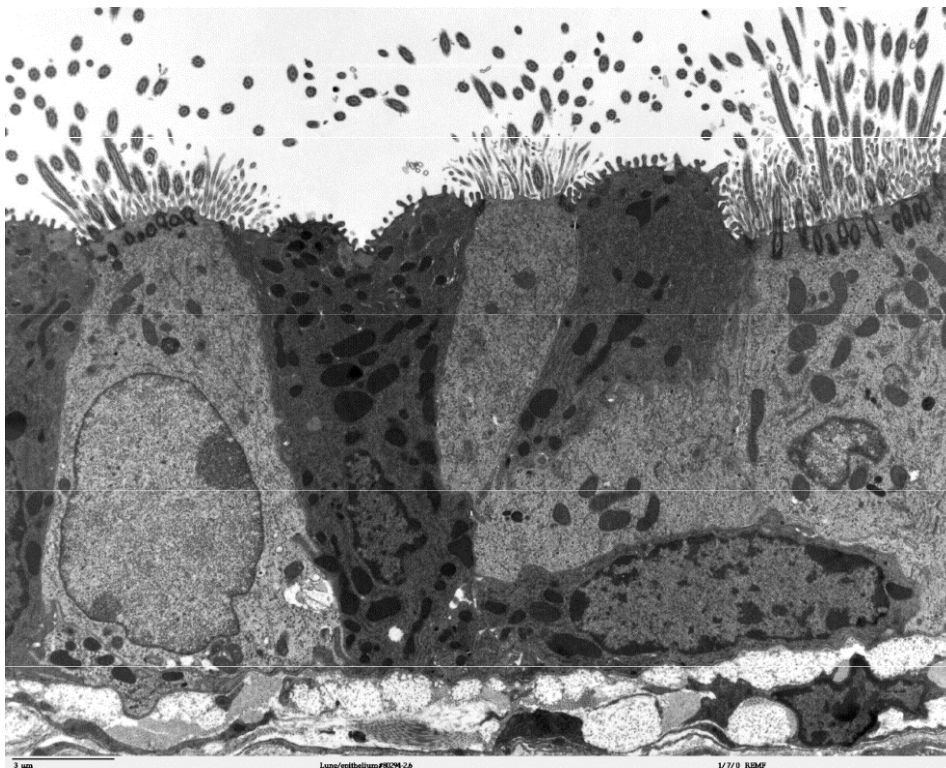
CLASSIFICATION OF EPITHELIAL TISSUE

According to

- 1) morphology
- 2) function

- Covering (sheet) epithelium
- Trabecular epithelium
- Reticular epithelium

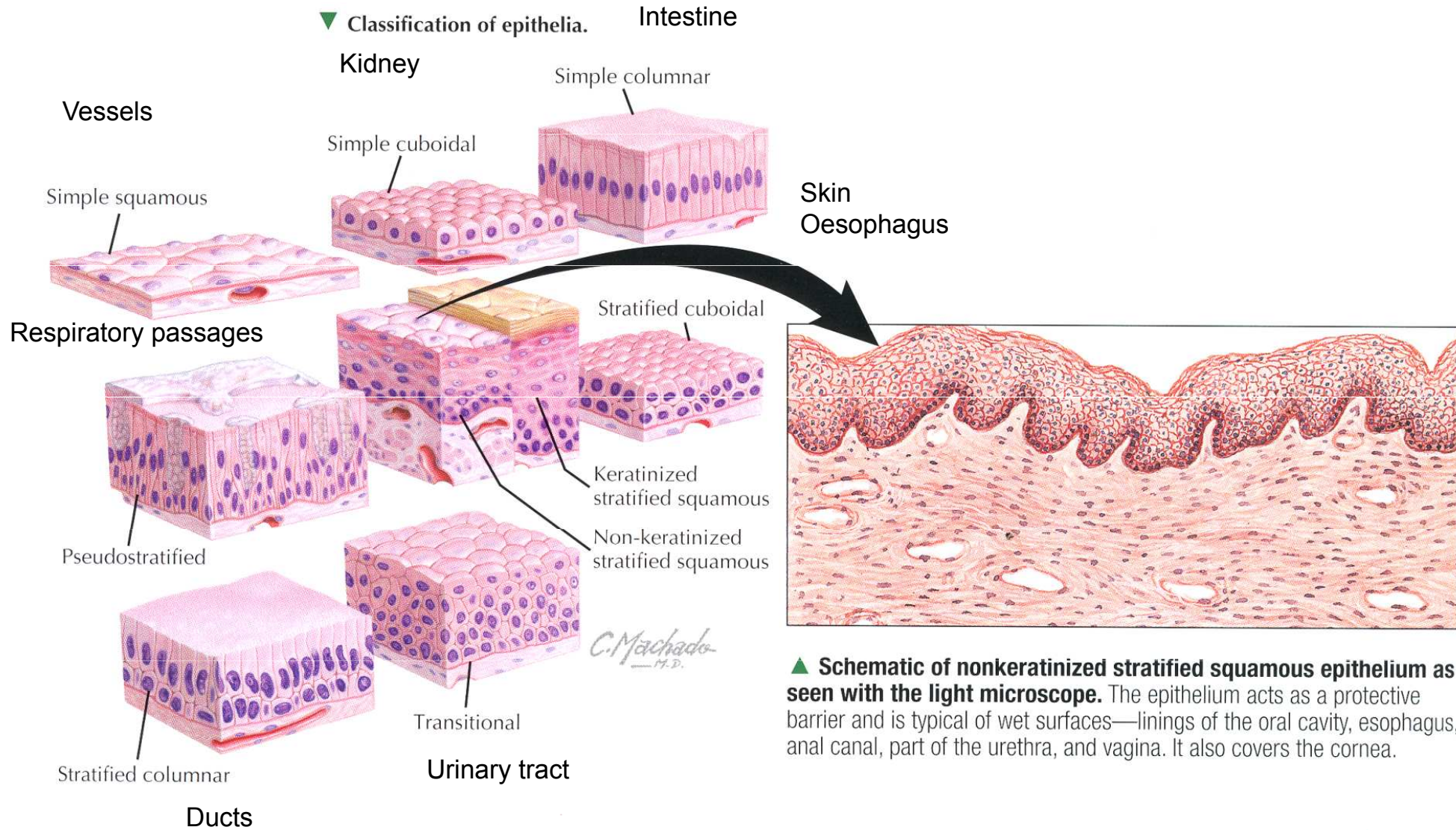
- Covering
- Glandular
- Resorptive
- Sensory
- Respiratory
- Alveolar
- Germinal
- ...



Classification by morphology

CLASSIFICATION OF EPITHELIAL TISSUE

1) Covering (sheet) epithelia

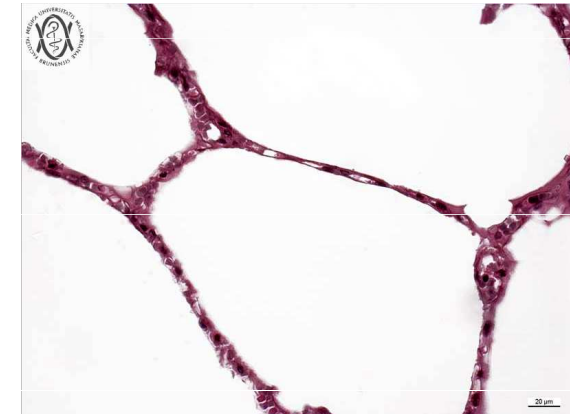
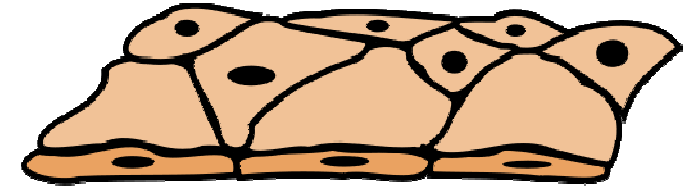


CLASSIFICATION OF EPITHELIAL TISSUE

■ Simple squamous epithelium

- Single layer of flat cells with central flat nuclei
- Capillaries
- Lung alveolus
- Glomerulus in renal corpuscle

} Selective permeability

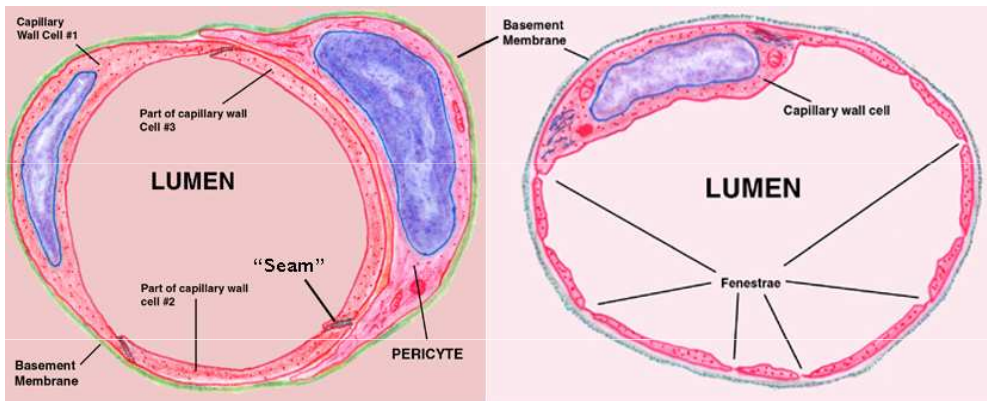


Endothelium

heart, blood, and lymphatic vessels.

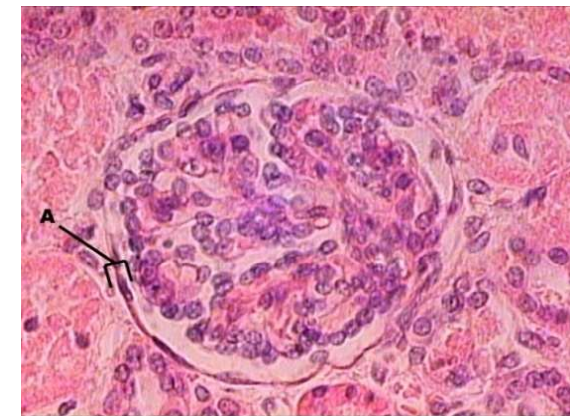
Mesothelium

serous membranes - body cavities

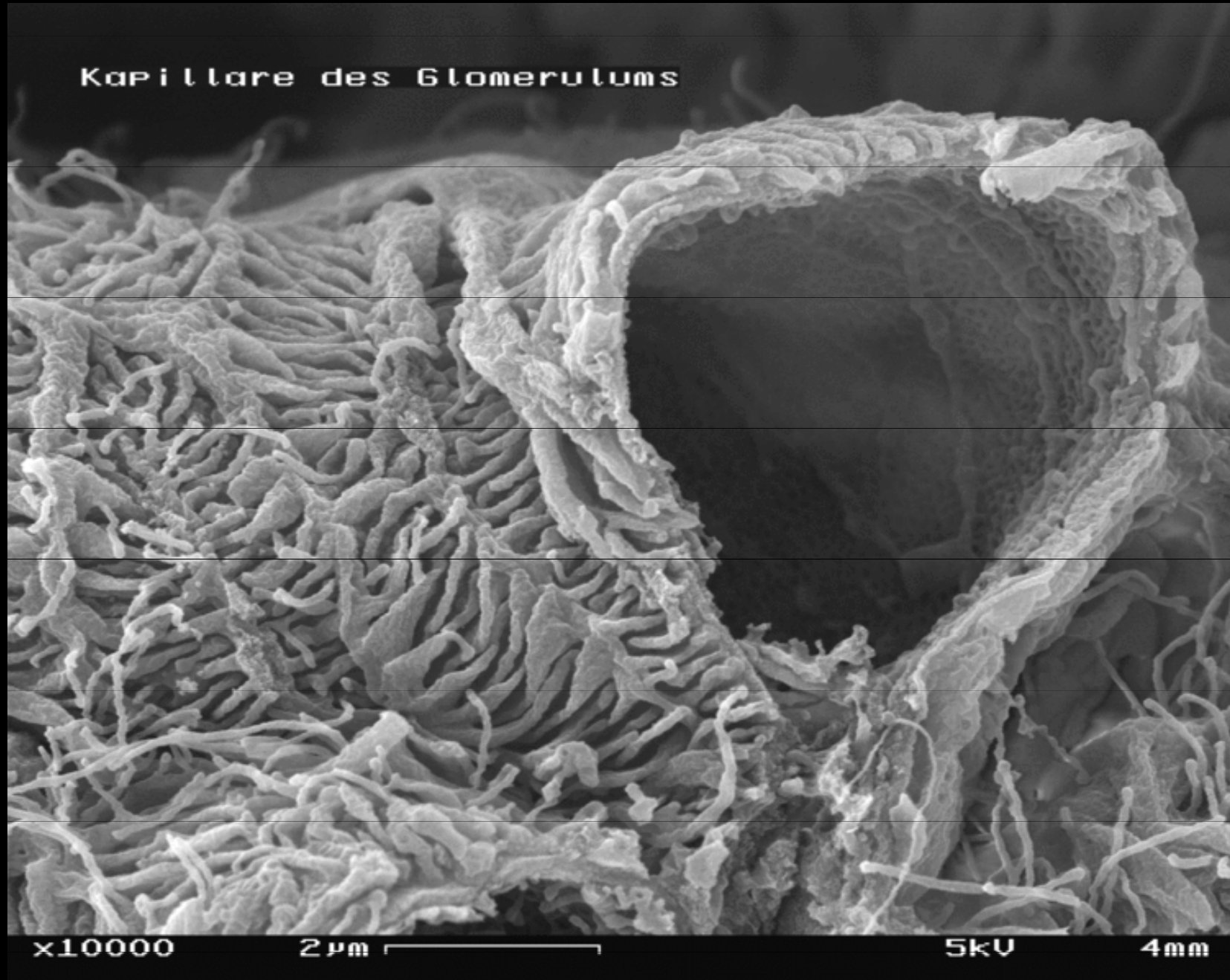


Closed or Continuous Capillary

Fenestrated Capillary



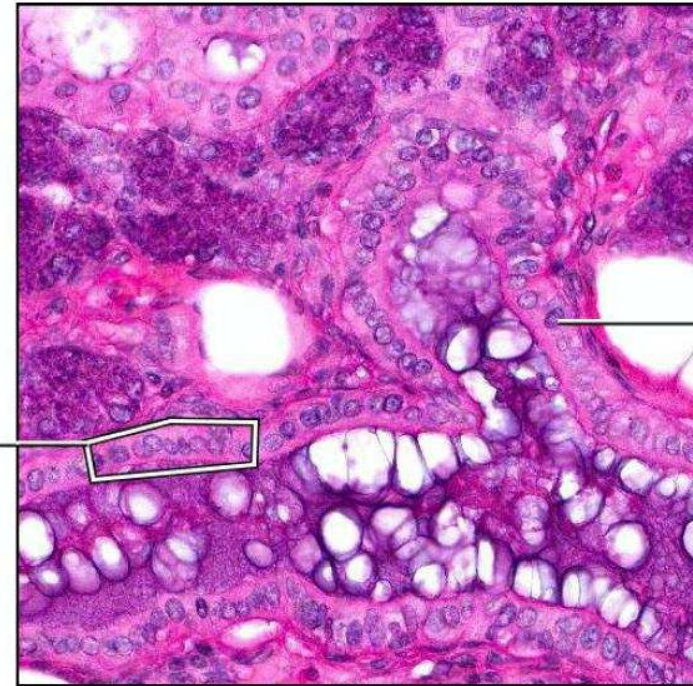
CLASSIFICATION OF EPITHELIAL TISSUE



CLASSIFICATION OF EPITHELIAL TISSUE

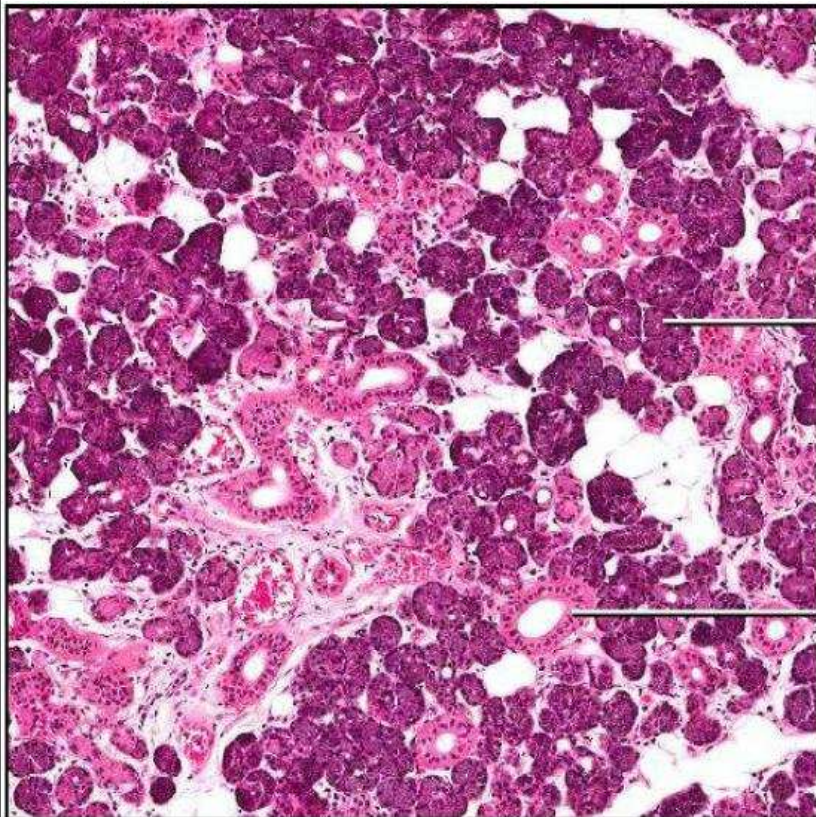
■ Simple cuboidal epithelium

- Single layer of cubic cells with large, spherical central nuclei
- Secretion or resorption



Nucleus of cuboidal epithelium cell

Simple cuboidal epithelium



Serous acini

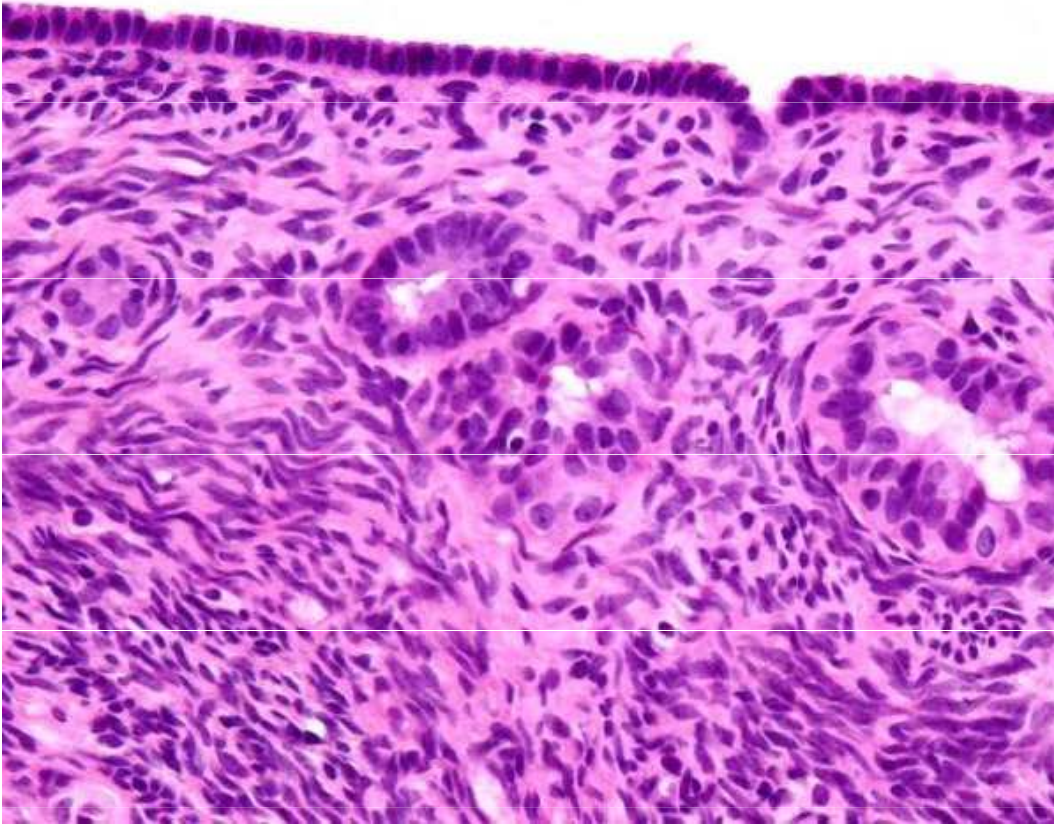
Simple cuboidal epithelium of intralobular duct

Examples:

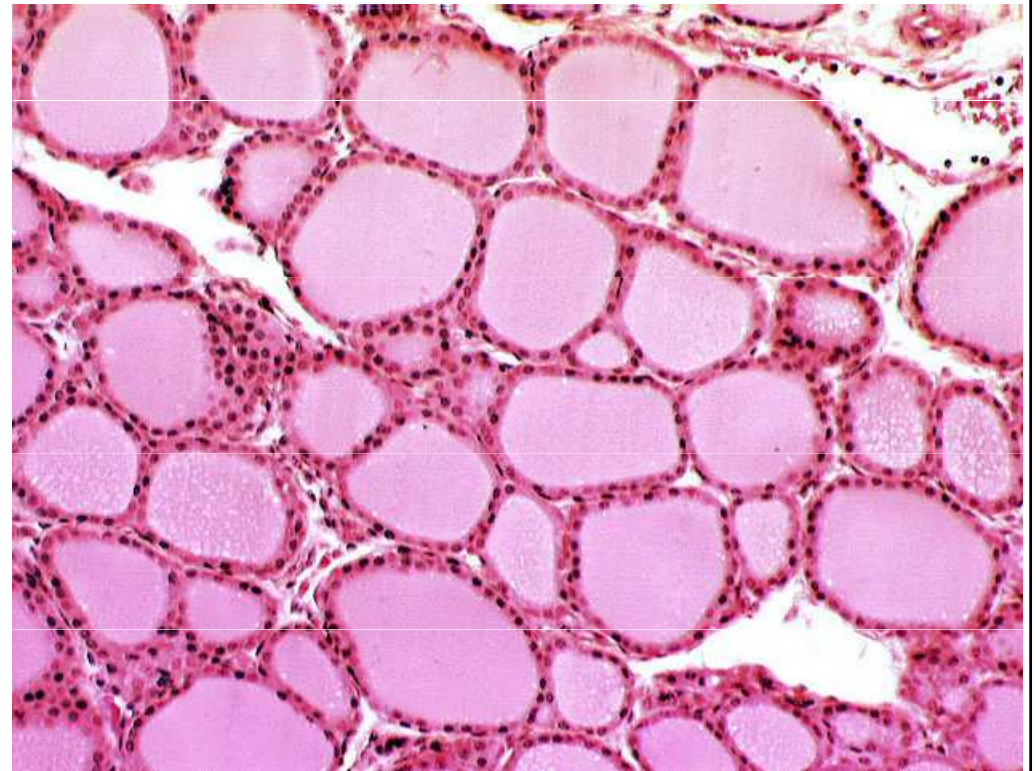
- Ovarian surface epithelium
- Renal tubules
- Thyroid
- Secretion acini

CLASSIFICATION OF EPITHELIAL TISSUE

Ovarian surface epithelium



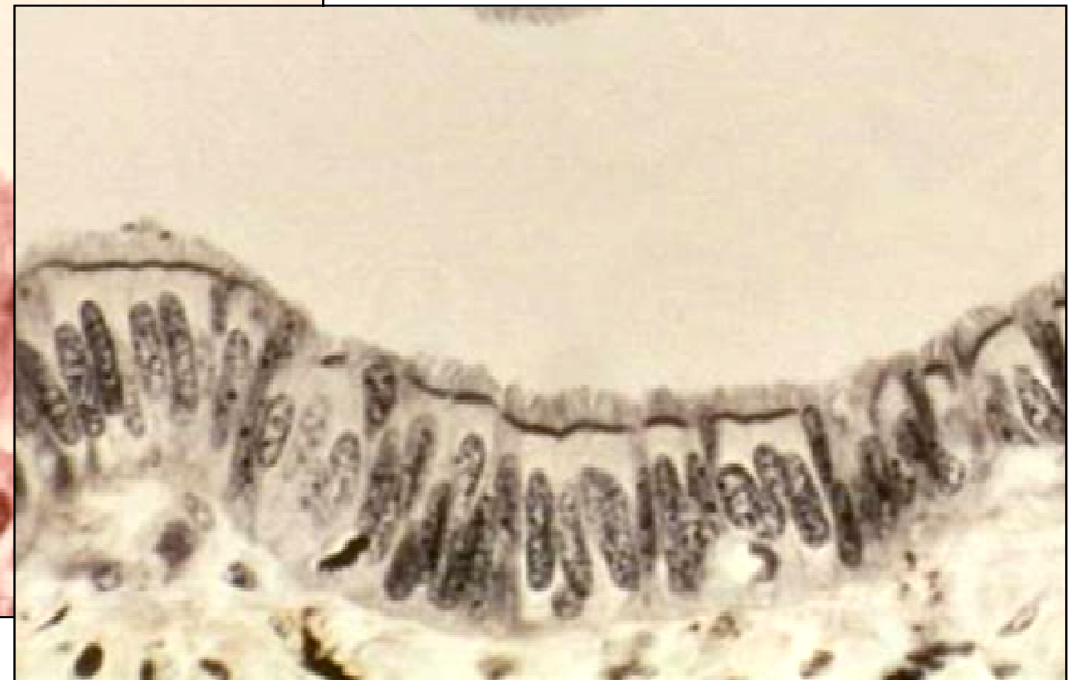
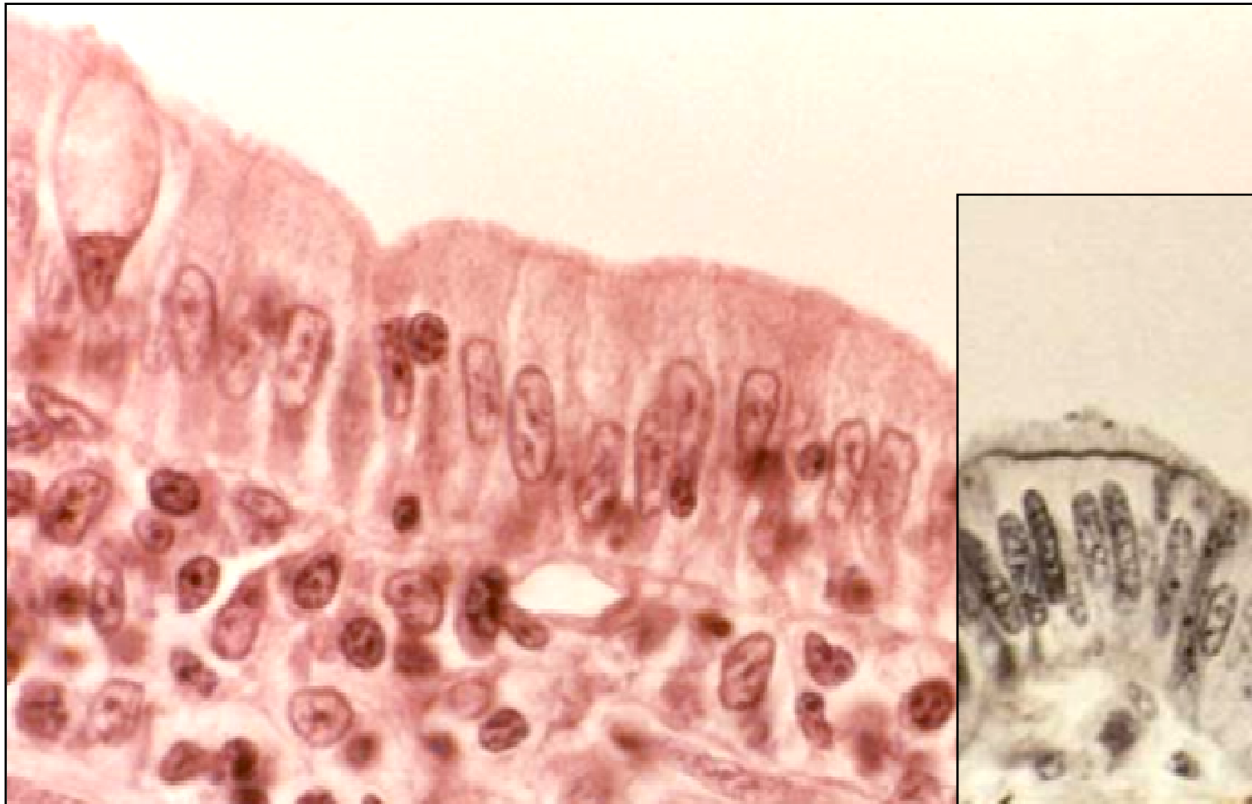
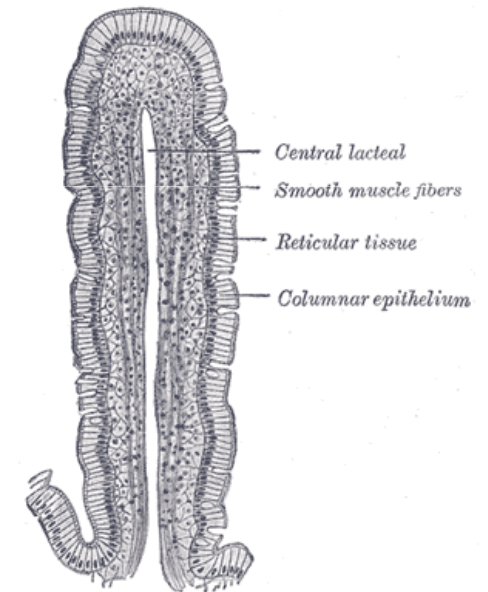
Thyroid follicles



CLASSIFICATION OF EPITHELIAL TISSUE

■ Simple columnar epithelium

- Single layer of columnar cells with large, oval, basally located nucleus
- **Typical epithelium of GIT**
 - stomach
 - small and large intestine
 - gall bladder

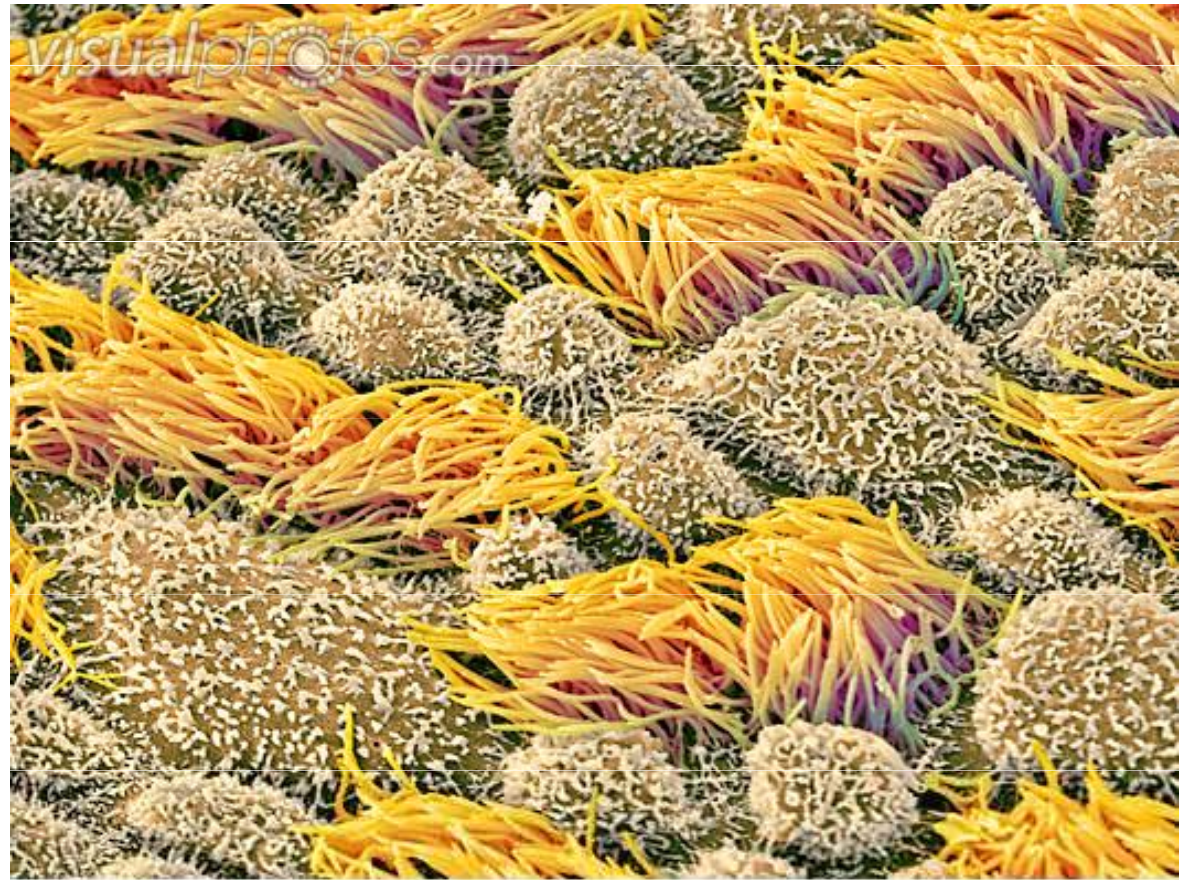
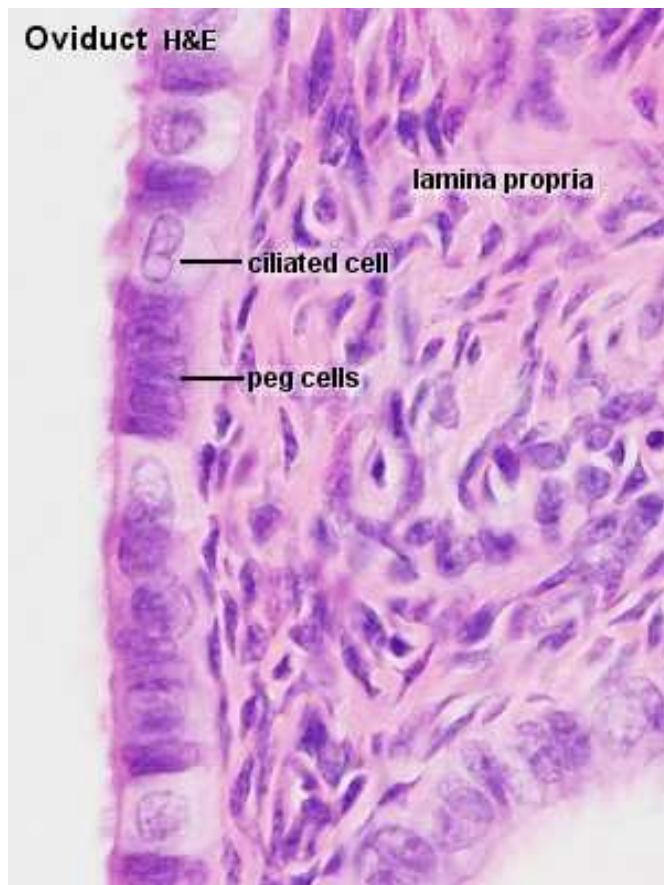


CLASSIFICATION OF EPITHELIAL TISSUE

■ Simple columnar epithelium with kinocilia

Uterine tube

- flow of the oocyte towards the uterus

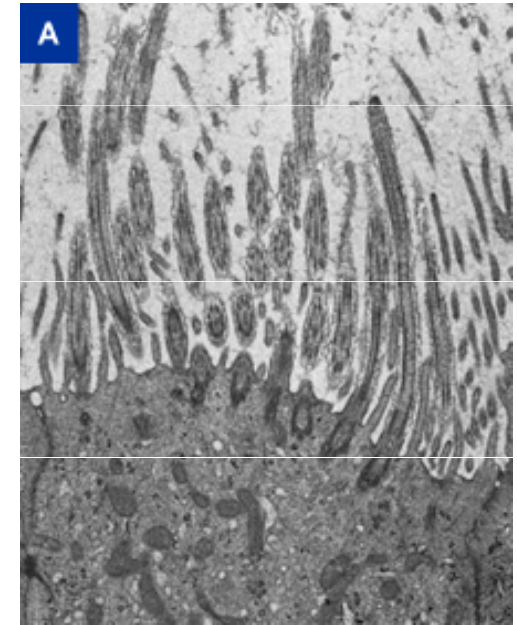
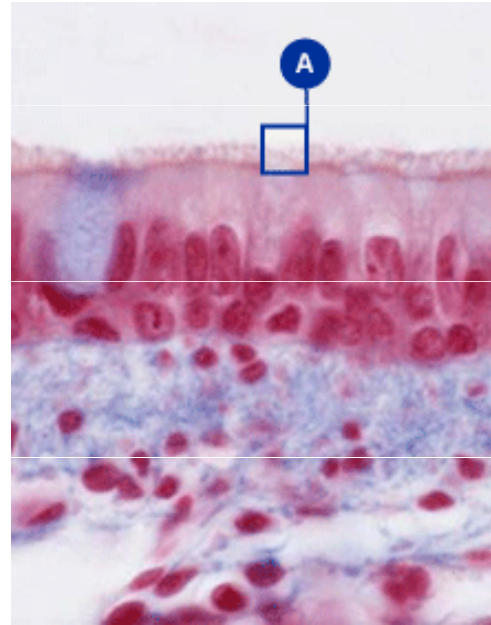
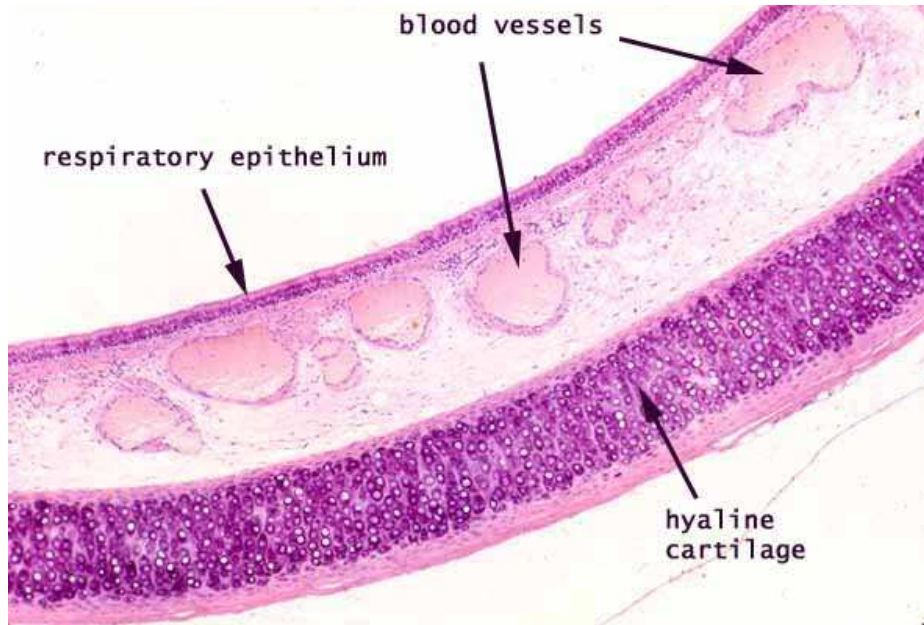


CLASSIFICATION OF EPITHELIAL TISSUE

■ Pseudostratified columnar epithelium with kinocilia

Upper respiratory passages

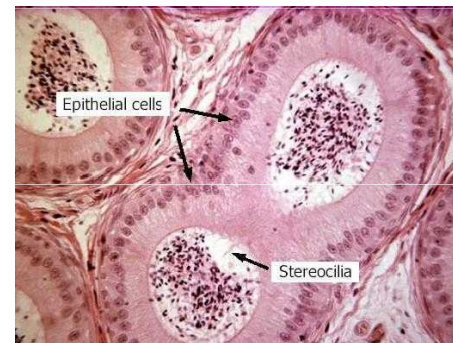
- Removal of mucus produced by epithelial glands



■ Pseudostratified columnar epithelium with stereocilia

Male reproductive passages

- Epididymis
- Ductus deferens



CLASSIFICATION OF EPITHELIAL TISSUE

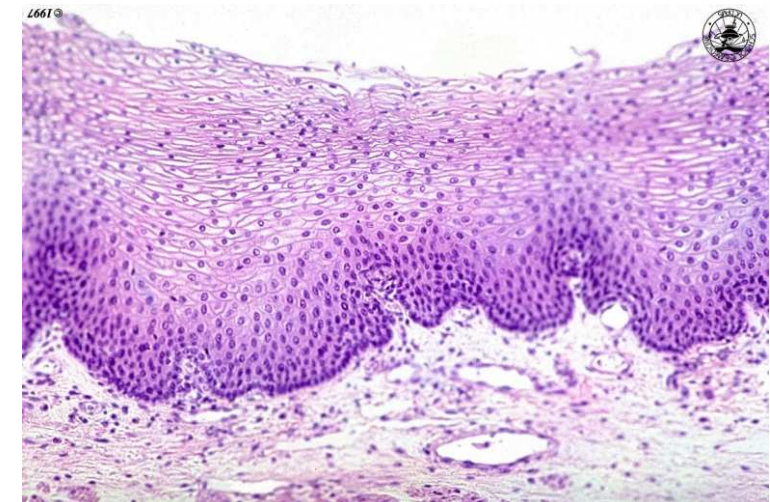
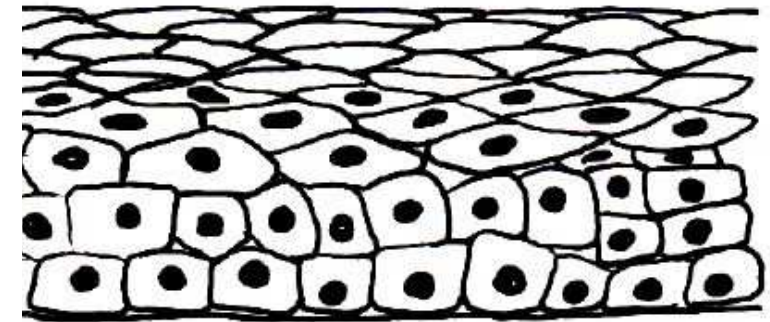
▪ Stratified squamous epithelium

- Multiple layers of cubic cells with central nuclei, flattening towards surface
- First layer in contact with BM, last layer – flat
- Constant abrasion
- Mechanical resilience
- Protection from drying
- Rapid renewal

Keratinized vs. non-keratinized

Examples:

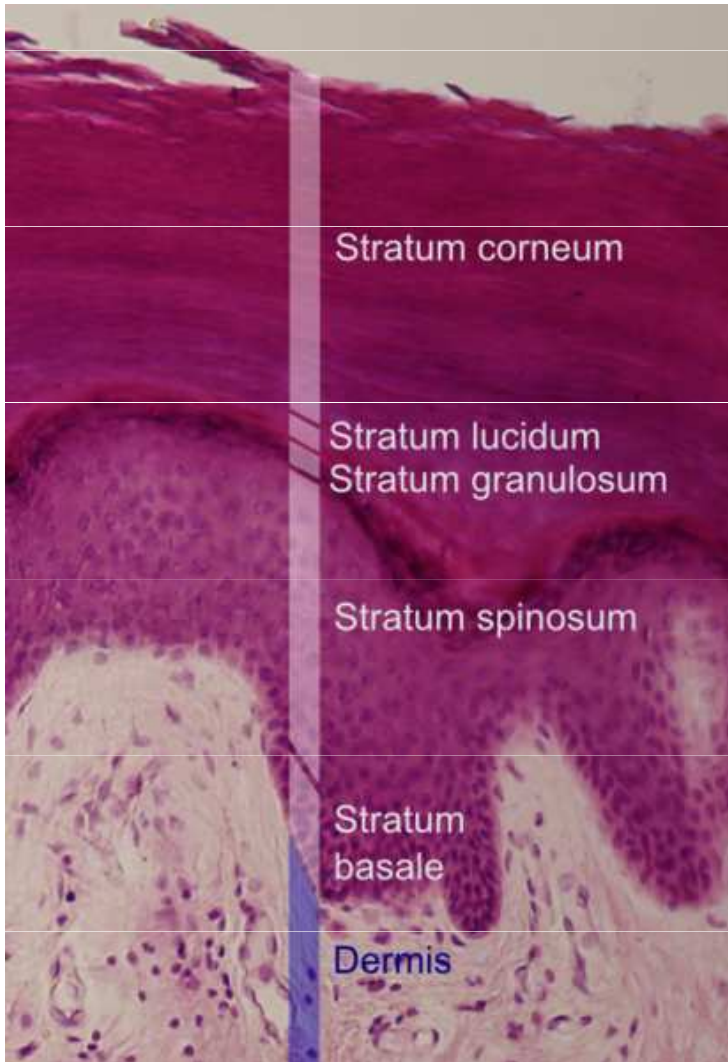
- Cornea
- Oral cavity and lips
- Esophagus
- Anal canal
- Vagina



CLASSIFICATION OF EPITHELIAL TISSUE

Stratified squamous epithelium

Keratinized



Skin (epidermis)

Nail

Keratins

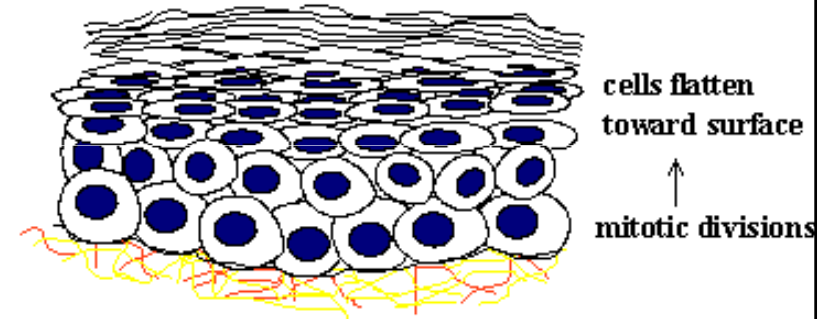
Fibrous proteins, ~ 40 types

Very stable, multimeric

Disorders of keratin expression
– variety of clinical symptoms

e.g. Epidermolysis bullosa simplex

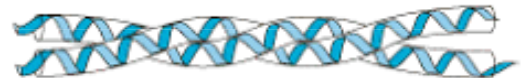keratinized stratified squamous
dead, keratinized cells at surface



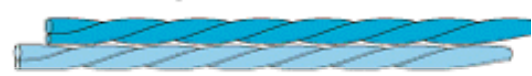
α -Helix




Coiled coil of two α -helices



Protofilament (pair of coiled coils)



Filament (four right-hand twisted protofibrils)

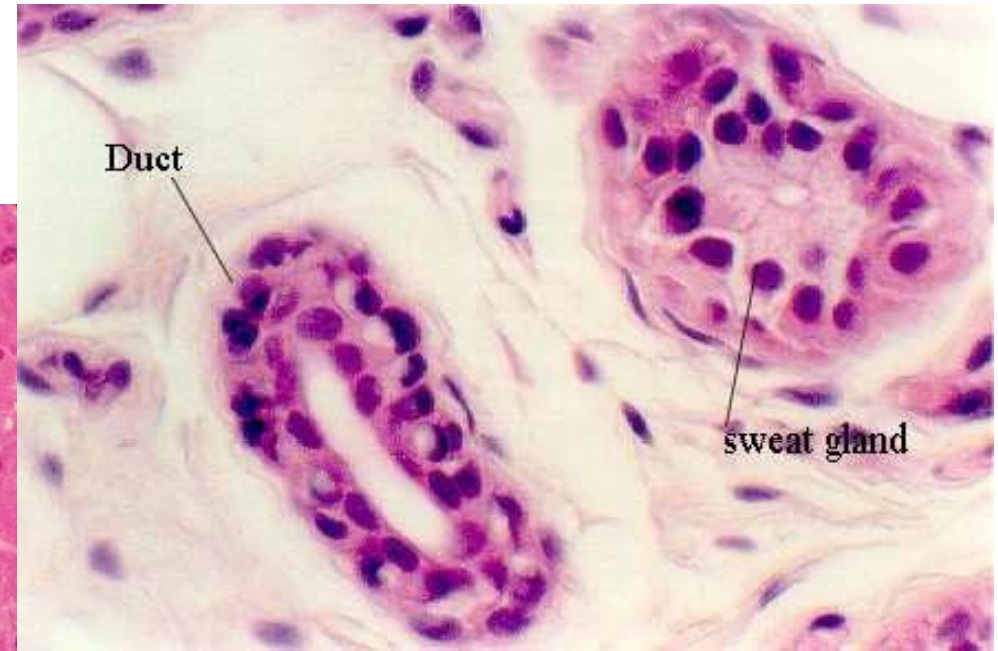
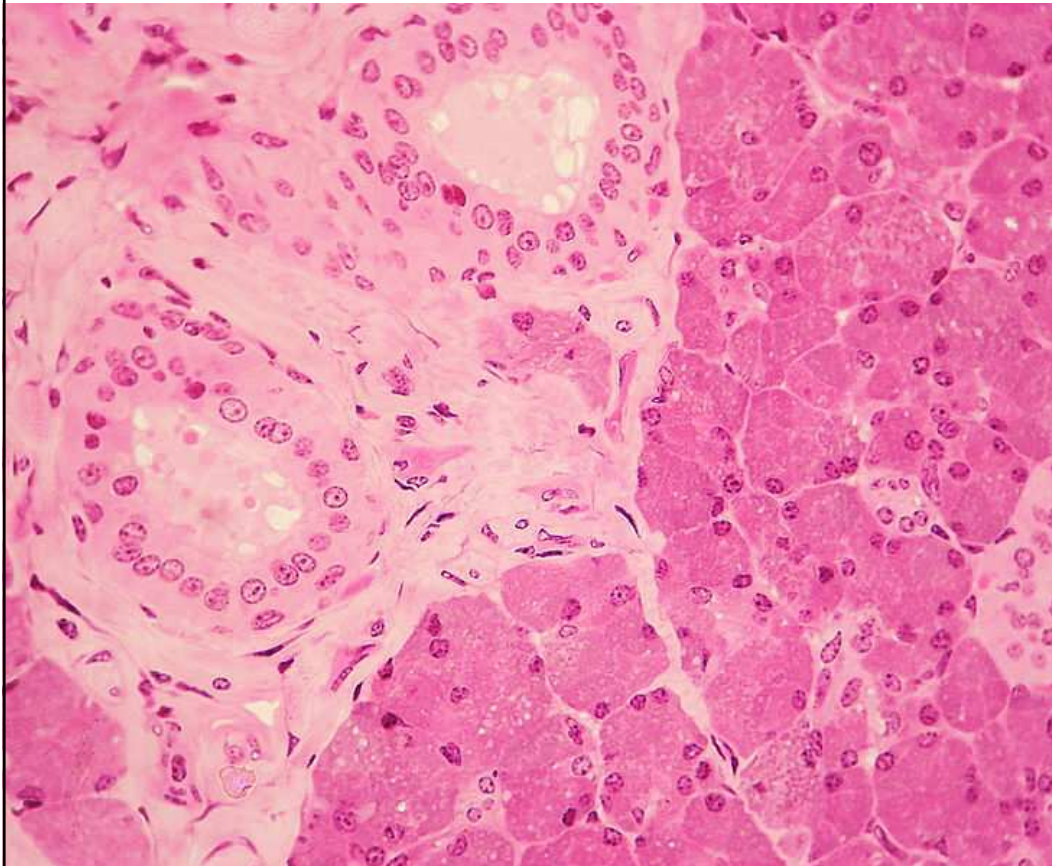


CLASSIFICATION OF EPITHELIAL TISSUE

▪ Stratified cuboidal epithelium

Large ducts of :

- sweat glands
- mammary glands
- salivary glands



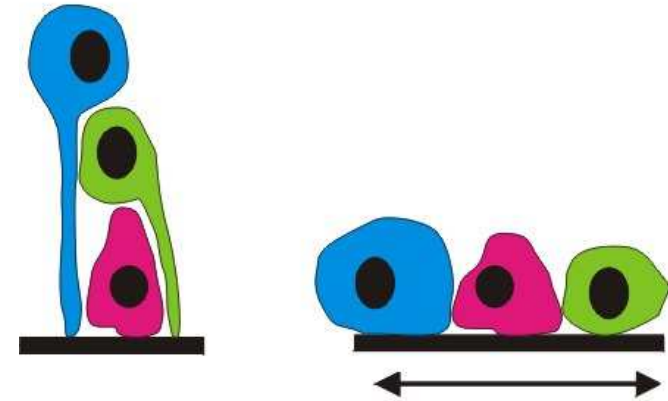
CLASSIFICATION OF EPITHELIAL TISSUE

■ Transitional epithelium (urothelium)

- fluctuation of volume
- organization of epithelial layers
- membrane reserve
- protection against hyperosmotic urine

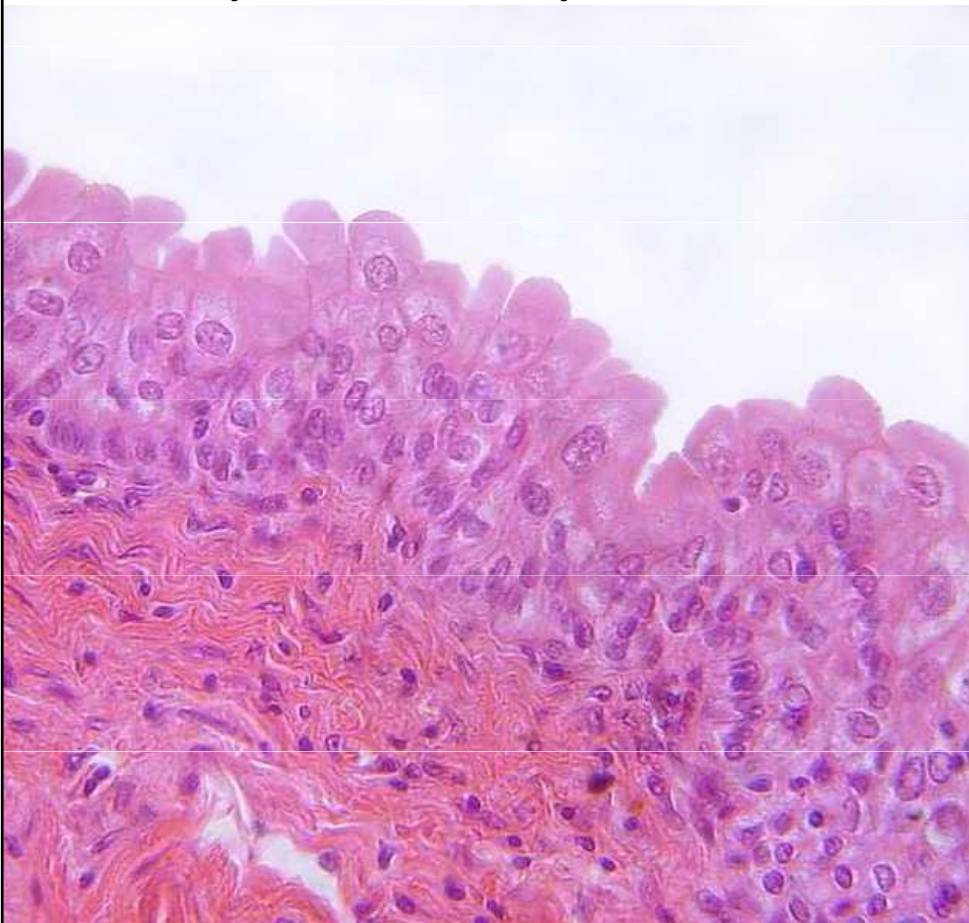
Urinary system

- urinary bladder, kidneys, ureters

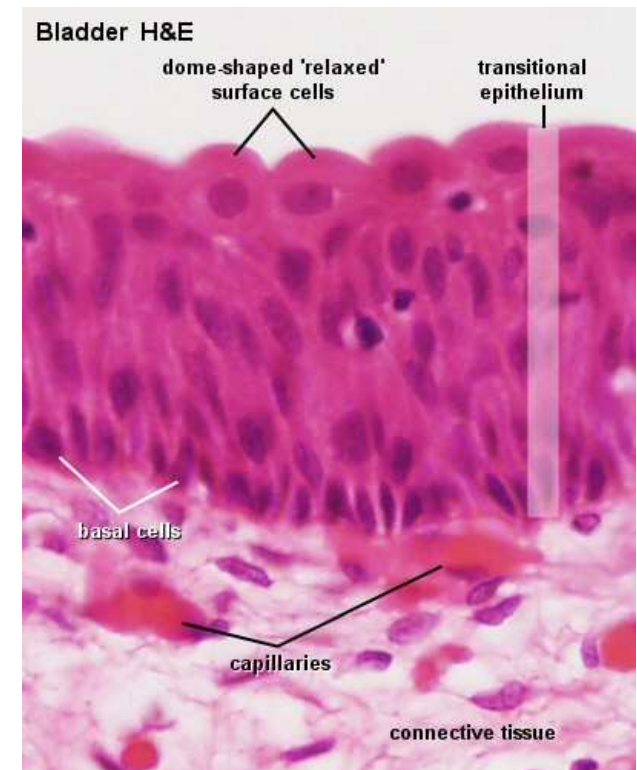


Empty: rather cuboidal with a domed apex

Relaxed: flat, stretched



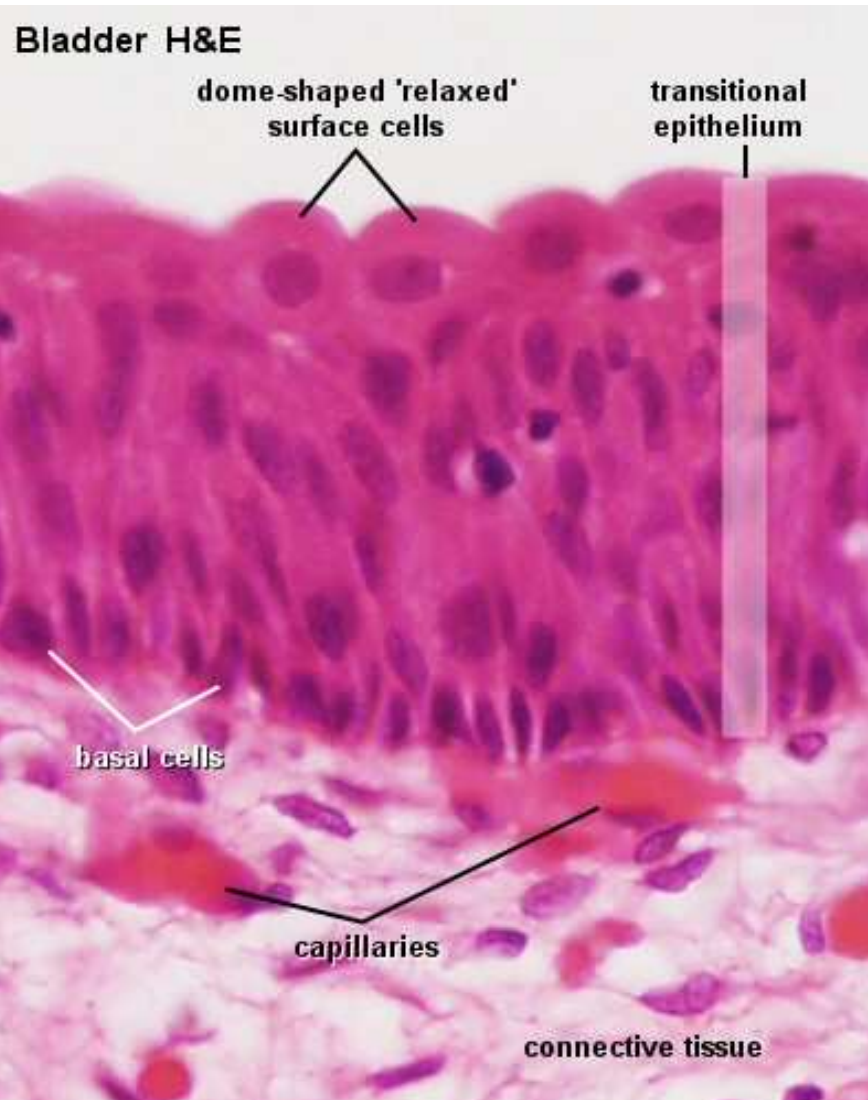
Basal cells
Intermediate layer
Surface cells



CLASSIFICATION OF EPITHELIAL TISSUE

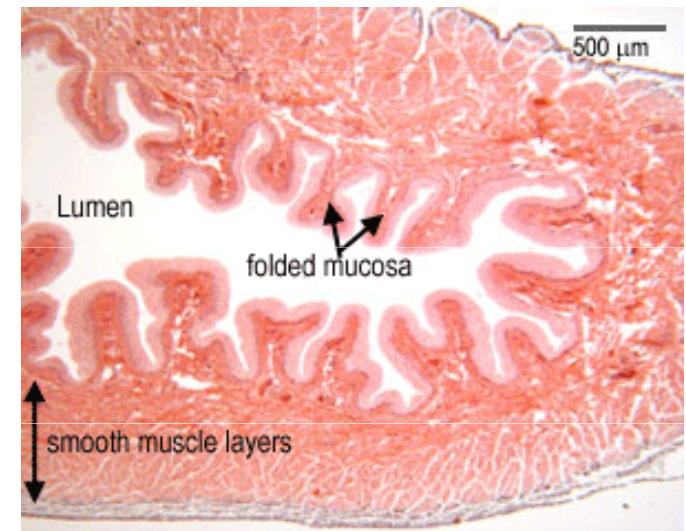
■ Transitional epithelium (urothelium)

- glycosaminoglycan layer (GAG) on the surface
- osmotic barrier
- antimicrobial properties



Barrier architecture:

- GAG-layer
- surface cells (tight junctions), uroplakin proteins in the apical cell membrane
- capillary plexus in the submucosa

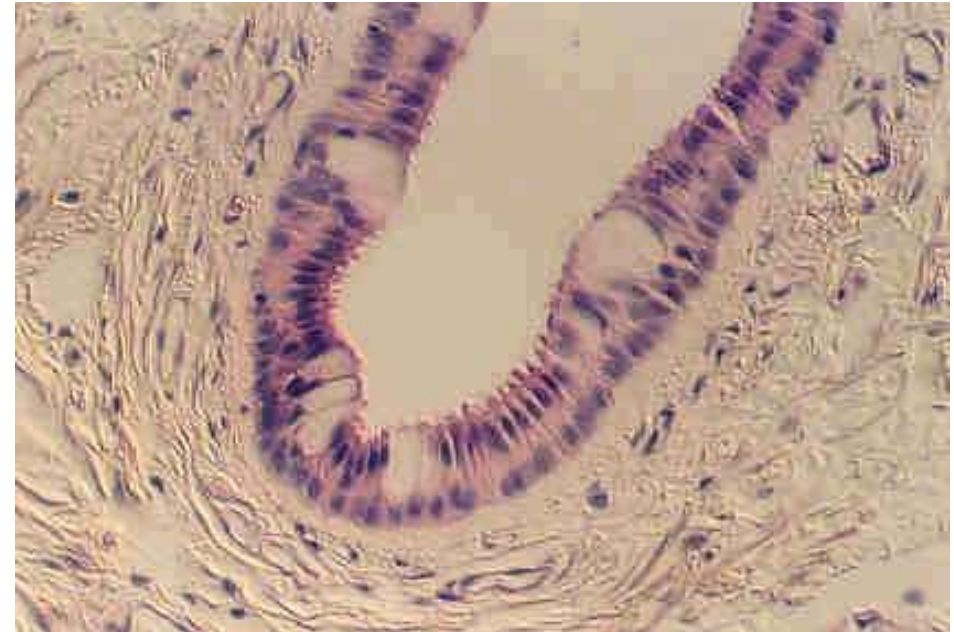
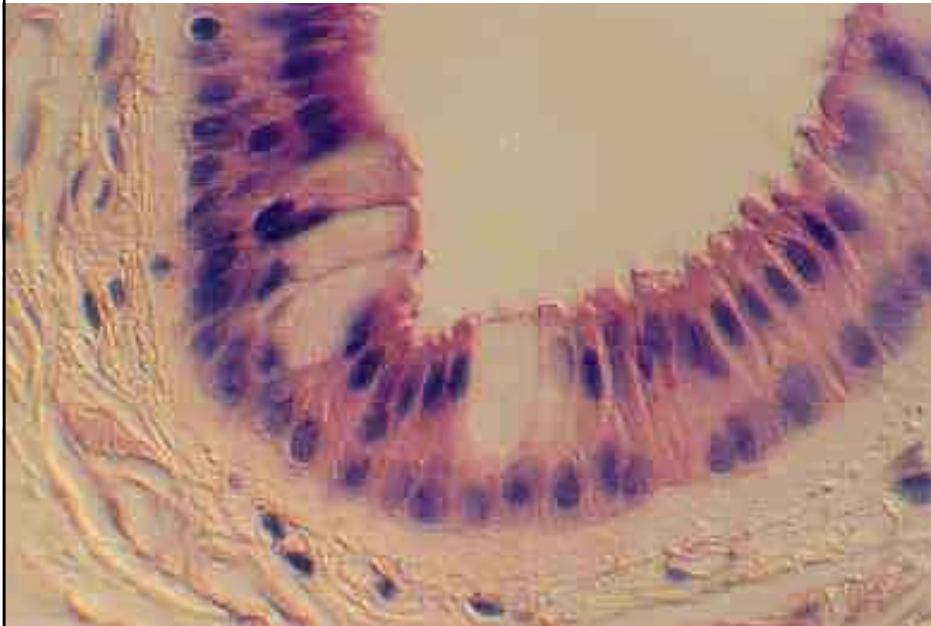
CLASSIFICATION OF EPITHELIAL TISSUE

■ Stratified columnar epithelia

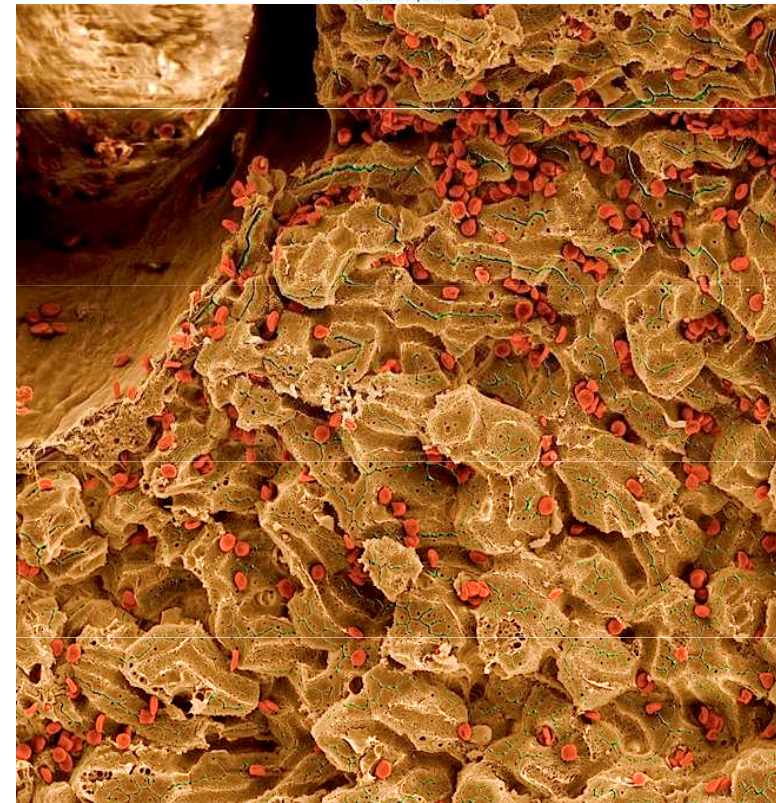
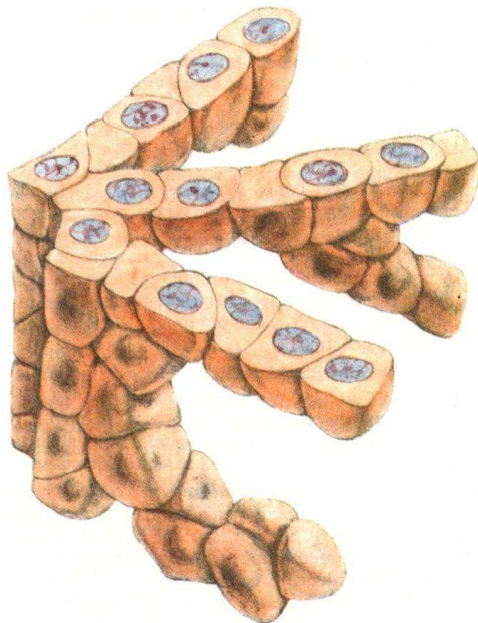
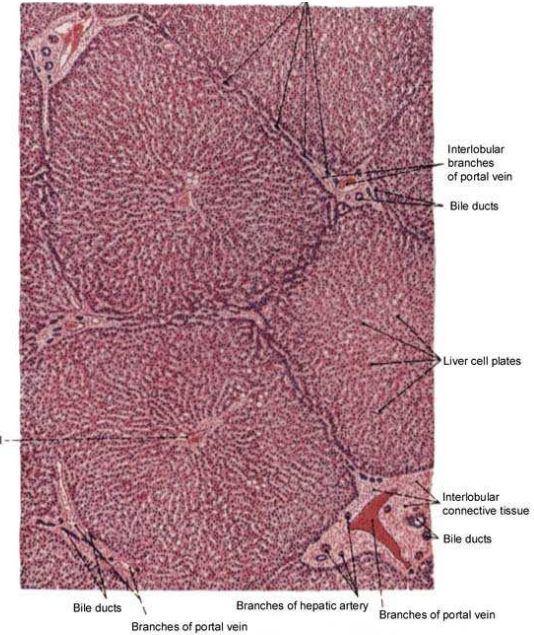
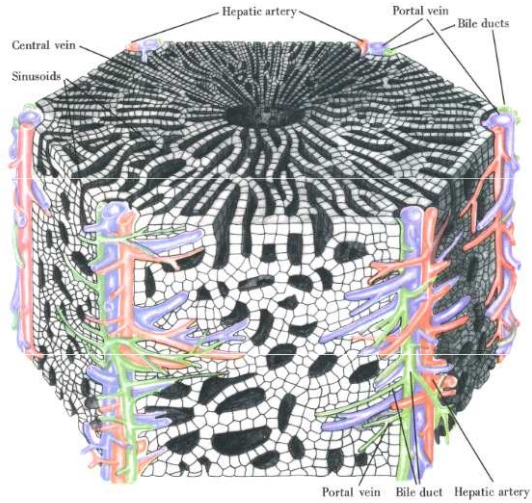
- several layers of columnar cells
- secretion / protection

- ocular conjunctiva
- pharynx, anus – transitions
- uterus, male urethra, vas deferens
- intralobular ducts of salivary glands



CLASSIFICATION OF EPITHELIAL TISSUE

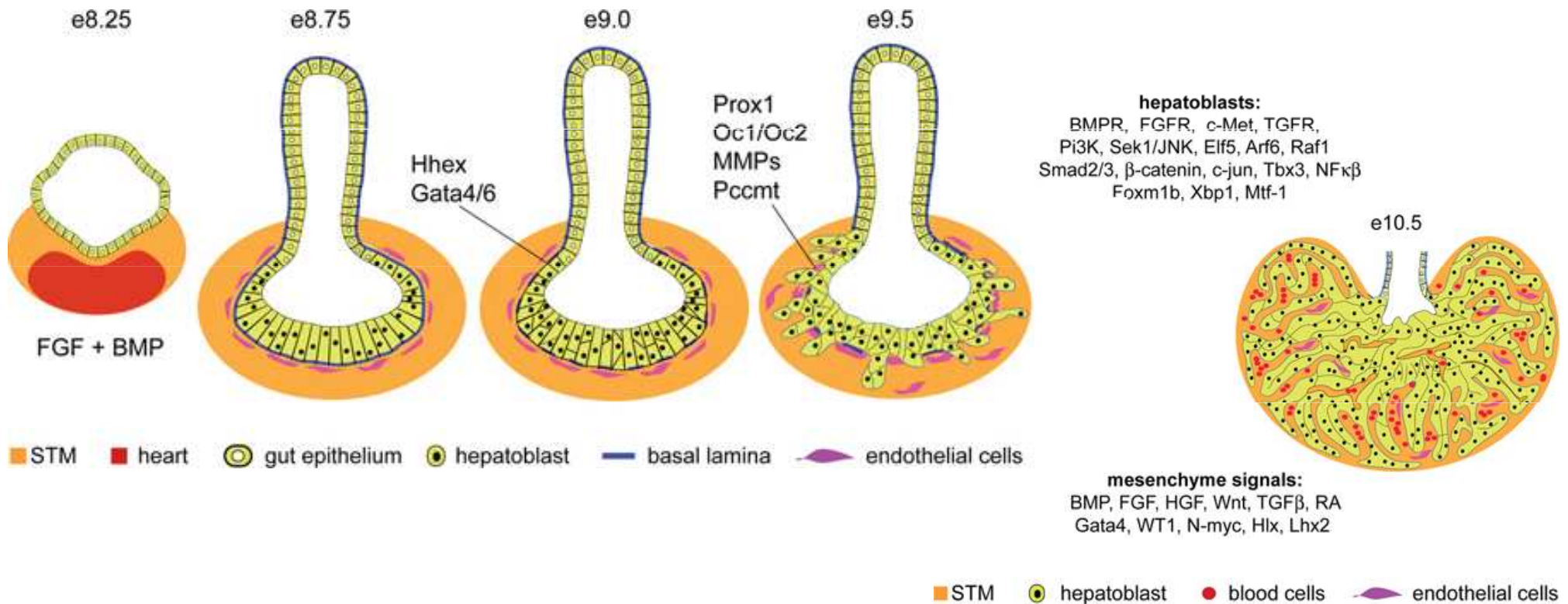
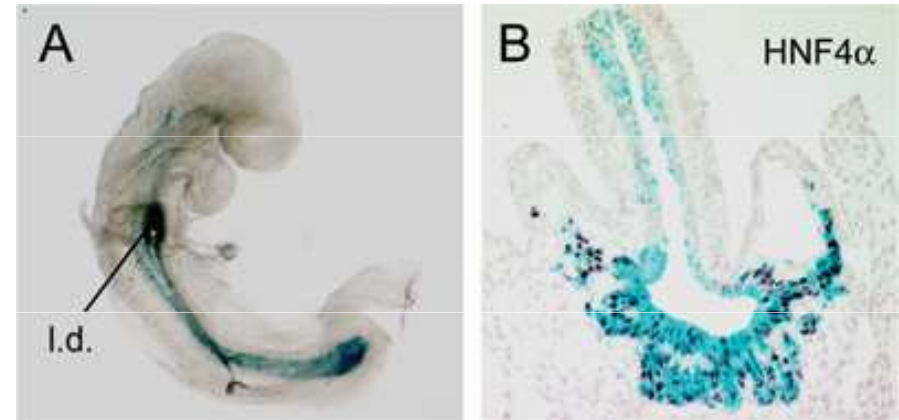
2) Trabecular epithelium



CLASSIFICATION OF EPITHELIAL TISSUE

■ Liver

Cords of hepatocytes

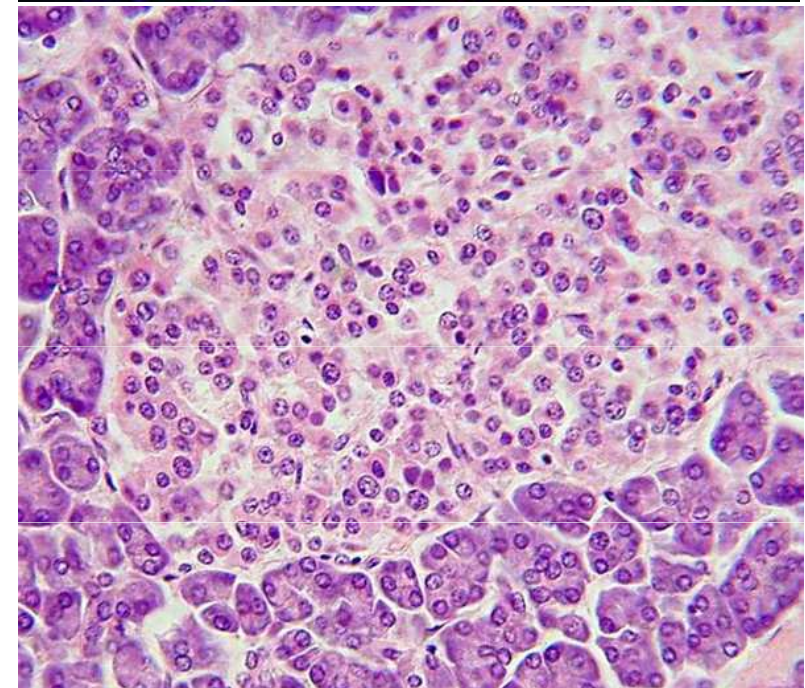
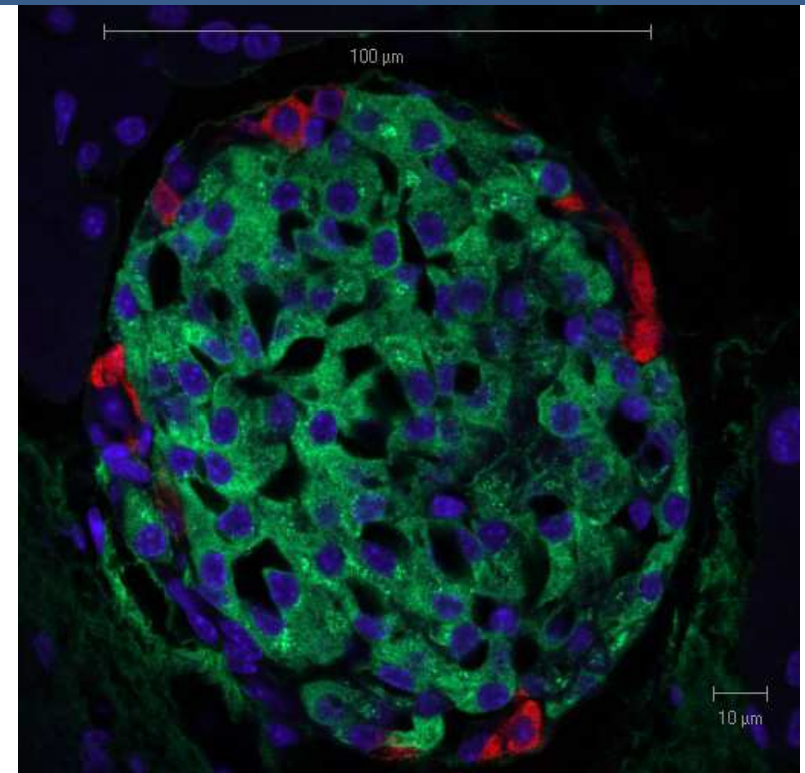
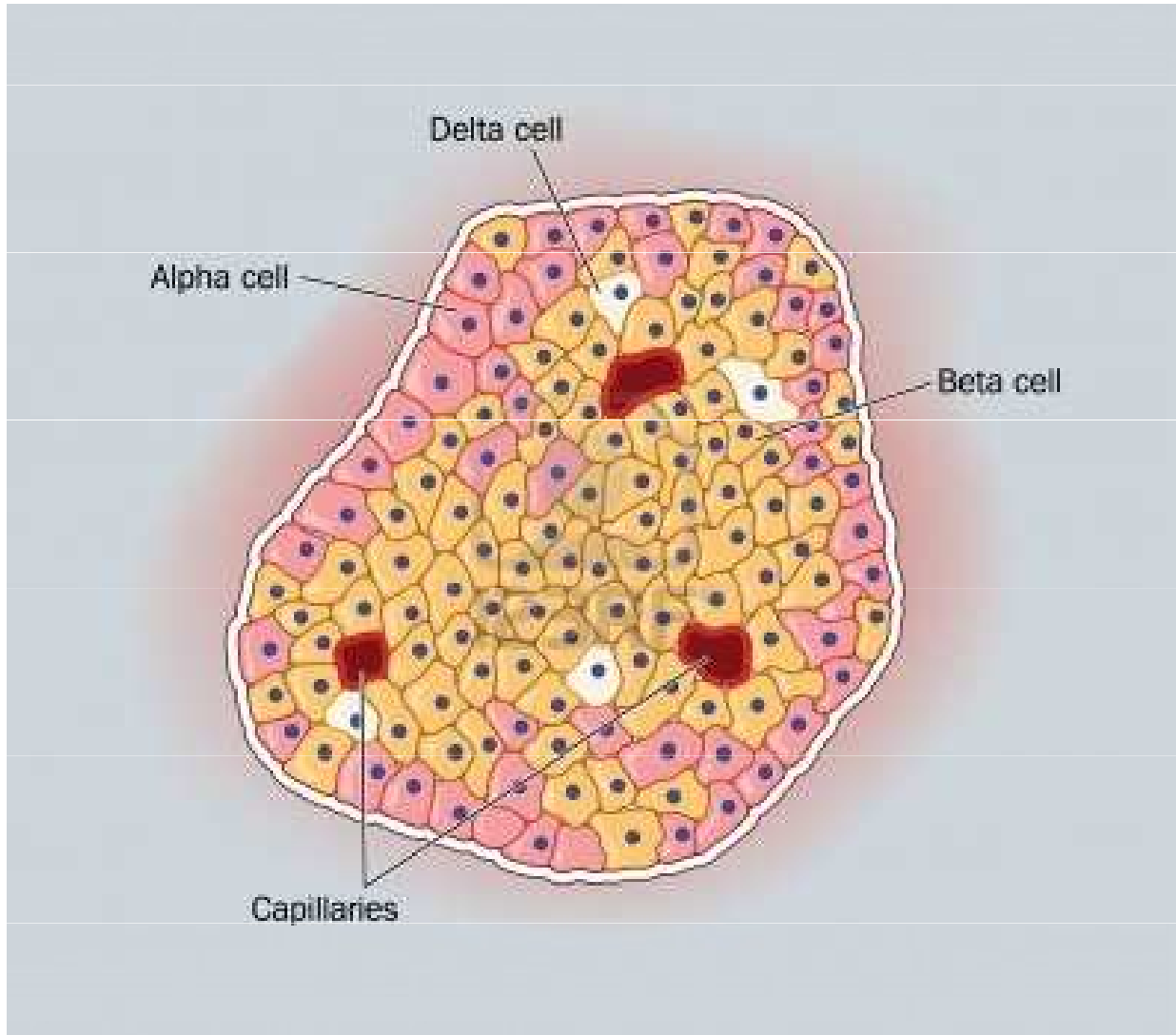


CLASSIFICATION OF EPITHELIAL TISSUE

■ Endocrine glands

Islets of Langerhans

Cords of endocrine active cells

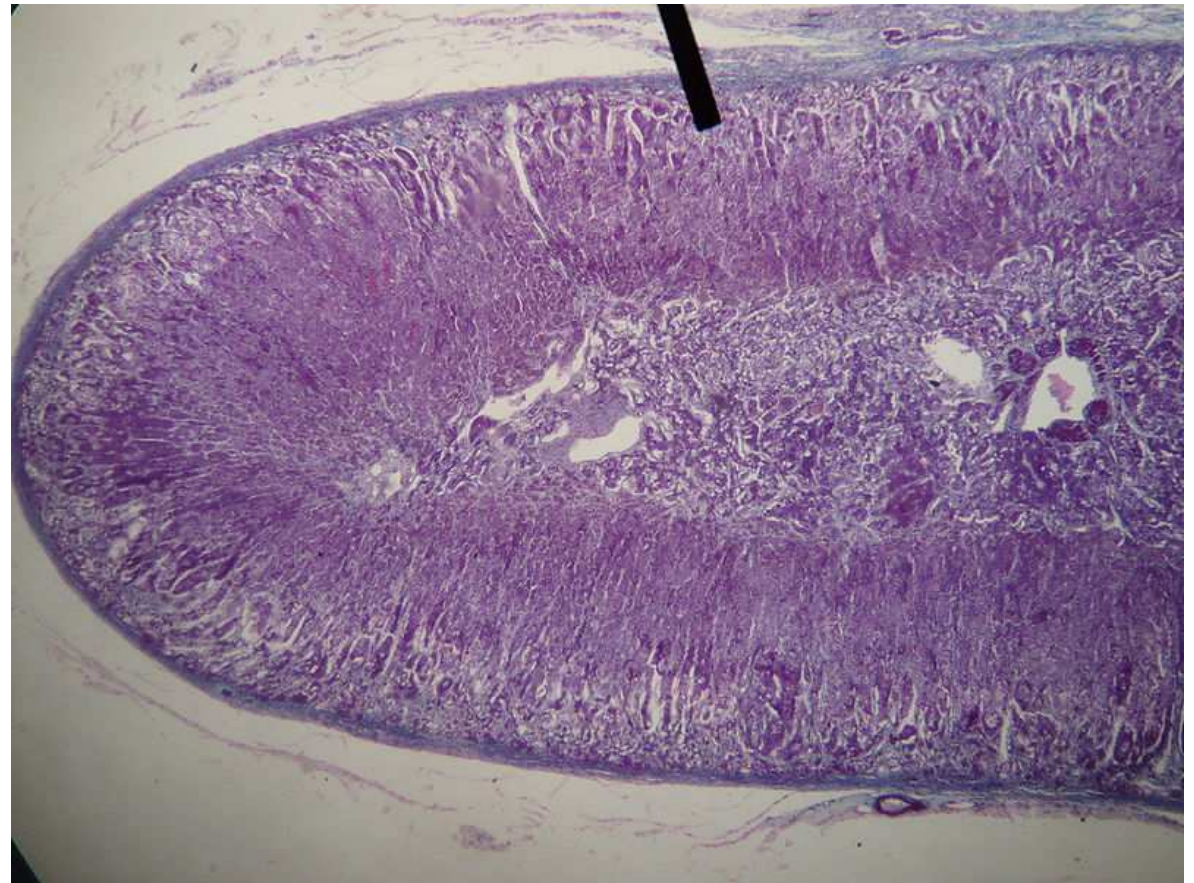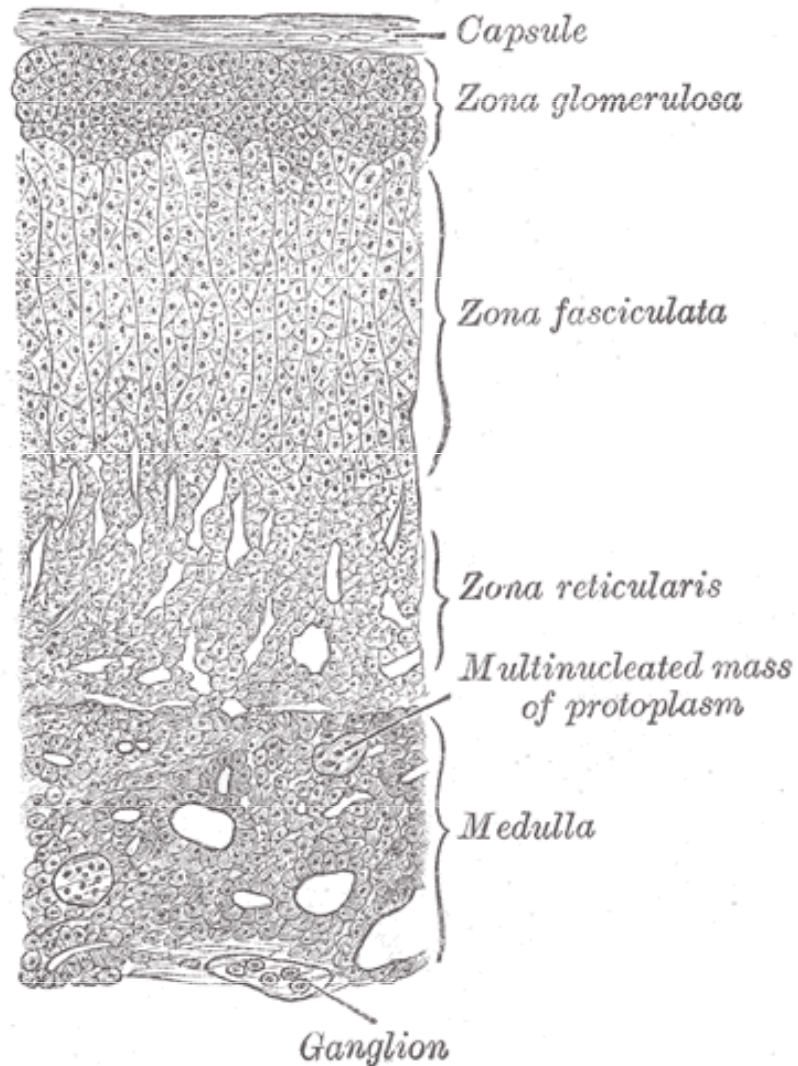


CLASSIFICATION OF EPITHELIAL TISSUE

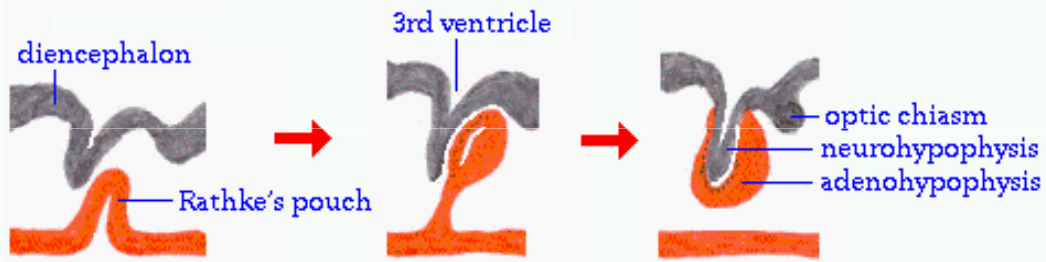
- **Endocrine glands**

Adrenal cortex

Cortex of adrenal gland – epithelial cells in cords secreting corticoid

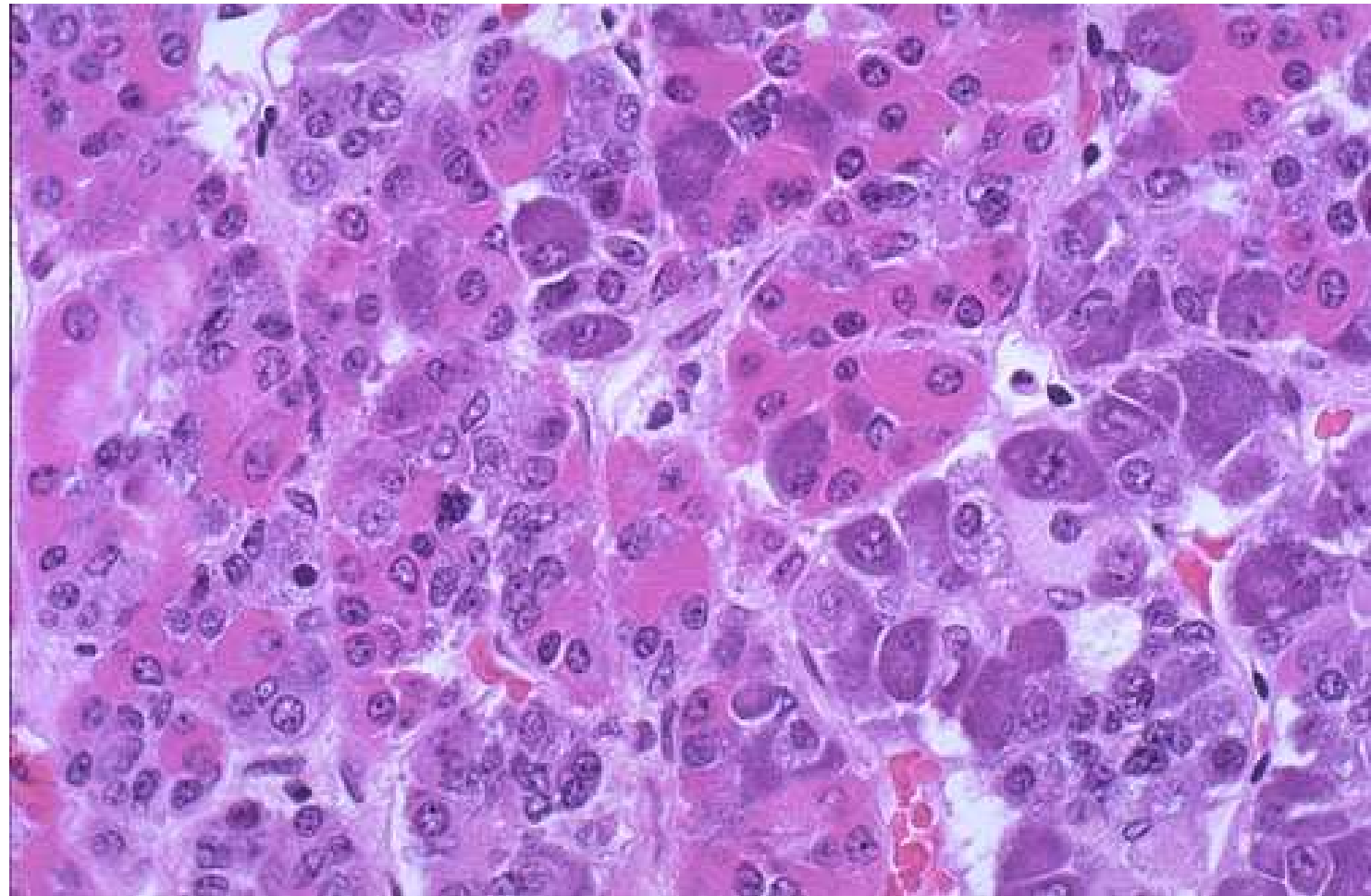


CLASSIFICATION OF EPITHELIAL TISSUE



- Endocrine glands

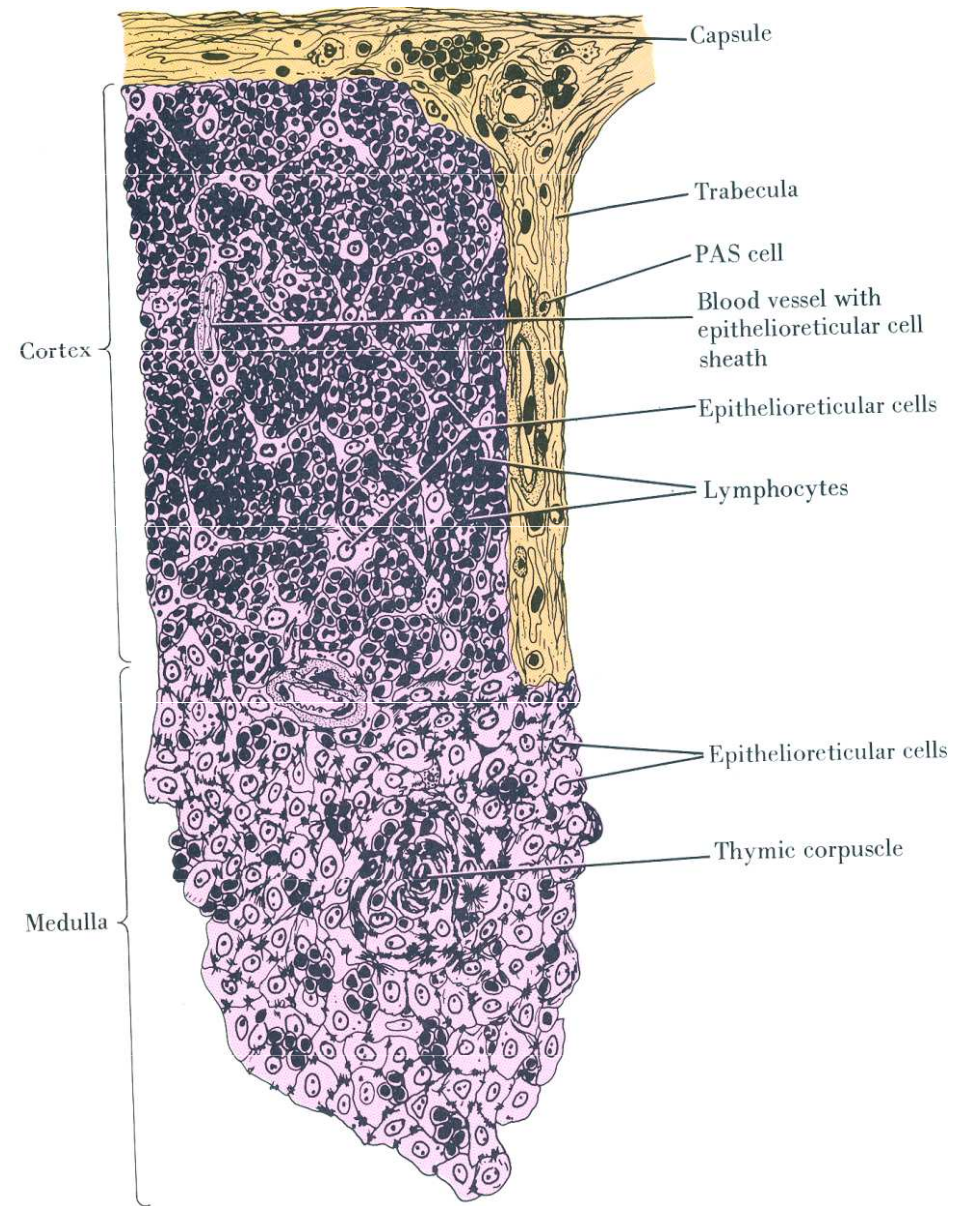
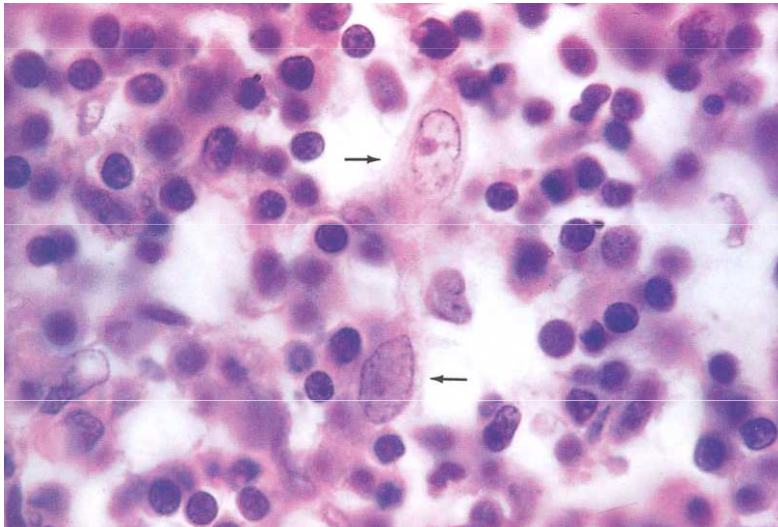
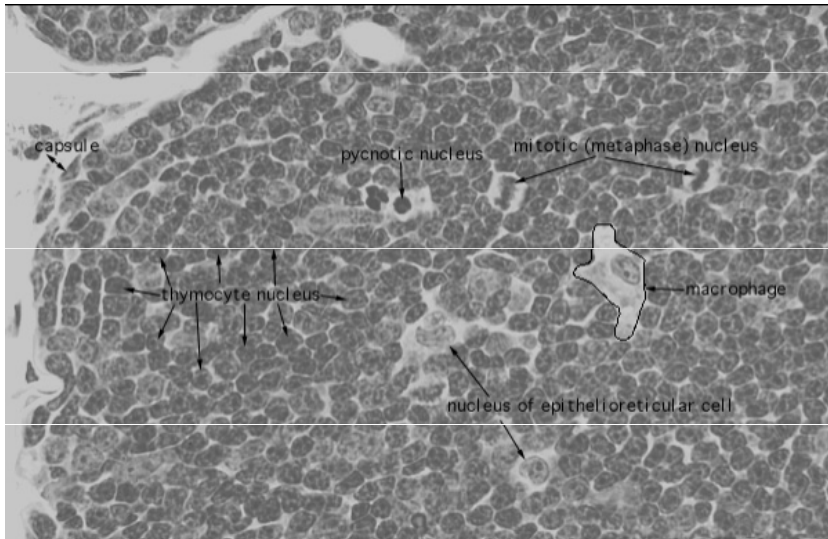
Adenohypophysis – anterior pituitary



CLASSIFICATION OF EPITHELIAL TISSUE

3) Reticular epithelium

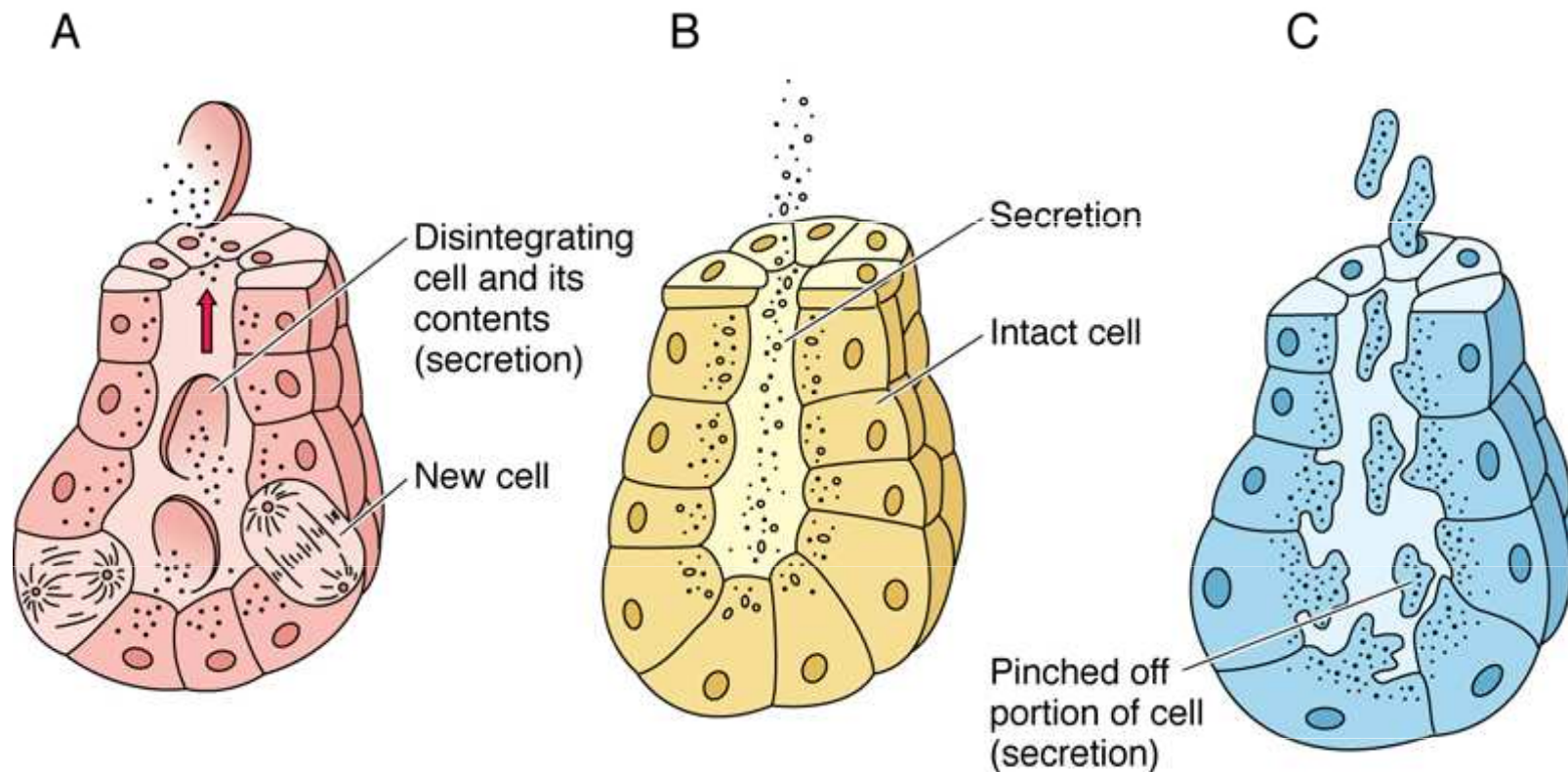
Thymus



Classification by function

Glandular epithelium

- Secret ↔ excret
- Process of secretion:

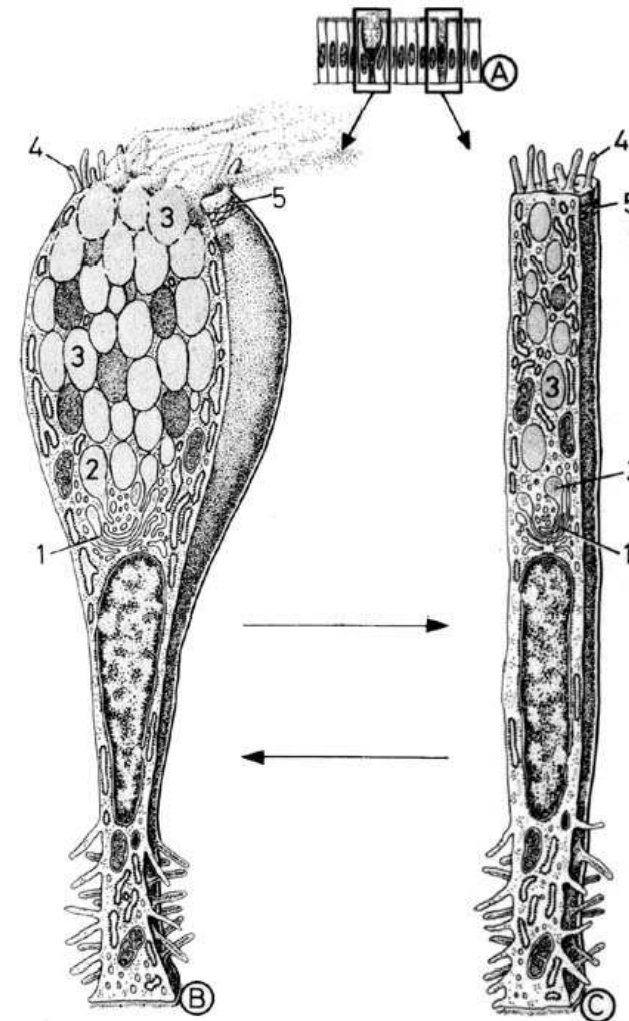
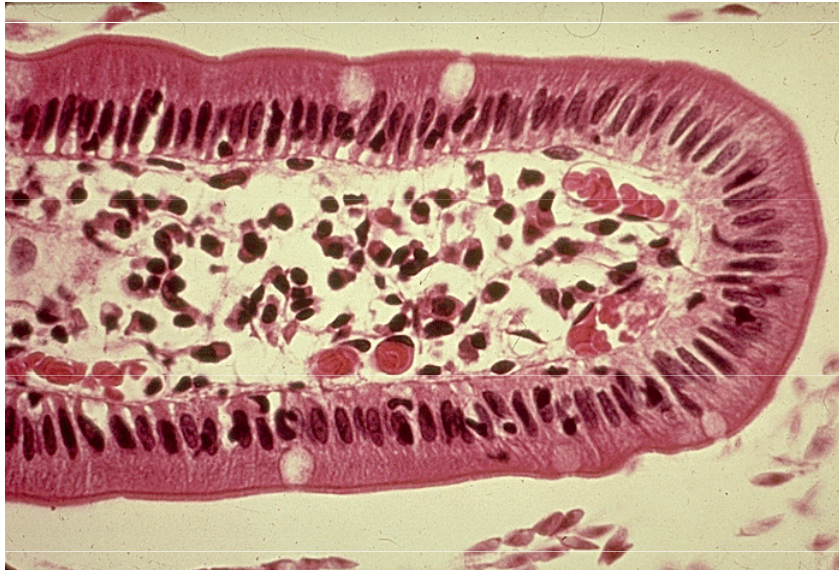


Holocrine × Merocrine × Apocrine

GLANDULAR EPITHELIUM

■ Single cell glands

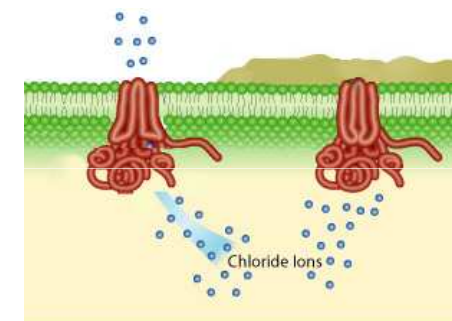
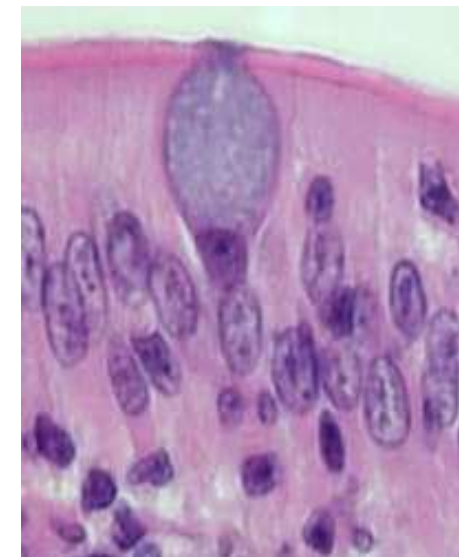
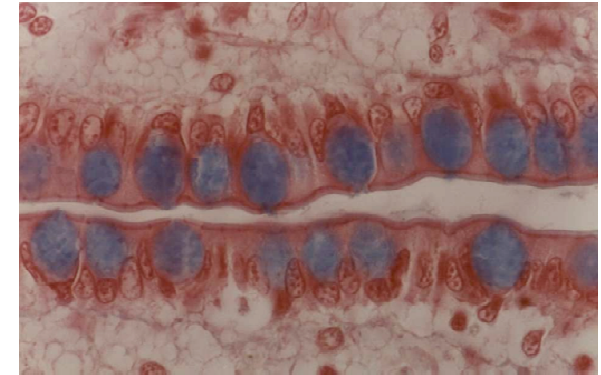
- Goblet
- Enteroendocrine



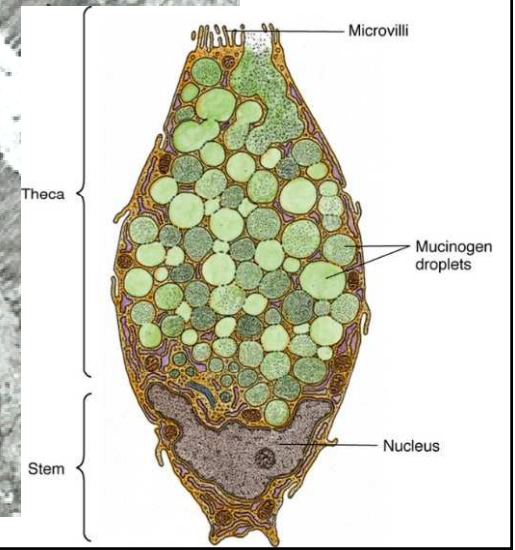
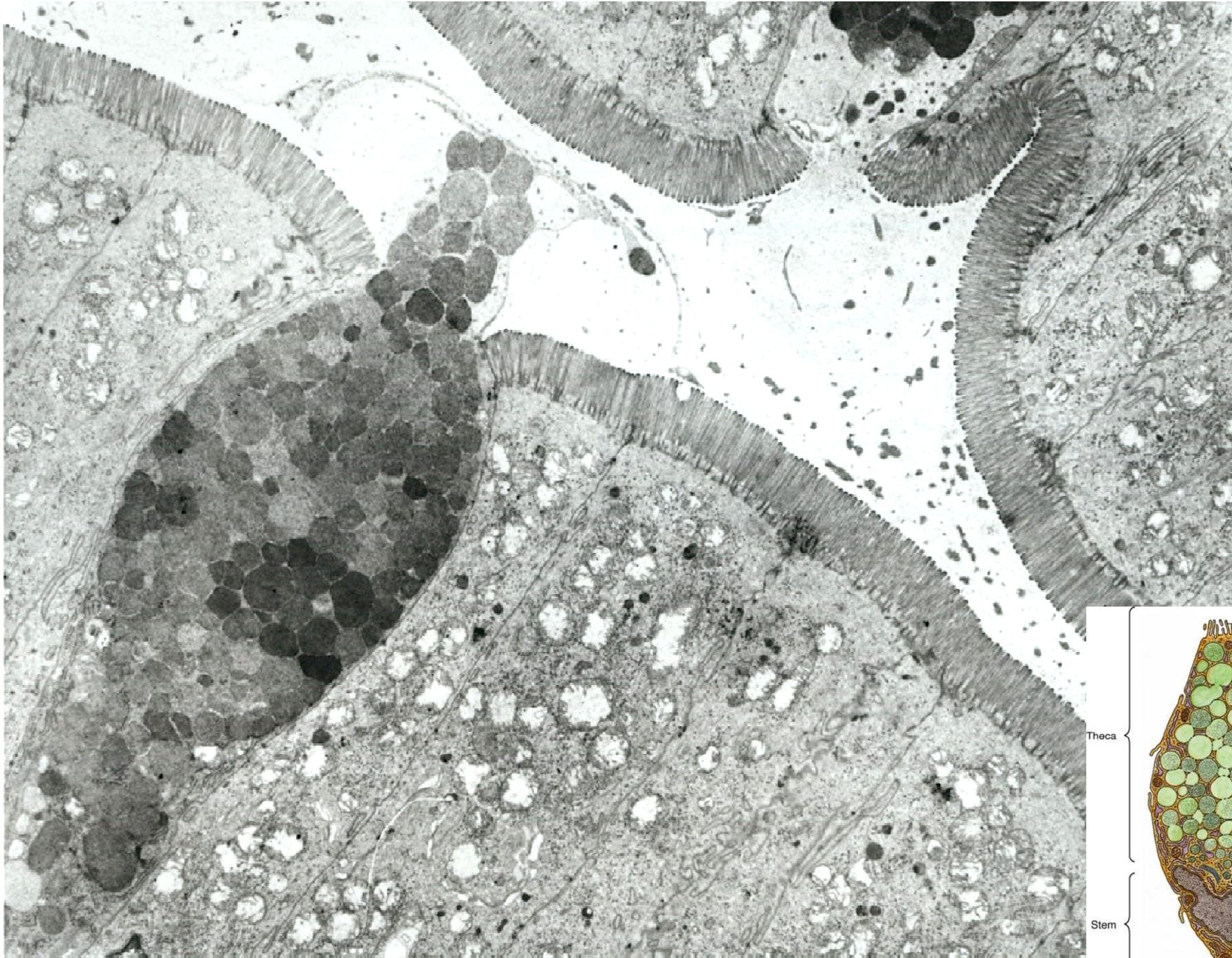
GLANDULAR EPITHELIUM

■ Goblet cells

- Mainly respiratory and intestinal tract
- Produce mucus = viscous fluid composed of electrolytes and highly glycosylated glycoproteins (mucins)
- Protection against mechanic shear or chemical damage
- Trapping and elimination of particular matter
- Secretion by secretory granules constitutive or stimulated
- After secretion mucus expands extremely – more than 500-fold in 20ms
- Dramatic changes in hydration and ionic charge
- Chronic bronchitis or cystic fibrosis – hyperplasia or metaplasia of goblet cells



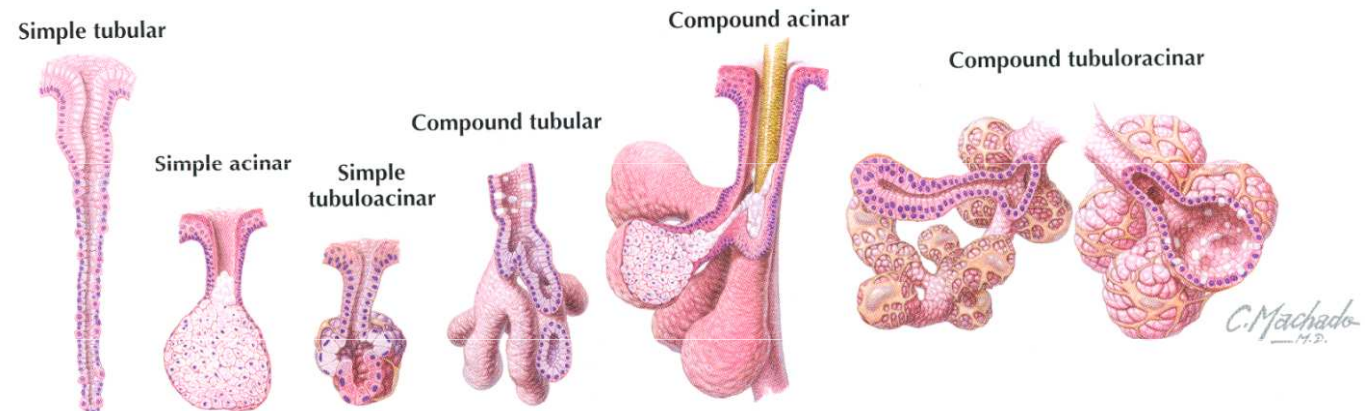
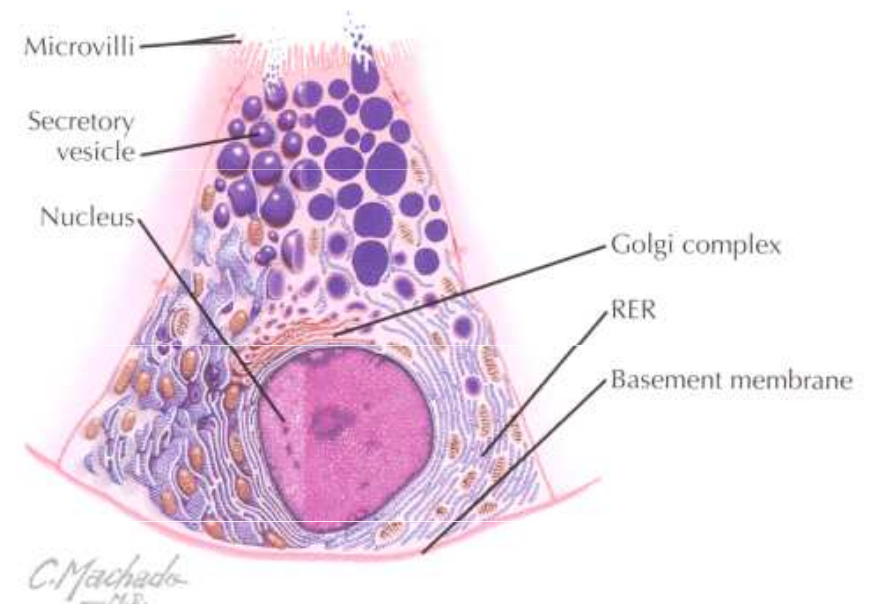
GOBLET CELL



GLANDULAR EPITHELIUM

■ Multicellular glands

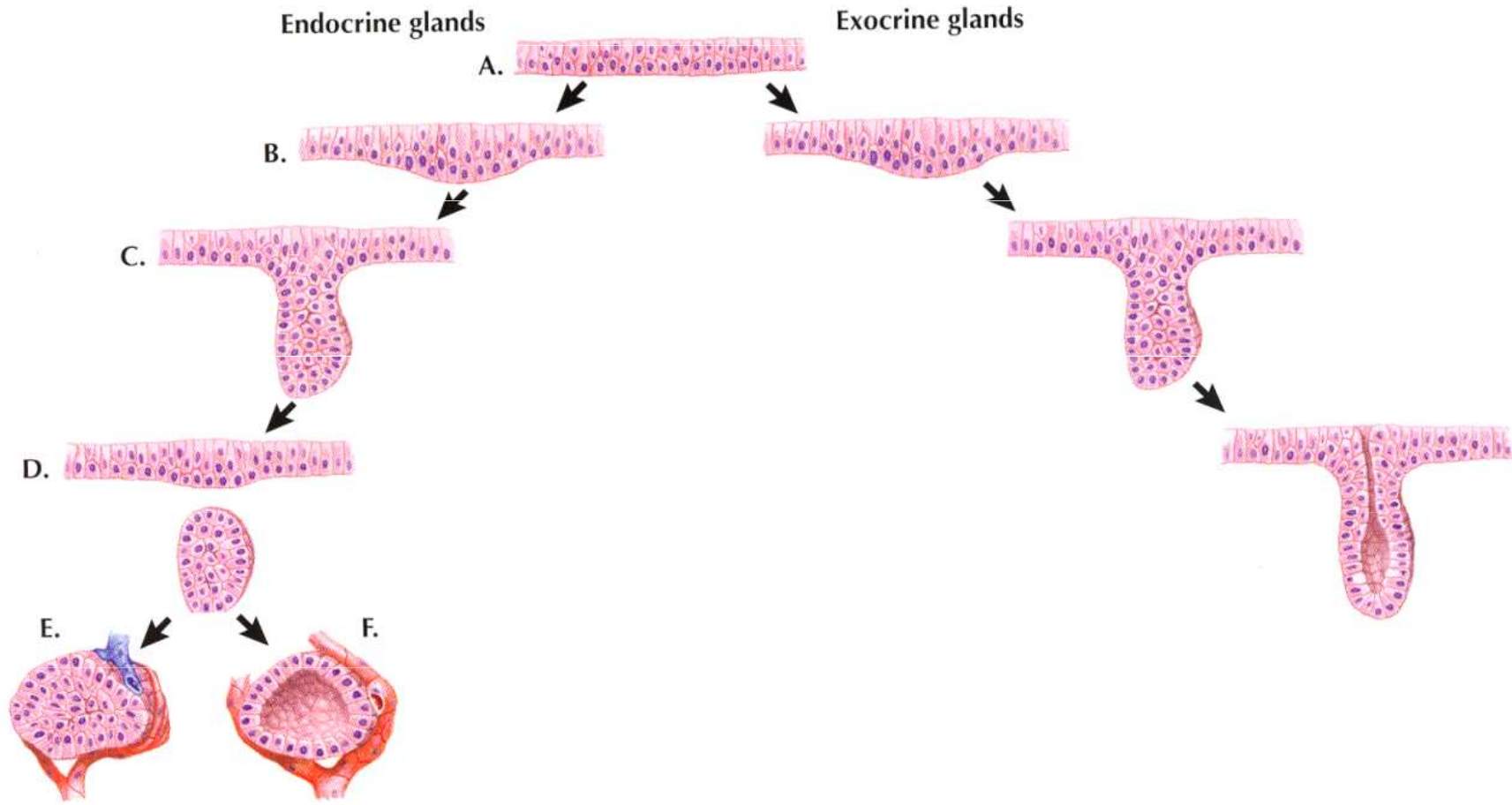
- Shape of secretion part
 - Alveolar (acinar)
 - Tubular
 - Tubuloalveolar (tubuloacinar)
- Branching
 - Simple
 - Branched
 - Compound
- Secretion
 - Mucous
 - Serous
 - Compound



GLANDULAR EPITHELIUM

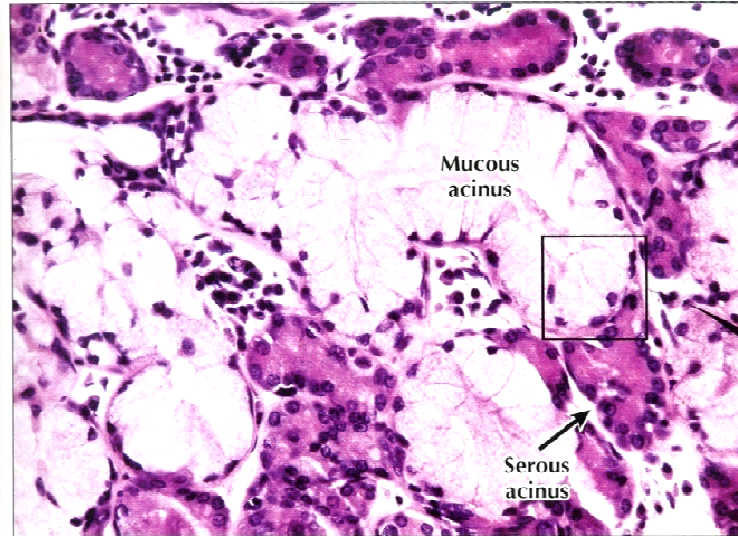
■ Multicellular glands

– Endocrine vs. exocrine



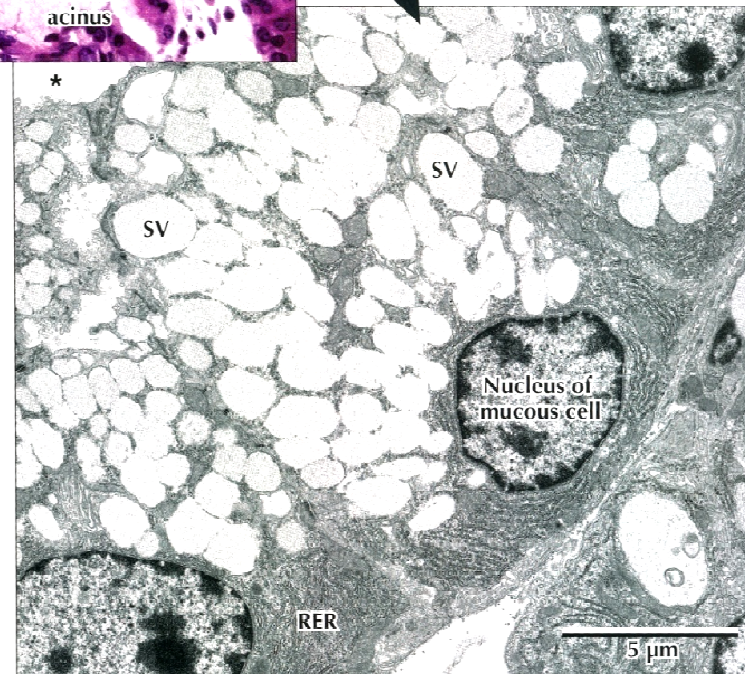
GLANDULAR EPITHELIUM

■ Mucous glands



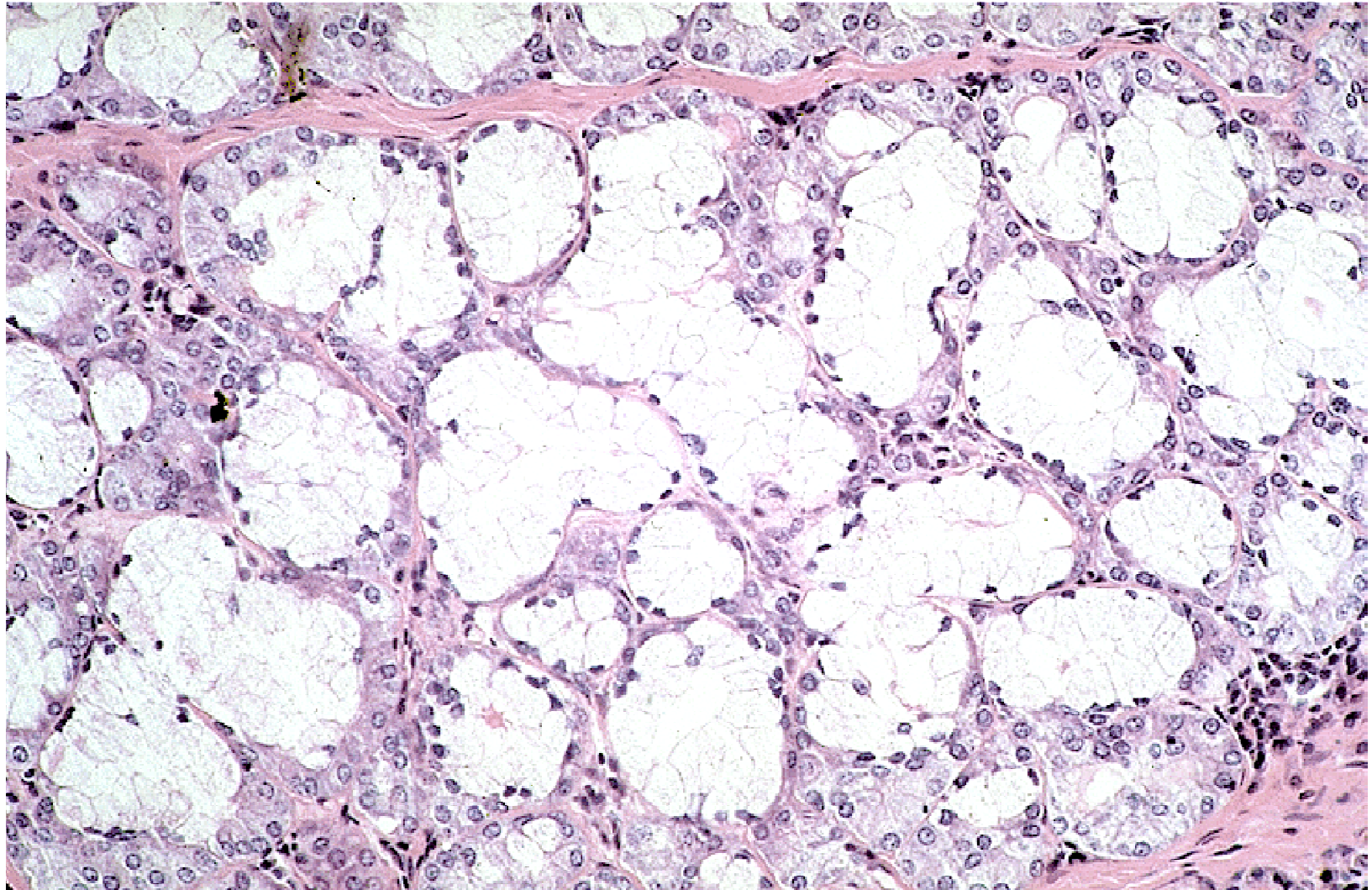
◀ **LM of part of a mixed seromucous gland in the trachea.** Several mucous acini with pale-stained mucous cells are seen. The basal nuclei are flat, and cells appear washed out because mucous droplets dissolved during specimen preparation. Darker stained serous cells in adjacent acini have more rounded basal nuclei. Serous cells are smaller than mucous cells. The square outlines the area of interest seen in the EM below. 295 \times . H&E.

▶ **EM of part of a mucous acinus in a mixed salivary gland.** Parts of three mucous cells line the acinus lumen (*). Euchromatic basal nuclei have prominent nucleoli. Basal cytoplasm contains many profiles of rough endoplasmic reticulum (RER). Many large, electron-lucent secretory vesicles (SV) dominating the remaining cytoplasm are discharged by exocytosis into the acinus lumen. 5400 \times .



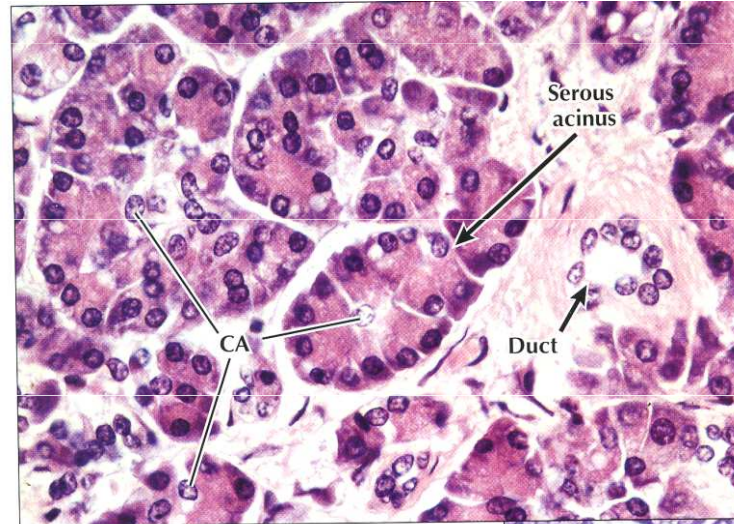
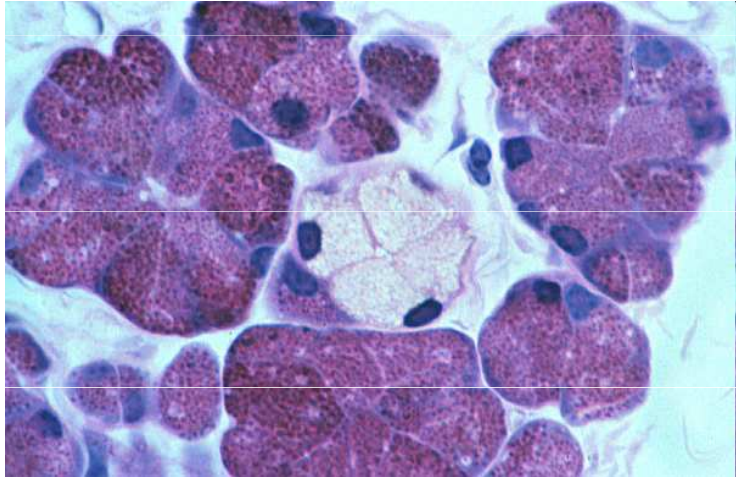
GLANDULAR EPITHELIUM

- Mucous glands

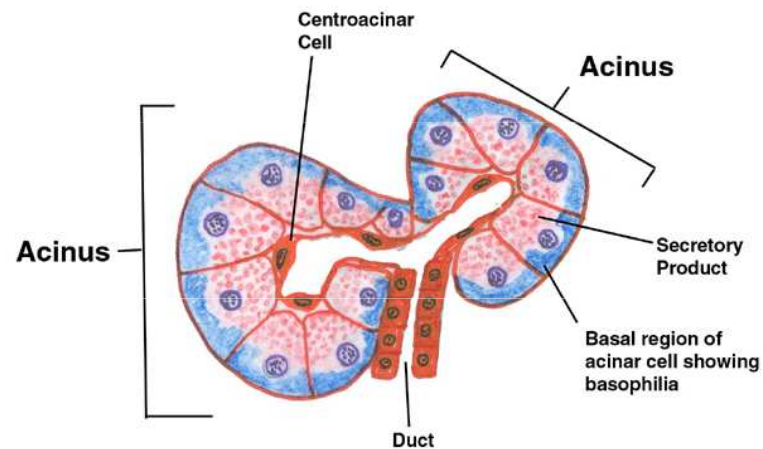


GLANDULAR EPITHELIUM

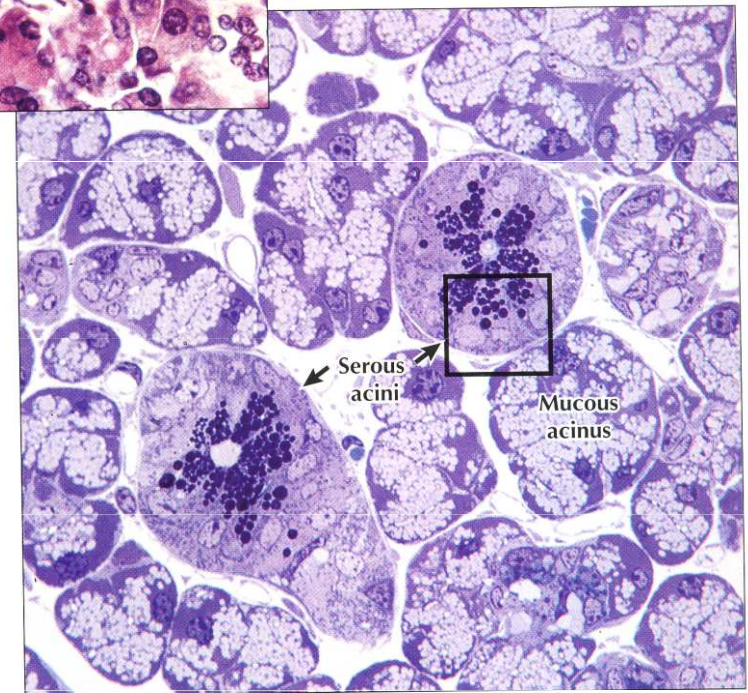
■ Serous glands



◀ **LM of part of the exocrine pancreas.** The exocrine part of the gland consists of closely packed spherical or pear-shaped serous acini. Several columnar to pyramidal acinar cells, with round basal nuclei, face a small central lumen in each **serous acinus**. Basal cytoplasm is basophilic; apical cytoplasm is more eosinophilic. Small clear centroacinar cells (**CA**) in acini centers help distinguish this purely serous gland from others, such as the parotid salivary gland. A small **duct**, in the connective tissue stroma, conveys secretions from acini to larger pancreatic ducts. 385 \times . *H&E*.



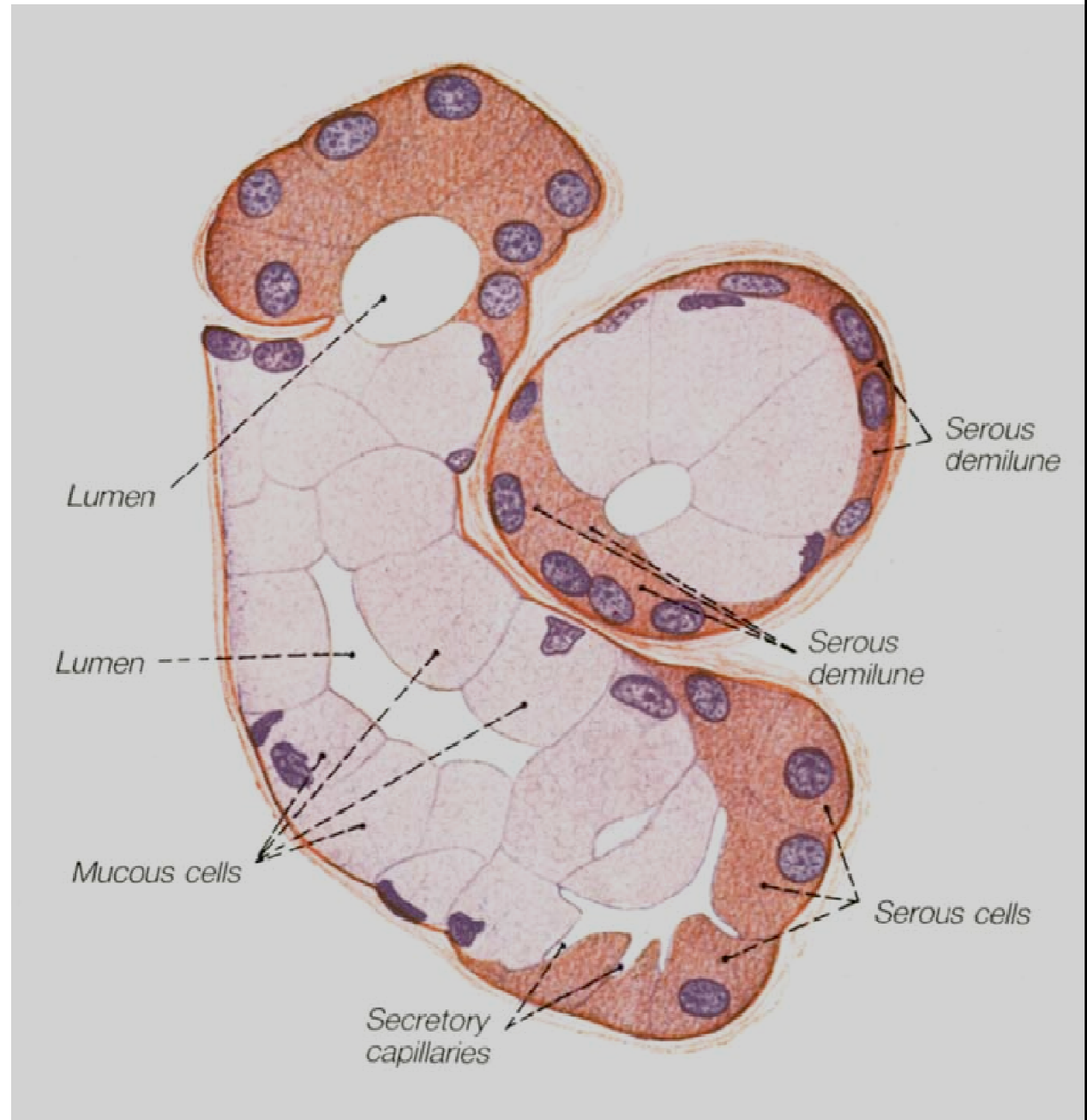
▶ **LM of part of a mixed salivary gland.** Several pale **mucous acini** surround two round **serous acini**. Serous cells have conspicuous, dark-stained secretory vesicles; mucous cells look vacuolated and washed out. EM in 2.15 shows the area in the square in detail. 600 \times . *Toluidine blue, plastic section*.



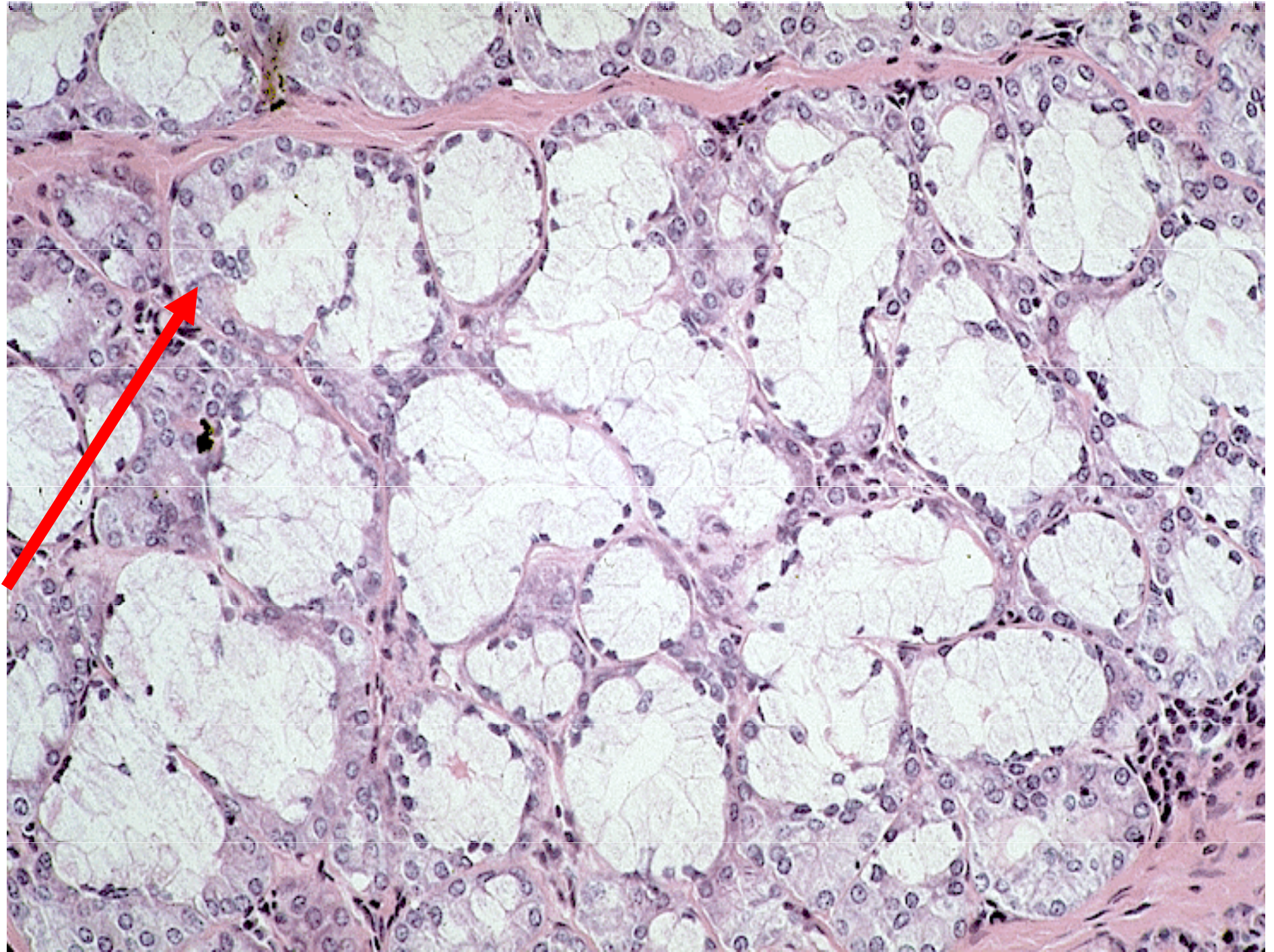
GLANDULAR EPITHELIUM

■ Compound glands

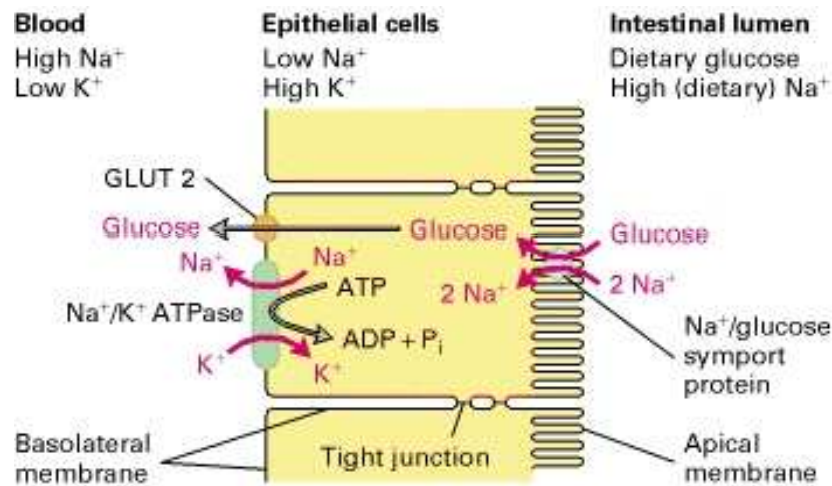
- both serous and mucous



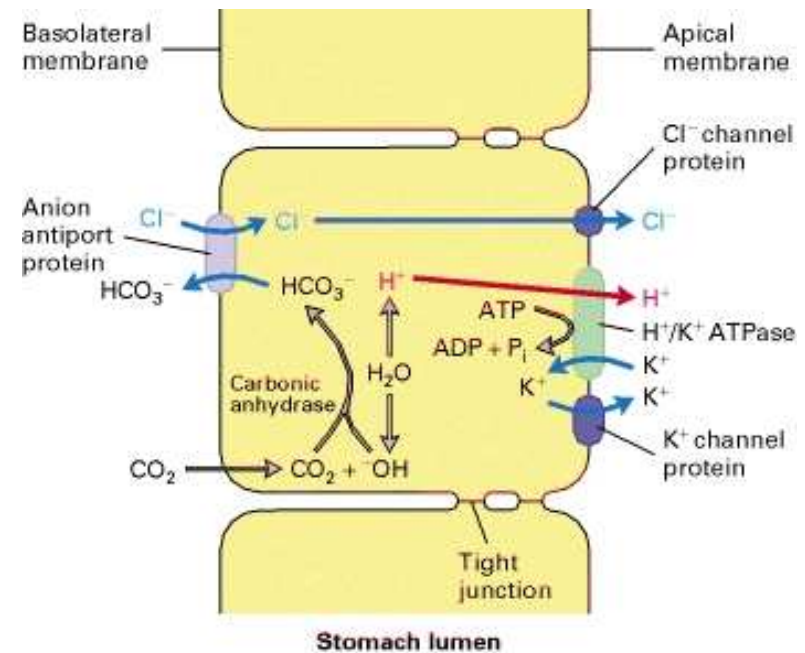
GLANDULAR EPITHELIUM



Absorptive epithelium



Glucose transport



HCl secretion in stomach

CLASSIFICATION OF EPITHELIAL TISSUE

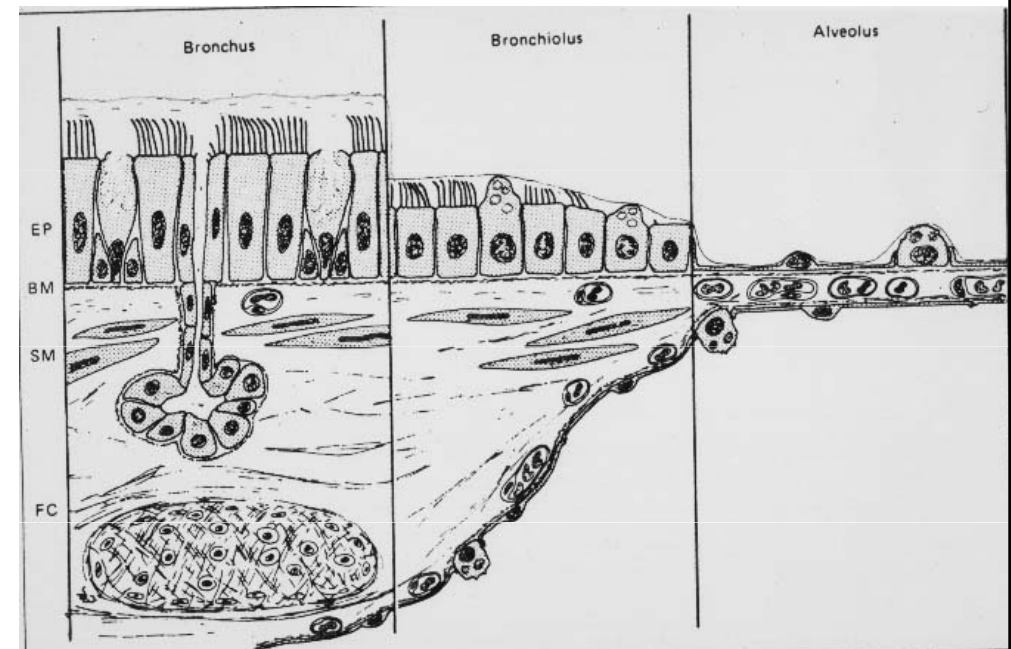
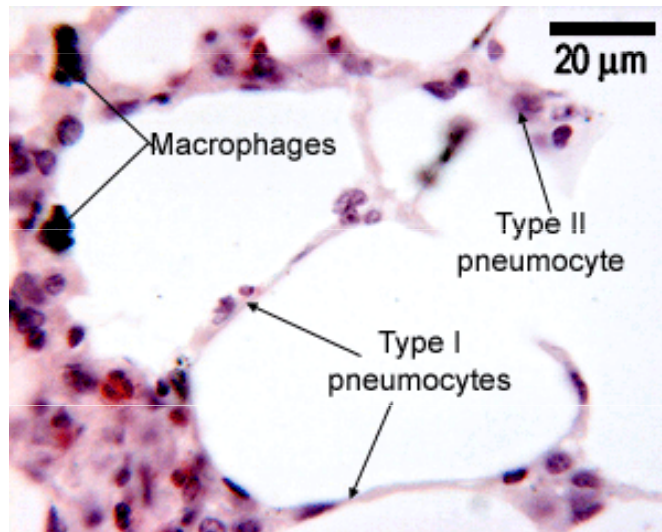
Respiratory epithelium

Epithelium of respiratory passages

- Moist, protection against injury and pathogen
- Remove particles by „mucociliary escalator“
- Pseudostratified columnar epithelium with cilia
- Basal cells → epithelium renewal

Alveolar epithelium

- Gas exchange
- Respiratory bronchioli, alveolar passages and alveoli
- Type I and II pneumocytes



CLASSIFICATION OF EPITHELIAL TISSUE

Sensory epithelium

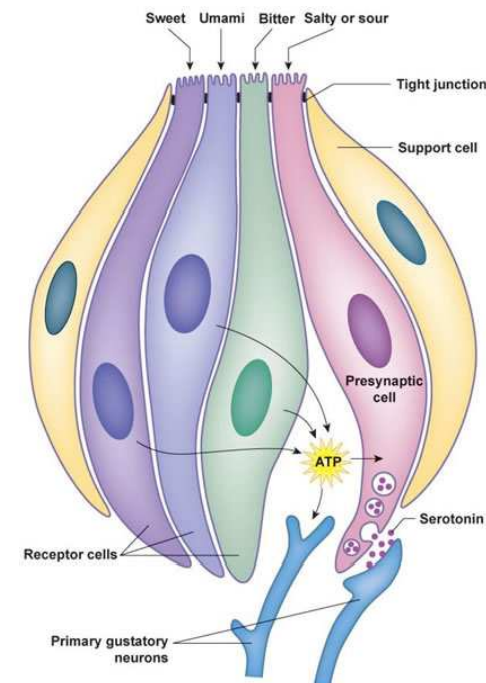
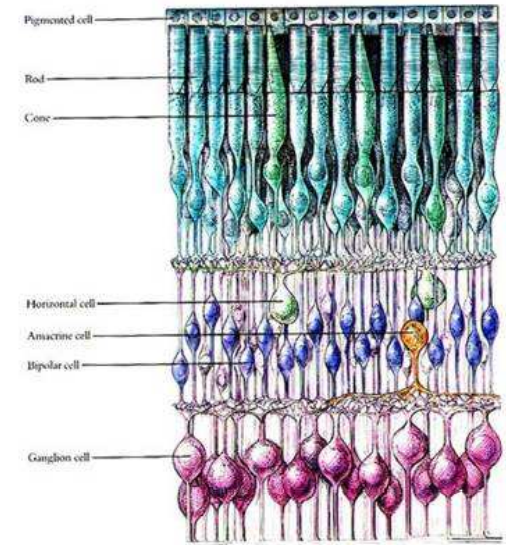
- Supportive and sensory cells

Primary sensory cells

- directly convert stimuli to membrane potential
- receptor region, body, axonal process
- olfactory epithelium (*regio olfactoria nasi*), rods and cones

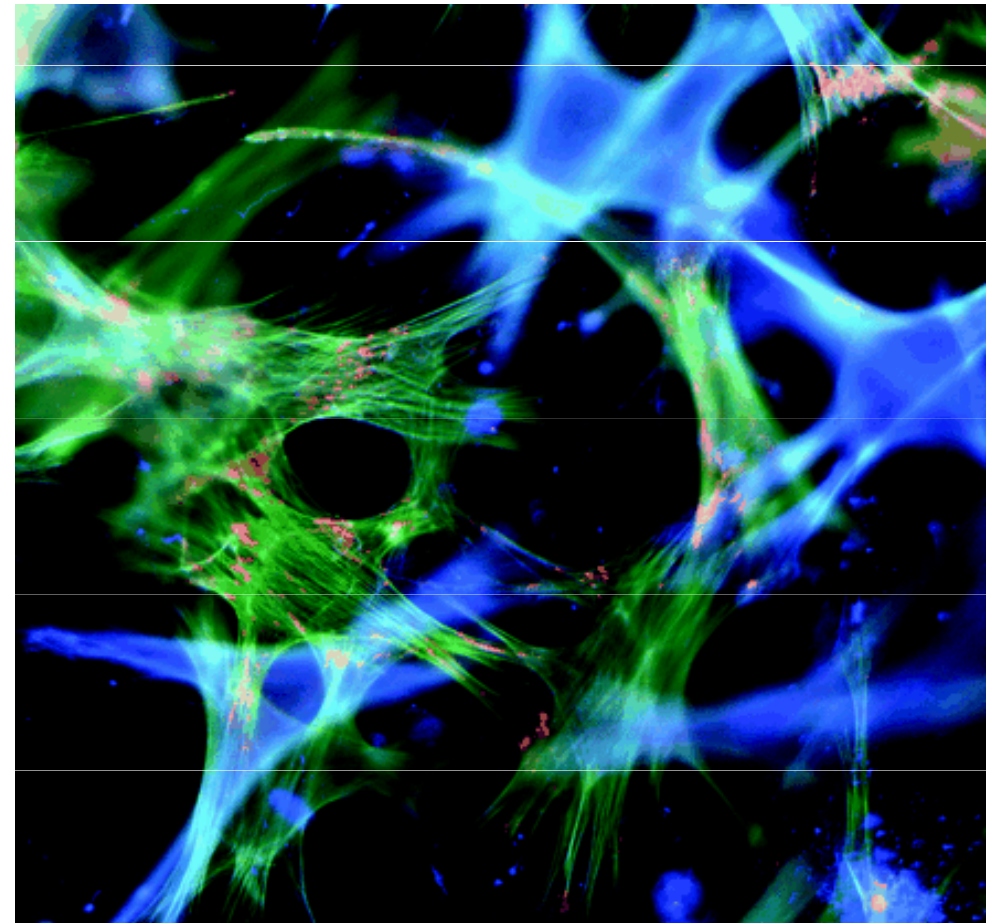
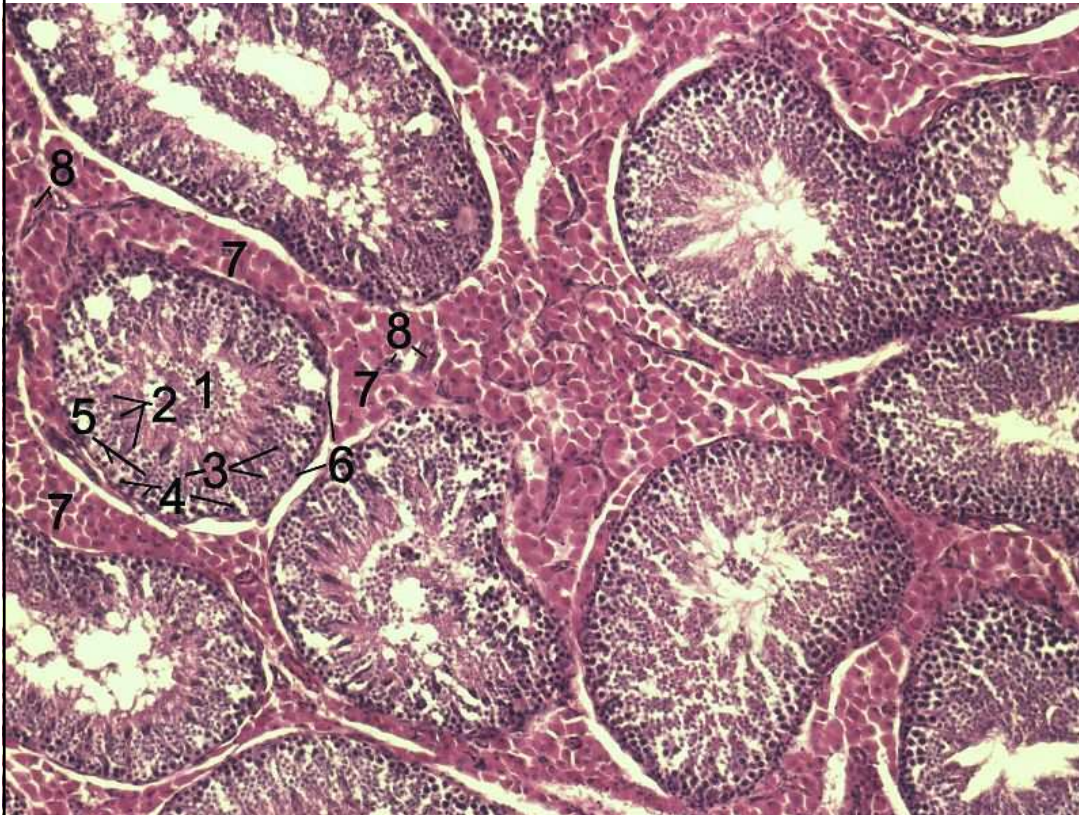Secondary sensory cells

- receptor region and body
- signal is transmitted by adjacent neurons terminating on secondary sensory cell
- taste buds, vestibulocochlear apparatus



Myoepithelium

- star-like or spindle cells
- connected by nexus and desmosomes
- actin microfilaments, myosin and tropomyosin
- contraction
- sweat and salivary glands – enhancing secretion

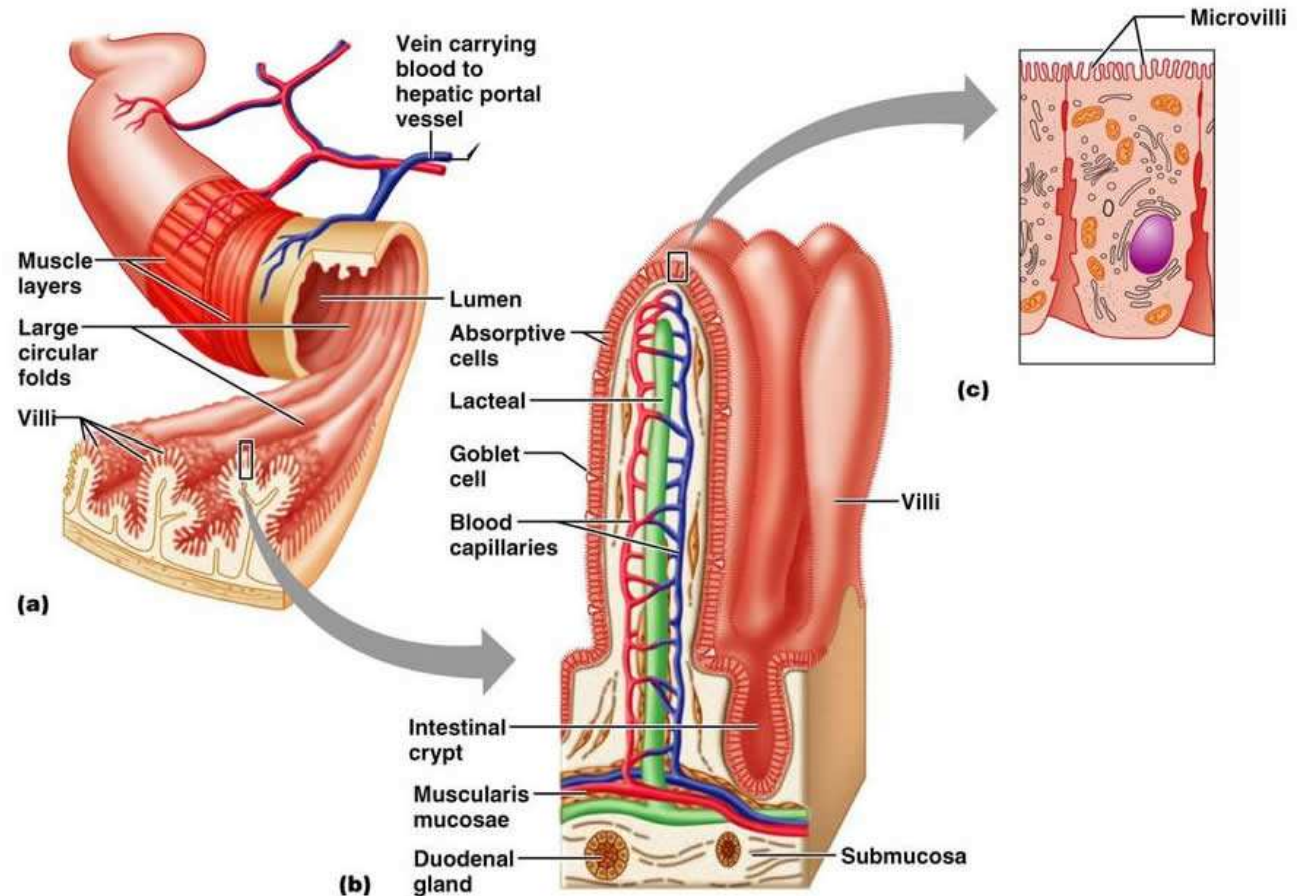


REGENERATION OF EPITHELIAL TISSUE

Renewal of epithelium

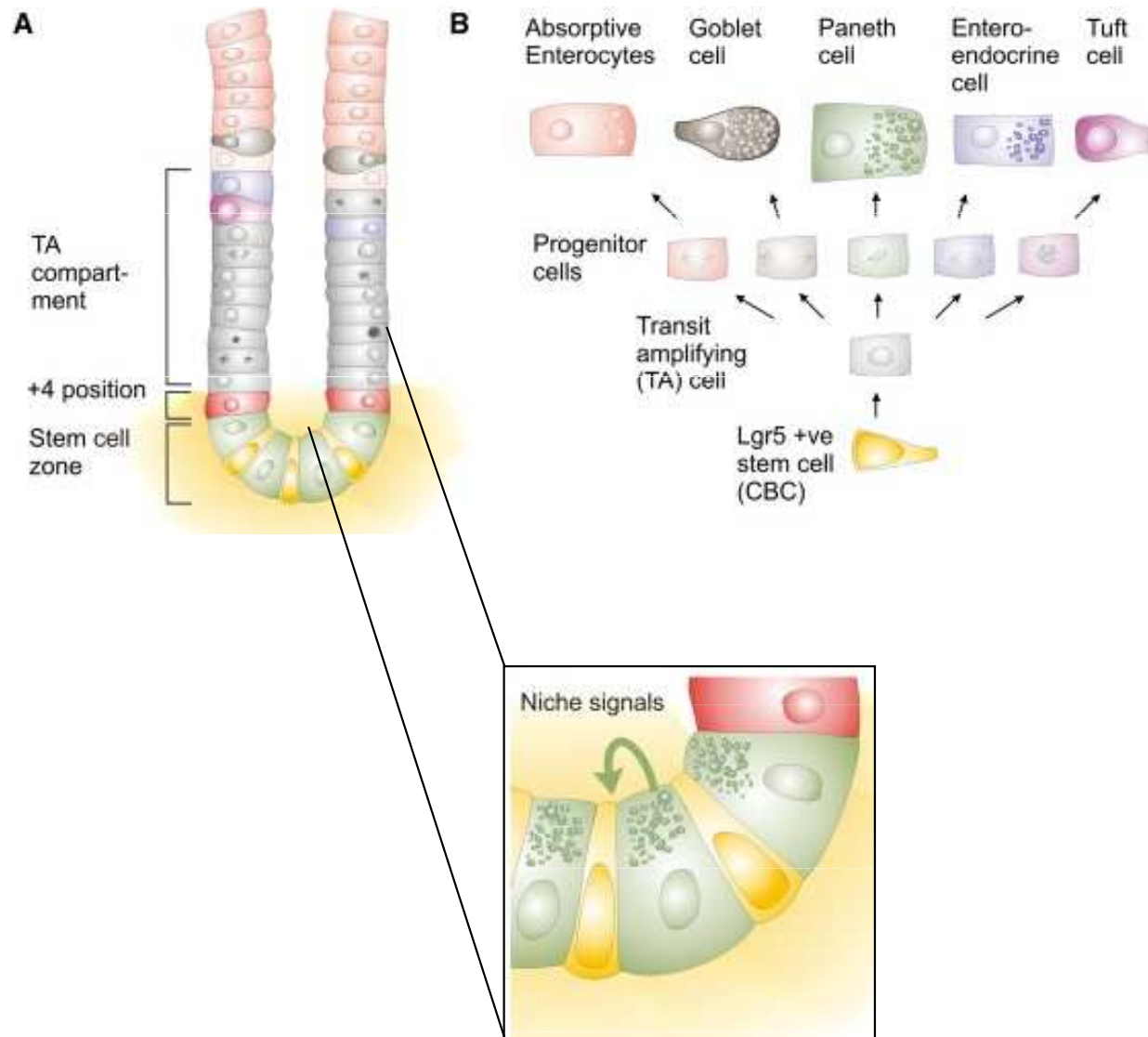
- different regenerative potential (epidermis \times sensory epithelium of inner ear)
- multi- a oligopotent stem cells
- microenvironment – *stem cell niche*

Example: Regeneration of intestine epithelium



REGENERATION OF EPITHELIAL TISSUE

Example: Regeneration of intestine epithelium

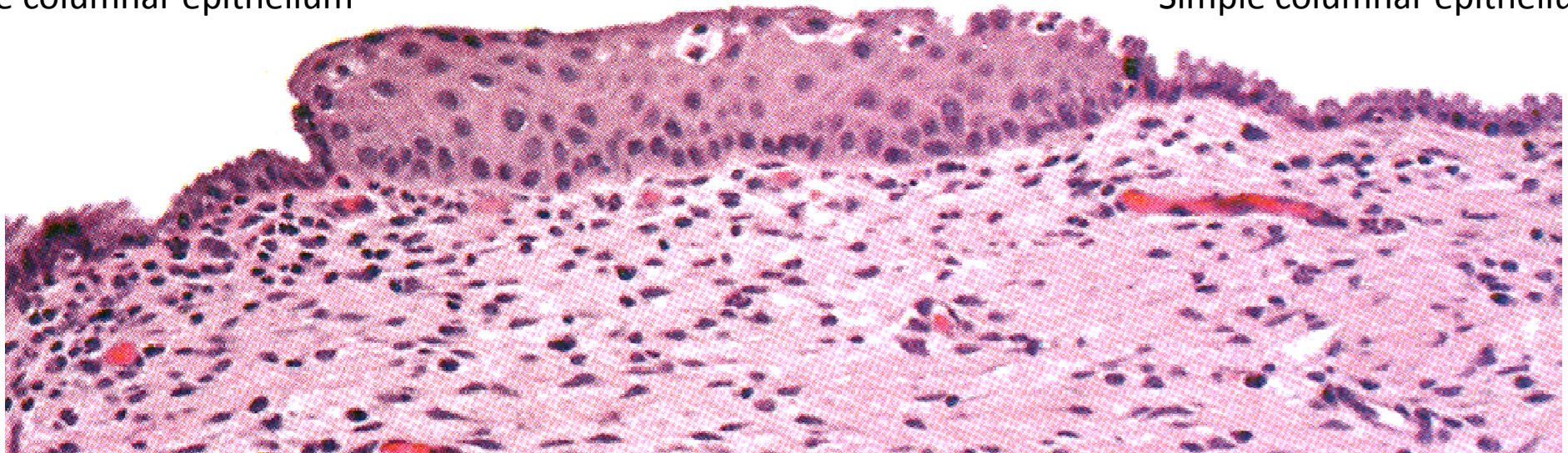


Abnormal renewal: metaplasia

Stratified squamous epithelium

Simple columnar epithelium

Simple columnar epithelium

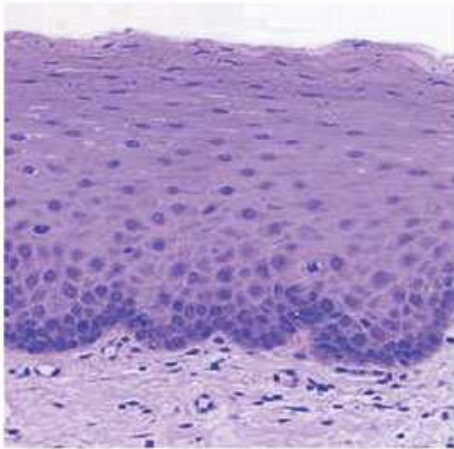


- squamous metaplasia of cervix uteri
- respiratory passages

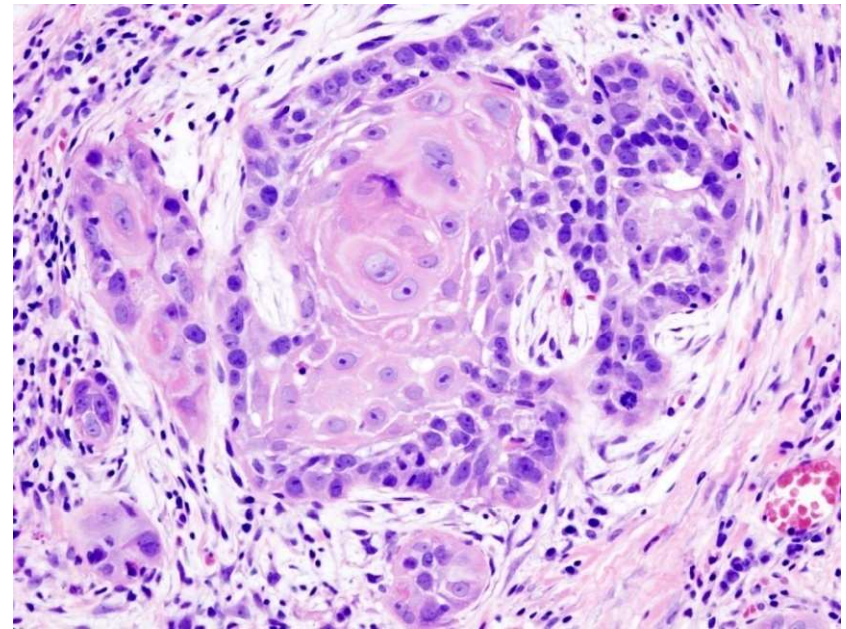
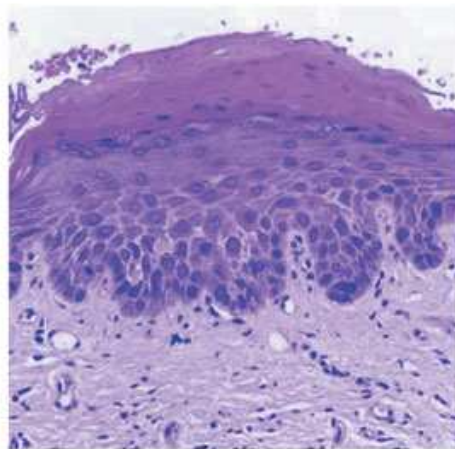
Abnormal renewal: metaplasia

- risk of development of precancerous lesions

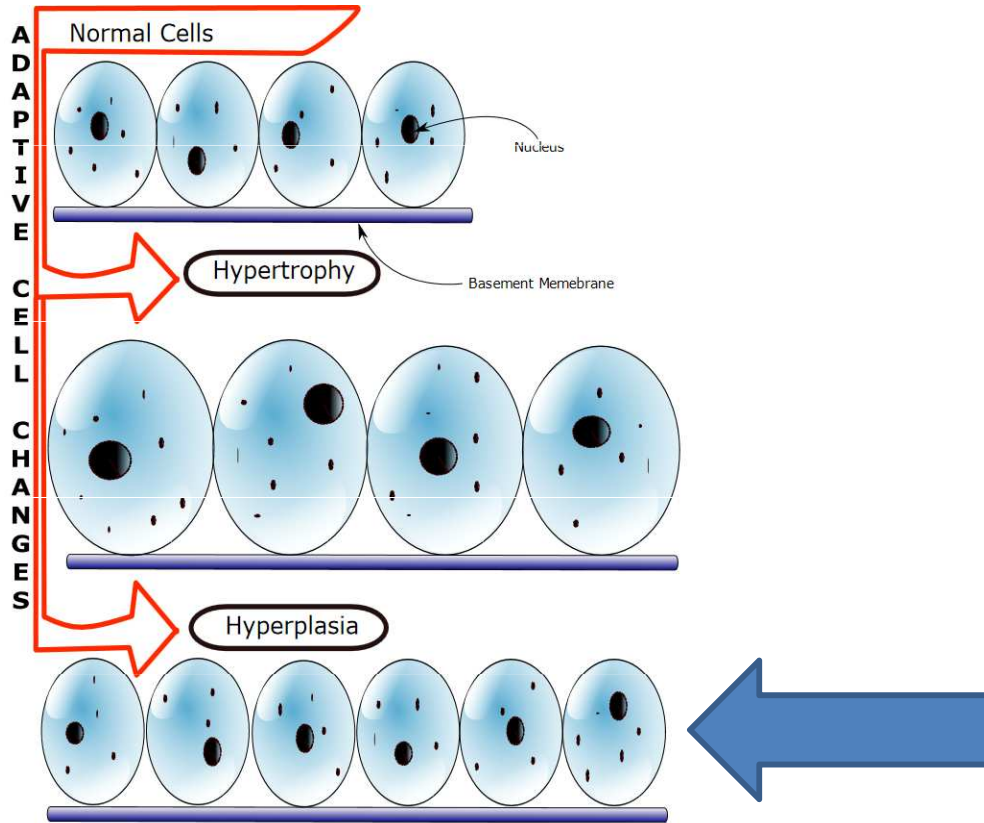
c Normal oral mucosa



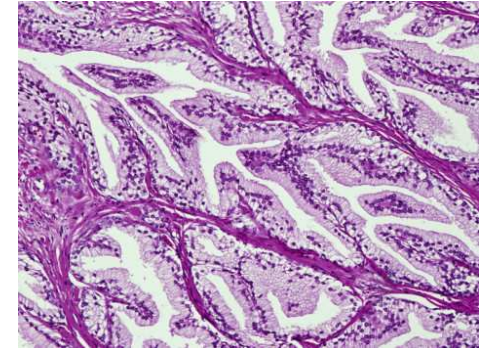
d Moderate dysplasia



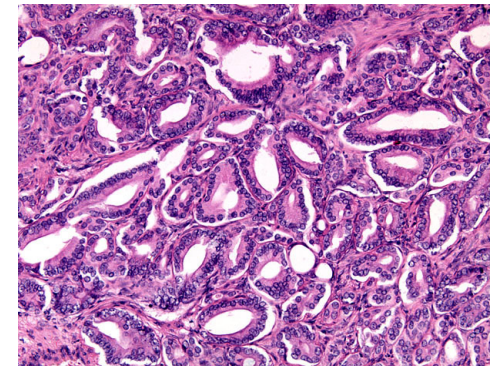
Abnormal renewal: hyperplasia



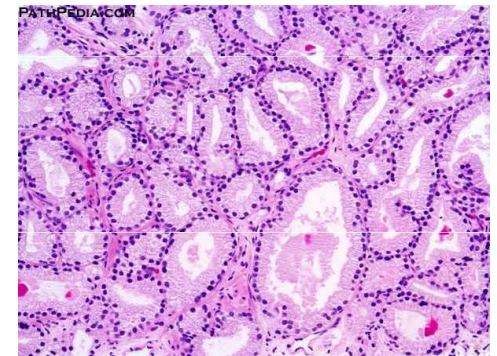
Normal prostate



Hyperplasia of prostate glandular epithelium

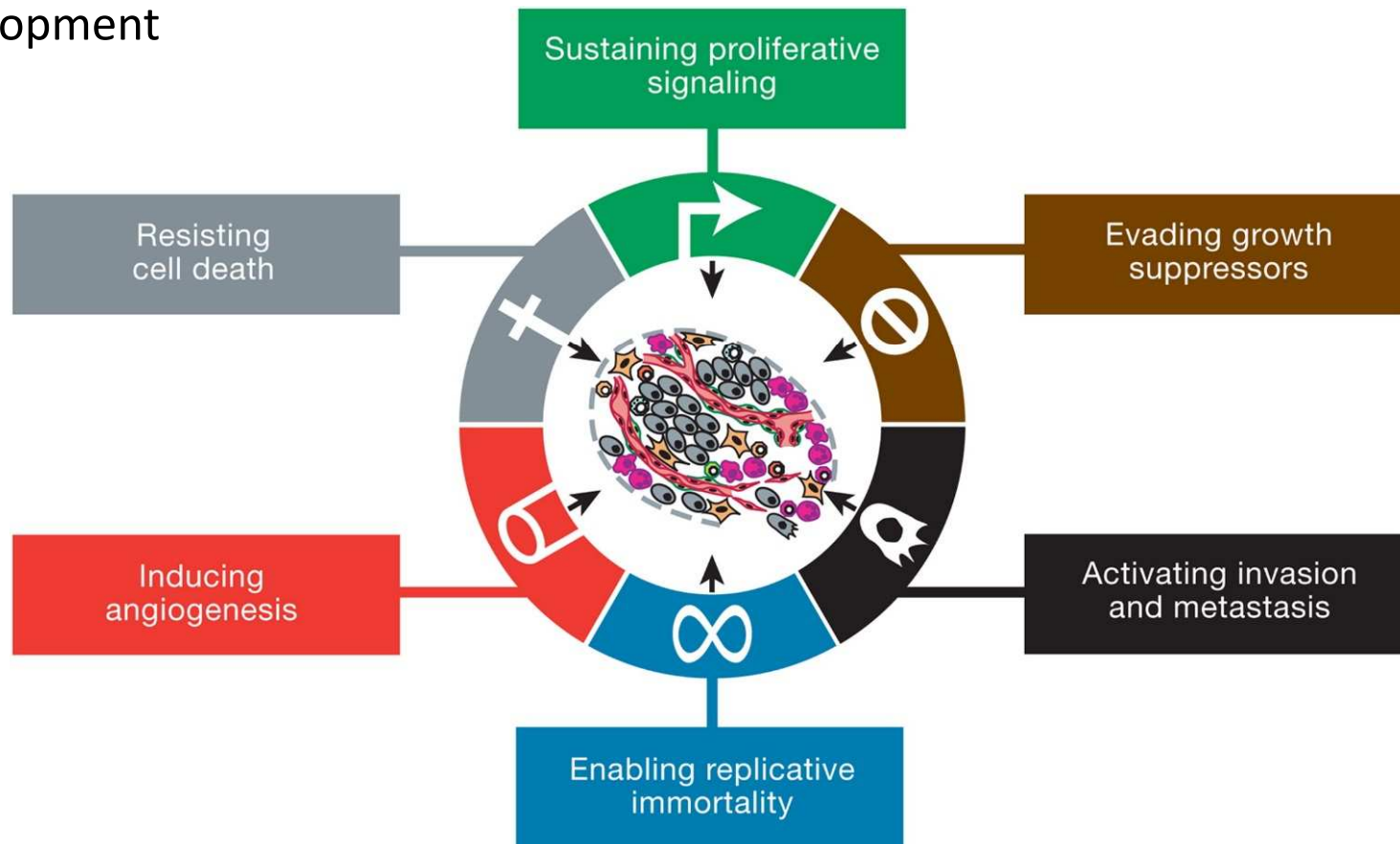


Prostate adenocarcinoma



Abnormal renewal: dysplasia and neoplasia

- uncoupling from regulatory mechanisms
- change in morphology and acquisition of new biological properties
- tumor development

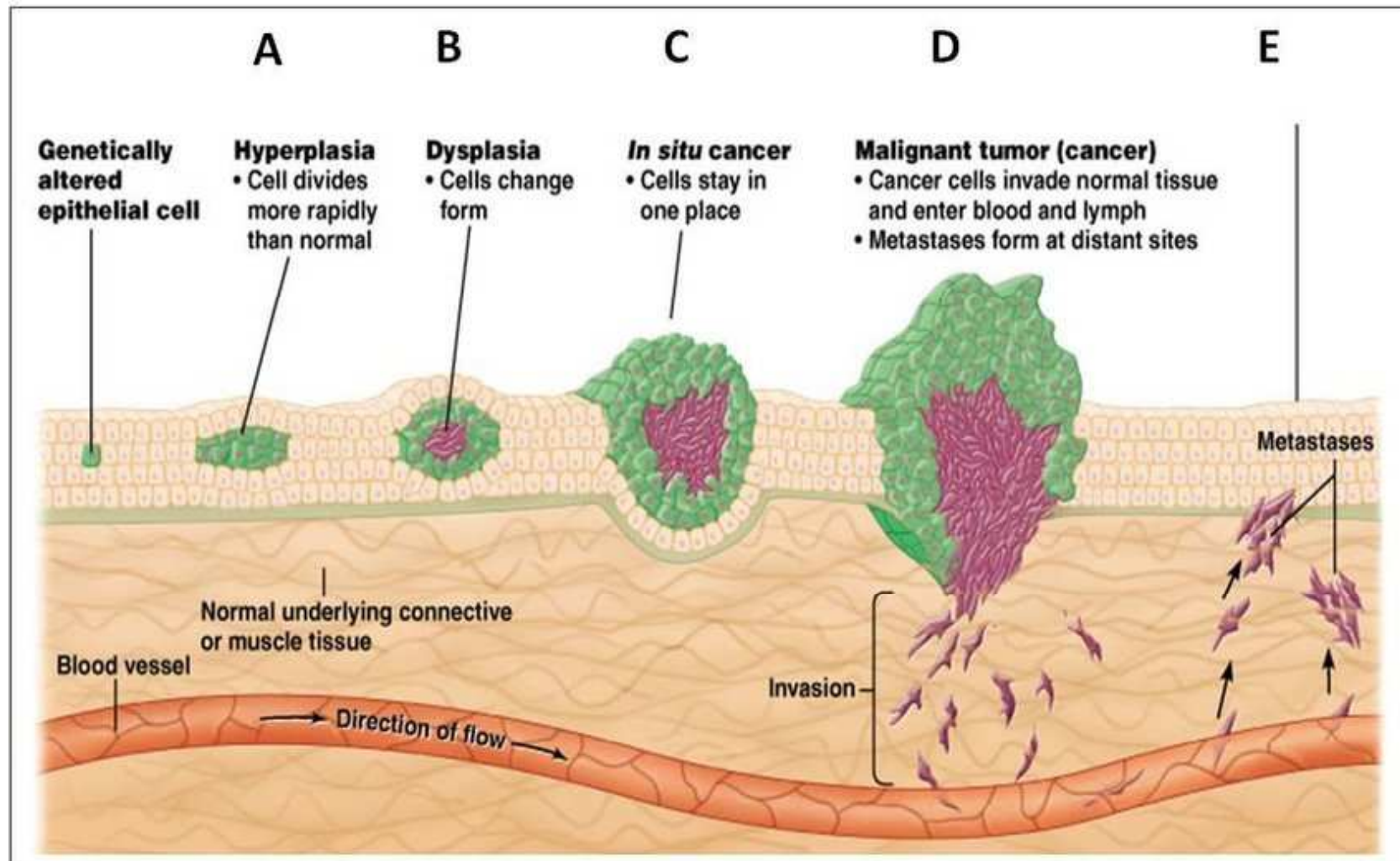


Hanahan & Weinberg, Cell 2011. The six hallmarks of cancer.

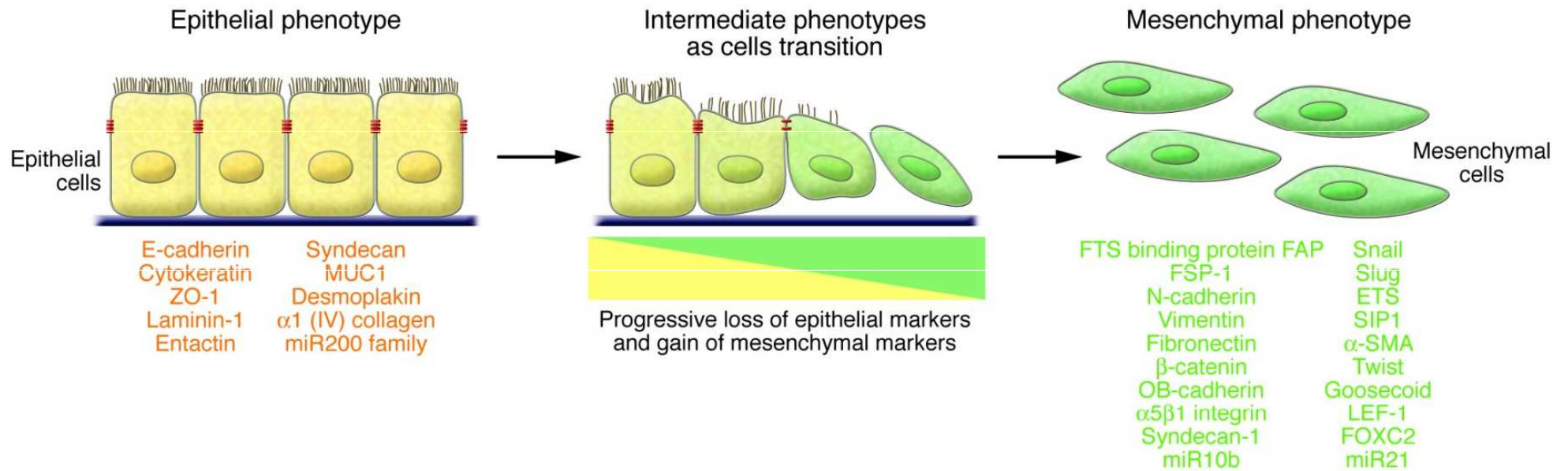
<https://doi.org/10.1016/j.cell.2011.02.013>

Abnormal renewal: neoplasia

- uncoupling from regulatory mechanisms
- tumor development

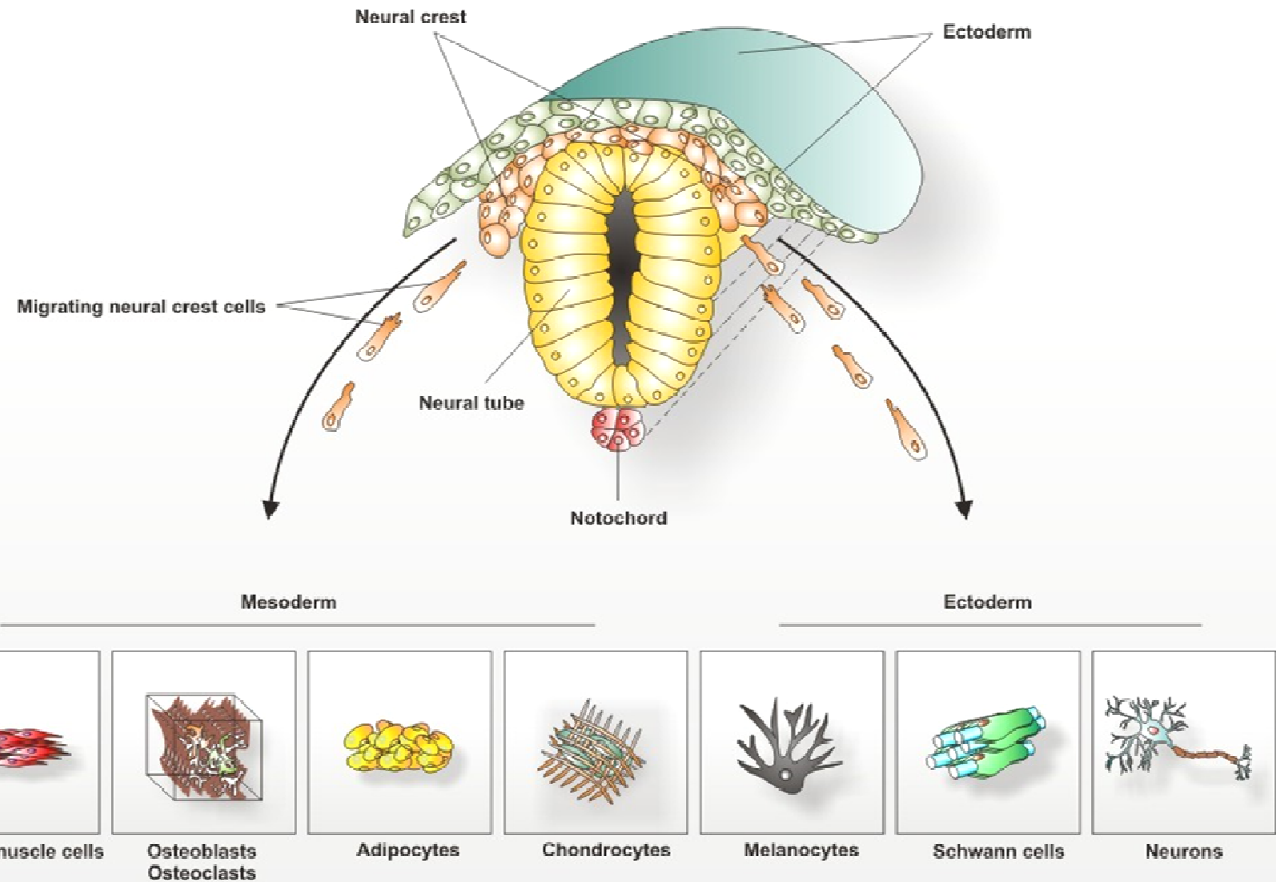
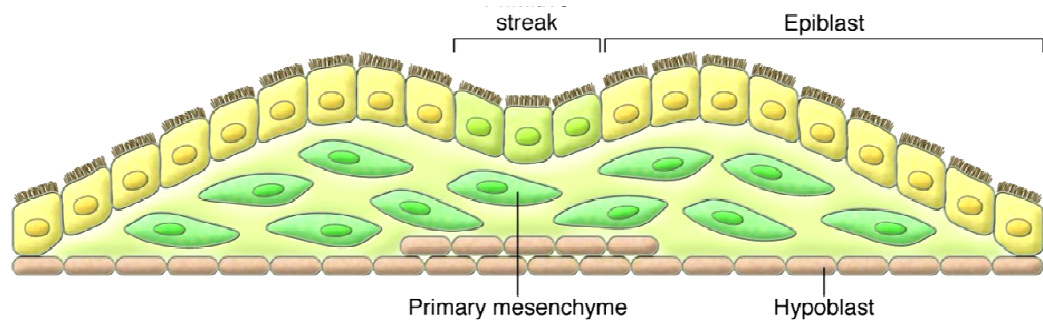


Epithelial to mesenchymal transition (EMT)

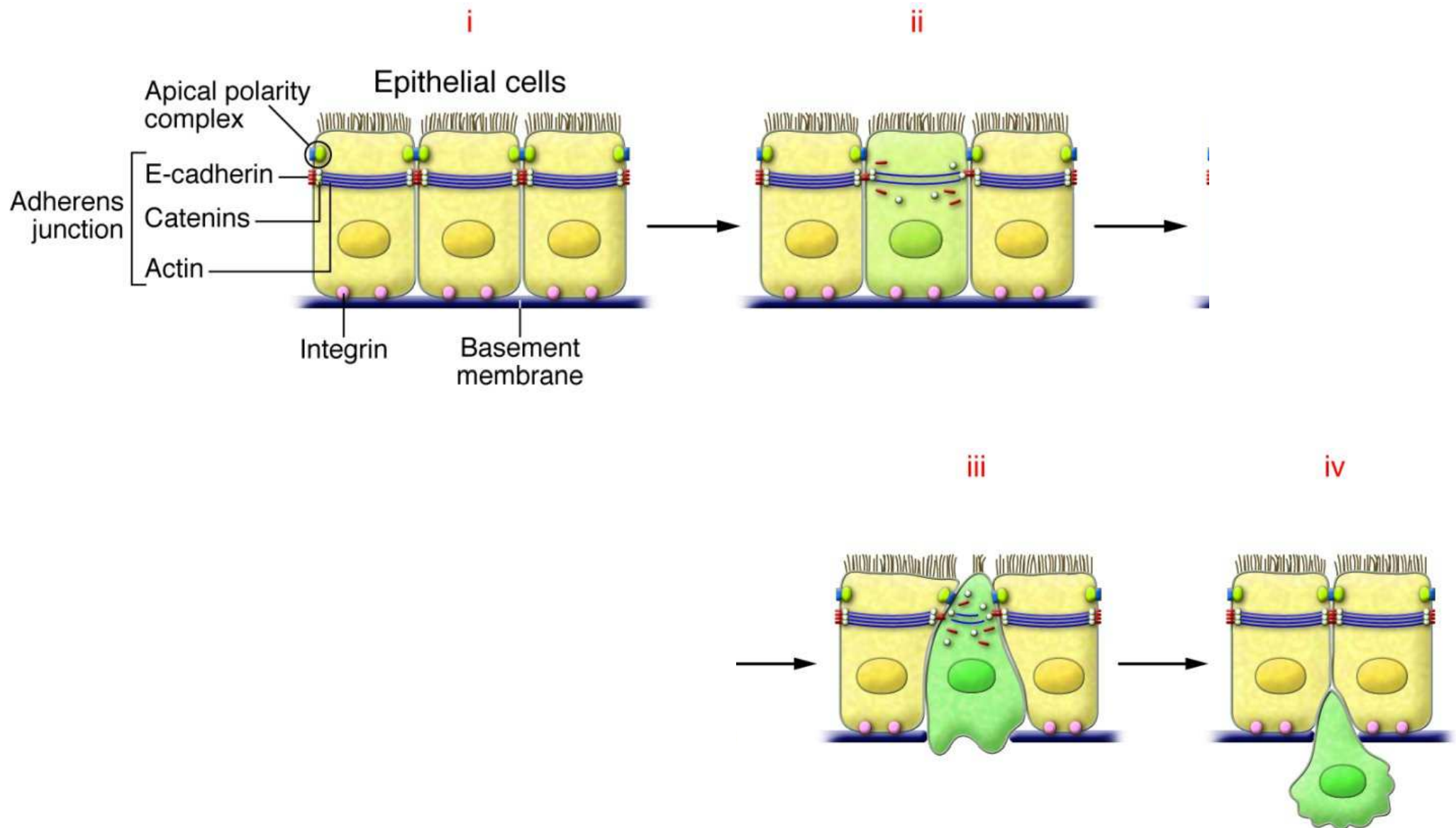


PLASTICITY OF EPITHELIAL TISSUES

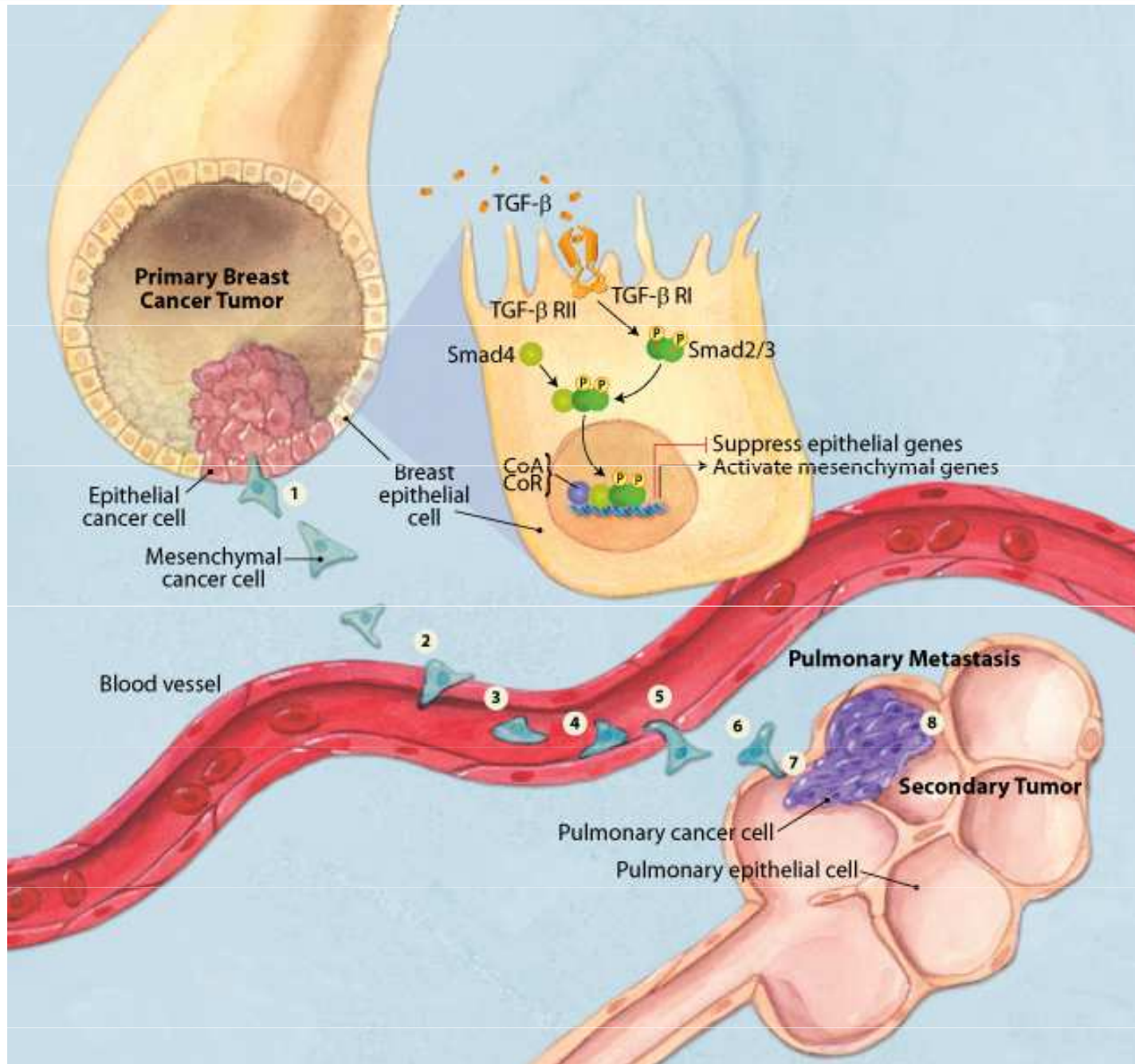
■ EMT in embryonic development



EMT in tumor dissemination

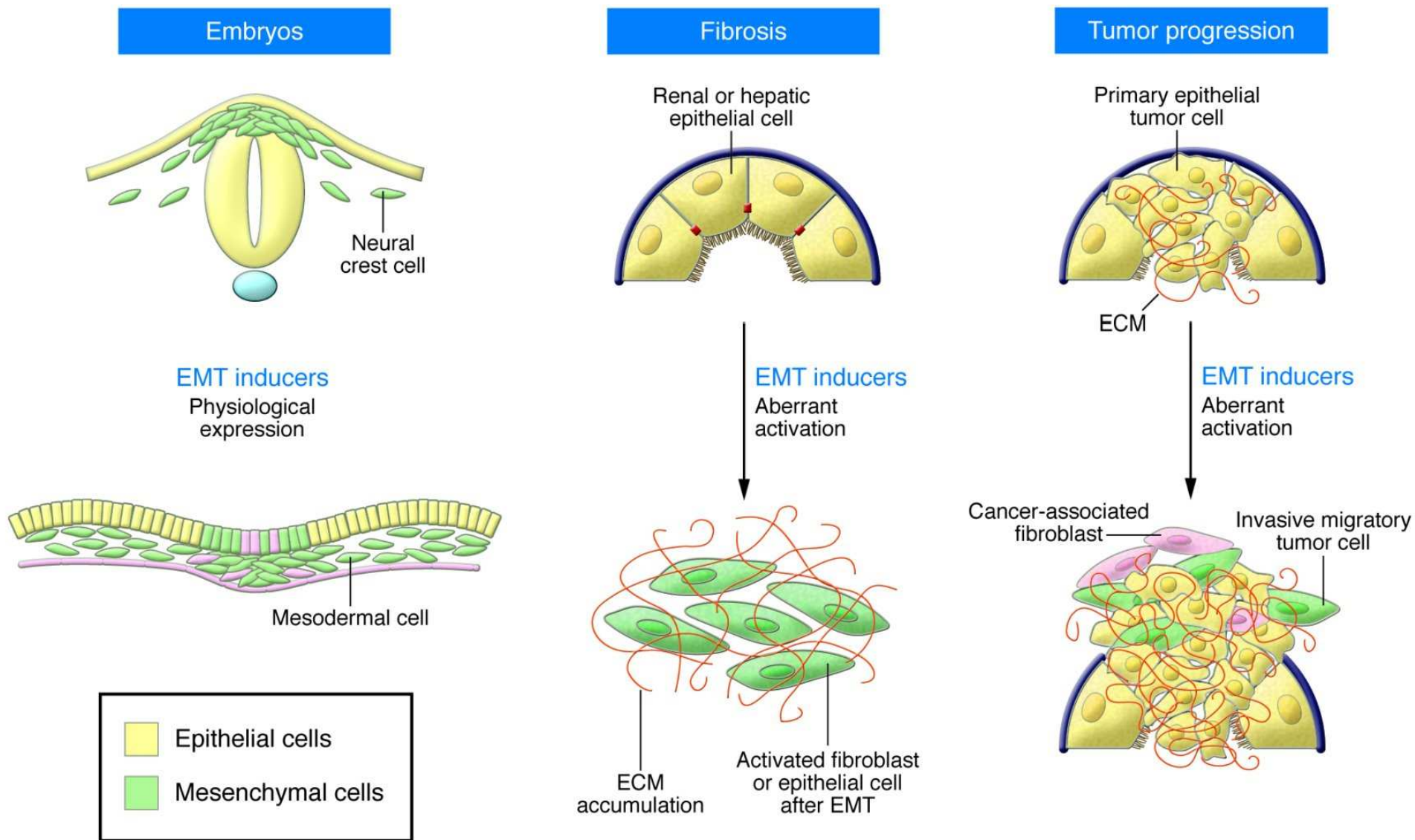


PLASTICITY OF EPITHELIAL TISSUES

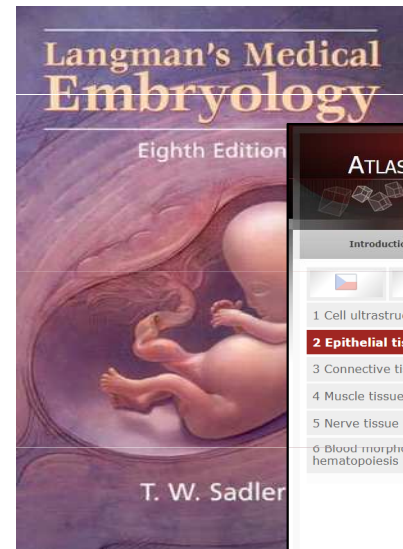
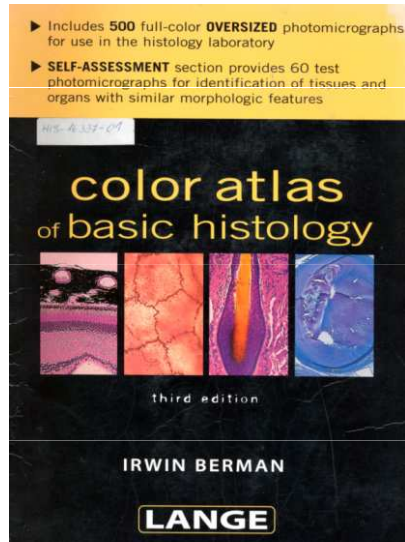
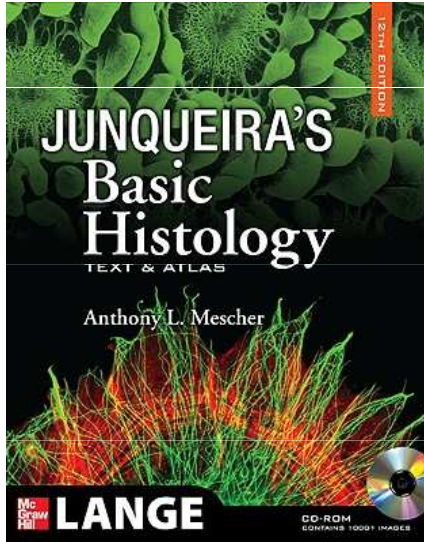
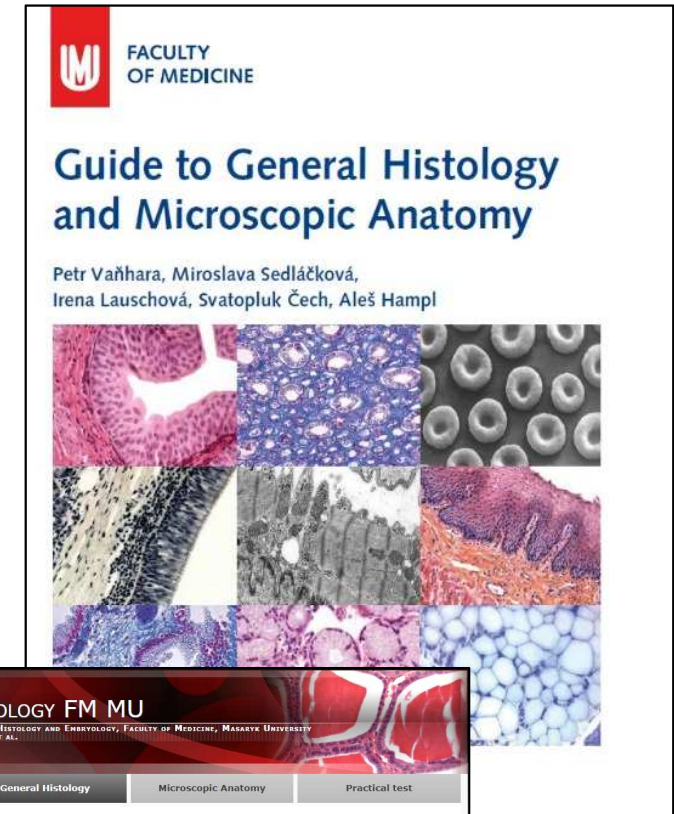





PLASTICITY OF EPITHELIAL TISSUES

■ EMT



FURTHER STUDY



ATLAS OF HISTOLOGY FM MU
DEPARTMENT OF HISTOLOGY AND EMBRYOLOGY, FACULTY OF MEDICINE, MASARYK UNIVERSITY
PETR VAŇHARA ET AL.

Introduction	General Histology	Microscopic Anatomy	Practical test
<p>2 Epithelial tissue</p> <p>Cells of epithelial tissue are tightly arranged, most frequently into sheets. Apical part of the epithelial cell is oriented towards a free space or cavity and is equipped by various functional structures (microvilli, stereocilia, kinocilia, etc.). The basal part interacts with basement membrane. Epithelial cells are laterally connected by intercellular junctions (adhering, occluding, communicating). Epithelial tissue contains scarce extracellular matrix and is avascular.</p> <p>Based on the structure, epithelia are classified as <i>sheet</i> or <i>covering</i> (continuous planar structures), <i>trabecular</i> (cells form anastomosing cords - in liver or endocrine glands) and <i>reticular</i> epithelium (star-shaped cells form three dimensional network - in thymus). Based on the function, epithelia are classified as <i>covering</i> (epithelial membranes or sheets), <i>glandular</i>, <i>absorptive</i>, <i>respiratory</i>, <i>sensory</i>. The most common type of epithelial tissue is the covering epithelium, that is further classified according to the number of layers and cell morphology.</p>			
<p>1 Cell ultrastructure</p> <p>2 Epithelial tissue</p> <p>3 Connective tissue</p> <p>4 Muscle tissue</p> <p>5 Nerve tissue</p> <p>6 Blood morphology and hematopoiesis</p>	<p>2.1 Simple squamous epithelium - amniotic ectoderm of umbilical cord (HES)</p> <p>2.2 Simple squamous epithelium - pneumocytes in lung alveolus (HE)</p> <p>2.3 Simple cuboidal epithelium - kidney (AZAN)</p> <p>2.4 Simple columnar epithelium - gallbladder (AZAN)</p> <p>2.5 Simple columnar epithelium - oviduct (HE)</p> <p>2.6 Pseudostratified columnar ciliated epithelium - trachea (Iron-hematoxylin)</p> <p>2.7 Nonkeratinized stratified squamous epithelium - esophagus (HES)</p> <p>2.8 Keratinized stratified squamous epithelium - epidermis (HE)</p> <p>2.9 Transitional epithelium - ureters (HE)</p> <p>2.10 Pseudostratified columnar ciliated epithelium - trachea (HE)</p> <p>2.11 Serous acinus (alveolus) - lacrimal gland (HE)</p> <p>2.12 Mucous tubule - sublingual salivary gland (cross section, HE)</p> <p>2.13 Mucous tubule - sublingual salivary gland (longitudinal section, HE)</p> <p>2.14 Demilune of Gianuzzi - submandibular salivary gland (HE)</p> <p>2.15 Trabecular epithelium - liver parenchyma</p>	<p>2.1 Simple squamous epithelium - pneumocytes in lung alveolus (HE)</p> <p>2.4 Simple columnar epithelium - gallbladder (AZAN)</p> <p>2.6 Pseudostratified columnar ciliated epithelium - trachea (Iron-hematoxylin)</p> <p>2.8 Keratinized stratified squamous epithelium - epidermis (HE)</p> <p>2.10 Pseudostratified columnar ciliated epithelium - trachea (HE)</p> <p>2.12 Mucous tubule - sublingual salivary gland (cross section, HE)</p> <p>2.14 Demilune of Gianuzzi - submandibular salivary gland (HE)</p>	

<http://www.med.muni.cz/histology>



Thank you for attention

pvanhara@med.muni.cz

<http://www.med.muni.cz/histology/petr-vanhara/>

<http://www.med.muni.cz/histology/education/>