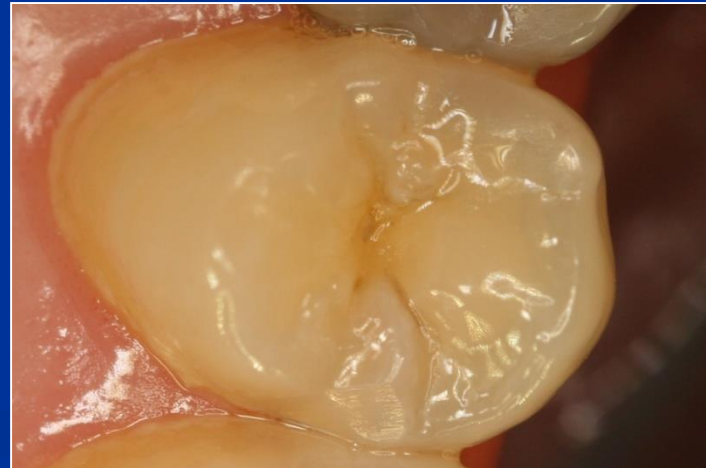

Class II.

Location:

Defects affecting one or both proximal surfaces of posterior teeth.



Interdental space

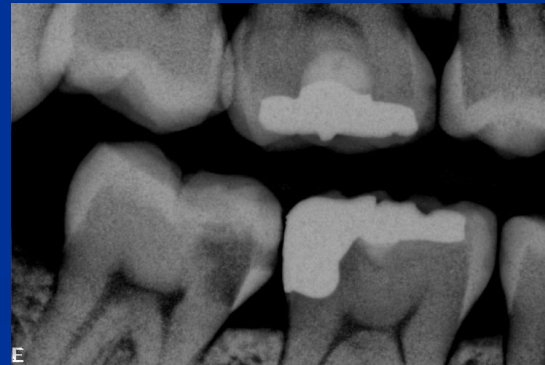- Interdental space is caries danger area (below the contact point).
- Interdental space is infilled with interdental palilla, that moves apically during the time and the space is open.
- Dental caries begins below the contact point.

Class II.

Origin:

Proximal surface below the contact point

Propagation of dental caries from
the occlusal surface

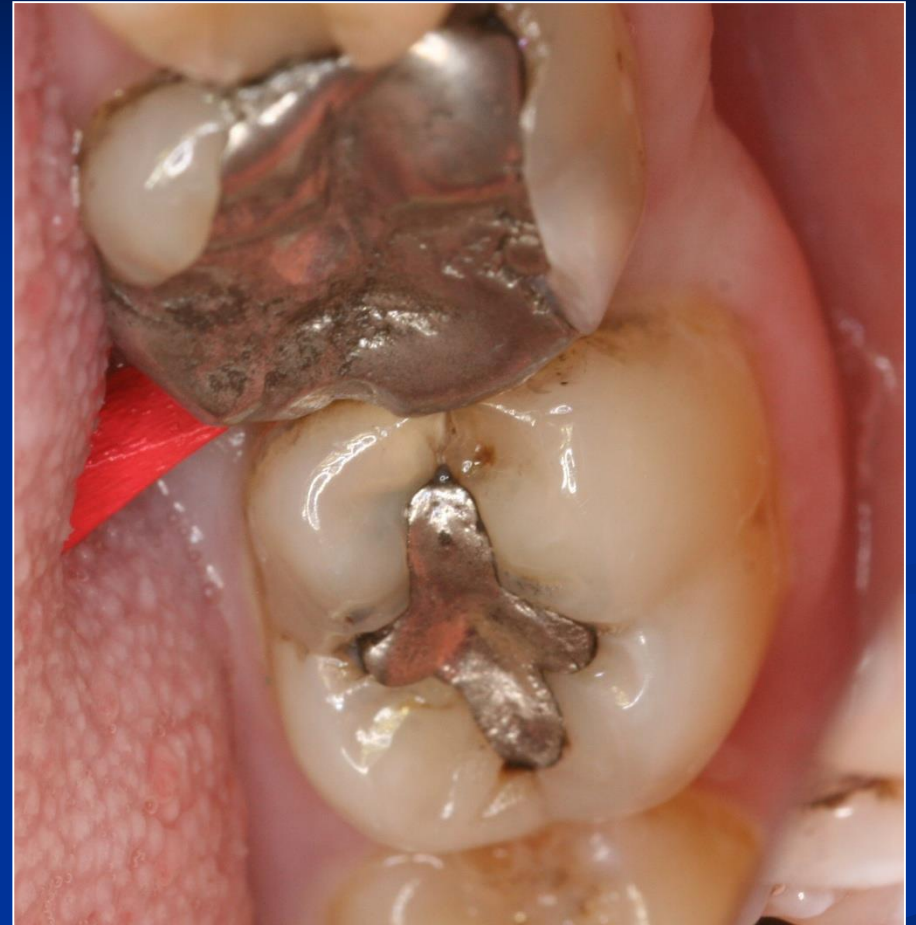
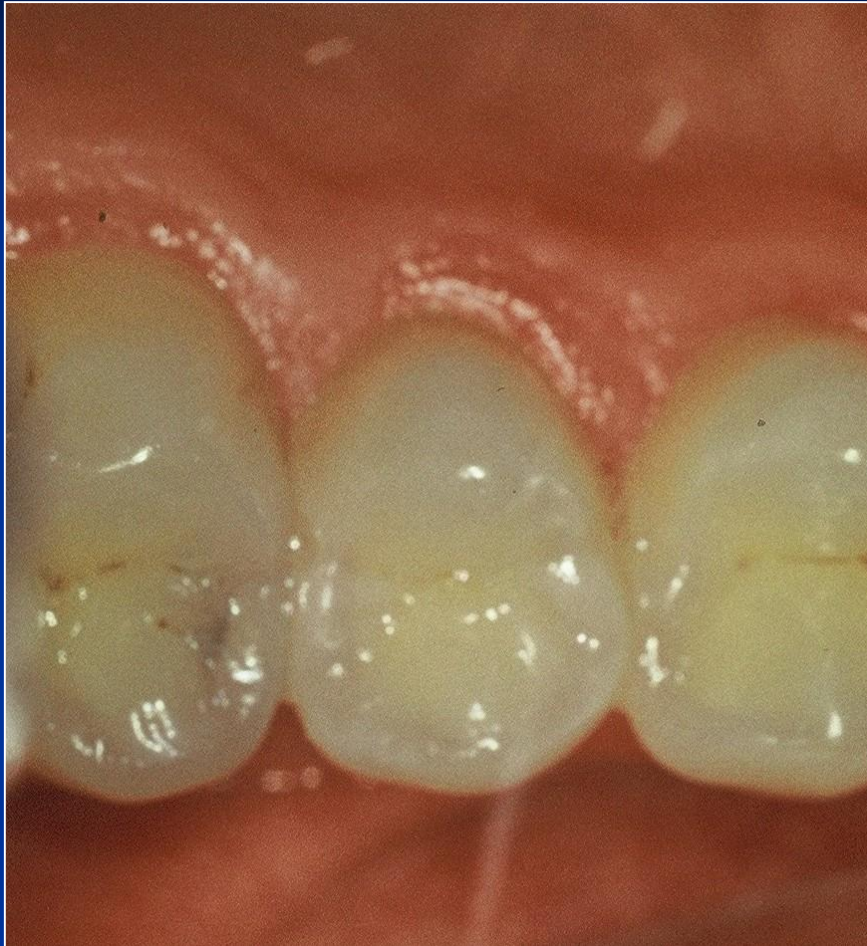
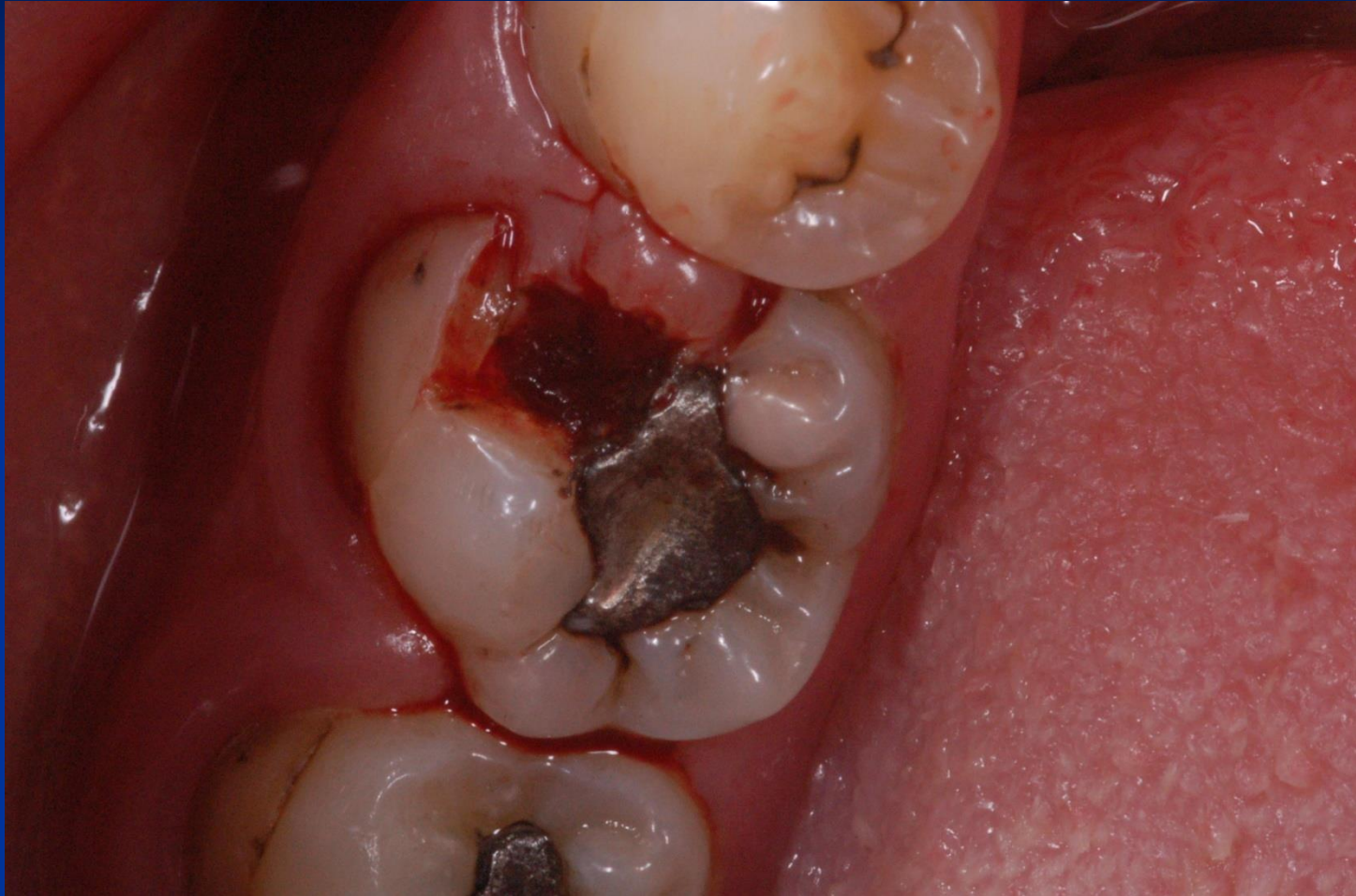Symptoms

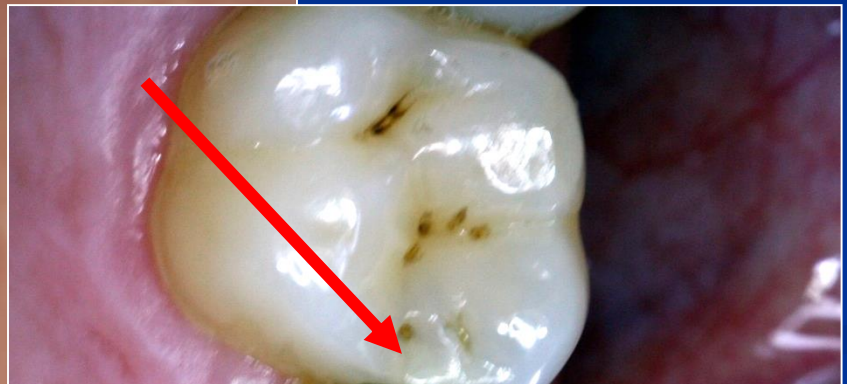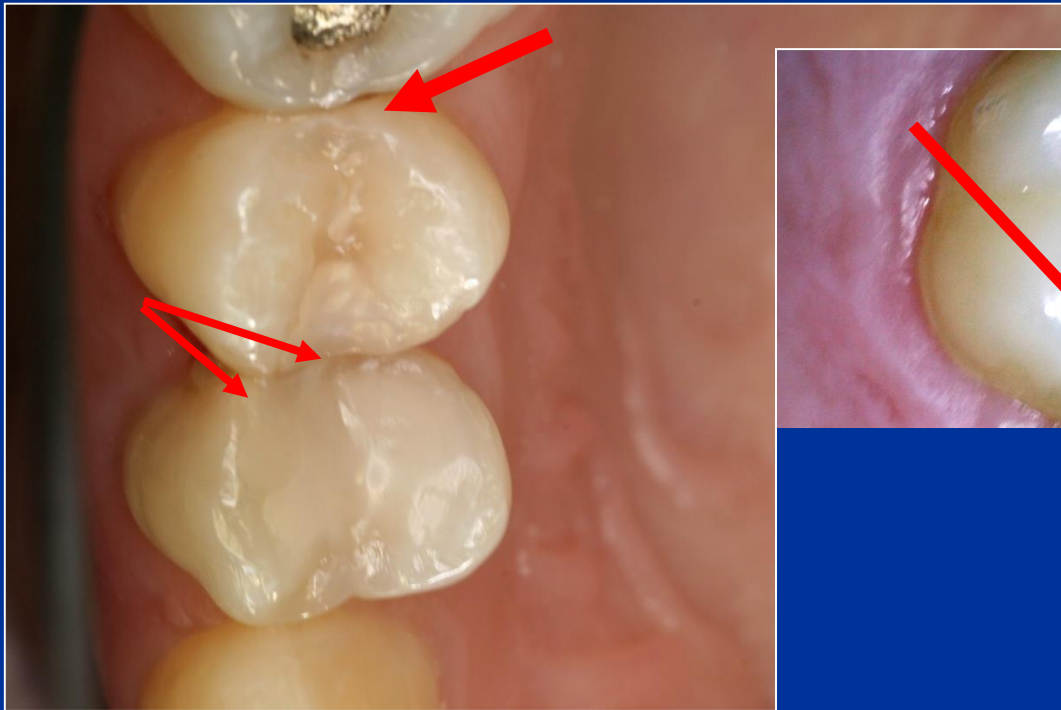
- No symptoms
- Increased sensitivity (cold, sweet)
- Retention of food
- Defect (cariou lesion is open – the enamel is broken)
- Bite sensitivity (when cariou lesion is open)

Diagnosis

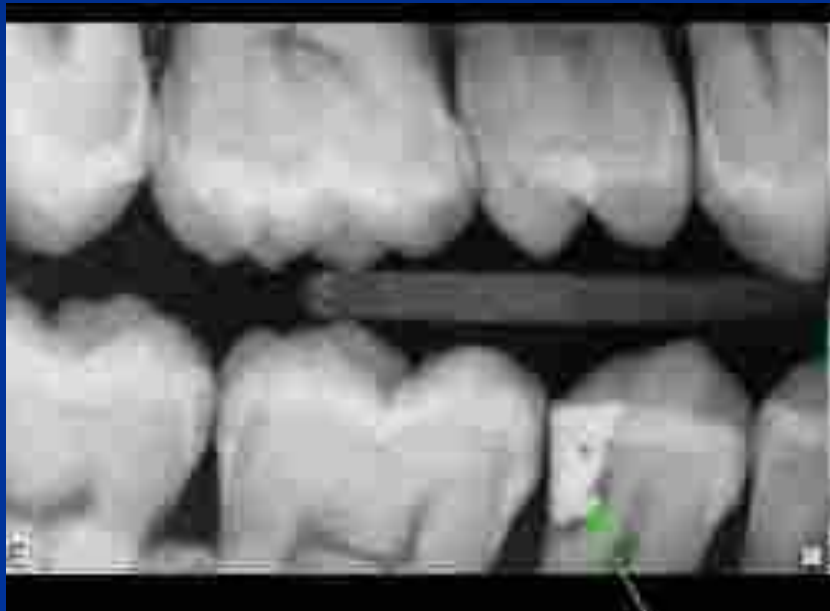- Visual changes of tooth structure (chalk white colour).
- Transillumination (white light, or Diagno Cam).
- Radiography



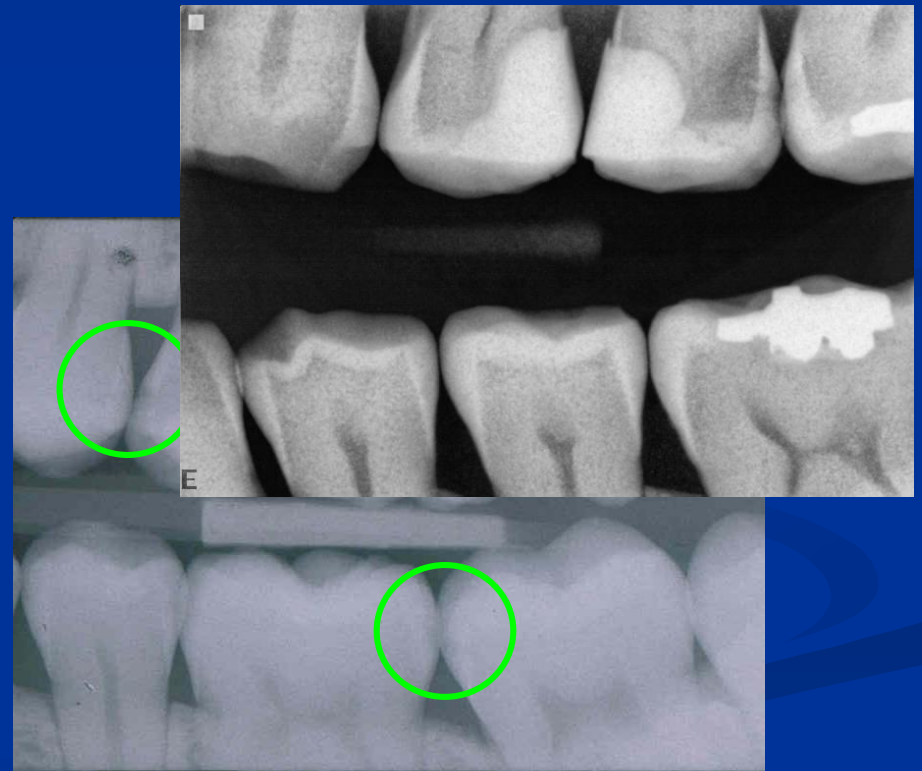
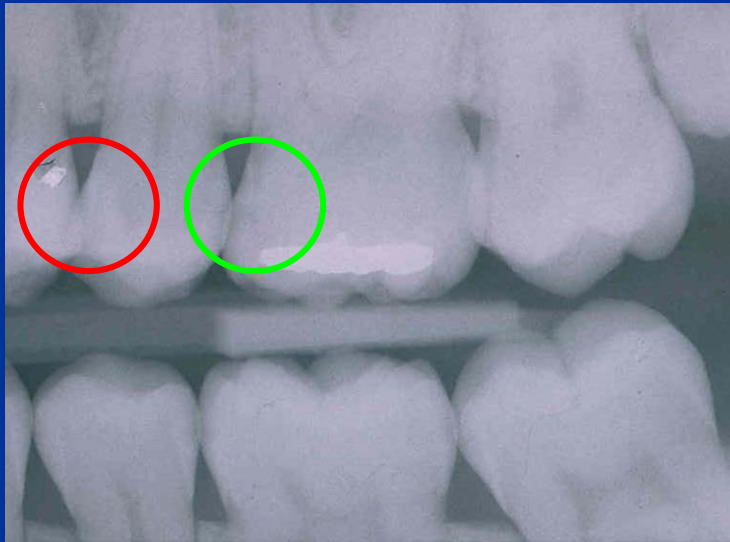




Bite wing

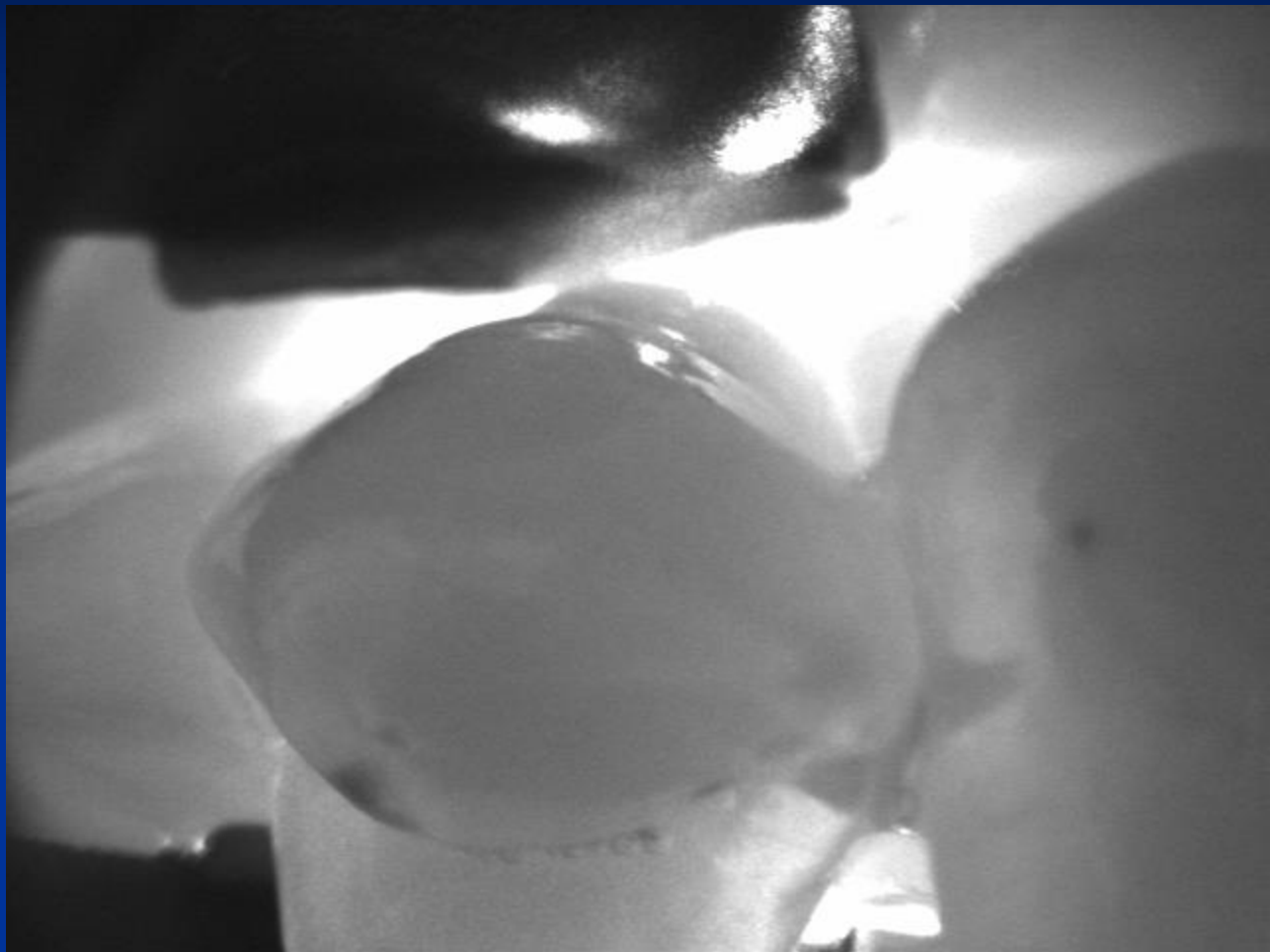


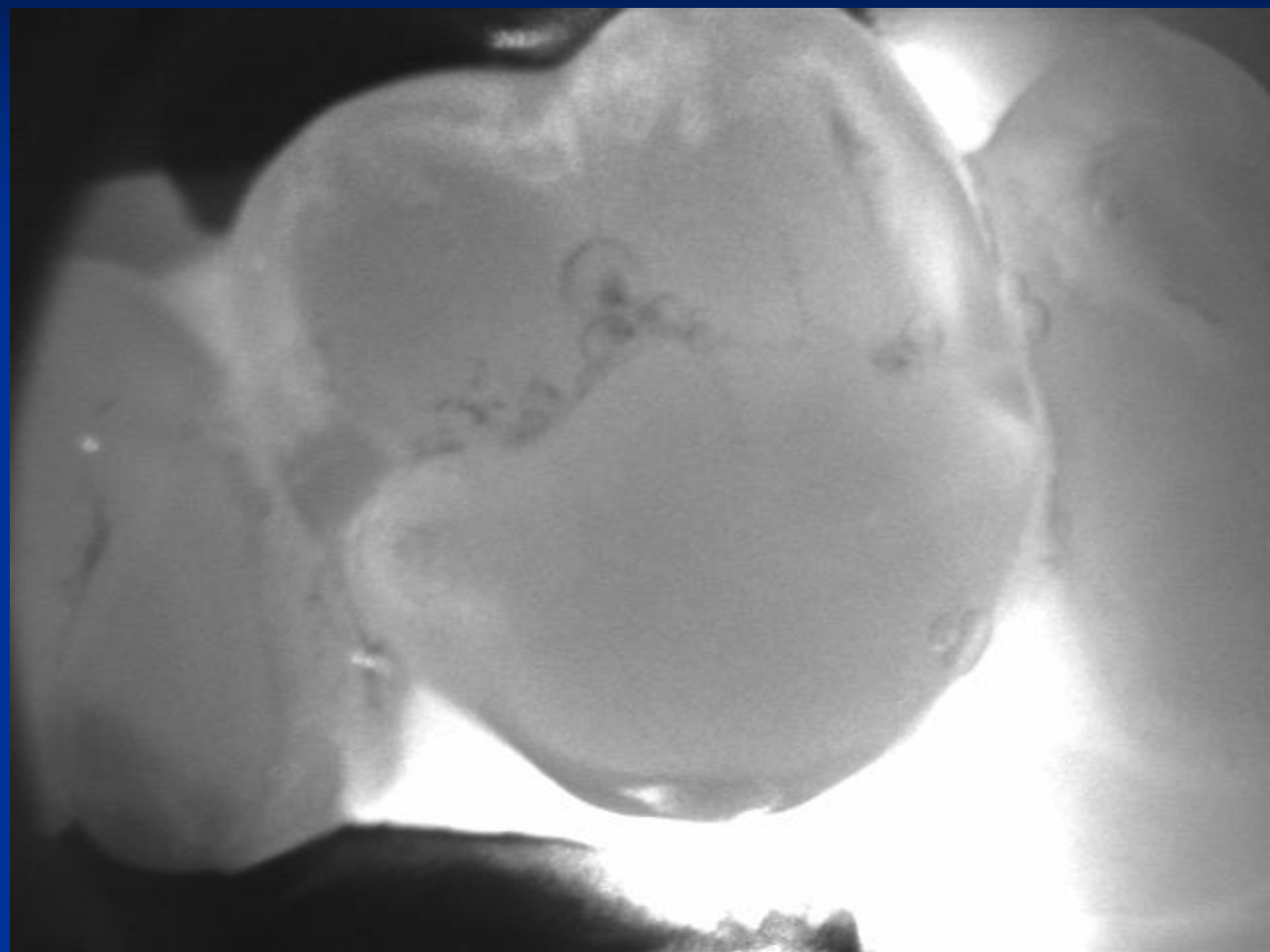
- D1 – projasnění do ½ tloušťky skloviny
- D2 – projasnění na hranici skloviny a dentinu
- D3 – projasnění do dentinu
- D4 - projasnění sahající do dřeňové dutiny

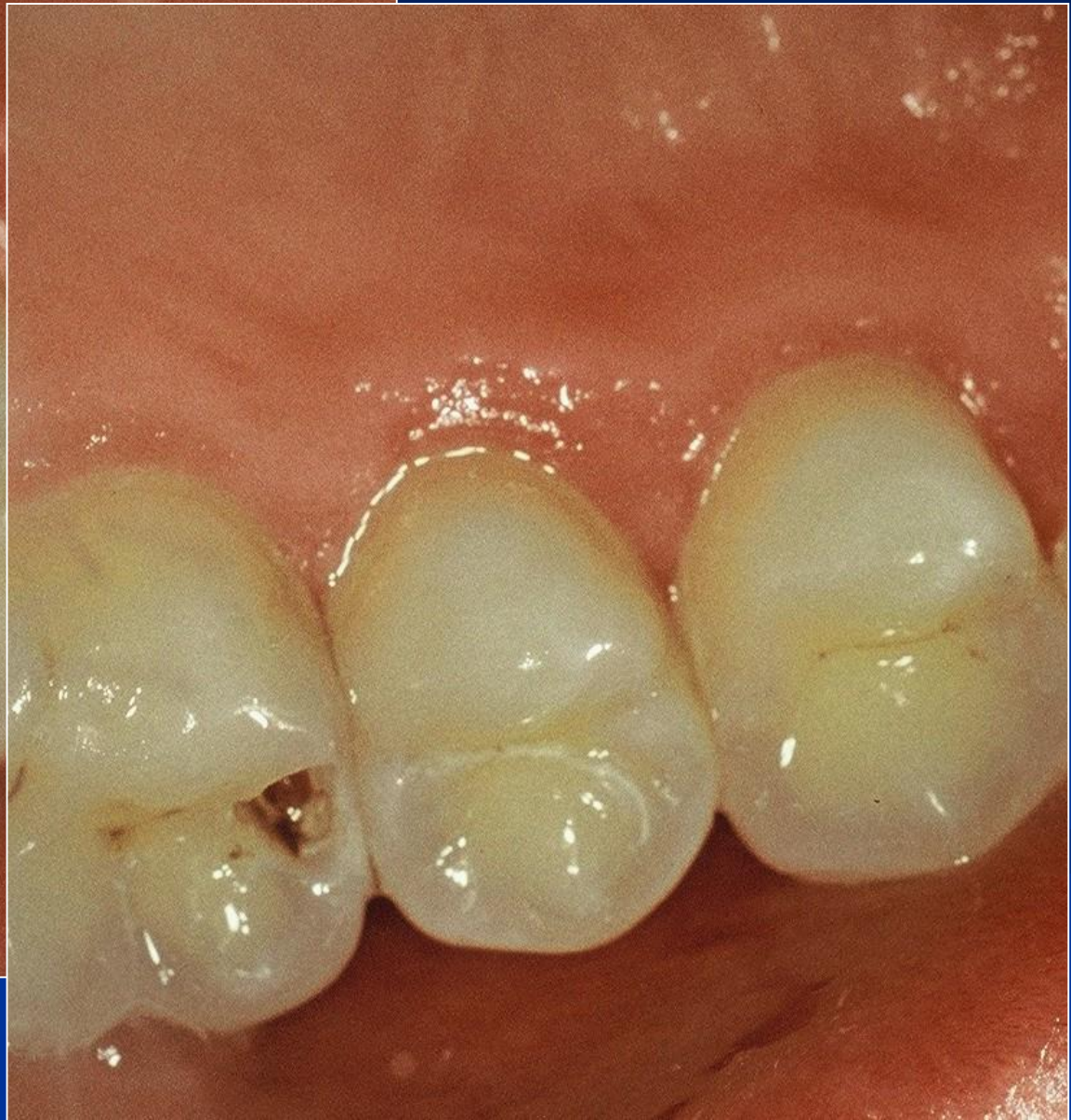
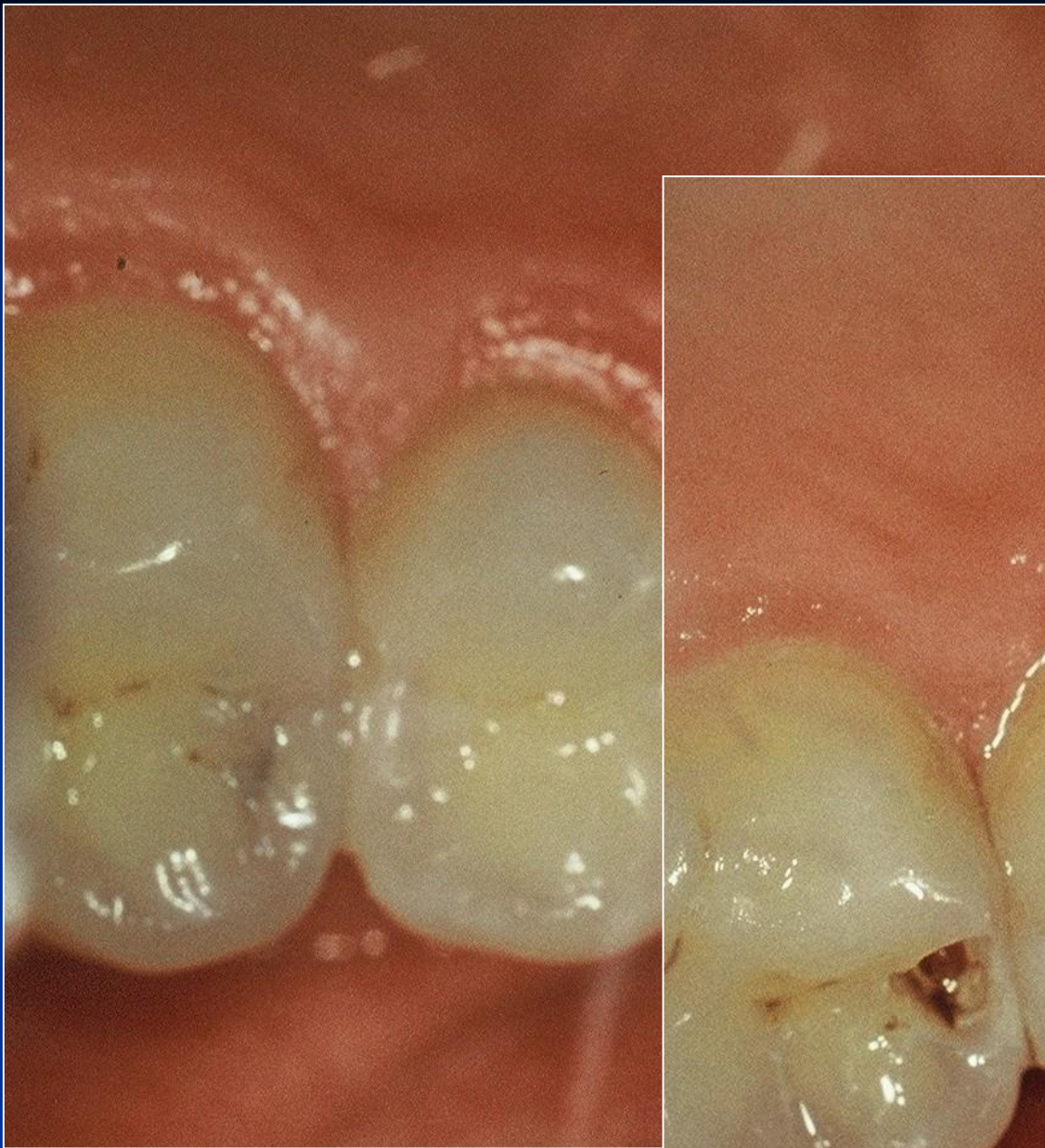
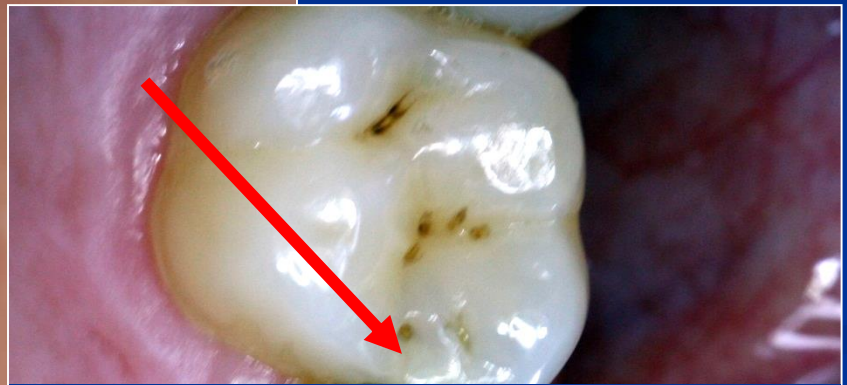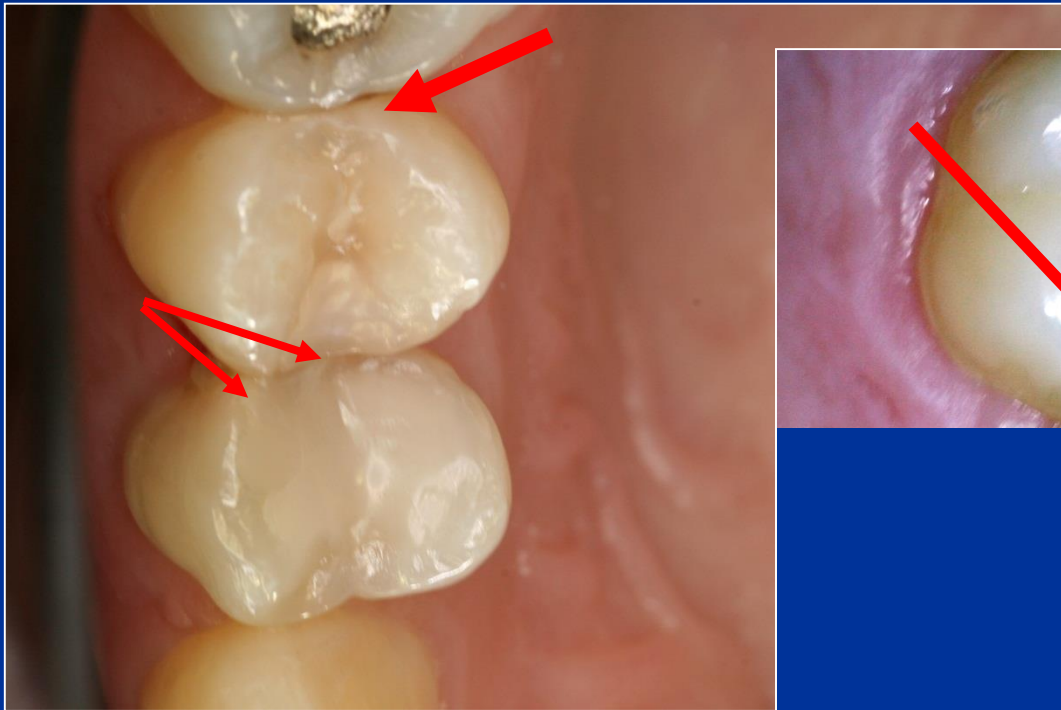
DIAGNOCam





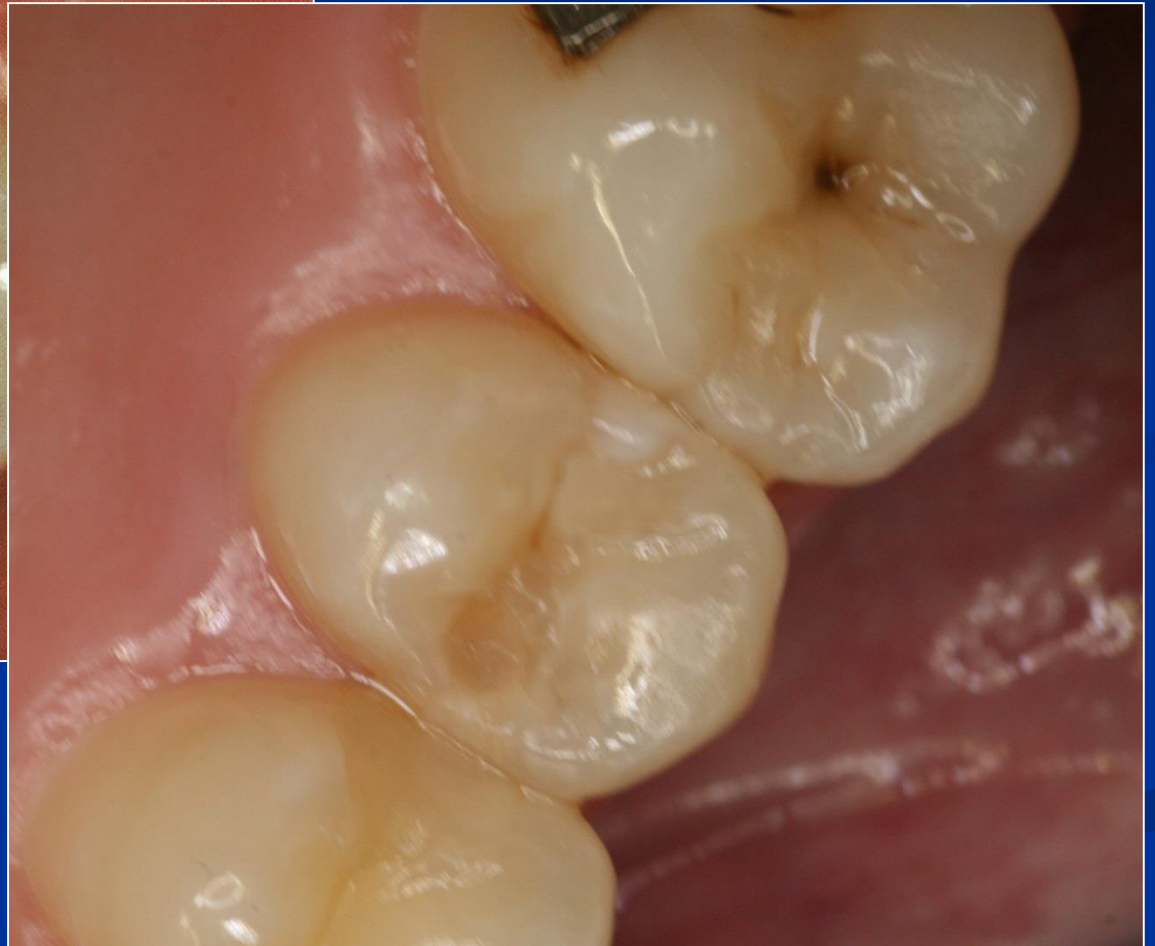
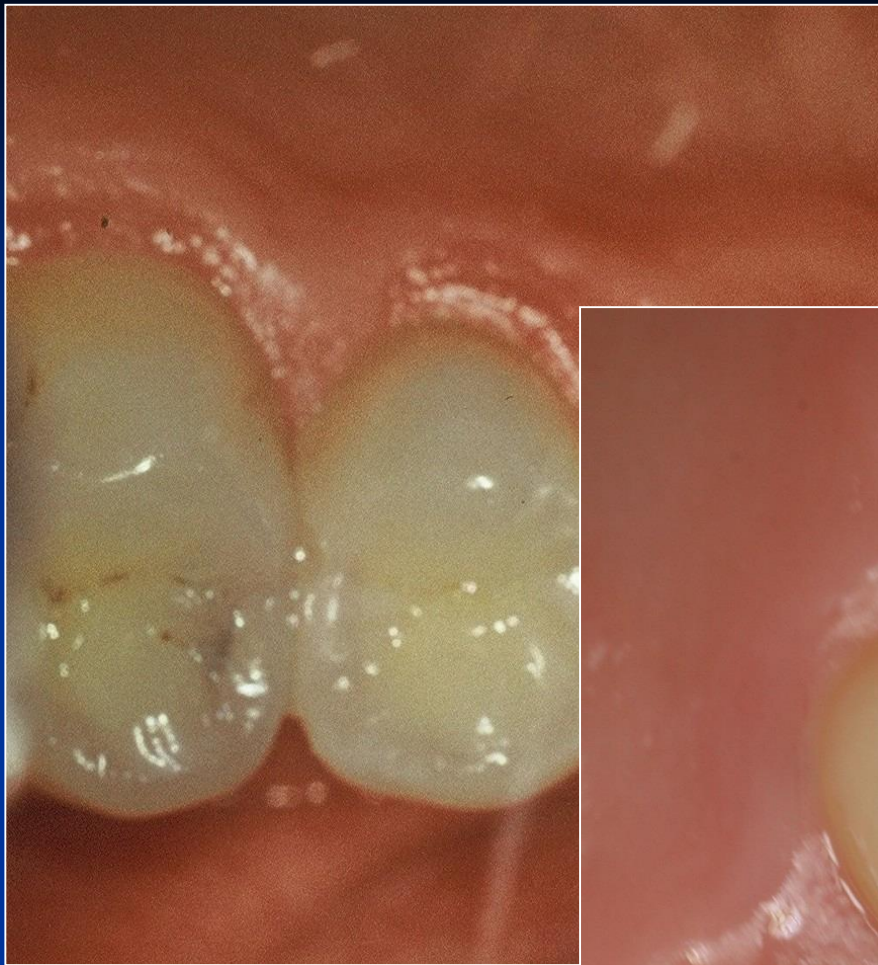
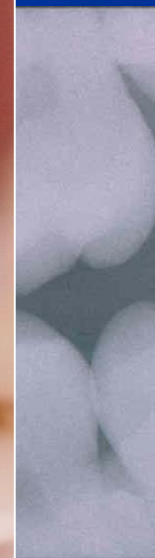
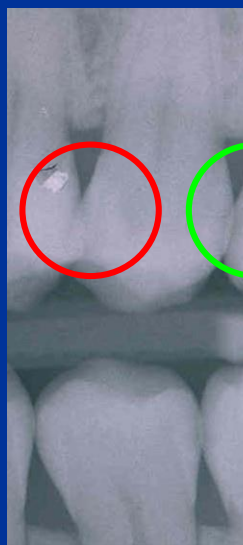
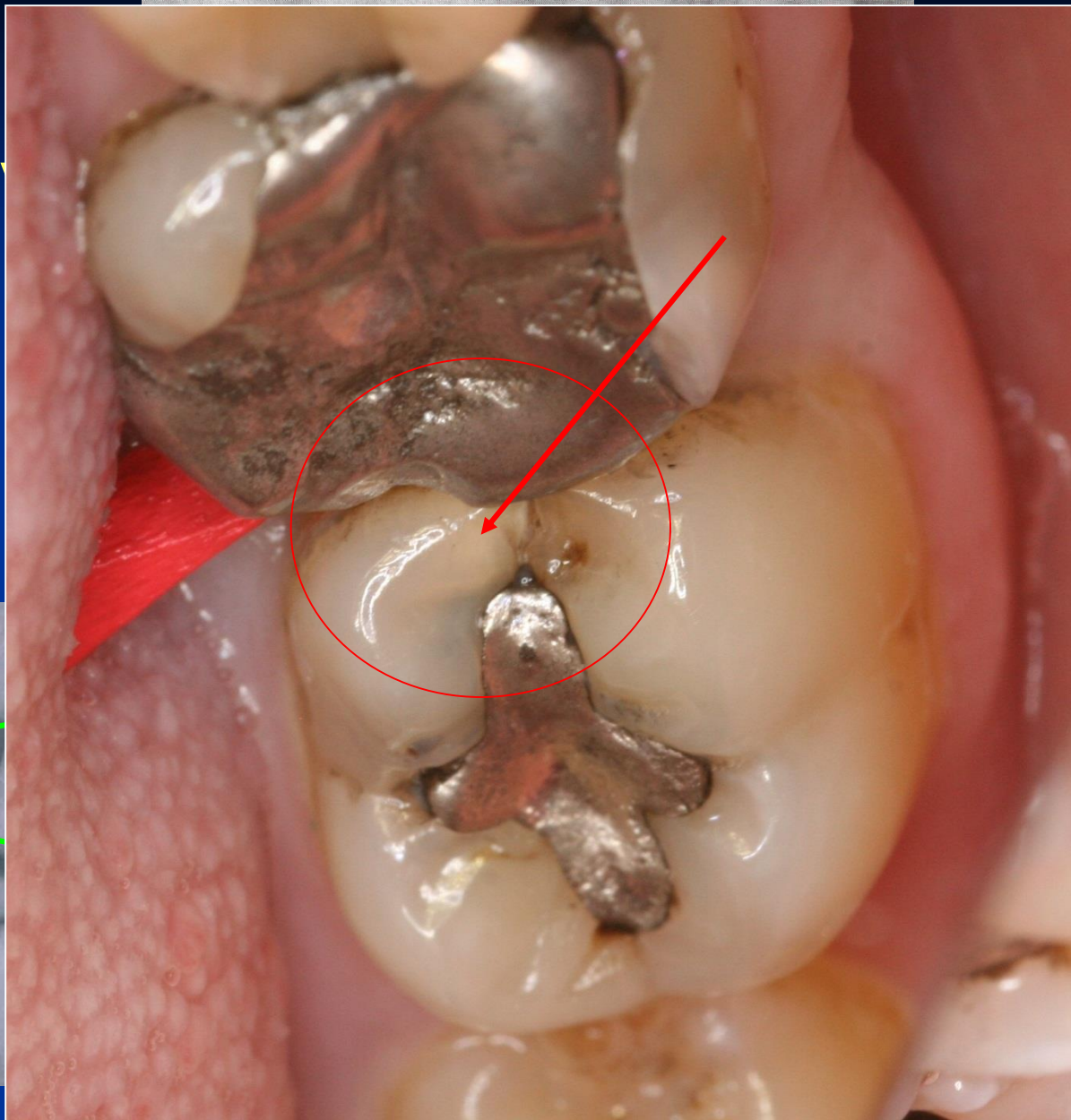








4 stupňo
grading



KTG vyšetření – Bite wing

Filling materials

- Amalgam
- Composite materials
- Glass ionomer cements

Choice of the material depends on

- Size of carious lesion
- Level of oral hygiene
- Occlusal loading
- Cooperation of the patient and other factors

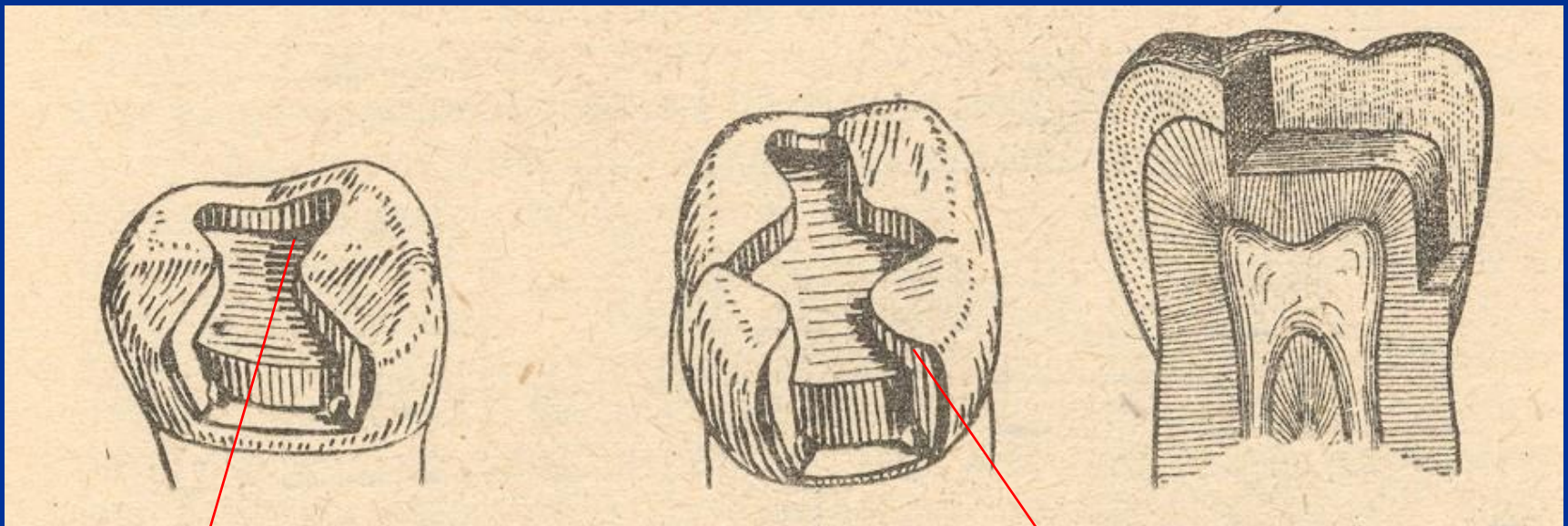
Preparation - amalgam

- Conventional preparation acc. to the Black's rules
- Slot preparation
- Large preparation – cusp(s) involved

Preparation - adhesive materials (composites, glass ionomers)

- Conventional preparation for composites
- Adhesive slot
- Tunnel preparation

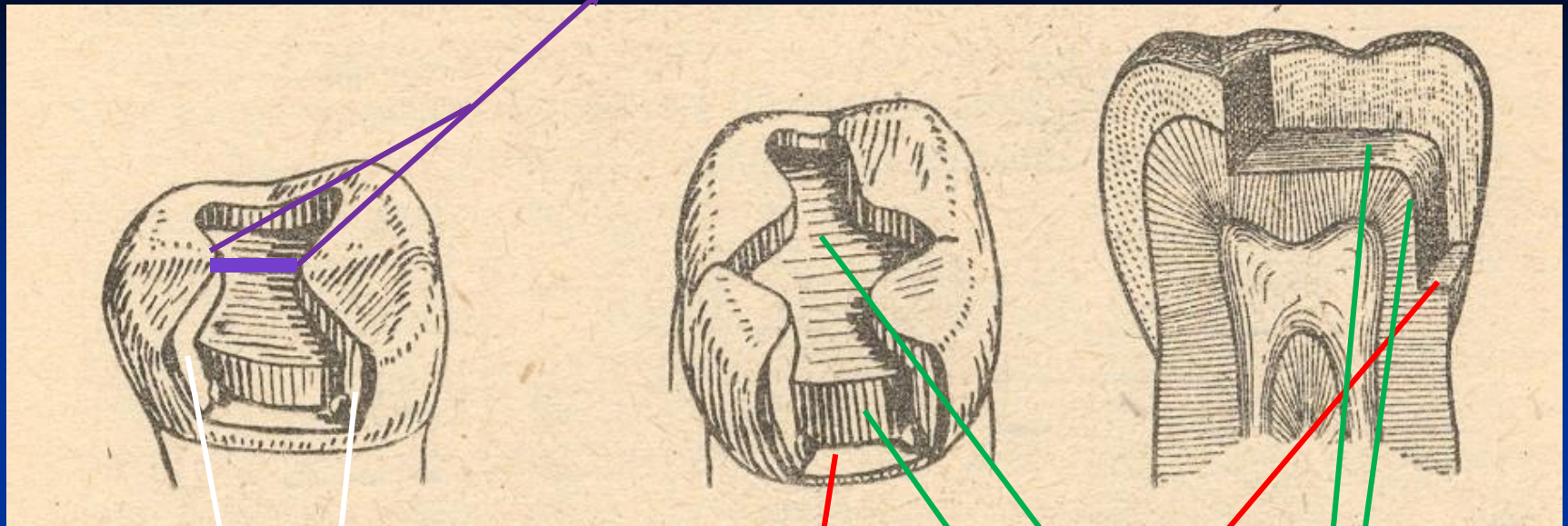
Conventional preparation amalgam



Occlusal cavity

Proximal cavity - box

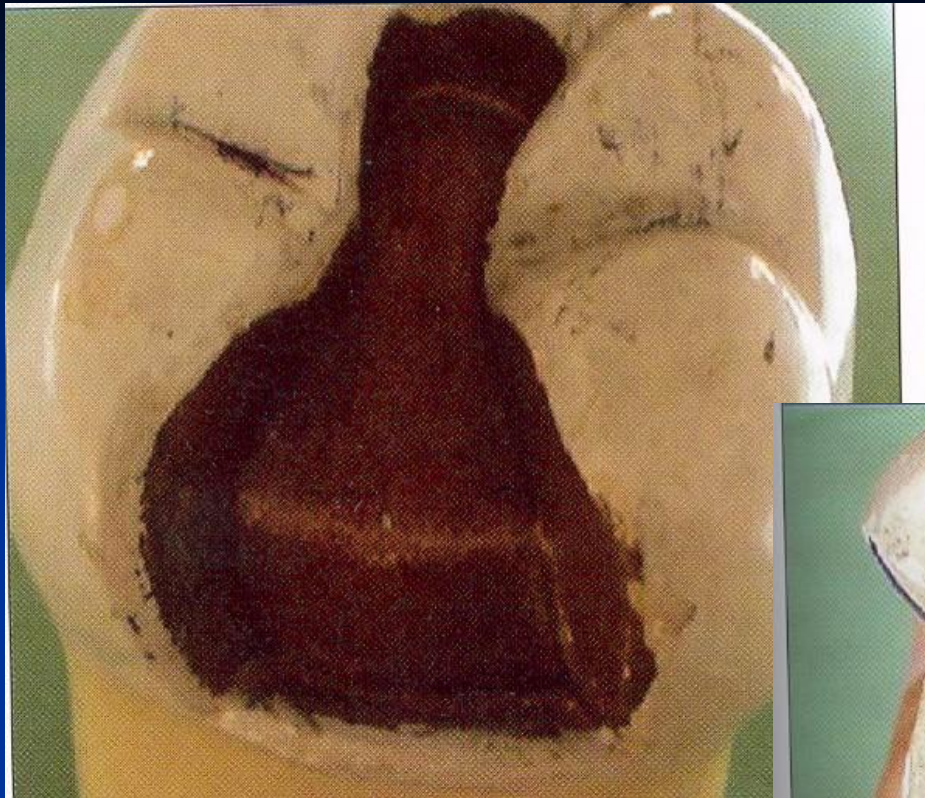Isthmus



Axial wall

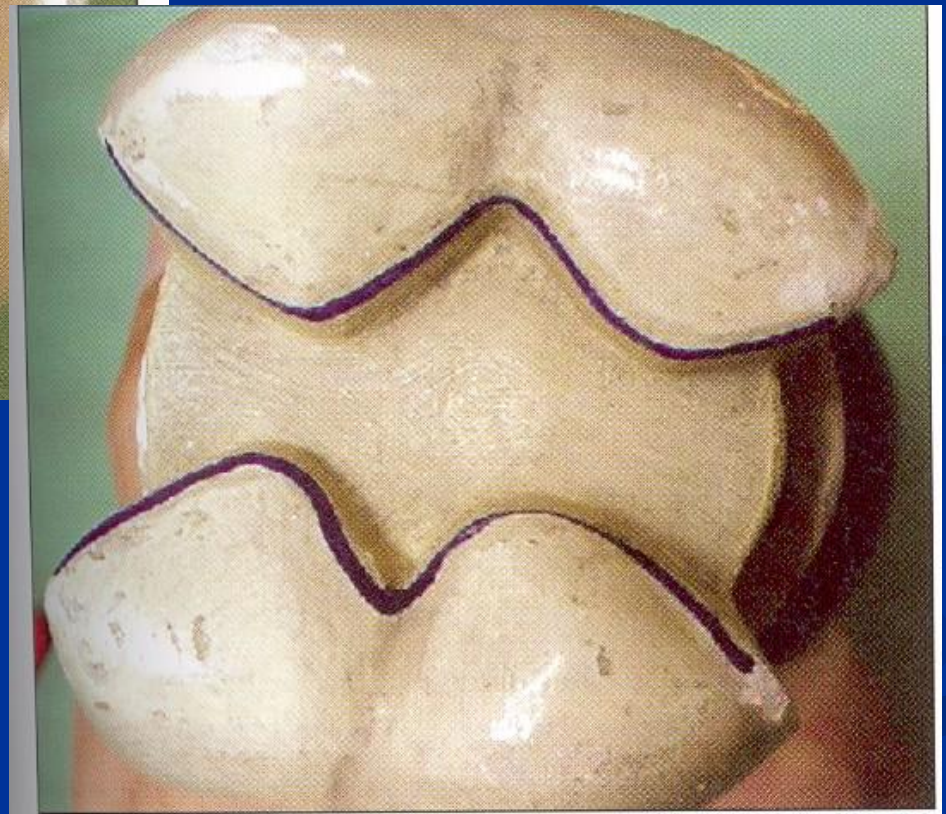
Pulpal walls

Gingival wall



MO, OD: one proximal surface affected – mesio-occlusal disto-occlusal

MOD: mesiodisto-occlusal



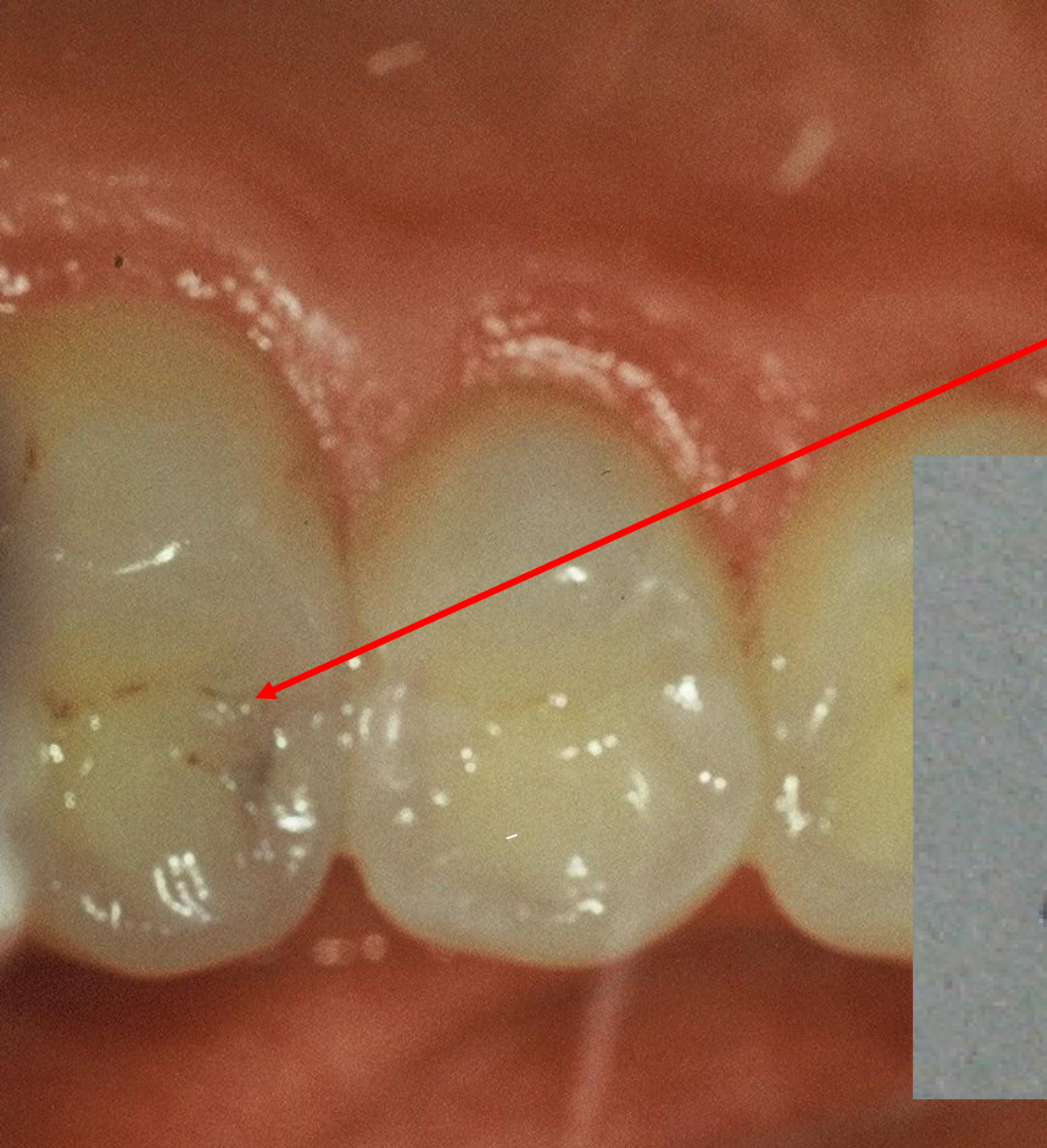
Access to the cavity

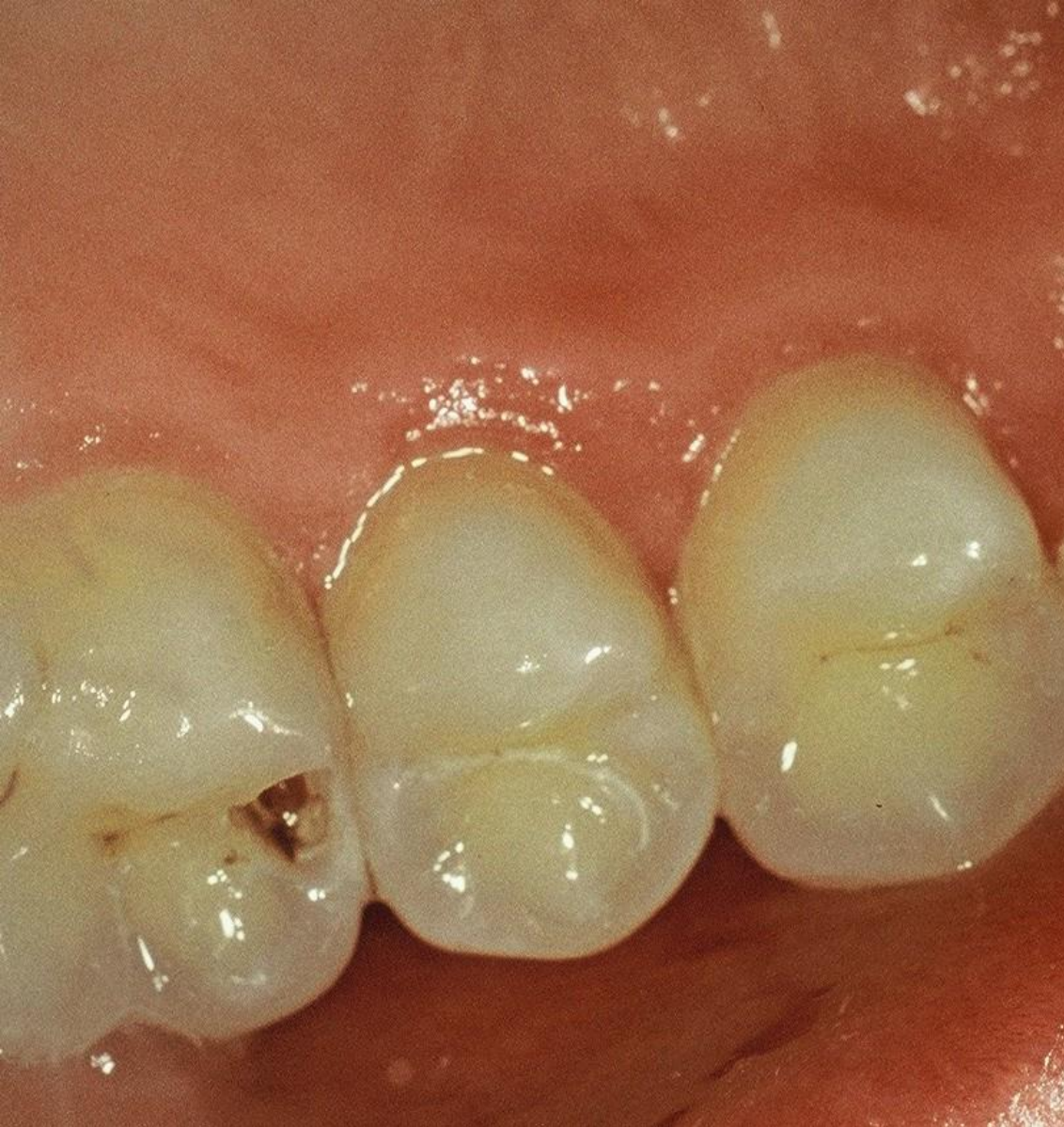From the occlusal surface

Through the undermined enamel

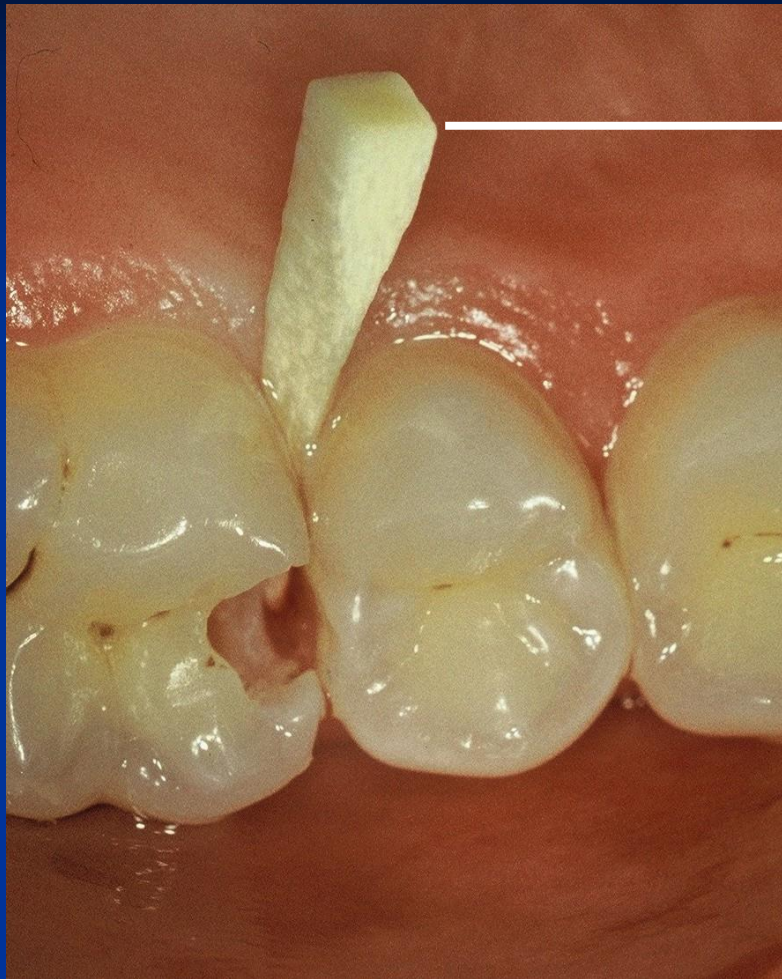Separation using wooden wedges is useful

Pre op

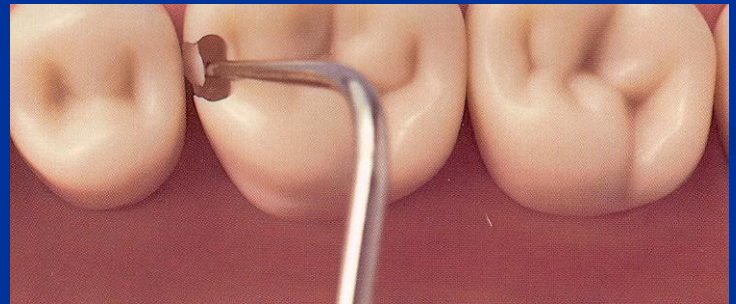




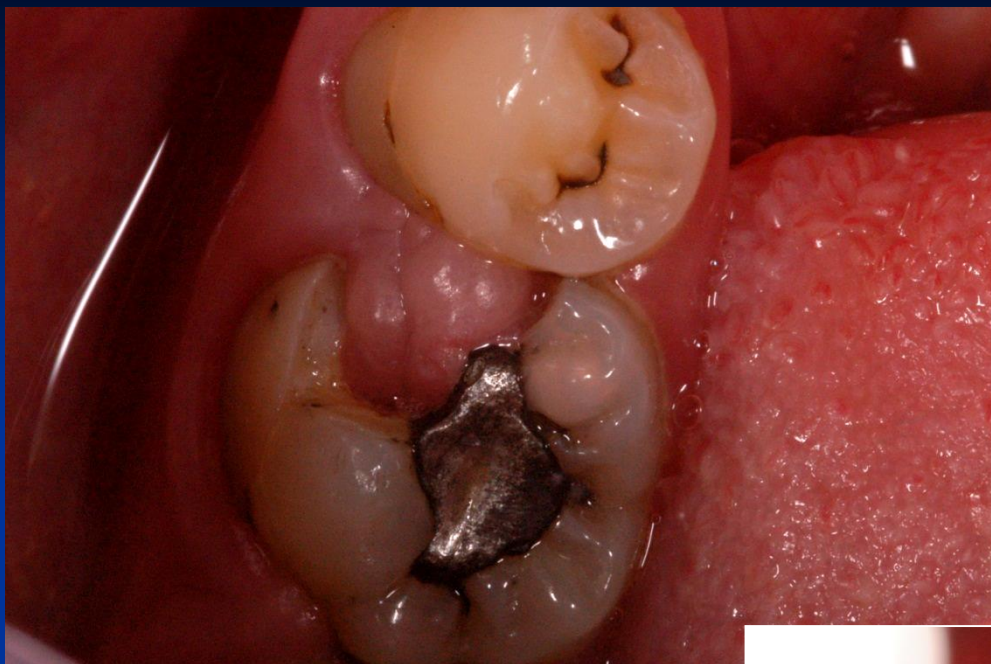Access to the cavity



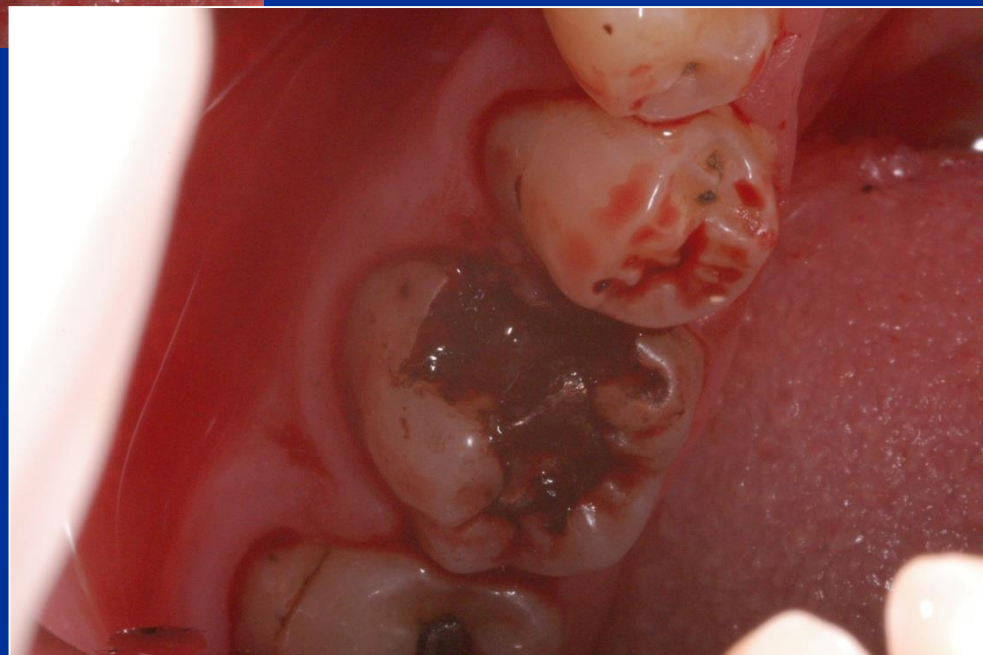Wooden wedge



Breaking the thin enamel layer out of the cavity



➤ Remove of the gingiva that grows into the cavity



Cavosurface margin and extention for prevention

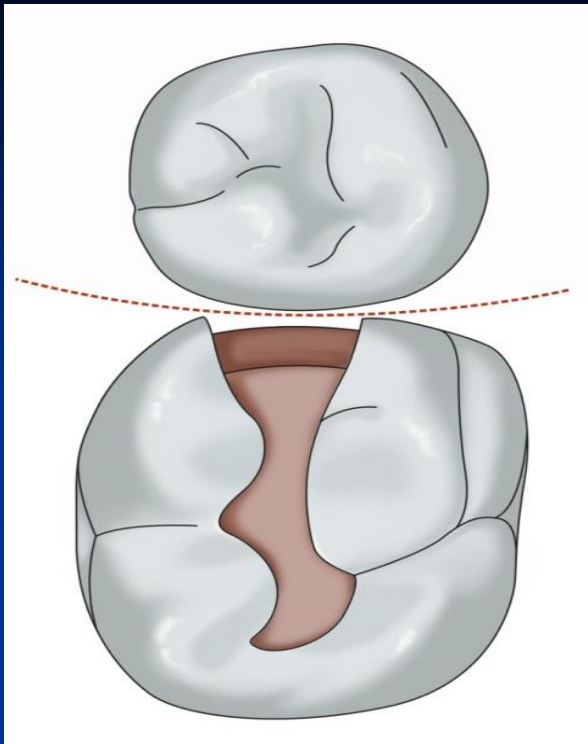
Proximal box:

Vestibullary and orally – axial walls (the border between the oral/vestibular and proximal surface.

Below the free gingiva (0,5 mm)

Occlusal

Class I.

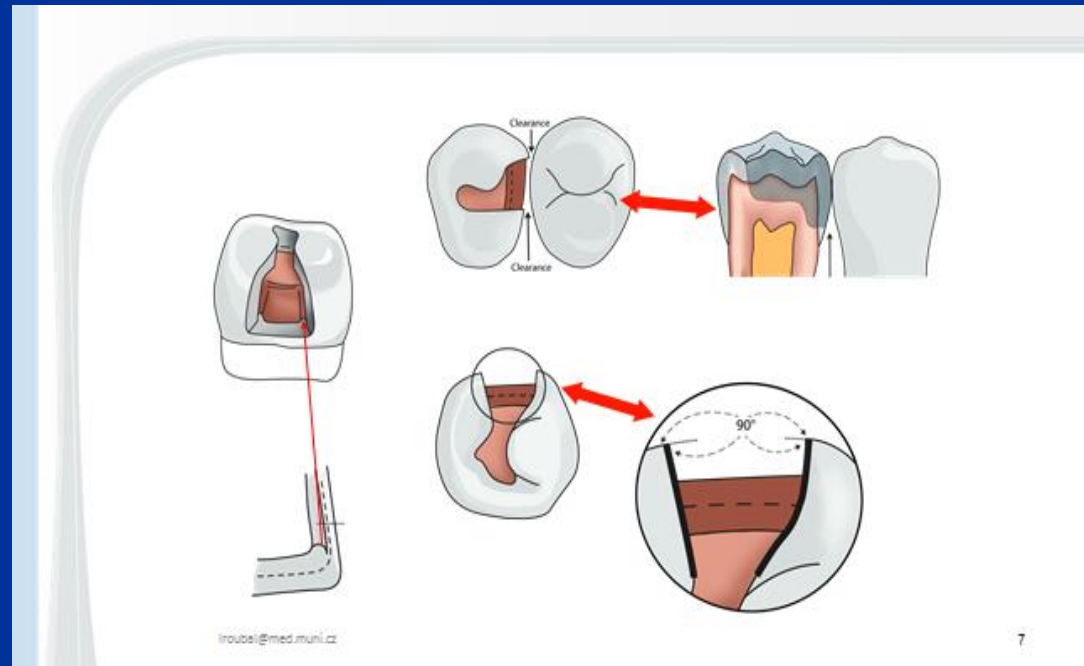


Gingival wall is parallel with the cementoenamel junction and it is situated approx. 0,5 mm below free gingiva.


Axial walls

Study the contact area (contact point):
The axial walls (cavosurface margins) are approx. 0,5 mm vestibular and orally
Over this area.

The contact of the treated tooth is made of the restorative materials.



American rule



Tangents from the middle of treated tooth to the next tooth – where these cross the treated Tooth there are borders of the preparation

Retention

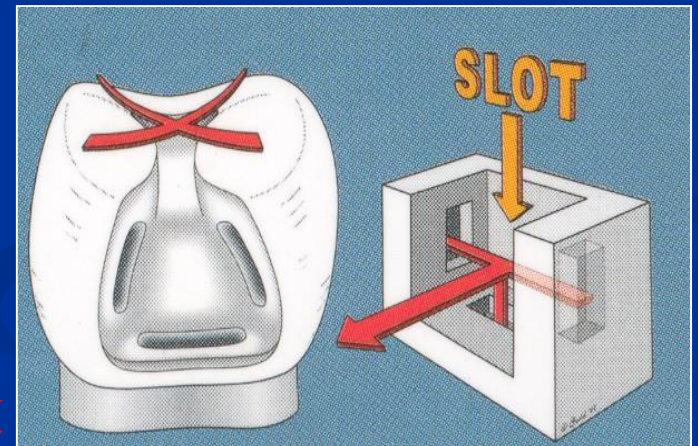
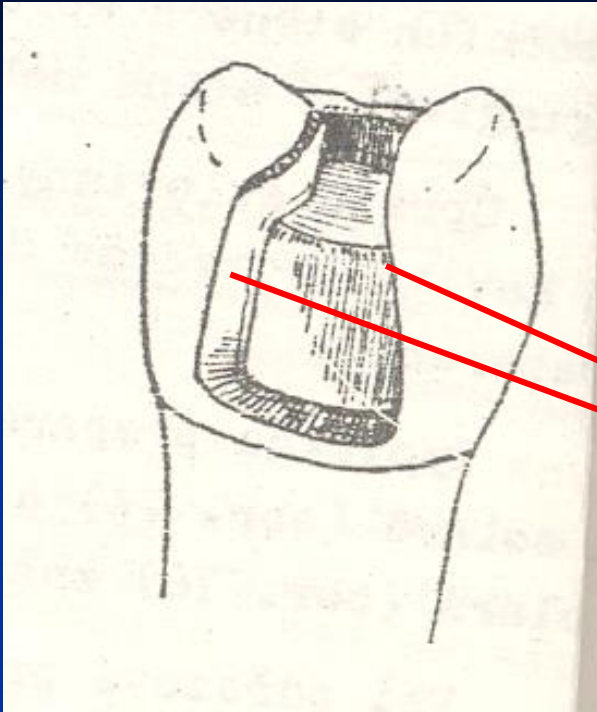
- Occlusal cavity
- Undercuts
- Grooves

Proximal cavity – box

Slight divergency of axial walls

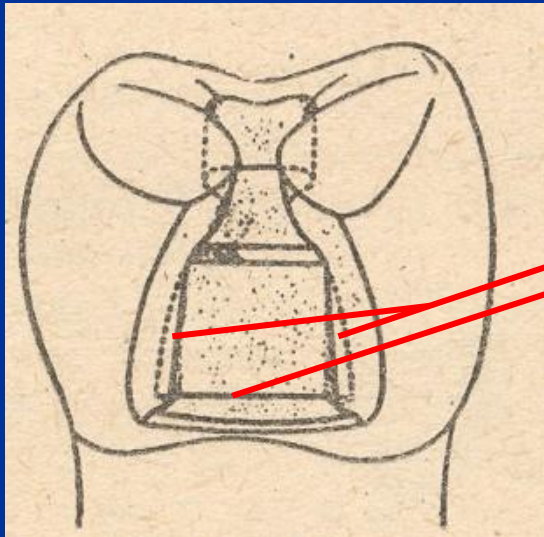
Gingival wall follows the cementoenamel junction

Gingival wall is below free gingiva



Autoretention

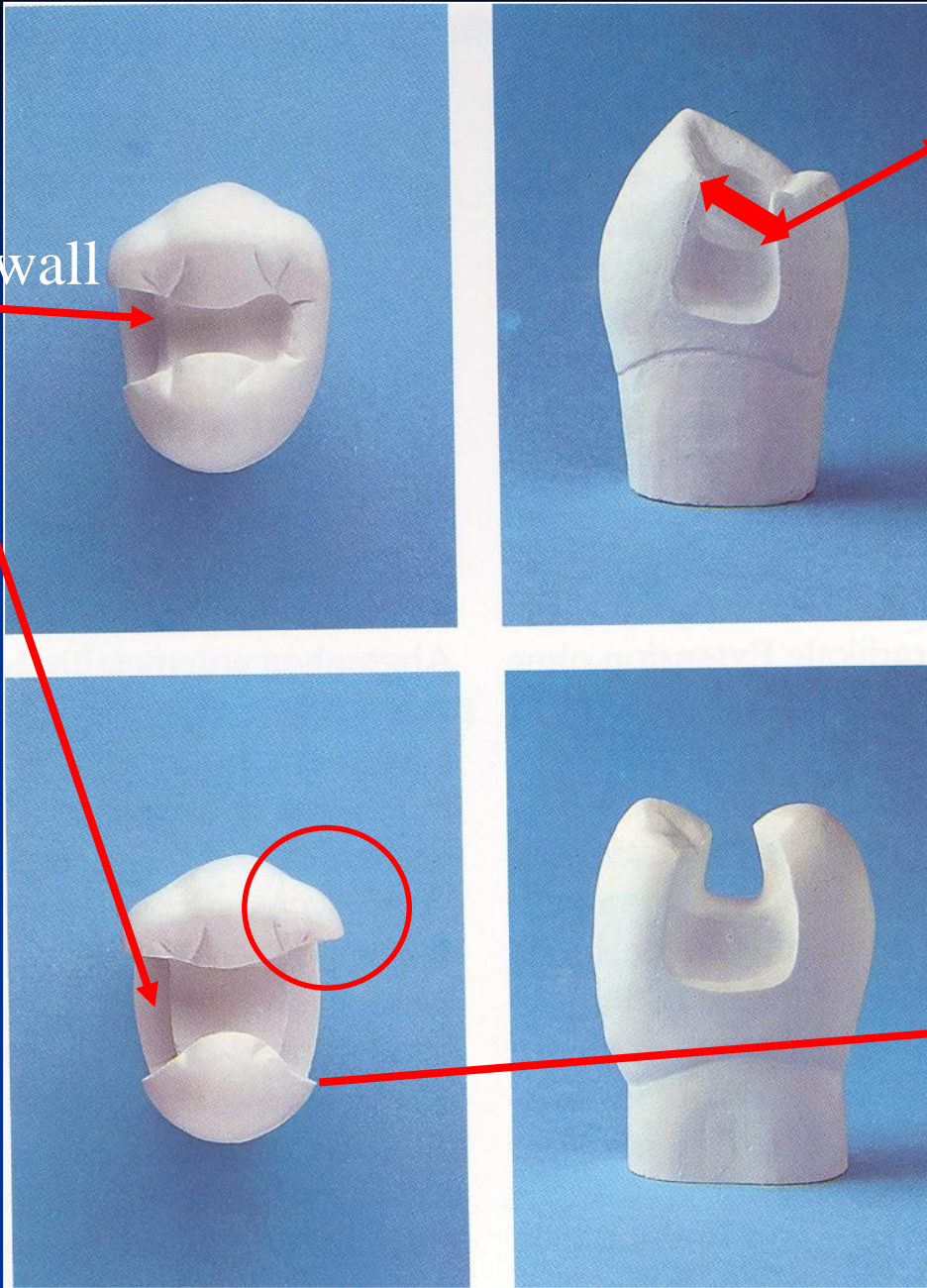
Grooves



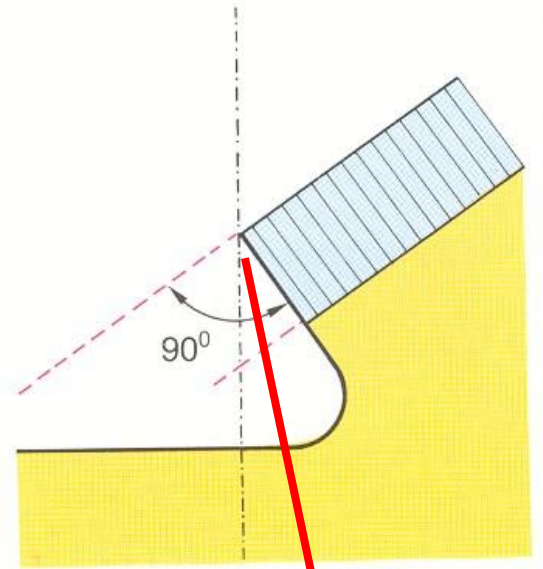
Resistance

- No undermined enamel
- No sharp edges
- Isthmus is $1/3 - 1/4$ intercuspidal distance
- Angle between axial and gingival wall: 90° , or 85°
- Width of gingival wall is 1 mm at least
- Thickness of the filling 2 – 4 mm (4mm if cusp replacing)

Gingival wall



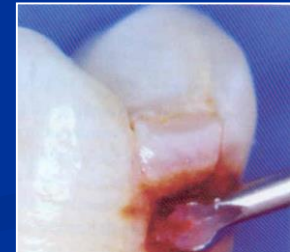
Isthmus



Cavosurface angle

Excavation of carious dentin

Rounded bur

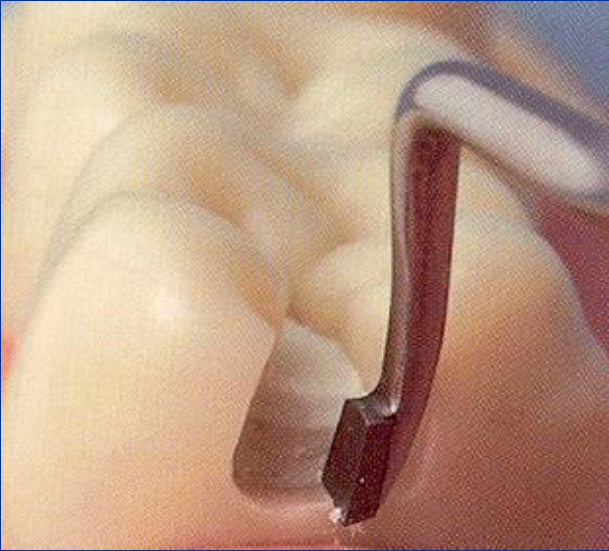
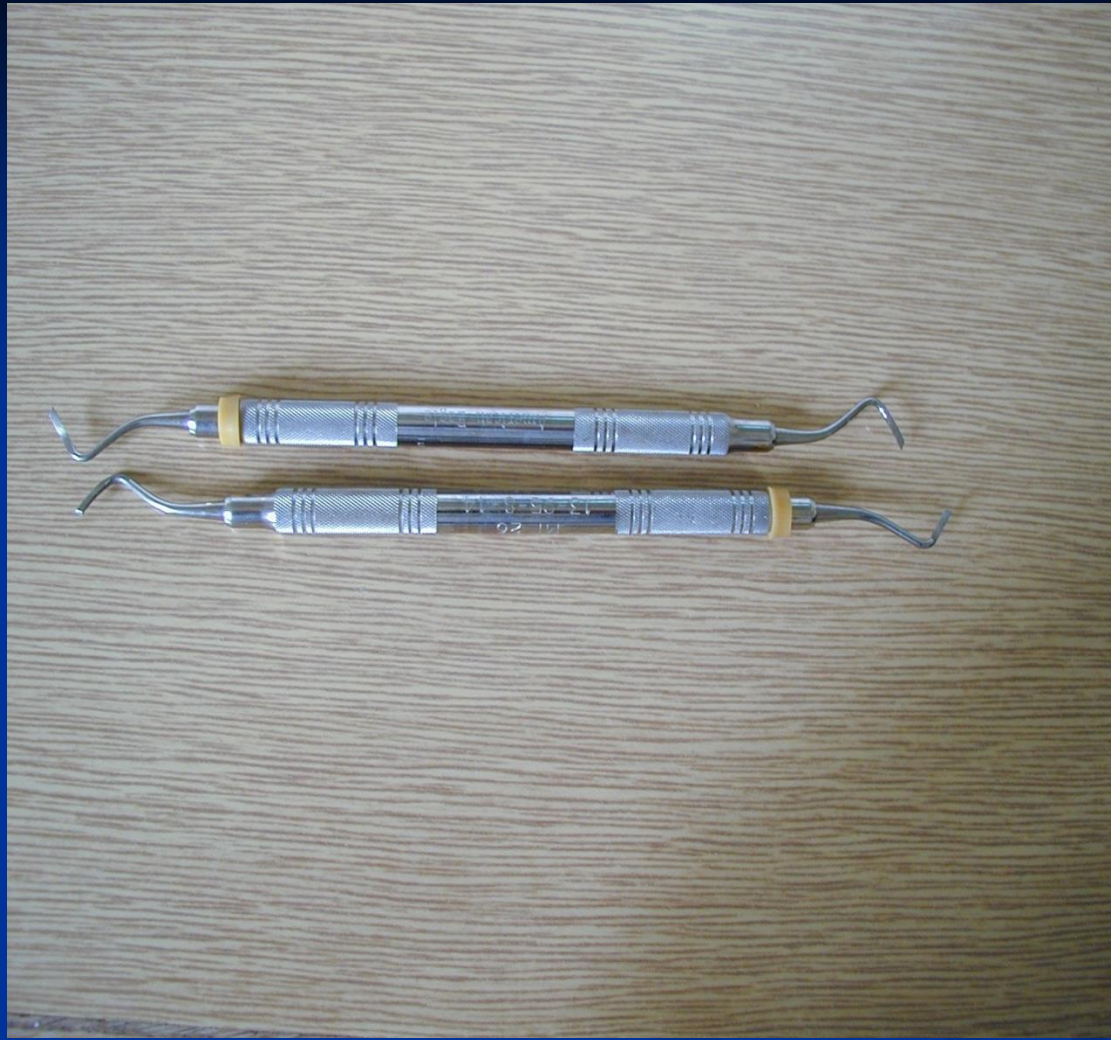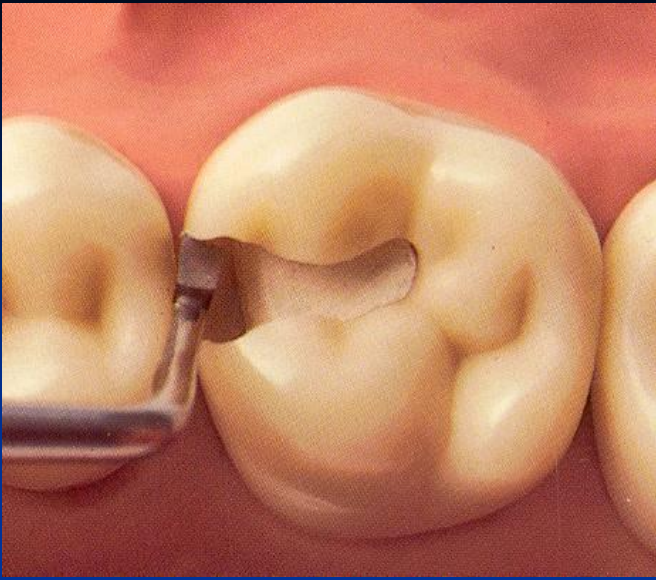


(Caries Detector, Kuraray, Japonsko; Caries Marker, VOCO, Německo)

Finishing of the walls of the cavity

- Red coded diamond bur
- Chisel on the gingival wall (if in enamel)



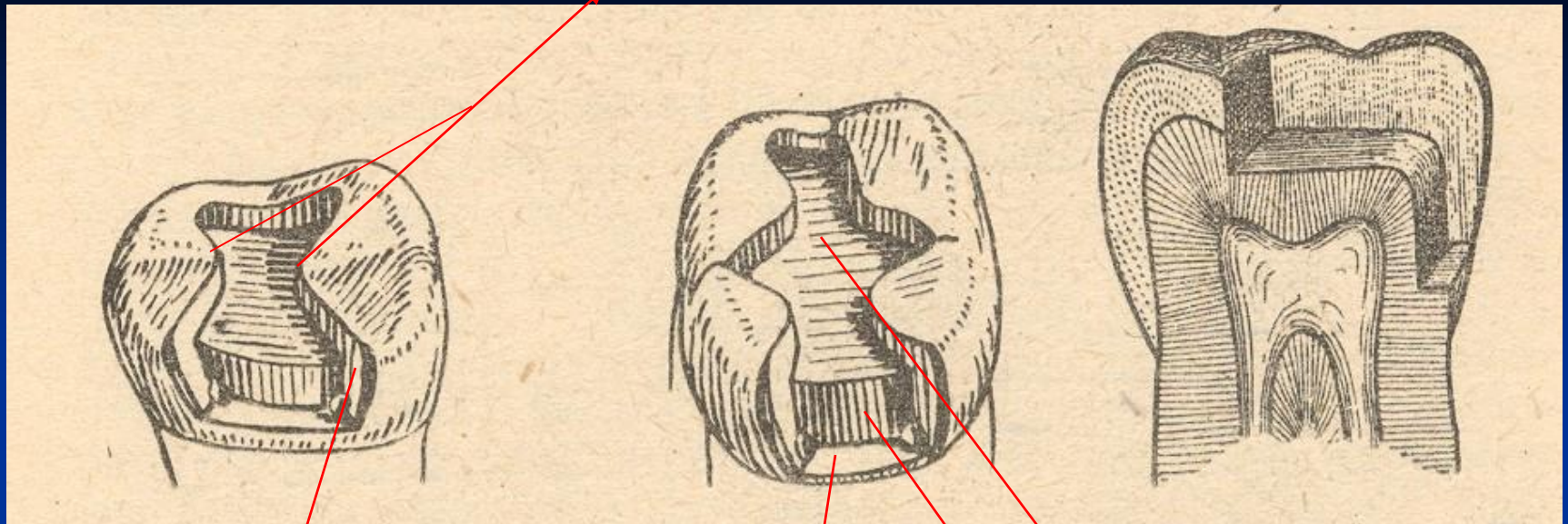




Final check

- Goog light, mirror

Isthmus



Axial wall

Pulpal wall

Gingival wall

Matrix placement

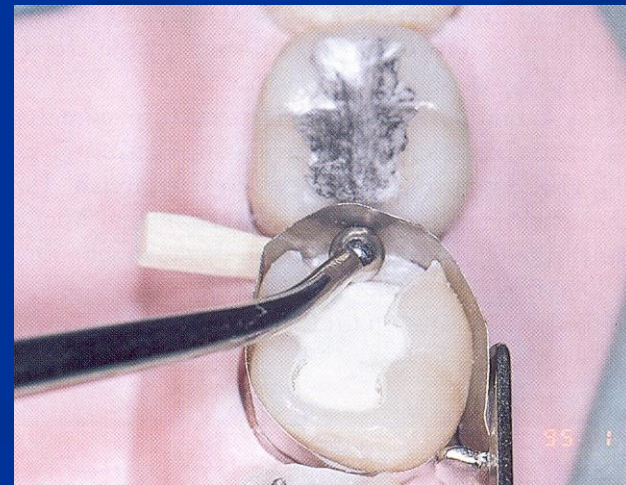
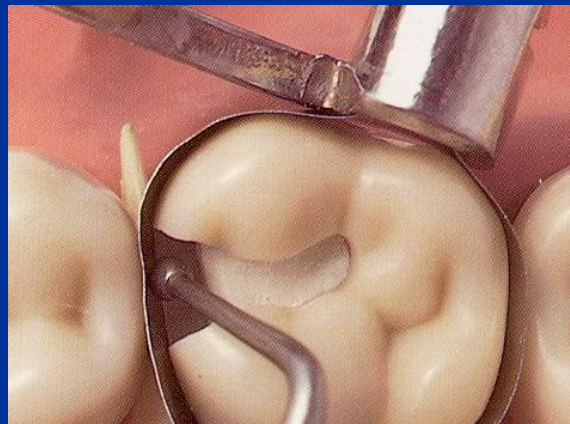
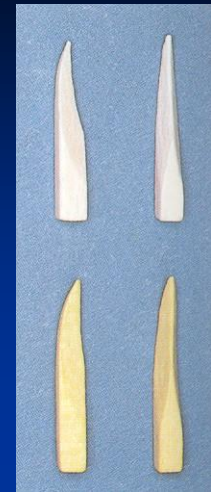- Matrix primarily is used when a proximal surface is to be restored

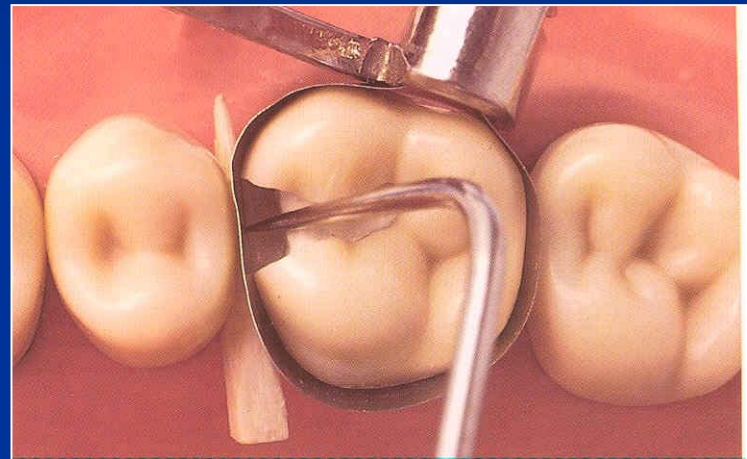
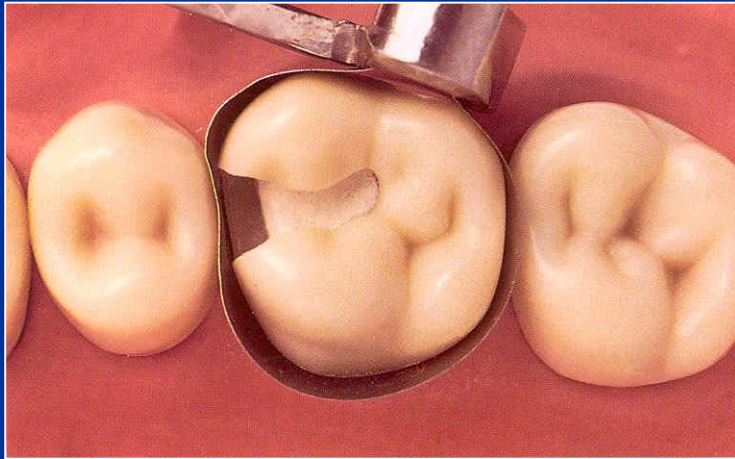

The objectives:

- Provide proper contact
- Provide proper contour
- Confine the restorative material
- Reduce the amount of excess material

Matrices

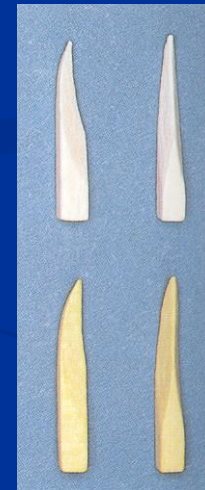
- Ivory I retainer Ivory 1
- Hawe Neos retainer Ivory 8
- Tofelmire matrix and retainer







Wedges

- Wooden wedges
 - tighten the matrix band
 - compress the gingiva
 - separate the teeth



Wedging

- Slip the matrix band over the tooth (apical to the gingiva margin – 0,5, - 1 mm)
- Tighten the matrix, check it with probe
- Place a wedge
- Turn the retainer $\frac{1}{4}$ counterclockwise
- Contour the band

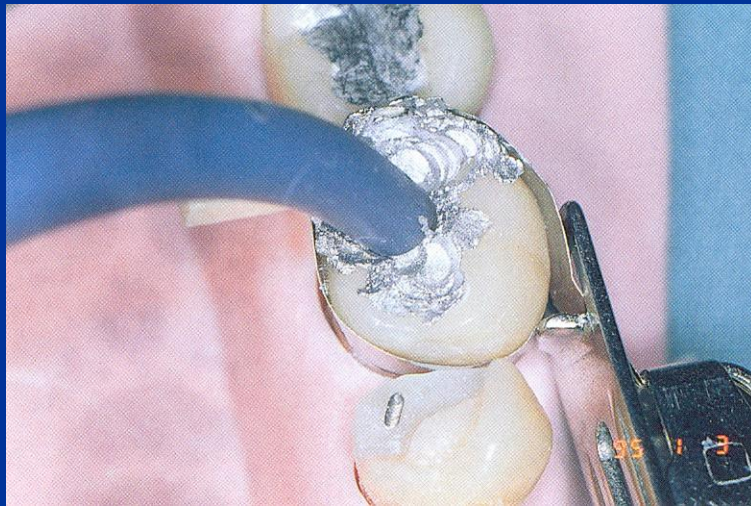
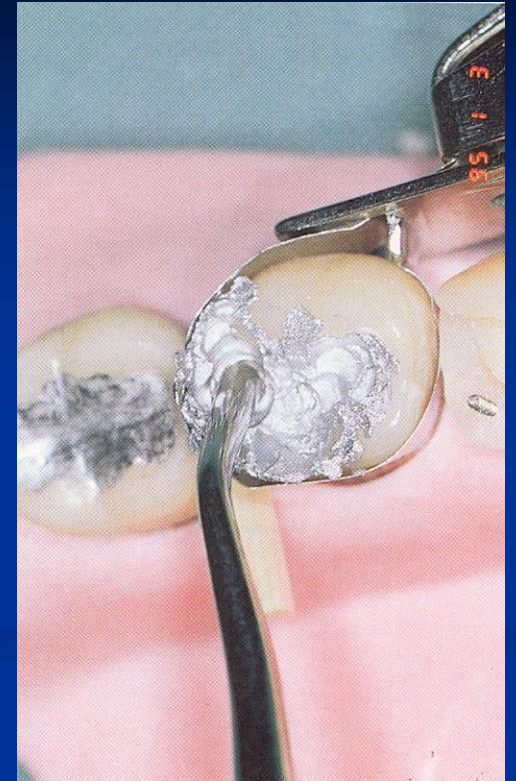


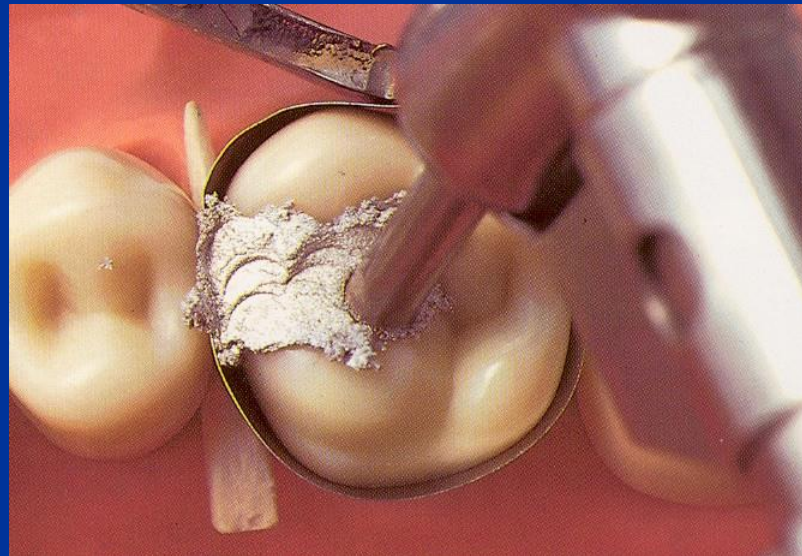
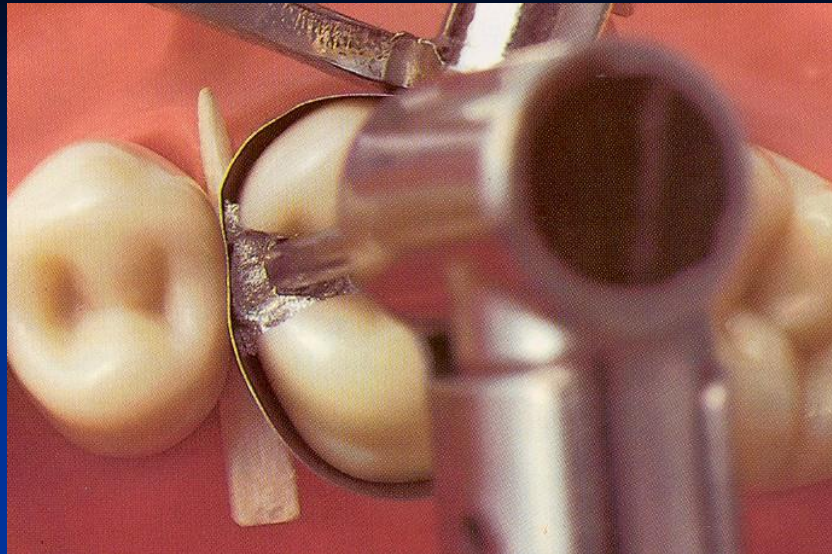
Amalgamators

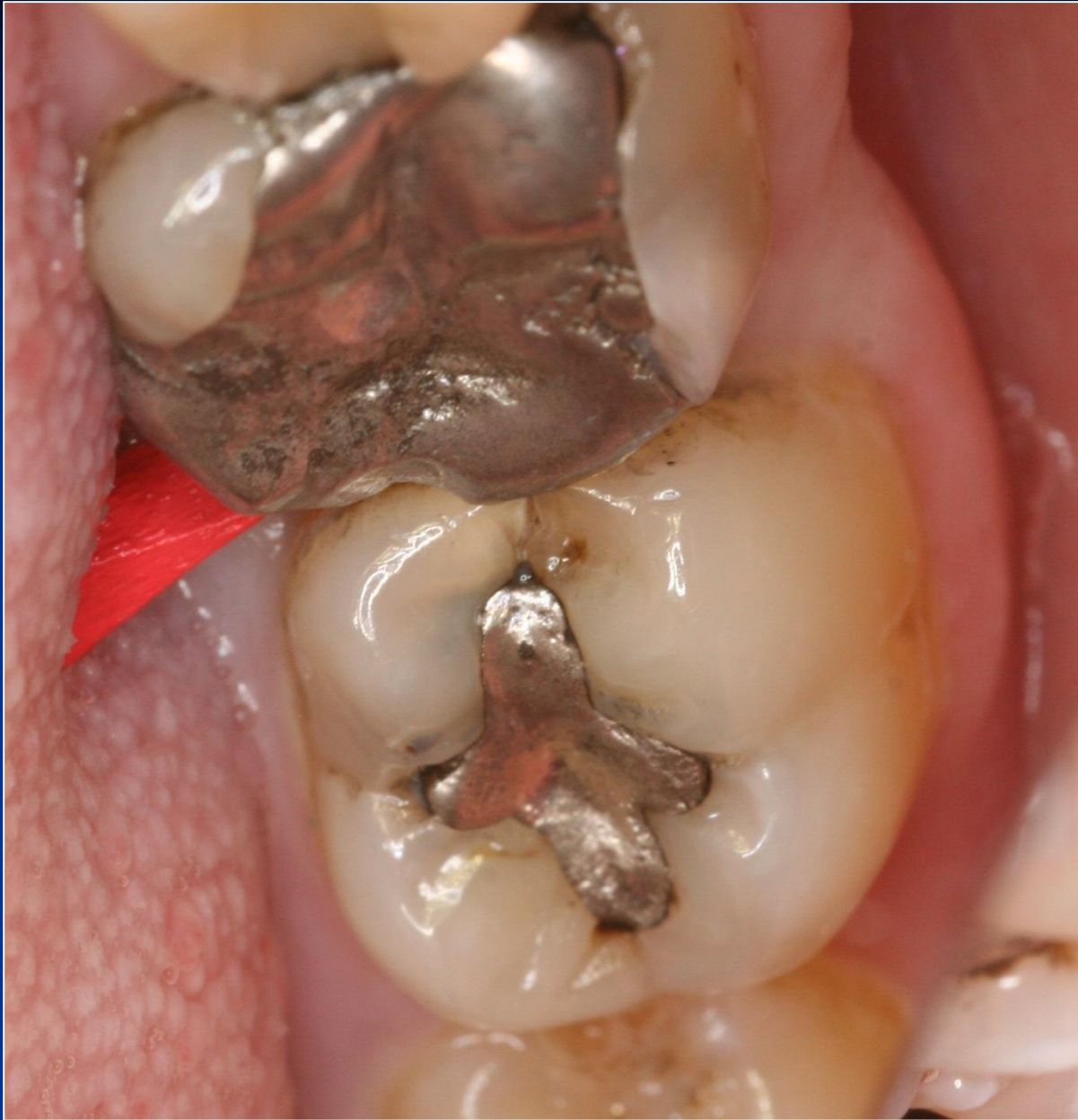Condensation of amalgam

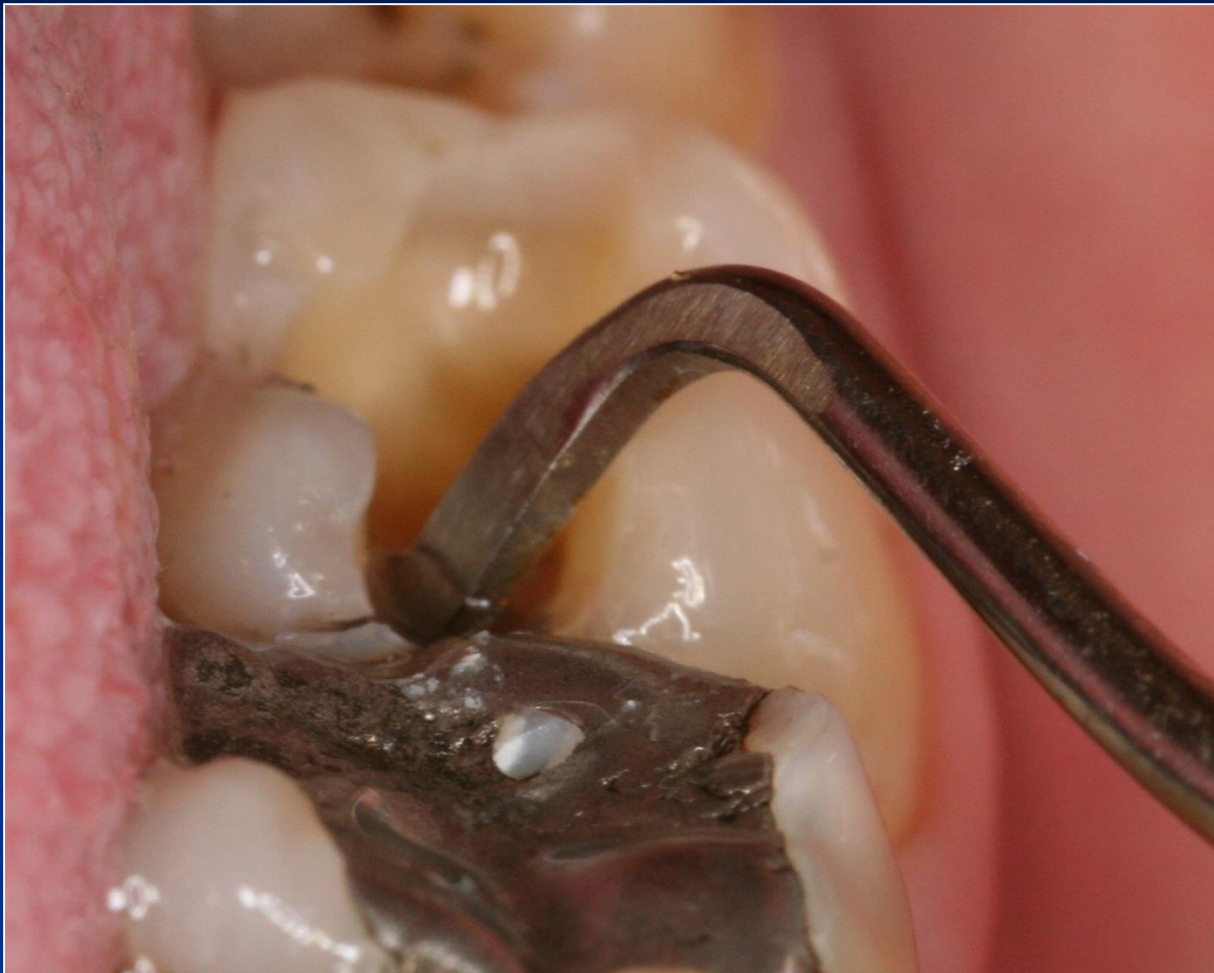- Condensor – with the straight front
- Power driven condensation

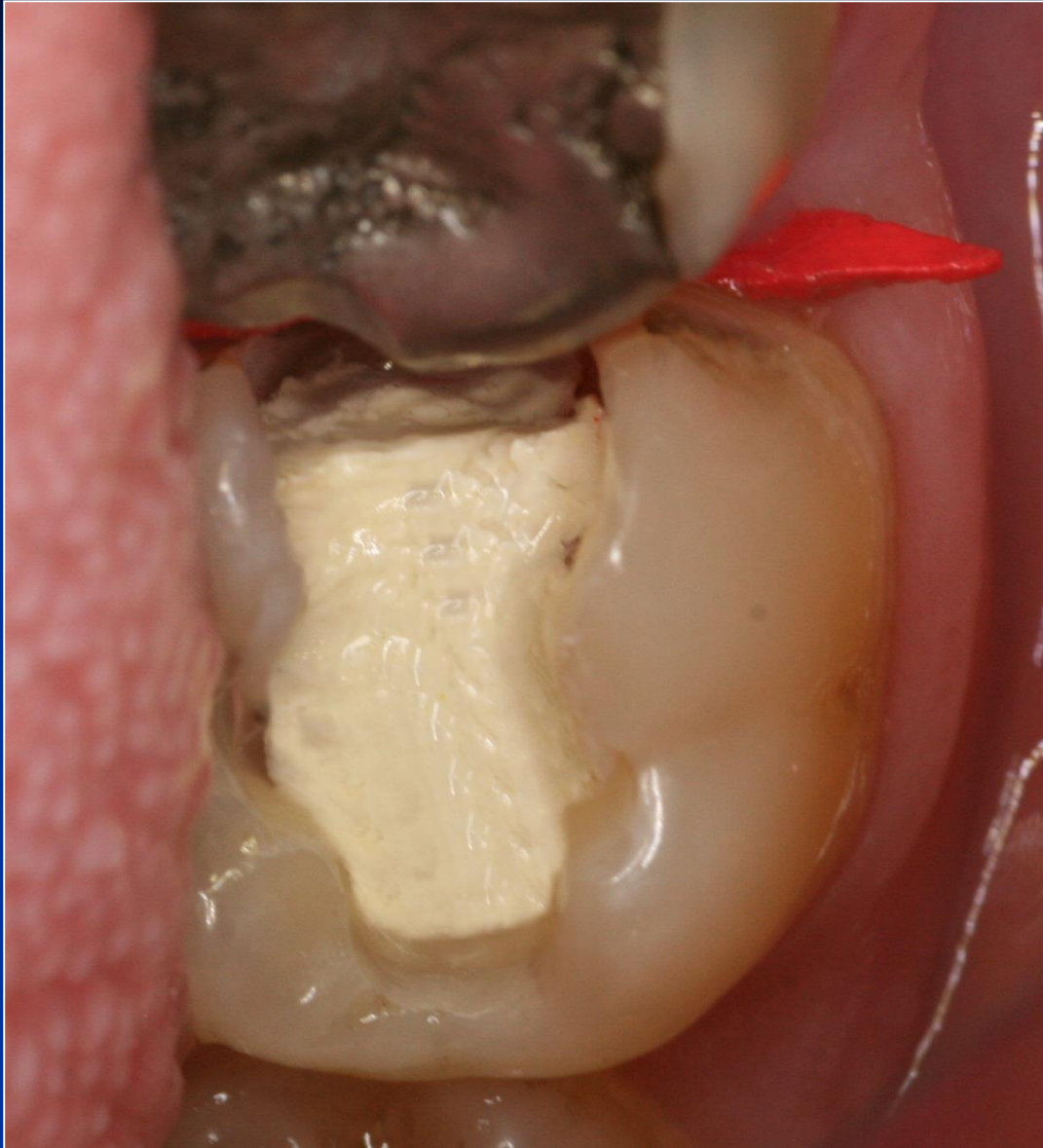How big should the front be?

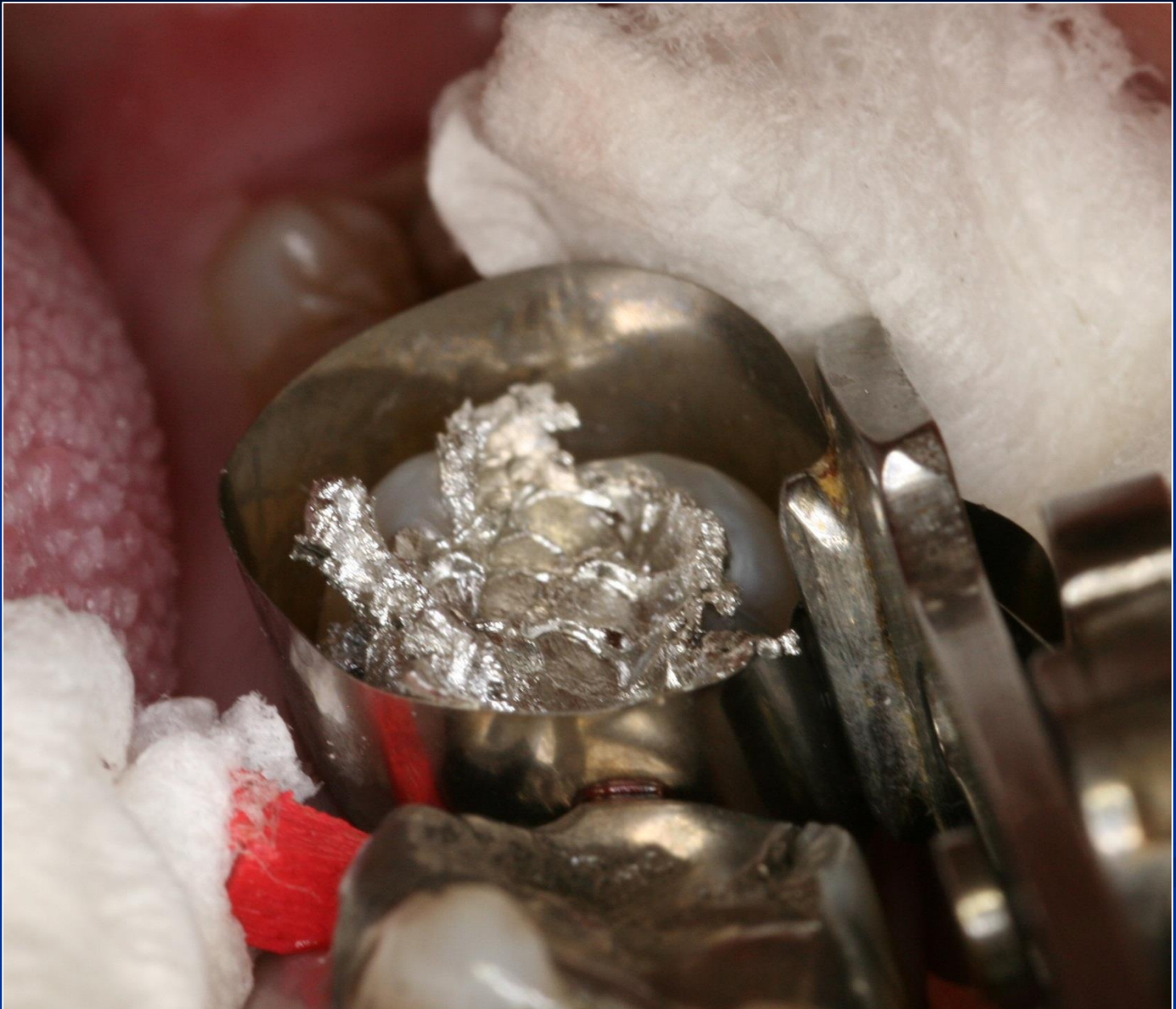


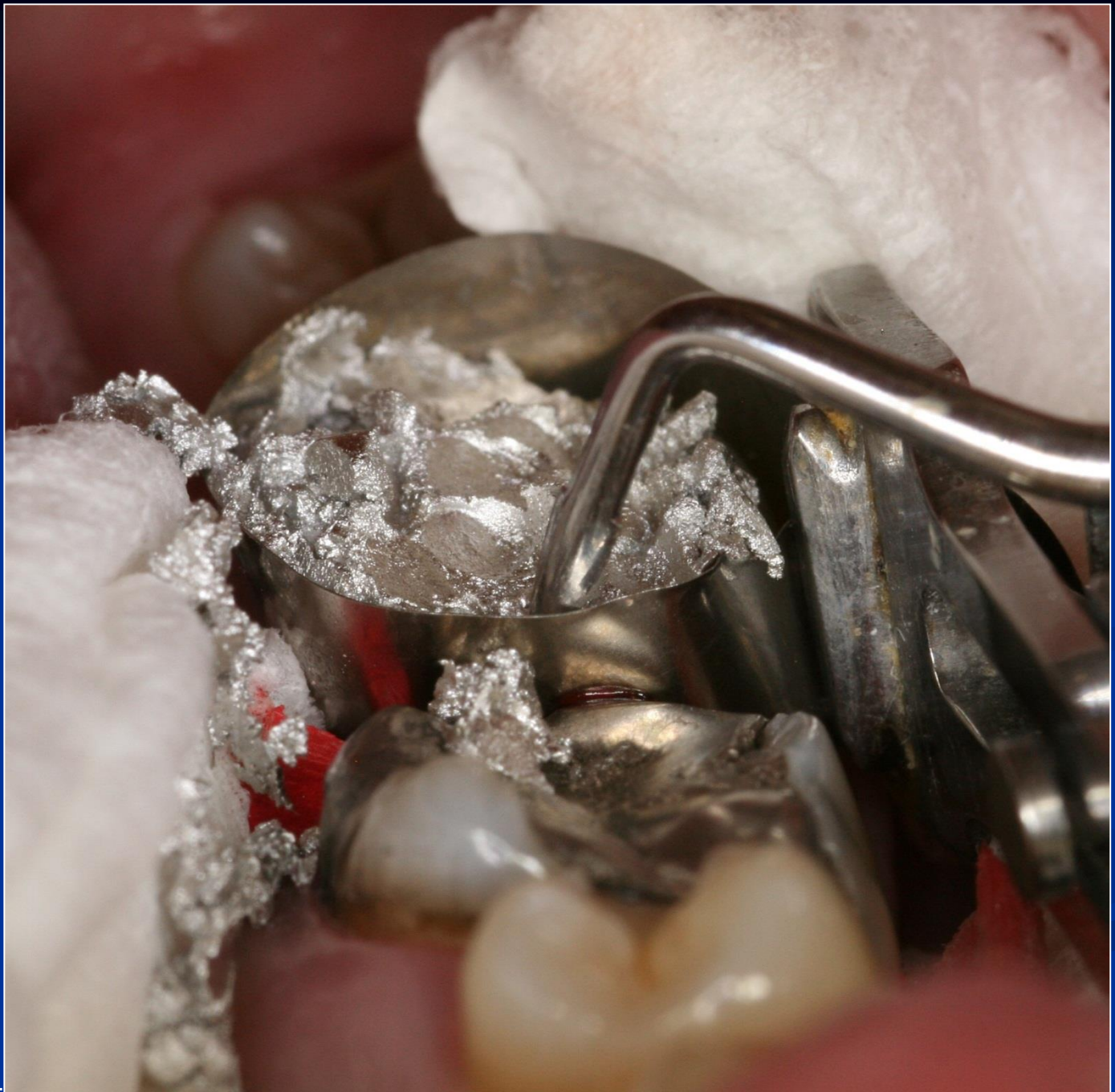


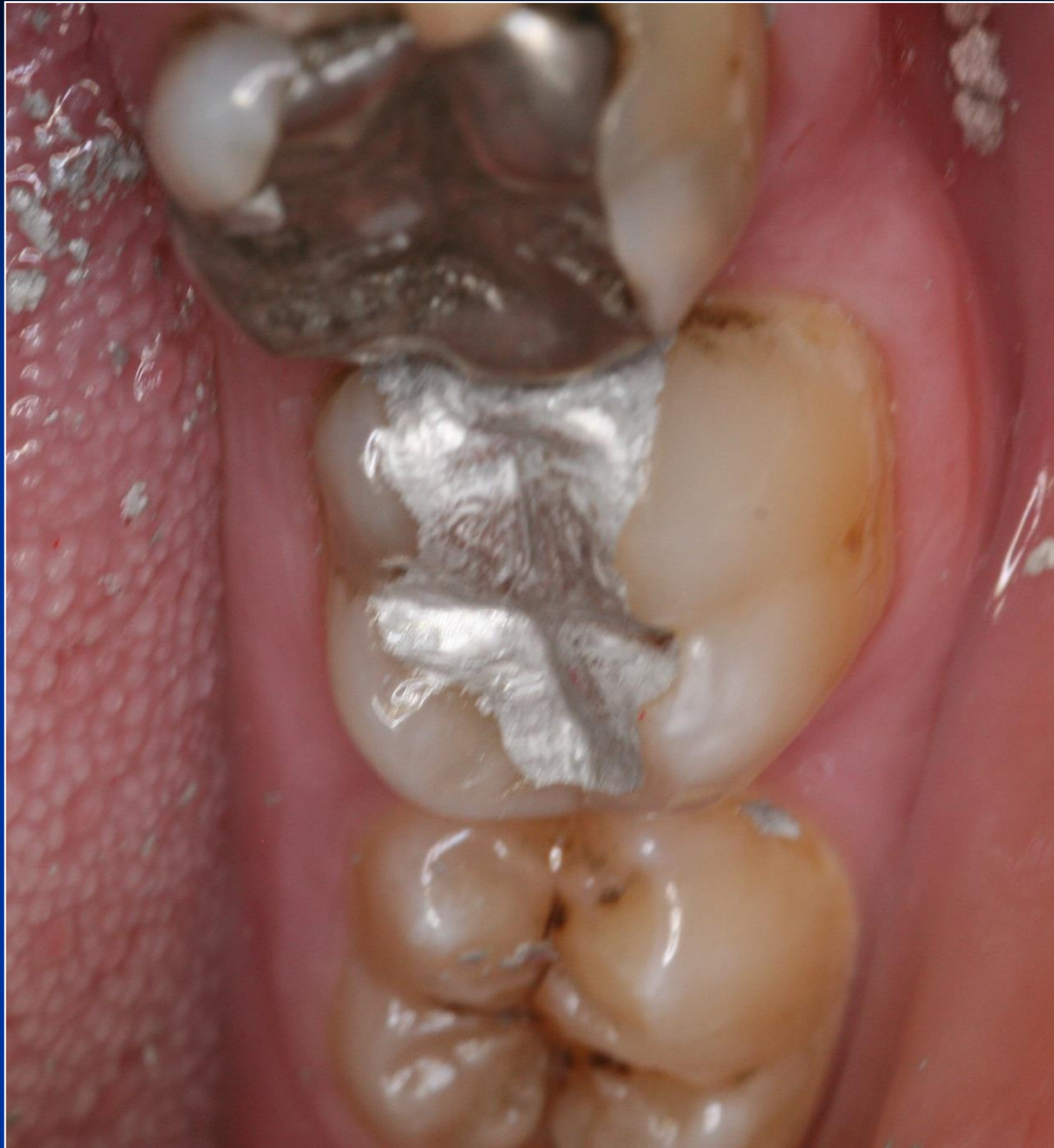





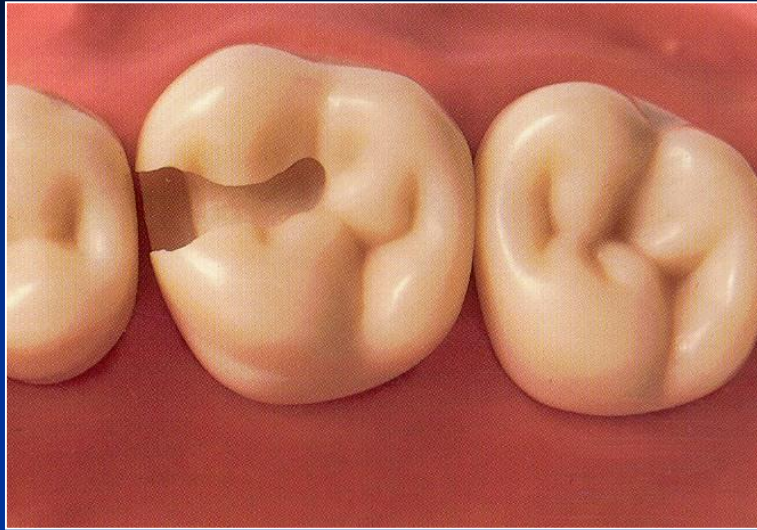




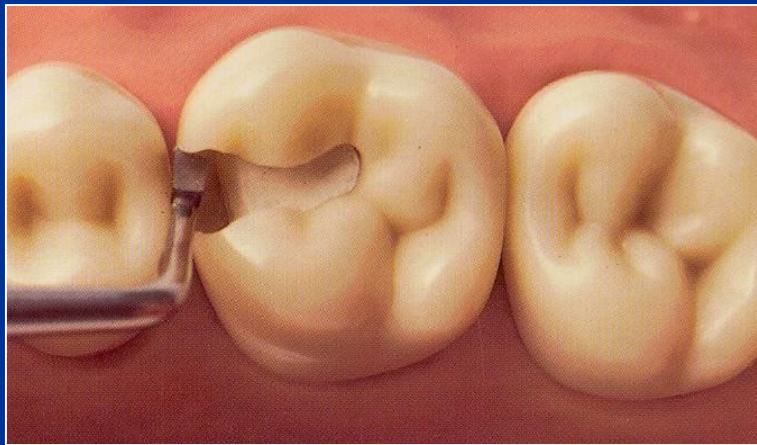
Base

- Zinkoxidphosphate cement
- Zinkoxidkarboxylate cement
- Glass ionomer cement
- Zinkoxideugenol

On pulpal walls only!




The base must be hardened



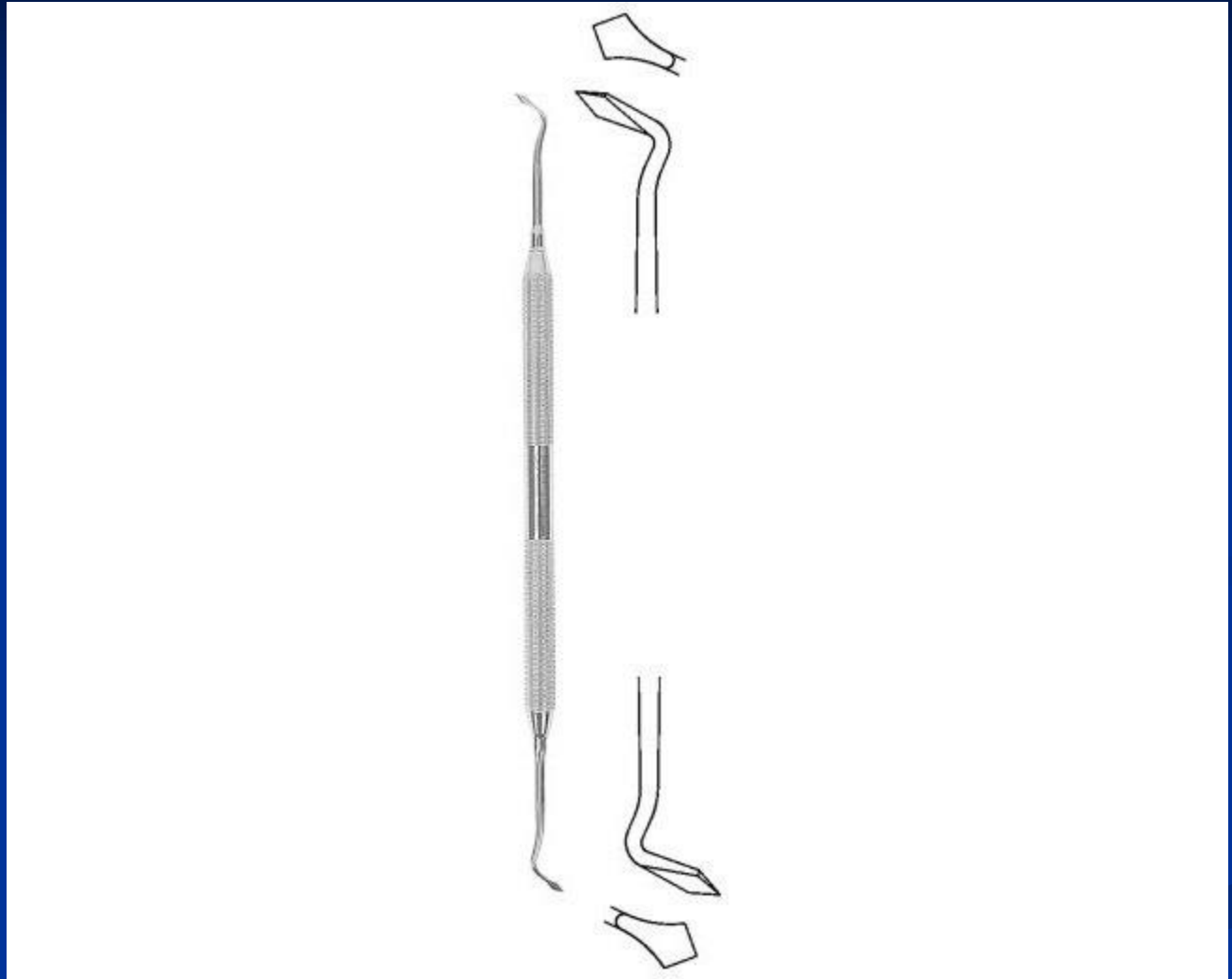
Instruments

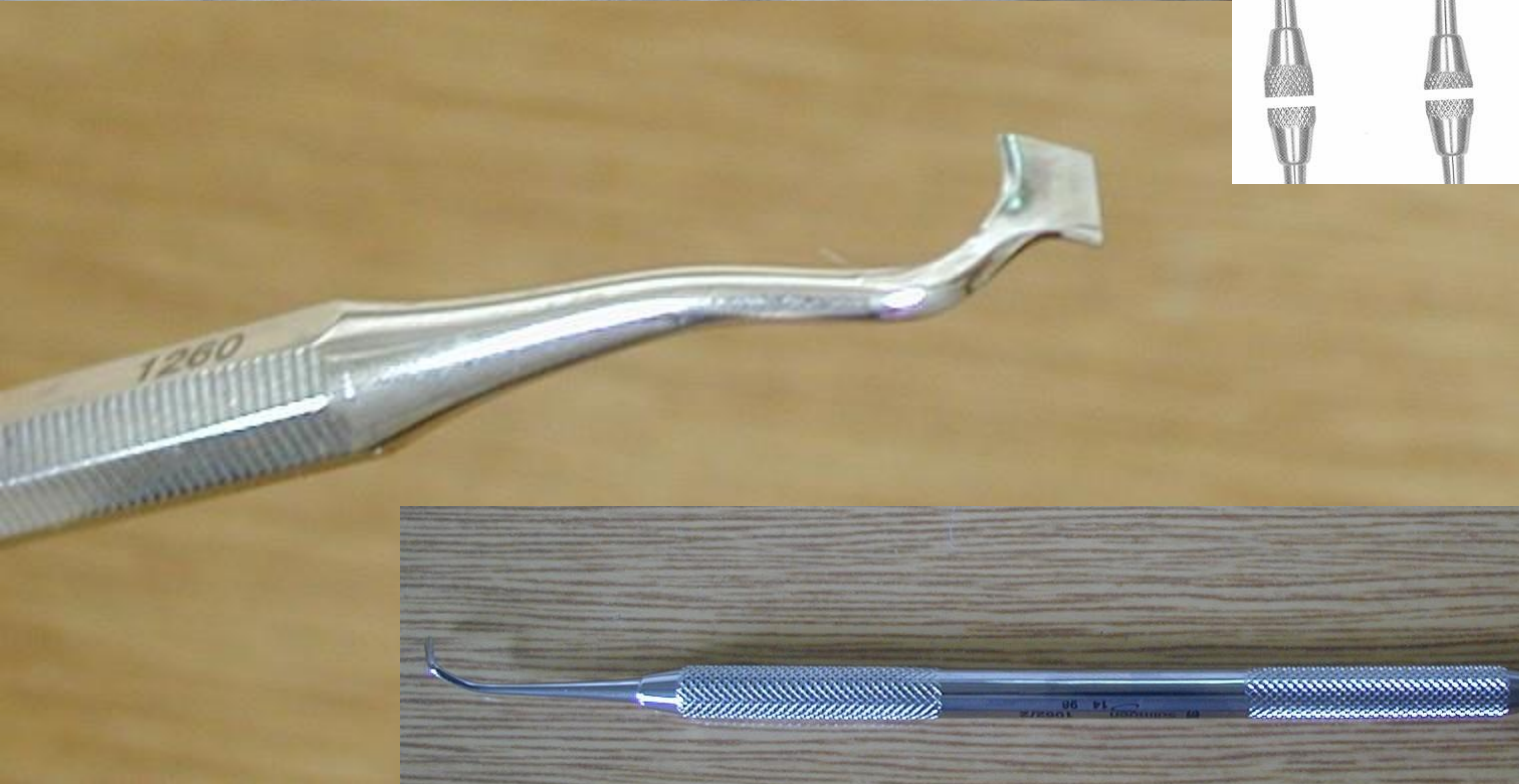
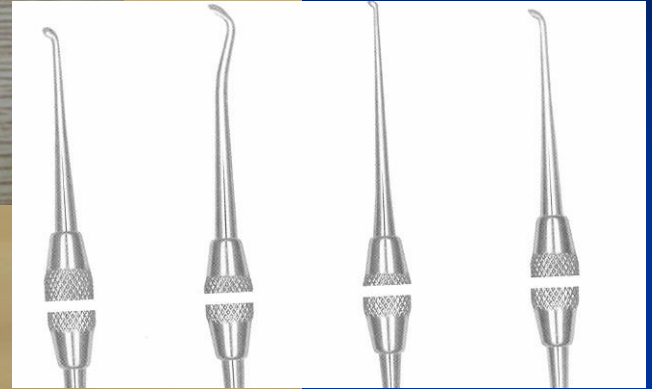
- Preparation
- Filling
- Finishing and polishing

Cpátko tyčinkové

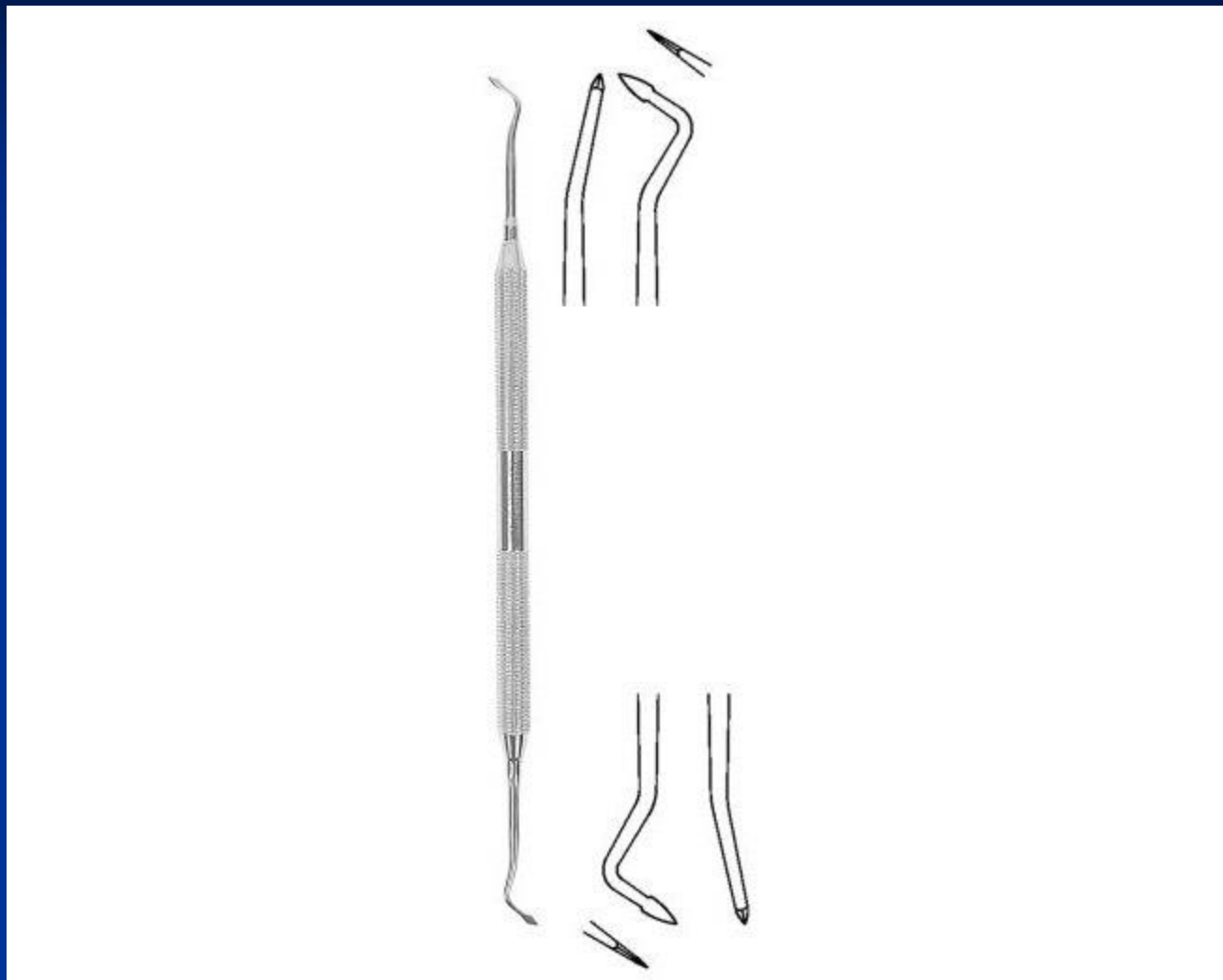

Ořezávač -Frahm






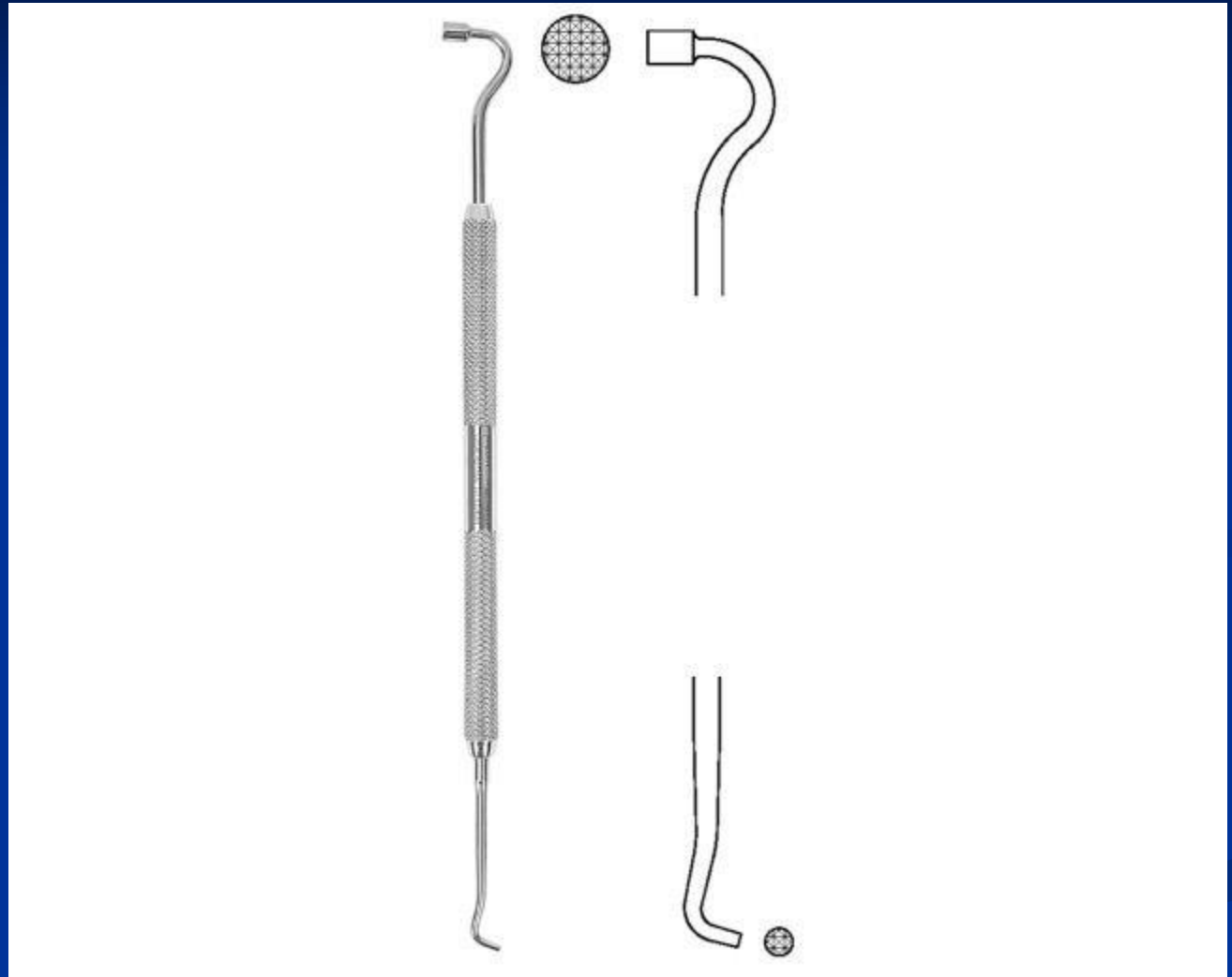
Sapin

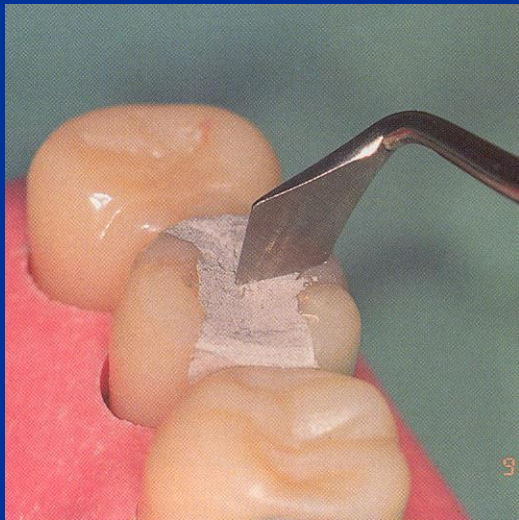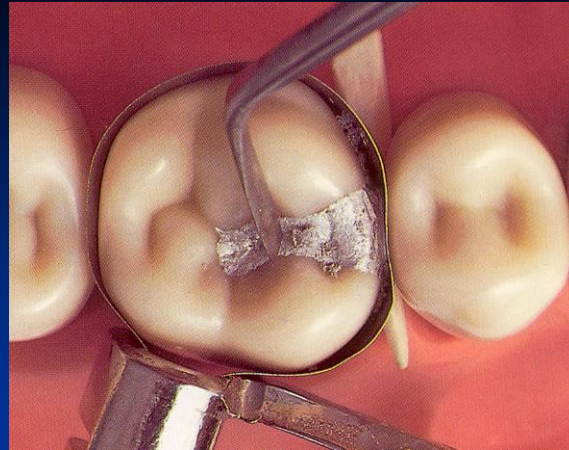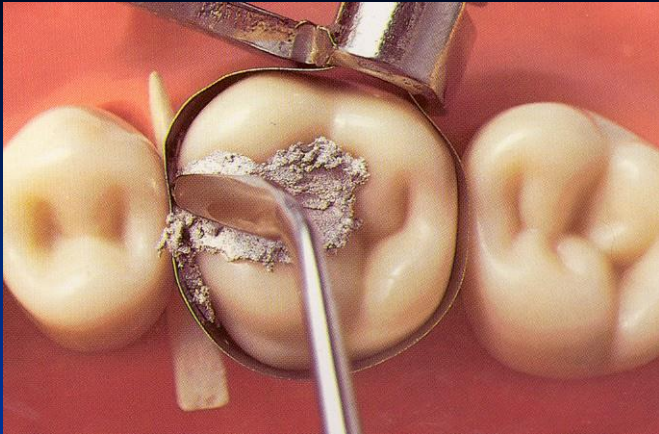


Discoid-cleoid



Amalgam carrier





Carving
Burnishing

