

Class II cavity

Location:

Proximal surfaces of premolars and molars

Materials:

Amalgam

Composite

Inlay

Indication for material selection

Amalgam: medium to large cavities.

Composite: small to medium cavities, excellent oral hygiene and the possibility of securing a completely dry working field required.

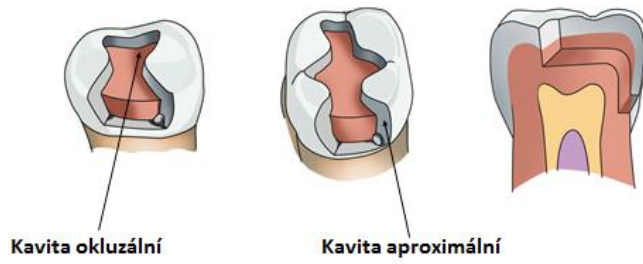
Inlay: large cavities, excellent oral hygiene required.

PREPARATION FOR AMALGAM

During the classic preparation, we create a composite cavity which has two parts – occlusal and proximal. One proximal surface (mesial or distal) may be affected. Then such cavity is called MO (mesio-occlusal), OD (occluso-distal), or DO (disto-occlusal). Both proximal surfaces may be affected in which case the cavity is called MOD (mesio-occluso-distal). The transition between the occlusal and proximal cavity is termed isthmus. This is the narrowest place of preparation and it is of fundamental significance for retention of the filling.

Fig. 1: Composite cavity, its parts and names of individual walls

Konvenční preparace podle Blacka = složená kavita



Kavita okluzální

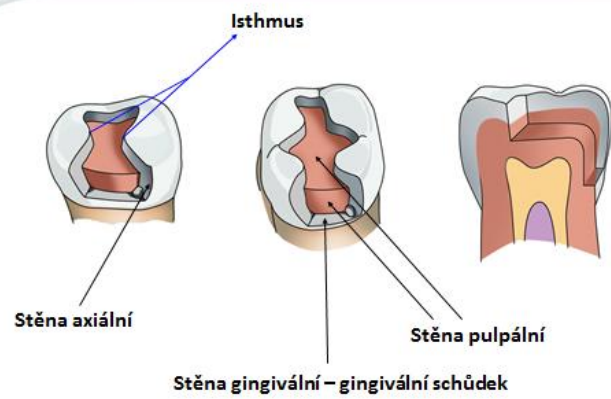
Kavita aproximální

troubel@med.muni.cz

1

Occlusal cavity

Proximal cavity



Stěna axiální

Stěna pulpální

Stěna gingivální – gingivální schůdek

troubel@med.muni.cz

2

X

Axial wall

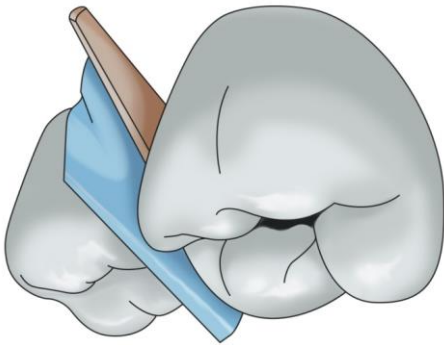
Gingival wall – gingival step

Pulpal wall

Access:

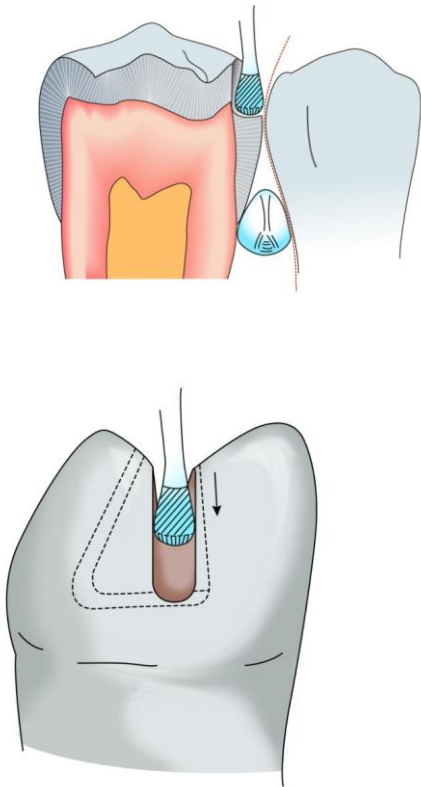
Before starting the preparation, the protection of the adjacent tooth is necessary - a metal band which is fixed with a wedge or clip (crocodile clip).

Fig. 2: Protection of the adjacent tooth with a band with a wedge



The carious lesion is usually hidden under the contact point, the access is from the occlusal surface with a fissure drill or with a diamond cylinder bur or pear-shaped bur of standard grit (blue code). We begin in the central fissure and guide the preparatory instrument in the direction towards the affected proximal surface. We penetrate the carious lesion. After that the cavity on the occlusal surface is prepared - according to the principles for Class I

Fig. 3 a, b: Initiation of the preparation



It is important to place correctly the axial walls and the gingival wall on the proximal surface. Fig. 4c and 5

The gingival wall (gingival step) is located 0.5 mm below the gingival border (standard – conventional preparation)

It is parallel to the cementoenamel junction.

To place the proximal walls correctly, it is important to consider that the filling must restore the contact point. The contact point must be made of the filling. The filling exceeds the contact area on the vestibular and oral part by approximately 0.5 mm. The so-called American rule may serve for a rough orientation. We lead tangents from the middle of the prepared tooth to the adjacent tooth, and the border of proximal cavity should be where these lines cross the outline of the prepared tooth. However, if we follow only this rule without a thorough evaluation of the contact point, we would open the cavity proximally too much. It is therefore better to examine the contact area of the

teeth. The contact point on the treated tooth is always made of filling, the axial wall and the external contour of the tooth are in 90° angle.

Fig. 4: Preparation of proximal cavity

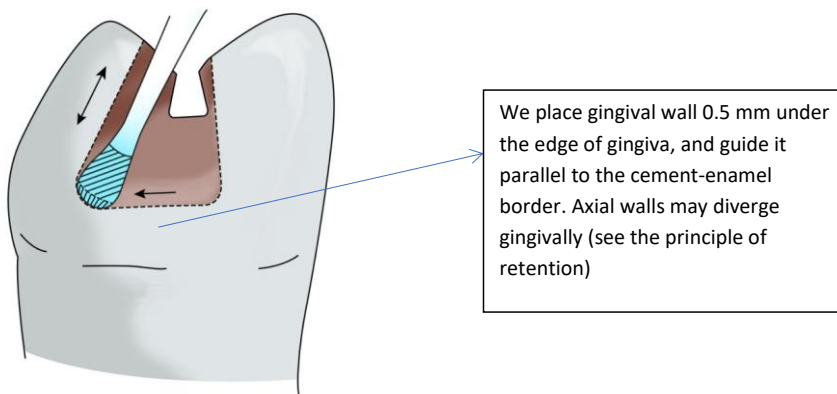


Fig. 5: View into the prepared cavity

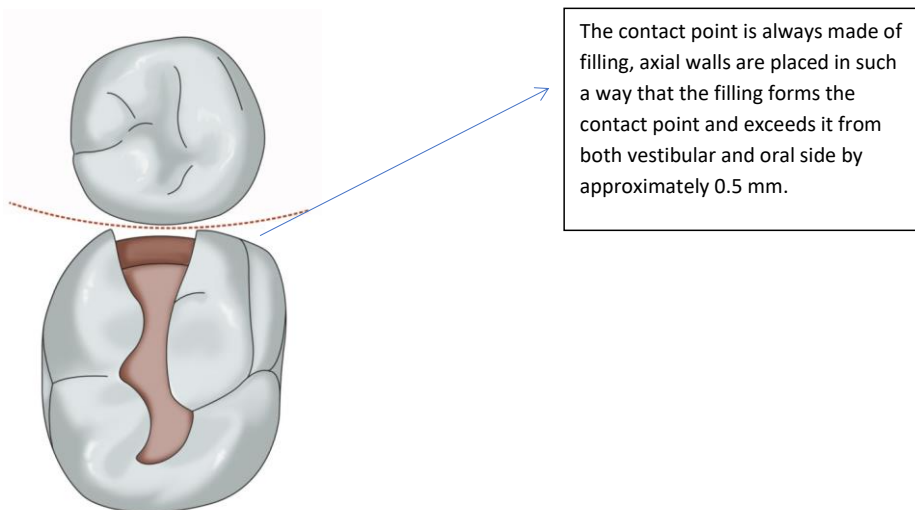
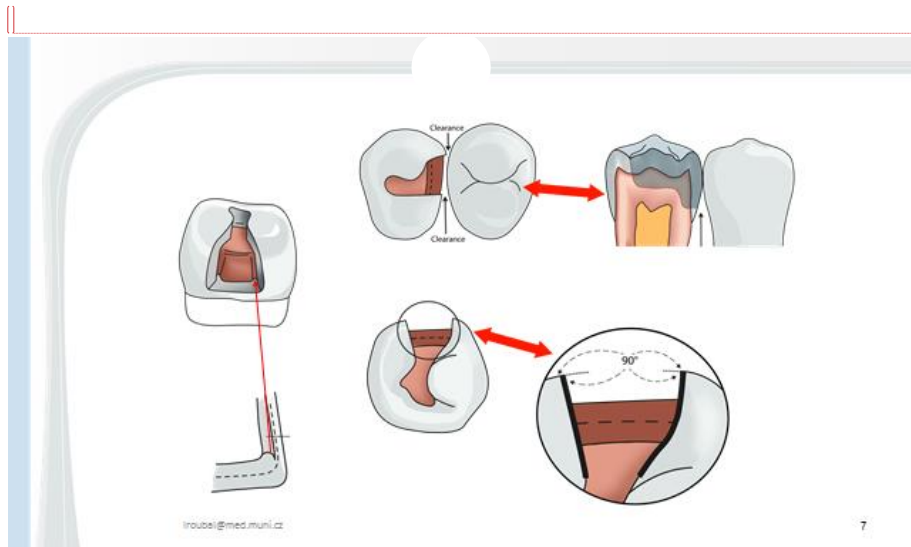


Fig. 6:



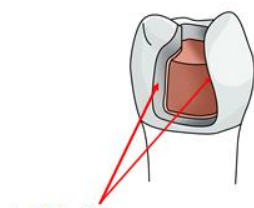
Okomentoval(a): [Z1]: Nepřekládám

The principle of retention

According to the classic rules, the preparation of a cavity on the occlusal surface is significant for retention. We also prepare undercuts in the cavity on the occlusal surface, the walls of the proximal cavity diverge gingivally. It is also possible to prepare longitudinal grooves in proximal walls and a transverse groove in the gingival step in the close proximity of pulpal wall.

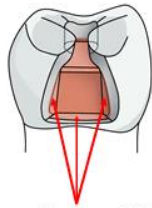
The width of isthmus is also important for retention – it is the narrowest place of the cavity, ca 1/4 to 1/3 of the distance between two dental tubercles.

Fig. 7: View of the proximal cavity - the axial walls are divergent towards gingiva



Axiální stěny
divergují gingiválně

troubel@med.muni.cz



Rýhy a zářezy vertikálně v axiálních stěnách
a horizontálně v gingiválním schůdku

8

Fig. 8a: Preparation of retention groove

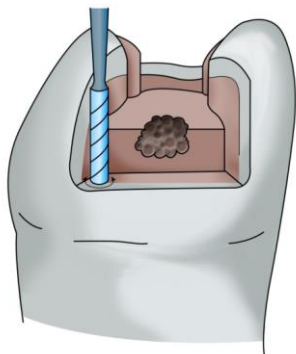
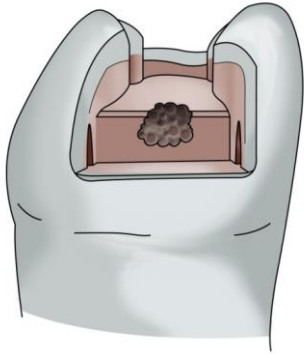


Fig. 8b: cavity with retention grooves in axial walls



The principle of resistance

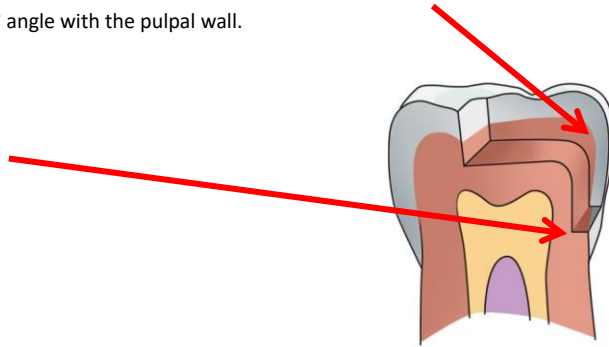
We never leave enamel unsupported by dentin at the edge of the cavity. All edges and transitions must be rounded. The commonest mistake is a sharp transition between both pulpal walls (the occlusal one and the proximal one). This leads to a fracture of the filling in isthmus.

In terms of resistance, the configuration of the gingival wall is also important. The gingival wall should be about 1 mm wide, which is important for supporting the filling. It is perpendicular to the proximal pulpal wall, or alternatively it slopes down to this wall (in this case there is about 85° angle). If the gingival wall slopes down in the opposite direction (i.e. the angle was more than 90°), the filling will be forced into the interdental space during chewing and it will break horizontally in the isthmus.

The isthmus must not be too narrow, because then there is a risk of fracture in this exposed area.

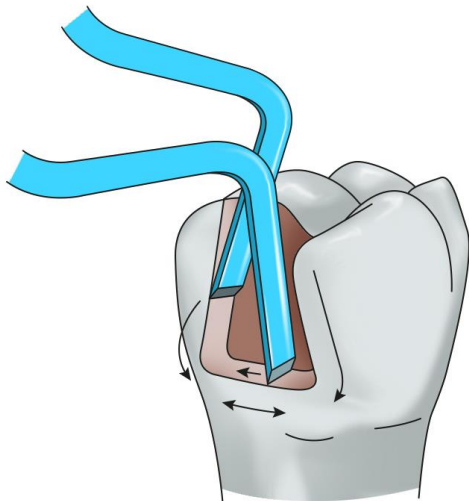
We also need to pay attention to the axial walls which must not diverge too much proximally, but they should form about 90° angle with the contour of the tooth (cavosurface angle). If this angle is greater, the filling forms thin projections which may break away. If the angle is smaller, there is a risk that a thin projection of axial wall breaks off. See Fig. 3

Fig. 9: The transition between pulpal walls in the occlusal and proximal cavity must be rounded. The gingival wall forms a 90° angle with the pulpal wall.



We finish the preparation by smoothing the cavity walls by a fine diamond bur (red code), the outer edge of the gingival step as well as the axial walls may be prepared by enamel chisels. The aim is to remove undermined enamel prisms.

Fig. 10: Treating cavity edges with chisels



Modification of Class II cavities

Slot cavity

We prepare slot cavities in small caries if the oral hygiene is good. In this case we do not prepare the cavity on the occlusal surface, the proximal cavity opens on the occlusal surface only as an aperture which does not extend beyond the marginal ridge.

Retention of the filling is provided by divergence of proximal walls in the direction towards the gingival ones, we also prepare retention grooves in axial walls as well as in the gingival step. Moreover, axial walls may first converge and then diverge in mesiodistal direction. Fig. 6: Preparation of slot requires small instruments and work with loupes.

Fig. 11a, b:

Slot preparation when viewed from proximal and occlusal side.

Fig. 7a:

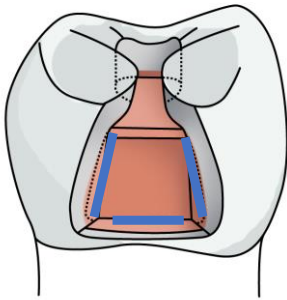


Fig. 7b:

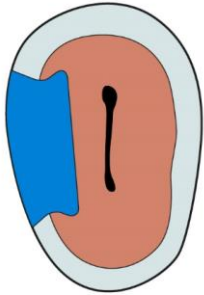
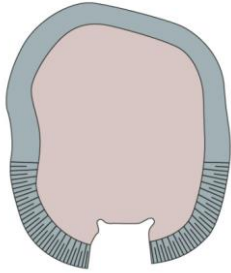


Fig. 7c:



Preparation with cusp ablation or alternatively with anchoring into the pulp chamber.

If the cusp is undermined with carries, it is possible to ablate it and replace it with filling. In place of the cusp the filling must be thicker (ca 3 – 4 mm). In terms of retention, auxiliary grooves, small cavities – pins (in which the condensed amalgam creates small pins) are of advantage, we can also prepare small apertures (slots).

Fig. 9a: A cavity with ablation of the cusp and retention grooves

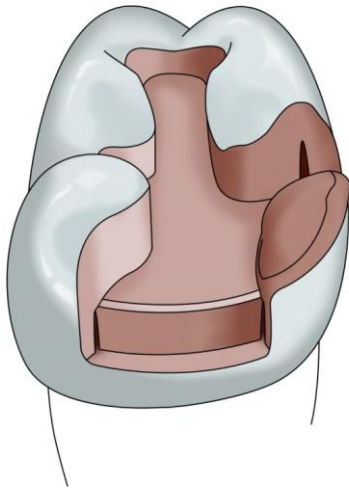
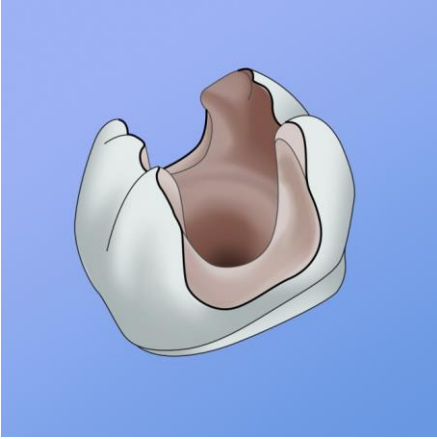


Fig. 9b: A defect after ablation of a cusp and finishing of the walls

In teeth without pulp (after an endodontic treatment) amalgam may be condensed into the pulp chamber. However, in this case amalgam partly or fully covers the occlusal surface (so-called amalgam overall), its thickness is 3–4 mm.

Fig. 10: Finishing with cusps replacement – anchoring into the pulp chamber.

Fig. 10b: Preparation with anchoring into the pulp chamber



Preparation for composite

Preparation for composite differs from preparation for amalgam as follows: we do not create undercuts and we bevel enamel in the proximal cavity. We bevel axial walls and also the outer edge of the gingival step if it is located in the enamel part of the tooth. If the gingival step is located elsewhere than in the enamel, we do not bevel it but only smoothen it. We do not bevel enamel in the occlusal cavity where we again only smoothen the walls. The smallest cavity for composite is adhesive slot – an aperture of a simple shape without undercuts, it opens in the direction of the occlusal surface without exceeding the marginal ridges.

Fig. 11 a: Proximal cavity prepared for composite, view from occlusal side

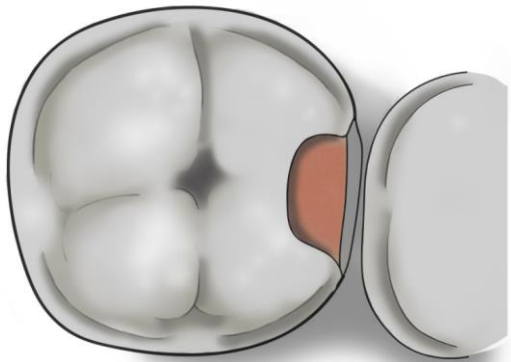


Fig. 11b: Proximal cavity prepared for composite, view from proximal side

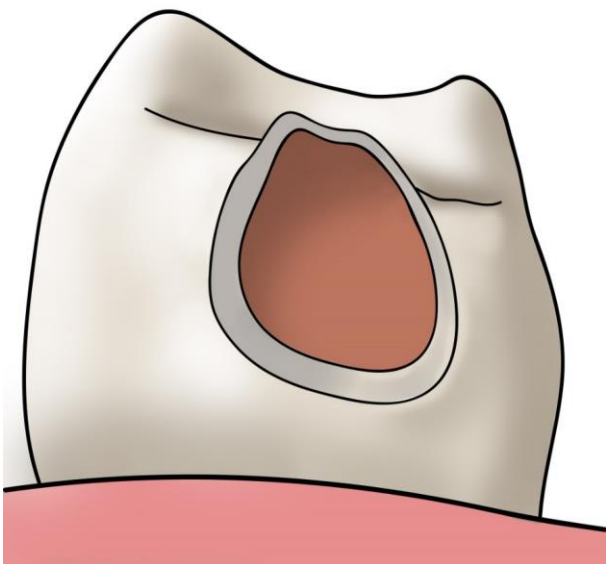


Fig. 11 c: Enamel bevelling on the external edge of gingival step

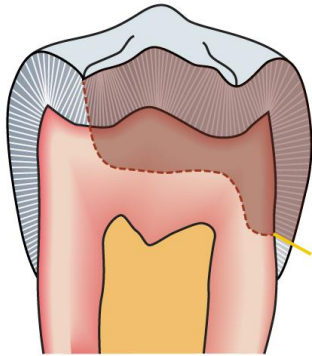


Fig. 11 d: Slot cavity for composite

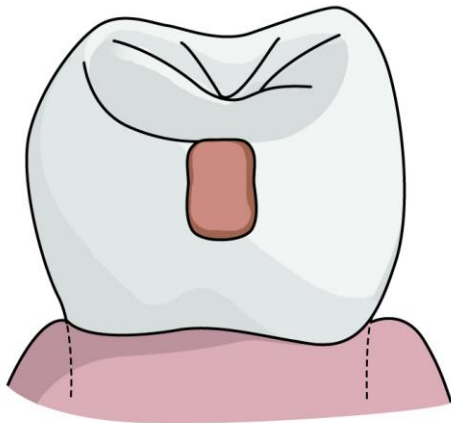
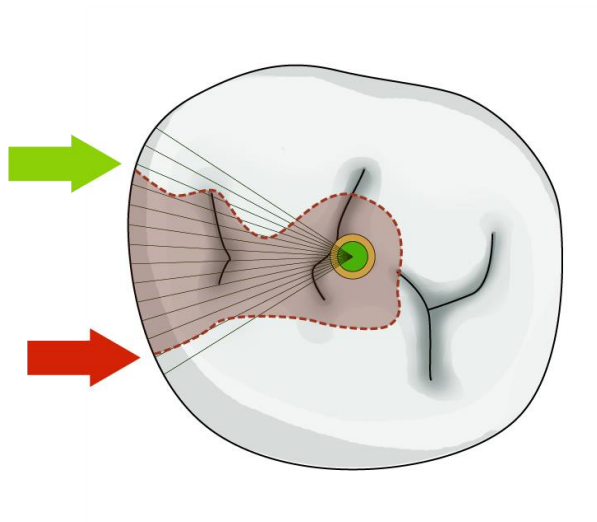


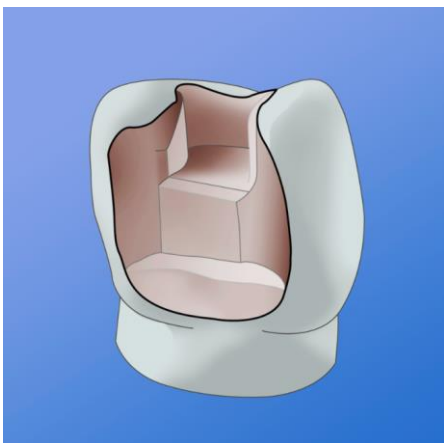
Fig. 11 d: Difference in preparation of axial walls – green for composite (bevelled), red for amalgam (no bevelling)



Preparation for inlay/onlay

The cavity has simple contours without undercuts, the walls diverge in occlusal direction.

Fig. 13: Cavity prepared for inlay



MAKING OF THE FILLING

Class II cavity is so-called outline cavity. The contours of the tooth are namely damaged, and therefore we must work with a matrix.

A matrix is a tool which helps to form the filling into the tooth contours, it enables condensation of the filling material and also undisturbed solidification of the filling.

Matrices may surround the whole tooth (circular) or they can complete the tooth's contour only on the proximal surface (sectional, or segmental matrix).

Circular matrices are tightened by retainers.

The most commonly used retainers and matrices are:

the retainer Ivory 8 in combination with matrices Hawe Neos or the retainer Tofelmire together with matrices Tofelmire or Hawe Neos. We seal the matrix with a wedge. The wedge is made of wood or plastic (less comfortable manipulation). Its task is to seal the matrix to prevent gingival overhang, and it also separates the teeth somewhat from each other, which contributes to formation of a tight contact point (the separation of teeth compensates the thickness of the matrix).

Fig. 14 a: A circular matrix with a wedge – scheme.

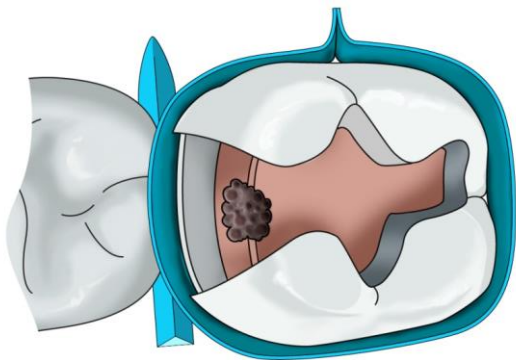
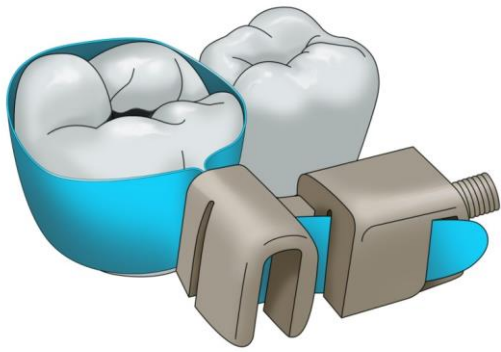


Fig. 14 b: The matrix is fastened in a retainer which is positioned vestibularly. Tofelmire retainer.



Matrices Hawe Neos are of various sizes and shapes – for cavities of types MO, OD, MOD, premolars, and molars. Their thickness is 0.03 or 0.05 mm. Some matrices are convex in order to form a better contact point.

Fig. 15 a: Various types of Hawe Neos matrices

Vhodné znovu vyfotit

Okomentoval(a): [Z2]: Nepřekládám






Fig. 15 b: Hawe Neos retainers – paired



Vhodné znovu vyfotit a vyfotit i univerzální napínač

Okomentoval(a): [Z3]: nepřekládám

Fig. 16: Tofelmire retainers and matrices



Ivory 8 retainers may be universal (they have a rectangular window) or paired (they have a trapezoid window).

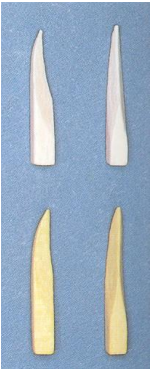The retainer is placed from the vestibular side of the treated tooth while the matrix surrounds the circumference of the tooth. In case we use a paired retainer, the narrower side of the window is positioned gingivally; the retainer therefore serves for the upper left and bottom right quadrant or for upper right and bottom left quadrant. The advantage of a paired retainer is somewhat better adaptation of the matrix.

In Tofelmire retainer, the position of the band may be changed, and the retainer is therefore suitable for the whole dental arch. It is again positioned vestibularly.

By tightening the screws of the retainer, the matrix band is sealed around the tooth.

A wedge must be used for a flawless adaptation of the matrix band. Wedges are usually made of wood, shaped according to the anatomy of the proximal area and are available in various sizes. It is necessary to choose the correct size of the wedge so that it seals the matrix but does not prevent forming the contours of the filling. The wedge also separates slightly the teeth which contributes to a better formation of contact point (after removing the wedge, this slight distance between the teeth disappears and contact point is renewed, the thickness of matrix is also compensated in this way).

Fig. 17: Various wedges



After tightening the matrix, we can form the contours proximally e.g. with a plugger

Fig. 18 a: The matrix after tightening is drawn into the cavity slightly

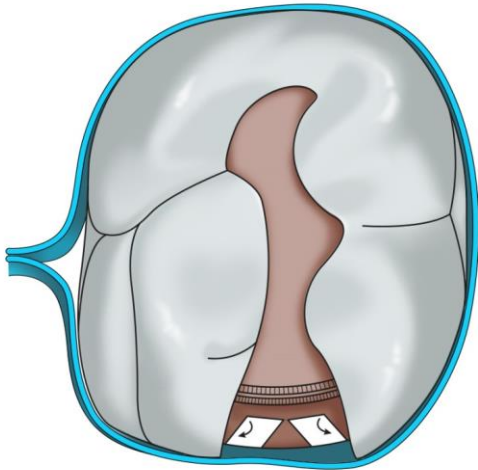
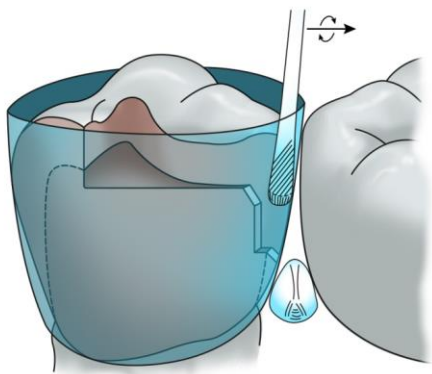


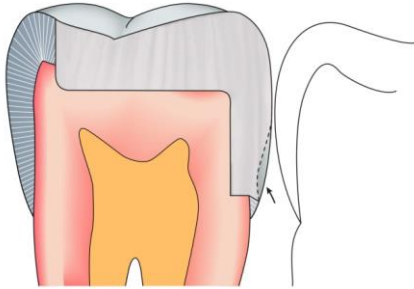
Fig. 18 b: After inserting the wedge, we loosen the retainer slightly and form the contour of the matrix by a ball plugger (?)



Okomentoval(a): [Z4]: otazník, který byl v původním textu, ponechávám

Fig. 18 e:

The consequence of an unsuitable (too big) wedge



MAKING THE FILLING

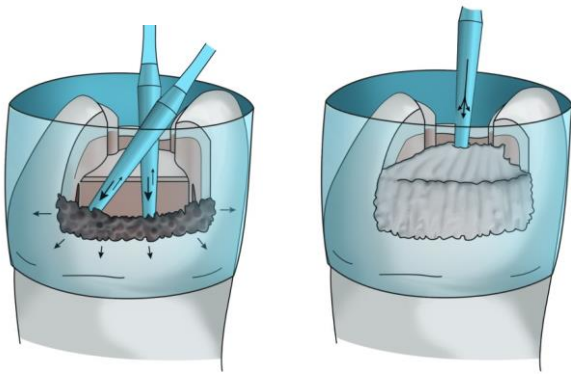
AMALGAM

After completing the preparation, we choose a suitable matrix and a retainer, place the matrix into the retainer, fasten the matrix there and apply it onto the tooth. We tighten the retainer and insert a suitable wedge. We loosen the screw of the retainer very little (about 1/4 of a revolution) and check the contact point, it is possible to shape contour in the matrix by a ball plugger so that the contact point is as natural as possible. Then we can proceed with depositing amalgam in portions (with an amalgam gun or carrier), and condense it as long as the cavity is filled with a slight excess.

Fig. 18 a, b, c

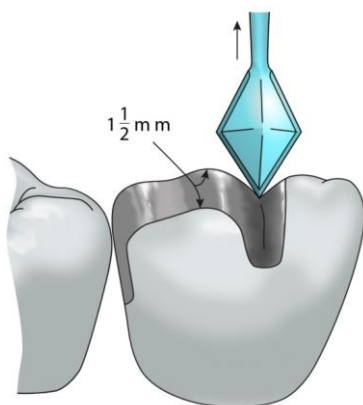
Fig. 19 a, b: A thorough condensation of amalgam in proximal cavity.

First we condense amalgam transversally into the edges of the cavity vestibular and orally, then perpendicularly to the gingival step.



Before taking off the matrix, we remove any excessive amalgam around the matrix (with an explorer or carver) and also excess of amalgam on the occlusal surface may be removed in this phase. As soon as amalgam may be carved, we start doing that even when the matrix is still in place. Then we carefully remove the retainer, and wedge, and as the last we take off the matrix band – we remove the band carefully from the proximal space with a slight pressure towards the adjacent tooth. We finish carving the filling while paying attention to forming the marginal ridges and cusps.

Fig. 20 a: The principle of carving – carver Frahm



Okomentoval(a): [Z5]: Chybí zde „stromečkovými“, nevěděla jsem, jak to přeložit. „opatrně ji „stromečkovými“ pohyby vyjmeme“

Fig. 20 b: The principle of carving – carver Discoid-Cleoid

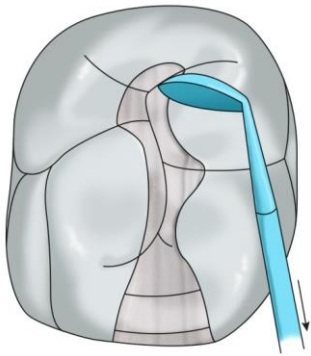
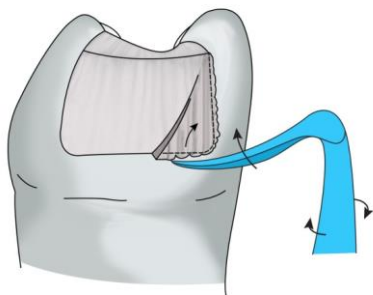


Fig. 20 c, d: Removal of excess amalgam proximally – Carver Wiland



We articulate the filling very precisely – we ask the patient to bite gently, in the place of higher filling a shiny little area forms. In the end we bevel the filling, in the occlusal cavity we move from the middle of the filling to its edges and in the proximal part from the edges to the middle of the filling.

We polish the filling during the next appointment with rotary instruments (finishing and polishing instruments). Finishing instruments (shallow grooves between blades) remove any unevenness, polishing instruments (without blades) hammer out the filling slightly. In the occlusal part of the cavity we polish from the middle to the edges, and in the proximal part from the edge to the middle.

Fig. 21 a: The direction of guiding the polishing instrument

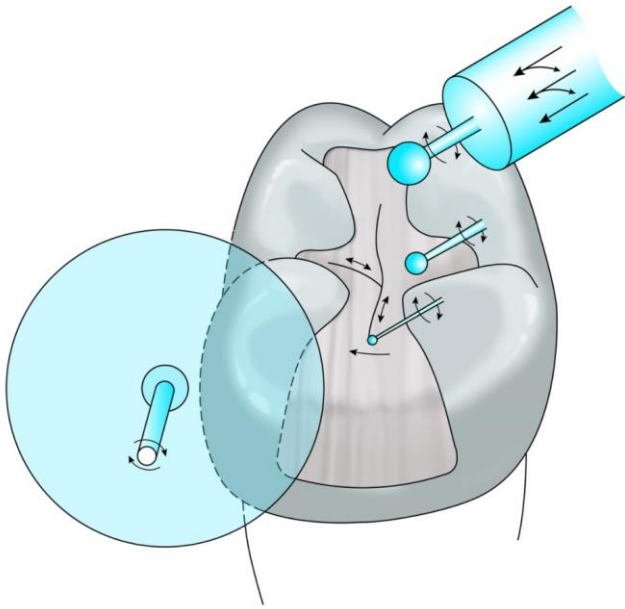


Fig. 21b: Polishing with rubber cups

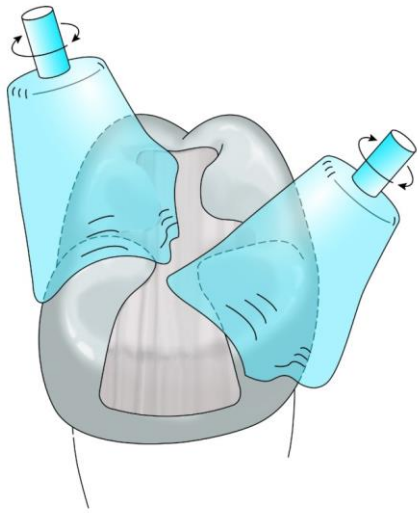
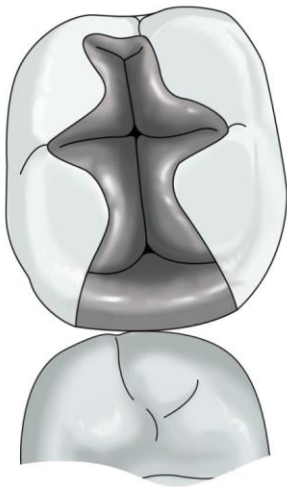
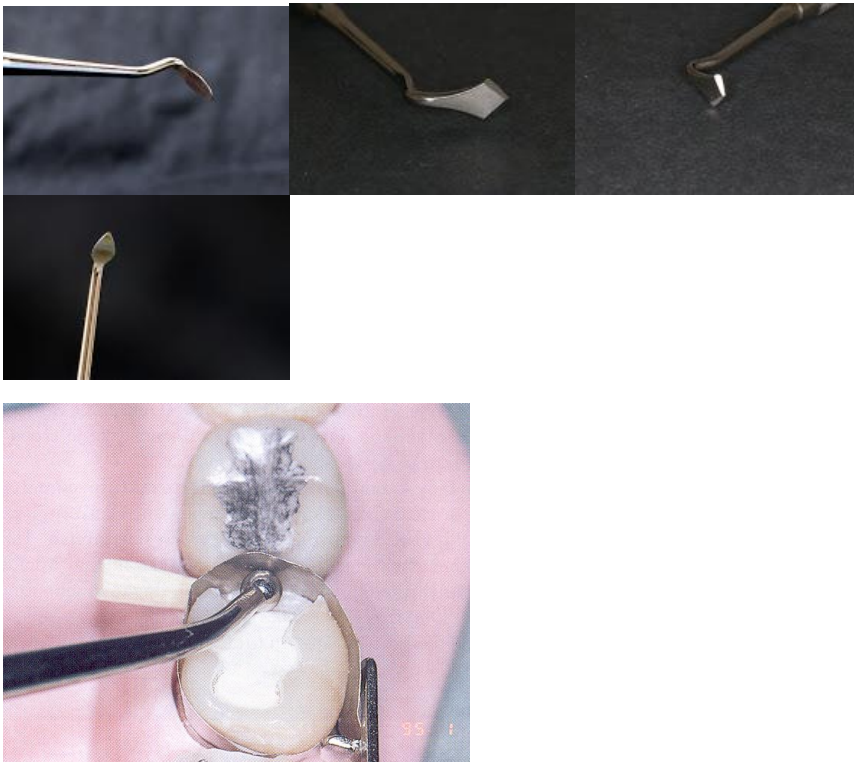

Fig. 22: Completed filling



Carvers



COMPOSITE

We make composite filling with circular or sectional matrix, sectional matrix is used in combination with a separator (a ring which is manipulated with pliers on the cofferdam clamps). Making the contact point is namely much more complicated than in amalgam filling. We begin with the surface of contact point – making the proximal wall and in this way, we transform the “outline cavity” to “central cavity” (class I). Composite is deposited in layers – max. 1.5 mm, each layer must be cured thoroughly.