

Traumatologie axiálního skeletu



MUDr. Dušan Matejička
MUDr. Martin Prýmek

ÚRAZY PÁTEŘE

- 3-6 % všech úrazů
- 70 % hrudní a bederní
- 30 % krční
- 20 % jisté neurologické postižení

Etiologie spinálního traumatu

- Leucht et al. 2009

Table 3

Relationship between cause of accident and fracture localisation.

Cause of accident	Fracture localisation				
	C1-2	C3-7	T1-10	T11-L2	L3-5
High-energy fall	18 (8.2%)	14 (6.4%)	15 (6.8%)	150 (68.5%)	22 (10%)
Simple fall	11 (9.6%)	9 (7.9%)	5 (4.4%)	75 (65.8%)	14 (12.3%)
Traffic	21 (14.1%)	26 (17.4%)	30 (20.1%)	58 (38.9%)	14 (9.4%)
Sports	3 (10.3%)	9 (31%)	4 (13.8%)	12 (41.4%)	1 (3.4%)
Miscellaneous	2 (3.9%)	4 (7.8%)	8 (15.7%)	33 (64.7%)	4 (7.8%)
Total	55 (9.8%)	62 (11%)	62 (11%)	328 (58.4%)	55 (9.8%)

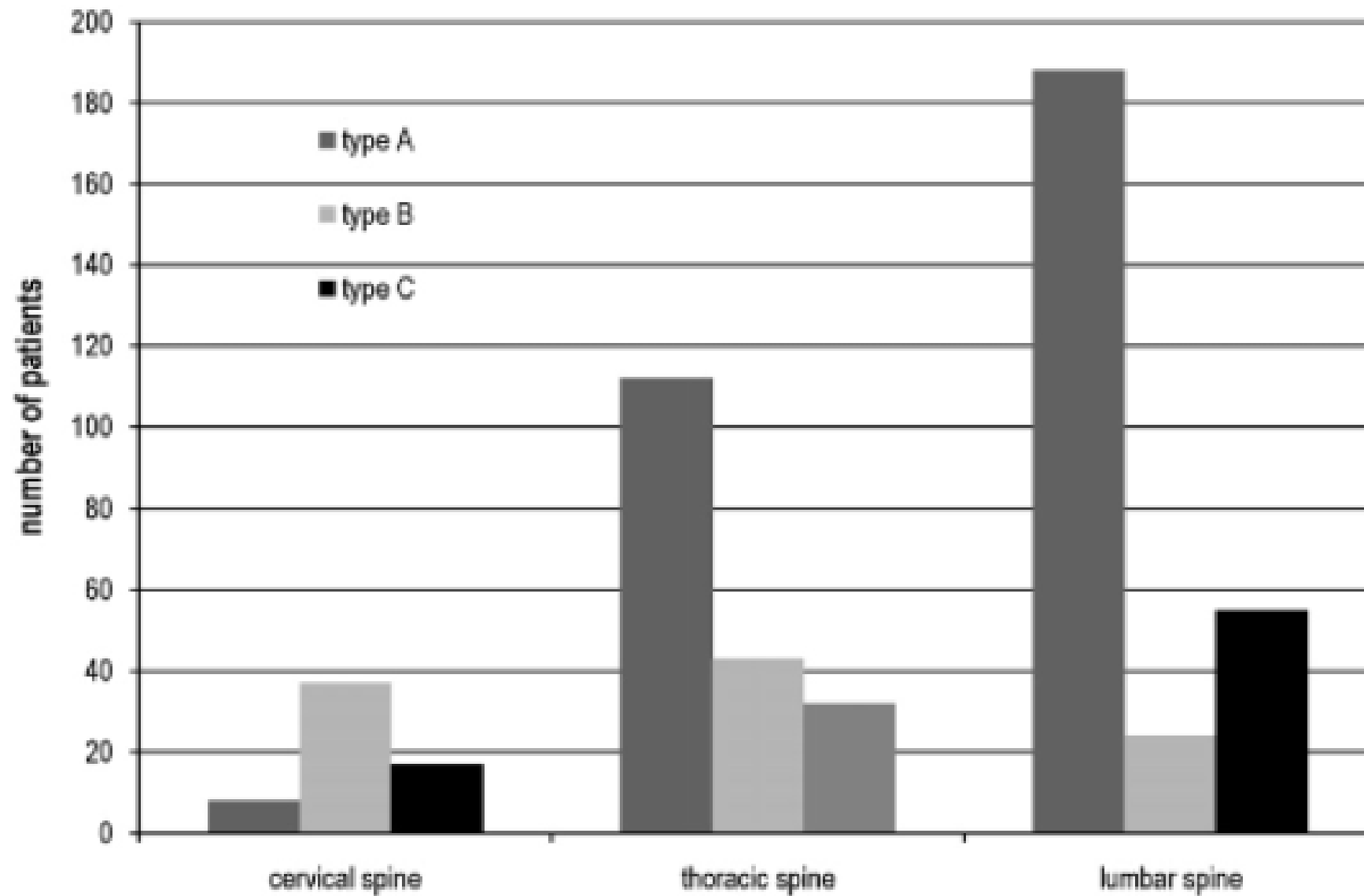


Fig. 5. Incidence of fracture mechanism in each spinal level.

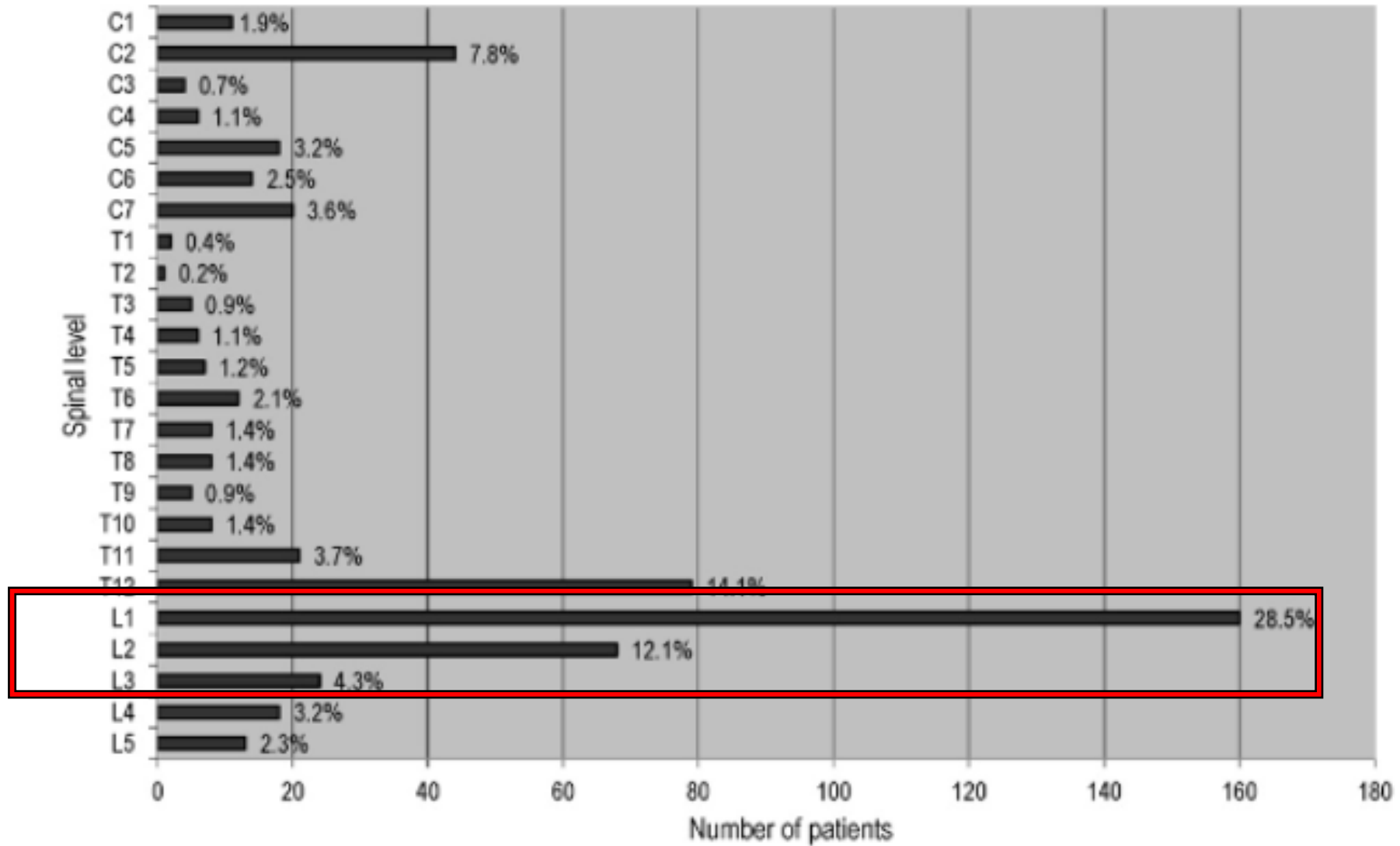


Fig. 4. Distribution of spine fractures for each vertebra.

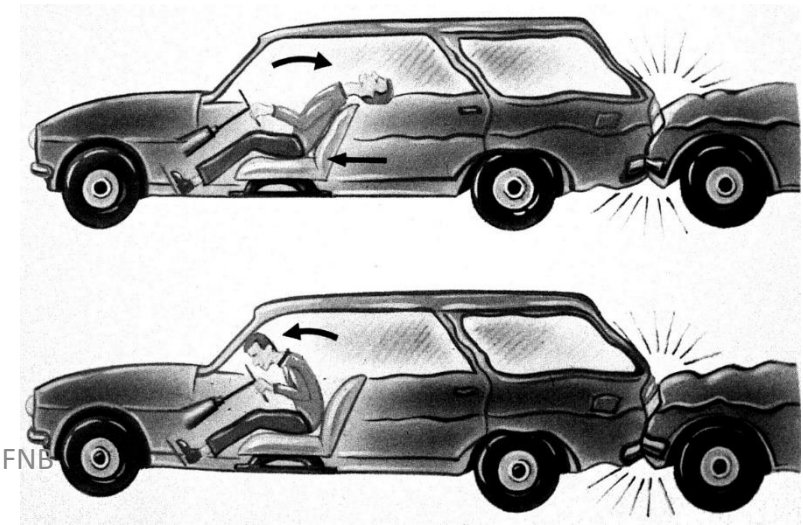
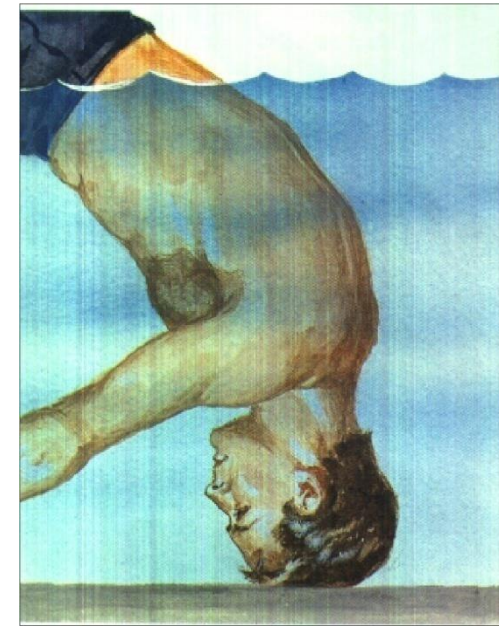
TYPY PORANĚNÍ

Tlak působící v ose páteře

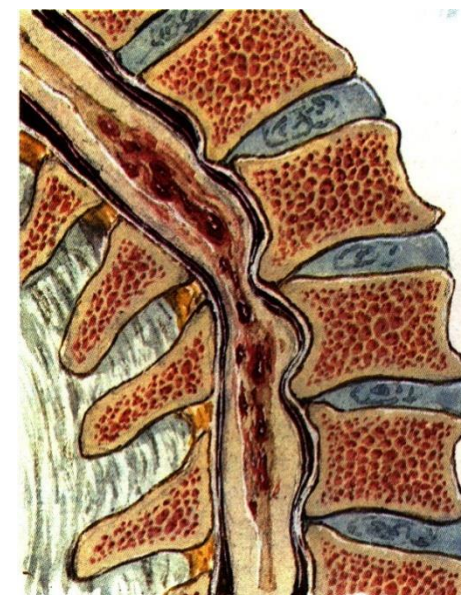
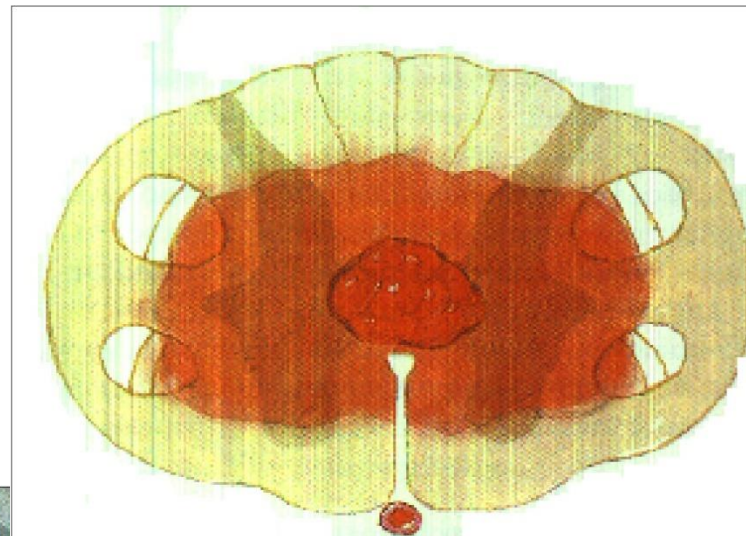
- Tlak působící ohyb
- Rotace
- Kombinace

MECHANISMUS ÚRAZU

- High energy trauma – mladí pacienti
- Nad 60let i low energy (osteoporóza)
- 45% Pády
- 45% Dopravní nehody whip slash injury
- 10% Sport



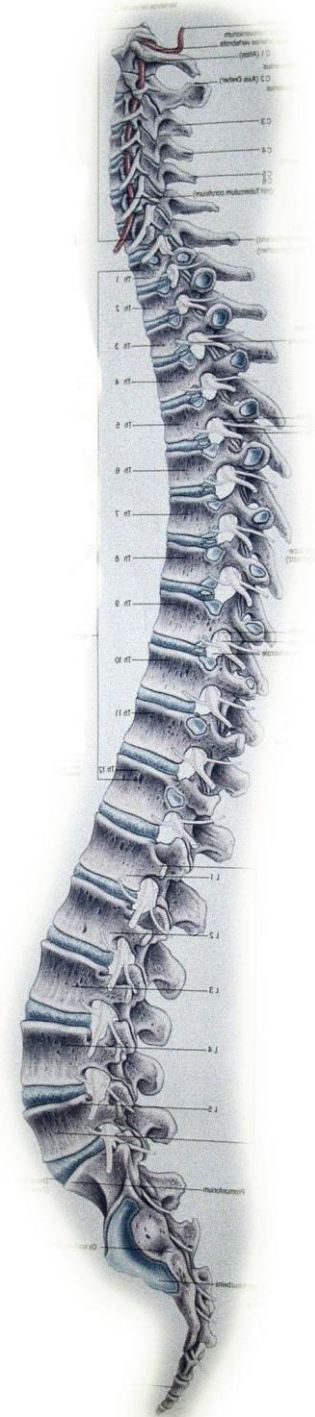
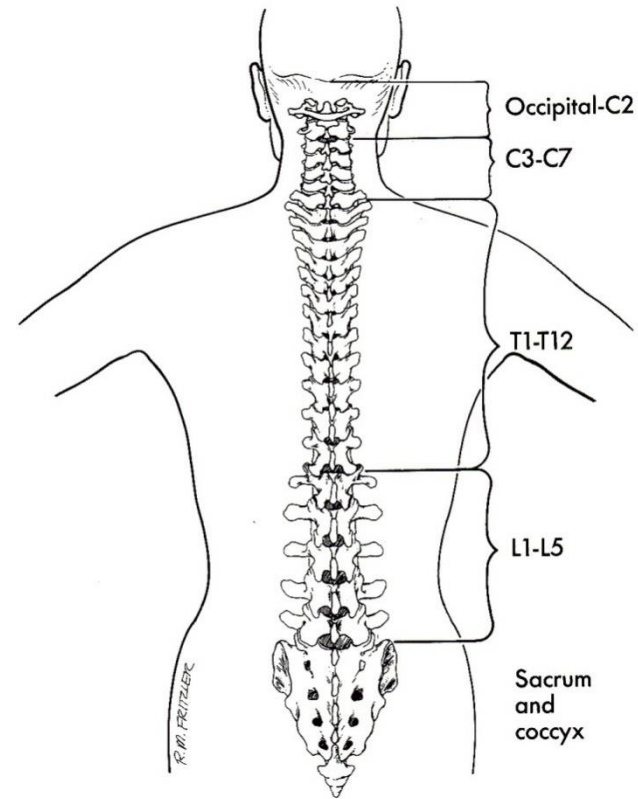
Hematomyelie



PÁTEŘ

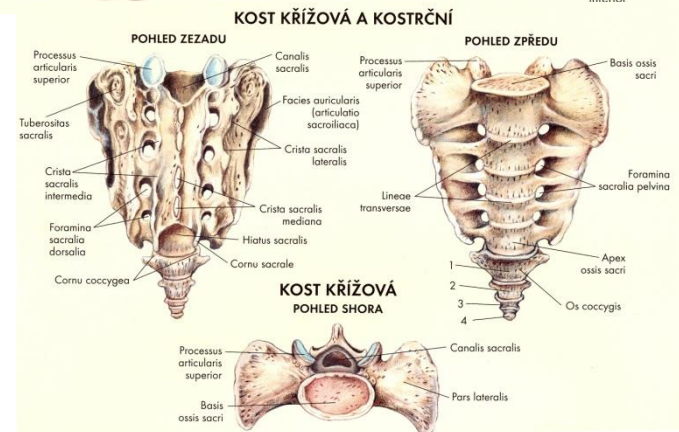
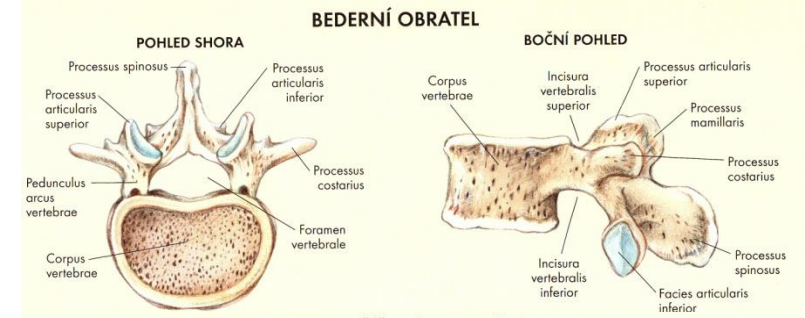
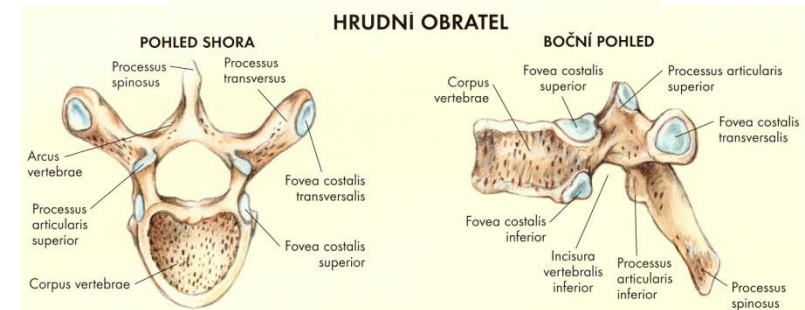
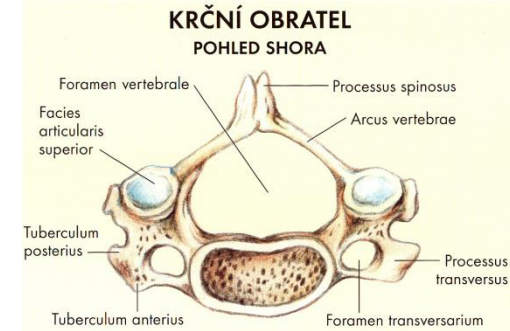
- krční
 - hrudní
 - bederní
 - kost křížová
 - kostrč
-
- podpora těla
 - ochrana míchy/dur. vaku

C
T
L



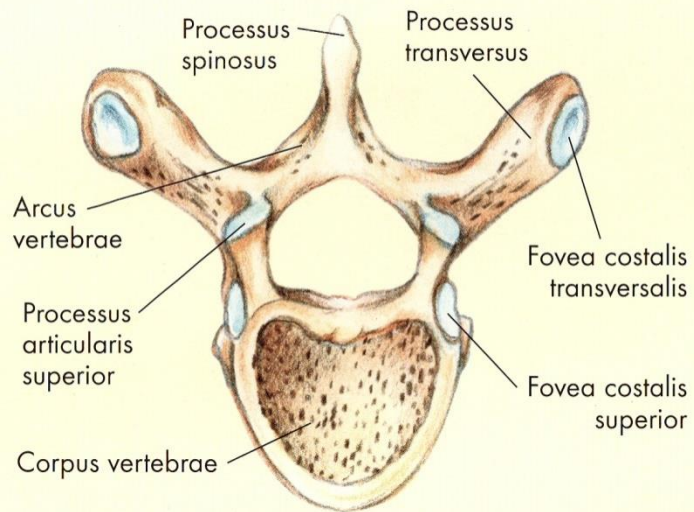
Stavba obratle

- Obratlové tělo
- Pedikly
- Oblouk
- Kloubní výběžky
 - horní
 - dolní
- Postranní výběžky
- Trnový výběžek

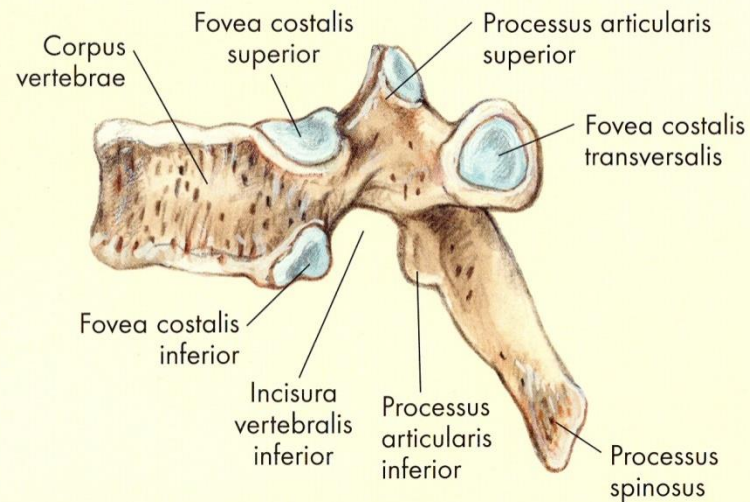


HRUDNÍ OBRATEL

POHLED SHORA

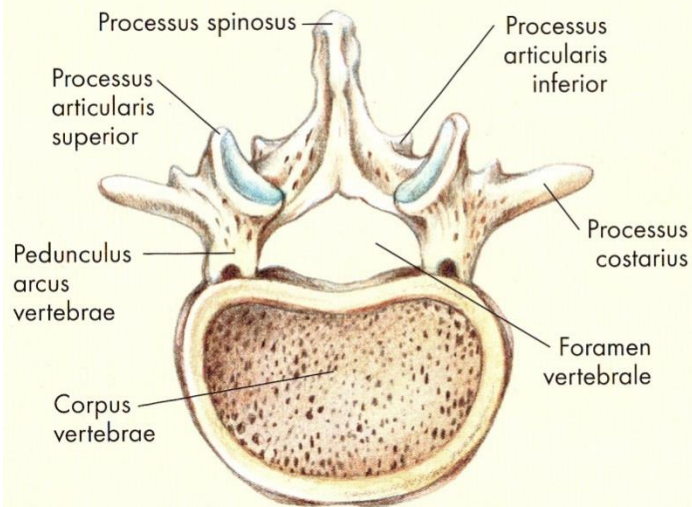


BOČNÍ POHLED

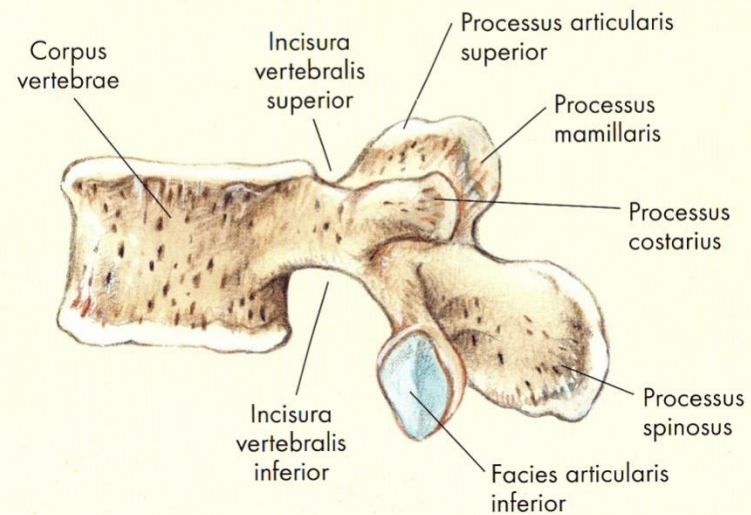


BEDERNÍ OBRATEL

POHLED SHORA



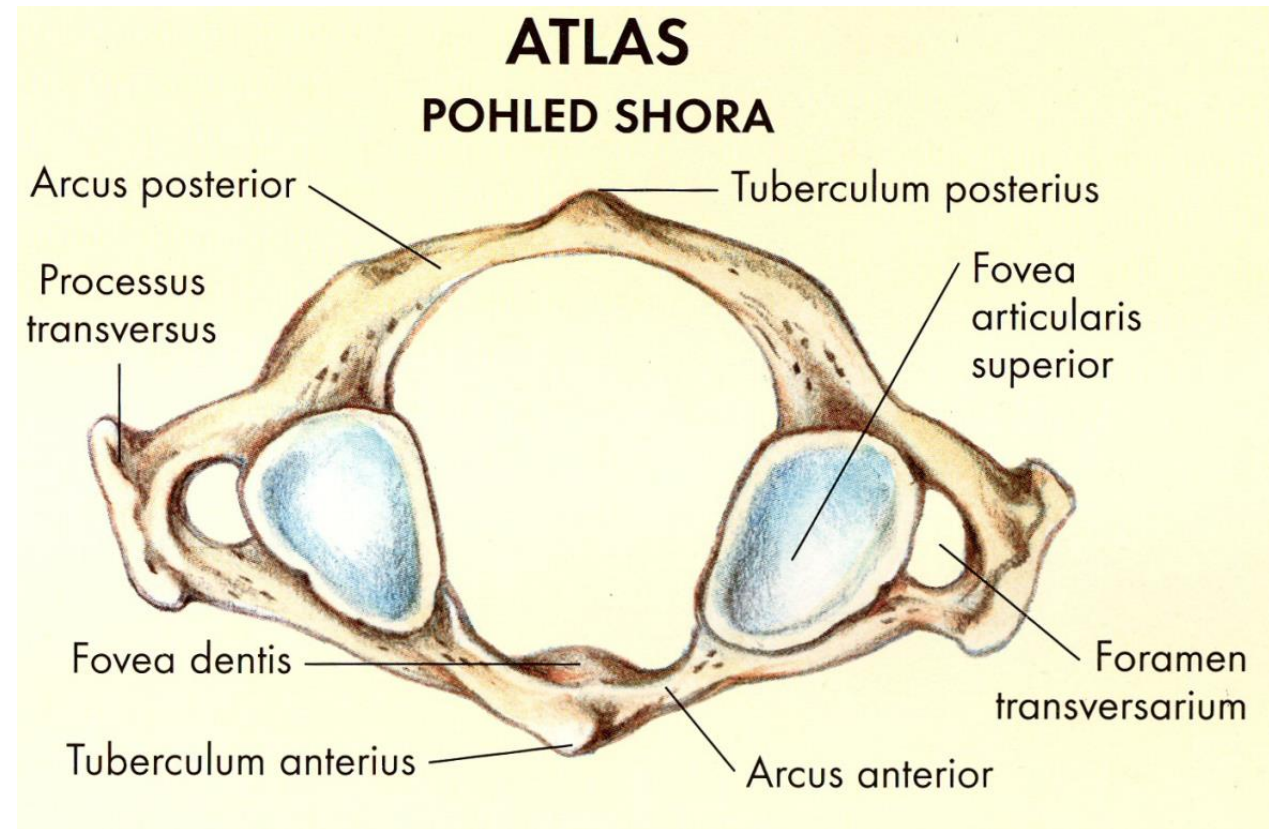
BOČNÍ POHLED



C1

C1 = atlas

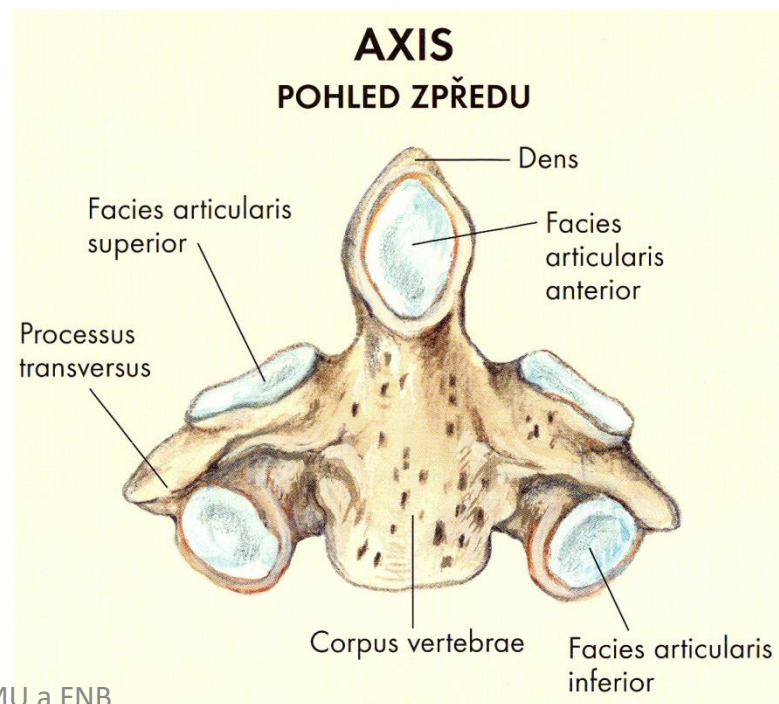
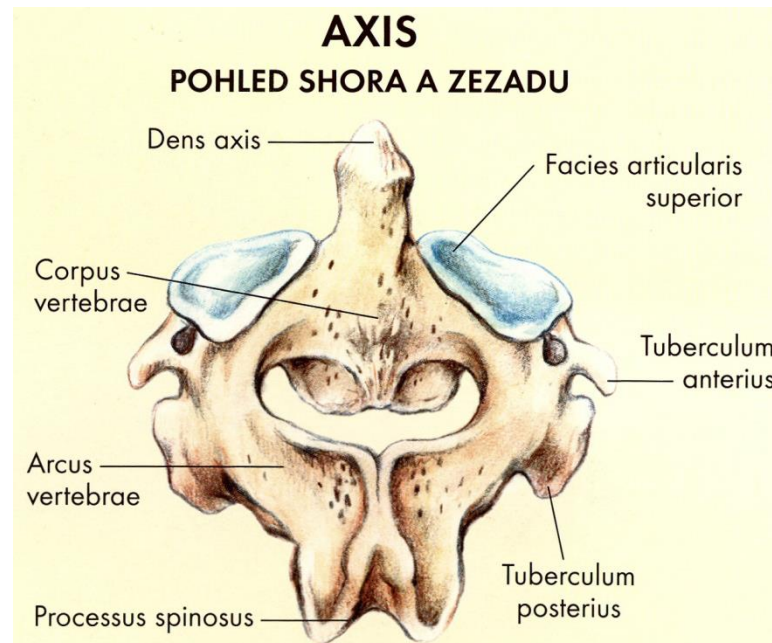
Oblouky + kloubní výběžky

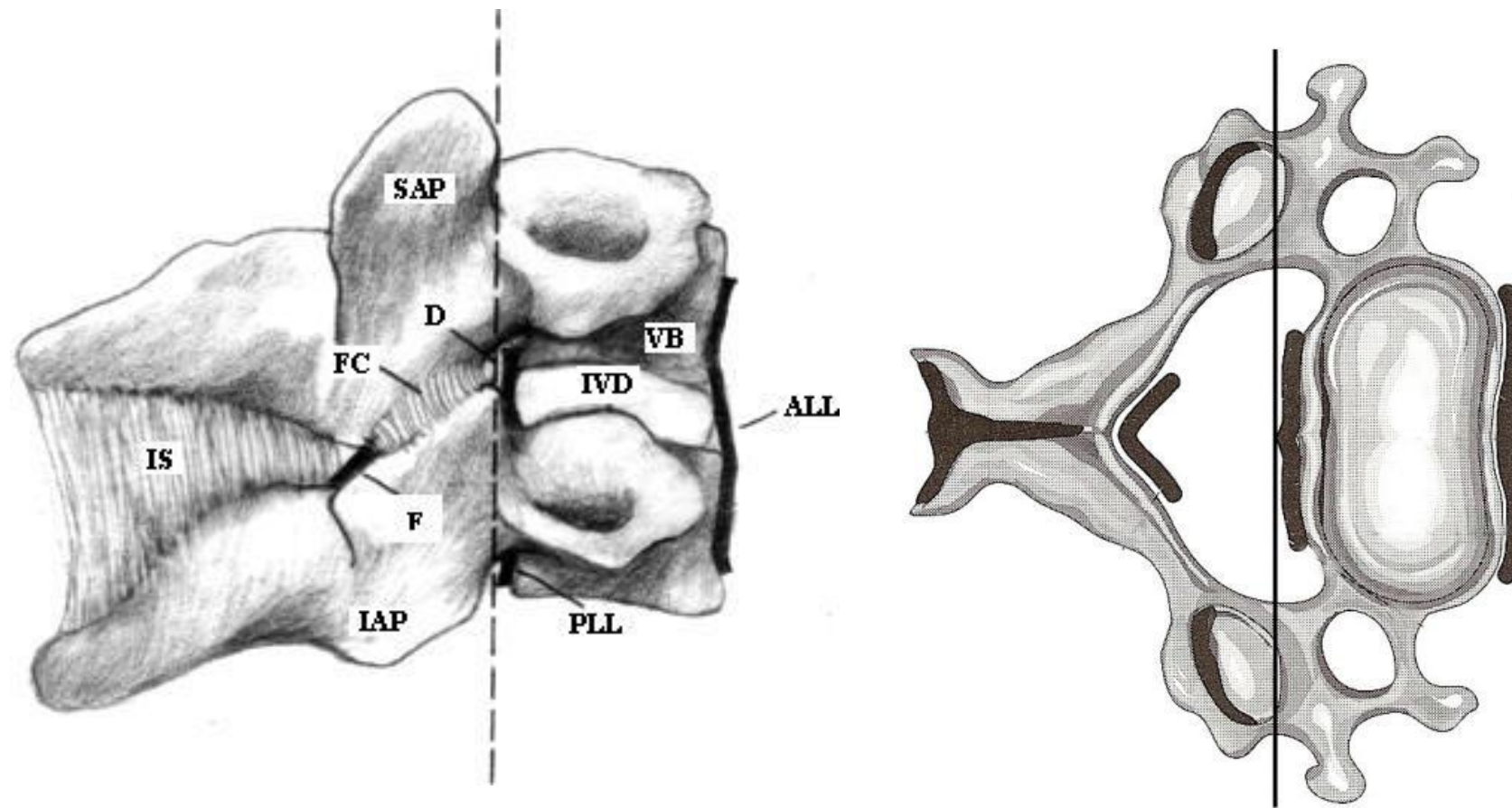


C2

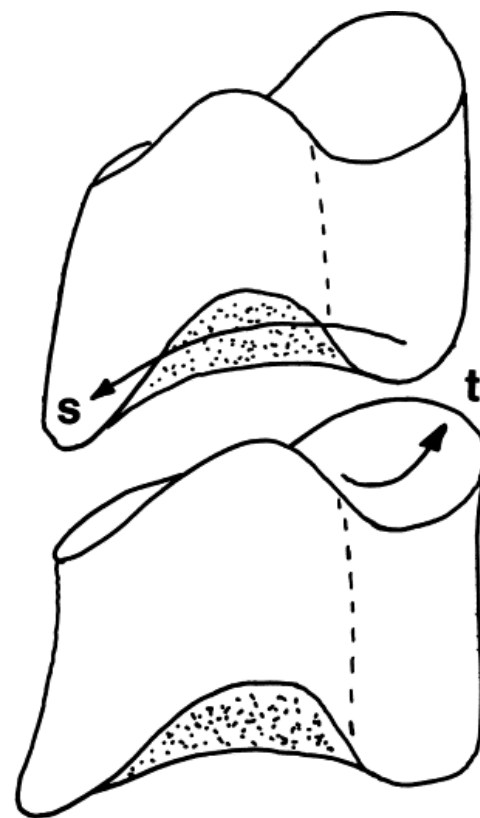
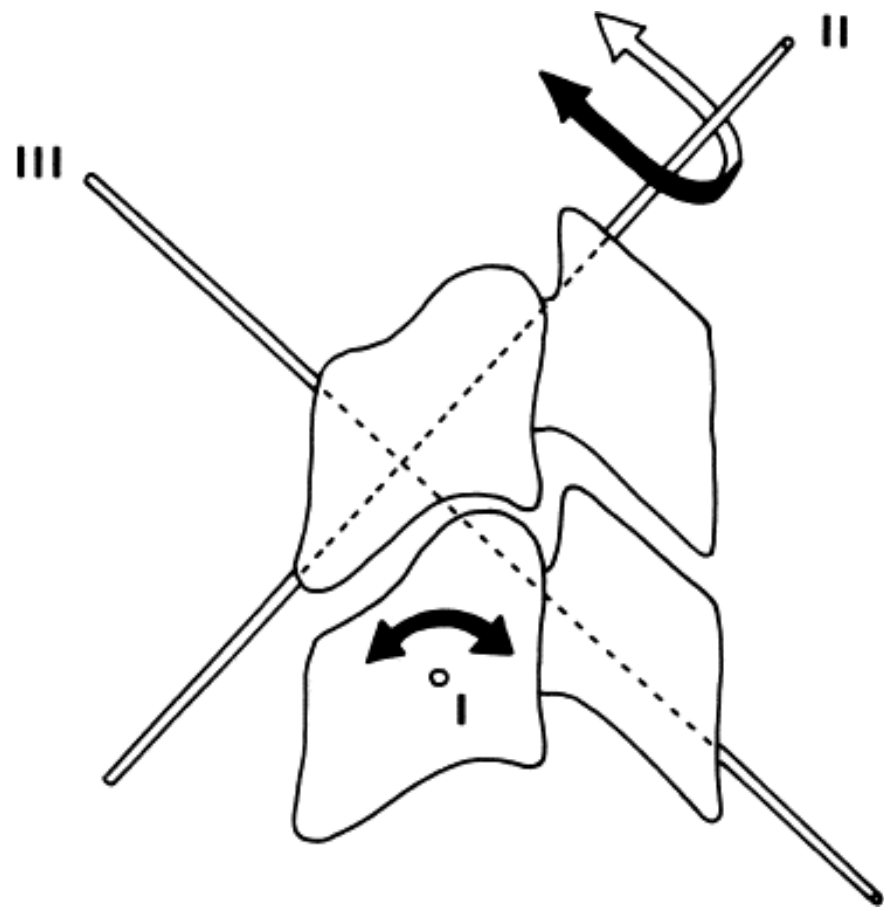
axis, čepovec

- Tělo
- Zub
- Kloubní výběžky





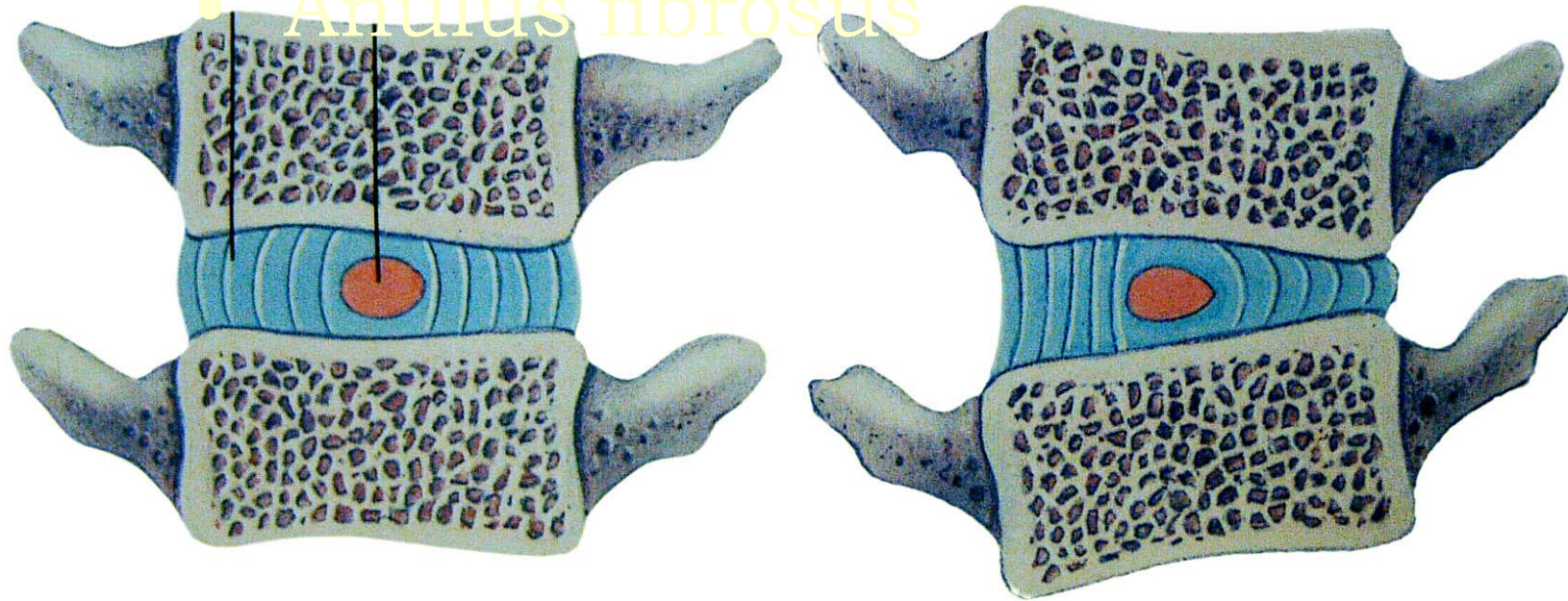
- struktury zadního sloupce podle *Holdswortha*



Meziobratlová ploténka

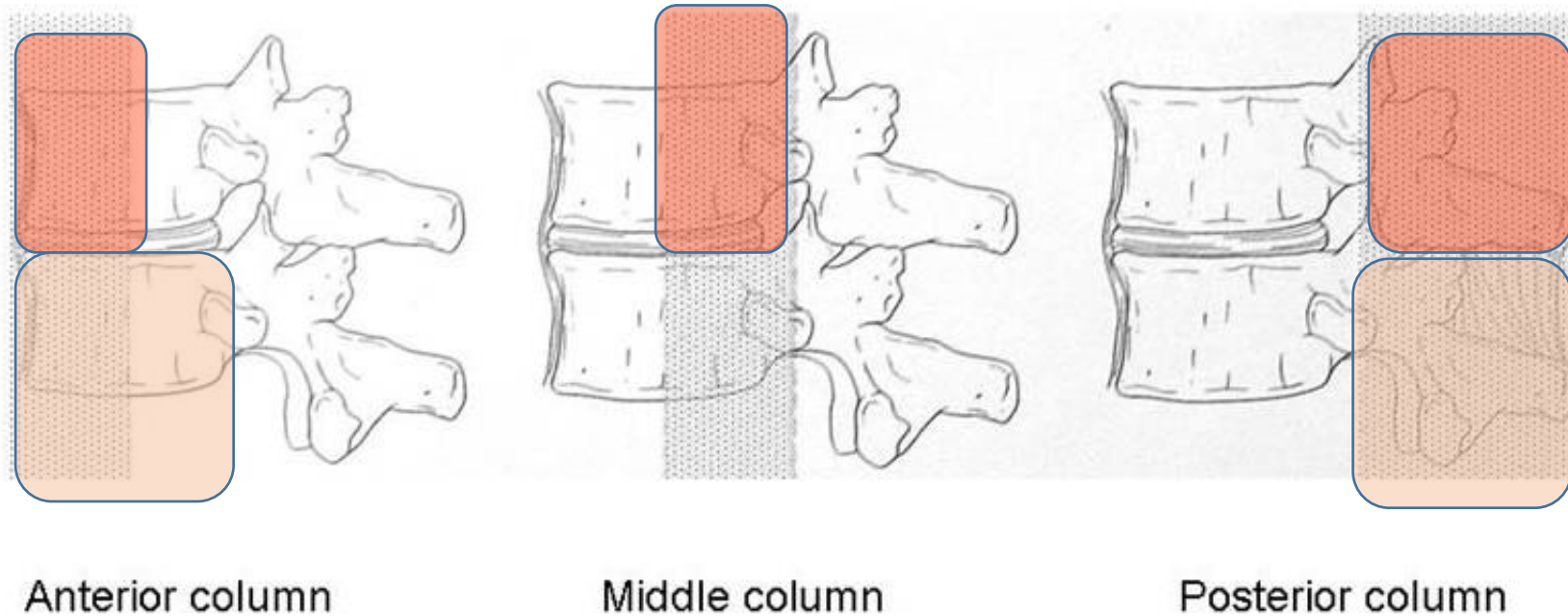
discus intervertebralis

- Nucleus pulposus
- Anulus fibrosus



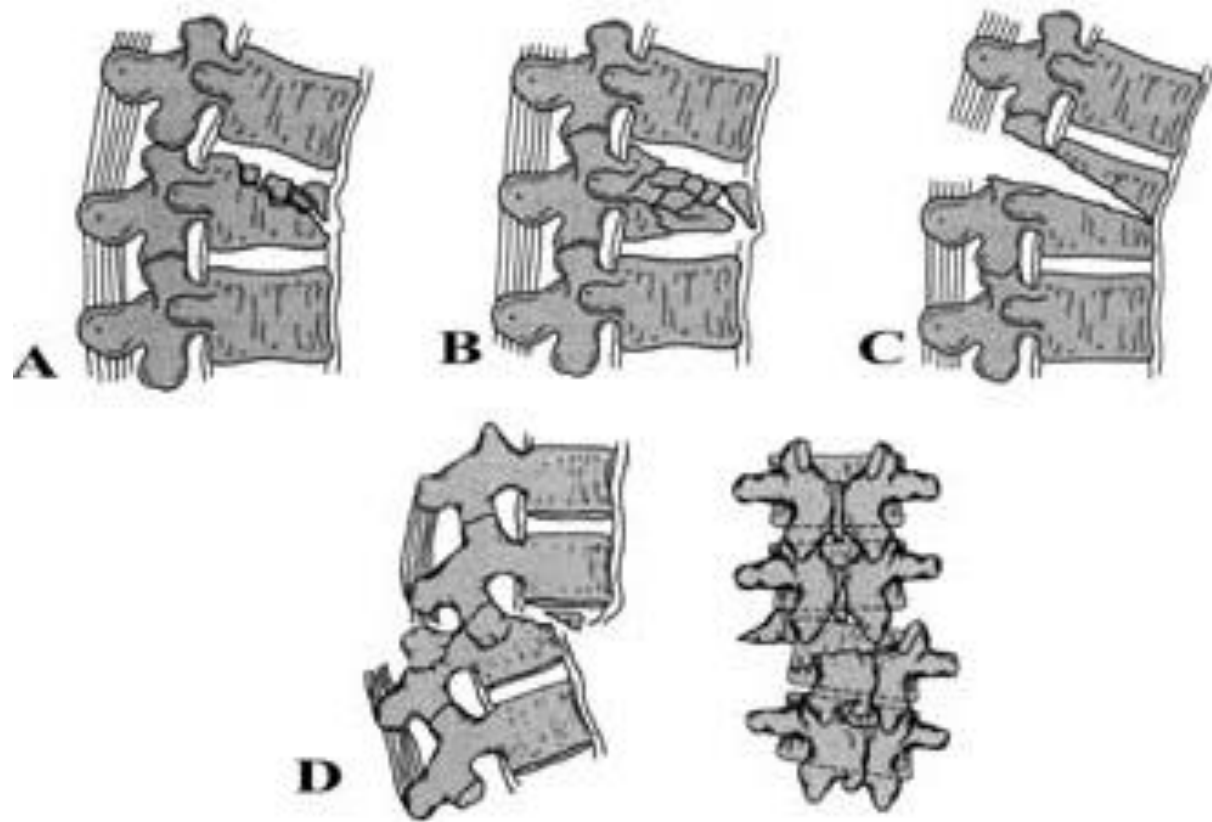
Denisova tříslupcová teorie – obsolentní !!

Denis 3-column theory

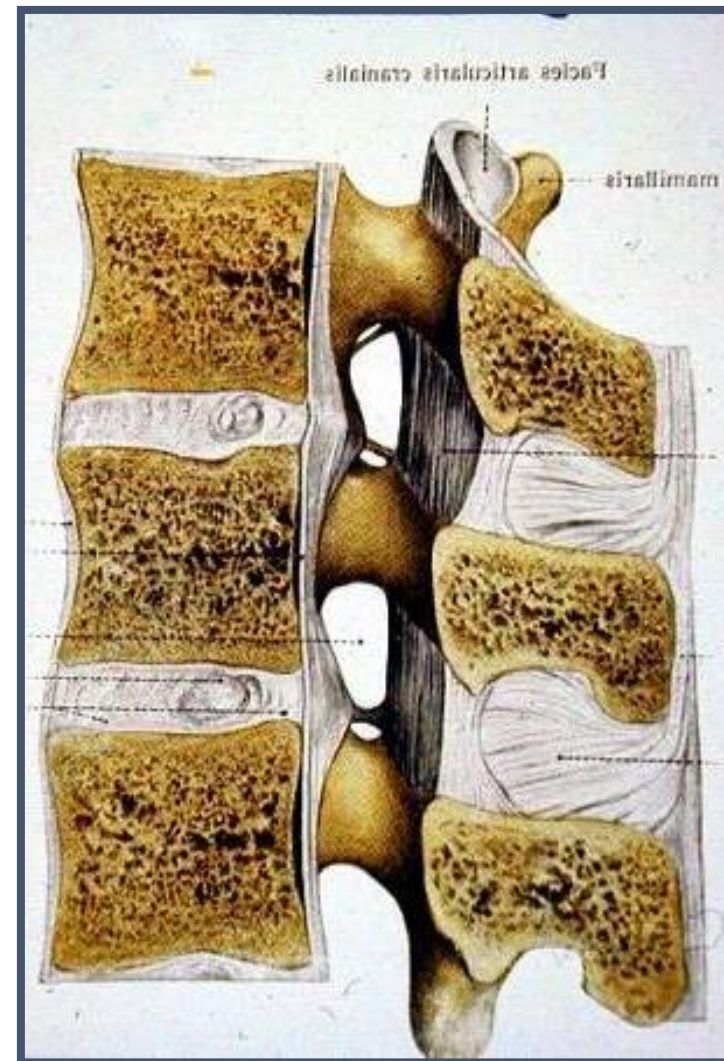
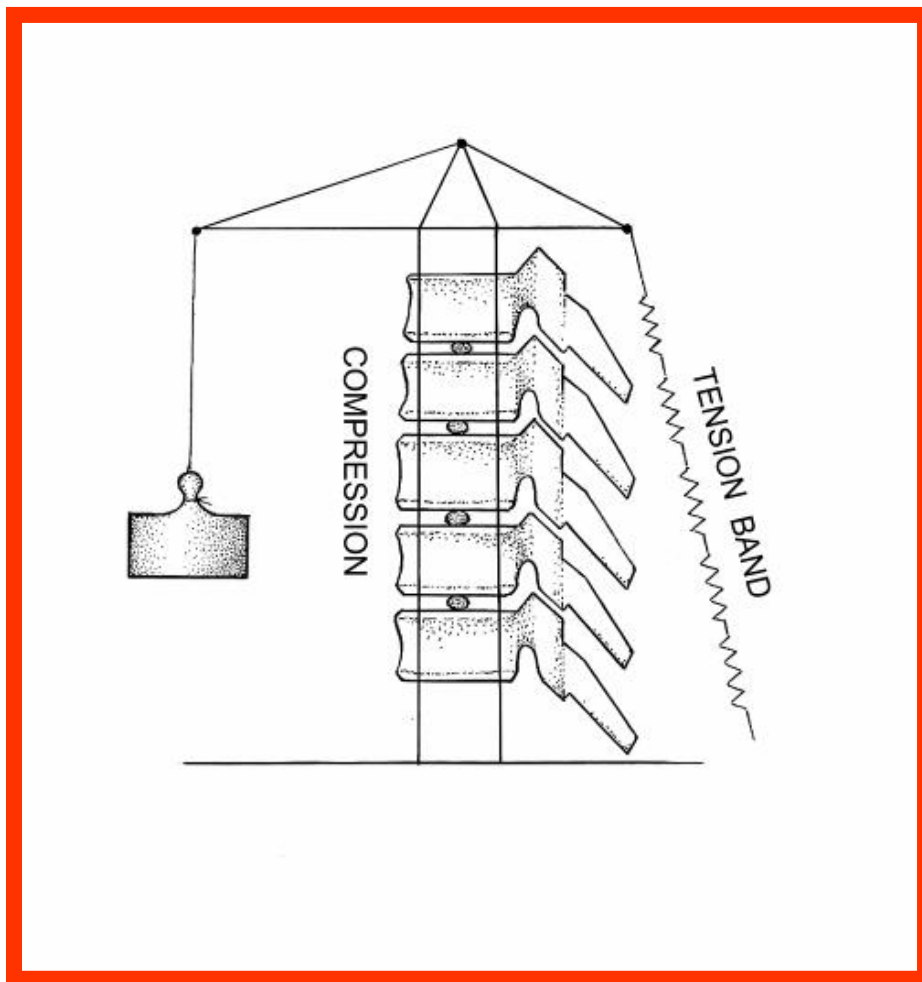


Dvouslupcová (Magerl)

Denisova tříslupcová teorie – obsolentní !!

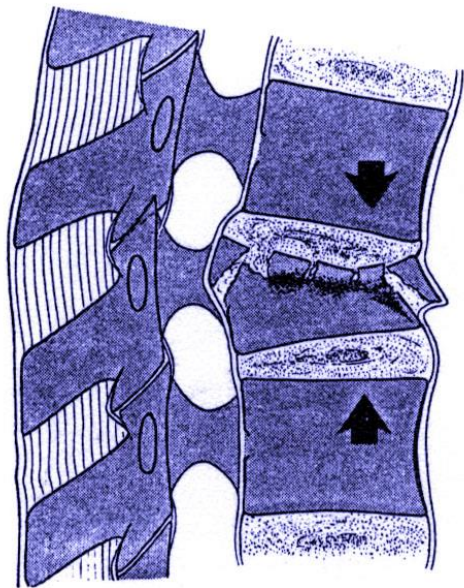


Dvousloupcová teorie (Magerl)

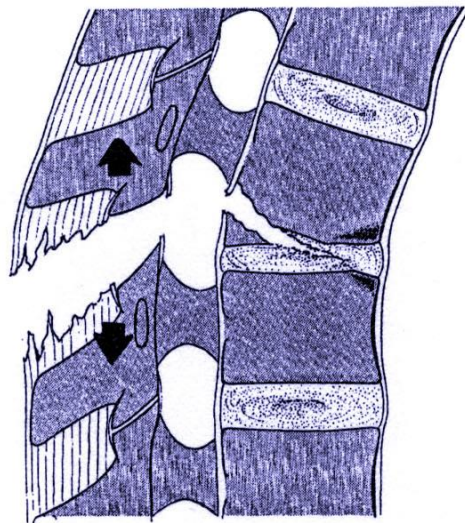




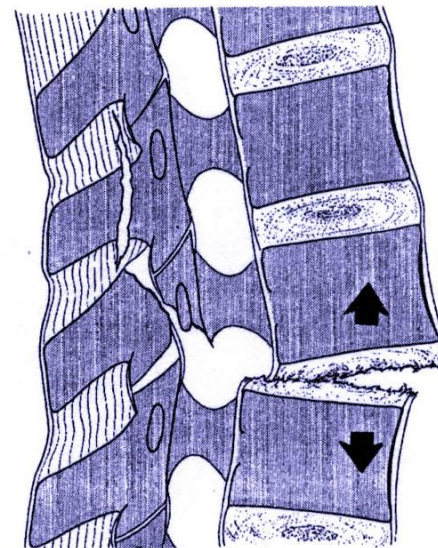
A



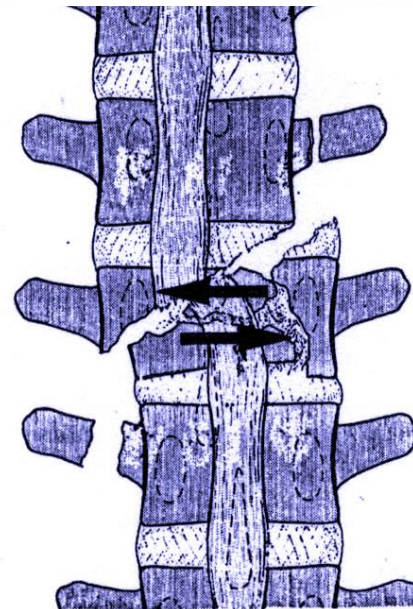
B



C



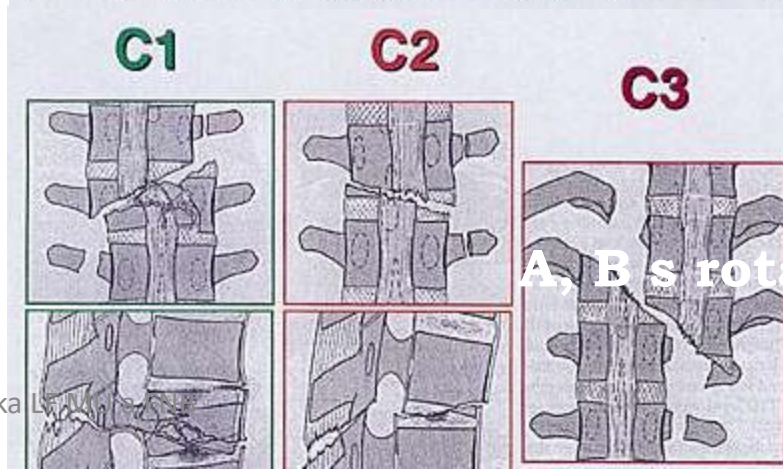
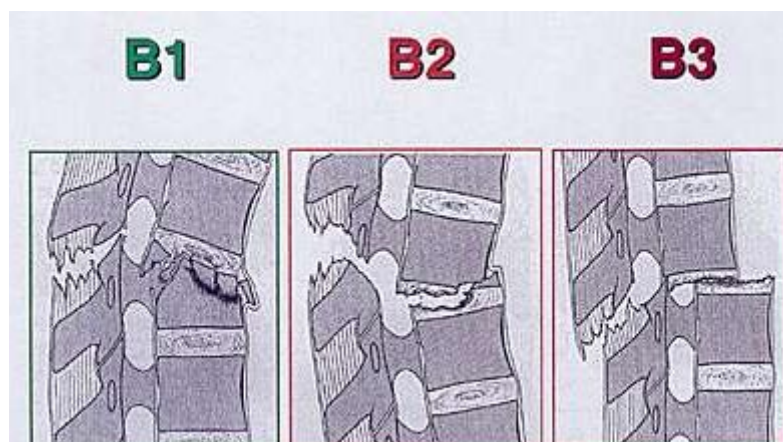
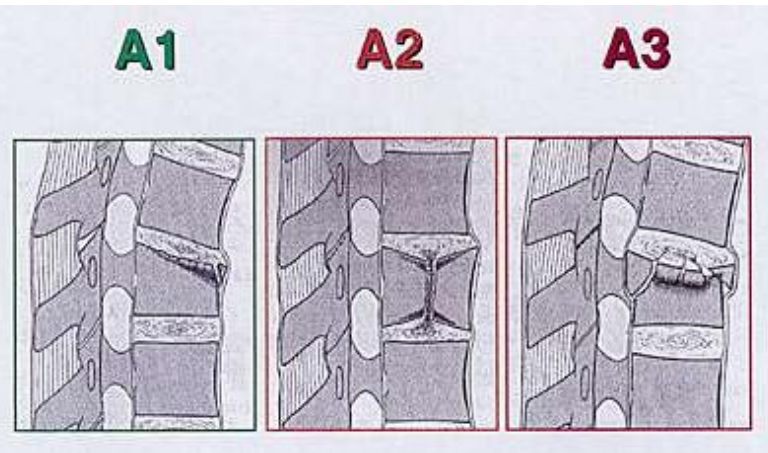
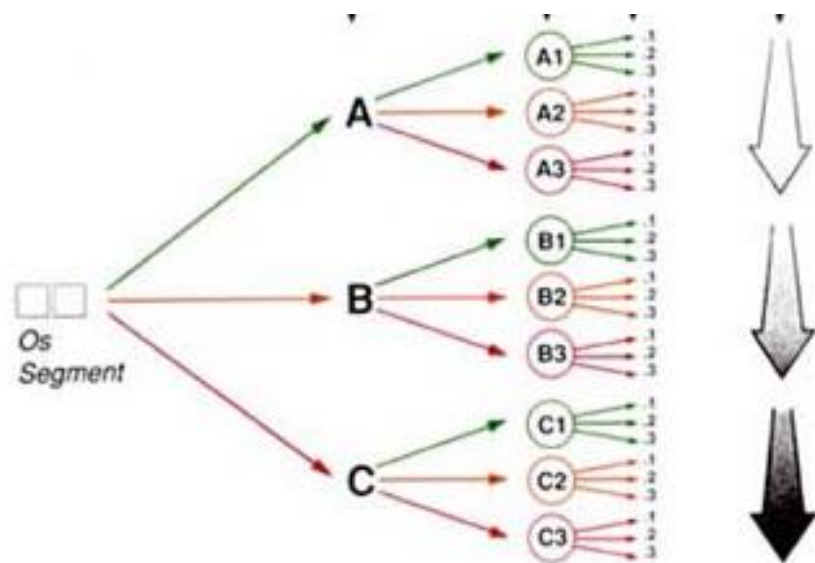
C



D




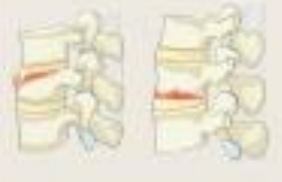





Flekční, extenční a rotační mechanismus

AO klasifikace (Magerl)

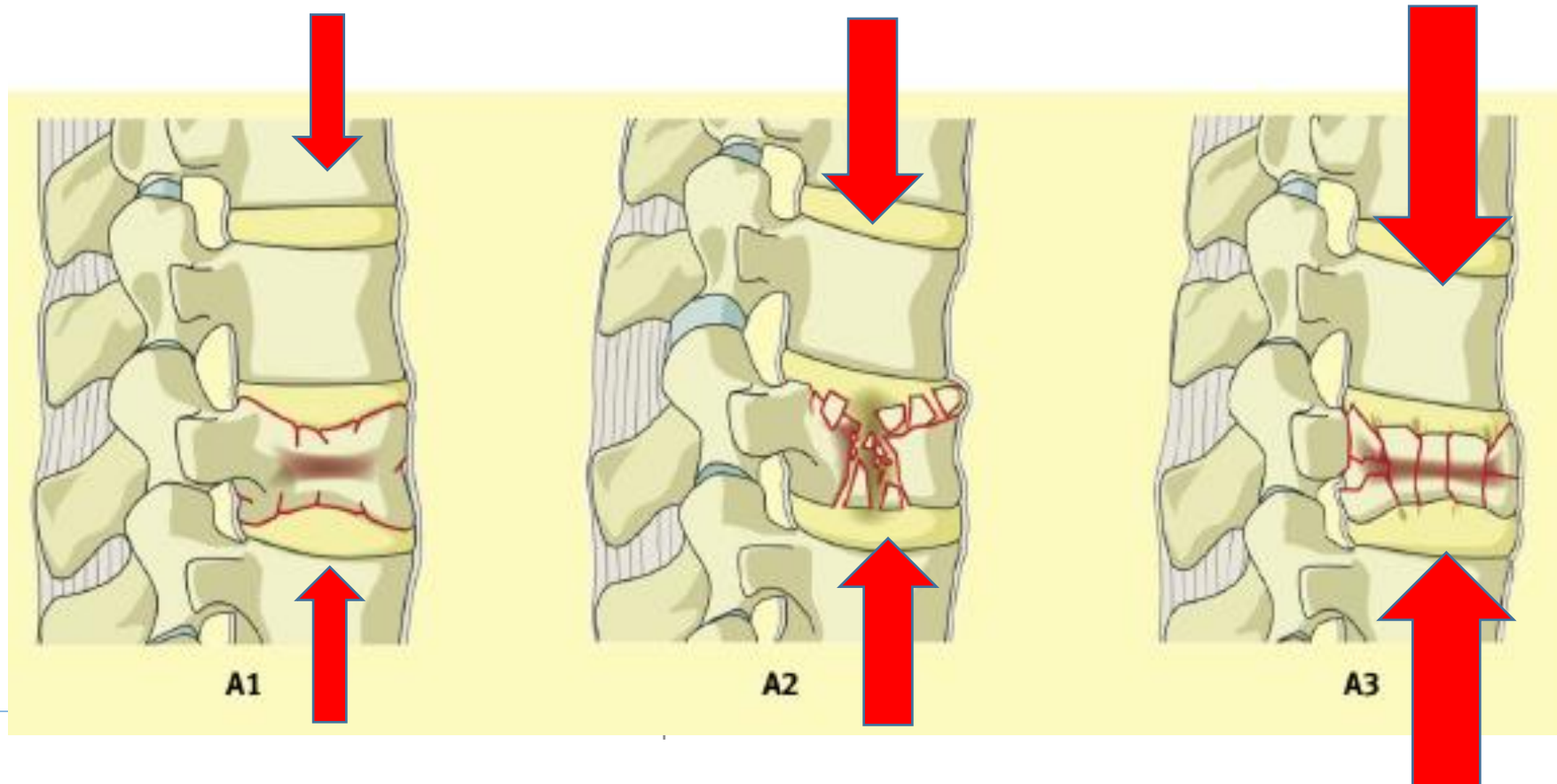


A, B s rotací

AOSpine Thoracolumbar Classification System

Type A. Compression Injuries	Type B. Distraction Injuries	Type C. Translation Injuries
<p>A0. Minor, nonstructural fractures Fractures which do not compromise the structural integrity of the spinal column such as transverse process or spinous process fractures.</p> 	<p>B1. Transosseous tension band disruption Chance fracture Horizontal/pure tension failure of the posterior tension band. The divided Chorda function.</p> 	<p>C Displacement or dislocation There are no collages because collages are possible due to dislocation/distraction. Can be combined with subtypes A, B or B.</p> 
<p>A1. Wedge-compression Fracture of a single vertebra without involvement of the posterior wall of the vertebral body.</p> 	<p>B2. Posterior tension band disruption Same as type B1 fracture failure of the posterior tension band together with a type A fracture. Type A fracture should be classified separately.</p> 	<p>B3. Hyperextension Burst through the disk or vertebral body leading to a hyperextended position of the spinal column. Commonly seen in children. Distraction occurring especially the disk are typical but there is a possible hyperextension fracture displacement.</p> 
<p>A2. sFR Fracture of both vertebrae without involvement of the posterior wall of the vertebral body.</p> 	<p>A3. Incomplete burst Fracture with any involvement of the posterior wall only - single vertebrae fracture - vertebral fracture of the lamina is usually present and does not constitute a tension band failure.</p> 	<p>A4. Complete burst Fracture with any involvement of the posterior wall without vertebrae - vertebral fracture of the lamina is usually present and does not constitute a tension band failure.</p> 

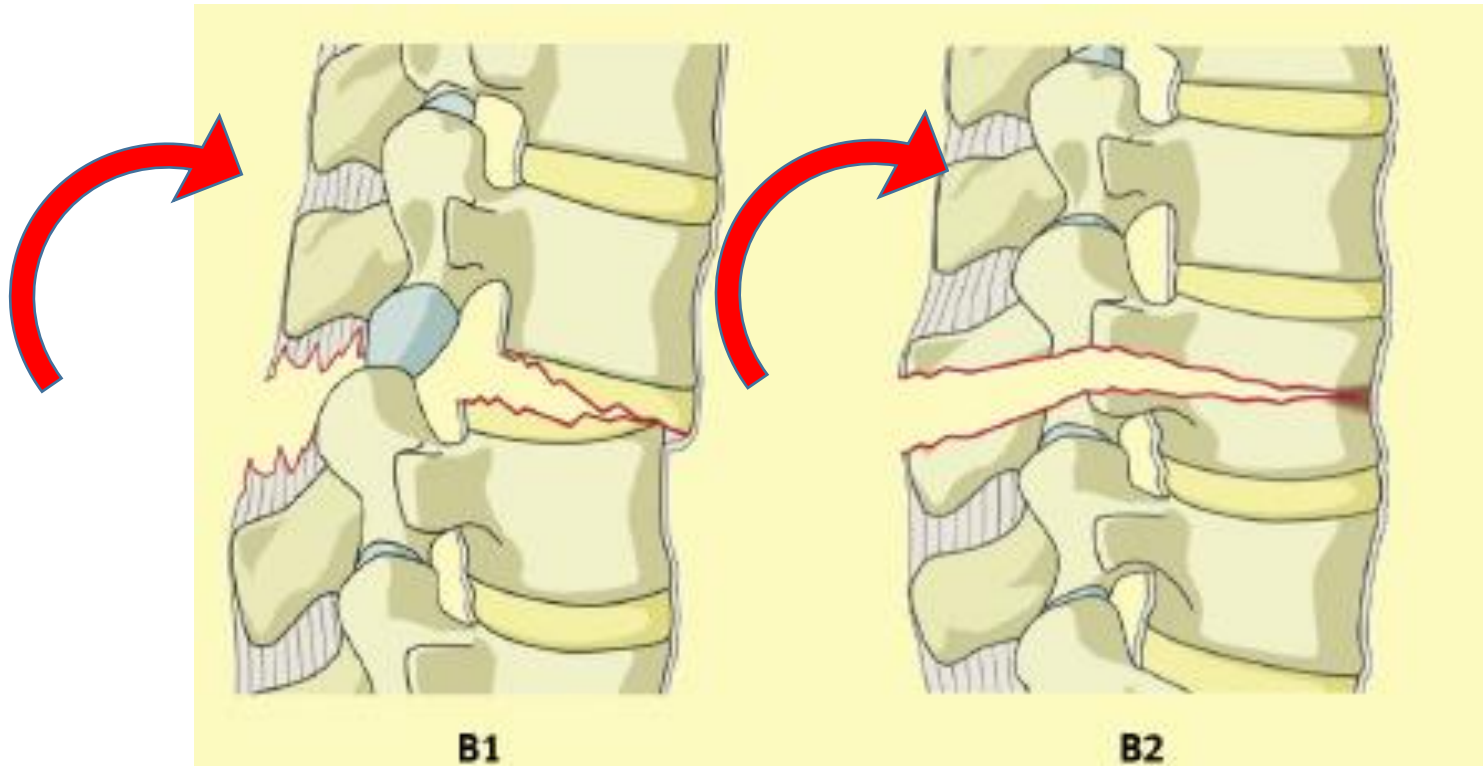
AO Typ A – mechanismus úrazu KOMPRESNÍ MECHANISMUS



AO typ B – mechanismus úrazu

B1,2 ZADNÍ TAHOVÝ SLOUPEC

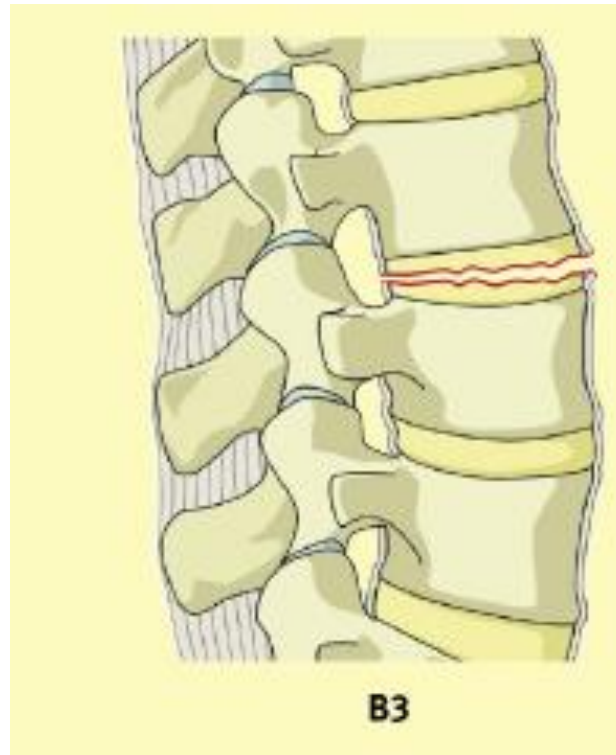- FLEKČNĚ DISTRAKČNÍ MECHANISMUS



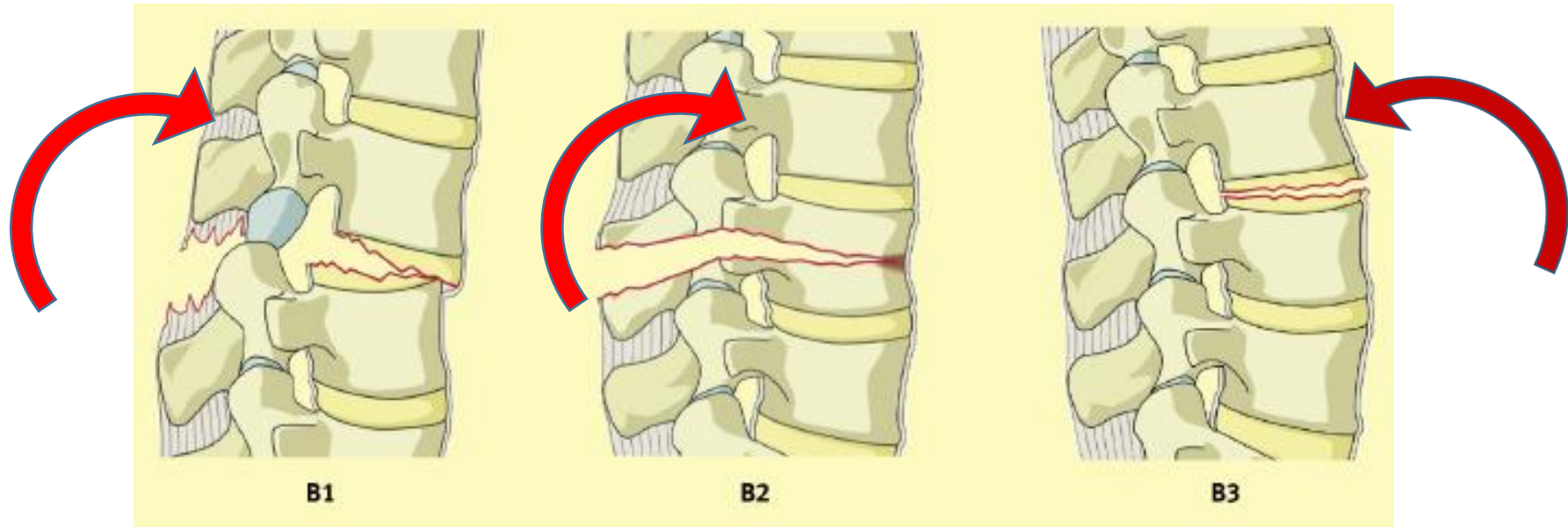
AO TYP B – mechanismus úrazu

B3 PŘEDNÍ TAHOVÝ SLOUPEC

- **EXTENZE**



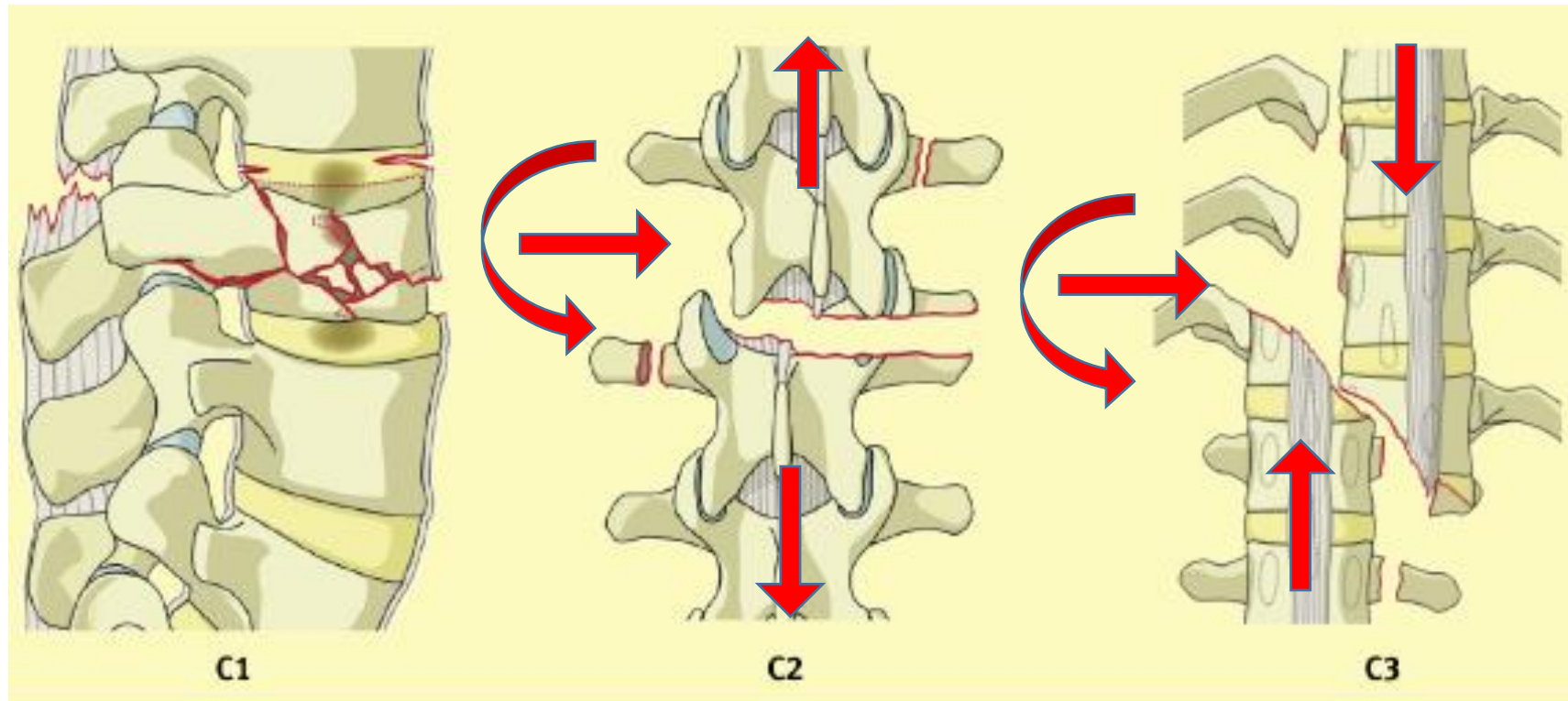
AO typ B – mechanismus úrazu



AO typ C

- Disrupce přední i zadního sloupce
- Zahrnuje **translační dislokaci či distrakci** za hranicí fyziologického rozsahu

AO typ C - mechanismus úrazu



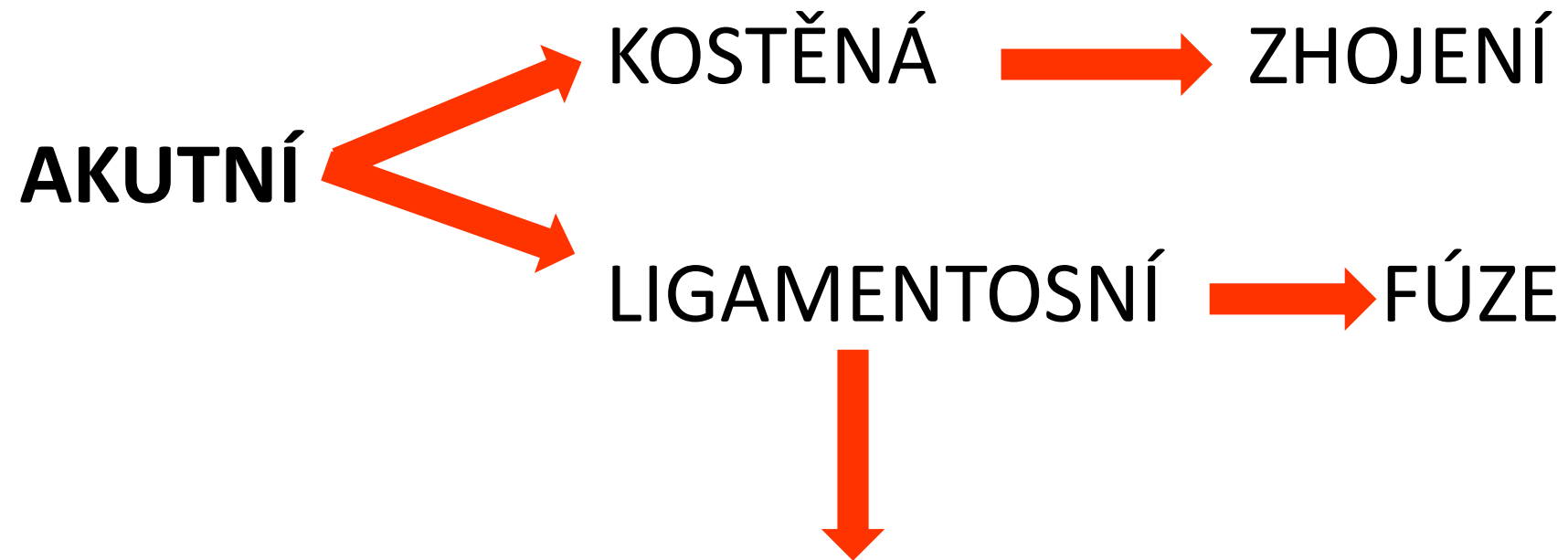
INSTABILITA

Mnoho podobných definic

(Louis, Roy-Camille, White and Panjabi, Frymoer and Krag)

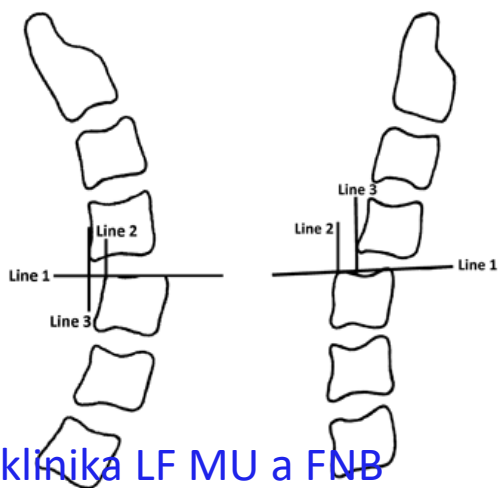
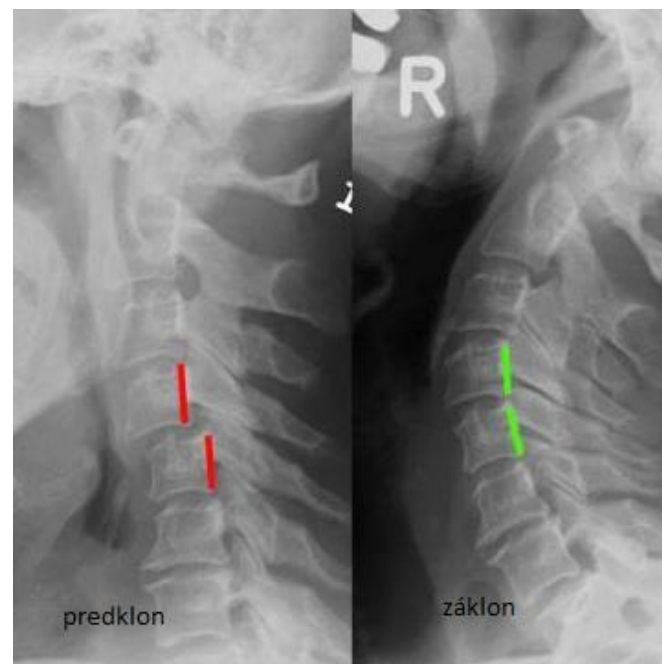
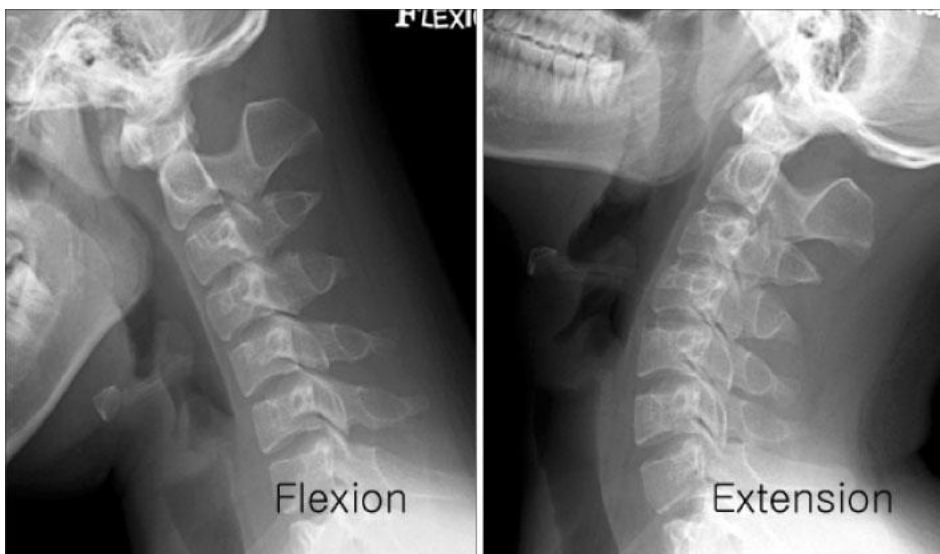
**PÁTEŘ NETOLERUJE A NEZVLÁDÁ
FYSIOLOGICKÉ ZATÍŽENÍ**

INSTABILITA



CHRONICKÁ INSTABILITA

Nestabilita C páteře

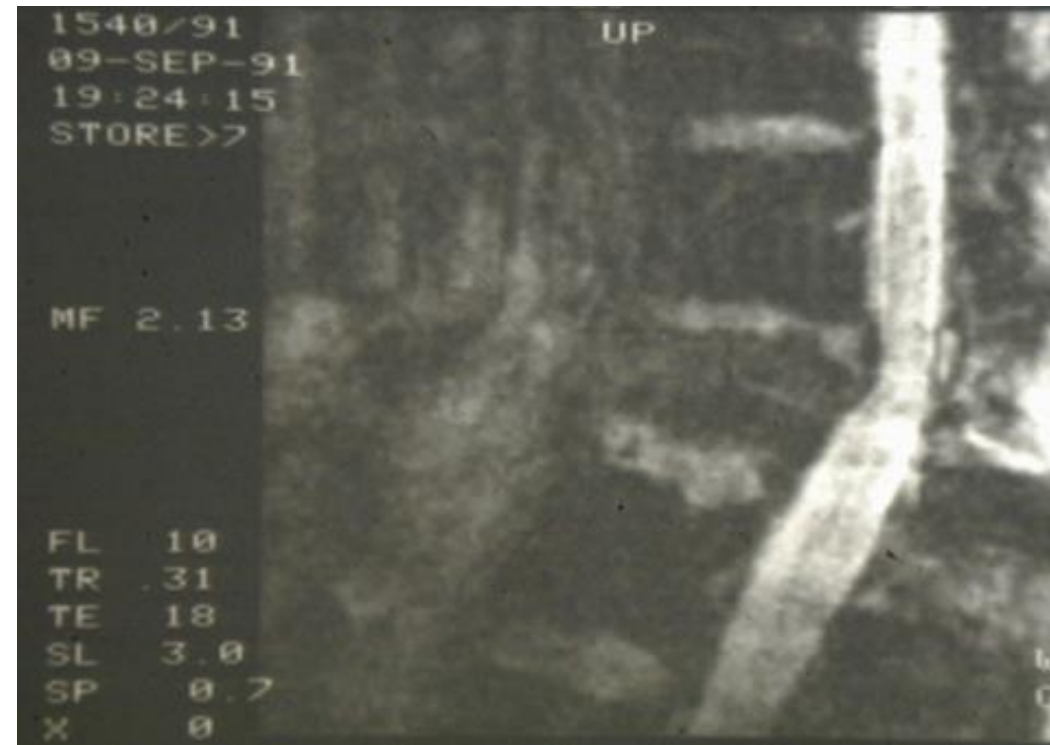

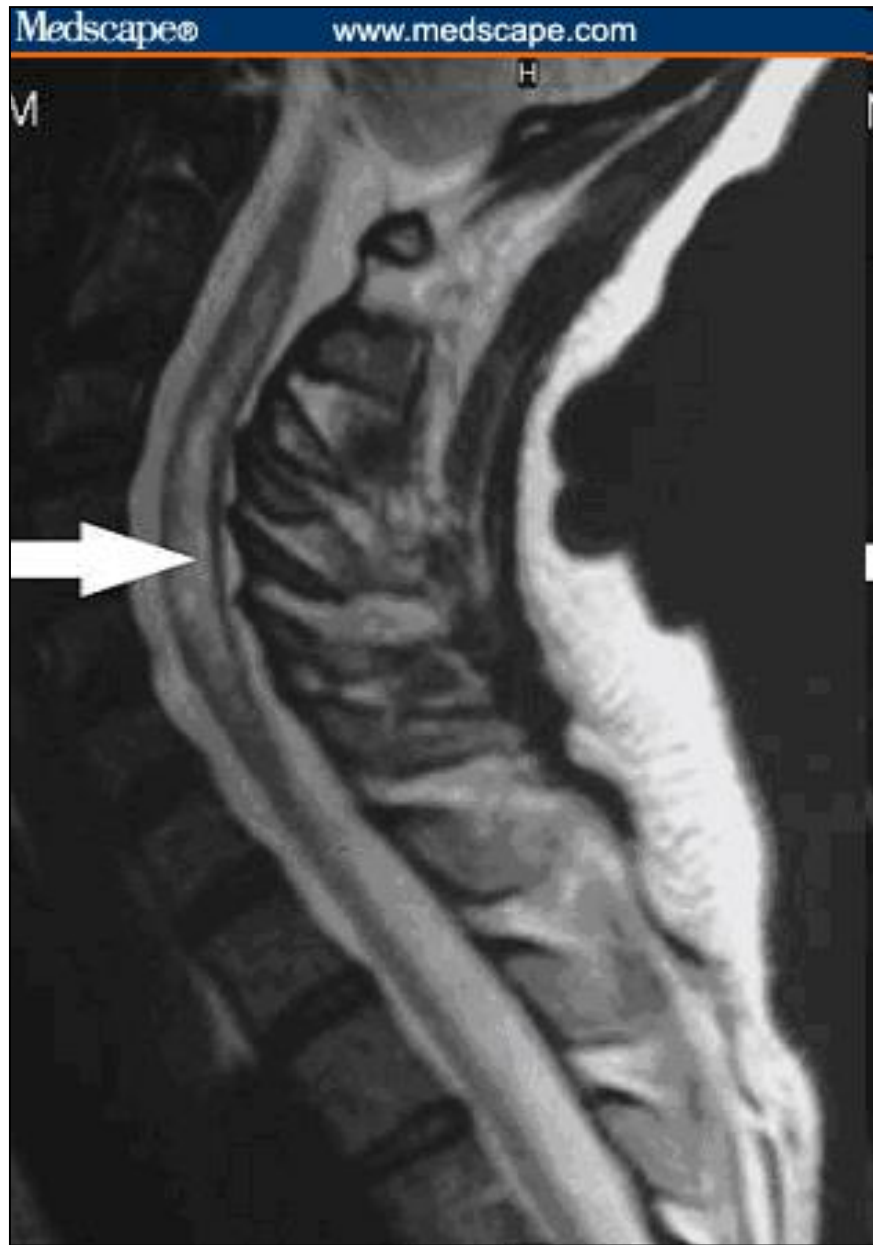LIGAMENTÓZNÍ INSTABILITA

- konzervativní léčba nemůže vést ke zhojení
- výsledkem je chronická progredující nestabilita
- může vzniknout pseudoatroza nebo kyfotická deformita
- ligamentozní nestabilitu je možné zhojit pouze fusí postiženého segmentu

Neurologický deficit

- Fragment v páteřním kanále
- Dislokace-většinou kyfotizace, translace
- Bezpostřední vznik při úrazu
- Postupný vznik zapříčiněný edémem či ischemií





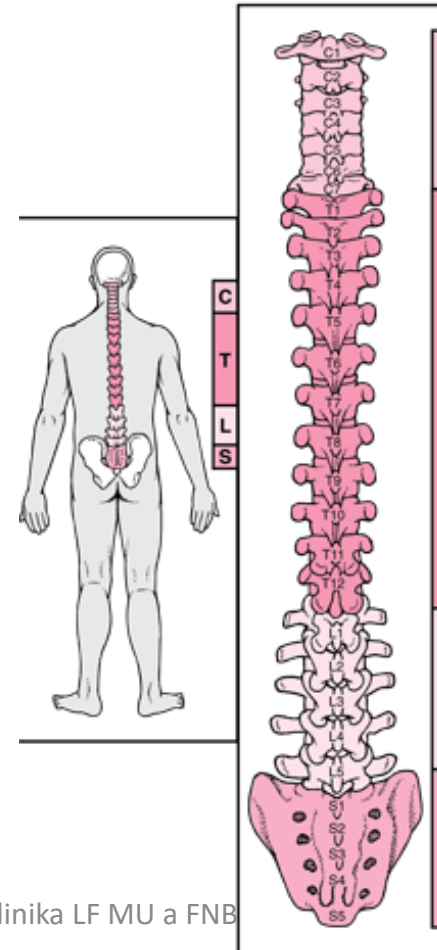
Ortopedická klinika LF MU a FNB

Hodnocení poškození míchy

- 3 složky :
 - motorické funkce
 - senzorické funkce
 - míšní reflexy

- Smyslem je určit výšku a typ postižení

Effects of Spinal Injury



Level of Injury	Effect*
CERVICAL Between C1 and C5	Paralysis of some or all muscles used for breathing and all arm and leg muscles Typically, fatal unless a ventilator is used
Between C5 and C6	Paralysis of the legs, trunk, hand, and wrist Weakness of the muscles that move the shoulder and elbow
Between C6 and C7	Paralysis of the legs, trunk, and part of the wrists and hands Normal movement of the shoulders and elbows
Between C7 and C8	Paralysis of the legs, trunk, and hands
THORACIC C8 to T1	Paralysis of the legs and trunk Weakness of the muscles that move fingers and hands Horner's syndrome (with a drooping eyelid, a constricted pupil, and reduced sweating on one side of the face) Possibly normal movement of the shoulders and elbows
T2 to T4	Paralysis of the legs and trunk Loss of sensation below the nipples Normal movement of the shoulders and elbows
LUMBAR T5 to T8	Paralysis of the legs and lower trunk Loss of sensation below the rib cage
T9 to T11	Paralysis of the legs Loss of sensation below the navel
T11 to L1	Paralysis of and loss of sensation in the hips and legs
SACRAL L2 to S2	Various patterns of leg weakness and numbness, depending on the precise level of injury
S3 to S5	Numbness in the perineum

* At any level of the spinal cord, severe injury can cause loss of bladder and bowel control.

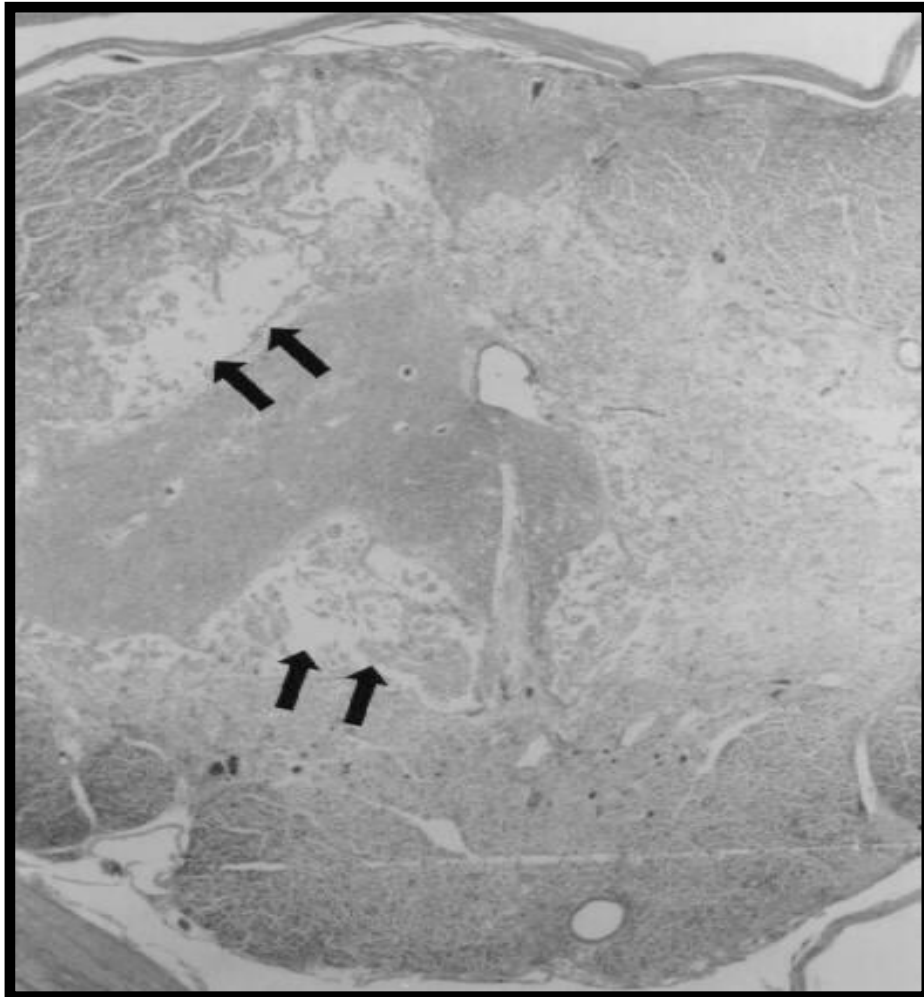
Poranění míchy /spinal cord injury/

- **poranění míchy /PM/** - poškození míchy způsobující dočasné a/nebo trvalé změny motorických, senzorických, a nebo autonomních funkcí míchy.
- typ :
 - primární,
 - sekundární
- rozsah :
 - kompletní
 - parciální

Primární poranění míchy

- primárně PM – přímo úrazovým dějem.
- Není možné ho ovlivnit
 - komprese míchy kostnými fragmenty, hematodem, intervertebrálním diskem
 - Torze, distrakce , stříh nepříznivá prognóza
 - ischemie
 - Penetrující poranění

Sekundární poranění míchy



- Cévní změny:
 - Snížený průtok
 - trombóza
 - vazospazmus
 - hemorrhagia
- elektrolytové změny
- volné O₂ radikály
- Zánětlivá reakce
- výsledkem je nekróza neuronů

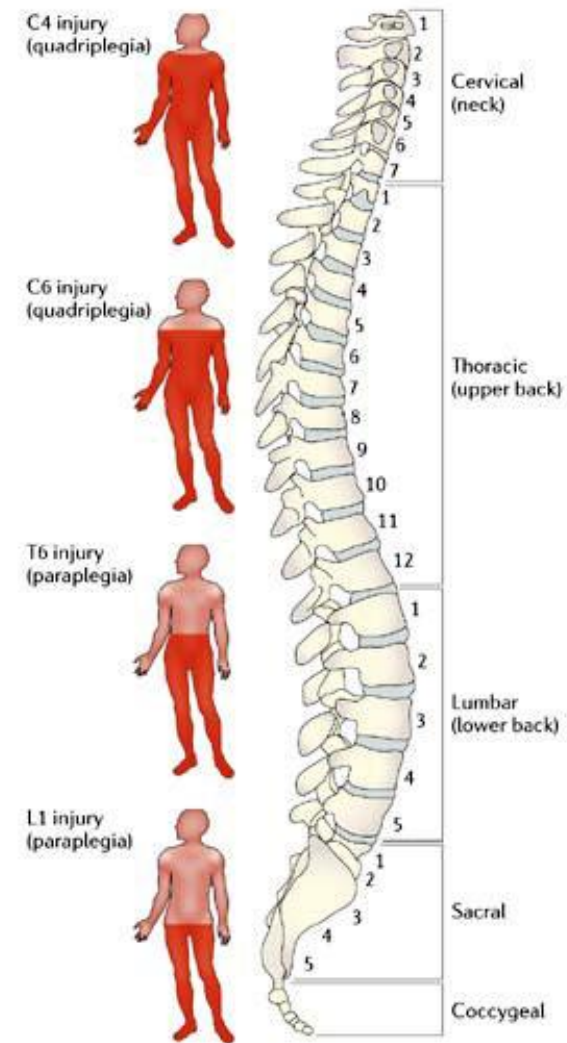
Sekundární poranění míchy

- vzniká jako následek primárního postižení
- **je částečně ovlivnitelné a to je i cílem léčby a našeho snažení !**
- možnosti jeho ovlivnění :
 - oxygenace, optimální Tk
 - *farmakologická léčba /kortikoidy ???/*
 - *chirurgická léčba /dekomprese míchy, stabilizace páteře/*

Typy poranění míchy

/spinal cord injury/

- **kompletné léze** /podle výšky poranění/
 - cervikální tetraplegie
 - hrudní paraplegie
- **parciální lézi** /např./
 - anterior cord sy.
 - central cord sy.
 - Brown-Sequard sy.
 - posterior cord sy.
 - conus medullaris
 - cauda equina sy.



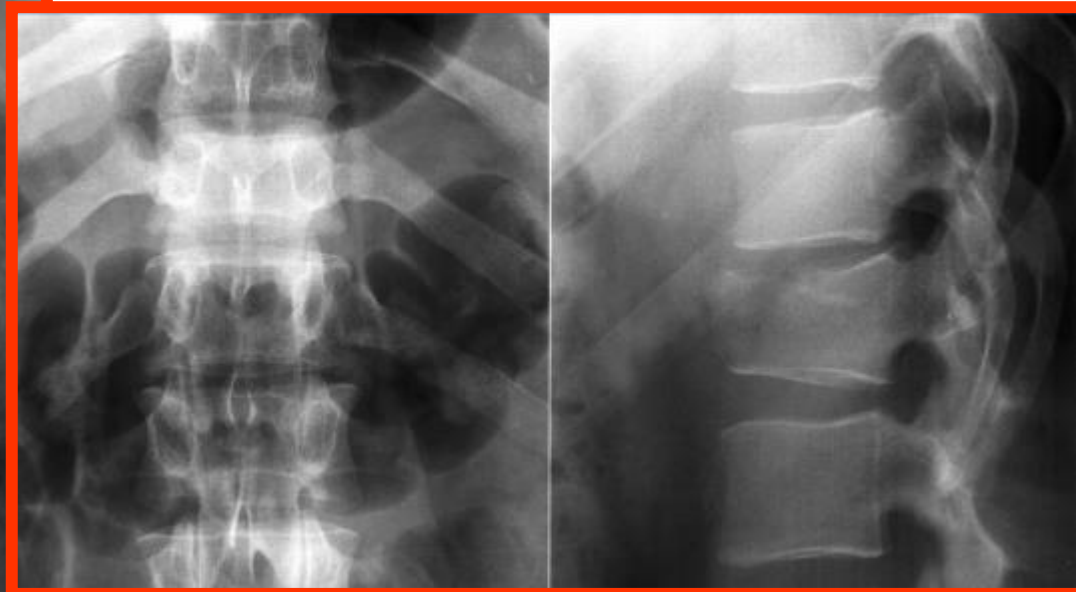
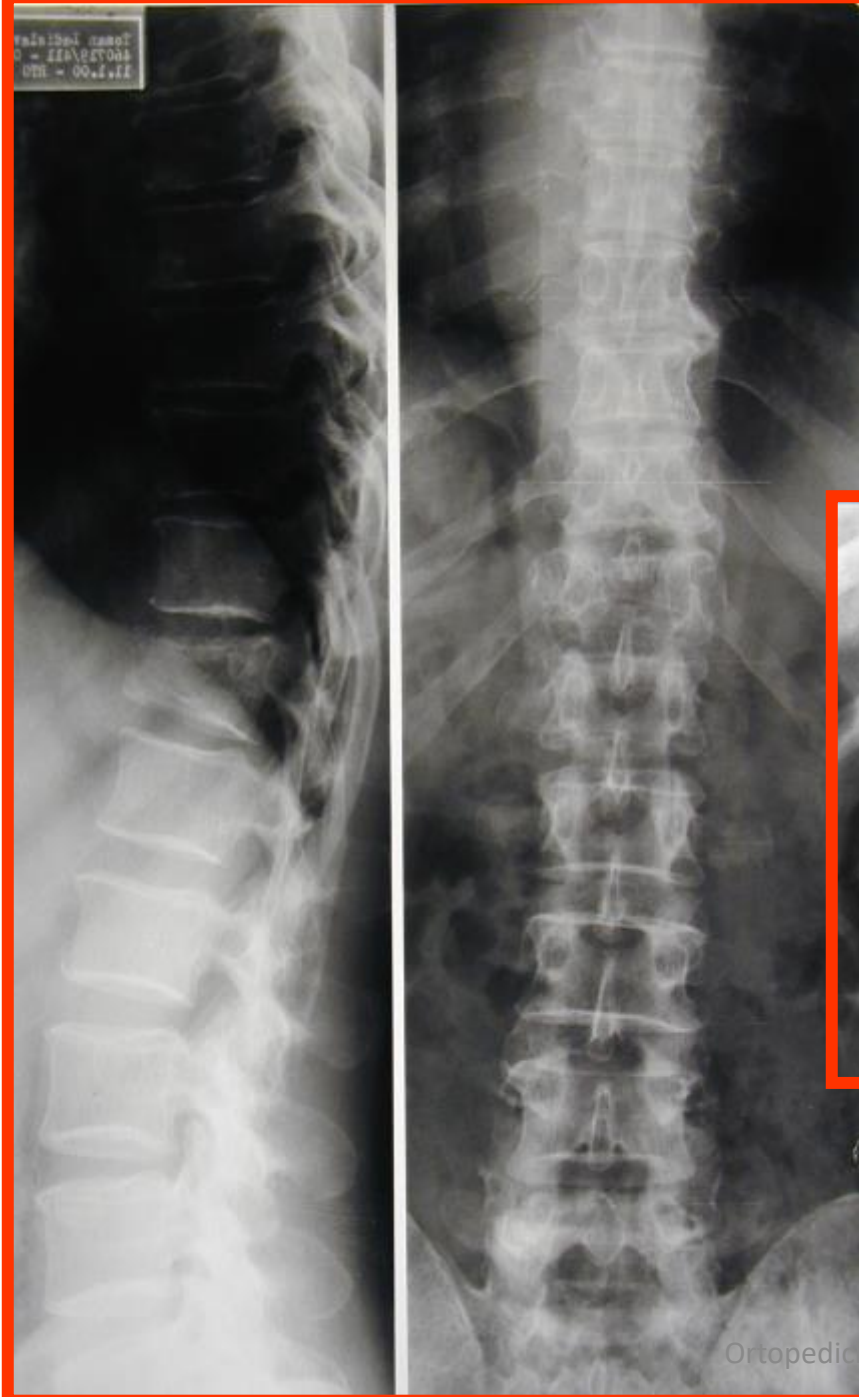
Frankelova klasifikace Neurologického deficitu

- A** **kompletní výpad motoriky i sense**
- B** **motorika chybí, sense zachována**
- C** **zachována neužitečná motorika**
- D** **jistý deficit motoriky**
- E** **normální neurologický nález**

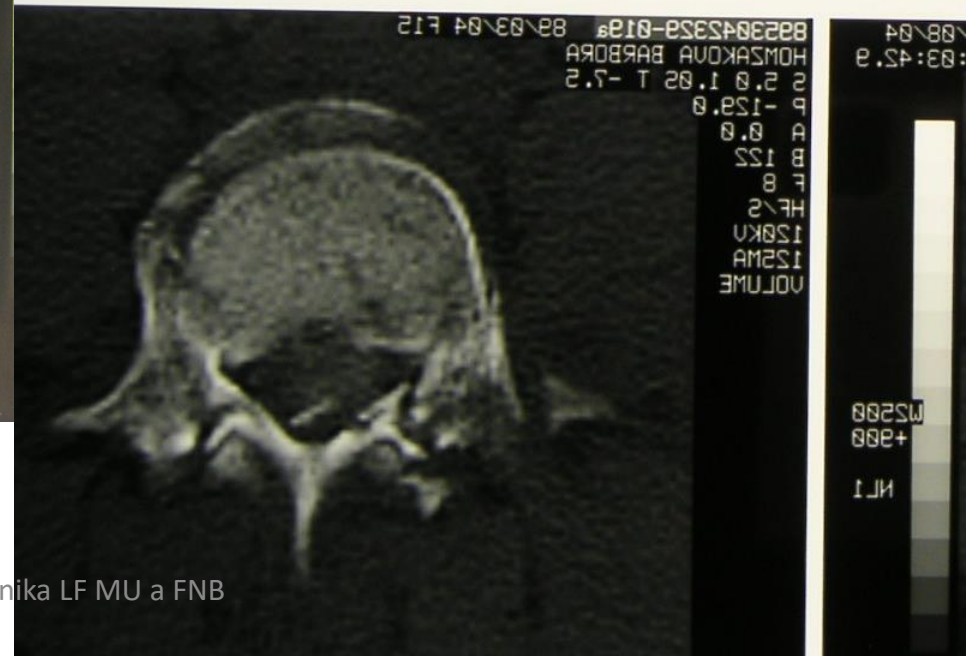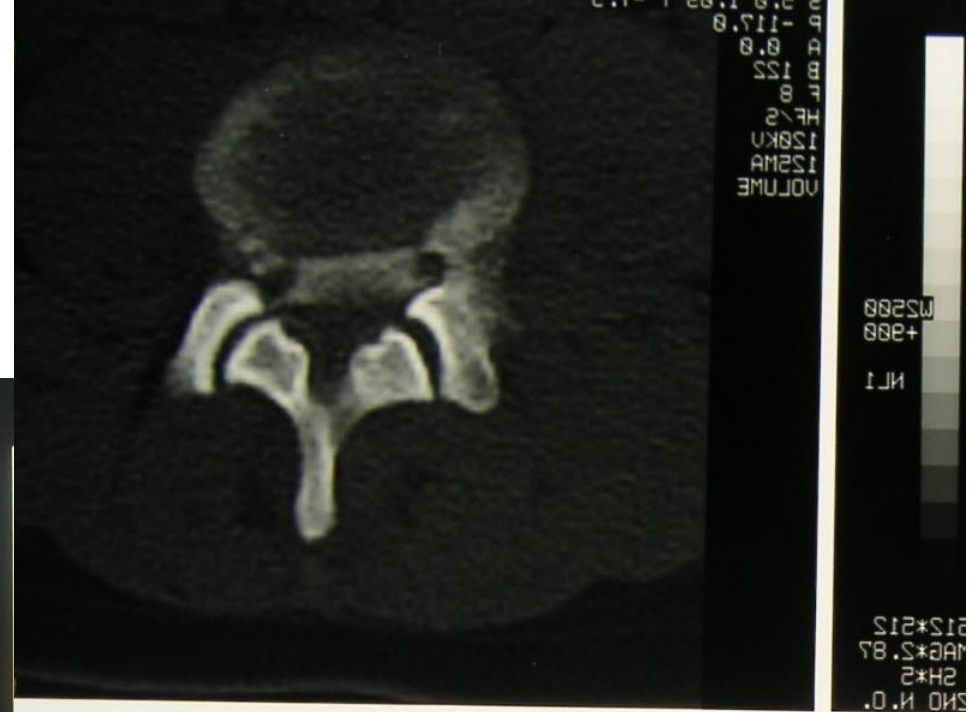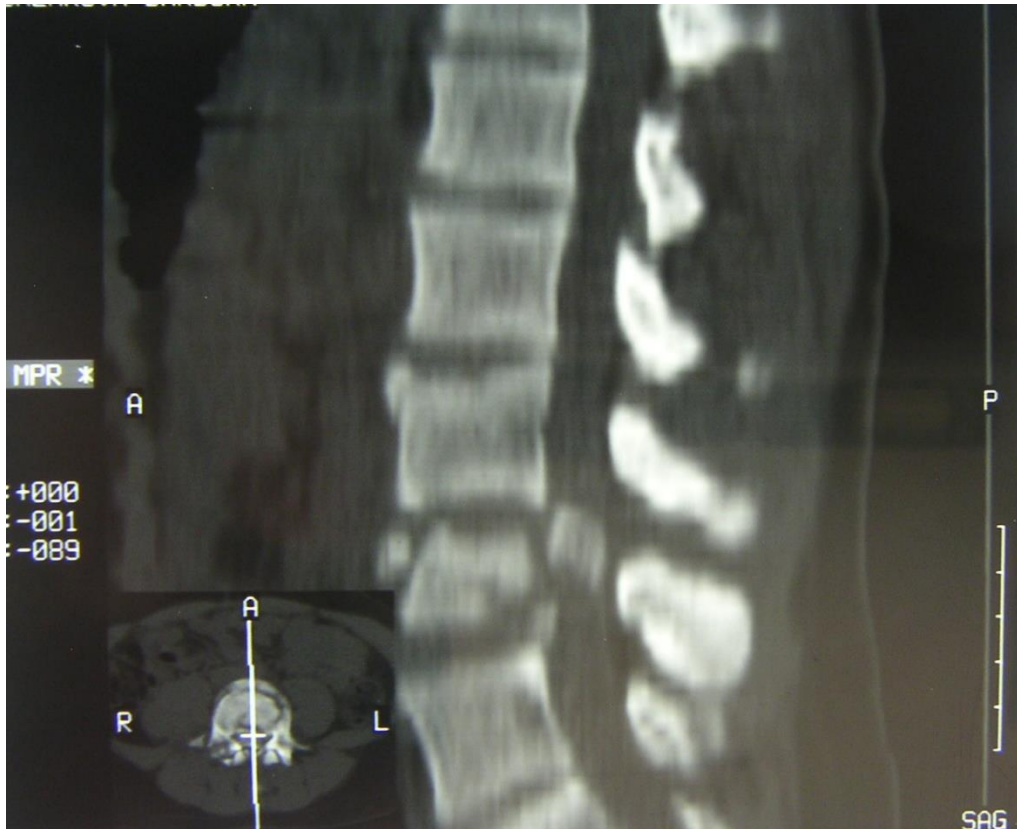
VYŠETŘENÍ

- **Anamnéza**
- **Klinické vyšetření**
- **RTG**
- **Neurologie**
- **CT**
- **MRI**

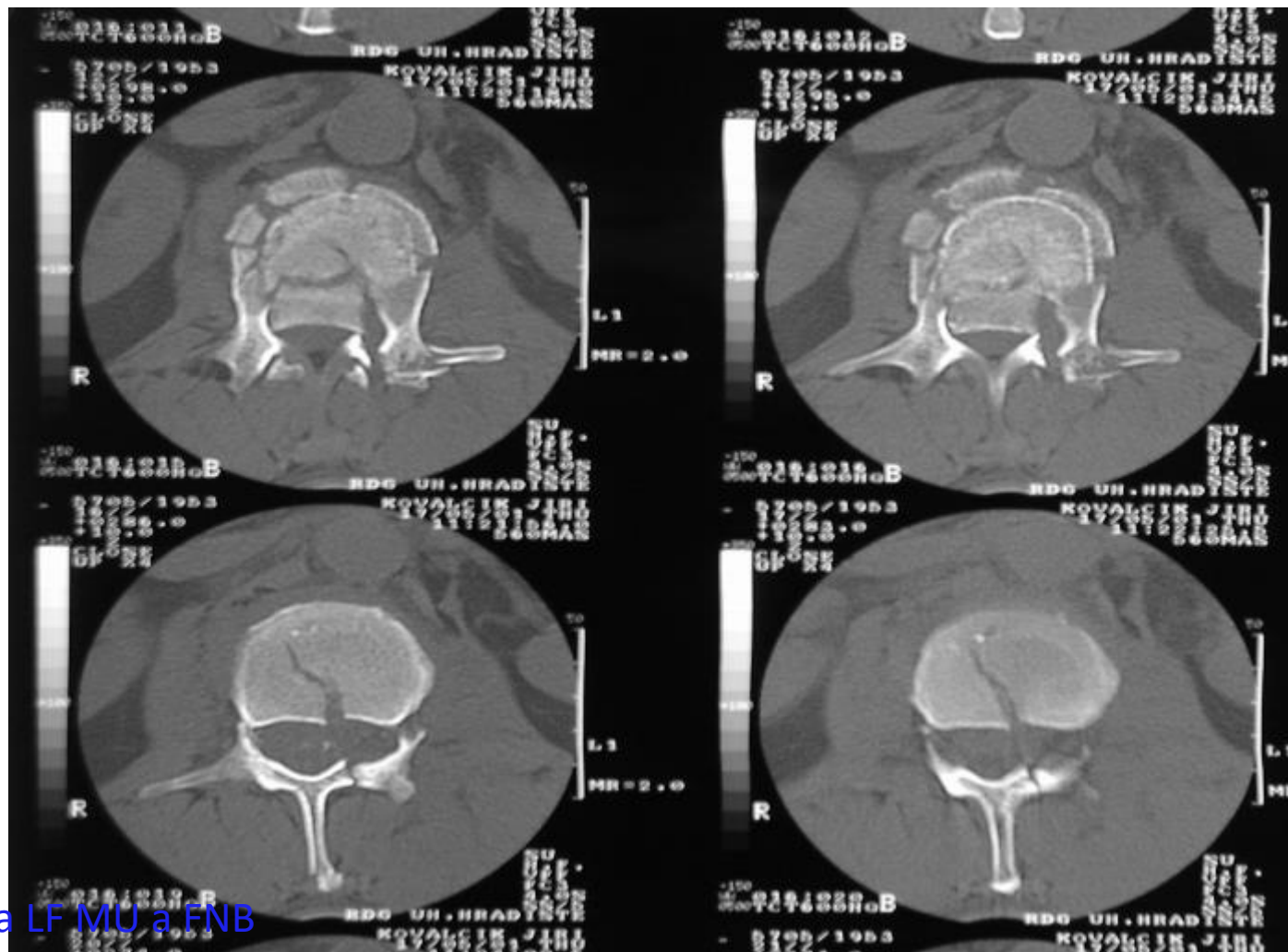
RTG

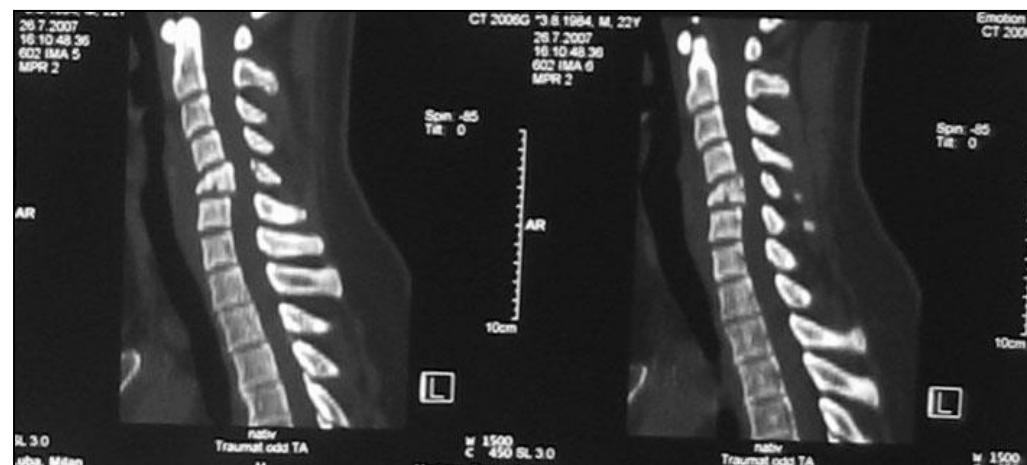
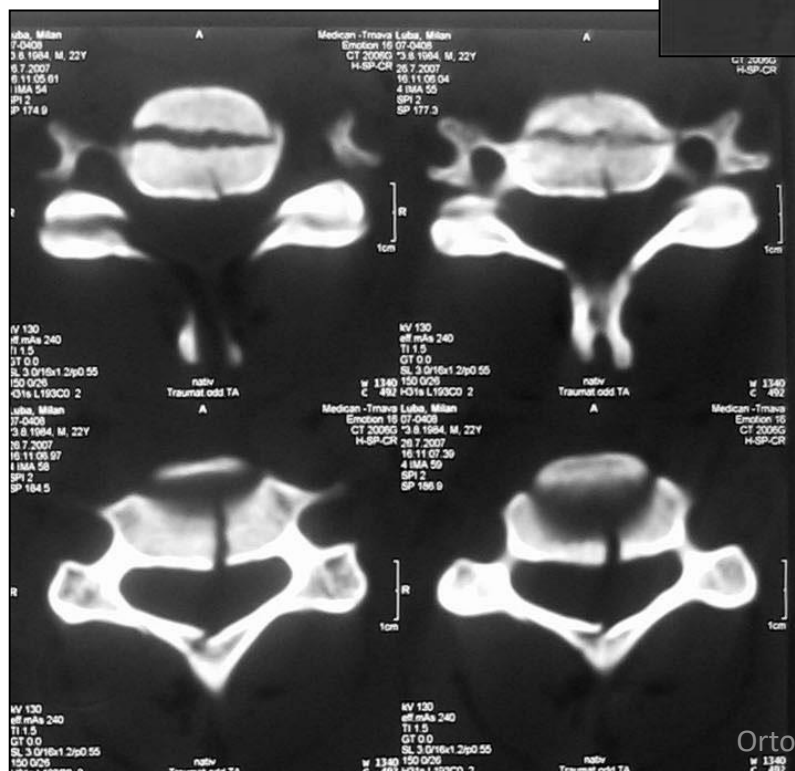
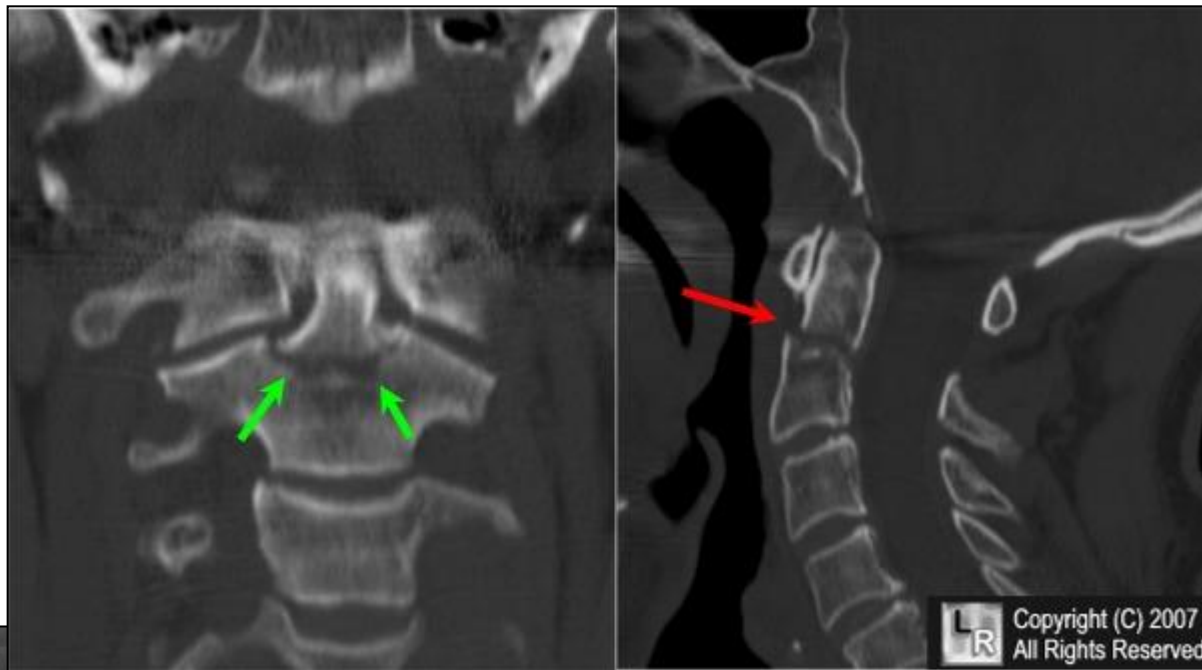


CT

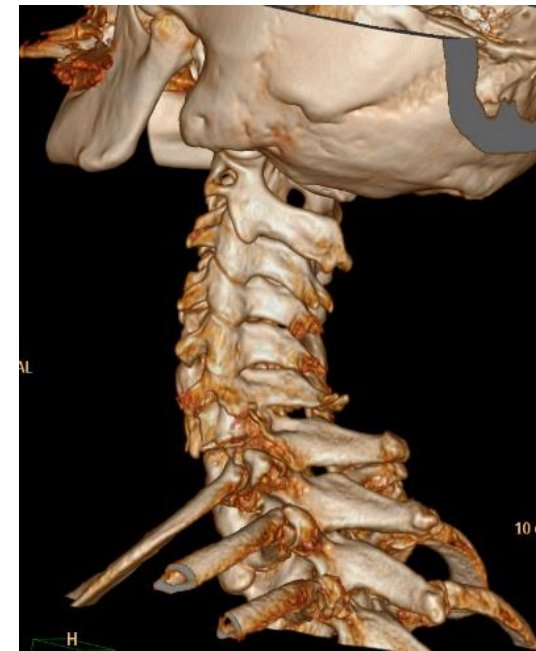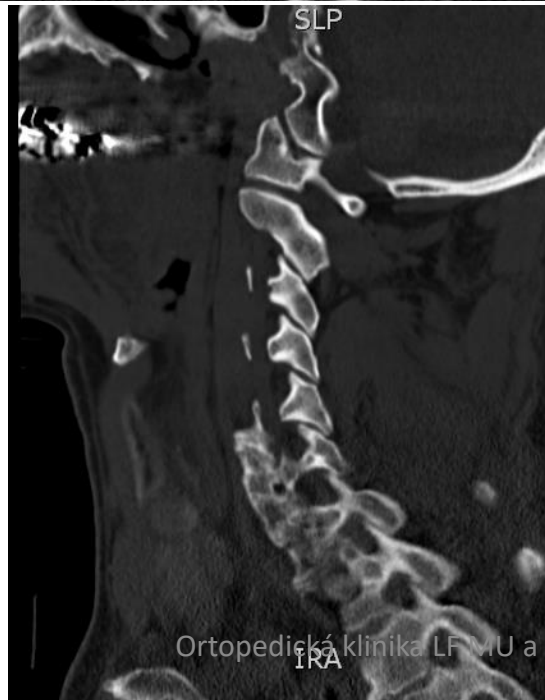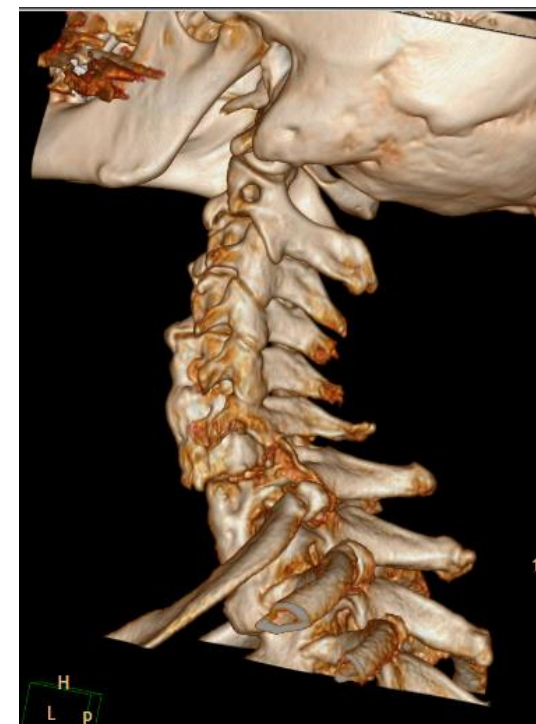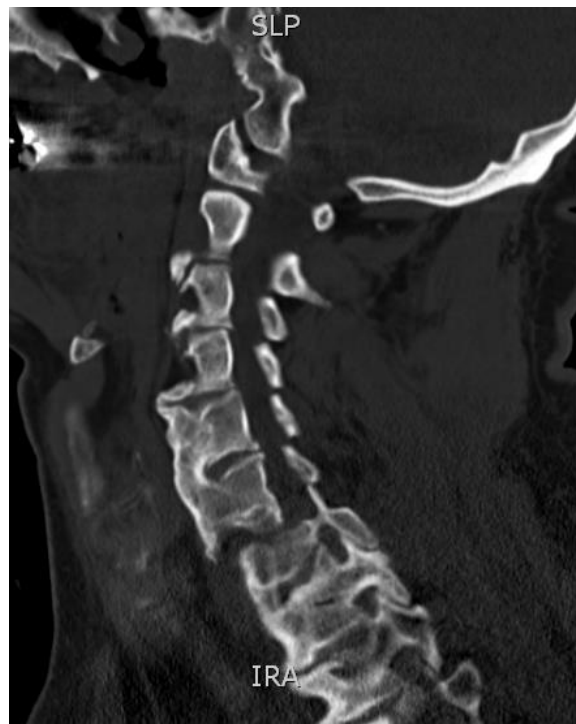


CT

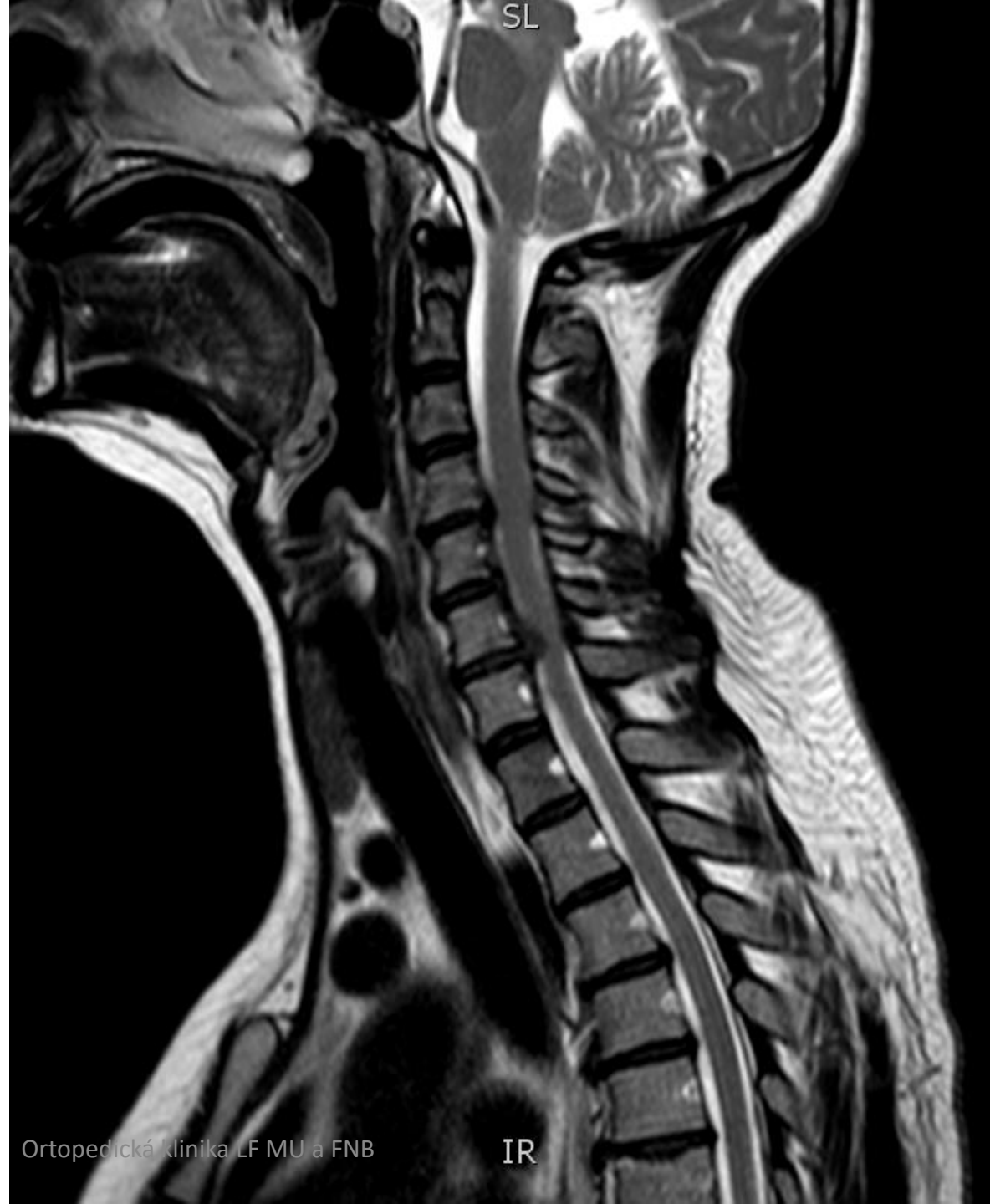
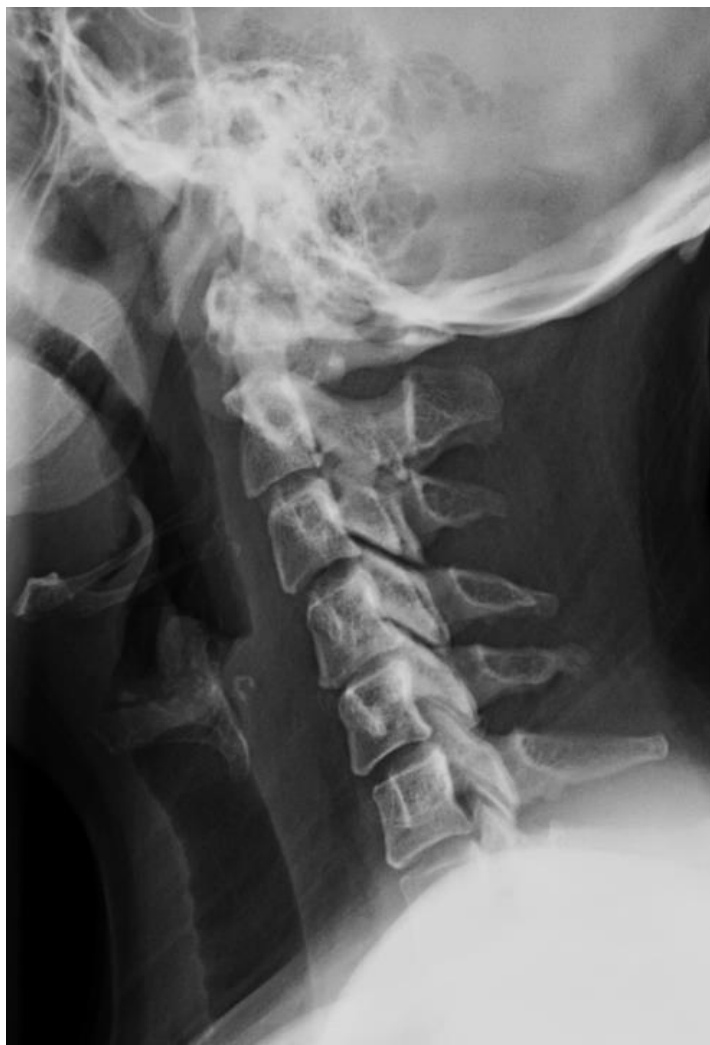


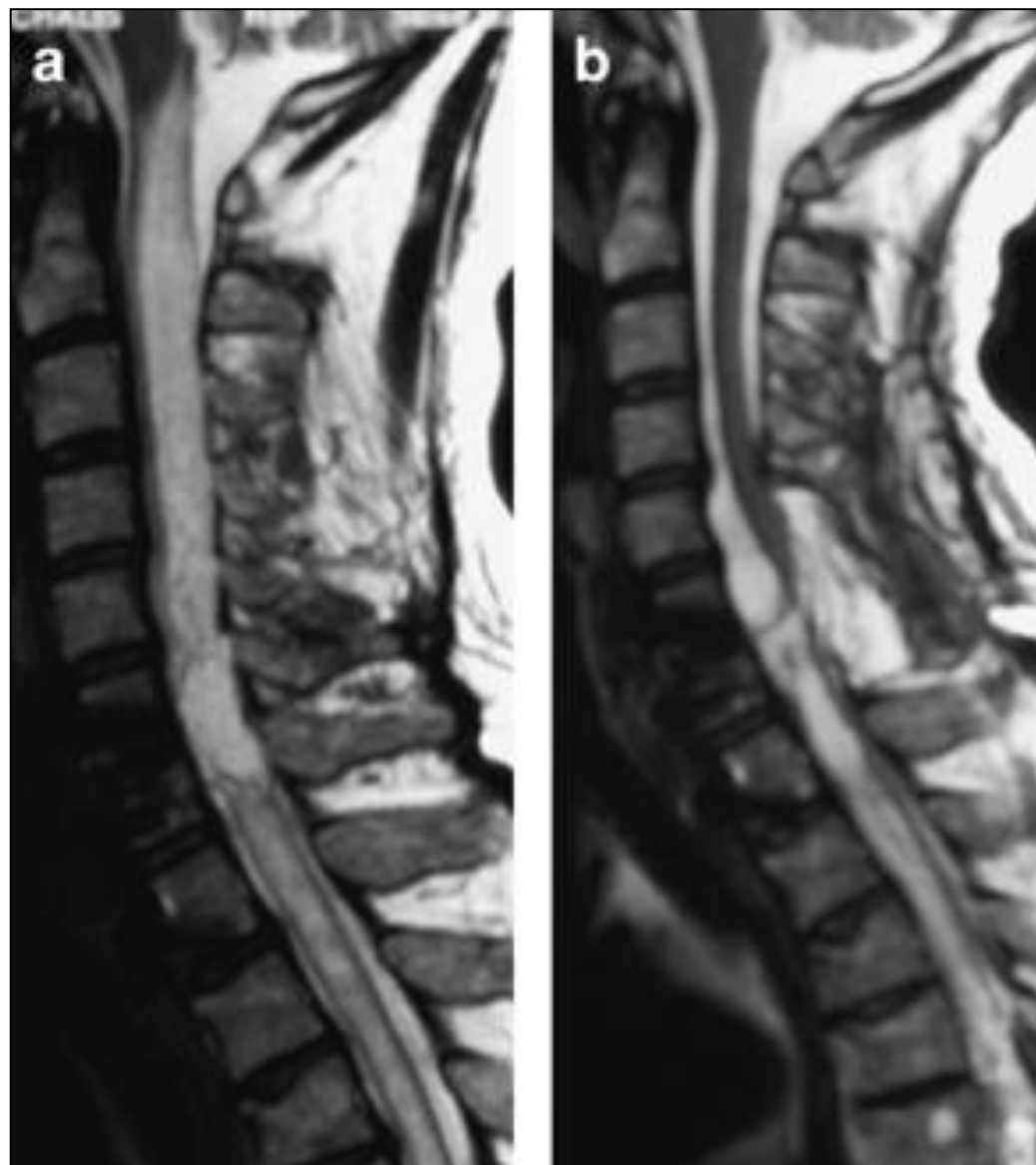3D CT

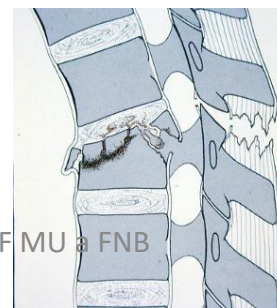
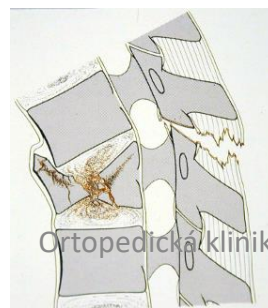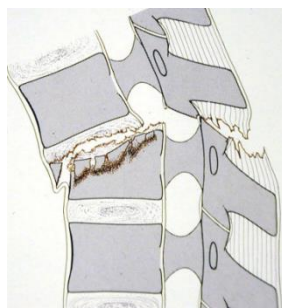
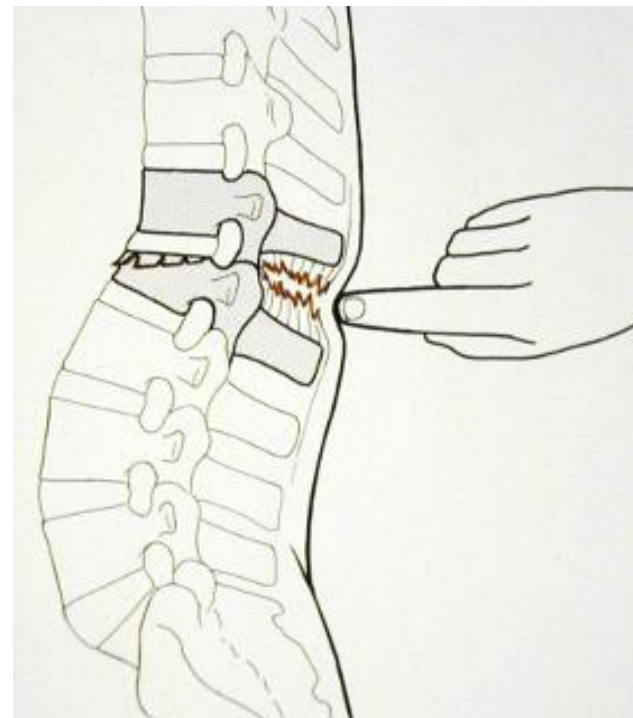

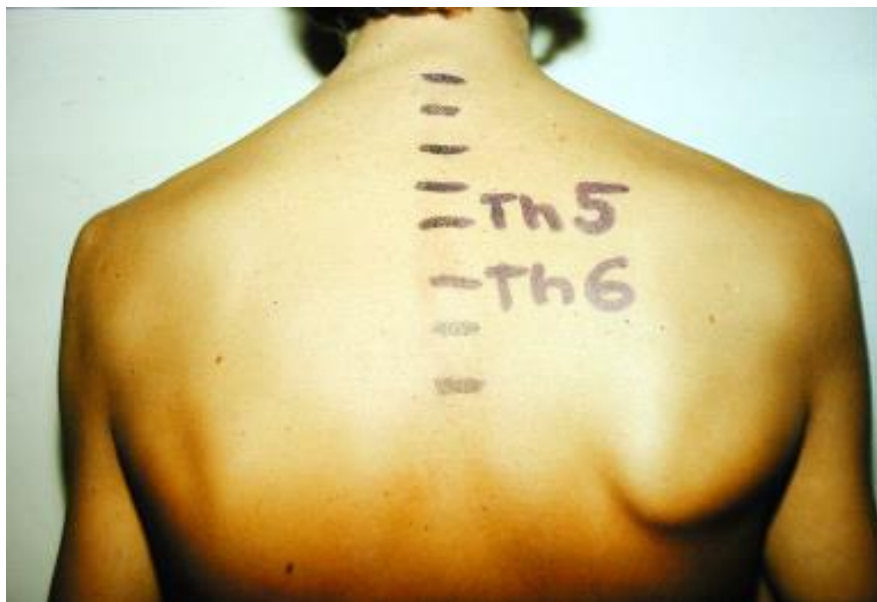
MRI





KLINICKÉ VYŠETŘENÍ



CÍLE TERAPIE

- **NEBOLESTIVOST**
- **FUNKČNOST**
- **STABILITA**

TERAPIE

- konzervativní
 - ortesy, korzety
 - klid na lůžku
- operační
 - *Dekomprese, uvolnění míchy a nervových struktur*
 - *zadní výkony*
 - *přední výkony*
 - kombinované

PRVNÍ POMOC

- FIXACE KRČNÍ PÁTEŘE
- PŘI MANIPULACI VYLOUČIT POHYB T A L PÁTEŘE
- SPINÁLNÍ JEDNOTKA

„Log-roll“ manévr

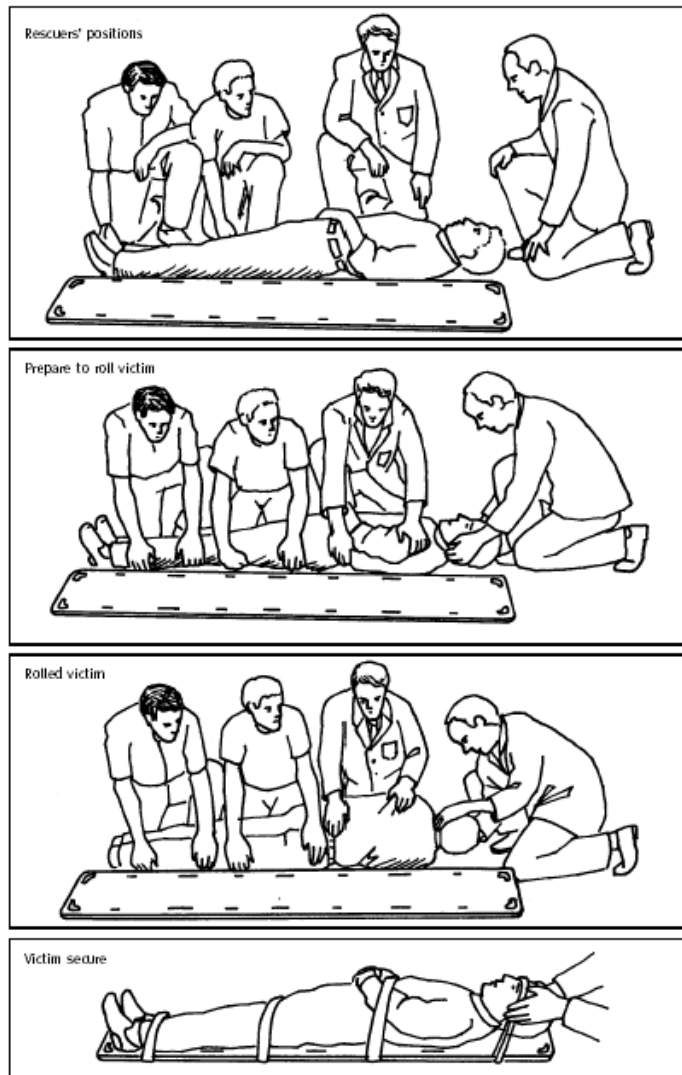
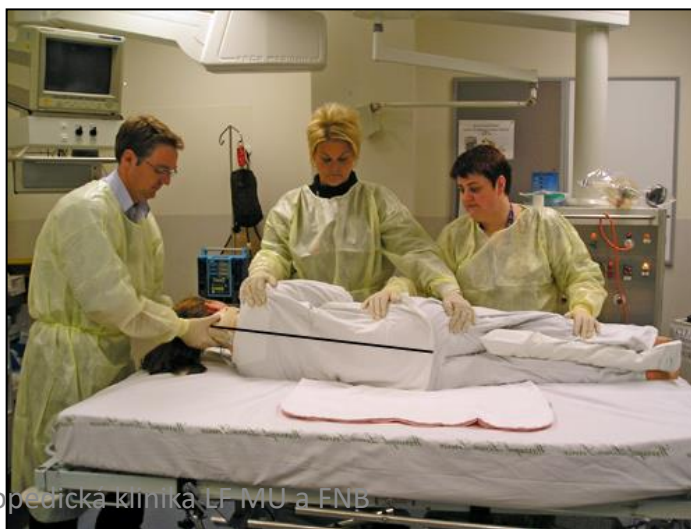
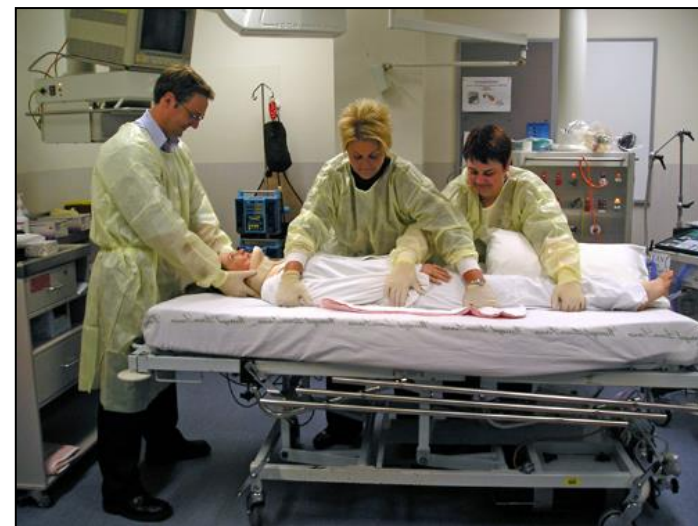
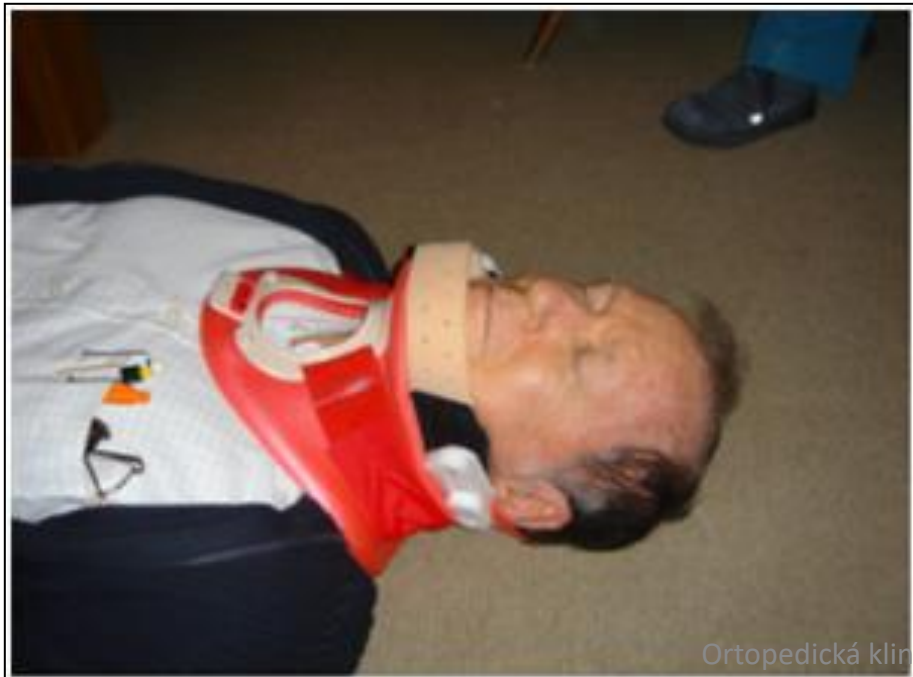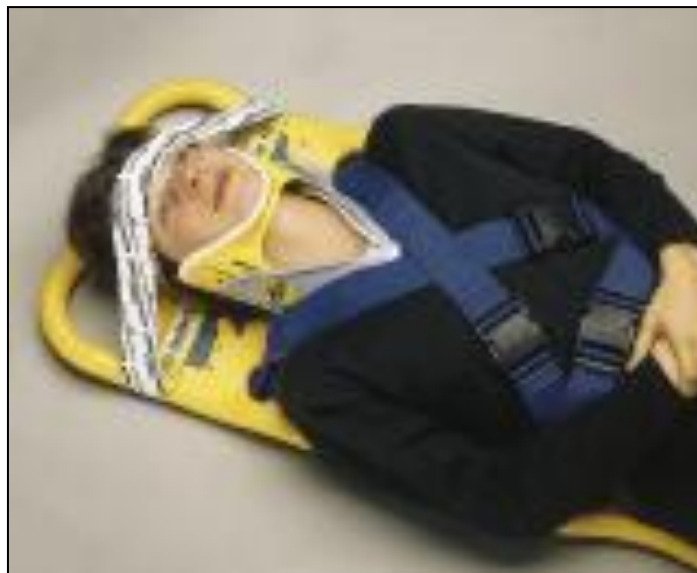Figure 12.4: Rollover technique using spine board

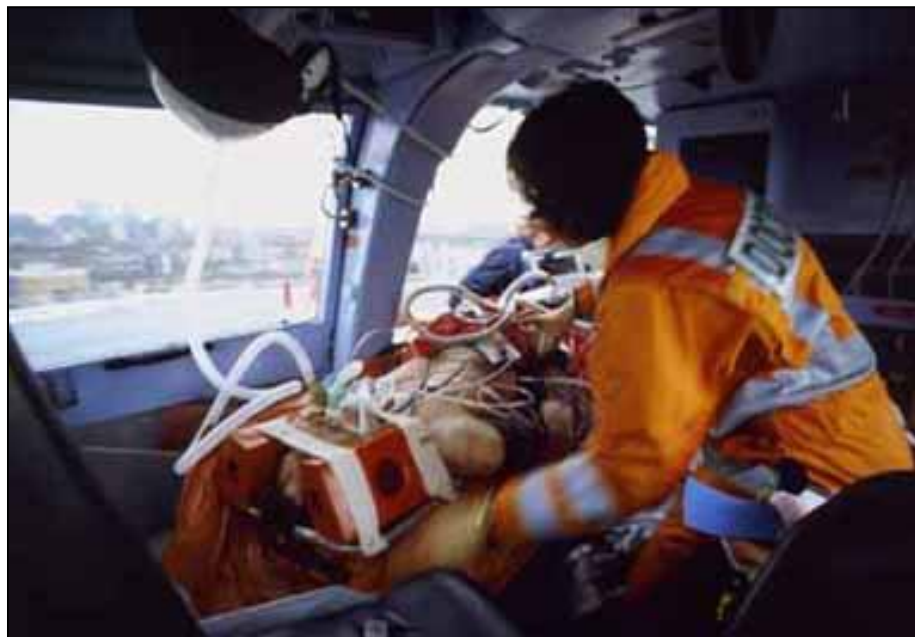

Imobilizace páteře + transport

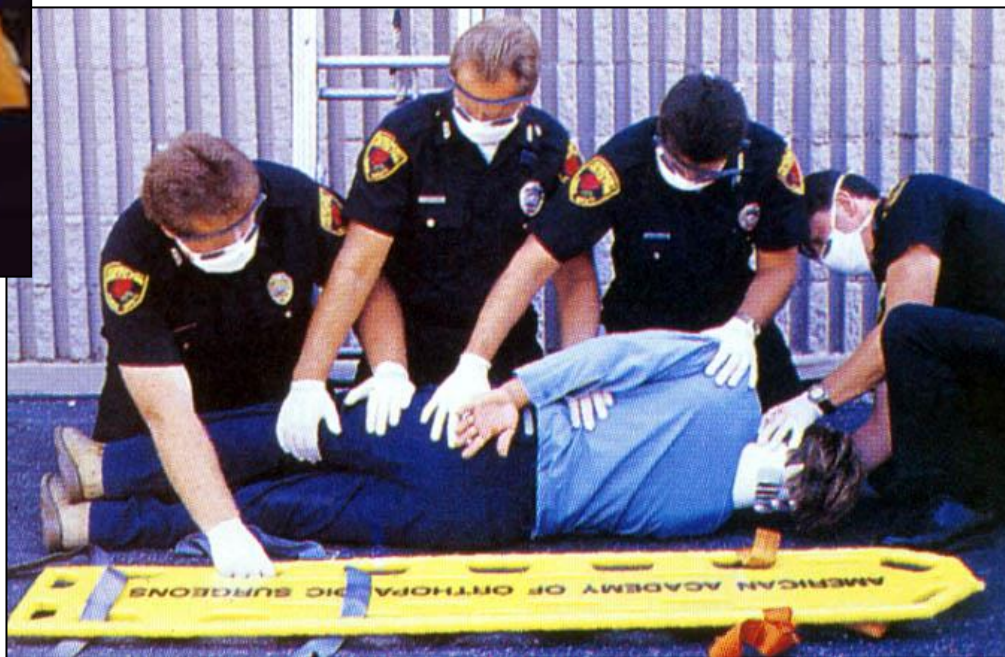- „*in line position*“
- **fixace C páteře**
 - tvrdý krční límec /25-30% pohyblivosti/
 - stranová opora hlavy /5-10% pohyblivosti/
- Fixace hlavy
- Fixace trupu a končetin
- Transportní podložka
 - „back board“ **!!! riziko vzniku dekubitů**
 - vákuová matrace – šetrnější při delším transportu



Imobilizace páteře + transport



- Omezit manipulaci s pacientem na minimum!
- „in line“ poloha





Ortopedická klinika LF MU a FNB

TERAPIE

- **KONZERVATIVNÍ vs. OPERAČNÍ**
 - TYP ZLOMENINY
 - STUPEŇ INSTABILITY
 - NEUROLOGICKÝ NÁLEZ

KONZERVATIVNÍ LÉČBA

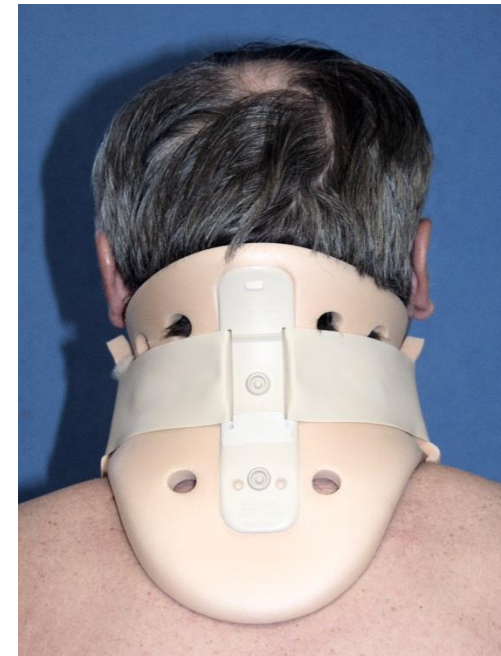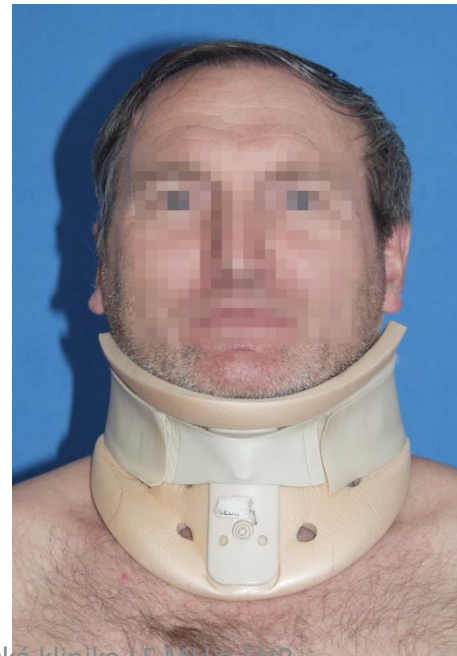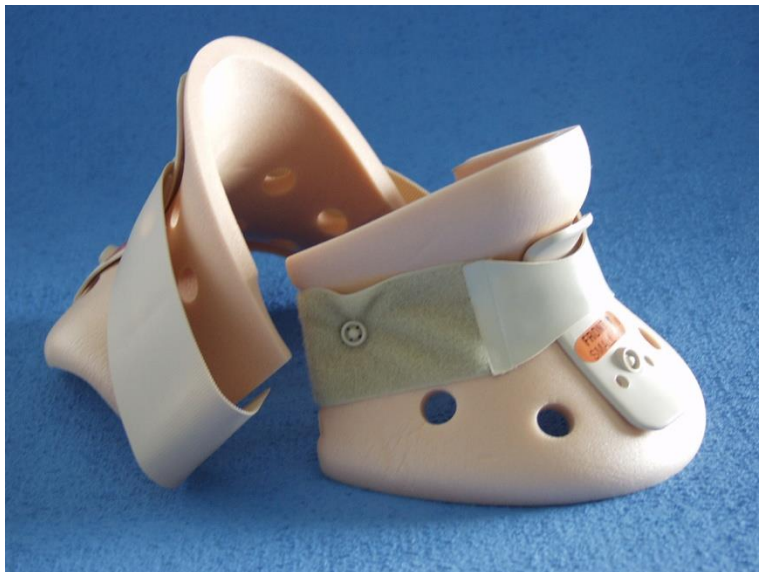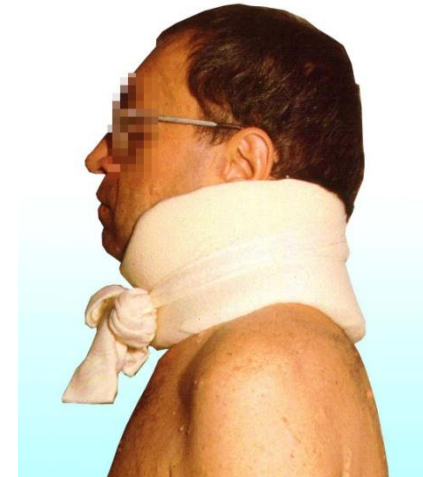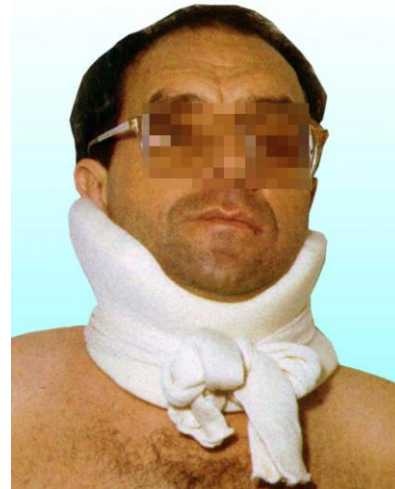- žádná nestabilita
- pouze nestabilita v kostěné části
- žádné poranění důležitých vazů či disků

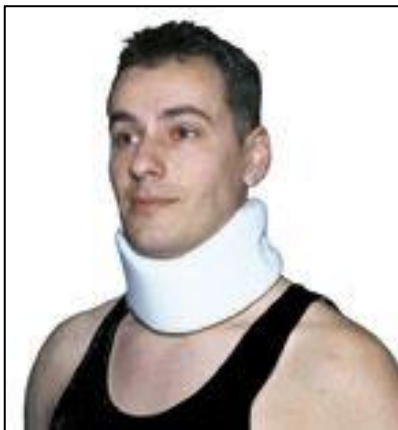INDIKACE OPERACE

- NEUROLOGICKÝ DEFICIT
 - Nutná časná operace do 6hod
- NESTABILITA PÁTEŘE

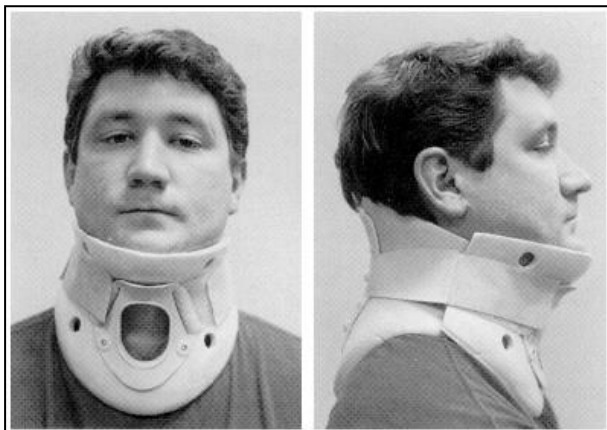
KONZERVATIVNÍ LEČENÍ

- Klidový režim
- Límce - molitanový
-Philladelphia

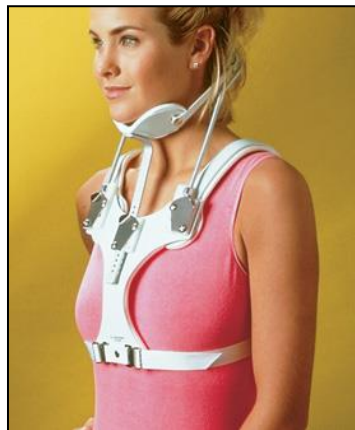



100 %



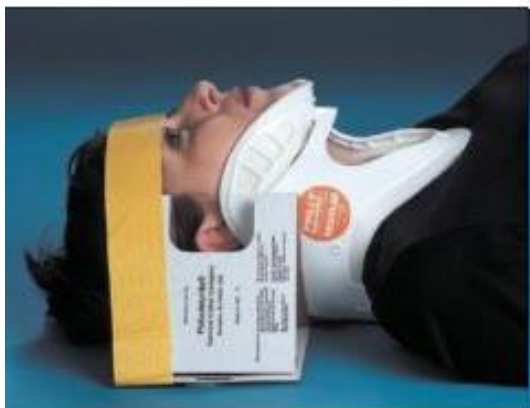40-45 %



30-35 %



5-10 %



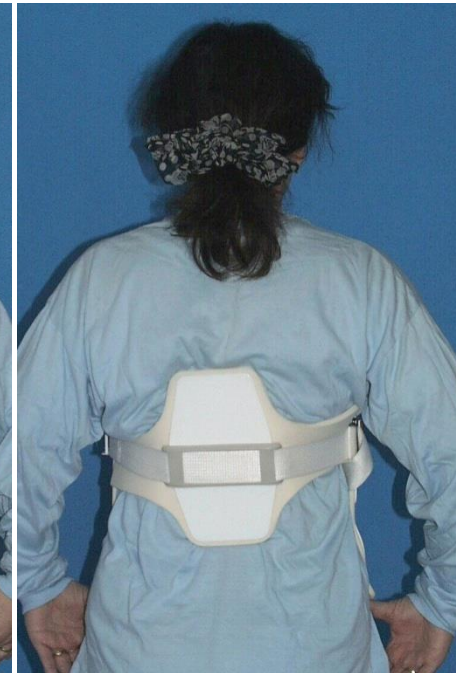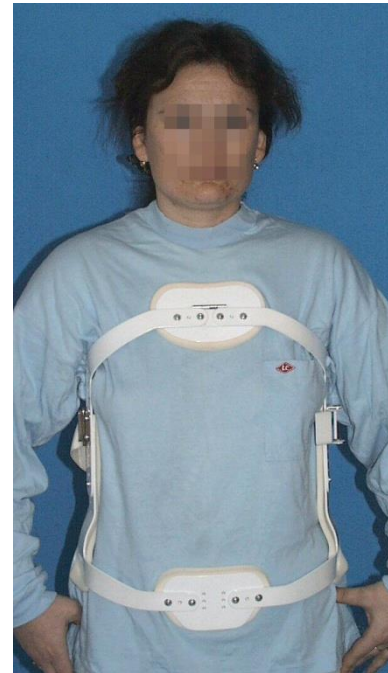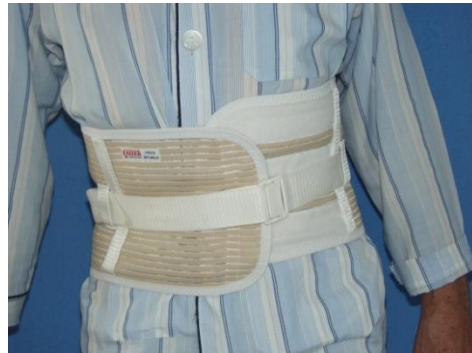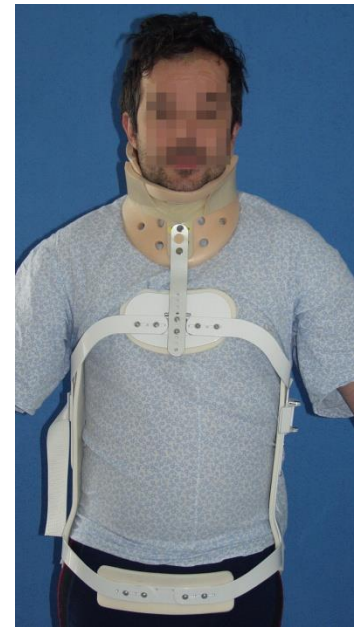KONZERVATIVNÍ LEČENÍ

T páteř

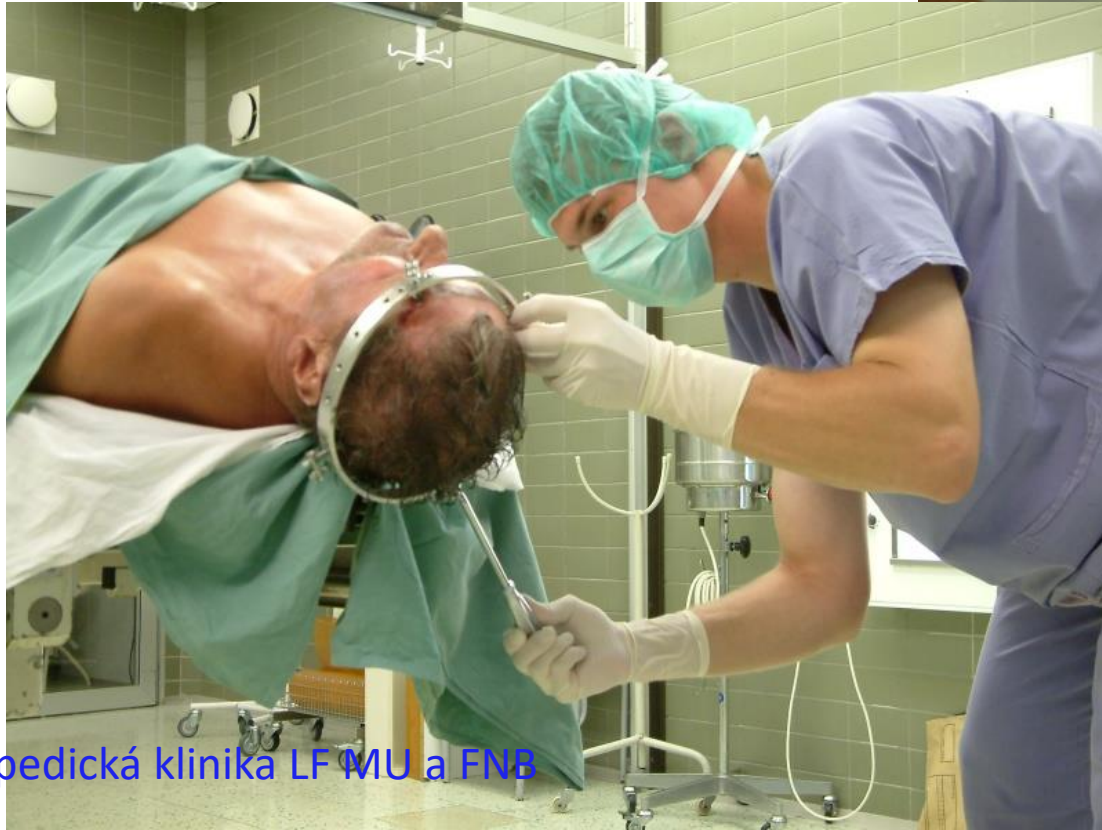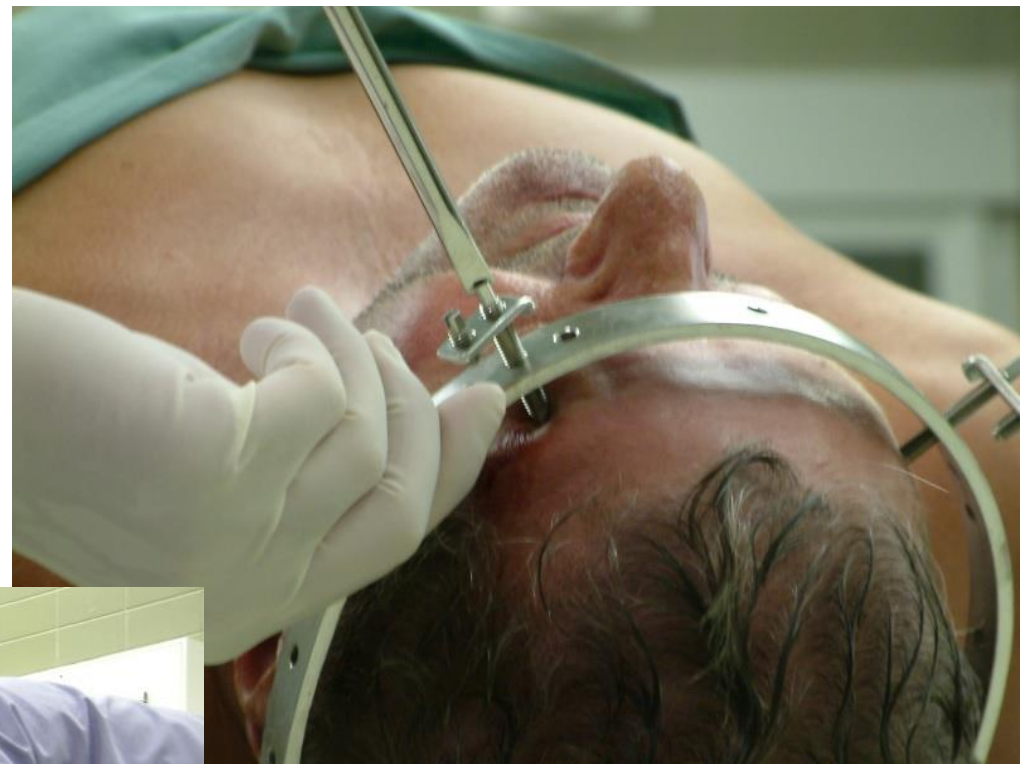- Jewetova ortesa

LS páteř

- Jewetova ortesa
- bederní pás



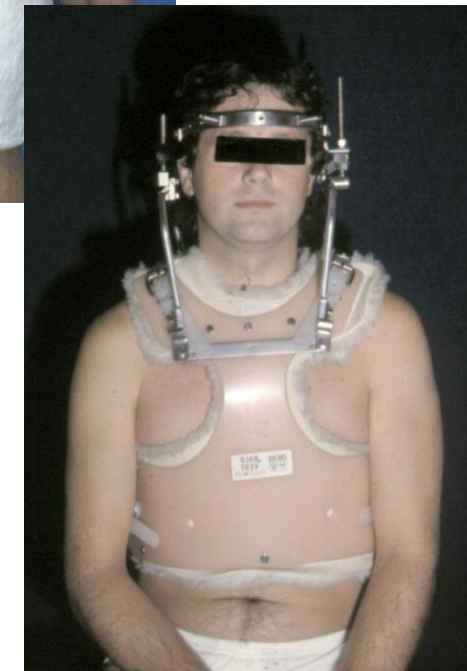
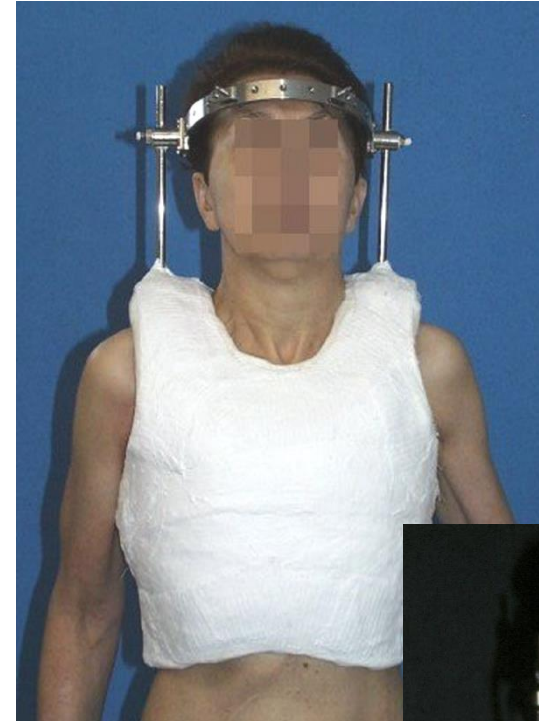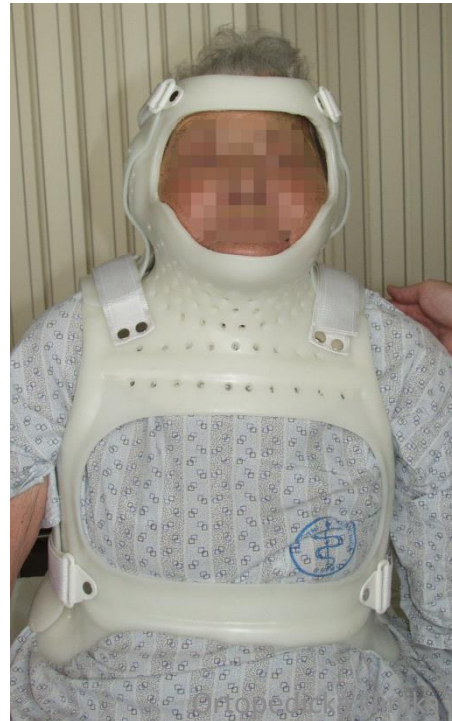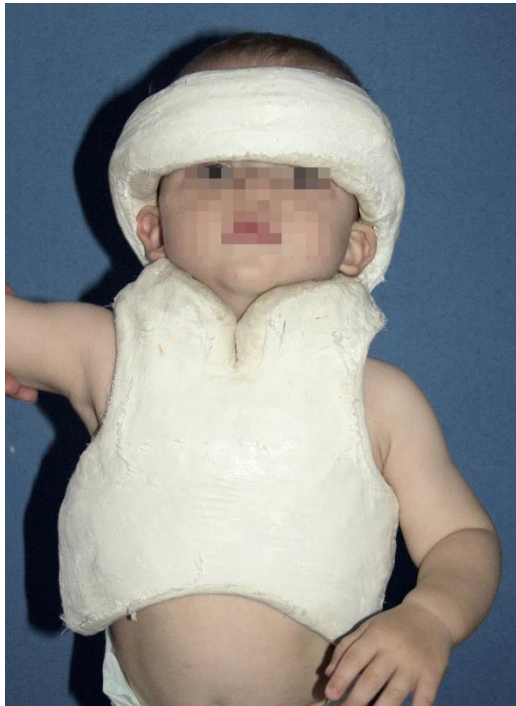HALO TRAKCE

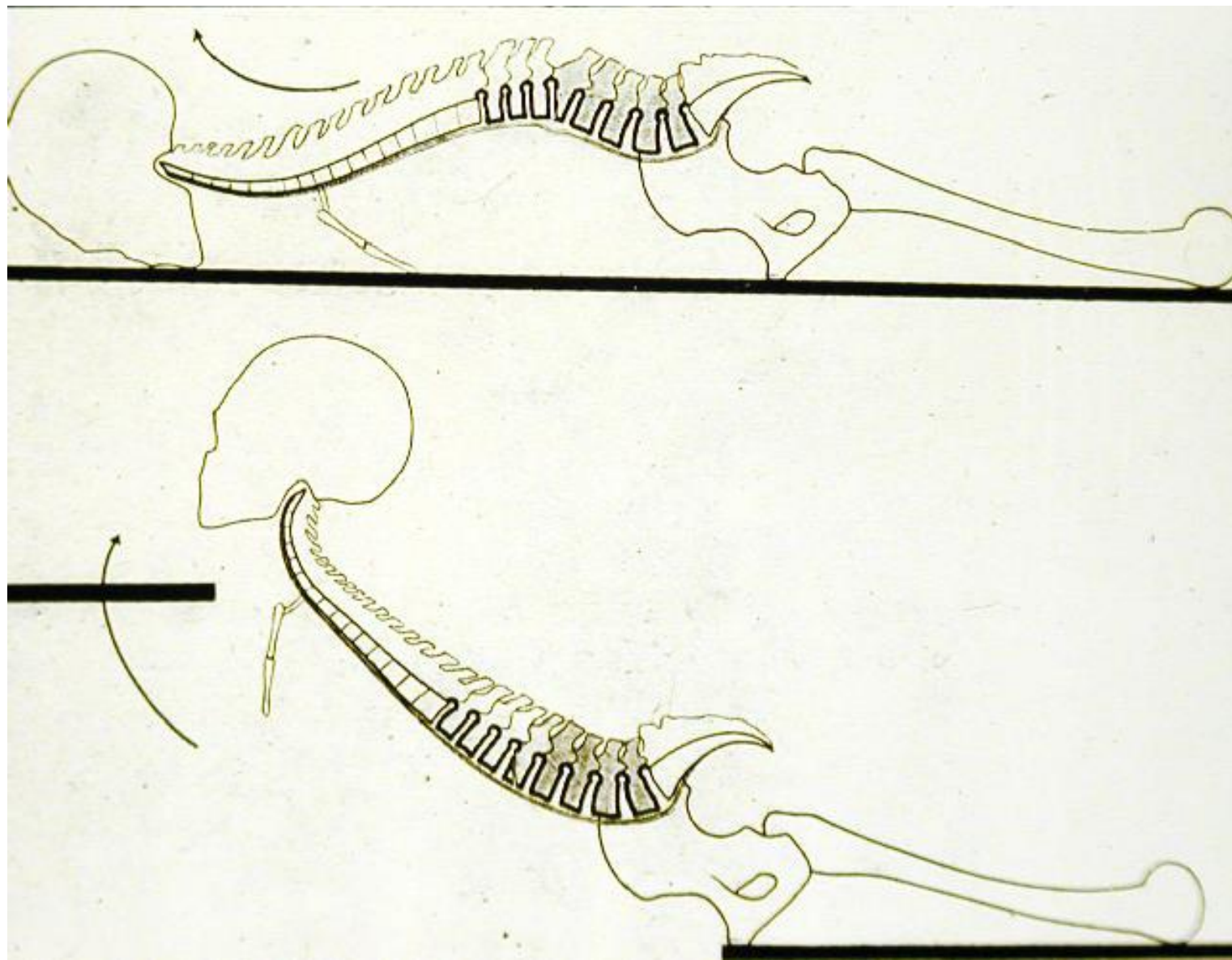


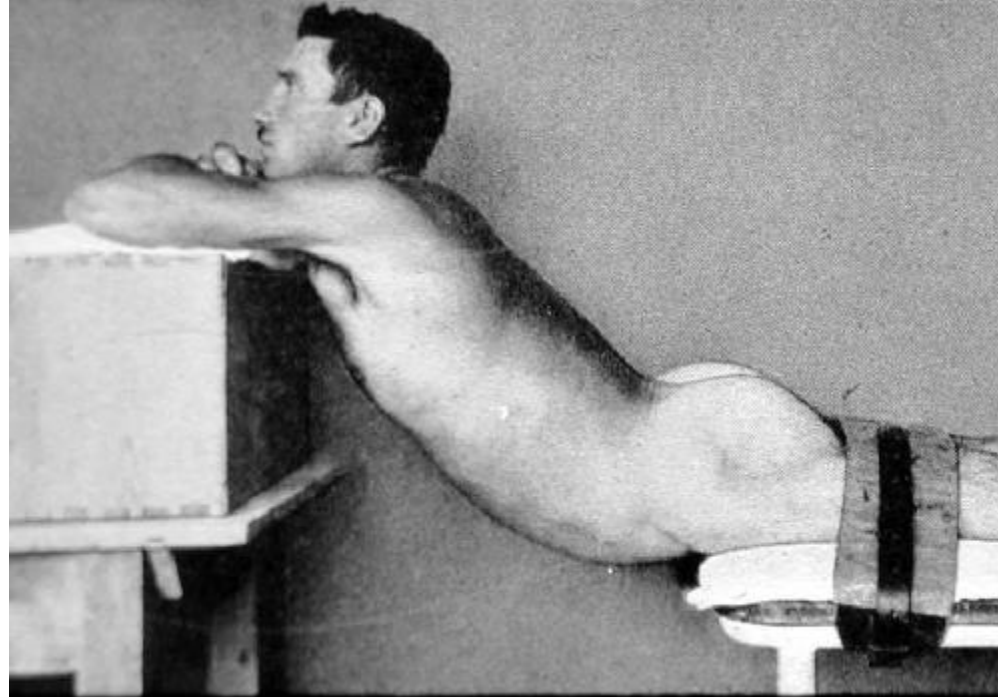
KONZERVATIVNÍ LEČENÍ-sádrové korzety

C páteř

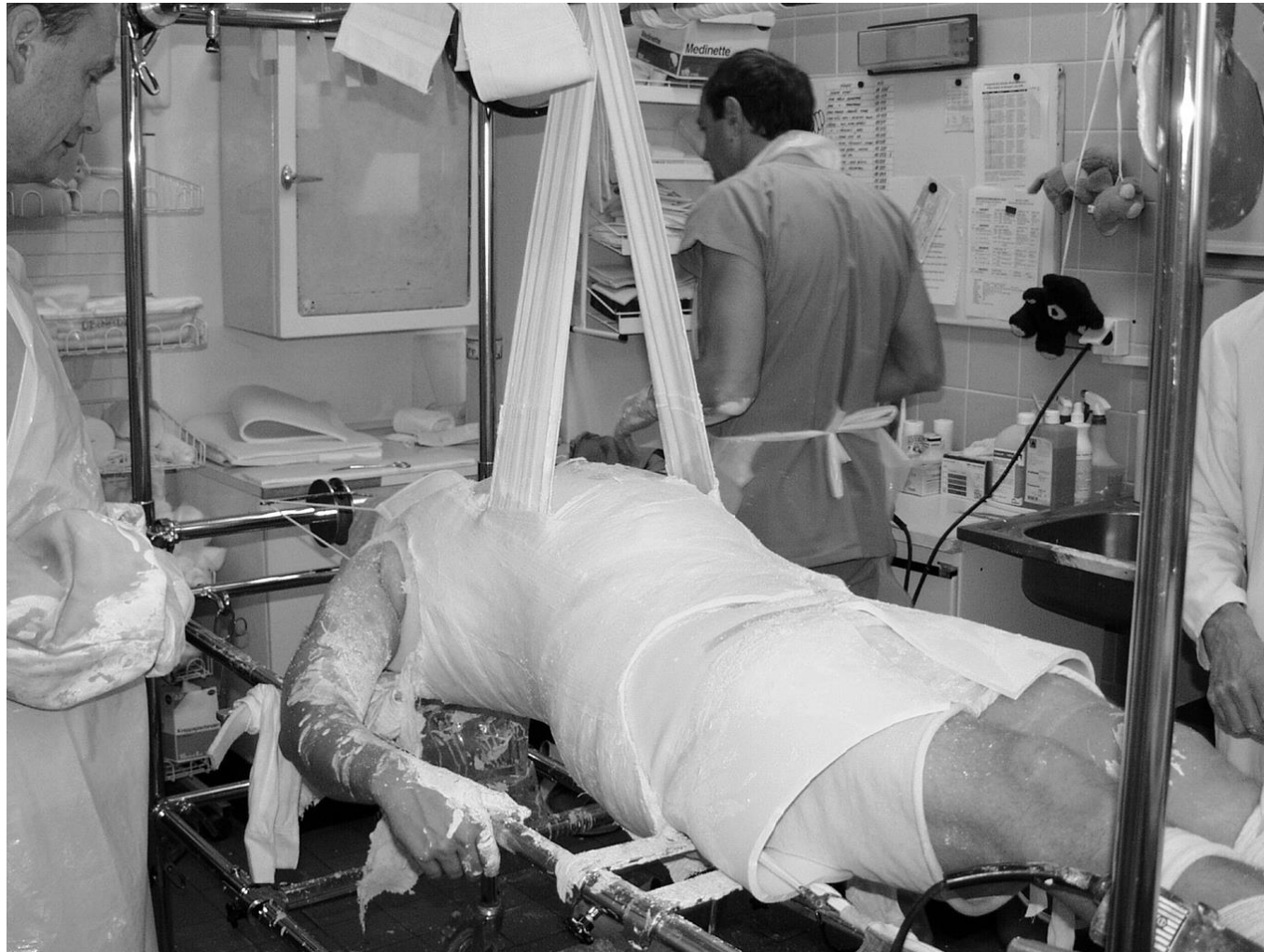- halo-cast, halo-vest
- Minerva

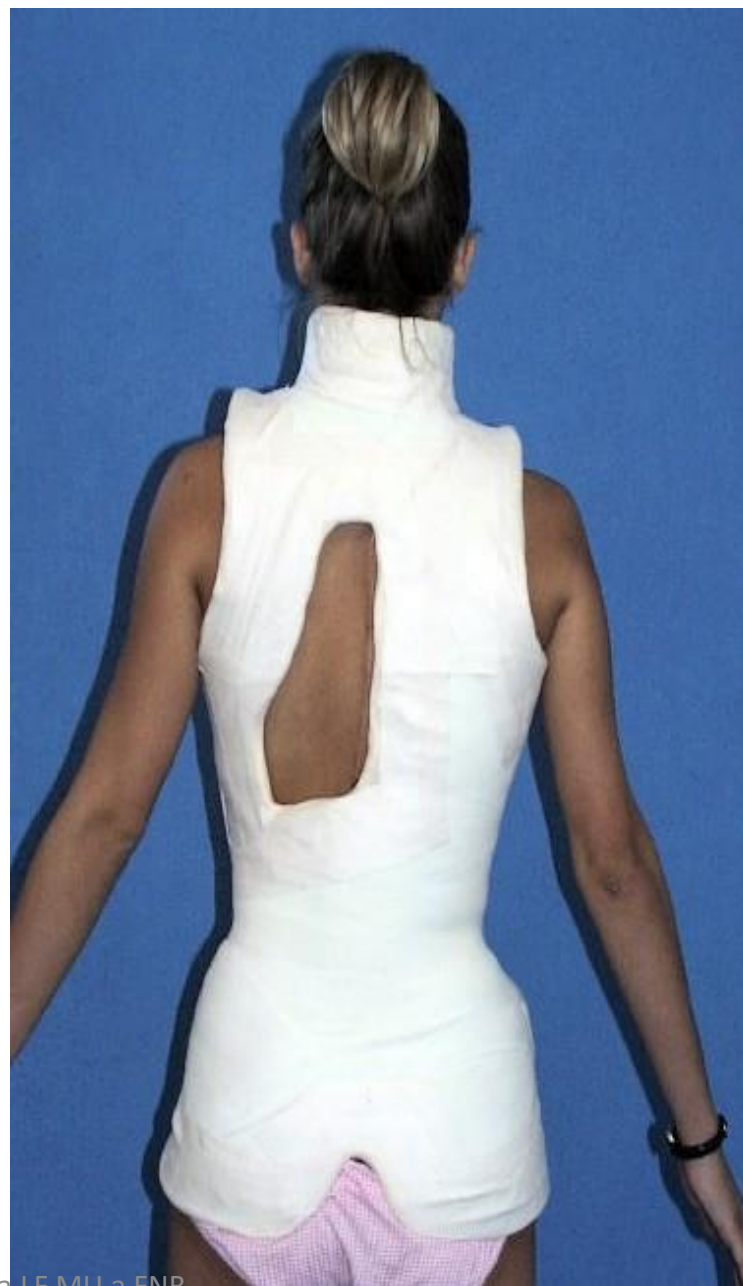
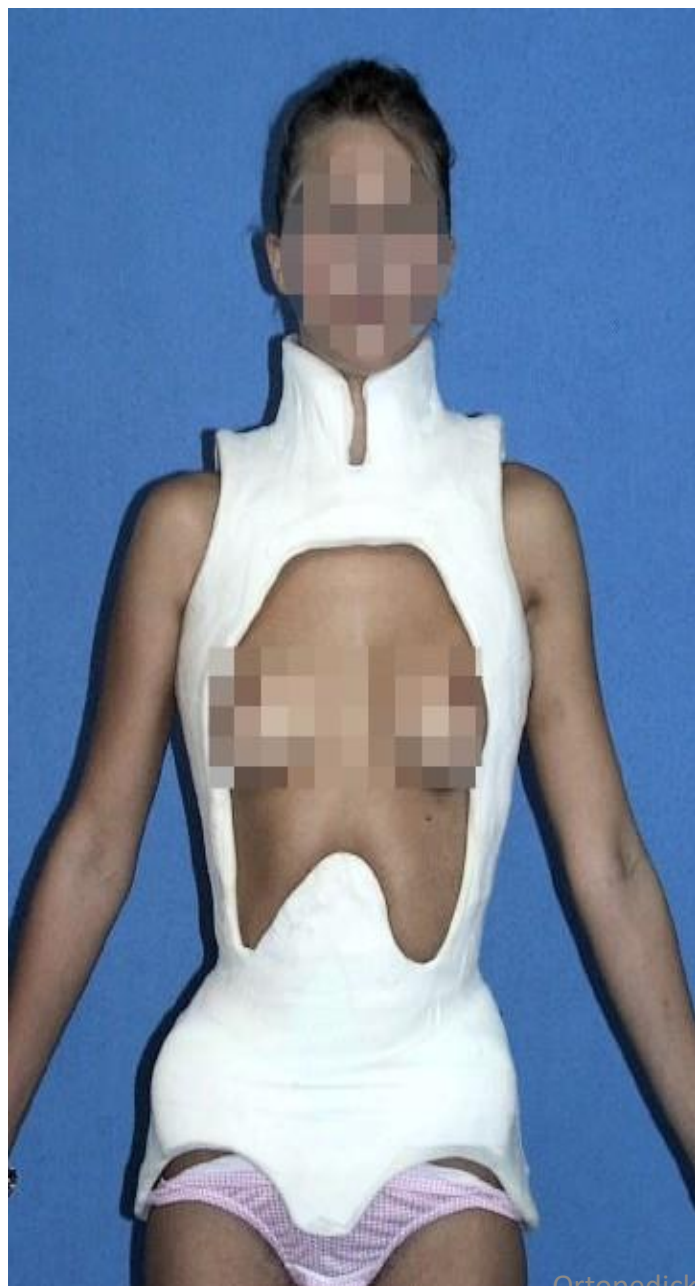


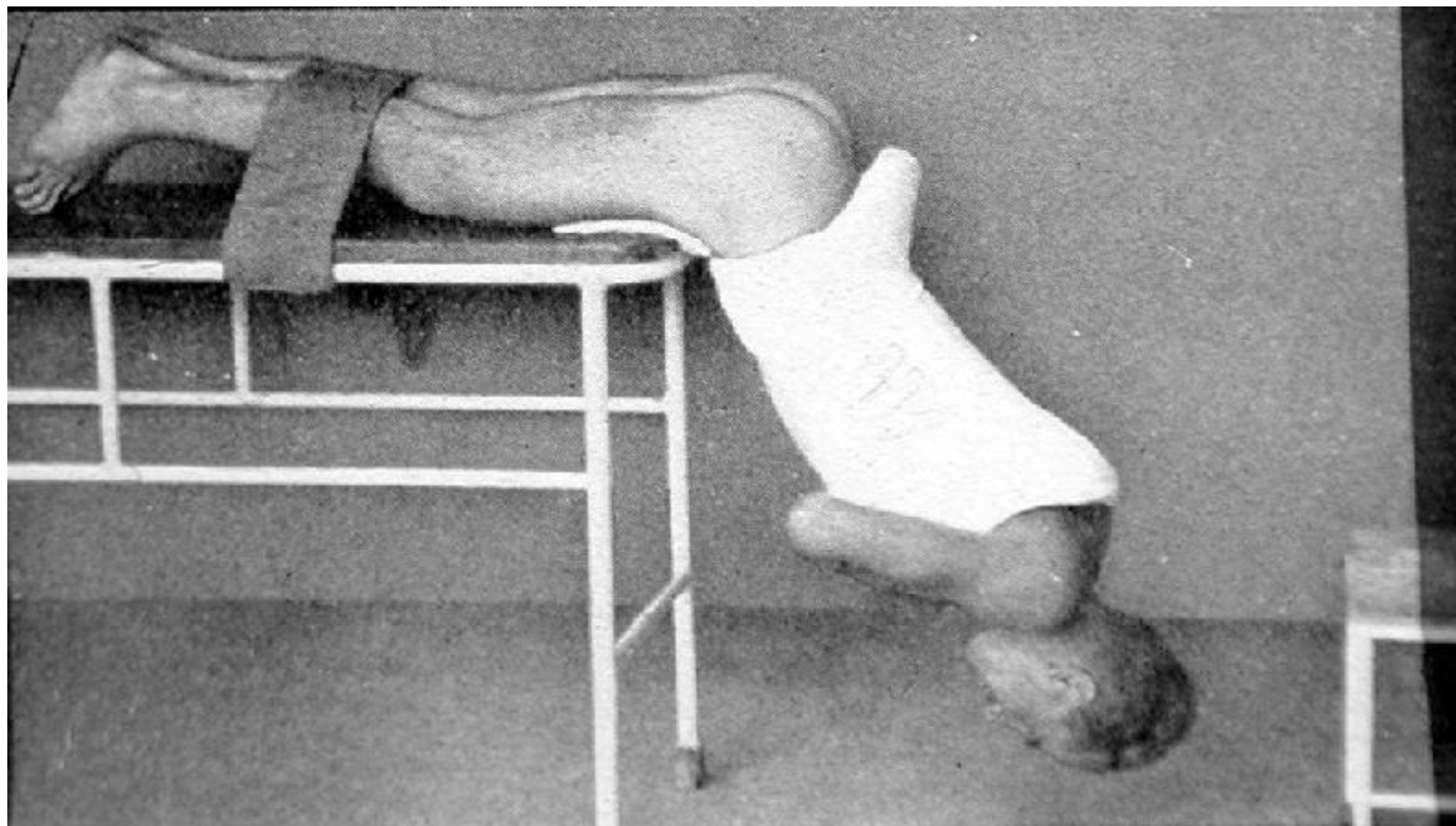


KONZERVATIVNÍ LEČENÍ sádrové korzety

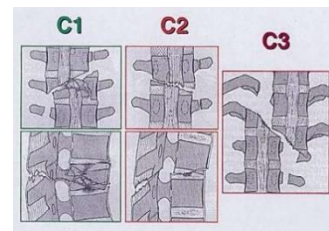
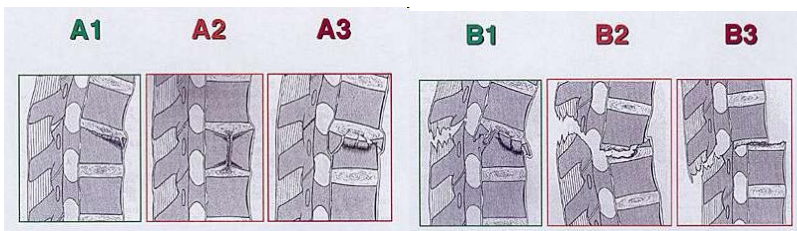

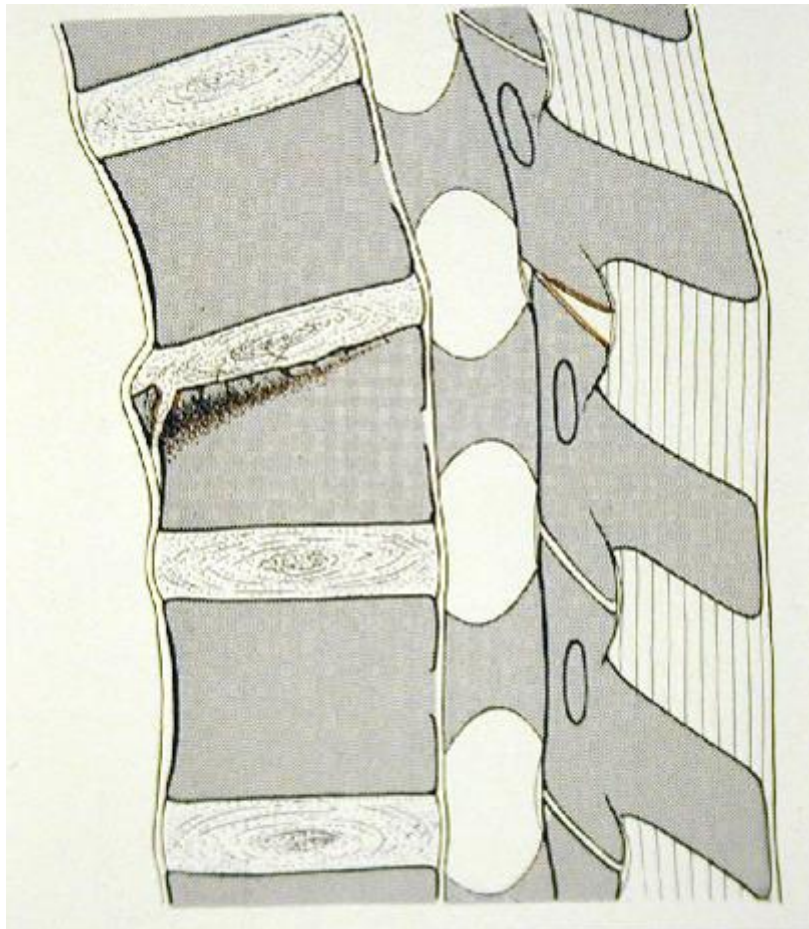

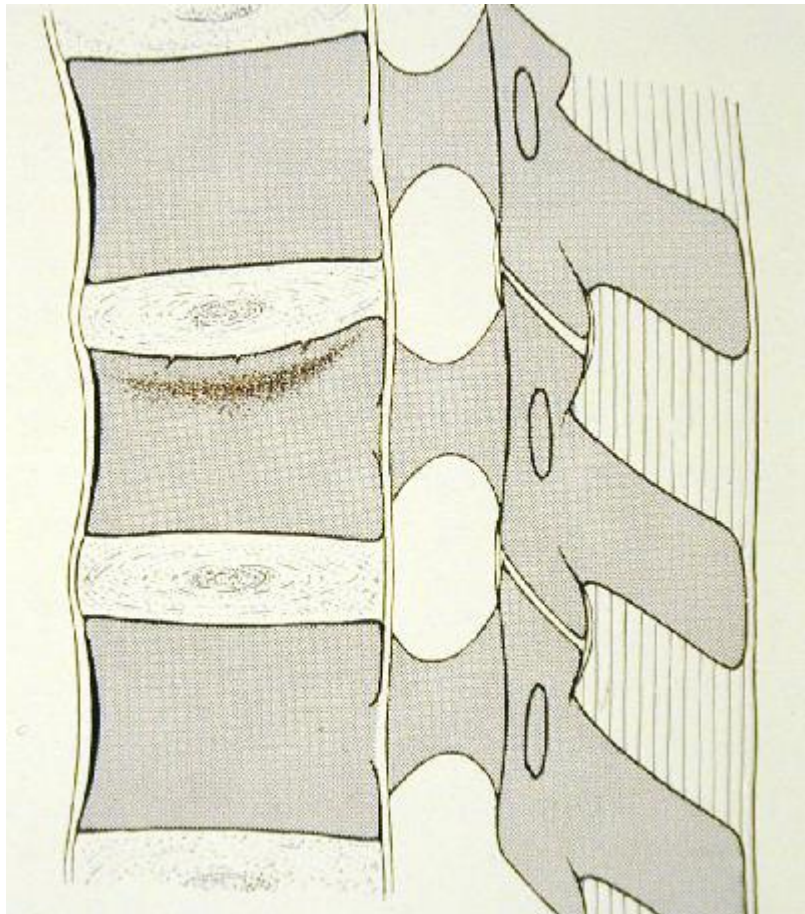
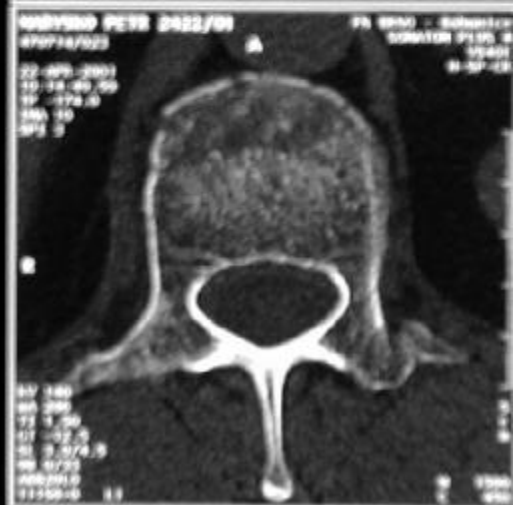
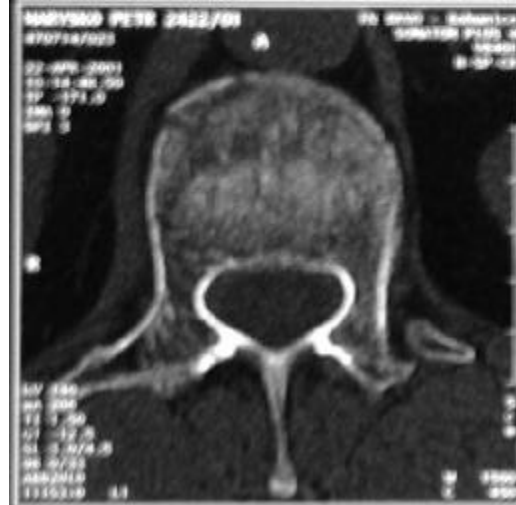
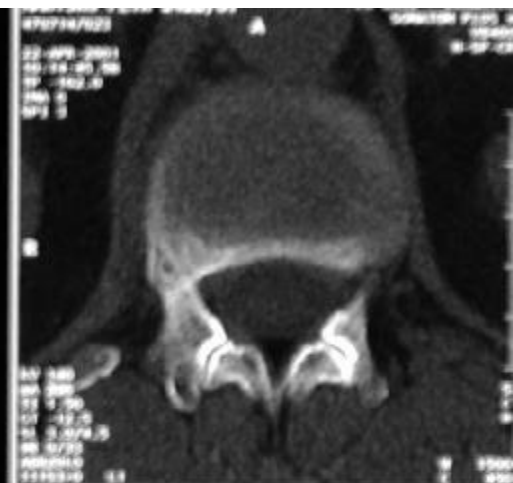
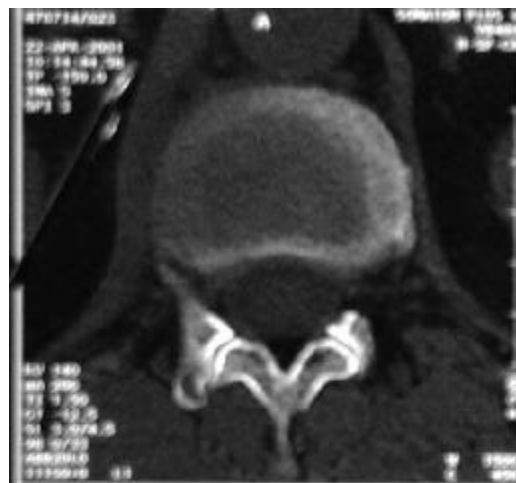
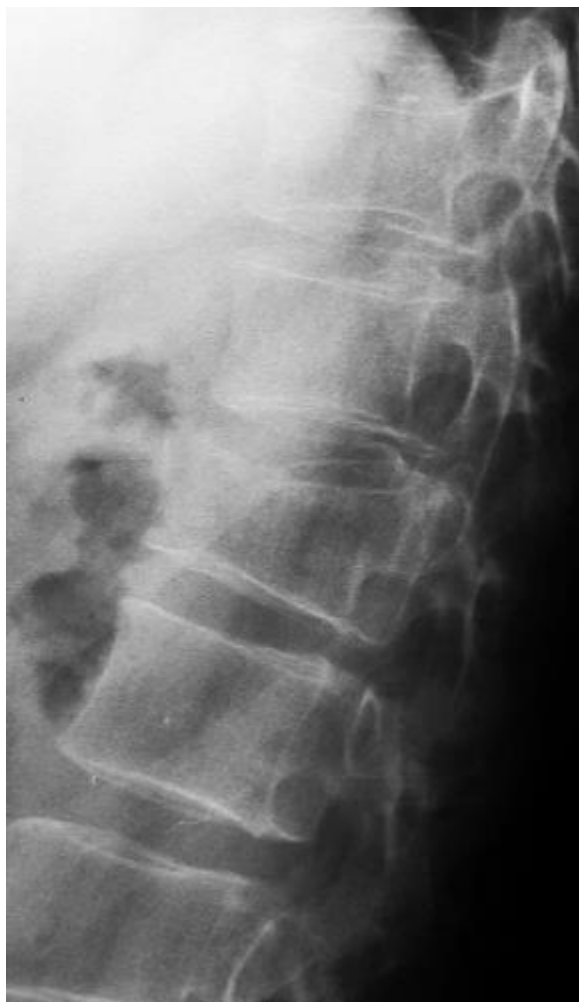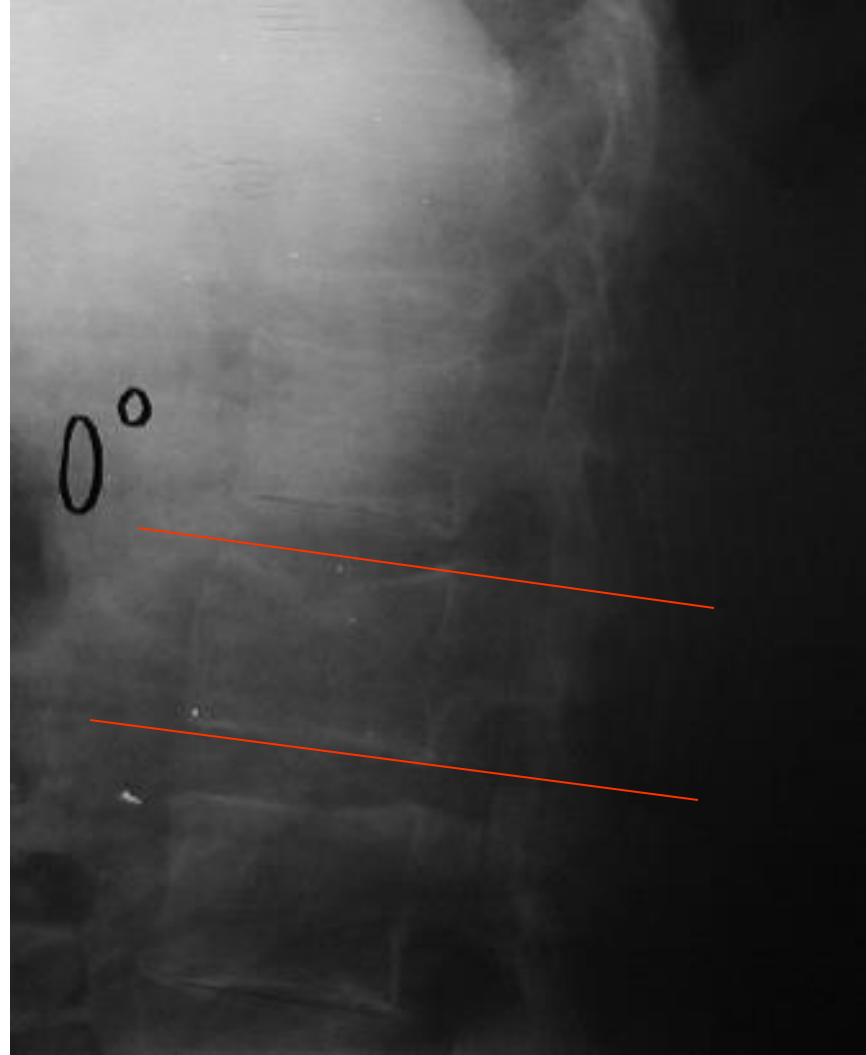
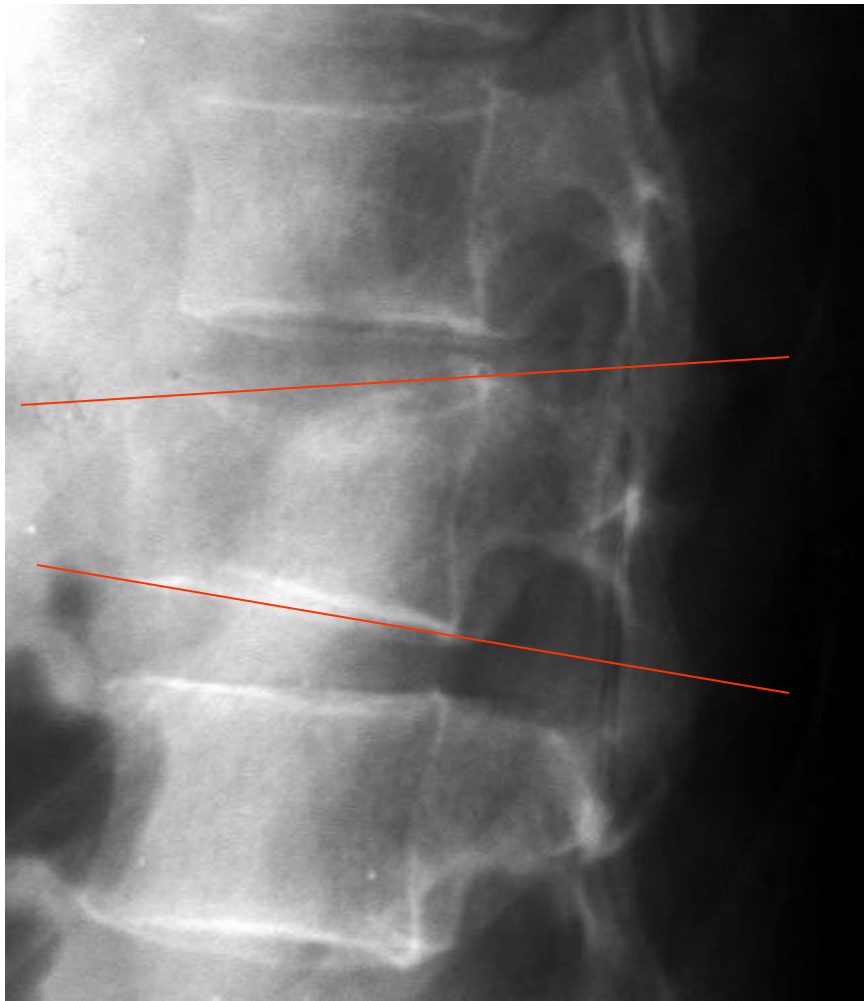




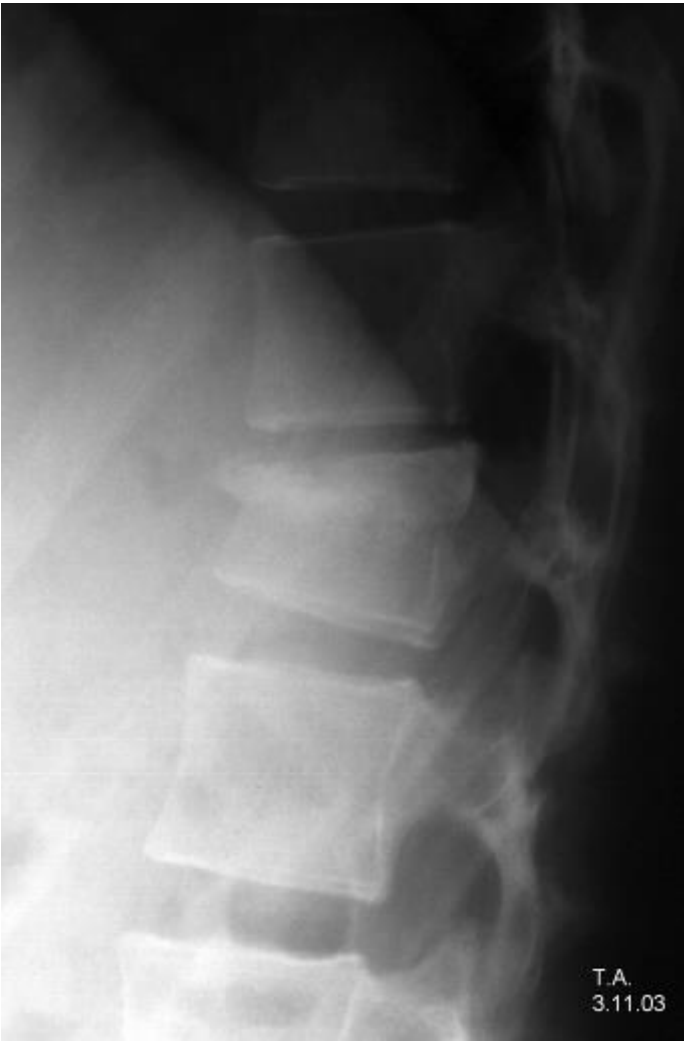Ortopedická klinika LF MU a FNB

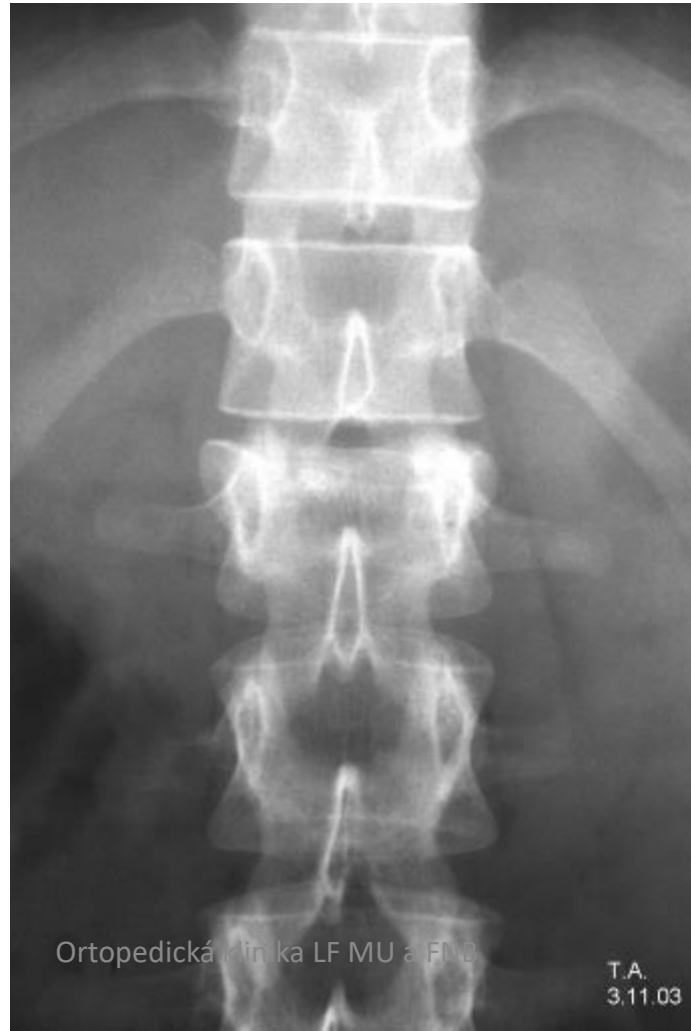






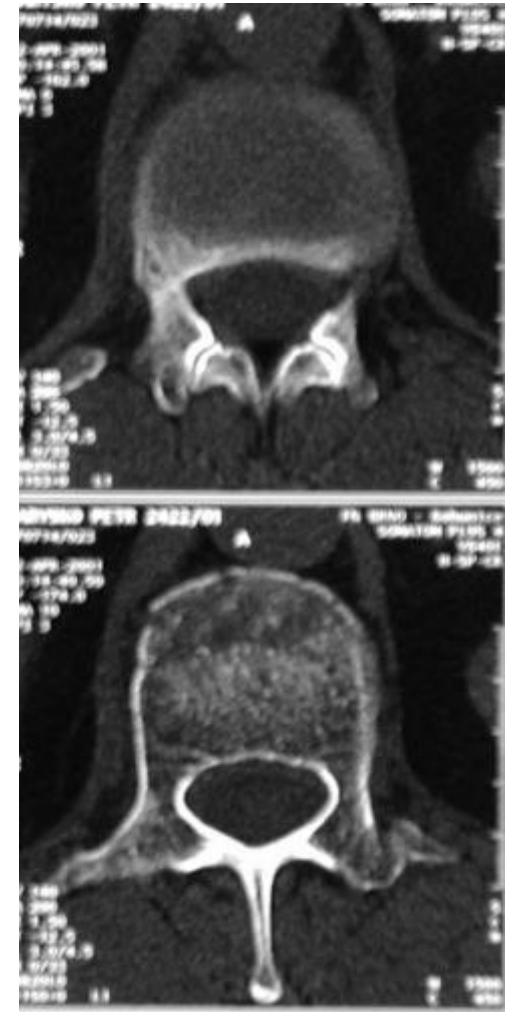
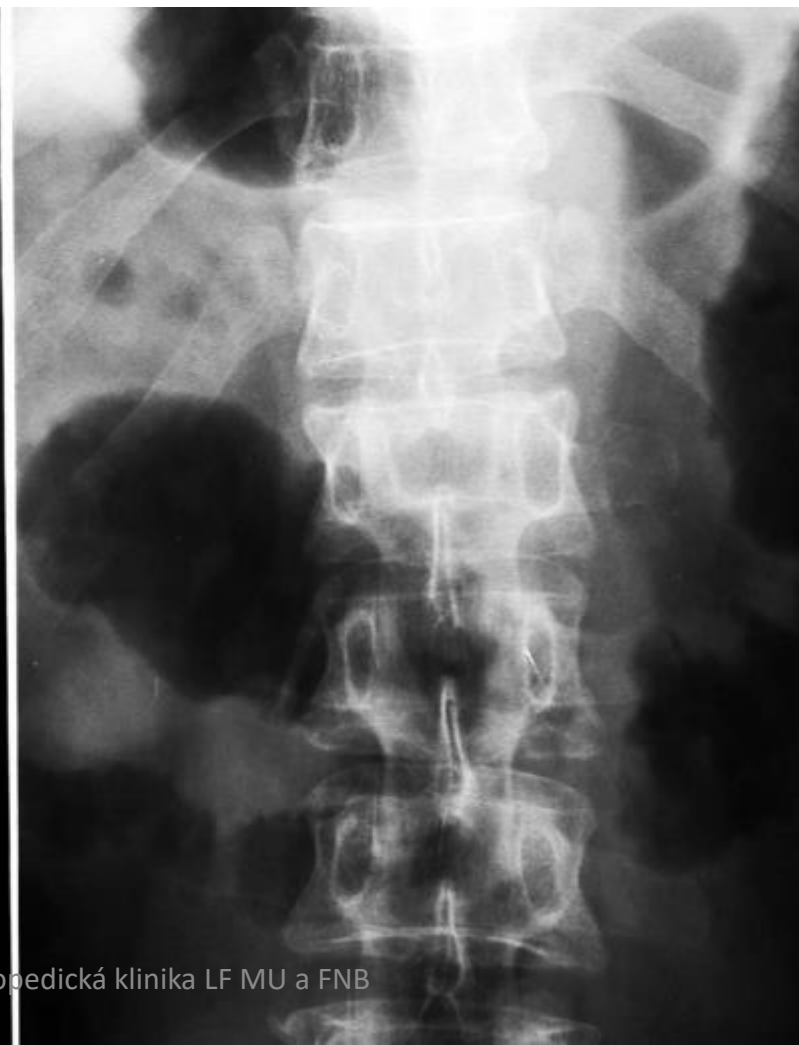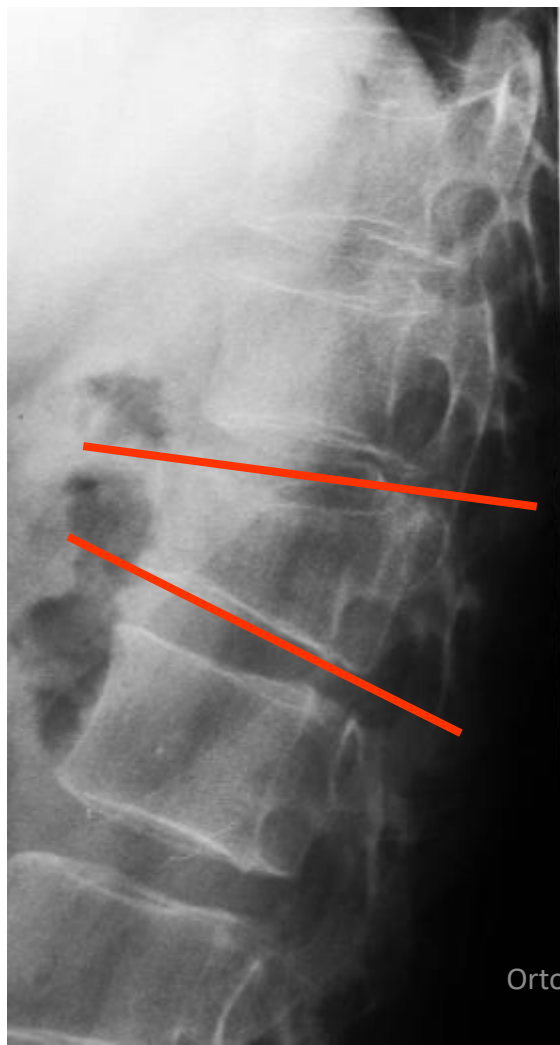
T.A.
3.11.03



Ortopedická klinika LF MU a FNB

T.A.
3.11.03





OPERAČNÍ TERAPIE

- NÁPRAVA DEFORMIY
- DEKOMPRESSE NERV. STRUKTUR
– přímá či ligamentotaxí
- STABILIZACE
– užití úhlově stabilních implantátů
- FÚZE
– je-li potřeba

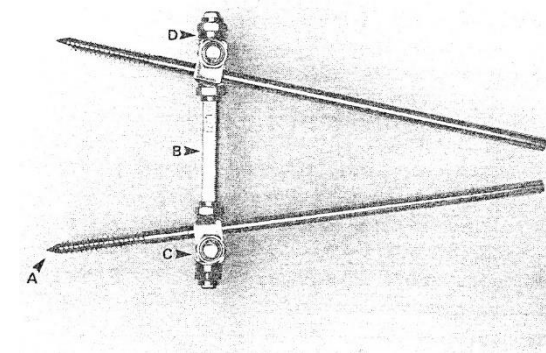
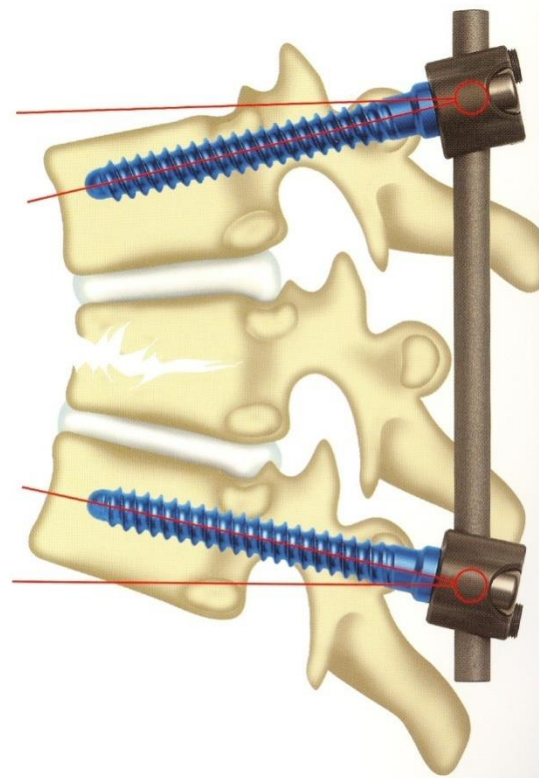
OPERAČNÍ TERAPIE

akutní fáze

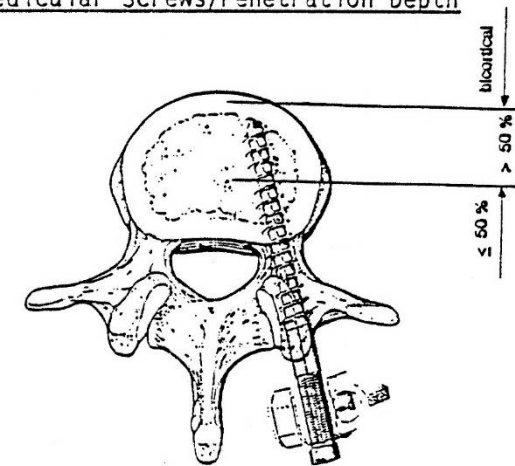
- C páteř
 - přední výkony
- T, L páteř
 - zadní výkony

PRINCIPY OPERAČNÍ LÉČBY

- repozice
- lordotizace
- stabilizace

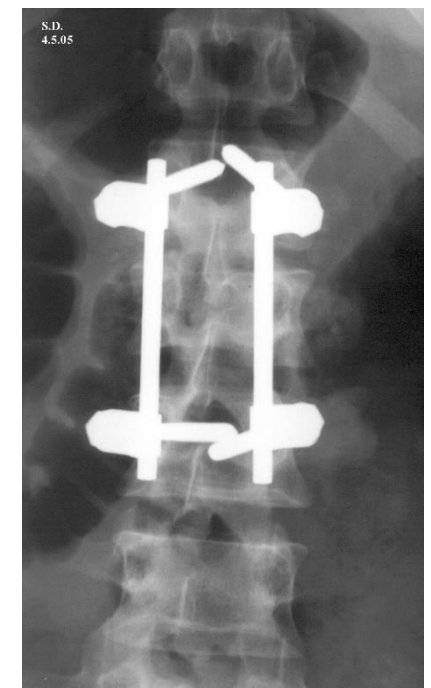
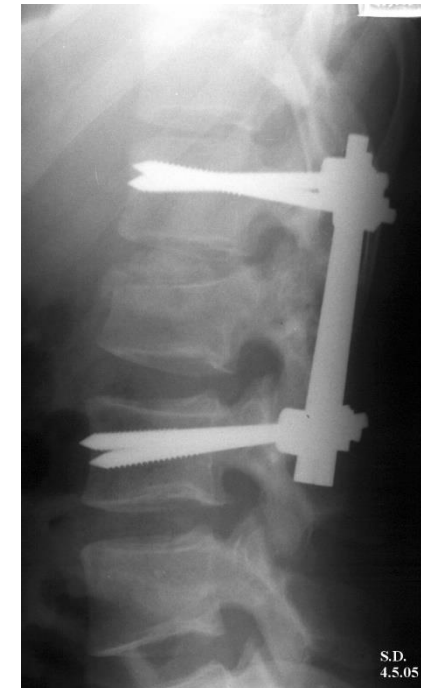
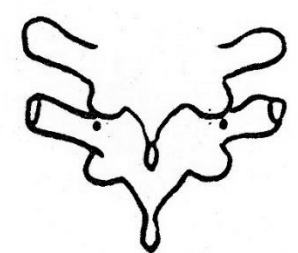
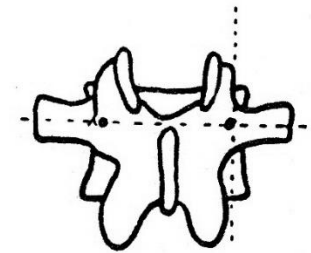
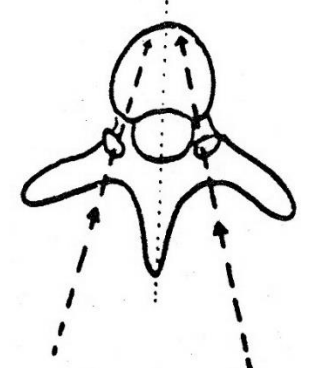
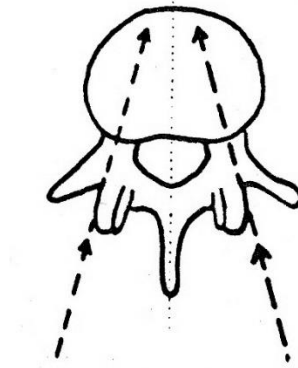


Pedicular Screws/Penetration Depth

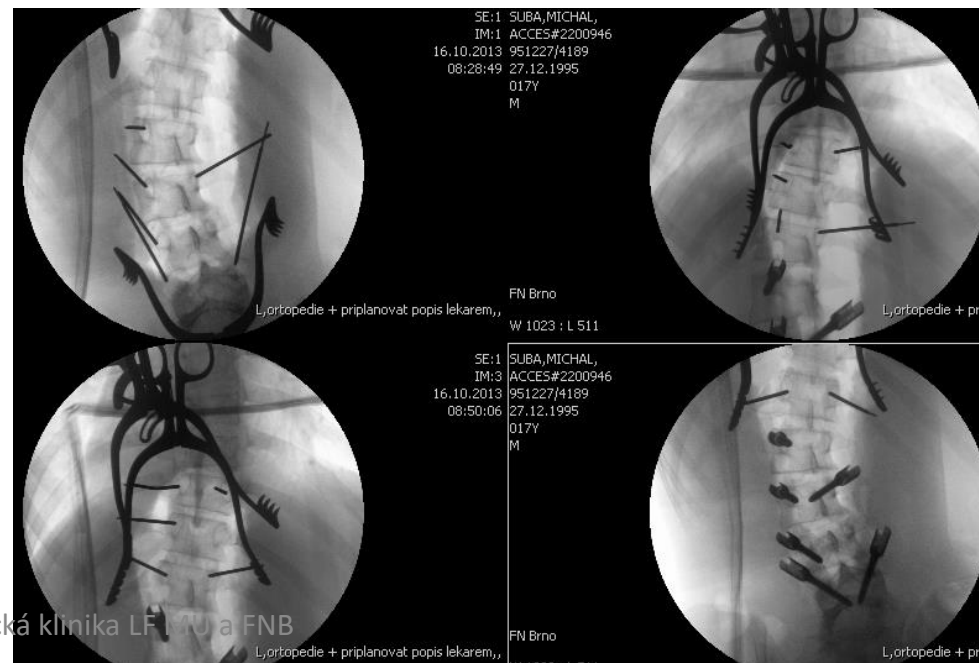
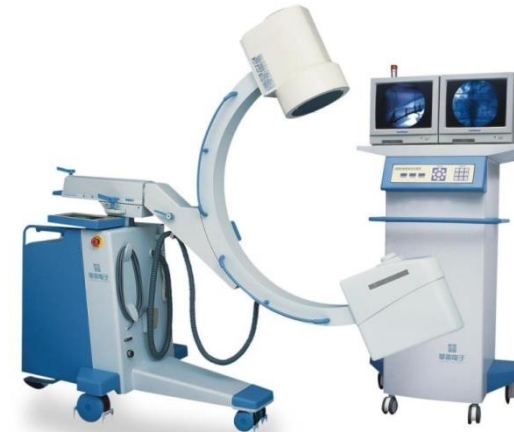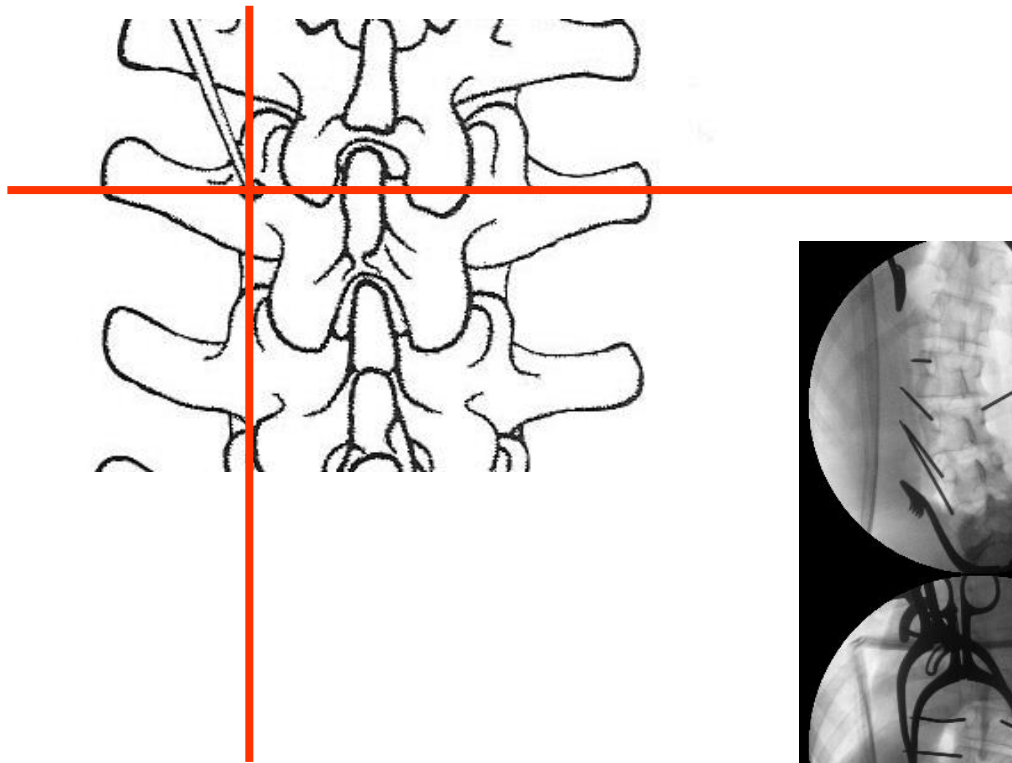


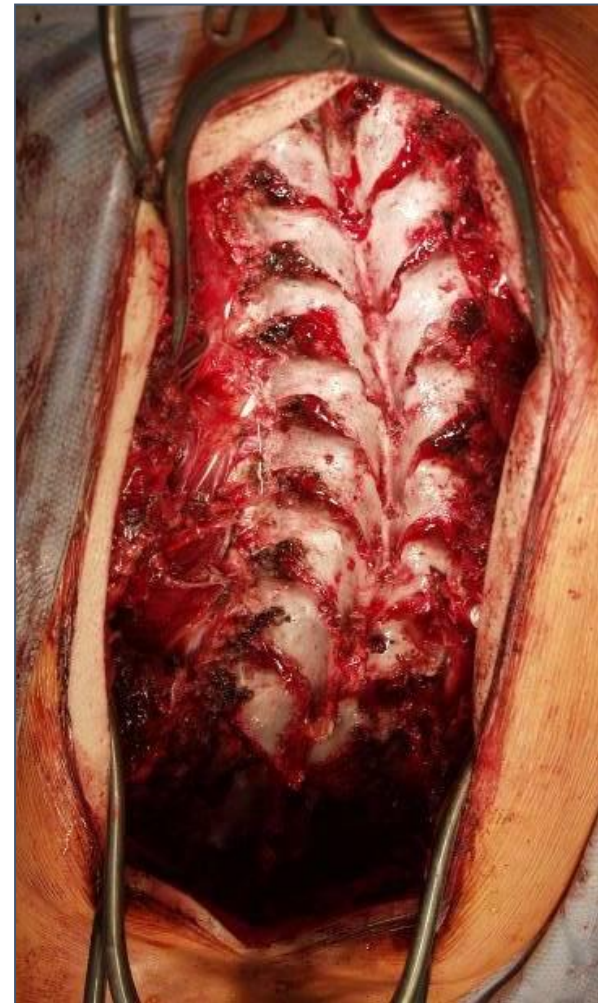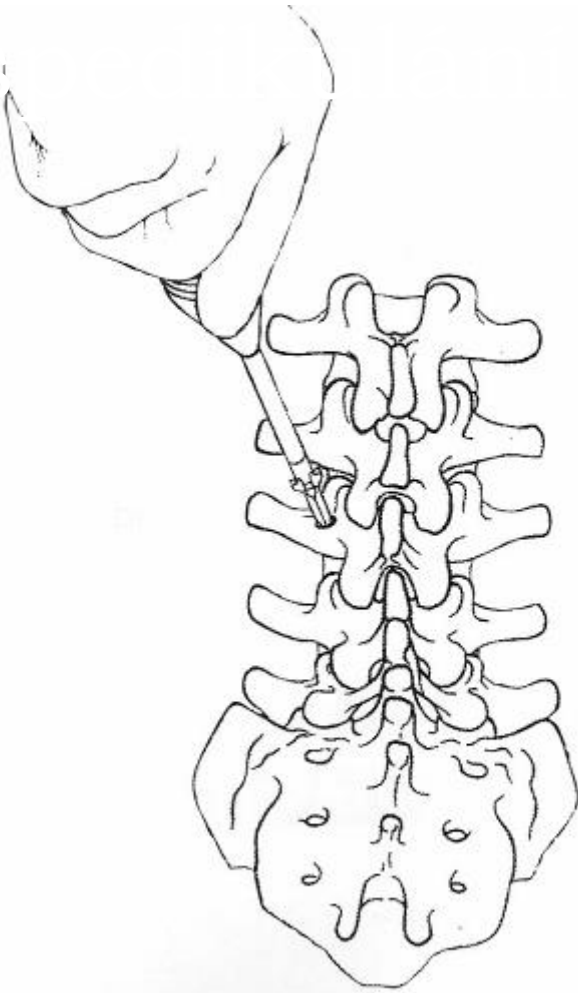
OPERACE TL PÁTEŘE ZE ZADU

- Transpedikulární šrouby
- Kameny
- Tyčky
- Croslinky

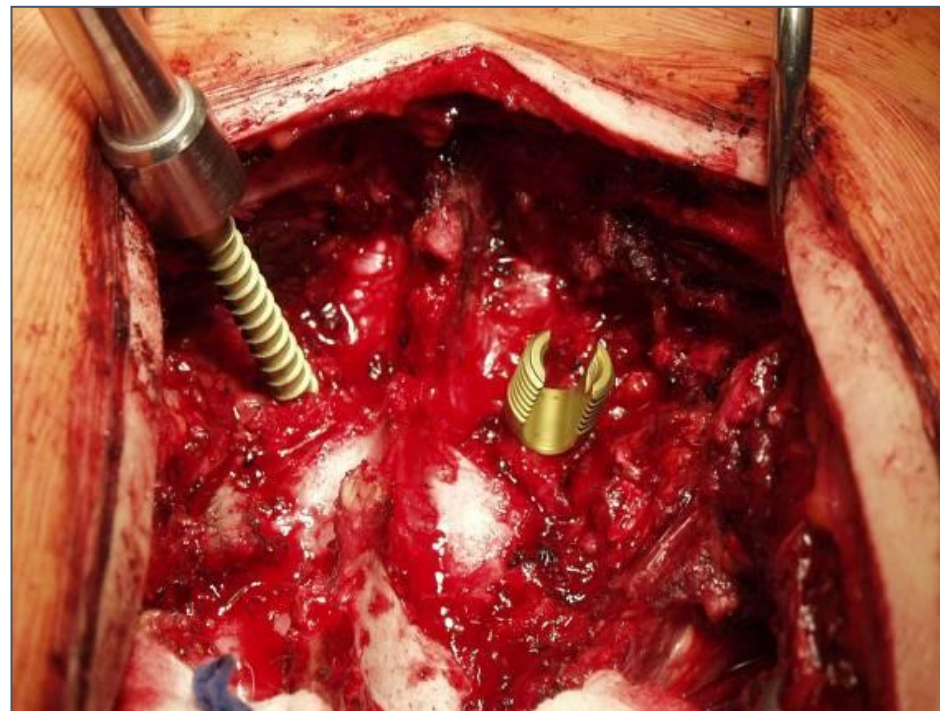
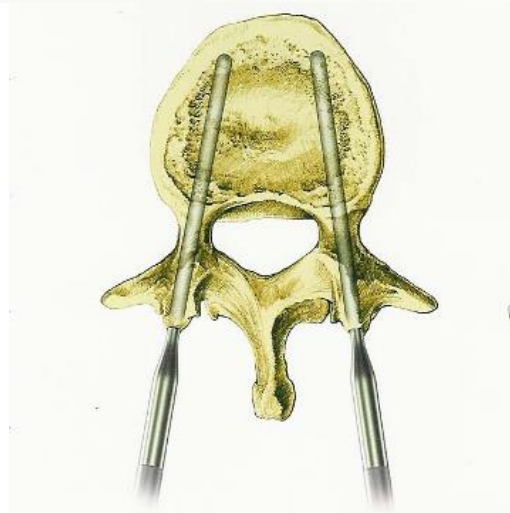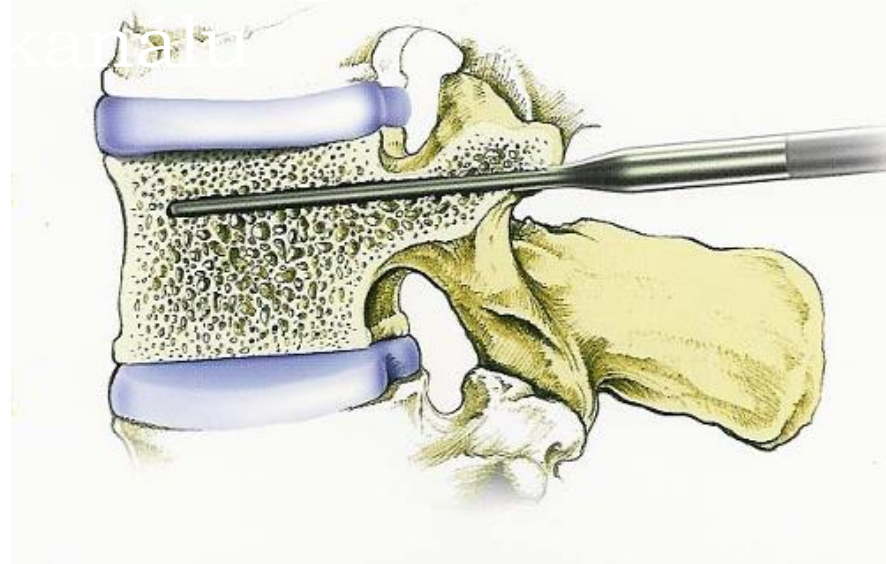


Transpedikulární šrouby - cílení





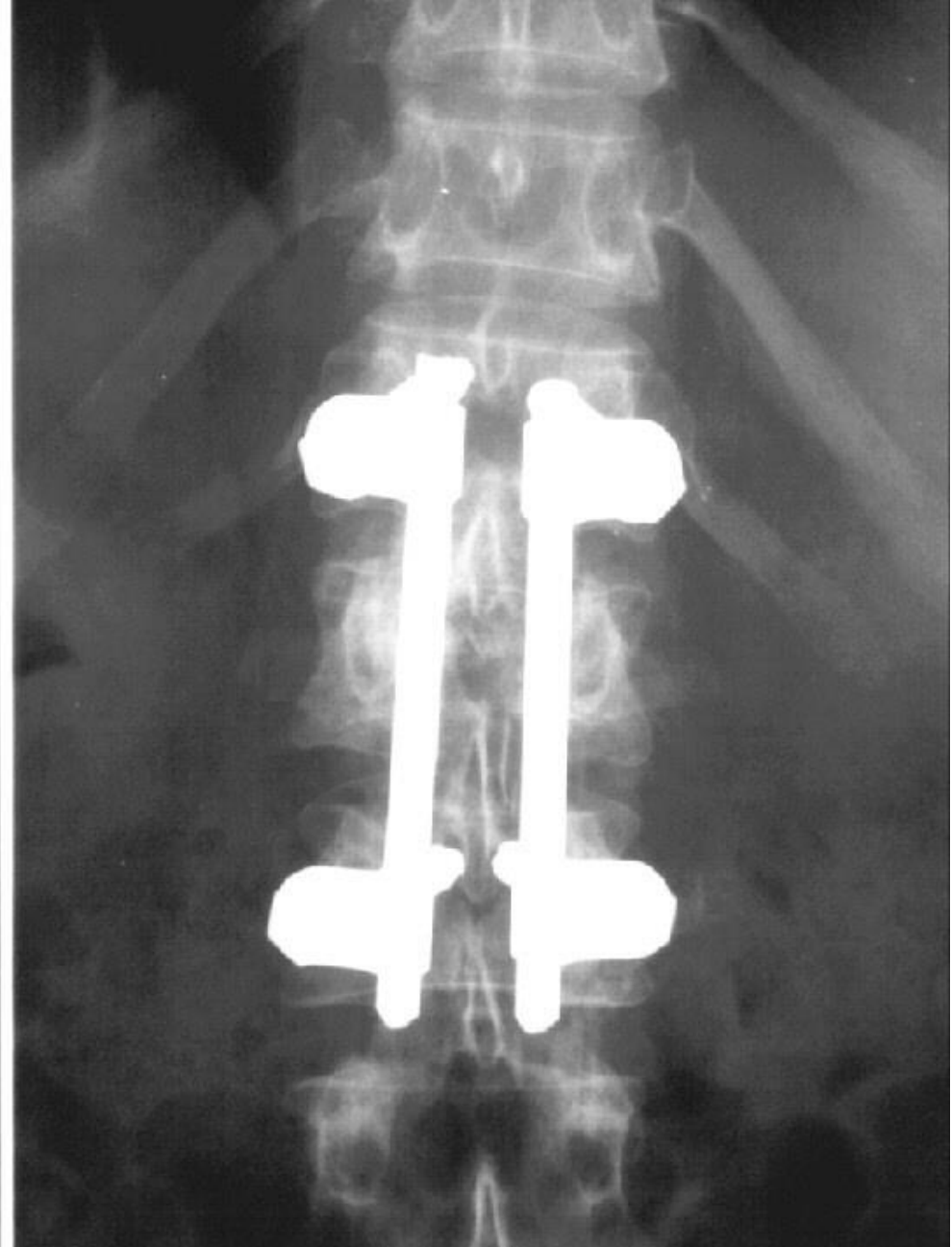
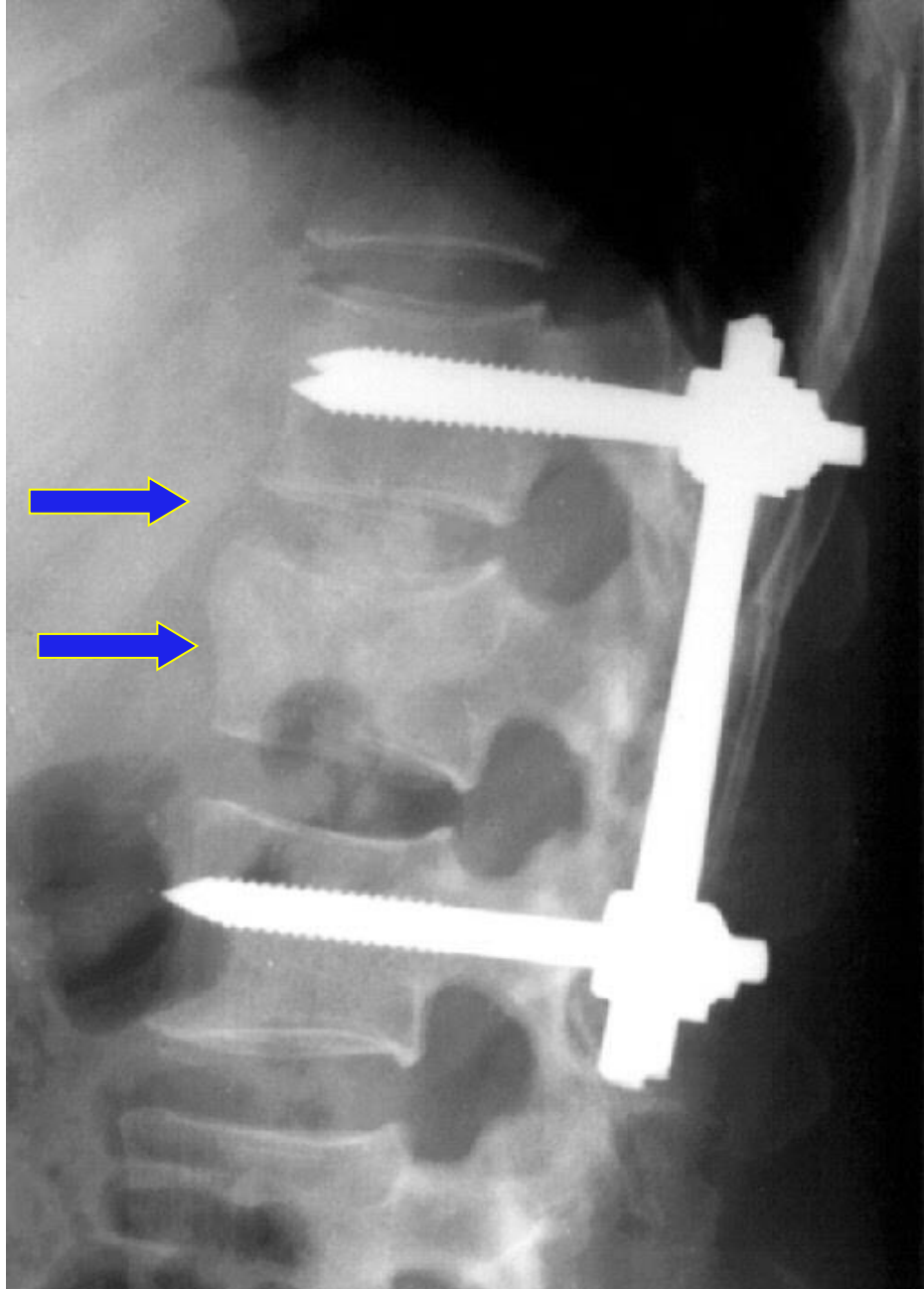
Transpedikularní kanál



intersomatická fuse

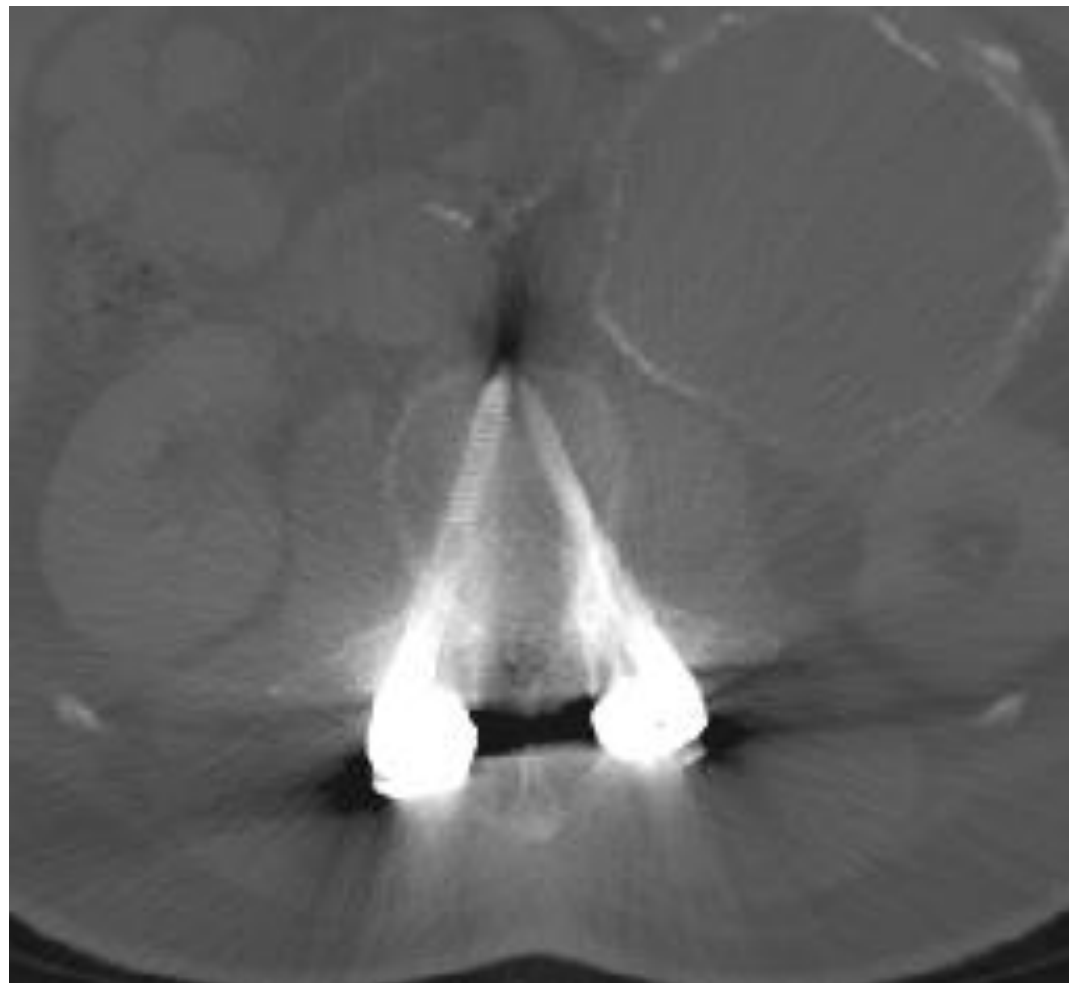


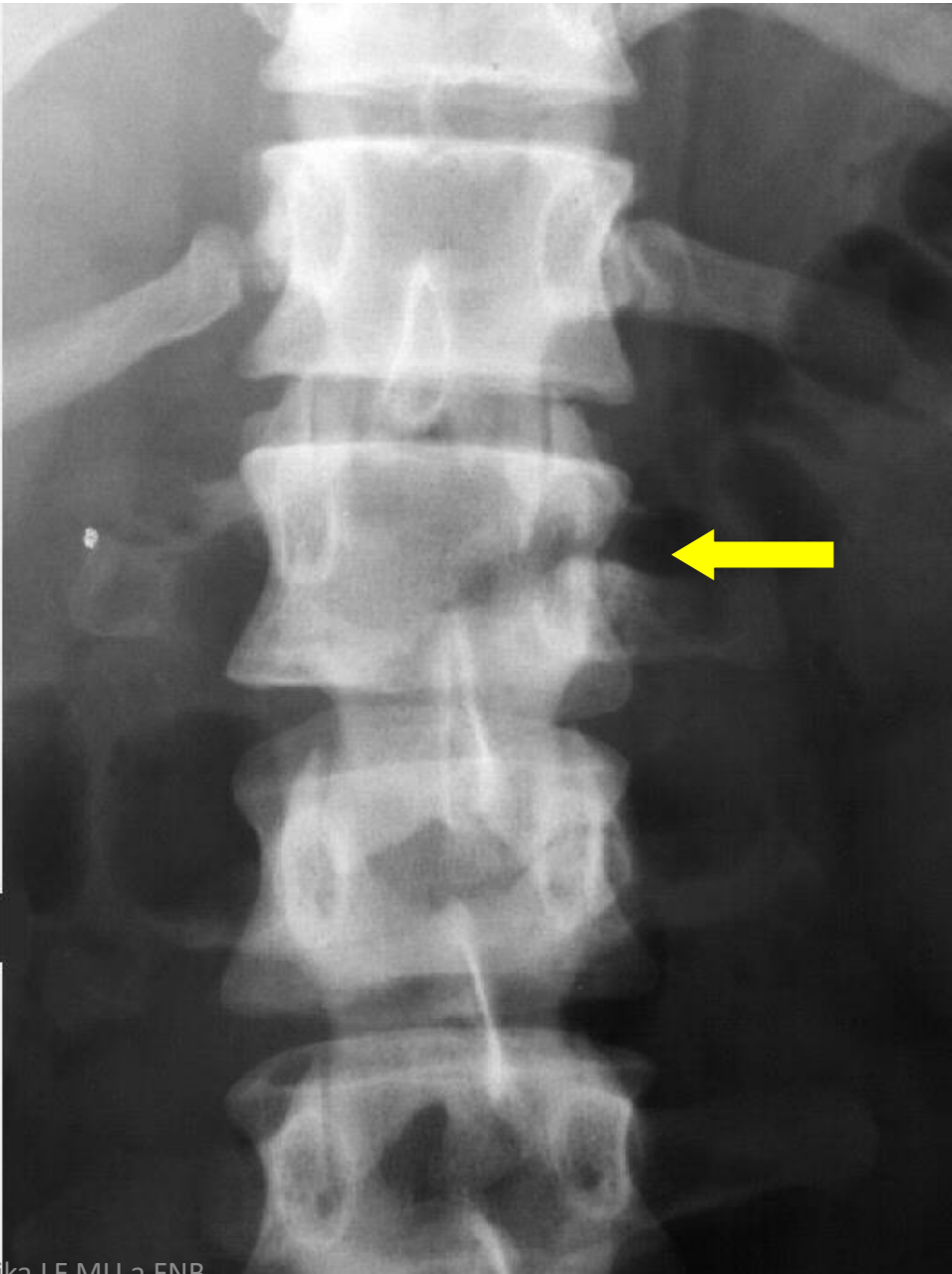
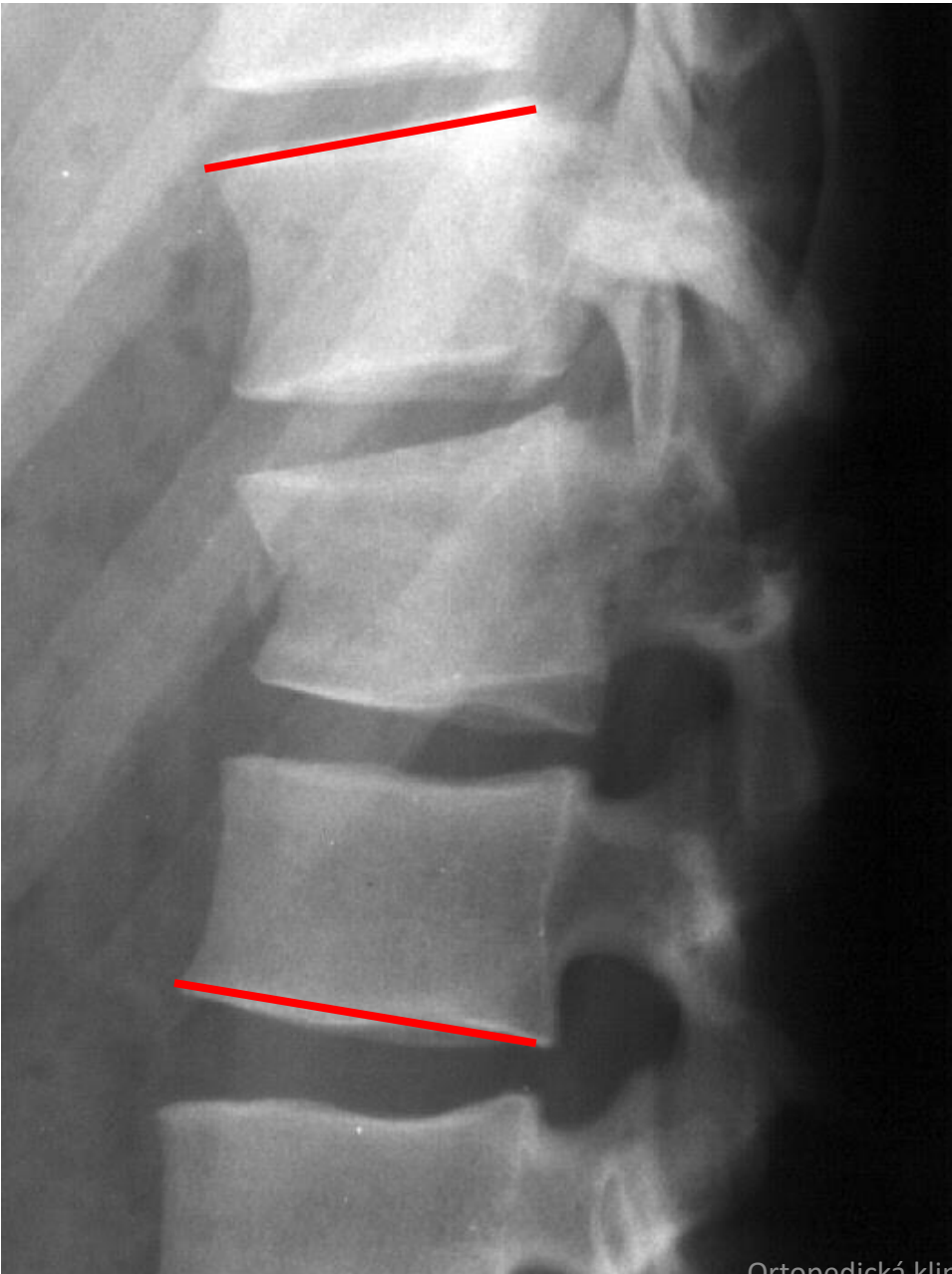
spongioplastika

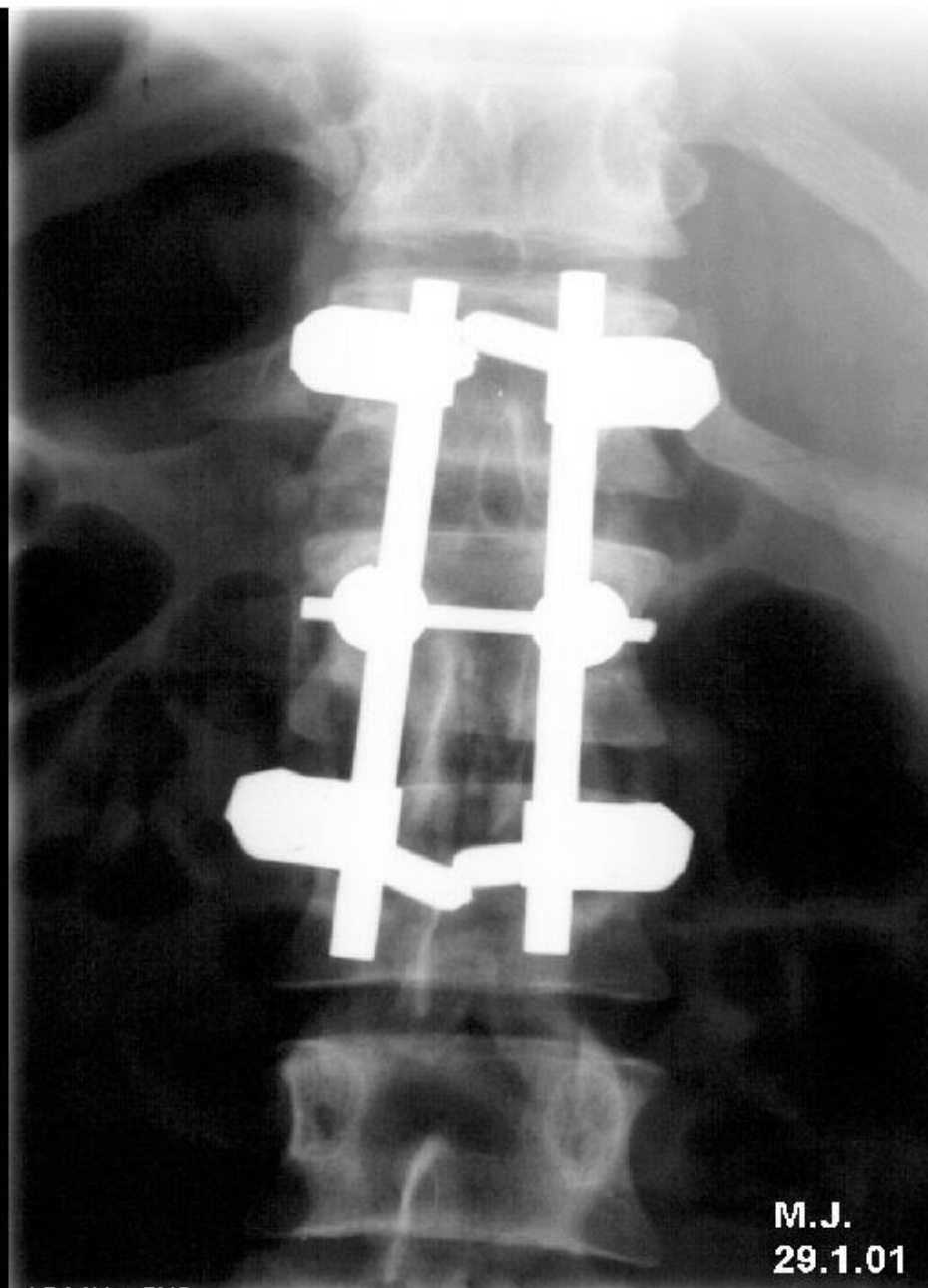
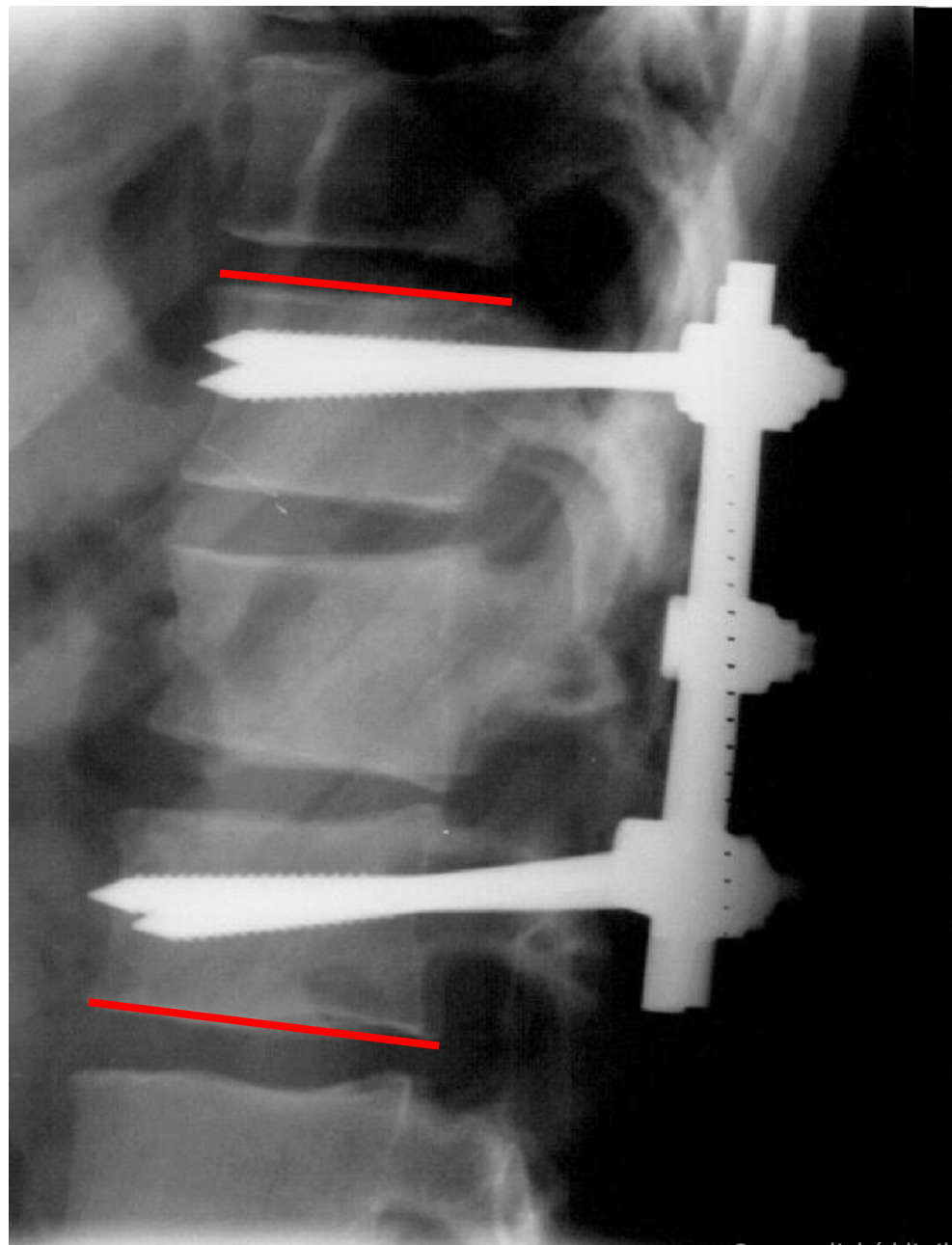


STABILIZACE PÁTEŘE ZE ZADU

CT scan transpedikulárně zavedených šroubů



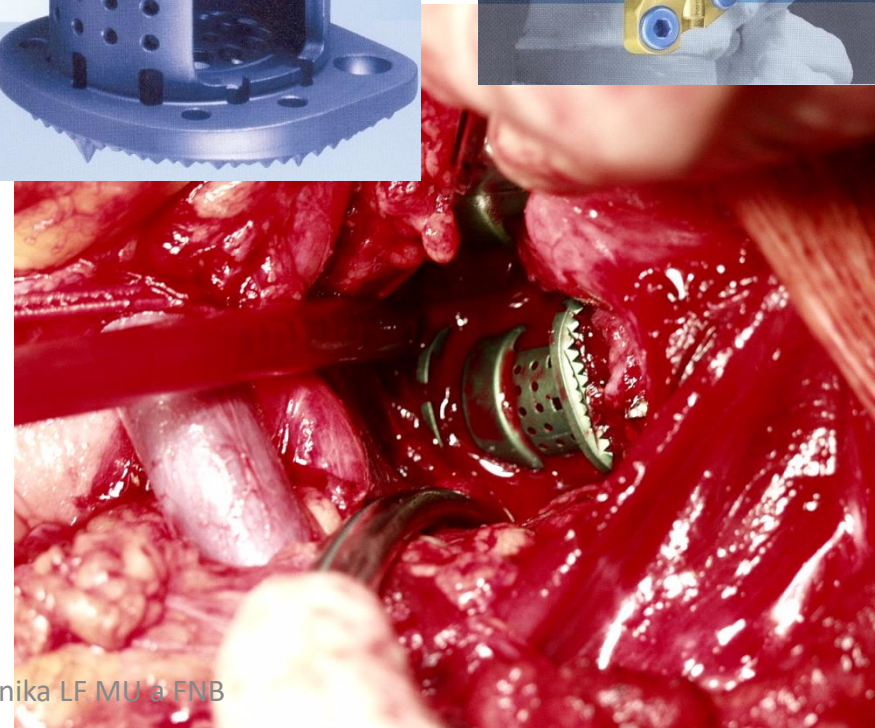
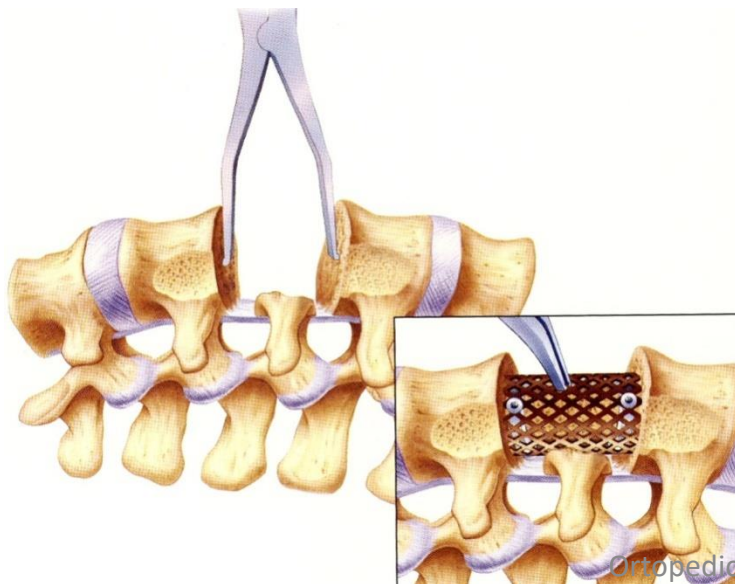
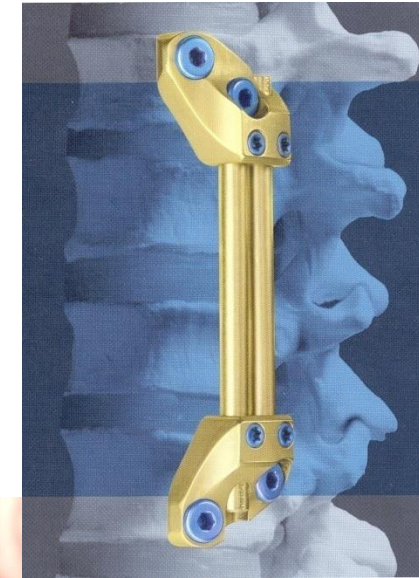


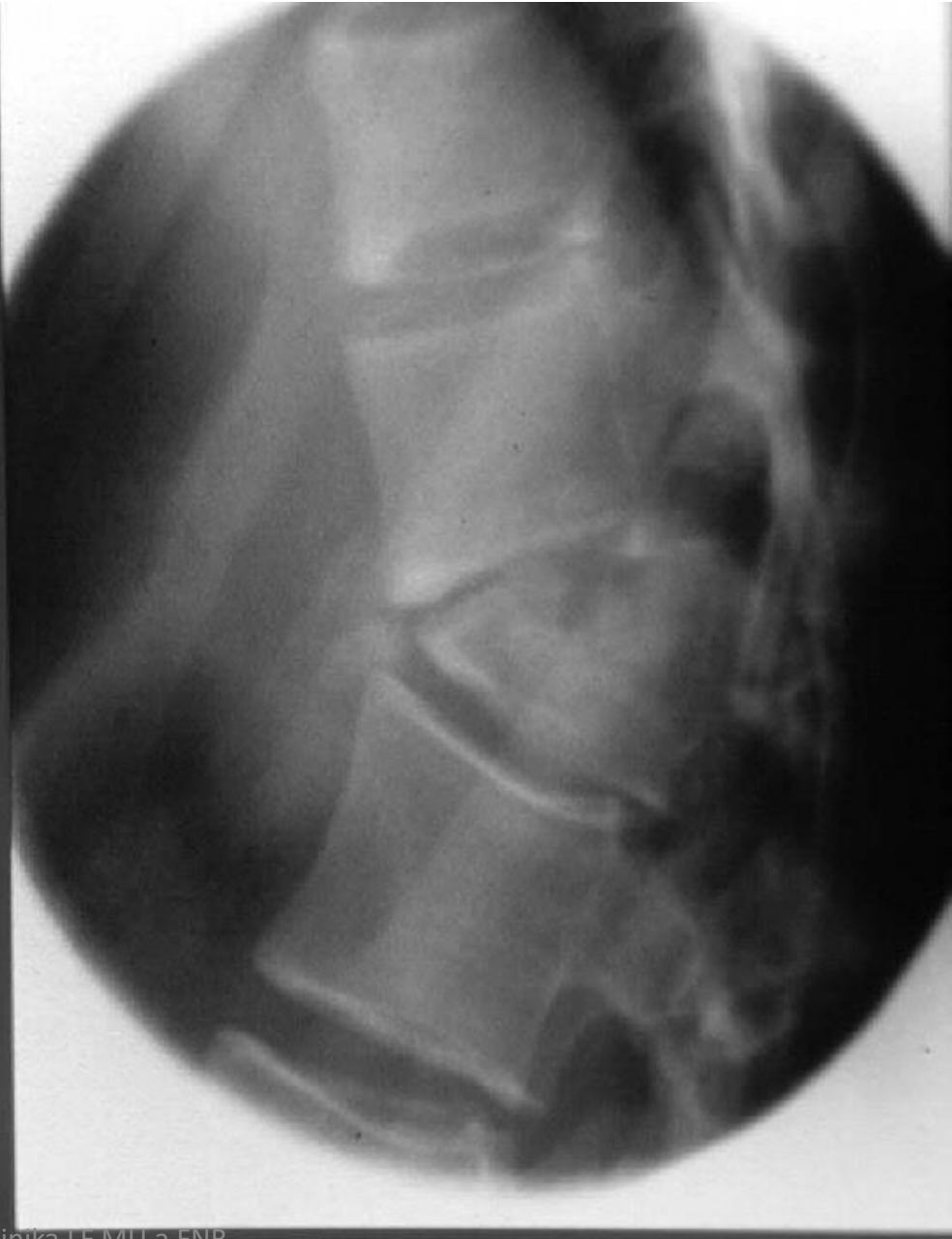
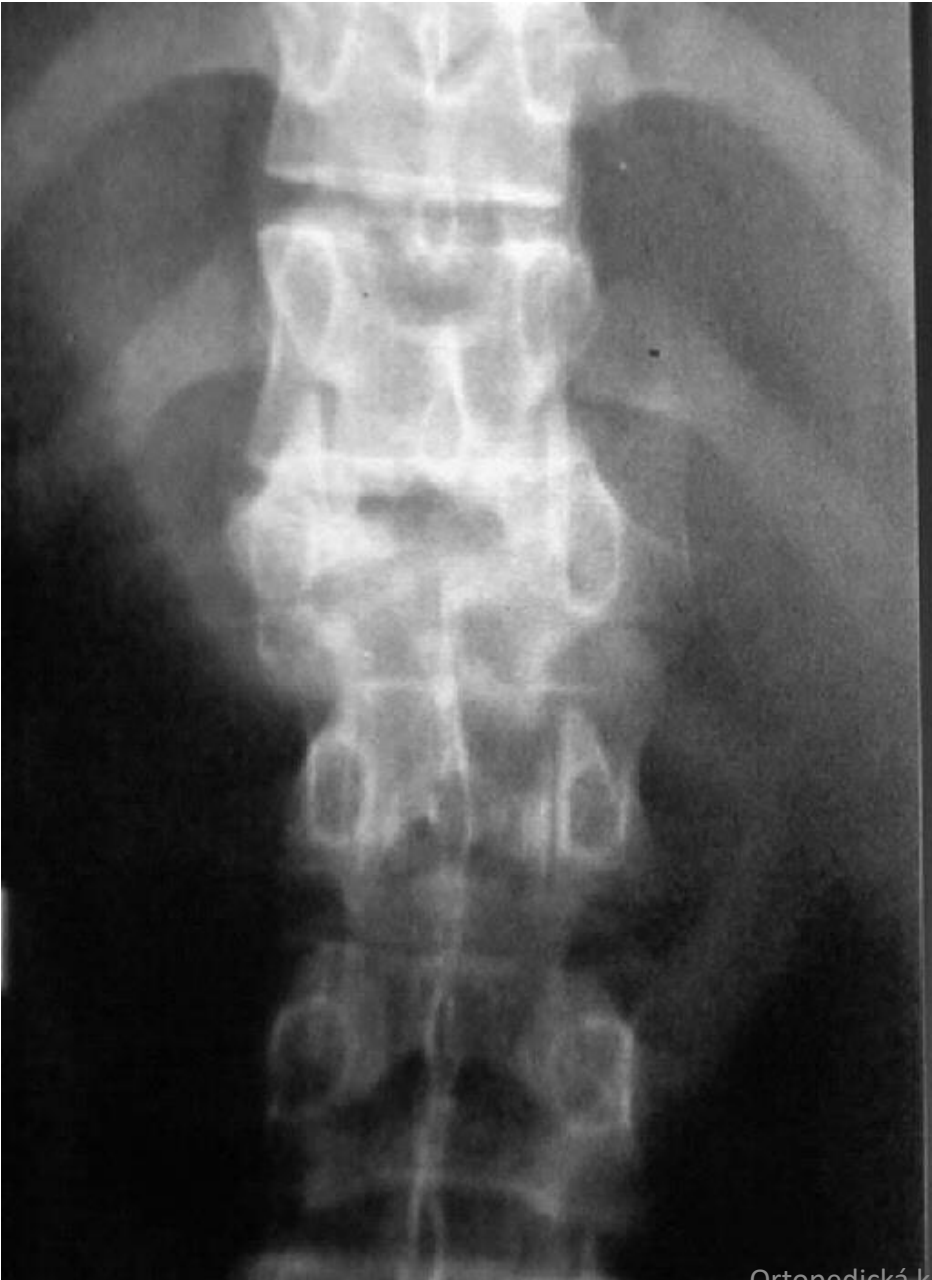
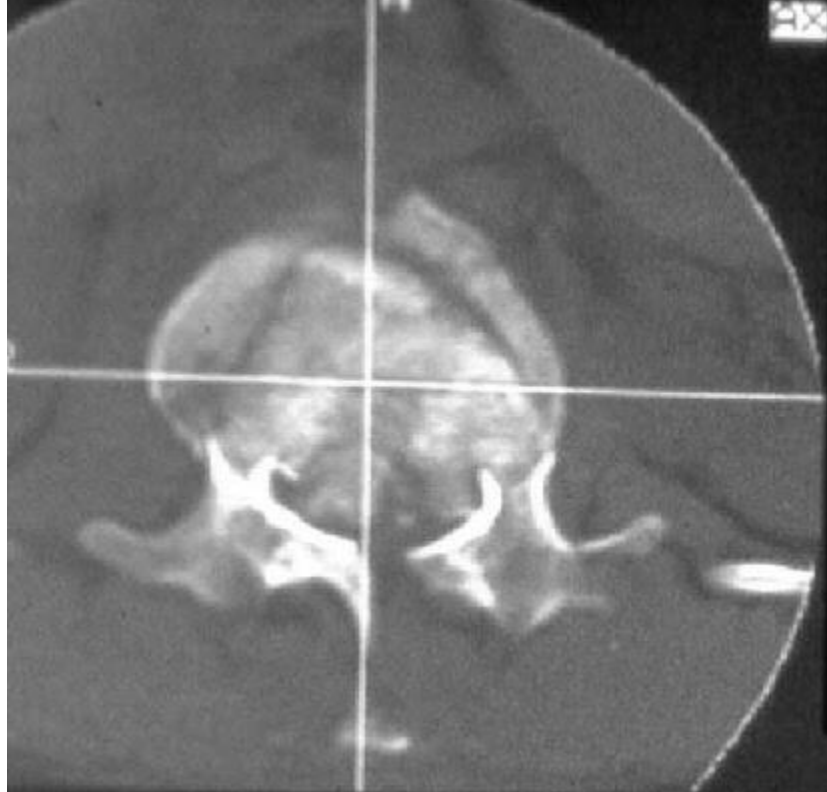M.J.
29.1.01

TL PÁTEŘ- OPERACE ZEPŘEDU



- náhrada těla
- stabilizace

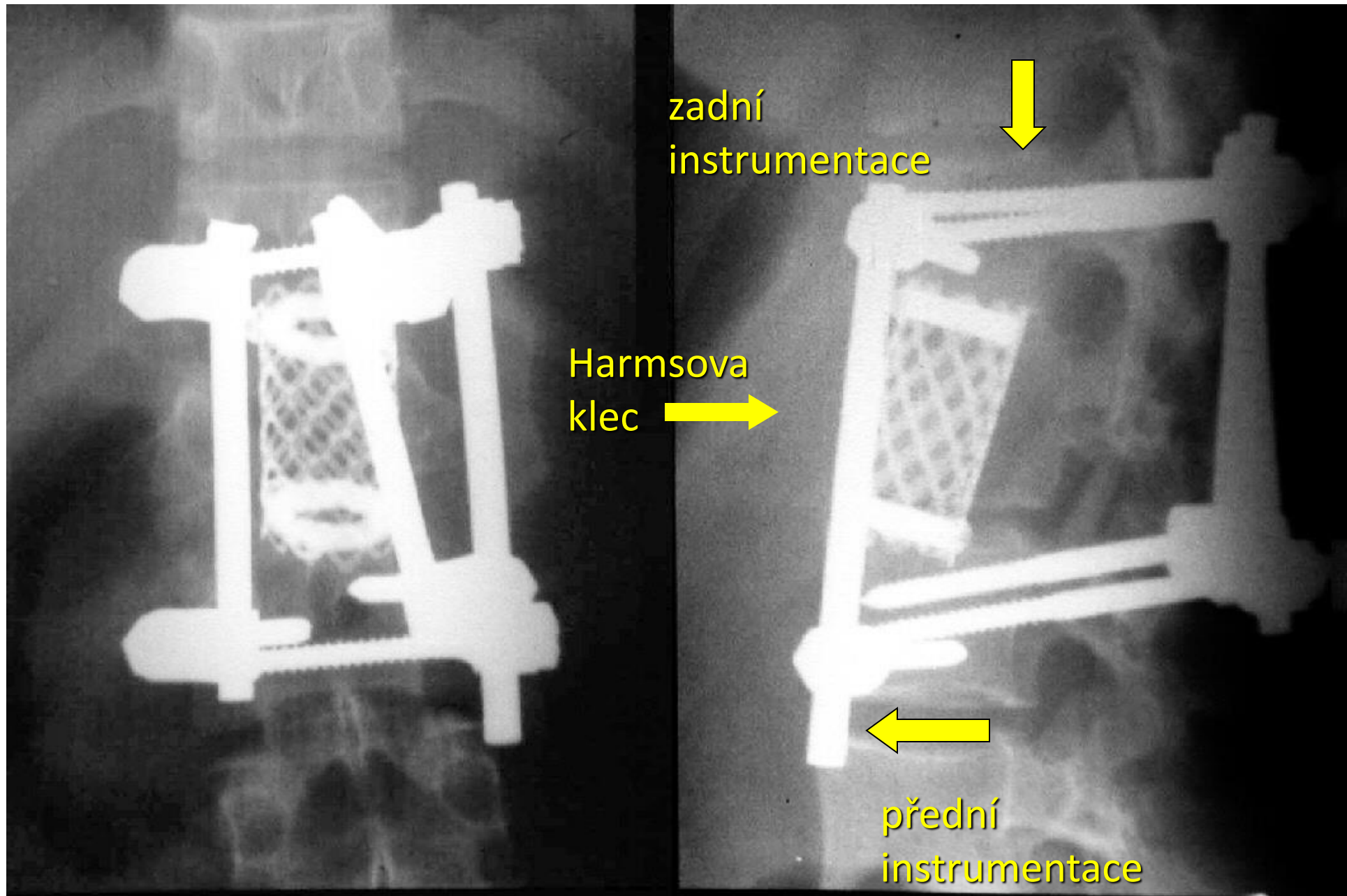








COR



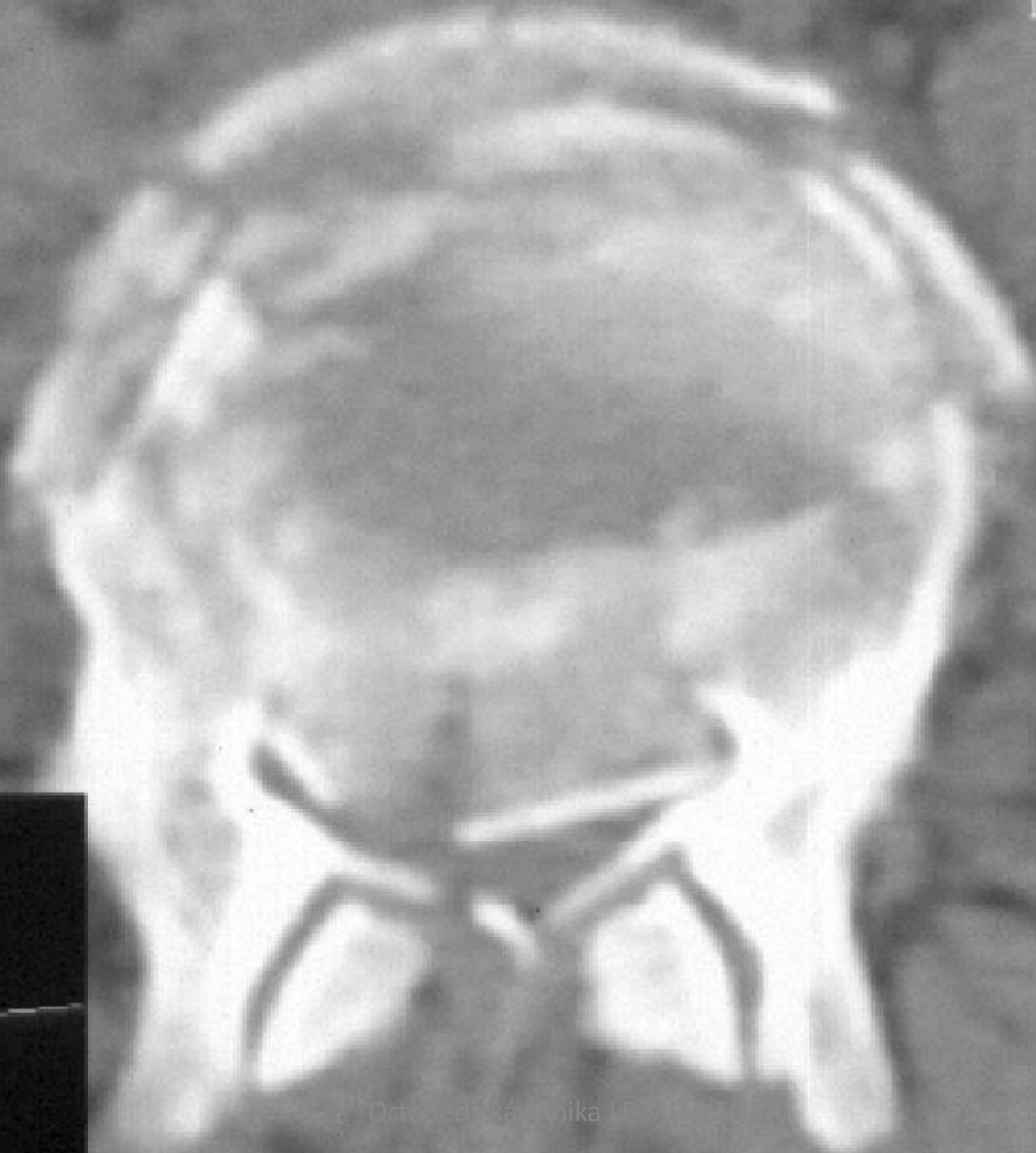


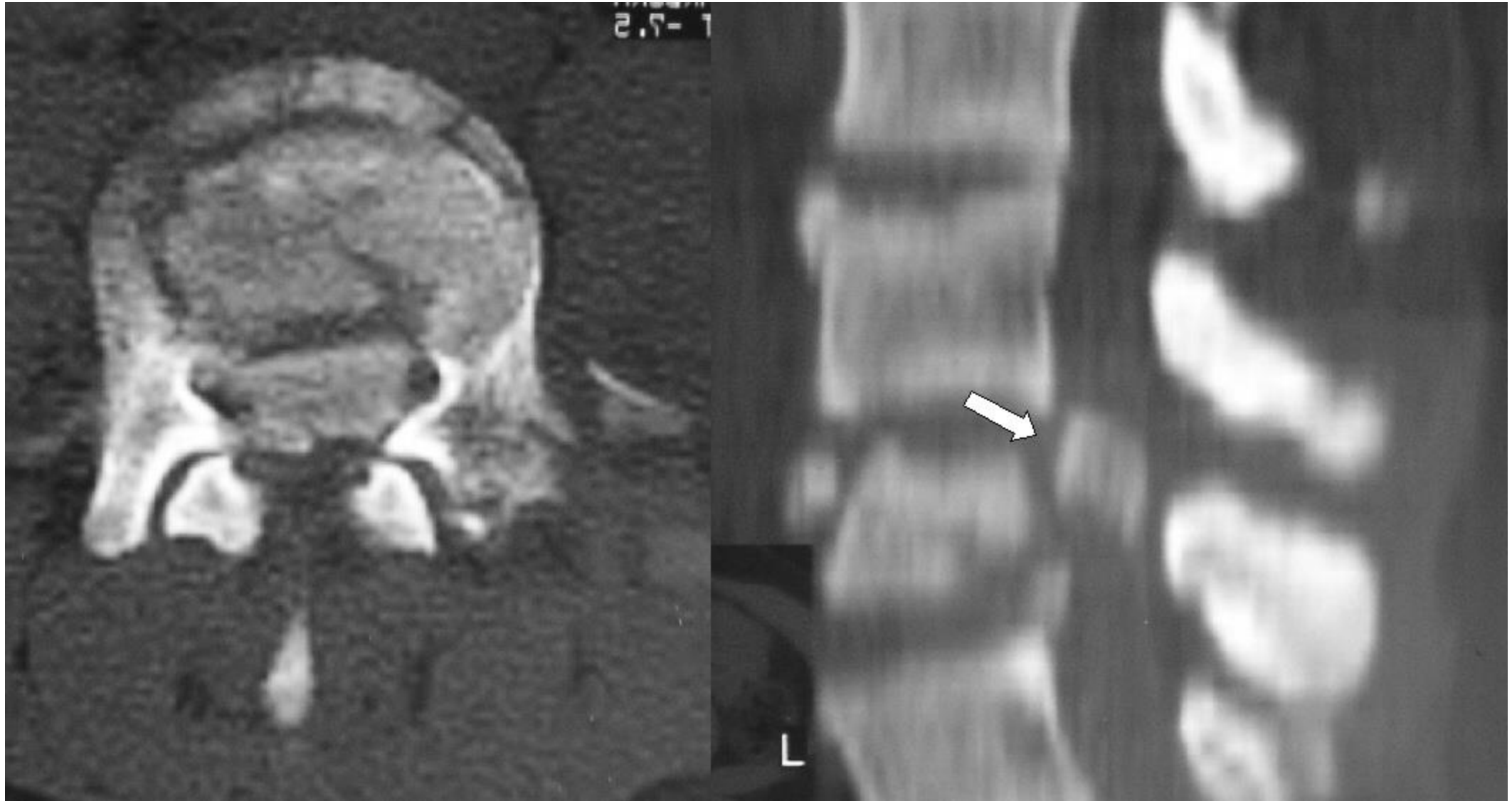
Synex
extenzní
impl.

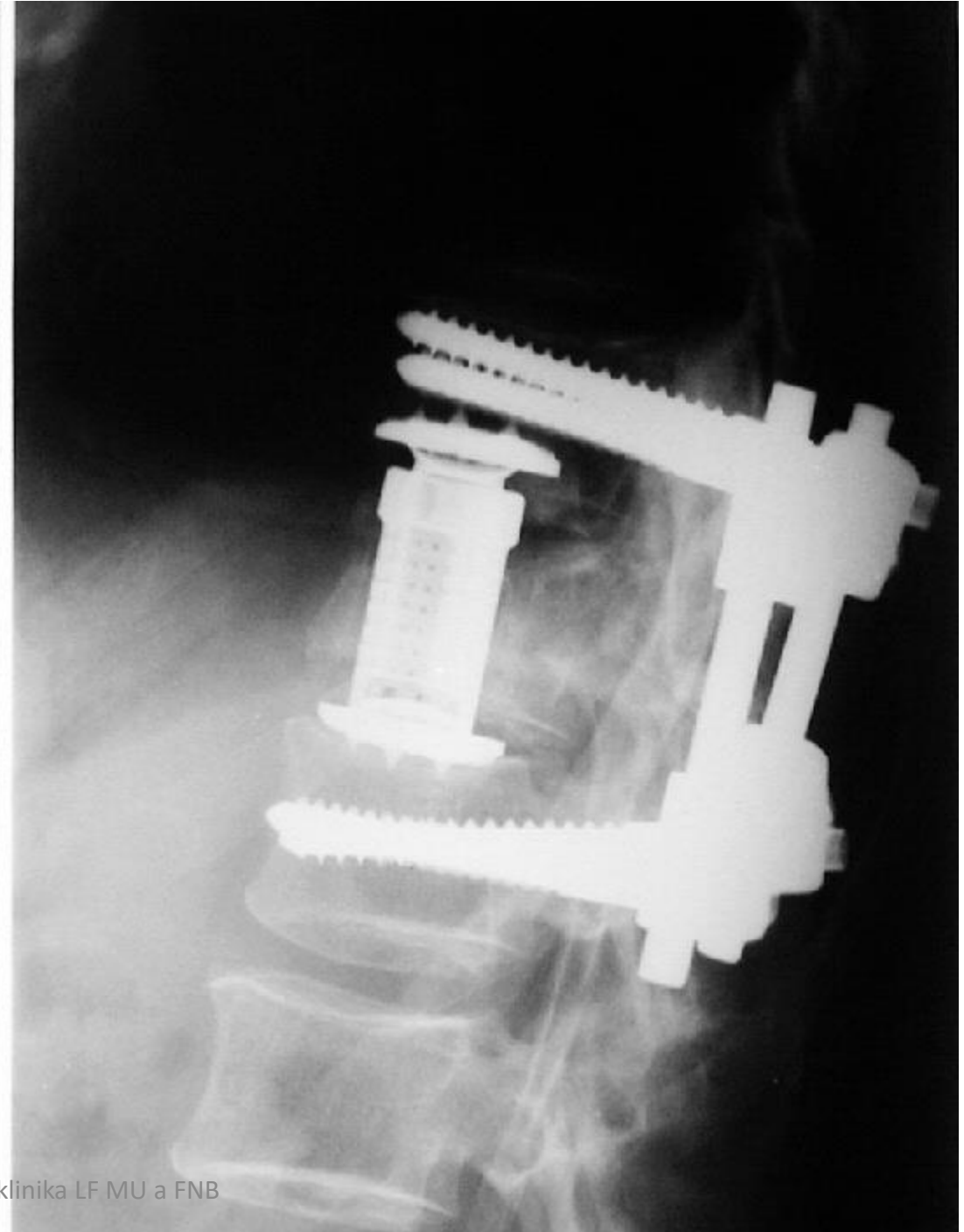
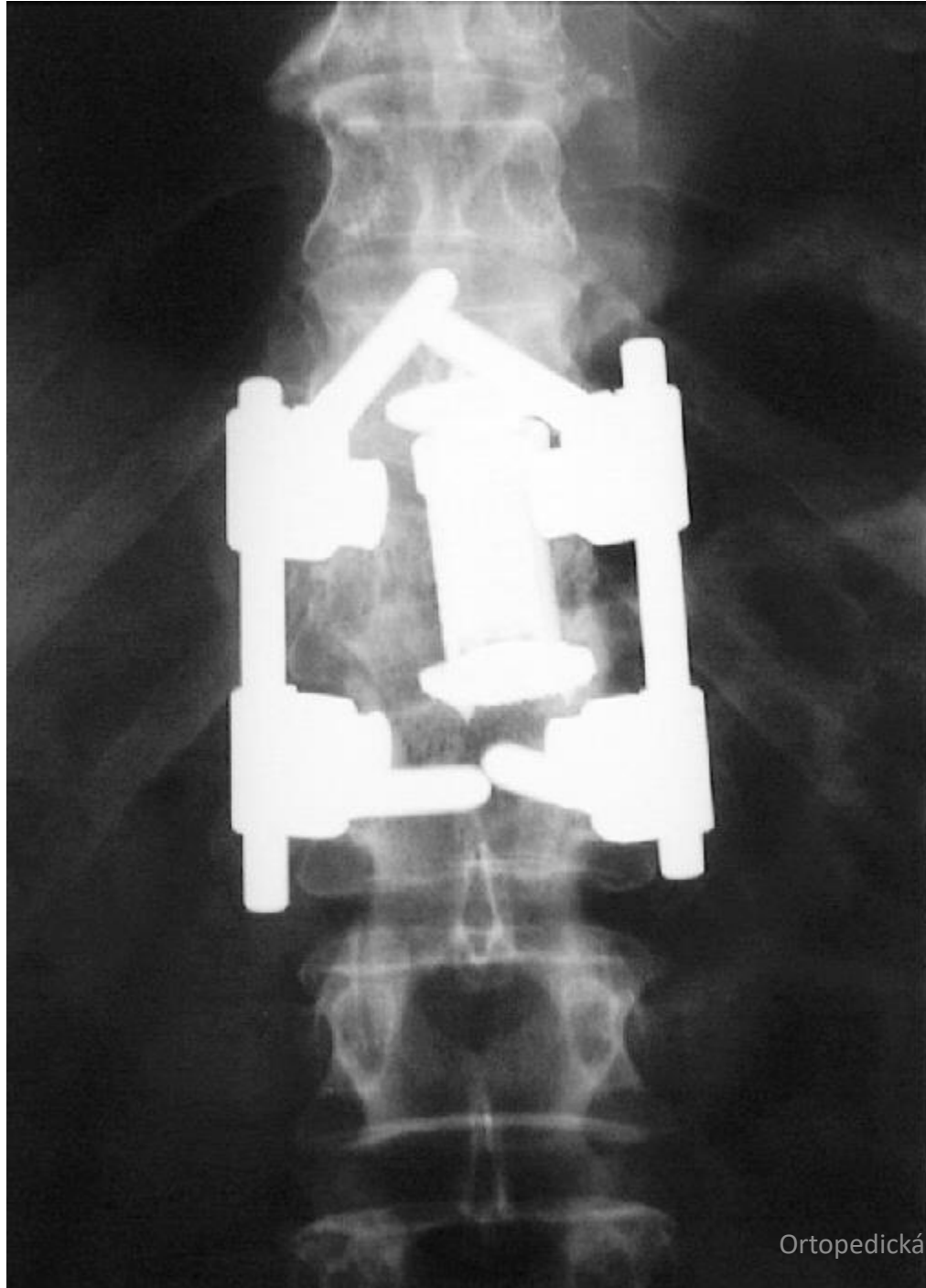


VEL
627

27 Nov 99 22:
ELSCINT Helix
140kV, 40
SC 25
SW 5

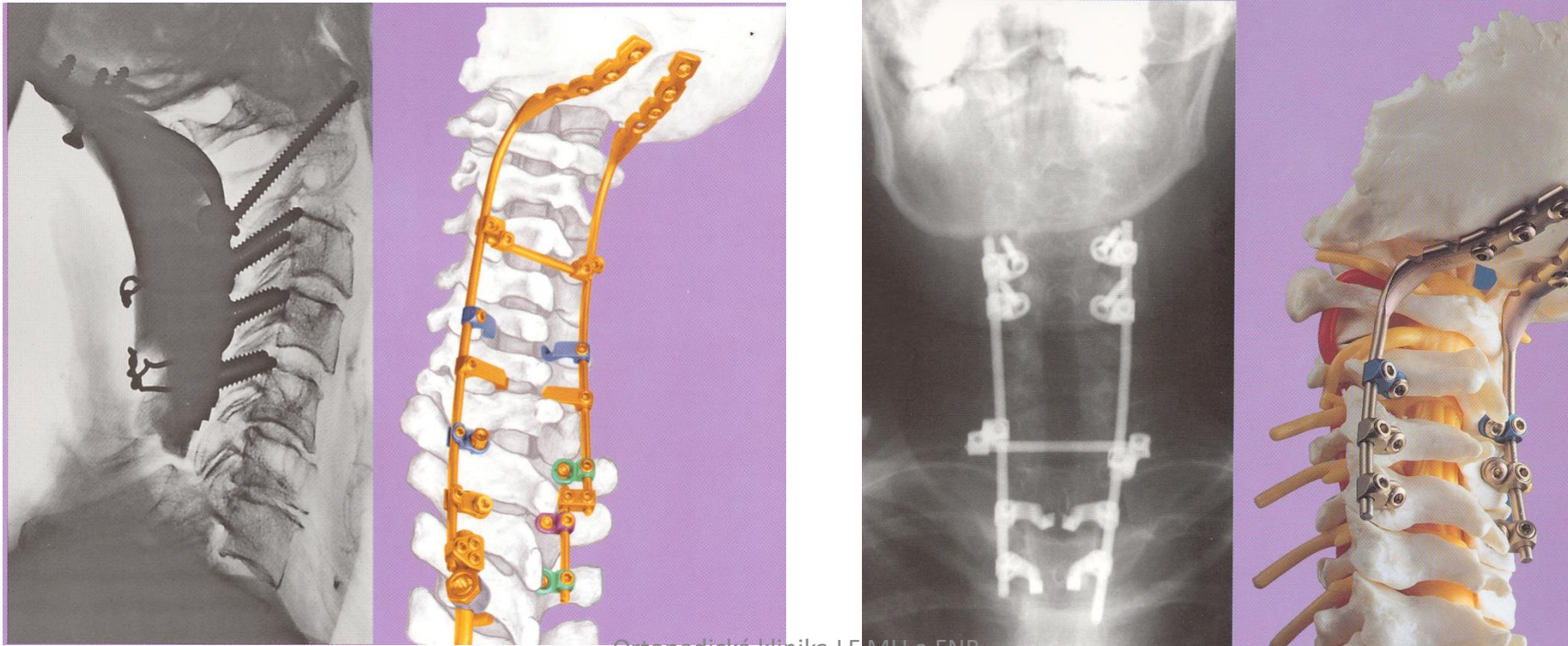






STABILIZACE OC přechodu

- Synthes
- Star Lock
- CerviFix



PORANĚNÍ C1,2

Méně časté, velké násilí působící na OC a C

Zlomenina tylní kosti

Zlomenina oblouku C1

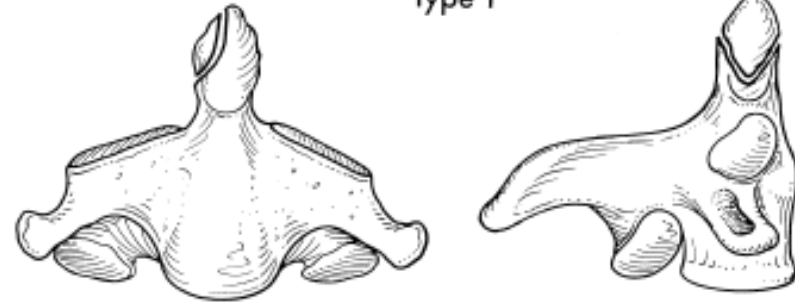
Odlomení zubu C2

Zlomenina těla C2

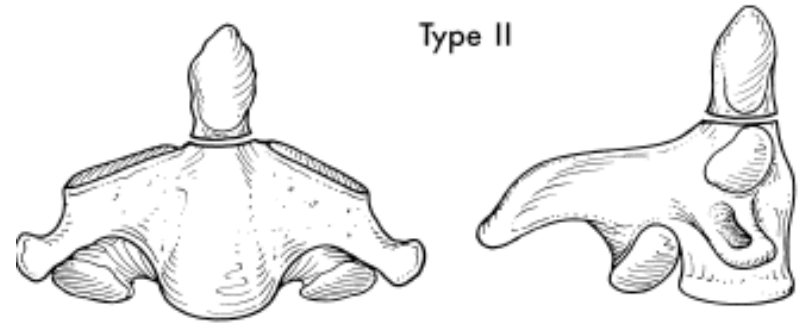
KONZERVATIVNÍ TERAPIE

ZLOMENINA DENTU

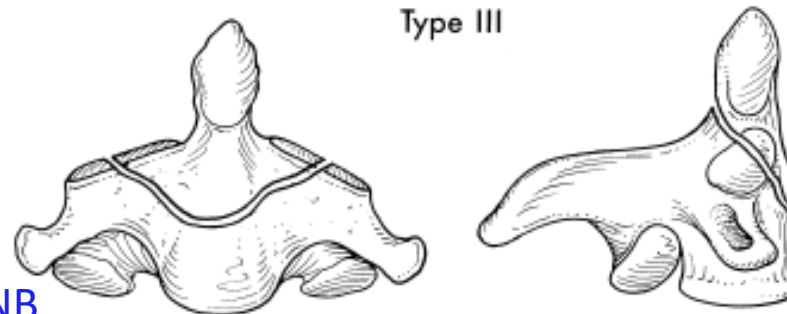
Type I



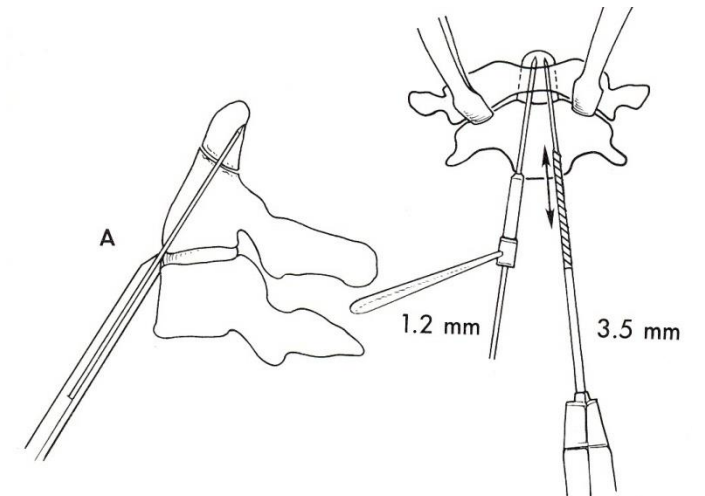
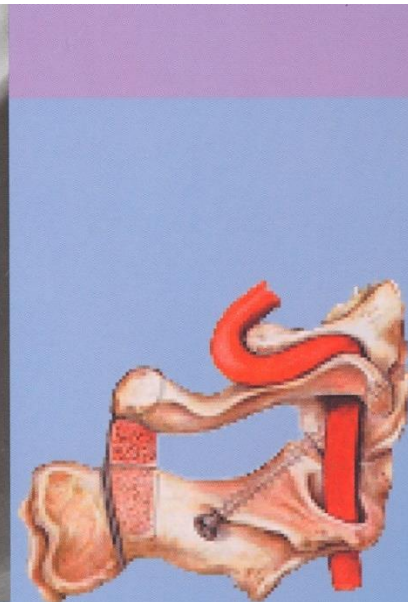
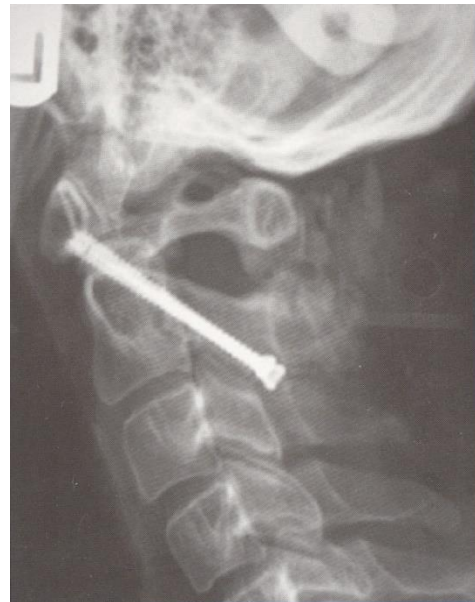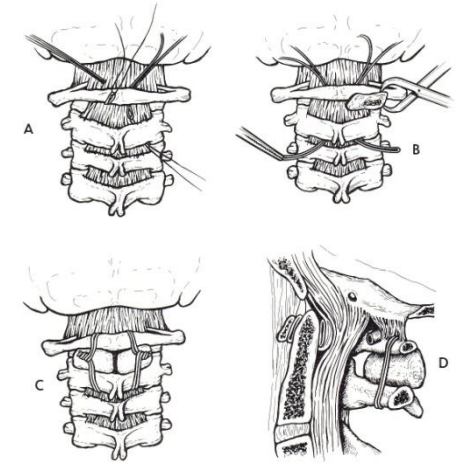
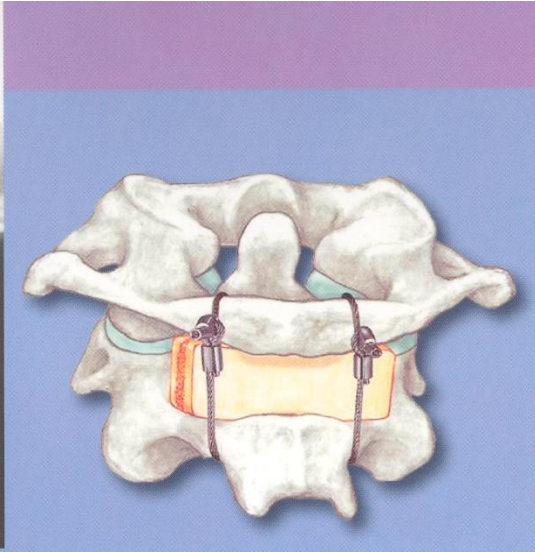
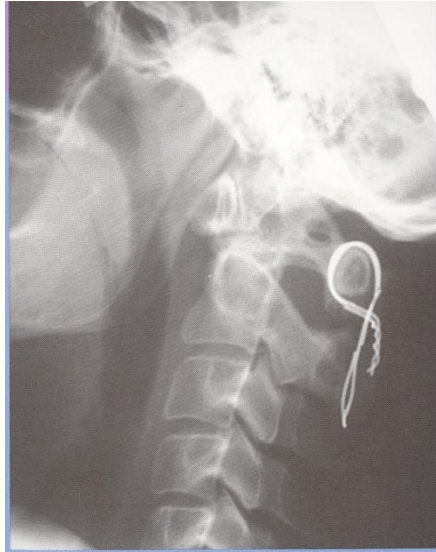Type II



Type III

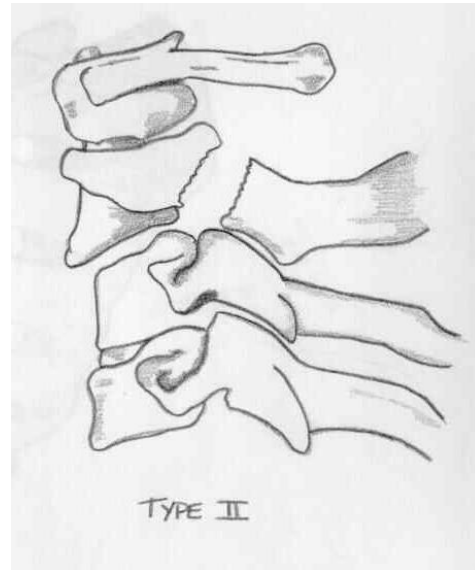
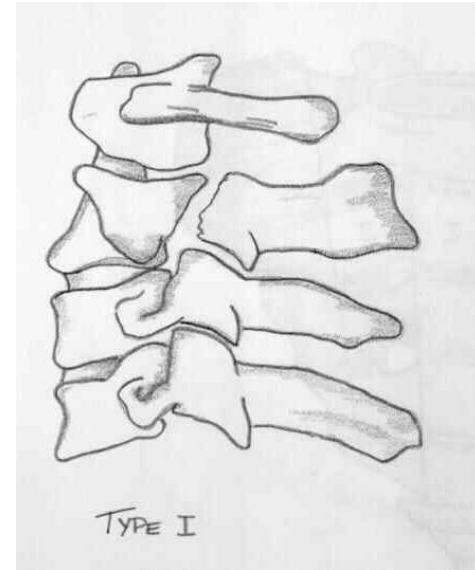
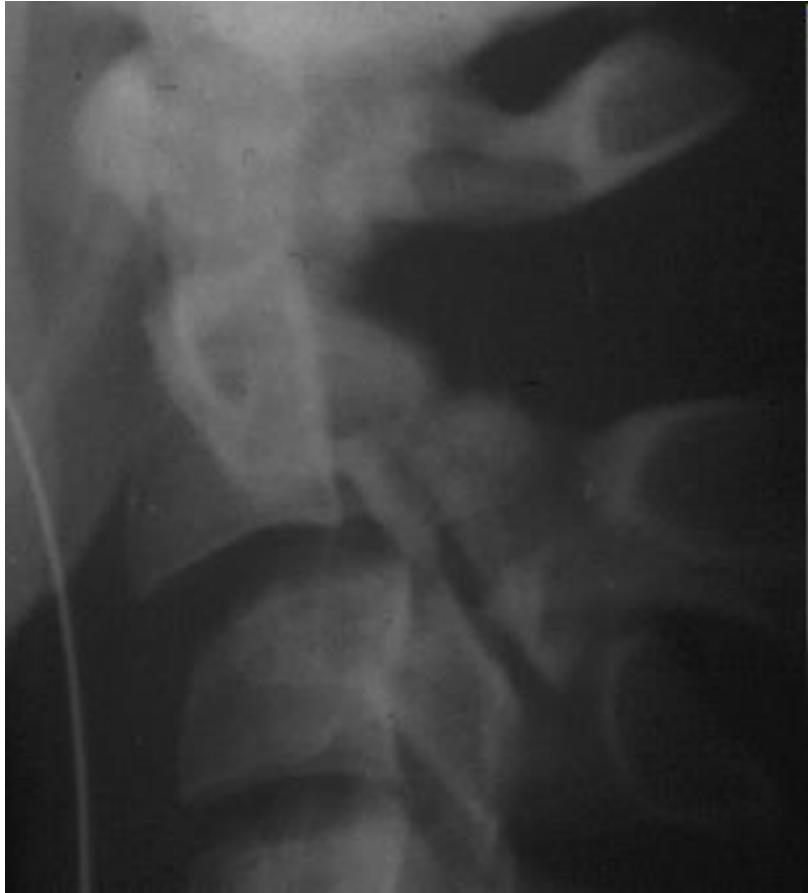

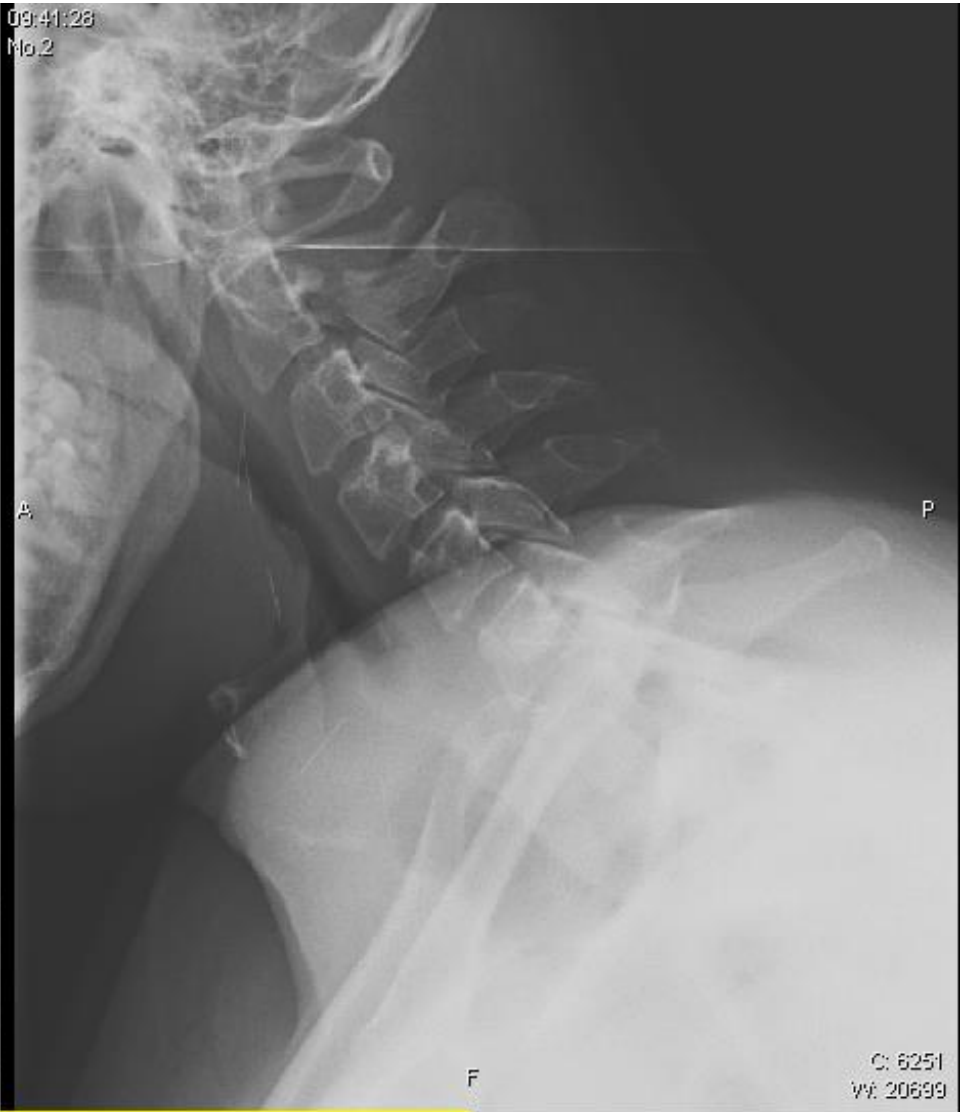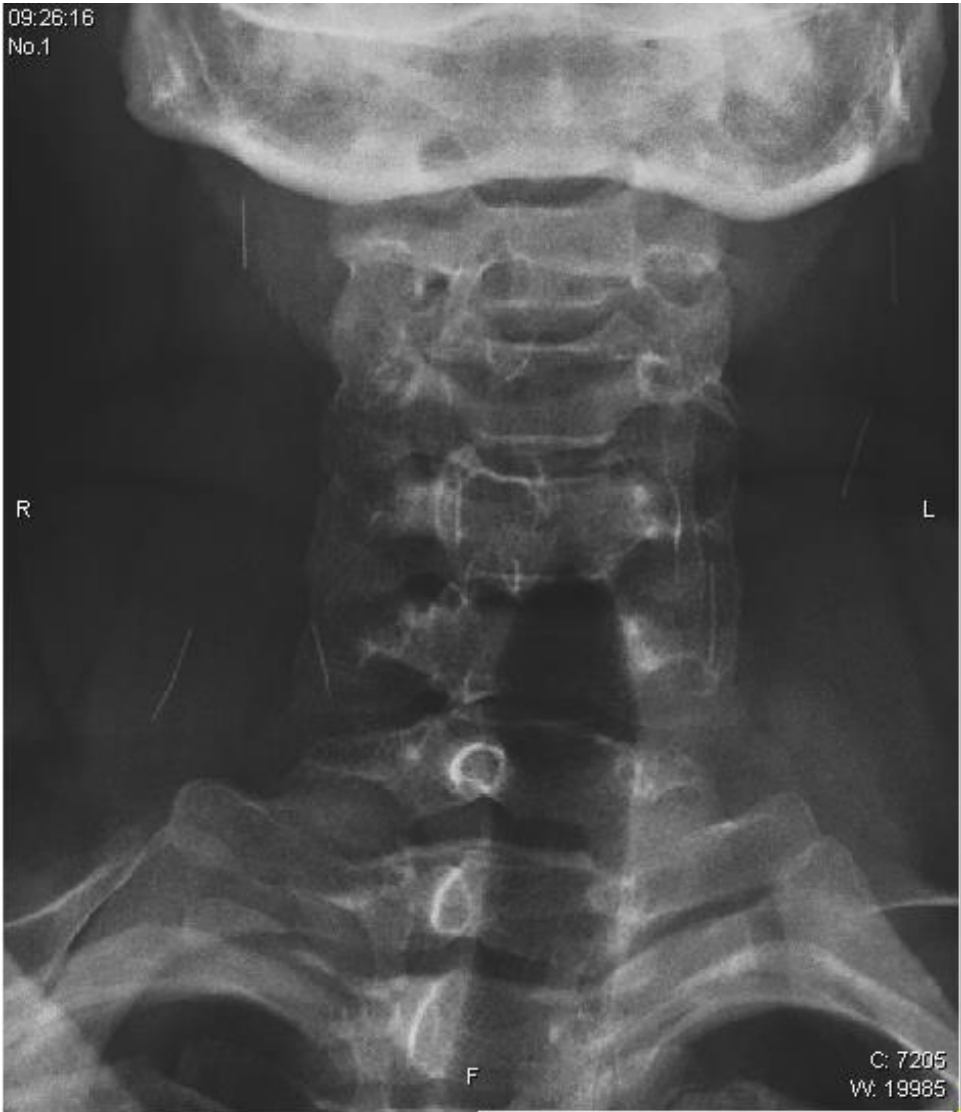ZLOMENINA DENTU

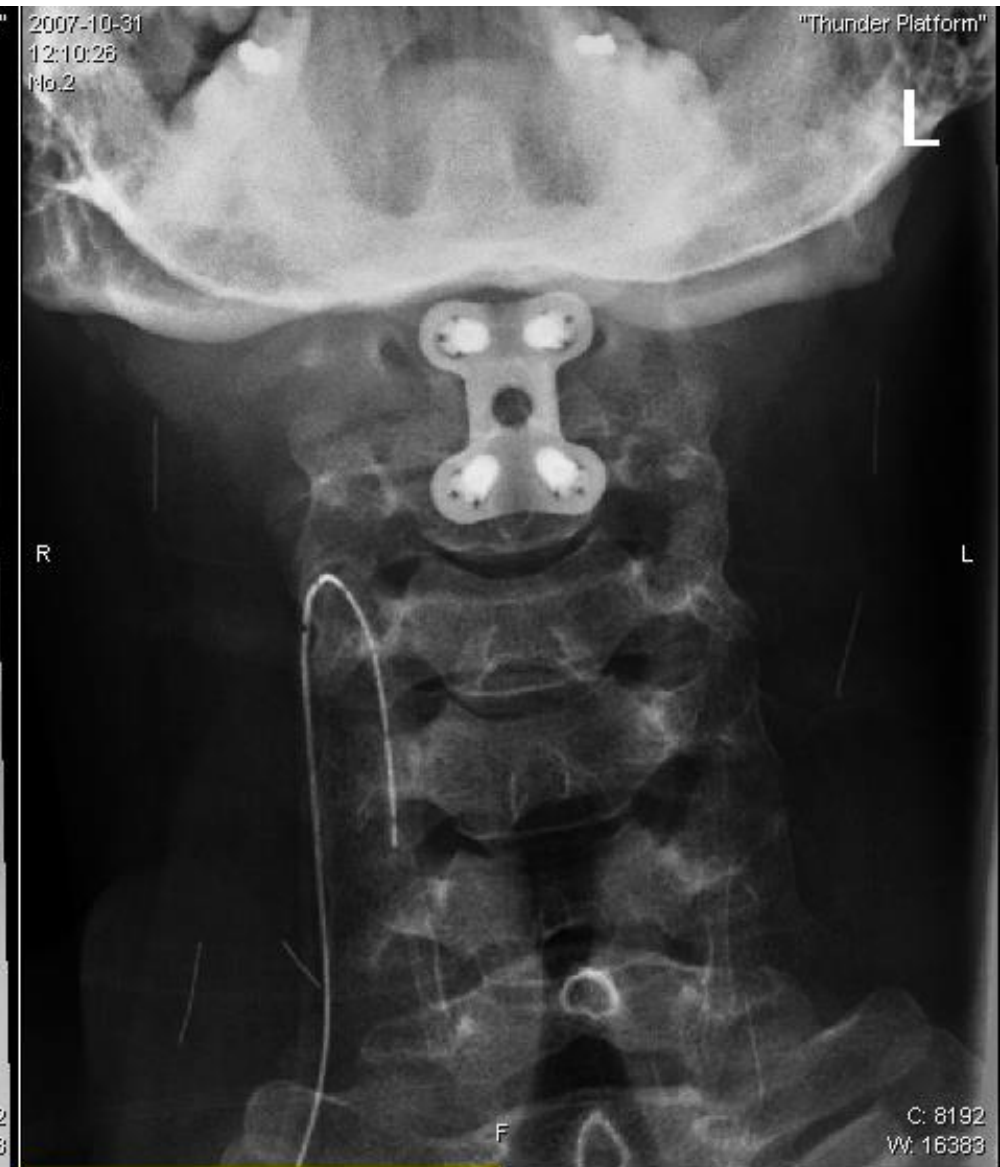
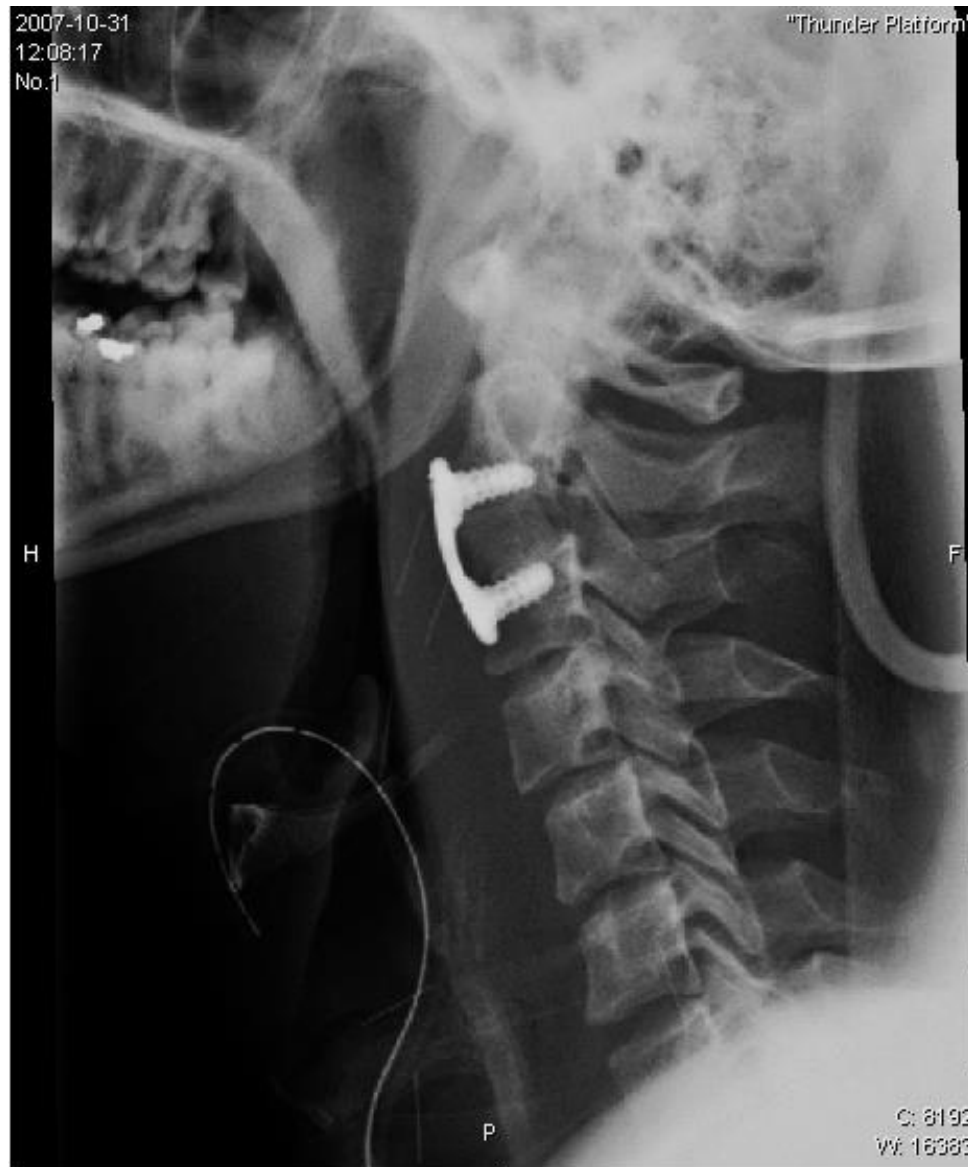
KATOVSKÁ ZLOMENINA

traumatická olisthesa C2





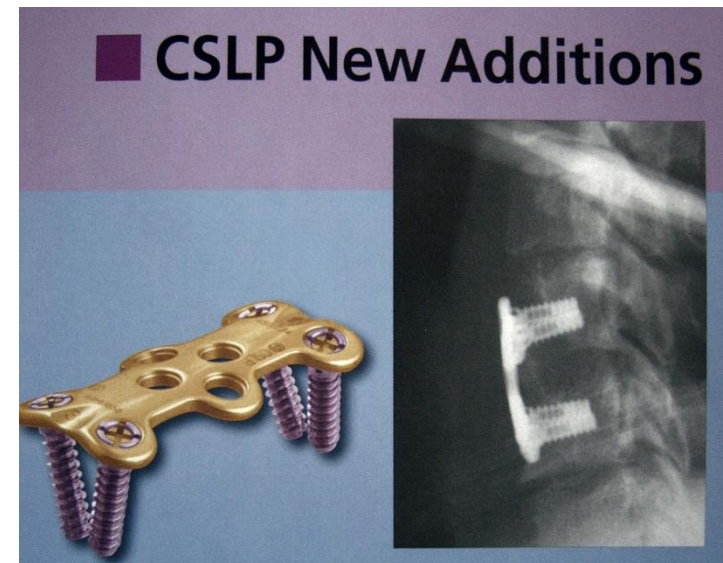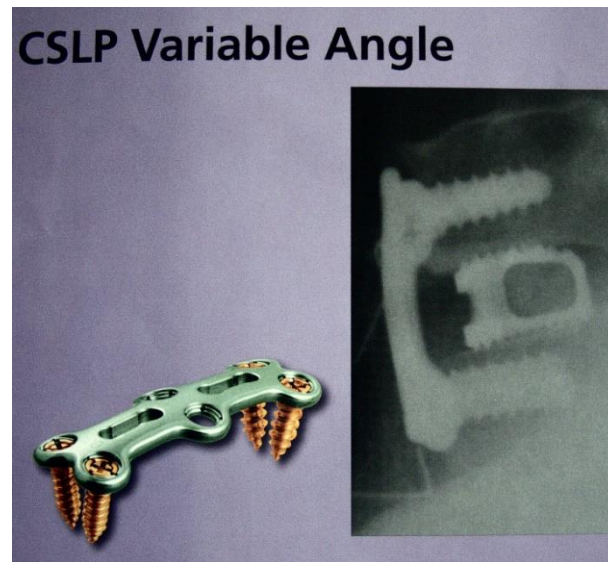

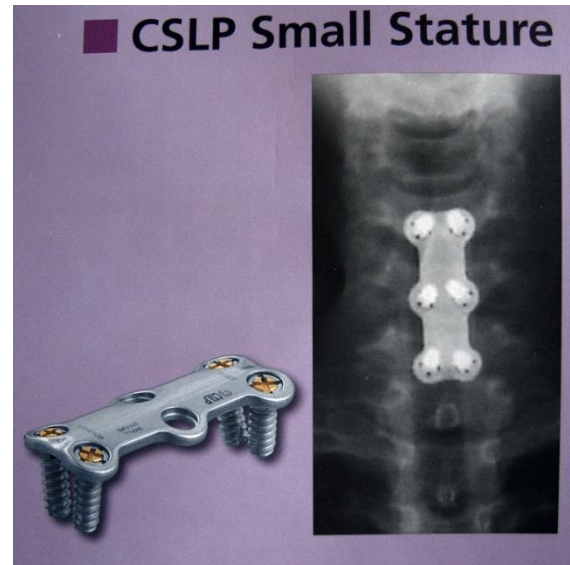
PORANĚNÍ C PÁTEŘE

- Tříštivé zlomeniny těl
- Poranění disků a ligament
 - diskoligamentózní léze
- Kombinované
 - tear drop

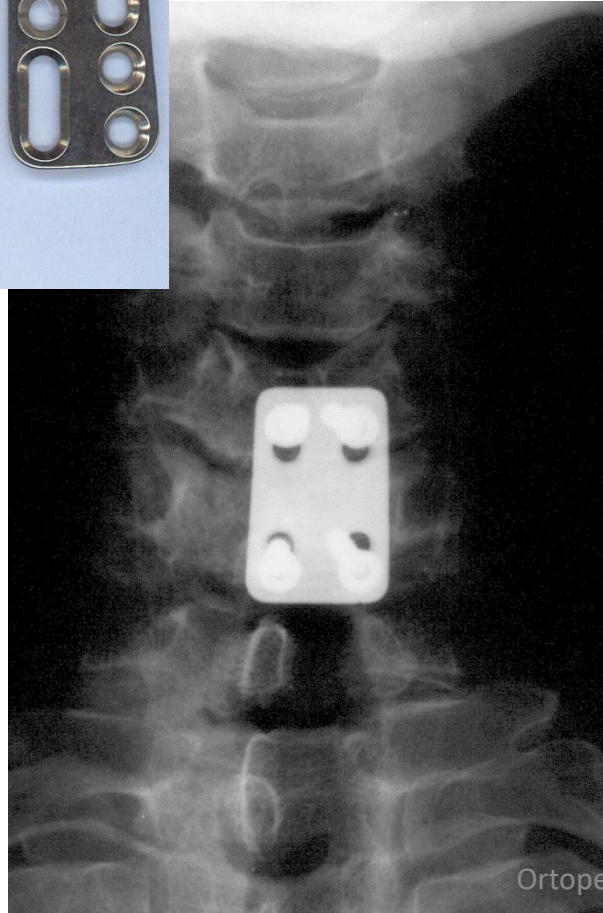

C páteř

- přední výkony
 - náhrada těl
 - náhrada disků
- stabilizace

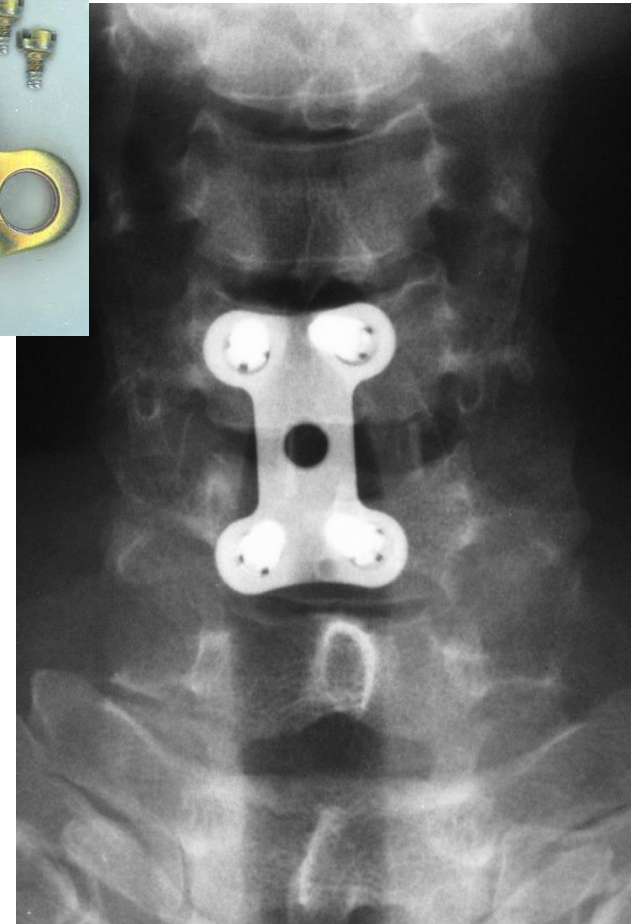

KRČNÍ DLAHY- STABILIZACE

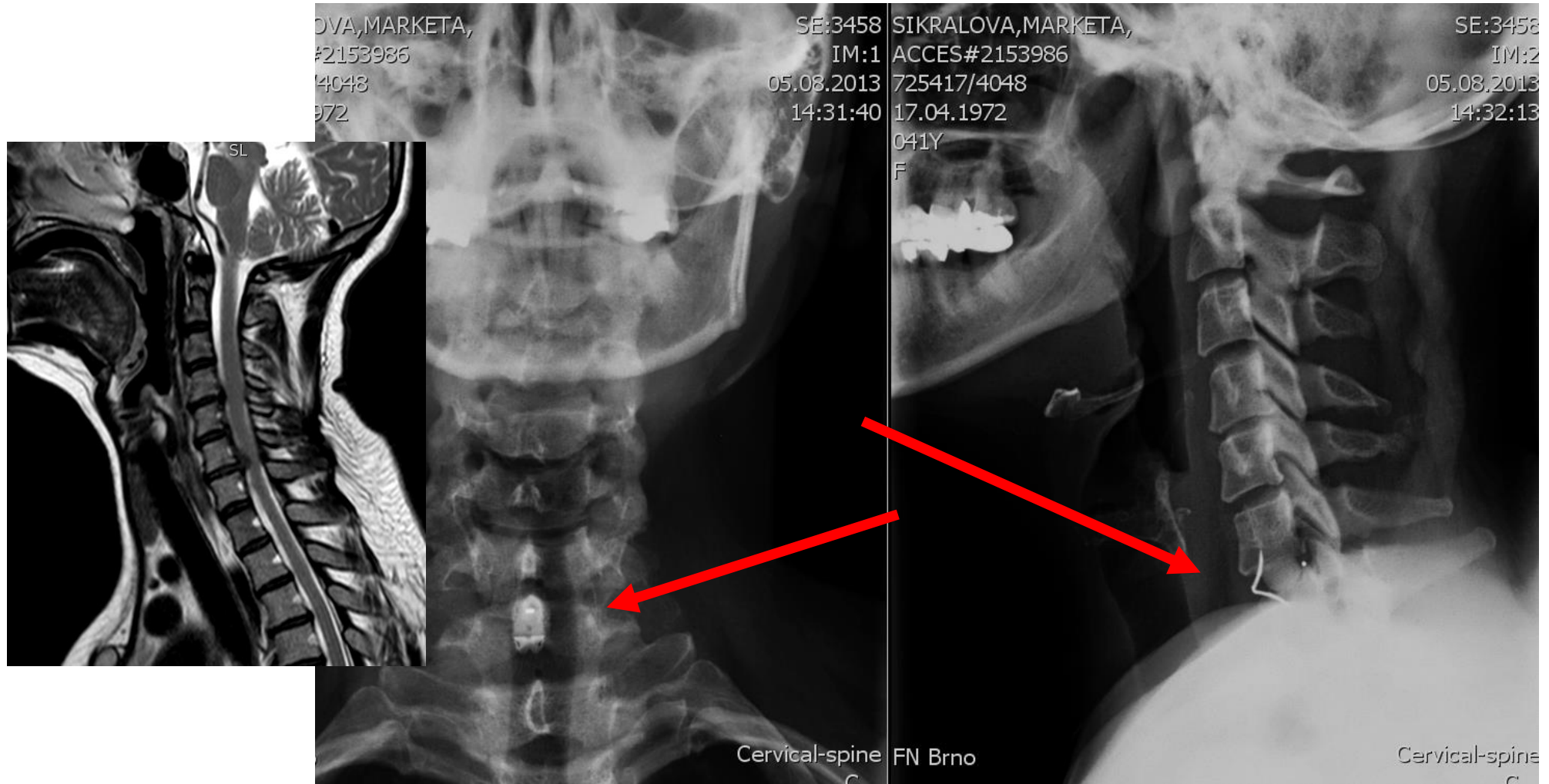
- **CASPAR**



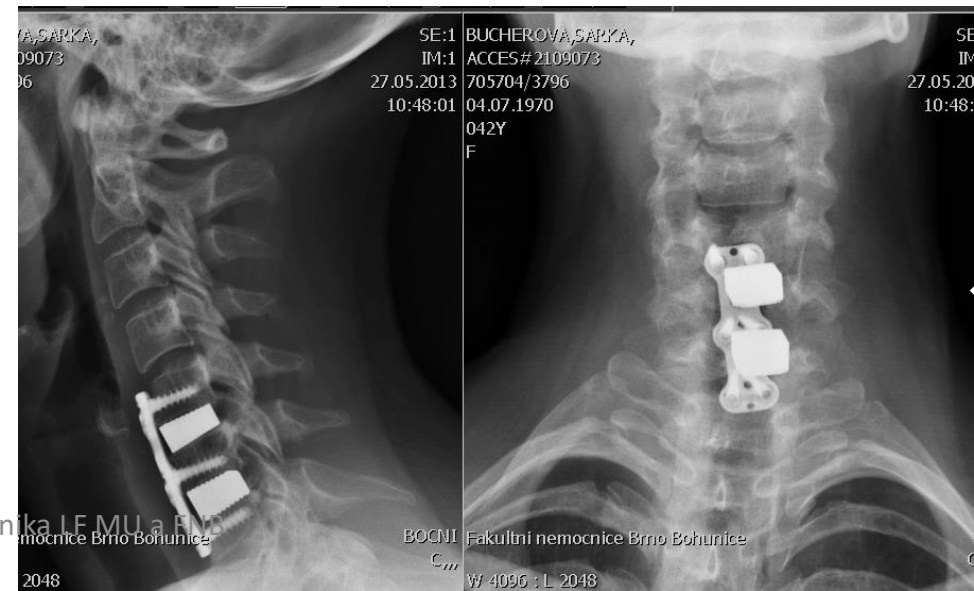
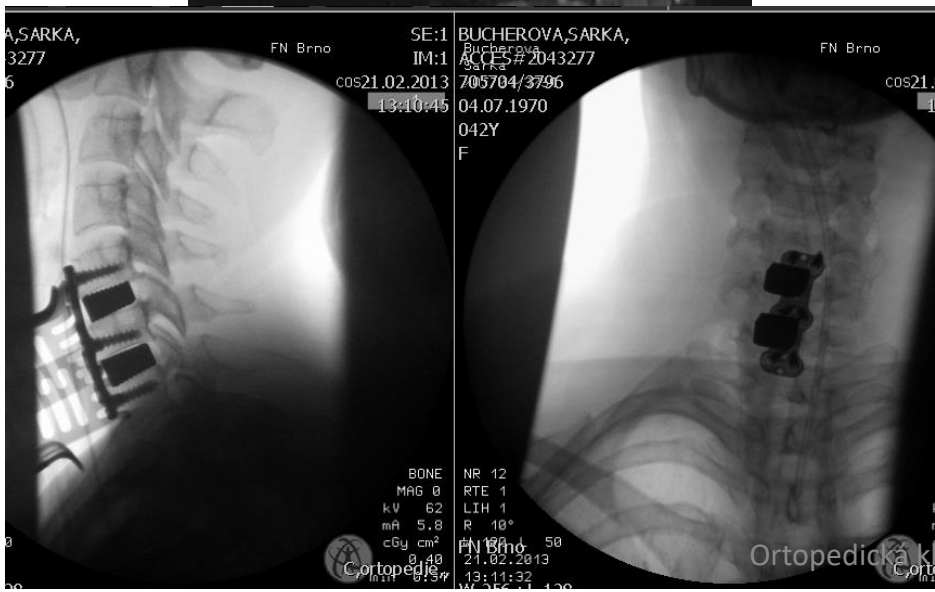
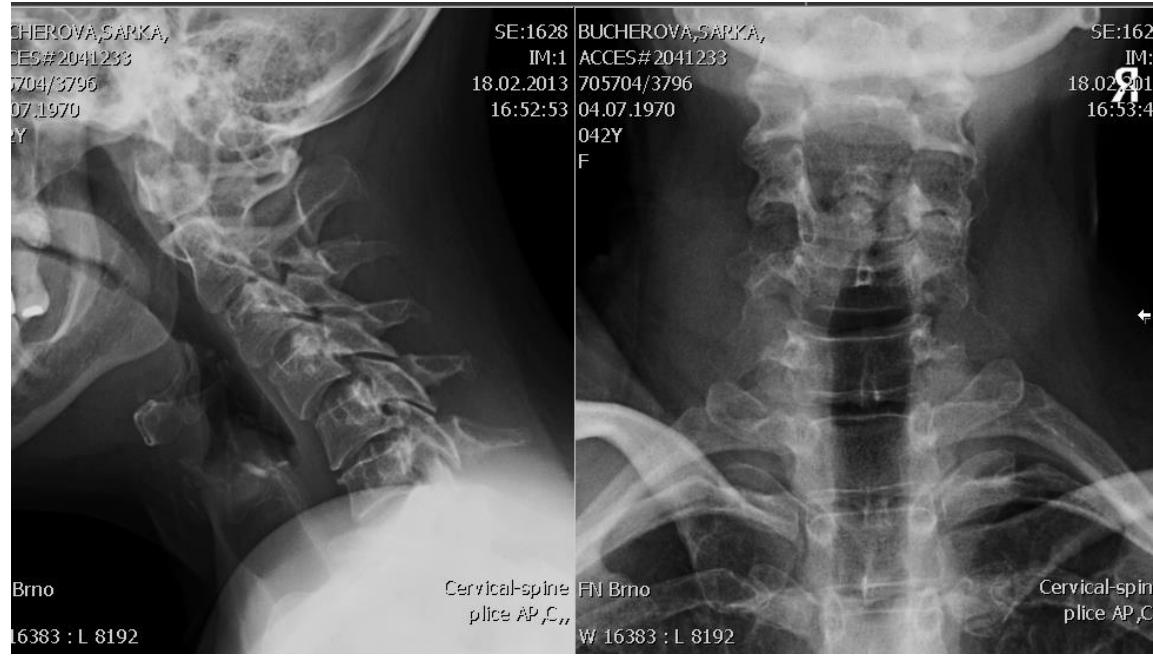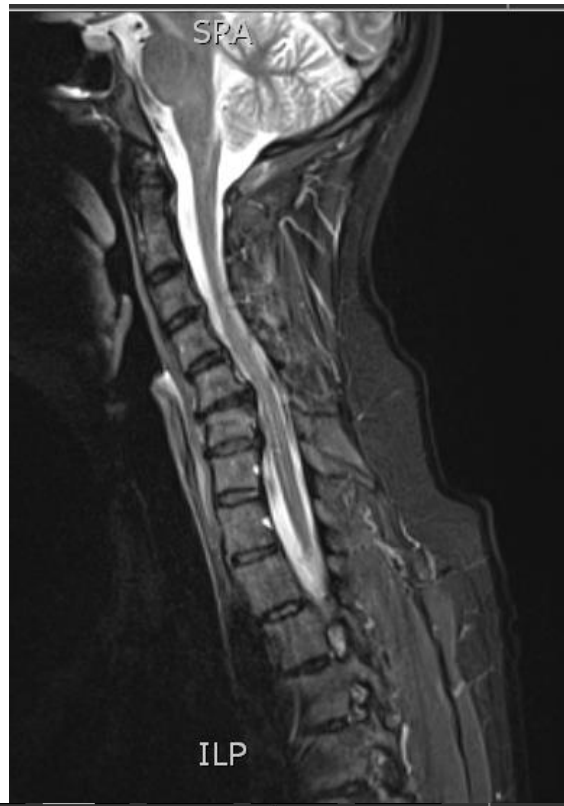- **SYNTHES**



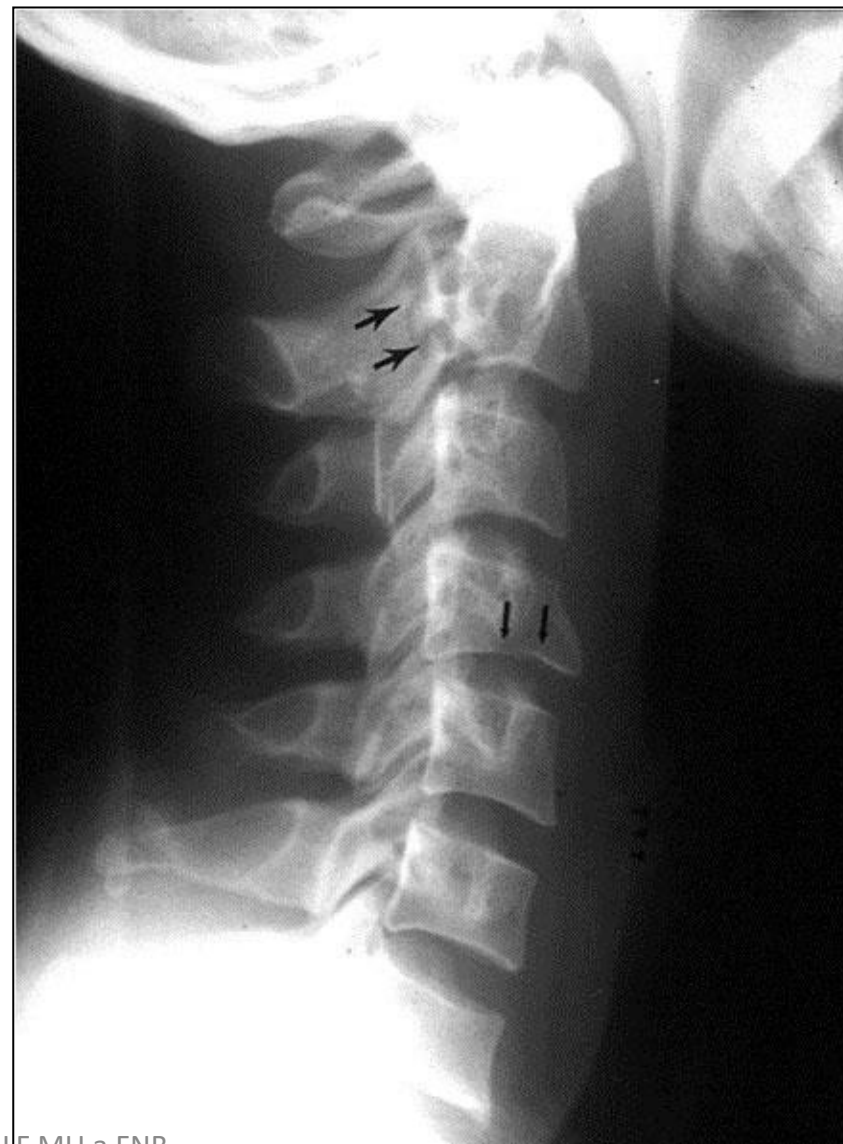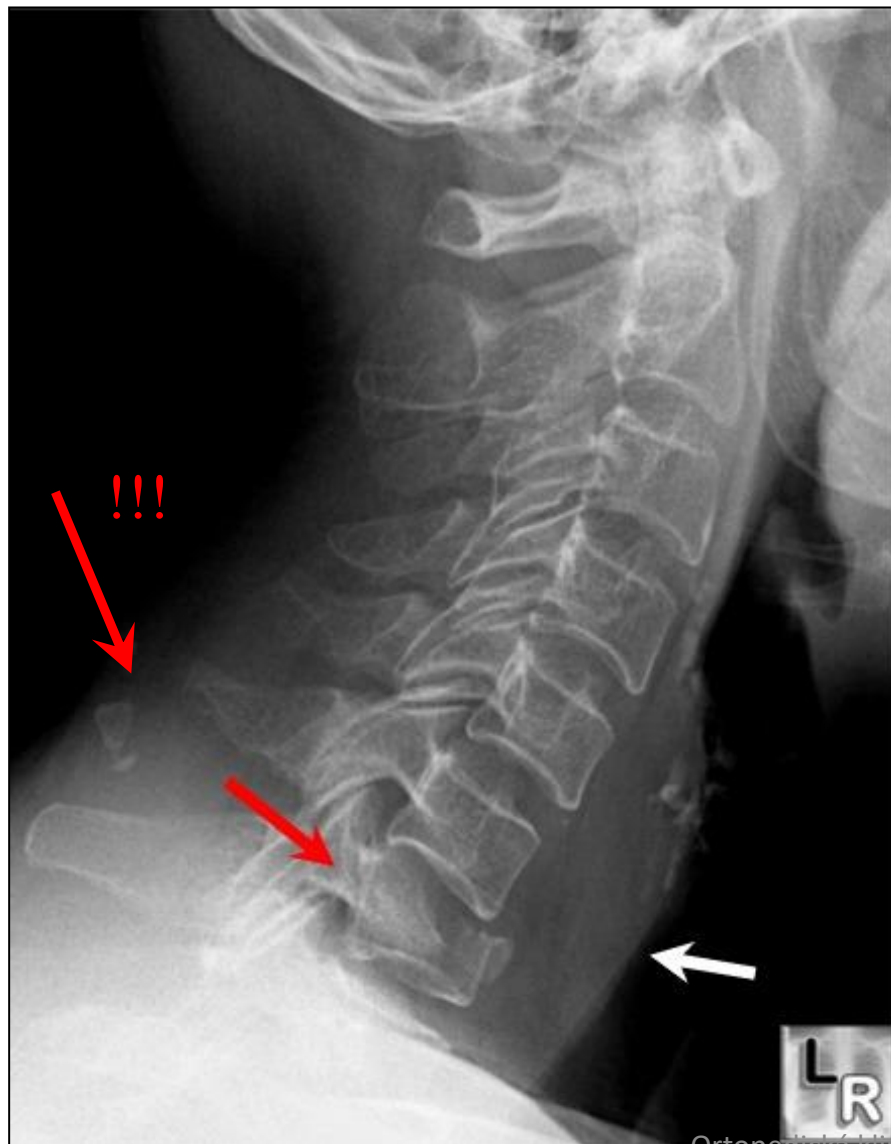INTERSOMATICKÁ FÚZE



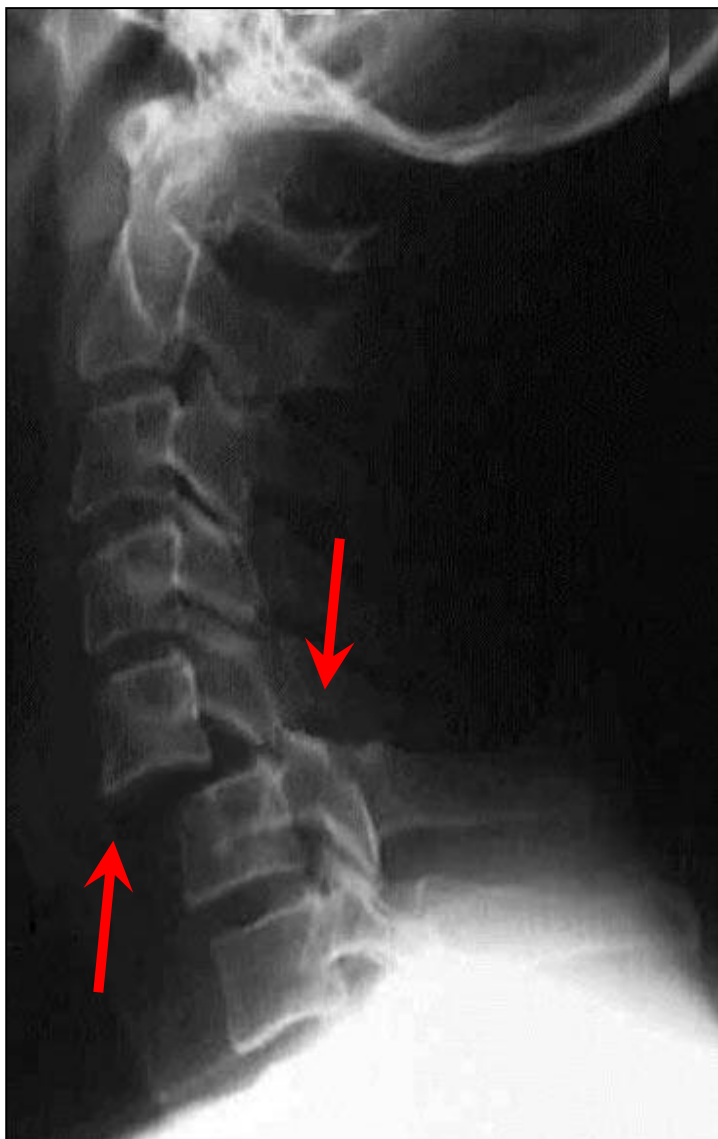Náhrada disku trabecular metal



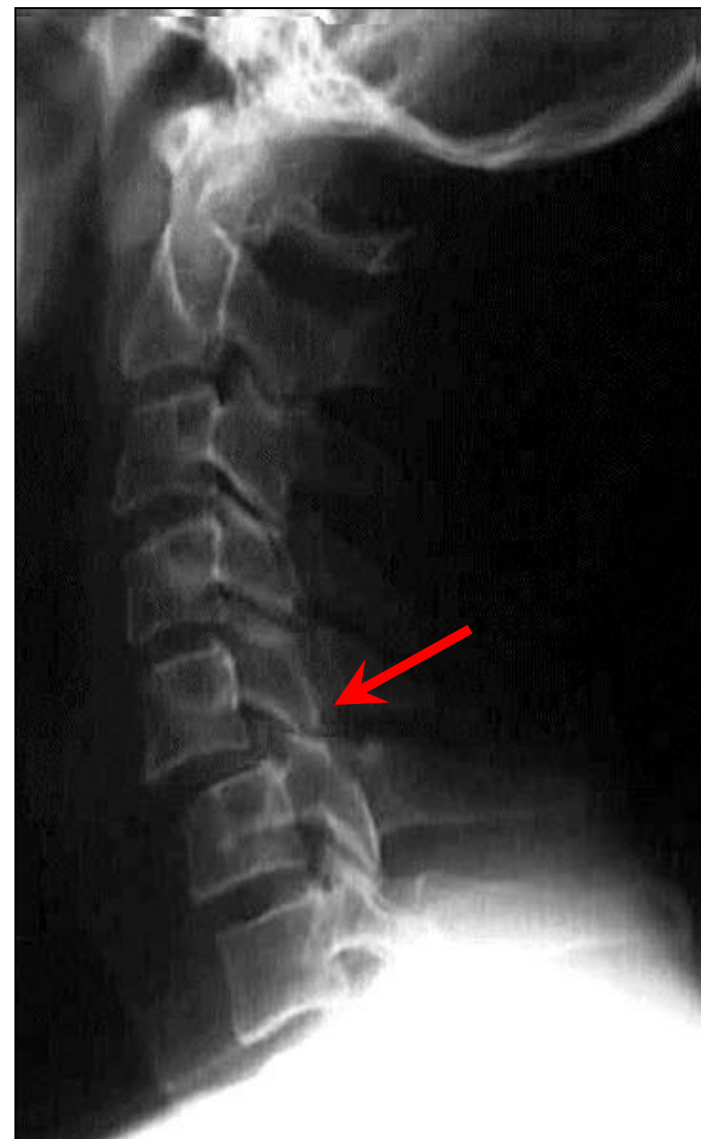Zlomenina těla a prevertebrální hematom



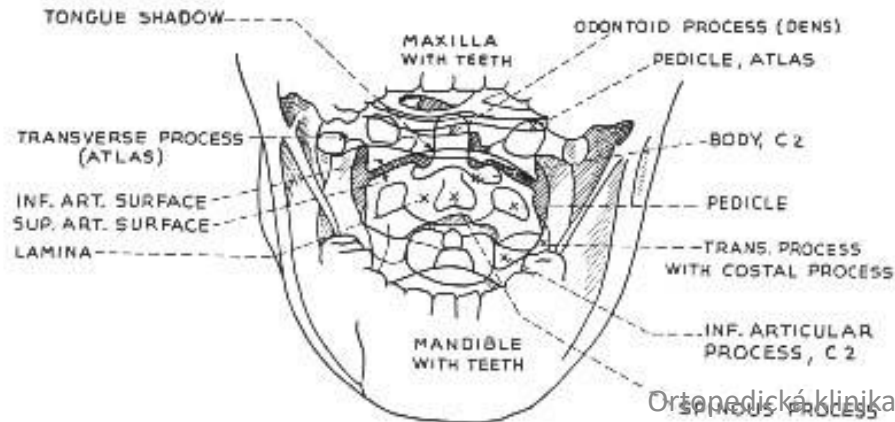
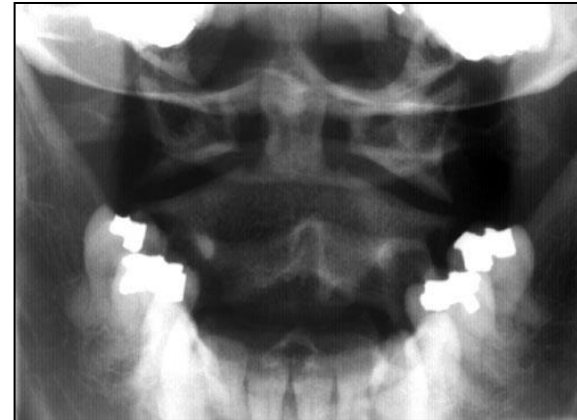
Bilaterální luxace C5/6

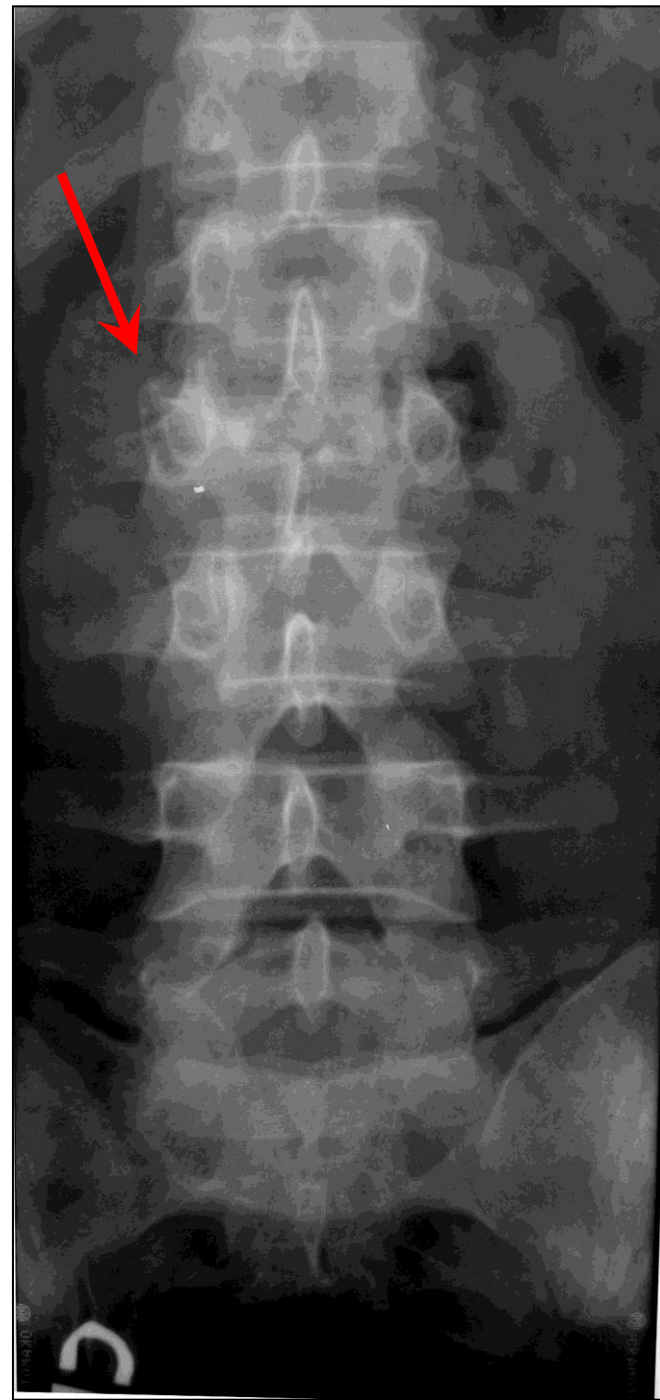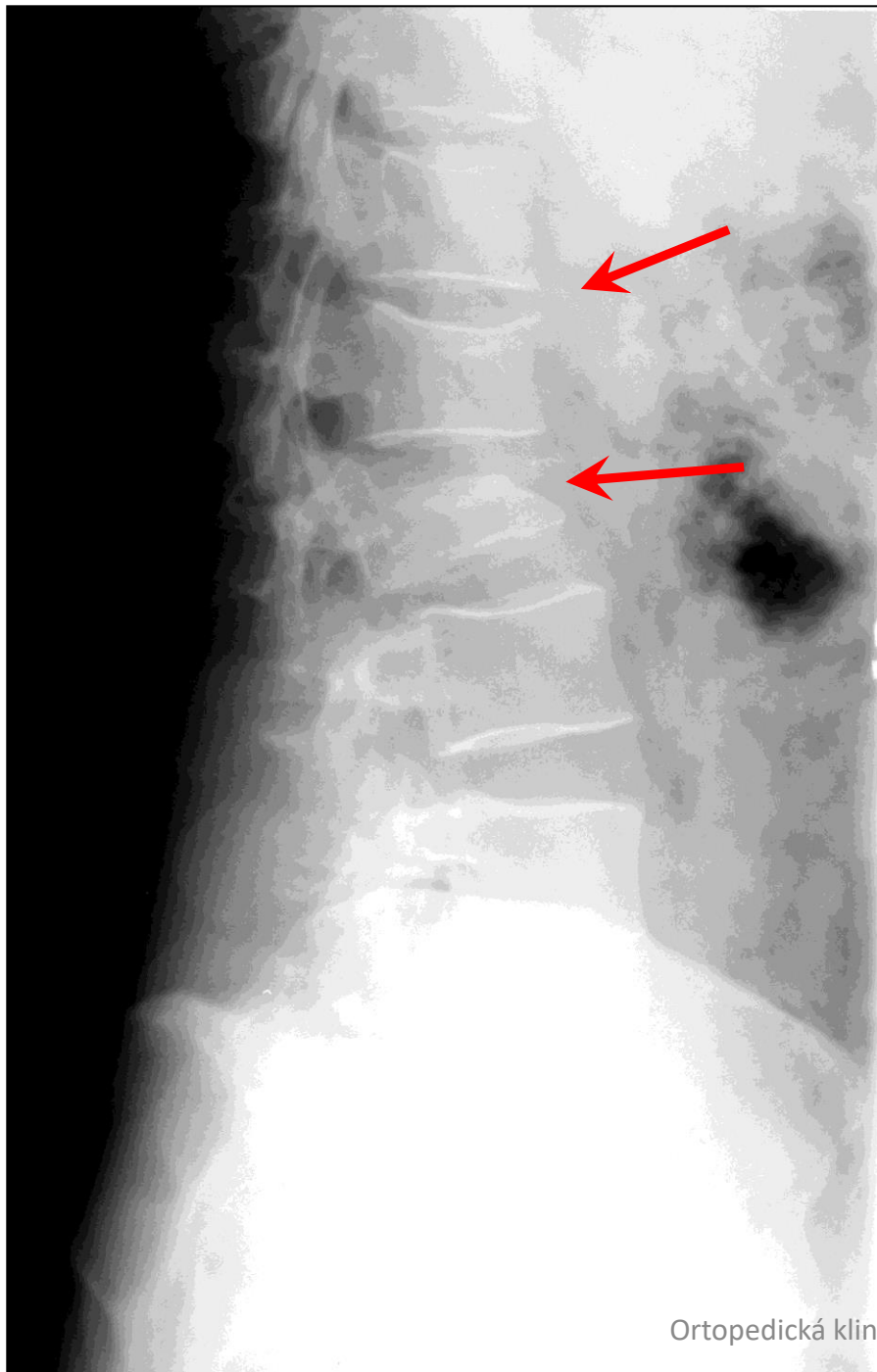


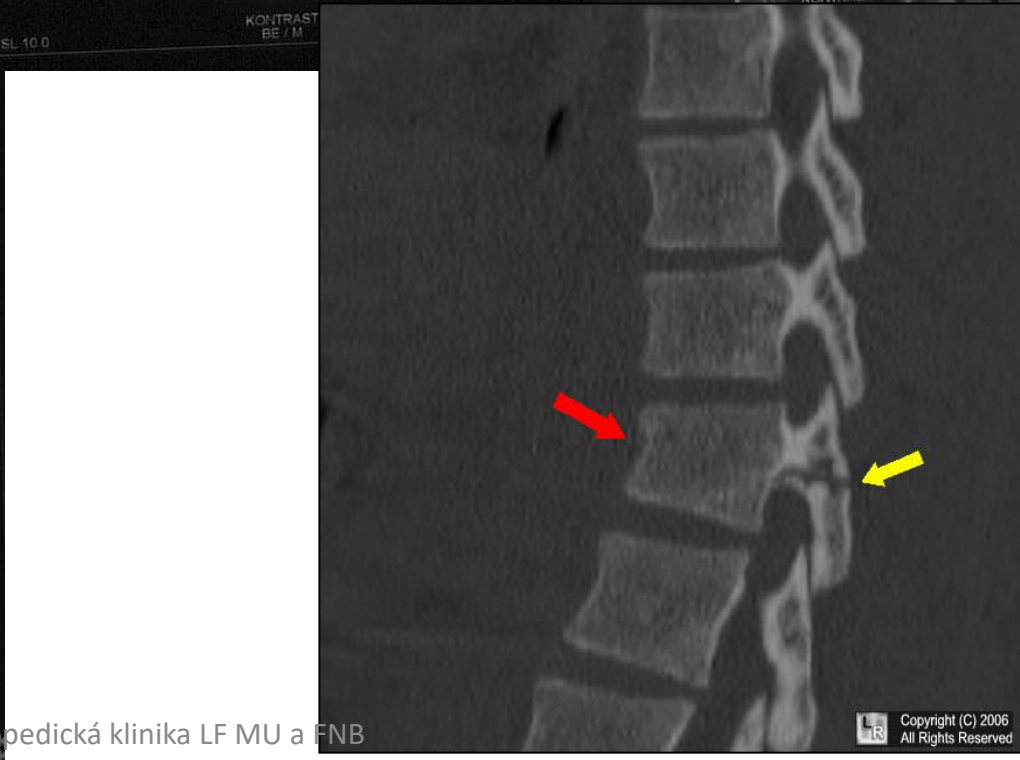
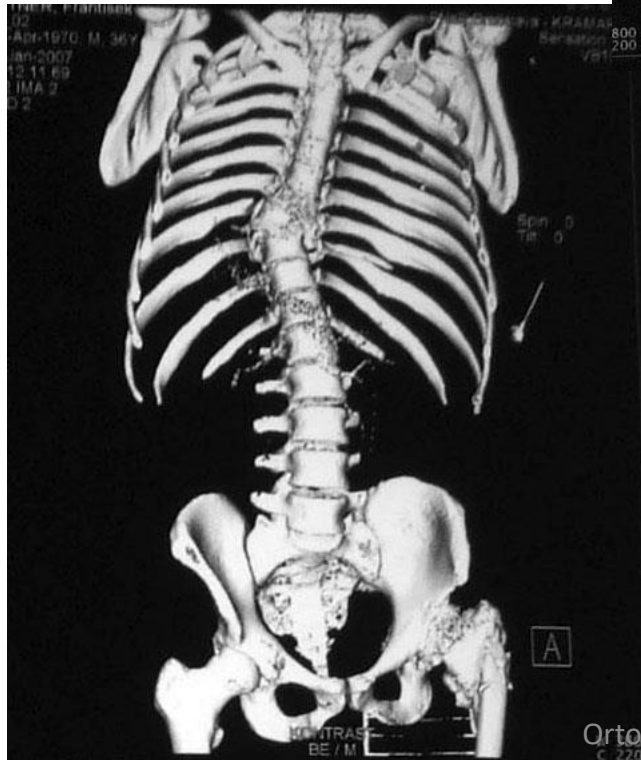
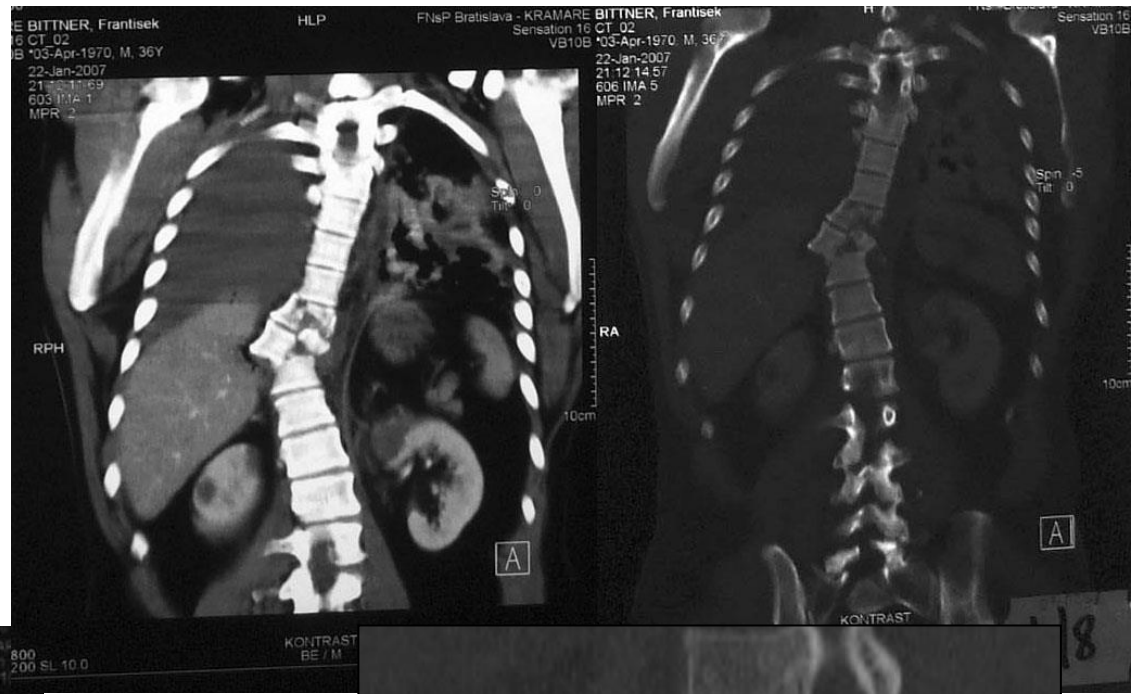
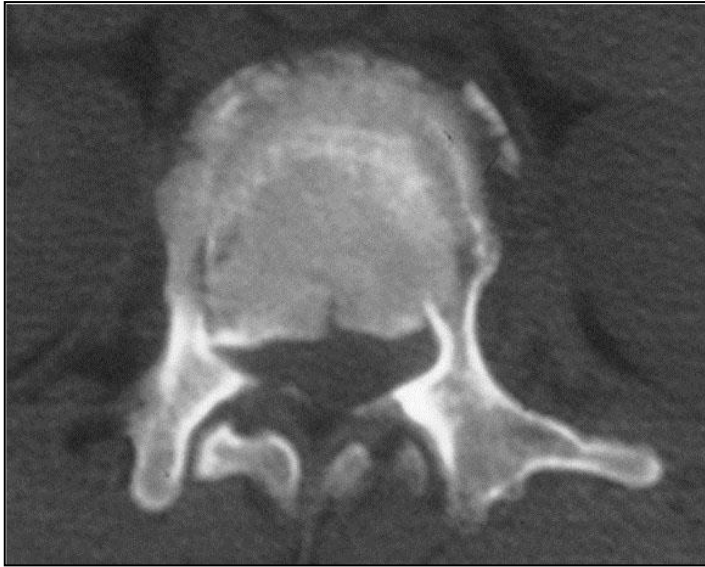Unilaterální luxace C5/6

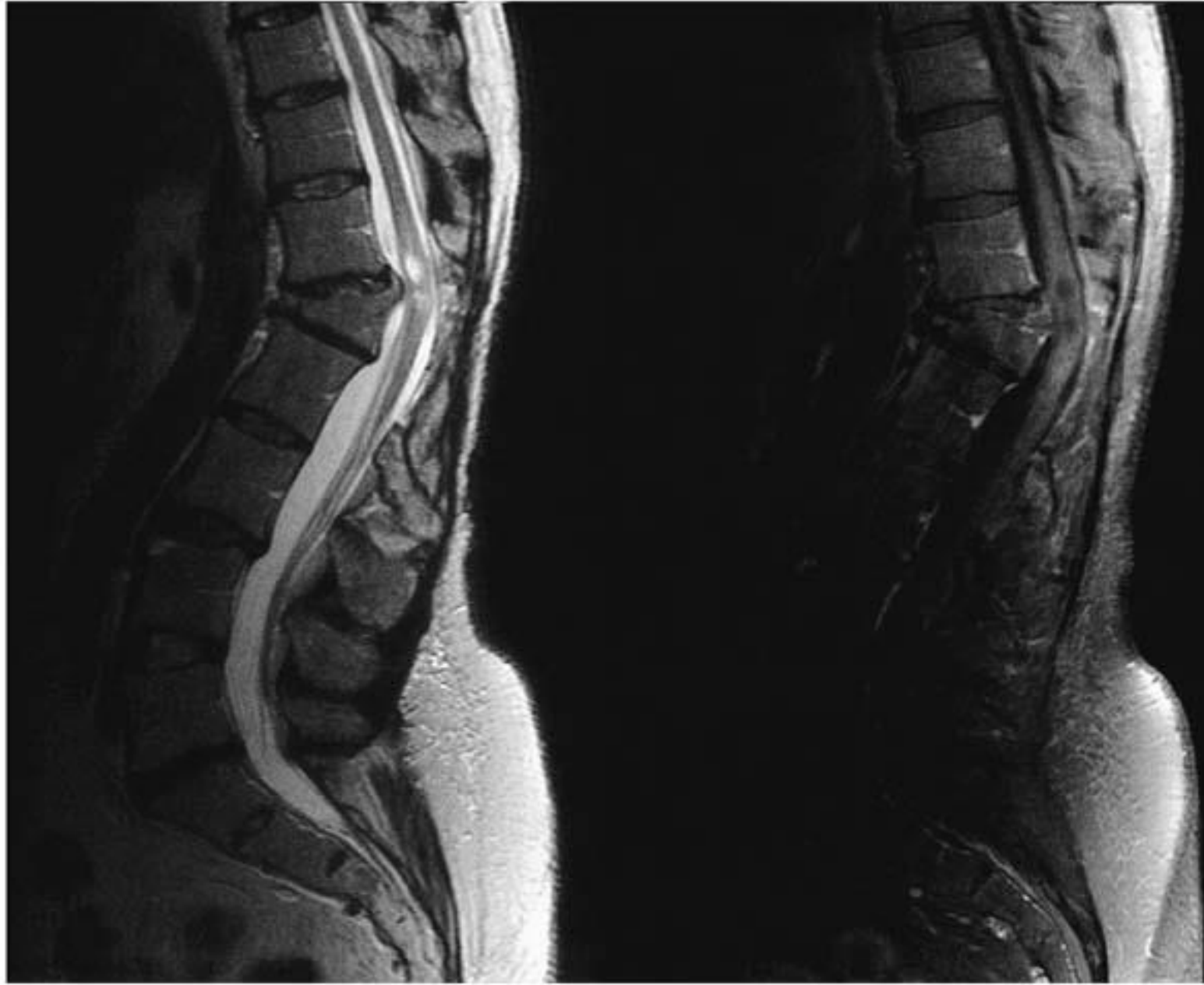

Transorální projekce C2







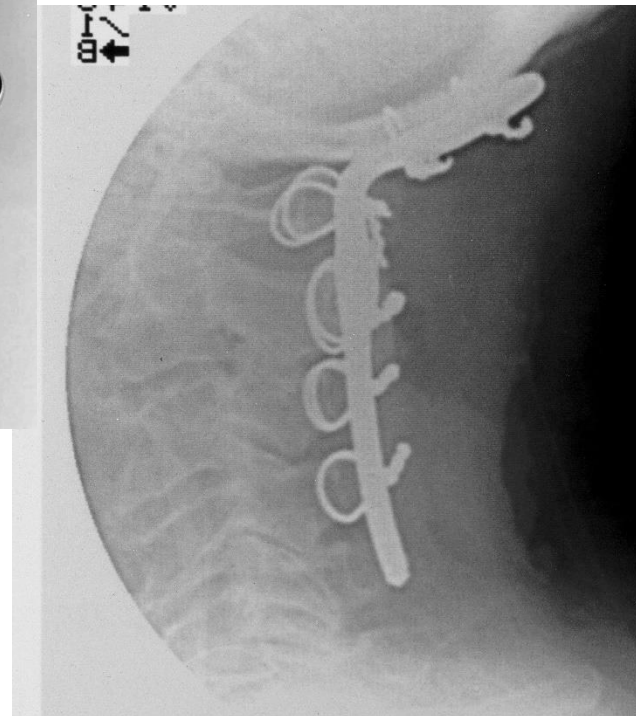
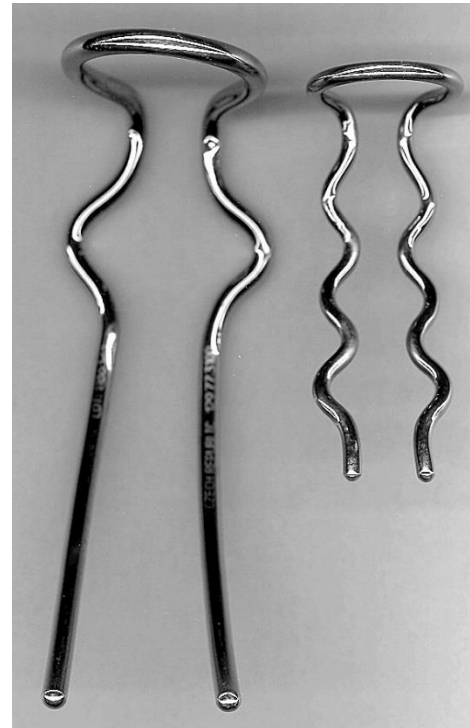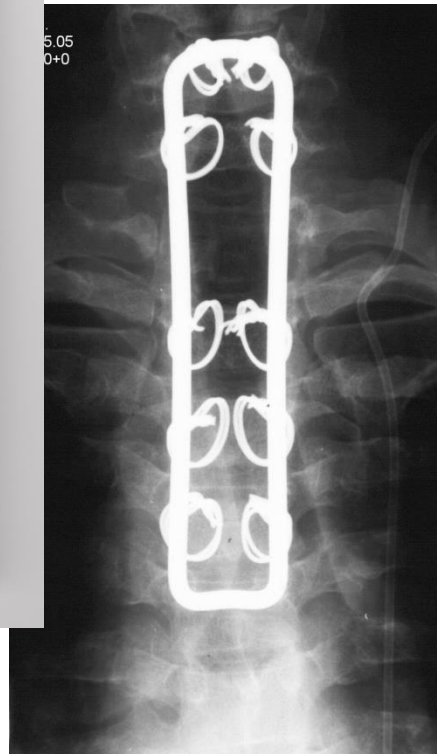


A

B

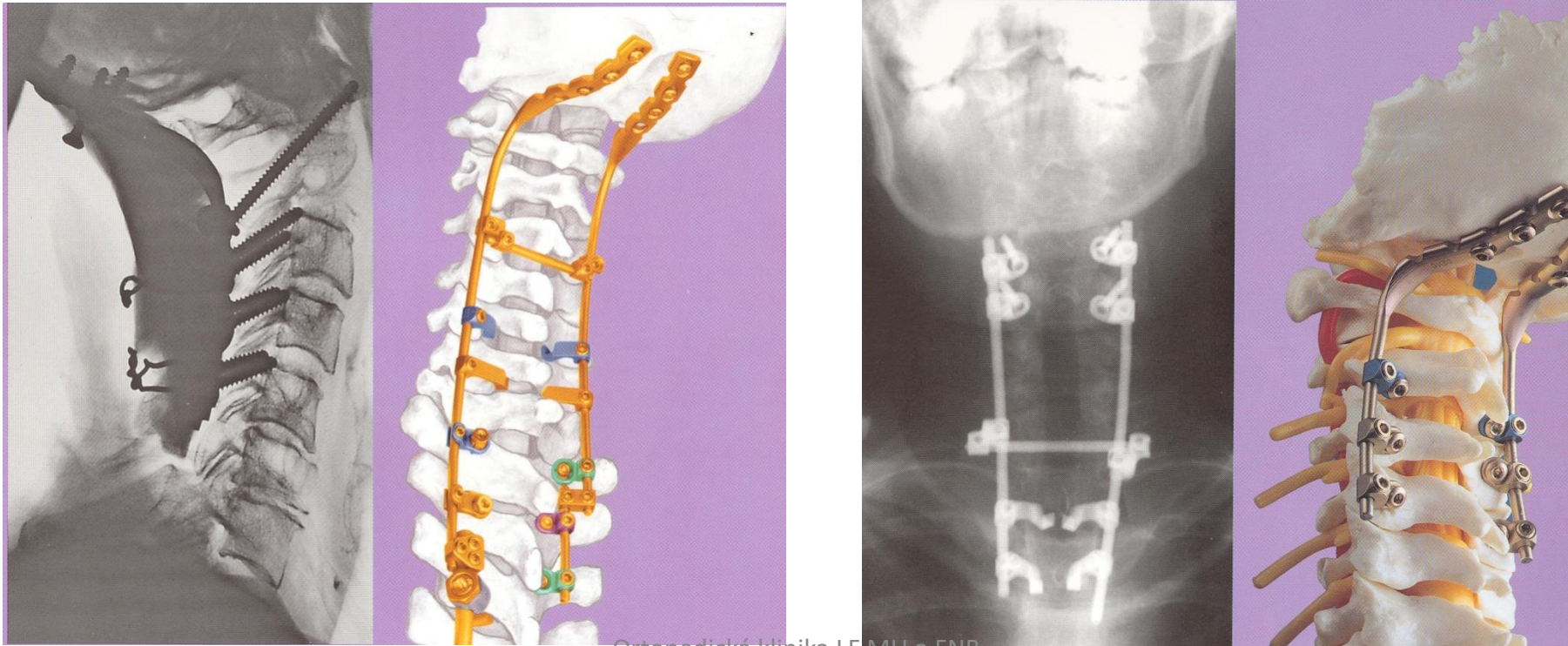
OPERACE ZE ZADU

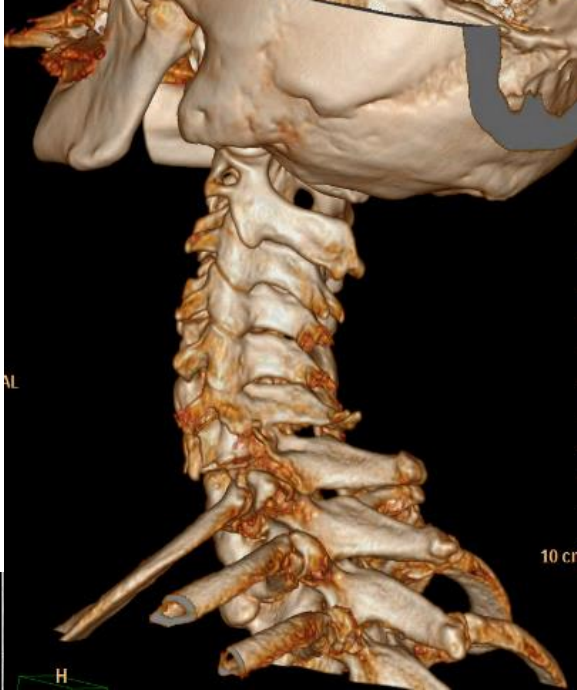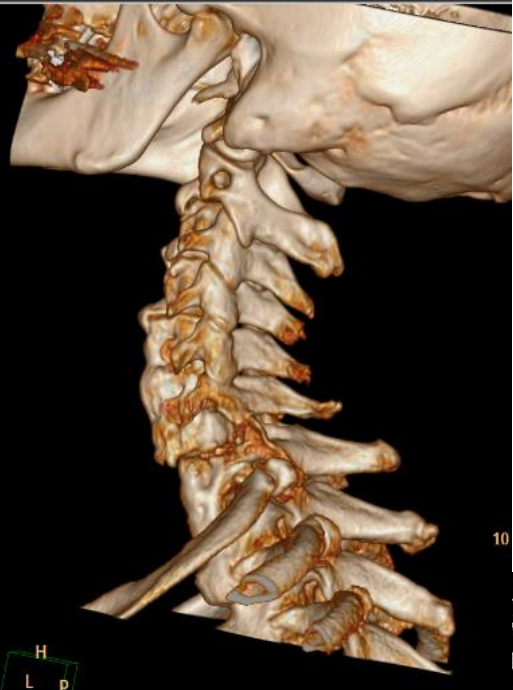- Hartshill



ZADNÍ STABILIZACE

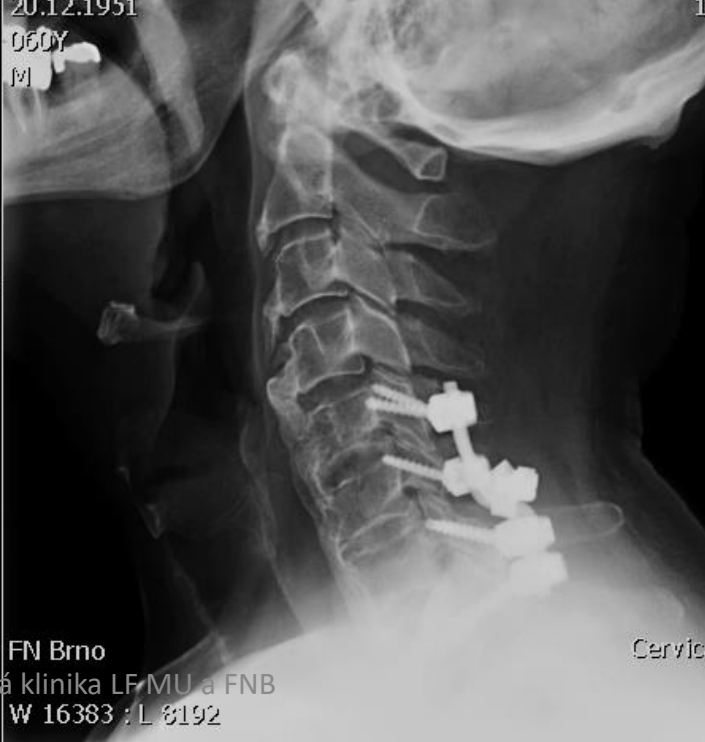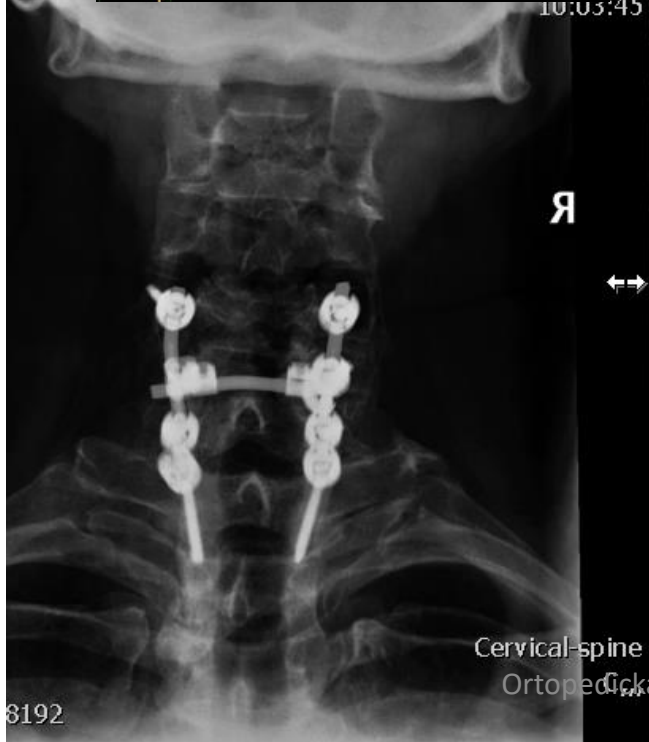- Synthes
- Star Lock
- CerviFix





MIP, 3301
H
L P
10:03:45

28
1:1
112
20.12.1951
060Y
M



8192

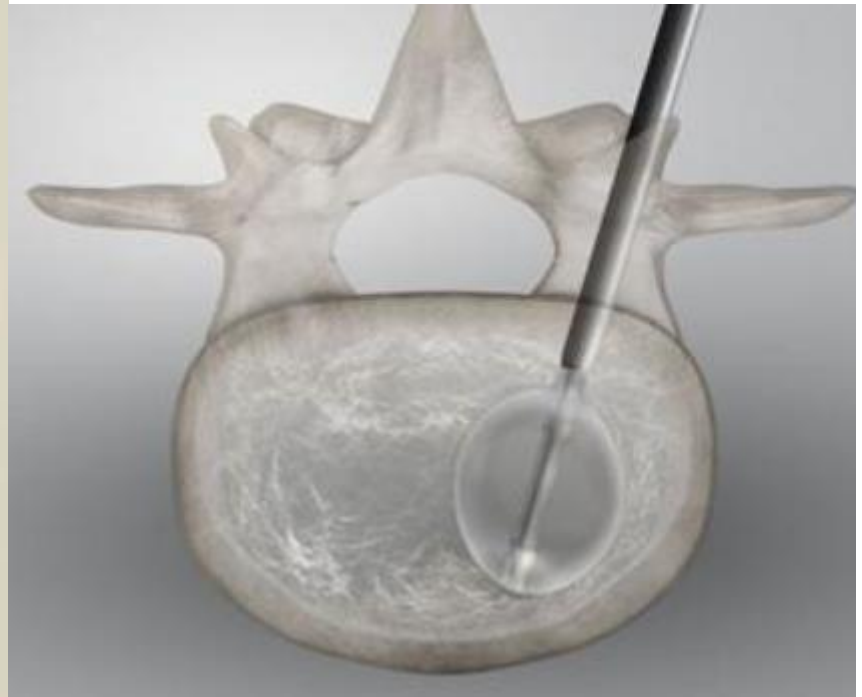
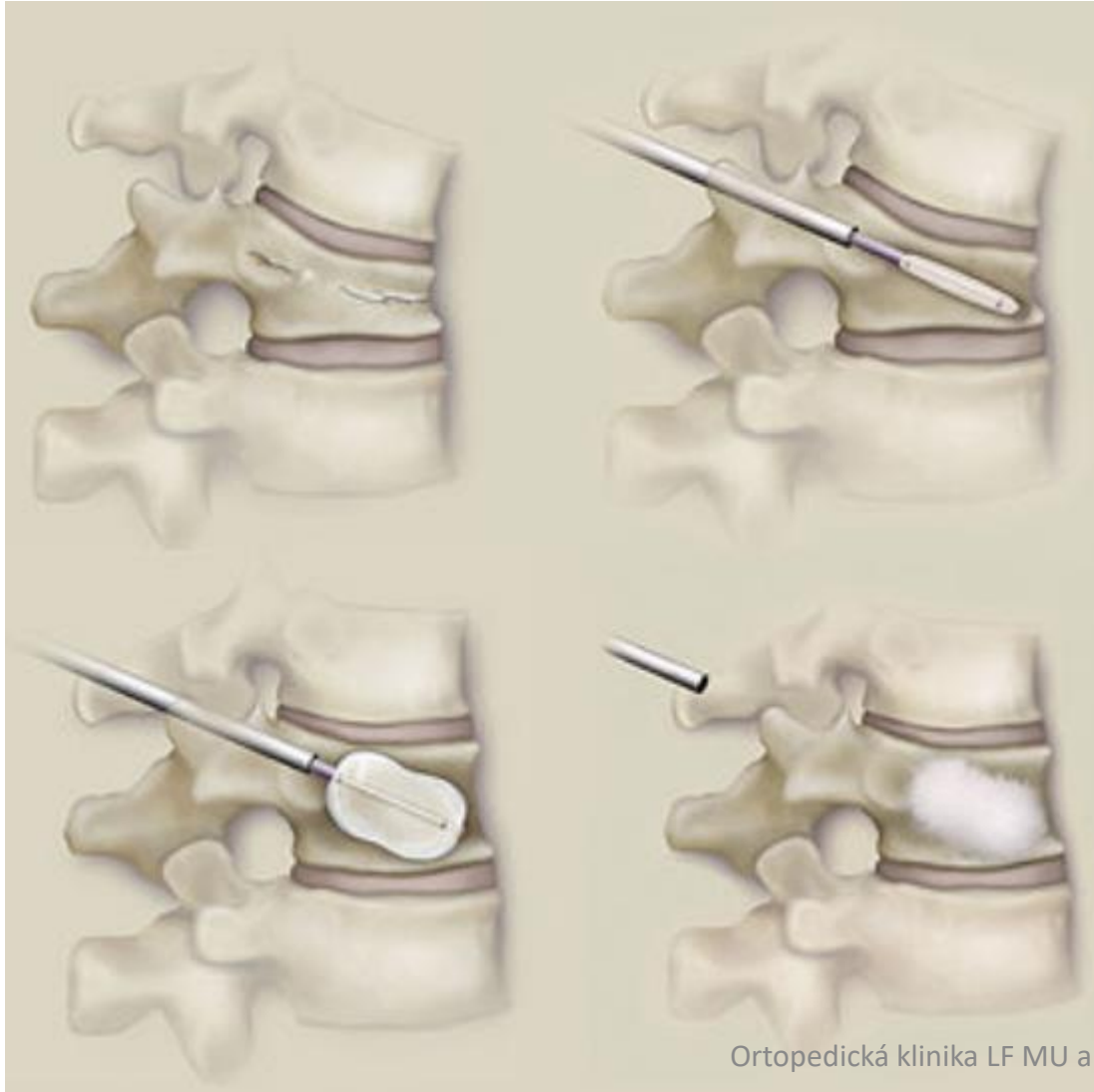
Cervical spine FN Brno
Ortopedická klinika LF MU a FNB
W 16383 ; L 8192

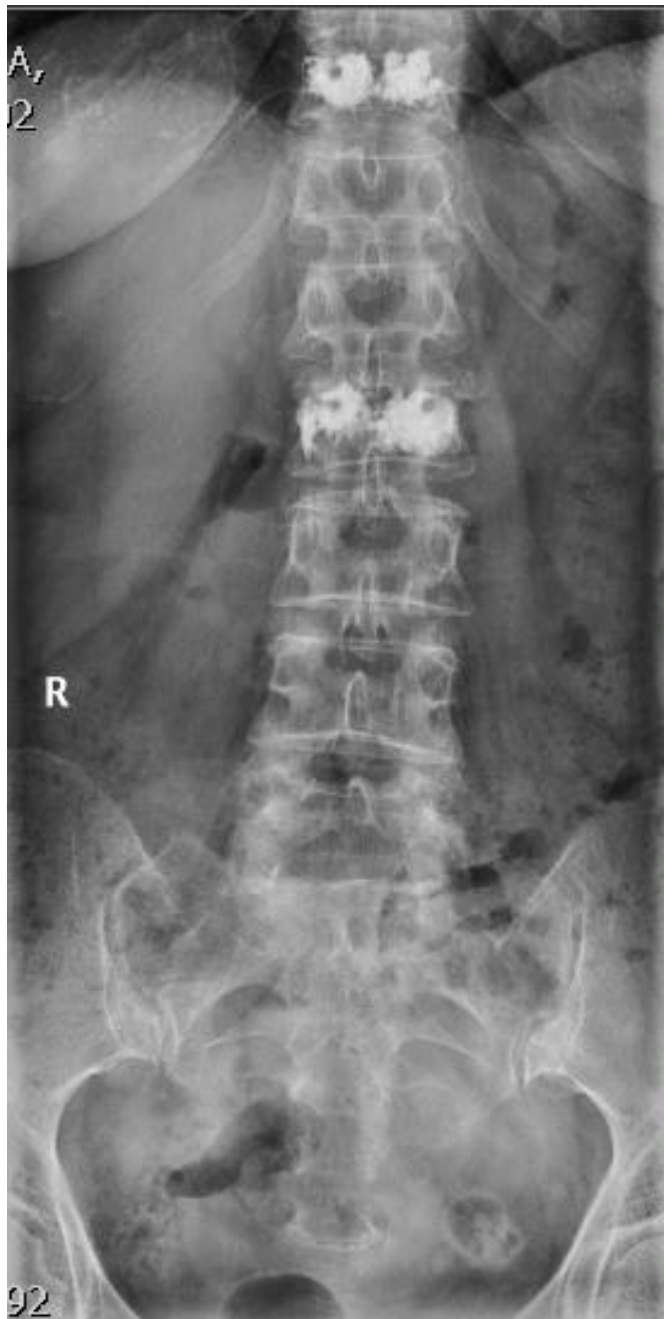Cervica

MINIINVAZIVNÍ POSTUPY

- VERTEBROPLASTIKY,
KYPHOPLASTIKY
- PERKUTÁNNÍ FIXACE

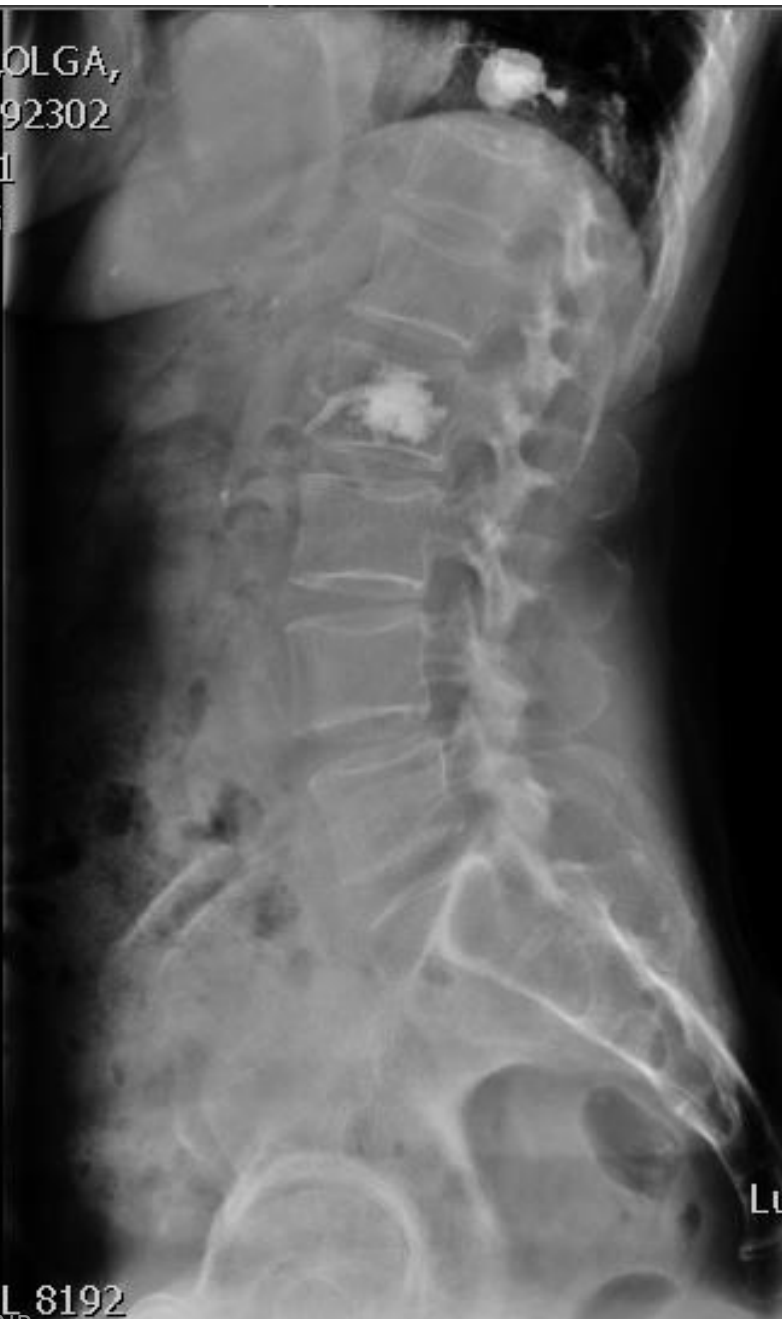VERTEBROPLASTIKA - Kyfoplastika





SE:3879 DARDOVA, OLGA,
IM:1 ACCES#2192302
03.10.2013 455705/951
11:04:06 05.07.1945
068Y
F

Lumbar-spine FN Brno
Th, L,,
W 16383 : L 8192

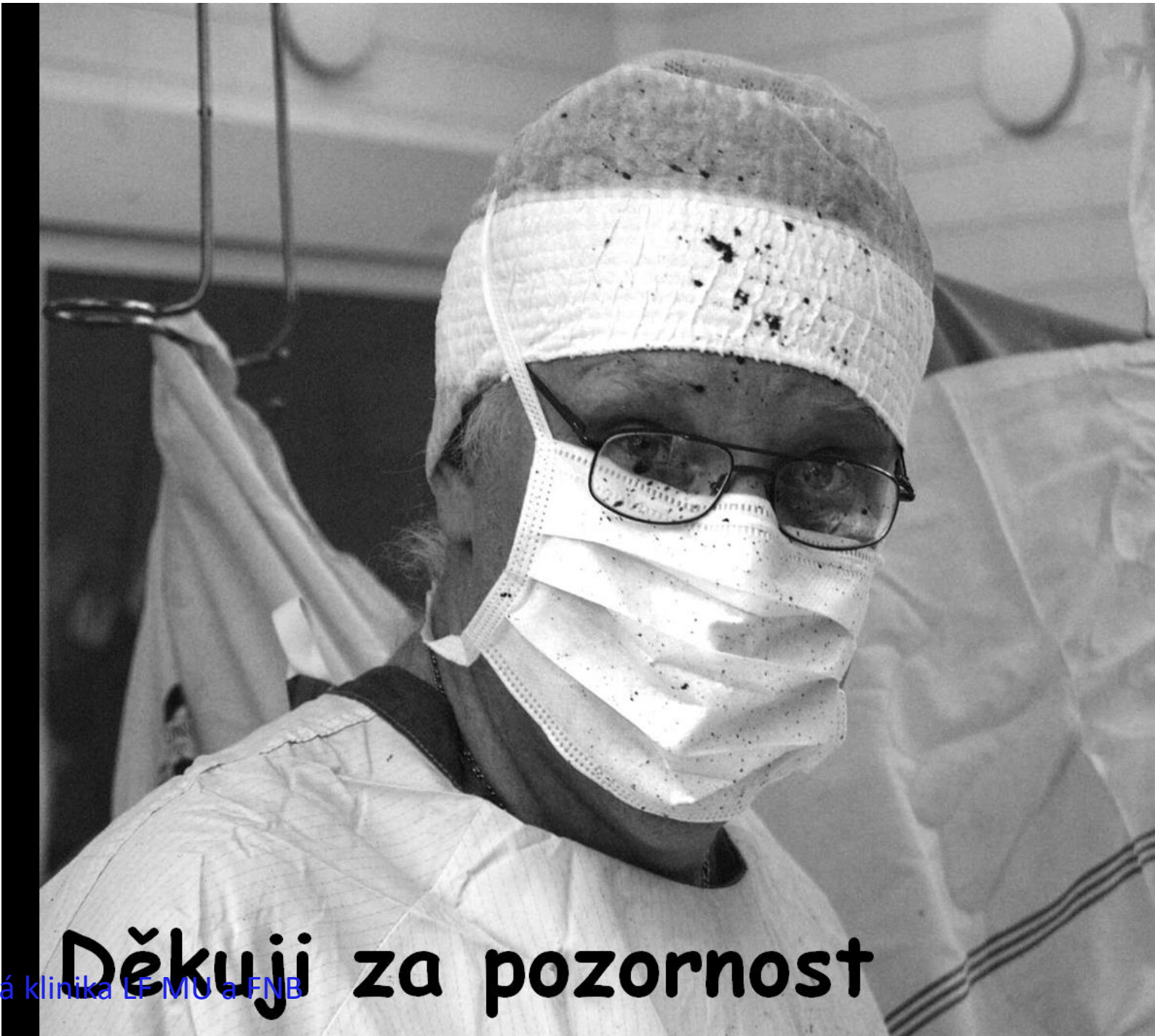

Komplikace operační terapie

- Zvýšené krevní ztráty
 - epidurální žíly, kost
- Špatné umístění transpedikulárních šroubů
 - mediálně či kaudálně
- Poranění durálního vaku
 - riziko vzniku likvorové píštěle
- Infekce
 - časná, pozdní

POOPERAČNÍ DOLEČENÍ

- límec
- Jewet ortéza, bederní pás
- sádrový korset
- 0



Děkuji za pozornost

Ortopedická klinika LF MU a FNB