


# COVID-19 through the eyes of a pneumologist -series of case studies-



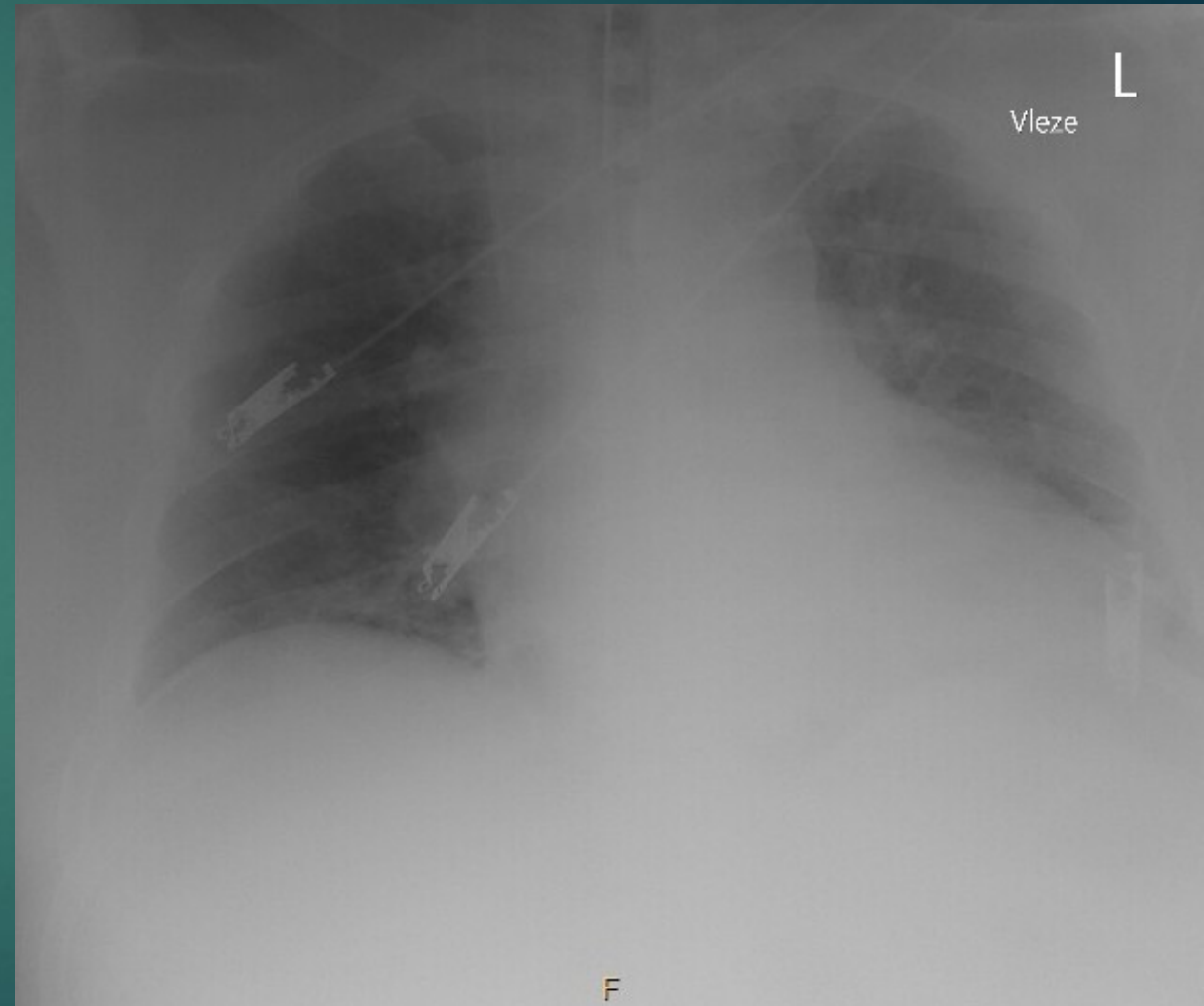
...we are starting to miss the good old COPD

MUDr. Ondřej Venclíček  
ICU of Department of Respiratory Diseases, University Hospital Brno



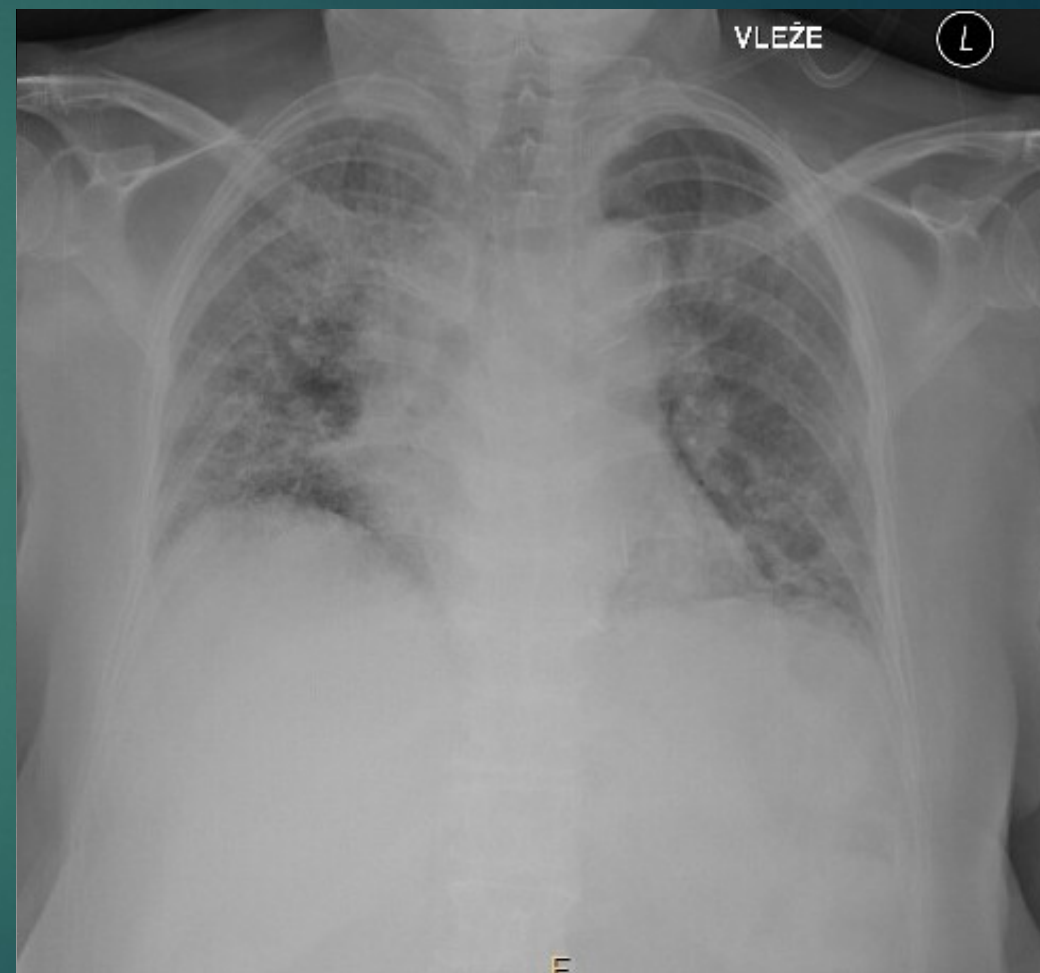# Case no. 1: R. L.

- ▶ 52 years old man, 194 cm, 160 kg
- ▶ Obesity, diabetes, hypertension, hyperlipidemia
- ▶ Former smoker
- ▶ Hospitalization 12.10.20
- ▶ Therapy: dexamethason, LMWH, ATB...
- ▶ HFNO with limited effect, NIV without effect
- ▶ Intubated 14.10.20, tracheostomy 21.10.20
- ▶ Successful weaning 27.10.20
- ▶ Sudden overall worsening and subsequent death 29.10.20



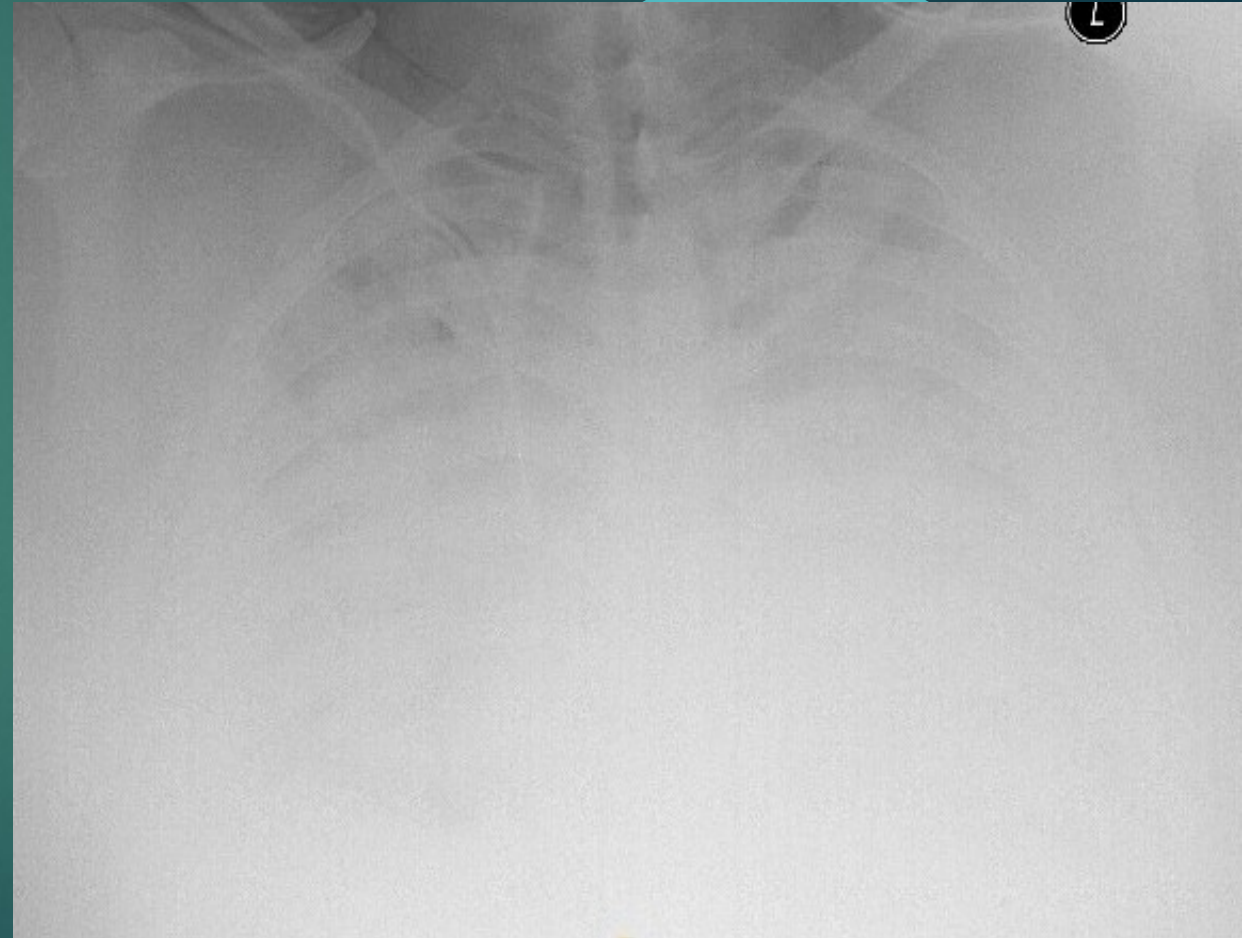
# Case no. 2: J. H.

- ▶ 61 years old woman, 160 cm, 67 kg
- ▶ UIP-IPF, lung Tx 5/2020, diabetes, nefropathy, hypertension, hepatopathy
- ▶ Hospitalised 26.10.20
- ▶ Therapy: remdesivir, dexamethason, LMWH, ATB...
- ▶ Oxynotherapy insufficient, good effect of HFNO (3.-10.11.2020), no need for intubation
- ▶ Complicated with development of DIC
- ▶ 24.11.20 released from ICU



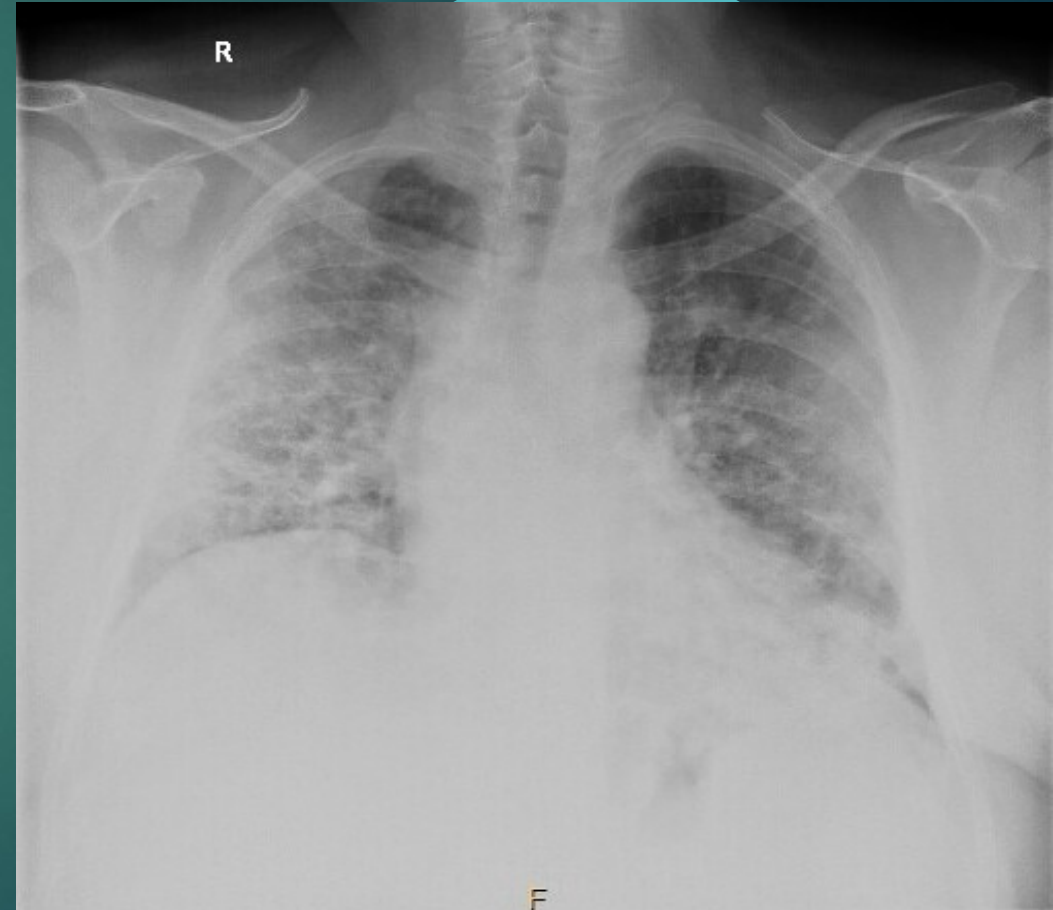
# Case no. 3: J. S.

- ▶ 48 years old man, 182 cm, 180 kg
- ▶ Obesity, diabetes, hypertension, hyperlipidemia, COPD, nephropathy
- ▶ Hospitalised 10.11.20
- ▶ Therapy: convalescent plasma, LMWH, ATB...
- ▶ Oxygenotherapy and HFNO insufficient, NIV without effect. Intubated 15.11.20. The same day cardiac arrest, 1 minute succesful CPR.
- ▶ Even mechanical ventilation insufficient, transfer to ECMO. Dies the same day.



# Case no. 4: J. H.

- ▶ 55 years old man, 185 cm, 150 kg
- ▶ Obesity, hypertension, diabetes, nephropathy
- ▶ Hospitalised 22.10.20
- ▶ Therapy: dexamethason, LMWH, ATB...
- ▶ Oxygenotherapy and HFNO insufficient, good effect of NIV
- ▶ Released home 16.11.20 with home oxygenator
- ▶ Persistent post-COVID lung infiltration



# Case no. 5: J. N.

- ▶ 44 years old man, 187 cm, 117 kg
- ▶ Obesity, hypertension
- ▶ Hospitalised 10.11.20
- ▶ Therapy: dexamethason, remdesivir, LMWH, ATB...
- ▶ Oxygenotherapy insufficient, HFNO with limited effect, good effect of NIV
- ▶ Patient got much better, scheduled for transfer to standard ward. Night before transfer sudden overall worsening of state, intubation, cardiac arrest, unsuccessful CPR. Dies 15.11.20.

