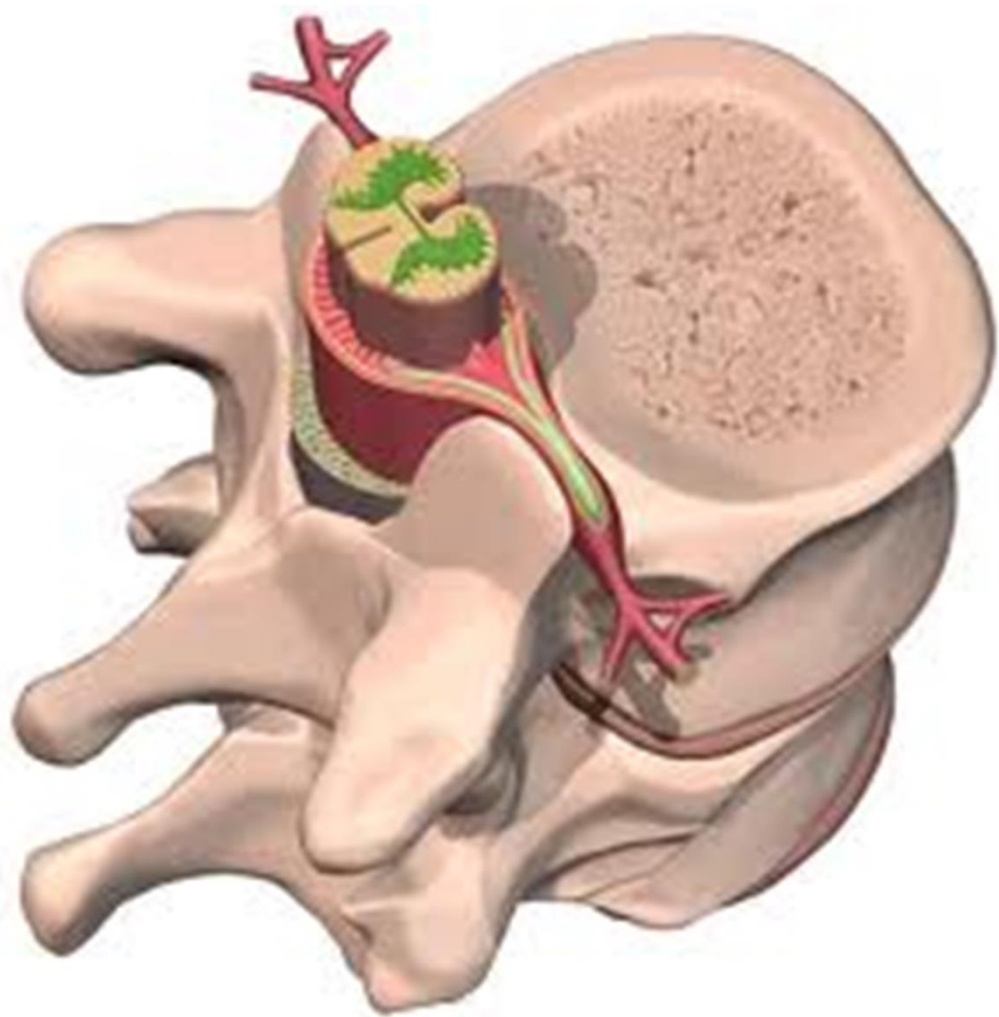
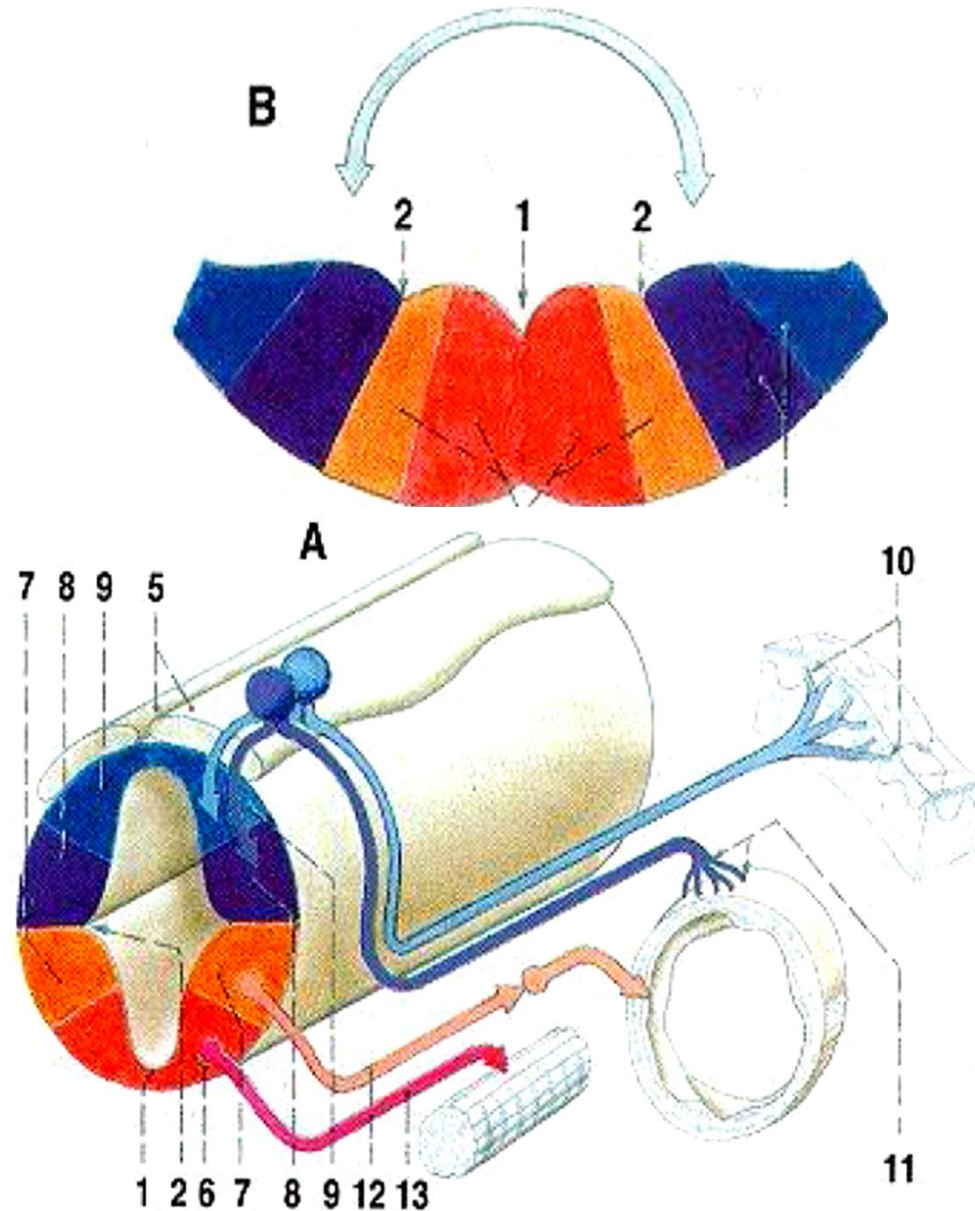
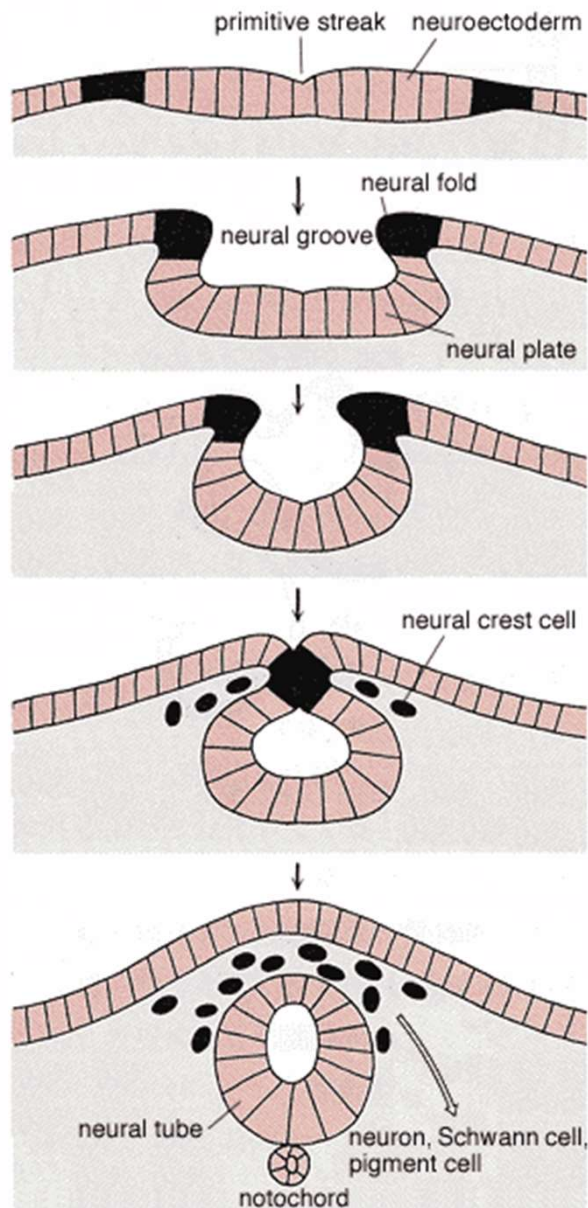


The spinal cord - Medulla spinalis





The development of the neural tube in the area of the spinal cord



The spinal cord - Medulla spinalis

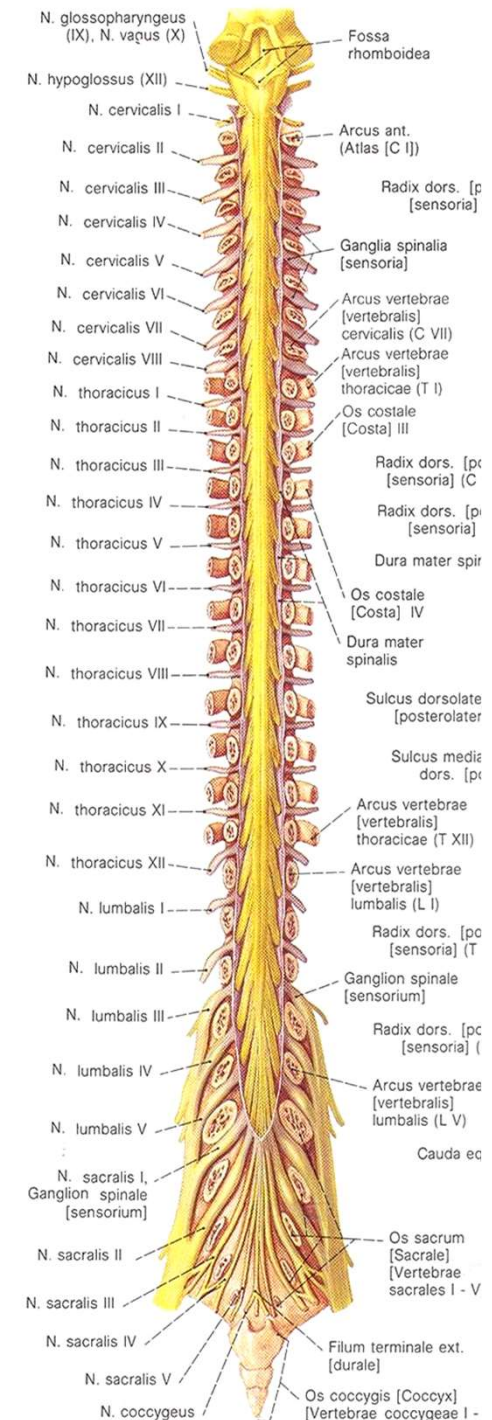
- length 40 – 50 cm, thickness 1cm
- weight circa 30g
- it is located within the spinal canal
- it follows curvature of vertebral column

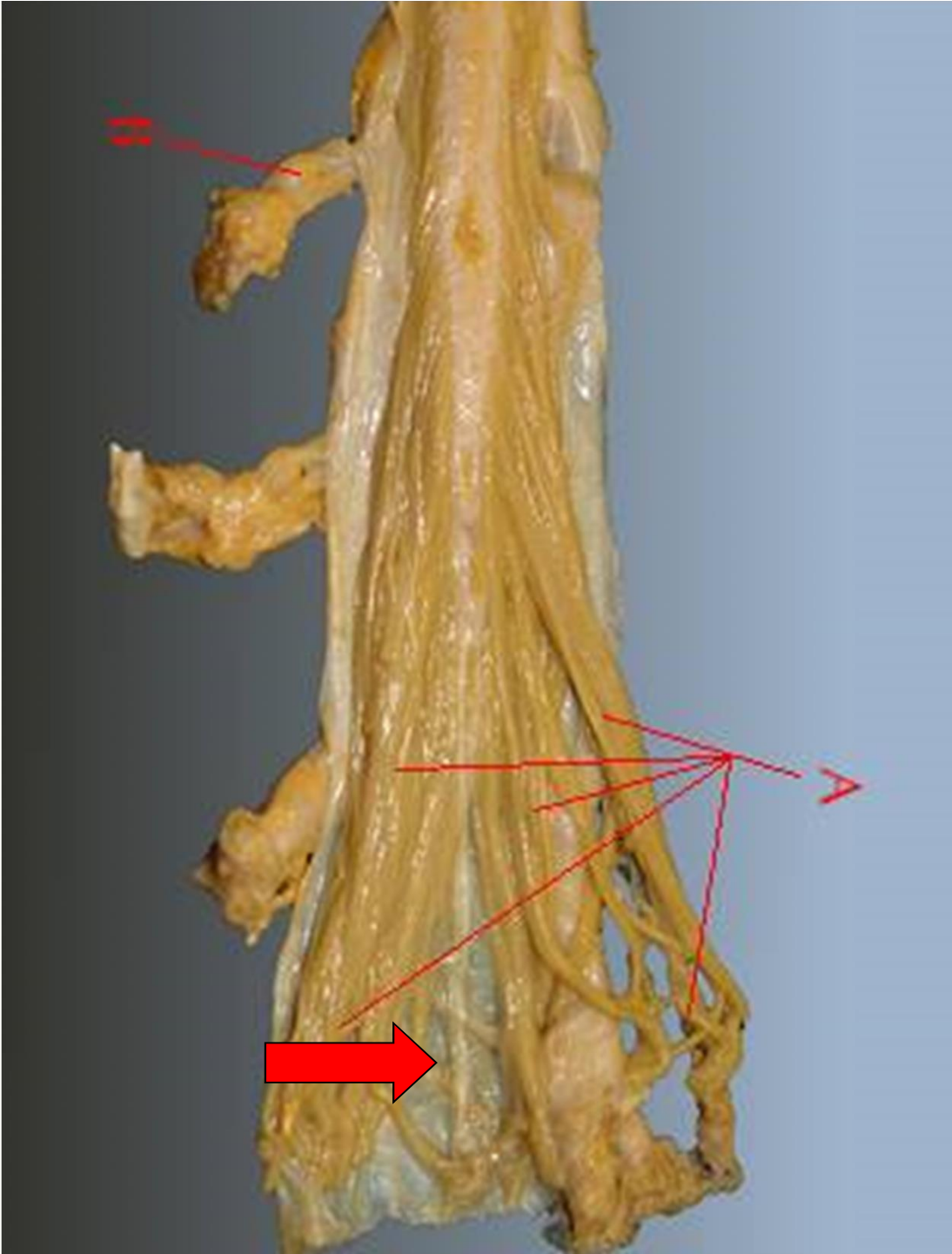
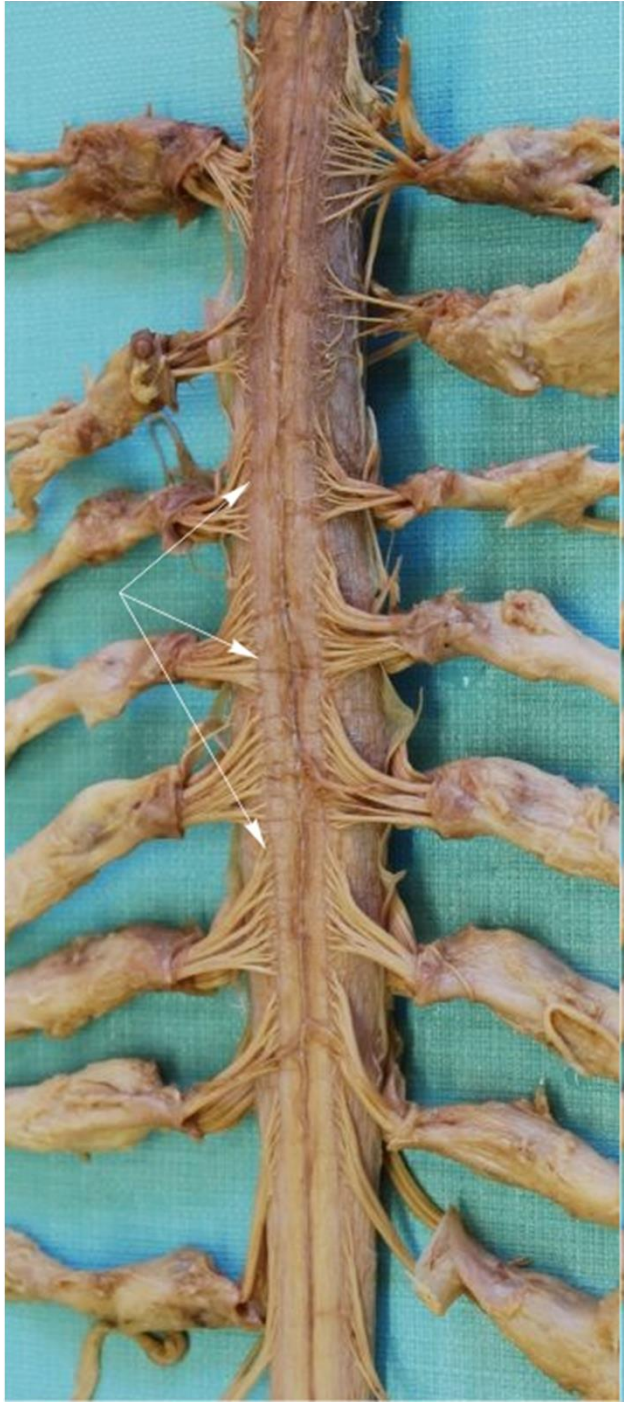
Cranially: it continues as medulla oblongata,

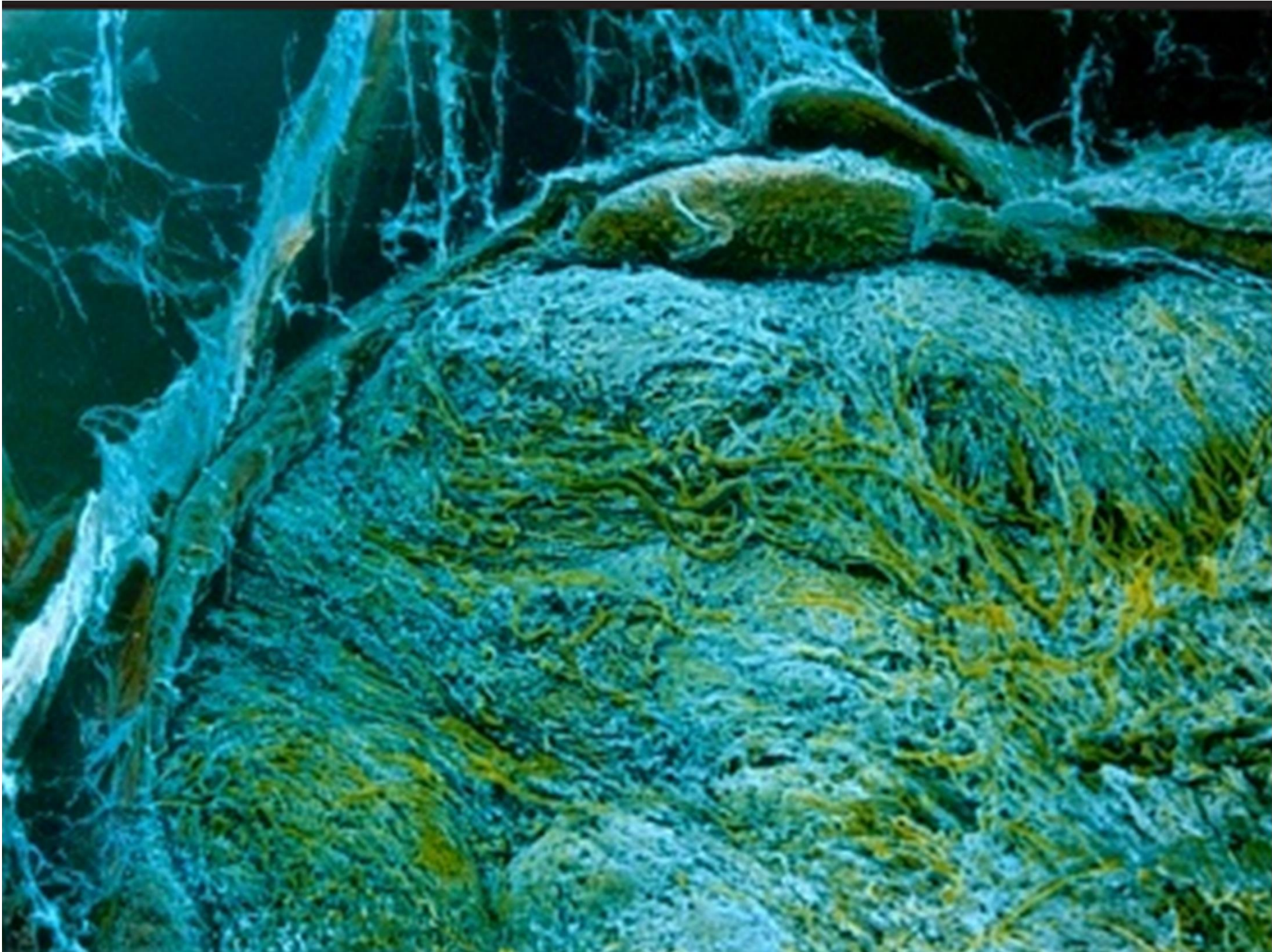
Borderline is decussatio pyramidum or detachment of 1st spinal nerve

Caudally: **conus medullaris** (♂ apex lies at the level of intervertebral disc L1-2, ♀ body of L2) – filum terminale (25 cm, 1 mm)

Caudal part of vertebral canal is filled with nerve roots– **cauda equina (a horse's tail)**

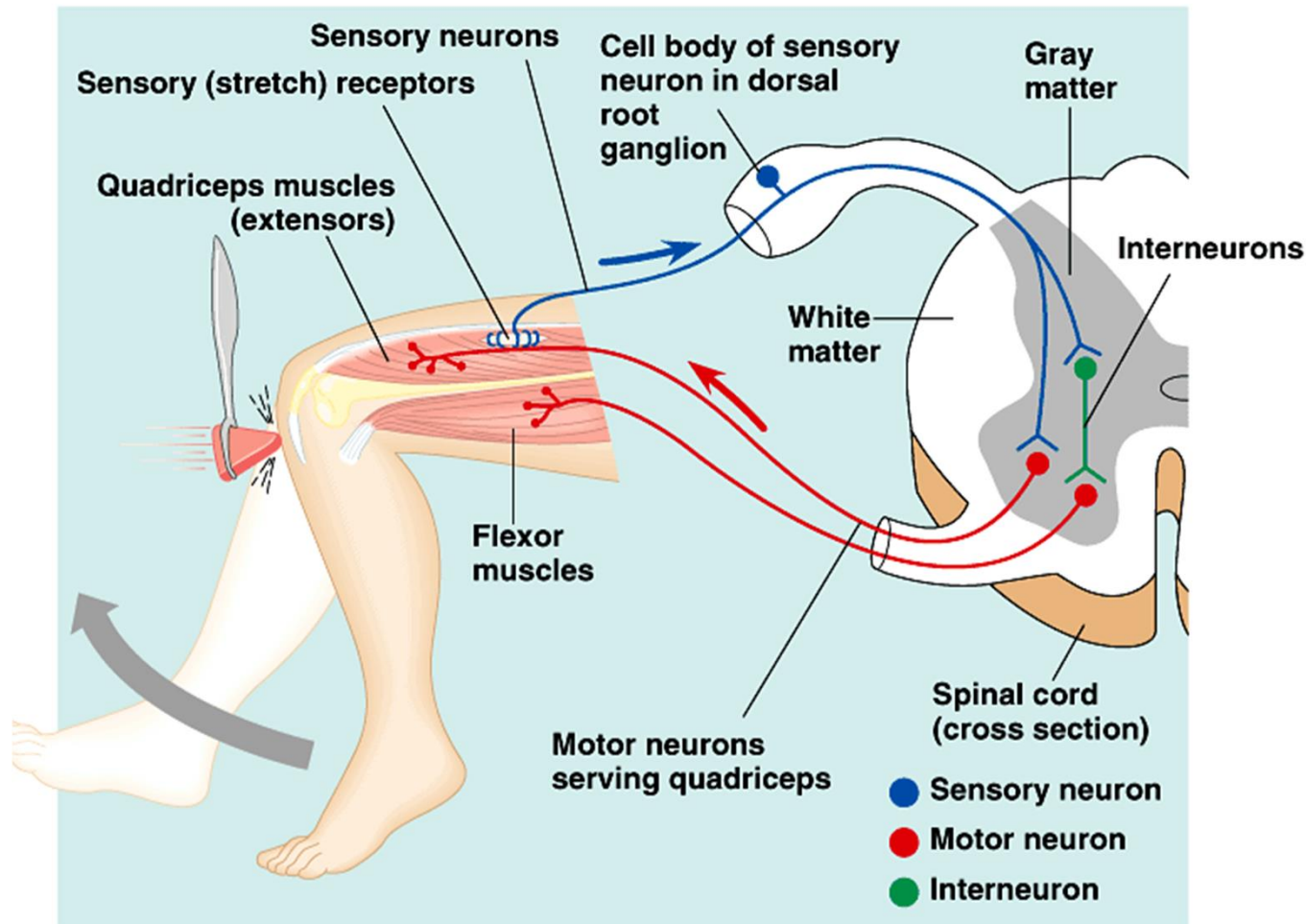






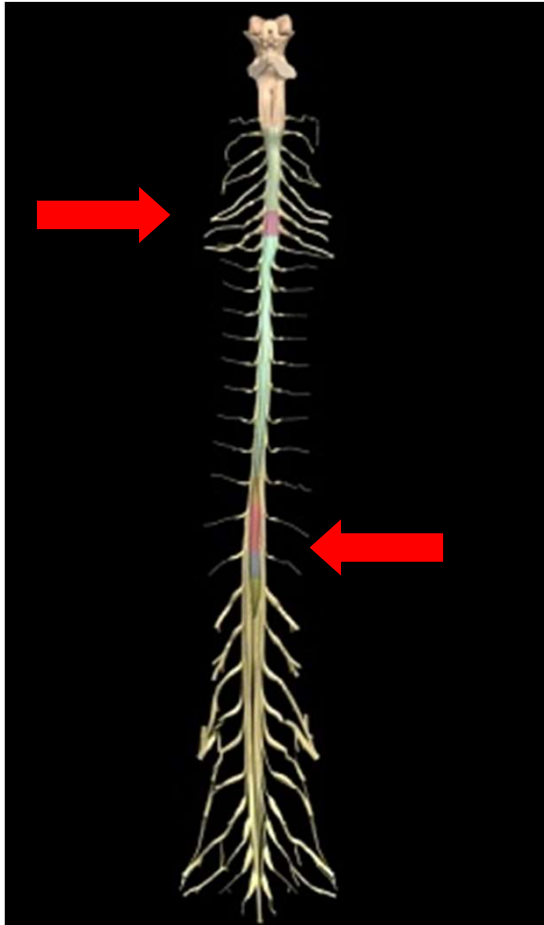
The spinal cord

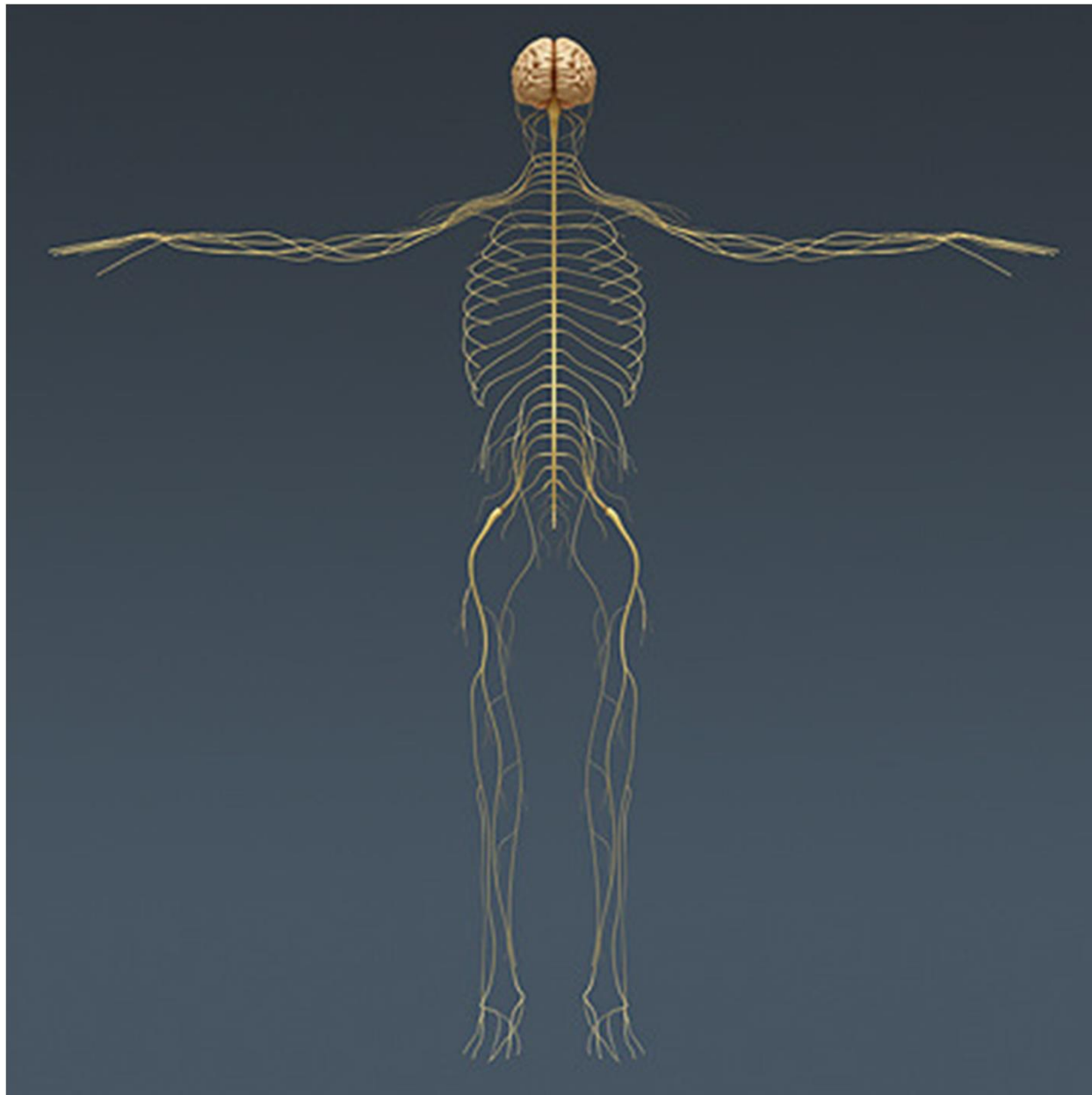
- It keeps structure of original neural tube with canalis centralis in the middle
- At the level of spinal cord, there are realized simple unconditional reflexes



The spinal cord

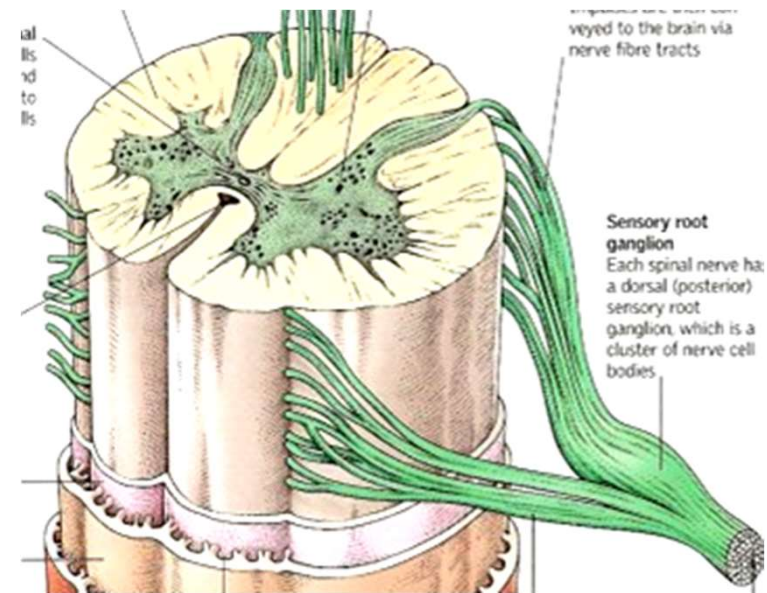
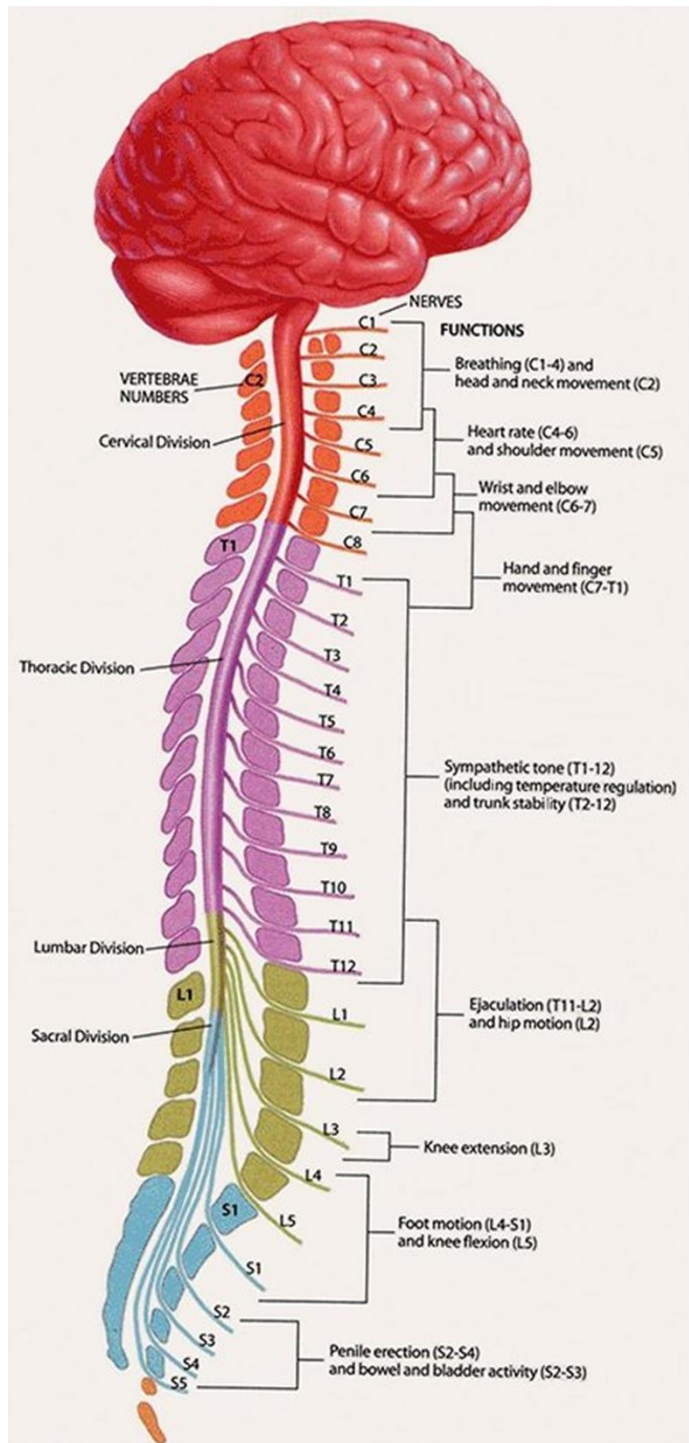
- thickness of the spinal cord is not the same in all sections – **enlargements**
intumescentia cervicalis (C3-T2)
intumescentia lumbalis (T9-L1)
places where the nerves for limbs arise






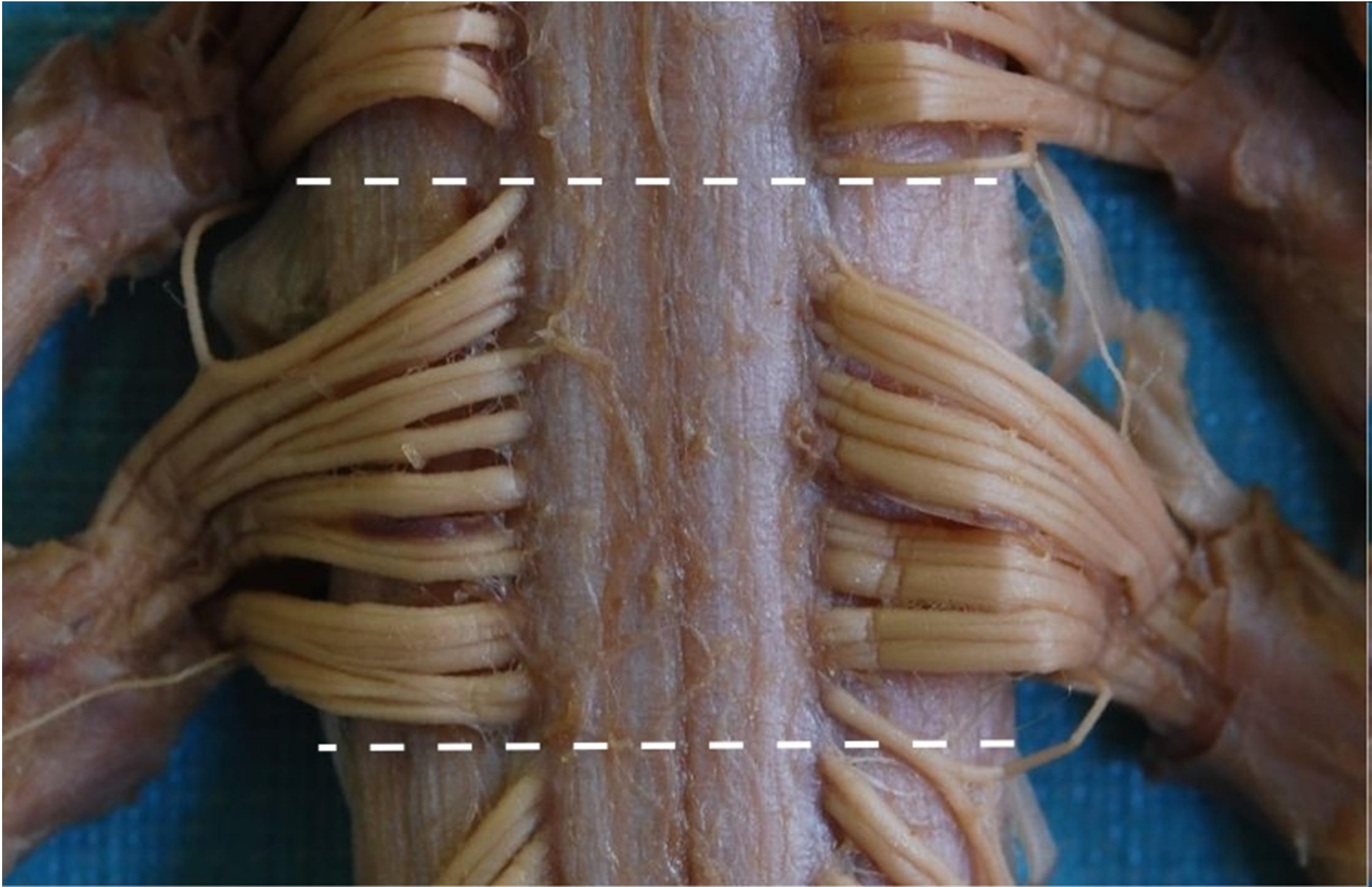
The spinal segment

• A section of the spinal cord from which arise fila radicularia (root fibers) of one pair of spinal nerves



- Anterior root= radix anterior
- posterior root= radix posterior
- Ganglion spinale






Structure of the spinal nerve

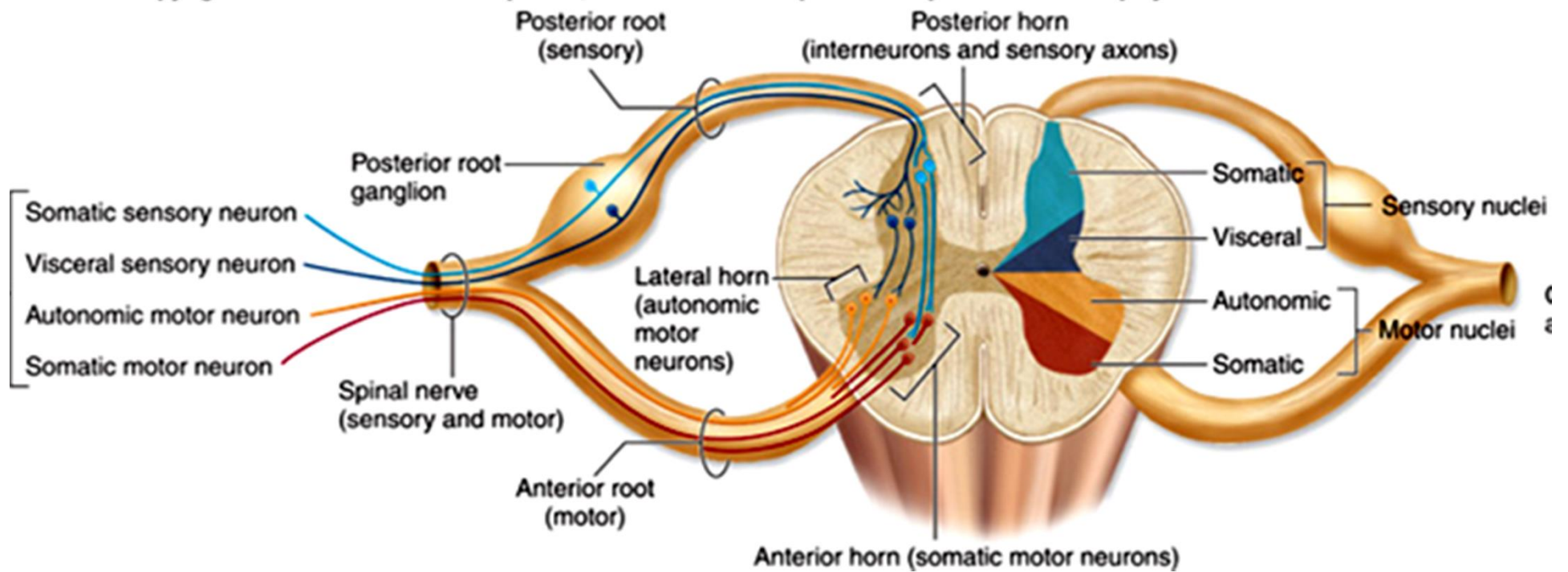
- radix anterior: motor
- radix posterior: sensory
- Ganglion spinale

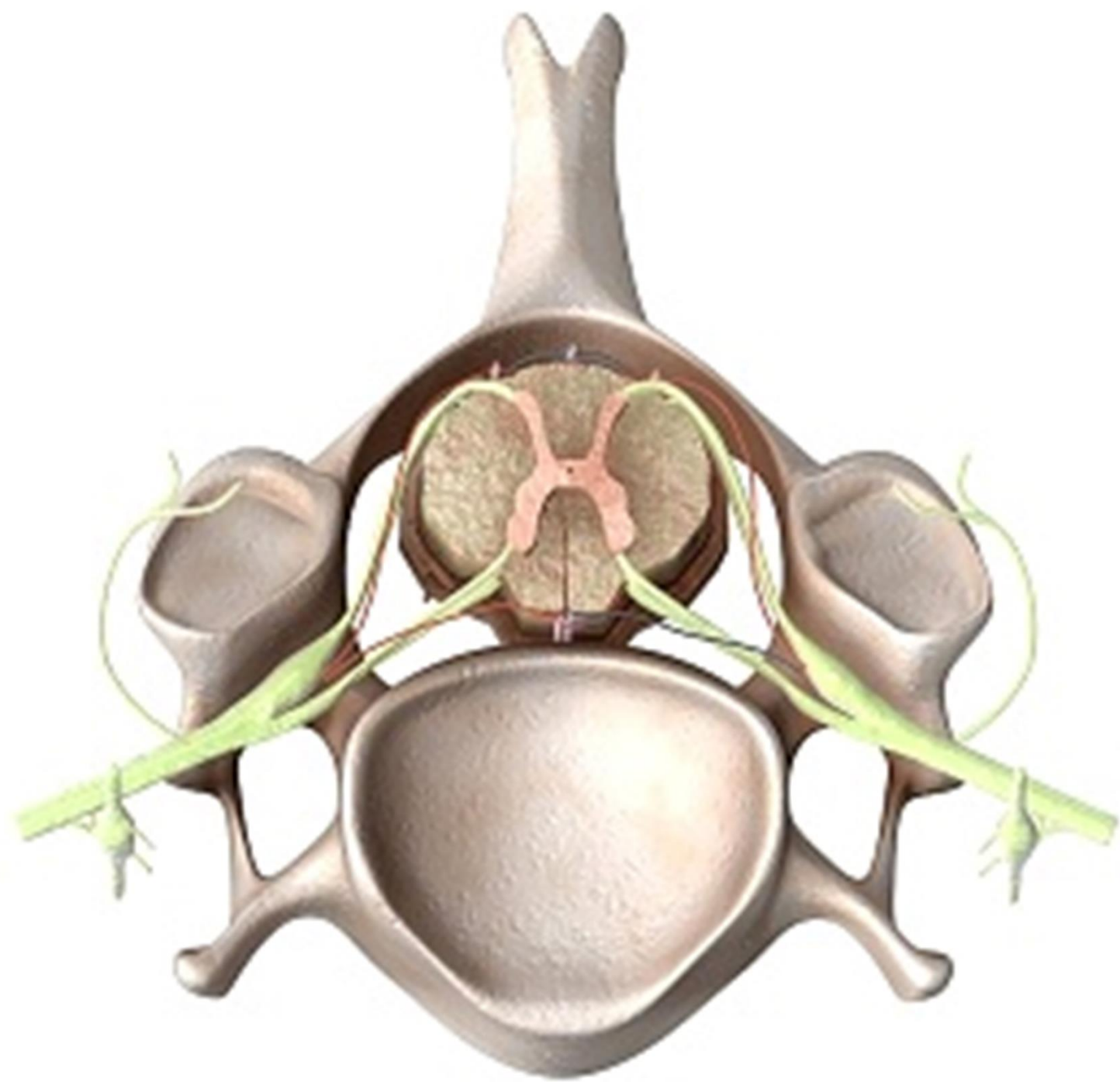


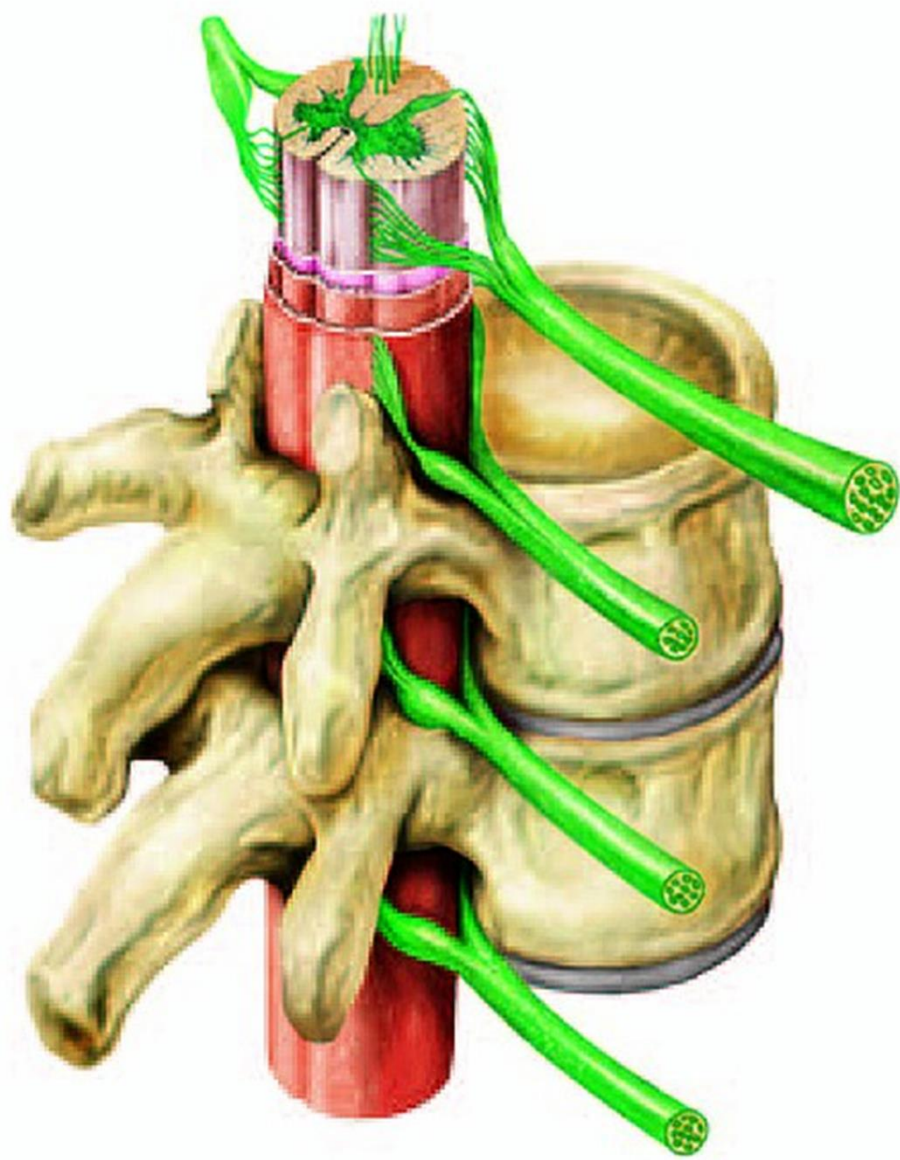
Spinal nerve



- ramus dorsalis mixed
- ramus ventralis mixed







• Number of spinal segments corresponds to number of spinal nerves

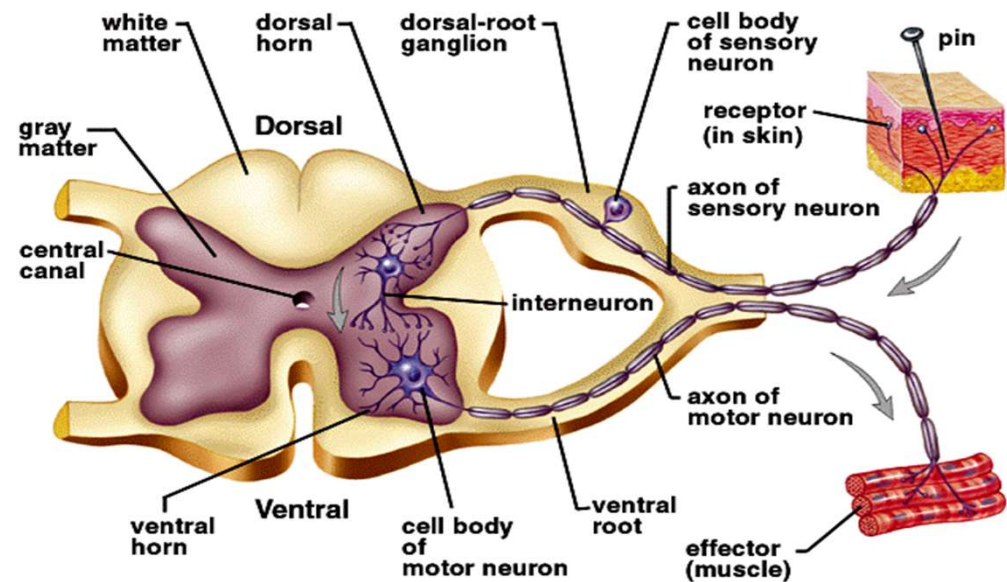
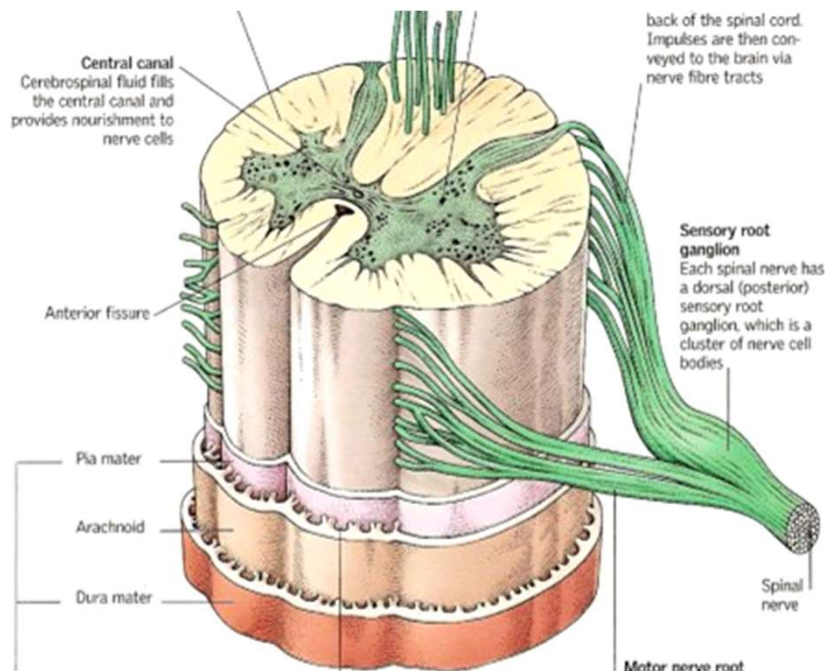
Cervical part (*pars cervicalis*): 8 segments (C1-8), C1 arises between the occipital bone and atlas, *nervi cervicales*

Thoracic part (*pars thoracica*): 12 segments (Th1-12), *nervi thoracici*

Lumbar part (*pars lumbalis*): 5 segments (L1-5), *nervi lumbales*

Sacral part (*pars sacralis*): 5 segments (S1-5), *nervi sacrales*

Coccygeal part (*pars coccygea*): 1 segment (Co1), *nervus coccygeus*



- **Longitudinal grooves**

Fissura mediana anterior

Sulcus medianus posterior

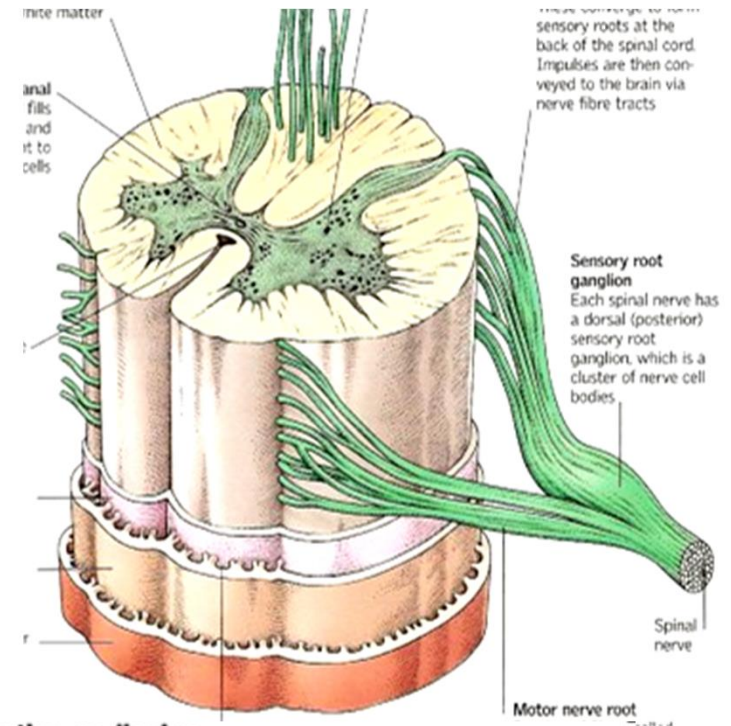
Sulcus anterolateralis

Sulcus posterolateralis

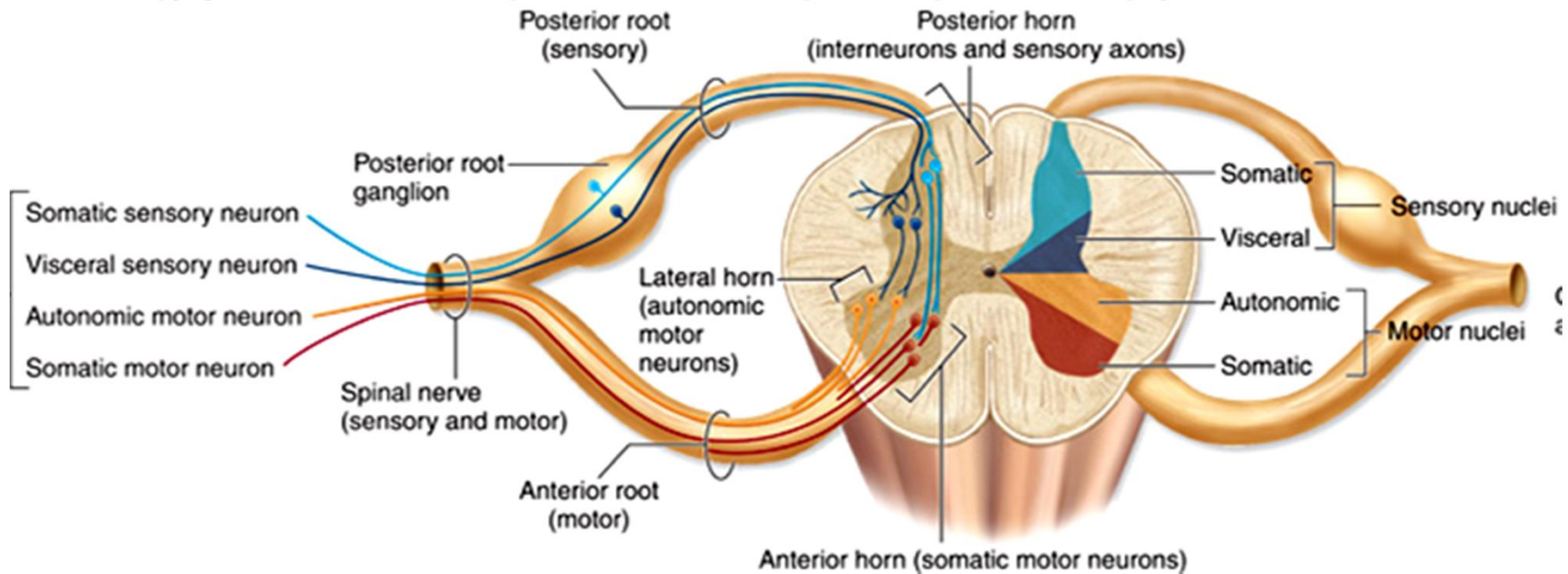
Sulcus intermedius posterior

- **sulcus anterolateralis (motor)**

- **sulcus posterolateralis (sensory)**

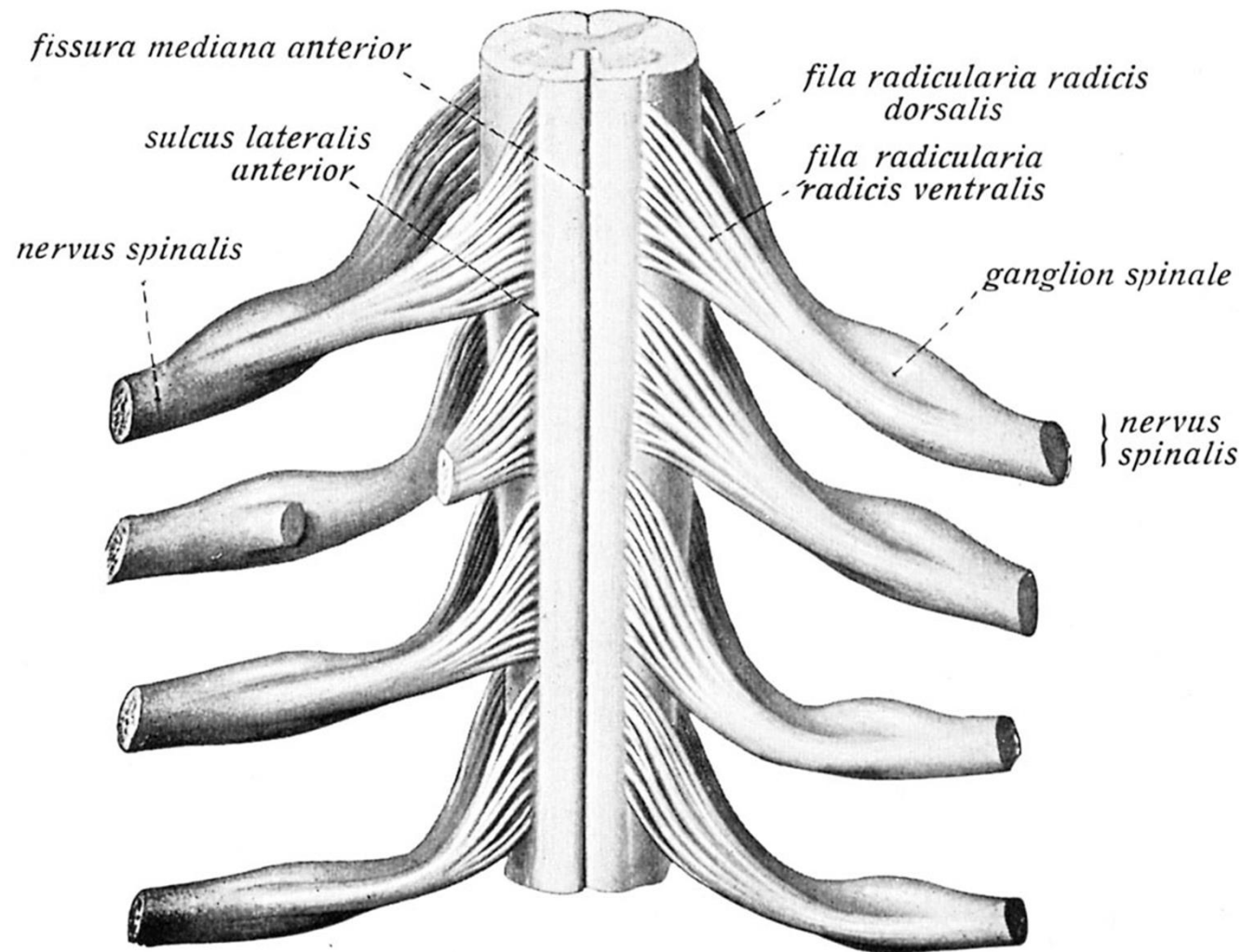


Copyright © The McGraw-Hill Companies, Inc. Permission required for reproduction or display.



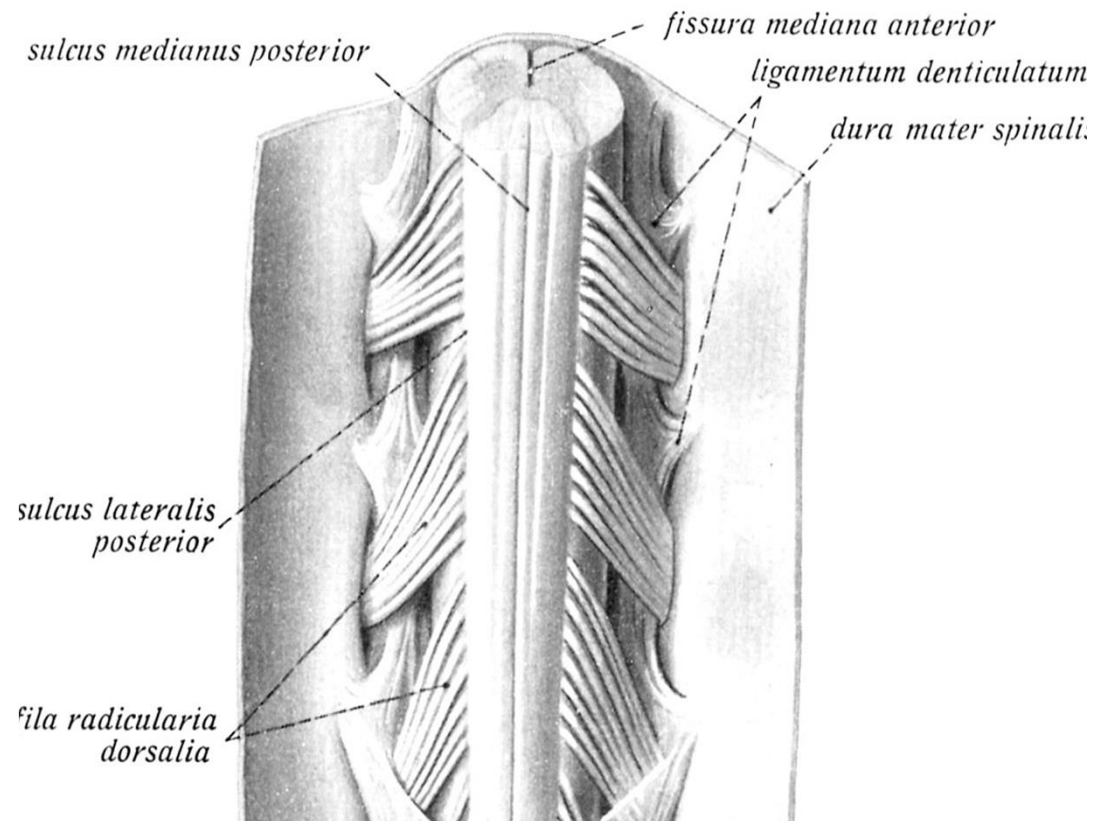
The spinal cord – anterior view

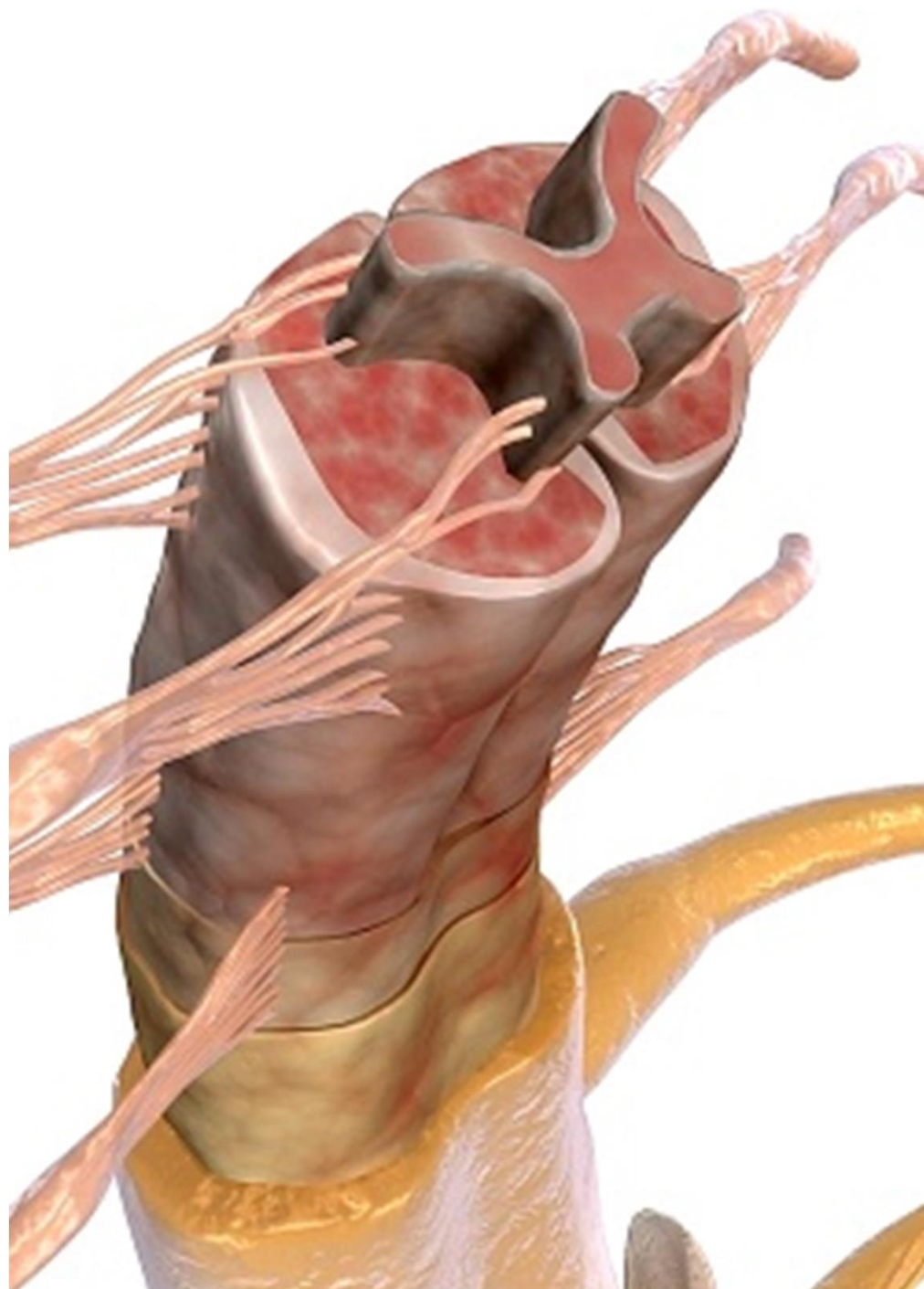- Fissura mediana anterior
- Sulcus anterolateralis- radix anterior



The spinal cord: posterior view

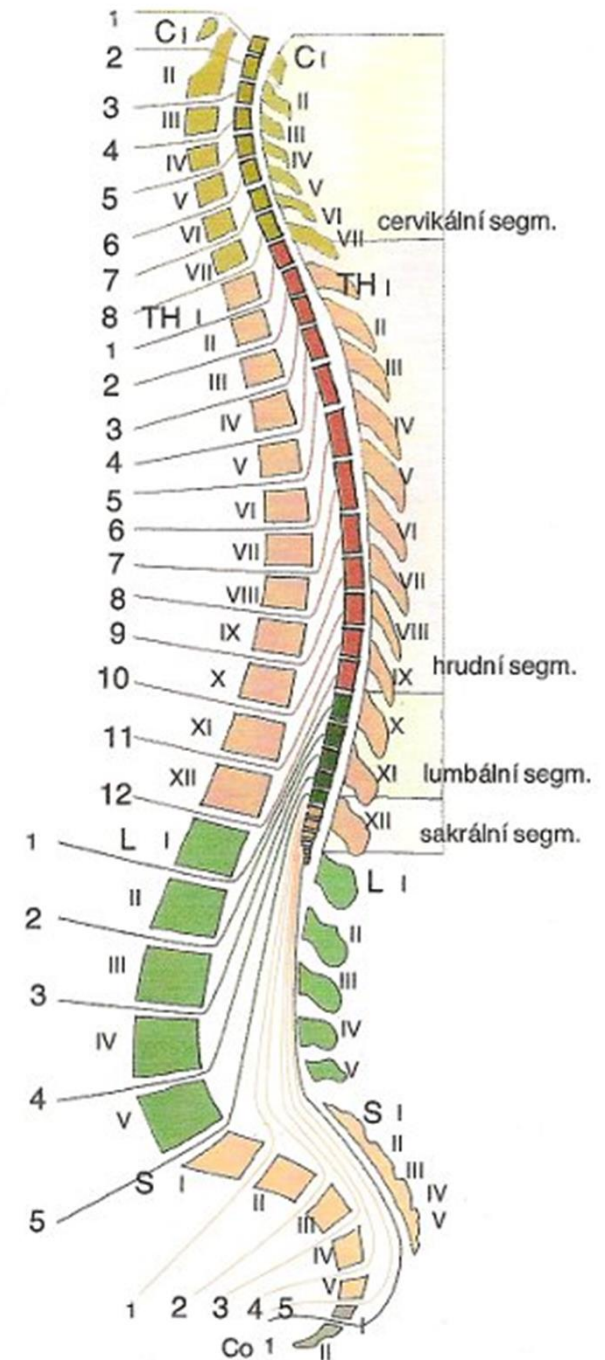
- **Sulcus medianus posterior**
- **Sulcus posterolateralis**
 - radix posterior
- **S. intermedius posterior**

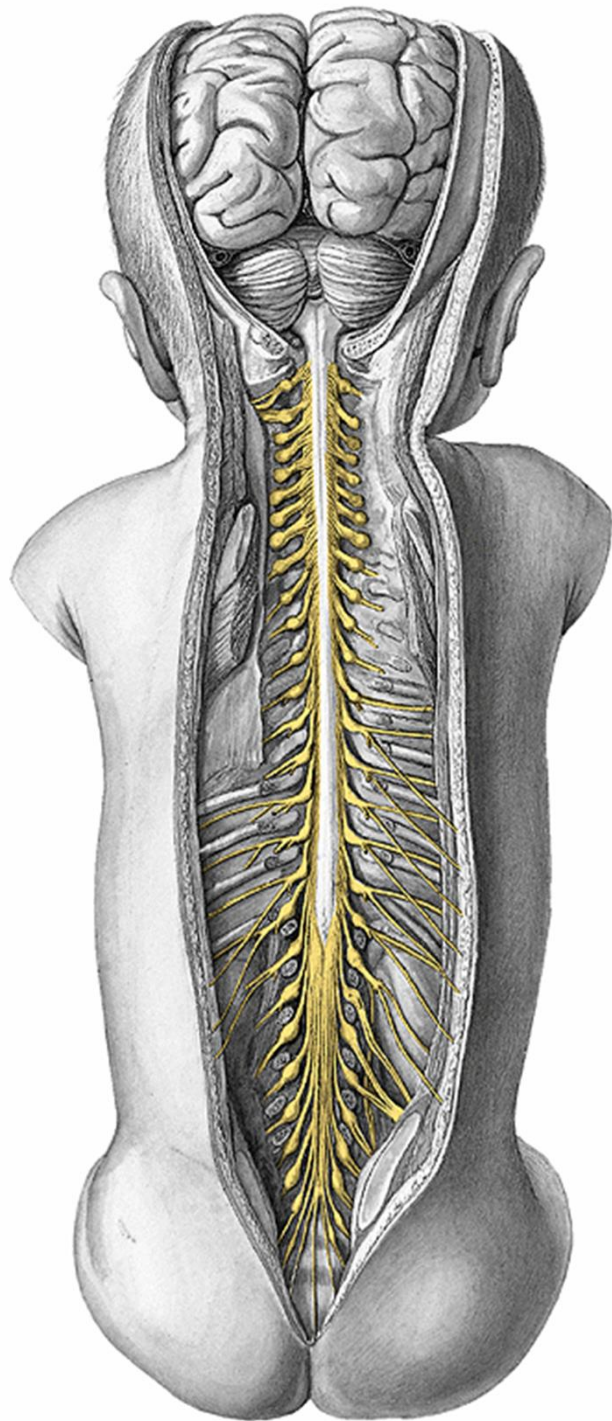




During the third month of intrauterine development, the spinal cord fills whole length of the spinal canal. Later the vertebral column grows much faster than the spinal cord and the spinal cord of newborn usually ends at **L3**.

Due the different speed of growth, the lumbar and sacral roots are extended to reach appropriate intervertebral spaces and they form **cauda equina**. The superior thoracic and cervical roots pass horizontally.





Central nervous system (CNS)

Brain

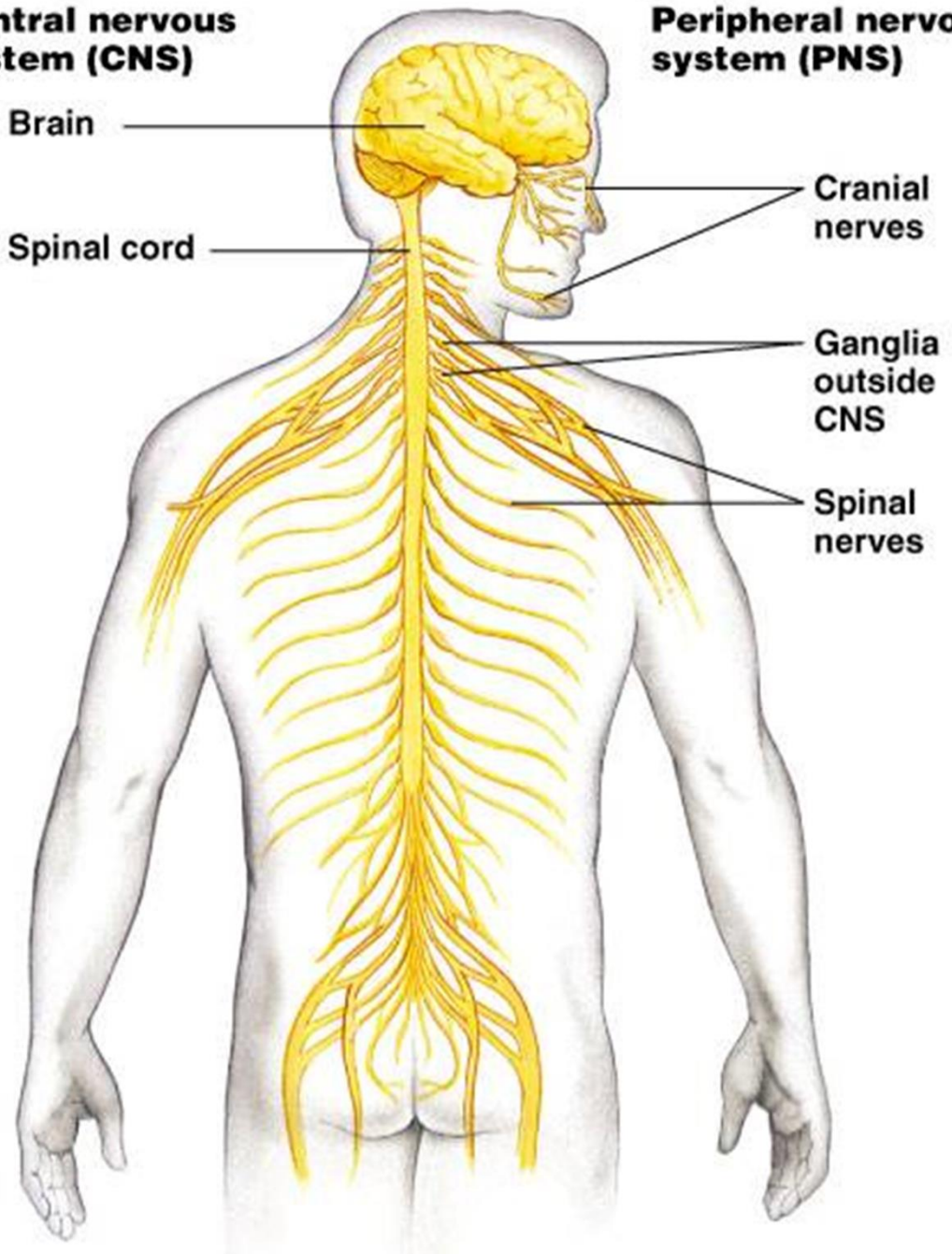
Spinal cord

Peripheral nervous system (PNS)

Cranial nerves

Ganglia outside CNS

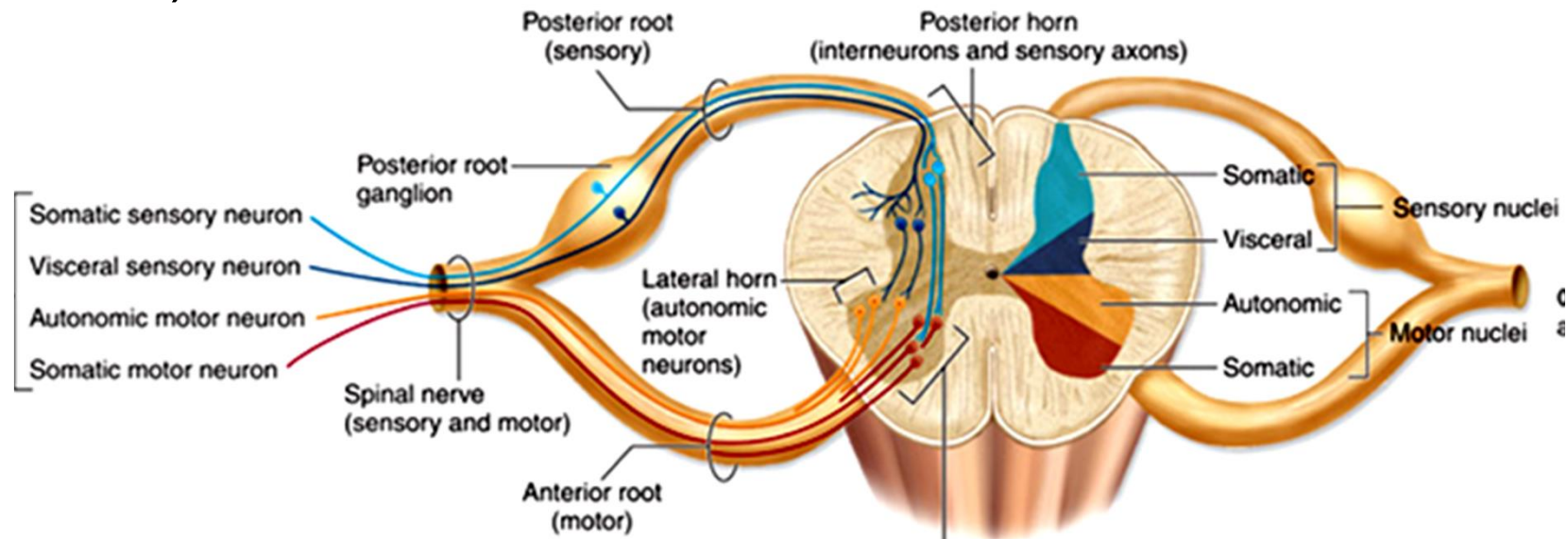
Spinal nerves



Internal structure of the spinal cord

Grey matter (bodies of neurons)

- Around the central canal, it has the shape of a butterfly
- It protrudes into two horns— **at the front:** thicker and shorter *cornu anterius*, with **motoneurons** whose axons form efferent (**motor**) neural pathways
at the back: thinner and longer *cornu posterius*, on whose neurons end axons of pseudounipolar neurons (of the spinal ganglia) of the afferent (**sensory**) pathways
- Between both horns, there are **interneurons** (connective neurons)



White matter (axons)

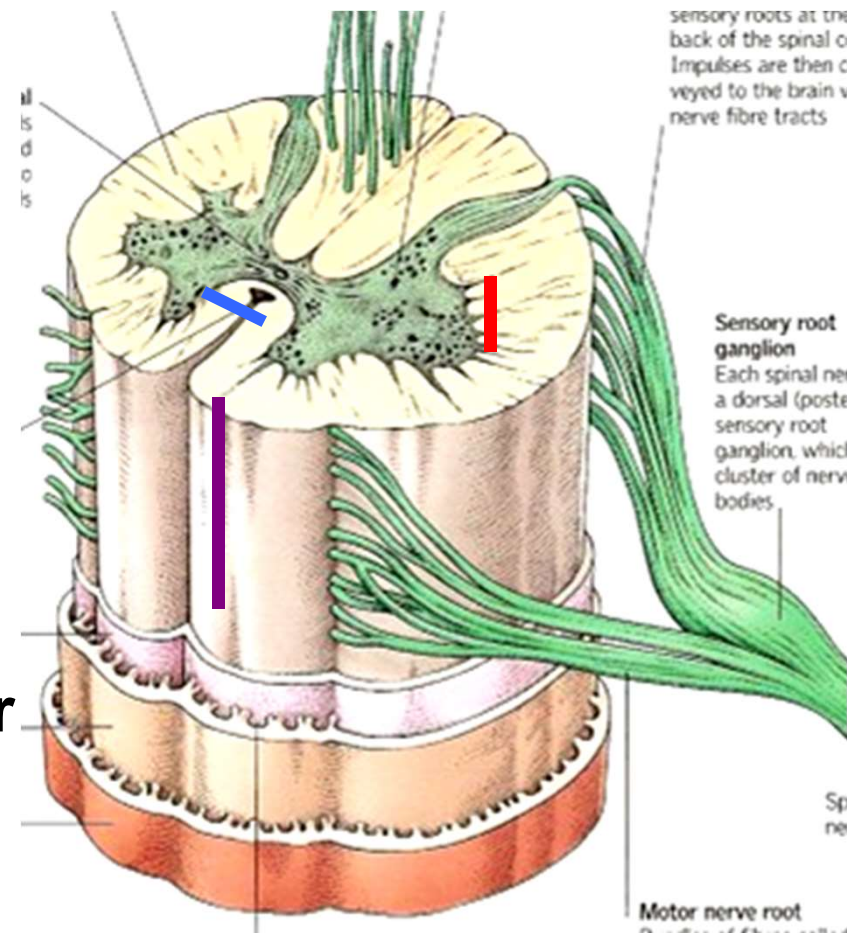
- Located on surface, it is formed by **bundles of myelinated axons**, we distinguish following pathways:

associative: connect two different places of the same spinal segment on the same side

comissural: connect right and left half of the same segment

projective: go ascending or descending through the spinal cord and enter the brain, there are two types (according direction of course):

- **descending:** pass within anterior part of spinal cord and continue as **motor pathways**
- **ascending:** pass within anterior part of spinal cord and they are continuation of **sensory pathways**



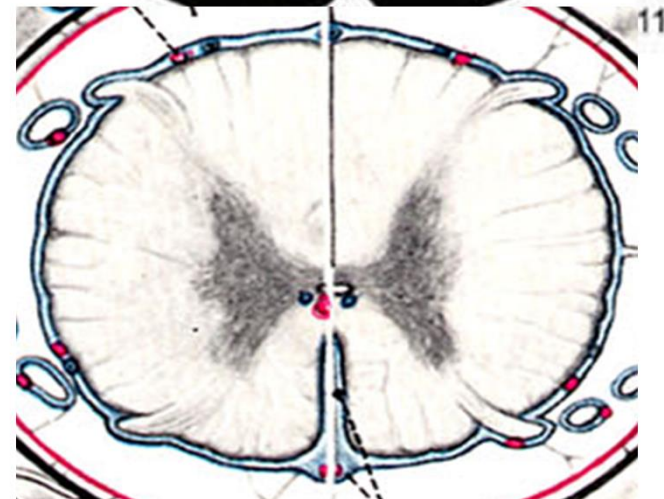
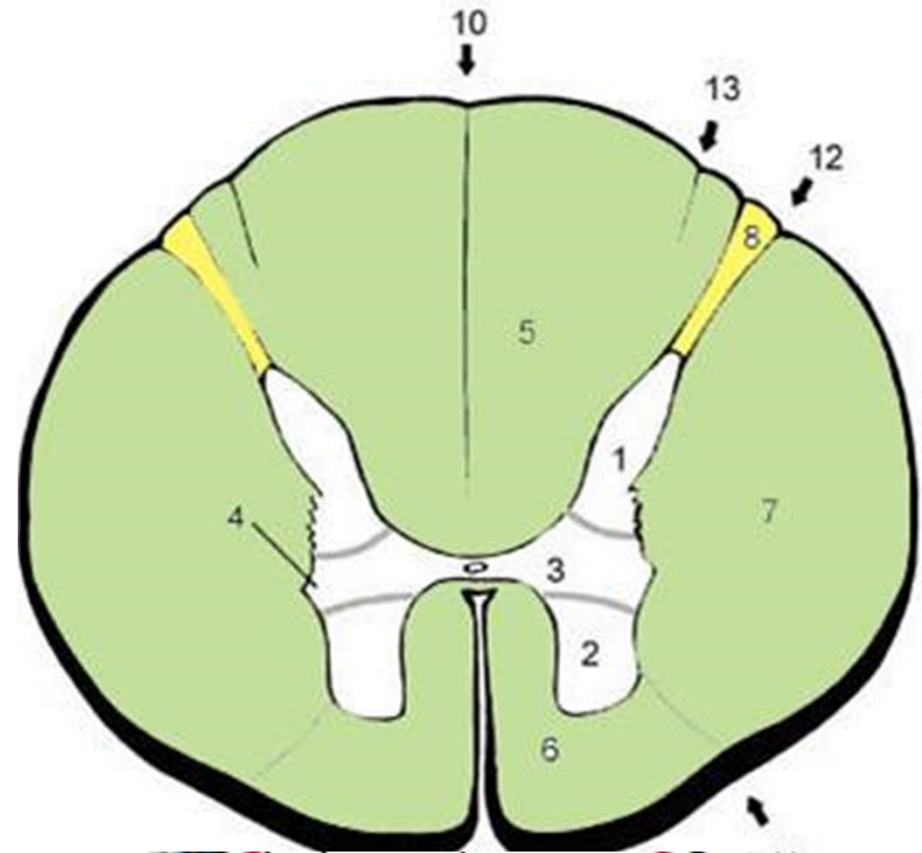
The spinal cord – crosssection

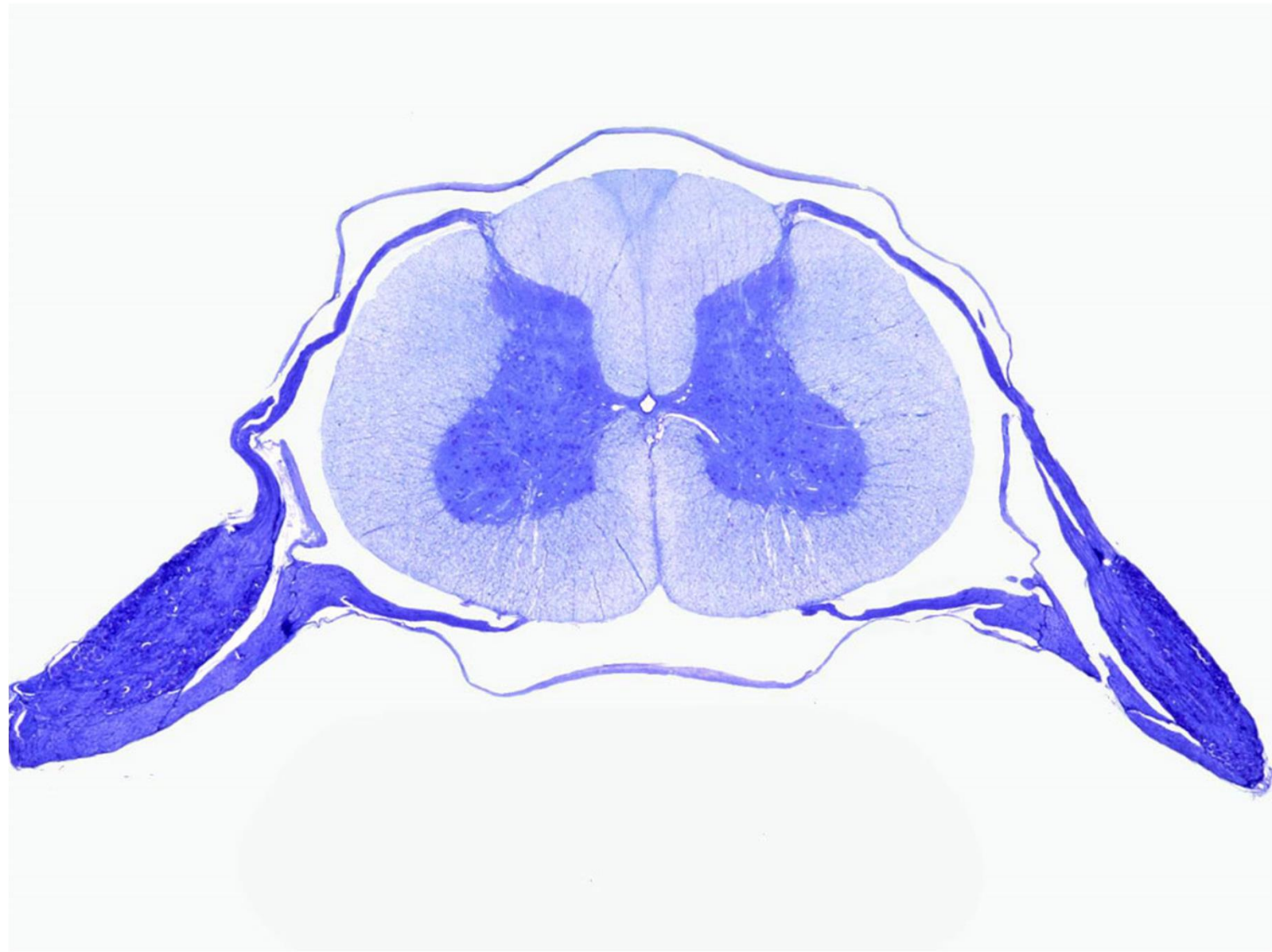
Grey matter (*substantia grisea*)

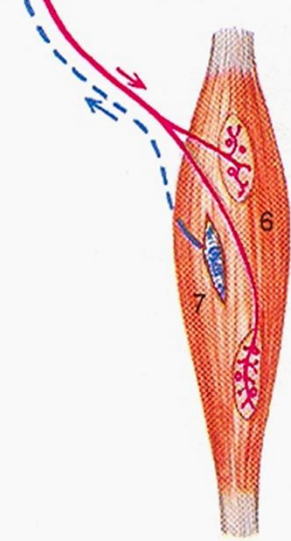
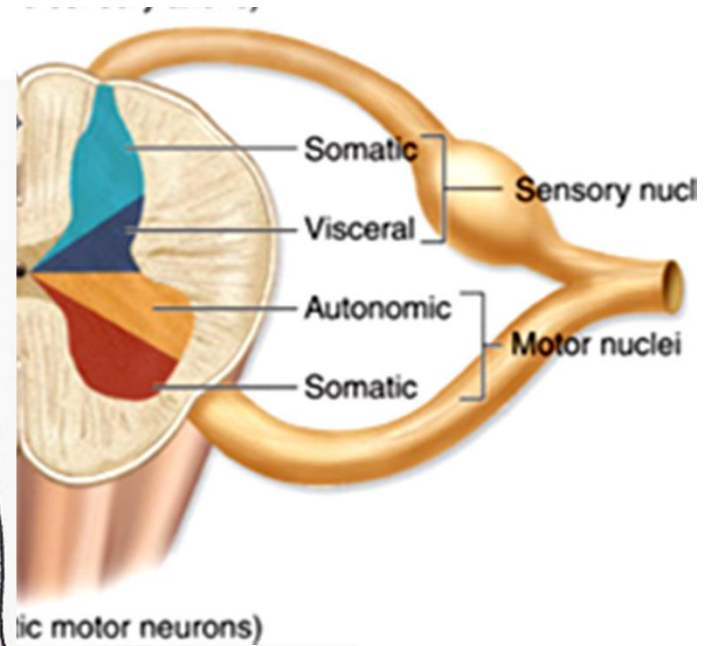
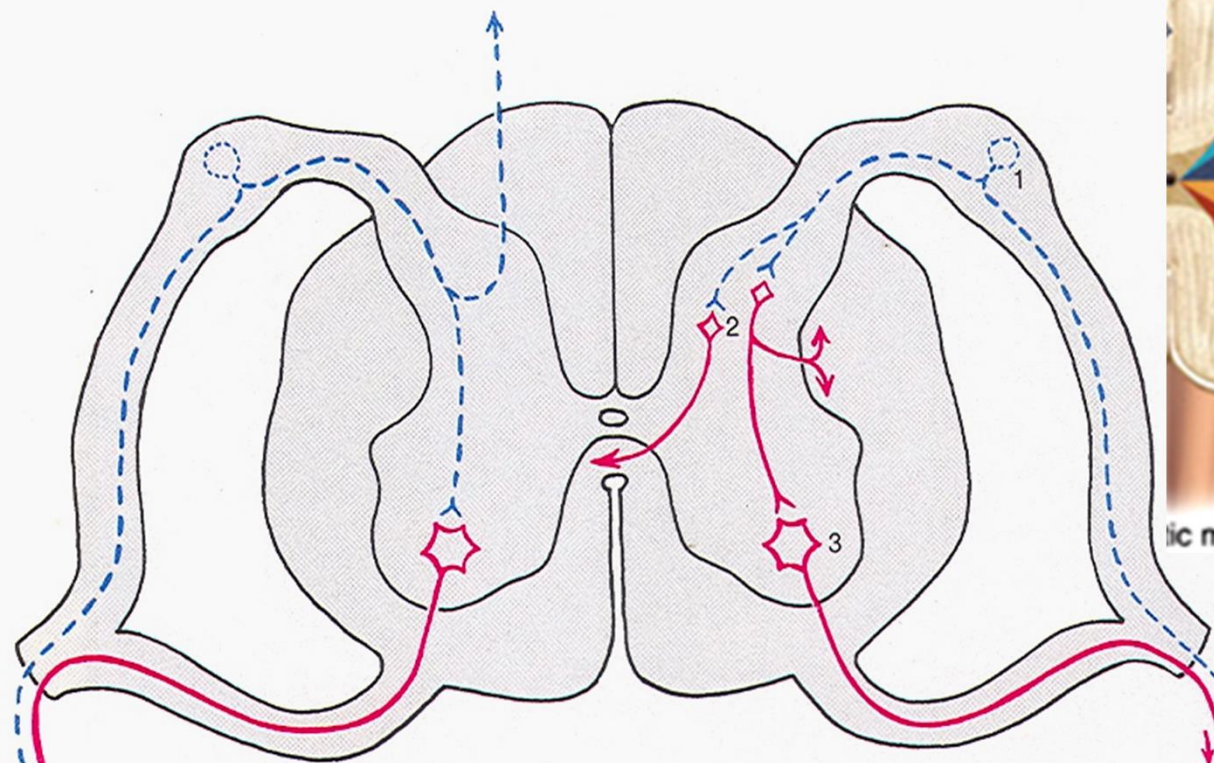
- canalis centralis
- cornu anterius
- cornu posterius

White matter (*substantia alba*)

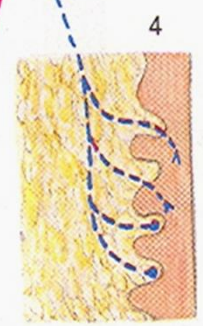- funiculus anterior
- funiculus lateralis
- funiculus posterior







- 1 = Dorsal root ganglion
- 2 = Interneurons
- 3 = Motor neuron of ventral horn
- 4 = Skin
- 5,6 = Motor end plates
- 7 = Muscle spindle

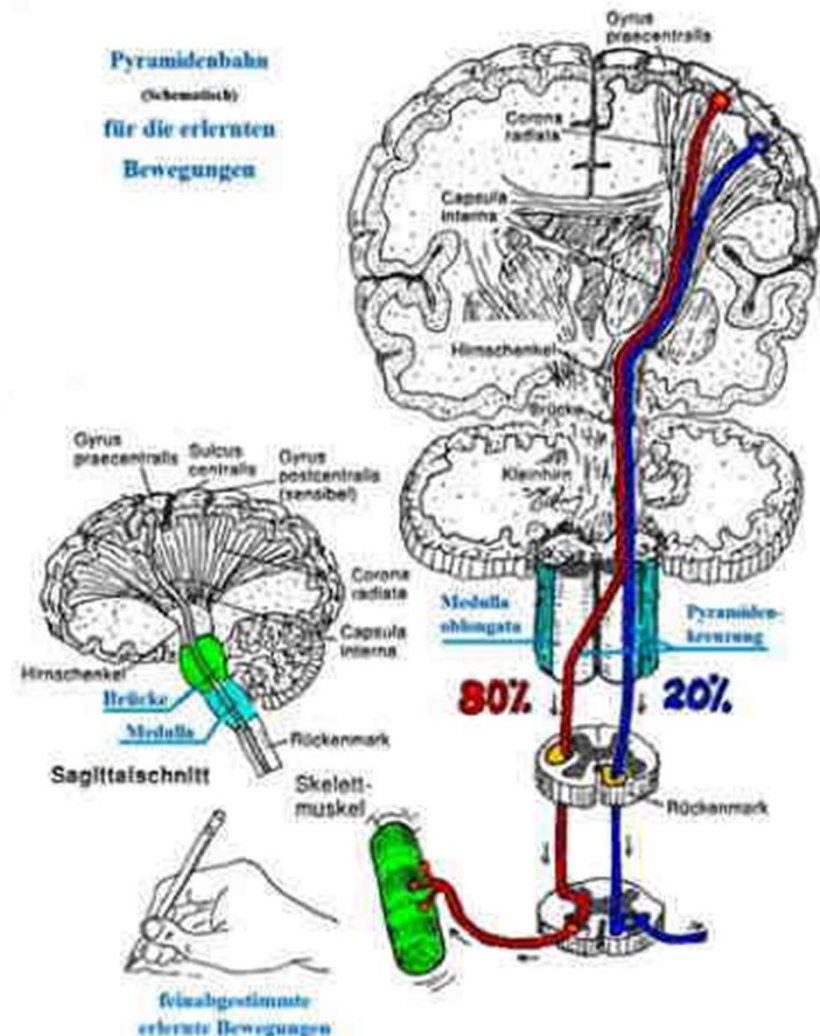


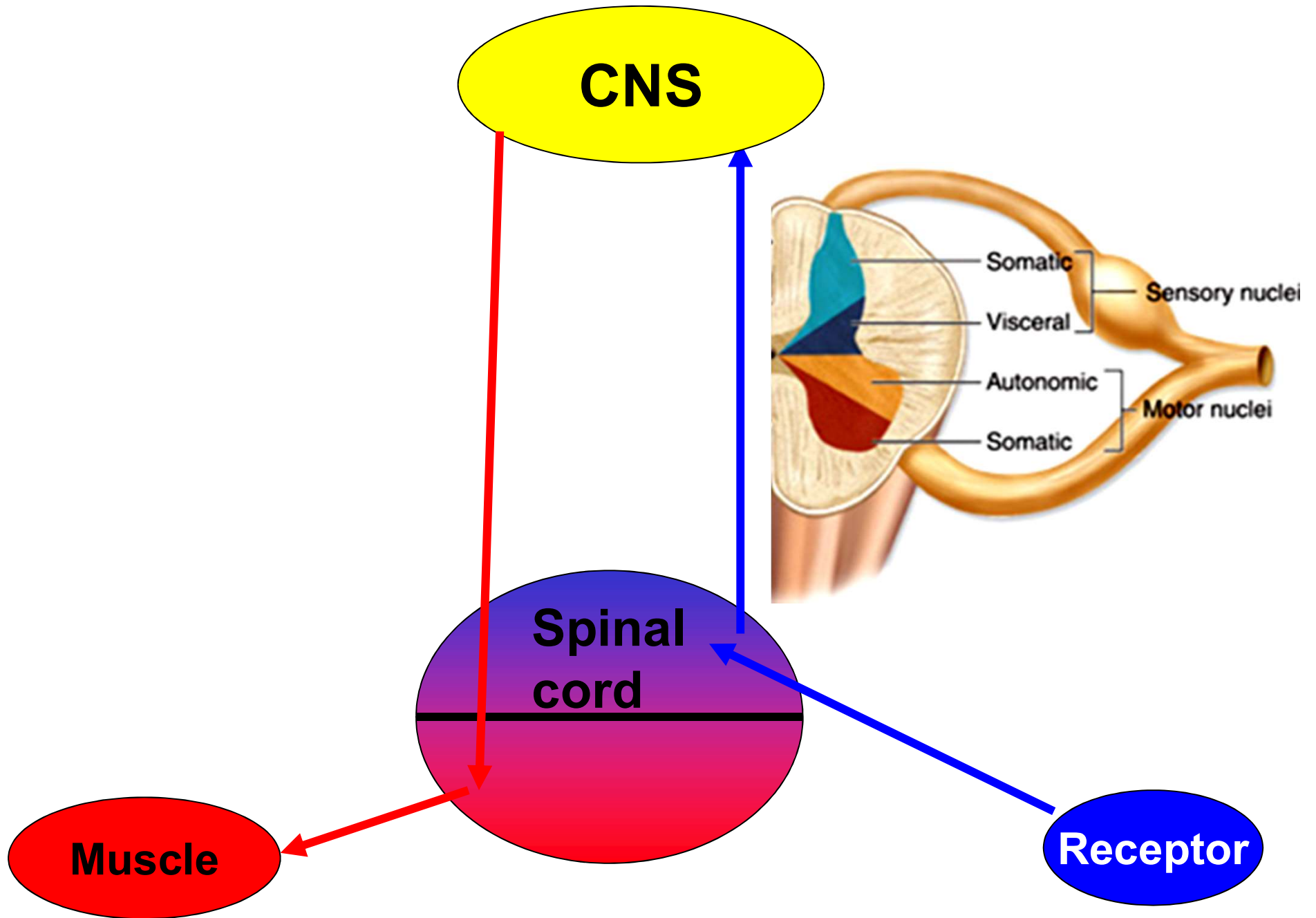
The pathways within spinal cord– white matter

- **Ascending (afferent) sensory**
 - somatosensory and viscerosensory information converge within spinal nerves
- **Descending (efferent) motor**
 - somatomotor
 - visceromotor (autonomous)

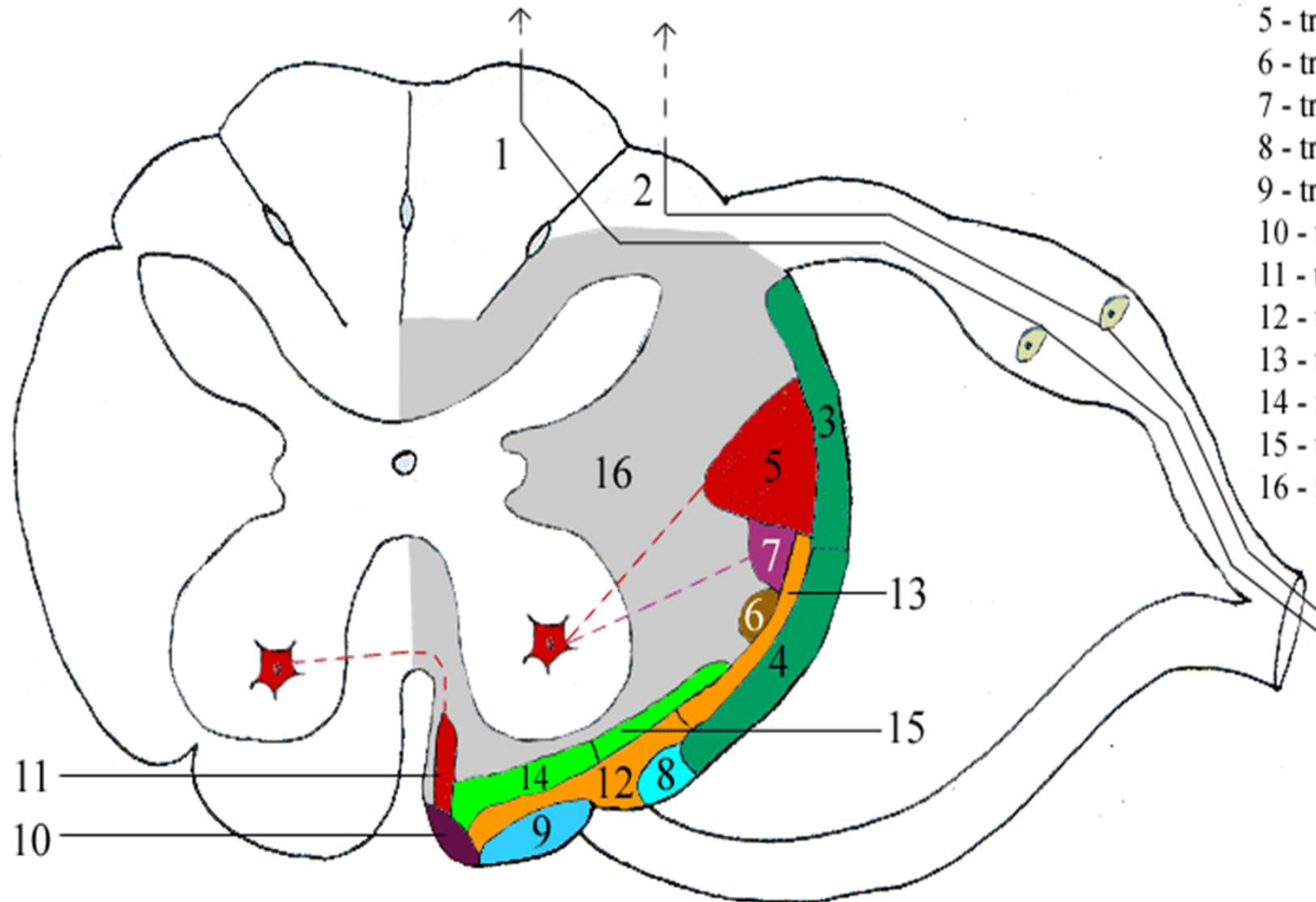
- **Crossing of tracts !!!**

(damage can cause contralateral paralysis)





Crossection – white matter of spinal cord and its tracts



- 1 - fasciculus gracilis /Golli/
- 2 - fasciculus cuneatus /Burdachi/
(jen v oblasti horních Th a C segmentů)
- 3 - tractus spinocerebellaris posterior
- 4 - tractus spinocerebellaris anterior
- 5 - tractus corticospinalis lateralis
- 6 - tractus spinotectalis
- 7 - tractus rubrospinalis
- 8 - tractus spinoolivaris
- 9 - tractus vestibulospinalis (med. et lat.)
- 10 - tractus tectospinalis
- 11 - tractus corticospinalis anterior
- 12 - tractus spinothalamicus anterior
- 13 - tractus spinothalamicus lateralis
- 14 - fibrae reticulospinales
- 15 - tractus spinoreticularis
- 16 - fasciculi proprii

Protopathic sensibility: sensibility to strong stimulations such as pain, temperature, and some forms of touch

Epicritic sensibility: the sensibility to gentle stimulations permitting fine discriminations of touch and temperature

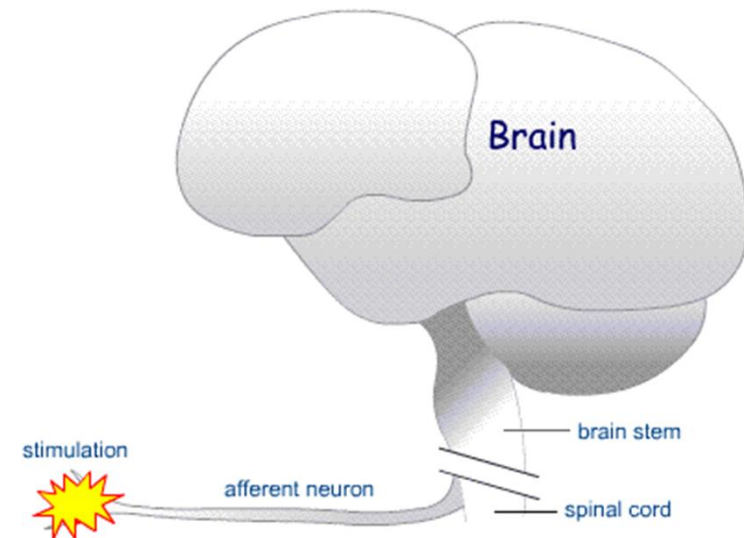
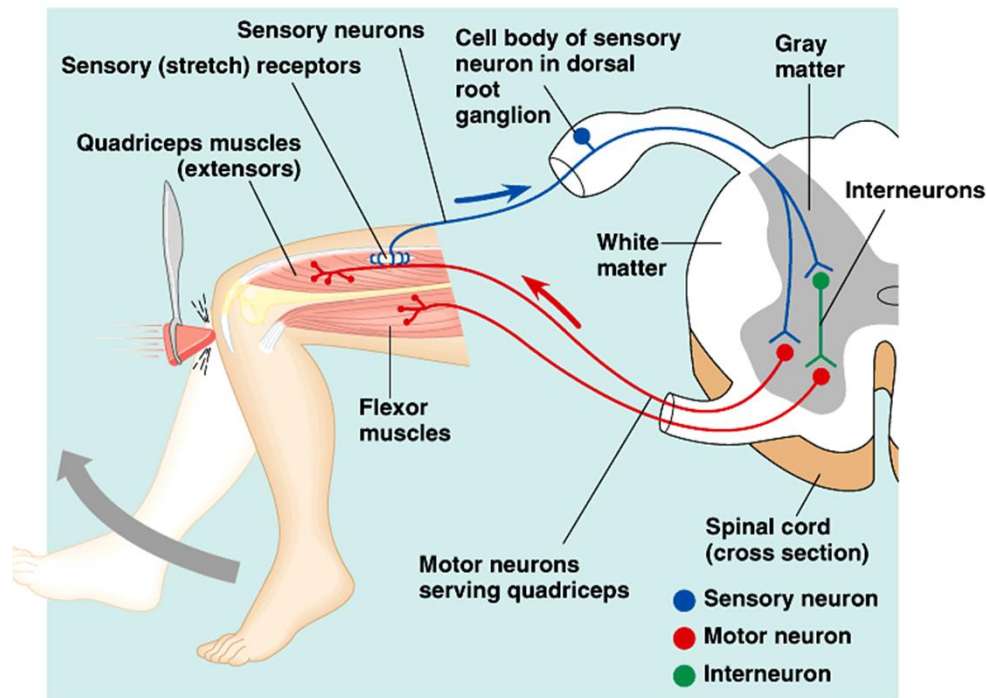
Proprioception: information from locomotor system

Ascending tracts

Modality: ***touch, pain, heat-cold, position (proprioception)***

Receptor: ***Exteroceptors, Interoceptors, Proprioceptors***

- First neuron: ***ganglion nervi spinalis***
- Second neuron: ***spinal cord / brain stem***
- Third neuron: ***thalamus (nuclei ventrobasales)***
- Ending: ***cerebral cortex, cerebellar cortex, brain stem***



Descending tracts

Tractus corticospinalis = pyramidal tract

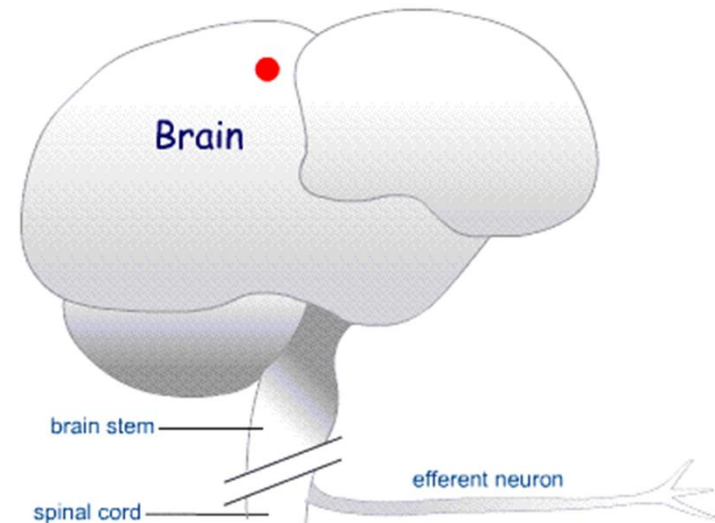
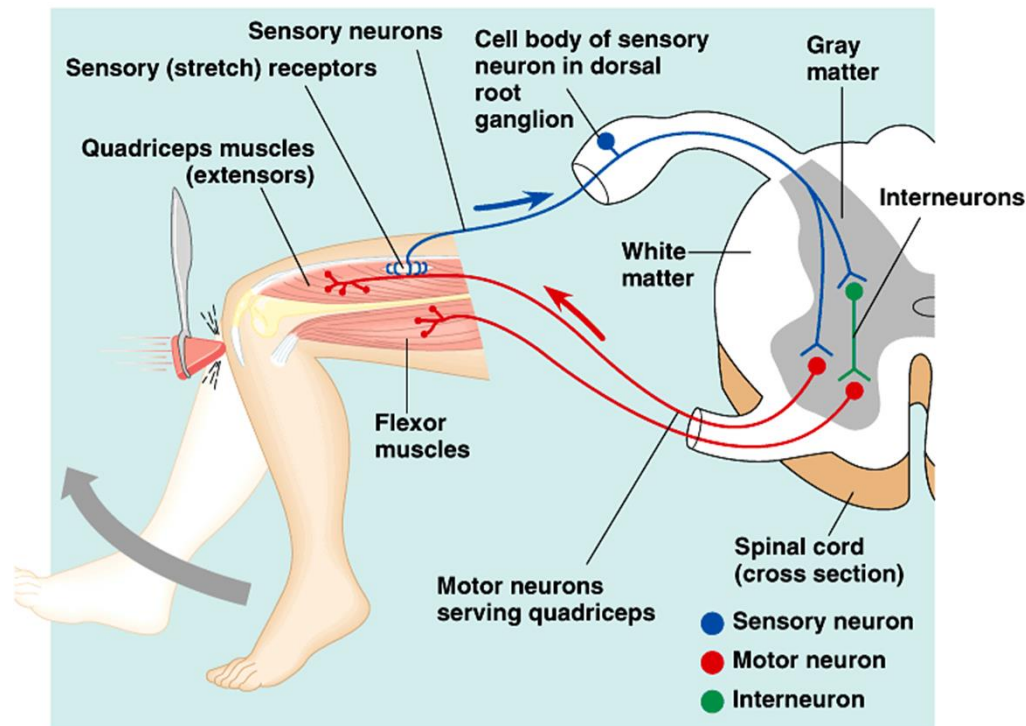
main motor tract – *voluntary movement*

1st neuron – cerebral cortex(pyramidal cell)

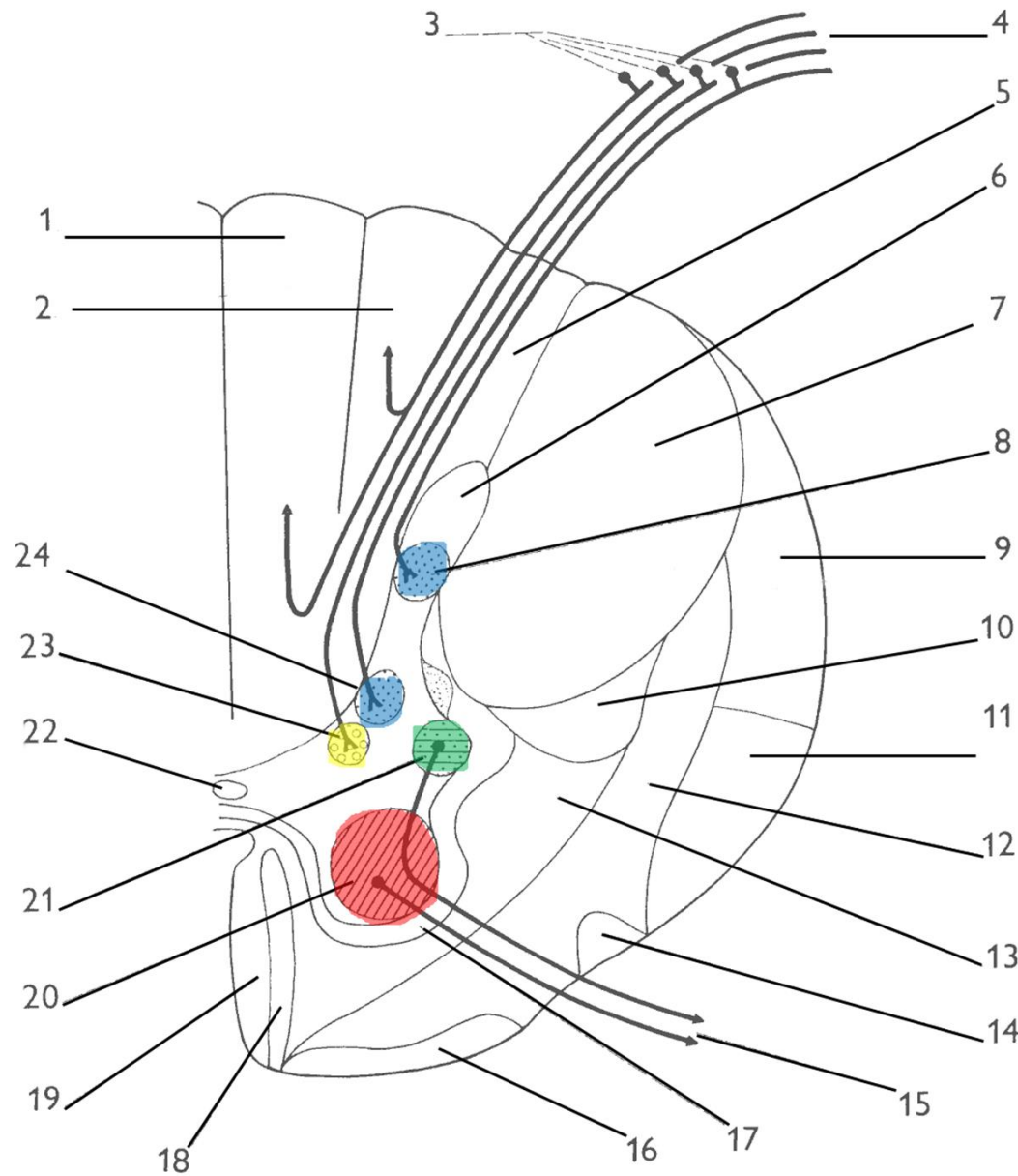
2nd neuron – alfa-motoneurons → spinal nerve

Extrapyramidal tracts

Involuntary movement



Nuclei



Ncl. Proprius

Ncl. Thoracicus

Ncl. Intermediomedialis

Ncl. Intermediolateralis

Ncll. motorii

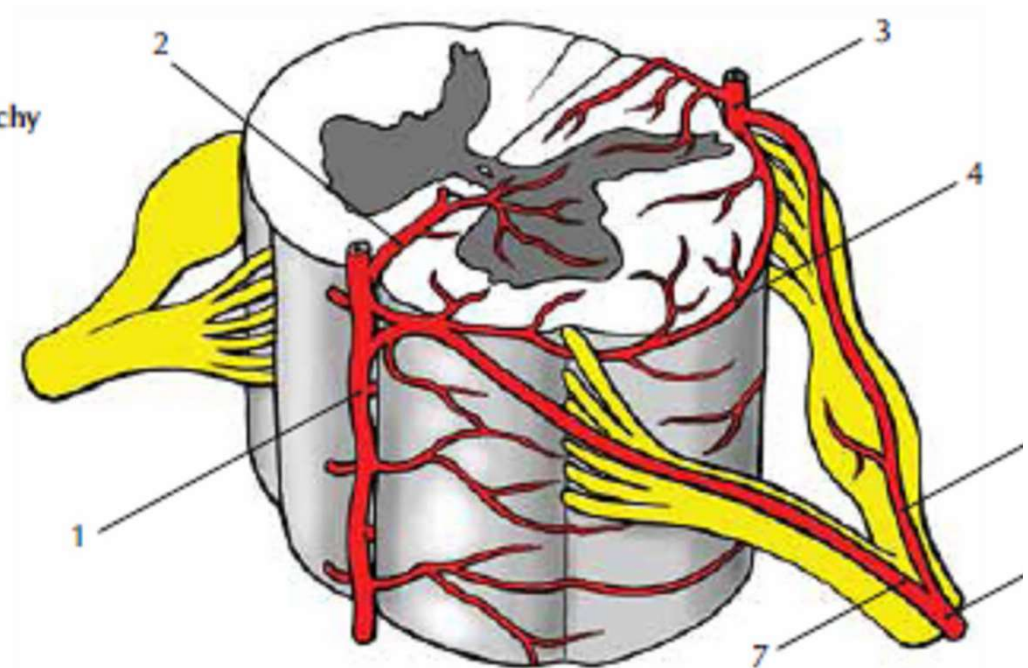
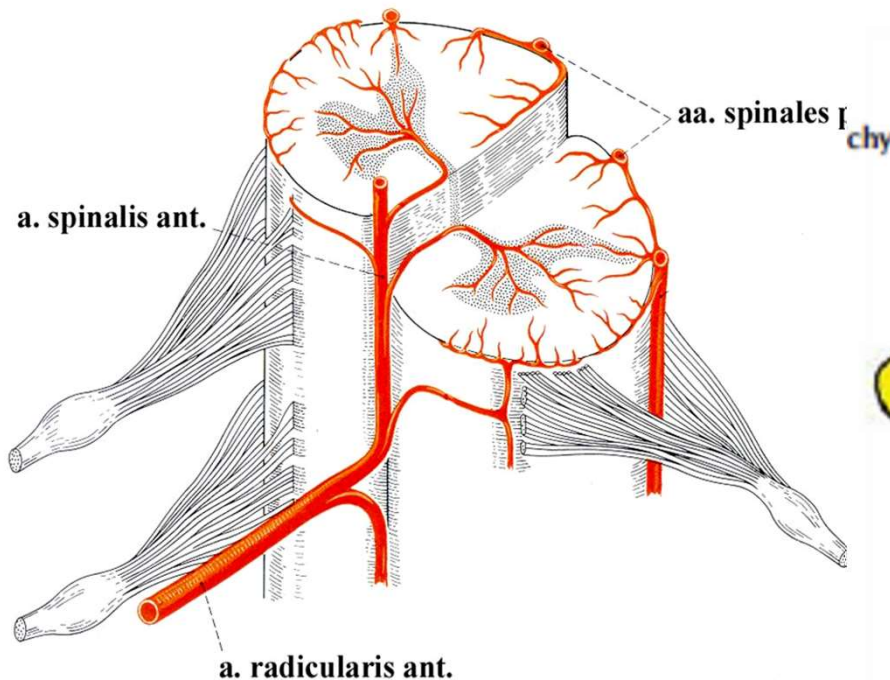
The arterial supply

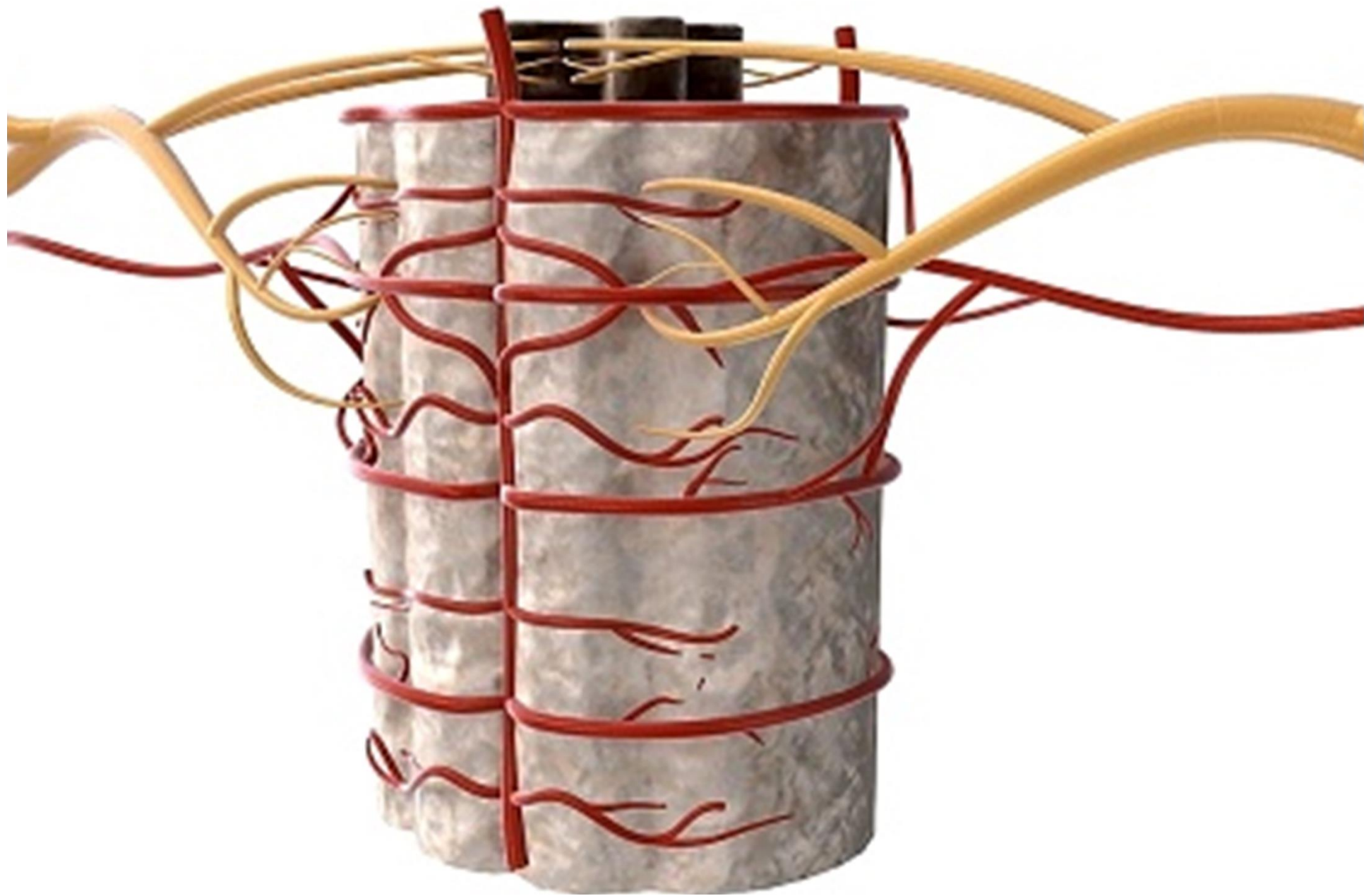
Longitudinal arteries:

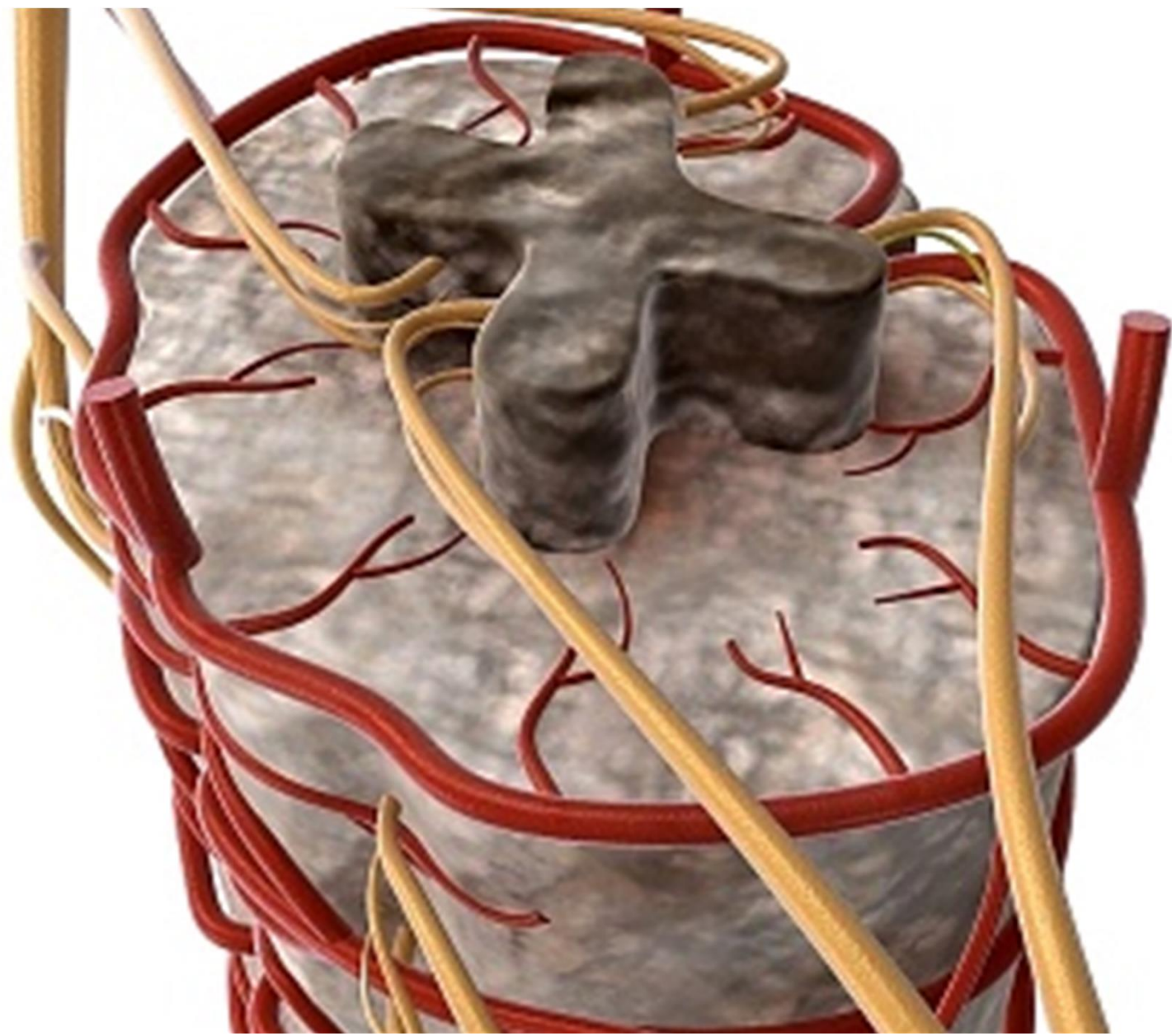
a. spinalis ant. (unpaired, anteriorly) a. vertebralis

aa. spinales post. (most often 4, posteriorly)

transverse arteries: segmental branches

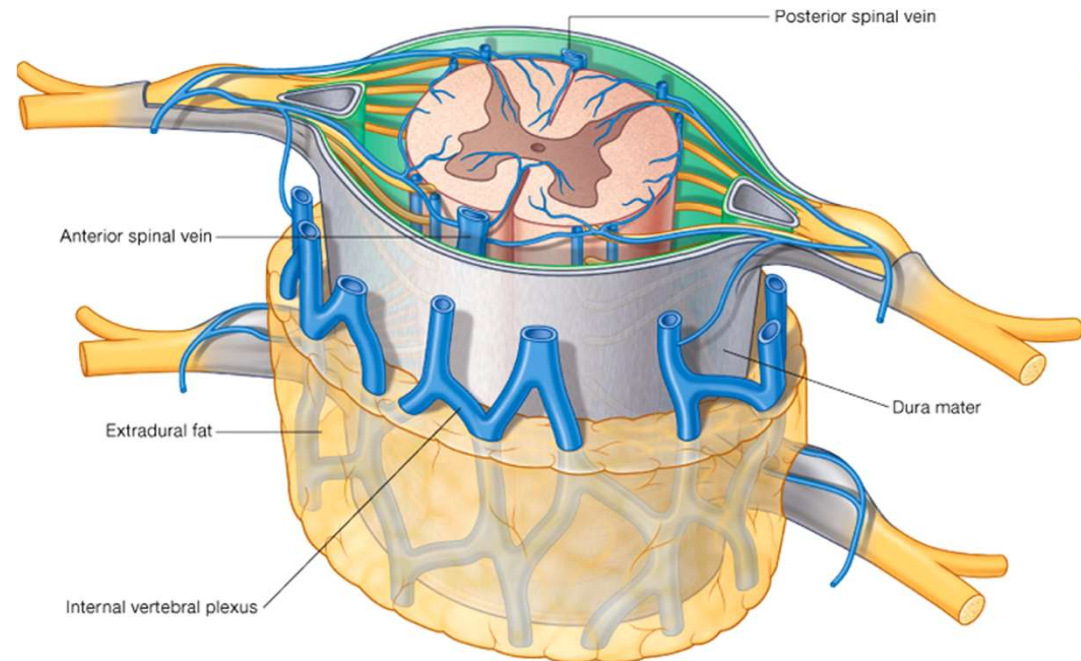
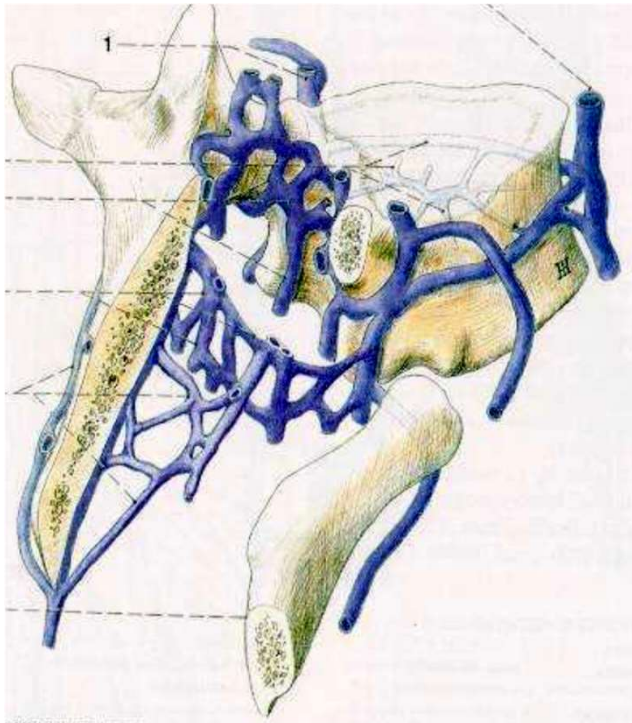






Veins of spinal cord

- **Longitudinal veins**
- **Transverse veins ...into vv. intercostales posteriores**



Drake: Gray's Anatomy for Students, 2nd Edition.
Copyright © 2009 by Churchill Livingstone, an imprint of Elsevier, Inc. All rights reserved.

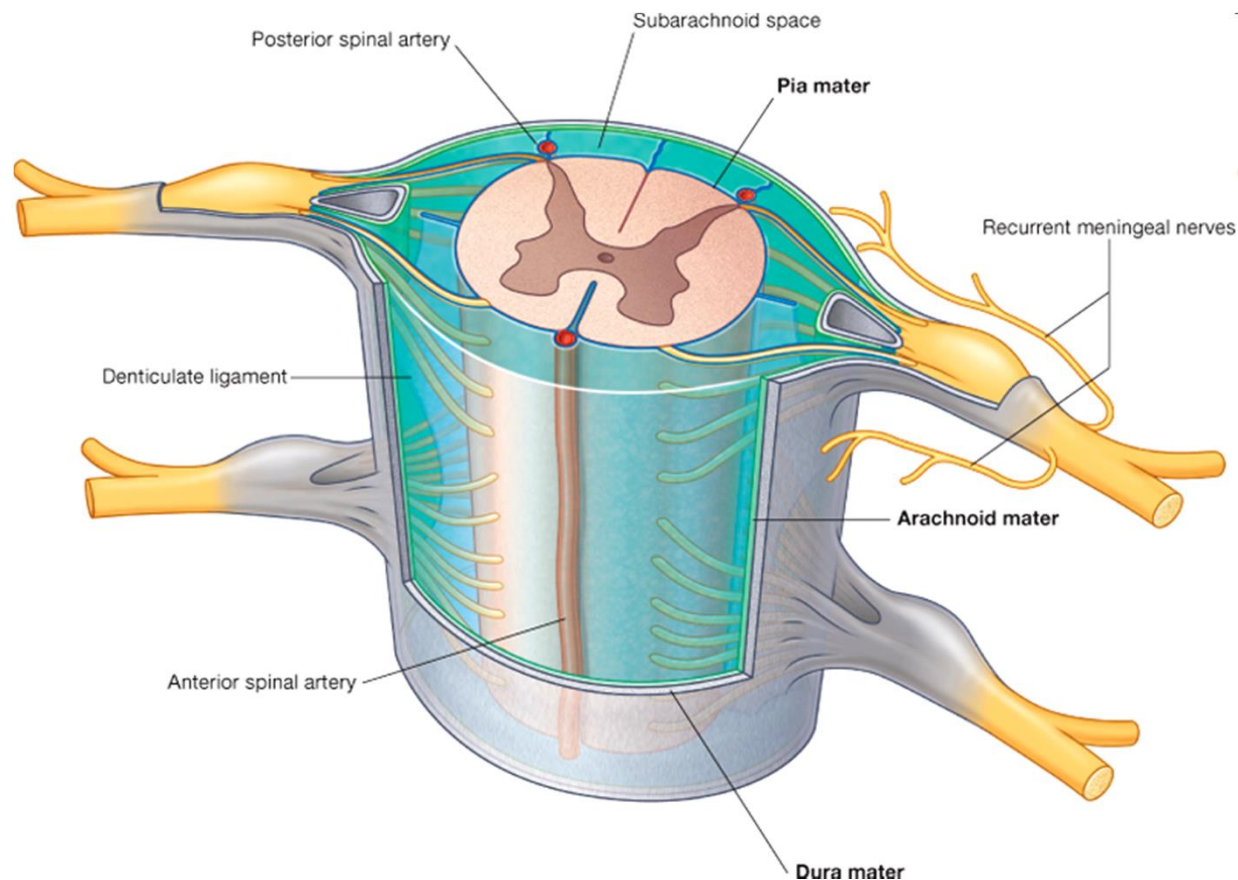
THE SPINAL MENINGES

Meninges of the brain and spinal cord

- **CNS (spinal cord and brain) is covered with several layers of coverings**
- **Most superficial is a bony covering, that is formed by bones of skull and by vertebrae**
- **Below the bony covering, there are *meninges*. They are fibrous coverings, which form following structures:**
 - **dura mater**
Cranial and spinal dura mater
 - **arachnoid mater**
Cranial and spinal arachnoid mater
 - **pia mater**
Cranial and spinal pia mater

SPINAL DURA MATER

- Covering fibrous membrane of the spinal cord
- Within the spinal canal, there is a space between dura and the periosteum (known as epidural space), which is filled with fibrous tissue and venous plexuses
- It doesn't enter the grooves and fissures on surface of the spinal cord



Saccus durae matris spinalis

- It extends from foramen magnum till body of S2 -(filum terminale externum)
- The spinal cord and cauda equina
- It is separated from walls of spinal canal using fibrous tissue
- It continues onto surface of the spinal nerves within foramen intervertebrale



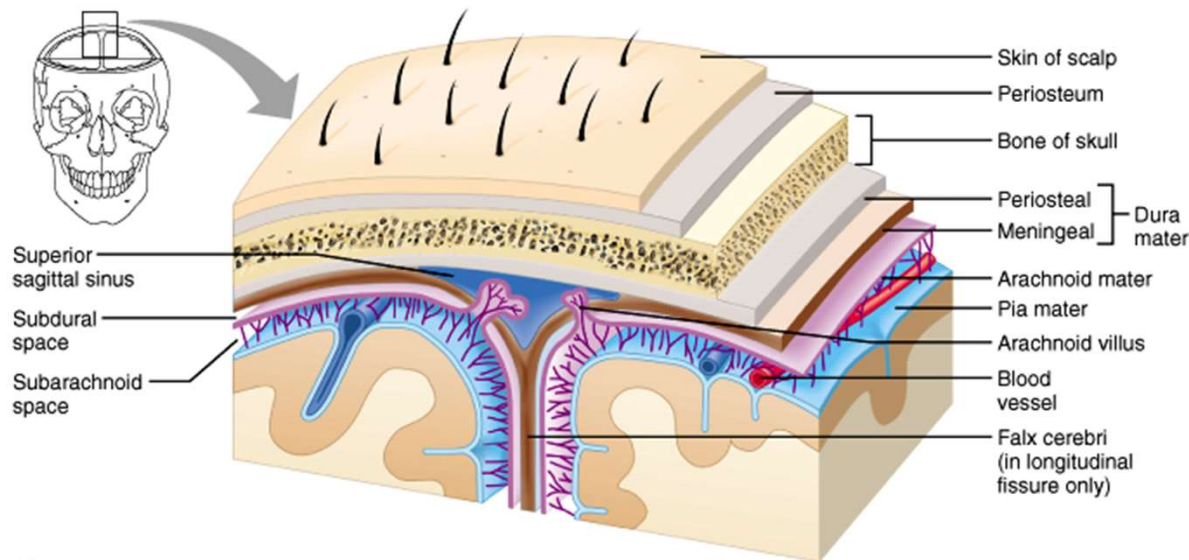
Spaces around dura mater

- spatium epidurale:

Brain - virtual space

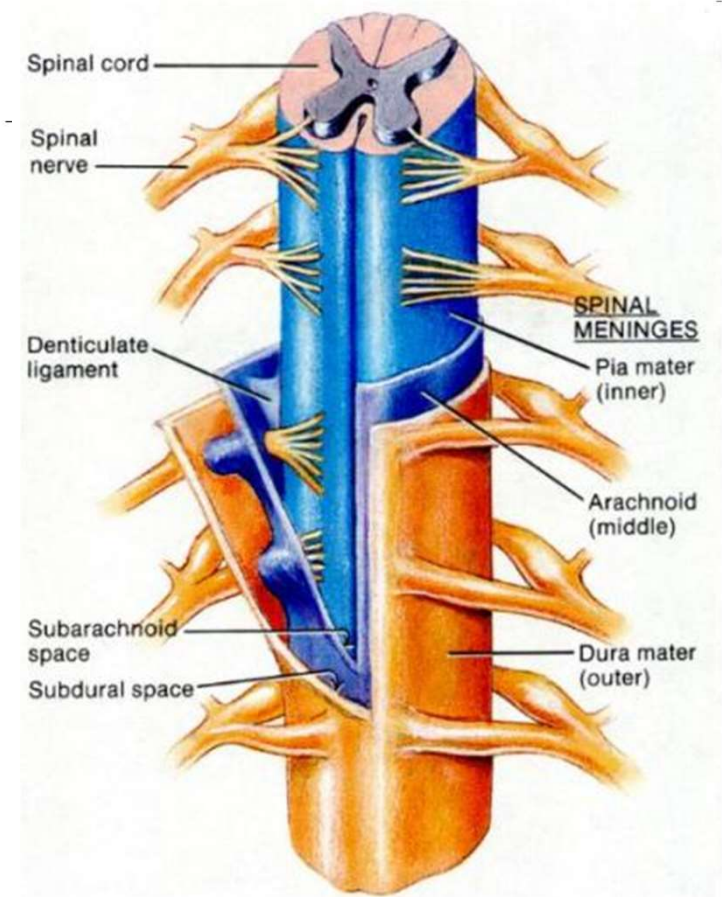
Spinal cord – here it is present

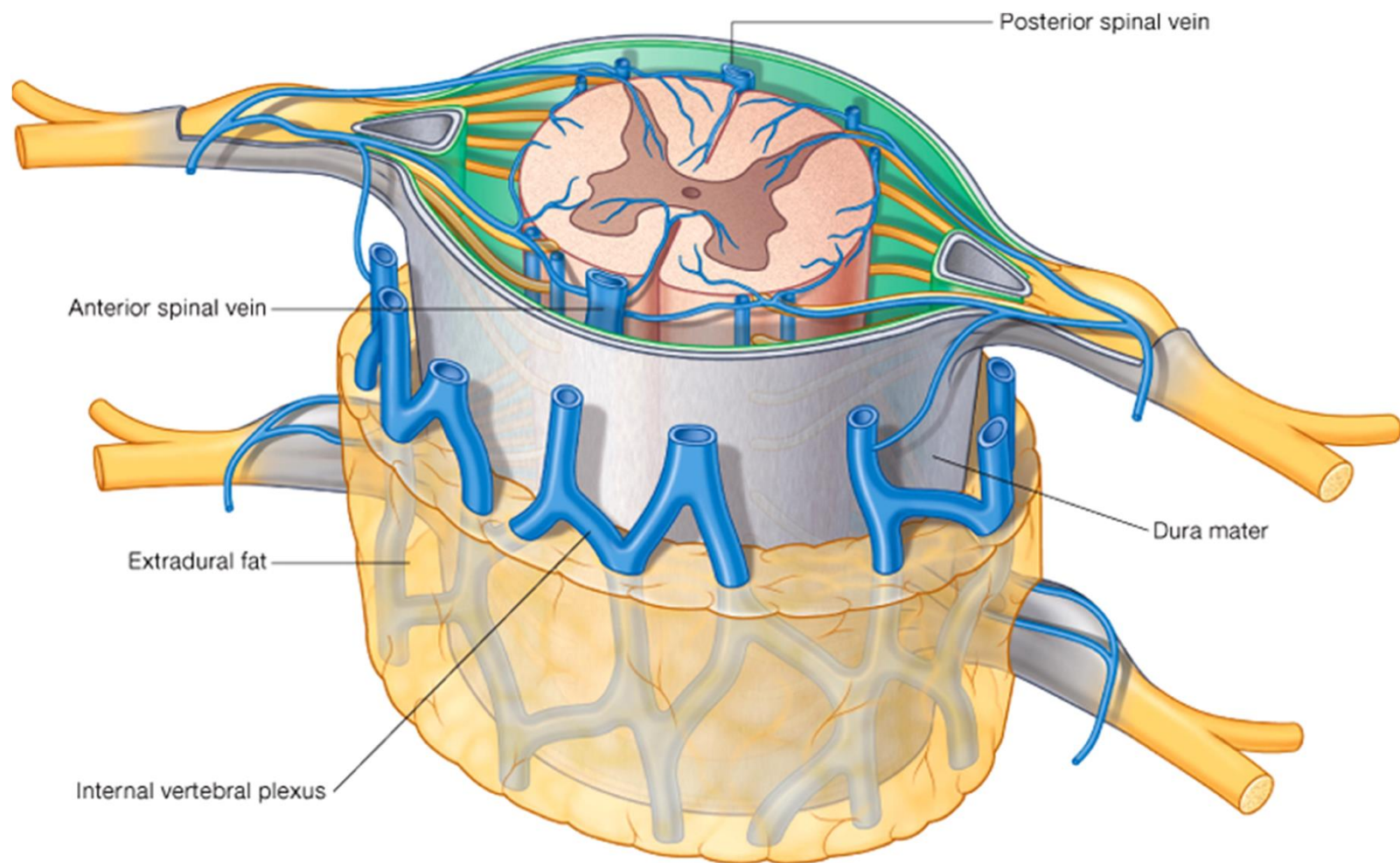
- spatium subdurale: virtual space



(a)

Copyright © 2001 Benjamin Cummings, an imprint of Addison Wesley Longman, Inc.





Drake: Gray's Anatomy for Students, 2nd Edition.
Copyright © 2009 by Churchill Livingstone, an imprint of Elsevier, Inc. All rights reserved.

SPINAL ARACHNOID MATER

- **Finer fibrous membrane**
- **It covers the spinal cord below dura mater**
- **It doesn't enter the grooves and fissures on the surface of the spinal cord**
- **Between dura and arachnoid, there is subdural space, between arachnoid and pia mater subarachnoid space, that is filled with cerebrospinal fluid, which forms water pillow absorbing impacts against the brain**

SPINAL PIA MATER

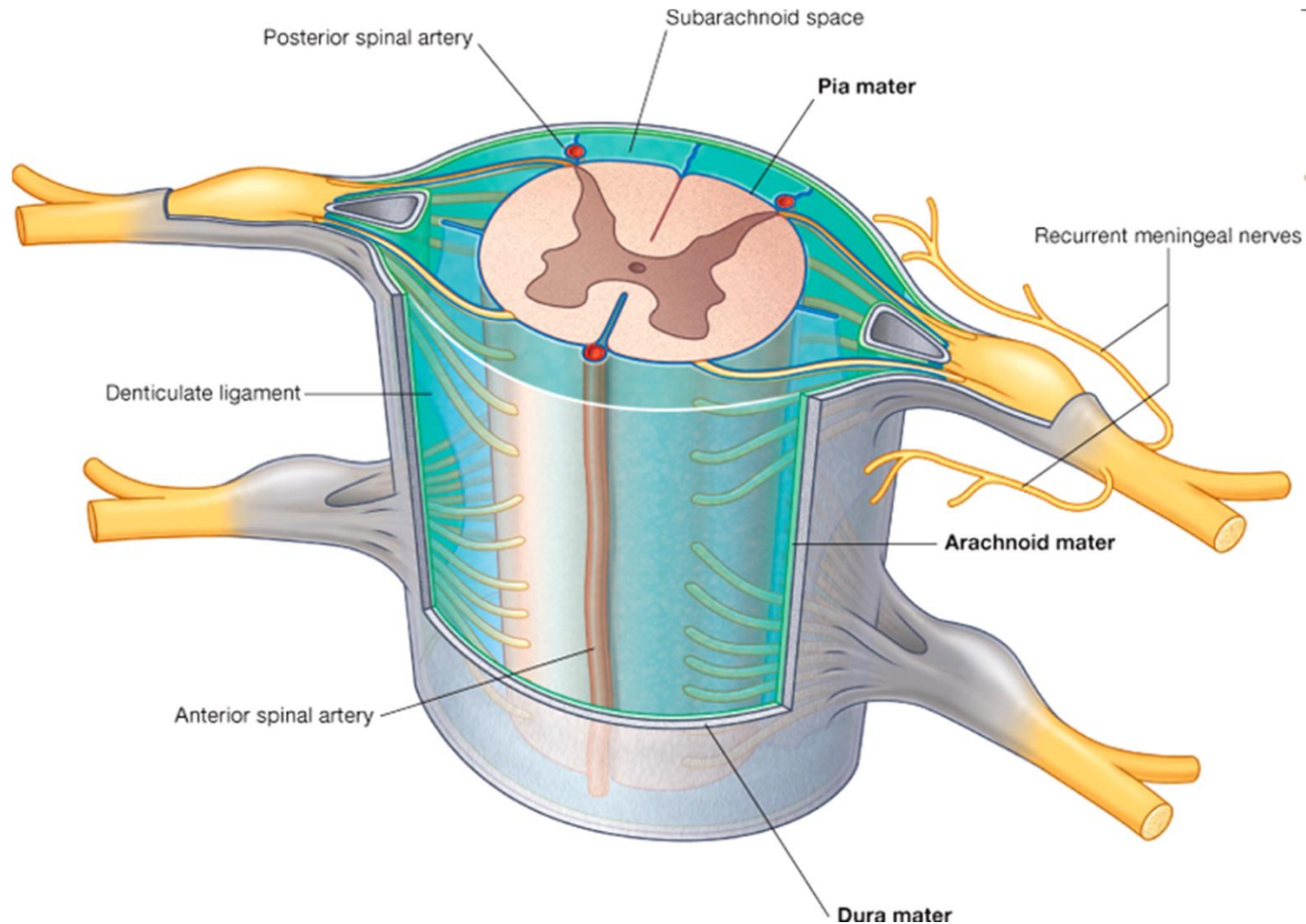
- **Very fine fibrous membrane, that contains numerous blood vessels**
- **It lies directly on the surface of the spinal cord and it permeates into all grooves and fissures**

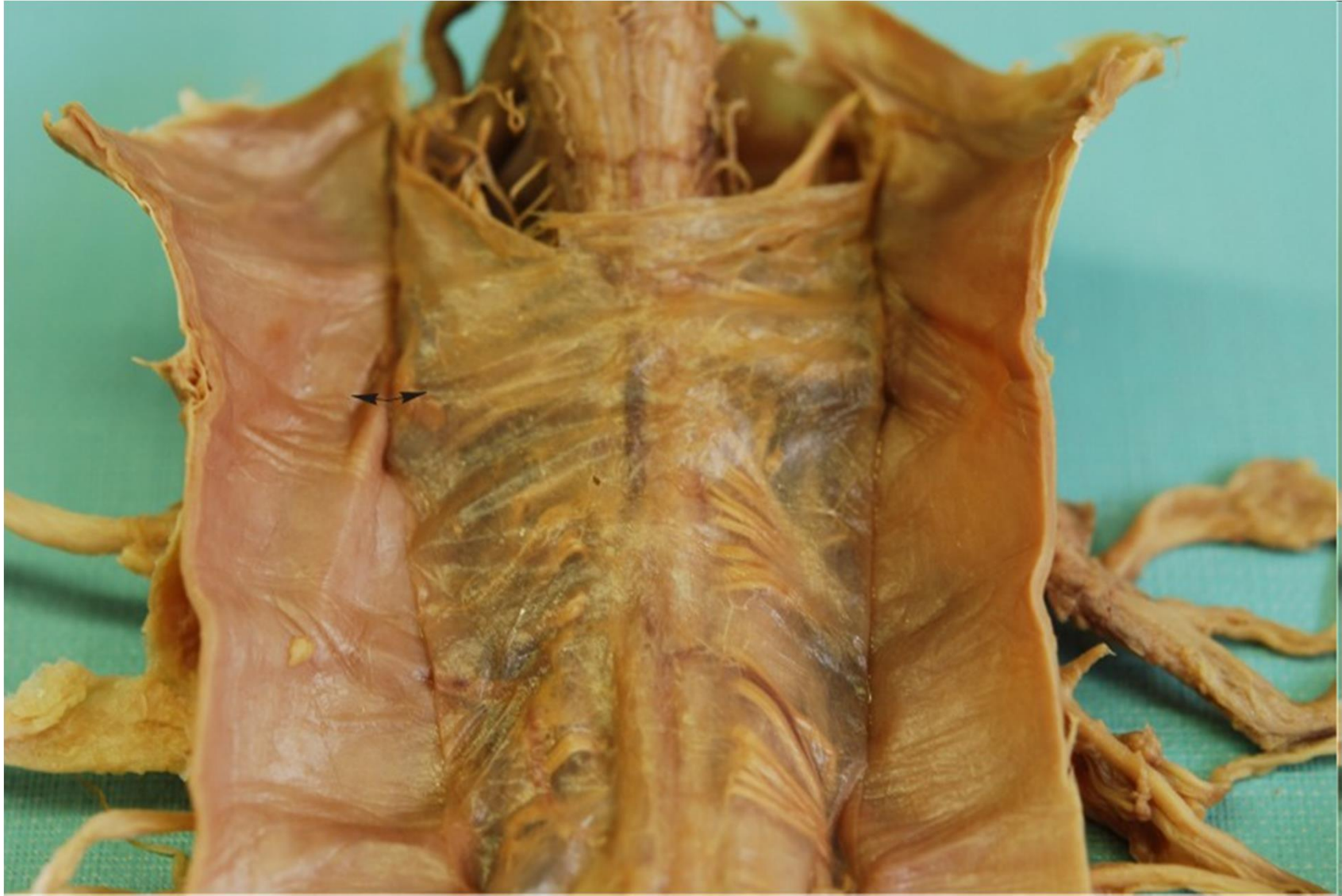Endorhachis – periosteum of spinal canal

Spinal dura mater - outermost sheet of spinal meninges, it forms **saccus duræ matris spinalis**

Spinal arachnoid – avascular membrane, it tightly touches the inner surface of dura mater

Spinal Pia mater – innermost sheet of spinal meninges, it contains vessels

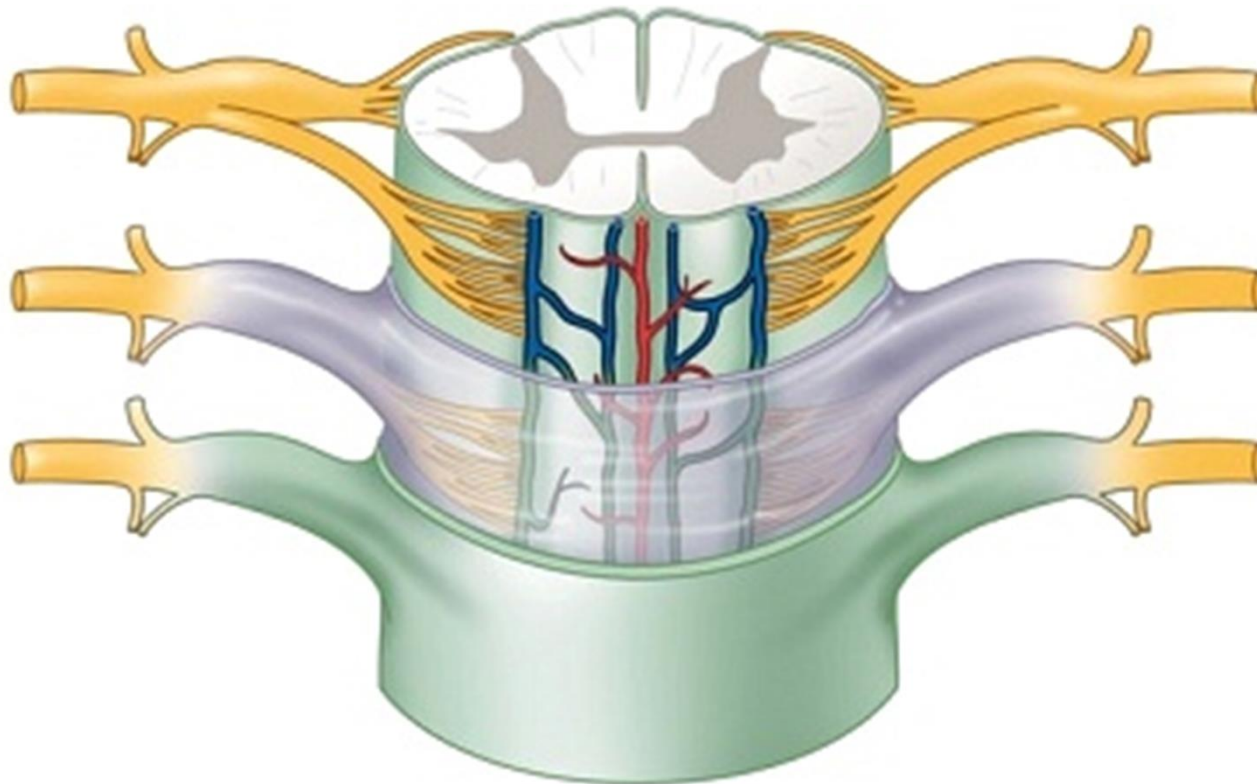




Spatium epidurale – space between endorhachis and saccus durae matris spinalis, it is filled with fat tissue and contains venous plexuses

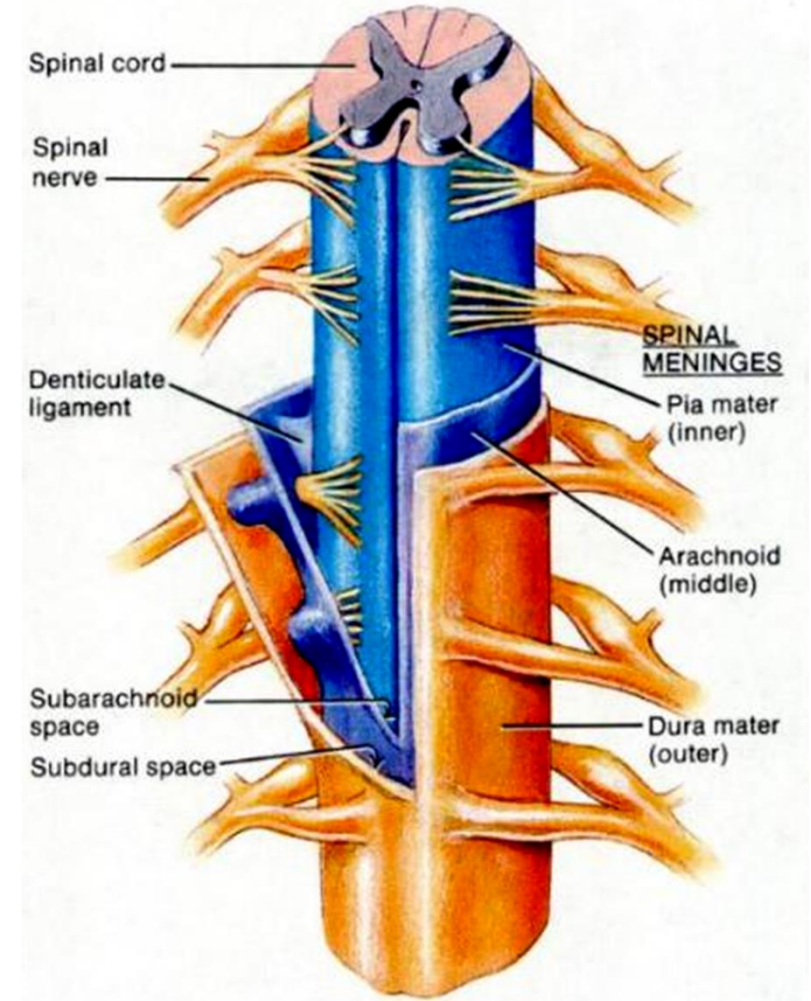
Spatium subdurale – just slitted space between dura mater spinalis et arachnoidea spinalis, which is enlarged just under some pathological condition (subdural hematoma)

Spatium subarachnoideum – space between arachnoidea spinalis et pia mater spinalis, it contains the cerebrospinal fluid



Layers within the spinal canal

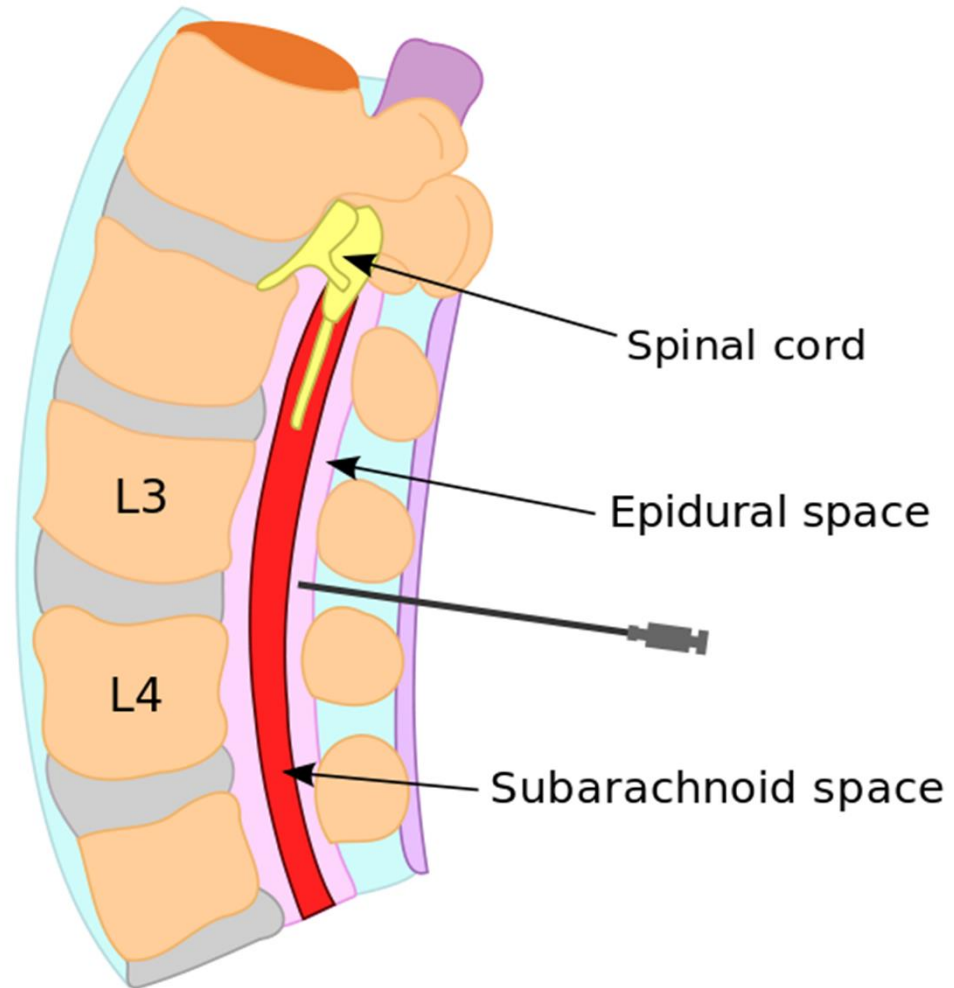
- Periosteum = Endorhachis
- **Spatium epidurale**
- Dura mater spinalis
- **Spatium subdurale**
- Arachnoidea mater spinales
- **Spatium subarachnoideum**
- Pia mater spinalis
- Medulla spinalis



Clinical use

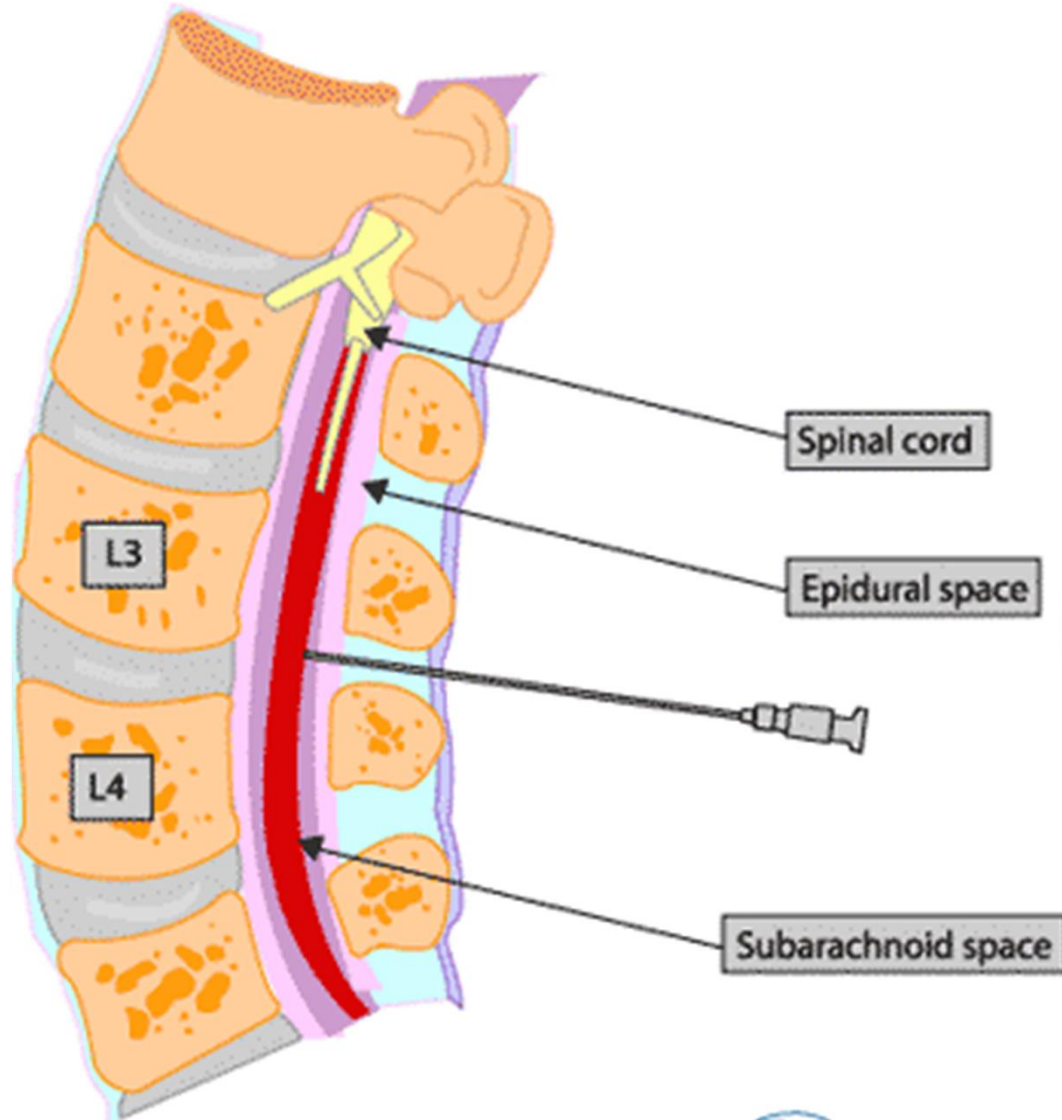
- epidural anesthesia
- Spinal tap (spinal anesthesia), drug delivery

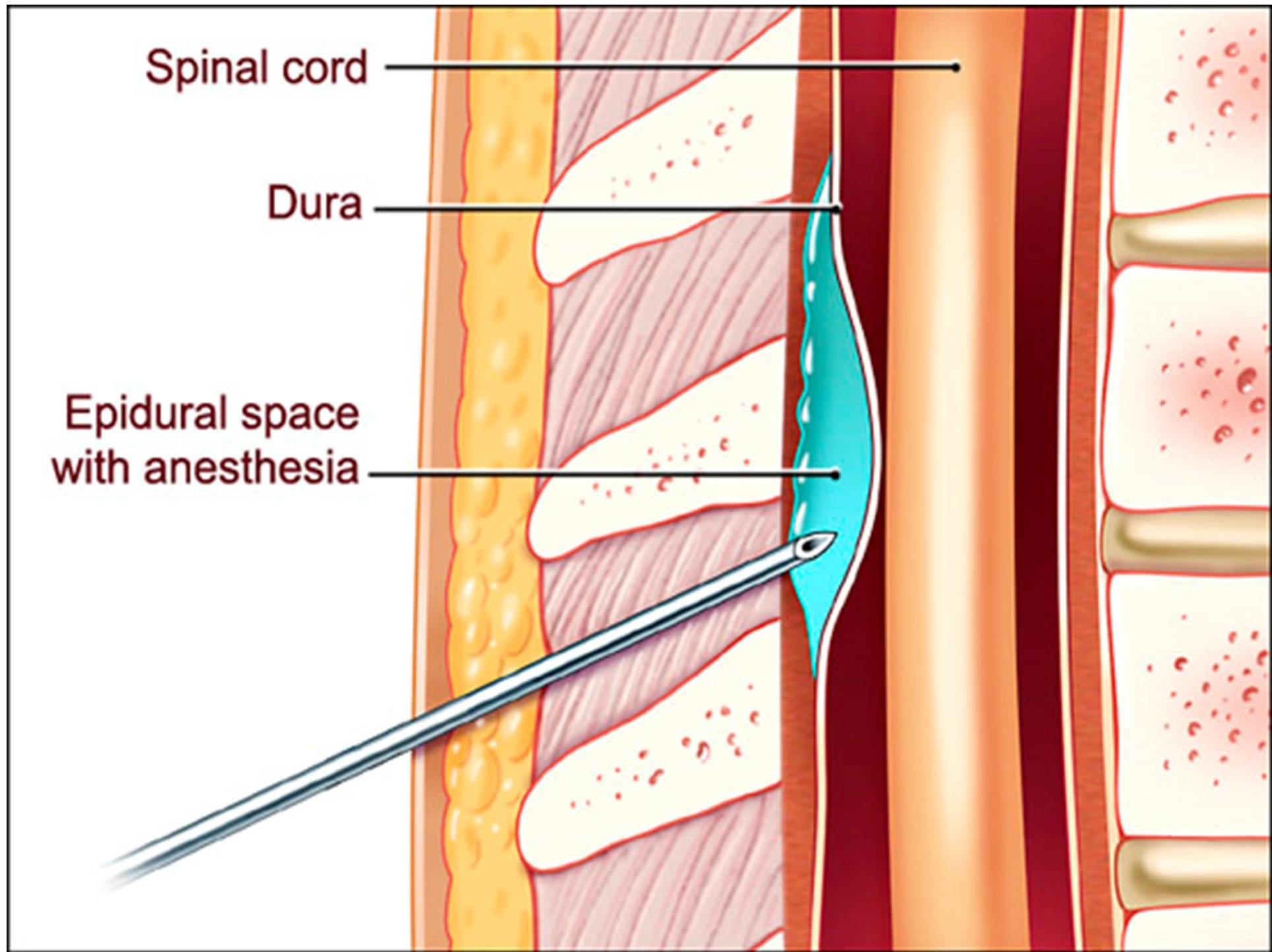
Epidural anesthesia – spatium epidurale



Spinal tap – spatium subarachnoideale

- L3–L4, L4-L5





CEREBRAL MENINGES

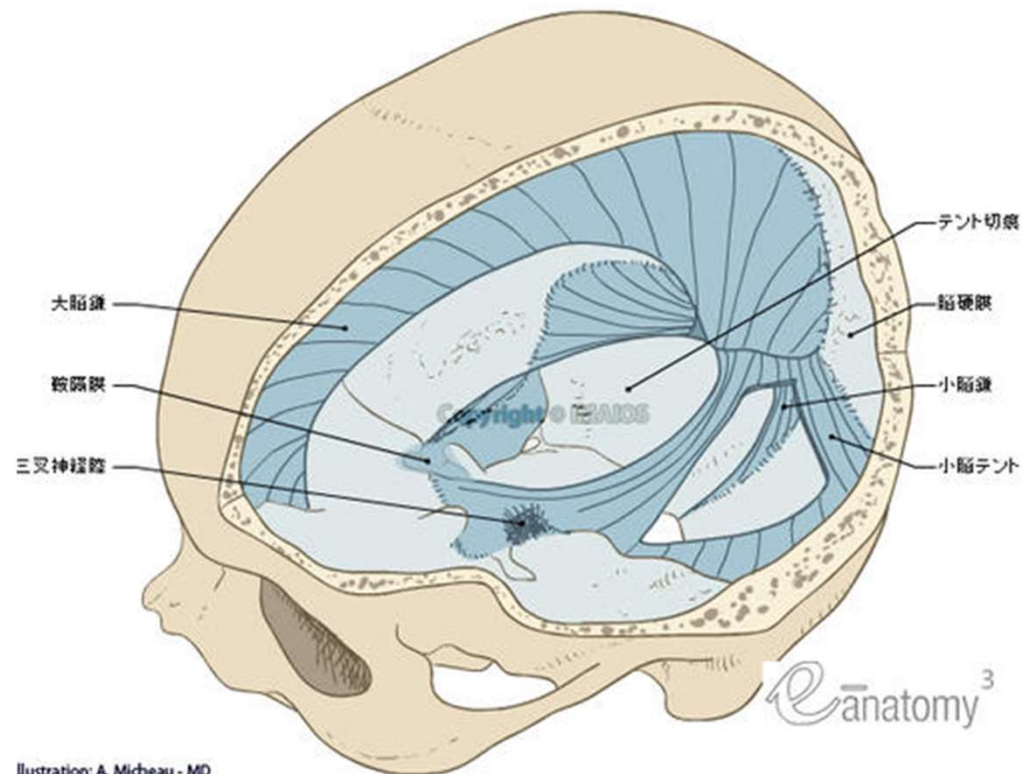
CRANIAL DURA MATER

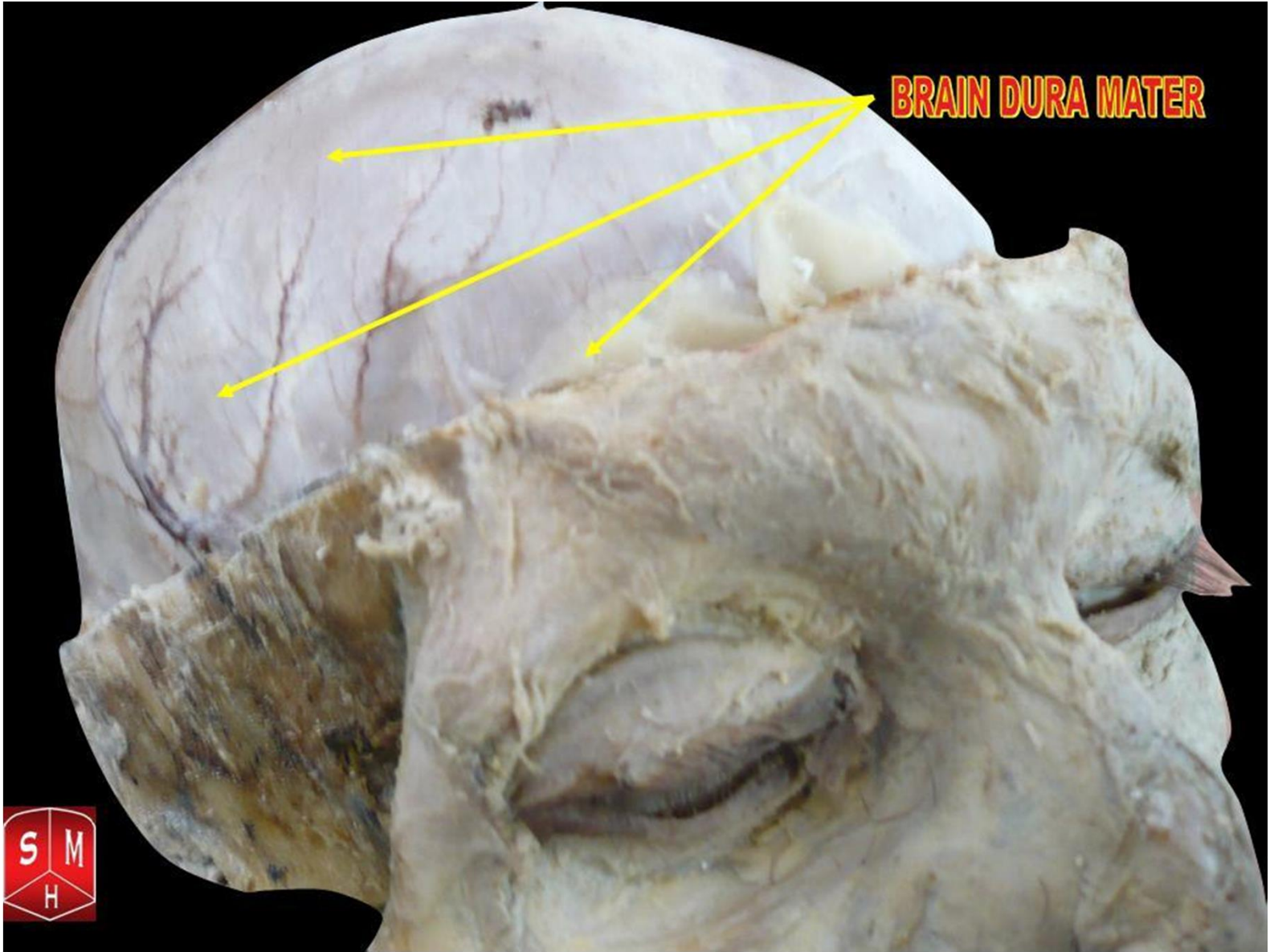
Outmost covering, solid collagen tissue

It covers the cranial cavity (it touches tightly the periosteum)

Here is no real epidural space, it forms only under pathological conditions.

It doesn't enter the grooves and fissures on surface of the brain, it enters only the largest fissures of the brain, where it emits its folds





Cranial dura mater

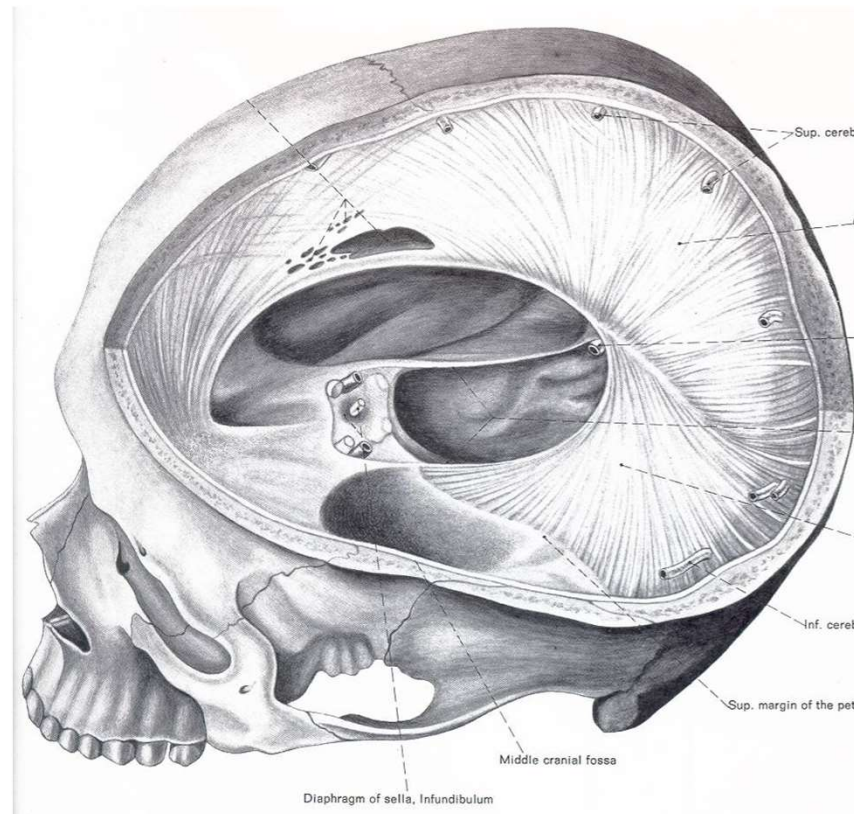
Cranial dura mater enters only the largest fissures of the brain, where it emits its folds:

falx cerebri

tentorium cerebelli

falx cerebelli

• Within all falxes and their attachments on the bones, there are passing sinuses

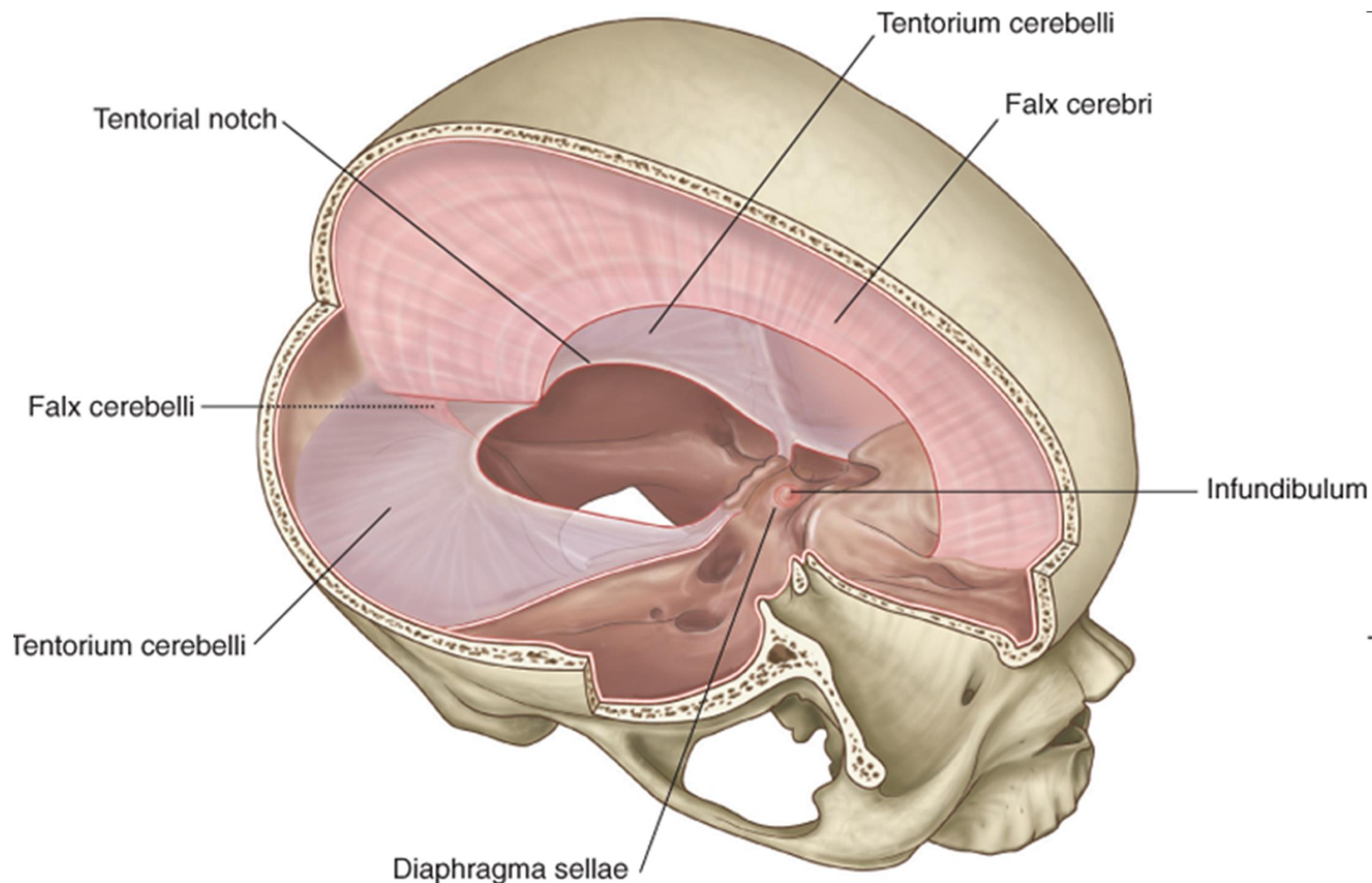


falx cerebri:

- Sickle-shaped fold
- It arises from the whole cranial vault in the median plane from frontal to occipital bone and permeates into fissura longitudinalis cerebri
- Along outer margin passes an important venous sinus (*sinus sagittalis superior*)
- Near inner margin of falx cerebri, there passes another venous sinus (*sinus sagittalis inferior*)

falx cerebelli:

- Smaller sickle-shaped fold, that is located in the median plane
- Is situated between cerebellar hemispheres
- Attached on crista occipitalis interna
- Within its attachment passes smaller venous sinus (*sinus occipitalis*)

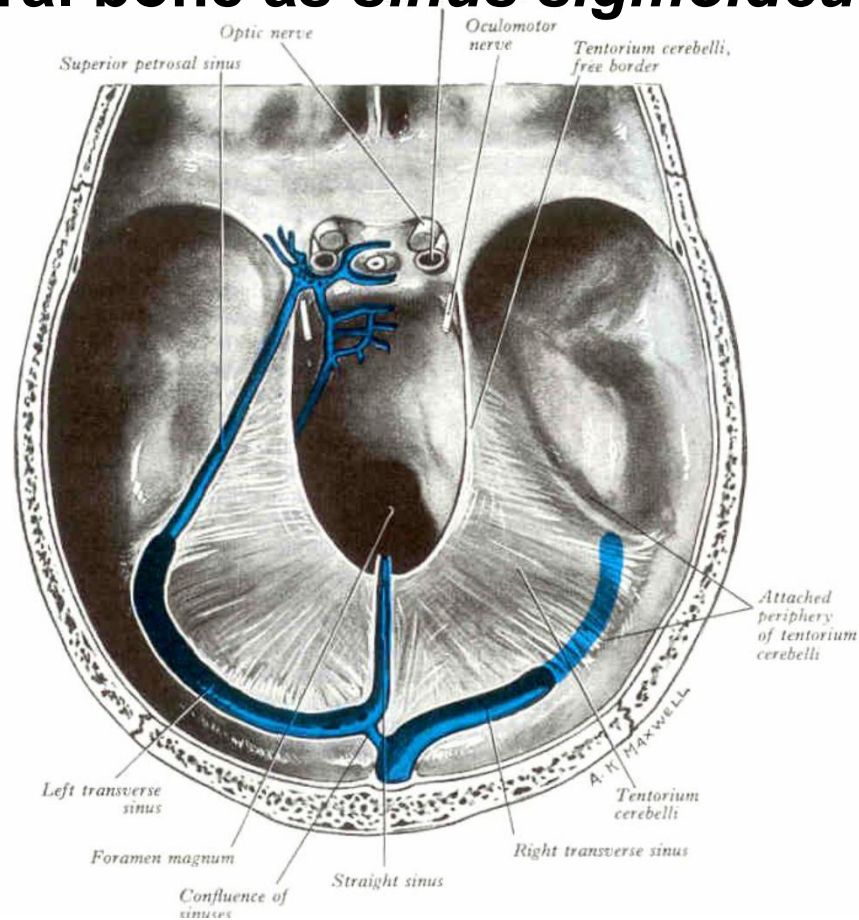


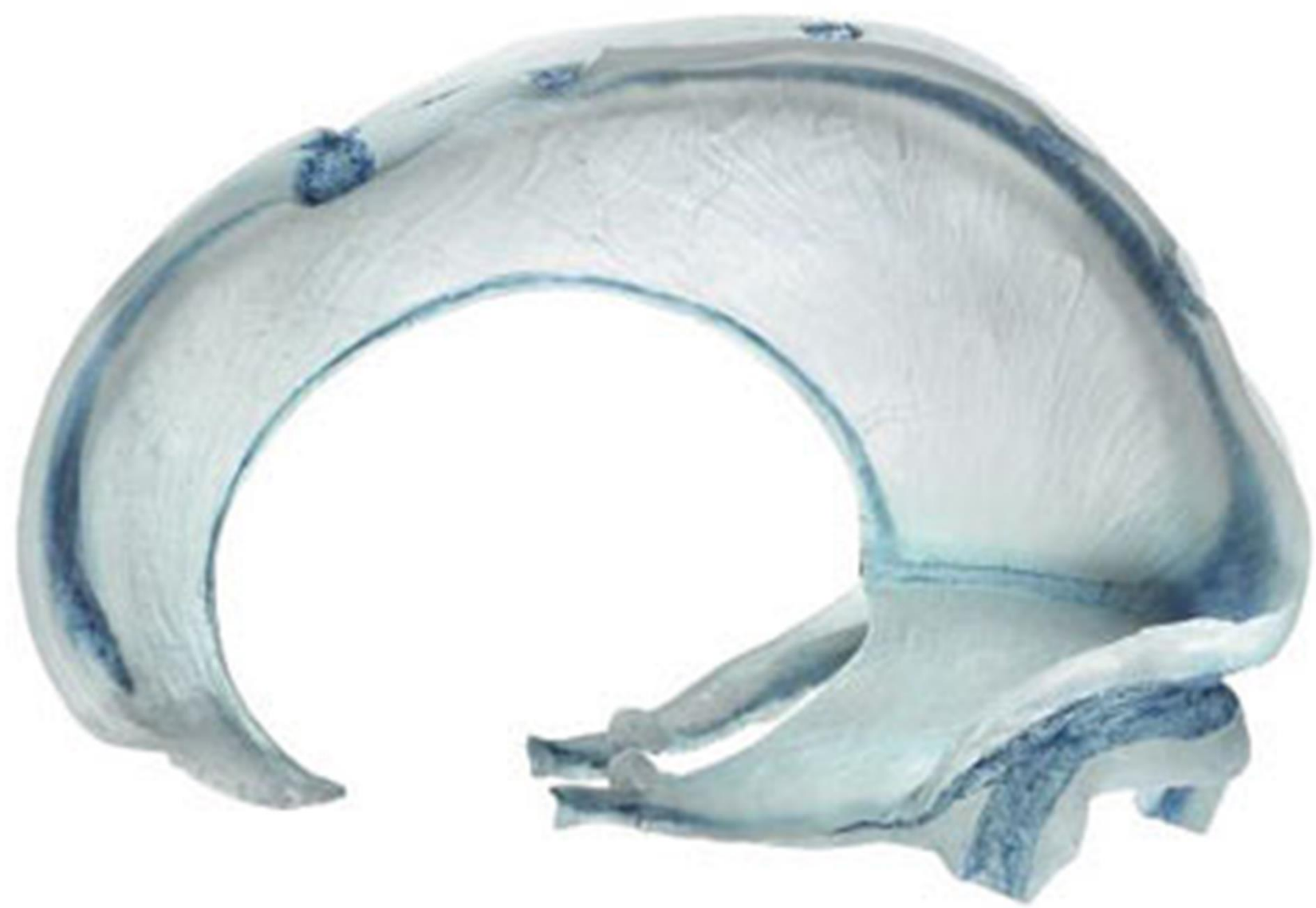Drake: Gray's Anatomy for Students, 2nd Edition.

Copyright © 2009 by Churchill Livingstone, an imprint of Elsevier, Inc. All rights reserved.

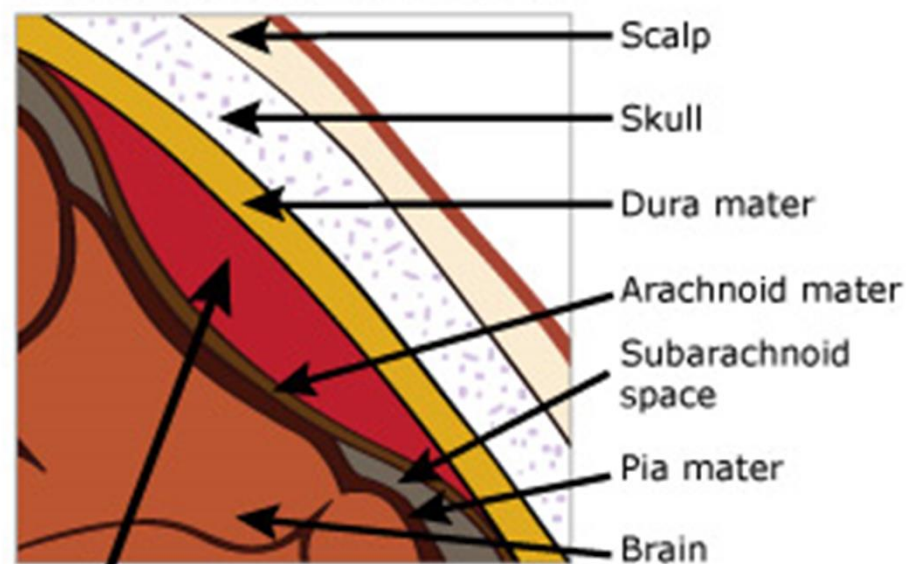
tentorium cerebelli: fold of dura mater

- It is located in transversal plane, enters fissura transversa cerebri (fissure that separates cerebellar hemispheres from cerebral hemispheres)
- It is attached on the margins of sulcus sinus transversi on occipital bone and within its attachment passes large venous sinus (*sinus transversus*) (it continues both sides onto temporal bone as *sinus sigmoideus*)



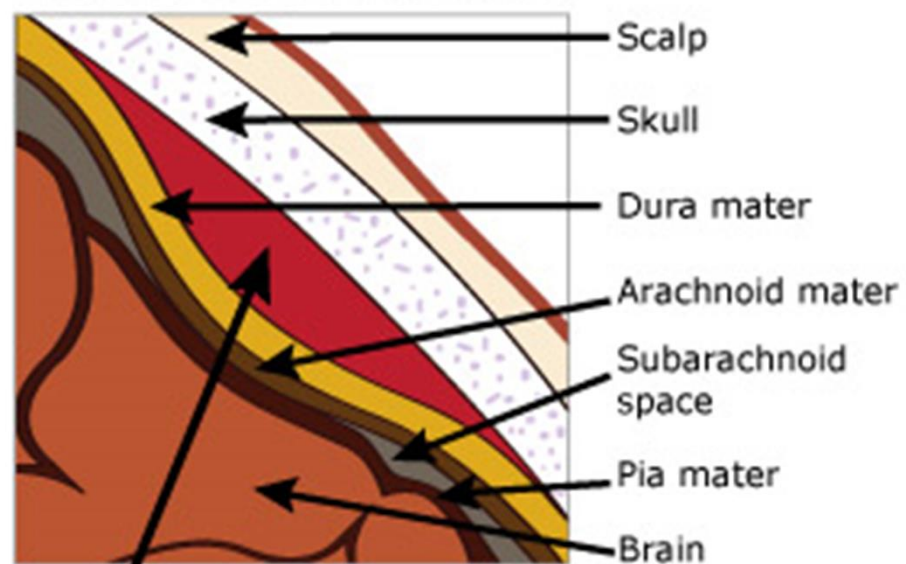


SUBDURAL HEMATOMA

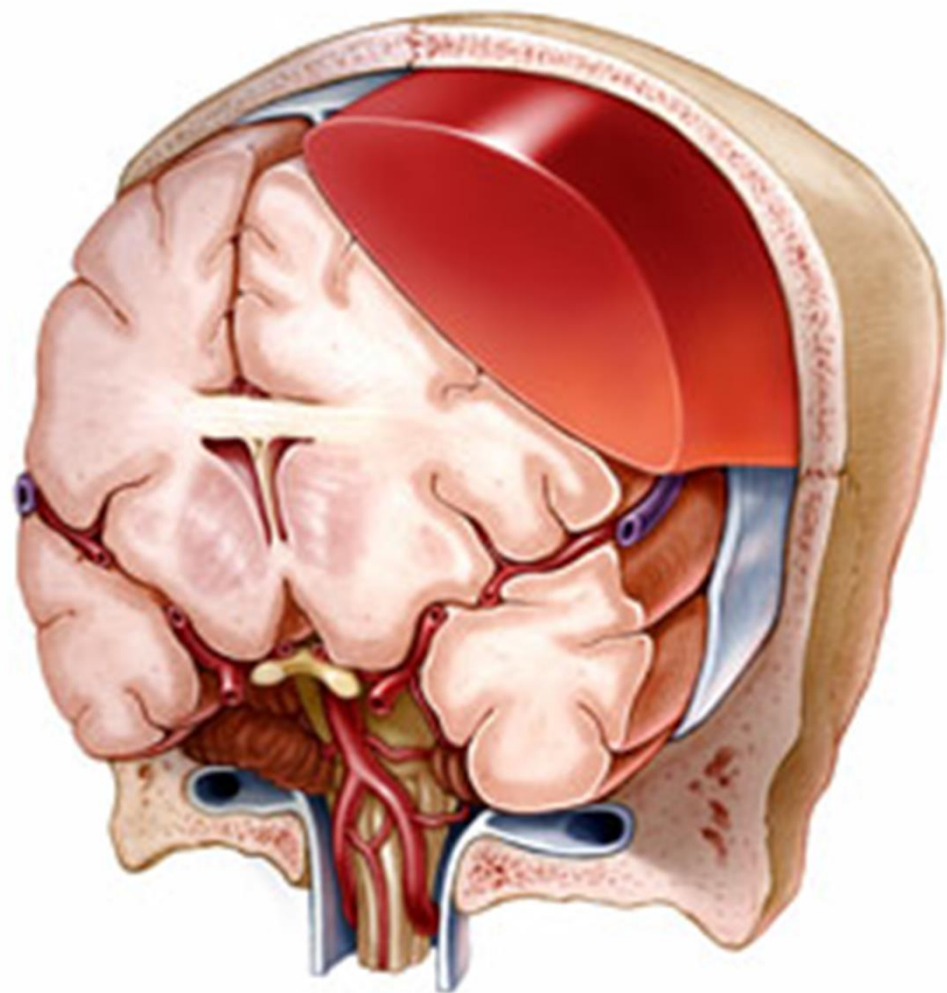


Bleeding into the space between the dura mater and the brain itself

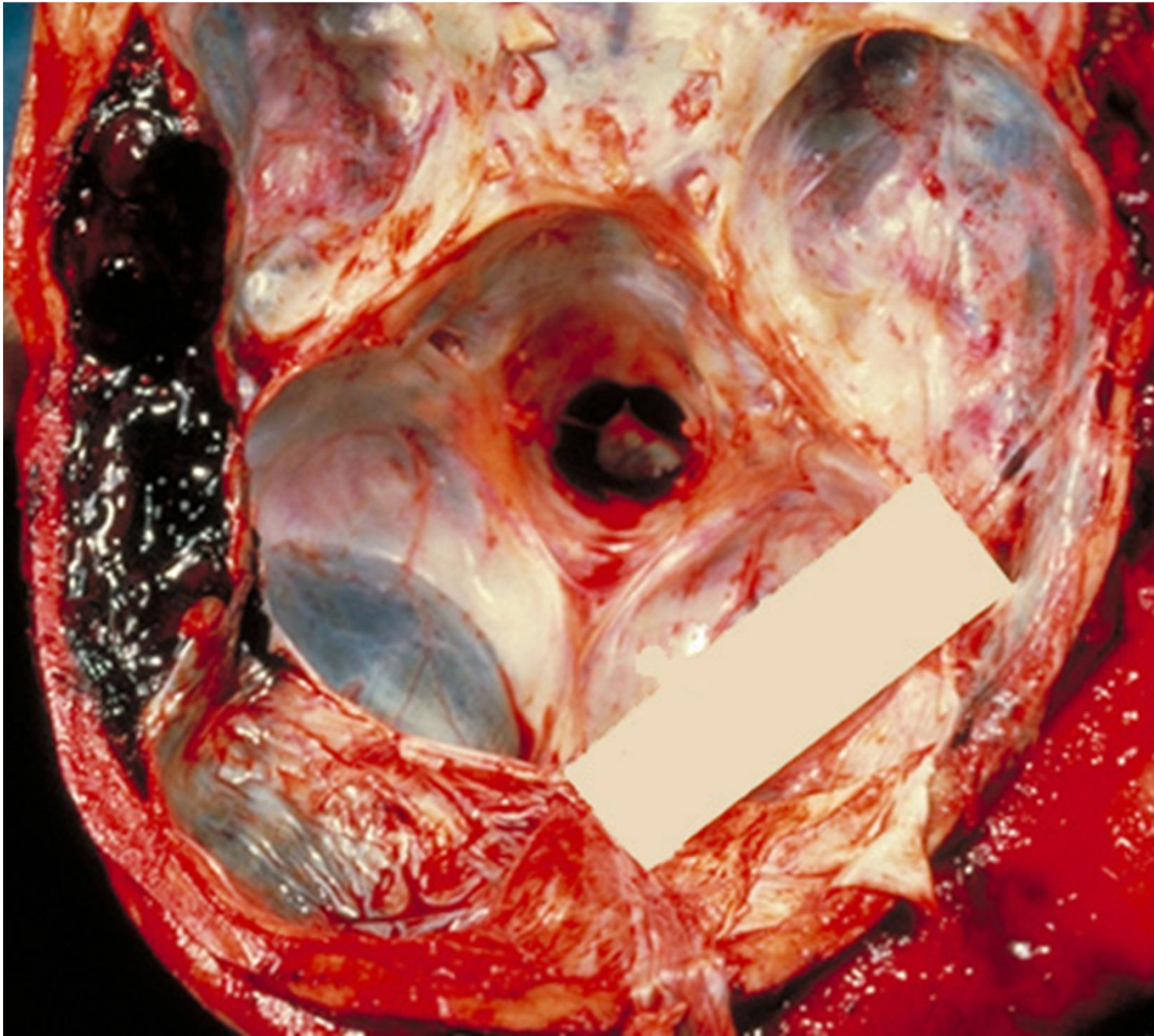
EPIDURAL HEMATOMA

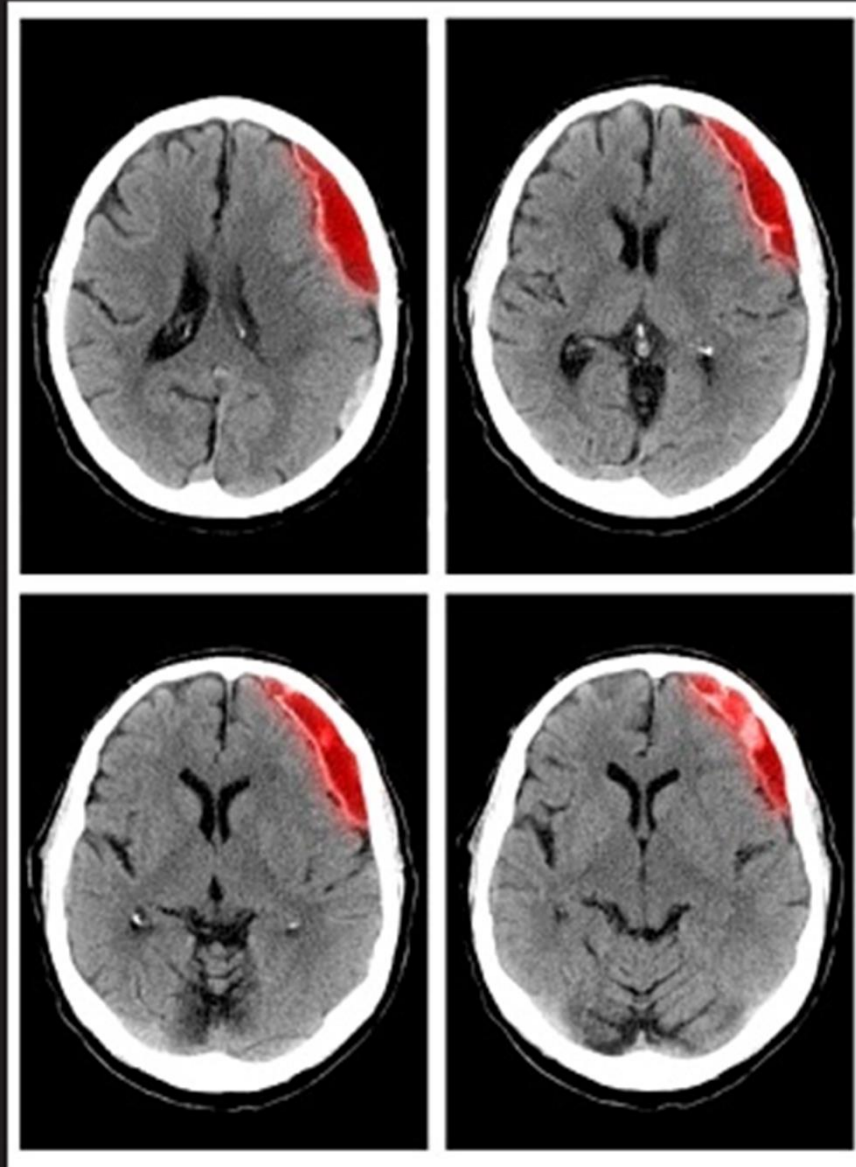


Bleeding into the space between the dura mater and the skull



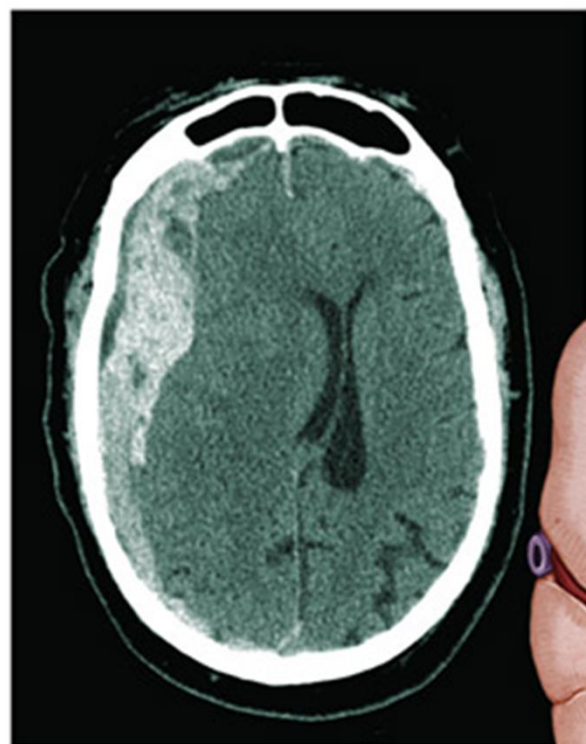
Epidural hematoma



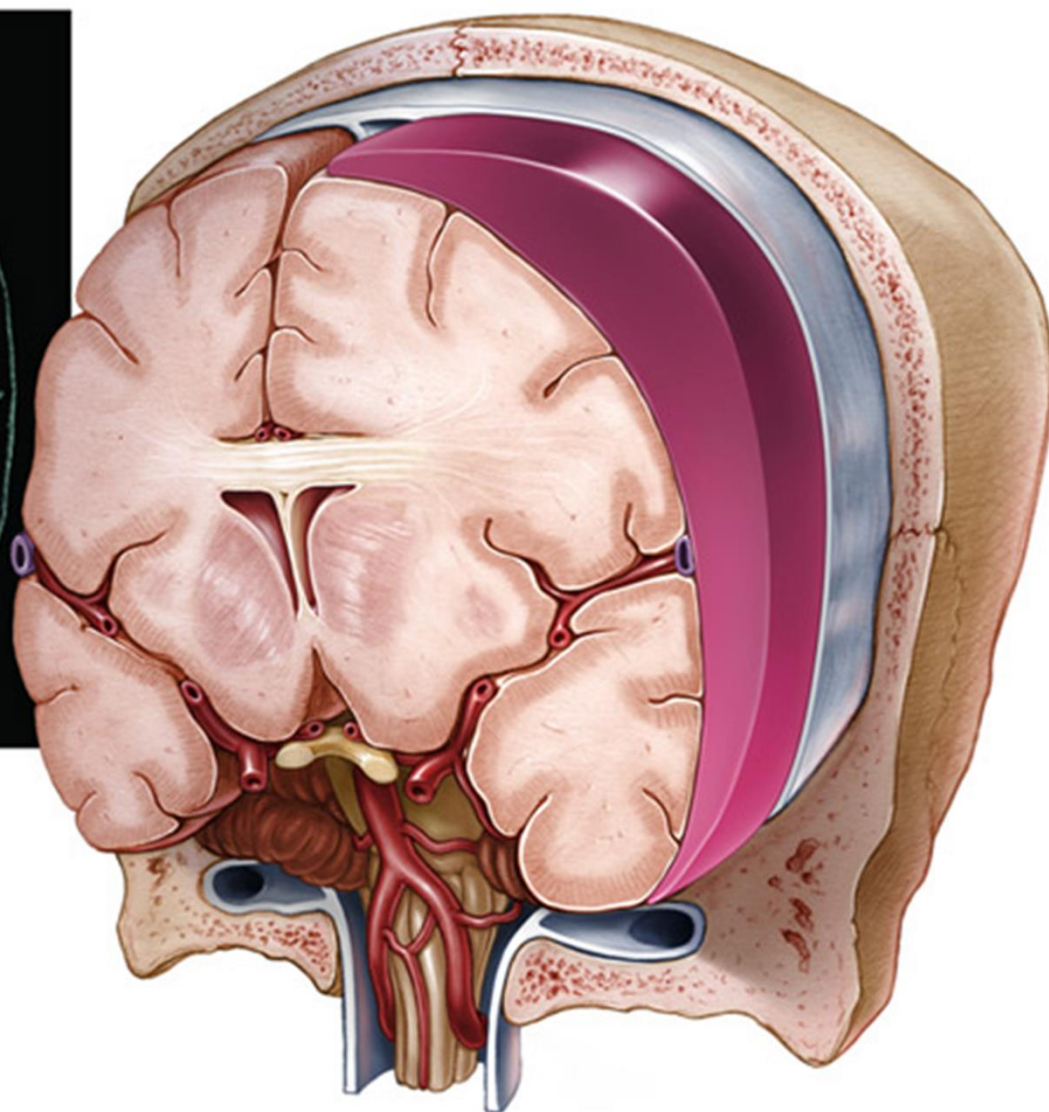


CT scan of the head with subdural hematoma

Subdural hematoma Illustration

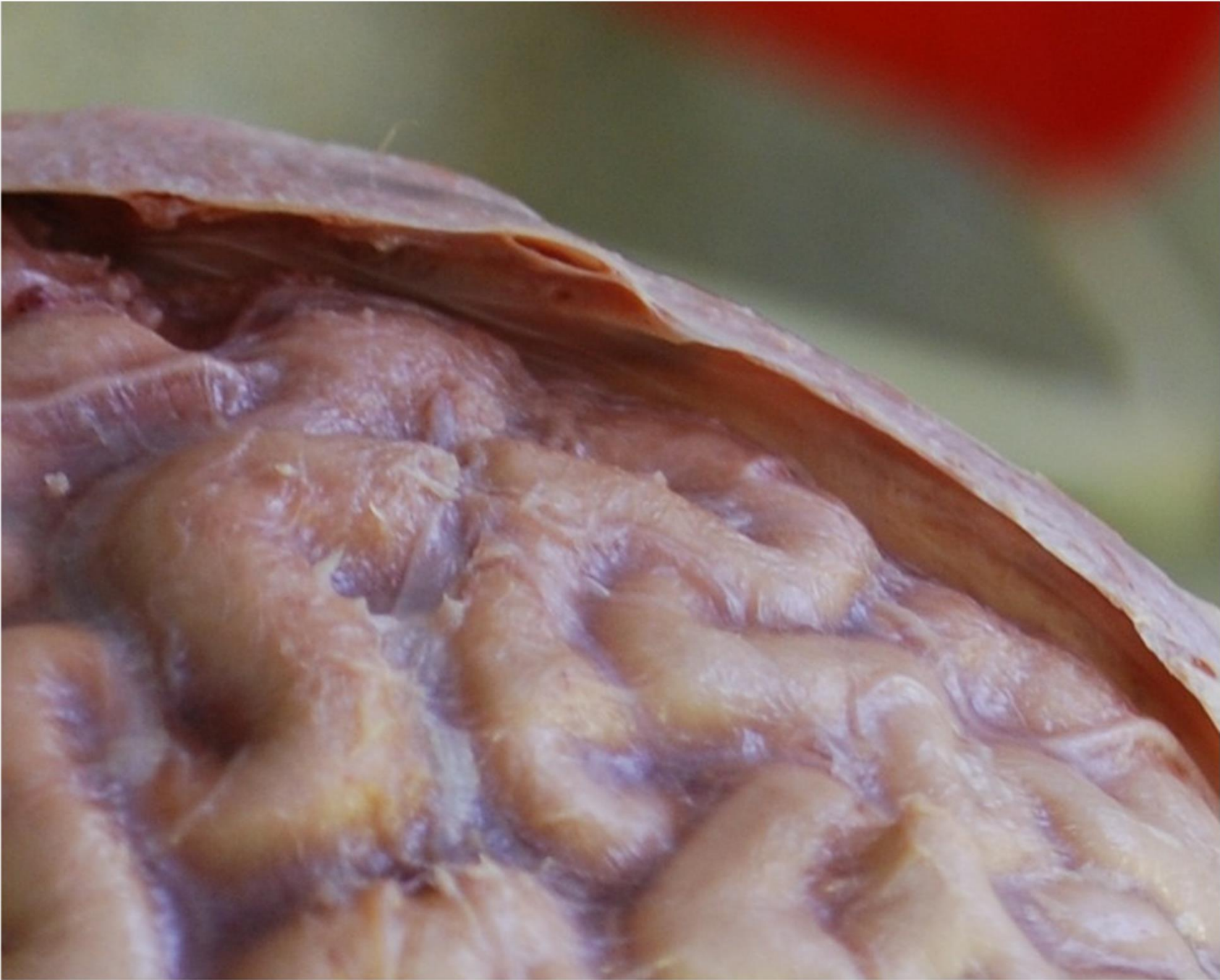

Epidural Hematoma



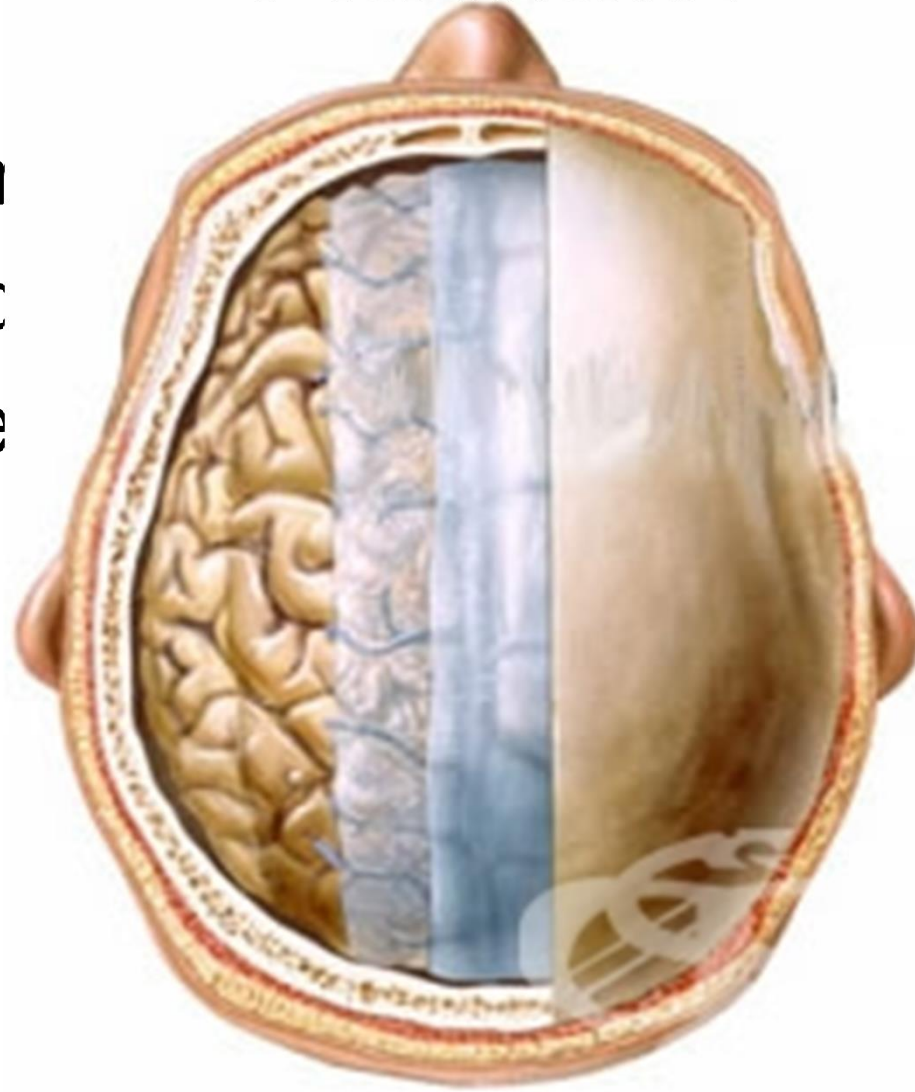
Arachnoid mater

- avascular membrane
- between dura mater and arachnoid-spatium subdurale
- between arachnoid and pia mater-spatium subarachnoideale (cerebrospinal fluid)
- it doesn't enter grooves and fissures



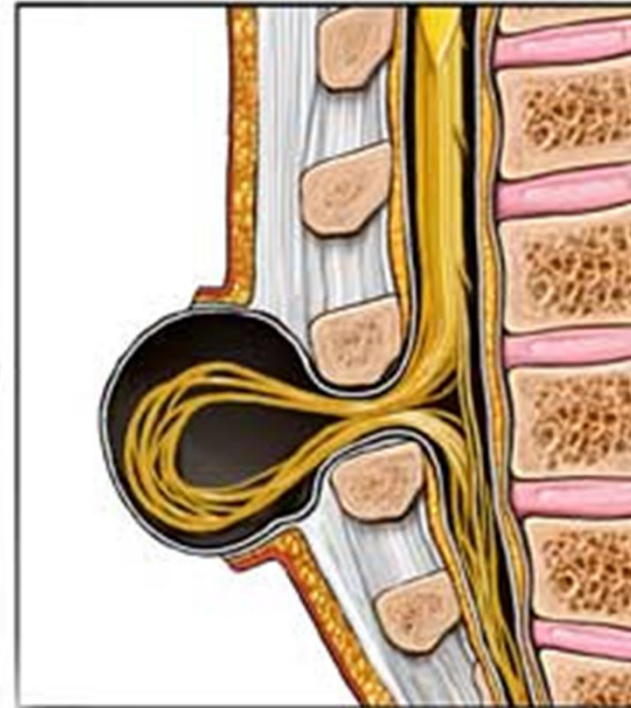
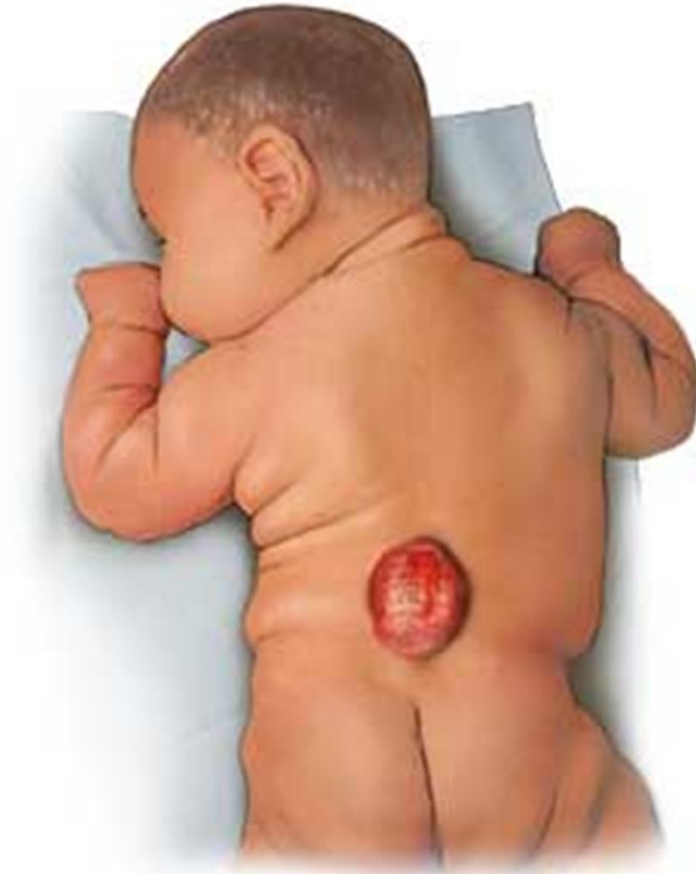Pia mater

- fibrous n
- it protruc
- it reache

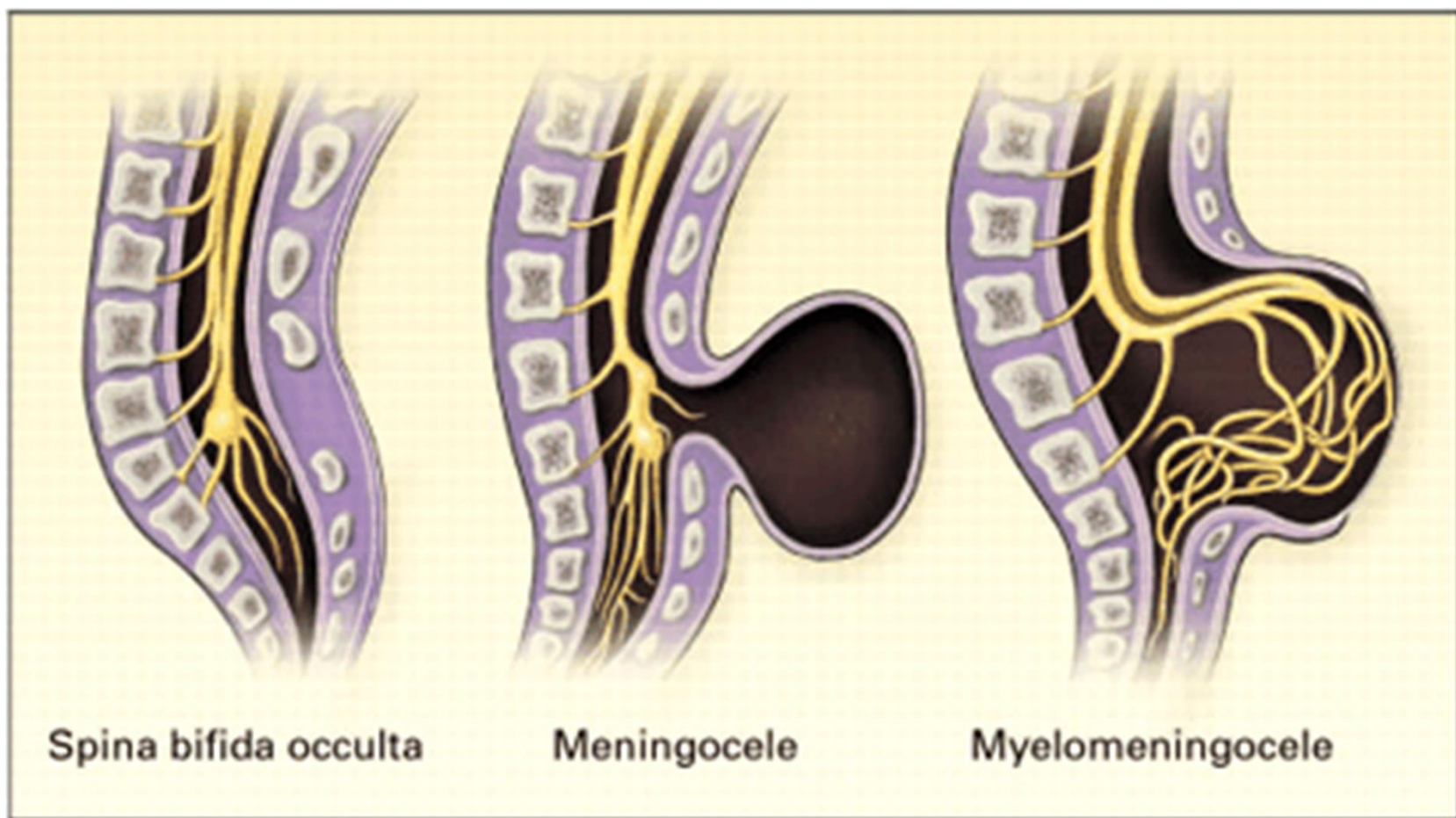


1 vessels
ssures

Spina bifida



Defect in vertebrae allows spinal nerves to protrude



Pictures:

Atlas der Anatomie des Menschen/Sobotta. Putz,R., und Pabst,R. 20. Auflage. München:Urban & Schwarzenberg, 1993

Netter: Interactive Atlas of Human Anatomy.

Naňka, Elišková: Přehled anatomie. Galén, Praha 2009.

Čihák: Anatomie I, II, III.

Drake et al: Gray's Anatomy for Students. 2010