

Malignant bone tumors

Pazourek L., Ondrůšek Š., Rozkydal Z.

Osteosarcoma

Malignant osteoid

Epidemiology

- 3 new cases /1 milion/ year
- 2. decade
- Metaphysis of long bones
 - 1/2 in knee region
 - distal femur
 - proximal tibia
 - proximal humerus

Classification

- Primary

- Central

- High-grade

- Conventional high-grade (80 – 90%)

- Osteoblastic

- Chondroblastic

- Fibroblastic

- Telangiectatic

- Low-grade

Peripheral

High-grade

Low-Grade

Parosteal

Periostal

- Secondary

- in Paget's disease of bone
- post radiation

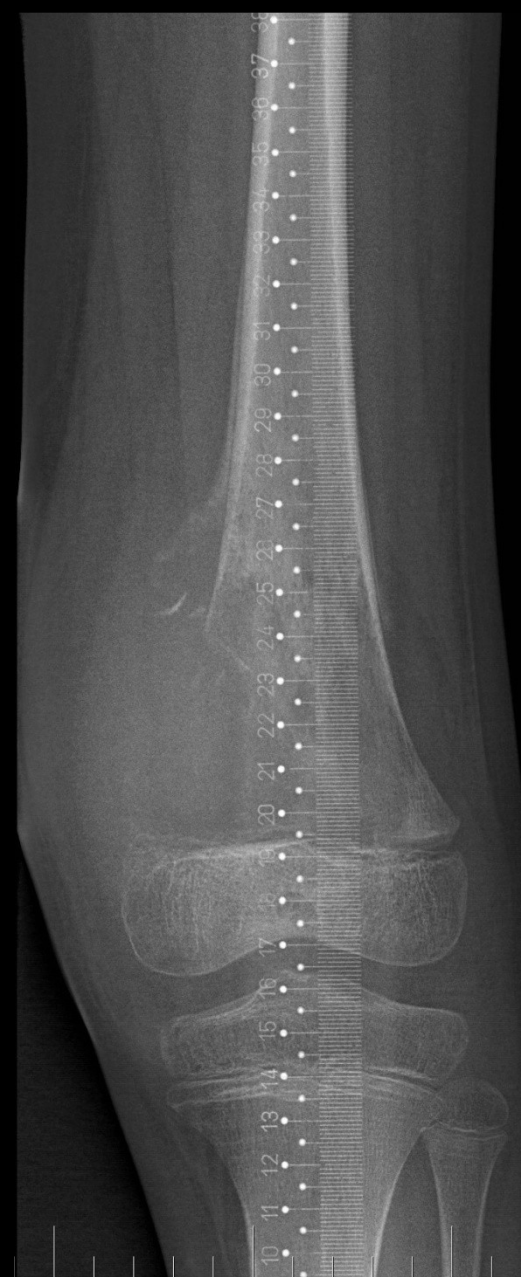
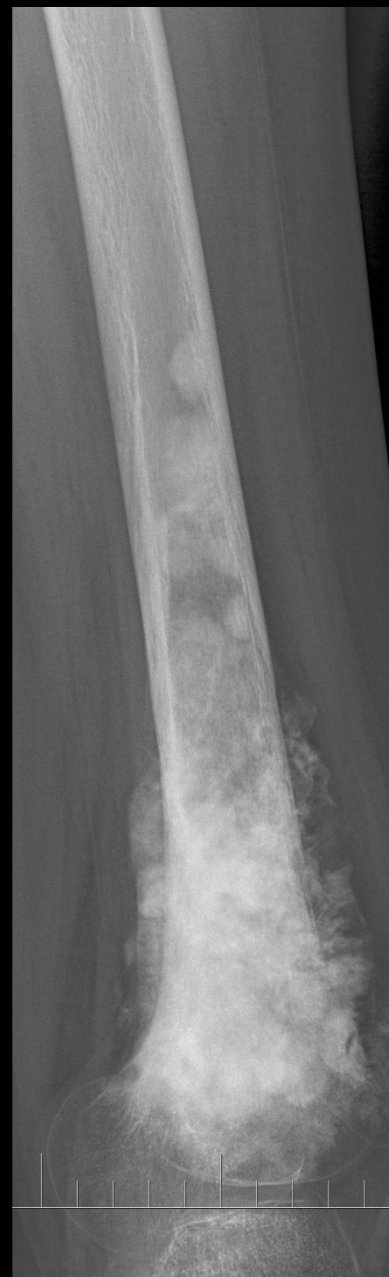
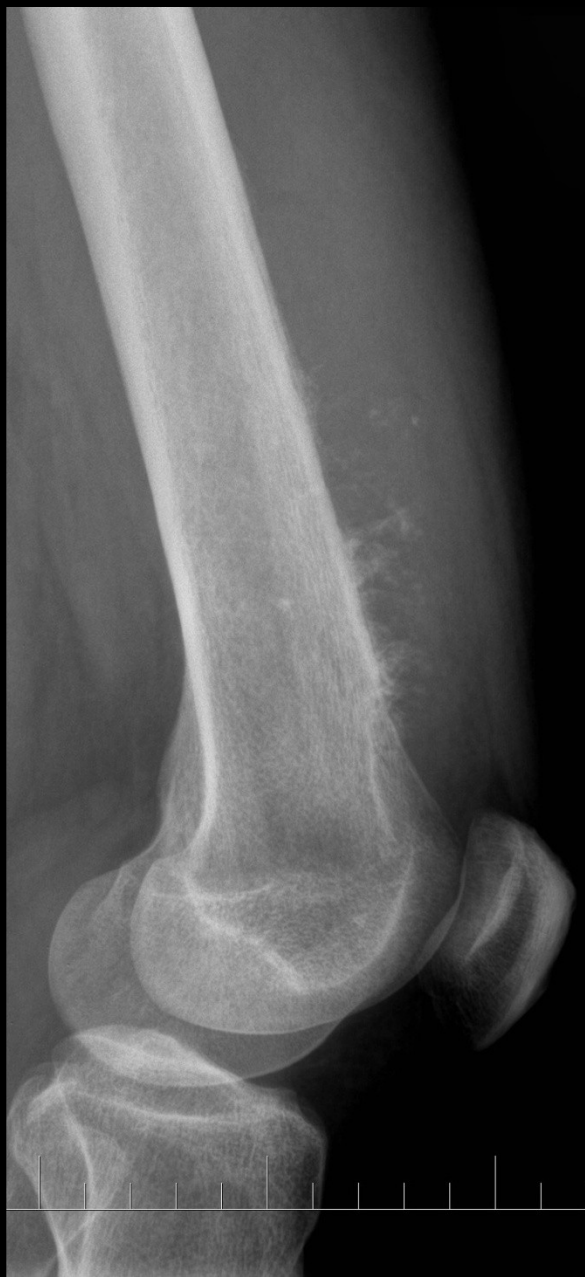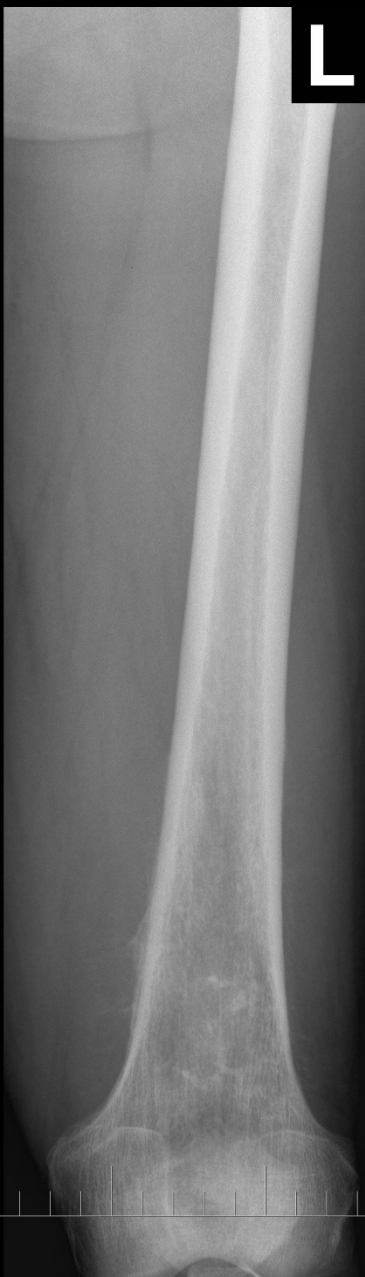Symptoms

- pain
 - during night, in rest
- swelling
- pathological fracture
- metastases in the time of diagnosis
 - in 10-25 % of patients

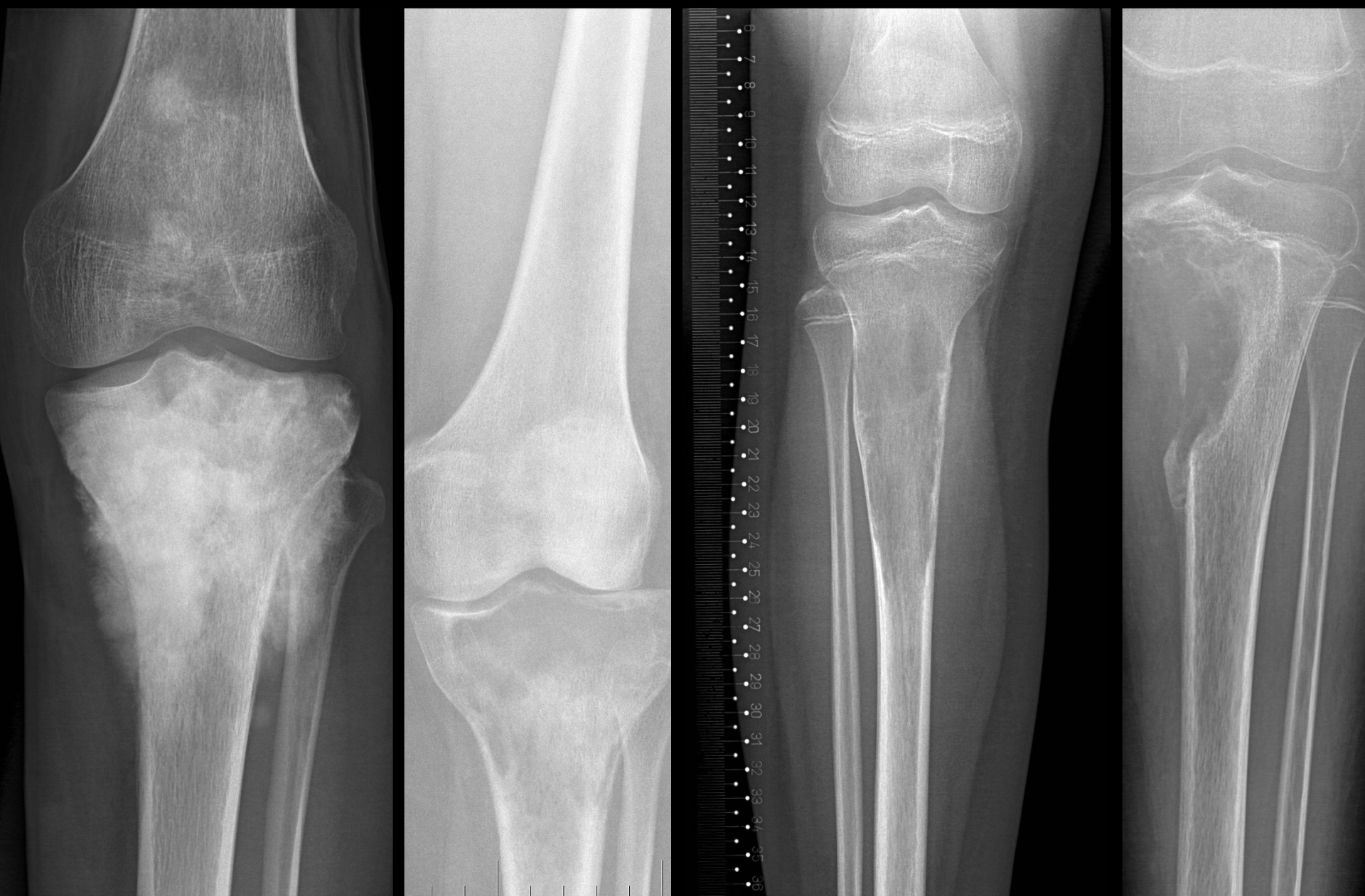Diagnostics

- X-ray
- CT / MRI
- Scintigraphy
- Chest X- ray or spiral CT
- Ultrasonography
- Biopsy – excisional, needle

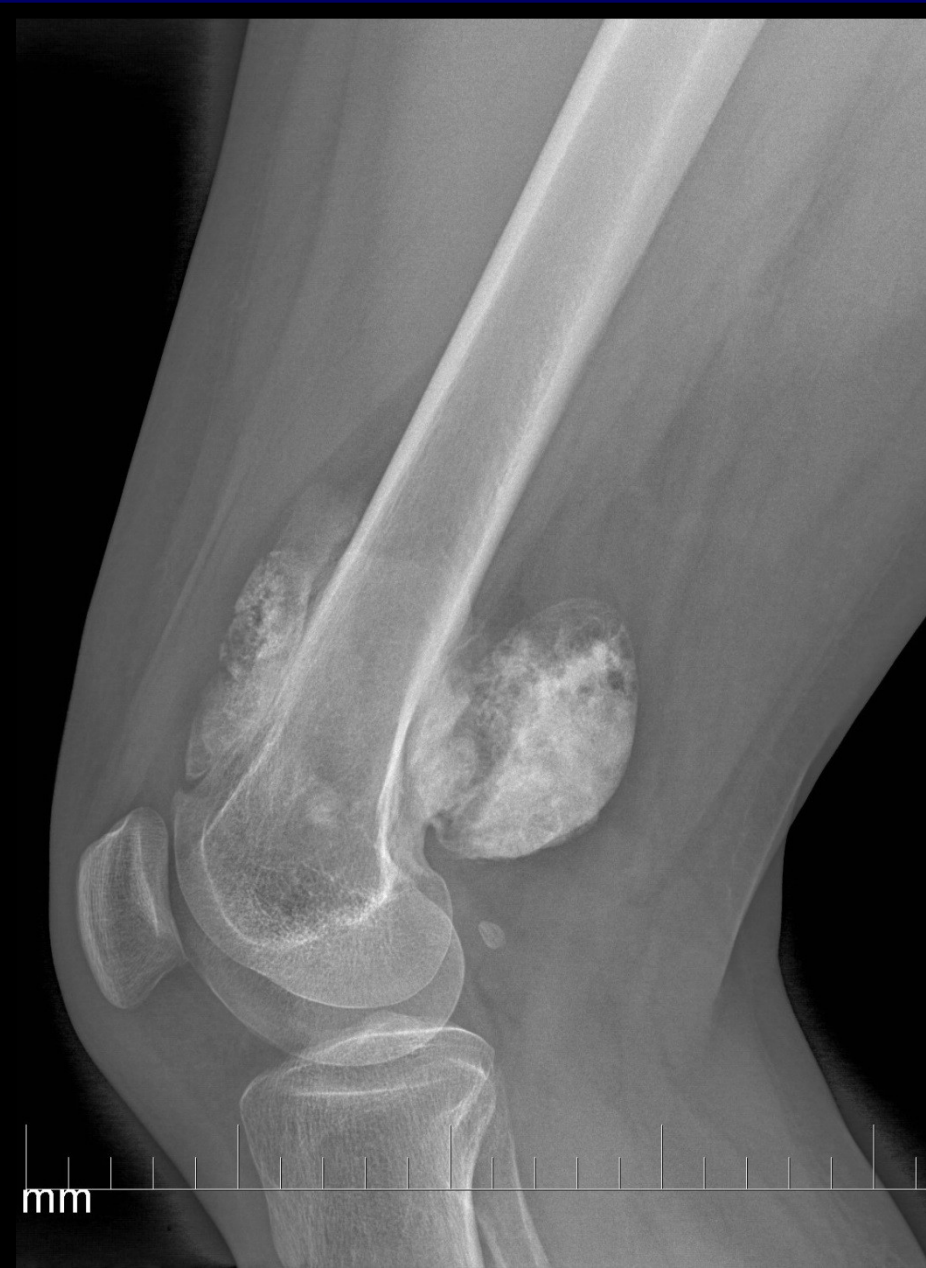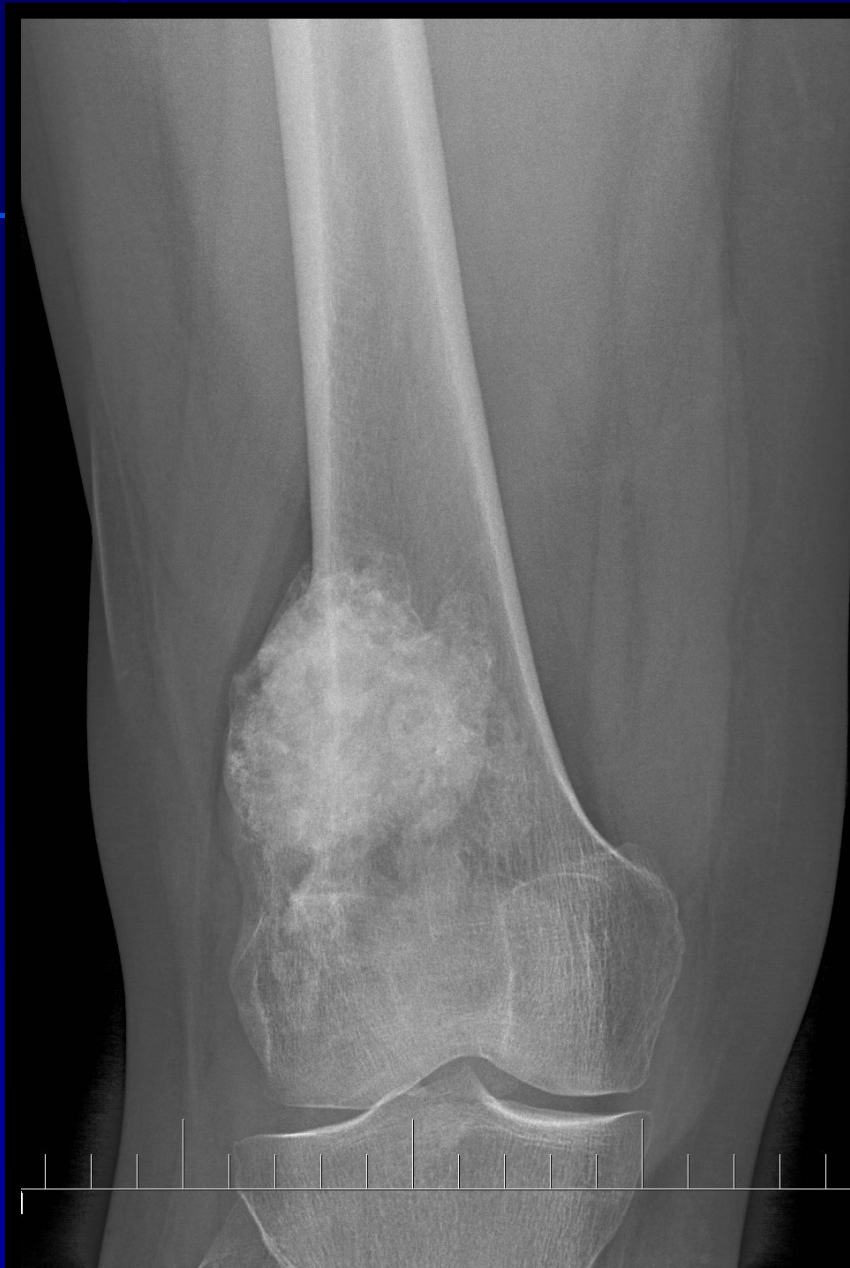Conventional osteosarcoma



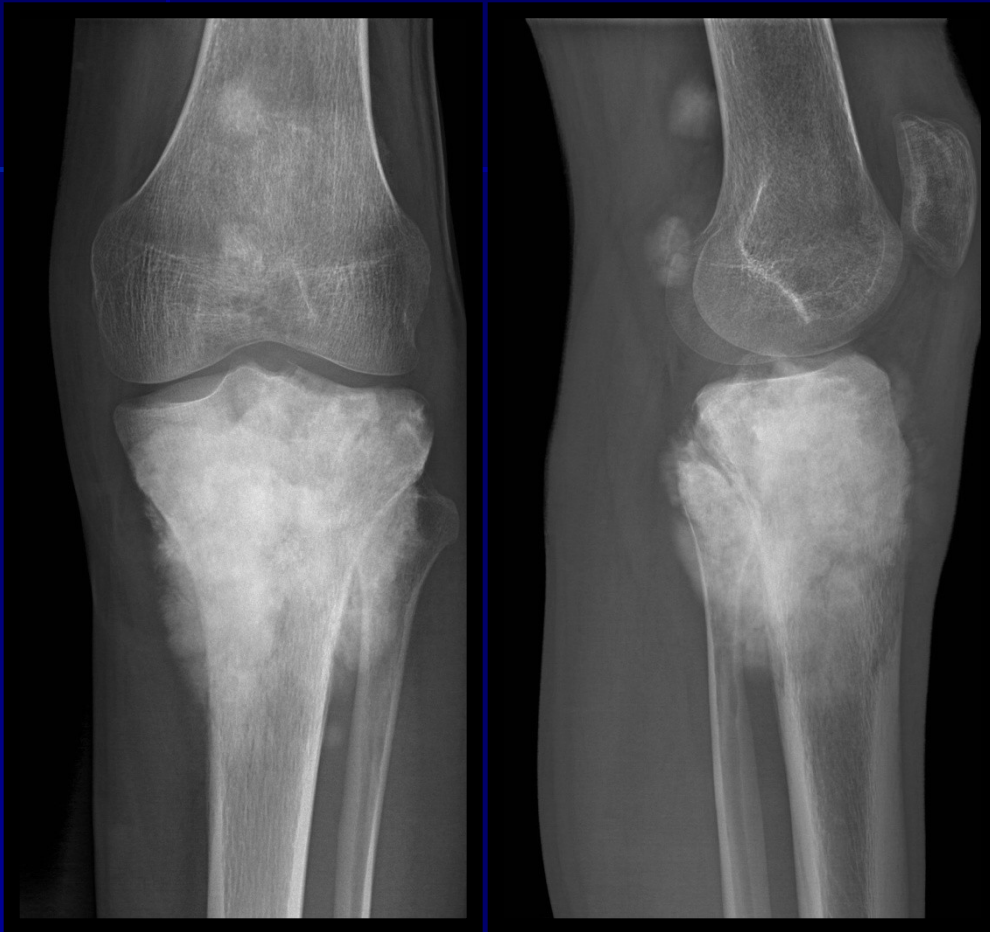
Conventional osteosarcoma



Parosteal osteosarcoma



OSA



- Missed case
- Wrong prognosis

Oncologic reflex

Therapy

- neoadjuvant chemotherapy
- surgery – radical resection / amputation
- adjuvant chemotherapy
- Metastasectomy in lungs

- Chemotherapy: (EURAMOS protocol)
 - metotrexat, doxorubicin, adriamycin, cisplatina, ifosfamid, etoposid.
- In low-grade OSA – only surgical treatment

- OSA is a radioresistant tumor

Prognostic factors

- Metastases
- Size of the tumor
- Axial localisation
- Radicality of surgery
- Response to chemotherapy

Prognosis

– 5 years survival

- 70% - conventional high-grade OSA without MTS and with good response to chemotherapy (to 10 % of vital tumor cells)
- 90% - u low-grade OSA after radical surgery

Chondrosarcoma

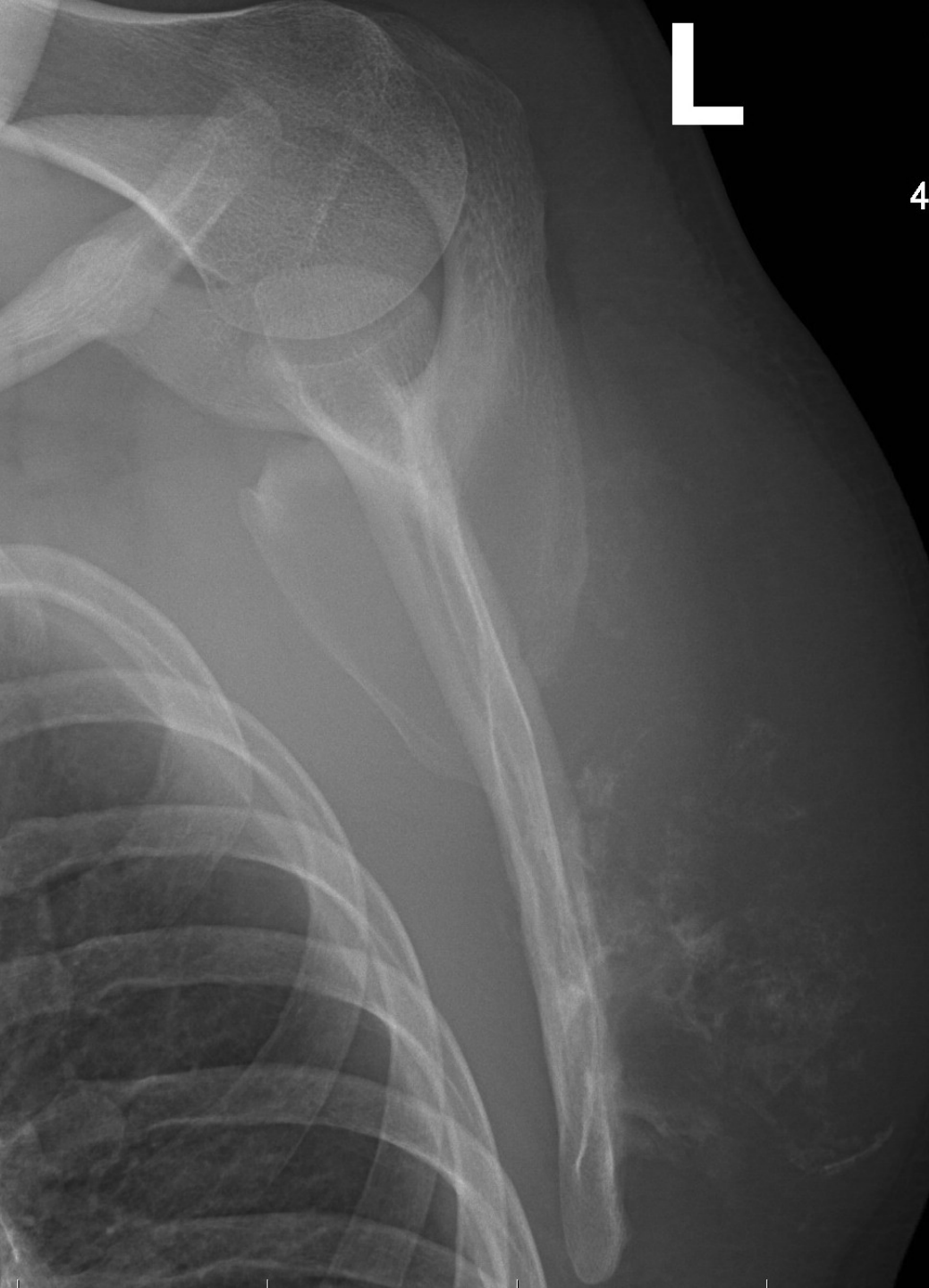
Epidemiology

- 10% of primary malignant bone tumors
- Age:
 - primary: 40 – 60 years
 - secondary: 25 – 45 years
- Localisation-
pelvis, proximal femur, proximal humerus

Etiology

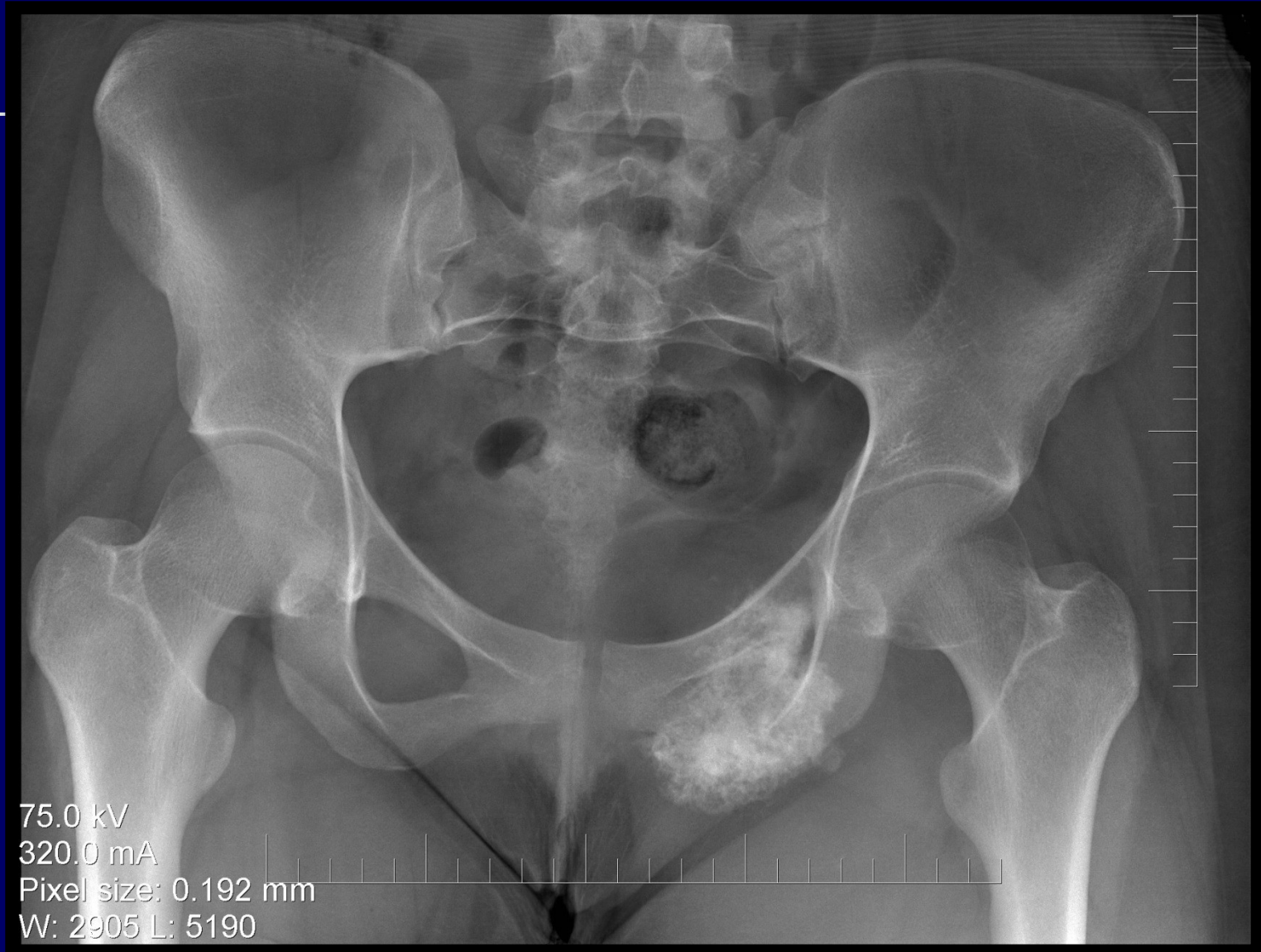- **Secondary**

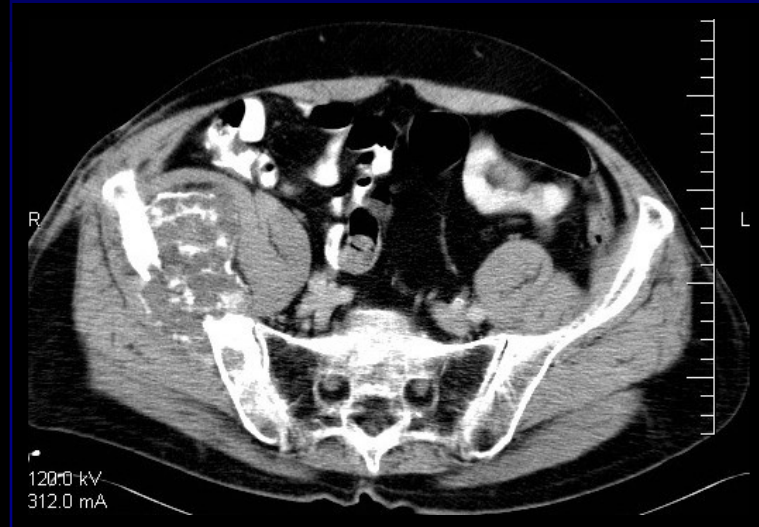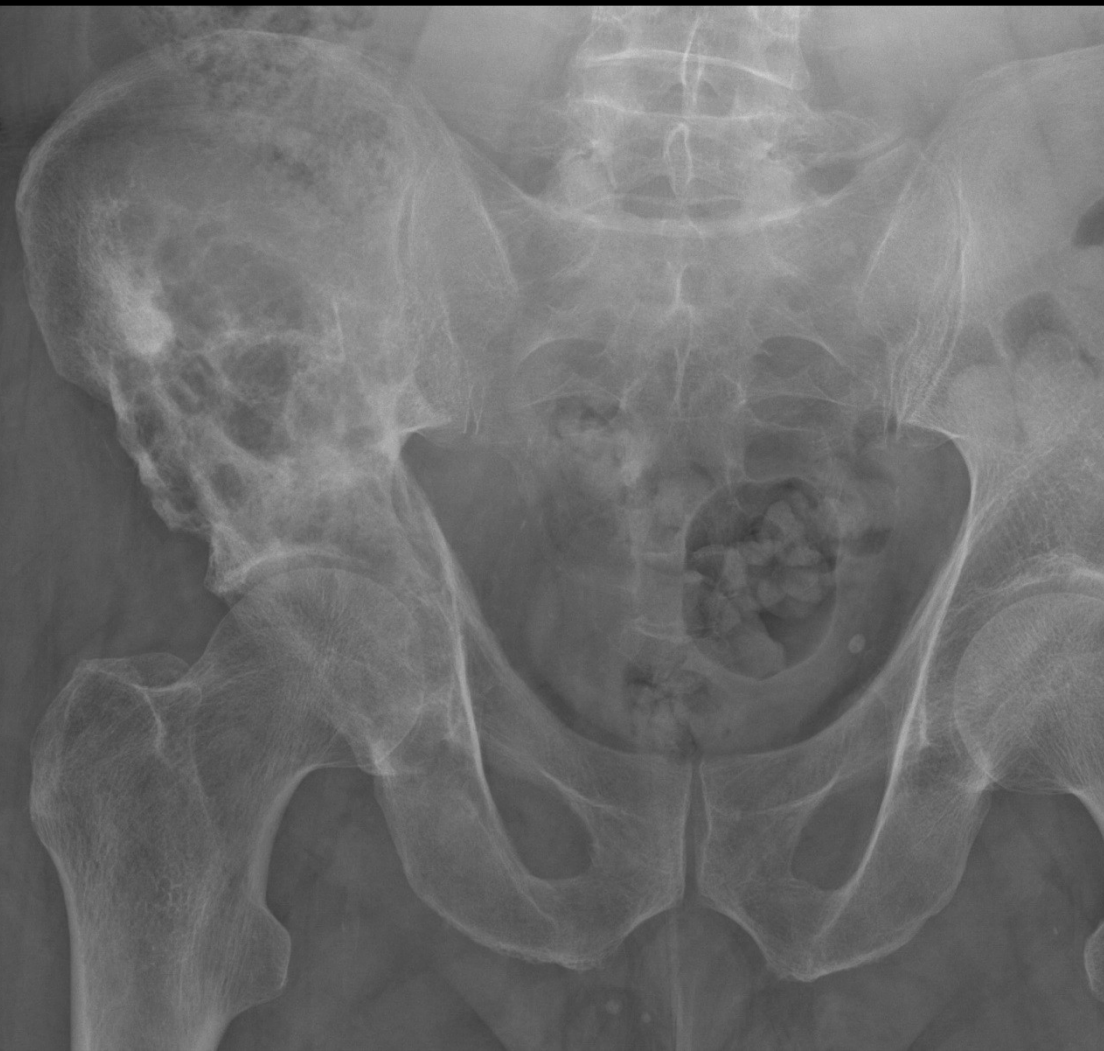- **Multiple enchondromas** (M.Ollier, Maffucci sy)
- **Exostosis disease**
cartilage over 2 cm
- **Chondroblastoma, chondromyxoid fibroma ...**



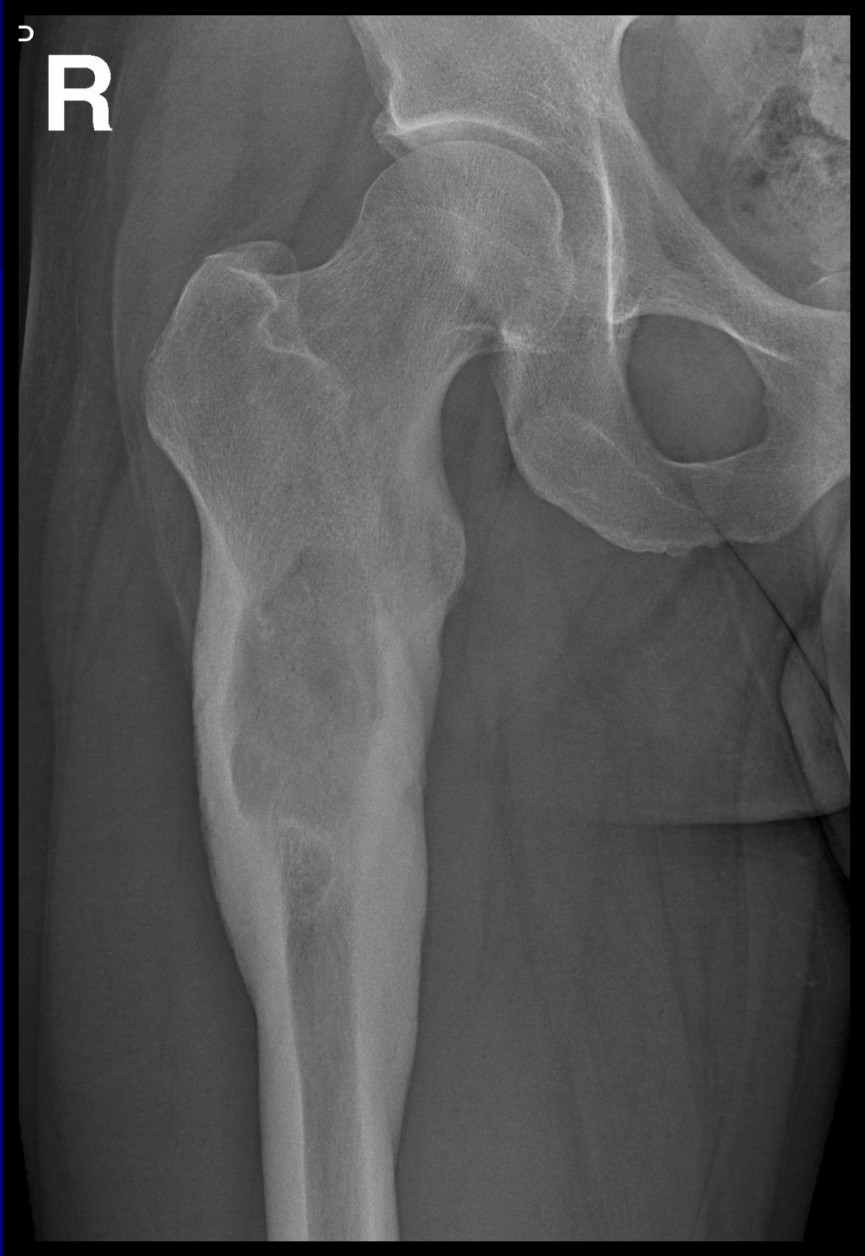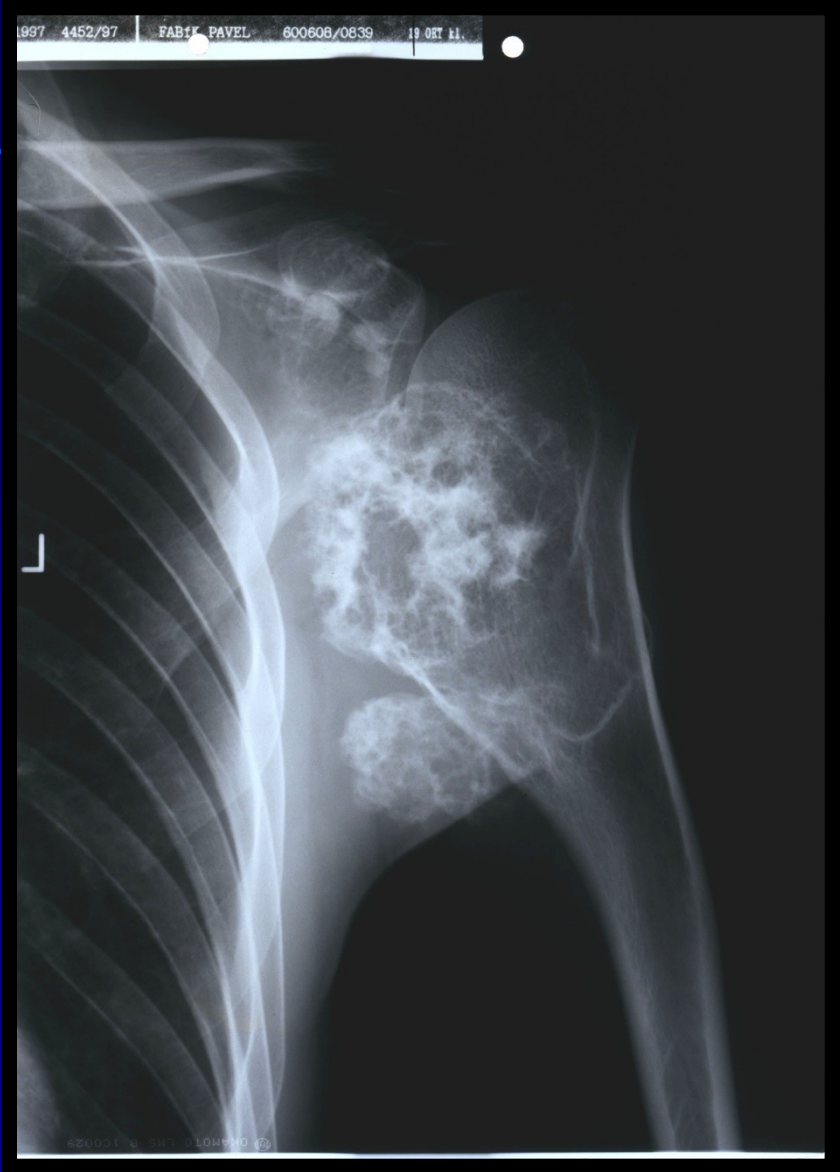
Calcifications

Chondrosarcoma

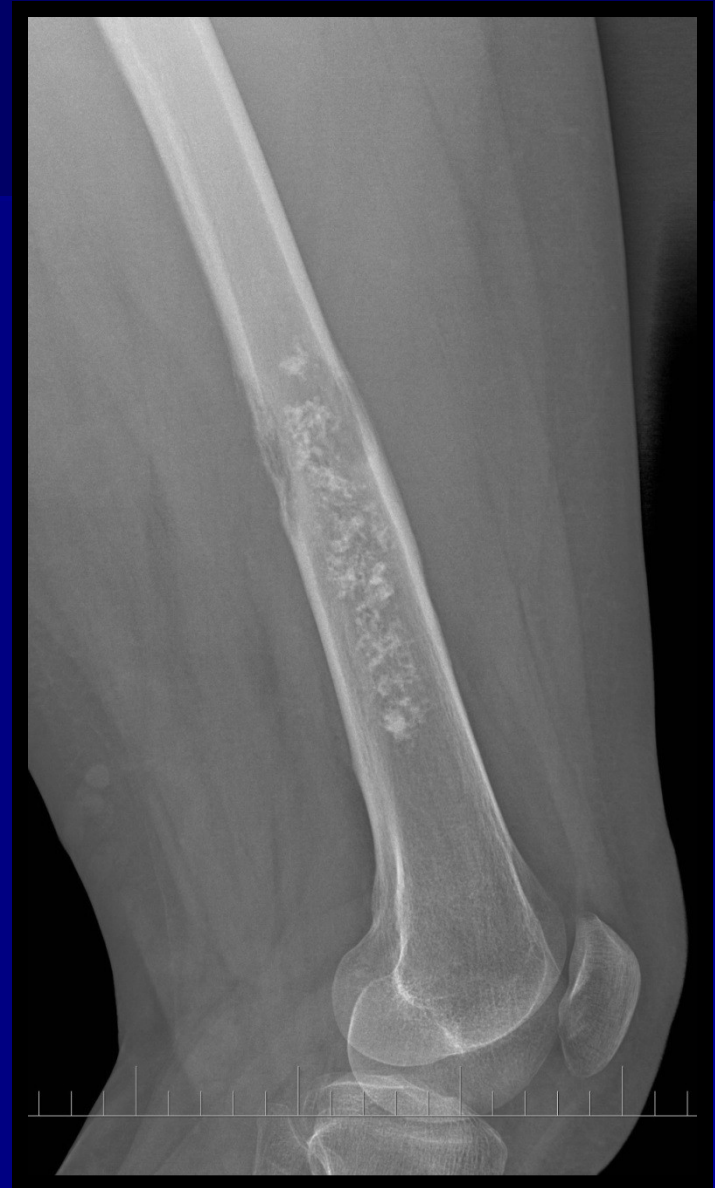
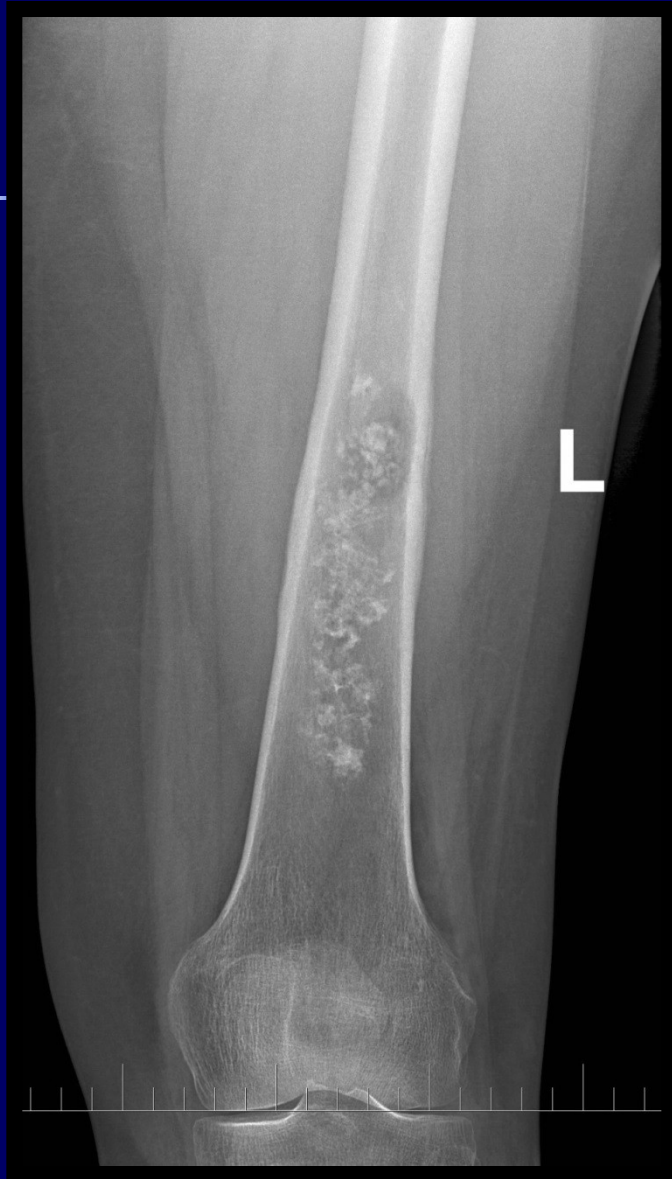


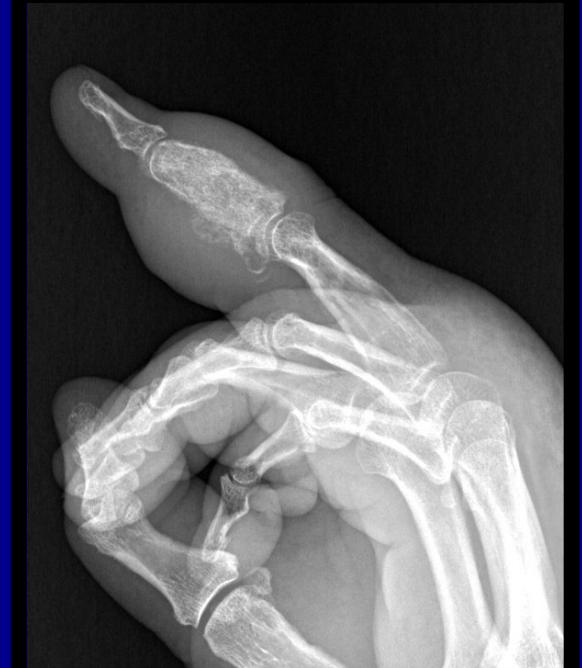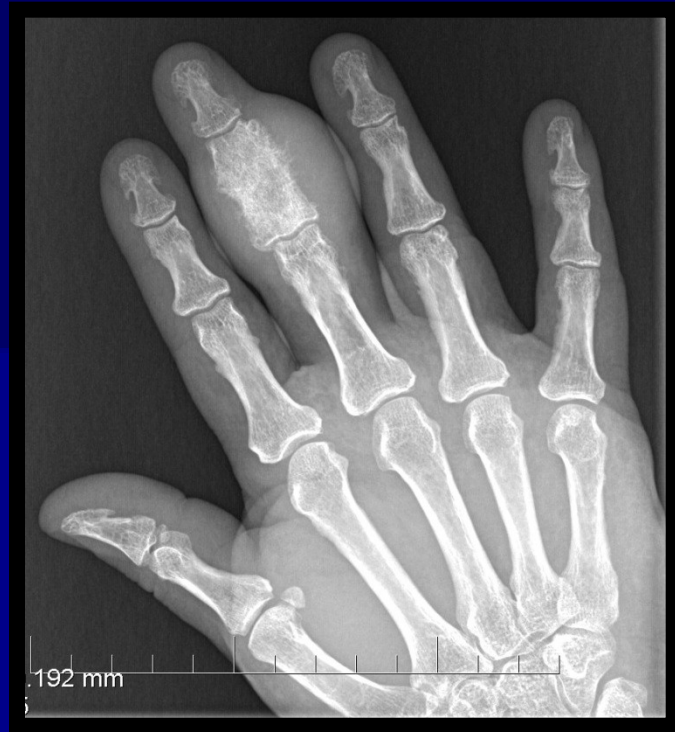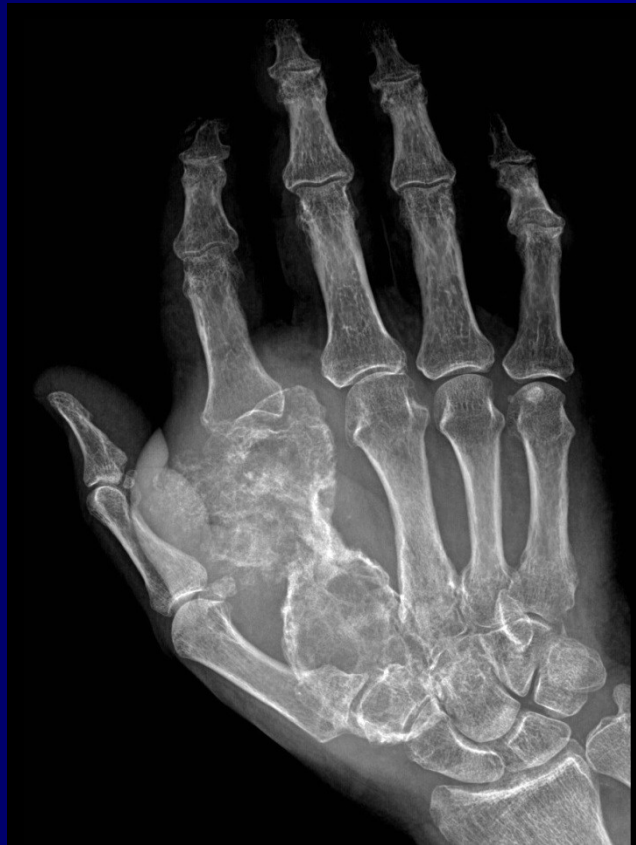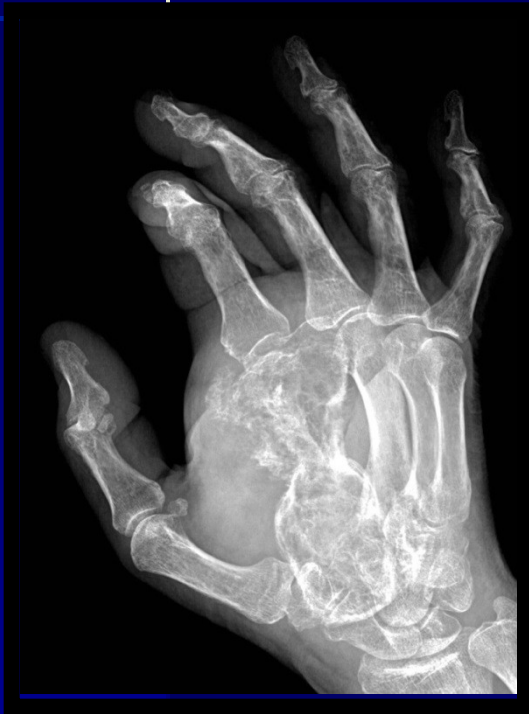Chondrosarcoma



Chondrosarcoma



Chondrosarcoma



Therapy

- Radical resection – wide resection, amputation
- Metastasectomy in lungs
- Chemoresistant tumor
- Radioresistant tumor

Prognosis

- **Prognostic factors:**
 - Radicality of surgery
 - Size
 - Histological grading
- **In intralesional surgery – 90% risk of local recurrence and lung metastases**
- **Prognosis:**
 - Conventional low-grade 90% 10 years
 - Conventional high-grade 20-40% 10 years
 - Dediferenciated sarcoma 15% 5 years

Ewing sarcoma family

Group of high grade malignant round cells bone tumors with neuroectodermal differentiation and specific translocation.

- Ewing sarcoma
- PNET (periferal neuroectodermal tumor)
- Askin tumor of the chest wall
- Neuroblastoma in adults

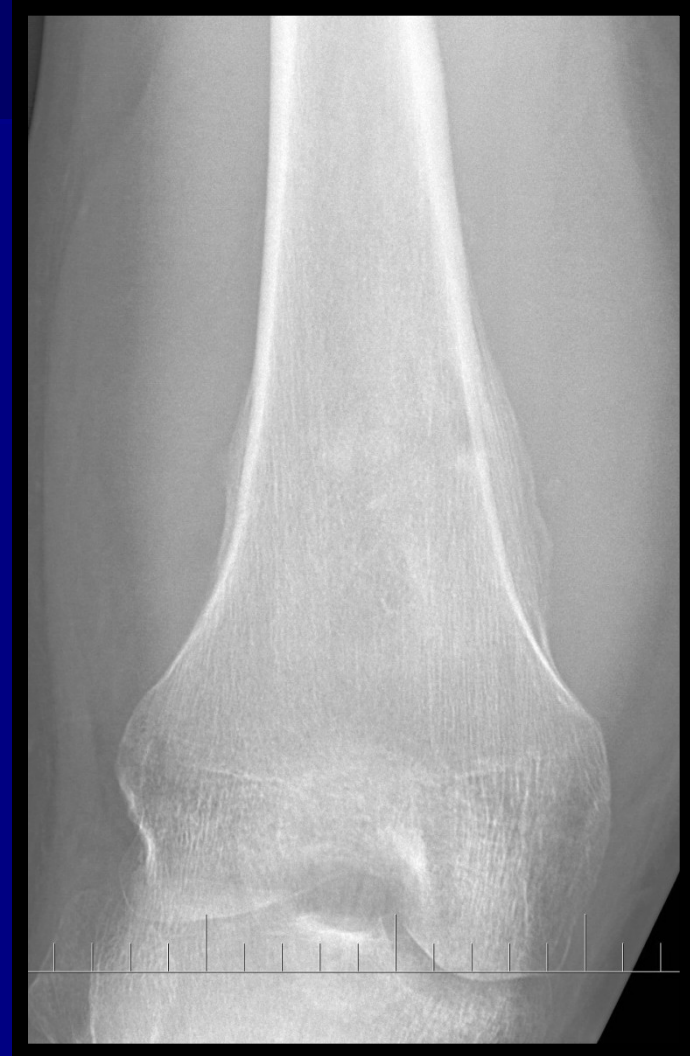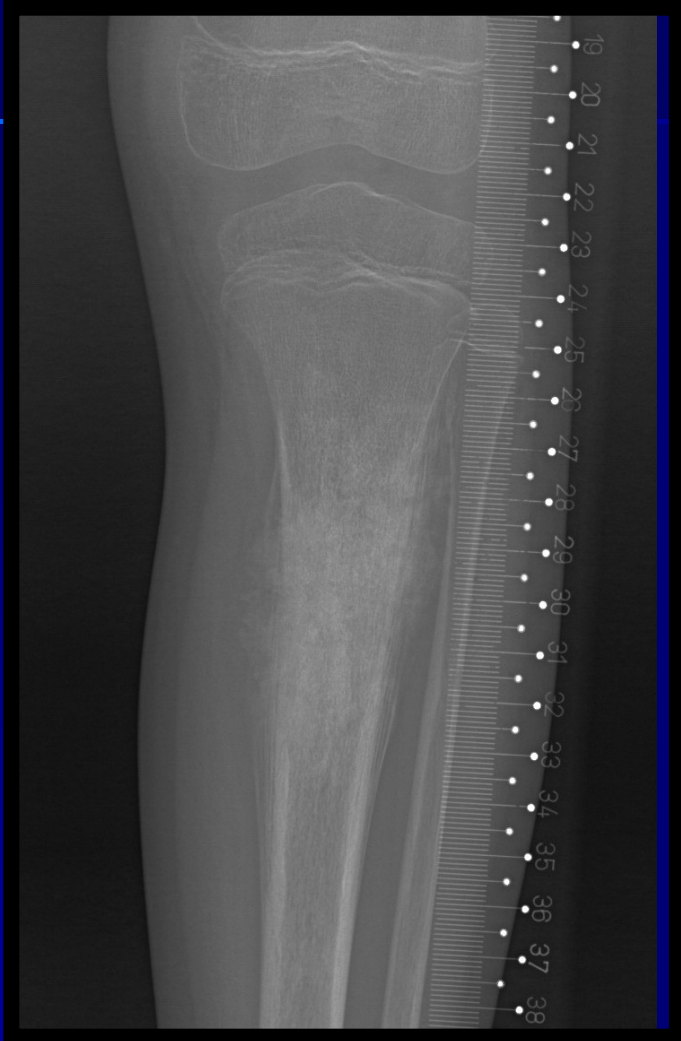Epidemiology

- One new case /1 mil./ 1 year
- 5-25 years
- In metaphysis of long bones with extension into diaphysis and in flat bones (pelvis, scapula)

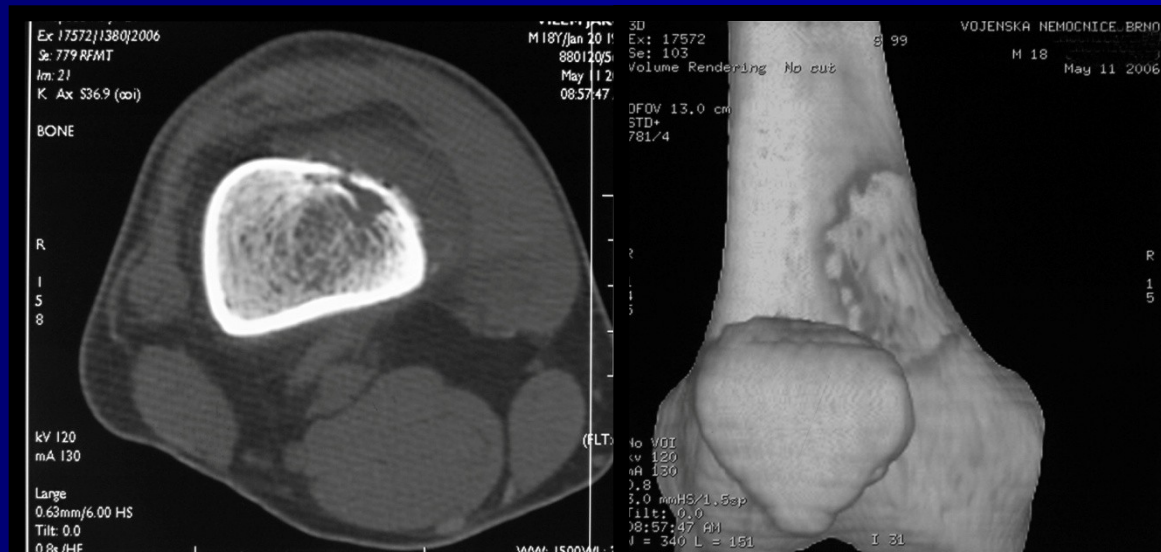
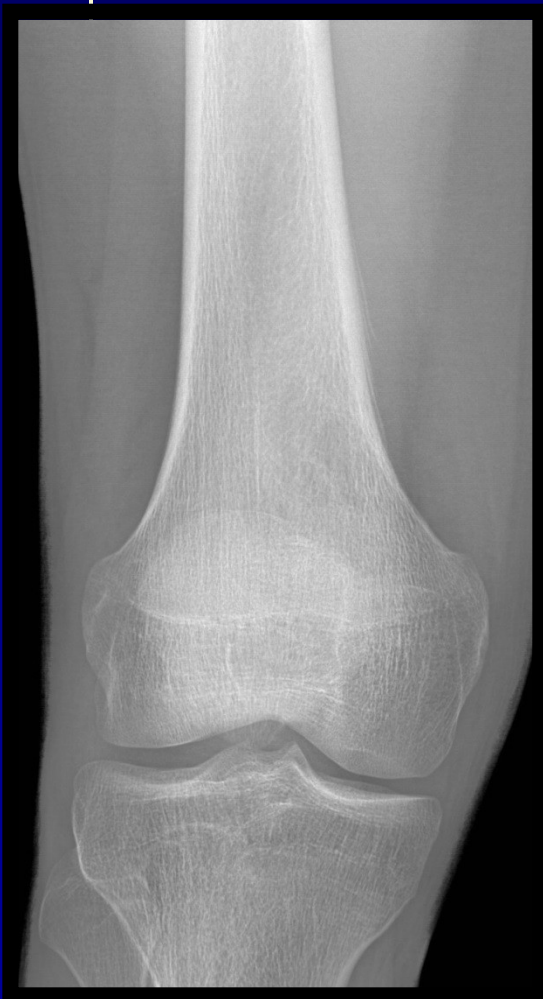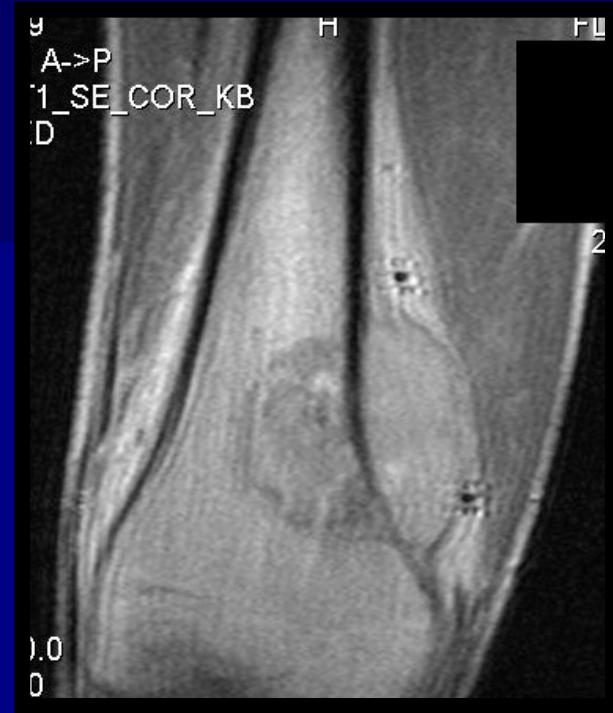Symptoms

- pain
- swelling
- Fever, redness,
- Leucocytosis, ESR elev.
- Biopsy- + identification of specific gene translocation t(11,22)q(24,12)

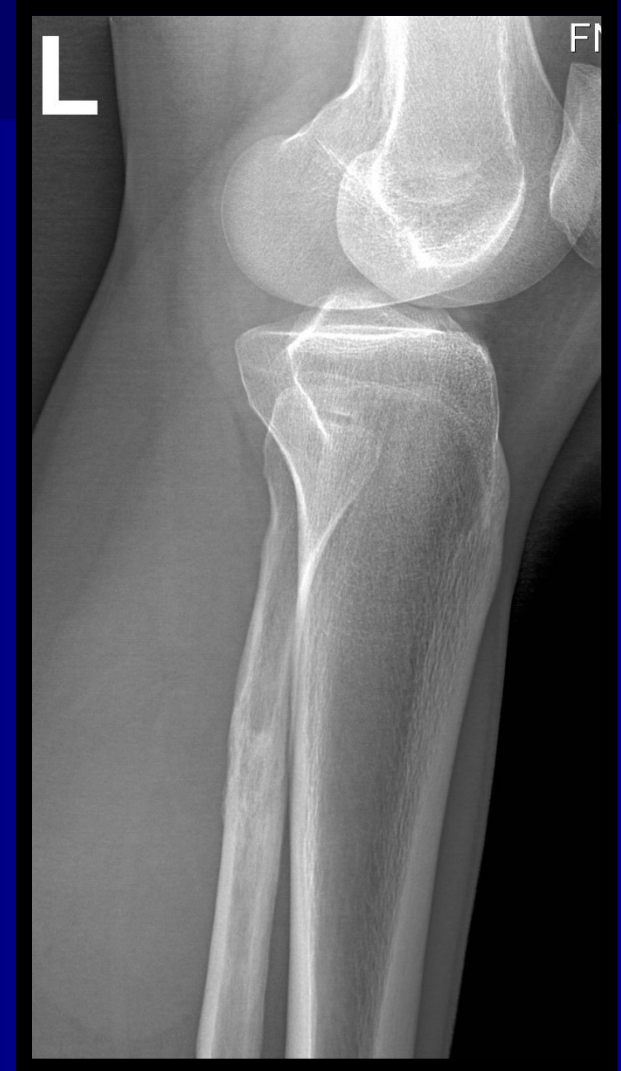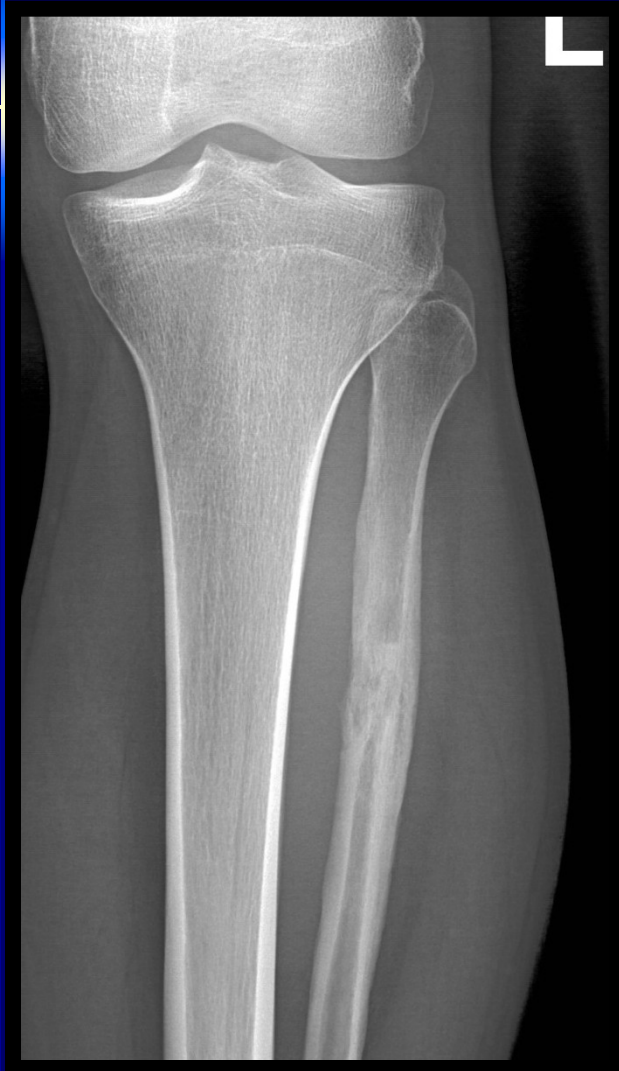Ewing sarcoma



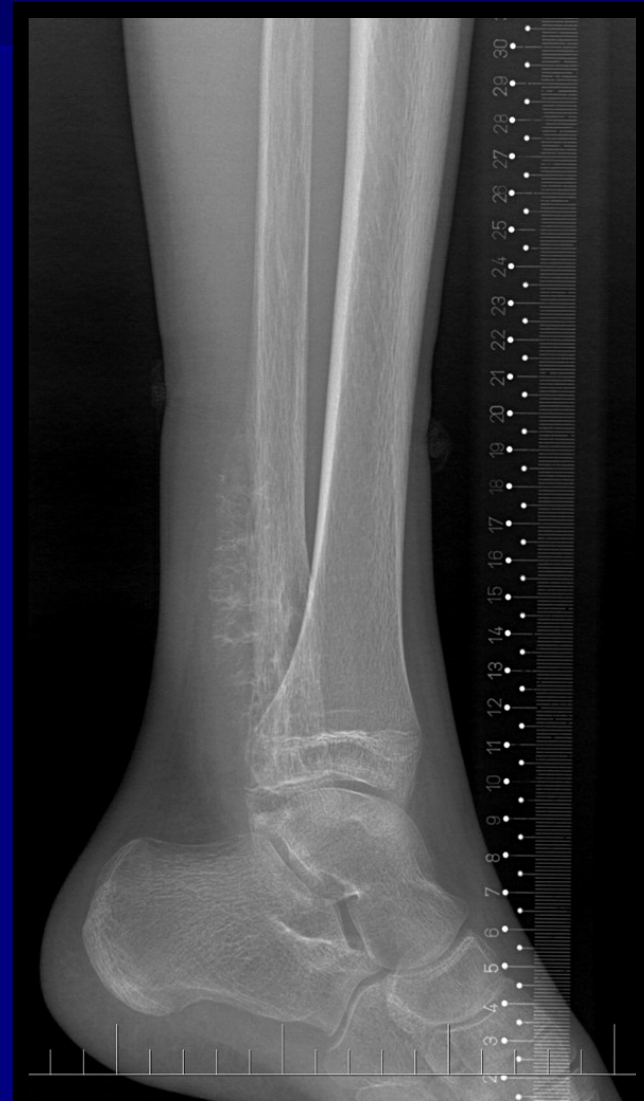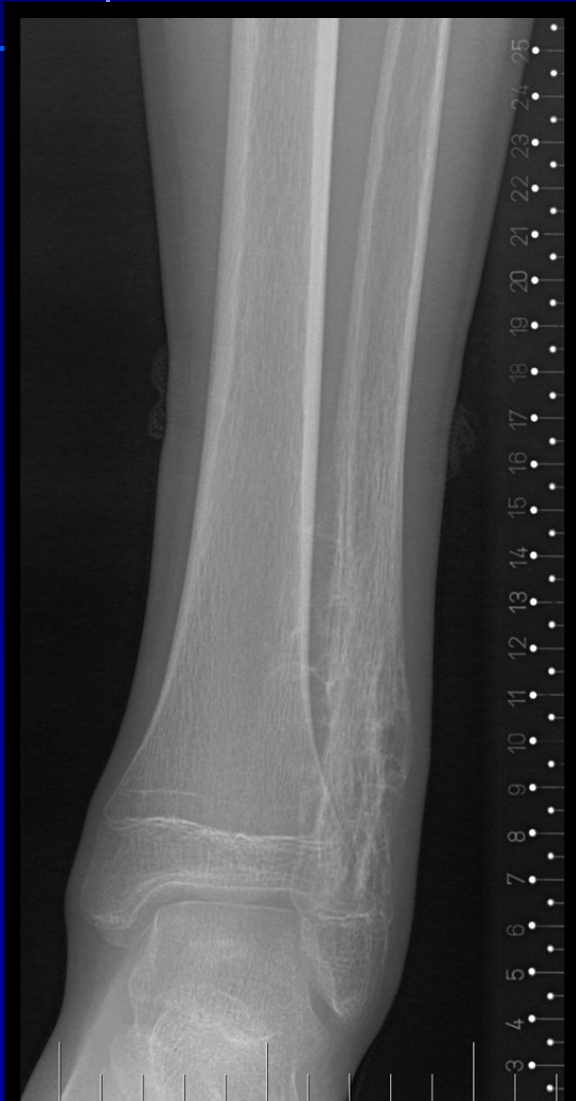Ewing sarcoma



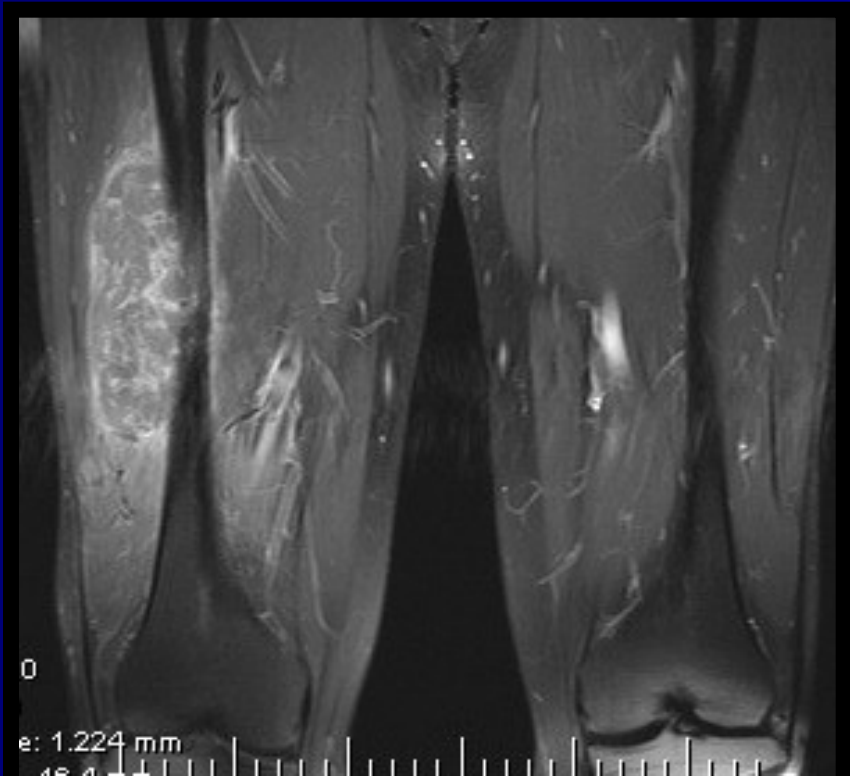
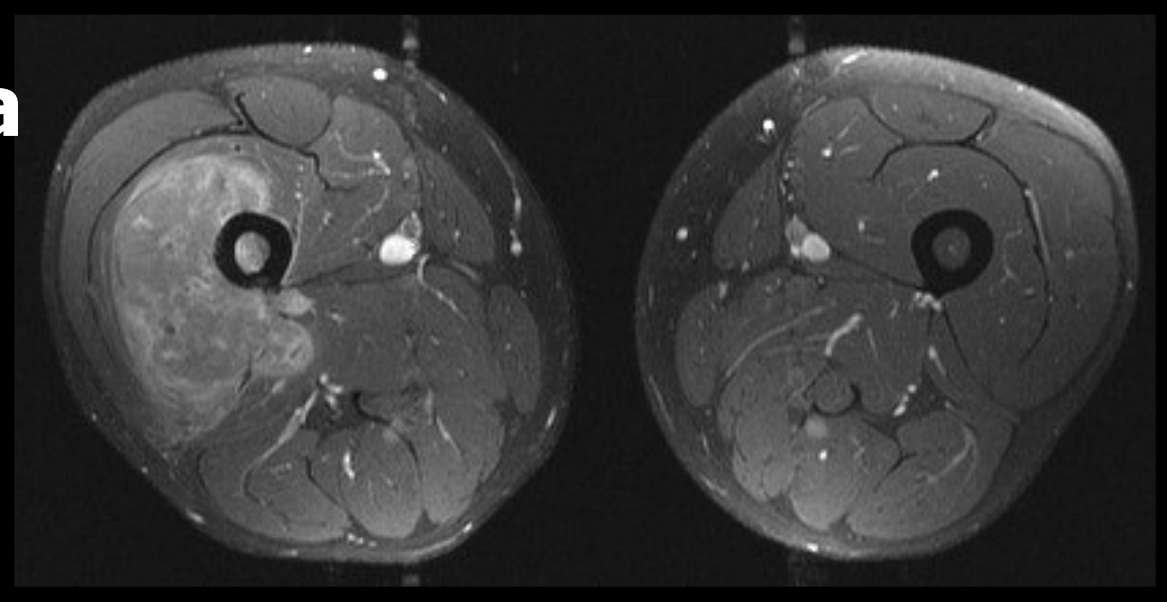
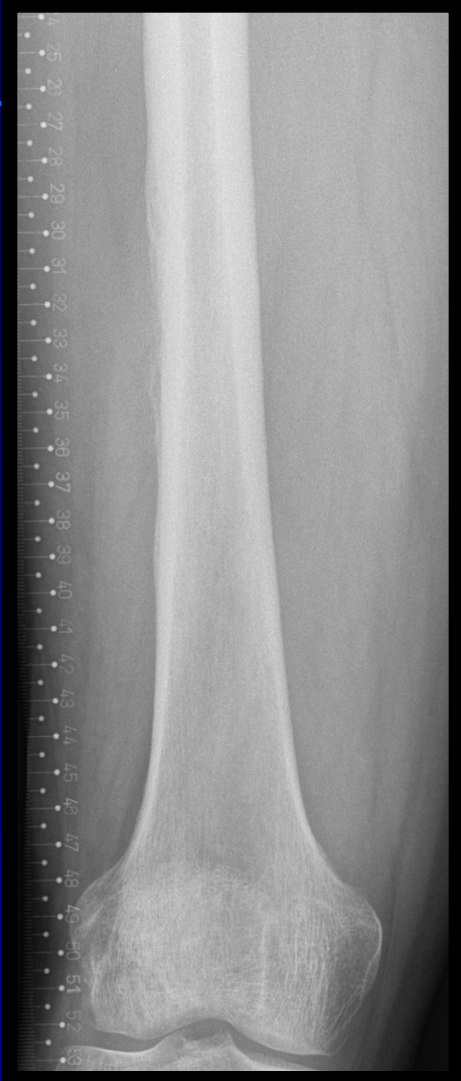Ewing sarcoma



Ewing sarcoma



Ewing sarcoma



Therapy

- Chemo and radio sensitive tumor
- Neoadjuvant chemotherapy
- Local therapy:
 - Radiotherapy
 - Wide resection
 - Radiotherapy and wide resection
- Adjuvant chemotherapy
- In risk patients: transplantation of bone marrow
- Metastasectomy in lungs

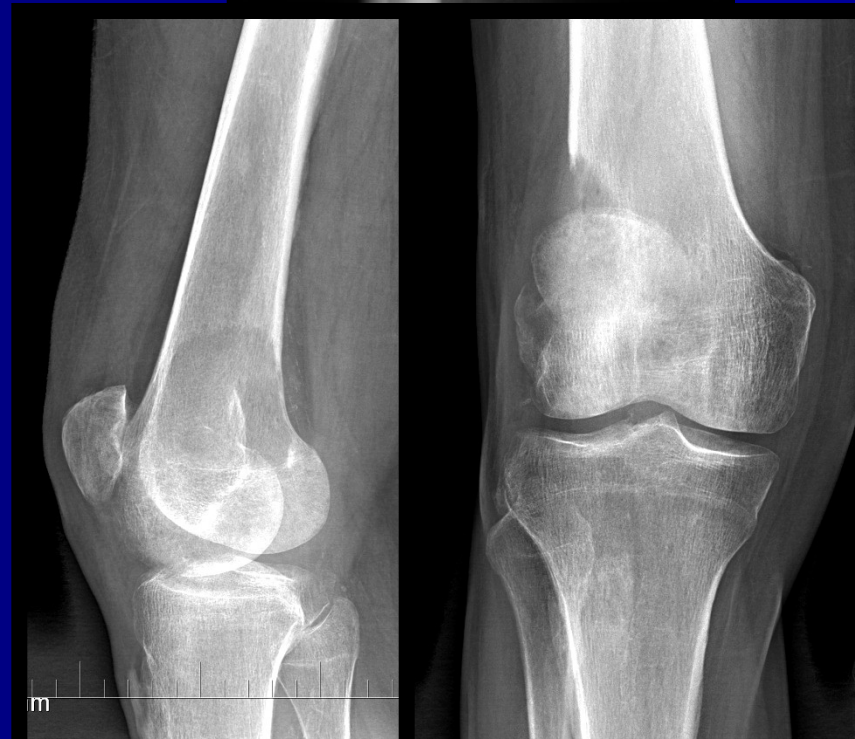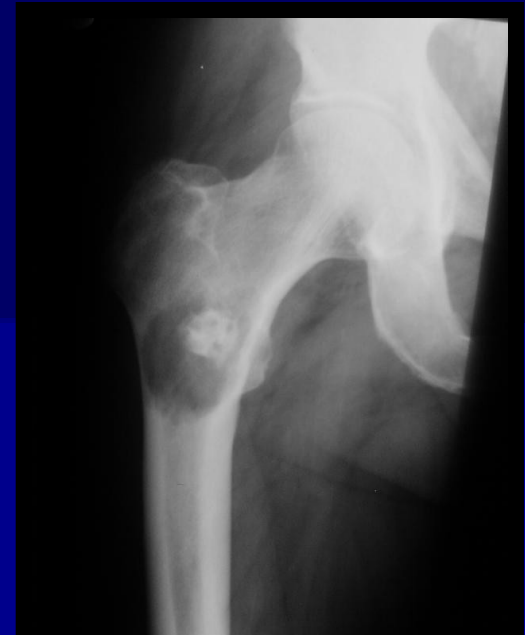Prognosis

- Response to chemotherapy (systemic disease)
- **5-years survival in 60 % of patients**
- **Worse prognosis:**
 - metastases
 - **Size over 100cm³**
 - **Surgery not possible**
 - **Axial localisation**
 - **Local recurrence**
 - **Some genetic variants**

Malignant fibrous histiocytoma in bone

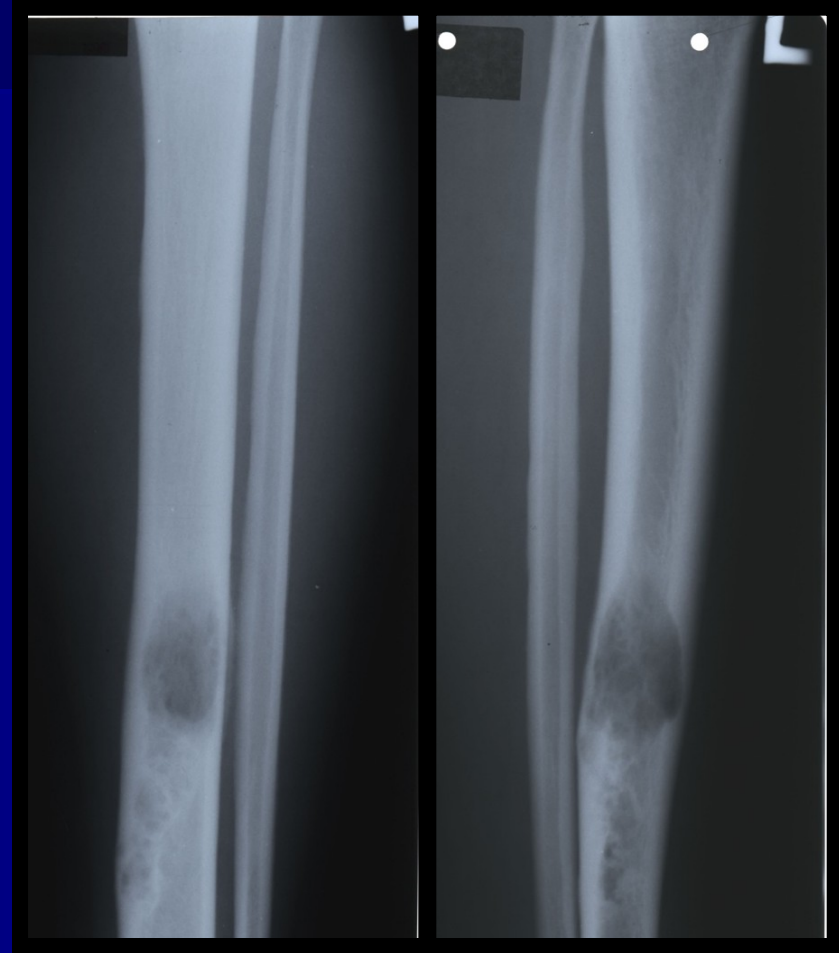- **In 5. decade**
- **In long bones – femur, tibia**
- **X- ray osteolytic lesion + cortical erosions, soft tissue mass**

- **Therapy: neoadjuvant chemotherapy + wide resection or amputation + adjuvant chemotherapy**
- **It is a radioresistant tumor**
- **Survival 35 % 5 years**



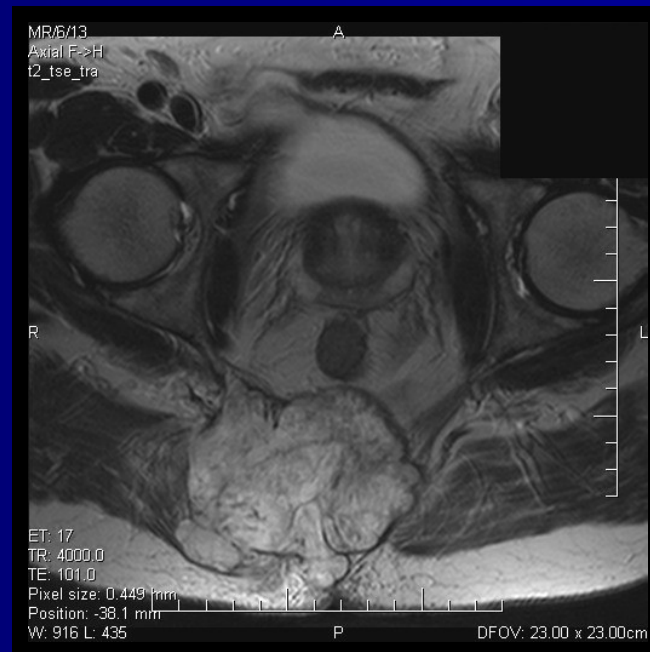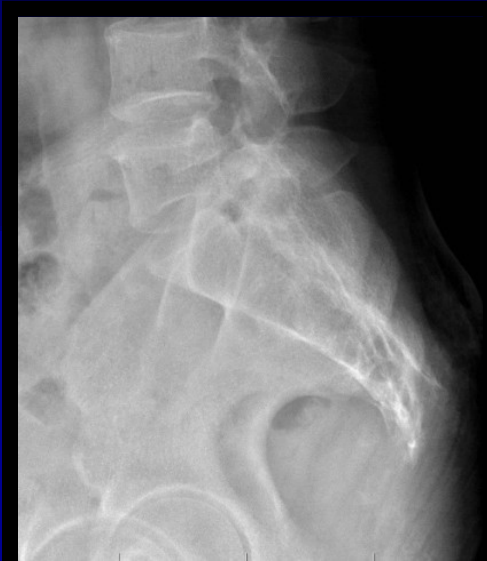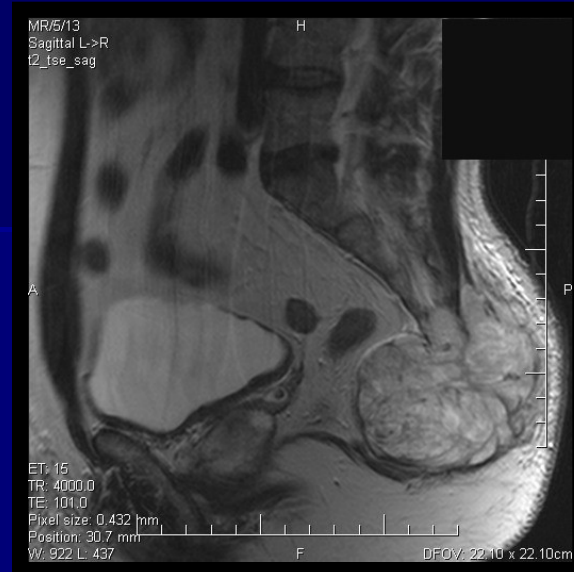Adamantinoma

- Very rare
- 90 % in tibia
- Therapy: radical resection
- Radioresistant tumor
- Prognosis – unclear



Chordoma

- Axial localisation
- Osteolytic lesion
- Th- radical surgery or radiotherapy
- Prognosis- bad

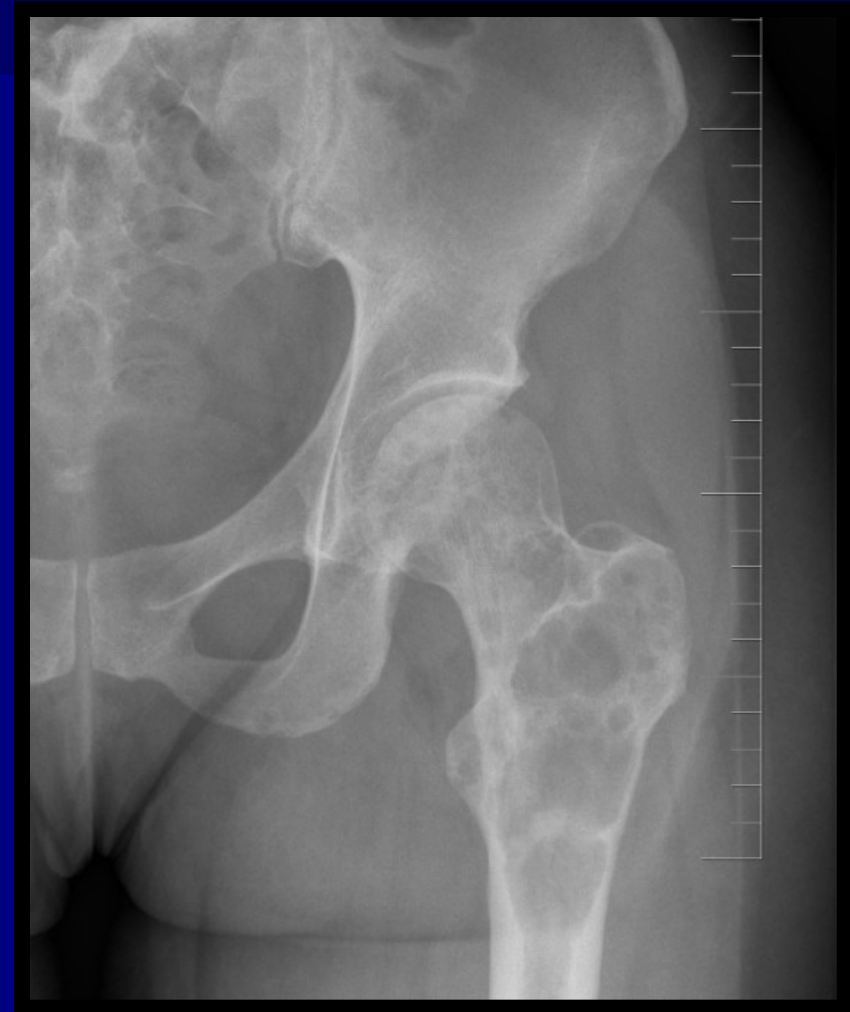

Malignant vascular tumors

- **Hemangioendotelioma**
- **Hemangiopericytoma**
- **Angiosarcoma**

- Osteolytic lesions
- Therapy: wide resection or amputation
- Chemotherapy in high grade

- Radiotherapy in non oper. cases



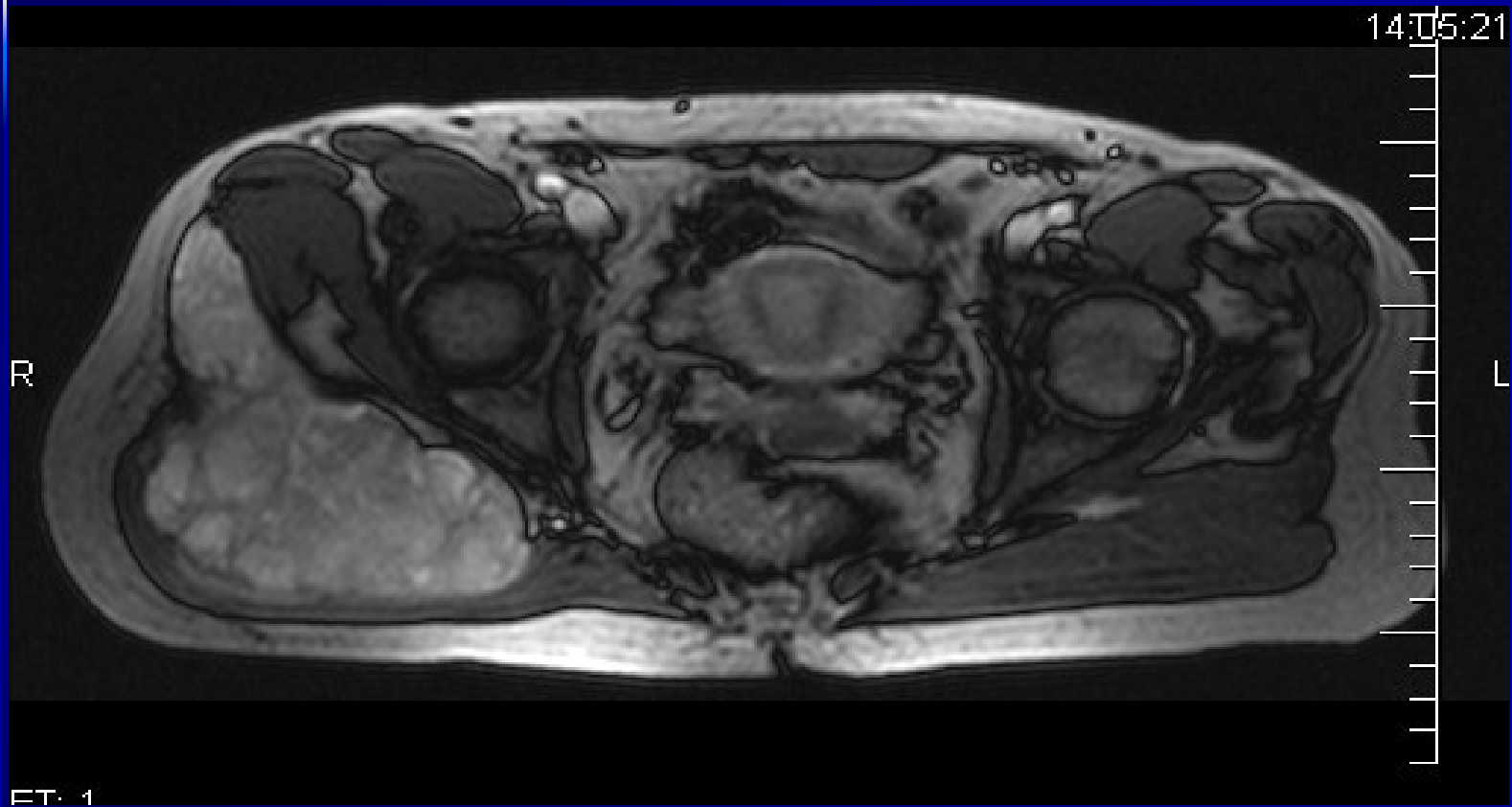
Soft tissue sarcomas (STS)

- Undifferentiated sarcomas
- Synovial sarcoma
- Liposarcoma
- Leiomyosarcoma
- Myxofibrosarcoma
- Malignant schwannoma
- ... (50 types)

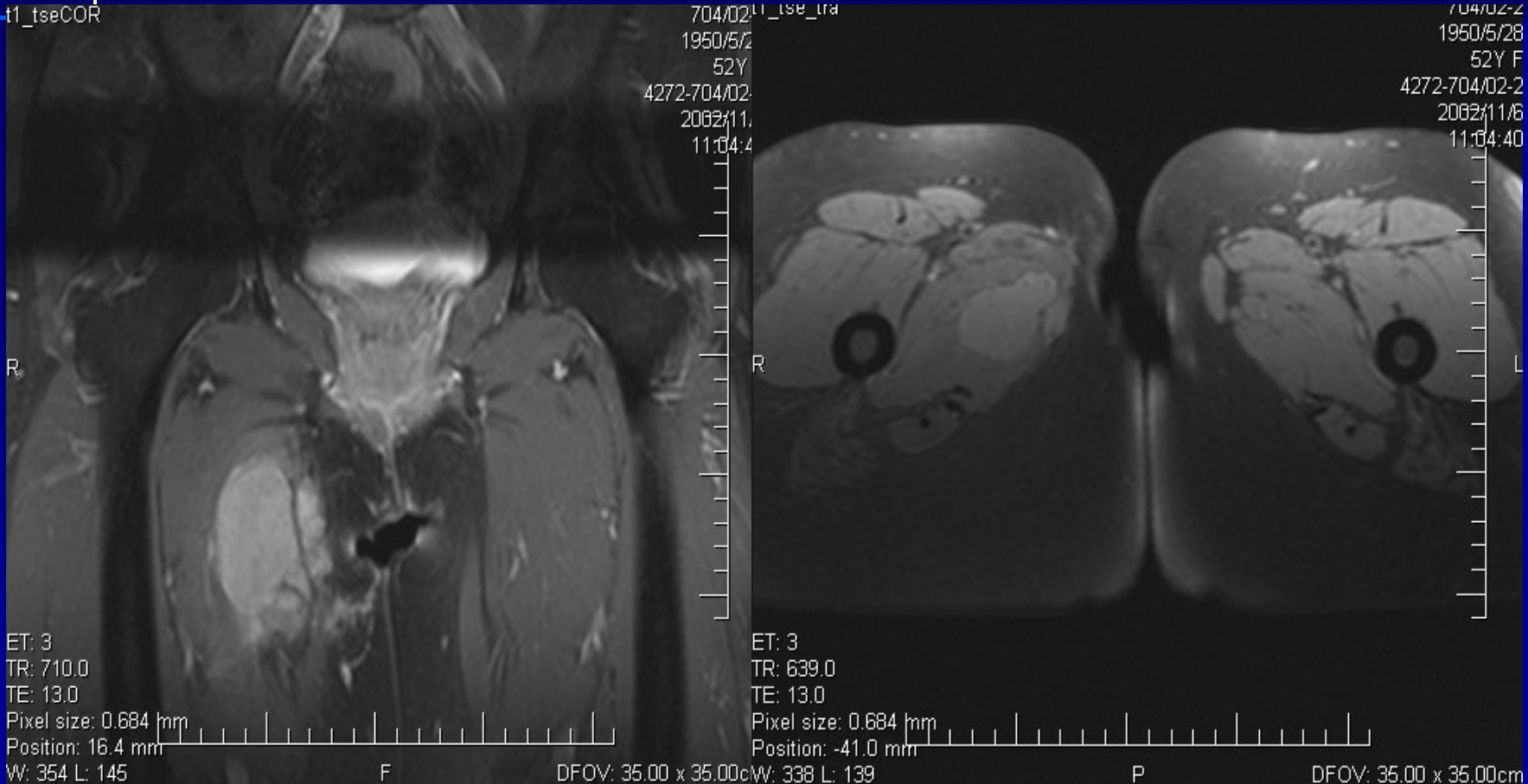
Therapy

- Neoadjuvant chemotherapy in G III
- Wide resection
- Adjuvant radiotherapy ?
- Adjuvant chemotherapy ?
- Palliative radiotherapy in inoperable tumors
- Palliative chemotherapy in metastatic disease

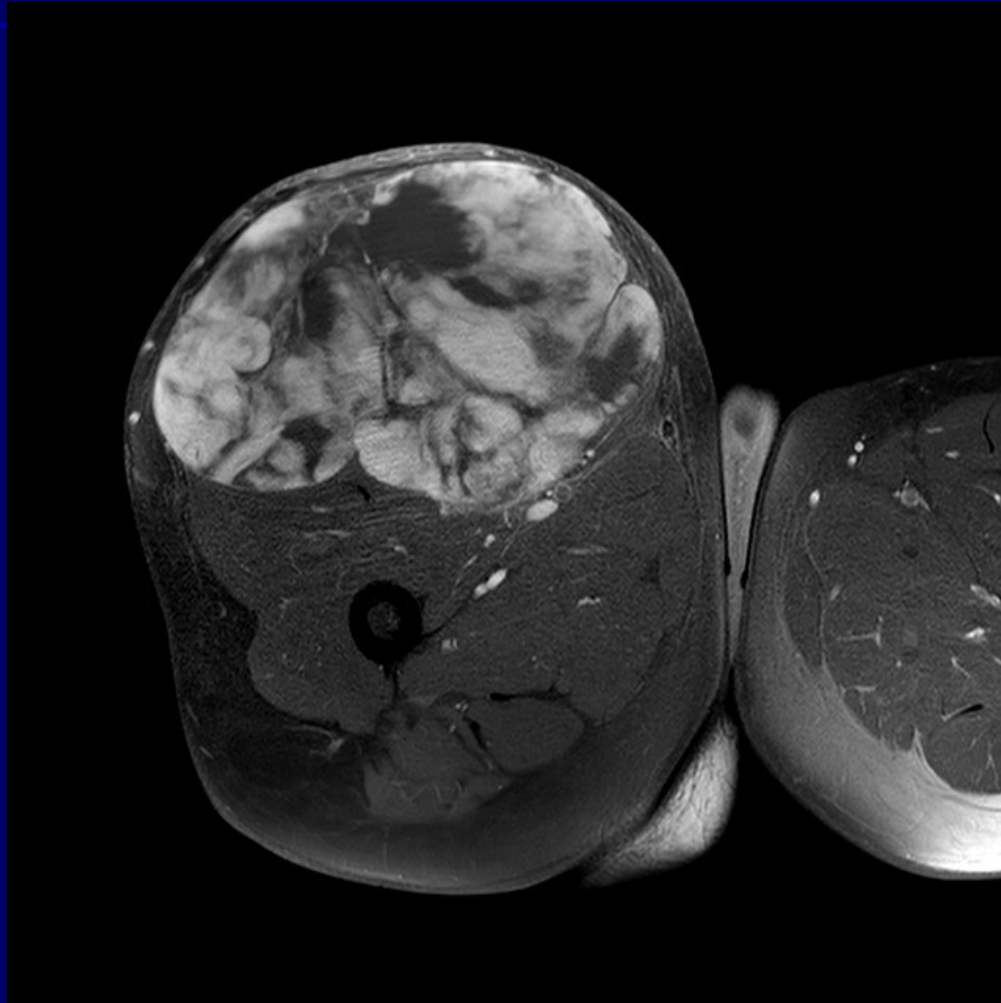
High grade undifferentiated pleomorphic sarcoma



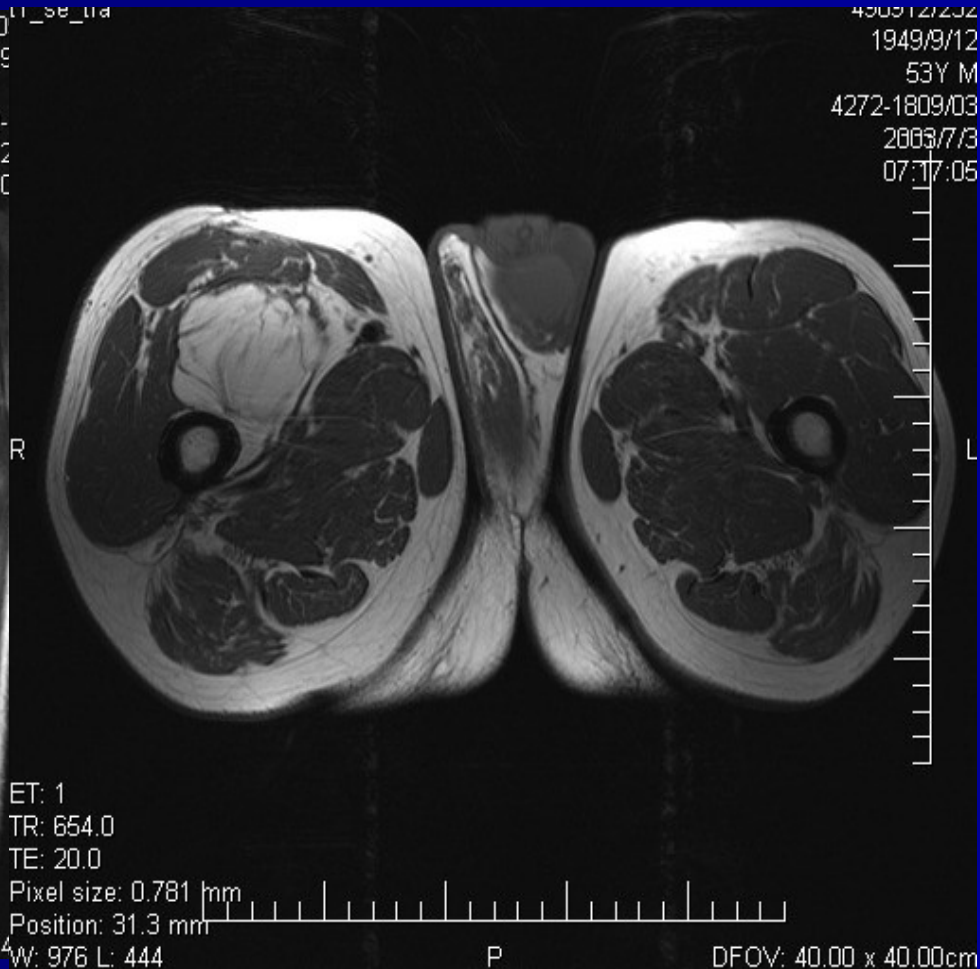
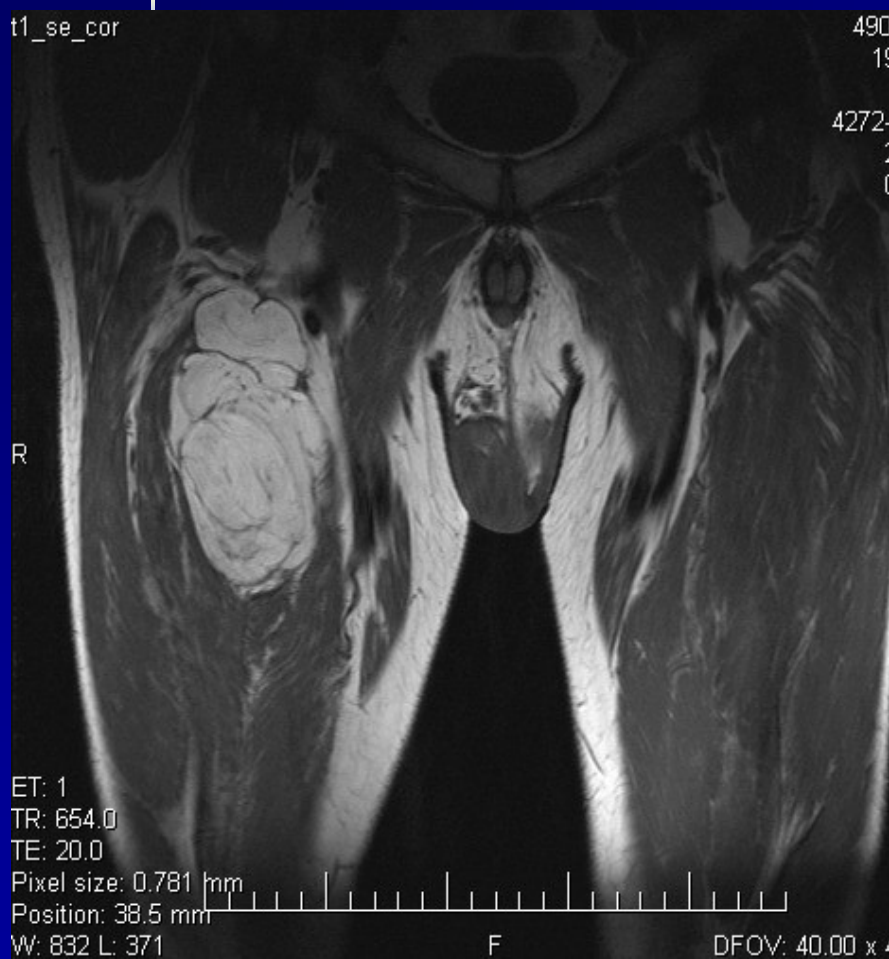Synovial sarcoma



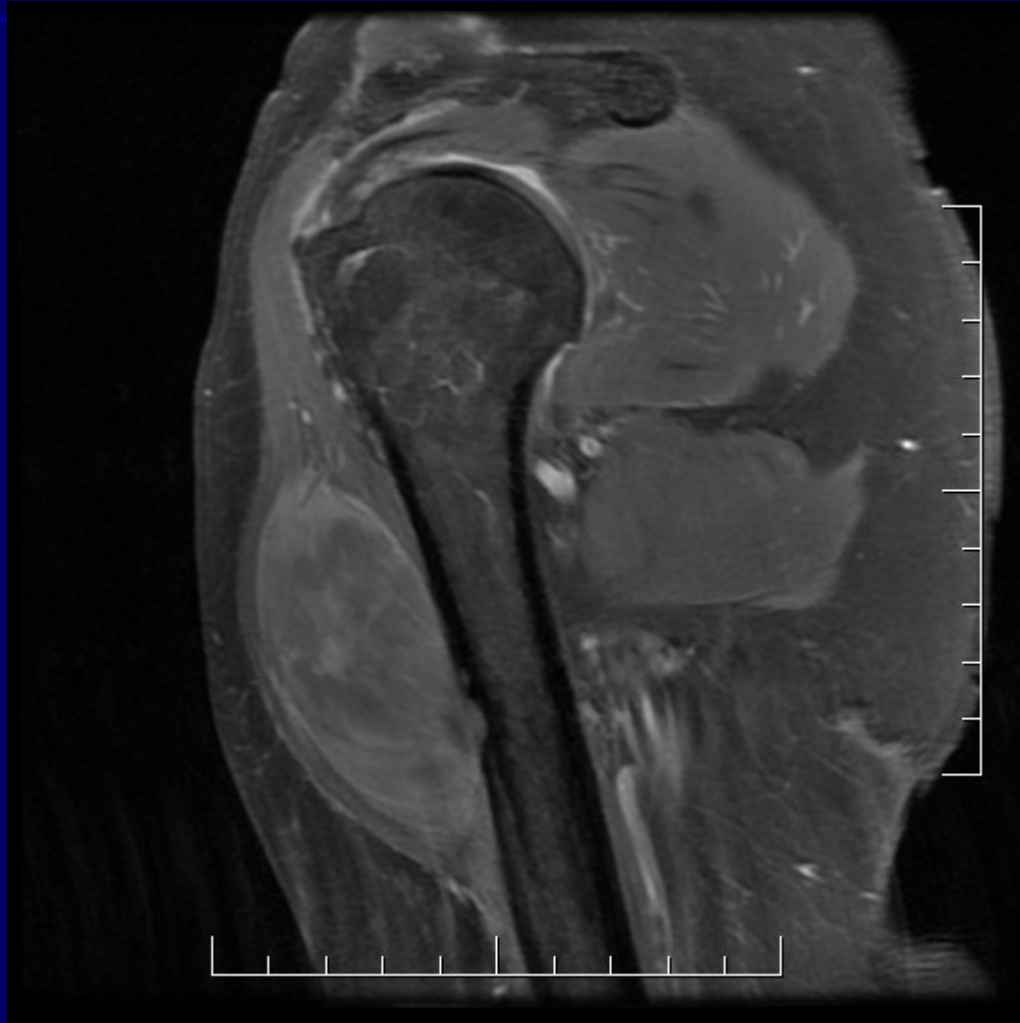
Liposarcoma (myxoid subtype)



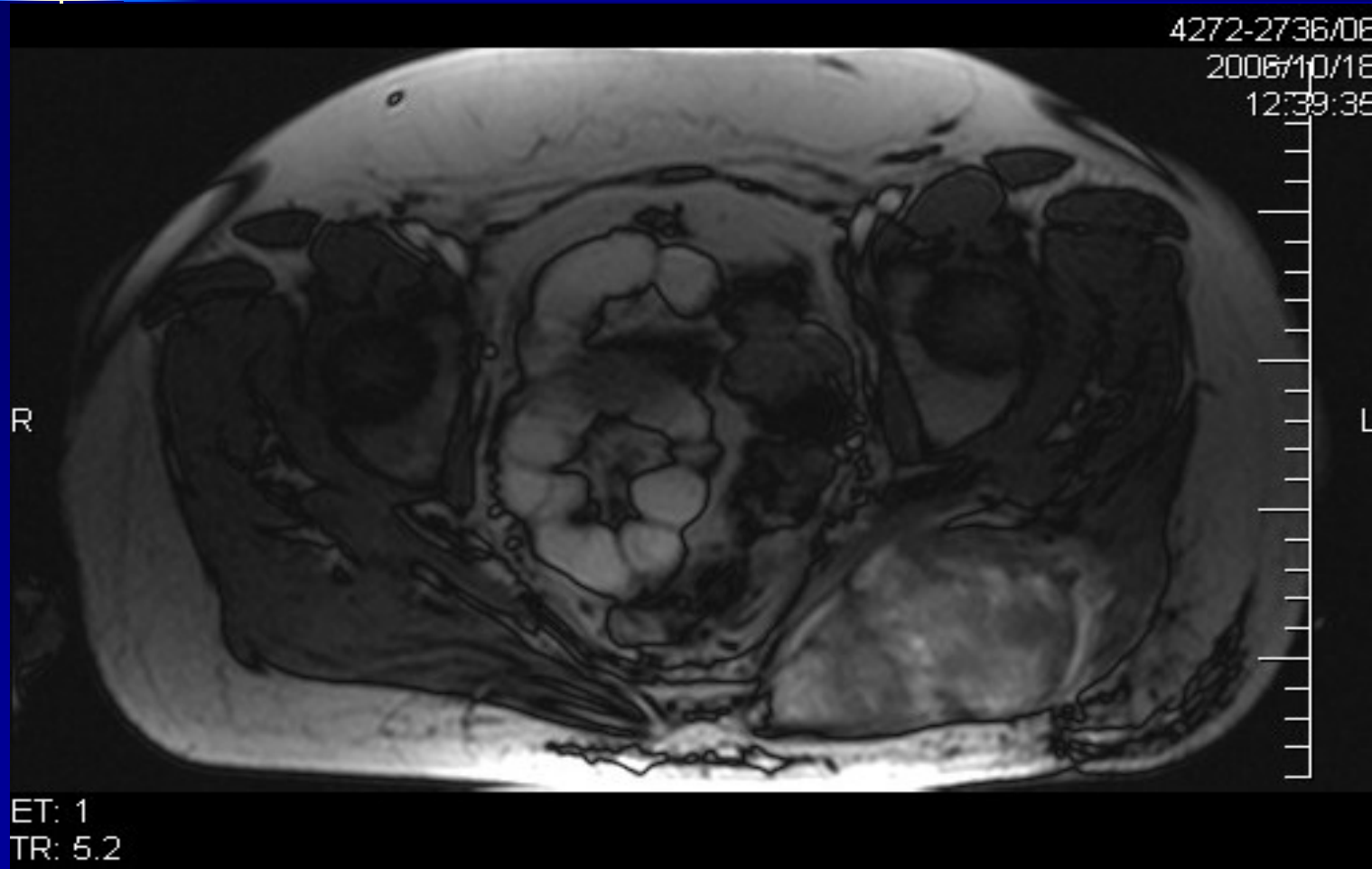
Liposarcoma (well differentiated subtype)



Myxofibrosarcoma



Leiomyosarcoma

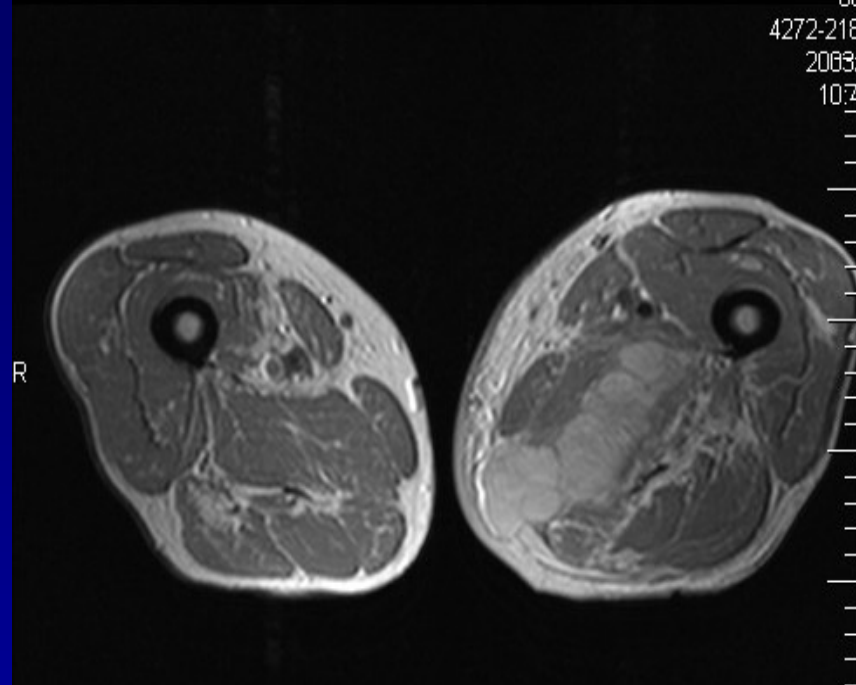


Malignant schwannoma

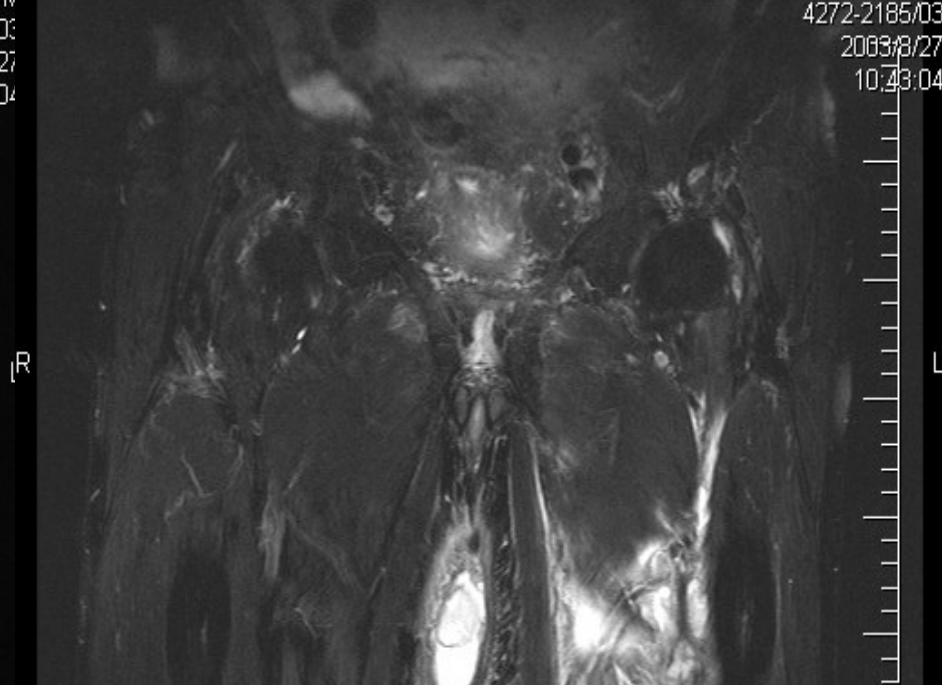
AXIAL F->H
pd+t2_tse_tra

REZNAK JAJ
230413/448
1923/4/13
80Y M
4272-2185/03
2003/8/27
10:43:04

230413/448
1923/4/13
80Y M
4272-2185/03
2003/8/27
10:43:04



ET: 5
TR: 4880.0
TE: 14.0
Pixel size: 0.781 mm
Position: -8.6 mm
W: 1087 L: 517



ET: 7
TR: 3140.0
TE: 108.0
Pixel size: 0.879 mm
Position: 10.2 mm
W: 263 L: 94

DFOV: 40.00 x 40.00cm

DFOV: 45.00 x 45.00cm

Hemoblastosis in skeleton

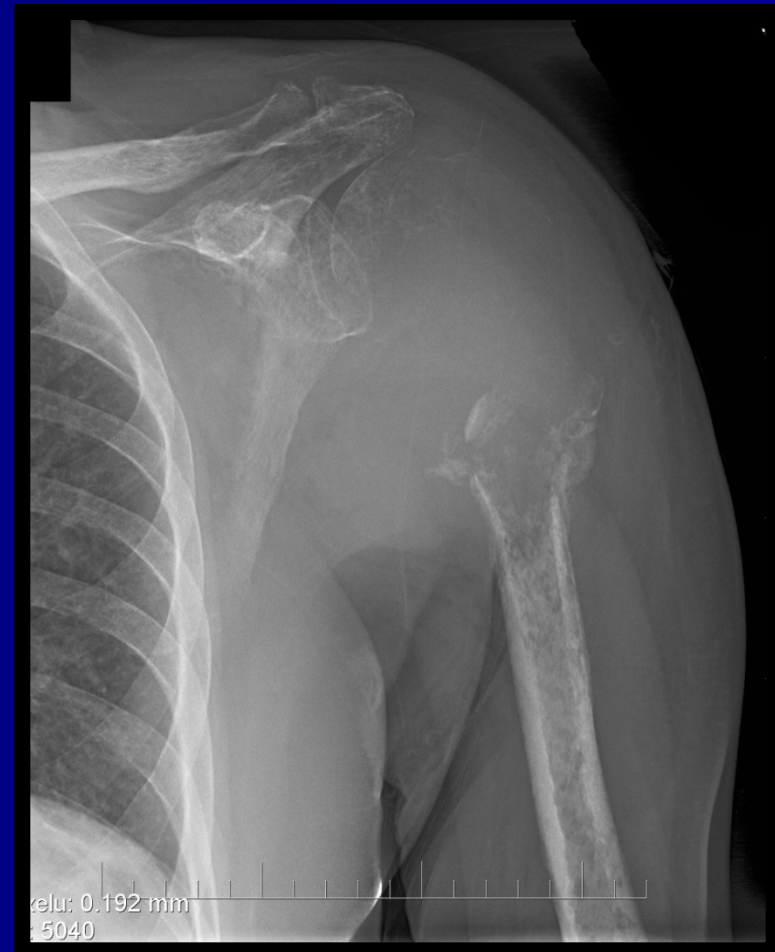- **Primary bone tumors**
 - Multiple myeloma (plasmocytoma)
 - Solitary plasmocytom (myelom)
 - Primary bone lymfoma

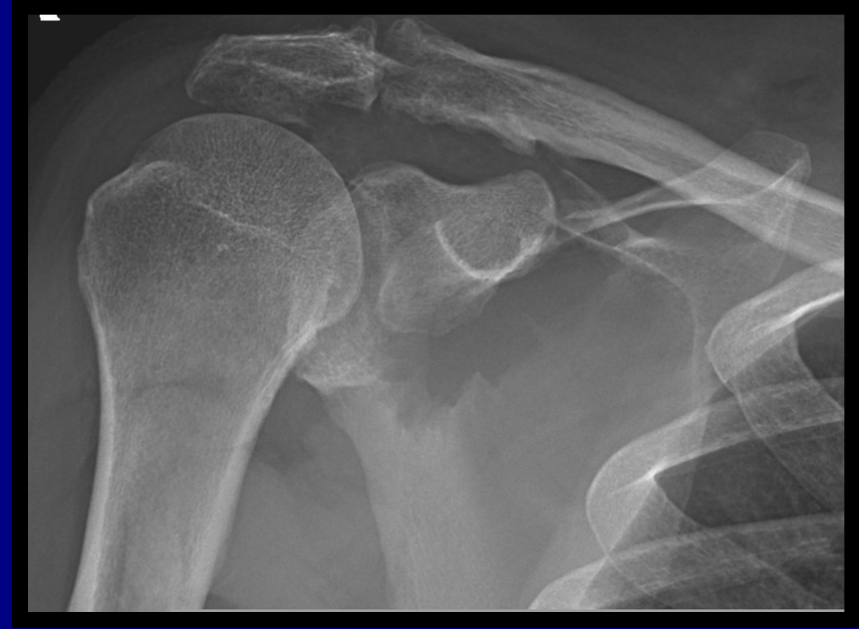
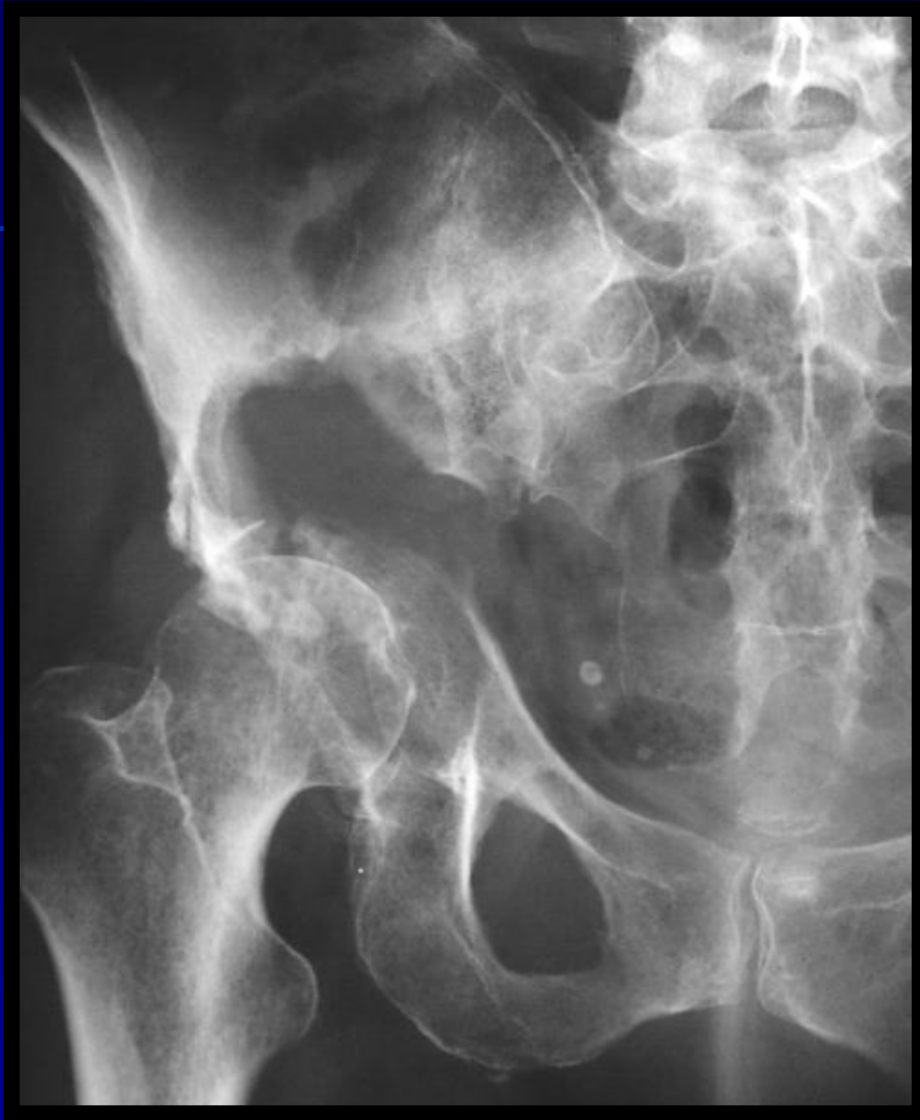- **Secondary lesions**
 - Hodgkin lymfoma
 - Non-Hodgkin lymfoma
 - Leukemia

Therapy- chemotherapy and radiotherapy
in hematooncology

Multiple myeloma

- Most frequent bone tumor
- 5 – 6. decade
- **Symptoms:**
 - pain
 - Pathological fracture
 - weaknes
 - letargy
 - infections
 - Renal failure
 - Headache

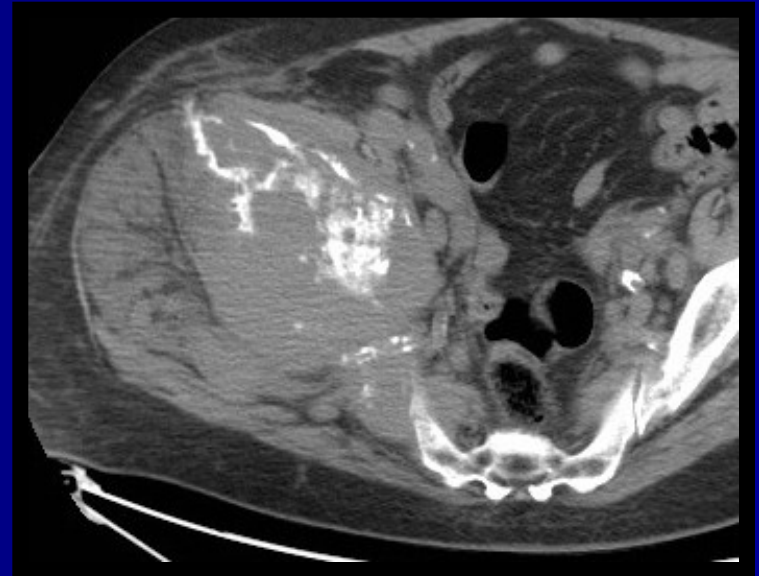
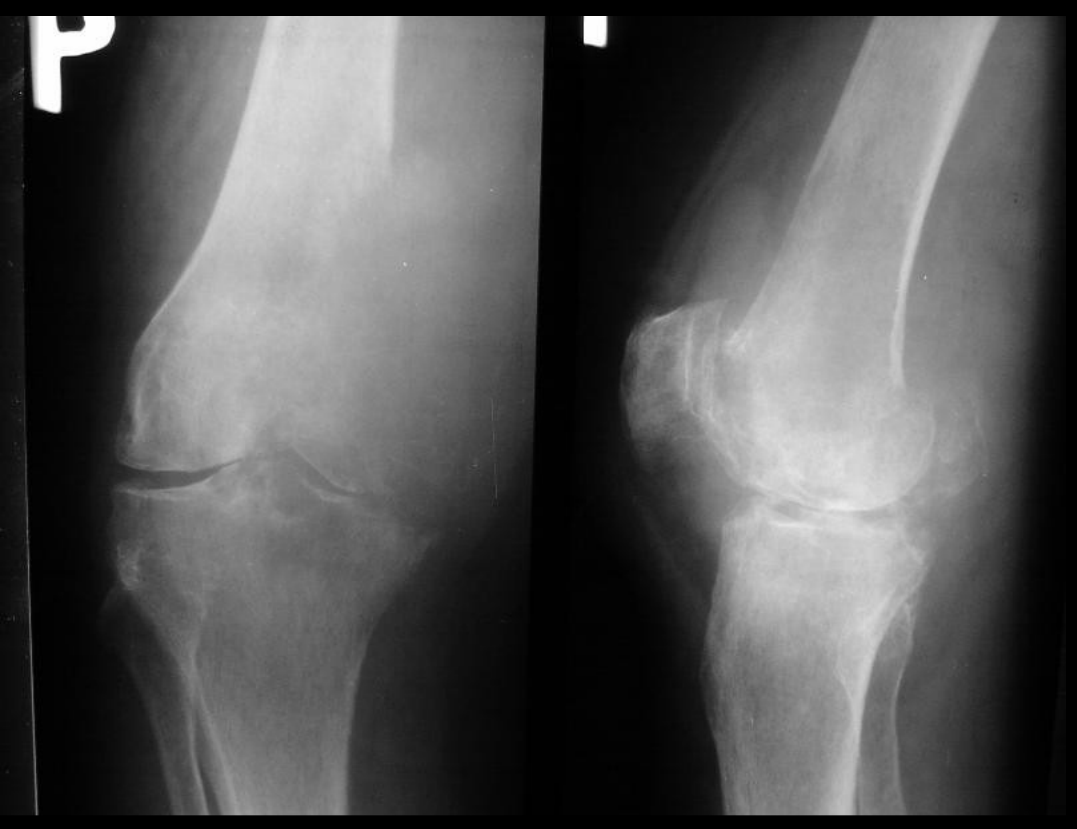


Solitary plasmocytoma

- **Rare**
- **Osteolytic lesion**
- **Resection with replacement + chemotherapy**
- **Prognosis- better than in multiple myeloma**

Primary bone lymphoma



Skeletal metastases

Carcinoma with MTS into the skeleton

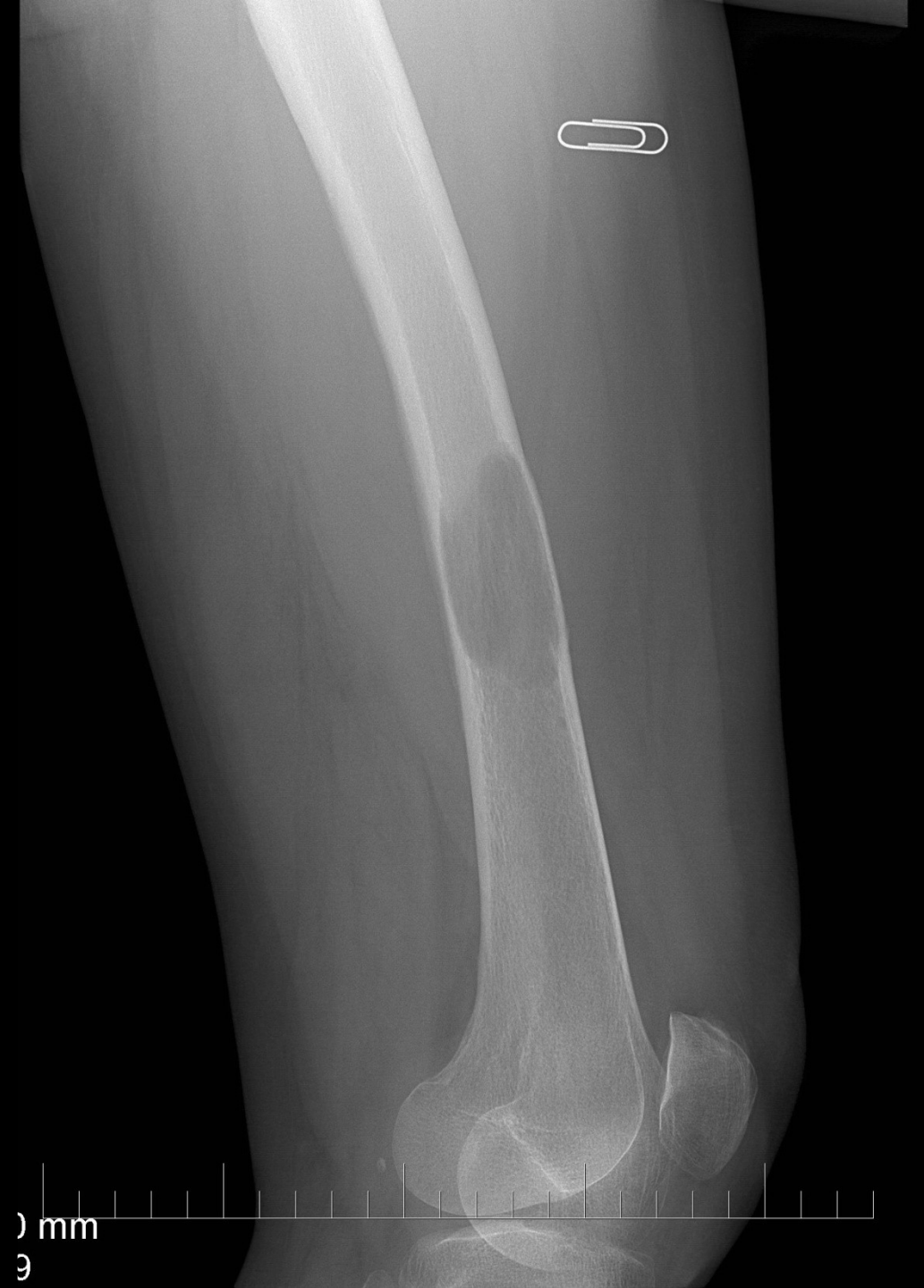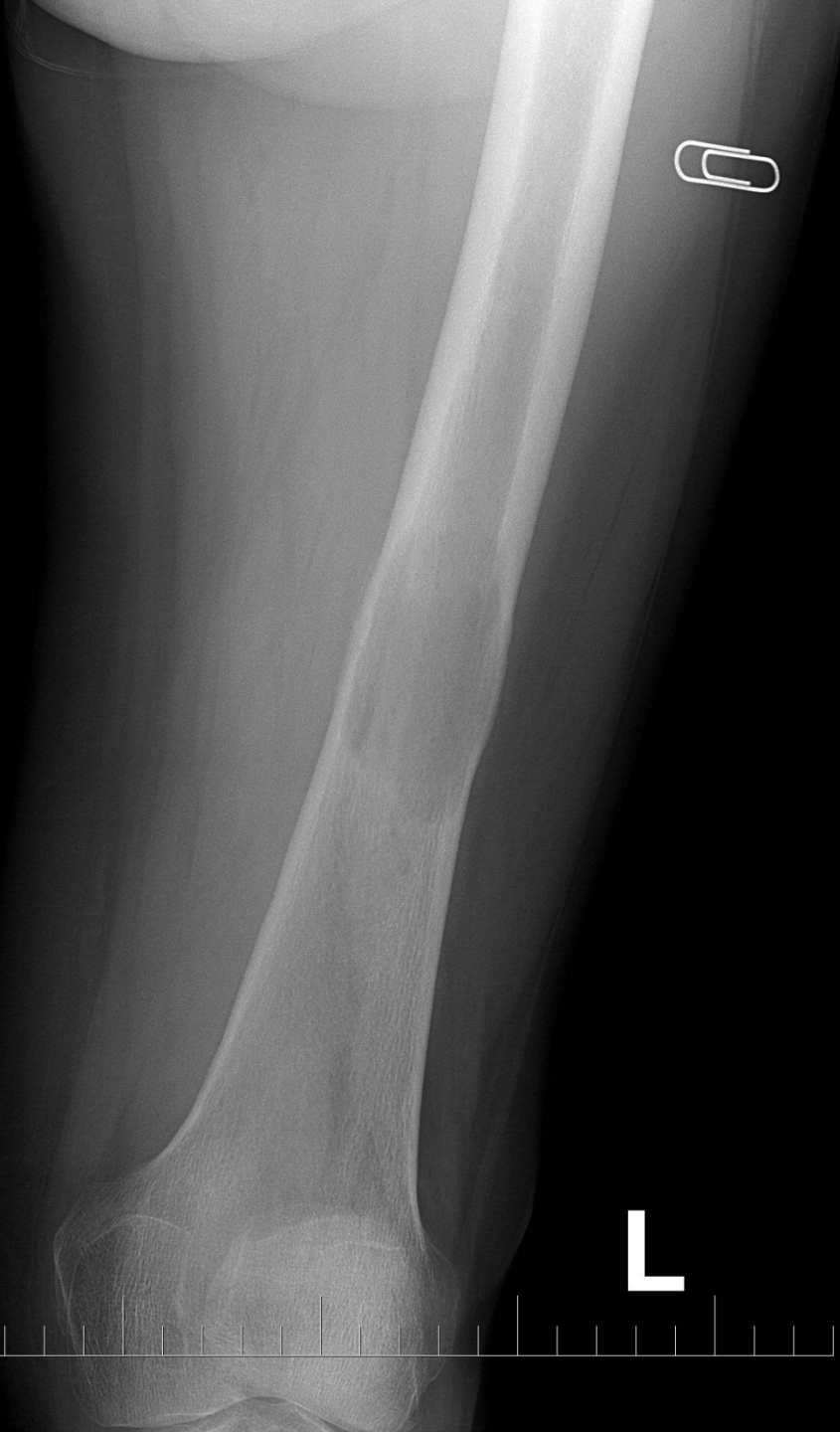- Breast
- Prostate
- Lung
- Kidney
- Thyreoidal gland

Localisation

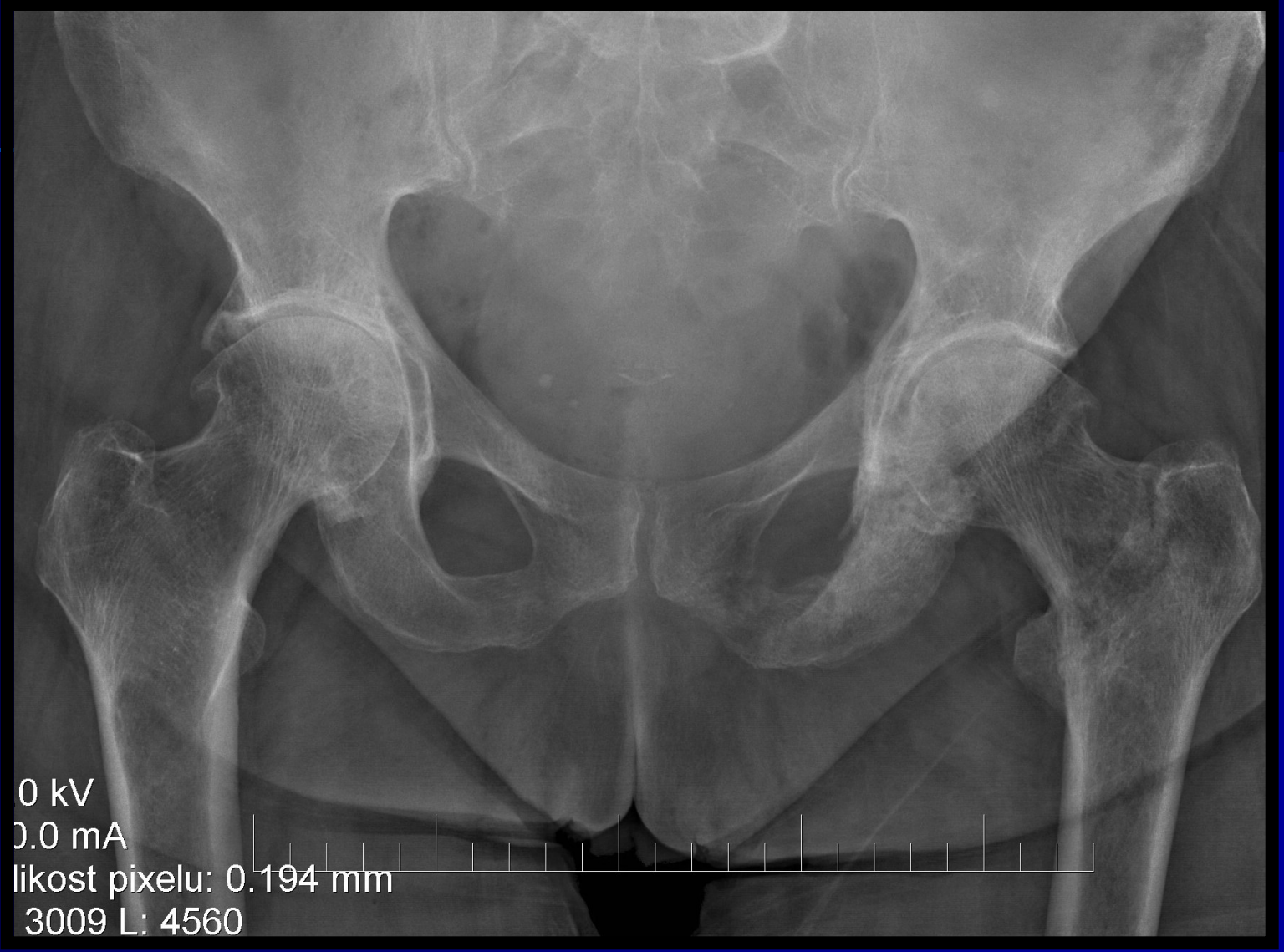- Axial skeleton, pelvis, ribs, proximal femur and humerus

X-ray

- Osteolysis, osteosclerosis, periosteal reaction



) mm
9



0 kV

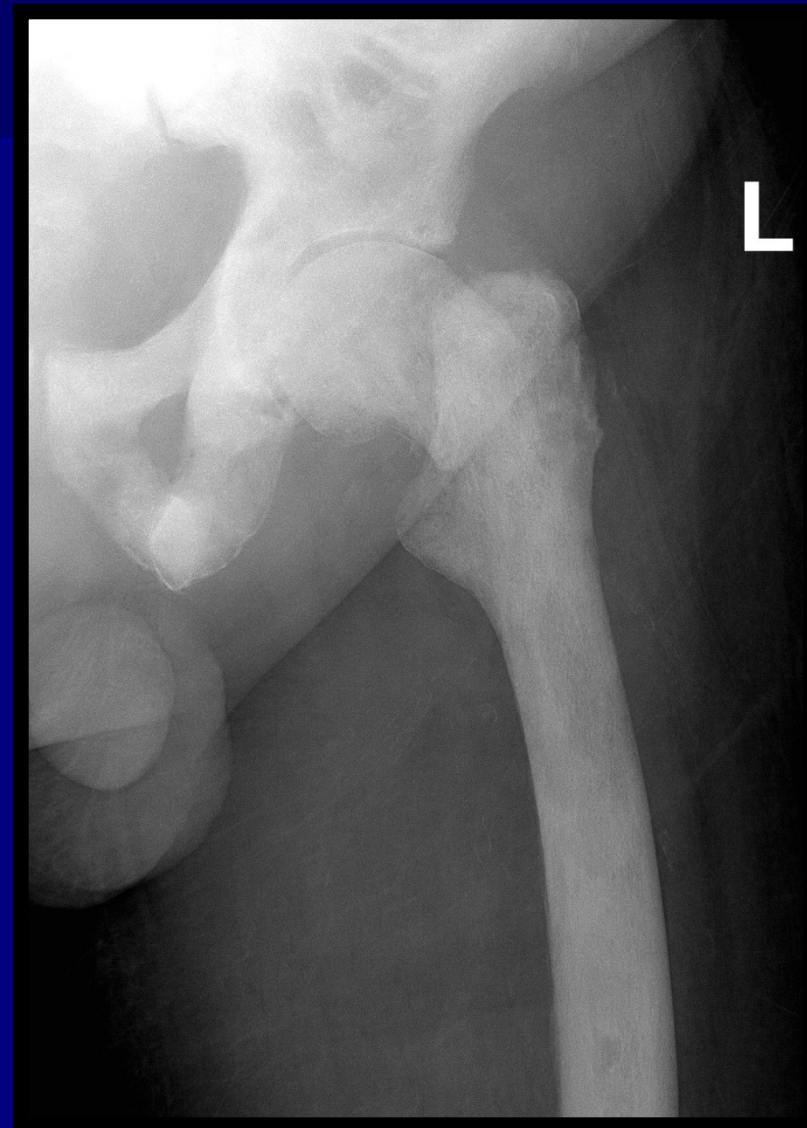
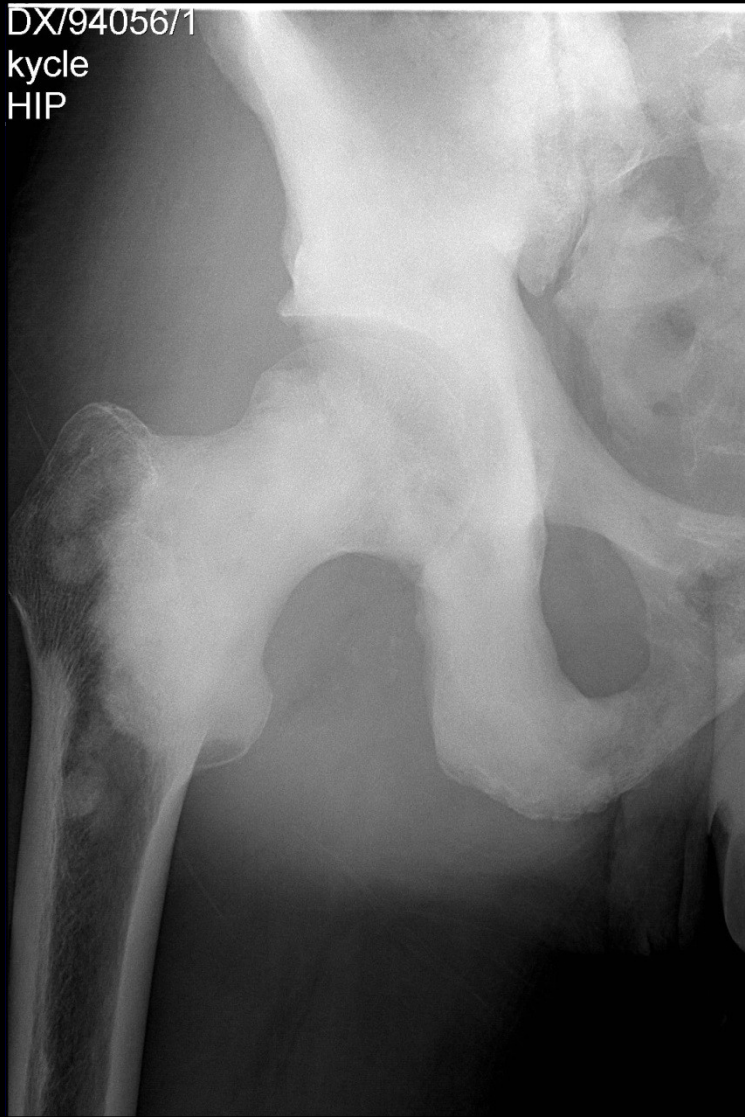0.0 mA

likost pixelu: 0.194 mm

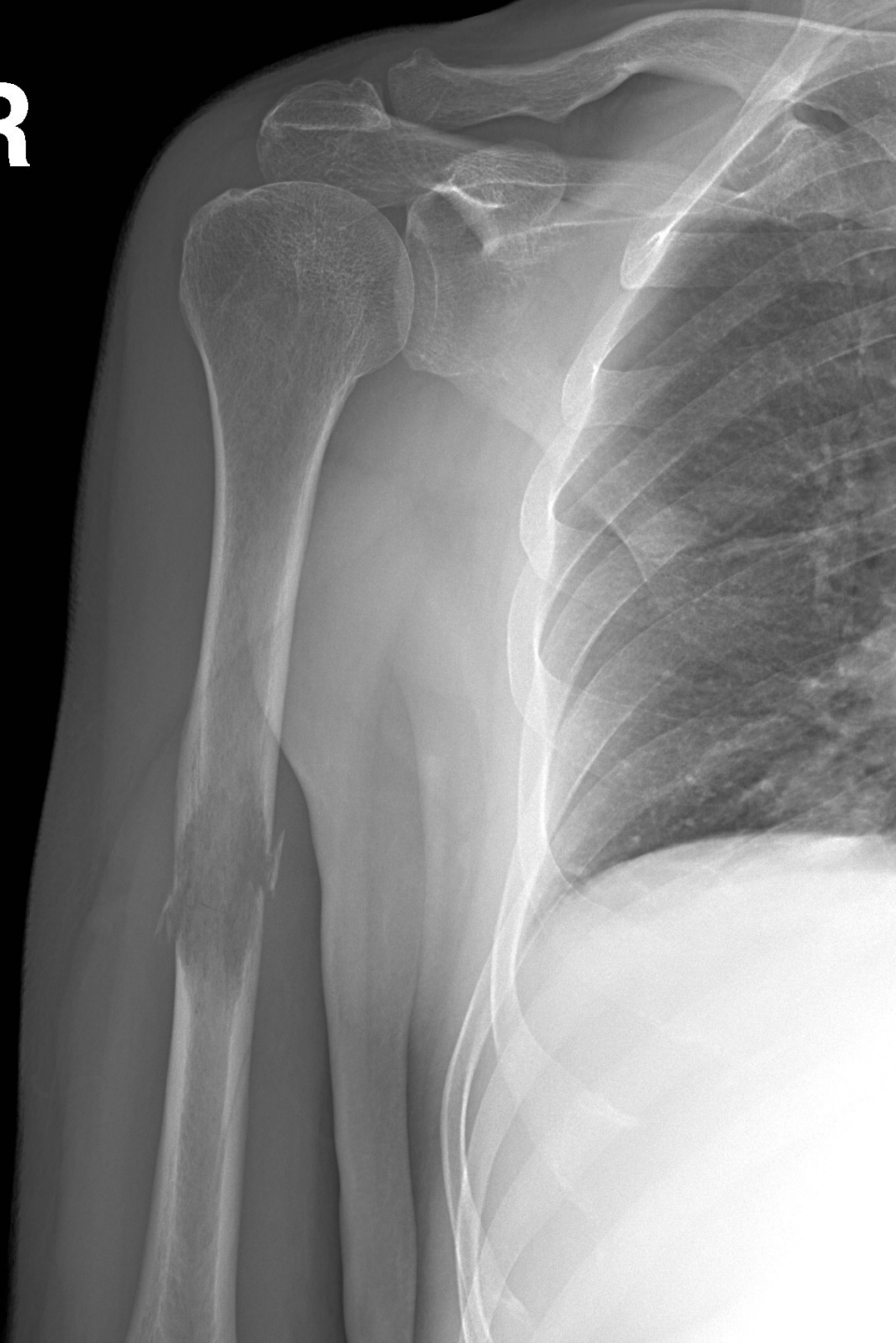3009 L: 4560



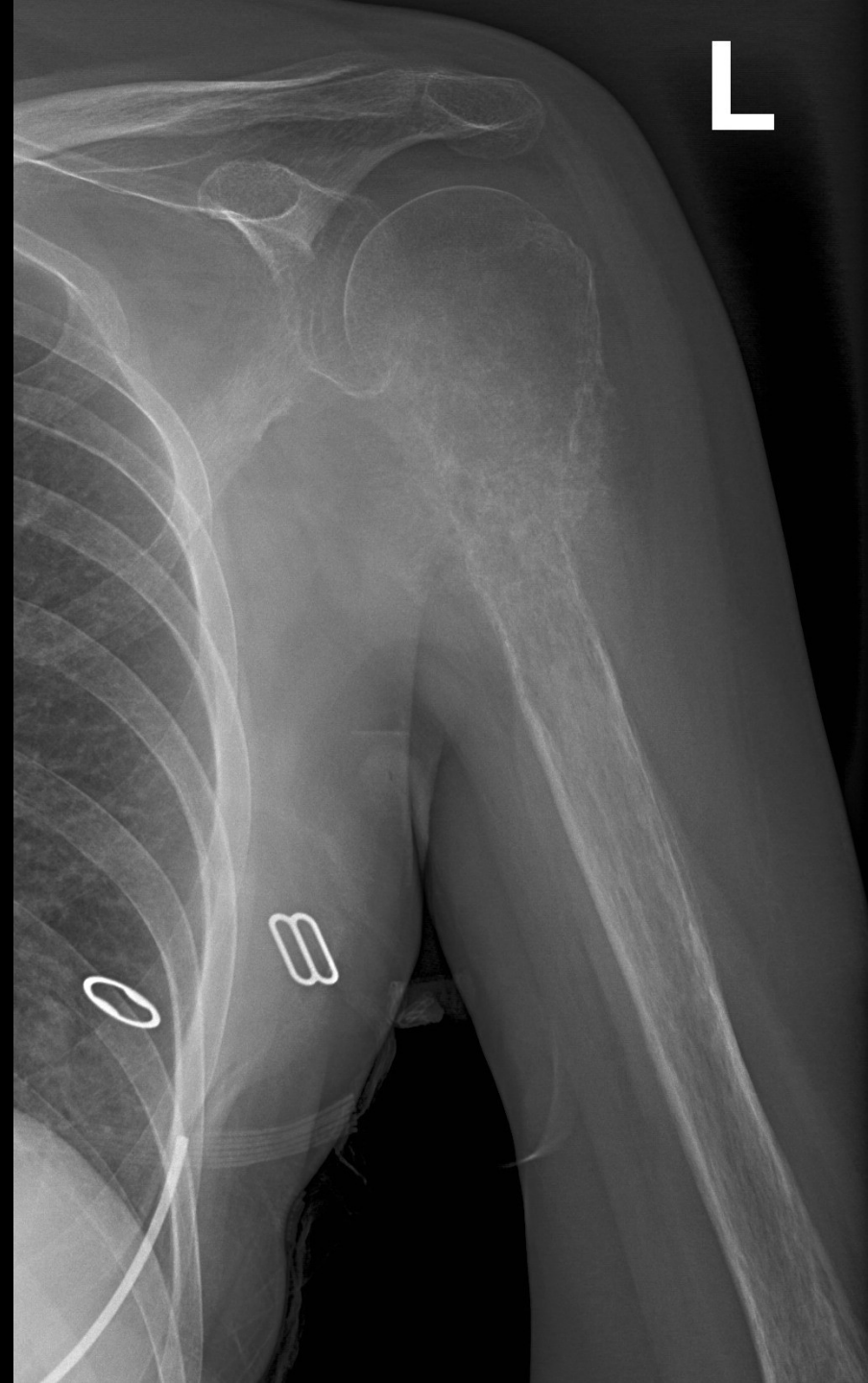
DX/94056/1
kycle
HIP



R



L

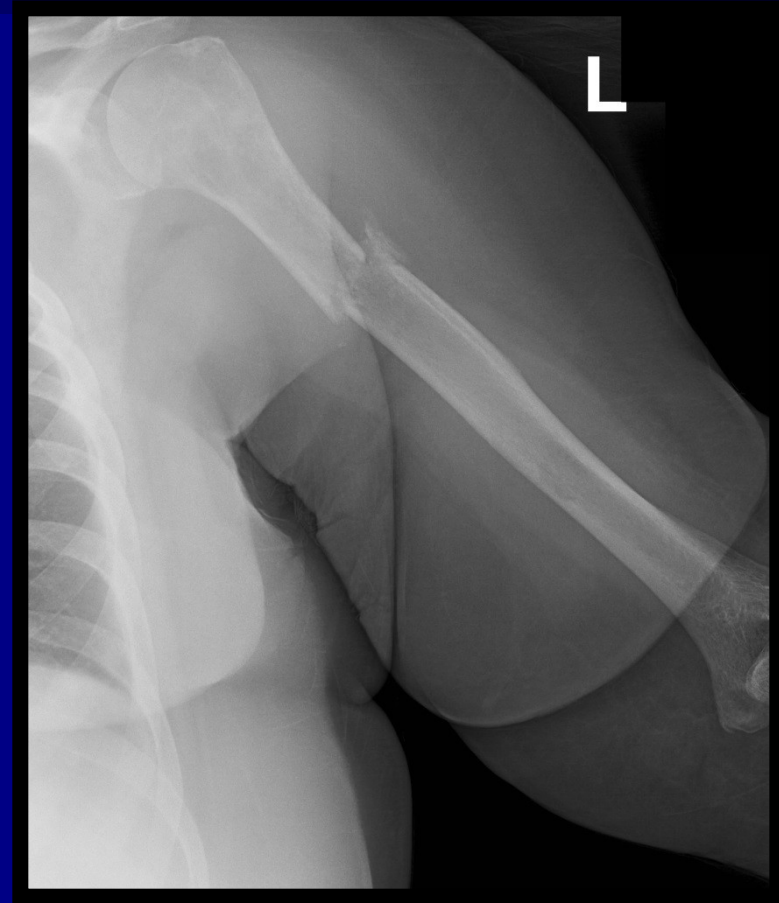

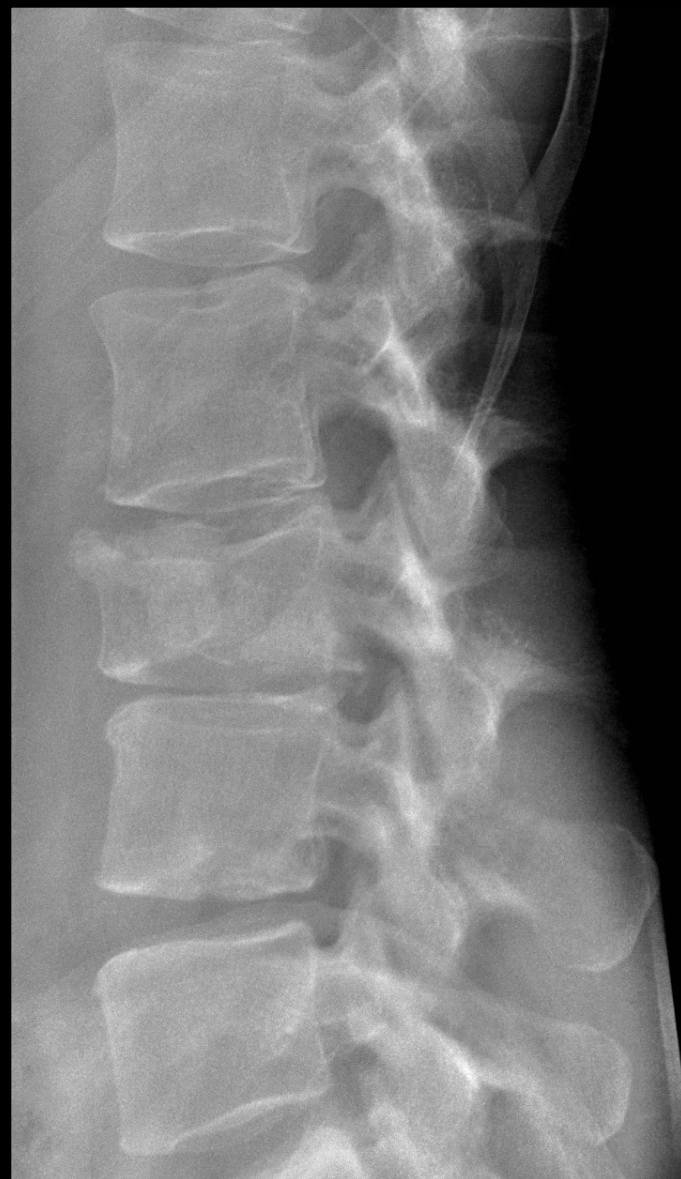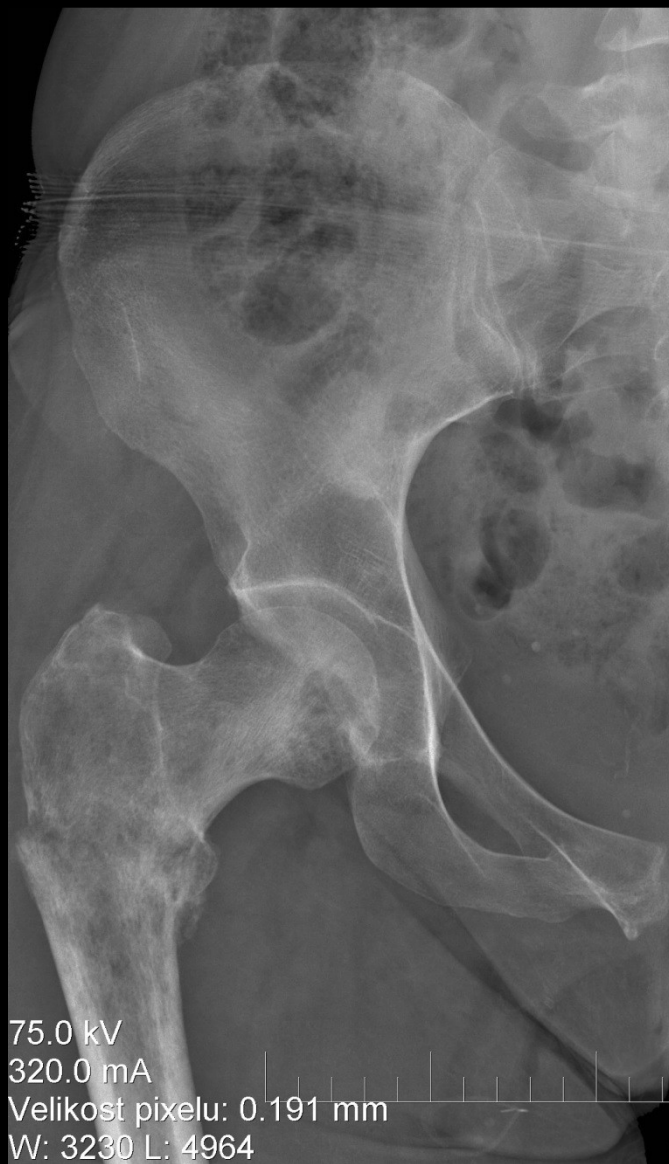Diagnostics

- History
- Radiological findings
- Scintigraphy
- Oncoscreening
- Biopsy

Complications

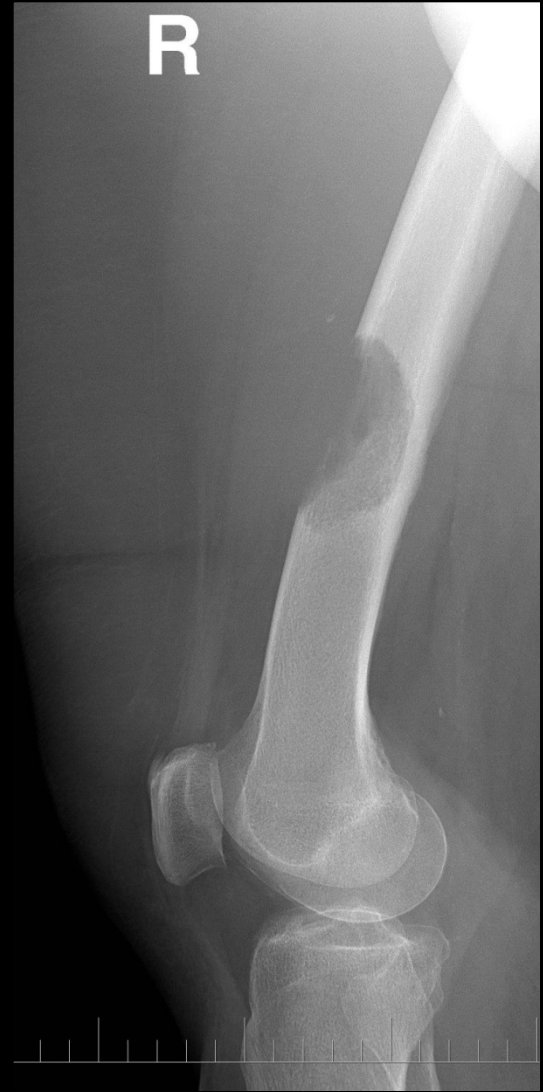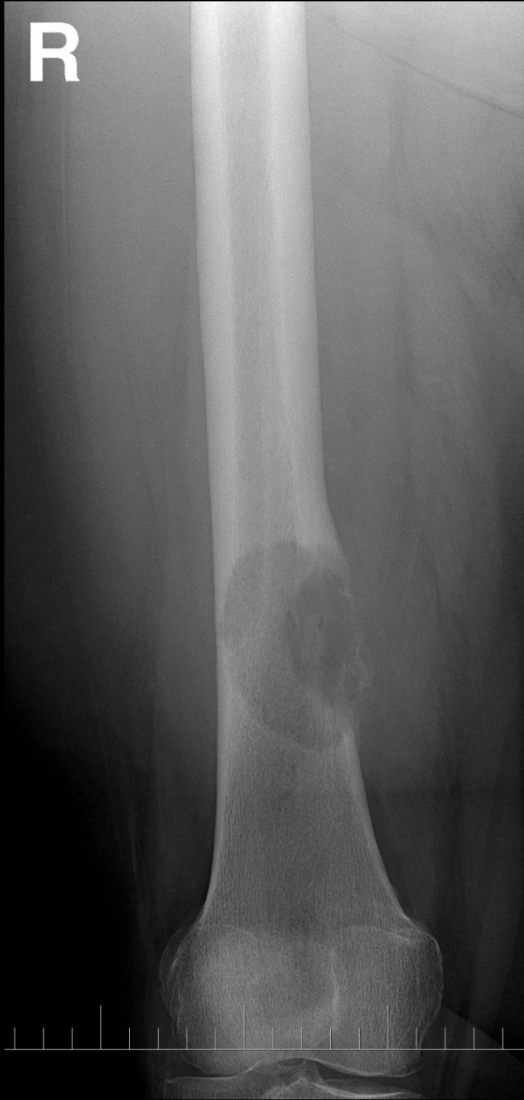- Pathological fracture
- Hypercalcemia
- Spinal cord lesion
- Anemia





Mirel's score- risk of pathological fx

Points	1	2	3
Localisation	Upper extremity	Lower extremity	Trochanteric region
Pain	Mild	Moderate	Severe
Type	Osteoplastic	Mixed	Osteolytic
Size	<1/3 of diameter	1/3 – 2/3 diameter	>2/3 diameter
≤ 7 points	Risk 4%		Preventive OS not indicated
8 points	Risk 15%		OS ??
≥ 9 points	Risk 33% and more		OS is indicated



Therapy

- Systemic therapy of carcinoma
 - Chemotherapy
 - Hormonal therapy
 - Immunotherapie, biological therapy ...
- Therapy of bone metastases
 - Bisphosphonates
 - Radioterapy
 - Surgery: radical, paliative
 - Conservative treatment
 - Others - RFA, embolisation ...
- Paliative management

Surgery of bone metastases

Radical surgery – solitary MTS
good prognosis

Simple surgery with mobilisation –
multiple metastases
• worse prognosis

Types of surgery in MTS

	Removal of tumor	operation
No		Intramedullary nailing
Curretage		Cementoplasty + osteosynthesis
resection		Total replacement Intercalary spacer
Amputace		No
Spinal surgery		Instrumentation + fusion