

# Clinical examination in orthopaedics

Z. Rozkydal

L. Pazourek

# Clinical examination

The aim- establish the diagnosis

1. History
2. Objective examination - general
3. Objective examination - local
4. Laboratory tests
5. Imaging methods

# History

Family

Personal

Pharmacological

Social

Occupation

Epidemiological

Current problems

Analysis of pain

# Family

- Congenital abnormalities
- Important diseases in family (heart, DM, haemophilia, oncological diseases, neurological diseases, TB)
- Birth, miscarriage

# Personal

- Important general diseases (hypertension, DM, heart, tumors, lung problems)
- Coagulopathies
- Infections
- Injuries: consequences, complications
- In children- pregnancy, birth  
psychomotor development

# Current symptoms

## Local

Pain, motor function, limping, deformity, ROM, swelling, loss of sensation

General: fever, shivering, cachexia

## Cause of the problem

- injury
- overloading
- Infection
- systemic diseases (endocrine, metabolic, inflammation, neurological, haematological.)

- Development of symptoms
  - Onset, duration
  - Intensity
  - Aleviation, increasing factors
- Management in the past time
  - Examination in the past time
  - Conservative therapy
  - Operative therapy
- Mobility, occupation
- Emotions, psychological condition
- Simulation, dissimulation, aggravation

# Analysis of pain

Intensity, frequency, duration

Acute, chronic

Local, irradiating

Visceral

Type- sharp, blunt, burning, stubbing

Neuralgia

Nerve root pain

Phantom pain

Neurogenic claudication



# Analysis of pain

Localised, diffuse

Psychological background

During activity or in rest

VAS – visual analogue scale

Scale of ten degrees

0 - no pain

10 - the most severe pain not bearable

Pain 5 or more- change of management

# Pharmacology

- Medicines used currently
- Important medicines: warfarin, heparin, other anticoagulants, antiepileptics, cytostatics, immunosuppressives, NSA, corticoids, biological treatment
- Alcohol, smoking, drugs
- Allergy (antibiotics, metal, disinfection liquids, iodine)

# Occupation and social

- Occupation, type of work, manual labor
- Rent
- Social situation (living, marriage)

Management after discharge

# Gynecological history

- Cycles, gravidity, menopause, current gynecological problems
- Epidemiological history  
influenza, viral infections, herpes simplex, focal infections (UTI, stomatological infections, ulcers, erysipiel)

# **Objective examination**

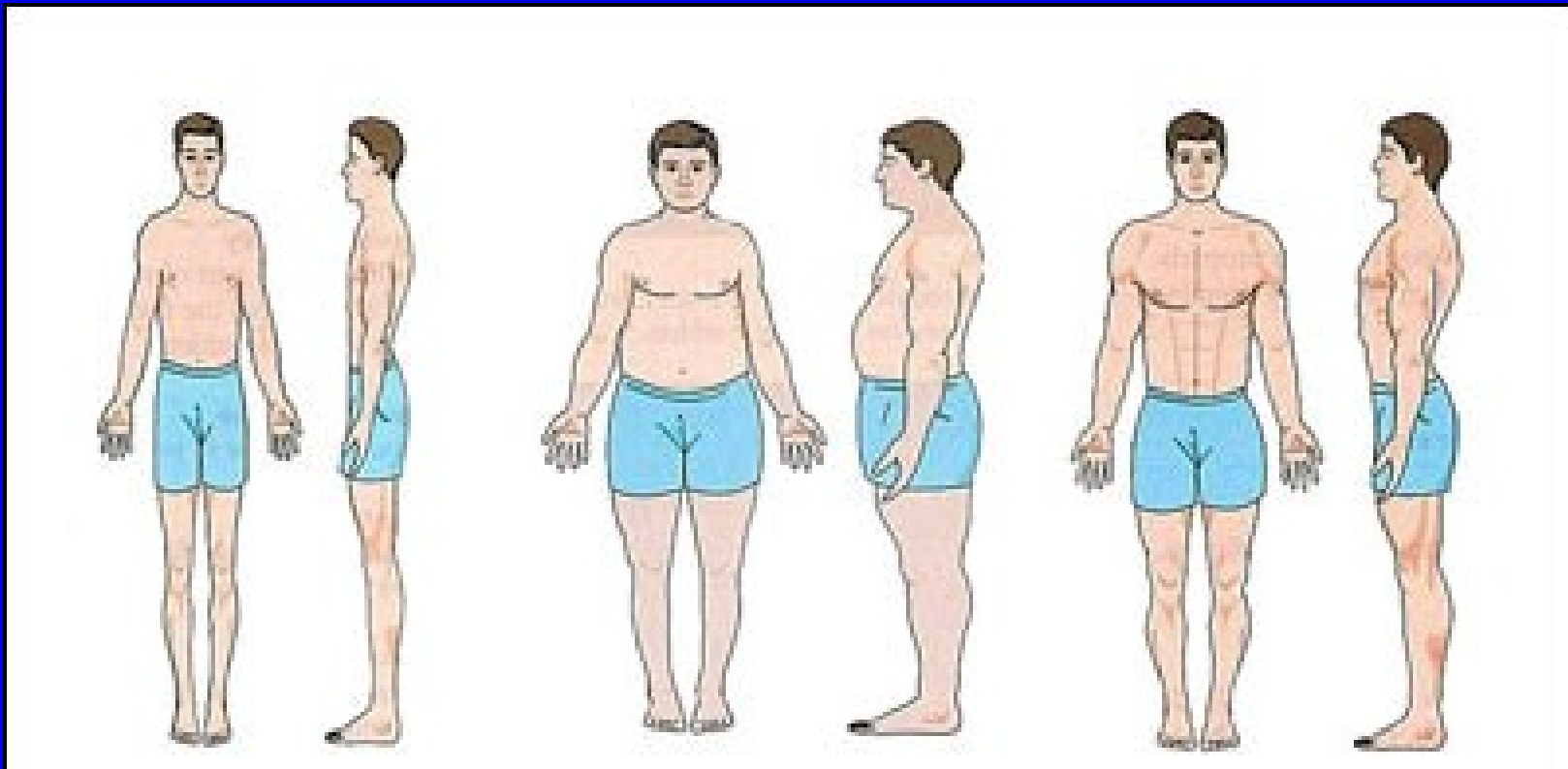
General examination

General orthopaedic examination

Local orthopaedic examination

Posture and gait

# Somatotype



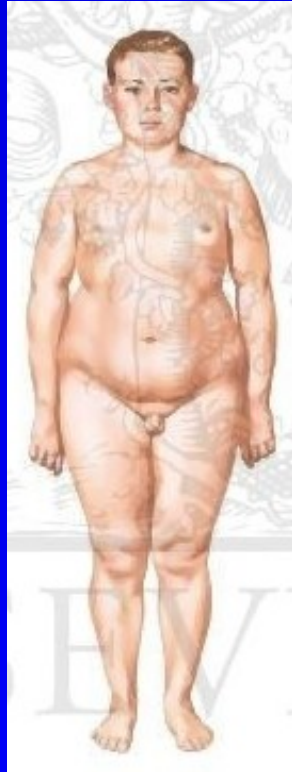**asthenic**

**pycnic**

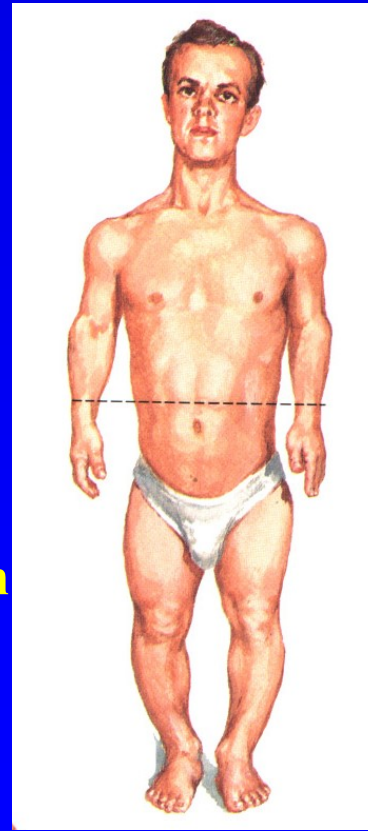
**normosthenic**



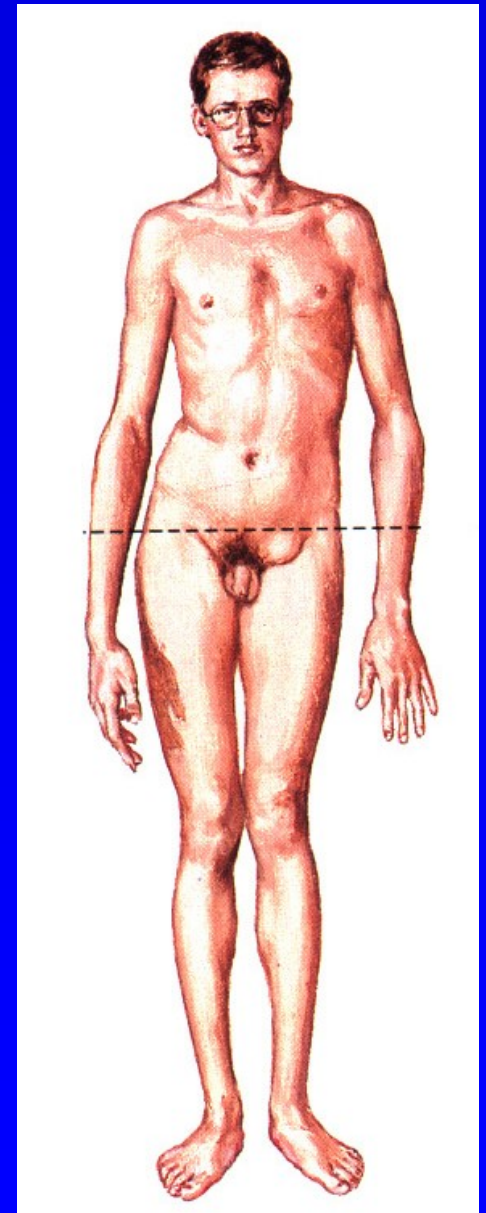
**Gigantisms**



**Fröhlich syndrom**



**Achondroplasia**



**Marfan syndrom**



**Nanisms**

# Nutrition

- **Body mass index:**  $\frac{\text{weight kg}}{\text{height}^2 \text{ m}^2}$   
(BMI)
- Below 20 - cachexia
- 20-25 - normal weight
- 25-30 - overweight
- 30-35 - obesity
- Over 35 - severe obesity

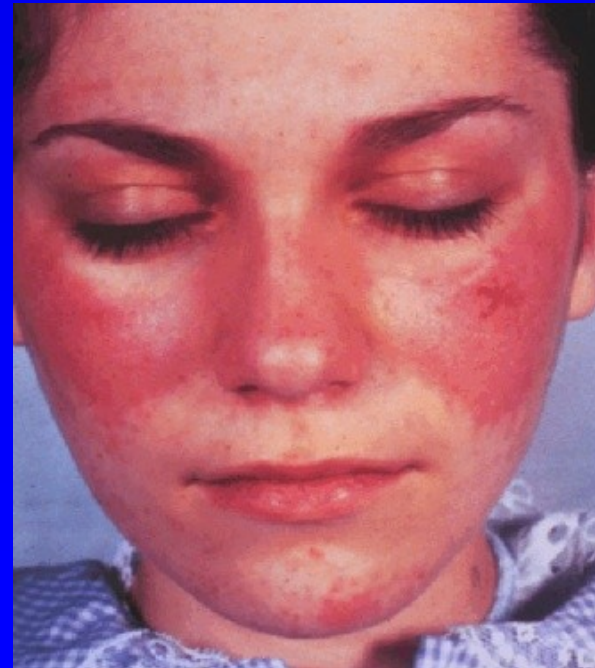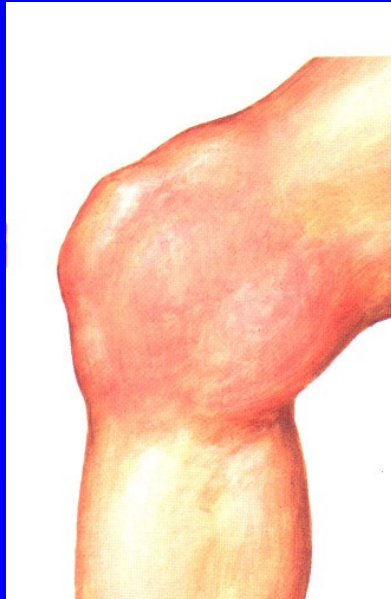


# Body Mass Index- recent data

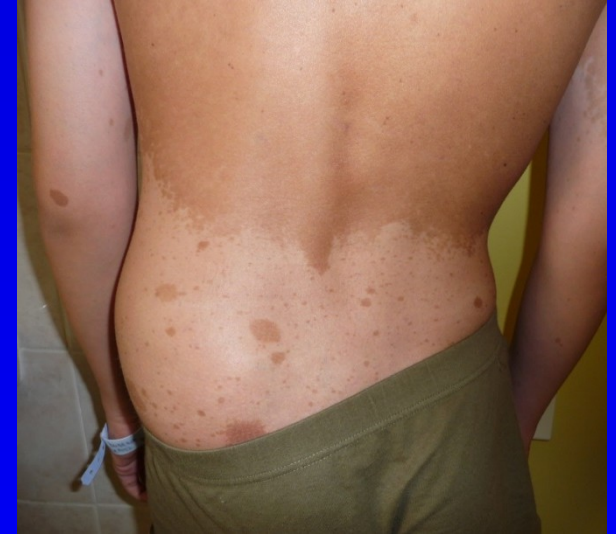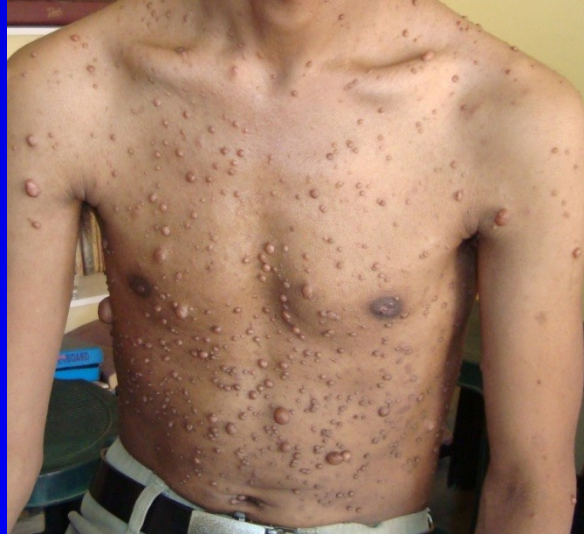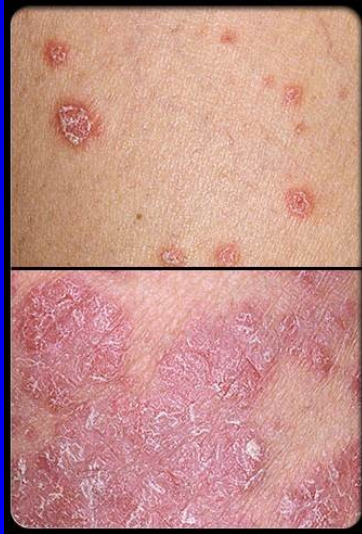	Stages
těžká podvýživa	$\leq 16,5$
podváha	16,5–18,5
ideální (zdravá) váha	18,5–25
nadváha	25–30
mírná obezita	30–35
střední obezita	35–40
morbidní obezita	$> 40$

# Skin

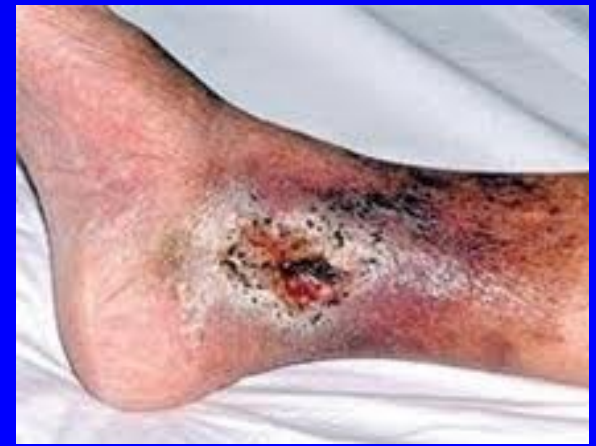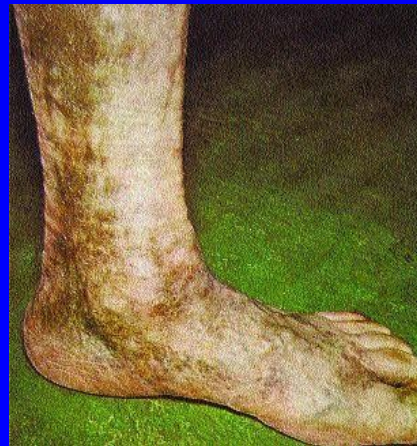
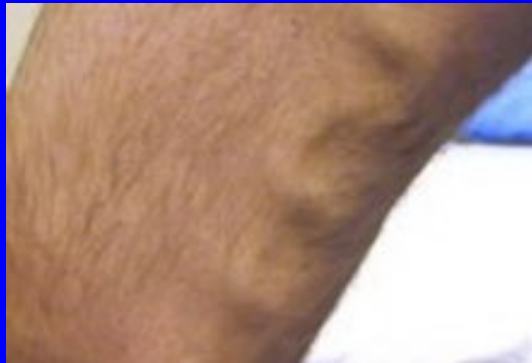- Colour



- pigmentation, naevus



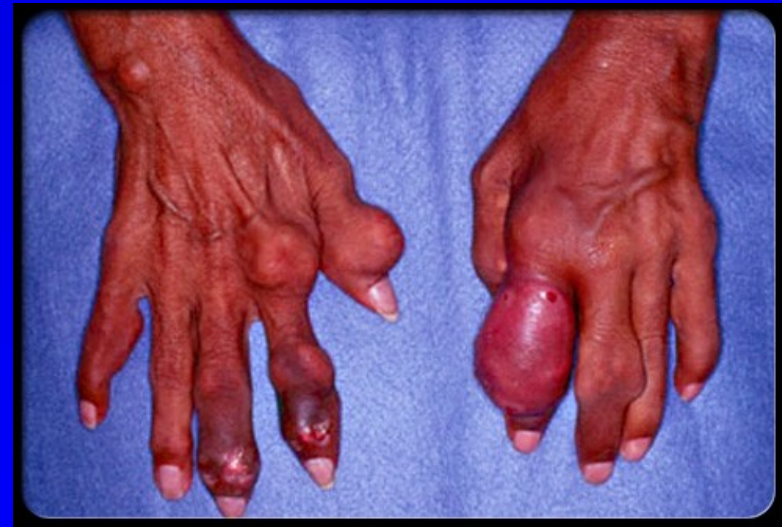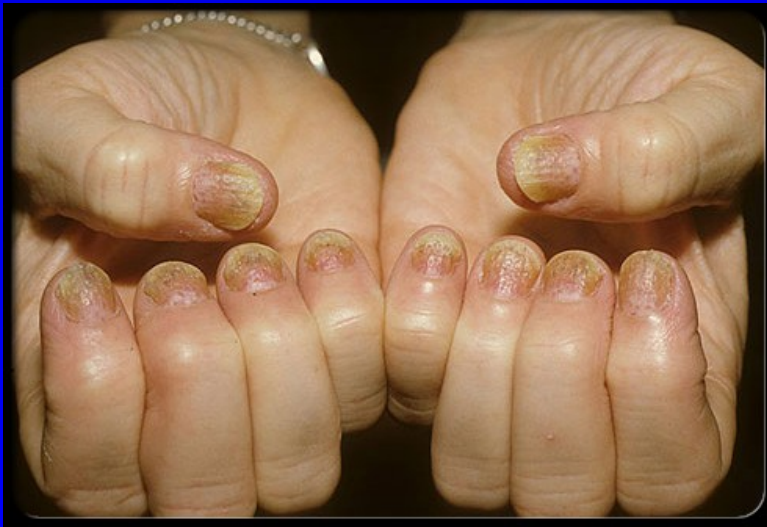- Trophicity, turgor



- Fistulas, ulcers

- Subcutaneous nodes

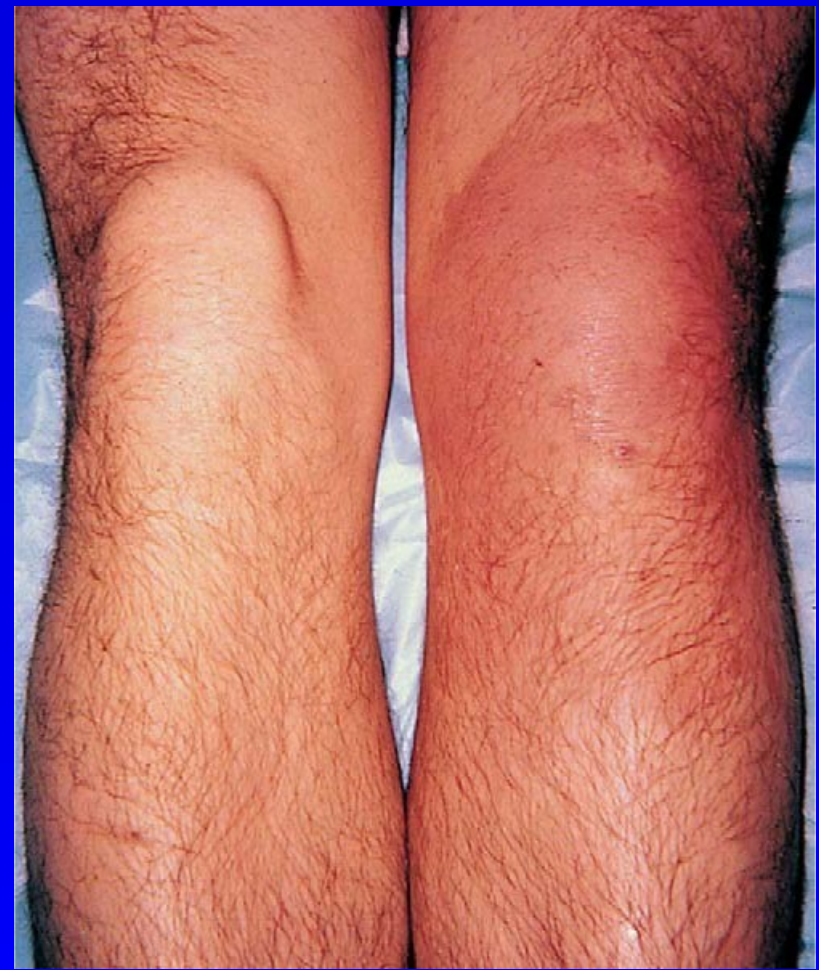- nails



- Lymfadenopathy, soft tumors, inflammations

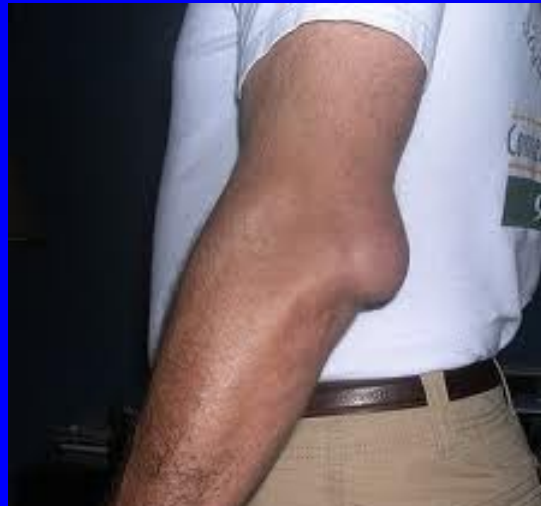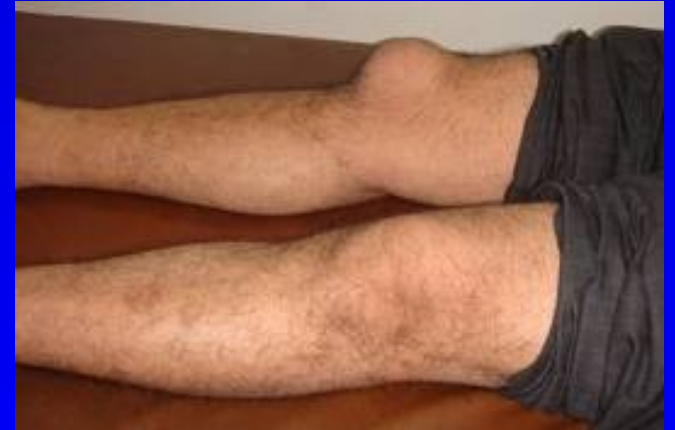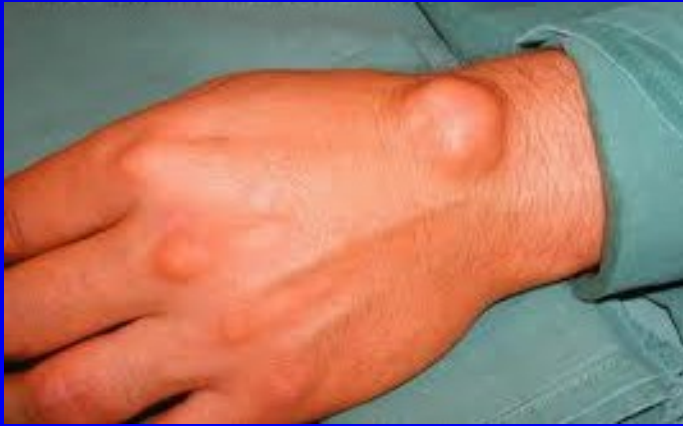# Swelling

- Local
- General
- Decollement

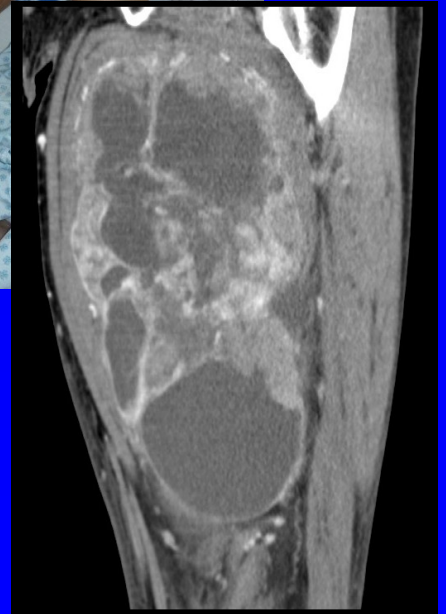
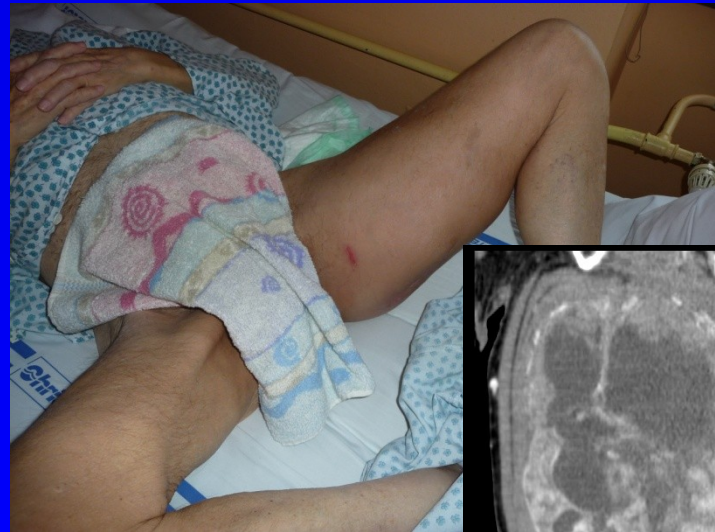
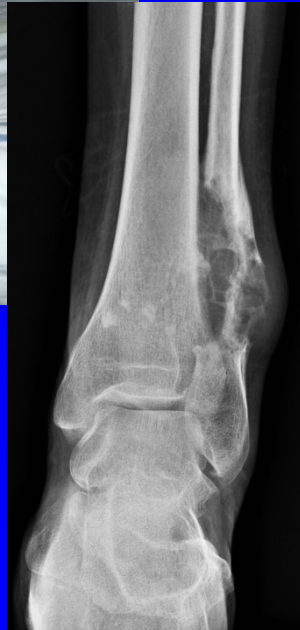
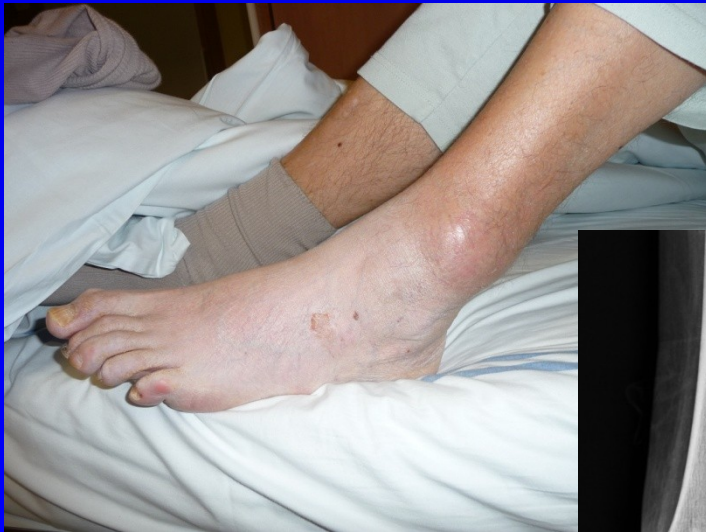**Local signs of inflammations:**  
redness, swelling, pain, warm, limited  
function, soft mass, effusion, discharge

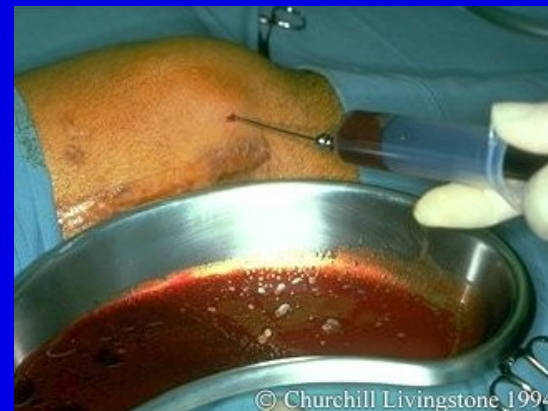
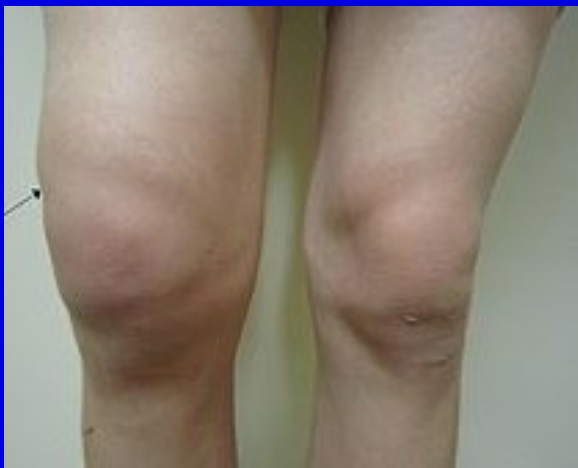# Soft mass



- Haematoma
- Lymphonodes
- Tumor



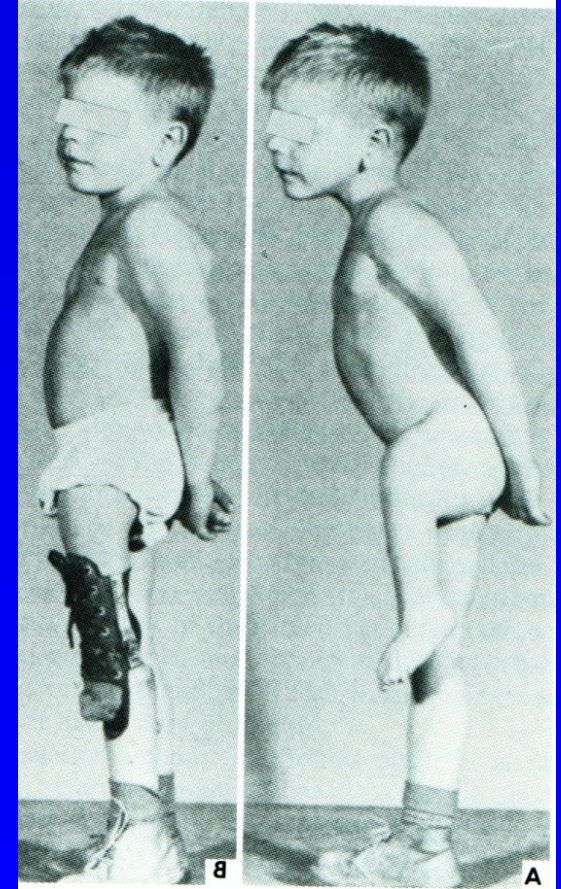
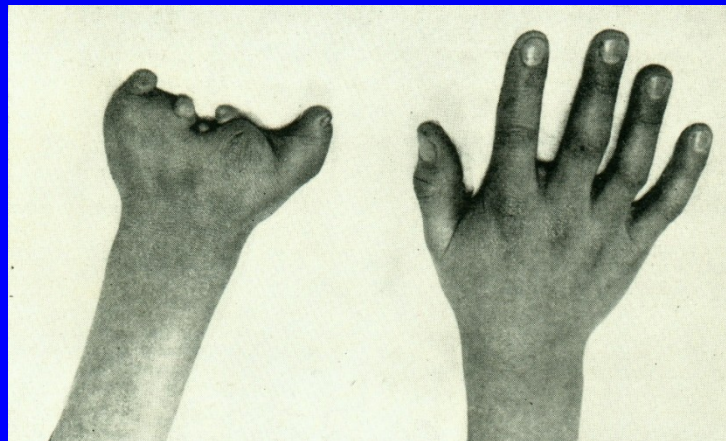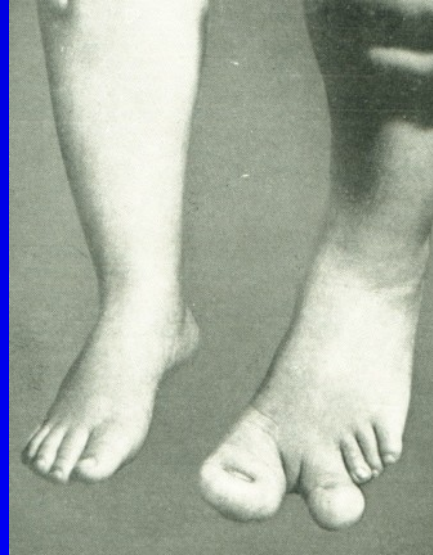
# Effusion





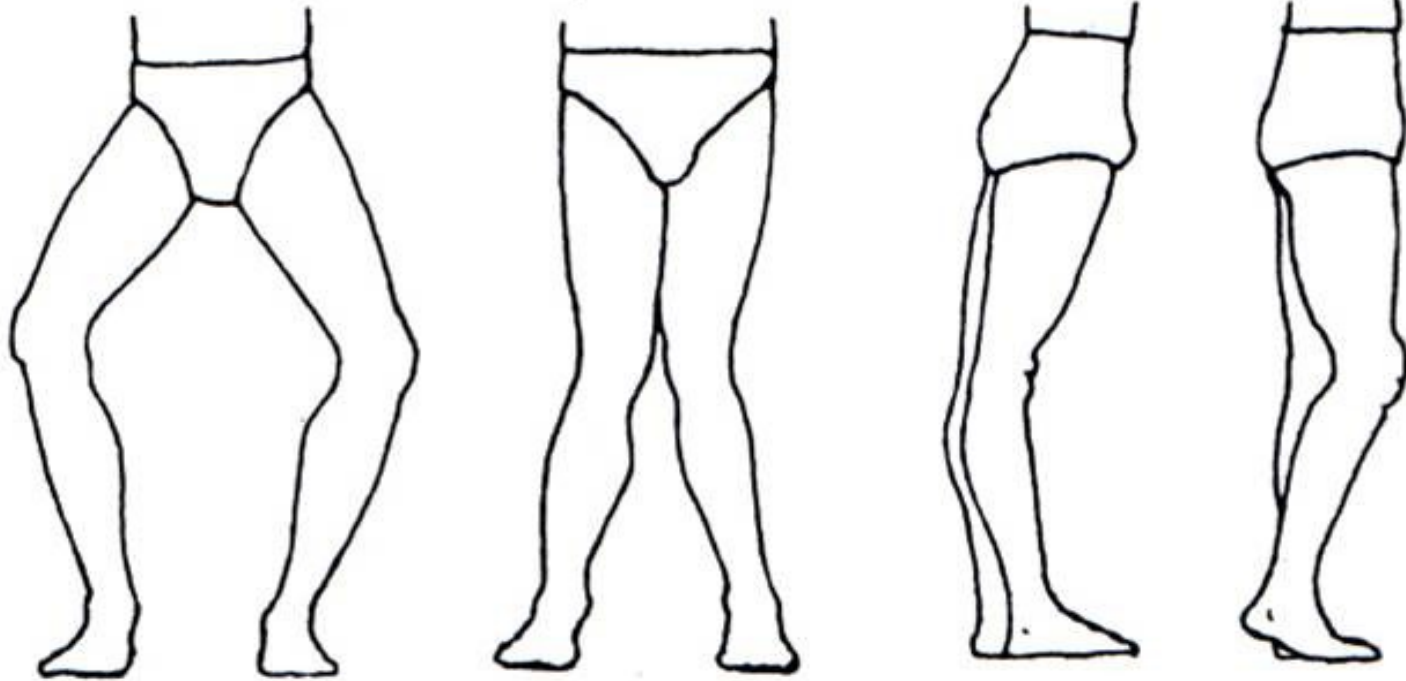
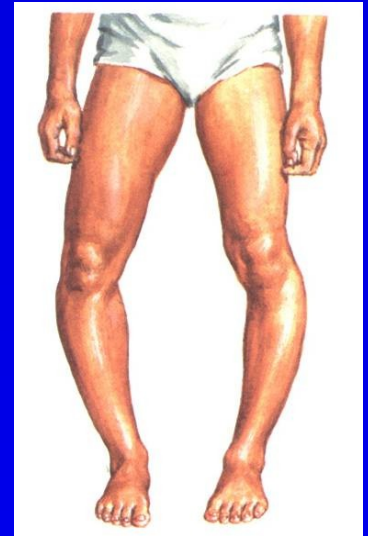
# Congenital deformity

- 1. Shape, size
- 2. Differential
- 3. Duplicity
- 4. Gigantisms
- 5. Hypoplasia



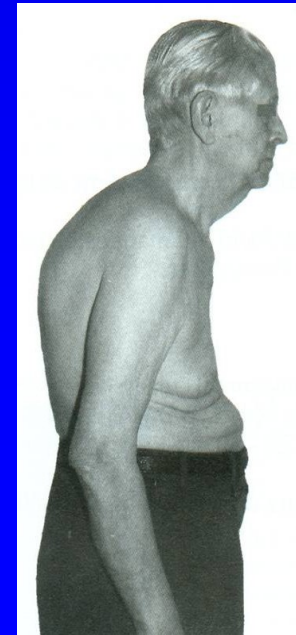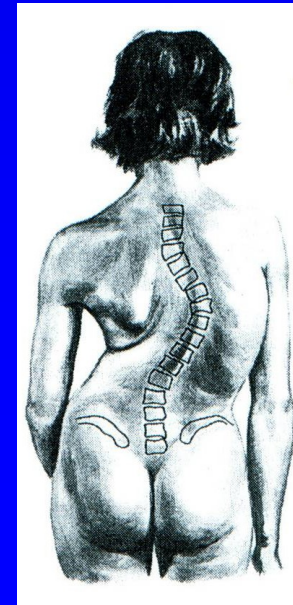
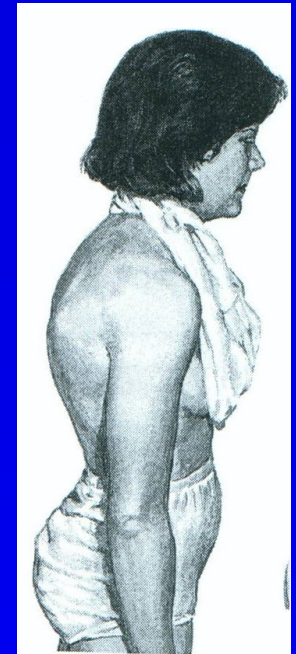
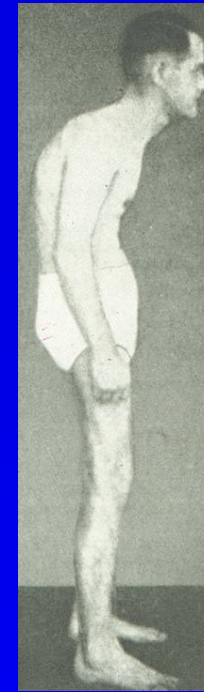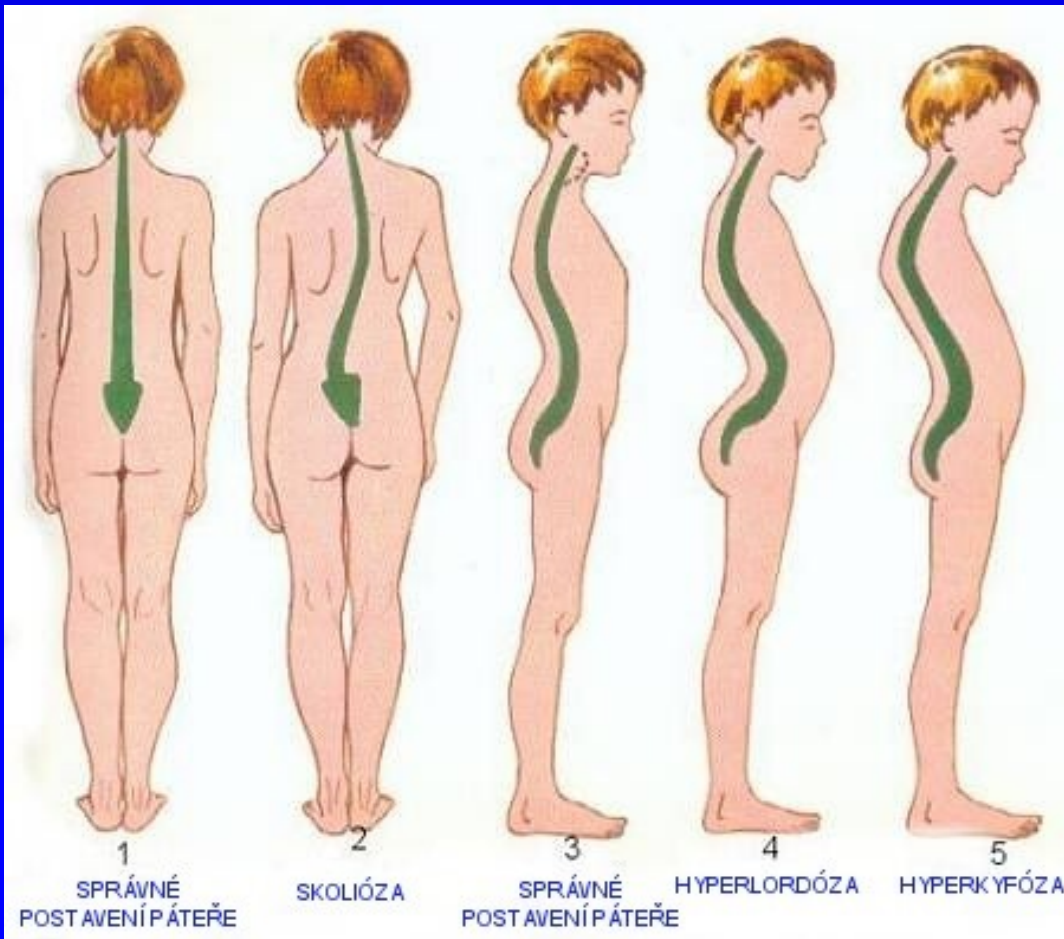
# Malalignment

- varus x valgus
- antecurvation x recurvation
- rotation deformity

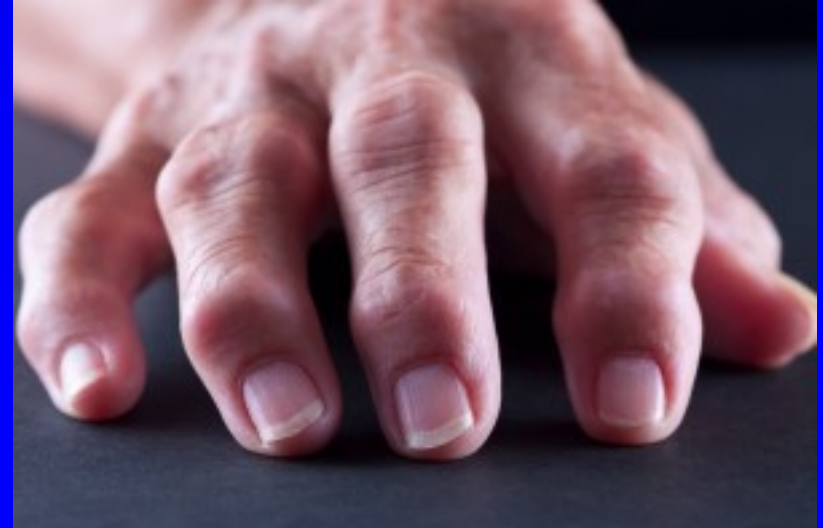
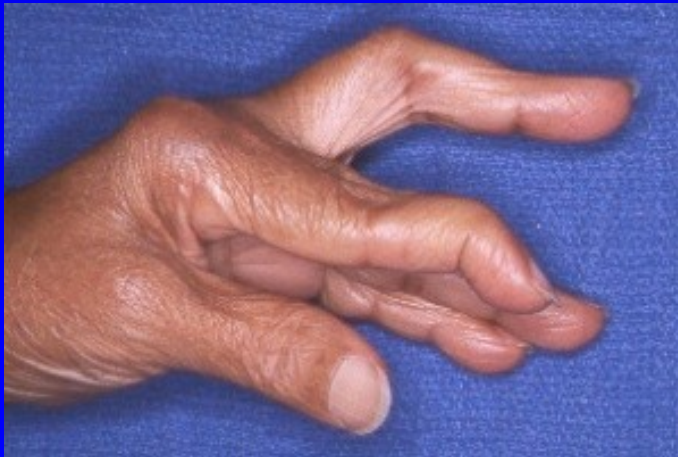
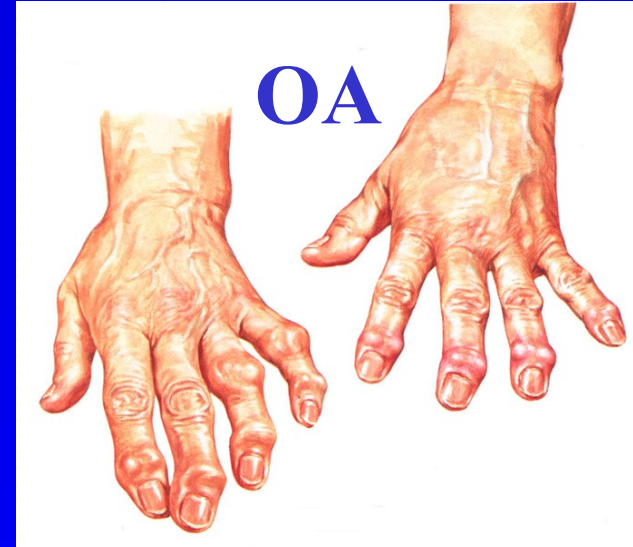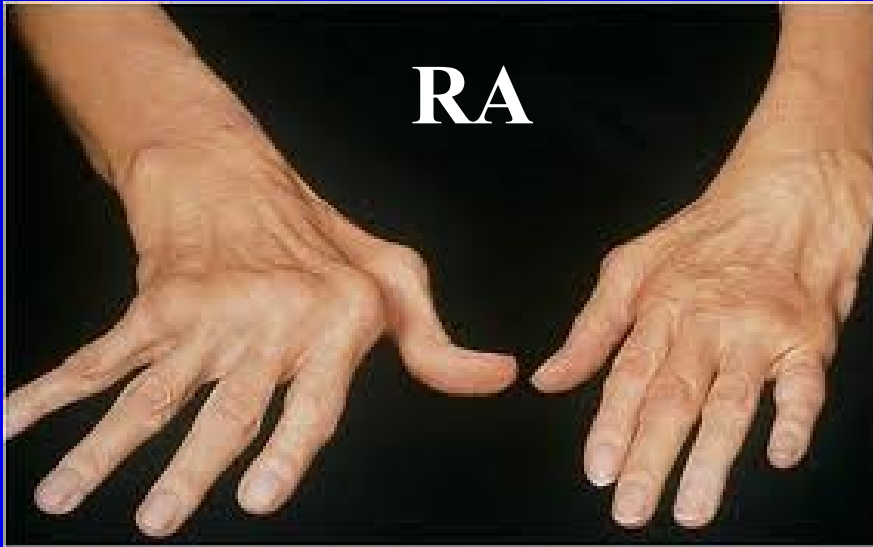# Deformity of spine

- Scoliosis
- Hyperkyphosis, hyperlordosis



# Hand deformities



Boutonniere deformity  
Swan neck deformity

# Foot deformities



Talipes cavus



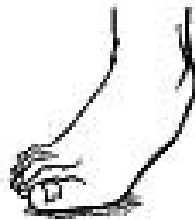
Talipes equinus



Talipes calcaneus



Talipes valgus



Talipes equovalgus




Talipes calcaneovalgus



Talipes varus



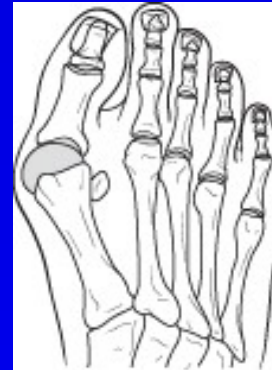Talipes equinovarus



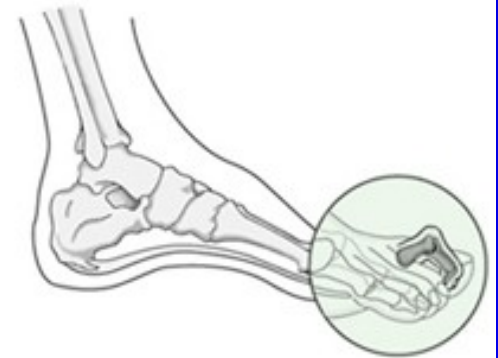
Talipes calcaneocavus



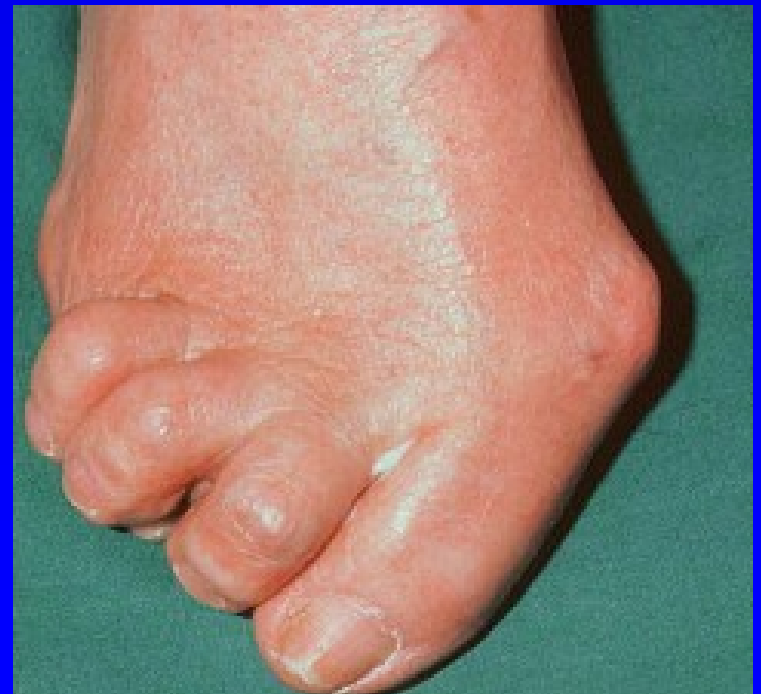Talipes cavovarus



Bunion



Clawtoe



# Length of extremity

## Lower extremity

- Spinomaleolar distance
- Umbilicomaleolar distance
- Support during standing
- X- ray of the hip, knee, ankle joint

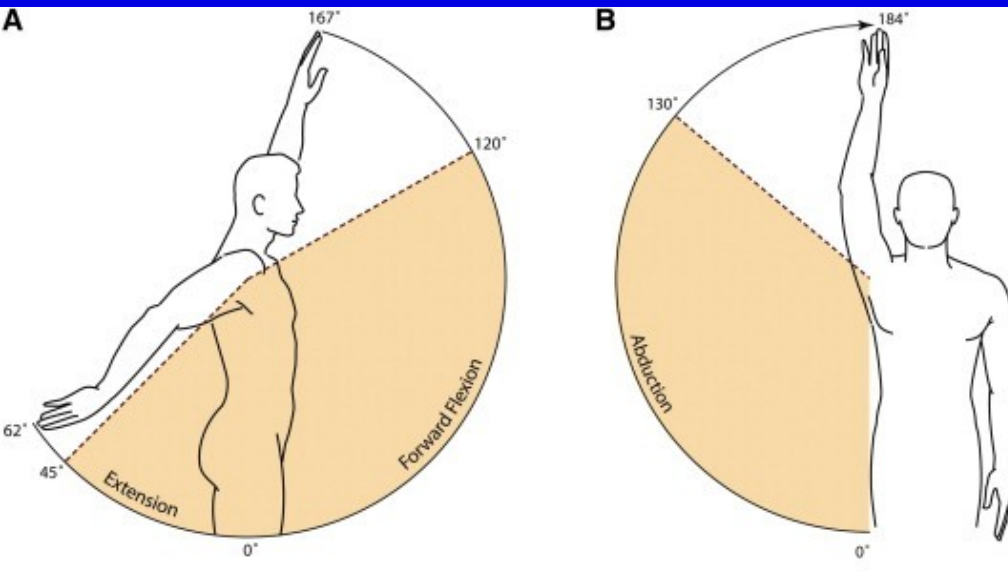
Upper extremity: acromion- 3. finger

- Circumferential measurement

# ROM

- Active and passive movements
- **S**agittal
- **F**rontal
- **T**ransversal = horizontal
- **R**otation

# Shoulder



**S:** extenze - 0 - flexe

50 - 0 - 180

**F:** abdukce - 0 -  
addukce

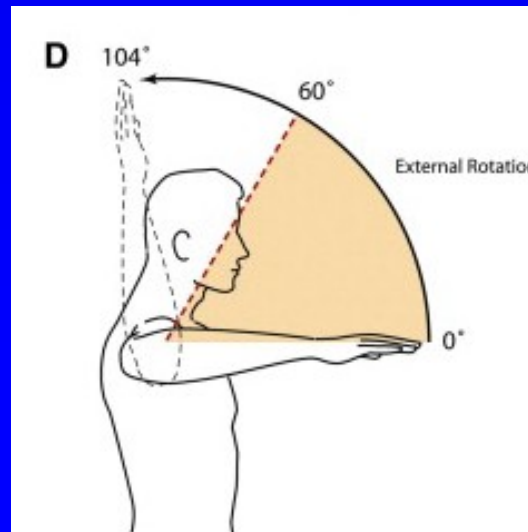
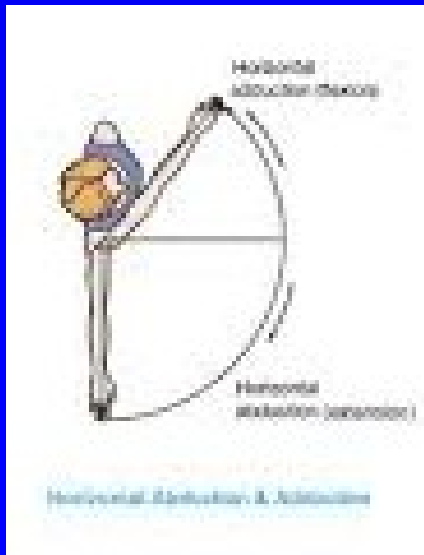
180 - 0 - 25

**T:** abdukce - 0 -  
addukce

110 - 0 - 30

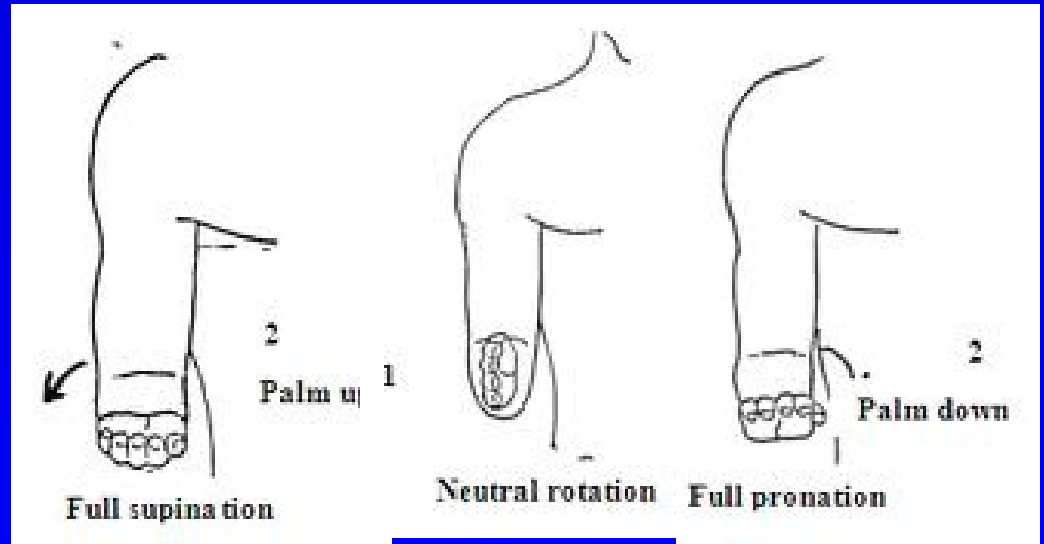
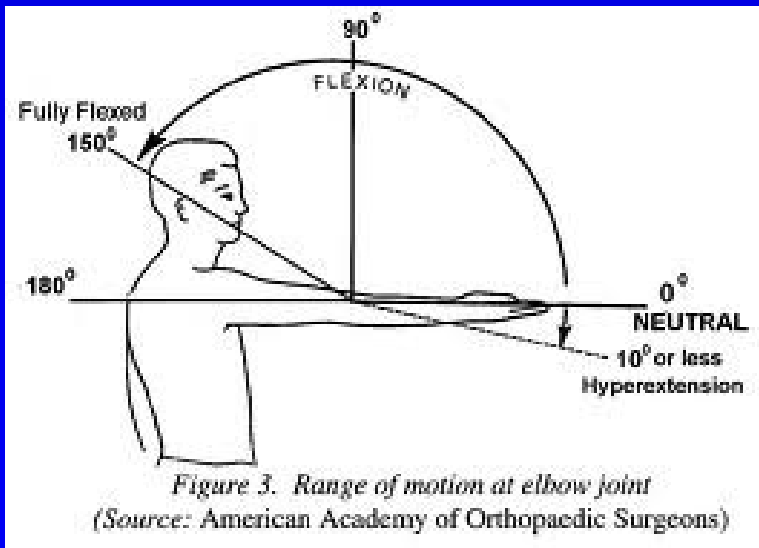
**R:** ZR - 0 - VR

90 - 0 - 90





# Elbow

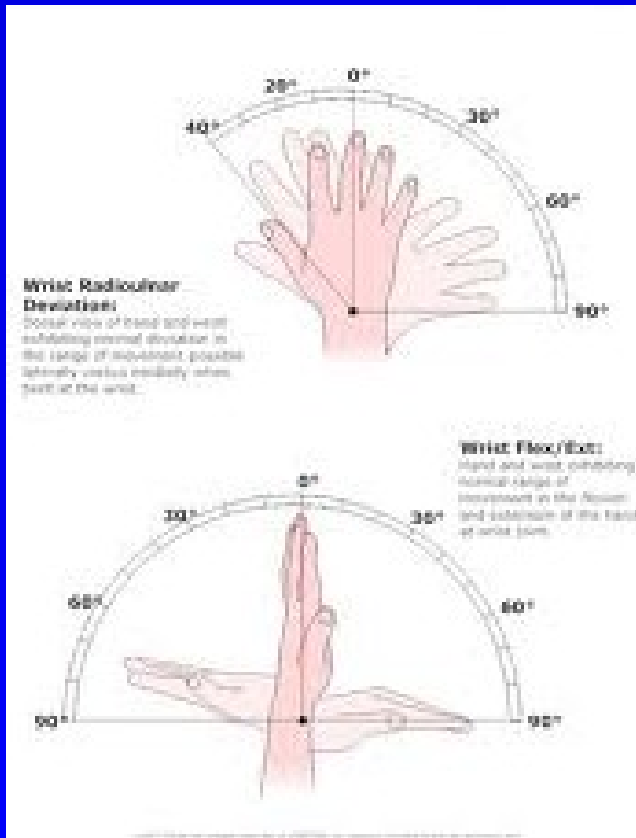


**S: extenze - 0 -  
flexe**

**10 - 0 - 150**

**R: supinace - 0 - pronace  
90 - 0 - 90**

# Wrist



**F: rad. dukce - 0 - uln. dukce**

**20 - 0 - 40**

**S:extenze (dorz. flexe) - 0 – flexe (palm. flexe)**

**80 - 0 - 80**

# Hip

**S:** extenze - 0 - flexe  
15 - 0 - 140

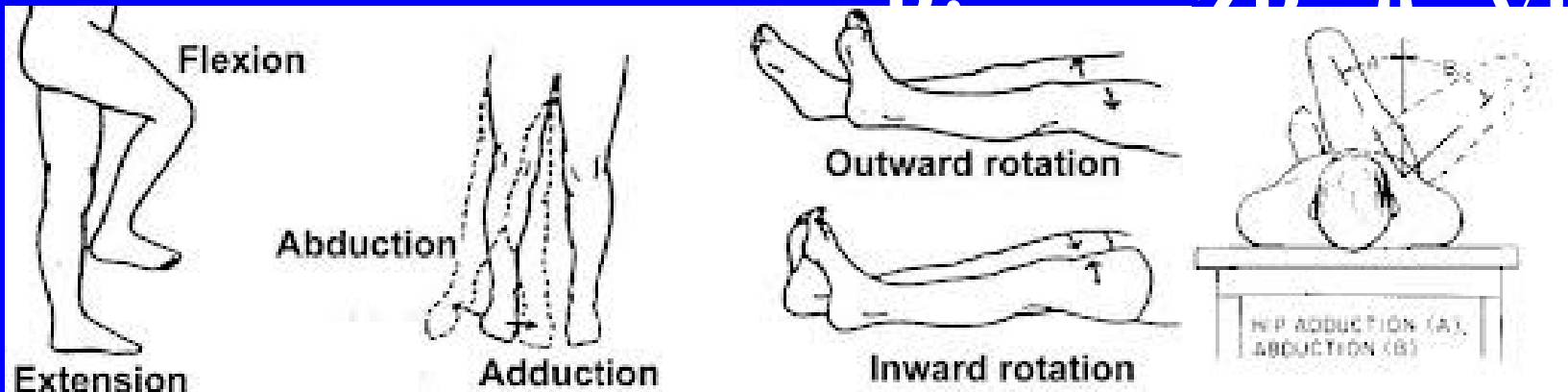
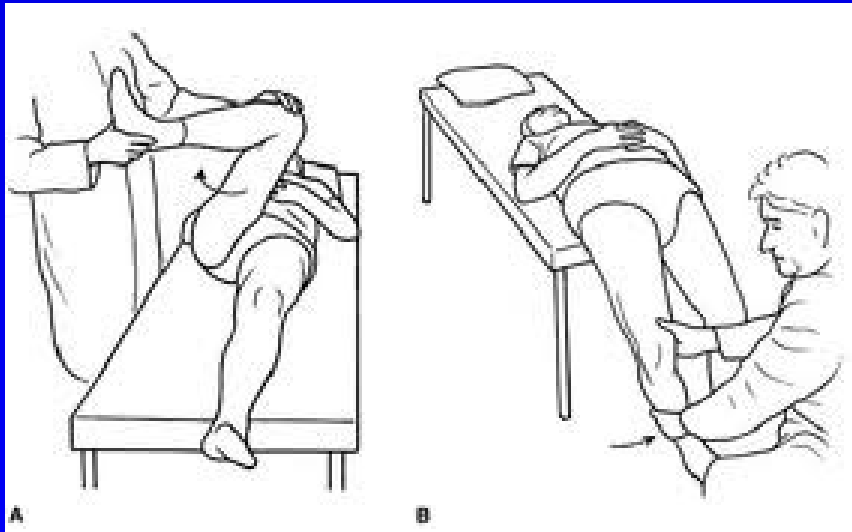
**F:** abdukce - 0 -  
addukce

60 - 0 - 40

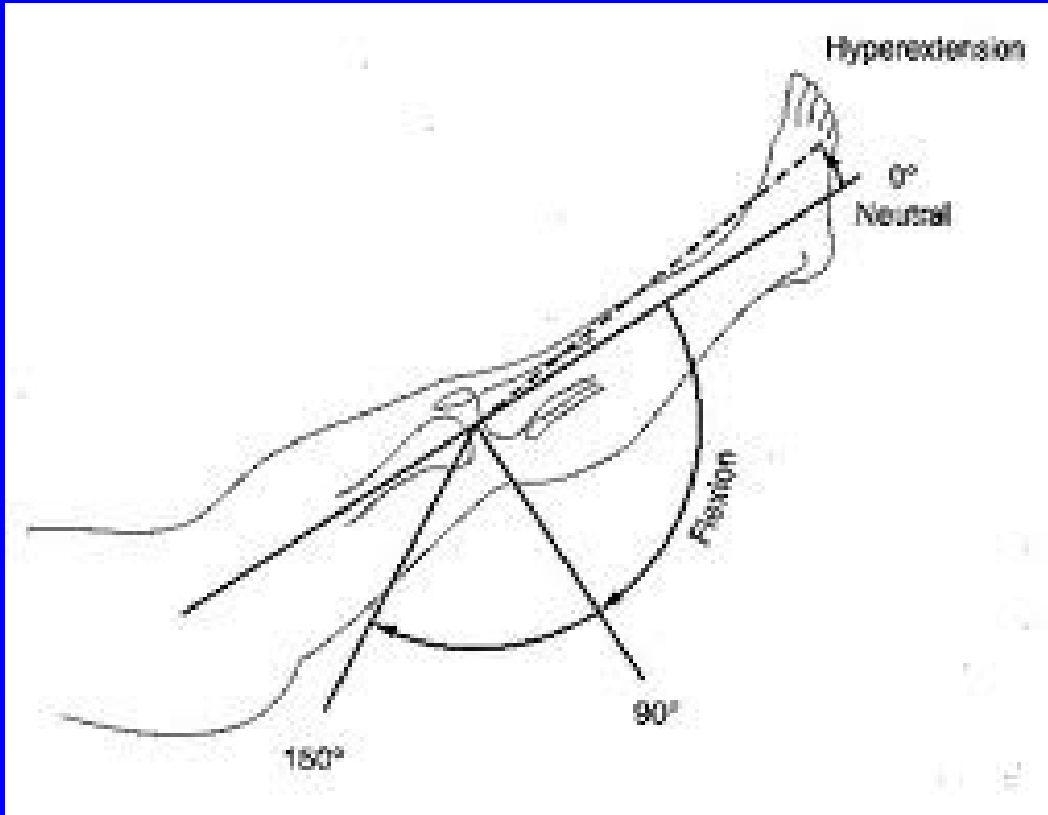
**T:** abdukce - 0 -  
addukce

80 - 0 - 30

**D:** ZD 0 VR



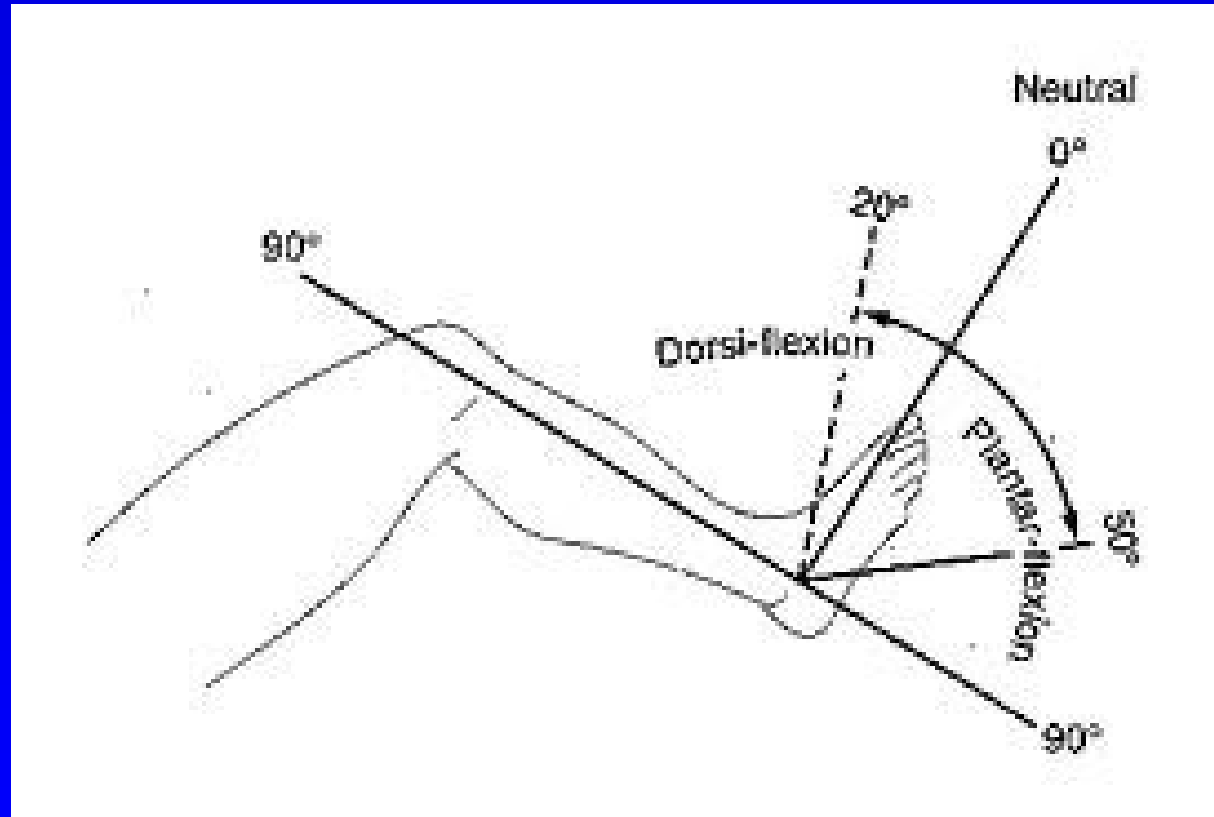
# Knee



**S: extenze - 0 -  
flexe**

**0 - 0 - 140**

# Ankle

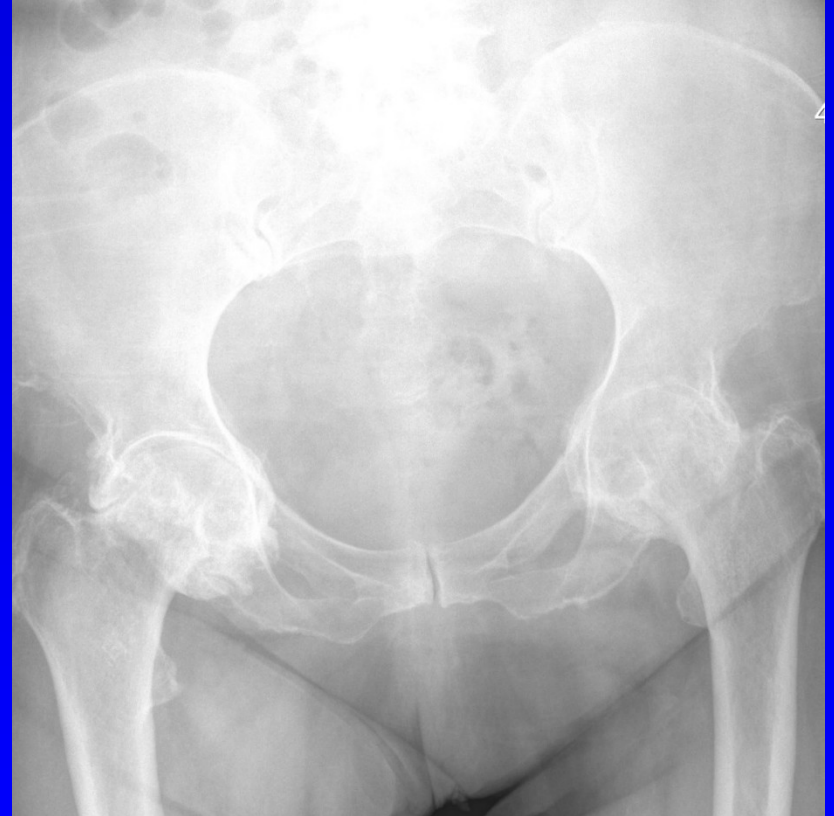

**S: extenze (dorzi flexe) - 0 - flexe  
(plantiflexe)**

**20 - 0 - 50**

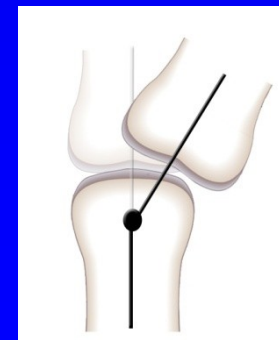
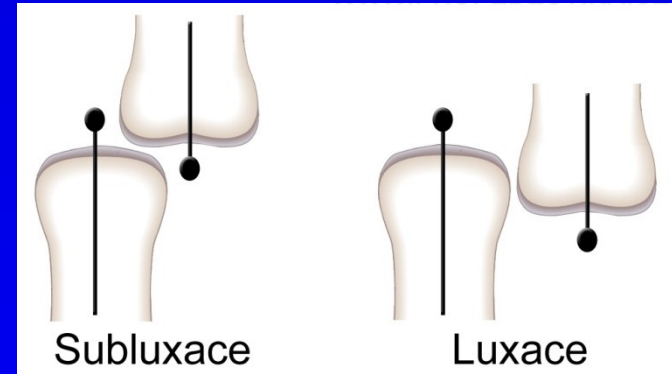
# Ancylosis

- **Extrarticular**
- **Intraarticular**



# Stability of joints

- Stable joint
- Unstable joint
- Instability
  - acute
  - chronic
  - habitual

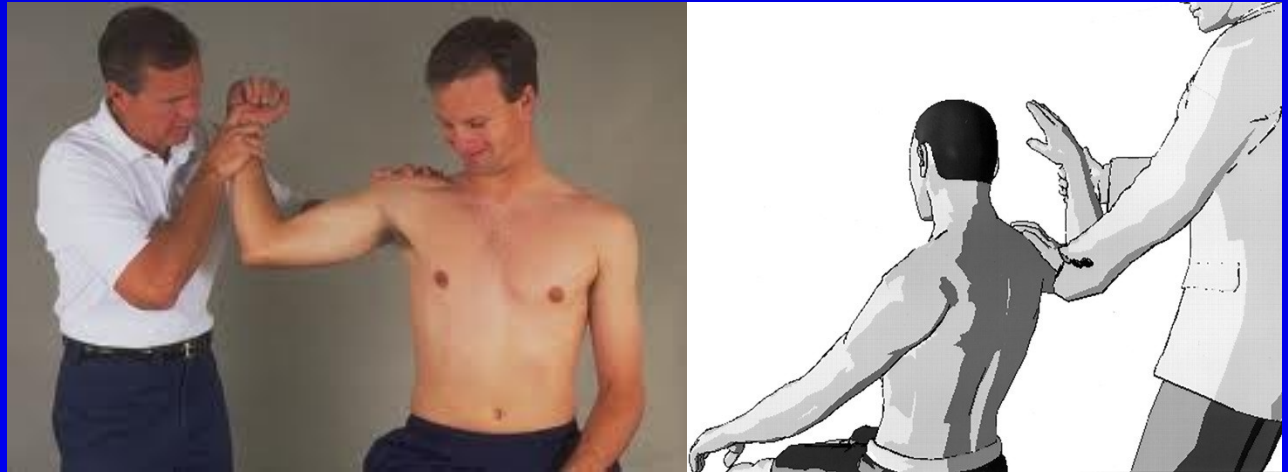


Deviace

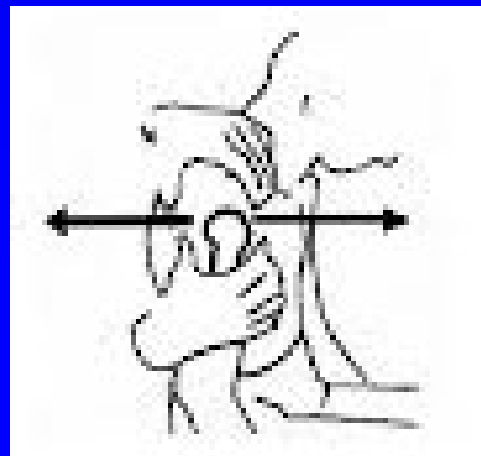
Desaxace

# Shoulder

**Apprehension test**



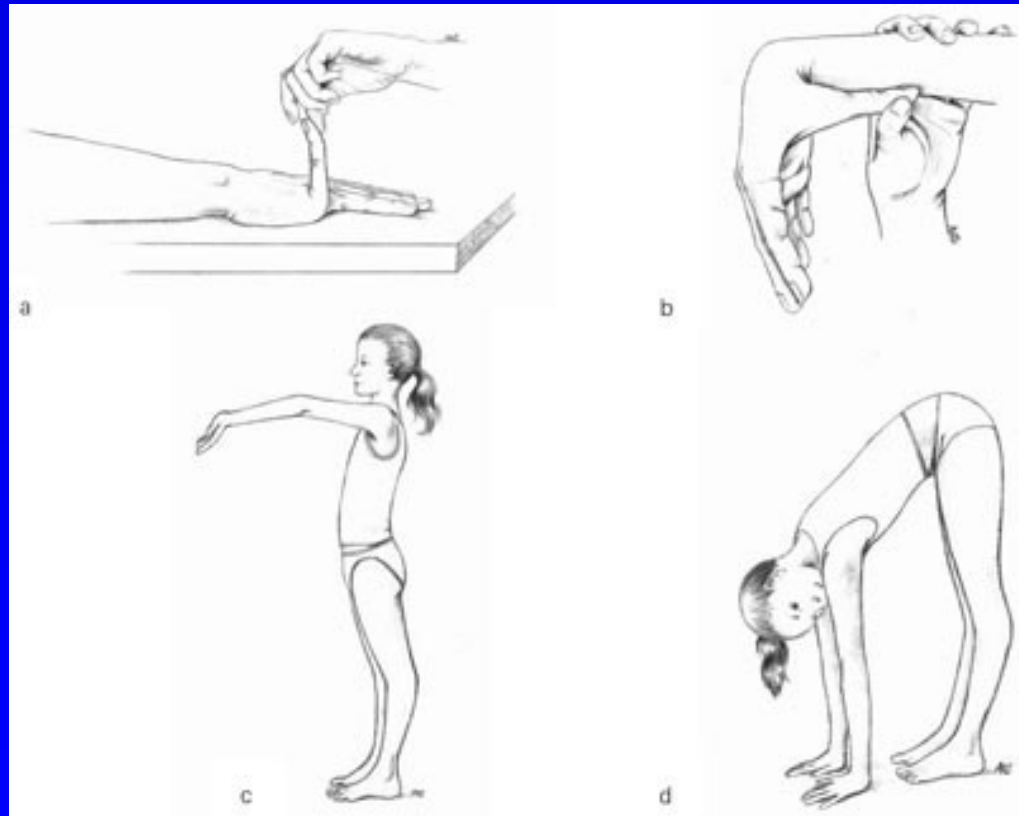
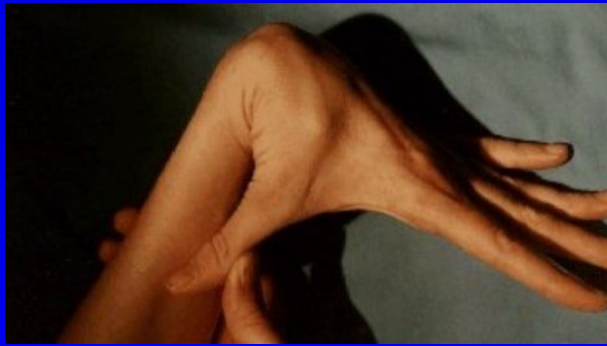**Drawer sign**







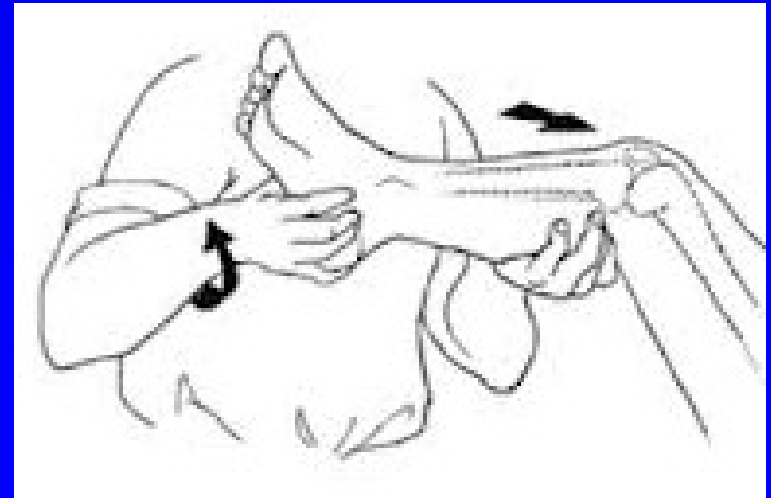
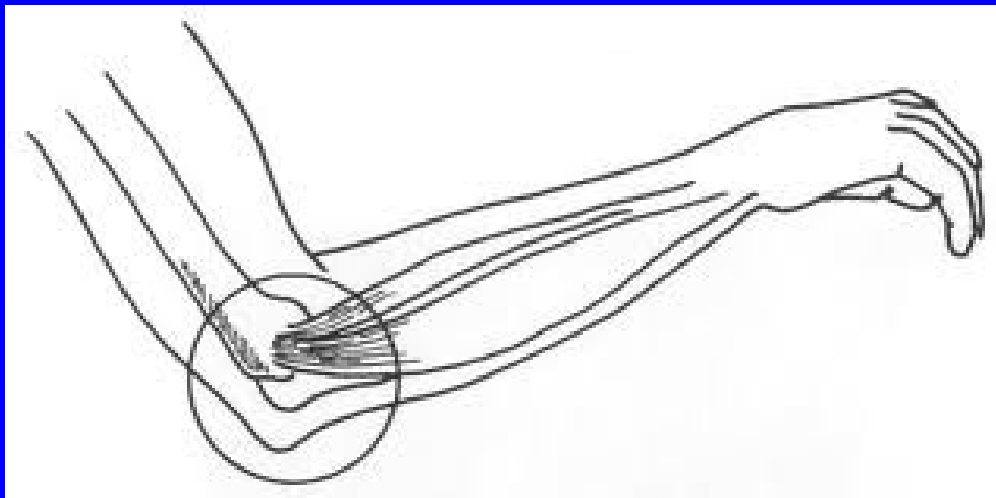
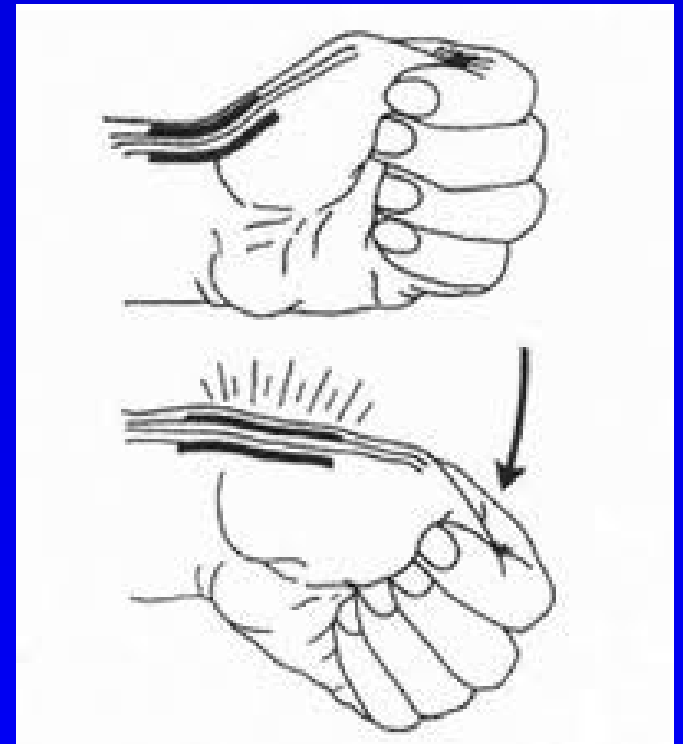
# Laxity



- test

# Maneuvers

- Maneuvers

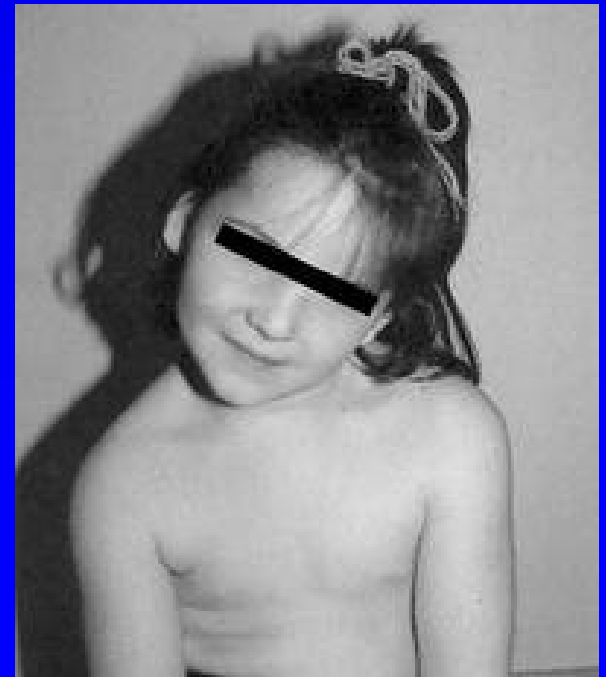
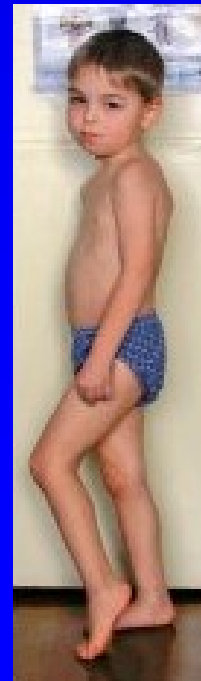
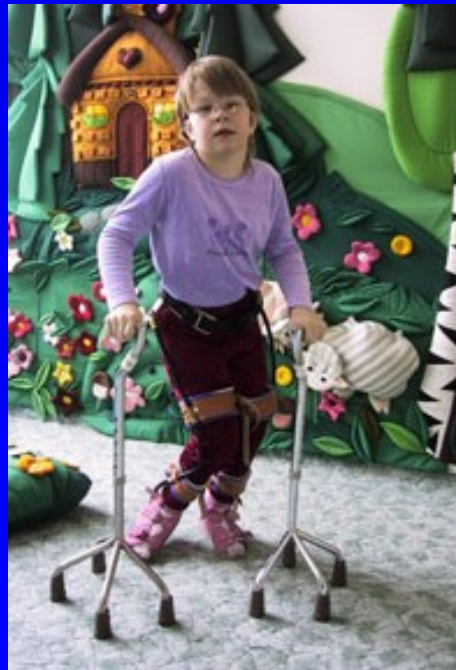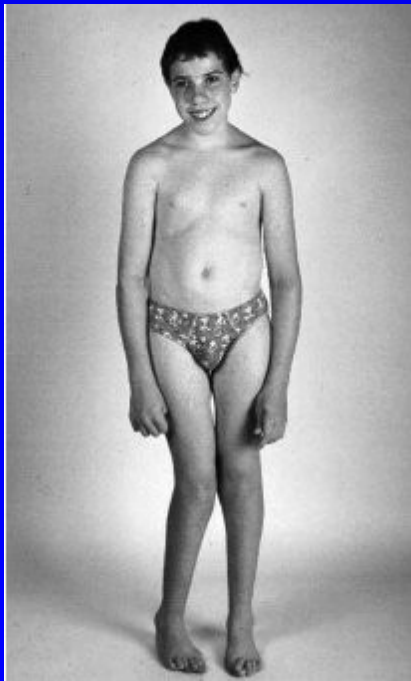# Sound phenomenons

- Crepitus

# Contracture

- Lumbago, torticollis
- Cerebral palsy



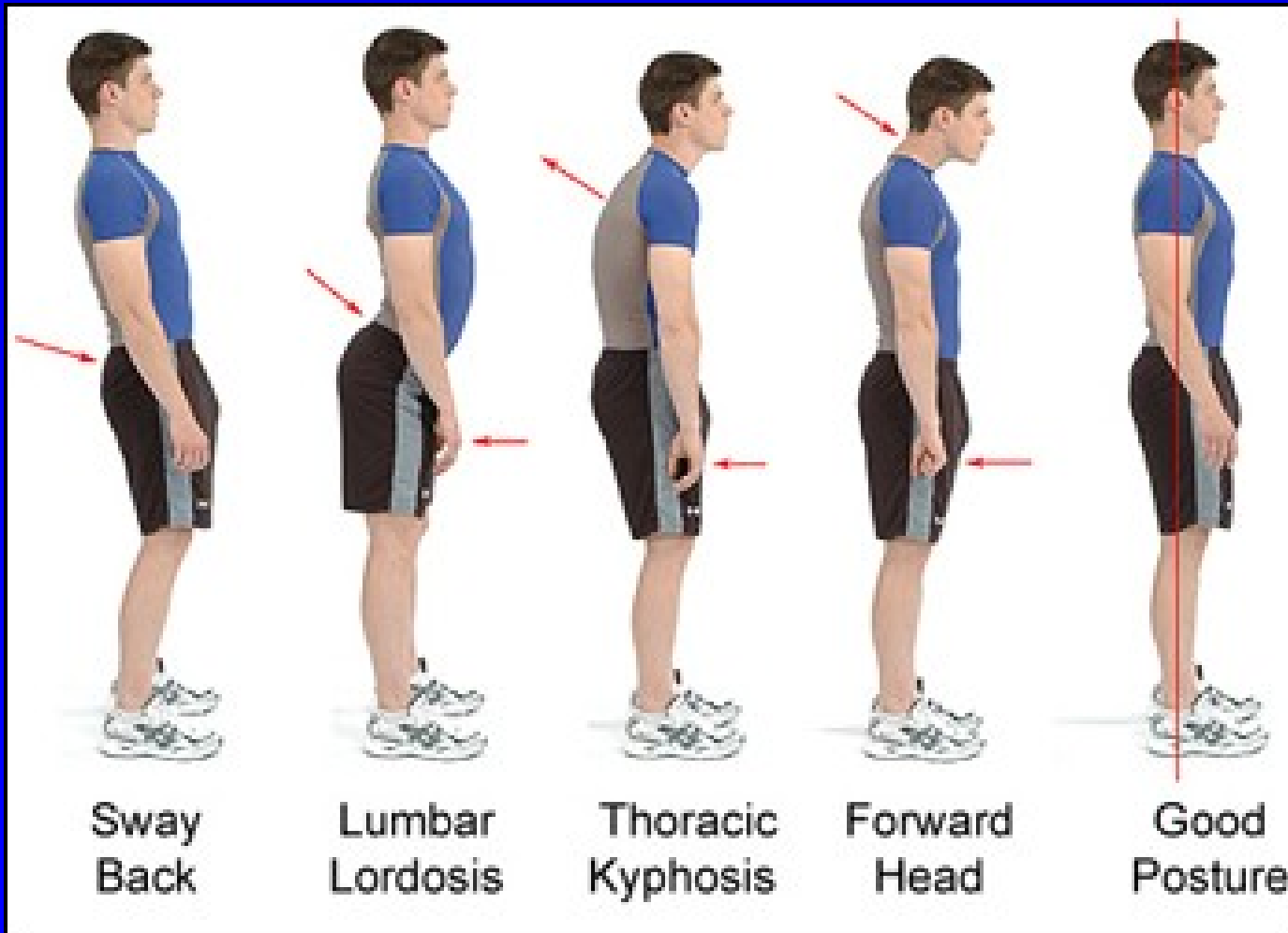
# Muscles

- Trophicity
- Tonus
- Cramps
- Power

# Muscle test

0 - no activity	0 %
1 - trace	10 %
2 - motion without gravity	25 %
3 - motion against gravity	50 %
4 - motion against gravity and slight resistance	75 %
5 - normal activity	100 %

# Posture




Correct

Wrong



# Gait

- 1. heel strike
- 2. standing
- 3. toe off
- 4. swing phase



# Limping

- Antalgic gait
- Shortening of a lower extremity
- Ancylosis
- Trendeleburg sign and gait
- Hemiparetic gait
- Spastic gait
- Drop foot gait
- Parkinson gait

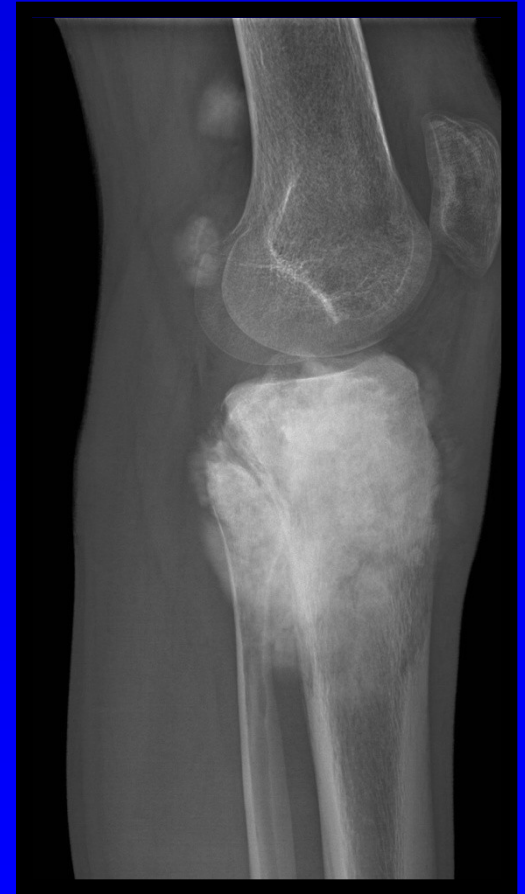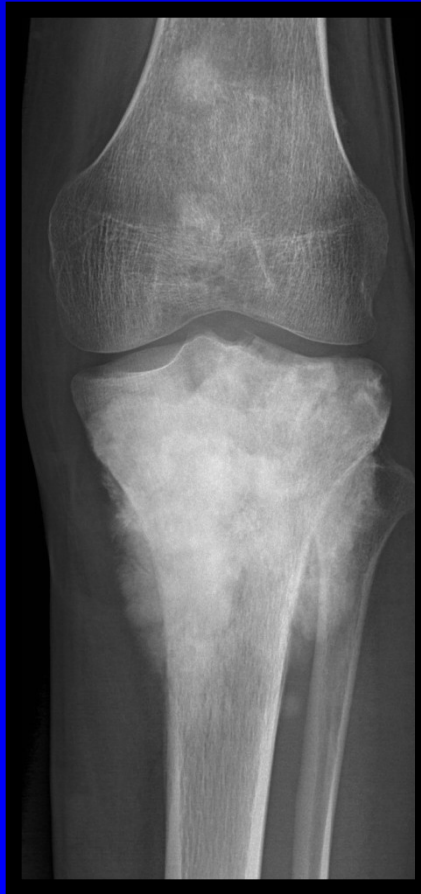# Imaging methods

- X-ray, artrography
- Angiography
- Ultrasonography
- CT, MRI
- Scintigraphy
- DEXA
- Biopsy

# X-ray

In two planes

- bone hypertrophy
- bone atrophy
- osteolysis
- osteonecrosis



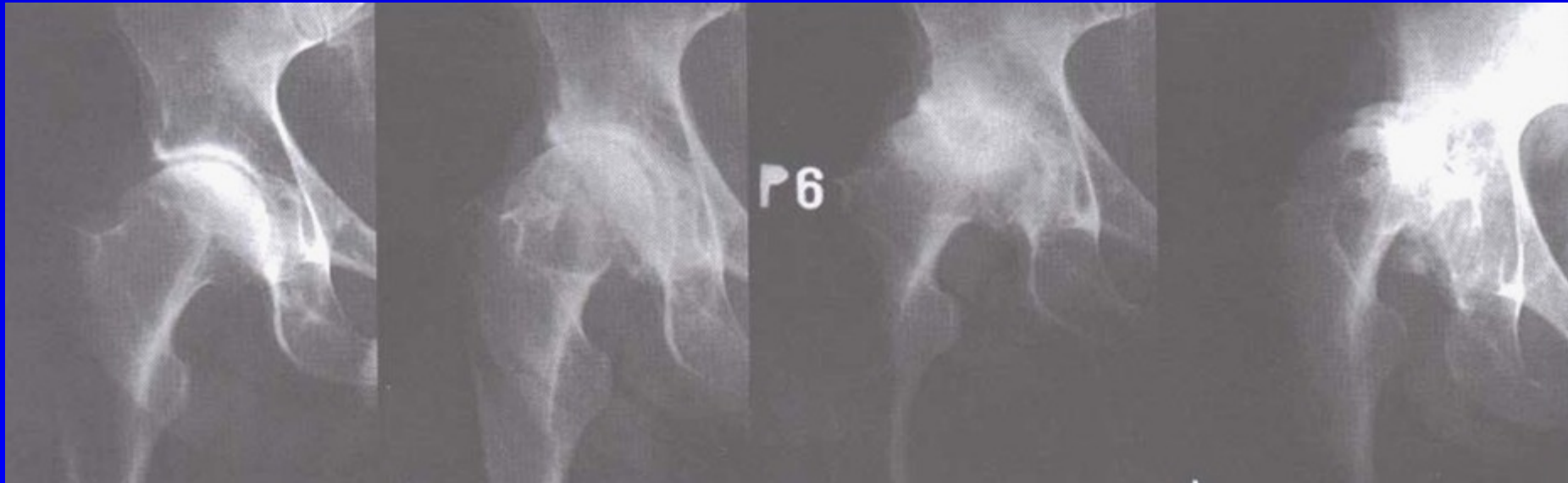# Kellgren- Lawrence clasification of O.A.

I.

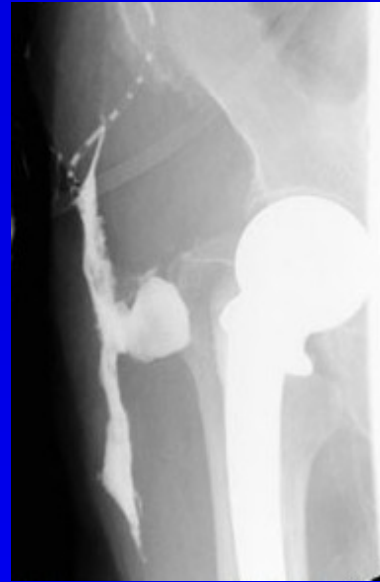
II.

III.

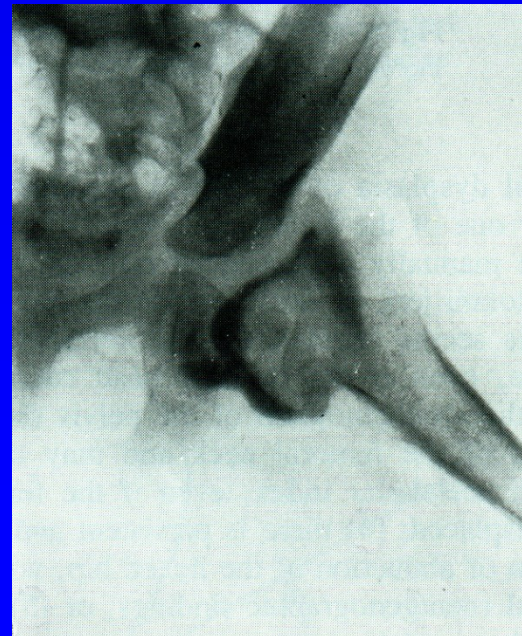IV.



Fistulography



Artrography



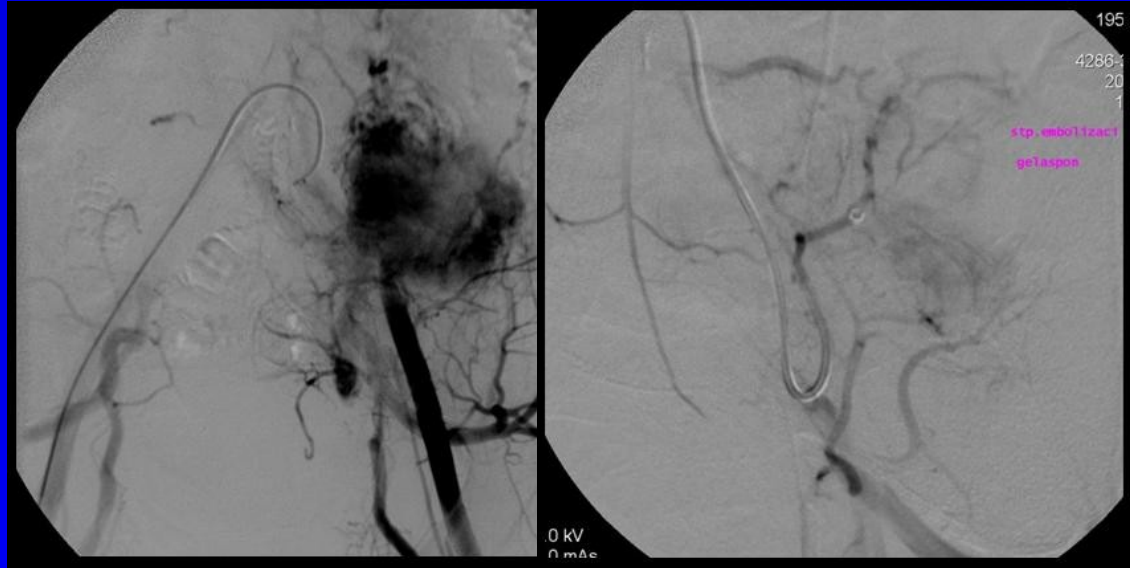
# Angiography

Classical

CT angiography

MR angiography

Digital subtraction angiography



# Ultrasonography

Echogenicity of tissues

Bone, fibrous tissue, muscles, adipous tissue, cartilage, fluid

Anechogenic structure- black

Hypoechogenic structure- grey

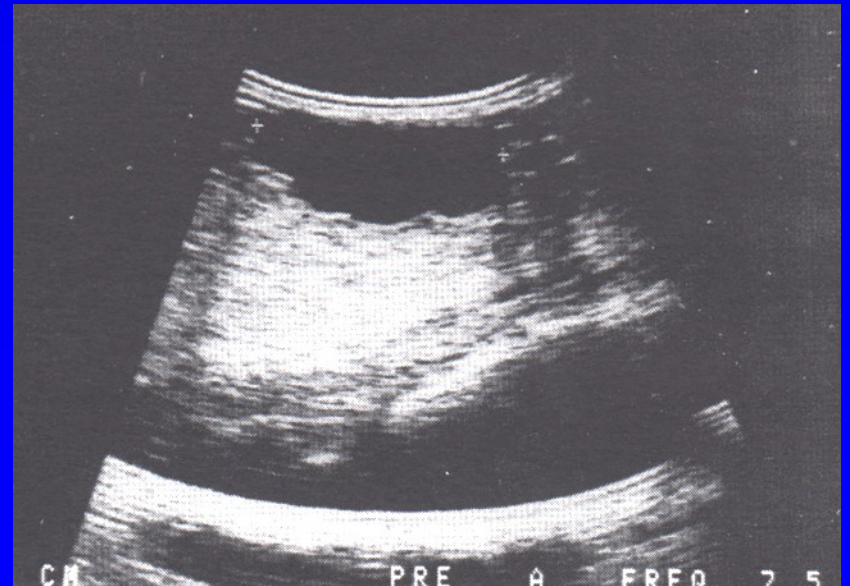
Hyperechogenic structure- white

Soft tissues

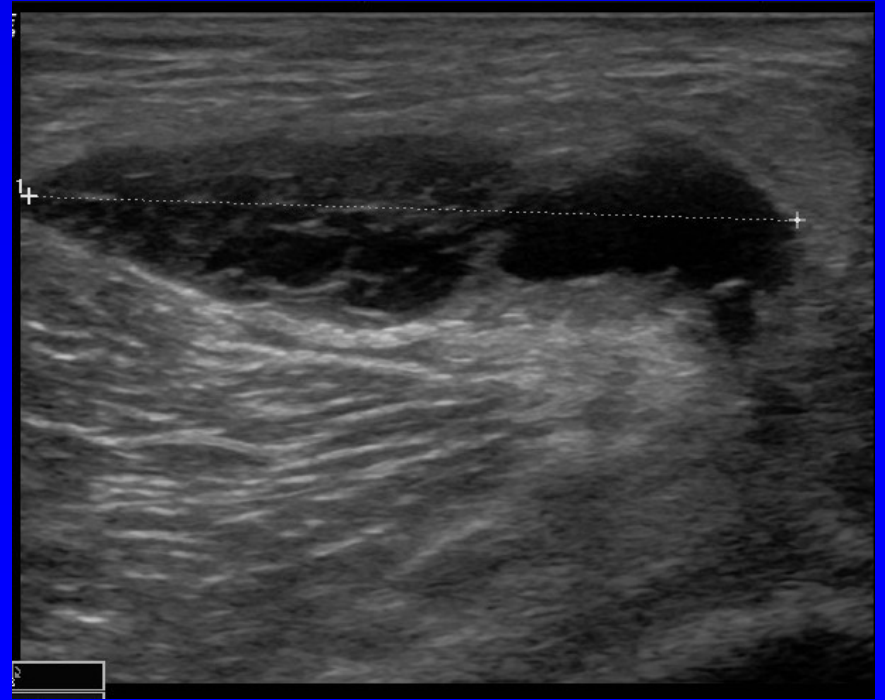
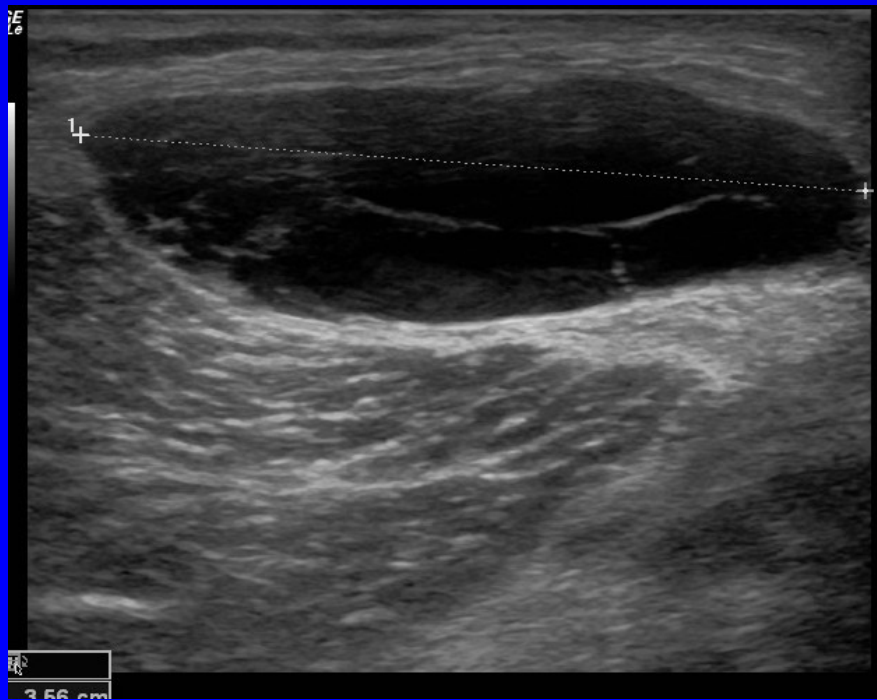
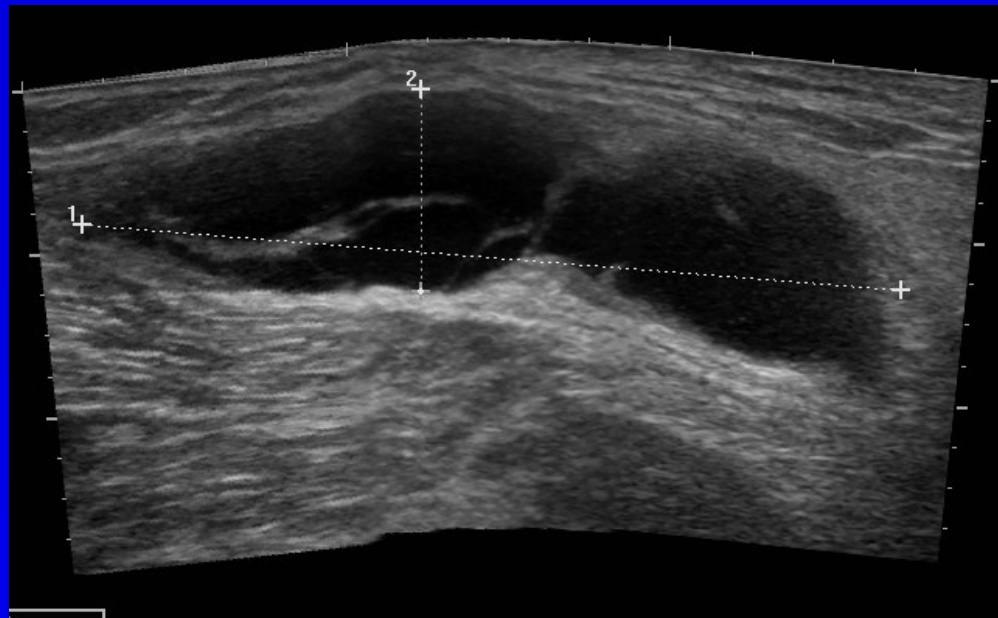
Tumors

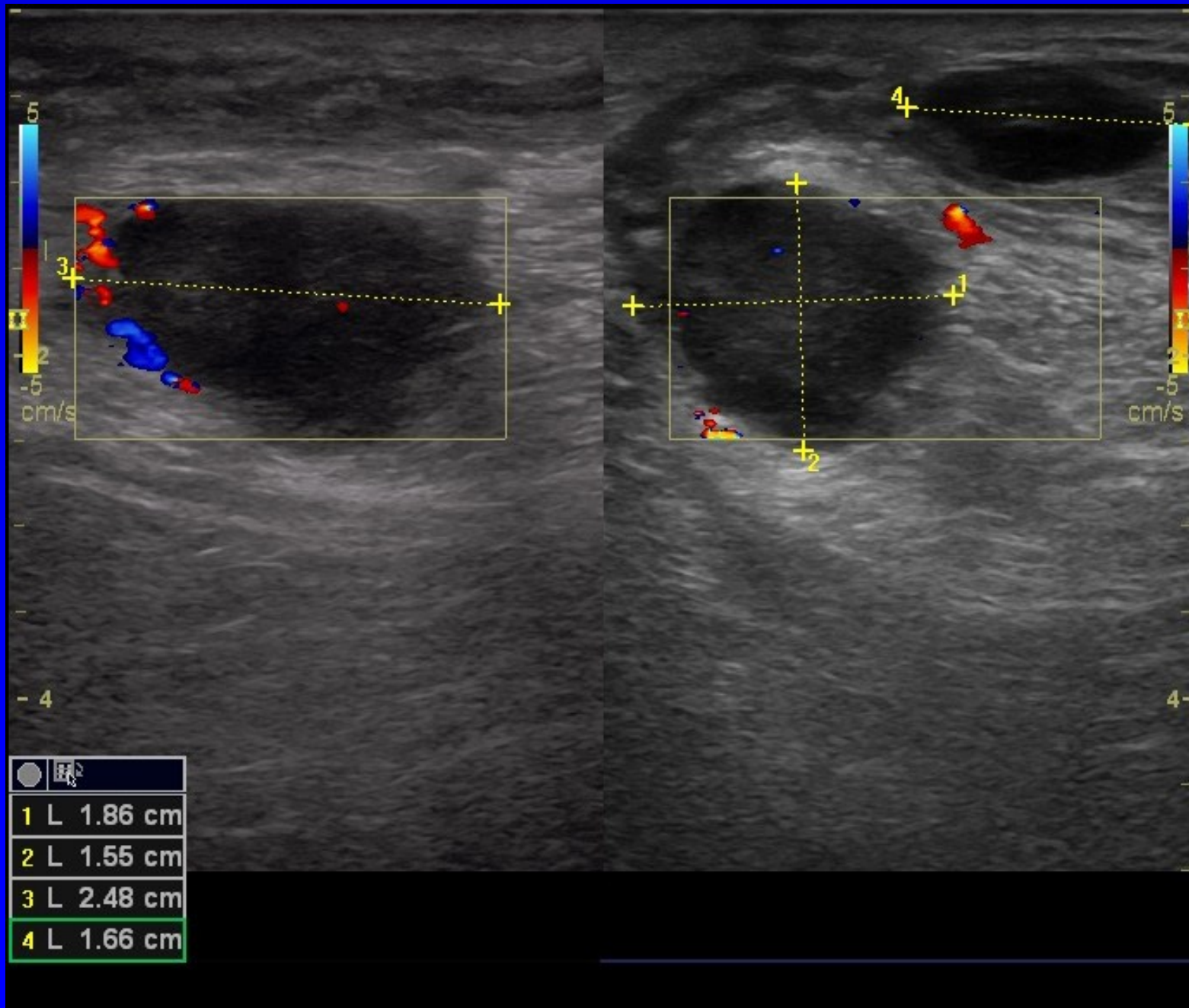
DDH

Effusion in joints









# CT scann

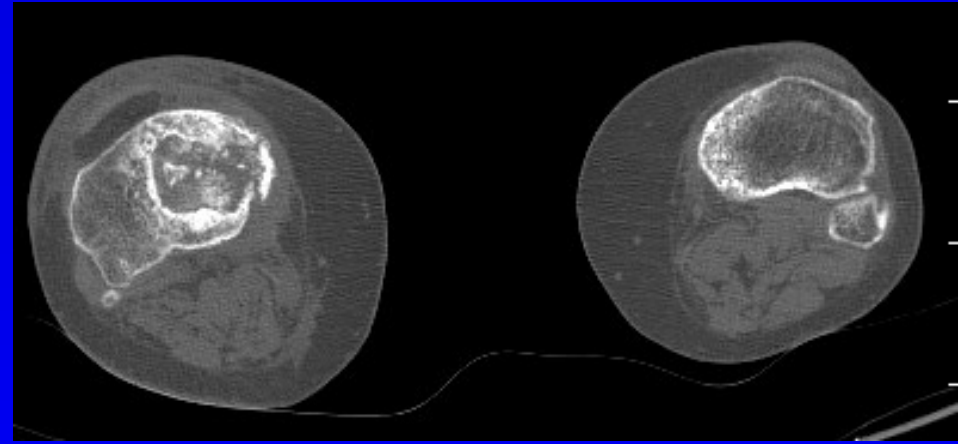
Absorption of X-ray beams

Air – 1000 H.U.

Water 0 H.U.

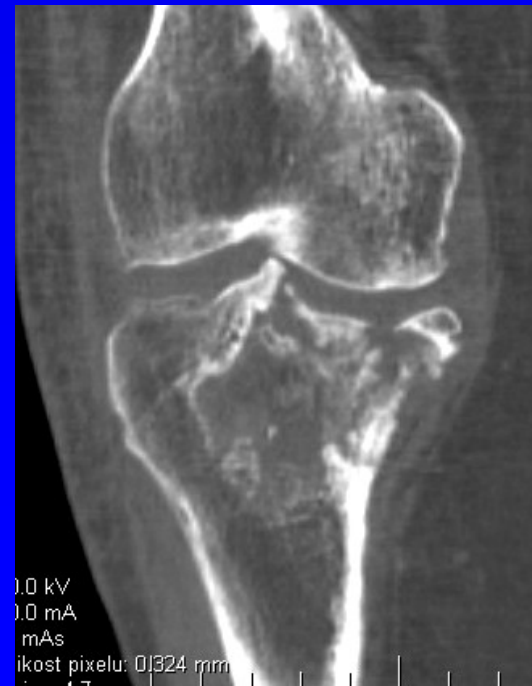Bone + 1000 H.U.

Enhancement with a dye

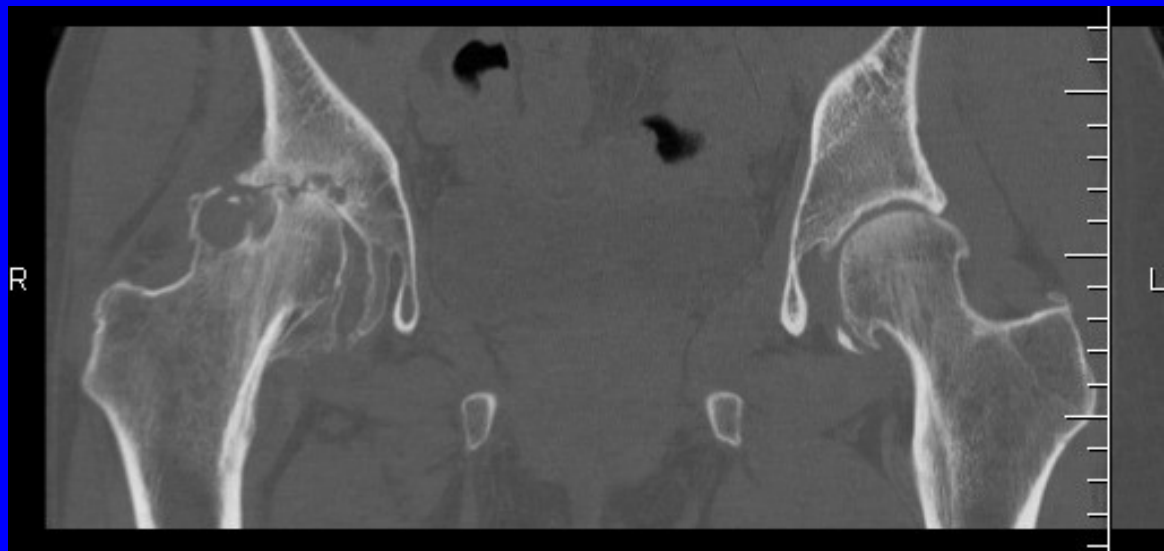
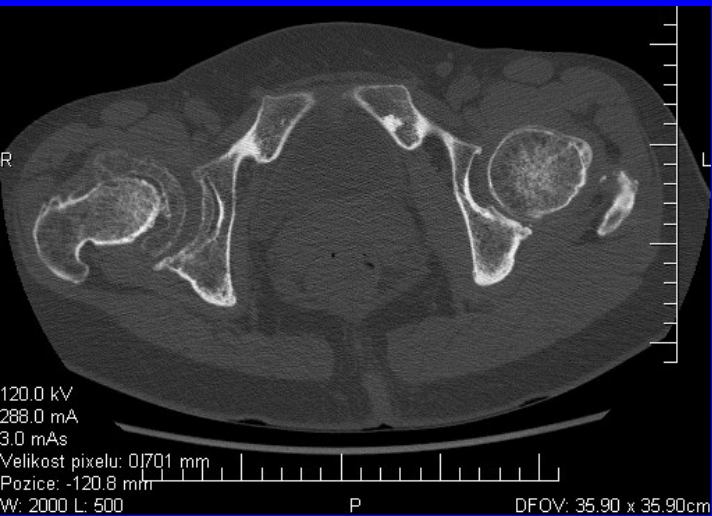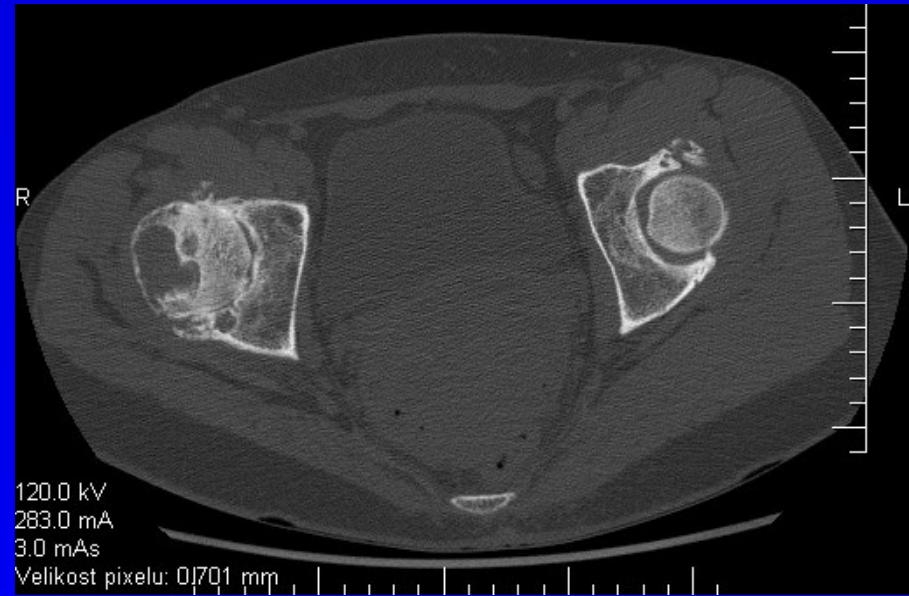
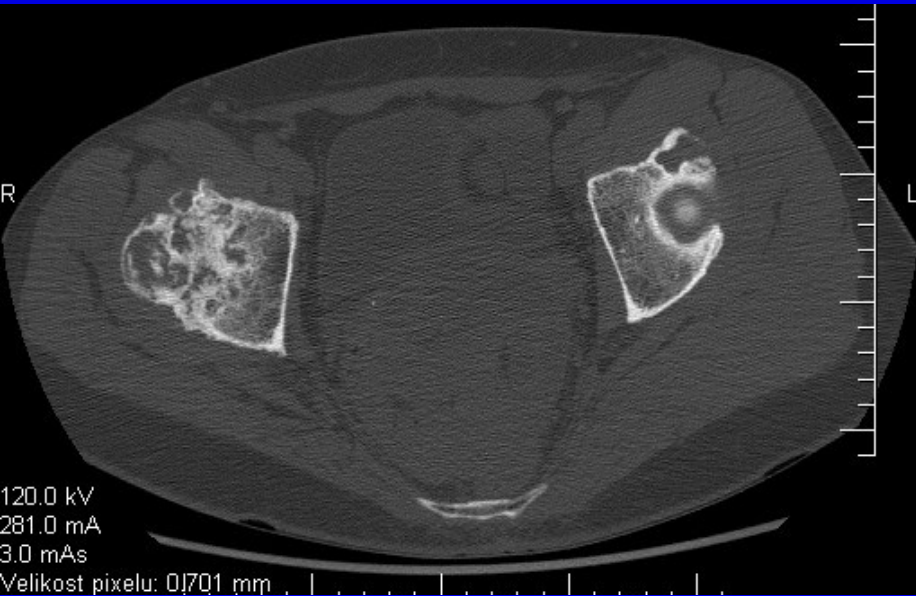


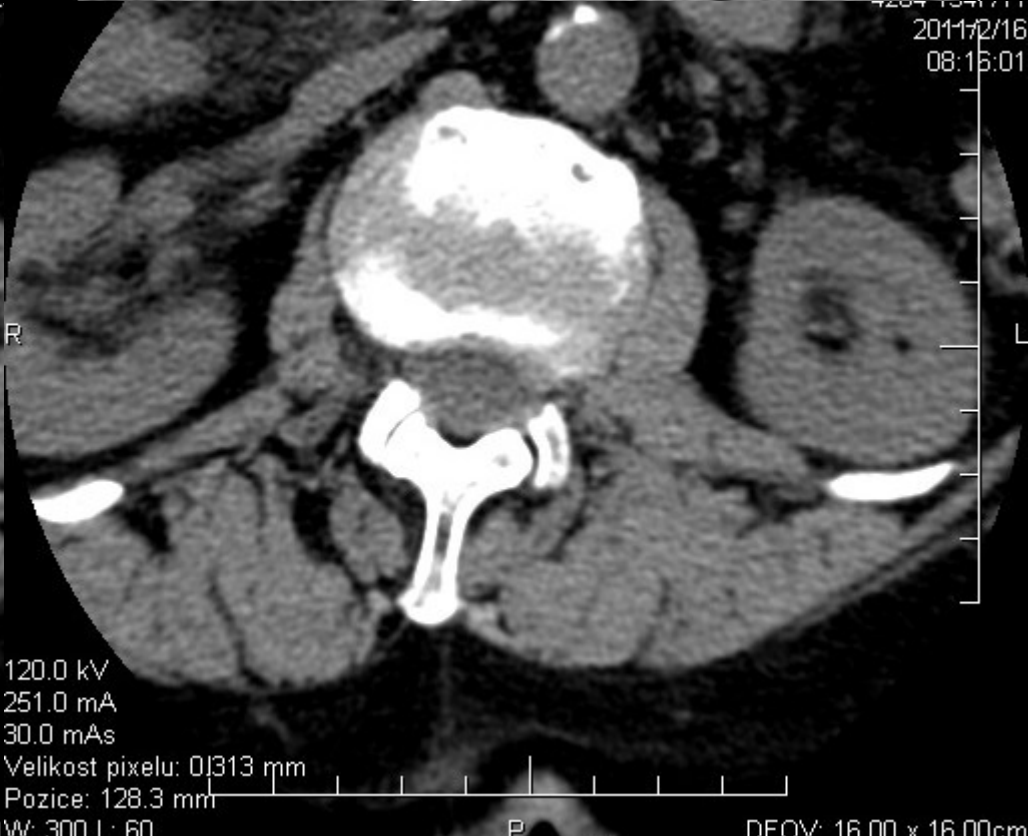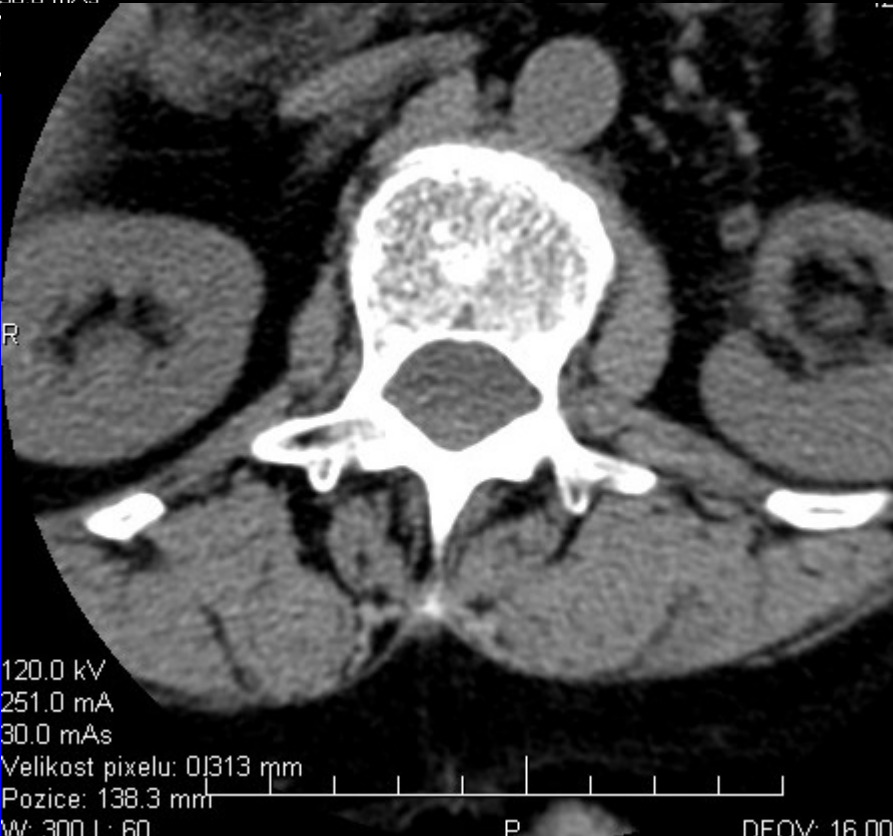
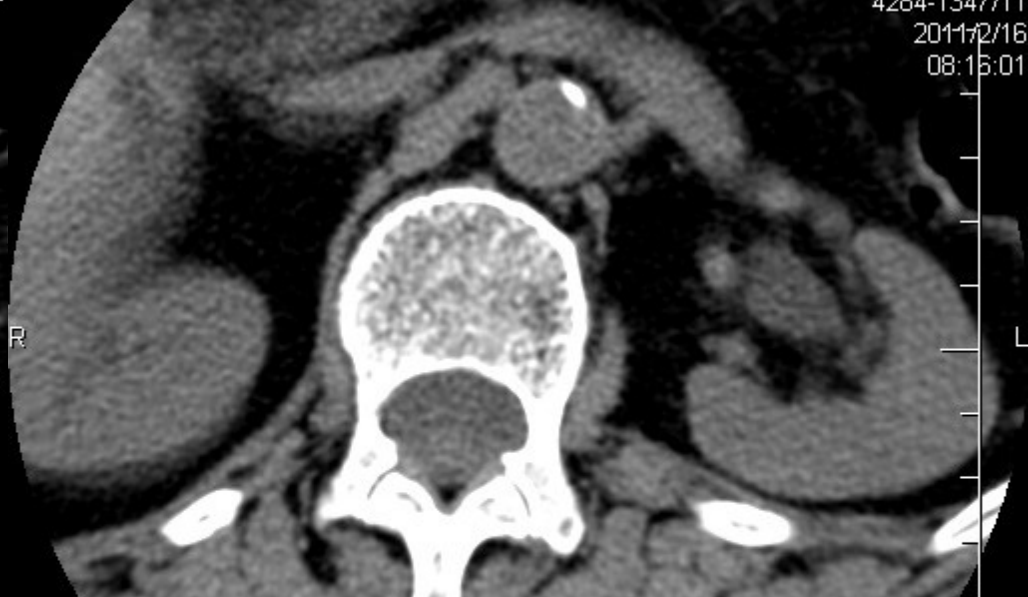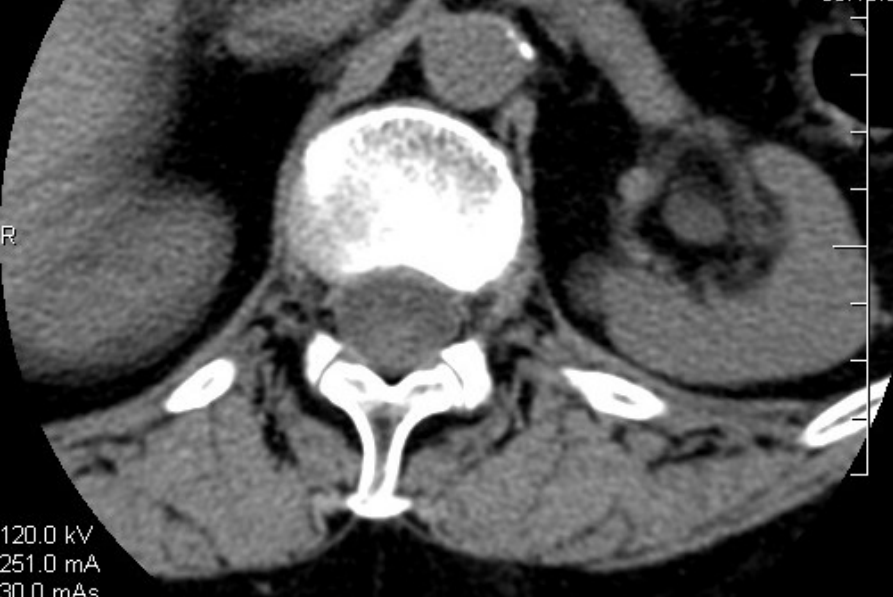Bone lesions

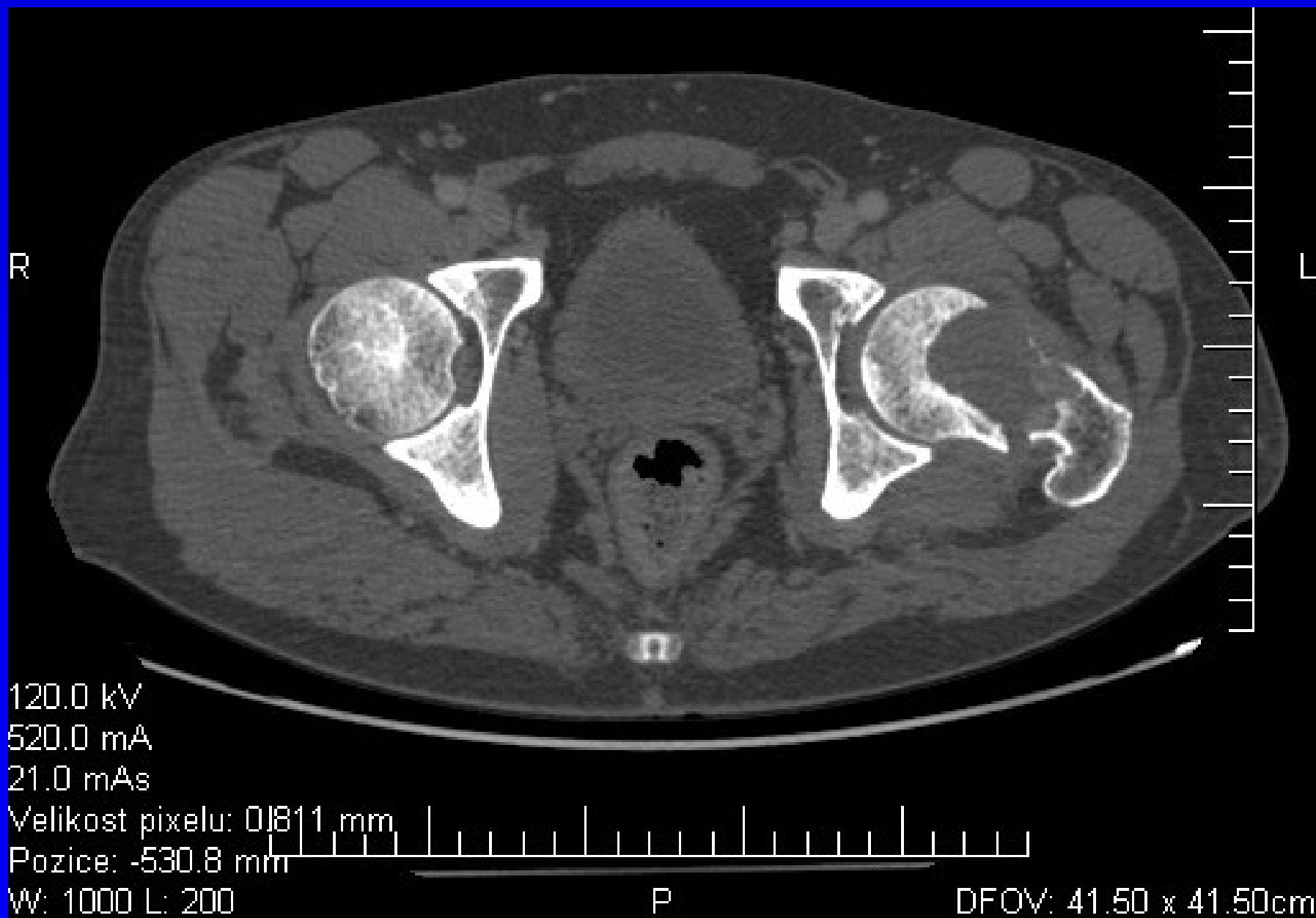Bone tumors



# CT



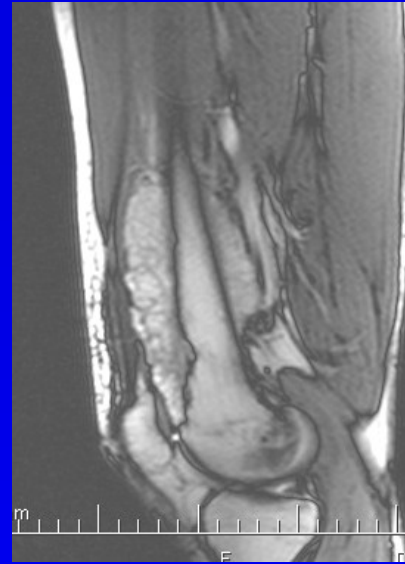




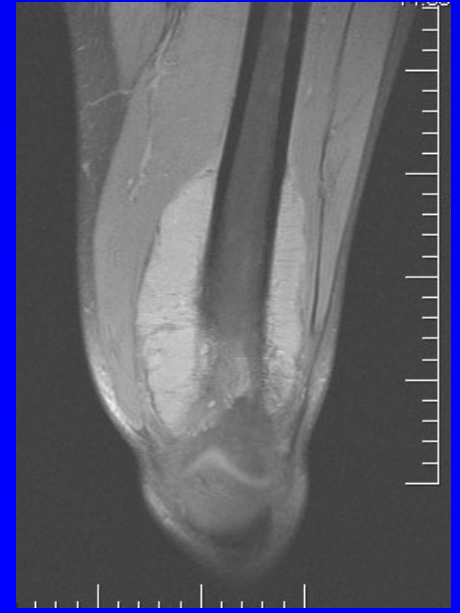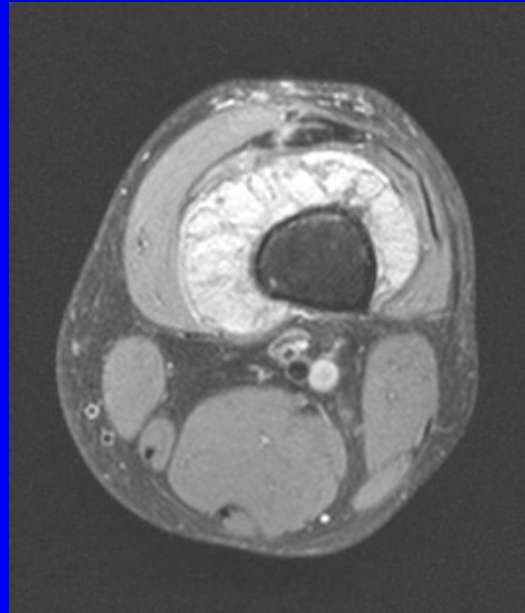
# MRI

Magnetic field

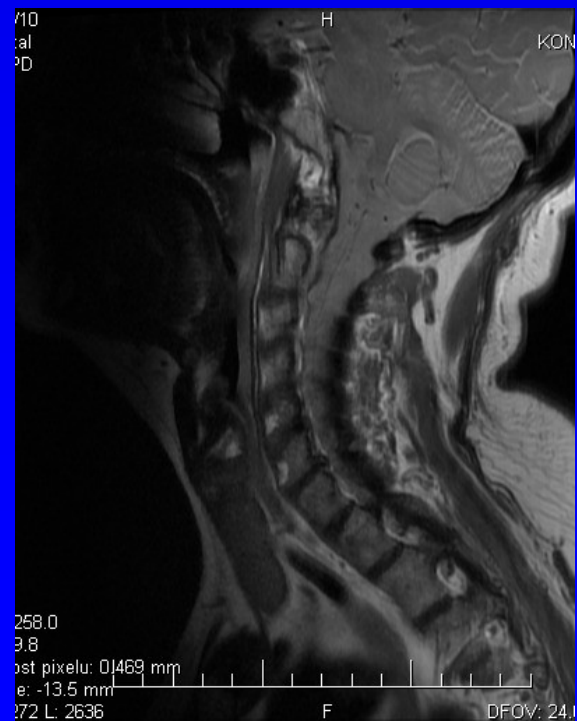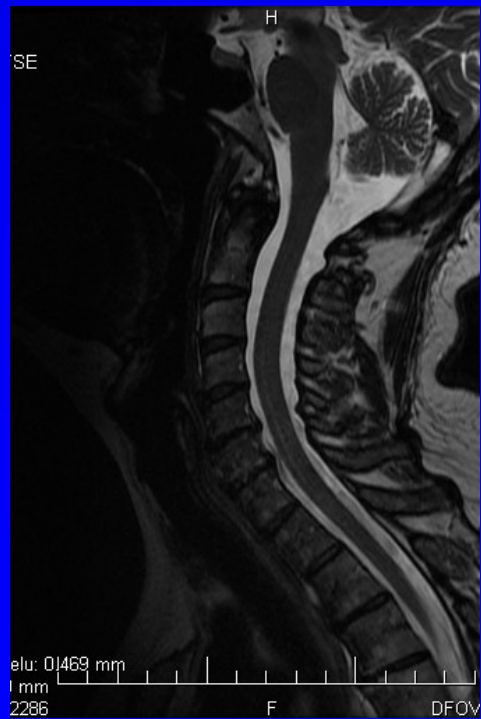
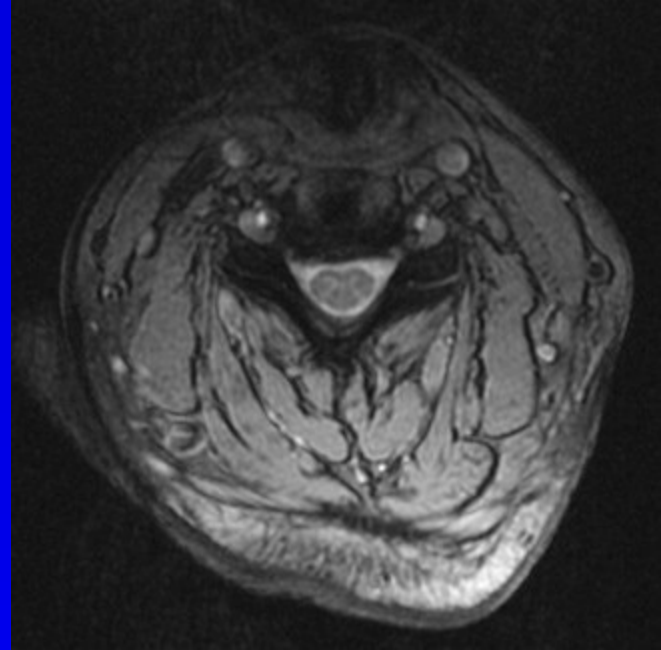
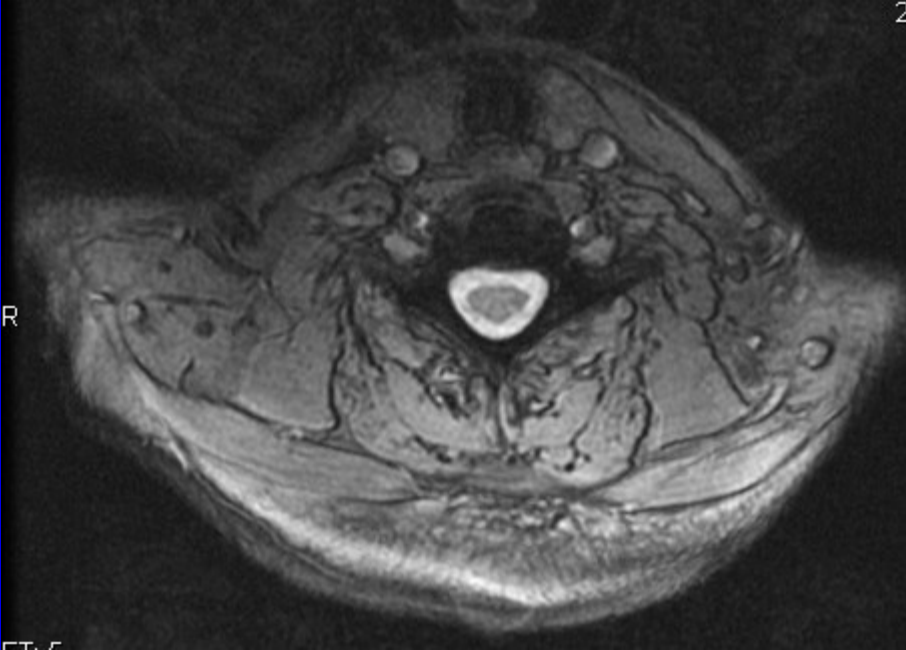
Hyposignal- dark  
Hypersignal - white



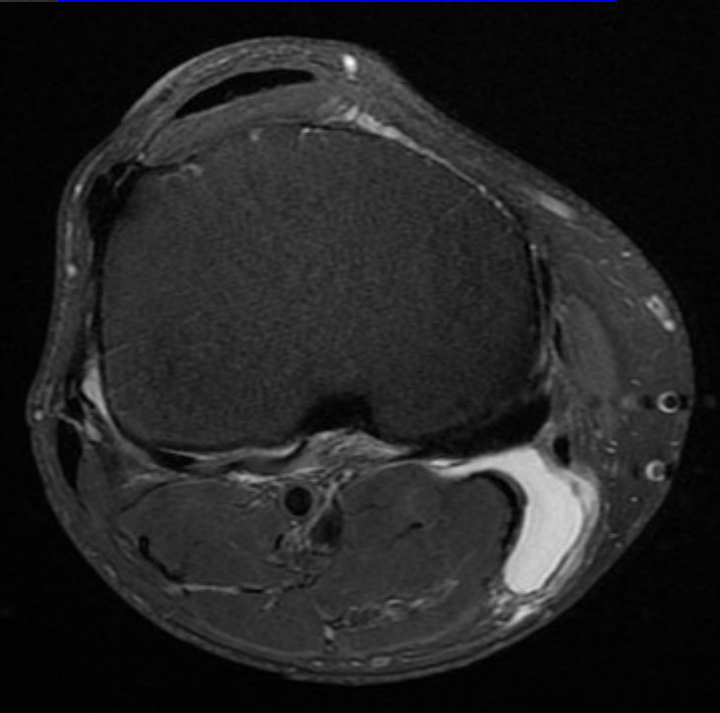
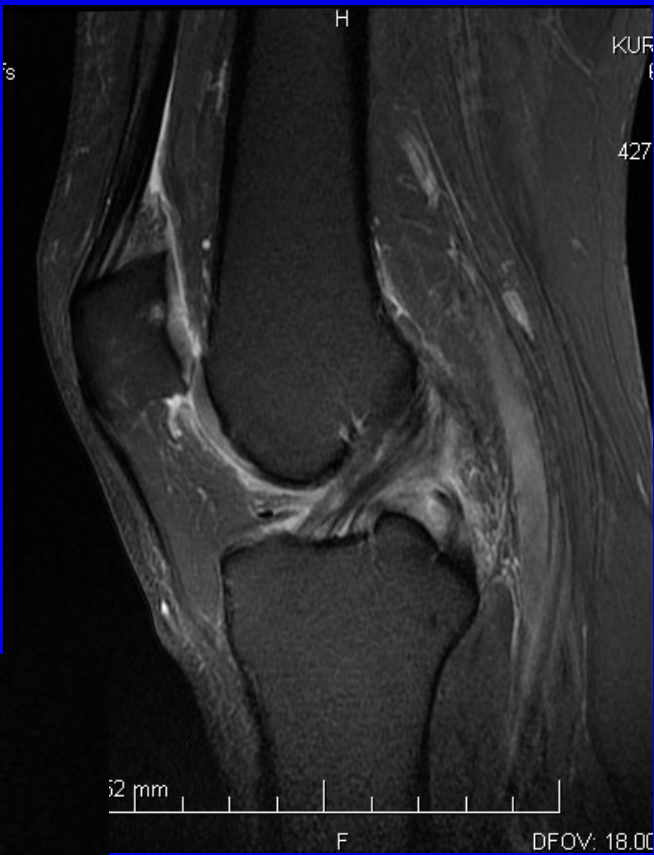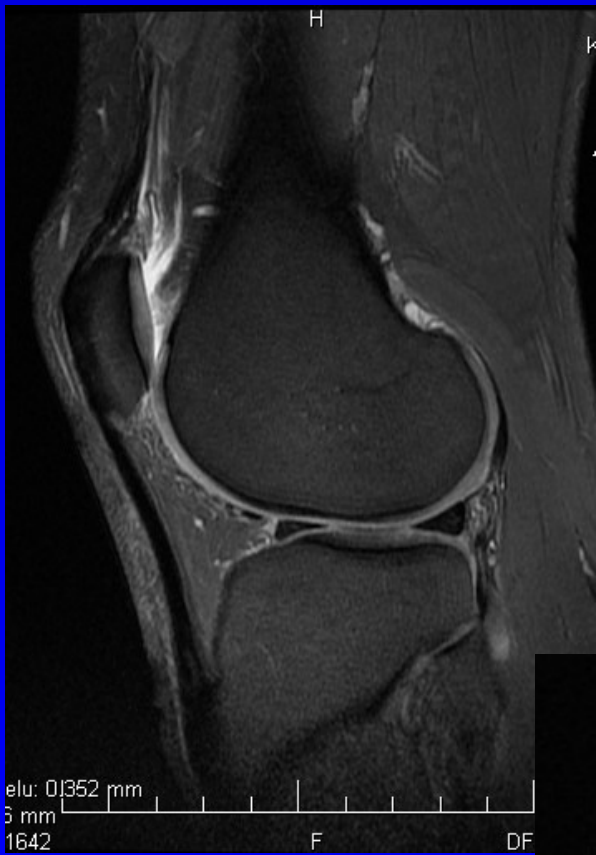Soft tissue tumors  
Soft tissue mass  
Spine

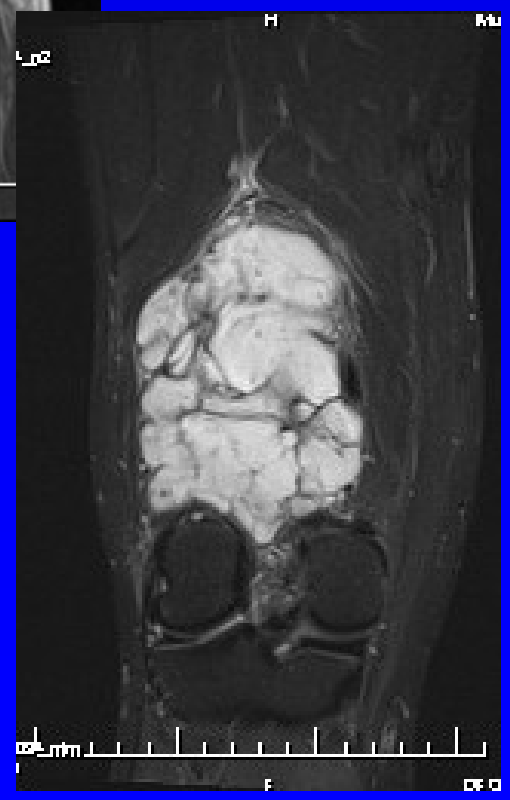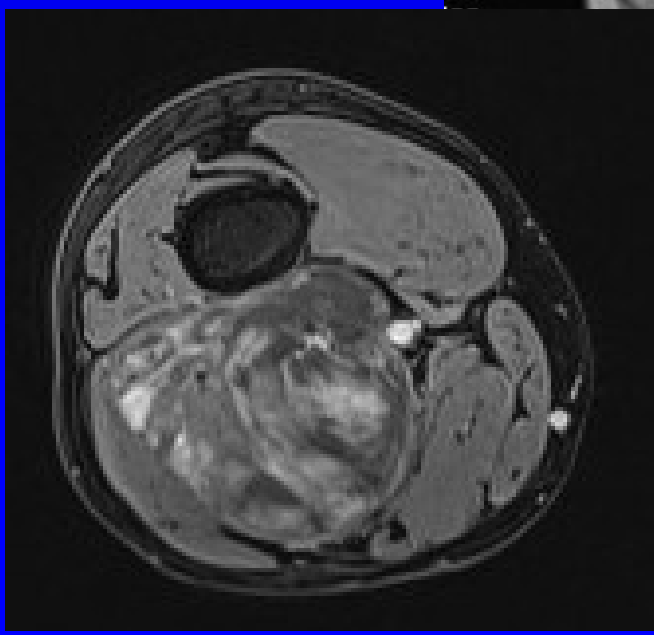

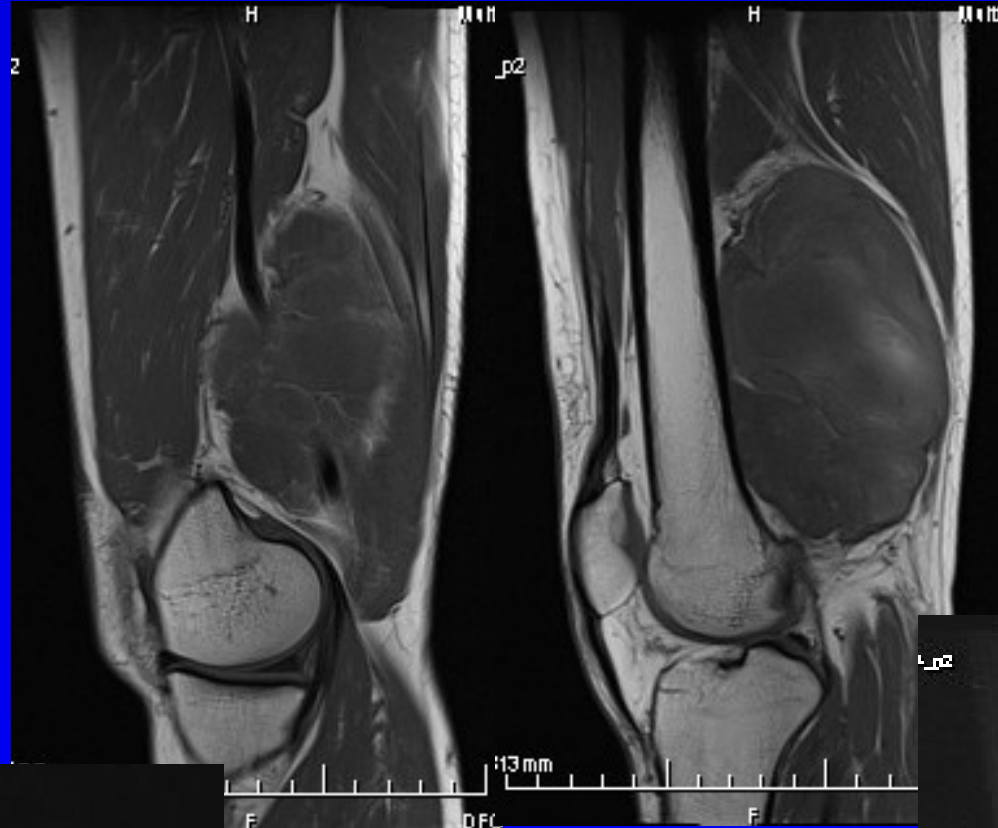
# MRI





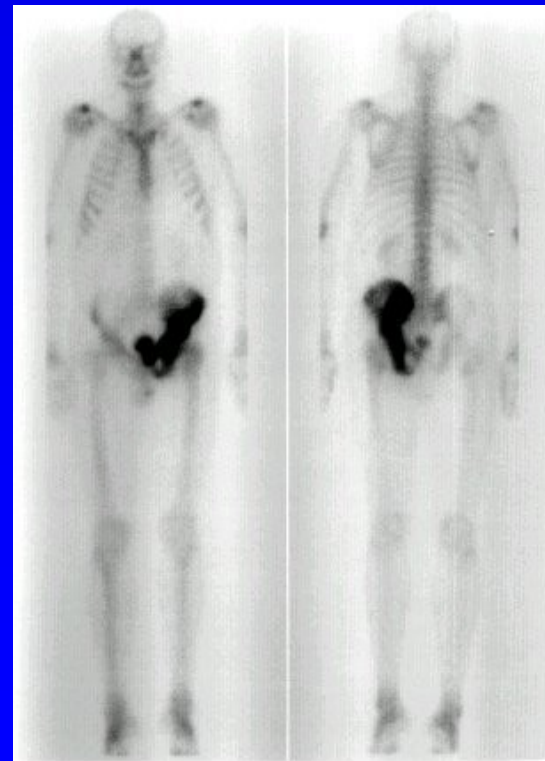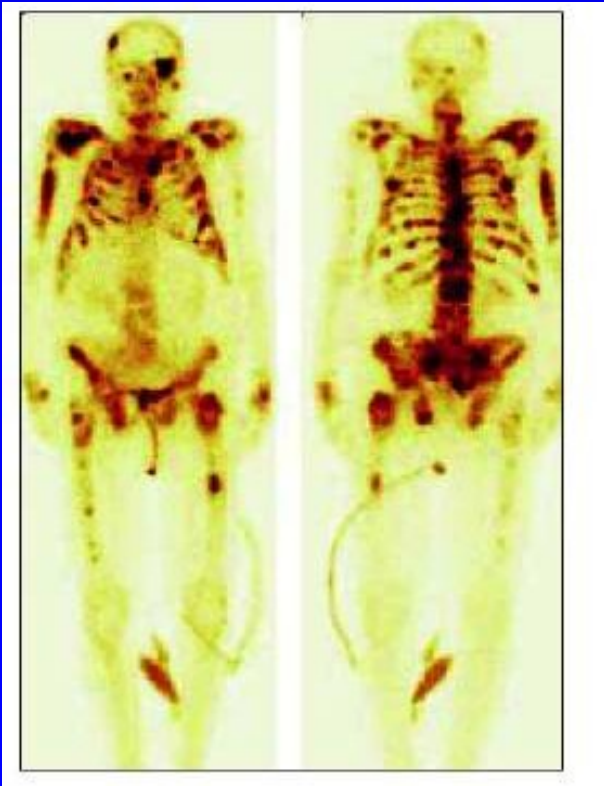




# Scintigraphy

Tc 99

Bone tumors and metastases



# Densitometry DEXA

Absorption of X-ray of two energies (70 and 140 kV)

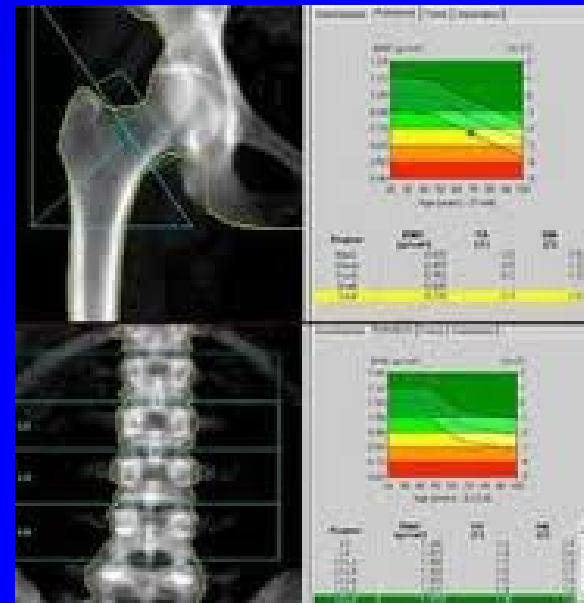
BMD- bone mineral density in  $\text{g}/\text{cm}^2$

T- score - difference from peak bone mass

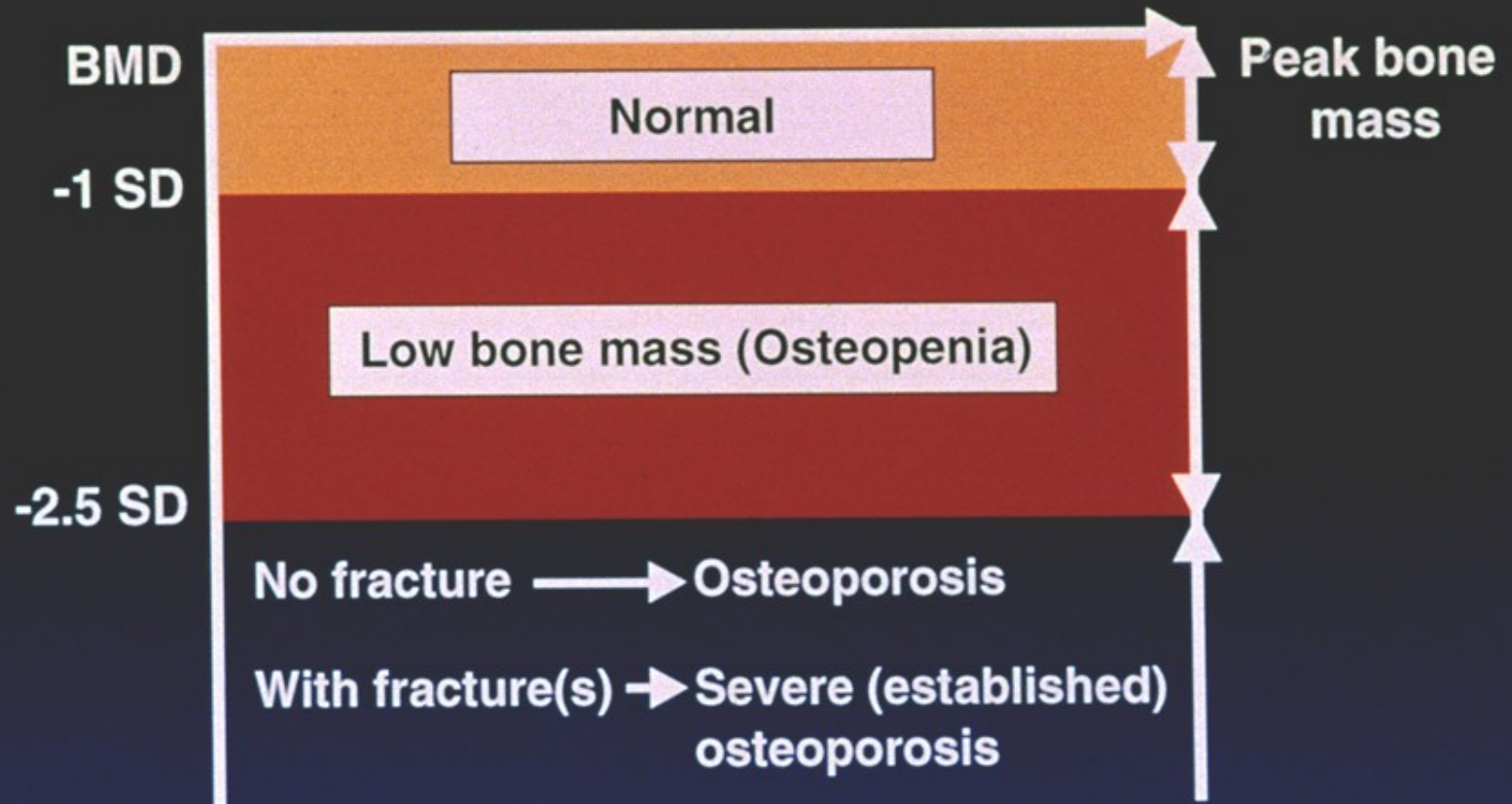
Z- score - difference in the same age

Change - difference from previous examination

1 SD = 10% of bone mass



# WHO definition of osteoporosis

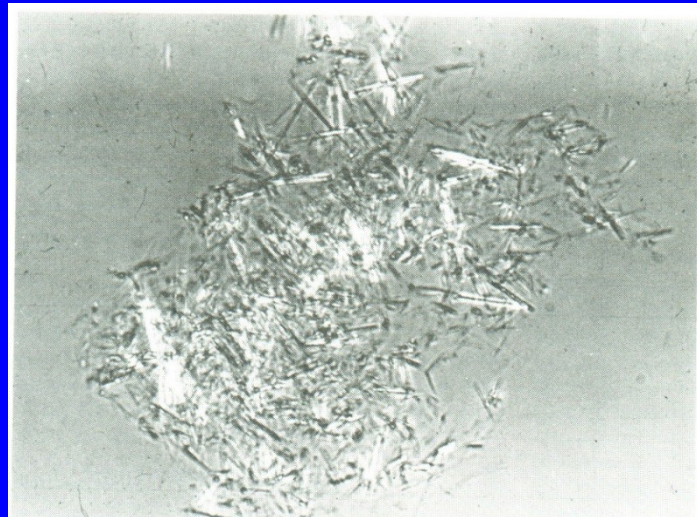



# Laboratory tests

- Inflammation: ESR, leu, CRP, diferencial, ELFO
- Osteopathy: Ca, P, ALP, bone isoenzyme of ALP  
osteocalcin, osteonectin, PTH, vitamin D
- Bone markers- no specific in bones
- PSA in carcinoma of prostate

# Joint effusion

- Microscopic
- Biochemic
- Bacteriologic
- PCR
- Immunologic
- Cytologic



# Biopsy

Histological examination

Biopsy – open  
needle  
CT, ultrasonography

